

**Injuries and diseases of the jaws : the Jacksonian prize essay of the Royal College of Surgeons of England, 1867 / by Christopher Heath.**

**Contributors**

Heath, Christopher, 1835-1905.  
Augustus Long Health Sciences Library

**Publication/Creation**

Philadelphia : P. Blakiston, Son & Co., 1884.

**Persistent URL**

<https://wellcomecollection.org/works/jkuhmt48>

**License and attribution**

This material has been provided by This material has been provided by the Augustus C. Long Health Sciences Library at Columbia University and Columbia University Libraries/Information Services, through the Medical Heritage Library. The original may be consulted at the the Augustus C. Long Health Sciences Library at Columbia University and Columbia University. where the originals may be consulted.

This work has been identified as being free of known restrictions under copyright law, including all related and neighbouring rights and is being made available under the Creative Commons, Public Domain Mark.

You can copy, modify, distribute and perform the work, even for commercial purposes, without asking permission.



Wellcome Collection  
183 Euston Road  
London NW1 2BE UK  
T +44 (0)20 7611 8722  
E [library@wellcomecollection.org](mailto:library@wellcomecollection.org)  
<https://wellcomecollection.org>

COLUMBIA LIBRARIES OFFSITE  
HEALTH SCIENCES STANDARD



HX00036510



RD 526

H35

Columbia University  
in the City of New York

1884

School of Dental and Oral Surgery



Reference Library





Digitized by the Internet Archive  
in 2010 with funding from  
Open Knowledge Commons

INJURIES AND DISEASES

OF

THE JAWS



*BY THE SAME AUTHOR.*

---

**A Course of Operative Surgery.** With 20 Plates drawn from Nature, by M. LÉVEILLÉ, Coloured. Second Edition, large 8vo, 30s.

**Practical Anatomy :** A Manual of Dissections. With 24 Coloured Plates and 269 Wood Engravings. Fifth Edition, 8vo, 15s.

**A Manual of Minor Surgery and Bandaging,** for the Use of House-Surgeons, Dressers, and Junior Practitioners. With 129 Engravings. Seventh Edition. 8vo, 6s.

**The Student's Guide to Surgical Diagnosis.** Second Edition. 8vo, 6s. 6d.





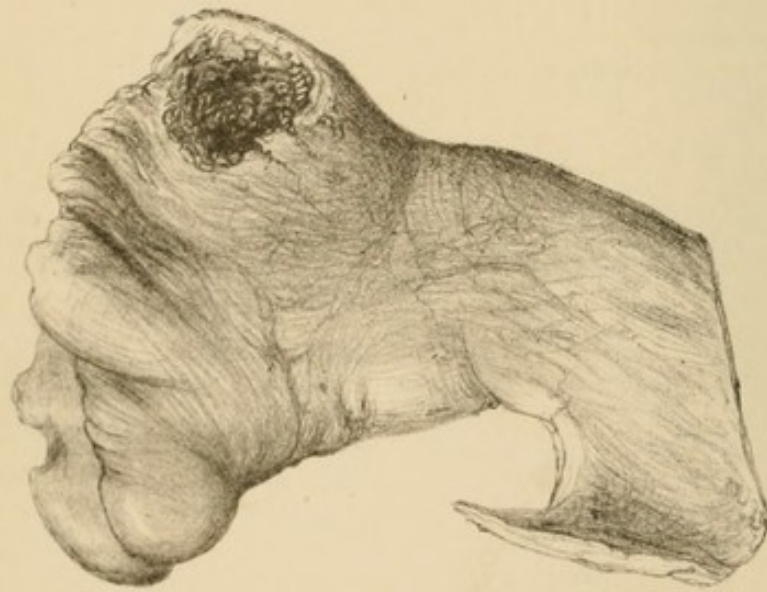


Fig 1

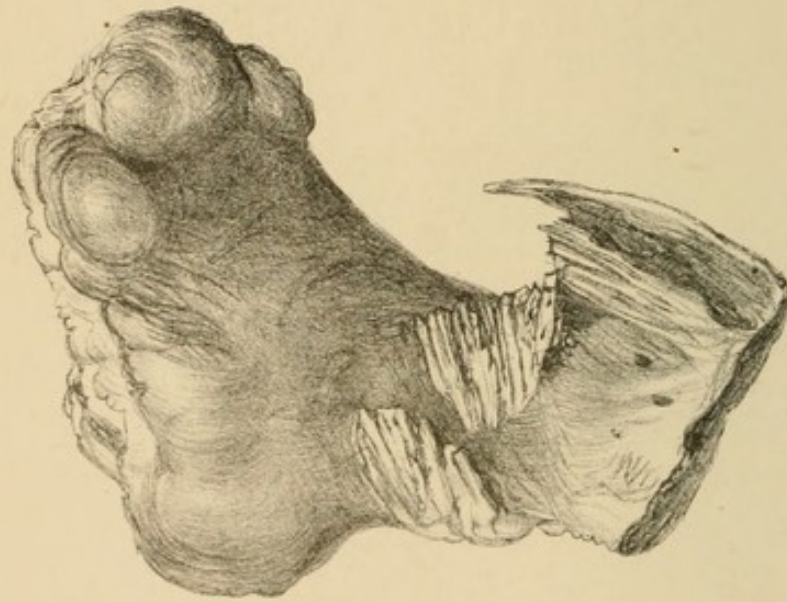


Fig 2

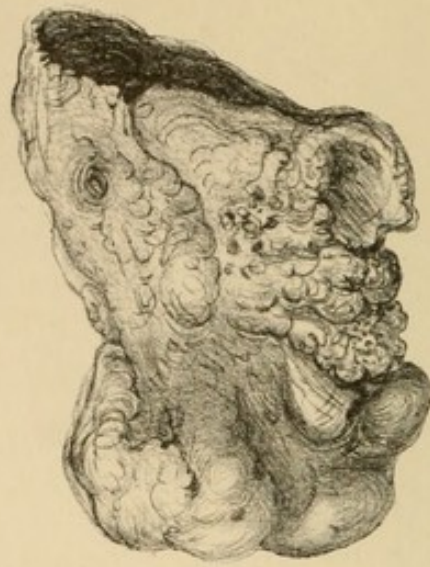


Fig 3

# INJURIES AND DISEASES

OF

## THE JAWS:

THE JACKSONIAN PRIZE ESSAY OF THE ROYAL COLLEGE OF  
SURGEONS OF ENGLAND, 1867.

BY

CHRISTOPHER HEATH, F.R.C.S.,

HOLME PROFESSOR OF CLINICAL SURGERY IN UNIVERSITY COLLEGE, LONDON, AND SURGEON  
TO UNIVERSITY COLLEGE HOSPITAL;  
CONSULTING SURGEON TO THE DENTAL HOSPITAL.

*THIRD EDITION.*

PHILADELPHIA:  
P. BLAKISTON, SON & CO.,  
1012, WALNUT STREET.  
1884.



RD 526

H35

1884

P R E F A C E  
TO  
T H E   T H I R D   E D I T I O N .

---

IN the twelve years which have elapsed since the publication of the second edition of this book, I have been able to add considerably to my personal experience of the subjects included within it. This has led in some instances to a modification of the views previously expressed, and especially with regard to the pathology and treatment of multilocular cysts of the lower jaw. In connection with this subject, I have particularly to mention the microscopic investigations of Mr. Frederick Eve, to whose labours I am much indebted; and also to thank Mr. Rushton Parker, of Liverpool, for his assistance in classifying the tumours of the jaw according to modern pathological research. A chapter on the Diseases of the Temporo-maxillary Articulation has been added. To the successive Surgical Registrars of University College Hospital, Messrs. Beck, Godlee, Gould, Pepper, Burton, Silcock, Boyd and Horsley, my very best thanks are given for the careful records of my hospital cases, and the microscopic examination of numerous specimens of disease.

CHRISTOPHER HEATH,

36, CAVENDISH SQUARE,  
*February, 1884.*



P R E F A C E  
TO  
T H E F I R S T E D I T I O N .

---

“THE Injuries and Diseases of the Jaws, including those of the Antrum, with the treatment by operation or otherwise,” having been announced as the subject for the Jacksonian Prize of 1867, I prepared an essay upon the subject, to which I had for some years devoted considerable attention; and having been successful, I have printed it with but slight alterations. My very best thanks are due to those gentlemen who, by generously placing valuable preparations of disease at my disposal, enabled me to study the pathology of the subject more successfully than I could otherwise have done, and also to those who have kindly given me notes of interesting cases under their charge, or have lent me valuable illustrations, of which due acknowledgment has been made in each instance. I venture to hope that the information thus brought together may be of service to those under whose care similar cases may be placed.

CHRISTOPHER HEATH.

*September, 1868.*

# TABLE OF CONTENTS.

| CHAP.   | PAGES   |
|---|---------|
| I. FRACTURE OF THE LOWER JAW . . . . .                                | 1—14    |
| II. COMPLICATIONS OF FRACTURE OF LOWER JAW . . .                      | 15—32   |
| III. TREATMENT OF FRACTURED LOWER JAW . . . . .                       | 33—55   |
| IV. FRACTURES OF THE UPPER JAW . . . . .                              | 56—65   |
| V. GUNSHOT INJURIES OF THE JAWS . † . . . .                           | 66—82   |
| VI. DISLOCATION OF THE JAW . . . . .                                  | 83—97   |
| VII. INFLAMMATION, ABSCESS, PERIOSTITIS . . . . .                     | 98—109  |
| VIII. NECROSIS OF THE JAWS . . . . .                                  | 110—126 |
| IX. REPAIR AFTER NECROSIS; TREATMENT . . . . .                        | 127—141 |
| X. HYPEROSTOSIS . . . . .   | 142—151 |
| XI. DISEASES OF THE ANTRUM . . . . .                                  | 152—177 |
| XII. CYSTS OF TEETH; DENTIGEROUS CYSTS . . . . .                      | 178—195 |
| XIII. CYSTS OF LOWER JAW AND MULTIFOCULAR CYSTIC<br>TUMOUR . . . . .  | 196—213 |
| XIV. TUMOURS CONNECTED WITH TEETH AND ODONTOMATA                      | 214—226 |
| XV. DISEASES OF THE GUMS—EPULIS . . . . .                             | 227—247 |
| XVI. TUMOURS OF THE PALATE . . . . .                                  | 248—253 |
| XVII. EPITHELIOMA OF THE GUMS AND ANTRUM . . . .                      | 254—259 |
| XVIII. NON-MALIGNANT TUMOURS OF THE UPPER JAW . .                     | 260—286 |
| XIX. SARCOMATOUS                    "                   "             | 287—301 |
| XX. MALIGNANT                        "                   "            | 302—313 |
| XXI. DIAGNOSIS AND TREATMENT OF TUMOURS OF THE<br>UPPER JAW . . . . . | 314—326 |
| XXII. NON-MALIGNANT TUMOURS OF THE LOWER JAW . .                      | 327—343 |
| XXIII. SARCOMATOUS                   "                   "            | 344—368 |
| XXIV. MALIGNANT                     "                   "             | 369—378 |
| XXV. DIAGNOSIS AND TREATMENT OF TUMOURS OF THE<br>LOWER JAW . . . . . | 379—387 |
| XXVI. CLOSURE OF THE JAWS . . . . .                                   | 388—411 |
| XXVII. DISEASES OF THE TEMPORO-MAXILLARY ARTICULATION                 | 412—427 |
| XXVIII. DEFORMITIES OF THE JAWS . . . . .                             | 428—433 |
| APPENDIX OF CASES . . . . .   | 434—472 |

# TABLE OF CONTENTS

|                     |      |
|---------------------|------|
| Introduction        | 1    |
| Chapter I           | 10   |
| Chapter II          | 25   |
| Chapter III         | 40   |
| Chapter IV          | 55   |
| Chapter V           | 70   |
| Chapter VI          | 85   |
| Chapter VII         | 100  |
| Chapter VIII        | 115  |
| Chapter IX          | 130  |
| Chapter X           | 145  |
| Chapter XI          | 160  |
| Chapter XII         | 175  |
| Chapter XIII        | 190  |
| Chapter XIV         | 205  |
| Chapter XV          | 220  |
| Chapter XVI         | 235  |
| Chapter XVII        | 250  |
| Chapter XVIII       | 265  |
| Chapter XIX         | 280  |
| Chapter XX          | 295  |
| Chapter XXI         | 310  |
| Chapter XXII        | 325  |
| Chapter XXIII       | 340  |
| Chapter XXIV        | 355  |
| Chapter XXV         | 370  |
| Chapter XXVI        | 385  |
| Chapter XXVII       | 400  |
| Chapter XXVIII      | 415  |
| Chapter XXIX        | 430  |
| Chapter XXX         | 445  |
| Chapter XXXI        | 460  |
| Chapter XXXII       | 475  |
| Chapter XXXIII      | 490  |
| Chapter XXXIV       | 505  |
| Chapter XXXV        | 520  |
| Chapter XXXVI       | 535  |
| Chapter XXXVII      | 550  |
| Chapter XXXVIII     | 565  |
| Chapter XXXIX       | 580  |
| Chapter XL          | 595  |
| Chapter XLI         | 610  |
| Chapter XLII        | 625  |
| Chapter XLIII       | 640  |
| Chapter XLIV        | 655  |
| Chapter XLV         | 670  |
| Chapter XLVI        | 685  |
| Chapter XLVII       | 700  |
| Chapter XLVIII      | 715  |
| Chapter XLIX        | 730  |
| Chapter L           | 745  |
| Chapter LI          | 760  |
| Chapter LII         | 775  |
| Chapter LIII        | 790  |
| Chapter LIV         | 805  |
| Chapter LV          | 820  |
| Chapter LVI         | 835  |
| Chapter LVII        | 850  |
| Chapter LVIII       | 865  |
| Chapter LIX         | 880  |
| Chapter LX          | 895  |
| Chapter LXI         | 910  |
| Chapter LXII        | 925  |
| Chapter LXIII       | 940  |
| Chapter LXIV        | 955  |
| Chapter LXV         | 970  |
| Chapter LXVI        | 985  |
| Chapter LXVII       | 1000 |
| Chapter LXVIII      | 1015 |
| Chapter LXIX        | 1030 |
| Chapter LXX         | 1045 |
| Chapter LXXI        | 1060 |
| Chapter LXXII       | 1075 |
| Chapter LXXIII      | 1090 |
| Chapter LXXIV       | 1105 |
| Chapter LXXV        | 1120 |
| Chapter LXXVI       | 1135 |
| Chapter LXXVII      | 1150 |
| Chapter LXXVIII     | 1165 |
| Chapter LXXIX       | 1180 |
| Chapter LXXX        | 1195 |
| Chapter LXXXI       | 1210 |
| Chapter LXXXII      | 1225 |
| Chapter LXXXIII     | 1240 |
| Chapter LXXXIV      | 1255 |
| Chapter LXXXV       | 1270 |
| Chapter LXXXVI      | 1285 |
| Chapter LXXXVII     | 1300 |
| Chapter LXXXVIII    | 1315 |
| Chapter LXXXIX      | 1330 |
| Chapter LXXXX       | 1345 |
| Chapter LXXXXI      | 1360 |
| Chapter LXXXXII     | 1375 |
| Chapter LXXXXIII    | 1390 |
| Chapter LXXXXIV     | 1405 |
| Chapter LXXXXV      | 1420 |
| Chapter LXXXXVI     | 1435 |
| Chapter LXXXXVII    | 1450 |
| Chapter LXXXXVIII   | 1465 |
| Chapter LXXXXIX     | 1480 |
| Chapter LXXXXX      | 1495 |
| Chapter LXXXXXI     | 1510 |
| Chapter LXXXXXII    | 1525 |
| Chapter LXXXXXIII   | 1540 |
| Chapter LXXXXXIV    | 1555 |
| Chapter LXXXXXV     | 1570 |
| Chapter LXXXXXVI    | 1585 |
| Chapter LXXXXXVII   | 1600 |
| Chapter LXXXXXVIII  | 1615 |
| Chapter LXXXXXIX    | 1630 |
| Chapter LXXXXXX     | 1645 |
| Chapter LXXXXXXI    | 1660 |
| Chapter LXXXXXXII   | 1675 |
| Chapter LXXXXXXIII  | 1690 |
| Chapter LXXXXXXIV   | 1705 |
| Chapter LXXXXXXV    | 1720 |
| Chapter LXXXXXXVI   | 1735 |
| Chapter LXXXXXXVII  | 1750 |
| Chapter LXXXXXXVIII | 1765 |
| Chapter LXXXXXXIX   | 1780 |
| Chapter LXXXXXXX    | 1795 |
| Chapter LXXXXXXXI   | 1810 |
| Chapter LXXXXXXII   | 1825 |
| Chapter LXXXXXXIII  | 1840 |
| Chapter LXXXXXXIV   | 1855 |
| Chapter LXXXXXXV    | 1870 |
| Chapter LXXXXXXVI   | 1885 |
| Chapter LXXXXXXVII  | 1900 |
| Chapter LXXXXXXVIII | 1915 |
| Chapter LXXXXXXIX   | 1930 |
| Chapter LXXXXXXX    | 1945 |
| Chapter LXXXXXXXI   | 1960 |
| Chapter LXXXXXXII   | 1975 |
| Chapter LXXXXXXIII  | 1990 |
| Chapter LXXXXXXIV   | 2005 |
| Chapter LXXXXXXV    | 2020 |
| Chapter LXXXXXXVI   | 2035 |
| Chapter LXXXXXXVII  | 2050 |
| Chapter LXXXXXXVIII | 2065 |
| Chapter LXXXXXXIX   | 2080 |
| Chapter LXXXXXXX    | 2095 |
| Chapter LXXXXXXXI   | 2110 |
| Chapter LXXXXXXII   | 2125 |
| Chapter LXXXXXXIII  | 2140 |
| Chapter LXXXXXXIV   | 2155 |
| Chapter LXXXXXXV    | 2170 |
| Chapter LXXXXXXVI   | 2185 |
| Chapter LXXXXXXVII  | 2200 |
| Chapter LXXXXXXVIII | 2215 |
| Chapter LXXXXXXIX   | 2230 |
| Chapter LXXXXXXX    | 2245 |
| Chapter LXXXXXXXI   | 2260 |
| Chapter LXXXXXXII   | 2275 |
| Chapter LXXXXXXIII  | 2290 |
| Chapter LXXXXXXIV   | 2305 |
| Chapter LXXXXXXV    | 2320 |
| Chapter LXXXXXXVI   | 2335 |
| Chapter LXXXXXXVII  | 2350 |
| Chapter LXXXXXXVIII | 2365 |
| Chapter LXXXXXXIX   | 2380 |
| Chapter LXXXXXXX    | 2395 |
| Chapter LXXXXXXXI   | 2410 |
| Chapter LXXXXXXII   | 2425 |
| Chapter LXXXXXXIII  | 2440 |
| Chapter LXXXXXXIV   | 2455 |
| Chapter LXXXXXXV    | 2470 |
| Chapter LXXXXXXVI   | 2485 |
| Chapter LXXXXXXVII  | 2500 |
| Chapter LXXXXXXVIII | 2515 |
| Chapter LXXXXXXIX   | 2530 |
| Chapter LXXXXXXX    | 2545 |
| Chapter LXXXXXXXI   | 2560 |
| Chapter LXXXXXXII   | 2575 |
| Chapter LXXXXXXIII  | 2590 |
| Chapter LXXXXXXIV   | 2605 |
| Chapter LXXXXXXV    | 2620 |
| Chapter LXXXXXXVI   | 2635 |
| Chapter LXXXXXXVII  | 2650 |
| Chapter LXXXXXXVIII | 2665 |
| Chapter LXXXXXXIX   | 2680 |
| Chapter LXXXXXXX    | 2695 |
| Chapter LXXXXXXXI   | 2710 |
| Chapter LXXXXXXII   | 2725 |
| Chapter LXXXXXXIII  | 2740 |
| Chapter LXXXXXXIV   | 2755 |
| Chapter LXXXXXXV    | 2770 |
| Chapter LXXXXXXVI   | 2785 |
| Chapter LXXXXXXVII  | 2800 |
| Chapter LXXXXXXVIII | 2815 |
| Chapter LXXXXXXIX   | 2830 |
| Chapter LXXXXXXX    | 2845 |
| Chapter LXXXXXXXI   | 2860 |
| Chapter LXXXXXXII   | 2875 |
| Chapter LXXXXXXIII  | 2890 |
| Chapter LXXXXXXIV   | 2905 |
| Chapter LXXXXXXV    | 2920 |
| Chapter LXXXXXXVI   | 2935 |
| Chapter LXXXXXXVII  | 2950 |
| Chapter LXXXXXXVIII | 2965 |
| Chapter LXXXXXXIX   | 2980 |
| Chapter LXXXXXXX    | 2995 |
| Chapter LXXXXXXXI   | 3010 |
| Chapter LXXXXXXII   | 3025 |
| Chapter LXXXXXXIII  | 3040 |
| Chapter LXXXXXXIV   | 3055 |
| Chapter LXXXXXXV    | 3070 |
| Chapter LXXXXXXVI   | 3085 |
| Chapter LXXXXXXVII  | 3100 |
| Chapter LXXXXXXVIII | 3115 |
| Chapter LXXXXXXIX   | 3130 |
| Chapter LXXXXXXX    | 3145 |
| Chapter LXXXXXXXI   | 3160 |
| Chapter LXXXXXXII   | 3175 |
| Chapter LXXXXXXIII  | 3190 |
| Chapter LXXXXXXIV   | 3205 |
| Chapter LXXXXXXV    | 3220 |
| Chapter LXXXXXXVI   | 3235 |
| Chapter LXXXXXXVII  | 3250 |
| Chapter LXXXXXXVIII | 3265 |
| Chapter LXXXXXXIX   | 3280 |
| Chapter LXXXXXXX    | 3295 |
| Chapter LXXXXXXXI   | 3310 |
| Chapter LXXXXXXII   | 3325 |
| Chapter LXXXXXXIII  | 3340 |
| Chapter LXXXXXXIV   | 3355 |
| Chapter LXXXXXXV    | 3370 |
| Chapter LXXXXXXVI   | 3385 |
| Chapter LXXXXXXVII  | 3400 |
| Chapter LXXXXXXVIII | 3415 |
| Chapter LXXXXXXIX   | 3430 |
| Chapter LXXXXXXX    | 3445 |
| Chapter LXXXXXXXI   | 3460 |
| Chapter LXXXXXXII   | 3475 |
| Chapter LXXXXXXIII  | 3490 |
| Chapter LXXXXXXIV   | 3505 |
| Chapter LXXXXXXV    | 3520 |
| Chapter LXXXXXXVI   | 3535 |
| Chapter LXXXXXXVII  | 3550 |
| Chapter LXXXXXXVIII | 3565 |
| Chapter LXXXXXXIX   | 3580 |
| Chapter LXXXXXXX    | 3595 |
| Chapter LXXXXXXXI   | 3610 |
| Chapter LXXXXXXII   | 3625 |
| Chapter LXXXXXXIII  | 3640 |
| Chapter LXXXXXXIV   | 3655 |
| Chapter LXXXXXXV    | 3670 |
| Chapter LXXXXXXVI   | 3685 |
| Chapter LXXXXXXVII  | 3700 |
| Chapter LXXXXXXVIII | 3715 |
| Chapter LXXXXXXIX   | 3730 |
| Chapter LXXXXXXX    | 3745 |
| Chapter LXXXXXXXI   | 3760 |
| Chapter LXXXXXXII   | 3775 |
| Chapter LXXXXXXIII  | 3790 |
| Chapter LXXXXXXIV   | 3805 |
| Chapter LXXXXXXV    | 3820 |
| Chapter LXXXXXXVI   | 3835 |
| Chapter LXXXXXXVII  | 3850 |
| Chapter LXXXXXXVIII | 3865 |
| Chapter LXXXXXXIX   | 3880 |
| Chapter LXXXXXXX    | 3895 |
| Chapter LXXXXXXXI   | 3910 |
| Chapter LXXXXXXII   | 3925 |
| Chapter LXXXXXXIII  | 3940 |
| Chapter LXXXXXXIV   | 3955 |
| Chapter LXXXXXXV    | 3970 |
| Chapter LXXXXXXVI   | 3985 |
| Chapter LXXXXXXVII  | 4000 |
| Chapter LXXXXXXVIII | 4015 |
| Chapter LXXXXXXIX   | 4030 |
| Chapter LXXXXXXX    | 4045 |
| Chapter LXXXXXXXI   | 4060 |
| Chapter LXXXXXXII   | 4075 |
| Chapter LXXXXXXIII  | 4090 |
| Chapter LXXXXXXIV   | 4105 |
| Chapter LXXXXXXV    | 4120 |
| Chapter LXXXXXXVI   | 4135 |
| Chapter LXXXXXXVII  | 4150 |
| Chapter LXXXXXXVIII | 4165 |
| Chapter LXXXXXXIX   | 4180 |
| Chapter LXXXXXXX    | 4195 |
| Chapter LXXXXXXXI   | 4210 |
| Chapter LXXXXXXII   | 4225 |
| Chapter LXXXXXXIII  | 4240 |
| Chapter LXXXXXXIV   | 4255 |
| Chapter LXXXXXXV    | 4270 |
| Chapter LXXXXXXVI   | 4285 |
| Chapter LXXXXXXVII  | 4300 |
| Chapter LXXXXXXVIII | 4315 |
| Chapter LXXXXXXIX   | 4330 |
| Chapter LXXXXXXX    | 4345 |
| Chapter LXXXXXXXI   | 4360 |
| Chapter LXXXXXXII   | 4375 |
| Chapter LXXXXXXIII  | 4390 |
| Chapter LXXXXXXIV   | 4405 |
| Chapter LXXXXXXV    | 4420 |
| Chapter LXXXXXXVI   | 4435 |
| Chapter LXXXXXXVII  | 4450 |
| Chapter LXXXXXXVIII | 4465 |
| Chapter LXXXXXXIX   | 4480 |
| Chapter LXXXXXXX    | 4495 |
| Chapter LXXXXXXXI   | 4510 |
| Chapter LXXXXXXII   | 4525 |
| Chapter LXXXXXXIII  | 4540 |
| Chapter LXXXXXXIV   | 4555 |
| Chapter LXXXXXXV    | 4570 |
| Chapter LXXXXXXVI   | 4585 |
| Chapter LXXXXXXVII  | 4600 |
| Chapter LXXXXXXVIII | 4615 |
| Chapter LXXXXXXIX   | 4630 |
| Chapter LXXXXXXX    | 4645 |
| Chapter LXXXXXXXI   | 4660 |
| Chapter LXXXXXXII   | 4675 |
| Chapter LXXXXXXIII  | 4690 |
| Chapter LXXXXXXIV   | 4705 |
| Chapter LXXXXXXV    | 4720 |
| Chapter LXXXXXXVI   | 4735 |
| Chapter LXXXXXXVII  | 4750 |
| Chapter LXXXXXXVIII | 4765 |
| Chapter LXXXXXXIX   | 4780 |
| Chapter LXXXXXXX    | 4795 |
| Chapter LXXXXXXXI   | 4810 |
| Chapter LXXXXXXII   | 4825 |
| Chapter LXXXXXXIII  | 4840 |
| Chapter LXXXXXXIV   | 4855 |
| Chapter LXXXXXXV    | 4870 |
| Chapter LXXXXXXVI   | 4885 |
| Chapter LXXXXXXVII  | 4900 |
| Chapter LXXXXXXVIII | 4915 |
| Chapter LXXXXXXIX   | 4930 |
| Chapter LXXXXXXX    | 4945 |
| Chapter LXXXXXXXI   | 4960 |
| Chapter LXXXXXXII   | 4975 |
| Chapter LXXXXXXIII  | 4990 |
| Chapter LXXXXXXIV   | 5005 |
| Chapter LXXXXXXV    | 5020 |
| Chapter LXXXXXXVI   | 5035 |
| Chapter LXXXXXXVII  | 5050 |
| Chapter LXXXXXXVIII | 5065 |
| Chapter LXXXXXXIX   | 5080 |
| Chapter LXXXXXXX    | 5095 |
| Chapter LXXXXXXXI   | 5110 |
| Chapter LXXXXXXII   | 5125 |
| Chapter LXXXXXXIII  | 5140 |
| Chapter LXXXXXXIV   | 5155 |
| Chapter LXXXXXXV    | 5170 |
| Chapter LXXXXXXVI   | 5185 |
| Chapter LXXXXXXVII  | 5200 |
| Chapter LXXXXXXVIII | 5215 |
| Chapter LXXXXXXIX   | 5230 |
| Chapter LXXXXXXX    | 5245 |
| Chapter LXXXXXXXI   | 5260 |
| Chapter LXXXXXXII   | 5275 |
| Chapter LXXXXXXIII  | 5290 |
| Chapter LXXXXXXIV   | 5305 |
| Chapter LXXXXXXV    | 5320 |
| Chapter LXXXXXXVI   | 5335 |
| Chapter LXXXXXXVII  | 5350 |
| Chapter LXXXXXXVIII | 5365 |
| Chapter LXXXXXXIX   | 5380 |
| Chapter LXXXXXXX    | 5395 |
| Chapter LXXXXXXXI   | 5410 |
| Chapter LXXXXXXII   | 5425 |
| Chapter LXXXXXXIII  | 5440 |
| Chapter LXXXXXXIV   | 5455 |
| Chapter LXXXXXXV    | 5470 |
| Chapter LXXXXXXVI   | 5485 |
| Chapter LXXXXXXVII  | 5500 |
| Chapter LXXXXXXVIII | 5515 |
| Chapter LXXXXXXIX   | 5530 |
| Chapter LXXXXXXX    | 5545 |
| Chapter LXXXXXXXI   | 5560 |
| Chapter LXXXXXXII   | 5575 |
| Chapter LXXXXXXIII  | 5590 |
| Chapter LXXXXXXIV   | 5605 |
| Chapter LXXXXXXV    | 5620 |
| Chapter LXXXXXXVI   | 5635 |
| Chapter LXXXXXXVII  | 5650 |
| Chapter LXXXXXXVIII | 5665 |
| Chapter LXXXXXXIX   | 5680 |
| Chapter LXXXXXXX    | 5695 |
| Chapter LXXXXXXXI   | 5710 |
| Chapter LXXXXXXII   | 5725 |
| Chapter LXXXXXXIII  | 5740 |
| Chapter LXXXXXXIV   | 5755 |
| Chapter LXXXXXXV    | 5770 |
| Chapter LXXXXXXVI   | 5785 |
| Chapter LXXXXXXVII  | 5800 |
| Chapter LXXXXXXVIII | 5815 |
| Chapter LXXXXXXIX   | 5830 |
| Chapter LXXXXXXX    | 5845 |
| Chapter LXXXXXXXI   | 5860 |
| Chapter LXXXXXXII   | 5875 |
| Chapter LXXXXXXIII  | 5890 |
| Chapter LXXXXXXIV   | 5905 |
| Chapter LXXXXXXV    | 5920 |
| Chapter LXXXXXXVI   | 5935 |
| Chapter LXXXXXXVII  | 5950 |
| Chapter LXXXXXXVIII | 5965 |
| Chapter LXXXXXXIX   | 5980 |
| Chapter LXXXXXXX    | 5995 |
| Chapter LXXXXXXXI   | 6010 |
| Chapter LXXXXXXII   | 6025 |
| Chapter LXXXXXXIII  | 6040 |
| Chapter LXXXXXXIV   | 6055 |
| Chapter LXXXXXXV    | 6070 |
| Chapter LXXXXXXVI   | 6085 |
| Chapter LXXXXXXVII  | 6100 |
| Chapter LXXXXXXVIII | 6115 |
| Chapter LXXXXXXIX   | 6130 |
| Chapter LXXXXXXX    | 6145 |
| Chapter LXXXXXXXI   | 6160 |
| Chapter LXXXXXXII   | 6175 |
| Chapter LXXXXXXIII  | 6190 |
| Chapter LXXXXXXIV   | 6205 |
| Chapter LXXXXXXV    | 6220 |
| Chapter LXXXXXXVI   | 6235 |
| Chapter LXXXXXXVII  | 6250 |
| Chapter LXXXXXXVIII | 6265 |
| Chapter LXXXXXXIX   | 6280 |
| Chapter LXXXXXXX    | 6295 |
| Chapter LXXXXXXXI   | 6310 |
| Chapter LXXXXXXII   | 6325 |
| Chapter LXXXXXXIII  | 6340 |
| Chapter LXXXXXXIV   | 6355 |
| Chapter LXXXXXXV    | 6370 |
| Chapter LXXXXXXVI   | 6385 |
| Chapter LXXXXXXVII  | 6400 |
| Chapter LXXXXXXVIII | 6415 |
| Chapter LXXXXXXIX   | 6430 |
| Chapter LXXXXXXX    | 6445 |
| Chapter LXXXXXXXI   | 6460 |
| Chapter LXXXXXXII   | 6475 |
| Chapter LXXXXXXIII  | 6490 |
| Chapter LXXXXXXIV   | 6505 |
| Chapter LXXXXXXV    | 6520 |
| Chapter LXXXXXXVI   | 6535 |
| Chapter LXXXXXXVII  | 6550 |
| Chapter LXXXXXXVIII | 6565 |
| Chapter LXXXXXXIX   | 6580 |
| Chapter LXXXXXXX    | 6595 |
| Chapter LXXXXXXXI   | 6610 |
| Chapter LXXXXXXII   | 6625 |
| Chapter LXXXXXXIII  | 6640 |
| Chapter LXXXXXXIV   | 6655 |
| Chapter LXXXXXXV    | 6670 |
| Chapter LXXXXXXVI   | 6685 |
| Chapter LXXXXXXVII  | 6700 |
| Chapter LXXXXXXVIII | 6715 |
| Chapter LXXXXXXIX   | 6730 |
| Chapter LXXXXXXX    | 6745 |
| Chapter LXXXXXXXI   | 6760 |
| Chapter LXXXXXXII   | 6775 |
| Chapter LXXXXXXIII  | 6790 |
| Chapter LXXXXXXIV   | 6805 |
| Chapter LXXXXXXV    | 6820 |
| Chapter LXXXXXXVI   | 6835 |
| Chapter LXXXXXXVII  | 6850 |
| Chapter LXXXXXXVIII | 6865 |
| Chapter LXXXXXXIX   | 6880 |
| Chapter LXXXXXXX    | 6895 |
| Chapter LXXXXXXXI   | 6910 |
| Chapter LXXXXXXII   | 6925 |
| Chapter LXXXXXXIII  | 6940 |
| Chapter LXXXXXXIV   | 6955 |
| Chapter LXXXXXXV    | 6970 |
| Chapter LXXXXXXVI   | 6985 |
| Chapter LXXXXXXVII  | 7000 |
| Chapter LXXXXXXVIII | 7015 |
| Chapter LXXXXXXIX   | 7030 |
| Chapter LXXXXXXX    | 7045 |
| Chapter LXXXXXXXI   | 7060 |
| Chapter LXXXXXXII   | 7075 |
| Chapter LXXXXXXIII  | 7090 |
| Chapter LXXXXXXIV   | 7105 |
| Chapter LXXXXXXV    | 7120 |
| Chapter LXXXXXXVI   | 7135 |
| Chapter LXXXXXXVII  | 7150 |
| Chapter LXXXXXXVIII | 7165 |
| Chapter LXXXXXXIX   | 7180 |
| Chapter LXXXXXXX    | 7195 |
| Chapter LXXXXXXXI   | 7210 |
| Chapter LXXXXXXII   | 7225 |
| Chapter LXXXXXXIII  | 7240 |
| Chapter LXXXXXXIV   | 7255 |
| Chapter LXXXXXXV    | 7270 |
| Chapter LXXXXXXVI   | 7285 |
| Chapter LXXXXXXVII  | 7300 |
| Chapter LXXXXXXVIII | 7315 |
| Chapter LXXXXXXIX   | 7330 |
| Chapter LXXXXXXX    | 7345 |
| Chapter LXXXXXXXI   | 7360 |
| Chapter LXXXXXXII   | 7375 |
| Chapter LXXXXXXIII  | 7390 |
| Chapter LXXXXXXIV   | 7405 |
| Chapter LXXXXXXV    | 7420 |
| Chapter LXXXXXXVI   | 7435 |
| Chapter LXXXXXXVII  | 7450 |
| Chapter LXXXXXXVIII | 7465 |
| Chapter LXXXXXXIX   | 7480 |
| Chapter LXXXXXXX    | 7495 |
| Chapter LXXXXXXXI   | 7510 |
| Chapter LXXXXXXII   | 7525 |
| Chapter LXXXXXXIII  | 7540 |
| Chapter LXXXXXXIV   | 7555 |
| Chapter LXXXXXXV    | 7570 |
| Chapter LXXXXXXVI   | 7585 |
| Chapter LXXXXXXVII  | 7600 |
| Chapter LXXXXXXVIII | 7615 |
| Chapter LXXXXXXIX   | 7630 |
| Chapter LXXXXXXX    | 7645 |
| Chapter LXXXXXXXI   | 7660 |
| Chapter LXXXXXXII   | 7675 |
| Chapter LXXXXXXIII  | 7690 |
| Chapter LXXXXXXIV   | 7705 |
| Chapter LXXXXXXV    | 7720 |
| Chapter LXXXXXXVI   | 7735 |
| Chapter LXXXXXXVII  | 7750 |
| Chapter LXXXXXXVIII | 7765 |
| Chapter LXXXXXXIX   | 7780 |
| Chapter LXXXXXXX    | 7795 |
| Chapter LXXXXXXXI   | 7810 |
| Chapter LXXXXXXII   | 7825 |
| Chapter LXXXXXXIII  | 7840 |
| Chapter LXXXXXXIV   | 7855 |
| Chapter LXXXXXXV    | 7870 |
| Chapter LXXXXXXVI   | 7885 |
| Chapter LXXXXXXVII  | 7900 |
| Chapter LXXXXXXVIII | 7915 |
| Chapter LXXXXXXIX   | 7930 |
| Chapter LXXXXXXX    | 7945 |
| Chapter LXXXXXXXI   | 7960 |
| Chapter LXXXXXXII   | 7975 |
| Chapter LXXXXXXIII  | 7990 |
| Chapter LXXXXXXIV   | 8005 |
| Chapter LXXXXXXV    | 8020 |
| Chapter LXXXXXXVI   | 8035 |
| Chapter LXXXXXXVII  | 8050 |
| Chapter LXXXXXXVIII | 8065 |
| Chapter LXXXXXXIX   | 8080 |
| Chapter LXXXXXXX    | 8095 |
| Chapter LXXXXXXXI   | 8110 |
| Chapter LXXXXXXII   | 8125 |
| Chapter LXXXXXXIII  | 8140 |
| Chapter LXXXXXXIV   | 8155 |
| Chapter LXXXXXXV    | 8170 |
| Chapter LXXXXXXVI   | 8185 |
| Chapter LXXXXXXVII  | 8200 |
| Chapter LXXXXXXVIII | 8215 |
| Chapter LXXXXXX     |      |



# ILLUSTRATIONS.

| FIG. |  | PAGE |
|------|--|------|
| 1.   | Fracture with over-lapping . . . after <i>Malgaigne</i>                              | 9    |
| 2.   | „ with displacement . . . „  | 10   |
| 3.   | „ of condyles and coronoid process . <i>Fergusson</i>                                | 12   |
| 4.   | Fracture united at an angle, from St. George's Hospital Museum . . . <i>Original</i> | 21   |
| 5.   | „ „ (Hepburn) . . . „  | 21   |
| 6.   | „ „ „ . . . „  | 21   |
| 7.   | Displacement with fibrous union . . . after <i>Malgaigne</i>                         | 24   |
| 8.   | Fibrous union, from University College Museum . <i>Original</i>                      | 29   |
| 9.   | Ununited fracture after gunshot injury . . <i>Cox Smith</i>                          | 31   |
| 10.  | „ „ „ . . . „  | 31   |
| 11.  | Four-tailed bandage for lower jaw . . . <i>Original</i>                              | 33   |
| 12.  | Gutta-percha splint . . . <i>Erichsen</i>  | 34   |
| 13.  | „ „ „ . . . „  | 34   |
| 14.  | Hamilton's apparatus . . . after <i>Hamilton</i>                                     | 35   |
| 15.  | Hammond's wire splint . . . <i>Original</i>  | 36   |
| 16.  | „ „ „ . . . „  | 37   |
| 17.  | Thomas's wire-suture . . . <i>Erichsen</i>   | 39   |
| 18.  | „ „ „ . . . „  | 40   |
| 19.  | Wheelhouse's method . . . „  | 41   |
| 20.  | Hayward's mouth-piece . . . <i>B. Hill</i>   | 43   |
| 21.  | Gunning's interdental splint . . . „   | 44   |
| 22.  | „ „ „ . . . „  | 45   |
| 23.  | „ „ „ . . . „  | 46   |
| 24.  | „ „ „ . . . „  | 47   |
| 25.  | Bean's apparatus . . . after <i>Hamilton</i>   | 48   |
| 26.  | Lonsdale's apparatus . . . <i>B. Hill</i>  | 51   |
| 27.  | „ „ modified . . . „   | 52   |
| 28.  | Moon's splint . . . <i>Bryant</i>  | 52   |
| 29.  | „ „ „ . . . „  | 52   |
| 30.  | Fracture of upper jaw . . . <i>Salter</i>  | 57   |
| 31.  | Plate for ditto . . . „  | 57   |
| 31a. | Gunshot fracture of upper jaw . . . <i>Cox Smith</i>                                 | 71   |
| 31b. | „ „ „ . . . „  | 71   |
| 32.  | Gunshot injury of face . . . <i>Debout</i>   | 73   |
| 33.  | Ununited gunshot fracture . . . <i>Cox Smith</i>                                     | 78   |
| 34.  | „ „ „ . . . „  | 78   |
| 35.  | Gunshot injury of face . . . <i>Debout</i>   | 79   |
| 36.  | „ of jaw . . . „   | 79   |
| 37.  | Silver chin . . . „  | 80   |
| 38.  | Dissection after loss of jaw . . . „   | 80   |
| 39.  | Dislocation of jaw . . . <i>Astley Cooper</i>  | 85   |
| 40.  | „ „ „ . . . after <i>Malgaigne</i>   | 86   |
| 41.  | Dissection of dislocation of jaw . . . <i>Original</i>                               | 87   |
| 42.  | Dislocation of jaw . . . <i>Fergusson</i>  | 88   |
| 43.  | „ old . . . <i>R. W. Smith</i>   | 89   |
| 44.  | „ „ . . . <i>J. Couper</i>   | 91   |







| FIG. |  |                             | PAGE |
|------|--|-----------------------------|------|
| 99.  | Misplaced tooth . . . . .                                  | <i>Forget</i>               | 215  |
| 100. | " " " " " " " " " " " "                                    | "                           | 215  |
| 101. | Odontoma (Fergusson) . . . . .                             | <i>Tomes</i>                | 218  |
| 102. | " " " " " " " " " " " "                                    | <i>Forget</i>               | 219  |
| 103. | " (Author) . . . . .                                       | <i>Original</i>             | 222  |
| 104. | " " " " " " " " " " " "                                    | "                           | 222  |
| 105. | " " " " " " " " " " " "                                    | <i>Salter</i>               | 224  |
| 106. | " " " " " " " " " " " "                                    | "                           | 224  |
| 107. | " " " " " " " " " " " "                                    | <i>Forget</i>               | 224  |
| 108. | " " " " " " " " " " " "                                    | <i>Tomes</i>                | 225  |
| 109. | Hypertrophy of gum (MacGillivray) . . . . .                | <i>Original</i>             | 229  |
| 110. | " " (Author) . . . . .                                     | "                           | 230  |
| 111. | " " " " " " " " " " " "                                    | "                           | 230  |
| 112. | Hypertrophy of alveolus " " " " " " " " " " " "            | "                           | 231  |
| 113. | Papillary tumour of gum (Fergusson) . . . . .              | <i>Salter</i>               | 234  |
| 114. | " " of palate (Cock) . . . . .                             | "                           | 235  |
| 115. | " " " " section " " " " " " " "                            | "                           | 235  |
| 116. | Epulis (Hutchinson) . . . . .                              | <i>Original</i>             | 235  |
| 117. | " myeloid (Hutchinson) . . . . .                           | "                           | 236  |
| 118. | " giant-celled (Wilkes) . . . . .                          | "                           | 237  |
| 119. | " (Author) . . . . .                                       | "                           | 238  |
| 120. | " " " " " " " " " " " "                                    | "                           | 241  |
| 121. | " case of Mary Griffiths . . . . .                         | <i>Liston</i>               | 242  |
| 122. | " " " " " " " " " " " "                                    | "                           | 243  |
| 123. | Cross-cutting forceps . . . . .                            | "                           | 245  |
| 124. | " " " " " " " " " " " "                                    | "                           | 245  |
| 125. | Bone-forceps . . . . .                                     | <i>Fergusson</i>            | 246  |
| 126. | " " " " " " " " " " " "                                    | "                           | 246  |
| 127. | Tumour of hard palate (Author) . . . . .                   | <i>Original</i>             | 250  |
| 128. | Epithelioma of gum . . . . .                               | <i>Fergusson</i>            | 255  |
| 129. | Fibrous tumours of upper jaw . . . . .                     | <i>Liston</i>               | 262  |
| 130. | Ann Struther before operation . . . . .                    | "                           | 263  |
| 131. | " " after operation . . . . .                              | "                           | 263  |
| 132. | Mrs. Frazer . . . . .                                      | "                           | 264  |
| 133. | Large recurrent enchondroma (Author) . . . . .             | <i>Original</i>             | 270  |
| 134. | Osseous tumour (Dupuytren) . . . . . after V. de Cassis    |                             | 278  |
| 135. | " " " " " " " " " " " "                                    | "                           | 278  |
| 136. | " " (Fergusson) . . . . .                                  | <i>Original</i>             | 281  |
| 137. | " " (Duka) . . . . .                                       | <i>Pathological Society</i> | 284  |
| 138. | Myeloid of upper jaw . . . . .                             | <i>Canton</i>               | 293  |
| 139. | Medullary sarcoma (Craven) . . . . .                       | <i>Original</i>             | 303  |
| 140. | " " " " " " " " " " " "                                    | "                           | 305  |
| 141. | Double medullary sarcoma (Author) . . . . .                | "                           | 306  |
| 142. | Medullary sarcoma of both jaws " " " " " " " " " " " "     | "                           | 307  |
| 143. | Epithelioma of antrum " " " " " " " " " " " "              | "                           | 311  |
| 144. | Gensoul's incision . . . . .                               | <i>Fergusson</i>            | 316  |
| 145. | Lizars' " " " " " " " " " " " "                            | "                           | 317  |
| 146. | " " " " " " " " " " " "                                    | "                           | 317  |
| 147. | Scar of face . . . . .                                     | "                           | 318  |
| 148. | Incisions on face . . . . .                                | <i>Liston</i>               | 319  |
| 149. | Saw . . . . .  | <i>Fergusson</i>            | 320  |
| 150. | Lion forceps . . . . .                                     | "                           | 320  |
| 151. | Fibrous tumour of lower jaw (University College) . . . . . | <i>Original</i>             | 327  |
| 152. | " " " " " " " " " " " "                                    | <i>Spencer Wells</i>        | 328  |







THE  
INJURIES AND DISEASES OF THE  
JAWS.

---

CHAPTER I.

FRACTURE OF THE LOWER JAW.

FRACTURE of the lower jaw is usually the result of direct violence, though Professor Pancoast met with a case in which fracture of the neck of the bone had resulted from a violent fit of coughing, in an old man upwards of seventy years of age. (Gross's "Surgery," p. 964.) Blows received on the jaw in fighting or a kick from a horse are the most common causes of the accident; but falls from a height upon the face also produce some of its most serious forms, owing to the comminution resulting. The unskilful application of the dentist's "key" has been known to cause a complete fracture of the bone, but more frequently in former years than at the present time, when that instrument has been almost entirely superseded by the forceps.

Fractures of the alveolus are frequently unavoidable during the extraction of the molar teeth, even in the most skilful hands, since the position assumed by the fangs is occasionally such that extraction without displacement of the bone to some extent is impossible. These cases ordinarily give, however, little inconvenience, since the removal of the alveolus only hastens the absorption which must necessarily ensue upon the removal of the teeth, unless indeed the fracture should be so extensive as to affect the alveoli of the neighbouring teeth, in which case exfolia-



tion of a troublesome character may be produced. Unavoidable accidents of this kind have on several occasions been made the ground for legal proceedings against the operator ; but most unfairly so, since the exercise of the greatest skill and care cannot on all occasions prevent mishaps due to the natural conformation of the parts.

On this subject, which is of considerable interest to those practising dental surgery, I may quote a passage from a paper in the "Dental Cosmos," by Dr. J. Richardson, illustrating the difficulty which may be met with. He says :—

"I have never come to regard extracting teeth as an operation free from liability to grave complications. I seize hold of a tooth to-day with more misgiving, with more caution, than I did the first year of my practice. Eleven years' experience may be supposed to have given me some confidence and expertness in this operation, yet with each year's added experience the operation grows in importance, and dictates greater vigilance and prudence. I feel my way through the operation with more and more caution, guard every movement with greater circumspection, and magnify my skill more and more with every success. Through eleven years my experience has been free from serious accident, but the catastrophe came at last when I had no possible reason to expect it.

"Within the past two months I fractured the inferior jaw severely in attempting to remove the anterior right inferior molar. It was in this way. The patient was a lady about twenty-five years of age. The crown of the tooth was much decayed, but I had a firm hold upon the neck. Alternate lateral traction was made upon the tooth, moderately at first, but increasing at every movement of the forceps. There seemed to be complete immobility of the tooth until the instant of its giving way, which it did with the outward movement of the forceps. I comprehended instantly, from the enlargement of the gum below the processes, that a fracture of the maxilla had occurred. On examination I found the detached portion adhering firmly to the fangs



of the tooth, and extending antero-posteriorly about an inch and a quarter, and in depth about three fourths of an inch or more. I made no further attempts to remove either the tooth or fragment of bone, but pressed them firmly back to their places, and directed the patient to keep the mouth persistently closed. I hoped for a reunion of the fractured parts."—*British Journal of Dental Science*, August, 1863.

Mr. James Salter, in his valuable work on "Dental Pathology and Surgery" (1874) devotes a chapter to "The casualties which may arise in the operations of tooth-extraction," in which he mentions that, in extracting an incisor tooth from the upper jaw, the whole mass of bone corresponding to the intermaxillary bones broke away, and was merely held in place by the soft tissues. Fortunately the bone reunited without an untoward symptom. Mr. Salter also refers to a case in which a most able operator broke the horizontal ramus of the lower jaw completely through, in extracting a tooth with the forceps.

Gunshot injuries of the face may produce the most terrible injuries of the lower jaw, by splintering and removing large portions of it; and the mere explosion of gunpowder in its immediate neighbourhood, as when a pistol is fired into the mouth by a would-be suicide, will produce a fracture of the bone. (See chapter on "Gunshot Injuries.")

Fractures of the lower jaw are remarkable from the fact that they are almost always *compound* towards the mouth, though the skin is rarely involved except in gunshot injuries. The fibrous tissue of the gum being very inelastic, tears readily when the bone is broken across, and thus the saliva and the air come in contact with the fractured surfaces. This statement only applies, however, to fractures of the body of the bone, for when the ramus, or still more when the coronoid process or condyle is broken, the bone is too deeply seated for the injury to extend into the mouth.

Fracture may occur at various points in the lower jaw, and the body of the bone is the portion most frequently injured (in 40 out of 43 cases recorded by Hamilton); the



ramus from its position and coverings being much less liable to injury except from extreme violence, such as the passage of a wheel over the face or a gunshot injury. The coronoid process is occasionally broken off obliquely, and the neck of the jaw has been repeatedly broken on one or both sides of the bone in cases subjected to great violence.

In the body of the jaw the fracture appears to occur most frequently in the neighbourhood of the canine tooth, this position being determined probably by the greater depth of its socket, and the consequent weakness of the bone at that point; but the fracture may happen at any other point, and has been known to occur exactly at the symphysis in cases too old to admit of separation of the two portions of the bone. Of the forty cases of fracture of the body recorded by Hamilton, four were perpendicularly through the symphysis, and eighteen of the remainder were known to be oblique, whilst of the whole number no less than thirteen were examples of double and triple fractures. In twenty examples of fracture through the body, not including fracture of the symphysis, the line of fracture was fourteen times at or very near the mental foramen; twice between the first and second incisor; three times behind the last molar; and once between the last two molars.

The line of fracture, except at the symphysis, is usually oblique, and, according to Malgaigne, the thickness of the bone is also divided obliquely, so that generally the fracture is at the expense of the outer plate of the anterior fragment and the inner plate of the posterior fragment, though this rule is not without exception.

It is impossible to gather any reliable details respecting the position of recent fractures of the lower jaw occurring in the London hospitals; and as this fracture is rarely a fatal accident *per se*, the hospital museums contain comparatively few specimens. An examination of those, however, yields the following results:—

*The College of Surgeons* possesses no specimen of recent fracture of the lower jaw, and only a doubtful one of united fracture near the angle (880).



*St. Bartholomew's Hospital* possesses one specimen of fracture of the lower jaw (i. 897), "showing a fracture on the right side, which extends obliquely through the bone between the canine and bicuspid teeth and passes through the mental foramen."

*St. Thomas's Hospital* has one recent and moist specimen (27)—"A comminuted fracture of the lower jaw. The bone is fractured near the symphysis and near to both angles, so as to expose the nascent pulps of the last molar teeth. The inferior maxillary nerves are not lacerated."

*Guy's Hospital* has only one specimen (1091,<sup>70</sup>)—"A lower jaw having a doubtful fracture (united) on the left side at the angle."

*King's College Museum* is very rich in recent fractures, having no fewer than four.

1. A fracture between the incisor teeth, running obliquely to the left at the expense of the external plate of the left segment. The right coronoid process is broken off obliquely downwards from the sigmoid notch, and the necks of both condyles are fractured obliquely. This is the preparation figured by Sir William Fergusson in his "Practical Surgery," p. 521, and was taken by him from a patient who fell from a great height, and received fatal injuries. (Fig. 3.)

[This preparation corresponds very closely to that described by M. Houzelot, where, in consequence of a fall from a height, there were produced fractures of the symphysis, of both condyles, and of *both* coronoid processes. (Malgaigne, p. 323.)]

2. Is an example of double fracture of the body of the jaw. On the right side the fracture runs between the lateral incisor and the canine tooth obliquely backwards, at the expense of the external plate of the posterior fragment. On the left side the fracture extends from the posterior socket of the third molar tooth (which was broken at the time, leaving the anterior fang *in situ*), obliquely backwards, at the expense of the outer plate of the anterior fragment.

This was from a man who was struck on the jaw with the fist, and died of *delirium tremens* in King's College Hospital



in 1857, whilst the author was Sir William Fergusson's house-surgeon.

3. Is an example of double fracture of the body, and of fracture of both condyles. On the right side there is, in front of the last molar tooth, a fracture running obliquely forwards and then backwards, thus  $>$ , the upper division being at the expense of the outer plate of the posterior fragment, and the lower at the expense of the outer plate of the anterior fragment. On the left side a very oblique fracture runs forward from the front of the second molar tooth, which is broken. A part of the external plate has been broken off and is wanting. The necks of both condyles are broken obliquely downwards and inwards.

The preparation is from a woman who threw herself out of window and fell forty feet.

4. Is an example of comminuted fracture at and to the right side of the symphysis. The left half of the bone is cut nearly vertically through the socket of the left lateral incisor. The right half is cut very obliquely from the canine tooth at the expense of the inner plate, and the fragments would complete the missing portion of alveolus.

*University College Museum* is also very rich in injuries of the jaw, having four specimens of recent fractures; one of bony union; and one of fibrous union. All the recent specimens show a fracture in the neighbourhood of the symphysis, which no doubt influenced Mr. Erichsen in the opinion he has expressed as to the usual position of fracture: "I have seen fractures most frequently in the body of the bone near the symphysis, extending between the lateral incisors, or between those teeth and the canine. The symphysis itself is not so commonly fractured, the bone being thick in this situation. The angle is frequently broken, but the neck and coronoid process rarely give way." ("Science and Art of Surgery," p. 264.)

1. Is a vertical fracture through the symphysis, with a horizontal fracture running through the alveolus on the right side, separating the portion containing the right lateral incisor, canine, and first bicuspid teeth.



2. Shows a fracture running at first vertically, and then slightly obliquely to the left through the socket of the left lateral incisor. The neck of the left condyle is broken off obliquely and very low down, so that the fissure runs downwards and backwards in a line with the posterior border of the coronoid process.

3. Is a vertical fracture through the symphysis, with a portion of dried integument adhering. Both condyles are broken off obliquely.

4. Is a remarkable example of multiple and comminuted fracture. One fracture runs obliquely forwards in front of the left first molar tooth into the mental foramen. A second fracture runs vertically between the right incisor teeth. A third fracture runs very obliquely from the last molar on the right side down to the lower border of the bone, opposite the canine tooth. This is met by a fourth fracture running obliquely backwards in front of the first molar tooth of the same side. The lower border of the bone in the mental region is broken off and comminuted into numerous fragments, one of which contains the mental foramen of the right side. The left condyle is also broken off obliquely.

5. Is an example of united fracture of the jaw in the right molar region, with loss of all the teeth on the right side except the last molar. The fracture was apparently oblique, and is somewhat irregularly united by bone, with the result of contracting the alveolar arch, so that the left lower teeth have been thrown inside those of the upper jaw; and both having been exposed to extra attrition, owing to the absence of teeth on the opposite side, are much worn away, the lower on their outer and the upper on their inner surfaces.

6. Is a wet preparation, showing fibrous union of the jaw beyond the right canine tooth, a great part of the body of the bone in that situation being wanting. Hence it was probably a case of comminuted fracture, with exfoliation of a portion of bone. (Fig. 8.)

*St. George's Hospital Museum* contains one remarkable specimen of united fracture of the lower jaw (i. 38). The



fracture has taken place to the right of the symphysis, and there has been a loss of substance, from comminution probably, so that the two halves of the body of the bone meet at an acute angle, all the teeth of the right side in front of the bicuspid being wanting. There are small outgrowths of bone both in front and behind in the neighbourhood of the fracture, which is irregularly united, leaving a hole in the middle of the union like the socket of a tooth. The right mental foramen is much smaller than the left, the line of fracture being apparently close in front of it. The sigmoid notches of this jaw are unusually large. (Fig. 4.)

In the catalogue of St. George's Museum is an account of a lower jaw fractured through the base of the coronoid process and through the neck of the condyle, in which the lower fragment had been displaced into the meatus auditorius externus, separating the cartilaginous from the osseous portion for nearly half its circumference. The preparation has, however, unfortunately disappeared.

The *London Hospital Museum* contains one specimen of recent fracture of the lower jaw. A fracture extends obliquely backwards between the second and third molar teeth to the *left* side, the external and internal plates of the bone being equally involved. There is also an oblique (downwards and backwards) fracture of the neck of the *right* condyle.

The Museums of Westminster, Middlesex, Charing Cross, and St. Mary's Hospitals contain no specimens of fractured lower jaw.

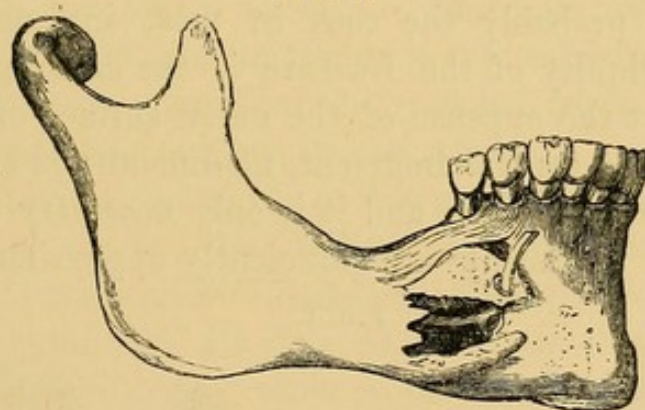
*Symptoms.*—These are ordinarily well marked. Since even in simple vertical fracture of the symphysis the patient will be conscious of pain and slight crepitus on pressing the jaws together, and the surgeon will readily perceive the irregularity of the teeth due to alteration in the level of the fragments. The position of a patient with fracture of the jaw is very characteristic, since he endeavours to support and steady the fragments with his hands in the most careful manner, and his anxiety for relief is often most ludicrously complicated by his inability to explain by word of mouth



what his ailment is. Where the laceration of the gum has permitted displacement of the fragments, manipulation on the part of the surgeon is unnecessary for the establishment of the diagnosis ; but when any doubt exists he should grasp the jaw on each side with the forefingers introduced into the mouth, and will have no difficulty in perceiving the movement and crepitus between the fragments.

When a single fracture occurs on one side of the median line, the smaller fragment is liable to displacement by muscular action, being drawn outwards and at the same time a little forwards, so as to overlap the larger fragment. This is due to the action of the temporal and masseter muscles, but principally to the latter, and is favoured by the generally oblique direction of the line of fracture and consequent

FIG. 1.



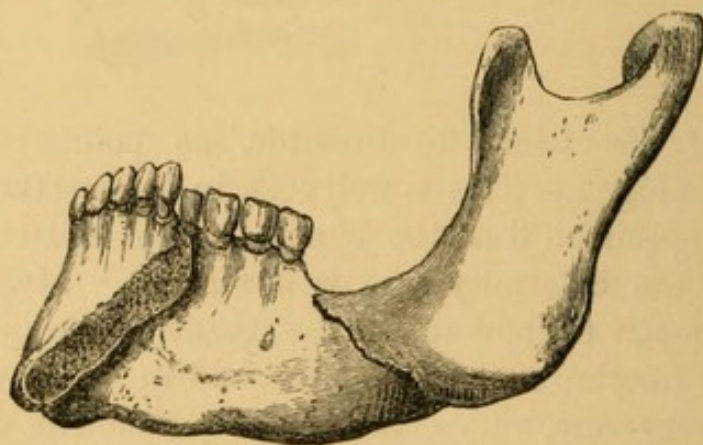
tendency of the bones to override, as pointed out by Malgaigne. (Fig. 1.) This is well seen in the fracture of the left side in specimen 3 of the King's College collection, and during life the deformity was well marked. Mr. Lawson was good enough to show me a case recently in which union of a similar fracture had taken place, and in which, notwithstanding every care, very considerable permanent displacement of the fragment had occurred. An instance of the obliquity of the fragment being reversed is given by Dr. Kinloch in the *American Journal of Medical Sciences* for July, 1859. Here the patient, who was fifty years of age, met with a compound fracture of the right side of the jaw, in front of the masseter muscle. "The line of fracture divided



the bone obliquely through its thickness, the obliquity being at the expense of the external plate of the small posterior fragment, and of the internal plate of the large or anterior fragment. The displacement was singular and marked. The small fragment projected inwards and slightly upwards into the cavity of the mouth. The large fragment rode the small one, having retreated downwards and backwards, and its extremity, which was somewhat pointed, could be felt externally under the integument."

In double fractures of the body of the jaw, one being on each side of the median line, the displacement is necessarily greater, since the muscles attached to the chin tend to draw the central loose piece downwards and backwards towards the hyoid bone, whilst both lateral portions are drawn forwards and outwards, as described in the previous paragraphs. When, as is probably the case in most instances of the kind, the obliquity of the fracture is the same on the two sides—*i.e.*, at the expense of the outer surface of both extremities of the central fragment, no difficulty is experienced in reducing the fracture, and it is only necessary to see that the posterior fragments are sufficiently approximated to the

FIG. 2.



central portion ; but when, as in specimen 2 of King's College, the obliquity is different on the two sides, the fracture being at the expense of the outer plate of the posterior fragment on the right side, and the reverse on the left side (consequent no doubt upon the blow having been struck to the left of the median line), it is obvious that great difficulties will be en-



countered both in reducing and maintaining the apposition of the fragments, as indeed was the case with the patient in question.

Malgaigne records an almost similar case in which reduction could not be effected. "The middle fragment, which was strongly drawn downward and backward, was easily brought forward nearly to a level with the other two, but when it came close to that on the right side it seemed to catch against its posterior surface, as is seen in the figure (fig. 2), and no effort could disengage it. On post-mortem examination the right fragment in its upper half was bevelled at the expense of the external surface, the middle one at the corresponding part at the expense of its internal face. This bevelled edge opposed an almost insurmountable obstacle to its disengagement; there was an overlapping of the edges of which one would have no idea. And even after death we found that, to effect the reduction, it was necessary to carry the middle portion downward and forward, so as to carry it first below and then in front of the other."

An extraordinary example of double fracture of the jaw was brought before the Edinburgh Medico-Chirurgical Society on the 20th of November, 1861, by Dr. Struthers, being from a man, æt. 19, who in Australia was caught by the coulter of his plough, when a great part of his jaw was broken off and torn away. The specimen embraced the entire body of the bone and more than half of the right ramus, which had been fractured obliquely backwards and downwards from the root of the coronoid process to the middle of the posterior edge. On the left side the fracture extended obliquely across the angle, from behind the socket of the second molar tooth to just in front of the angle. The patient recovered. (*Edinburgh Medical Journal*, December 1861.)

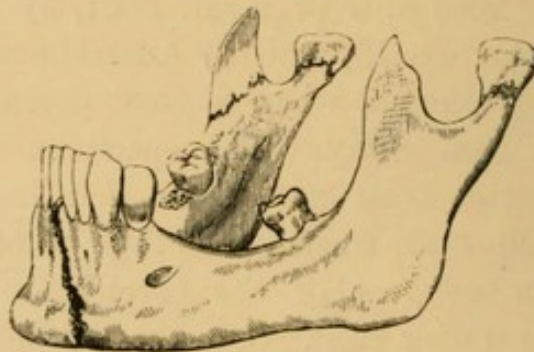
Fracture of the ramus is usually produced by some crushing force, such as the wheel of a carriage, as in a case recently under my care, and the bruising of the soft parts is therefore considerable. But little displacement ordinarily occurs, owing to the deep situation of the bone, and the



fact that it is well supported on each side by the masseter and internal pterygoid muscles. In the case alluded to under my own care, the patient was a boy of twelve, and the prominent symptom was the projection of the lower incisors beyond the upper jaw, with slight displacement towards the injured side. But when there is much laceration and loss of substance, as in gunshot injuries, the upper fragment is apt to be tilted forward by the temporal muscle, as was noticed in a case under my own care, which will be found in the Appendix (Case III.). Pain is referred to the part, and on passing the finger well back into the fauces, irregularity and crepitus may be detected when the patient moves the jaw.

Fracture of the neck of the condyle is not so rare an accident as has been stated by some authors, judging from the number of museum specimens of the accident which exist. Fig. 3, from Sir William Fergusson's "Practical Surgery," shows very well the ordinary appearance of the fracture, though in some specimens the line of fracture is more obliquely

FIG. 3.



placed. This is well seen in specimen 3 in University College Museum, where the left condyle is broken off so obliquely and so low down that the line of fracture runs downwards and backwards from the middle of the sigmoid notch. The cause in all the recorded cases is the same—viz., a fall from a considerable height. The symptoms are obscure, there being pain and difficulty of movement on the affected side, and crepitus perceived by the patient. The condyle is



drawn inwards and forwards by the pterygoideus externus, as can be ascertained by passing the finger into the mouth, and the jaw-bone is apt to become slightly displaced, so that the chin is turned *towards* the affected side and not *from* it, as is the case in dislocation.

Dr. Fountain has recorded in the *New York Medical Journal*, January, 1860, a case of fracture of the neck of the left condyle with fracture through the body on both sides, caused by a fall from a height, in which the following symptoms were present. The jaw was displaced backwards and laterally on the left side—a displacement which was temporarily rectified as long as traction was made at the symphysis, which the connexions of the middle fragment with the membranous and muscular tissues permitted. As soon as this traction was removed the lateral deformity was reproduced, and every contrivance resorted to failed to maintain a permanent reduction of the fracture of the neck, until the upper and lower teeth were wired together so as to keep up traction on the lower jaw. The case did well, and recovered without any deformity.

When double fracture of the neck occurs, the violence must have been so great as in most cases to lead shortly to fatal results, but M. Bérard has recorded a case in which the double fracture did not at first lead to any displacement, but on the fifth day convulsions ensued, which led to considerable displacement and subsequent death.

Watson, of New York, has moreover recorded a case of recovery in the person of a man who fell from the yard-arm of a vessel, breaking his thigh and arm bones and *both* condyles of the lower jaw, with the following symptoms:—“His face was somewhat deformed by the retraction of the chin; the mouth could not be opened so as to protrude the tongue to any great extent beyond the teeth, and the teeth of the upper and lower jaw could not be brought into contact. In attempting to move the jaw the patient experienced pain and crepitation just in front of the ears; the crepitation could be easily felt by placing the fingers over the fractured condyles. Nothing was done for the



fractures of the jaw. In a few weeks the rubbing of the broken surfaces and attendant soreness ceased to trouble him; but the shape of the jaw and difficulty of opening the mouth to any great extent still remained unaltered." (*New York Journal of Medicine*, October, 1840.)

Reduction of a fracture of the neck of the jaw, should complete displacement have occurred, can only be effected by acting upon the condyle and the jaw at the same time. The finger carried far back in the mouth should throw the condyle out, whilst the jaw is brought into its proper relation with the other hand. The fragments must then be pressed firmly together, and against the glenoid cavity, with a bandage. Ribes, to whom this plan is due, applied it with success. (Malgaigne.)

Fracture of the coronoid process is a rare accident. Thus Hamilton says that Houzelot's case is the only one which he has found. Curiously enough, however, he employs the illustration from Fergusson's "Practical Surgery" a few pages before, in which a fracture of the coronoid process is seen, and which is taken from specimen 1 in King's College. The fragment would, no doubt, be drawn upwards and backwards by the temporal muscle, and might be felt in its new situation, though this displacement would probably be limited by the very tough and tendinous fibres which are so closely connected with the bone, forming the insertion of the temporal muscle, and reaching down to the last molar tooth. According to Sanson, fractures of the coronoid process do not admit of union, but Mr. Holmes ("Principles and Practice of Surgery") thinks that this statement is entirely unsupported, and that the idea that fracture of the coronoid process of the jaw does not unite by bone rests on no evidence.

Considerable inflammation frequently follows a fracture of the jaw, even of a simple kind, particularly if it has been neglected or overlooked for some hours. The face becomes swollen, and the tissues beneath the chin infiltrated with serum, which is sometimes converted into pus, giving rise to troublesome abscesses.



## CHAPTER II.

## COMPLICATIONS OF FRACTURE OF THE LOWER JAW.

*Wounds of the face* are rare accompaniments of fracture of the lower jaw, except in cases of gunshot injury, and when found are usually the result of a kick from a horse. The wound itself requires treatment on ordinary principles, and is of little moment as regards the fracture (which is doubtless "compound" also into the mouth), except as interfering with the application of the necessary retentive apparatus. In a case of extensive fracture of the lower jaw, the result of a kick from a horse, which I saw in the Westminster Hospital, under Mr. Holthouse's care, the lip and chin were extensively torn; and in a case of Mr. Berkeley Hill's, in University College Hospital, the result of a fall, the wound beneath the chin very much interfered with the application of a modified form of Lonsdale's apparatus, which it was found necessary to employ.

*Hæmorrhage*, beyond that resulting from laceration of the gums, is rarely met with, since, although theoretically one might imagine that the inferior dental artery would frequently be torn across, this appears not to be the case; a result due, no doubt, to the fact that the elasticity of the artery allows of its stretching sufficiently to avoid rupture. In the *Lancet* of 12th October, 1867, a case of fractured jaw is reported, under the care of Mr. Maunder, in which severe hæmorrhage into the mouth occurred through a fissure in the gum behind the last molar tooth. This was effectually controlled by digital compression of the carotid artery, which was maintained for two hours and a half, after which no further bleeding occurred. Secondary hæmorrhage has also been met



with, for Stephen Smith, of New York, reports a case of double fracture in which about a pint of blood was lost from the seat of fracture on the twentieth day. Injury of the soft parts about the jaws may give rise to severe hæmorrhage, requiring prompt treatment; thus Mr. Lawson has reported (*Medical Times and Gazette*, 1862,) a case in which it became necessary to lay open the face in order to secure the facial and transverse facial arteries, torn by the wheel of a cart, which had fractured both the upper and lower jaws.

In the Appendix will be found a case (Case I.) of compound comminuted fractures of both upper and lower maxillæ, with extensive laceration of the face, in which tracheotomy became necessary, owing to the urgent dyspnoea supervening a few hours after the accident, due, probably, to blood becoming infiltrated into the tissues about the base of the tongue. A case of death during the administration of chloroform, which occurred at St. Bartholomew's Hospital in 1882, seems to have been due to injury of the larynx and extravasation of blood into the muscles of the root of the tongue, accompanying a fracture of the lower jaw caused by a blow in fighting.

*Dislocation and fracture of the teeth* are not unfrequently met with, the former being the direct result of a blow, or the consequence of the fracture running through the socket, and the latter the result of direct violence; or, in the molar region particularly, in consequence of indirect force through the neighbouring teeth; or from the teeth being forcibly driven against those of the upper jaw. (Tomes.) Where the fracture had passed through the socket, the tooth may fall between the edges of the bone and prevent their proper coaptation, and this should be borne in mind when a tooth is missing and difficulty is experienced in setting a fracture, since Erichsen mentions a case where union was prevented until the tooth was removed. In the molar region the crown of the tooth may be broken off, one fang remaining *in situ* and the other dropping into the fracture, as was the case with the patient under my own care, from whom specimen 2



of the King's College Museum was taken. Teeth which are merely *loosened*, generally become reattached and useful, and should therefore not be removed.

I am indebted to Mr. Margetson of Dewsbury for a case in which double fracture of the jaw occurred, with dislocation of several of the teeth, and fracture of the left second bicuspid, the crown of which was imbedded for more than two years in the tissues of the mouth, behind the incisor teeth. Mr. Margetson removed the crown from its abnormal position and also the fang; and both, together with a plaster cast, showing very well the deformity resulting from the fracture of the jaw, are in the Museum of the College of Surgeons. (2123.)

The front teeth may be broken off, with the portion of the alveolus containing them, by a horizontal fracture, either alone or in combination with a vertical fracture through the thickness of the bone. Specimen 1 of University College shows a vertical fracture through the symphysis, with a horizontal fracture running through the alveolus on the right side, separating the portion containing the right lateral incisor, the canine, and first bicuspid teeth. Such a fragment may be made to re-unite if treated at once, but when some days have elapsed, and the fragment is only attached by a portion of gum, removal must necessarily be performed. A case of the kind was recently under my own care, in the person of a man aged sixty, who had had a blow on the left side of the jaw six days before I saw him. I found a loose piece of alveolus three-quarters of an inch in length, and containing the left incisors and canine teeth, which was merely held by a portion of gum, there being no other injury to the jaw. The preparation is now in the Museum of the College of Surgeons. (879.)

In fracture of the lower jaw in children—a very rare accident—when the fracture happens to involve the cavity in which a permanent tooth is being developed, exfoliation of the tooth, with a portion of the alveolus, is almost certain to ensue, as was noticed by Mr. Vasey in a case occurring in St. George's Hospital.

*Paralysis and Neuralgia from injury to the inferior dental*

21-



## 18      COMPLICATIONS OF FRACTURE OF LOWER JAW.

nerve may be the immediate result of the accident, or be caused at a later period by some pressure arising from the development of callus. In by far the greater number of cases no injury of the nerves accrues, and this may be partly explained, as Boyer originally pointed out, by the fact that "the greater part of these fractures takes place between the symphysis and the foramen by which the nerve comes out."

A case of paralysis of the inferior dental nerve, from a gunshot wound of the ramus, which was under my care some years ago, will be subsequently referred to; and Malgaigne describes a specimen, in the Musée Dupuytren, also the result of gunshot injury, in which the dental nerve was ruptured, and its canal obliterated at the seat of fracture. (See Fig. 7.)

Temporary paralysis of the inferior dental nerve must be of rare occurrence, since Malgaigne did not meet with it; and Hamilton thinks that "the explanation may be found in the fact that the fragments seldom overlap to any appreciable extent, and that even the displacement in the direction of the diameters of the bone is generally inconsiderable, or, if it does exist, it is easily and promptly replaced." He thinks, moreover, that temporary anæsthesia of the chin might not improbably be overlooked at first, and would have ceased by the time the apparatus was removed. A. Bérard saw a case of vertical fracture without displacement between the second and third molar teeth, in which complete temporary anæsthesia of the lip and chin as far as the median line existed (*Gazette des Hôpitaux*, August 10th, 1841). A case of temporary paralysis of the dental nerve, from fracture, is mentioned also by Robert (*Gazette des Hôpitaux*, 1859, p. 157), occurring in a woman, aged sixty-four, who was run over by a carriage, and who also suffered from fracture and displacement of the malar bone, with *permanent* anæsthesia of the infra-orbital nerve.

The cases of convulsions coincident with fracture of the jaw, recorded by Rossi and Flajani, would appear to have been due to injury of the brain, the result of the original accident and unconnected with the fracture, but it



may happen that direct injury may be inflicted on the skull by the broken jaw. Thus Dr. Lefèvre (*Journal Hebdomadaire*, 1834) gives the case of a sailor, aged twenty-two, who fell from a height upon his chin with the following result. There was almost complete inability to open the mouth, the jaws being tightly closed and the lower drawn backwards and a little to the left. There were tenderness and ecchymosis in the left temporo-maxillary region, and a little blood flowed from the left ear. The case was diagnosed to be one of fracture of the neck of the condyle. The man died six months after with brain symptoms, and on opening the head, the left glenoid cavity was found driven in, with a starred fracture of the temporal bone, between the fragments of which the condyle of the jaw was found. There was a large abscess in the brain.

Similarly in the Museum of St. George's Hospital, there is a temporal bone with the unbroken condyle of the inferior maxilla driven through the glenoid cavity, producing a fracture of the middle fossa of the base of the skull in a case where there was an extensive comminuted fracture of the jaw itself, which, however, is not preserved. In contrast with this, may be mentioned another case which also occurred in St. George's Hospital, and the details of which will be found in the Appendix (Case II.), where the neck of the condyle and the base of the coronoid process having been broken through, the lower fragment was displaced and had produced laceration of the meatus auditorius externus, separating the cartilaginous from the osseous portion for nearly half its circumference. In this case considerable serous discharge flowed from the ear, leading to the suspicion of injury to the skull, but there were no brain symptoms, and the patient dying with *delirium tremens*, the skull, the membranes, and the brain were found perfectly healthy.

In connexion with these cases may be mentioned those recorded by M. Morvan (*Archives Générales*, 1856), who gives two cases of his own, and one by Montezzia, where a blow on the chin was followed by bleeding from the ear;



## 20 COMPLICATIONS OF FRACTURE OF LOWER JAW.

and one case by Tessier, where a double fracture of the jaw from a kick by a horse was followed by bleeding from both ears. In all these instances the patients recovered.

An instance of neuralgia, consequent upon old fracture of the lower jaw, occurred in St. Bartholomew's Hospital in 1863. Mr. Wormald, under whose care the patient was, opened up the dental canal and excised a portion of the inferior dental nerve with the most satisfactory result. (*Medical Times and Gazette*, April 4th, 1863.)

*Abscess* is not a very uncommon complication of severe injuries of the jaw, the matter pointing below the bone, and being in some cases probably as much the result of injudicious pressure by retentive apparatus as of the injury. A certain amount of pus commonly finds its way into the mouth through the lacerated gum in all cases of severe fracture, but the exit is usually sufficient to prevent the occurrence of abscess within the mouth. In neglected cases of fracture, the abscess may be connected with necrosis, and may open at some distance down the neck, and remain patent for many months; thus I am indebted to Mr. Margetson, of Dewsbury, for a case where, in consequence of a neglected fracture (which from the twisting of the face to the left side would appear to have been one of the neck of the left condyle), three years after the receipt of the injury there was still a fistulous opening on the left side of the neck, about two inches below the angle of the jaw.

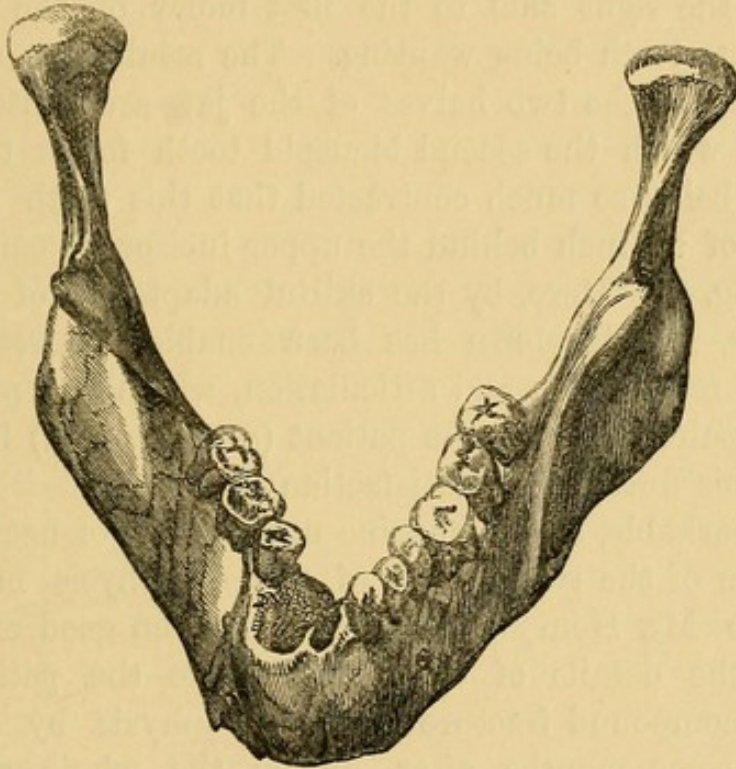
*Salivary fistula* may result from a compound fracture of the lower jaw, or from an abscess bursting externally in the case of a simple fracture. The treatment would of course be that for salivary fistula, arising from other causes, such as necrosis, &c. In the Appendix will be found a case (Case III.) occurring under the author's care, in which a salivary fistula was connected with necrosis and false joint in the ramus of the jaw, following a gunshot injury, and which was successfully closed.

*Necrosis* to the extent of small portions of the alveolus not unfrequently follows fracture of the jaw, and without any permanent deformity occurring; but when the necrosis



affects the whole thickness of the bone, as may happen when the fracture is comminuted, and a portion becomes so detached as to lose its vitality, the consequent deformity may be very great. Of this a specimen in St. George's Hospital

FIG. 4.



Museum (fig. 4) affords a good example, a loss of substance to the right of the symphysis having occurred, leading to the union of the halves of the bone at an acute angle.

FIG. 5.

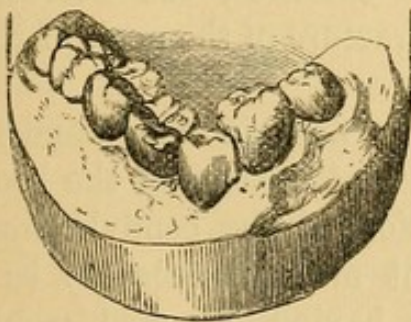
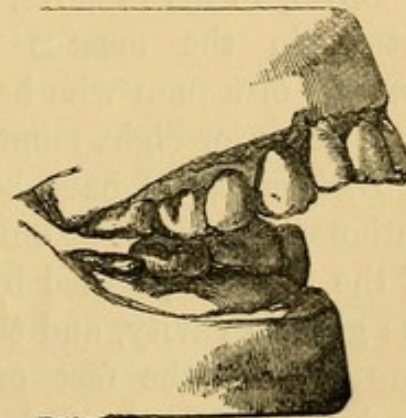


FIG. 6.



A still better example of the same kind of deformity, and from a similar cause, is seen in fig. 5, taken from a model



lent to me by Mr. Hepburn. The patient several years ago received a kick from a horse, which produced a compound comminuted fracture of the lower jaw. The central portion became necrosed and was removed by the late Mr. Aston Key, and appears to have extended from the second bicuspid tooth of the right side to the first molar on the left, the intervening teeth being wanting. The result, as seen in the model, is that the two halves of the jaw are united at an angle, of which the second bicuspid tooth forms the apex, the jaw being so much contracted that this tooth is three-quarters of an inch behind the upper incisor, as can be well seen in fig. 6. Here, by the skilful adaptation of artificial apparatus, Mr. Hepburn has been enabled to restore the power of mastication and articulation, which was previously much impaired, so that the patient (a clergyman) is able to perform his duties with satisfaction.

A remarkable, and I imagine unique, case of necrosis and exfoliation of the two halves of the symphysis menti occurred to Mr. Henry Power, who has been good enough to give me the details of the case. Here the patient sustained a compound fracture of the symphysis by a severe fall, and some months after, during the whole of which time profuse suppuration was going on in the part, two thin lamellæ of bone, apparently the surfaces of the symphysis, came away, after which rapid solidification of the fracture ensued.

Boyer, in his lectures, mentions having extracted from a fistula in the meatus auditorius externus, the necrosed condyle of a man who had had a fracture of the neck of the bone seven or eight months before.

*Dislocation.*—I have been able to find, in the standard authors, the records of only two cases of fracture of the body of the jaw complicated by dislocation of the condyle from the glenoid cavity, and the accident must of necessity be a rare one, for the fact of fracture having occurred would tend to prevent the dislocation, since the leverage necessary would thus be interfered with. The cases in question are given by Malgaigne in his work on "Dislocations," one being



recorded by Delamotte, who saw a fracture of the body of the jaw with double dislocation, produced by the kick of a horse in a girl of between eleven and twelve years. The other was a more remarkable case, recorded by Robert, who saw a dislocation of the left condyle *outwards*, with fracture of the jaw in front of the right ramus, in a man who was knocked down on his left cheek, the wheel of a carriage passing over the right.

A third case, however, is reported by Mr. Croker King (*Dublin Hospital Gazette*, 1855), and occurred in a boy of eight, who suffered a fracture at the symphysis with dislocation of the left condyle upwards and backwards. There was bleeding from the ear, and the chin was much retracted and turned to the left; the mouth was open, but could be closed, and it was then observed that the lower molars overlapped the upper, but that the lower incisors were at least one inch *behind* the upper. Reduction was easily effected, and the case did well. (Owing to an obscurity and apparent contradiction in the report, this case has been put down by Weber as an instance of unusual dislocation *without* fracture.)

A fourth case of the kind is also briefly referred to by Mr. Gunning, of New York, in his paper on "Interdental Splints." (*New York Medical Journal*, 1866.) "The patient was thirty-six years old; the jaw was fractured through the symphysis and the right condyle dislocated *outward* and *backward*, February 10th, 1866, in falling down stairs and striking the chin on a small desk." The dislocation was reduced before Mr. Gunning was called in.

The case of fracture of the glenoid cavity by the displaced condyle in St. George's Hospital, already referred to, cannot be regarded as one of true dislocation. The treatment in these cases would of course be reduction of the dislocation before setting the fracture.

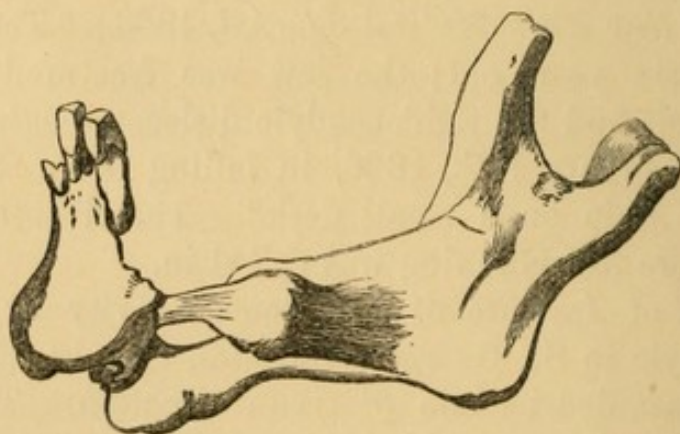
In fractures of the neck of the jaw the condyle itself has been found displaced. Thus Holmes Coote (in his article on Injuries of the Face, Holmes' "System of Surgery," vol. ii.) mentions that Bonn, writing in 1783, gives an account of a case of the kind. There was a longitudinal fracture in the



middle of the bone, and at the same time the right condyle was broken off and dislocated forwards and inwards, lying united by callus near the foramen ovale. The pointed upper extremity of the neck of the lower jaw articulated with the glenoid cavity, and the separated head with the lateral part of the tubercle of the temporal bone. There was motion in the false joint. The same author mentions a case of fracture and dislocation of both condyles of the lower jaw, in a young man who had numerous injuries and lived five weeks. The condyles were found to be broken off, and fixed near the foramen on either side.

*Irregular Union.*—Where the displacement of the fragments has been great, it may be impossible to keep them in proper position, and the result may be an irregular union of the bone, interfering more or less with its functions in after-life. This is particularly liable to occur in cases of double fracture, where the central portion of the jaw is much displaced by the muscles attached to it; and Malgaigne gives a drawing from a specimen of the kind in the Musée Dupuytren (fig. 7), in which the middle fragment

FIG. 7.



is displaced downwards and backwards, and has also undergone such a change of position that its lower border is inclined forward, and its anterior surface looks almost directly upwards, the union on one side being partly fibrous.

An almost precisely similar state of things existed in a case of double fracture which came under Mr. Bickersteth's



care, and which will be found in detail under the head of "Treatment of Ununited Fracture," the central portion of the jaw having become much depressed, and united on one side, so that when the molars were in contact the incisor teeth were separated more than half an inch, the opposite fracture being still ununited. Here Mr. Bickersteth remedied the deformity by sawing through the bone at the seat of the united fracture, and replacing the fragment in its proper position.

The specimen of united fracture in University College Museum illustrates very well the effect of irregular union upon the teeth, and the masticatory power of the jaw. The fracture was in the right molar region, and appears to have led to the loss of all the teeth on that side except the last molar. The irregular union has resulted in a contraction of the alveolar arch, so that the left teeth have been thrown within those of the upper jaw, with the result of wearing away the opposed surfaces of the two sets—viz., the lower teeth on their outer and the upper on their inner surfaces. Hamilton expresses an opinion, "that time and the constant use of the lower jaw in mastication will gradually effect a marked improvement in the ability to bring the opposing teeth into contact." The specimen above referred to illustrates the only mode in which such an improvement could, in my opinion, occur.

The deformity resulting from loss of a portion of the bone near the symphysis, has been already referred to under the head of "Necrosis." Loss of substance in other parts of the jaw is apt to result in fibrous union or false joint, and this is especially the case in gunshot injuries.

*Non-union and False Joint.*—Fractures of the lower jaw ordinarily unite with great rapidity and certainty, notwithstanding the difficulties often met with in maintaining perfect apposition of the fragments. Hamilton has noticed one instance, in an adult person, in which the bone was immovable at the seat of fracture on the seventeenth day, and says that in no instance under his own observation has the bone refused finally to unite, although union has been



## 26 COMPLICATIONS OF FRACTURE OF LOWER JAW.

delayed as long as eleven weeks. Cases of non-union and false joint have, however, been recorded and treated by Physick, Dupuytren, and others; and a case has already been referred to which occurred under my own care, in which false joint followed a gunshot injury of the ramus of the jaw. (See Appendix, Case III.) The liability of the lower jaw to false joint, as compared with other bones, may be gathered from a table of 150 cases drawn up by Norris (*American Journal of Medical Sciences*, January, 1842). Of these 150 cases 48 occurred in the femur, 48 in the humerus, 33 in the leg, 19 in the forearm, and two in the lower jaw.

Non-union may be simply the result of neglect of treatment, and union may take place readily as soon as the parts are placed under favourable circumstance. Thus a patient was under Mr. Wormald's care who, five weeks before admission into St. Bartholomew's Hospital, had fractured his jaw between the canine and bicuspid teeth on the left side, for which he had not been treated. There was some little necrosis, and sinuses had already formed beneath the chin; but under appropriate treatment the bone thoroughly united in five weeks. (*Medical Times and Gazette*, Jan. 17, 1863.) And yet, on the other hand, fracture of the jaw has no doubt been occasionally untreated, and still has united. Thus Boyer saw consolidation occur, though not without deformity, in a water-carrier who would not endure any dressing, nor abstain from either speaking or chewing when the pain did not prevent him. Notwithstanding the most careful treatment, however, the jaw may fail to unite if the case has been complicated in any way. Thus Mr. Berkeley Hill mentions a case (*British Med. Journal*, March 2, 1867) of double fracture, where great difficulty was experienced in adapting suitable apparatus, and where one fracture united perfectly, but the other remained ununited. And again, on the other hand, over-solicitous attention appears occasionally to interfere with union; for A. Bérard relates the singular case of a child whose fracture made no progress towards recovery till the apparatus, an ordinary bandage, was removed; and Mr. Hill's case, mentioned above, illus-



trates the same point, for he informs me that the second fracture became consolidated without any treatment.

The occurrence of necrosis at the point of fracture is the most probable cause of non-union, and a small amount of this may prevent, or at least delay, the union taking place, as in Mr. Power's case, where two thin lamellæ exfoliated from the symphysis; and, moreover, callus is not thrown out so copiously for the repair of fractures of the jaw as it is in the long bones. Gunshot injuries seem especially liable to produce ununited fractures of the lower jaw, probably by inducing necrosis; and of this an example under the author's care has been already alluded to. On this subject the late Dr. Williamson, of Fort Pitt, has made the following observations in his work on "Military Surgery," p. 22:—

"Ununited fracture of the lower jaw does not seem to have been of such frequent occurrence amongst the wounded from the Crimea as those from India. Six were admitted from India with fracture of the lower jaw. Of these three were invalided, two sent to duty, and one to modified duty. Of these six cases, three were instances where the fracture remained still ununited, though the ends of the bone were in contact. In one case the ball struck one side of the lower jaw, and was cut out on the opposite side one month after, fracturing the bone on both sides. In one, the ball was cut out from below the tongue. In one case, from a shell wound, there was a double fracture, one on the right side of the ramus, and also another near the symphysis, with great laceration of soft parts, and resulting deformity; the first-named fracture remained ununited. In another case there was a double fracture from a musket-ball; the fracture at the entrance of the ball still remains ununited; that at the exit has become united. In one case, from round shot, the whole of the left ramus of the lower jaw had been extracted at the time, or came away by exfoliation, leaving a large chasm and great deformity on this side of the cheek from laceration of the soft parts. In one case there was a fracture on the left side, at the angle of the jaw, still ununited.



"Attempts were made to excite action in the ends of the bone by forcibly rubbing together, and afterwards keeping the two fracture ends at rest by wire round the teeth, and a piece of cork placed between the teeth of the posterior fragment and that of the upper jaw, but without success. It was not thought advisable to try the effects of a seton or other means of inducing the effusion of new bone."

Rokitansky, in his "Pathological Anatomy" (Sydenham Society's Translation, iii. p. 216), describes the unnatural joints resulting from fracture as of two kinds; "one more or less resembling a synarthrosis, the other like a diarthrosis, and accordingly, in its proper sense, a new joint. In the former case, the fractured ends of the bone are held together by a ligamentous tissue. Either a disc of ligament the thickness of which may vary, is interposed between them, and allows of but little movement, or, as occurs when there has been loss of substance either from injury, absorption of the fractured ends, or otherwise, ligamentous bands connect the fragments, and allow them to move freely on each other. The connecting tissue appears to be nothing more than the intermediate substance, which has failed to become transformed into the secondary callus and remains in its first state.

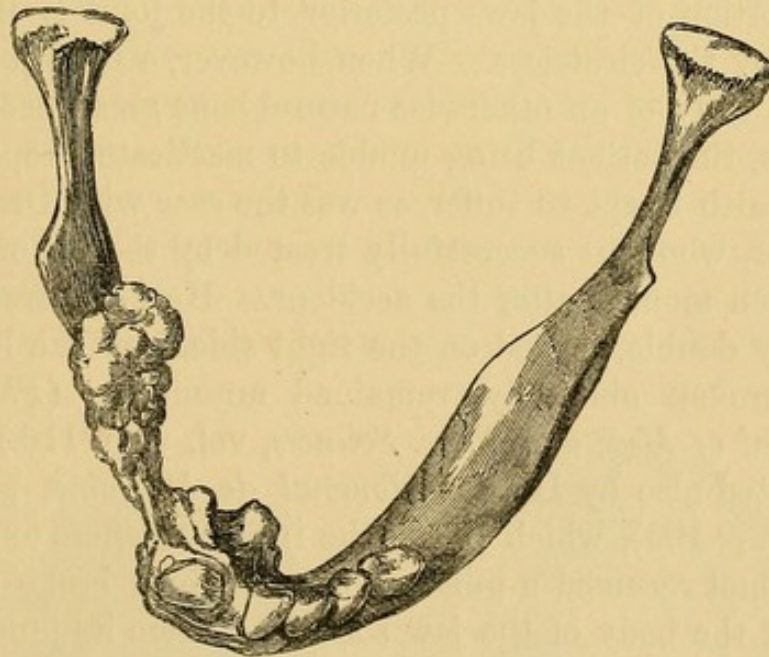
In the second case, a ligamentous articular capsule is formed, and is lined by a smooth membrane which secretes synovia. The fractured surfaces adapt themselves to each other and become covered with a layer of tissue which is fibro-ligamentous, or more or less fibro-cartilaginous, or which resembles and sometimes (Howship) really is cartilage. They may articulate immediately with one another, or may have between them an intervening layer of ligament which corresponds to an interarticular cartilage; and their movement upon each other is more or less free, according to the size of the articular capsule and the form of the articulating surfaces. These last are sometimes horizontal, (plane?) and smooth; they glide over each other, and allow of restricted motion; sometimes one surface becomes convex and the other concave; sometimes both are rounded off,



and lying within a capacious articular capsule far apart, they come in contact only during particular movements. The articulating capsule is the product of the inflammation of the soft parts; the cartilaginous layer which covers the ends of the bone is secondary callus arrested in its metamorphosis and converted into a fibroid tissue. The other ligamentous cords which are sometimes present, and the structures resembling an interarticular cartilage, are remnants of the intermediate substance. Both forms of new joint, but more particularly the synarthrodial form, have an analogue in the lateral new joints sometimes formed between the masses of callus thrown out around two adjoining fractured bones."

The only museum specimen of ununited fracture of the lower jaw I have met with is in University College (fig.8), and

FIG. 8.



belongs to Rokitansky's first division, since it is a good example of fibrous union filling the interval between the right canine tooth and the ramus of the jaw, there having evidently been considerable loss of bony substance at the seat of fracture. A very similar specimen is, I am informed, in the Museum of the Royal College of Surgeons of Edinburgh, the fibrous tissue extending from the symphysis to the left



### 30 COMPLICATIONS OF FRACTURE OF LOWER JAW.

bicuspid teeth. I have no doubt, however, that the other form, the true false joint, does occur in the lower jaw both as the result of violence (and particularly in the ramus of the jaw) and as the result of operative interference, having had the opportunity of watching the formation of a false joint in two cases in which I performed Esmarch's operation for closure of the jaws, which will be referred to in another part of this essay.

The amount of inconvenience which the patient experiences from an ununited fracture of the jaw will vary according to the position of the false joint. In the ramus it appears to give very little, if any, inconvenience, the new joint performing the function of the temporo-maxillary articulation; and the same may be said, according to my experience, of the false joints purposely made for the relief of closure of the jaws, although in the body of the bone, since the portion of the jaws posterior to the joint is immovably fixed by the cicatrices. When, however, a false joint occurs in the body of an otherwise natural bone great inconvenience results, the patient being unable to masticate properly; and his health is apt to suffer, as was the case with Dr. Physick's patient, who was successfully treated by the use of the seton eighteen months after the accident. Here the fracture, originally double, united on the right side, but the left, which was broken obliquely, remained ununited. (*Philadelphia Journal of Med. and Phys. Sciences*, vol. v. p. 116.) A case is related also by Horeau (*Journal de Médecine*, par Corvisart, x. p. 195), which shows the inconveniences experienced. A colonel received a gunshot wound which broke the right side of the body of the jaw some lines from its junction with the ramus, resulting in a false joint between the first and second molar teeth. In the ordinary condition of things these two teeth were on the same level, and they were not deranged even by pushing the fragments from behind forward or from before backward. But if the posterior fragment was raised and the anterior depressed, the second molar tooth was several lines above the level of the first. The result was great difficulty in chewing on the injured side, and



consequently the food was habitually carried to the left molar teeth, and its trituration was neither easy nor complete. The digestion became impaired, and the patient suffered from pain after food, &c. I have recently seen a gentleman whom I attended some years ago with Mr. Moger, of Highgate, and who had received most serious injuries of the face from the pole of a waggon. In this case the patient barely escaped with his life, owing to erysipelas and great constitutional disturbance. There was double fracture with extensive necrosis of the lower jaw, which has resulted in a false-joint on the right side ; but for this the patient has declined all treatment, whether surgical or mechanical, and though he is quite incapacitated for mastication, he is well nourished by means of food passed through a mincing-machine.

A remarkable case of ununited fracture in the mental region, the result of gunshot injury in the Crimea, is recorded by the late Mr. Cox Smith, of Chatham (*Dental Review*, 1858-9), and was satisfactorily treated mechanically by that gentleman. The condition of the parts was briefly as follows:—The symphysis with the incisors, right canine, and one bicuspid tooth, having been carried away, the jaw was divided into two unequal portions, which fell together when at rest ; but upon opening the mouth

FIG. 9.

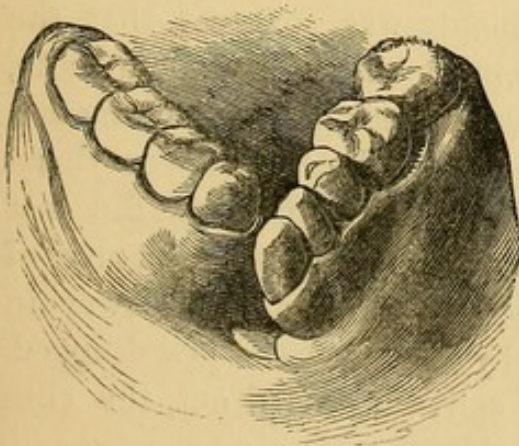
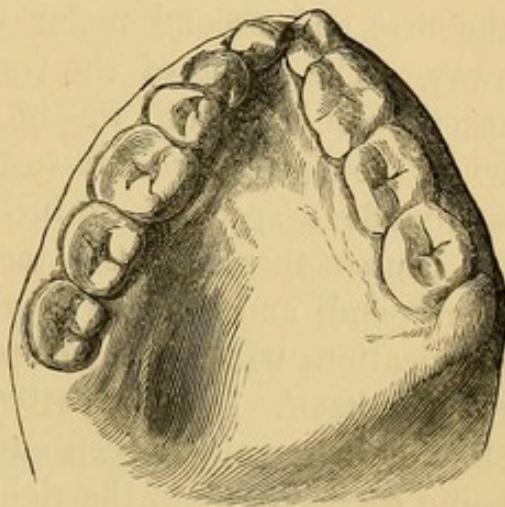


FIG. 10.



the left only was fully acted upon by the muscles and the right rode over it, as shown in the illustration



## 32 COMPLICATIONS OF FRACTURE OF LOWER JAW.

(fig. 9). Much pain was caused by any attempt to separate the two fragments so as to make them correspond to the teeth of the upper jaw; hence mastication was impossible, articulation was much interfered with, and the patient could only sleep on his back, since lying on either side caused displacement of the corresponding section of the jaw. Fig. 10 shows the model first taken by Mr. Smith, and its resemblance to cases of united fracture with loss of substance in the incisor region previously described, will be at once noticed. The treatment of this interesting case will be referred to under another section.

The case of ununited fracture successfully treated by Dupuytren was also the result of a gunshot injury, and the following was the condition of the parts when the patient came under that surgeon's care, four years after the receipt of the injury (Dupuytren's *Leçons Orales*, vol. iv.). The ball had struck the right side of the jaw just in front of the masseter, and had carried away a portion of the bone at the junction of the body with the ramus. The posterior fragment, which contained the wisdom tooth, was twisted so that the tooth looked towards the tongue, and at the same time was drawn outwards into the cheek. The anterior fragment formed by the remainder of the bone was displaced so that its fractured end was carried to the right side and below the other, an interval of an inch intervening, corresponding to the first and second molar teeth which had been carried away. The riding of the fragments was so great that the second bicuspid tooth was in contact with the wisdom tooth, when the parts were left to themselves; but, when traction was made, a space of an inch was produced between them. Of course therefore the teeth of the two jaws did not correspond, and there was consequently great difficulty of mastication, which was increased by the want of power in the jaw itself. If unsupported by a bandage the jaw dropped, the mouth remained open and saliva dribbled out, the chin being carried over to the right side.



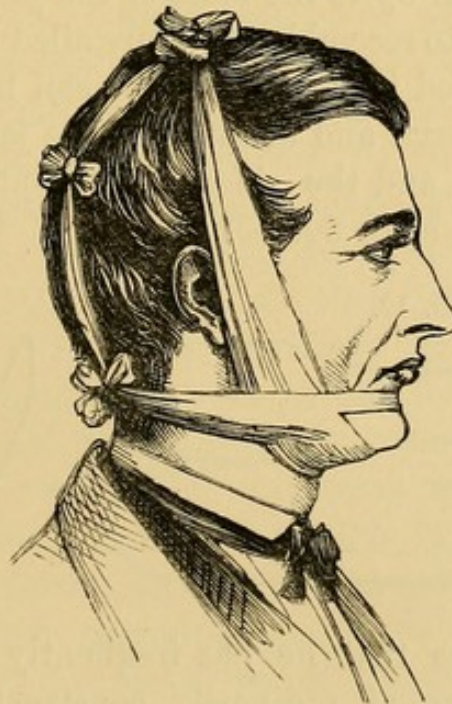
## CHAPTER III.

## TREATMENT OF FRACTURED LOWER JAW.

THE treatment of fractured lower jaw after the reduction of any displacement, the occasional difficulties of which have been alluded to in a previous section, is usually of a simple character; but cases sometimes arise in which the most carefully adapted mechanical contrivances fail to effect a good union. The apparatus employed for the maintenance of the fractured portions in apposition may be conveniently divided into two classes, external and internal to the mouth, though it may be necessary to combine the two methods in a few instances.

The simplest form of external apparatus consists of the

FIG. 11.



ordinary four-tailed bandage or sling, with a slit for the chin to rest in (fig. 11). This is made of a piece of bandage



about a yard long and three inches wide, which should have a slit four inches long cut in the centre of it, parallel to and an inch from the edge. The ends of the bandage should then be split to within a couple of inches of the slit, thus forming a four-tailed bandage with a hole in the middle. The central slit can be readily adapted to the chin, the narrow portion going in front of the lower lip, and the broader beneath the jaw; and the two tails corresponding to the lower part of the bandage are then to be carried over the top of the head, while the others are crossed over them and tied round the nape of the neck. The ends of the two bandages may then be knotted together, as seen in the illustration.

A single roller may be employed to support the jaw, as recommended by the American surgeons Gibson and Barton; but this is more difficult of application, and is more apt to become disarranged.

Combined with the sling, a well padded splint of either pasteboard or gutta-percha may be often advantageously employed. The material which is selected being cut long enough to pass well up to the sides of the jaw, is to be divided at the ends, so as to resemble the four-tailed bandage (fig. 12). Being then softened in warm water it can be lined with lint or some soft material and adapted to the jaw, the chin resting on its centre, and the sides being doubled around and beneath the bone, as in fig. 13.

FIG. 12.

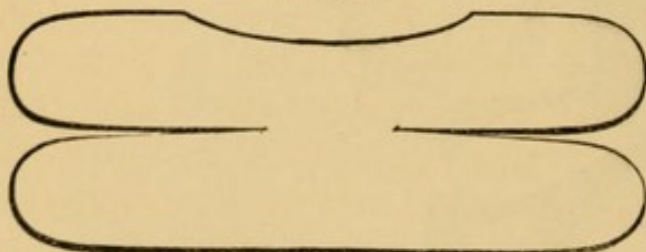
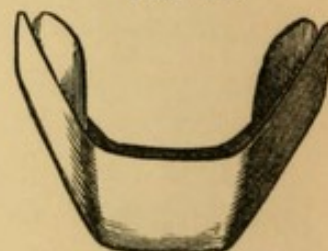


FIG. 13.

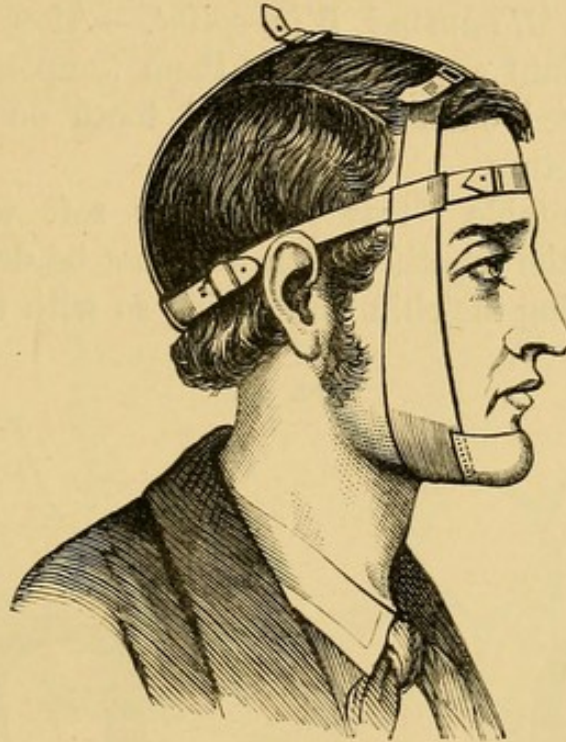


Hamilton states that he has frequently noticed the tendency of the sling, as ordinarily constructed, to carry the anterior fragment backwards, especially when there is a double fracture. He has devised a special form of apparatus (fig. 14)



for which he claims the following ;—" The advantage of this dressing over any which I have yet seen consists in its capability to lift the anterior fragment vertically ; and, at

FIG. 14.



the same time, it is in no danger of falling forwards and downwards upon the forehead. If, as in the case of most other dressings, the occipital stay had its attachment opposite to the chin, its effect would be to draw the central fragment backwards. By using a firm piece of leather as a maxillary band and attaching the occipital stay above the ears, this difficulty is completely obviated."

Ligature of the teeth with silk or wire is a method which has frequently been employed for the treatment of fractured jaw, but is unsatisfactory, from the loosening of the teeth and irritation of the gums which are apt to be produced. When employed, care should be taken to select, if possible, perfectly sound teeth around which to apply the ligature, which should be prevented from sinking down to the neck of the tooth so as to cut the gum. An astringent wash should be frequently employed during the treatment to maintain the healthy firmness of the gums themselves.

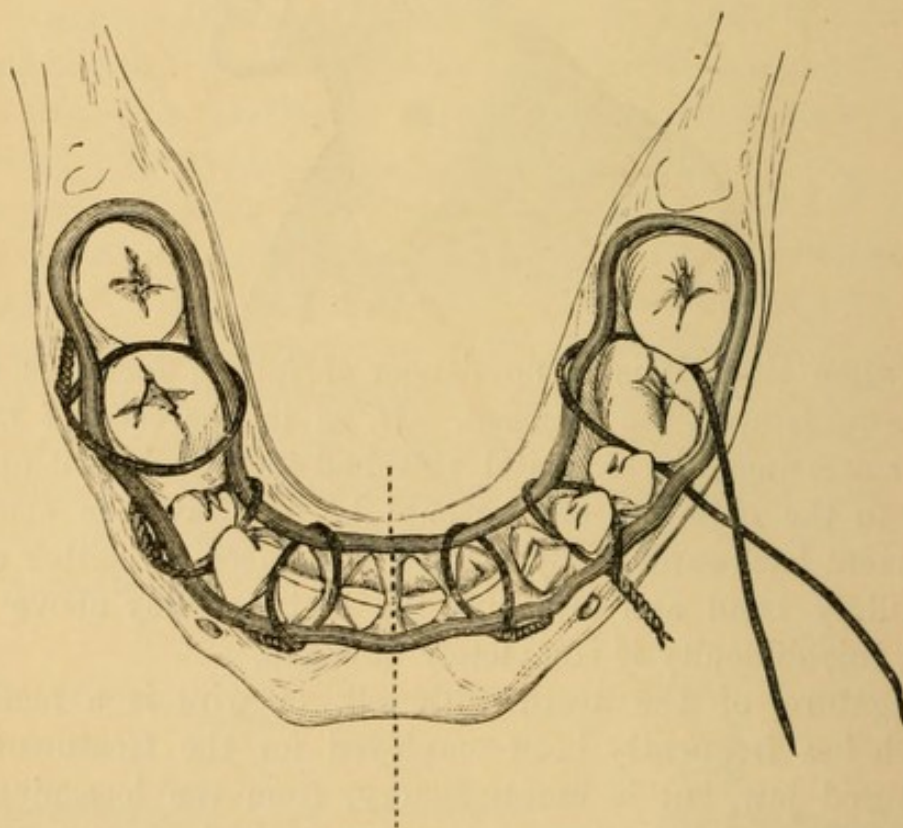


A more satisfactory apparatus is the wire-splint devised by Mr. Hammond, L.D.S., of Leinster Square, who has kindly supplied the following details of the method of applying it.

*To make the Hammond Wire-splint.*—After bringing the broken parts into apposition, tie them temporarily together with silk passed outside the second tooth on each side of the line of fracture.

With a suitable "tray" and very soft wax, take an impression of the mouth (which need not be deeper than the teeth), supporting the chin while doing so with the left hand.

FIG. 15.



Make a model of this in plaster of Paris in the usual way. If there has been any displacement of the parts, saw down between the teeth corresponding to the fracture, adjust the several pieces to the proper "bite," and fix in position.

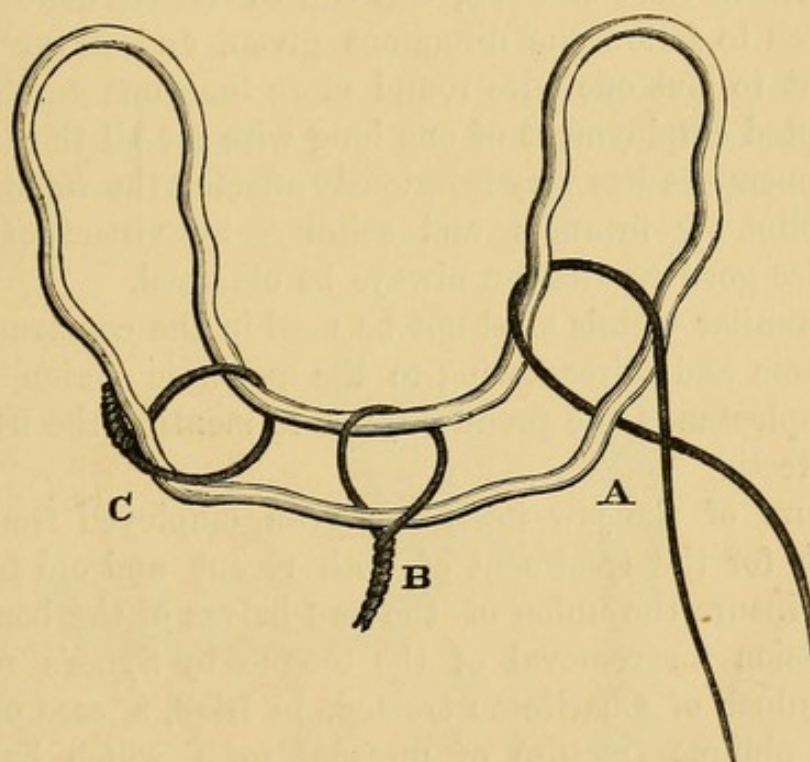
Now take a length of iron wire (stout hair-pin size) and carefully make a frame to fit round the teeth, soldering the ends together with silver solder. Cut several five-inch



lengths of fine soft iron binding wire—both ends of which should be cut to points, which will greatly facilitate the passing of them through the tartar between the teeth. Should there be much tartar a fine “broach” may be necessary.

*To apply the Splint.*—Place the patient upright in a high-backed chair, and rinse the mouth. Slip the frame over the teeth, holding it gently in place with the left hand, and

FIG. 16.



with the right hand take one of the pointed wires and pass it between the first and second molars on the left side, directing it slightly downwards so that the end will come out under the inner bar of the frame. Have the forefinger of the left hand inside to feel for the point, and with it turn the wire upwards and outwards so as to avoid wounding the tongue. Then bring this wire back, as shown in fig. 16, *i.e.*, over the inner bar of the frame, and under the outer; cross the ends and turn them aside—repeat this on the right side of the mouth. When all the ligatures are passed, seize the ends of the first wire with a small pair of pliers, and twist them on each other nearly tight, doing the same



on the left side, and when the pressure is equalized cut off the wires about half an inch from the frame, as at B. Now twist all the ligatures quite tight, and tuck them away under the frame, as at C. The jaw will now be found perfectly firm, and the patient able to bite steadily on it without pain.

It will be found after a few days that the ligatures will require twisting a little tighter (owing to the movement of the teeth in their sockets), this can easily be done if care be taken to follow the directions given, and never on any account to put one wire round more than one tooth. The attempted employment of one long wire for all the teeth by some operators has very injuriously affected the reputation of this splint for firmness and solidity, by virtue of which qualities good results can always be obtained.

Dissimilar metals must not be used in the construction of the frame and wires, owing to the galvanic action set up and unpleasant taste produced, not to mention the irritation to the teeth.

Suture of the jaw itself has been employed from time to time for the treatment of both recent and old fracture, and to insure the union of the two halves of the bone after its division for removal of the tongue by Syme's method. Dr. Kinloch of Charleston treated, in 1858, a case of compound oblique fracture of unusual form, which has been already referred to (p. 9), by this method, after other means had failed. "A semi-lunar incision, about two inches long, was made upon the side of the face, the middle of the incision reaching under the base of the jaw. With Brainard's smallest-sized drill a perforation was made through each fragment, the drill being entered on the outside, close to the base of the bone, and about one-eighth of an inch from the rough extremity of each fragment, and made to traverse the bony tissue and the mucous membrane covering it within the buccal cavity. The drill was afterwards thrust between the fragments and turned about, so as to slightly lacerate the intermediate connecting tissue. A stout silver wire was then passed through the perforations in the bone,

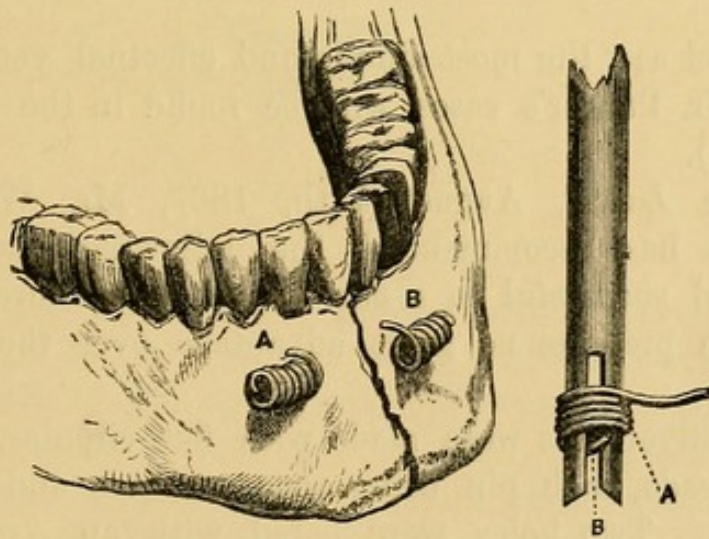


from without inwards through the posterior fragment, and in the contrary direction through the anterior one; and their ends were tightly twisted together, so as to bring the fragment into secure apposition.

"By the 26th of September good consolidation was effected, and the suture, which had occasioned but little suppuration, was untwisted and removed. On the 15th of October the patient left the hospital, with the fistulous opening healed and a good use of the jaw."—*American Journal of Medical Sciences*, July 1859.

Mr. Hugh Thomas of Liverpool has recently advocated the use of the wire-suture in the treatment of recent fractures, and two of his illustrative cases, which had most satisfactory results, will be found in the *Lancet*, January

FIG. 17.

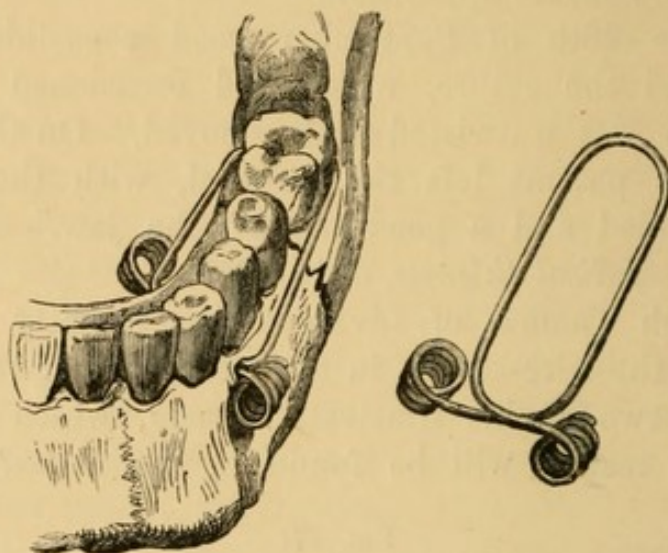


19th, 1867. This method has been more fully elucidated in a pamphlet, and consists either in drilling the fragments and passing a copper wire, each end of which is then coiled upon a "key" formed by a steel rod with a slit in it (fig. 17); or, in cases where the teeth are sound, in passing a loop of wire around the teeth on each side of the fracture, and then twisting it up with the key (fig. 18). The advantage of this method is that the wire can be tightened from time to time, as may be required during the treatment, without liability to breakage. I have employed it in a case of division of the



jaw for removal of the tongue, with advantage; and my friend Mr. Rushton Parker of Liverpool speaks highly of

FIG. 18.



the method as "the most simple and effectual yet devised." One of Mr. Parker's cases will be found in the Appendix (Case IV.).

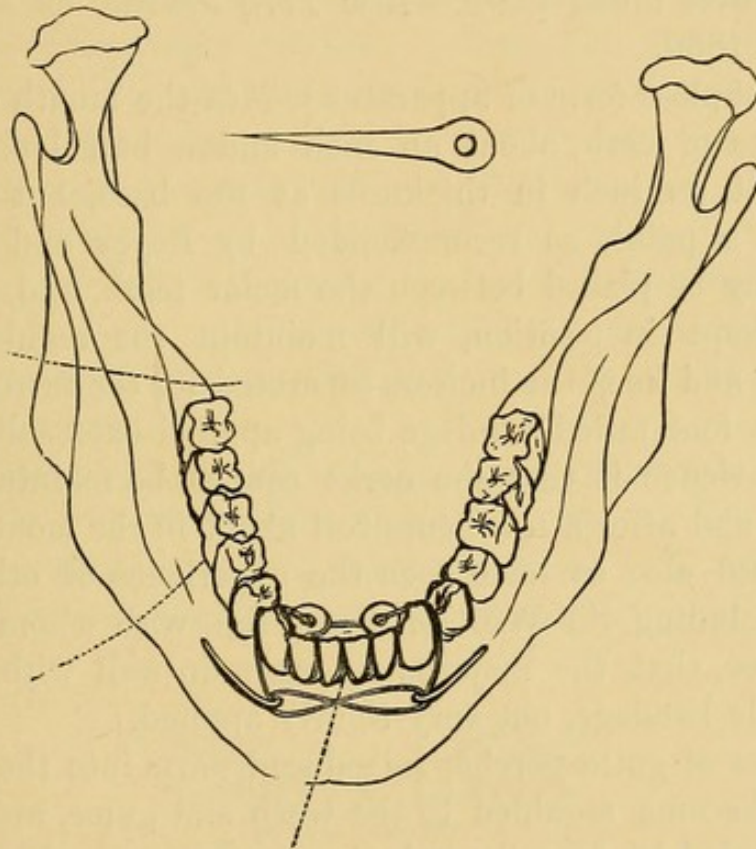
In the *Lancet*, August 17th, 1867, Mr. Wheelhouse of Leeds has recommended the following plan, which has proved successful in a case of triple fracture (fig. 19), but which presents no great advantage over the ordinary wire:—

"Two silver pins were made with flat, circular, and perforated heads, each pin being about an inch and a quarter in length. Two holes were bored with an Archimedian drill through the substance of the jaw-bone—one between the roots of the outer incisor and canine teeth of the unbroken side, and the second between the roots of the same teeth of the fractured side. Through these holes the two pins were passed from *behind forwards*, the perforated heads threaded with a good stout silk ligature, resting upon the floor of the mouth under cover of the frænum of the tongue. Having been well thrust forward through the drill-holes, the points were bent in opposite directions, the loose fragment was placed in good position, the ligature was brought



forward over the teeth, and a figure-of-8 suture was then made round the reversed ends of the pins."

FIG. 19.



According to Malgaigne, Guillaume de Salicet advised not merely to tie the adjacent teeth together, but to fasten them to those of the upper jaw. The necessity for such a contrivance must be very rare, but Dr. Fountain successfully treated a case of double fracture and fracture of the left condyle, which has been already referred to (page 13), by a somewhat similar method. "Holes were drilled through a front incisor of each jaw, and a double strand of fine annealed jeweller's iron wire was passed through and twisted so as to keep the parts in exact apposition, the central fracture, which gave no trouble, being supported by a pasteboard splint. In ten days the wires gave way, and a cord was inserted composed of four of the same wires; and in this way the jaw was held securely and immovably until all the fractures were united—viz., four weeks, during which time the patient was nourished by liquids, which were easily



drawn into the mouth through the teeth. Perfect union, without a particle of deformity, took place, and now, nearly four years after, no one would be able to tell that any fracture had ever taken place.—*New York Journal of Medicine*, January, 1860.

The simplest form of apparatus *within* the mouth consists of wedges of cork, about an inch and a half long and a quarter of an inch in thickness at the base, but sloping away to a point, as recommended by Boyer and Miller. These may be placed between the molar teeth, and, if they can be kept in position, will maintain the regularity of the teeth and keep the incisors separated for the introduction of food, a four-tailed bandage being applied externally. My own experience is that the corks cannot be maintained in position, and after a few hours roll about in the mouth; and this I find also to have been the experience of other surgeons, including Sir William Fergusson, with whom also I fully agree, that the majority of cases do well with merely the simple bandage, not very tightly applied.

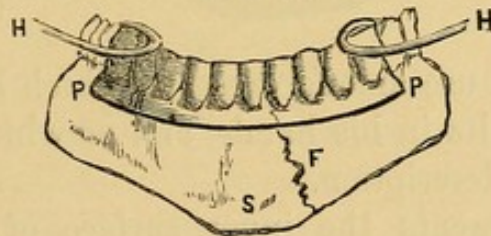
Wedges of gutta-percha, introduced warm into the mouth, so as to become moulded to the teeth and gums, are highly recommended by Hamilton, both as supports and, in some degree, as lateral splints for the fracture. Mütter's clamp, consisting merely of a plate of silver, folded over the tops and sides of two or more teeth adjacent to the fracture, is a contrivance which, in its original form, can have been but of little service, but as modified by Mr. Tomes and others is a very efficient method of treating fractures of the body of the jaw. The modification consists in making the silver cap fit accurately to the teeth, for some distance on each side of the fracture, by moulding it to a plaster cast of the jaw. The cap is then lined with gutta-percha, which, being warmed when the apparatus is applied, fills up interstices and fixes the cap, the fragments being maintained in position whilst the application is being made. Although the assistance of a dentist would be required for the proper preparation of the cap, it may not be out of place to notice the best method of obtaining a satisfactory model upon which the cap is to



be formed, for which I am indebted to Mr. Tomes. When the displacement of the fragments is great (as is invariably the case where such apparatus is required), it is best to take a cast of the jaw in wax, without attempting to bring the fragments into proper relation. Into this the plaster is poured, and, when set, a fac-simile of the displaced fracture is of course produced. By now sawing out the piece of plaster between the extremities of the fragments, these can be brought together, and a model of the perfect jaw will be produced, upon which the metal can be carefully fitted. When all is prepared, by carefully adjusting the fracture, the cap will of necessity fit and will maintain the fracture in its normal position.

Mr. Howard Hayward has been very successful in treating cases of fracture of the jaw, of both recent and old date, by silver caps, fitted accurately to the teeth on each side of the fracture, and also over the gum to the depth of half an

FIG. 20.



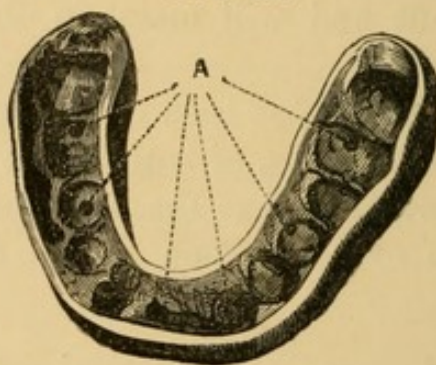
inch in front and a quarter of an inch behind them (fig. 20.) To the upper surface of the plate two pieces of stout curved wire are soldered, so as to turn round the angles of the mouth without touching them, and these are attached to a simple gutta-percha splint, moulded externally to the jaw, and retained in position by an ordinary four-tailed bandage. Holes drilled in the metal cap, opposite the point of fracture, permit of the exit of any discharge, but this is usually insignificant in quantity when the fracture is once properly set. Mr. Hayward prefers metal to vulcanite or gutta-percha for the cap, on account of its small bulk, and the consequent small interference with the natural closure of the mouth—a point of some importance, on account of the retention of the saliva.



Mr. Barrett, dental-surgeon to the London Hospital, has kindly shown me models of cases in which he has obtained most satisfactory results, by both metal and vulcanite interdental splints, secured in the mouth by small screws passing between the necks of the teeth. One of his cases was in a child, and here the delicate temporary teeth suffered no damage from the screws.

Mr. Gunning, of New York (*New York Medical Journal*, and *British Journal of Dental Science*, 1866), has contrived a form of interdental splint, composed of the vulcanite-rubber

FIG. 21.



now in common use among dentists, which has yielded very satisfactory results in his hands, and of which the following is a condensed description.

Fig. 21 represents the inner surface of a splint which incloses all the teeth and part of the gum of the lower jaw, and merely rests against the upper teeth when the jaws are closed. This splint is adapted to the treatment of all cases which have teeth on both sides of the fracture, except those with *obstinate* vertical displacement. The holes marked A go through the top of the splint, for the purpose of syringing the parts within with warm water during treatment. The dark round spots in all the cuts represent holes for similar purposes.

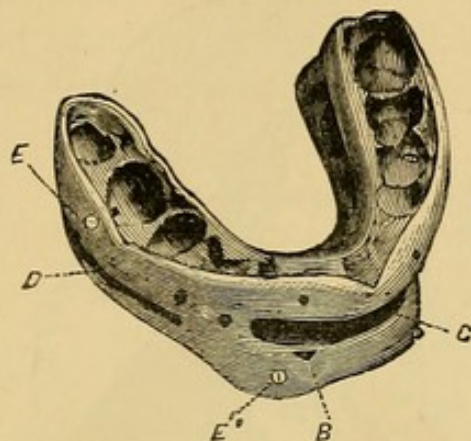
Mr. Gunning has generally used this splint without any fastenings, but in children, or even adults, it is sometimes advisable to secure it by packthread wire screws passing into or between the teeth, or by the wings and band of fig. 24.

In cases with obstinate vertical displacement, the splint,



in addition to fitting the teeth and gum of the lower jaw, must also inclose the upper teeth, as shown in fig. 22,

FIG. 22.



where screws may be seen opposite both the lower and upper teeth.

By this arrangement the fragments of the lower jaw are secured, not only relatively to each other, but also to the upper jaw. B, is a triangular opening, of which one side corresponds to the cutting edge of the lateral incisor, which stood in the end of the fragment most displaced before the splint was applied. C, an opening for food, speech, &c. D, a channel for the saliva from the parotid gland to enter the mouth, its fellow being seen on the other side of the splint. E', a screw opposite the lower canine tooth, the head of the fellow screw being just discernible. E, the head of a screw opposite the upper first molar tooth, the end of its fellow being seen on the other side.

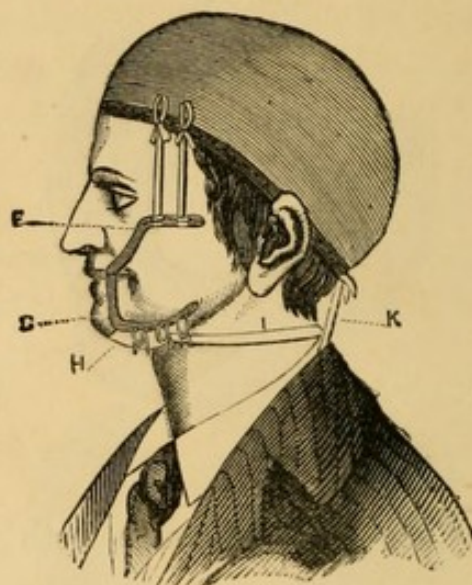
Fig. 23 shows the wings for cases *having no teeth in either jaw*—the ends of the wings within the mouth being imbedded in a vulcanite splint similar in principle to that of Fig. 22. F, upper wing. G, lower wing. H, mental band to hold the jaw up to the splint. I, neck strap to keep the band back. K, balance strap to hold the cap in place.

Wings made of steel may be quite light. They should have fine teeth along the edges where the bands and tapes bear to prevent slipping, and small holes every half-inch to hold the strings, lacing, &c. The arch of the wings should



be high enough to give the lower lip room to go well up. The wings for each side of the jaw are in one piece, and the

FIG. 23.



parts within the mouth pass back in the line of the upper gum. They are thinned down and pierced with holes, that the rubber in which they are imbedded may hold them firmly.

The tape strings pass from the cap inside and under the upper wings, then up between them and the tape lacings (fig. 23) which keep the strings from slipping, to the cap whence they started. The mental band passes up between the sides of the lower jaw and the wings, where it is tied by the strings, which pass through the holes. The band is cut off to show this; but when worn it should be turned down on the outside and pinned just below the wings. The neck strap should be sewed to the mental band on one side and pinned on the other, and worn tight enough to keep the band from slipping forward over the chin.

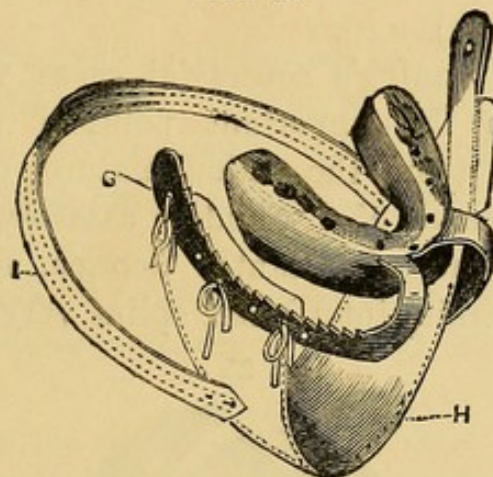
The jaw and splint are supported by the cap in front of its centre. This is counterbalanced by the elastic strap which passes from the back of the cap down around a non-elastic, and much heavier, strap, extending across and fastened to the shoulders by elastic ends. The balance strap returns to the cap, and is buckled tight enough to hold the jaw up. At night it may be slackened to do this with



the neck flexed. It slides on the shoulder strap as the head inclines to either side.

In order to meet the case of practitioners out of reach of a dentist, Mr. Gunning has suggested a splint made of tin and lined with gutta-percha (fig. 24) very much resembling Mr. Hayward's metal cap. Six or eight sizes are to

FIG. 24.



be cast and kept ready for use, from which one could be selected suitable for the jaw. The wings are of malleable iron, tinned to prevent rusting and for more readily soldering. Three sizes would probably be sufficient to select from.

The splint should have a handle in front that it may be used as a cup to take the impression of the jaw—the holes being useful to allow a small probe to be pressed through the wax down to the teeth, thus allowing air to enter to facilitate the removal of the impression, and when in use as a splint giving entrance to warm water, thrown from a syringe, to keep the parts clean.

The splint should be made to fit well by bending, cutting off the edges and rounding them smoothly. When a tooth projects so as to keep the splint from fitting, a hole may be cut to let the tooth through, if the metal cannot be hammered out. This should all be done before taking the impression, as a well-fitted cup assists greatly in this important matter.

(The adaptability of this splint is shown in the fact that the one from which the cut was taken had been used suc-

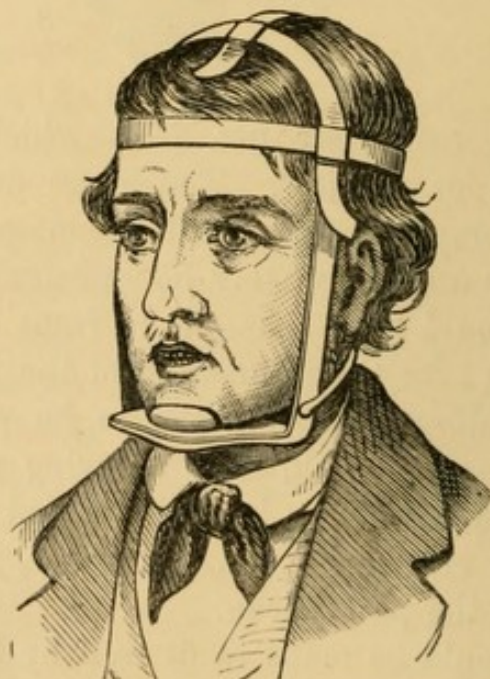

cessfully on two different jaws, so unlike that the first was a quarter of an inch wider, where the ends of the splints rested, than the second. When fitting it to the second jaw, it was necessary to cut off a part of the right wing, to keep it clear of the corner of the mouth. This accounts for the difference in the width of the arches as seen in the cut. The indentations on the top of the splints were made by the boys in eating.)

One of Mr. Gunning's successful cases was particularly interesting from the important political position of the patient, no less than the serious nature of the injuries, received at the hands of a would-be assassin.

Mr. J. B. Bean of Atlanta, Georgia, appears to have employed a vulcanite interdental splint very similar to Mr.

FIG. 25.



Gunning's, but with the addition of a mental compress, with great success among the wounded soldiers of the Confederate army, and his apparatus is very favourably reported upon by Inspector-General Covey. (*Richmond Medical Journal*, and *British Journal of Dental Science*, 1866.) Hamilton also speaks well of the apparatus in the fourth edition of his work on "Fractures," and gives an illustration, from which the accompanying drawing (fig. 25) is taken.



Dr. Covey writes :—" The adjustment of the splint to the fracture is very simple. It is inserted into the mouth of the patient ; the fragments drawn forward, and the teeth adjusted to their corresponding indentations. The jaws are then closed and held firmly in position by the application of the mental compress and occipito-frontal bandage ; this prevents any displacement of the splint or motion of the jaws.

The mental compress is designed for retaining the teeth in their indentations of the splint, by upward pressure applied to the base of the mental process, counteracting thus the traction of those muscles which most tend to cause displacement. There is an advantage also in relieving the parts from the lateral pressure produced by the four-tailed bandage or double-cross roller bandage, generally applied to these cases.

The compress is composed of a light piece of wood, which is four and a half inches in length, three-sixteenths of an inch in thickness, and one inch and a half in width in the middle, tapering to seven-eighths of an inch, and round at the ends ; to each of which is attached a metallic side-piece four or five inches in length, and from three-quarters to one inch in width ; also a shallow cup fitting the apex of the chin. Encasing these side pieces are the temporal straps made of stout cloth, and secured by a strong cord at the base of each piece.

The occipito-frontal bandage is composed of a band passing around the head, from the forehead to the occipital protuberance behind, and secured by a buckle one inch to the right of the median line behind ; of another strap secured to the band in front and behind ; and a third strap extending from the temporal buckles on either side, and secured to the middle strap at the point of crossing."

A combination of external and internal splints was invented by Rutenick, a German surgeon, in 1799, and improved by Kluge. It is thus described by Dr. Chester (*Medico-Chirurgical Review*, vol. xx. p. 471) :—" It consists, 1st, of small silver grooves, varying in size according as they are to be placed



on the incisors or molars, and long enough to extend over the crowns of four teeth ; 2nd, of a small piece of board, adapted to the lower surface of the jaw, and in shape resembling a horse-shoe, having at each horn two holes, one on either side ; 3rd, of steel hooks of various sizes, each having at one extremity an arch for the reception of the lower lip, and another, smaller, for securing it over the silver channels on the teeth, and at the other end a screw to pass through the horse-shoe splint, and to be secured to it by a nut and a horizontal branch at its lower surface ; 4th, of a cap or silk nightcap to remain on the head ; and 5th, of a compress corresponding in shape and size with the splint. The net or cap having been placed on the head and the two straps fastened to it on each side, one immediately in front of the ear and the other about three inches farther back, which are to retain the splint in its position by passing through the two holes in each horn ; a silver channel is placed on the four teeth nearest to the fracture, on this the small arch of the hook is placed, and the screw end having been passed through a hole in the splint, is screwed firmly to it by a nut, after a compress has been placed between the splint and the integuments below the jaw. If there is a double fracture, two channels and two hooks must of course be used."

Bush invented a similar apparatus in 1822, and Houzelot in 1826 ; since which the apparatus has been variously modified by Jousset, Lonsdale, Malgaigne, and perhaps others.

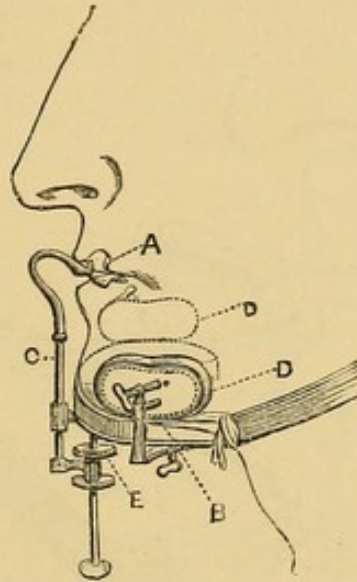
Lonsdale's apparatus, as Mr. Berkeley Hill remarks (*British Medical Journal*, March 2, 1867), "is only suited to cases of fracture between the incisors, as its ivory cap is too short to reach far along the arch of the teeth. It is also very cumbrous ; and causes great pain by the pressure under the chin necessary to keep the fragment in place, and by the jogging of the vertical part against the sternum."

Fig. 26 shows this apparatus somewhat modified by Mr Hill, to whom I am indebted for the illustrations. In the ordinary Lonsdale's apparatus, the rod carrying the



ivory cap (A) for the incisors slides freely up and down a bar projecting downwards from the chin-piece (B), and, when in the required position, is fixed by a pin. Mr. Hill has had a screw thread cut on the bar, on which a nut (E)

FIG. 26.



travels so as to force down the rod carrying the cap (A), and thereby approximate the cap on the incisors to the chin-piece.

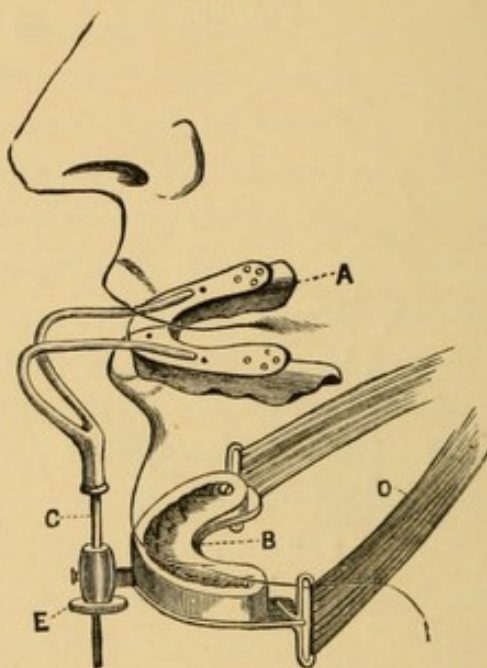
When this apparatus is to be applied, the fragments are placed in position by the hands, the ivory cap set on the incisors, and the chin-piece, which should be well padded with lint or wool stitched in wash-leather, brought up into place under the jaw, and the two made fast. The two cheek-pieces are then adjusted so as to press lightly on the jaw at each side, to prevent the apparatus from swaying aside out of place; and a tape is fastened to a hole at each end of the horse-shoe, and carried behind the neck, to keep the instrument from slipping forwards. So applied, Lonsdale's apparatus permits opening of the mouth for eating and speaking; and, if the fracture be single and between the incisors, it keeps the fragments in position very fairly.

Fig. 27 represents the modification of Lonsdale's splint, contrived by Mr. Berkeley Hill, for the treatment of a complicated case of double fracture in University College Hos-



pital in 1866, the ivory cap of the incisors being replaced by a metal mould of the alveolar arch, and the lateral pads removed.

FIG. 27.



Mr. Moon, of Guy's Hospital, has devised another modification of Lonsdale's splint, which has the advantage of being made in two halves (fig. 28 B B.) so as to fit any jaw exter-

FIG. 28.

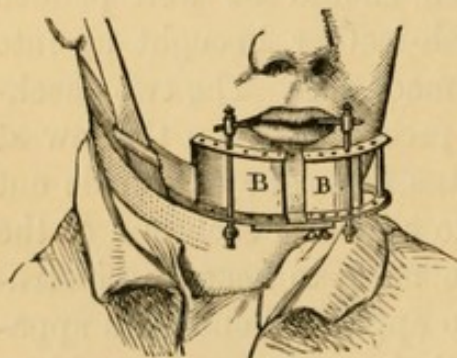
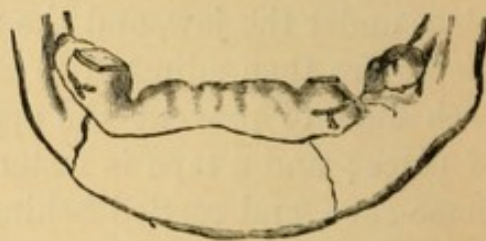


FIG. 29.



nally. The metal cap for the teeth (fig. 29) is kept in place by horizontal bars passing at the angles of the mouth, or may be used separately by being secured with wires.

The great difficulty in using all forms of rigid splints to the



jaw is the tendency of the support for the chin to produce abscess and ulceration by pressing upon the sharp border of the bone ; and the cases in which a simple metallic interdental splint would not effect a cure must be rare.

The treatment of fracture of the neck of the lower jaw, in those rare cases where the patient survives the injury and the nature of the accident is recognised, is sufficiently simple when there is no displacement, since the ordinary bandage will in most cases suffice. When, however, the condyle is displaced by the action of the pterygoideus externus, reduction must be effected as recommended by Ribes, by drawing the jaw horizontally forwards, and at the same time pushing the condyle outwards with the finger introduced far back into the mouth. Reduction being accomplished, the jaw must be pressed upwards and backwards to fix the condyle in the glenoid cavity, after which a bandage may be applied.

Gross says the best means to counteract the tendency of the external pterygoid to produce displacement is "to confine a thick graduated compress behind the angle of the bone, the treatment being in other respects the same as in fracture of the body of the jaw." (Gross's "Surgery," p. 967).

*The Treatment of Ununited Fracture of the Jaw.*—The causes of non-union of a fractured jaw have been described in a previous section. When the delay is due to a superficial necrosis, time for exfoliation to take place is all that is required ; when, however, the necrosis is extensive, or the loss of substance great, it is not desirable to produce union between the fragments, since thereby an unsightly deformity will be induced, which can be avoided by the use of apparatus to retain the parts in their normal relation. This subject will be referred to more particularly under the head of "Gunshot Injuries."

Dupuytren, in 1818, treated a case of ununited fracture, the result of a gunshot injury, in the person of a Russian officer (*vide* p. 32), three years after the receipt of the injury, by resecting the extremity of one fragment and rasping the other. In order to maintain the fragments in position the dentist Lemaire was called in, and devised the following



plan, the fracture being on the right side of the jaw:—  
 “First, to carry the posterior fragment inward, he united by means of a platinum wire the wisdom tooth in this fragment to one of the bicuspid of the other side; then, to carry the anterior fragment forward and lessen the overlapping as much as possible, a second wire was stretched from the first lower bicuspid on the right side to the first upper bicuspid on the left; and a third bound together the two canine teeth on the left side.” (*Vide* Malgaigne, and for the entire case Dupuytren’s *Leçons Orales*, vol. iv.) A cure was accomplished at the end of two months, but one of the wires had nearly bisected the tongue; and as it had gradually become embedded the flesh had closed over it, and it had to be cut and withdrawn.

Dr. Physick in 1822 treated a case, two years after the receipt of the injury, by the introduction of a seton between the ends of the bones. This was left *in situ* for three months, and induced suppuration and the discharge of fragments of necrosed bone, with an ultimate cure. (*Philadelphia Journal of Medical and Physical Sciences*, vol. v. p. 116.)

Suture of the fragments of bone would appear to offer the readiest means for keeping the two portions in apposition, and this plan has been successfully carried into execution by Mr. Bickersteth, of Liverpool, who, in his paper read before the Medico-Chirurgical Society in 1864, narrated two cases in which he had succeeded in producing union by fastening the two fragments together by means of a drill, or some similar contrivance.

The first case was a fracture of the lower jaw, in which the bones had united in such a position as to render the patient a most unsightly object. As the incision that would have been necessary in this instance for the purpose both of putting the bone into proper position and removing deformity of the soft parts, would not have allowed the use of external splints or supports; and as it was found impracticable to effect this object by fixing the teeth by an appliance within the mouth, it was absolutely necessary that



some means should be devised by which the divided portions of the jaw could be securely fixed. It occurred to Mr. Bickersteth that pegs or nails would answer the purpose, especially as he had already observed their presence caused so little inconvenience. Accordingly, at the operation the apposition of the fractured portions was secured by means of two round-headed nails. They most effectually answered their purpose, and no external splint or bandage was required. The case did well, no undue action being set up. On the twenty-second day after the operation one of the nails came away. The patient left the infirmary perfectly well, the jaw being firmly united in its proper position, and the deformity of the soft parts removed. One of the nails remained in, and the last accounts state that its presence caused no inconvenience. The second case recorded was one that presented many points in common with the one just narrated. No external incision was made, and ordinary drill-heads were substituted for nails. The result was everything that the operator could have wished.

Dr. Cooper, of San Francisco, treated successfully an ununited fracture of the lower jaw by silver sutures. In the report of the case the exact seat of the fracture is not given, but it was evidently in the body of the bone. The periosteum was dissected up, the ends of the bone bared, after which they were carefully united, and the case did well. (*Philadelphia Medical and Surgical Reporter*, 1862, and *Medical Circular*, July 23, 1862.)



## CHAPTER IV.

## FRACTURE OF THE UPPER JAW.

FRACTURES of the upper jaw are not nearly so common as those of the lower, though their results are often more serious, owing to the great violence necessarily undergone. As in the lower jaw, fractures of the alveolus may result from the extraction of teeth, and particularly from the use of the "key;" and so well ascertained was this fact, that in former days even, when the key was recommended and employed extensively, Mr. Thomas Bell ("On the Teeth," p. 301) proscribed its use in extracting the upper wisdom teeth on account of the danger of producing fracture of the tuberosity of the maxilla, against which the fulcrum would rest. A fracture thus produced may extend to the palatine process, and even to the palate bone, and might, if extensive, give rise to necrosis and subsequent exfoliation of large portions of bone.

Fractures of the upper jaw may be produced indirectly by falls on the face; thus Liston ("Practical Surgery," p. 55) narrates the case of a man who, slipping on a slide in the street, fell and struck the *malar* bone of the left side; he had sustained a vertical fracture through the orbital process of the superior maxilla.

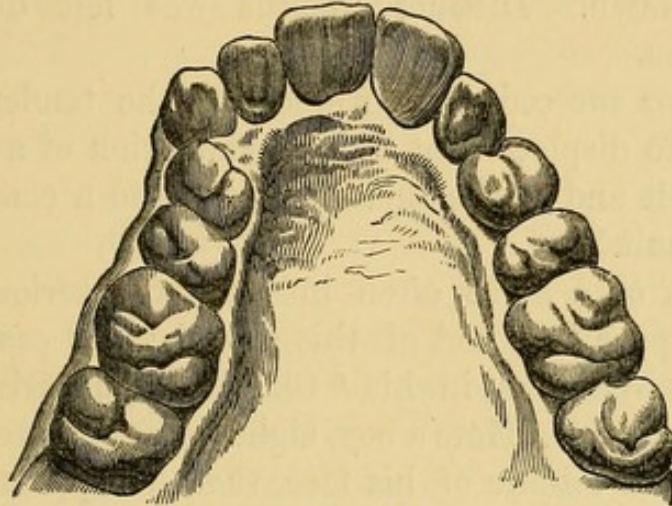
Direct blows upon the bone itself are, however, the most frequent causes of fracture, and these, from the nature of the injury, are often compound.

Mr. James Salter has recorded a case (*Lancet*, June 16, 1860) of a young gentleman who sustained fracture of the upper jaw from violent contact with a fellow-cricketer's forehead. Here fortunately none of the incisor teeth were knocked out, as so frequently happens in accidents of the



kind ; but a fracture of the bone was produced immediately behind the right canine tooth, which extended backwards so

FIG. 30.



Drawing from the plaster cast of the upper jaw, inverted.

FIG. 31.

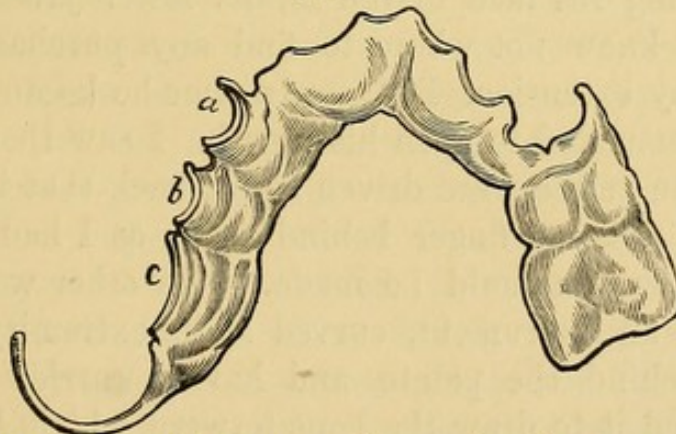


Illustration of the gold plate or splint ; *a*, *b*, and *c* corresponding to the first and second pre-molars and first molar respectively.

as to include the alveoli of the bicuspid and first molar teeth, which were driven inwards towards the median line, to the extent of about one-third of an inch, as seen in the drawing (fig. 30). There was a corresponding depression on the outer side of the jaw, and this was somewhat apparent also on the face. Very little swelling followed the injury, and there was not much pain except on manipulation. The principal inconvenience was due to the want of proper apposition of the teeth of the two jaws, and the mouth consequently could not be closed satisfactorily. On endeavour-



ing to force the displaced bone into its proper situation, considerable pain was produced ; it could not be completely reduced, and resumed its former position as soon as pressure was withdrawn. Distinct crepitus was felt during this manipulation.

Mr. Salter succeeded in overcoming the tendency of the fragments to displacement by the adaptation of a gold plate (fig. 31) to it and to the adjacent teeth, and a complete cure was the result.

The kick of a horse often inflicts most serious injuries upon the upper jaw, and of this the classical case recorded by Richard Wiseman, in his "Chirurgical Treatise" (1794), is a good example. Here a boy, eight years old, received such a blow on the middle of his face, that he appeared at first dead, and afterwards lay in a prolonged coma. "When I first saw him," says Wiseman, "he presented a strange aspect, having his face driven in, his lower jaw projecting forward ; I knew not where to find any purchase, or how to make any extension. But after a time he became sensible, and was persuaded to open his mouth. I saw then that the bones of the palate were driven so far back that it was impossible to pass my finger behind them, as I had intended, and the extension could be made in no other way. I extemporized an instrument, curved at its extremity, which I engaged behind the palate, and having carried it a little upward used it to draw the bone forward, which I did without any difficulty ; but I had hardly withdrawn the instrument when the fractured portions went back again. I then contented myself with dressing the face with an astringent cerate to prevent the afflux of the humours ; I likewise prescribed bleeding ; and some hours afterwards I had an instrument better constructed to reduce the large mass of displaced bone to its proper position. I had it held by the child's hand, by that of its mother, or of an assistant, each for a certain time. Nothing else was done. Thus by our united attention the tonicity of the parts was maintained ; the callus was developed, and in proportion as it became solidified the parts became stronger, the face assumed a good



appearance, certainly better than could have been hoped for after such marked displacement, and the child was entirely cured."

The most frightful injury to the face (except from gunshot wounds) I ever witnessed, was from the passage of a waggon wheel over the face of a man who fell in the street. Here the bones were completely shattered, and the maxillæ were torn from one another, and death was instantaneous. A cast of this frightful deformity is in the museum of the Westminster Hospital.

A case very nearly as desperate at first, but which fortunately recovered, was admitted into the same hospital in 1860, and resulted from the overturn of a cab upon the face of its fare, who at the moment was leaning out of window to direct the driver. Here, in addition to a fracture of the lower jaw a little to the left of the median line, there were two fractures of the superior maxilla, about an inch on either side of the median line; the nasal bones were broken; both malar bones were loose and separated from their attachments, and the left bone was fractured, as also the external angular process of the frontal bone. Though not positively ascertained, the vomer was no doubt fractured, and probably the vertical plate of the ethmoid too. In Dr. Fyffe's report of the case (*Lancet*, July 18, 1860), which I can confirm by personal observation, it is well noticed,—“It was remarkable to observe how movable the bones of the face were. On watching the patient's profile whilst he was in the act of swallowing food, the whole of the bones of the face were observed to move up and down upon the fixed part of the skull as the different parts were brought into motion; it appeared as if the integuments only retained them in their position. It was a curious feature in the case that notwithstanding the very extensive injury done, and the violent character of the force which caused them, not a single tooth was fractured or misplaced.” This patient made a perfect recovery, and his treatment will be alluded to under another section.

Fracture of the upper jaw extending into the antrum may



give rise to subsequent suppuration in that cavity, as remarked by Liston, but this is by no means a necessary consequence. A remarkable case of transverse fracture of the upper jaw which communicated with the nose and with both antra was recently under Mr. Hutchinson's care in the London Hospital, in which perfect recovery took place without exfoliation of any part of the bone, although the alveolus containing all the teeth was completely separated and depressed about half an inch. Here the injury was the result of a "jam" between a "lift" and a cross bar. (*Medical Circular*, February, 1867.) A very similar case occurred to Dr. Guentha, when a workman was struck in the face by the angle of a large mass of stone. Here there was complete separation of the alveolar process of the upper jaw, the entire arch in an unbroken state lying on the lower jaw, only suspended by some shreds of the gum and soft palate. This man also made a perfect recovery. (*British and Foreign Quarterly Review*, October, 1860.) In the summer of 1871 two patients were admitted into University College Hospital within a few hours of each other, in both of whom the superior maxillæ were fractured and freely movable. In one case perfect recovery ensued, and death in the other, the post-mortem examination proving that there was no injury to the base of the skull.

In cases such as these, when there is obvious displacement there can be no difficulty in the diagnosis of the fracture, but cases have no doubt frequently occurred where a fracture without displacement has been overlooked. Dr. A. Guérin has elaborately investigated this subject (*Archives Générales de Médecine*, July, 1866), and has shown from a preparation taken from a fatal case and from experiments upon the dead body, that violent blows below the orbits fracture not only the maxillary bones, but that the fracture usually extends to the vertical portion of the palate bone and the pterygoid process of the sphenoid, without producing the slightest displacement. The diagnosis of the injury cannot be established by any external manipulation, but by carrying the finger into the mouth and pressing against the



internal pterygoid plate, pain will be produced and mobility of the process will be ascertained. The diagnosis was confirmed in one of Dr. Guérin's cases which recovered, by an ecchymosis beneath the mucous membrane of the palate. In his fatal case he found fracture of the vertical plate of the ethmoid, in addition to the other injuries.

The nasal process of the superior maxilla has been fractured by blows which have also driven in the nasal bone, and in these cases emphysema of the cellular tissue of the face is not uncommon, and is best checked by the application of collodion. A complication of this form of fracture which has been met with, is permanent obstruction of the nasal duct, leading to subsequent troublesome epiphora, of which I have seen an instance.

Separation of the two maxillæ in the median suture has been seen in cases of fatal injury to the face, &c., on many occasions, but Malgaigne gives a case of the kind where the patient recovered. The patient, a man aged twenty-one, owing to a fall from a height sustained, in addition to other injuries, "a separation of the upper maxillary and palate bones in their median suture to the extent of nine millimetres, with depression of the entire left side of the face without any alteration of the soft parts." The parts came together spontaneously, and the patient recovered without deformity.

Hamilton, however, quotes (p. 102) a case from Harris, of New York, in which a child, two years of age, had separation of the maxillary and palate bones in the median line, the separation being sufficient to admit the little finger, and here the bones were still open six weeks after the accident.

*Complications.*—The teeth of the upper jaw may be broken or dislocated, as in the case of fracture of the lower jaw; but if merely loosened, should never be removed, since they will probably become again firmly attached.

Splintering of the bone is much more common in the upper than the lower jaw, particularly after gunshot injuries, and here modern experience has shown the advisability of leaving the fragments to become consolidated, as



they almost invariably do, and the non-necessity for the performance of dangerous operations of resection of the fragments—a subject which will be again referred to.

Hæmorrhage is much more frequent and copious in fractures of the upper than in those of the lower jaw, as might be anticipated from the greater vascularity of the part. A case of fracture of both upper and lower jaws, where profuse hæmorrhage was caused by division of the facial artery, has been already referred to, but the hæmorrhage not unfrequently comes from the internal maxillary vessel and may be immediately fatal. Secondary hæmorrhage in case of severe injury to the upper jaw is by no means uncommon, and according to the Surgeon-General of the American Army (Circular No. 6, Washington, November 1, 1865,) was the principal source of fatality in these cases, ligature of the carotid artery having been frequently performed with the result of only postponing for a time the fatal event.

*Nervous Affections.*—Injury to the infra-orbital nerve and its branches must necessarily ensue in cases of severe fracture and comminution of the superior maxilla, and consequent numbness or modification of sensation will be the result. A lady, recently under my care, who fell down a flight of stairs and sustained severe injuries to the head and face, although no fracture of the jaw could be detected, suffers from partial anæsthesia and a pricking sensation in the skin below the orbit. Robert mentions (*Gazette des Hôpitaux*, 1859, p. 157) the case of a woman who was run over and sustained a fracture with permanent paralysis of the infra-orbital nerve. Serious brain symptoms may ensue when the fracture runs back to the sphenoid bone as described by M. Guérin (p. 60), since the fissure may extend to the cranium, and this is especially likely to happen when the whole of the septum narium is driven back with the jaws.

*Treatment of Fracture of the Upper Jaw.*—Fractures of the upper jaw require but little treatment compared with those of the lower jaw, since the part is naturally so much more fixed that there is little difficulty in keeping the frag-



ments in position. The hæmorrhage, which is often free, must be arrested by cold, the application of styptics, and, as a last resource, the actual cautery. The operation of deligation of the carotid artery in these cases has yielded such unsatisfactory results as to render the surgeon unwilling to resort to it except under the most desperate circumstances, and he would in my opinion be justified in laying open the face and removing large fragments of bone so as to apply the cautery more satisfactorily, rather than resort to a dangerous and doubtful operation. When, as is most commonly the case, the soft tissues of the face are lacerated and the hæmorrhage arises from them, the bleeding vessels must be secured with ligatures in the ordinary manner.

All authorities are agreed as to the non-advisability of removing the fragments of a broken upper jaw, since, owing to the vascularity of the part, they almost invariably unite readily. Malgaigne says, "In common fractures of the upper jaw there is one principle which surgeons cannot too carefully bear in mind—that is, that all splinters, however slightly adherent, should be scrupulously preserved, as they become reunited with wonderful facility. This remark was made by Saviard; Larrey has strongly insisted on it, and we have seen that M. Baudens, who so much urges the extraction of splinters, has likewise made a special exception of these cases." (Packard's translation, p. 304.) Hamilton remarks that the experience of American surgeons during the war confirms these observations. "Owing to the extreme vascularity of the bones composing the upper jaw, the fragments have been found to unite after the most severe gunshot injuries with surprising rapidity, the amount of necrosis and caries being usually inconsiderable compared with the amount of comminution" (p. 106).

Notwithstanding this, however, Hamilton gives a lengthy account of a case of fracture of the upper jaw, in which he, in conjunction with Dr. Potter, thought it necessary to remove a fragment which included the floor of the antrum and had been drawn down and displaced in an attempt to extract a loose tooth. "The time occupied in this operation



was at least one hour, during which we were every moment in the most painful apprehension lest we should reach and wound the internal carotid artery, which lay in such close juxtaposition to the knife that we could distinctly feel its pulsation. After its removal the hæmorrhage was for an hour or more quite profuse, and could only be restrained by sponge compresses pressed firmly back into the mouth and antrum" (p. 103). Such dangerous operations are much to be deprecated, and cases already quoted prove that even after greater separation the bone will thoroughly reunite.

Mention has been made of the difficulty Wiseman experienced in reducing the fragments to their proper position in his case, and the means he adopted to overcome it. In the majority of cases the finger introduced into the mouth and passed around the alveoli will readily restore any irregularity, being aided, if necessary, by the introduction of a strong elevator or pair of dressing forceps into the nostril. The teeth in adjacent fragments may be advantageously wired together to keep them in position, or, where there is great comminution and irregularity of the alveoli, a piece of soft gutta-percha may be adapted to them so as to hold and support the fragments. The lower teeth should not be allowed to come in contact with this until it is thoroughly hardened, or they would become imbedded and thus cause its displacement. In very complicated cases, as in examples of fractures of both jaws, the vulcanite interdental splints of Mr. Gunning (described under Fractures of the Lower Jaw) might be employed, these having an aperture for the introduction of food.

Graefe employed an apparatus, of which the following description is given by Malgaigne (Packard's translation, p. 301). "A curved steel spring, properly padded, is applied over the forehead, and kept in place by a strap buckled around the occiput. This steel has at each side a hole with a screw for making pressure; and a steel brace to which it affords a *point d'appui*, for acting steadily on the dental arch. Now these braces, descending to the level of the free edge of the upper lip, curve backward so as to go around



the lip without wounding it; getting thus at the dental arch, they again curve so as to apply themselves to it. But as the pressure of the braces should have the effect of keeping the detached teeth in proper relation with the rest, a silver trough duly padded is made to fit over both to a sufficient length; and upon this trough the braces exert their pressure. It is easy to see how, by altering their height as regards the spring over the forehead, the pressure may be regulated to the right degree."

A somewhat similar apparatus, but with the addition of a pad which can be applied externally so as to support the cheek, was brought before the Surgical Society of Paris, in September, 1862, by M. Goffres.

In the rare cases of separation of the maxillæ, a spring passing behind the head and making pressure upon the maxillæ after the manner of Hainsby's hare-lip apparatus, might be advantageously employed.



## CHAPTER V.

## GUNSHOT INJURIES OF THE JAWS.

GUNSHOT injuries of the jaws have necessarily been incidentally referred to in considering fractures of those bones separately, but it will be convenient to class the injuries of the two maxillæ by fire-arms together, since these accidents affect both bones in the majority of cases. Laceration of the soft tissues and consequent hæmorrhage are almost constant accompaniments of wounds of the face, and the mortality attending them is high, both from the immediate effects of the injury, and from the frequent occurrence of secondary hæmorrhage. The effects of the modern arms of precision contrast unfavourably in this respect with those of the round bullet of the old fire-lock, for though the latter frequently lodged in one of the cavities of the face for an indefinite time, the irregular mass of metal driven with tremendous velocity by the modern rifle commits greater havoc, splintering the bones and lacerating the soft tissues most extensively.

The Surgeon-General of the American army reported in November, 1865 (Circular No. 6, Washington), that from the commencement of the war to October, 1864, of 4167 wounds of the face reported to him, there were 1579 fractures of the facial bones; and of these 891 recovered and 171 died—the terminations being still to be ascertained in 517 cases. Secondary hæmorrhage was the principal cause of mortality in these cases, and the carotid had frequently been tied with the result of postponing for a time the fatal result.

The Crimean returns from the 1st of April, 1855, to the



end of the war, show 533 wounds of the face, of which the bones were injured in 107 instances. 445 patients returned to duty, 74 were invalided, and 14 died.

Of 21 cases of wounds of the face with injury to the bones from the Indian Mutiny reported by Dr. Williamson, six were examples of fracture of the lower jaw, and of these three remained ununited.

The following extract is from the official "Medical and Surgical History of the British Army in the Crimea," vol. ii. p. 305, and illustrates the experience of that war, which has been largely confirmed by that of the later American war:—"Wounds of the face, though presenting often a frightful amount of deformity, are not generally of so serious a nature as their first appearance might lead the uninitiated to expect. The reason of this, apart from the fact that the face contains no vital organ, seems obviously to be the very free supply of blood which this part receives. From this cause the fleshy structures readily heal, and even the bones are so supplied that extensive necrosis rarely happens. The bone tissues, also, are softer than the long bones of the extremities, and we therefore but seldom here meet with long fissures and extensive necrosis as a result of concussion of bone, so often seen in them. This leads us to the very important practical inference, not in this situation, as a rule, to remove bony fragments, unless the comminution be great, or the fragment completely detached from the soft parts. Even partially detached teeth will often be found not to have lost their vitality, and, if carefully re-adjusted, will become useful. There is indeed no great object beyond, perhaps, the present comfort of the patient to be attained in removing either fragments of bone or loosened teeth in the great majority of instances. If they die, they become loose, and are readily lifted away without trouble to the surgeon, and but little pain to the patient. This observation is especially applicable to fractures of the lower jaw. Surgeons in this war have seen so many cases of badly-fractured instances of this kind unite, and that with a very small amount of deformity, that men of ex-



perience are now excessively chary of removing any portion of this bone, unless it has become dead, or the fragment is so situated as to interfere considerably with the adjustment of the remainder, or the bone so much comminuted as to give no probable hope of its becoming consolidated, or so sharply angular as to threaten further injury to the soft parts, or to interfere materially with their adjustment and retention *in situ*. In these fractures of the lower jaw, much less support and adjustment than we are in the habit of thinking advantageous in ordinary cases of fracture of it, will frequently be found necessary, or even admissible. A complicated apparatus cannot be borne at first, on account of the condition of the soft parts, and the application of slight support by a gutta-percha or Startin's wire splint, and a split bandage, is all that can be done. Any attempt at ligaturing the teeth is very generally not only useless, but injurious, and it is surprising how the parts often as it were adjust themselves, with but little aid from the surgeon. One interesting case may be mentioned where the whole of the bone, from angle to angle, was so comminuted by gunshot that no choice was left but to remove the fragments. The injury to the soft parts was very considerable, and one difficulty, occasioned by the loss of all support in front—viz., the tendency of the tongue to fall backwards and close the opening of the glottis, well illustrated. The man, however, generally remedied this himself with his fingers, and nothing was done, or required to be done, on this account beyond carefully watching him. He naturally, as it were, adopted a position on his side, resting mainly on his forehead, so as to have the face as much in the prone posture as possible, and thus the weight of the organ assisted in keeping it in position."

Gunshot wounds of the upper jaw through the mouth are usually of suicidal origin, and of this a specimen, presented by myself, is now in the Museum of the College of Surgeons (832), being the skull of a man who fired a pistol into his mouth. The red lines on the preparation mark the outline of the fracture, and it will be seen that a



great part of the hard palate was driven in, and that the bullet, after fracturing extensively the base of the skull, carried away a considerable portion of the vault of the cranium. The malar bone, with the outer wall of the antrum, is broken off on the right side, and the malar bone on the left is separated from the maxilla at the articulation. In a second case of the kind, which I also had the opportunity of examining immediately after death, the injuries were similar in extent.

In the preparation referred to there is an oblique fracture of the lower jaw on the left side, running backwards through the socket of the first molar tooth, and an oblique crack has been produced on the inner surface of the right side of the bone, in an exactly corresponding position. Fracture of the jaw had occurred also in the second case alluded to, and has been frequently noticed under similar circumstances, the fracture depending upon the concussion of the explosion and the rapid development of gas within the mouth. This is not without exception, however, since, in the University College Museum, there is the skull of a man who fired a pistol into his mouth, in which the palate is extensively damaged, but the lower jaw perfect. When the bullet actually enters the mouth the injury is usually immediately fatal, but Otto Weber has recorded (*Handbuch der Allgemeinen und Speciellen Chirurgie*, Part III. 1866) a case of recovery:—"The patient, through despair arising from pecuniary embarrassments, determined to shoot himself in the churchyard. He held the pistol before his open mouth, and, after firing, fell senseless to the ground. After some time he came to himself, looked for his spectacles, which had fallen off his face, and made the gravedigger bring him to me. The palatal vault was simply perforated, and the ball, completely flattened, was sticking in the body of the sphenoid bone, where it could be felt by the index finger introduced into the hole by which it had entered. After some fruitless attempts to extract it, it fell into the patient's throat and he spat it out. Subsequently the hole in the palate completely closed up again, and the patient recovered both physically



and morally." In this case the lower jaw does not appear to have suffered, but Mr. Barrett has shown me the model of a case in which a pistol bullet, fired at the open mouth, glanced off an incisor tooth, and ran up the side of the face, emerging near the malar bone, and where nevertheless the lower jaw was broken by the explosion.

I was once called in by Dr. Whitmarsh, of Hounslow, to see a patient who had fired a pistol, loaded with small shot, into his mouth, smashing the palate and fracturing the lower jaw in two places by the explosion, but who eventually made a good recovery; and in the *Lancet*, Nov. 7, 1868, will be found a remarkable case under the care of Mr. Sydney Jones, of recovery, after a similar injury, complicated by division of one optic nerve and injury to the brain.

Because a bullet has entered the mouth, and inflicted injury upon the bones of the palate, &c., it does not necessarily lodge there; thus, in the "Medical and Surgical History of the Crimea," is the case of John Collins, 97th Regiment, who was wounded on the 8th September and sent to hospital on the 14th, having been struck by a musket-ball, which had entered the mouth slightly cutting the upper lip, and had comminuted the palate plate of the superior maxilla, and appeared to be lodged somewhere among the ethmoid cells. There was but little constitutional disturbance. All the incisor teeth of the upper jaw became dead and had to be removed, as well as some fragments of the palate plate, but the wound slowly healed and finally filled up, leaving the man but little the worse, except for the loss of his teeth. Various careful examinations, made at different times, failed to detect the presence of any foreign body, and the man himself afterwards stated that he had always fancied the bullet fell out during his progress from the trenches to the regimental hospital.

Injuries of the palate may also be produced by wounds of the face; thus, Mr. Cox Smith, of Chatham, records the case of a soldier who came under his care, in whom the jaw and palate had been extensively fractured, and the incisor teeth

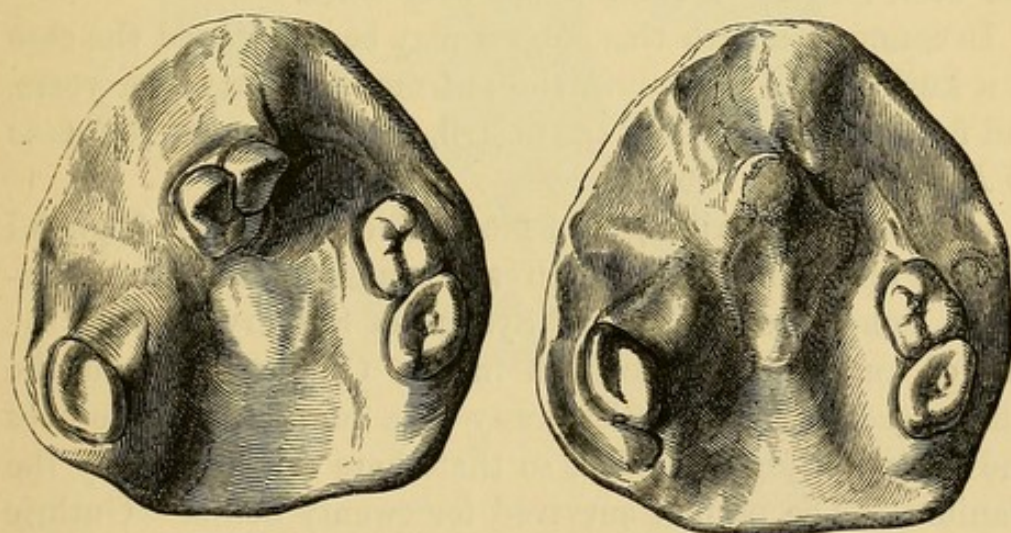


driven in, as seen in fig. 31a, so that the patient was unable to masticate or speak. By extracting these teeth (fig. 31b), Mr. Smith was able to adapt a set of artificial teeth, so as to restore to the patient the use of his mouth for all purposes.

Missiles, striking from without, occasionally lodge for a considerable time in the antrum or nose, and, sometimes, without their presence being suspected. In the "Medical and Surgical History of the Crimean War," will be found the case of a soldier who received a severe wound of the face. A grapeshot, weighing seventeen ounces, lodged in the jaw, having displaced the palate, with a portion of the maxilla, and all the molar teeth of the right side, into the

FIG. 31a.

FIG. 31b.



mouth. Here it was found necessary to enlarge the wound and remove the fragments (contrary to the general rule of practice) before the ball could be extracted, but the patient made a good recovery, notwithstanding severe secondary hæmorrhage. Still more remarkable, however, are cases which have occurred in civil practice, where the breech of a burst fowling-piece has lodged for years in the antrum. A remarkable case of this kind was reported in the *Edinburgh Medical Journal*, of September, 1856, by Dr. Fraser, of Newfoundland, who removed a piece of metal, weighing more



than four ounces, and measuring nearly three inches in length, from the jaw of a man who had sustained an accident seven years before. A still more extraordinary case is recorded in the Museum of Guy's Hospital, which possesses a model of the breech of a gun which had been lodged in the face of a man for twenty-one years! "The patient was shooting birds when the gun burst, the right eye was knocked out, and the roof of the orbit destroyed, and through it the brain protruded; the latter sloughed, and, after a long illness, the man recovered. At the latter end of 1856 he was suddenly seized with symptoms of choking, as from a foreign body in the throat, and, on putting his finger in his mouth to remove it, he drew forth the breech of a gun, much oxidized and covered with purulent matter. It is supposed that the piece of iron broke through the floor of the orbit, and had been lodging in the antrum ever since."

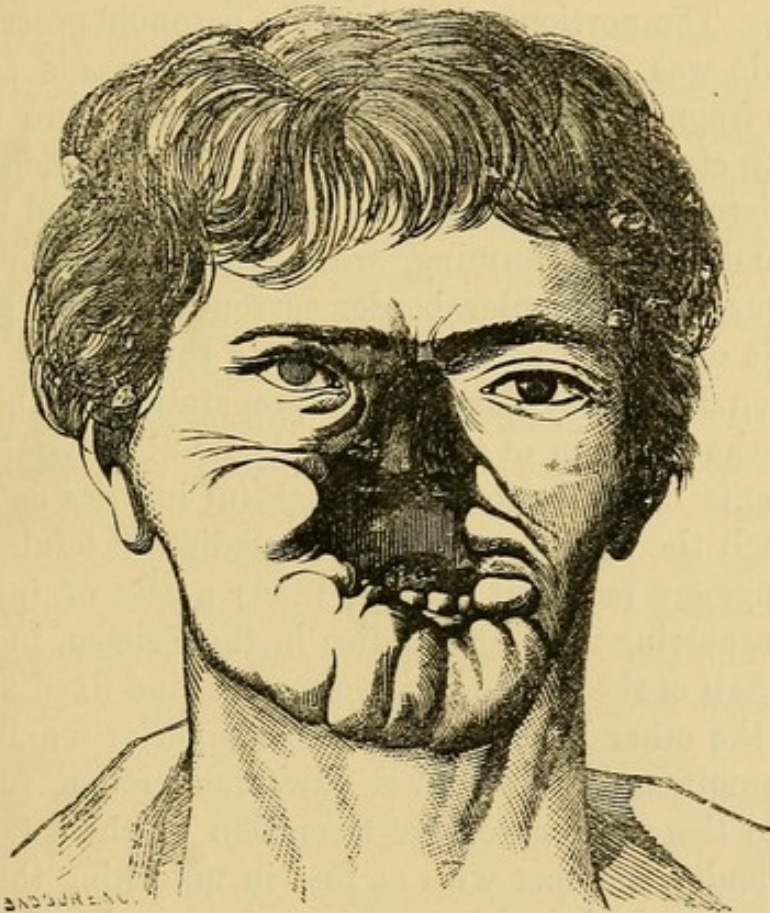
In connection with this subject may be mentioned the case of a knife-blade lodged in the antrum for forty-two years, and finally coming out of the nostril, reported in the *Bulletino di Bologna*, May, 1864.

Cannon shot, striking the face, inflict the most frightful injuries upon the jaws, which are usually fatal; thus Professor Longmore mentions ("System of Surgery," vol. i.) the case of an officer of Zouaves in the Crimea, who had the whole face and jaw carried away by a cannon-ball, the eyes and tongue being included, so that there remained only the cranium. The patient survived for twenty hours. Guthrie also relates a very similar case, as having occurred at the siege of Badajos. The wars of the first Napoleon afforded some frightful examples of injury to the jaws, which the unfortunate patients survived for years in one of the military asylums of Paris. The accompanying drawing (fig. 32), taken from an able paper by M. Emile Debout, "On the Mechanical Restoration of the Maxillæ" (*British Journal of Dental Science*, April, 1864), shows the condition of a corporal who was struck by a cannon-ball at the siege of Alexandria, in 1800. The shot carried away the greater part of the face, including three-fourths of the lower jaw,



and part of the tongue, and the man was thought to be dead. Under the solicitous care of Baron Larrey he recovered, however, and lived for more than twenty years. "It can be seen at a glance that speech and mastication were impossible. Poor Vauté concealed the deformity by wearing a mask, gilt inside, and imitating the colour of the skin

FIG. 32.



outside. He could even by means of this cover make himself a little understood, but his greatest distress arose from the incessant escape of the saliva, which was so great as to saturate in succession a number of linen compresses in the course of the day. After supporting his misfortune heroically for so many years, he put an end to his misery in 1821. In order to complete the history of a case in which he had felt so deep an interest, Larrey, on learning the death of Vauté, procured his head, the state of which he described.

The loss of substance occasioned by the ball was limited to the elliptic segment seen in the portrait. The left malar



bone had been carried away. The arch of the palate and the nasal fossæ down to the ethmoid had been destroyed. The inferior and internal orbital walls, down to the base of the skull, had been also destroyed. Two-thirds of the lower jaw were wanting. The right half of the middle portion of this bone, with three of the teeth, was found adherent to a part of the surface of the right ramus, which had been fractured. The portion supporting the coronoid process and the condyle was considerably depressed backwards to meet the other fragments of this bone; but, as they were not in sufficiently close contact, they had not grown to each other. All the edges of the bones broken away by the ball had become thinned and rounded, forming, with the corresponding soft parts, a puckered, irregular border surrounding the gulf in the middle of the face. To perpetuate the history of the case, Baron H. Larrey has had the preparation of the head placed in the museum of the Hospital of Val de Grâce."

Fragments of shell produce as frightful injuries as round shot, though the results are not so immediately fatal. Professor Longmore recorded (*Lancet*, 1855) a case of injury of the kind occurring under his notice in the Crimea, in which the right half of the palate was jammed in, and fixed at right angles to the other half, and the whole superior maxilla was much comminuted. The lower jaw was broken in three places, and there was extensive laceration of the soft parts. Great difficulty was met with at first in unlocking the parts of the palate which had been driven into each other, and when they were separated the right half hung down loosely in the mouth. The parts were carefully restored to position, and the patient made a good recovery without deformity.

In the Appendix will be found the report of a case (Case V.) of extensive injury to the jaws by a piece of shell, in which Dr. D. Lloyd Morgan, R.N. (to whom I am indebted for the report), was obliged to tie the common carotid artery for secondary hæmorrhage, with success, so far as the operation was concerned, though the patient died of cholera some time after.

A charge of small shot, if fired near enough to the face



to do more than lodge in the skin or jaw-bone (of which there is a good example in the Middlesex Hospital Museum), will produce as serious injuries to the jaws as a bullet. In the *Lancet* of 10th November, 1860, is the report by Mr. Swete, of Wrrington, of a case of very severe injury to the jaws from a charge of "dust shot," fired at a distance of four feet from the patient, a boy aged nine years. The charge entered the left side of the face, and passed out in front of the right ear, carrying away with it the greater part of the lower lip and jaw, and the whole of the chin. Several pieces of bone and teeth were picked up in an adjoining field, at a distance of ten yards. There was an extensive ragged wound of the face, extending nearly to the ear, the right half of the upper lip being destroyed, and the teeth and alveolus of the same side carried away. The lower jaw was shot away at the angle on the right side, and on the left about an inch of the body of the jaw and one molar tooth remained. Mr. Swete trimmed the ragged edges of the jaw and brought the lacerated parts together, and, contrary to expectation, the patient recovered and, by means of a plastic operation, was restored to a condition of considerable comfort.

Fracture of the lower jaw alone may be produced by bullets, and in this case the hæmorrhage is often severe from the divided facial artery, which vessel is generally involved. In the *Edinburgh Medical Journal*, Sept. 1860, Dr. John Brown, of the Bengal Medical Service, records four cases of the kind which are good examples of the variety of injury inflicted by a bullet:—

1. Was a gunshot injury of the jaw, attended by profuse hæmorrhage. The facial artery was secured, and a large portion of the comminuted bone removed. The patient did well.

2. Was a gunshot wound at the symphysis. There was a depression in the bone at the spot, but the ball had not perforated it. Did well.

3. Occurred in Lucknow. A Sikh was shot in the right side of the lower jaw; there was great arterial hæmorrhage from the facial artery, with a small wound over the angle and a larger one over the symphysis. Both were laid into



one, fragments were removed, and the facial artery tied. Died twelfth day.

4. Ball traversed the mouth and fractured both sides of the lower jaw near the angles. Died from pyæmia on twenty-first day.

The Catalogue of the Surgical Section of the United States Army Medical Museum (1866) contains numerous records of injuries of this kind, from which the following may be quoted as most remarkable:—

“3350. The right half of the inferior maxilla fractured by a musket-ball, a small portion of which is attached. The missile entered the mouth, struck the alveolar ridge at the molar teeth, comminuting it, and causing oblique fracture of the body of the bone. The patient died the same day from hæmorrhage, from rupture of the internal maxillary artery.

“1451. Wet preparation of the right side of the body of the inferior maxilla, fractured and comminuted by a musket-ball at the angle. A fragment containing the molar teeth is driven inward, and other fragments remain *in situ*, the total amount of bone shattered being two inches. The ball lodged in the thyroid cartilage, causing death by suffocation on the nineteenth day.

“3542. The inferior maxilla fractured and comminuted by a musket-ball. The alveolar ridge and the teeth are entirely removed; there is a horizontal fracture of the left ramus passing through the inferior dental foramen; on the right side there is a transverse fracture of the body of the bone at the last molar, and an oblique vertical fracture at the symphysis. The patient died from the effect of the wound of the tongue, causing hæmorrhage, for which the left common carotid was ligated.”

The experience of English surgeons in the Crimea, already referred to, has so completely settled the question of operative interference in cases of gunshot wounds of the lower jaw, that few military surgeons would be inclined to follow the example of M. Baudens (see Guthrie's “Commentaries,” p. 501) in laying open the cheek and removing or rounding



off all fragments. Where spicula are much displaced, or where a bleeding vessel is to be reached, it may be occasionally necessary to enlarge the wound, as in one of the cases already quoted, but this must be considered the exception rather than the rule.

A fracture may possibly be produced indirectly without the bullet actually striking the jaw; of this the following extraordinary instance occurred at the battle of Balaclava. A man of the 4th Light Dragoons received a compound fracture of the lower jaw by a grape-shot striking the flat of his sabre, while at the slope, and driving it against the side of his face and head. The blade was bent, but not broken, and the missile did not touch the man.

Fragments of the jaw have been driven into other parts of the body, and even into that of a neighbour. In the "Medical and Surgical History of the Crimean War" is reported the case of a soldier who was shot in the right cheek, the ball glancing downwards and lodging in the neck, from which it was extracted. Subsequently a foreign body was detected behind the right clavicle, which was cut down upon and proved to be a portion of the lower jaw. Hamilton, also, in his "Military Surgery" (p. 255), mentions the case of a Confederate soldier, who was kneeling and bending forward when he received a rifle ball upon his four lower incisor teeth. The ball and teeth disappeared, but were subsequently removed from beneath the skin at the top of the sternum.

The frequent occurrence of a false joint after gunshot injuries of the lower jaw has been already adverted to in the section upon False Joint. Since in gunshot cases a loss of substance has usually taken place which renders the union of the remaining portions an impossibility, some mechanical contrivance should be adapted by the dentist to hold the parts in their proper position and enable the patient to masticate. A case of false joint near the symphysis, treated in this manner most successfully by Mr. Cox Smith, has been already referred to, and will be found at page 31. Figs. 33 and 34 show the effects of mechanical treatment in sepa-



rating the fragments and the filling of the gap by artificial teeth, and should be contrasted with figs. 9 and 10. The sooner such apparatus is adapted after the receipt of the in-

FIG. 33.

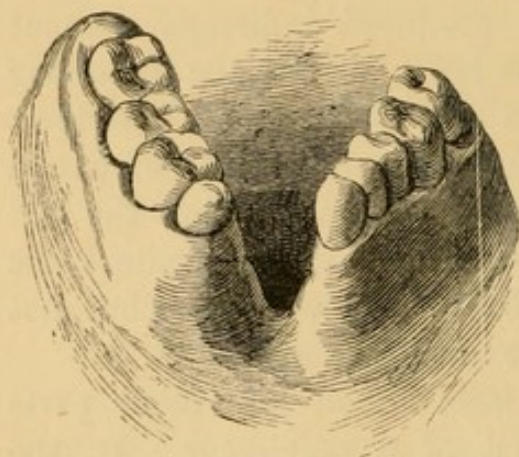
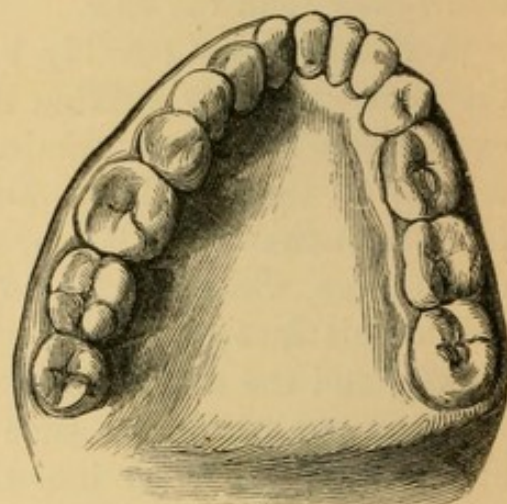


FIG. 34.

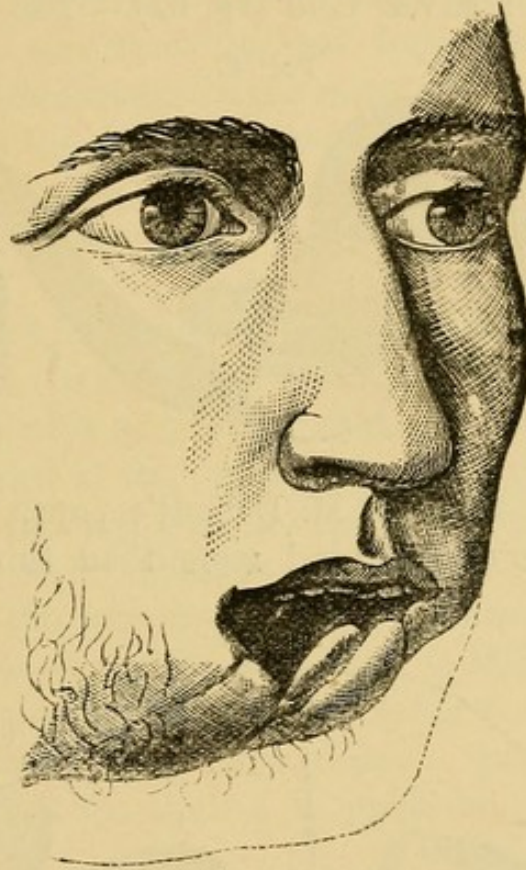


jury the better, since, as will be presently shown, the muscles have a constant tendency to draw the two sides of the jaw together. Not only is this effect produced upon the lower jaw, but there appears to be a secondary effect produced in these cases upon the upper jaw, the alveolar arch of which becomes gradually contracted from want of proper antagonism. M. Debout, in the paper already referred to, gives the case of a French corporal, who, during the Italian campaign, was wounded by a fragment of shell, which fractured the lower jaw and severely lacerated the integuments. The comminuted fragments were removed, and the soft parts brought together with sutures, so as to restore as far as possible the floor of the mouth. All that could be obtained, however, was to form a sort of channel concealed by the beard, as shown in fig. 35, by which the saliva flowed in great abundance. When the patient arrived at the Val de Grâce he was placed under the care of Professor Legouest, at whose request M. Preterre, the dentist, was called in. The latter gentleman, before making any attempt to remedy the mutilation by restoring the lower jaw, thought it necessary first of all to have an apparatus made for the purpose of preventing the contraction of the dental arch. Fig. 36 shows



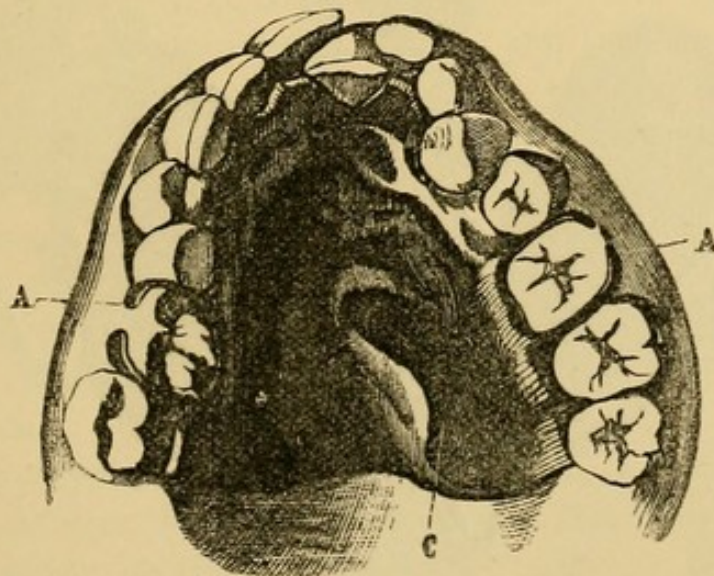
the apparatus in its place, A, c pointing to the position in which the alveolar border was when the case was first

FIG. 35.



seen. The completion of the case was prevented by the patient quitting the hospital.

FIG. 36.





Complete or nearly complete destruction of the lower jaw by a cannon-ball has more than once occurred, the patients surviving for many years, and the deformity being palliated by the use of a silver chin (fig. 37). The accompanying

FIG. 37.

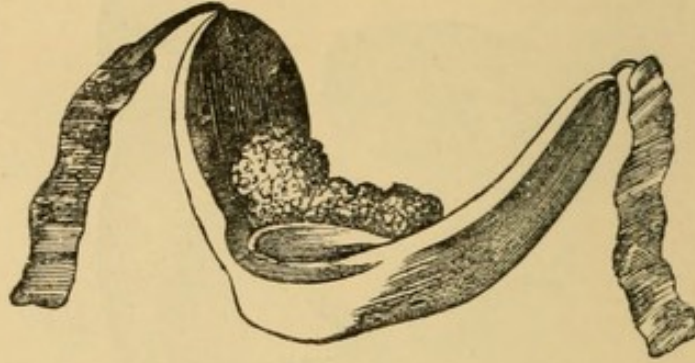
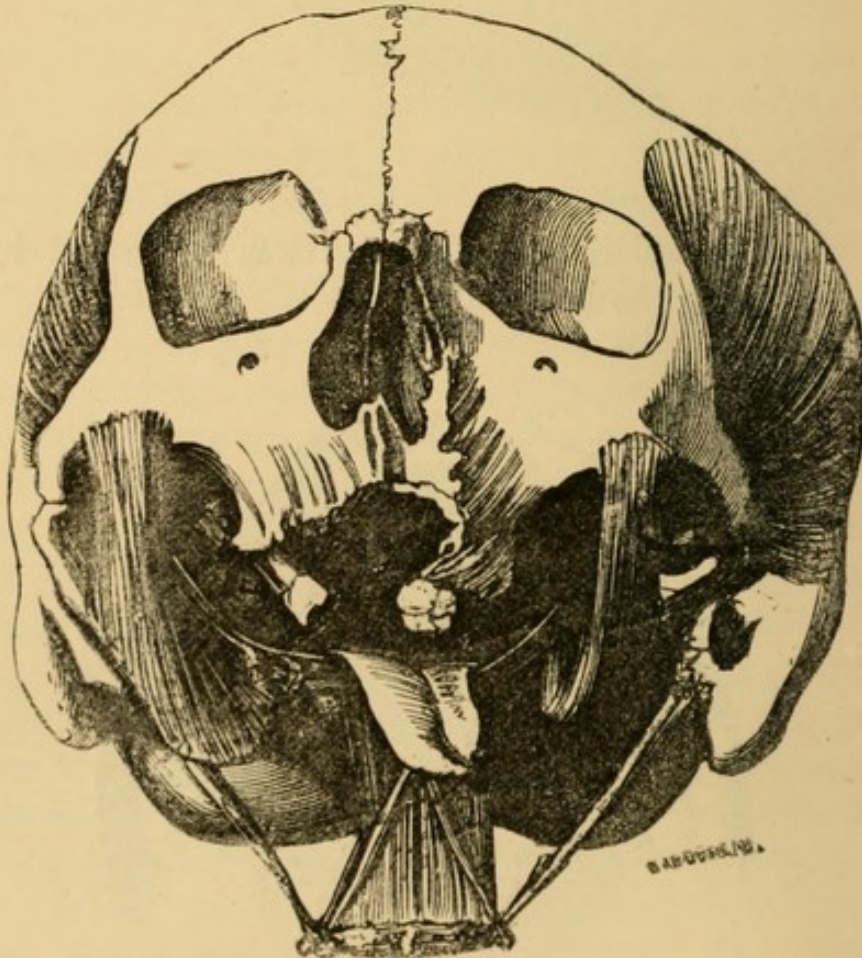


illustration (fig. 38) from M. Debout's paper, shows the dissection of a case of the kind more than thirty years after

FIG. 38.





the receipt of the injury, the history being as follows :—At the battle of Jena, Vernet had the body and left ramus of the lower jaw carried away by a cannon-ball. The soft parts, bruised and torn, hung down in front of the neck, and the tongue was much injured from the tip along the left side. At the ambulance the parts were adjusted as well as possible, and the dressing completed. An abundant suppuration ensued; splinters were detached from the extremities of the bones, and the whole was healed in three months.

Ribes, in 1818, describes thus the condition of the parts when Vernet had attained the age of forty-four :—“The soft parts and loose flaps of the lips, chin, and cheeks have become agglutinated at the upper part of the neck, above and to the side of the larynx at the root of the tongue, where they form by their adhesion divers folds and cicatrices. The opening—the mouth—is situated beneath the arch of the palate; the tongue lies concealed in the soft parts, and retracted towards the pharynx; the lower part of the tongue is closely adherent, and in a manner fixed to the parts beneath it, so that the tip can be projected only to the left, and not forwards.

“The patient wears a silver double chin, with which he can speak pretty distinctly; but is much inconvenienced by the incessant escape of the saliva.”—(*Dict. des Sciences Médicales*, vol. xxix. p. 425.)

Vernet lived twenty years longer; and some years before his death the mouth-opening became so narrow that, instead of being obliged to change the cloths or sponges, into which the saliva used to flow, five or six times a day, he scarcely wetted one.

In this case the steady contraction of the cicatricial tissues of the mouth had a beneficial tendency. The effect produced upon the teeth of the upper jaw is well seen in the illustration.

In the United States Army Museum is a remarkable specimen of attempted bony repair of a nearly as extensive injury, which is thus described :—“1162. The inferior



maxilla, probably fractured by a musket-ball. The body of the bone has been removed nearly to the angle on each side, and an irregular plate of new bone, measuring two inches in length, three-fourths of an inch in width, and one-half inch in thickness has formed anteriorly, and is connected to the rami on either side by ligamentous bands. The patient died one hundred and one days after the receipt of the injury."



## CHAPTER VI.

## DISLOCATION OF THE JAW.

DISLOCATION of the lower jaw may be unilateral or bilateral, the latter being the more frequent variety, since of 28 cases of dislocation given by Giraldès, 15 were of both condyles; and of 76 cases given by Malgaigne, 54 were the same, 31 of these last being in women. Bilateral dislocation occurs most frequently in middle age, though it is not unknown in youth and old age; thus Sir Astley Cooper gives the case of a child who experienced the accident from forcing an apple into his mouth, and both Nélaton and Malgaigne have met with it in old people of sixty-eight and seventy-two years of age. The possibility of dislocation of the jaw following traction on the chin with the finger or hook in delivery need be only alluded to, since the occurrence must be unknown, or nearly so, in the case of living children. The less frequent occurrence of the accident in the extremes of age may be explained, partly by the smaller liability of children and old people to external violence, and also by the fact that, owing to the obtuseness of the angle formed between the ramus and the body of the bone at those ages, the leverage of the jaw is diminished, and the muscles do not act in such vertical lines as in middle age. The explanation offered by M. Nélaton—viz., that in youth the coronoid processes are too short, and in old age directed too far back, to impinge upon the malar process of the upper jaw—appears to be untenable, and will be referred to in describing the pathology of dislocation.

The causes of dislocation are yawning, vomiting, or shouting, in all of which actions the patient's mouth is



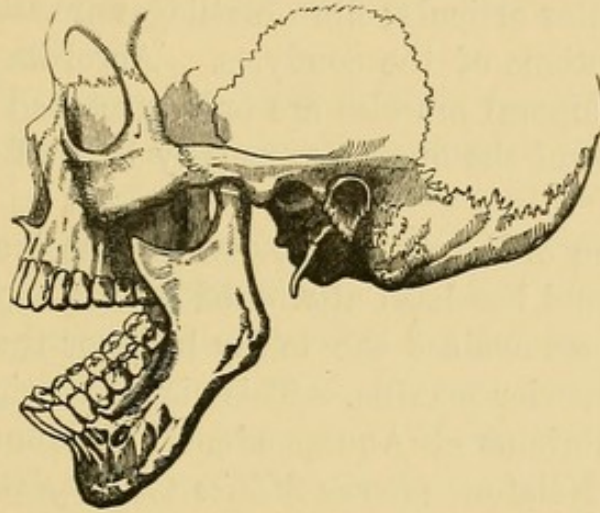
opened to its fullest extent; or it may result from blows or the kicks of animals, and this is particularly the case with the unilateral form of the affection. Causes acting within the mouth may also produce dislocation—*e.g.*, the introduction of an apple, as in Sir Astley Cooper's case, already alluded to, or the introduction of the stomach-pump. Extraction of teeth, even in the most skilful hands, has been known to produce the accident, which has also been caused by the ordinary dental operation of taking a model of the lower jaw. (Salter, *British Journal of Dental Science*, July, 1871.) Dr. Guignier, of Montpellier, has also reported (*Abstract of Medical Sciences*, vol. ii. 1866) an example of complete dislocation occurring during the laryngoscopic examination of a lady, aged thirty-eight, in whom reduction was readily effected.

The pathology of dislocation of the jaw has been a subject of considerable discussion and investigation from the earliest days of surgery to the present time, and various views respecting it have been brought forward by different authorities. When the mouth is opened to its fullest extent, each condyle of the jaw leaves the true glenoid cavity and rests against the articular eminence and the inter-articular fibro-cartilage, which is drawn forward by the pterygoideus externus, the same muscle which advances the jaw itself. The articular eminence is covered by articular cartilage, and by the synovial membrane reflected between it and the cartilage, and a second synovial membrane being placed between the cartilage and the condyle of the jaw, the necessary freedom of movement is insured. A cavity is thus left immediately behind the condyle, which can be readily felt in the healthy living subject, and which is only exaggerated in cases of dislocation. When the jaw is in this position, but a very slight force is needed to carry the condyle over the articular eminence and produce a dislocation, and this is brought about, either by a force applied to the chin, when, owing to the length of the lever, the result is readily induced; or by a spasmodic contraction of the external pterygoid muscles, which, as has been stated, are



already in action. The lateral ligaments of the joints have no power to check this, and the few fibres which surround the synovial membrane and form a loose capsule are easily stretched, but never tear. The accompanying illustration from Sir Astley Cooper's work on "Dislocations," shows

FIG. 39.



the position of the bone at this period, but is wanting in the ligaments and inter-articular cartilage, which latter is ordinarily carried forward with the condyle. Immediately that the condyles are dislocated the masseter and internal pterygoid muscles contract, and draw the jaw forwards and upwards so as to produce the projection of the chin characteristic of the accident. This last muscular action was originally described by Petit, and has been denied; but has recently been confirmed by Heinlezn and Busch, who found experimentally on the dead body, that by replacing the muscles by india-rubber bands acting in the same direction as the muscles, the luxation could be invariably maintained and the characteristic deformity produced.

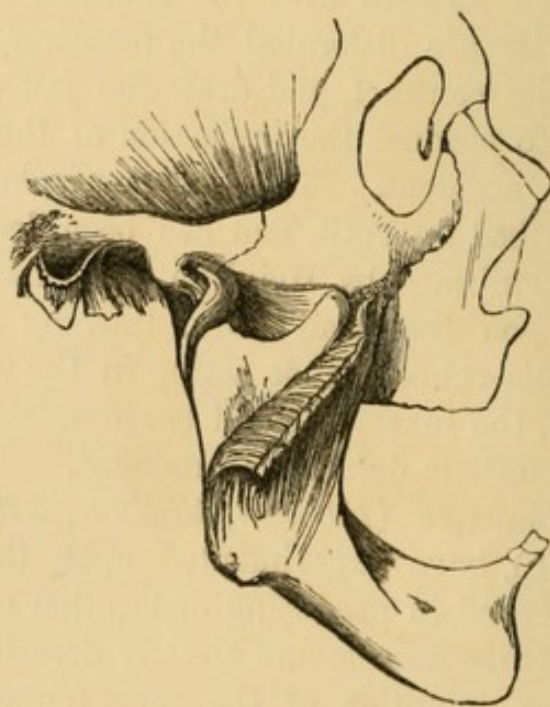
Both Maisonneuve (*L'Union Médicale*, 1863) and Otto Weber (*op. cit.*), have experimented upon the dead body, and have succeeded in producing dislocation of the jaw by imitating the three movements already described, when the following is the condition of the parts found upon dissection:—The condyles are in front of the root of the zygoma, the coronoid processes are completely surrounded by the



tendons of the temporal muscles, and are quite below, and scarcely ever touch the malar bone. The capsular ligament is tense, but not ruptured; the external lateral ligament is tense, and passes from behind forwards instead of from before backwards; the internal lateral and stylo-maxillary ligaments are stretched, and this is increased by raising the chin. The inter-articular fibro-cartilages are attached to and follow the motions of the condyles. According to Maisonneuve, the temporal muscles are only stretched; but Weber says that some of the fibres are usually torn off the coronoid process.

The fixation of the dislocated jaw has received a different explanation, and has been attributed to the catching of the coronoid process against the malar bone, or the malar process of the superior maxilla. This view was originally maintained by Fabricius ab Aquapendente, by Monro, and more recently by Nélaton (*Revue Médico-Chirurgicale*, tom. vi.), who is followed by Malgaigne in his treatise on "Disloca-

FIG. 40.



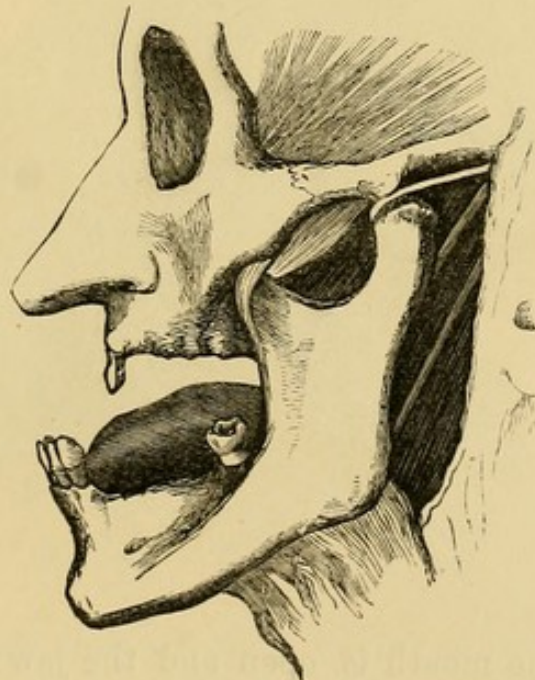tions" (1855). Nélaton maintains that in his experiments on the dead body he constantly found the coronoid process



fixed against the malar bone ; and he appeals also to a unique preparation of a pathological dislocation which he dissected and presented to the Musée Dupuytren. The accompanying illustration (fig. 40), reduced from Malgaigne's Atlas, is from the preparation in question. The coronoid process in this certainly touches the malar bone, and the relations of the inter-articular cartilage and external lateral ligaments are well seen.

Ribes and Monteggia agree with Maisonneuve and Weber in believing that in most jaws the coronoid process is not long enough to reach the malar bone ; and the last-named author mentions that Roser was unable to reduce an old dislocation of eight weeks' standing, even after cutting through both coronoid processes from within the mouth by means of bone forceps. From experiments I have myself instituted, I believe the view of Maisonneuve and Weber to be correct—viz., that the coronoid process does not become fixed against the malar bone. In the macerated skull it is easy to dislocate the condyle so far in front of the articular eminence

FIG. 41.



as to cause the coronoid process to be hooked against the malar bone ; but this is by no means easy on the subject, even

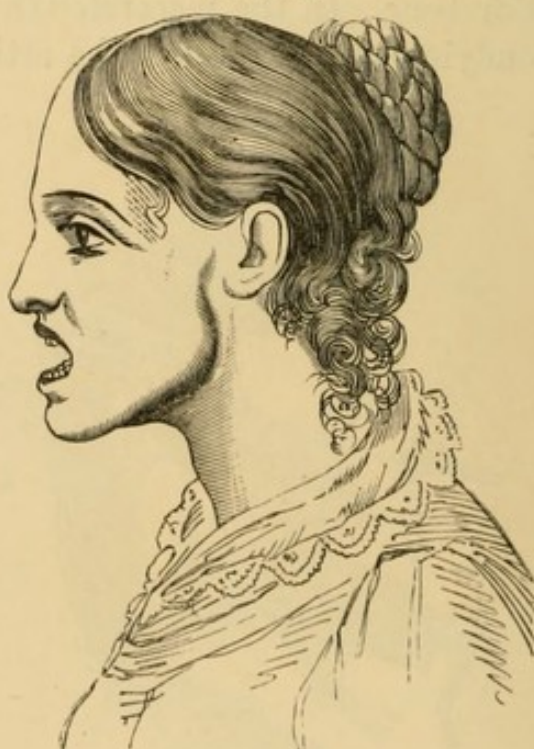

when the parts are dissected, and can only be accomplished by tearing the structures of the joint very considerably. Besides, the position the jaw assumes when the condyles are so driven forward, is not that of the ordinary form of dislocation, the jaws being too widely separated, and the chin drawn back instead of being advanced. Were the coronoid processes fixed against the malar bones, it would be impracticable to effect a reduction by elevating the chin, as is frequently done ; and, moreover, the gradual improvement noticed in old-standing cases of dislocation would be impossible.

A preparation, illustrating the anatomy of dislocation, was dissected for me by my friend Mr. Marcus Beck, and from one side of it the drawing (fig. 41) was made.

*Symptoms of Dislocation.*—When the dislocation is bilateral, the deformity is so evident as at once to attract

FIG. 42.

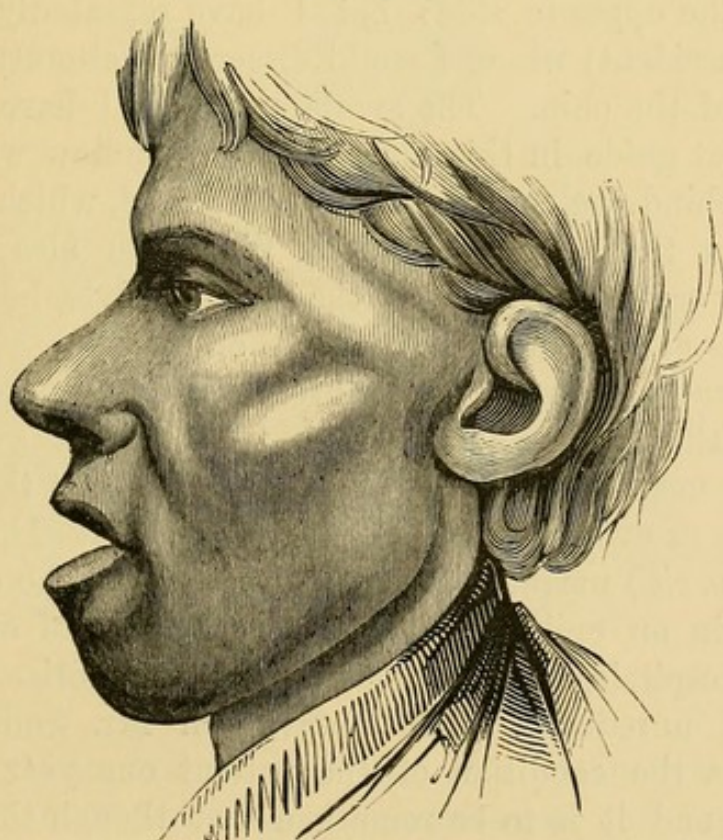


attention. The mouth is open and the jaw fixed, with the lower teeth carried beyond those of the upper jaw, as seen in fig. 42, from Fergusson. Speech and deglutition are much interfered with, since the lips cannot be approximated ; and,



for the same reason, the saliva dribbles from the mouth. On examining the neighbourhood of the temporo-maxillary joint, a distinct and unusual hollow will be seen immediately in front of the ear, and the condyle may be both seen and felt in front of this. The coronoid process forms a projection immediately behind and below the malar bone, and may be readily felt in its abnormal position from the mouth. The masseter is firmly contracted and strongly prominent. R. W. Smith, in his work on "Fractures and Dislocations," has also specially called attention to a prominence immediately *above* the zygoma, which has not been usually described, and which he believes is due to the condyle pressing forward and stretching the posterior fibres of the

FIG. 43.



temporal muscle, but which I believe to be caused by their spasmodic contraction. The accompanying drawing (fig. 43), taken, by permission, from the work referred to, illustrates both these points.



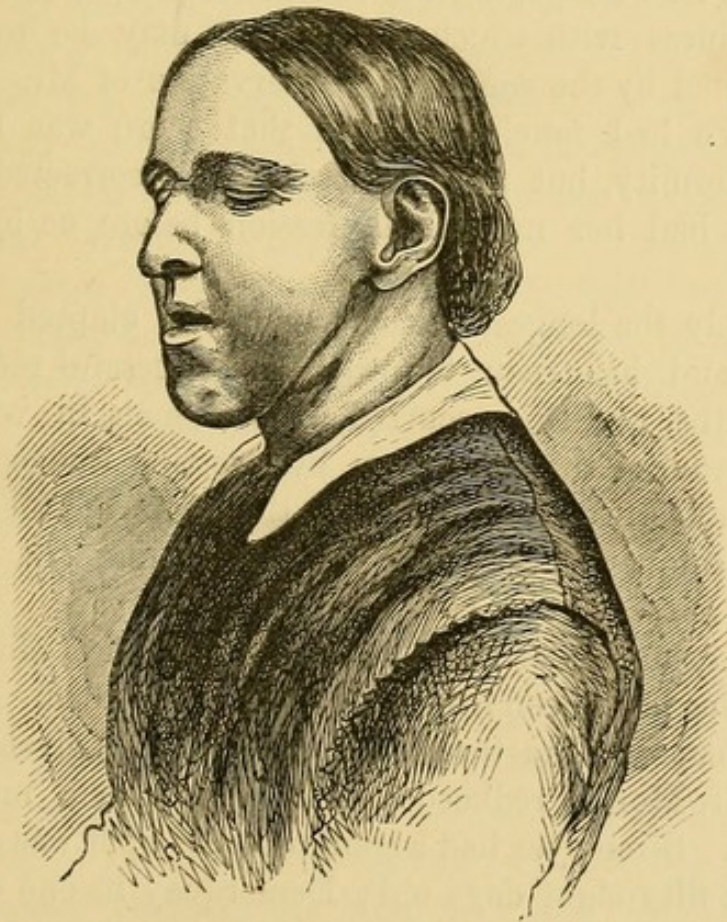
In dislocation of one condyle only the signs are less manifest, and may possibly be overlooked or misinterpreted. The chin is usually directed towards the *sound* side instead of toward the *injured* side, as is the case in fracture of the neck of the bone; the hollow in front of the ear is equally visible in this as in the double form of dislocation, and speech and deglutition are similarly to some degree interfered with. The obviousness of the direction of the chin to one side will depend in some degree upon the original prominence of that feature in the individual, and too much stress must not be laid upon the symptom: thus Hey, in his "Practical Observations in Surgery" (1814), remarks—"One would expect, from a consideration of the structure of the parts, and from the description given in systems of surgery, that the chin should be evidently turned towards the opposite side: but I have repeatedly seen the disease (accident) where I could discern no alteration in the position of the chin. The symptom which I have found to be the best guide in this case is, a small hollow which may be felt behind the condyle that is dislocated, which does not subsist on the sound side." R. W. Smith also mentions that, in a case of luxation of the right condyle, he had seen the efforts at reduction applied to the left side.

*Old-standing Dislocations.*—From various causes dislocations of the jaw have been from time to time overlooked, and have not been brought under the notice of the surgeon for weeks or even months after the accident. Thus R. W. Smith (*op. cit.*) narrates the case of a woman who dislocated her jaw in an epileptic fit, whilst an inmate of one of the Dublin hospitals, but, the accident escaping notice, the bone remained unreduced. The drawing in Mr. Smith's work represents the condition of the patient one year after the accident, and it is to be remarked that though the signs of dislocation are sufficiently obvious in the hollow in front of the ear and the projection of the chin, yet that the patient was able to close the lips so as to retain the saliva and speak intelligibly, but was able to open the mouth only to a limited extent.



Mr. John Couper has recorded an equally interesting case in the *London Hospital Reports*, vol. i. p. 262. More than three months before, the patient had dislocated her jaw bilaterally (for the second time) whilst yawning, and when seen, she presented the appearance shown in the illustration (fig. 44), for which I am indebted to the editors of the *Reports*. Mr. Couper found that the jaw had recovered a certain amount of mobility, so that the incisors of the two jaws could be approximated to within an inch, and

FIG. 44.



separated to an inch and a half, the molar teeth being nearly in contact during extreme closure. The chin was depressed and carried forward, and the hollow in front of the ear was well marked. The patient's utterance was slightly, if at all, impaired, and the labial consonants were pronounced as distinctly as other sounds, and the saliva was retained. Mr. Couper made attempts, under chloroform,



both with levers and forceps, to reduce the dislocation, but without success, but the effect of the operation was to increase the range of motion of the jaw.

A second case of old double dislocation of the jaw occurred in the London Hospital in the year following Mr. Couper's, and, being of only two months' standing, was reduced with some little difficulty by Mr. Hutchinson, who says (*London Hospital Reports*, vol. ii. p. 33): "The woman was unable to shut her mouth, and her chin struck forward, giving her face an awkward, lantern-jawed expression; but there was no wide gaping and she could easily shut her lips." The readiness with which the accident may be overlooked is illustrated by the concluding observation of Mr. Hutchinson—"We had fancied at first that there was but little facial deformity, but this impression was corrected at once when we had her natural expression before us by way of contrast."

Probably the longest period which has elapsed after the accident and has been followed by successful reduction is four months, and this occurred in a woman in whom Mr. Pollock reduced the dislocation, by inserting wedges between the molar teeth and drawing up the chin by means of a strap-tourniquet passed over the head. (*St. George's Hospital Reports*, vol. i.).

Other examples of the successful reduction of old-standing dislocations have been from time to time recorded. Thus Sir Astley Cooper ("Fractures and Dislocations") gives a case in which Mr. Morley reduced a dislocation after a month and five days. Stromeyer had a similar case. Spät was successful in a case fifty-eight days old; Demarquay in one of eighty-three days (Weber, *op. cit.*), and Donovan in one of even ninety-eight days (*Dublin Medical Press*, May, 1842).

*Rare Forms of Dislocation.*—A few cases of rare forms of dislocation with fracture have been described. The cases recorded by Robert of dislocation outwards with fracture on the opposite side, and by Mr. Croker King and Mr. Gunning of New York, of dislocation outwards and backwards with fracture of the symphysis, have been already referred



to under the head of "fracture complicated by dislocation." It might be supposed from the anatomy of the parts that dislocation backwards would be impossible without fracture of the front wall of the meatus auditorius externus or of the glenoid cavity, and the specimen in St. George's Museum (i. 28) is an instance in point. In Mr. King's case there can be little doubt that there was some injury to the meatus, from the hæmorrhage which occurred.

*Congenital Dislocations.*—Cases of congenital dislocation of the lower jaw, with more or less malformation, have been recorded by Guérin (*Gazette Médicale de Paris*, 1841) and R. W. Smith ("On Fractures in the Vicinity of Joints"), who gives elaborate drawings of the dissections of the case. Mention may be made also of the cases of congenital smallness and arrest of development recorded respectively by Langenbeck (*Archiv für Klin. Chir.*, i.) by Mr. Canton (*Pathological Society's Transactions*, vol. xii.), and Dr. Ogston's elaborate paper on "Congenital Malformation of the Lower Jaw," (*Glasgow Medical Journal*, 1875); but these subjects do not properly come within the scope of this work.

*Sub-luxation* of the jaw was first described by Sir Astley Cooper, and has been generally recognised by surgical writers since his time. It will be described in the chapter on diseases of the temporo-maxillary joint.

*Treatment of Dislocation.*—Although ordinarily requiring the assistance of the surgeon, dislocations of the jaw have been known to become reduced spontaneously, or with the aid of the patient alone. Nélaton mentions a case of spontaneous reduction occurring in his own practice; and Sir Astley Cooper narrates the case of a lady who reduced a dislocation of one side, induced by sea-sickness, with the help of an oyster-knife. Levison also gives the case of an old man who, suffering from recurring dislocation, especially when waking from sleep, "would pull his jaw and press it backwards, when, after about half an hour's work, bang it seemed to go, and all was right again."

In recent cases of dislocation, reduction may usually be accomplished with facility by various methods of manipula-



tion, but cases of long standing may require some instrumental assistance. The simplest mode is for the head of the patient to be held firmly against the breast of an assistant, while the operator, having protected his thumbs with lint or a towel twisted round them, presses them as far back as possible upon the molar teeth, grasping the jaw at the same time with his fingers. Pressure is then made downwards and backwards, so as to free the condyles from the articular eminence, and as soon as this is done the chin is elevated and the condyles slip into place. This plan may be advantageously modified by reducing the condyles successively though at the same operation, care being taken that the condyle first reduced is not again dislocated, as has happened more than once. The proceeding is thus rendered easier, because one condyle forms a point of support or fulcrum for the other, so that the entire jaw is used as a lever, instead of the thumbs forming the fulcra, as in the other method. This latter method also obviates the danger of the jaw suddenly closing upon the thumbs, though this is probably somewhat exaggerated.

Sir Astley Cooper recommended the introduction of two corks (or one in the case of single dislocation) between the molar teeth to act as fulcra, the chin being then drawn upwards; and narrates the case of a madman, where, for his own safety, he used two table-forks with a handkerchief wrapped round them to act as fulcra. The same method was originally employed by Ambrose Paré, who used wedges of wood instead of cork, and his example has been followed by numerous surgeons. Mr. Pollock employed this method successfully in 1866, in a case of dislocation of four months' standing; a gag being placed between the molar teeth, and the strap of an ordinary tourniquet being applied round the head and beneath the jaw, so that the screw might exert its power upon the dislocated bone. (*St. George's Hospital Reports*, vol. i.).

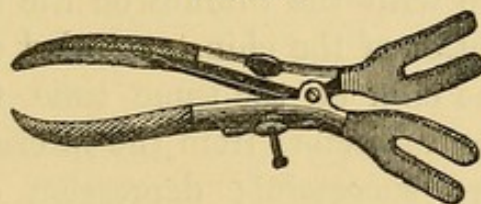
Instead of mere fulcra having been inserted between the molar teeth, levers have been employed to depress the lower jaw in cases of difficulty; thus Sir Astley Cooper narrates



that Mr. Fox, the dentist, "placed a piece of wood a foot long upon the molar tooth of one side, and raising it at the part at which he held it, depressed the point at the jaw on that side, and succeeded in reducing the condyle. He then did the same on the other side, and thus replaced the bone." Here, of course, the upper jaw formed the fulcrum, and the advantage of acting upon one condyle at a time is seen. This method is not invariably successful, however, for in the case of old dislocation under Mr. Couper's care, already related, that gentleman employed levers of pine wood six inches long without success.

A more powerful leverage action is obtained by the forceps invented by Stromeier, which is shown in the illustration (fig. 45). The forceps consists of two blades expanded

FIG. 45.



at the extremities, so as to fit pretty accurately the dental arches of the upper and lower jaws, and covered with leather. A spring between the handles tends to keep the blades closed, and a screw and nut, acting upon the handles, is able to close them so as to make the blades diverge forcibly; at the same time a movable pin loosens this, so that the blades may be closed again the moment they have done their work. The blades being closed, and introduced between the teeth as far as possible, are then separated by means of the nut and screw, until the condyles are disentangled from the articular eminences, when, being suddenly closed, they are withdrawn, an assistant at the same time pressing the jaw backwards, so as to bring the condyles into the glenoid cavities. In this way Stromeier reduced a dislocation of thirty-five days' standing.

Nélaton, whose view with regard to the locking of the coronoid processes against the malar bones has been already



referred to, advocates acting directly upon these processes, in order to force them and the condyles backwards. The surgeon may stand in front of the patient, and, with his thumbs pressing against the coronoid processes, within or without the mouth, may grasp the mastoid processes with his fingers, and thus have a firm *point d'appui* to act from; or, sitting behind the patient, he may place his thumbs on the nape of the neck, and endeavour to draw the jaw backwards with his fingers.

Maisonneuve, though differing from Nélaton with regard to the pathology of the affection, agrees with him in the propriety of acting upon the coronoid processes. The following were the conclusions he arrived at from numerous experiments on the dead body:—Blows on the cheeks or chin (which have been recommended in bygone days) were useless; pressure with the thumbs on the back teeth, combined with elevation of the chin, succeeded only a few times; depression of the chin at the same time that the thumbs pressed away the masseters from the interior of the mouth was rather more successful; depression of the chin and pressure on the coronoid processes from before backwards, with the thumbs in the mouth, effected reduction constantly and with ease.

In November, 1883, Mr. Golding Bird brought before the Clinical Society a man aged twenty-two, in whom an unreduced dislocation of both condyles had existed for eighteen weeks. After breaking down adhesions Mr. Bird succeeded in reducing the right condyle, and subsequently the left, by Nélaton's method of pressing directly upon the coronoid processes, followed by drawing up the chin.

In all cases of dislocation the administration of chloroform will facilitate the reduction, but it is not necessary in recent cases. In old-standing cases it should invariably be had recourse to, since the operation will necessarily be both painful and prolonged, in consequence of the formation of fibrous adhesions.

When reduction has been effected, the precaution should be taken to limit the movements of the jaw for a week or



two, by the use of the four-tailed bandage used in cases of fracture of the jaw. In individuals liable to recurring dislocation of the jaw (like the woman mentioned by Putégnat, whose jaw was dislocated once a month), some elastic support for the chin should be employed, and care be taken not to open the mouth too widely.

In the *Lancet* of April 14, 1883, Mr. Pughe, of Liverpool, has reported the case of a boy of four years, in whom the condyle was dislocated by a blow on the chin two years before, and in whom ankylosis between the condyle and the zygoma had taken place, causing complete closure of the jaws. Mr. Pughe resected the condyle, with the result that the patient could open his mouth to the extent of an inch, but had no lateral movement.



## CHAPTER VII.

## INFLAMMATION—ABSCESS—PERIOSTITIS.

INFLAMMATION of the periosteum leading to necrosis, and inflammation in connexion with carious teeth leading to abscess, appear to be common to both jaws, but there is a form of inflammation to which the lower jaw alone is subject, which requires notice. The inferior maxilla differs from the superior in consisting of two plates of compact tissue (of which the outer is the thinner) separated by cancellous bone, through which runs a canal for the passage of the inferior dental nerve and vessels, each of which gives an offset to each dental fang. When from the irritation of unsound teeth inflammation is excited, it rapidly spreads up the jaw, leading in a few hours to an amount of effusion into the cancellous structure which distends it, and forces out the external plate of the bone. This effusion, as I have had the opportunity of observing in my own person, is at first of discoloured serum, which by pressure on the jaw can be made to exude by the side of, or through, the hollow tooth which was the original cause of the mischief. If the source of irritation be allowed to remain, plastic effusion now takes place, leading to the formation of a distinct tumour, usually in the neighbourhood of the offending tooth. This is slowly absorbed on the early removal of the tooth, but if the irritation be allowed to continue, the effusion will become organized into fibrous tissue, and a very serious affection may thus be produced. From an attentive examination of numerous examples of fibrous tumour of the lower jaw, both before and after removal, I feel sure that the majority originate in the manner here described.



I had in the summer of 1867 a patient under my care—a boy aged fourteen—who was suffering from an enlargement of the lower jaw, due to an expansion of its wall by a growth evidently connected with a carious permanent first molar tooth. I had the peccant tooth extracted, but the enlargement of the jaw continued. In August some supuration occurred, and an abscess broke behind the angle of the jaw, but this soon healed, and in November he was perfectly free from pain and able to open the mouth thoroughly. I was anxious to perforate the jaw from the mouth so as to give exit to any fluid contained in it and extract any solid material which might exist, but the parents would not consent to any surgical interference. The face had in May, 1868, considerably diminished in size, but there was still a difference between the two sides; two years later, however, I could detect no difference between them. In a little girl of seven, also, whom I saw in 1872, with great enlargement of the right side of the lower jaw, in six years the part had resumed its natural shape. Stanley in his work on the Bones (p. 20) says, "I believe that a bone once enlarged by the expansion of its tissue will permanently remain so;" but this rule does not hold good with the lower jaw, which bone can most certainly undergo very considerable expansion and yet recover its original form.

*Abscess.*—Inflammation, the result of diseased teeth, may lead to suppuration and abscess, and this may occur either as the ordinary Alveolar Abscess or Gum-boil, or as an abscess in the substance of the jaw, either upper or lower, which is a more serious affection. In ordinary Alveolar Abscess (*parulis*) the mischief begins at the apex of the fang of a carious tooth by an effusion of plastic material, around which, according to Salter ("System of Surgery," vol. ii.), a little cavity is formed by the absorption of the alveolus, often accompanied by some amount of absorption of the fang itself. A portion of this lymph becomes converted into pus, and the remainder forms a kind of sac around it, so that it occasionally happens that, on the extraction of the peccant tooth, the sac and abscess are brought away with it.



So soon as matter is actually formed, rapid absorption of the surrounding bone takes place, and the pus makes for the surface, finding an exit either at the side of the tooth, or by perforating the socket and burrowing in the soft tissues. The direction which the pus of an alveolar abscess may take is very variable. According to Salter the commonest position for the matter to point is "on the outer surface of the jaw at a point corresponding, as nearly horizontally as may be, with the extremity of the fang of the affected tooth, and *piercing the gum within the mouth.*" But the matter may find its way on to the face, beneath the chin, or into the antrum, and, according to Tomes ("Dental Surgery"), "collections of matter, formed about the wisdom teeth, pass between the muscles and bone and escape at the angle of the jaw." Both Tomes and Salter mention the tendency of pus, derived from an upper incisor tooth, to burrow between the bone and periosteum of the hard palate and open upon the surface of the soft palate. The former also states that occasionally the pus separates the periosteum from one side of the hard palate, and forces it down to a level with the teeth.

Abscess connected with the upper incisor teeth may also point within the nostrils by small orifices presenting little teat-like elevations, which will be at once detected on a careful examination of the nostrils. The patient's attention will have probably been directed to the occasional discharge of pus from the nose, and the case may, without care, be erroneously treated as one of ozæna.

The early symptoms of alveolar abscess are those of inflammation of the periosteum lining the alveolus, and of the periodontal membrane of the tooth itself. There is a dull, obscure pain, relieved by biting upon the tooth, which appears to be raised slightly from the socket. The pain soon becomes of an acute, throbbing kind, and the constitutional symptoms are occasionally severe, amounting to high fever and delirium. The local symptoms are swelling and tenderness of the gum, and, according to Tomes, an early but evanescent symptom is a well-defined red ring encircling the neck of the tooth. The jaw becomes rapidly



swollen and the face consequently distorted, and the acute symptoms continue until the pus has found an exit, and then as rapidly subside.

*Treatment.*—In the early stage, if the affected tooth has been recently stopped, and more particularly if the nerve-pulp has been destroyed with arsenic, the stopping should be immediately removed, or a hole drilled into the pulp-cavity through the side of the tooth, so as to give exit to any accumulated fluid. (See paper on Rhizodontresis, by Mr. Hulme : *British Journal of Dental Science*, April, 1865.)

Where there is no obvious exciting cause for the inflammation, the application of one or two leeches to the gum through a leech-tube, and the subsequent fomentation of the part by means of hot water held in the mouth, may give relief; but if this is not the case, or if there be an obvious local source of irritation, extraction of the tooth, or stump of a tooth, should be immediately performed. There is a popular notion, which has received some support at the hands of certain members of the profession, that extraction of a tooth must not be performed during the stage of active inflammation of the alveolus. I know of no foundation for this statement, which is entirely devoid of truth, and yet it has formed the ground for an action against an eminent member of the dental profession. It may be well, therefore, to put on record the statement of the President of the "Association of Surgeons practising Dental Surgery," in answer to the question, "Is it right to refuse to extract a carious and aching tooth on account of the acuteness of the periosteal and maxillary inflammation which its presence has excited?" The President (Mr. Cattlin, F.R.C.S.) "was glad that Mr. Owen had brought under discussion, in his practical paper, an unskilful kind of practice which greatly increased human suffering, and was often very injurious to the patient in after-life. It was the erring practice of some to wait until the inflammation subsided; but if the tooth be retained, the swelling, as a rule, rapidly extends to adjoining parts, and sometimes causes necrosis, occasionally



infiltration into muscles, restricting the movements of the jaw, and often ending in abscess, which, bursting externally, permanently disfigures the face." (*Medical Press and Circular*, January 12, 1881.)

When matter has formed, and is finding a precarious exit by the side of the tooth, which is certainly dead and will only prove a source of irritation, its immediate extraction is the best practice. But when, as frequently happens, the matter has perforated the alveolus, and passed into the substance of the gum so as to produce an elastic fluctuating tumour between the teeth and the cheek, a free incision into it is the best and only mode of treatment; and in these cases, if the hole in the alveolus is sufficiently large to give free exit to the pus, the tooth may be eventually saved. I know of no reason for delaying the incision until the gum has become distended with pus, though the practice has its advocates. So soon as inflammatory swelling takes place, an incision will do good by relieving congestion and giving exit to exudations; and I have never seen reason to regret an early and free incision in such cases. A sharp scalpel or small bistoury is the best instrument for the operation, the ordinary gum-lancet being unsuitable and inconvenient for the purpose, and no damage to neighbouring parts can happen if the edge of the knife is directed towards the bone. I have once known the facial artery wounded from within the cheek, from neglect of this precaution.

In cases of abscess arising from the upper incisor teeth and extending along the palate, a free and early incision is even more necessary than in the ordinary form of abscess, since extensive necrosis and exfoliation of the hard palate, with consequent perforation, may not improbably result from the delay. The same rule holds good also in all cases of matter pointing within the cavity of the mouth; but where, as has already been mentioned, the matter shows a tendency to point on the skin of the face or neck, every means should be taken to avert, if possible, the opening in this situation, and to insure an exit for the matter within



the mouth. In order to fulfil the latter indication, which is most essential, the tooth or stump which has been the cause of the mischief should be immediately extracted, and a deep incision made through the gum near the spot where the matter points. It may be well to notice here, that the cause of the abscess in these cases is not unfrequently overlooked, owing to the distance between the tooth and the point where the matter appears, and that, in all cases therefore of abscess about the jaws or neck, it is well to investigate carefully the state of the mouth.

On two occasions I have known death result from a low form of cellulitis spreading between the muscles of the neck and leading to œdema of the larynx, distinctly traceable to neglected alveolar abscess, in patients whose constitution had been greatly damaged by intemperance. In the first, I had made free incisions in the mouth and neck, but œdema glottidis supervened in the night and proved fatal. In the second, I took the precaution of freely scarifying the mucous membrane of the throat, but here again, unfortunately, I was not summoned when the breathing became urgent. I would strongly advise in a similar case the early performance of laryngotomy as a safeguard, in addition to free incisions.

No greater mistake can be made than to encourage the pointing of an alveolar abscess on the surface of the skin by poulticing. During the early and acute stage of the inflammation, the warmth of a poultice may be grateful to the patient, and if applied for a few hours will do no harm, though I should myself greatly prefer the application of extract of belladonna and glycerine in equal proportions; but continued poulticing will merely lower the vitality of the part, and tend to the very result which is to be avoided if possible. Even when the skin is already reddened and adherent to the bone, its breaking may be avoided (provided a free exit for the discharge of matter into the mouth has been secured) by painting the surface with flexile collodion or with the tincture of iodine, all warm applications being discarded.



The sinuses left after an alveolar abscess has burrowed through the integuments, remain open so long as the cause of irritation is untouched, and the orifice though contracted never closes, being surrounded by granulations which sometimes grow to a large size. I recently had under my care a girl who was brought to me for the supposed growth of a horn from her chin, and the appearance was not unlike one of the horn-like growths of cuticle occasionally met with. It proved to be nothing more than a growth of epithelium on the top of long granulations around a fistulous opening, due to the presence of a stump in the lower jaw, the bone having been perforated by the abscess. The successful treatment of these sinuses, like those dependent upon the presence of dead bone elsewhere, can only be insured by the extraction of the offending tooth or stump. In these cases the fang is necrosed and forms a sequestrum in the same way as a piece of bone, and will keep up irritation so long as it is allowed to remain. The distance from the jaw at which an alveolar abscess may occasionally point not unfrequently leads to mistakes in diagnosis and treatment, particularly of the resulting sinus. I have on several occasions known a sinus, at some distance below the lower jaw, treated by injections when the fang of a tooth was keeping up irritation, and Salter has seen openings an inch below the clavicle dependent upon the same cause. I have once found the diseased fang so deeply buried and overlapped by the neighbouring teeth that it could only be detected by careful probing from the mouth, and it was necessary to remove the adjacent tooth in order to reach the cause of the sinus.

Abscess may form in the substance of the upper or lower jaw as a consequence of decayed teeth, but differing from ordinary alveolar abscess in the absence of any tendency to find an exit by the socket of the tooth. In the upper jaw this affection has been confounded with the so-called "abscess of the antrum," which is more properly an empyema, and which will be subsequently discussed; and Otto Weber (*Allgemeinen und speciellen Chirurgie*, iii.) strongly



maintains that abscess may form in the wall of the antrum, but perfectly separated from it both by the periosteum and the mucous membrane, or sometimes by a plate of bone.

Abscess in the substance of the lower jaw has been more frequently met with: thus Mr. Annandale, of Newcastle, met with a case of chronic abscess in the left side of the lower jaw of a boy aged ten, resulting apparently from repeated blows upon the part. Owing to the great thickening of the bone the abscess was not diagnosed, and the half of the jaw was removed, the boy making a good recovery. The tumour was of the size of an hen's egg, and extended from the first bicuspid tooth to the articulation. On section, the bone was found to be very dense, and contained a cavity of the size of a horse-bean, filled with pus, and lined by a distinct membrane of some thickness. (*Edinburgh Medical Journal*, December, 1860.) In a lady whom I saw with Mr. G. Bateman, there was a fluctuating swelling of the lower jaw in the incisive region, from which I evacuated by incision a quantity of offensive inspissated pus, a "residual abscess" due to irritation from incisor teeth which had been extracted some time before I saw the patient.

Another mode in which abscess may be formed in both the upper and lower jaws is by the suppuration of a "dentigerous cyst" connected with non-developed or imperfectly developed teeth. A remarkable case of this kind is reported by Weber (*op. cit.*) in which a woman, aged twenty-five, shortly after the partial eruption of a wisdom-tooth, found a tumour forming on the left side of the jaw, which in a year extended from the mental foramen to beyond the angle. The bone gave a crackling sound when pressed upon, and in one or two situations appeared to be entirely absorbed. An incision was made over it and the tissues turned aside, and on opening the tumour three ounces of thick flaky pus poured out. Part of the wall was removed, and the patient made a good recovery.

Probably the case described by Liston in his "Elements of Surgery" (p. 419), in which he mentions that osteo-



sarcoma may supervene on "spina ventosa" of the lower jaw, is an instance in point. The case was that of a young man, aged twenty-one, who had an abscess of the lower jaw in the molar region, which was evacuated through the mouth, and by means of a seton. Two years after, the abscess refilled, and again after another year; osteo-sarcoma then developed, necessitating the removal of half the jaw.

A remarkable specimen is in the Museum of King's College, of a large abscess of the lower jaw, for which half the bone was removed by Sir William Fergusson. The specimen has been divided and one half put up wet, showing the immensely thickened wall of the cavity; the other having been macerated, shows merely the shell of expanded and partially absorbed bone. The disease had followed an attack of erysipelas of the face and tooth-ache, and continued to increase for eleven years, discharging at intervals offensive matter.

*Periostitis.*—The jaws, no less than other bones of the skeleton, are subject to periostitis, which may be of the acute or chronic variety. The acute form may arise from the irritation of decayed teeth, or in young subjects from cutting the permanent teeth; from mechanical injury; or may be induced by a specific poison, such as that of the exanthemata, of mercury pushed to salivation, or the vapour of phosphorus. In strumous children, however, periostitis may occur without any obvious cause, except a constitutional taint, which leads, as we frequently see, to periostitis in other parts of the body.

Mr. Stanley, in his work on "Diseases of the Bones" (p. 71), alludes to cases of this kind, though he does not appear to connect them with a strumous diathesis. He says, "A large portion of the lower jaw in young persons occasionally perishes without any previous derangement of health, local injury, or other apparent cause. But in some cases an aching in the bone has preceded the death of it. Such examples of necrosis usually occur in early life, between the fourth and twentieth years, but rarely later."

The symptoms of periostitis are pain, which is aggra-



vated at night; heat of the part, with considerable swelling of the face and constitutional disturbance; the teeth are found to be raised somewhat from their sockets and loosened, and the least pressure upon them gives excruciating pain.

In all these cases the tendency of the inflammation to run on to suppuration, and thus induce necrosis of the bone, is so great that the disease is often not recognized in its early stage, but should it be so, the treatment relied upon in other parts of the body would be applicable here—viz., local depletion by leeches, a free incision through the affected periosteum to give exit to effusion, followed by poppy fomentations, and the exhibition of salines and sedatives.

The more chronic form of periostitis is usually of syphilitic origin, and leads to the formation of nodes here as in other parts. The palate is especially liable to these swellings, which are due to effusion between the periosteum and the bone, and which, if left untreated, will as surely lead to necrosis as the more acute forms. Mercury is inadmissible in these cases, but iodide of potassium in full doses will rapidly remove the swelling, and restore the periosteum to a healthy state.

The simple form of periostitis, which will lead to abscess and perhaps necrosis, is sometimes very insidious in its approach, and the intermittent pain, recurring usually at night, may mislead as to the original cause of the attack, the examination of the teeth being neglected, and the attention concentrated on a supposed constitutional diathesis. It is well, therefore, in all cases of supposed periosteal inflammation, to examine the condition of the teeth, both with the eye and by striking them pretty forcibly, and any tender tooth should be removed; since, according to Tomes, a greater or lesser degree of exostosis of the tooth itself is pretty certain to have taken place, which will keep up the irritation.

Dr. Gross, of Philadelphia, has called attention to a form of neuralgia occurring in edentulous jaws, and dependent



upon thickening and induration of the alveolar margin, by which the remains of the dental nerves become compressed and irritated. He recommends removal of the margin of the alveolus with cutting forceps, and speaks highly of the practice. Having seen the proceeding adopted on several occasions by Mr. Erichsen, and having used it myself, I think that there are undoubtedly cases of neuralgia which are relieved by the treatment, but that it is by no means of universal application in cases of neuralgia of the fifth nerve.

*Caries* of the jaws of idiopathic origin may be said to be unknown, for, as pointed out by Fergusson, the term caries ought not to be applied to the ulcerations met with in connection with the formation of abscesses or the separation of sequestra. In cases of ulceration and extensive destruction of the tissues of the face by syphilis or lupus, the jawbones are sometimes involved and become carious, producing the most frightful deformity; or in the case of syphilis (probably mercurio-syphilis in former years), the disease may begin in the palate and gradually destroy it, laying the mouth and nose into one, and passing forward to the face.

In the *Archiv für Pathologische Anatomie*, xviii. 347, Dr. H. Senftleben has given an elaborate description of what he terms *acute rheumatic periostitis* of the lower jaw, which appears, however, to differ in no essential particular from the ordinary form of acute periostitis following exposure, &c. He says that it attacks perfectly healthy and robust individuals with good teeth, after severe cold, commencing with violent toothache along one side of the lower jaw, considerable and often very intense fever, swelling of the cheek and gums, difficulty in chewing, &c. Active depletion is recommended, and an early incision if matter forms, but necrosis is a very frequent consequence. (*Sydenham Society's Year Book*, 1863, p. 259.)

Magitôt, in a paper read before the Academy of Medicine of Paris (1882) has described a form of alveolar periostitis, which he considers pathognomonic of diabetes. Without



going so far as this Dr. Pavyc recognizes the affection in the following extract from his work on Diabetes :—

“The teeth are not unfrequently observed to become loosened in diabetes, and it may be even to such an extent as easily to drop out. There is evidently some direct connection between this phenomenon and the disease. It seems as if the morbid condition of the system prevailing interfered with the nutritive action going on in the fang and its socket, and so led to the result. It is only when the symptoms are allowed to run on in a severe form that it is noticed, and supposing the teeth to have become already loosened, I have known them again become firm upon the disease being controlled by treatment.”



## CHAPTER VIII.

## NECROSIS OF THE JAWS.

THE jaws are specially liable to necrosis consequent upon inflammation, but there is a difference in the frequency with which the upper and lower jaw is attacked. According to Stanley ("Diseases of the Bones," p. 69), the order of frequency of necrosis of the bones of the skeleton is as follows:—Tibia, femur, humerus, flat cranial bones, *lower jaw*, last phalanx of finger, clavicle, ulna, radius, fibula, scapula, *upper jaw*, pelvic bones, sternum, ribs; and the greater immunity enjoyed by the upper as compared with the lower jaw is due, no doubt, partly to its less exposed position, but more especially to the fact that necrosis occurs less frequently in cancellous than in compact bone. The great difference in the supply of blood to the two bones must also have an influence, the upper jaw being supplied by very numerous branches of the internal maxillary arteries, which inosculate freely from side to side, whilst the lower jaw is supplied by two small branches only, which do not anastomose.

The causes and early symptoms of necrosis are usually those of periostitis, and have been described under that heading. When the inflammation fails to be arrested, the plastic effusion between the periosteum and the bone becomes rapidly converted into pus, and this, by separating the membrane from the bone, soon leads to the death of the latter. In long bones, where there is a medullary canal abundantly supplied with blood, or in the upper jaw where the vascularity is great, the bone is able to resist this necrotic action for some time, and even to recover, although bared of periosteum for a while; but in the lower jaw



this cannot be expected, and it is found that a very few hours after suppuration has been excited, the bone is in great part necrosed. This action does not extend, however, of necessity to the whole thickness of the jaw, for the disease almost invariably attacks the outer side of the bone first, and if timely relief be afforded to the pent-up matter, the periosteum on the inner side will escape injury, and that portion of the bone will be preserved. Or, even if the disease affect the whole thickness of the bone, it may still be confined to the alveolar border, which may exfoliate leaving the base of

FIG. 46.

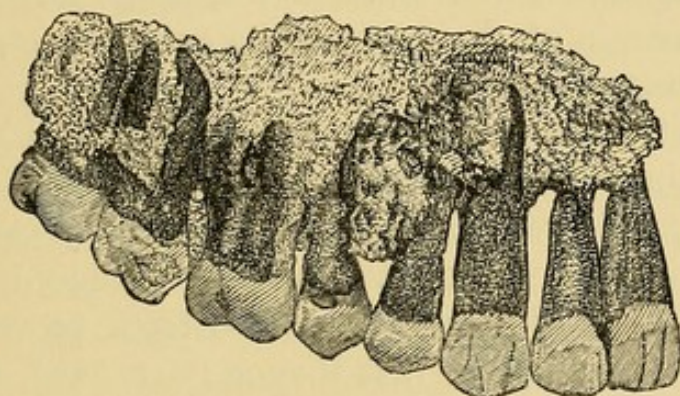
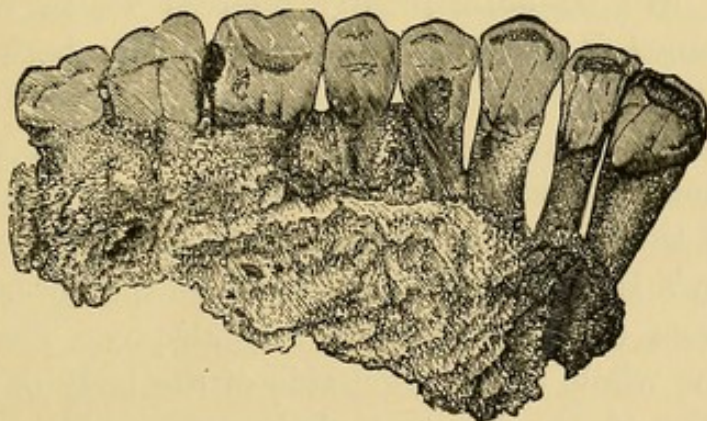


FIG. 47.



the jaw intact. Of this an excellent example is preserved in the Museum of the College of Surgeons in Dublin, where an unbroken exfoliation of the entire alveolar arch of the lower jaw, with the teeth still in it, closely resembles a set of artificial teeth. In the upper jaw also the disease may attack one part of the bone, the rest being intact, and thus a sequestrum may be formed from either the alveolus or the



palatine plate, or occasionally from both, of which a good example is seen in the preceding woodcuts, for which I am indebted to Mr. Nicholson, of Liverpool, fig. 46 showing the alveolar border, and fig. 47 the palatine plate of the sequestrum. When the pus resulting from the inflammation is unrelieved by timely incision, it tends to gravitate and find an exit for itself at the most easily reached surface. Thus, in the case of the upper jaw the tendency of the matter is to burst into the mouth, and it is the exception to find openings on the face, except when the whole of the bone is involved. In the case of the lower jaw, on the contrary, the matter finds numerous openings for itself along the lower margin of the bone, on its outer aspect, and even at some distance down the neck.

The effect of necrosis of the jaw upon the teeth is easily seen, since in cases of entire necrosis they become loose and discoloured, and even in partial necrosis they cannot bear the least pressure, owing to the pain produced. In the majority of cases of necrosis the loose teeth prove such an annoyance to the patient that they are extracted, if they do not drop out of their own accord; but cases have been met with, and will be subsequently referred to, in which the teeth remained *in situ* long after the bone was both necrosed and had been removed. In the case of young subjects, extensive necrosis of the jaw will ordinarily destroy the germs of the permanent teeth as well as the temporary teeth already cut, and of this a good example is to be seen in the Museum of St. Mary's Hospital, in a sequestrum of the lower jaw from a girl of from three to four, after small-pox. The necrosis involves the whole of the right side of the body of the bone and a portion of the ramus, including five temporary teeth and the half-developed permanent teeth, and, reaching beyond the symphysis, includes a portion of the outer plate of the left incisive region. But it has occasionally happened, after repair of the bone in young subjects, that the permanent teeth have been cut, thus leading to the supposition of a reproduction of the teeth as well as of the bone. Mr. Tomes has pointed out, that in these cases the sequestrum did not



involve the pulps of the permanent teeth, although encroaching upon them, and they therefore remained *in situ*, whilst the new bone was formed around them, and the teeth, when fully developed, made their appearance in the ordinary way.

From a consideration of these cases Mr. Tomes draws the following valuable practical deductions as regards the treatment of necrosis of the young jaw, which may be usefully referred to at this point :—"I think all will agree that it is desirable in those cases where necrosis of the jaw occurs during the presence of the temporary teeth, that the sequestrum should be allowed to remain until it is perfectly detached both from the contiguous bone and soft parts, before its withdrawal is attempted; and that its removal should be effected with the least possible injury to the latter, so that the permanent teeth, if not destroyed by the disease, may be placed under the most favourable circumstances for their future growth and evolution." ("Dental Surgery," p. 75.)

In 1868 Mr. Oliver Chalk brought before the Odontological Society some cases which, in his opinion, proved that a fresh development of teeth might occur even after the jaw, together with the germs of the second set, had been removed by necrosis. Having had the opportunity, however, of hearing the paper in question, and of examining Mr. Chalk's preparations, I must remain of my previous opinion, which coincides with that of Mr. Tomes—that such an event is impossible, and that the germs of any subsequently cut teeth must have been preserved, and become enclosed in the reparative material of the jaw. (See *British Journal of Dental Science*, Feb. 1868.)

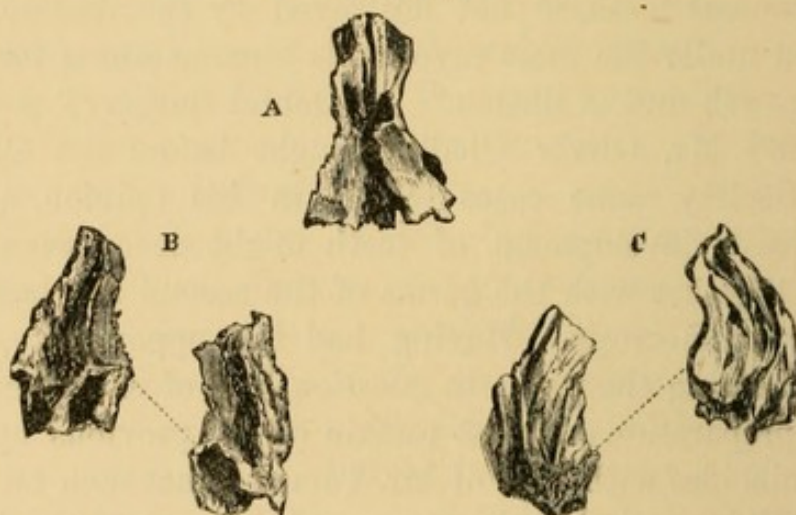
A specimen of necrosis, which accompanied this essay (College of Surgeons Museum, 1440) was from a boy named Barton Blackman, who subsequently came under my care with closure of the jaws by cicatrices, and was removed by the late Mr. Martin, of Portsmouth, in 1856, when the boy was ten years old. He had extensive necrosis of both jaws after fever, and the portions of sequestra preserved show exceedingly well the relation of the permanent to the tem-



porary teeth; in some instances the partly-formed second tooth having come away, and in others being left behind.

*Exanthematous Necrosis.*—Under this name, Mr. Salter has described (*Guy's Hospital Reports*, vol. iv., and *System of Surgery*, vol. ii.) the form of necrosis of the jaw in children which depends upon the poisonous effects of some of the exanthematous diseases, and especially scarlet fever. Mr. Salter claims to have been the first to call attention to this form of necrosis, and to trace it to its cause, and has met with over twenty instances of the affection. In the *Pathological Society's Transactions* (vol. xi.), he has described and figured seven specimens of the exfoliation—four after scarlet fever, two after measles, and one after small-pox. The disease appears to occur most frequently about the age

FIG. 48.



A, anterior; B, external; C, internal view of inter-maxillary bones.

of five or six years, when each jaw contains the whole of the first set, and the germs, more or less advanced, of the second set of teeth; but Mr. Bryant has recorded (*Pathological Soc. Trans.*, vol. x.) a case of exfoliation of the intermaxillary bones after measles, in a child of three (fig. 48), and the boy Barton Blackman, already referred to, is an instance of the kind, at the age of ten.

The disease first shows itself a few weeks after the occurrence of the feverish attack, in tenderness of the mouth and fœtor of the breath, and the gum is seen to be separated



from the teeth and alveolus. The disease is remarkably symmetrical, appearing almost simultaneously on both sides of the jaw, and rapidly denuding the bone, thus leading to necrosis and subsequent exfoliation of considerable portions of it. These usually include the whole depth of the alveolus, together with the partially-developed permanent teeth; but no case has been met with in which the lower border of the jaw was involved.

It is possible that this disorder might be confounded with *cancerum oris* in its early stage, but the absence of ulceration of the gum would at once distinguish it.

I am indebted to Mr. N. Tracy, of Ipswich, for a preparation of necrosis following scarlet fever, in a girl of thirteen, which accompanied this essay (College of Surgeons Museum, 1441). The disease was, as usual, symmetrical, but the right side was more deeply involved than the left. On the right side the sequestrum,  $1\frac{5}{8}$  inch in length, and  $\frac{5}{8}$  inch in depth, contained the permanent first molar and the uncut permanent bicuspid teeth, besides a temporary molar; and involved part of the socket of the second permanent molar behind, and of the canine in front. On the left side the disease involved only a portion of the alveolar border, including a temporary molar tooth. A model, taken three years later, showed the permanent gap left between the canine and the first molar teeth on the right side.

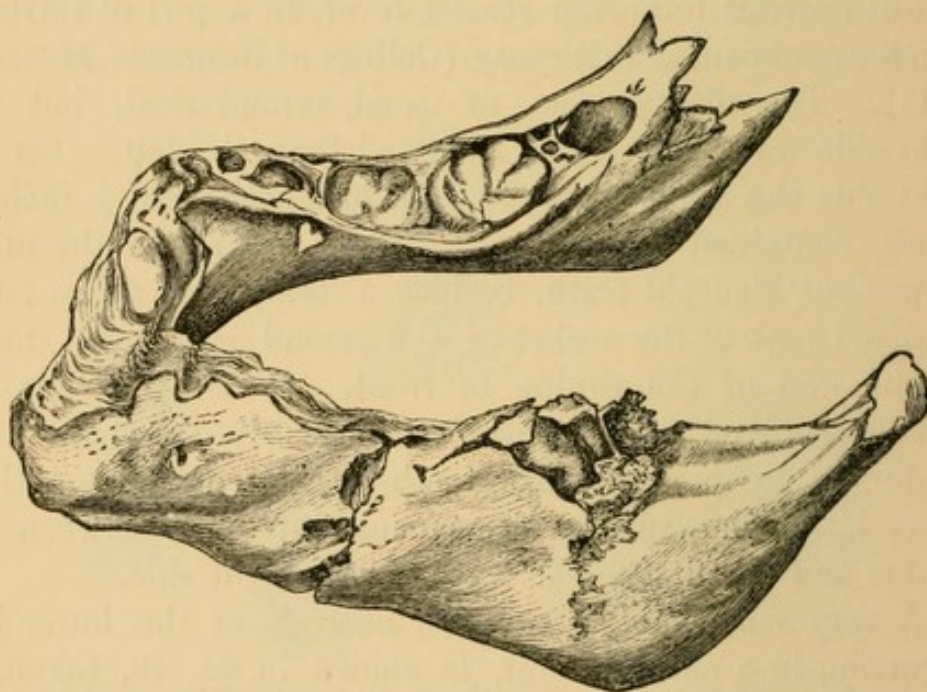
A very remarkably extensive necrosis of the lower jaw, occurring in a child of four, is shown in fig. 49, taken, by permission, from a specimen brought before the Pathological Society by Mr. Waren Tay (*Pathological Soc. Trans.*, 1874). The sequestrum includes the whole lower jaw, with the exception of one condyle, and the subsequent repair seems to have been very complete. The cause of the mischief appears to have been doubtful, but may have been due to the trick of sucking lucifer-matches, in which the child is said to have indulged. Mr. Tay brought this patient again before the Pathological Society in November, 1883, when there was a firm ring of new bone present in the situation of the jaw, quite firm enough to give support to artificial teeth if they



were supplied. At the posterior part of the left side a sharp-edged tooth has made its appearance lately. He could depress and elevate the jaw vigorously. On the left side, where the condyle was wholly removed, there was good lateral movement, but on the right side the movements were not so free, though he had no difficulty in chewing food.

Mr. Salter regards necrosis after continued fever as of rare occurrence. In the Guy's Hospital Museum, however, is a portion of lower jaw (1091, vii.), consisting of condyle, angle, and part of the body of the bone, separated by

FIG. 49.



necrosis after fever, from a boy of fourteen. He recovered with comparatively trifling deformity, and the skin remained sensitive, although a large part of the trunk of the nerve must have been destroyed. In St. George's Hospital Museum also there are specimens (II. 91 and 95) of necrosis of the lower jaw and clavicle in fever. A case of very extensive necrosis occurring after fever, under Mr. Stanley's care, will be referred to further on.

The repair of extensive necrosis of the alveolus of this character, in young persons, is a subject of some interest.



In the lower jaw no repair of the gap is necessary, since, fortunately, the disease leaves the strong lower border of the bone untouched, which preserves the contour of the face, and forms a base for artificial teeth at a later date. In the case of the upper jaw, however, a development of tough fibrous tissue takes place, which gradually fills up pretty completely the cavity left, and thus, to a great degree, prevents the falling in of the cheek and consequent deformity which would otherwise occur. In the Museum of King's College is a preparation of the nearly entire upper jaw of a child, which became necrosed as a consequence of small-pox, and was removed by Mr. Partridge, when surgeon to the Charing Cross Hospital. By the kindness of Mr. Canton, I have had access to a photograph of this patient, taken within the last few years, which shows the very slight deformity now present, in consequence of this repair of the original mischief.

This statement respecting the repair of a necrosed superior maxilla is, at first sight, in opposition to the opinion of Stanley ("On Diseases of the Bones," p. 72), who says, "under whatever circumstances the necrosis has occurred, it is not, as I believe, ever followed by the slightest reproduction of the lost bone." This I believe to be true *quoad* the reproduction of actual bone, and in the case of adults, but the filling up of the cavity by fibrous tissue I have witnessed in young subjects after the removal of tumours.

The case upon which Mr. Stanley founds the above observation is a remarkable one, from the apparent want of cause for the extensive mischief that ensued. The patient was a man aged thirty, who, twelve months before he applied to Mr. Stanley, began to suffer pain in his upper jaw, soon after which the teeth fell out of their sockets, and matter was discharged into the mouth. When the dead bone was sufficiently loosened, Mr. Stanley drew away the greater part of both superior maxillæ.

A very similar case occurring in a strumous man, aged forty, is recorded by Mr. Ernest Hart, in the *Lancet*, 19th July, 1862, and, by the kindness of that gentleman, I am



enabled to reproduce the drawings of the bones when removed, and of the patient after the operation.

FIG. 50.

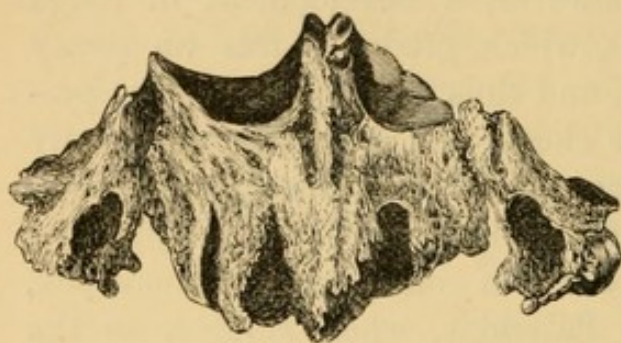


FIG. 51.



A second case, very similar to the above as respects the absence of cause for the disease, has been recently under my notice, the report of it having been kindly furnished to me by Dr. Garnham, of the Peninsular and Oriental Company's Service. The patient, aged forty, was an engineer in the Company's service, and enjoyed perfectly good health in the tropics for some years, but soon after his return to England his mouth became sore, sloughing of the gums took place, and, when I first saw him, very large portions of the alveolus of the lower jaw were necrosed, and lying exposed in the mouth. Subsequently these came away or were removed by Dr. Garnham, and the patient having been reduced to an edentulous condition, as regards the lower jaw, it became necessary to apply to Mr. C. J. Fox, the dentist, for artificial aid. Dr. Garnham attributes the disease to depression of the vital powers, owing to long residence in warm climates.

Any ulcerative affection of the mouth may lead to necrosis of the jaw: thus it has been met with during scurvy, after cancrum oris, and after mercurial salivation. A very extensive sequestrum resulting from cancrum oris is preserved in Guy's Museum (1091, v.), consisting of the symphysis and horizontal rami of the lower jaw, together with the first two molar teeth. Four years after its re-



moval, an osseous growth was found to have taken the place of the original portion of the lower jaw, the power of mastication being good and the sense of feeling nearly perfect. Profuse salivation from mercury being now of rare occurrence, necrosis from this cause is but seldom met with; but in former years the remedy seems sometimes to have been worse than the disease: thus Mr. Key presented to Guy's Museum a sequestrum consisting of two-thirds of the alveolar processes of the lower jaw, the disease having been induced by the use of mercury for ovarian dropsy. The exfoliation of the entire alveolus in the Museum of the Dublin College of Surgeons, already described, was also due to the exhibition of mercury. In the *American Medical Times* of February 23, 1861, Dr. E. S. Cooper records the case of a child, aged seven, in whom necrosis involving the left half of the lower jaw, including the coronoid and condyloid processes, had been produced by the administration of calomel. After removal of the sequestrum reproduction of the jaw took place, the reproduced bone being at first very much larger than the natural bone, but gradually improving in shape.

Mr. Stanley mentions (p. 72), and gives a drawing of a sequestrum preserved in St. Bartholomew's Museum (I. 102), embracing nearly the whole body of the lower jaw, which suffered necrosis after the administration of a few grains of calomel in a case of fever. It might be doubted whether the necrosis was not due as much to the fever as to the calomel in this case, but that Mr. Stanley mentions that the patient had excessive salivation and severe inflammation in the gums and cheeks.

The severe form of mercurial necrosis, of which patients suffering from syphilis were mostly the victims in the days when salivation was looked upon as a necessary part of the treatment, is now practically unknown. It was formerly met with also as a result of the destructive ptyalism, produced by the fumes of liquid mercury employed in the manufacture of looking-glasses. When glass plates were converted into mirrors by sliding and compressing them



on to sheets of tin-foil covered with pure quicksilver, the men employed were liable to have their teeth drop out, and frequently lost portions of the jaws, their lives being notoriously shortened. Since the introduction of a chemical process by which the mercury is deposited on the glass, these cases of induced necrosis have become almost unknown.

*Syphilitic poison* frequently produces necrosis of the jaws ; and here we find the observation of Stanley hold good as in other parts of the body. He says (p. 76) " Syphilis produces its effects mostly upon the compact osseous textures, and in portions of bones which have thin soft coverings, as the flat cranial bones ;" and it is in the compact tissue of the palatine plate of the superior maxilla, which is thinly covered by mucous membrane, that we find the ravages of syphilis most frequent. Occasionally the disease leads to necrosis of portions of the compact tissue of the lower jaw, or attacks the alveolus, or body of the upper jaw. Of this I have lately had two examples under my own care, one in a medical man, from whom I extracted a large piece of necrosed alveolus, and the other in a discharged soldier, aged twenty-three, in whom also there was extensive necrosis of the alveolus, extending from the lateral incisor to the first molar on the right side. There was no question as to the cause of the disease in either case. In cases of extensive tertiary ulceration of the face also, the bones may become secondarily affected.

The question of the influence of syphilis in producing necrosis of the alveolus, derives additional interest from the recent trial of an action against a dentist for damage due to necrosis, said to have been caused by the unskilful extraction of a tooth some months before. In this case one surgeon swore that necrosis of the jaw from syphilis was unknown, whilst the opposite view was strongly maintained by surgeons of great experience in syphilitic diseases (*British Medical Journal*, August, 1871).

The proper local treatment of any ulceration or necrosis of the palate is to protect the part from contact of the



tongue and food, and to close the aperture by a properly fitting plate of metal or vulcanite, attached to the teeth and arching immediately below the palate, without making pressure upon the edges of the hole itself. A caution may be given against any attempt on the part of the surgeon or patient to fill the gap in the roof of the mouth by any form of plug fitting into the hole left, the effect of which is to enlarge the aperture by absorption, so that the size of the plug has to be constantly increased in order to make it effectual. A preparation in St. Bartholomew's Museum shows the extent to which this absorption may be carried in process of years. The following is the description given in the Museum Catalogue :—

“The base of a skull from an elderly woman, who appeared to have been long in the habit of wearing a plug to close an opening in the palate. The opening gradually enlarging, attained such a size that nothing remains of the palatine portions of the superior maxillary and palate bones, and the alveolar border of the jaw is reduced to a very thin plate, without any trace of the sockets of the teeth. The antrum is on both sides obliterated by the apposition of its walls, its inner wall having probably been pushed outwards as the plug was enlarged to fit the enlarging aperture in the palate. Nearly the whole of the vomer also has been destroyed, and the superior ethmoidal cells are laid open. The plug is preserved ; it is composed of a large circular cork, with tape wound round it, and measures an inch and three-quarters in diameter, and an inch in depth. The history of the patient is unknown. She was brought from a workhouse to the dissecting rooms, with the plug tightly and smoothly fitted in the roof of the mouth.”—*St. Bartholomew's Catalogue*, 14.

Even the employment of a piece of softened gutta-percha is not unattended with risk : thus, several years ago I saw, with Mr. Lawson, a case in which the patient had thrust a considerable quantity of softened gutta-percha through an aperture in the palate into the nostril, where it formed a hard mass, which was extracted only with the greatest



difficulty and at the expense of tearing one of the alæ.

*Phosphorus-Necrosis.*—This, which is perhaps the most formidable kind of necrosis of the jaw, is a disease of modern time, having been called into existence only since the introduction of lucifer-matches, into the inflammable material of which phosphorus largely enters. The earliest mention by British writers of disease in connexion with the manufacture of lucifers, appears to have been by Dr. Wilks, in the *Guy's Hospital Reports* of 1846–47; but a paragraph from a German author upon the subject is quoted in the *Lancet* of August 29, 1846. The notice in the *Guy's Hospital Reports* is of a case of disease of the lower jaw with exfoliation, occurring in a lucifer-match maker; and the remark is made that the disease had been noticed to be common among workers in lucifer manufactories—a branch of industry which had then been introduced into London some ten years. In Germany, however (where lucifer manufactories were started some years earlier than in England), phosphorus-necrosis was recognised as early as 1839 by Lorinser, who published a paper upon the subject in 1845, and was followed by Strohl, Heyfelder, Roussel, and Gendrin, and by Sédillot, in 1846. In 1847 Drs. Von Bibra and Geist, of Erlangen, published a work (*Die Krankheiten der Arbeiter in den Phosphorzündholzfabriken, insbesondere das Leiden der Kieferknochen durch Phosphordämpfe*), which forms the basis of our present knowledge of the subject, and the conclusions of which further experience has fully confirmed.

In London the lucifer manufactories being principally at the East-end, cases of phosphorus-necrosis are most common in St. Bartholomew's, the London, and the Borough hospitals; and their museums, especially that of St. Bartholomew's, are very rich in specimens. The medical officers of these institutions having thus had special opportunities of study, have not failed to record their experience, and reference may be made to valuable clinical lectures upon the



subject by Mr. Simon (*Lancet*, 1850), Sir J. Paget (*Medical Times and Gazette*, 1862), and Mr. Adams (*Medical Times and Gazette*, 1863); and to the essay on Surgical Diseases connected with the Teeth, by Mr. J. Salter (*System of Surgery*, vol. ii.).

The cause of the disease is, unquestionably, the fumes of the phosphorus which are inhaled by the operatives during the process of "dipping" the matches, and in a lesser degree during the counting and packing them. When the disease first showed itself in Germany, it was thought that it depended upon the admixture of arsenic with the phosphorus; and it is curious that in the Museum of St. Bartholomew's there are some bones of cows from the neighbourhood of Swansea, which, under the influence of arsenical vapour, have become enlarged and covered with a new bone formation closely resembling that around phosphorus-necrosis. It has been proved, however, that arsenic has nothing to do with the disease; and if proof positive were wanting that phosphorus alone is the deleterious agent, it is supplied by a case quoted by Sir J. Paget, in the lecture referred to, of a man who induced necrosis of his jaws by inhaling fumes of phosphoric acid as a quack remedy for "nervousness."

Lorinser and the earlier writers considered the disease to consist in blood-poisoning, the necrosis of the jaw being consequent thereupon, and Mr. Adams (*loc. cit.*) thinks that the theory of blood-poisoning should not be altogether discarded, since the local disease would not account for the constitutional symptoms experienced. This view has recently received the support of the eminent Berlin surgeon Von Langenbeck, who maintains that all the general symptoms of phosphorus-poisoning are present long before the local disease, which he calls periostitis rather than necrosis, manifests itself. (*Berliner Klinische Wochenschrift*, Jan. 8th, 1872.) The majority of surgeons agree, however, in considering the affection essentially a local one, the constitutional symptoms being only consecutive, and an interest-



ing account of the post-mortem examination of a case of general poisoning by phosphorus, following necrosis of the jaw, will be found in the *Pathological Society's Transactions* for 1869.

It is found that the phosphorus fumes produce no injurious effects so long as the teeth and gums of the workers are sound, but as soon as the teeth become carious, or if a tooth is extracted so as to leave an open socket, the disease rapidly develops itself. The experiments upon animals, by Geist and Von Bibra, are amply confirmatory of this view, since they found that rabbits exposed to phosphoric fumes suffered no injury so long as the teeth and jaws were uninjured, but that if the teeth were extracted or the jaw broken periostitis and necrosis rapidly resulted. On the other hand, it may be mentioned that a case has been recorded by Grandidier (*Journal für Kinderkrankheiten*, 1861), of necrosis of the upper jaw from phosphorus fumes in a child but six weeks old, and in whom therefore the teeth were not developed, and Langenbeck is opposed to the notion that carious teeth predispose to the disorder.

The liability of the two jaws to the disease appears to be about the same, or perhaps with a slight preponderance in favour of the lower jaw. Of 52 cases given by German authorities, 21 were of the superior maxilla, 25 of the inferior maxilla; in 5 both jaws were involved, and one case is uncertain. (*British and Foreign Medico-Chirurgical Review*, April, 1848.) Mr. Salter (*loc. cit.*) says, "In five cases which I have witnessed, the lower jaw was diseased in four, and the upper in one; whereas four which occurred in the practice of a surgical friend, were confined to the upper jaw. In seventeen instances of which I have obtained particulars or seen specimens, nine were connected with the superior, and eight with the inferior maxilla. The disease is therefore pretty evenly balanced between the two jaws." The St. Bartholomew's Hospital Museum contains excellent specimens of both jaws affected by this form of disease.

The *Symptoms of Necrosis* of the jaws, from whatever



cause, are much the same, but as they present themselves in the most marked degree in phosphorus-necrosis, it will be convenient to describe them under this head.

Pain referred to the teeth is one of the earliest symptoms of the disease, and this, which was intermittent at first, becomes at length continuous. The teeth become loose, and pus is seen to exude from their sockets. At the same time the gums become swollen and tender, and are detached to a greater or lesser degree from the alveoli, giving constant exit to a purulent discharge. In all cases of necrosis the face is swollen, so that, if only one side of the jaw is affected, a peculiar lop-sided effect is produced. In the cases of phosphorus-necrosis, however, the swelling of the face is much more marked, the soft tissues around the bone being infiltrated and puffy to an extent which is not witnessed in other forms of the disease. One or more openings now form externally, through which pus constantly exudes, and the probe introduced through these, readily reaches bare and dead bone.

The patient's general health has by this time become seriously affected, owing both to the actual suffering he has undergone, and to the interference with his nutrition which the state of his mouth necessarily involves; it being impossible for him to take any but fluid or semi-fluid food, and that in small quantities. The constant presence of most offensive discharges in the mouth, and mixing with the food, must have an injurious effect upon the patient, though this is questioned by Salter, who remarks that these patients swallow daily many ounces of pus "without any obvious detriment to health." The necrosed portions of bone project more or less into the mouth, and give the patient great inconvenience, and in very severe cases of phosphorus-necrosis gangrene of the cheeks and lips ensues, with a rapidly fatal termination. In less severe cases, the patient may drag on a wretched existence for months, and sink at last from exhaustion, or may occasionally recover with considerable loss of bone and deformity.

Advanced necrosis of the upper jaw may lead to exten-



sion of mischief to the brain with a fatal result, as I have myself seen on one occasion. The patient was a young woman, aged twenty-three, in whom necrosis of the upper jaw had existed for nine months, when head symptoms supervened, and she rapidly sank and died comatose. At the post-mortem examination, I found an abscess in the anterior lobe of the cerebrum, evidently originating from the ethmoid bone, the cribriform plate of which was necrosed and perforated.



## CHAPTER IX.

## REPAIR AFTER NECROSIS—TREATMENT OF NECROSIS.

It has been already remarked under the head of Exanthematous Necrosis, that in young subjects a development of fibrous tissue takes place after loss of substance in the upper jaw. This is not the case when loss of part of the superior maxilla takes place in adult life, except in rare instances, it being remarkable that the periosteum of the upper jaw ordinarily makes no effort at repairing, by effusion, the mischief which has taken place. M. Ollier, of Lyons, in his very valuable work "*La Régénération des Os*," (1867) gives a case of phosphorus-necrosis of the upper jaws where a certain amount of new bone was produced, and also one of necrosis of the upper jaw from other causes, in which a development of osteo-fibrous tissue took place in a young woman of nineteen. He quotes also from the practice of Billroth, of Zurich, the case of a man, aged twenty-seven, in whom, after phosphorus-necrosis, a development of plates of bone took place. These cases must be regarded, however, as quite exceptional, Trélat in his thesis (1857), having failed to discover a case of osseous reproduction of the superior maxilla. In the lower jaw, however, the case is very different, the periosteum and the surrounding tissues being very active in producing new bone, to take the place eventually of that which is necrosed.

So soon as the periosteum is separated from the jaw by the formation of pus around the sequestrum, it appears to take on an active condition which leads to the effusion of plastic lymph. This becomes rapidly converted into fibro-cartilage and then into bone, which forms a more or less complete shell around the necrosed portion. Through the *cloacæ*, or openings in this new shell of bone,



which correspond to the external apertures on the skin, and also from the mouth, the dead bone or *sequestrum* can be readily examined with the probe, and, when sufficiently detached and loosened to be readily extracted, it should be removed if possible through the mouth so as to avoid deformity from an external wound. It is of importance that this removal should not be undertaken until the shell of new bone is sufficiently organized to maintain the shape of the original bone, for if otherwise, the reproduction of the bone will be interfered with, and perhaps prevented. So soon as the sequestrum is removed from the interior of the shell of new bone, the space thus left becomes rapidly filled with granulations springing up from the whole surface of the cavity, and these are soon converted into a fibrous mass which is ultimately developed into bone. In 1869 I had under my care in University College Hospital a case of necrosis of nearly the entire lower jaw in a man of twenty-two, from whose mouth I extracted several large sequestra, including the right condyle. In this case, and in others of the kind which I have seen, the repair has been of the most perfect kind, the movements of the jaw being as free as if the articulation had not been interfered with. The details of the case will be found in the Appendix (Case VI.).

In the *Medico-Chirurgical Trans.*, vol. lvii., is a case of phosphorus-necrosis, reported by Mr. Savory, in which, six months before the death of the patient, a lad of eighteen, the whole of the lower jaw was extracted, and is preserved in St. Bartholomew's Museum (I. 232). Although "at this time there was not sufficient firmness in any part of the region to indicate the formation of new bone, yet in the course of a week or two afterwards there was distinct evidence of new bone on either side about the angle, which gradually extended." The new lower jaw which had been formed is shown in fig. 52, and is perhaps one of the most perfect specimens of the kind ever seen. "In size, shape, and development it is very remarkable. The bone is solid and dense and in two pieces only. The greater portion constitutes the whole of the bone, with the exception of the



FIG. 52.

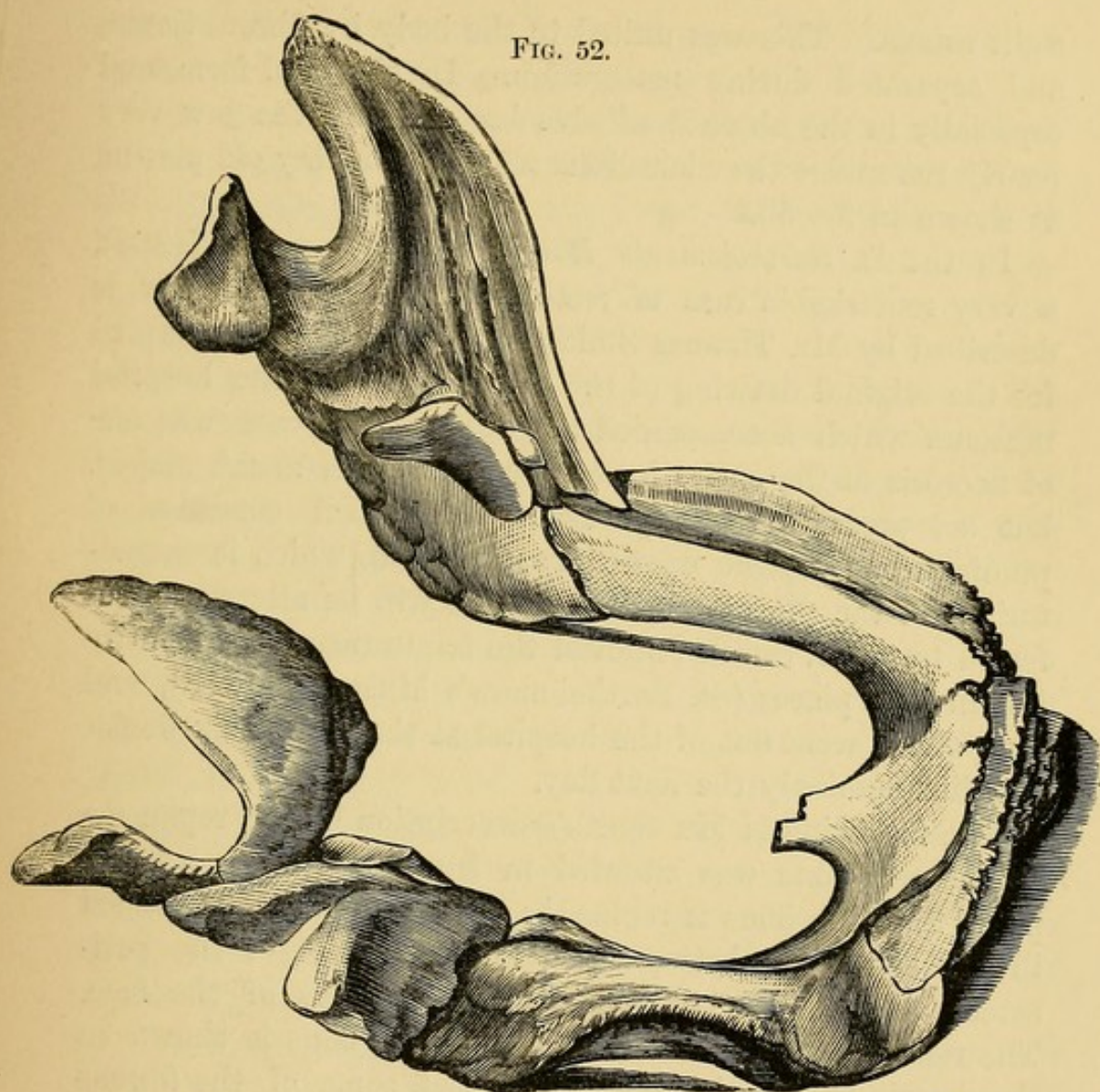
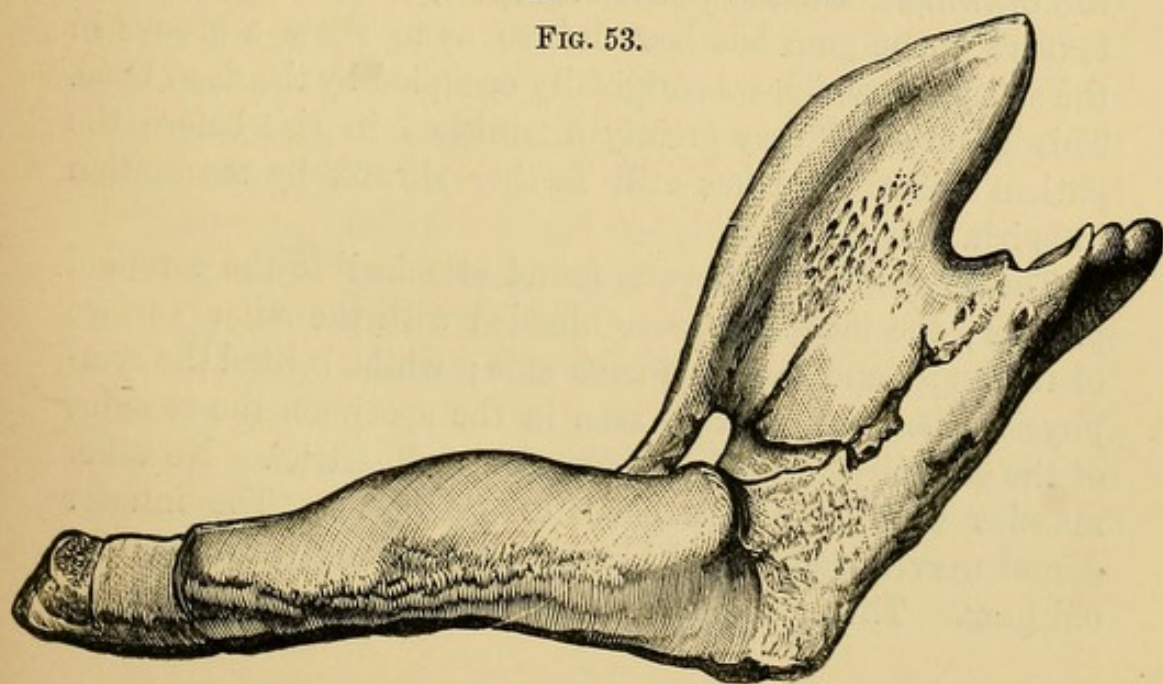


FIG. 53.





right ramus. This was united to the body by fibrous tissue, and separated during maceration. In size and form, and especially in the absence of alveolar portions, the jaw very nearly resembles the edentulous maxilla of a very old person, as shown in fig. 53.

In the *St. Bartholomew's Hospital Reports*, vol. i. (1865), a very remarkable case of restoration of the lower jaw is described by Mr. Thomas Smith, to whom I was indebted for the original drawing of the preparations in the hospital museum which accompanied this essay. The case was one of necrosis of the entire lower jaw in a lucifer-match maker, but *not* presenting the peculiar pathological condition of pumice-stone deposit upon the sequestrum, which is characteristic of the phosphorus disease and will be afterwards referred to. Mr. Smith removed the sequestrum of the entire jaw in two pieces (*St. Bartholomew's Museum*, I. 233), and the patient went out of the hospital at the end of six weeks, but died suddenly the next day.

The following is Mr. Smith's description of the repair:—  
“The new bone was situated in front of and on a lower plane than the bone it replaced; it was distinctly embedded in the soft parts between the anterior layer of the periosteum of the old jaw and the integuments of the face. The relative position of the old and new bone is shown in the drawing. On the posterior aspect, some of the fibrous texture of the gum has been left so as to show a groove in the soft parts, which was originally occupied by the dead bone. This groove had very greatly diminished in size before the patient's death, and has still further shrunk by maceration in spirit.

The temporal muscle was found attached to the coronoid process; the masseters were blended with the outer surface of the angle and ramus of each side; while, behind the symphysis, there may still be seen in the specimen the remains of the genio-hyoid, genio-hyoglossi, and digastrici. No other muscles were found attached to the bone. The inferior dental nerves were found lying in the fibrous texture of the old gum. There is apparently no provision for them in the



new jaw, from which they lay quite separated by both layers of the periosteum of the necrosed jaw.

The new bone consisted chiefly of three portions, of which two are formed by the coronoid process and condyle together, of either side; whilst the third and largest portion represents the right ascending ramus, the angle, horizontal ramus, and symphysis, and extends as far as the position of the eye-tooth on the left side. The part of the jaw that is wholly deficient in bony structure is included between the position of the eye-tooth and last molar of the left side. The parts in which most bone is found being apparently those points where ossification commenced, on the coronoid processes, the angles, and especially the neighbourhood of the symphysis, where the bone is more abundant, denser in its structure, and more perfectly formed than elsewhere.

The newly-formed jaw, on microscopic examination, shows all degrees of development, from a finely fibro-nuclear matrix up to perfect bone. The bone differs from ordinary compact bone in being excessively vascular, the Haversian canals being very large, near together, freely anastomosing, and here and there in their wall presenting fusiform and pouch-like dilatations, in fact, resembling in their outlines veins slightly varicose.

The bone is thickly studded with lacunæ, and these are peculiar in being very large in their cavities, less uniform in their general outline, and bearing fewer canaliculi than is usual in well-formed bone. In the newest parts of the bone the lacunæ are merely irregularly formed cavities without distinct canaliculi.

From the relation of the dead bone to the soft parts, lying as it did in a fossa formed by the gaping gums, from the relation of this fossa to the new bone, as seen in the specimen, it is evident that the regeneration of bone in this case did not take place from the osseous surface of the periosteum, but rather from the fibrous structure of the gum in front of the original jaw. The only portion of bone in this case formed directly from the detached periosteum, was removed at the time of the operation, and may be seen in the



necrosed jaw adhering to the ramus and angle of the left side. It formed no part of that system of bone formation which eventually reproduced the jaw."

This case is remarkable in more ways than one. In the first place, the absence of the pumice-like deposit upon the sequestrum would appear to exclude it from the category of phosphorus-necrosis, but the patient was undoubtedly exposed to the action of phosphorus, and it will be shown at a later period that this deposit is not of necessity connected with phosphorus. The second notable point is, that according to Mr. Smith's description the reparative material was formed not around, but entirely in front of or below the sequestrum. The third point, still more remarkable, is, that if Mr. Smith's observation is correct, the new structure was entirely *outside* the periosteum of the jaw, and was derived entirely from the surrounding soft parts.

Mr. Smith is too accurate an observer to have been deceived by the appearances, and we must conclude, therefore, that not only was the bone killed by the action of the poison, but that the periosteum also lost its vitality to such an extent that it was unable to secrete that pumice-like bone usually found in these cases, or to assist in any way to form reparative material. That the surrounding soft parts should under these circumstances have assumed the reparative function to the extent they did, is a remarkable instance of the adapting powers of Nature.

In commenting upon the above case, Mr. Smith expresses an opinion that "of late the office of the periosteum as an osteogenetic membrane has been much magnified at the expense and to the disparagement of other sources of bone reproduction." M. Ollier, on the other hand, whose physiological researches on the nature of periosteum are well known, in his work already alluded to, strongly maintains the bone-producing power of the periosteum and advises its preservation where possible; giving cases where this has been followed by the reproduction of bone, as has been frequently witnessed in England. The question of the so-called sub-



periosteal resection will be discussed under the head of Treatment of Necrosis.

Whatever the tissue from which the bone is reproduced, there can be no question as to the fact of its reproduction in the majority of instances of necrosis of the lower jaw. Even when, as in my own case already mentioned, the condyle with a large portion of the ramus of the jaw is necrosed, complete repair has been found in young subjects. Stanley, however, quotes a case of this kind from Desault, as one "of the least frequent examples of the reproduction of bone consequent on necrosis," and refers to one recorded by Mr. Syme. As additional examples may be quoted one by the late Mr. H. Gray (*Pathological Transactions*, vol. ii.), which occurred in the practice of Mr. Keate, and one by Dr. Cooper, of San Francisco, which has been already referred to. A case of sub-periosteal resection of one half of the jaw by M. Maisonneuve, in which complete repair took place, will be referred to further on. On the other hand it should be remarked that several instances of non-repair of lost bone have been recorded. Thus Stanley mentions a case under the care of Mr. Perry, which will be referred to again, in which no repair took place; and three similar cases are to be found in South's *Chelius*. Also in the *Lancet*, 25th January, 1862, it is mentioned that a patient from whom Mr. T. Wakley removed an extensive necrosis in 1857, was at that time to be seen about the streets exhibiting himself for a livelihood, and everting his mouth to show that his lower jaw was absent.

A remarkable feature in Mr. Perry's case, already mentioned, was, that though the entire jaw was necrosed and removed, yet "nearly all the teeth remained in the mouth, and were kept together by their connexion with the gum;" and according to Mr. Stanley, the patient "chewed her food by a movement of the upper jaw (?), aided by the action of the tongue in rubbing the morsel against the teeth." Extraordinary as it appears, that the teeth should thus remain *in situ*, the fact is undoubted, and is confirmed by other examples: thus, Mr. Sharp, of Bradford (*Medico-Chirurgical*



*Transactions*, vol. xxvii.), removed a large sequestrum from a young woman, aged twenty, through an incision beneath the chin, and all the teeth remained firm. In the *Medical Times and Gazette* of October 30th, 1858, also, it is mentioned that Mr. Skey brought before the students of St. Bartholomew's a young man of twenty, from whom, four months before, he had removed a sequestrum including the entire left side of the jaw from the ramus to the symphysis, and the right side as far as the last molar tooth. The sequestrum showed the sockets of twelve teeth—viz., all those of the left side, and the incisors, canine, and first bicuspid of the right side; but the whole of the alveolar border of the right side was not present in the sequestrum. Instead of coming away with the bone, the incisors, canine, and first bicuspid of the right side, and even the left central incisor had remained in the gum. The patient now applied to Mr. Skey to have these teeth removed, as, although they evidently possessed vitality and were firmly attached to the gums, they had sunk in position so as to be irregular and inconvenient. I have, however, seen one case in which the teeth remained firm and useful after extensive necrosis; but in this case the sequestrum involved only the outer plate of the jaw, the inner with a great part of each socket being left for the support of the fangs of the teeth.

An observation of Mr. Salter's (*System of Surgery*, vol. ii.) deserves notice, and it received confirmation from one of the cases recorded by Mr. Chalk in the paper already referred to. He says, "Though it has not been stated in books, this repair of the lower jaw is but temporary, for after a time—often a considerable time—the new bone diminishes by absorption to a mere arch, and ultimately there is scarcely enough bone to keep out the lower lip, and the chin is utterly lost. I have had an opportunity of examining this state of parts after the lower jaw had been removed ten years. How far this loss, by absorption of supplemental bone, may be prevented by supplying it with a function through the means of artificial teeth, is a question of theoretical interest and of practical importance."



One, almost constant, pathological peculiarity in cases of phosphorus-necrosis has been already alluded to, and deserves special notice ; it is the deposit of a peculiar, pumice-like, bony material around the necrosed portions of the lower jaw, for it is not found in cases of disease of the upper jaw. This is doubtless derived from the periosteum, although so closely adherent to the sequestrum as to be invariably brought away with it ; and though resembling true bone in some particulars, it is decidedly of a lower development.

According to Von Bibra (*op. cit.*), who has laboriously investigated the subject microscopically, the Haversian canals exhibit in part a larger diameter than those of normal bone and are empty, except where the deposit appears smooth and compact, and is partially covered with periosteum. They are *not parallel* with the general direction of the bone, but are placed *at right angles* to the latter ; they interlace with one another, sometimes expanding to form sacs, sometimes contracting, and end with open mouths on the surface. Their mouths are more minute in the most recent deposit, and appear larger in older layers. The bone corpuscles are rounded off or angular, and their circumference is less decided ; during the progress of the formation of the deposit they are very large, and their contour proportionably undefined. They appear filled and dark-coloured ; at first they are lighter and they have ramifications like those of normal bone, which increase in number with the age of the deposit. The fundamental structure of the deposit is laminated, and several layers are distinctly seen resting upon one another. It exhibits rents with which the ramifications of the corpuscles are connected, and which may therefore be considered as continuations of the latter. Spots are also visible here and there, which Von Bibra looks upon as accumulations of earthy matter. This matrix of the new deposit is at first very brittle ; after the deposit has been exposed to the process of absorption it shows a powdery appearance, as if sprinkled with a coarse powder.

This description of the microscopic appearances may be advantageously contrasted with that of the new bone in



Mr. T. Smith's case of restoration of the jaw (p. 131), of which the Haversian canals were parallel to those of the original bone instead of being at right angles to them, which is such a marked peculiarity of the pumice-like deposit.

It appears, however, that cases of necrosis other than those due to phosphorus occasionally lead to a deposit of pumice-like bone upon the sequestrum. Mr. Perry's case of necrosis of the entire lower jaw, already alluded to (and which will be found *in extenso* in the *Medico-Chirurgical Transactions*, vol. xxi.), is a case in point, the sequestrum, as may be seen from the drawing given of the preparation in St. Bartholomew's Museum, being thickly encrusted with new bone, closely resembling that seen in phosphorus cases. The disease in this case was attributed to rheumatism, and corresponds very closely to the description given by Dr. Senftleben of the later stages of acute rheumatic periostitis. (See p. 108.) He says, "Spontaneous separation of the sequestrum rarely ensues; it remains to some extent in organic connection with the osteophytes, and ultimately, after a number of months, a year, or even more, an operation has to be performed, in which both the sequestrum and the osteophytes are removed together." So far as I am aware, the new bone in Mr. Perry's case has not been submitted to microscopic examination.

A preparation in the College of Surgeons Museum (1442) bears upon this question. It is a portion of the lower jaw of a girl æt. ten, consisting of the condyle and part of the ramus and the coronoid process (separate), for which I was indebted to Mr. Lawson. The symptoms were those of necrosis, there being abscess, &c.; and in December, 1866, that gentleman cut down upon the seat of the disease and removed those portions which were separated from the rest of the bone. The preparation shows the ramus of the jaw at the lower part of normal thickness and apparently necrosed, but at the upper part there is around it a deposit of new bone, very closely resembling the pumice-stone deposit of phosphorus-necrosis. A portion of this has been detached, but it may be observed that the articular cartilage is perfect,



and the periosteum near it healthy, although, owing to the new deposit, the condyle and neck of the jaw are greatly altered in shape. This appears to me to have been a case of Ostitis rather than Periostitis, the deposit resembling that found under such circumstances ; and the fact of the deposit taking place beneath the apparently healthy periosteum, would appear to point to the same solution of the question.

*Treatment of Necrosis.*—In the early inflammatory stage of the disease, it is obviously of the first importance to get rid of any local cause which may be exciting or keeping up irritation, and therefore any diseased teeth or stumps should be immediately extracted, and the patient should be removed from the action of any local irritant, such as the fumes of phosphorus. Local abstraction of blood by leeches, both externally and internally, and by scarification of the gums, will relieve the congestion ; and the application of emollient poultices externally, and of poppy fomentations in the mouth, will relieve the pain. The bowels having been cleared, iodide of potassium should be had recourse to in full doses, according to the age of the patient, combined with opium if there is much pain and restlessness.

By these means the disease may be prevented from proceeding beyond the stage of periostitis, but if from the swelling of the parts about the jaw it is to be feared that the destruction of the bone is probable, free incisions should be made within the mouth down to the bone, to give exit to effusion, and thus, if possible, avert the death of the bone, after which the treatment above recommended should be pursued with assiduity. When necrosis has actually taken place, and pus has formed around the jaw, its tendency to the surface is so great that, if free exit for it is not made within the mouth, it will cause sinuses externally, and give rise to great disfigurement. Free incisions should therefore be made through the gums, but without disturbing the efforts at repair if they are already in progress. As all hope of arresting the disease must now be abandoned, it is useless to continue the administration of drugs except as general



tonics, and at the same time every effort must be made to support the patient's strength by suitable diet. Since it is impossible that the patient should masticate solid food, it is important that animal food should be prepared in a suitable manner, and this may be attained by making use of soups or essences of meat, and by reducing well-cooked meat to a mash with pestle and mortar. Milk and eggs form very suitable articles of food, and must be supplemented with wine or, better, stout.

The offensive discharges constantly present in the mouth must be combated with detergent gargles of chlorinated soda or permanganate of potash, and when the patient is unable to cleanse his mouth satisfactorily by his own efforts, it should be mopped out with small sponges affixed to a handle, assisted by the use of a syringe.

Most British surgeons agree in counselling non-interference with the sequestra in cases of necrosis until the shell of new bone around is sufficiently developed to maintain the form of the jaw; they are then to be extracted through the mouth, if possible, and if not, through incisions, placed so as to cause as little subsequent deformity as possible. When the sequestrum, although partially detached, is not ready for removal, and greatly inconveniences the patient, a part may be clipped off with the bone forceps, so as to present a smooth surface, and if the teeth are loose and troublesome they had better be removed at once, but if firm they should be left, since, as has been shown, they occasionally become useful. The caution already given against interfering with the permanent set of teeth in cases of necrosis in children should be borne in mind.

Some continental surgeons, however, interfere at any early date, and among them Professor Billroth, who, according to the report of the meeting of the Medical Congress at Zurich in 1861 (*Medical Times and Gazette*, June 8, 1861), "penetrates immediately, with one incision, which he makes parallel to the necrotic part, through the skin down to the bone; he then scrapes off the periosteum with its bony layers upwards and downwards, by means of a raspatorium,



and saws smaller or larger pieces of bone out of the jaw; or he nips those pieces off by means of bone-pincers. In a few cases it appeared advisable to disarticulate at once one or both coronoid and condyloid processes of the lower jaw, which was very easily done, as the joint had become very loose in consequence of the long suppuration. Of the six cases shown by the Professor, two were healed, and amongst them was one of total resection of the jaw in a woman of thirty-five years. This case was in so far remarkable, as two apparently healthy teeth had remained in the periosteum, which had become partly ossified, and in the gums, which had remained healthy; and these have now been used for seven months. Mastication is not impaired, and the woman has a much healthier appearance. The second case in which the resection of one-half of the jaw was performed, is also well healed; but the mouth is, of course, crooked. Two cases, in which a partial resection has been made, are progressing favourably; in another case the treatment with mercury and iodine has been commenced."

When the whole lower jaw is necrosed it is necessary to divide it before it can be extracted. This may be done, as in Mr. Perry's case, by making a section with the saw near the angle on each side, or, better, by dividing with the saw at the symphysis, either without external incision, as in Mr. T. Smith's case, or after reflecting flaps of skin, as in a case of Sir J. Paget's, which will be found in the *Lancet*, 1862. In a case of necrosis of the entire lower jaw, from phosphorus, which was in the London Hospital under Mr. Adams' care, that gentleman preferred to divide the symphysis with a mallet and chisel, and the case is moreover remarkable from the unusual occurrence of secondary hæmorrhage, for which ligature of the common carotid became necessary—the patient eventually recovering. The case will be found in detail in the *Medical Times and Gazette*, 1863.

Under the name of "Sub-periosteal Resection," operations have been described by foreign surgeons, which in no respect differ from the extraction of sequestra as ordinarily practised, and of which the following case, taken from the



*Lancet*, of 1863, is a good example :—" M. Rizzoli, of Bologna, submitted to the Surgical Society of Paris a case of necrosis of the lower jaw, from the fumes of phosphorus, in a man aged fifty-six years, in which the sequestra were removed through the mouth. M. Rizzoli made incisions on either side of the gums, scraped the thickened periosteum with a spatula from the dead bone, and removed the latter piecemeal. The preserved periosteum generated new bone in the place of the portions taken away, which comprised the body and part of the ramus on each side. It was, however, soon found that the upper part of the ramus and the condyle were also diseased; these portions of bone were also removed through the mouth with the same precautions, and the periosteum again acted in the same way. Eventually the man was able to use his jaw, and masticate, though deprived of teeth. M. Forget, who reported on the case, observed, very justly, that there was nothing new in the action of the periosteum in necrosis of bones, surgeons having long acted upon this periosteal property in such cases. M. Flourens had pointedly said, ' Take away the bone, preserve the periosteum, and the preserved periosteum will restore the bone;' but this applies less to cases of necrosis of bone than to cases of experiments on animals and operations performed on healthy bone and periosteum. And even in these cases it should be remembered that osseous substance is reproduced, but not the actual bone as it existed before the resection." In some cases, however, incisions have been made at a comparatively early stage, before the shell of new bone has been formed, and the sequestrum immediately extracted, with good results. It may be doubted, however, whether there is any real gain in such procedures, either in time or result, since the repair is no more rapid than if the sequestrum were left, and there is the additional risk both of the actual operation, and of the deformity which may result from the premature withdrawal of the sequestrum. A case from the practice of M. Maisonneuve, illustrating the practice in the lower jaw, will be found in the *Comptes Rendus*, April, 1861. In his standard work, "*La Régénération des Os*,"



M. Ollier, of Lyons, gives two cases of subperiosteal resection, one of the upper and one of the lower jaw, for necrosis, in neither of which was there any osseous development; and these cannot, therefore, be regarded as very satisfactory examples of a proceeding whose great aim is the development of new bone.

With regard to the prevention of phosphorus-necrosis, the following extract from Mr. Simon's report to the Privy Council (1863), may be quoted with advantage, as giving the results of Dr. Bristowe's careful investigation of the subject:—"The dangers to which I have adverted, as belonging to the phosphorus industry, belong exclusively to working with common phosphorus. Working with amorphous phosphorus is unattended with danger to health. Since, however, it appears that, with reasonable precautions, the use of common phosphorus for match-making need not be an unwholesome occupation, I cannot say that, in my opinion, the substitution of amorphous for common phosphorus in the manufacture is, for sanitary purposes, an object to be unconditionally insisted on. Yet having regard to the fact that amorphous phosphorus not only is manufactured without danger to the worker, but that its use in lucifer boxes also involves infinitely less danger of fire than belongs to common lucifer matches, I think that the substitution is altogether one to be desired. And, of course, with reference to any restriction which the legislature might think of imposing on the utilization of common phosphorus, it would deserve to be remembered that manufacturers would have at their option the alternative of using, without restriction, the innocuous amorphous material."



## CHAPTER X.

## HYPEROSTOSIS.

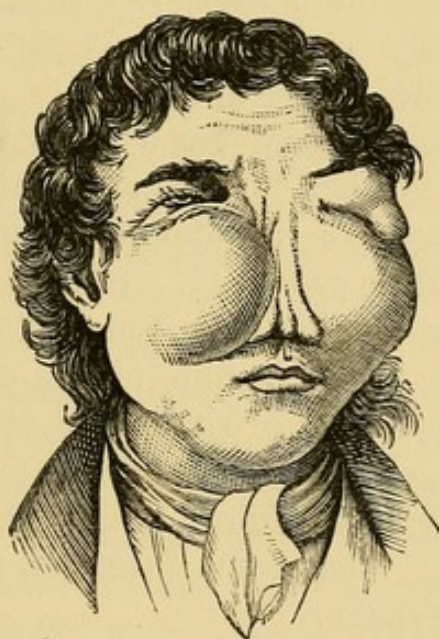UNDER the head of diffused hyperostosis it will be convenient to group together those remarkable examples of hypertrophy of the maxillæ, and more or less of other bones of the face and cranium, which have occurred from time to time, and have been recorded by Howship, Grüber, Astley Cooper, Bickersteth, and others. O. Weber regards the disease as the result of erysipelas, and compares it, in its results, to elephantiasis of the soft structures; while Virchow has given it the name of "leontiasis ossea."

Mr. Howship's case is recorded in that gentleman's "Practical Observations in Surgery" (1816). The patient, when about forty-five years of age, and apparently in perfect health, was exposed to a cold wind, immediately after which he perceived an itching and heat in his eyes, and swelling of the face rapidly supervened. A small tumour formed just below the inner angle of each eye, which burst, and, after twelve weeks, he was able to resume his employment. He suffered from inflammatory attacks in the tumours, with much pain in the head, on more than one occasion, and consulted many medical men, but no treatment relieved the disease or retarded the growth of the tumours, which increased slowly, and were of stony hardness. The eyes were projected from the orbits by the tumours, and the right eye inflamed and burst, while the left was accidentally ruptured by a blow. The patient lived to over sixty years of age, and died of apoplexy, having been occasionally maniacal during the last two years of his life. The accompanying portrait (fig. 54) is taken from



Mr. Howship's work. The skull of this patient is preserved in the College of Surgeons (1606), and shows, as might be anticipated from the portrait, two large masses of almost exactly symmetrical form and arrangement, which have partially coalesced in the median line. The growths are as hard as ivory, and consist of a very close cancellous structure. They project more than three inches in front of the face, and an inch beyond the malar bones on each

FIG. 54.



side ; they completely fill both orbits, the cavities of the nose, and, probably, both antra, and they extend as far backwards as the pterygoid plates of the sphenoid bone. In the Catalogue of the Museum it is stated that the man attributed the growths to repeated blows received on the face in fighting, but Mr. Howship makes no mention of this, and the information was probably derived from Mr. Langstaff, in whose collection the preparation originally was.

A skull of a Peruvian, also in the Museum of the College of Surgeons (1238), exhibits the same form of disease, but of a more diffused character, all the bones of the face, as well as the frontal and the adjacent parts of the sphenoidal and parietal bones, being enlarged and thickened in a re-



markable manner. The nasal fossæ and orbits are nearly closed, the superior maxillary bones, and the orbital portions of the malar and frontal bones, having grown into great knobbed and tubercular masses, in which their original form can be hardly discerned. The hard palate is similarly diseased. The lower jaw is enormously enlarged at its right angle, and in the greater part of its right half it measures upwards of five inches in circumference, and all but three of its alveoli are closed up. A section of the lower jaw shows that its interior is composed of an almost uniformly hard and compact, but finely porous, bone. There is no history attached to the specimen.

Sir Astley Cooper's patient was a Billingsgate fish-woman, long remarkable for her hideous appearance, who died of apoplexy in St. Thomas's Hospital, in the museum of which institution the skull is preserved. (C. 195.) In connexion with each superior maxilla is a rounded bony growth, extending from the lower margin of the orbit to the roots of the alveolar processes. The cavity of each antrum is occupied by the growth, which by its projection has encroached upon the nasal fossæ, and filled the frontal and ethmoidal sinuses. The case, therefore, closely resembles Mr. Howship's specimen.

Mr. Bickersteth's very remarkable specimen was exhibited to the Pathological Society of London in April, 1866, by Dr. Murchison, and its description in the Society's *Transactions* is illustrated with admirable lithographic drawings.

The patient, who died at the age of thirty-four, first noticed an enlargement of the bones of the face when a boy of fourteen. The swelling of the face gradually increased, and thirteen years after its commencement a similar hard swelling appeared along the course of the left fibula. About two years before death he began to suffer severe pain, which continued to his death, this being the result of emaciation, consequent upon the encroachment of the disease upon the mouth. All the bones of the head are more or less involved in the disease, with the remarkable exception of the occipital bone. The malar bones are developed into dense globular



masses, the size of an orange. The palatal processes of the superior maxillæ are also greatly diseased, a rounded mass projecting down on each side so as to fill up the cavity of the hard palate to a level with the alveolar ridge. The lower jaw is enormously thickened in every direction, the right side more so than the left. Little trace can be seen of a condyle, coronoid process, or sigmoid notch, the whole being fused into one uniform globular mass.

A very elaborate account of the specimen, with measurements and microscopical appearances by Mr. De Morgan, will be found in the 17th vol. of the *Pathological Society's Transactions*, from which the above is condensed.

A fourth specimen is preserved in the Musée Dupuytren, in which both upper and lower jaws are extensively affected, and specimens showing the disease in a lesser degree will be found in the museum of the Dental Hospital, Leicester Square, and elsewhere.

In all these specimens the external surface of the bones affected is more or less coarsely tuberculated; the tissue is hard and dense, and minutely perforated for the passage of bloodvessels. In the case of the lower jaw of the Peruvian skull, the interior is composed of an almost uniformly hard and compact, but finely porous bone. Traces of the original walls of the jaw are discernible nearly an inch beneath the surface of the most enlarged part, but its interior is filled up with the same kind of osseous substance as that which is outside the trace of the wall.

A microscopical examination of the St. Thomas's Hospital specimen "shows it to consist of two kinds of bony matter; one firm and compact, while the other is more or less soft and spongy. In the former, Haversian canals occur, having concentric laminae around them, but in the spongy portion cancelli only are present, and the bone exhibits a granular structure, with numerous bony cells arranged in no definite order."

In Mr. Bickersteth's specimen, "The compact structure is traversed in every direction by large branching and communicating vascular canals, forming in some places a close



network. . . . . The spaces between the canals are filled up by bone-tissue of ordinary character. The lacunæ are in general very numerous, but they are small, and for the most part elongated. Very few traces of true Haversian systems are to be seen."

It is stated in the report upon the last specimen, that the microscopical appearances are nearly identical with those of the Peruvian skull in the Hunterian Museum.

The disease appears to consist primarily in some inflammatory affection of the periosteum, which leads to the deposit of new bone, and the expansion and filling up of the original osseous structure. It appears to be entirely unconnected with syphilis or struma, and to be completely beyond the control of remedies, though the continued exhibition of iodine (a drug unknown when these cases were in their early stage) might possibly be of benefit. The resemblance these cases bear to one another is very remarkable, and there was, a few years back, an attendant at Somerset House who might have sat for the portrait of Mr. Howship's patient.

In the Museum of St. Bartholomew's Hospital is a specimen (I. 62), showing obliteration of the antra, due to hypertrophy of the bone, of the same character as in the specimen described above, but in an earlier stage. When the disease affects only one of the maxillæ, which is its favourite seat, operative interference will be advisable. Mr. Stanley ("On Diseases of the Bones," p. 297) gives the case of a girl of fifteen years in whom enlargement of the nasal process of the superior maxillæ had been observed for eight years, and was increasing. There was no external deformity, but it was thought advisable to interfere at an early date, when it was found that obliteration of the antrum had already taken place, as in the preceding case. The entire jaw was removed, but the patient unfortunately died of erysipelas.

In the Museum of King's College is another specimen (1201), which shows well the obliteration of the antrum by hypertrophy of its walls. The tumour was removed in 1842, by Sir William Fergusson, from a girl of twelve, in whom



some enlargement of the face had been noticed from the age of four, and whose portrait is shown in fig. 55, taken, by permission, from that eminent surgeon's "Practical Surgery." The patient made a perfect recovery, and the particulars of the case will be found in *The Lancet* of February and March, 1842. Fig. 56 shows her portrait after recovery from the operation.

FIG. 55.

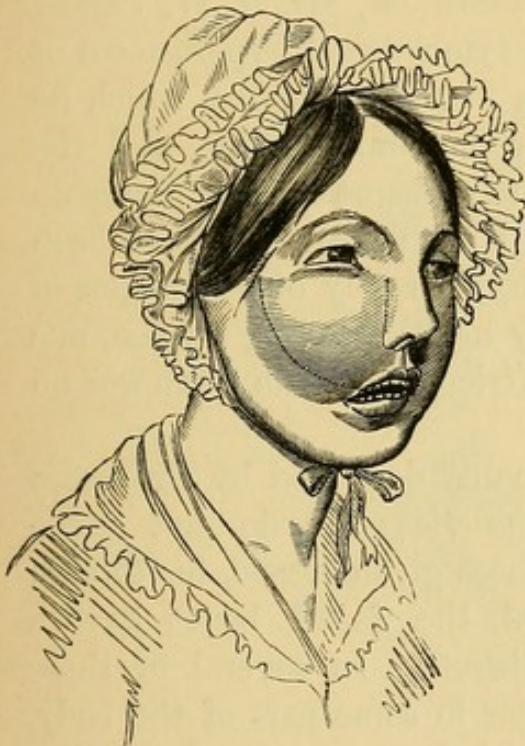
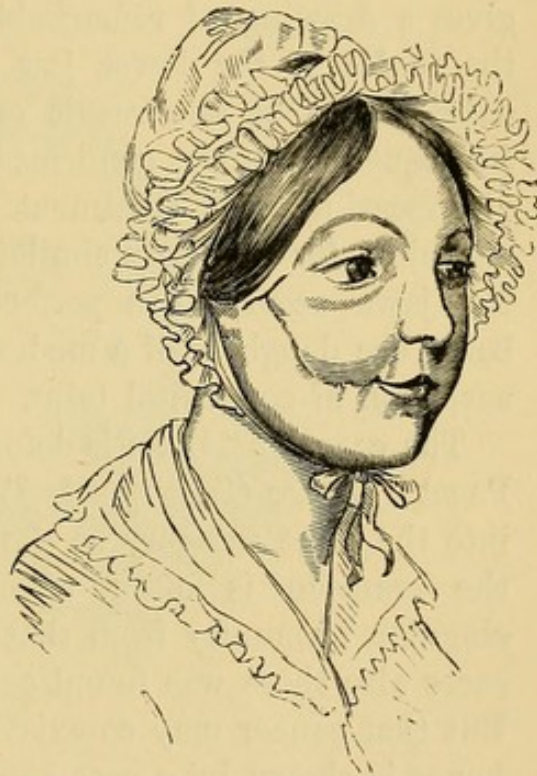
FIG. 56.



In the same museum is a specimen of the disease in the ramus of the lower jaw, removed by the same surgeon from a girl of thirteen, by sawing in front of the molar teeth and disarticulating. The patient made a good recovery.

I have now met with several cases more or less closely resembling those described above. The most marked one was in a lady, aged thirty-nine, who had a blow on the right cheek when fourteen, and noticed an outgrowth when about eighteen. When she was brought to me by Mr. Salzmann, of Brighton, I found a very marked projection of the right cheek, due to an enlargement of the superior maxilla, which was smooth and uniform on its surface. Without any external



incision I succeeded in gouging away a quantity of dense bone without opening any antral cavity, and thus reduced the face to a symmetrical appearance. The cure has, I believe, been permanent.

Lesser degrees of enlargement of both upper and lower jaws of the same kind are not very uncommon, and in one or two patients I have certainly seen good follow the prolonged administration of the syrup of iodide of iron. In the 31st vol. of the *Pathological Society's Transactions*, Mr. R. W. Parker gives a drawing of remarkable symmetrical hyperostoses of the angles of the lower jaw in a girl of twelve, which he considers to be the result of congenital syphilis, and the subsequent history confirmed the diagnosis, the gummata disappearing under treatment. I have, however, twice been consulted for precisely similar hypertrophy of the angles of the jaws occurring in perfectly healthy young women, one being the daughter of a medical friend, in whom there was no suspicion of congenital taint.

The cases of "Osteitis deformans" described by Sir James Paget (*Medico-Chirurgical Transactions*, li.) do not come into the same category as the cases given above, for though the cranium is often affected, the facial bones have a singular immunity from that disease. In several of these cases also there was found cancer in some part of the body. But that cancer may co-exist with hyperostosis of the jaw bones is shown by a case recorded by Dr. Cayley (*Pathological Society's Trans.*, xxix.), where cancer of the lung was found together with hyperostosis of the lower jaw, which presented the following appearances:—"The lower jaw was uniformly enlarged and the alveolar border projected beyond that of the upper one, with which it could not be brought into apposition. All the molar and pre-molar teeth were wanting, and the sockets of the molar teeth, except that for the first right and the last left one, were filled up with bone, the socket of the first right molar was much enlarged and would admit the tip of the little finger; it was continuous with the socket for the adjacent bicuspid, which had itself ulcerated through the anterior surface of the jaw. The



alveolar border of the bone was greatly expanded, especially in the molar regions, where it measured in depth two inches and a half. The rest of the bone was also greatly increased in thickness, the groove and foramen for the inferior dental vessels and nerve were remarkably deep and wide. The condyle on each side had a short thick neck, and the sigmoid notch was wider and less deep than usual. The angle was very obtuse, as in edentulous jaws.

FIG. 57.



A remarkable case of hyperostosis with hypertrophy of the tissues of the corresponding side of the face has been under my notice for fourteen years. The patient, a healthy boy, aged twelve, was sent to me in November, 1869, by Mr. Giles, of Staunton-on-Wye, under whose care he had been from birth. When three months old the patient's face was noticed to be enlarged on the left side, and this enlargement gradually increased until he presented the appearance shown in fig. 57, from a photograph taken in 1869. The left superior maxilla had shared in the hypertrophy, and the condition of the palate and teeth is shown in fig. 58, reduced from a cast, where it will be seen that



the temporary incisors and canine teeth are still *in situ* on the diseased side, though they have been replaced by the permanent teeth on the healthy side. I removed the left superior maxilla on December 1, 1869, in the hope that the removal of the bone and the necessary incisions in the cheek would lead to a permanent relief of the deformity. The patient made a perfectly good recovery, and I subsequently endeavoured to open the eye and to destroy a portion of the tissue of the cheek, but without much permanent success, the patient's condition two years after the operation being as unsightly as before. I have recently (1883) received from Mr. Giles photographs of this patient, which show that the hypertrophy of the soft parts has kept pace with the patient's growth.

FIG. 58.

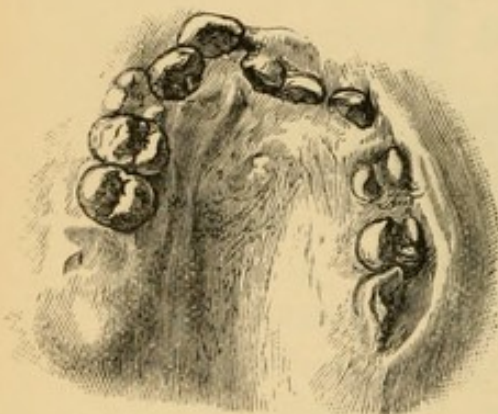
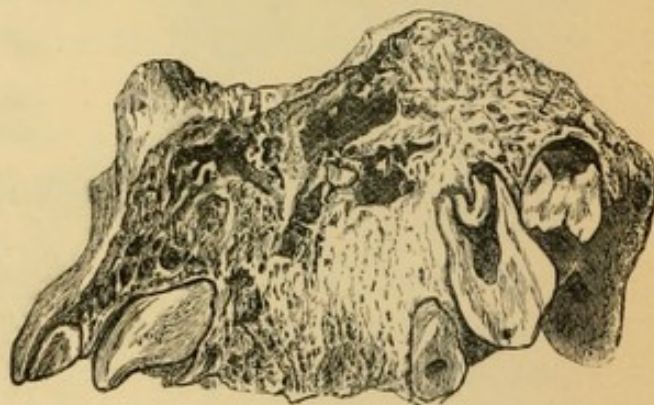

FIG. 59.



A section of the removed upper jaw showed considerable condensation of the bone, and the fact that the permanent incisors and canine teeth, together with the uncut molars, were imbedded in the bone, and holding very much their natural relations to the temporary teeth (fig. 59). Mr. Charles Tomes, who kindly examined the specimen microscopically, reported that "the structure is remarkable on account of the absence of well-developed regular Haversian systems. The bone is everywhere excavated by large irregular spaces, around which there is but little appearance of lamination, so that it presents some little resemblance to so-called 'primary bone'; the lacunæ are arranged somewhat irregularly. None of the peculiar branched vascular



canals, figured by Mr. De Morgan in his account of the microscopic characters of Mr. Bickersteth's case, were observed in their sections. That the whole of the bone has from an early period participated in the morbid action is indicated by the fact that, although the teeth have attained to something like the stage of development appropriate to the patient's age, the alveolar border has not the development of the jaw in the antero-posterior direction, being insufficient to allow of the second permanent molar coming down and ranging with the other teeth. The second molar is a small tooth, and the wisdom tooth is greatly stunted."



## CHAPTER XI.

## DISEASES OF THE ANTRUM.

BEFORE entering upon the consideration of the diseases of the antrum, it will be convenient to say a few words respecting the anatomical relations of that cavity. Known as early as the time of Galen, but connected inseparably with the name of Highmore, who described it as "conical and somewhat oblong," and from whose work figs. 60 and 61 are

FIG. 60.

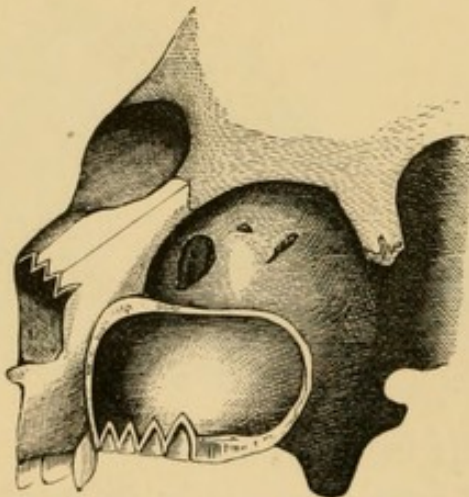
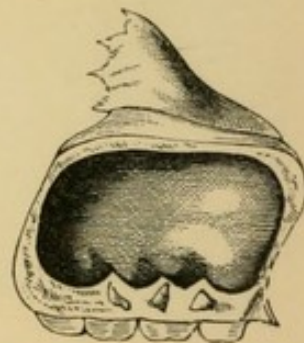


FIG. 61.

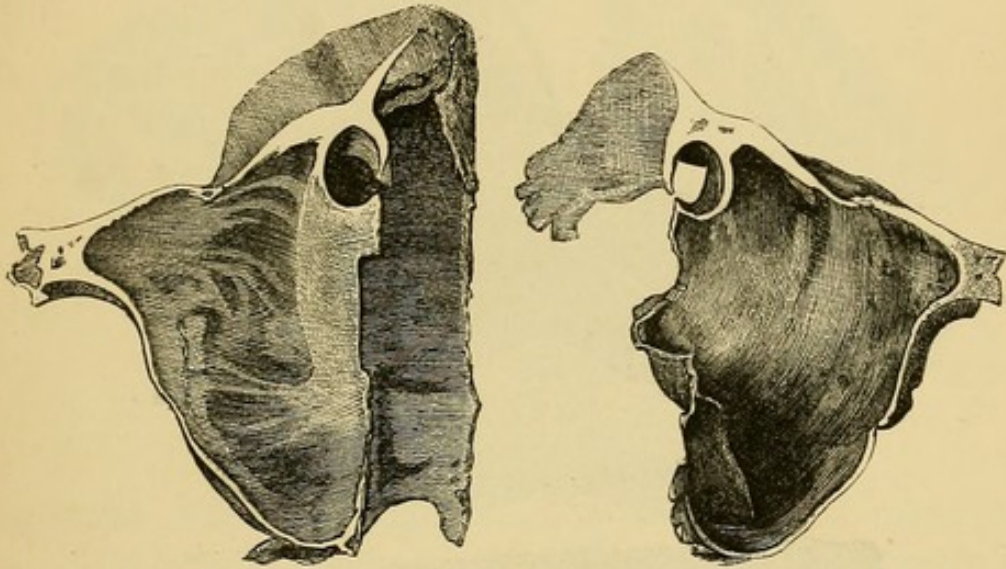


taken, the antrum has been more or less correctly described by all modern anatomists. Holden compares it aptly enough to "a triangular pyramid, with the base towards the nose and the apex towards the malar bone;" and mentions the occurrence of "thin plates of bone which are often found extending across the antrum." The most comprehensive account, however, of the antrum in modern times is to be found in a paper by Mr. W. A. N. Cattlin, F.R.C.S., in vol. ii. of the *Transactions of the Odontological Society of London*, and by the kindness of that gentleman I am enabled to reproduce his valuable illustrations.



As the result of the examination of a hundred specimens, Mr. Cattlin finds that, as a rule, the antrum is larger in the male than in the female, and that it diminishes in size with extreme age. In the young subject, likewise, the cavity is small, and its walls comparatively thick. Fig. 62 shows, in a

FIG. 62.

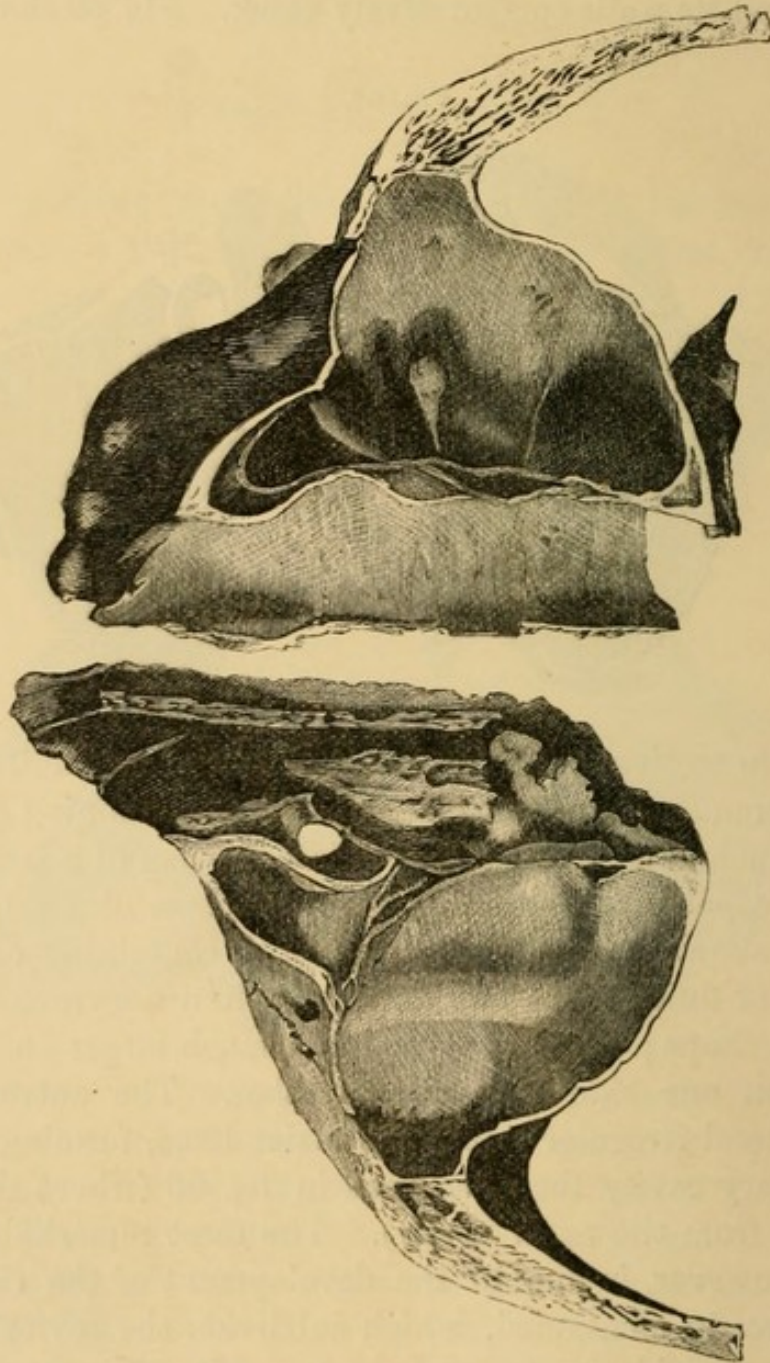


transverse section, both the roof and floor of an adult antrum of the common shape and size, capable of containing two and a half drachms of fluid. Fig. 63 is a drawing of a large adult antrum capable of containing eight drachms of fluid, whilst fig. 64 shows a small adult antrum containing only one drachm of fluid. The two antra are often unsymmetrical in size and shape; thus fig. 65 shows a much larger and deeper cavity on one side than on the other. The antrum may even extend irregularly into the malar bone, forming a supplementary cavity there, as seen in fig. 66 (where the view is taken from the nasal cavity). The most remarkable variation, however, is due to the development of the ridges of bone already mentioned, which subdivide the cavity; these are very variable in size and shape. Fig. 67 is an example of an antrum divided by a thin plate of bone, and fig. 68 of one divided by a thick ridge of bone. Fossæ of considerable depth are often found in the floor of the antrum, particularly at the anterior and posterior extremities, of which



fig. 69 is a good example, showing on one side a perforation by an alveolar abscess. A rare form is when fossæ or cells

FIG. 63.



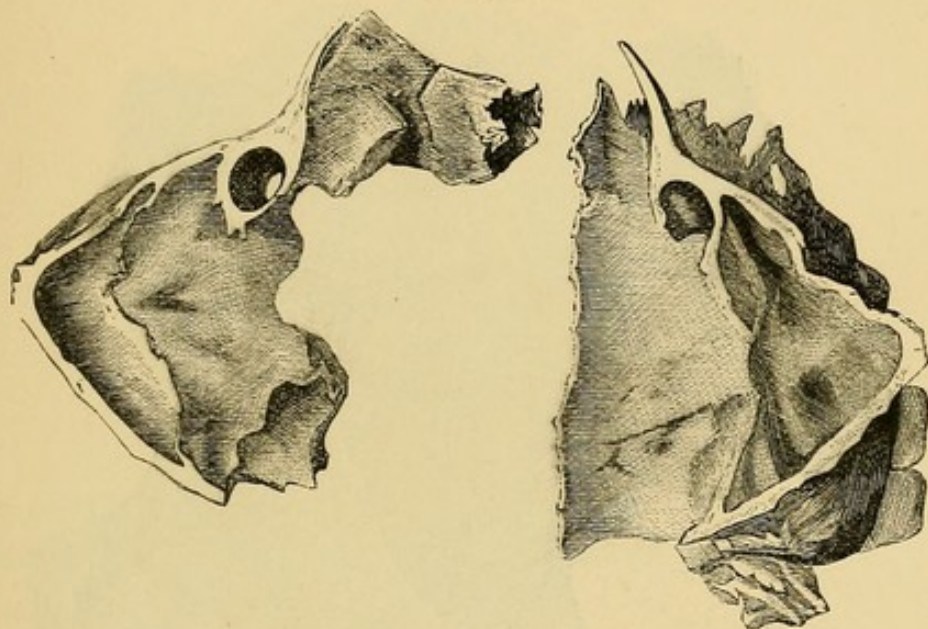
are developed beneath the orbital plate (fig. 70), or a *cul de sac* is formed close to the lachrymal groove (fig. 71).

The position and size of the opening between the antrum and the middle meatus of the nose are points of some im-



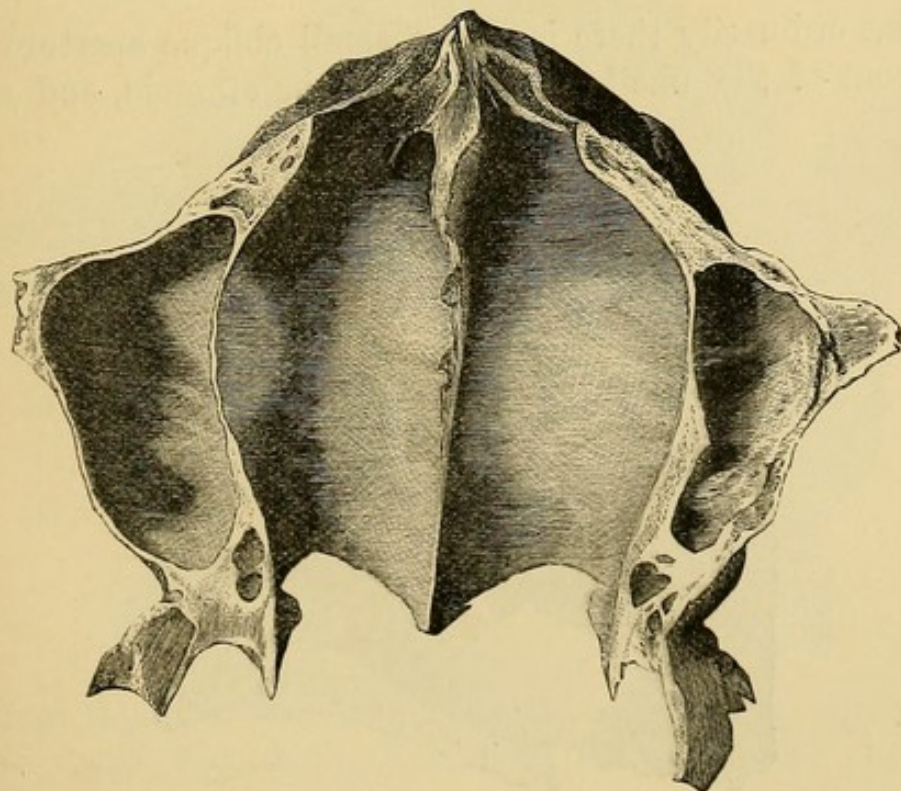
portance. The size of the aperture found in a macerated superior maxilla gives a very exaggerated idea of the open-

FIG. 64.



ing in the articulated skull, when it is encroached upon by the palate, inferior turbinate, and ethmoid bones, which narrow

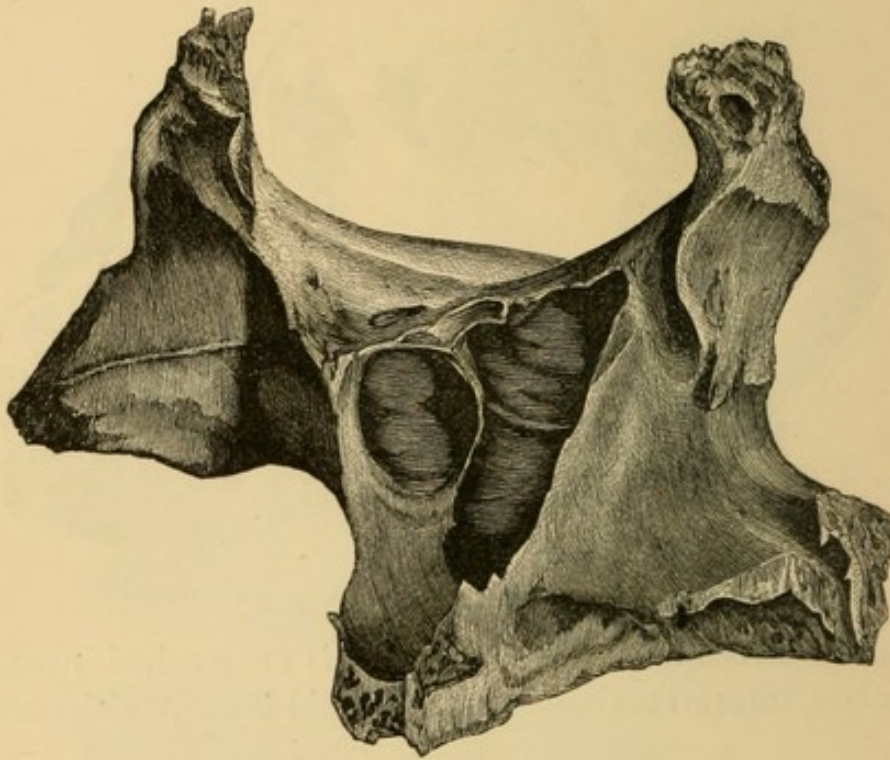
FIG. 65.





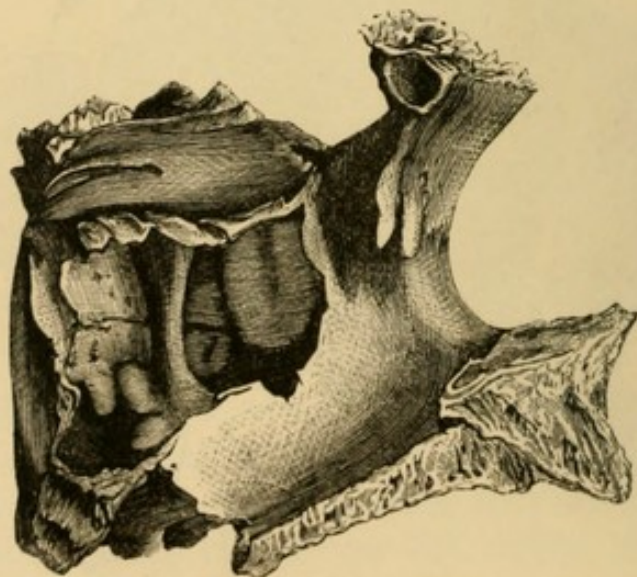
and subdivide the opening into two. In the recent subject these are covered in by the mucous membrane of the nose,

FIG. 66.



so that ordinarily there is only a small oblique aperture left in front of the unciform process of the ethmoid, and close

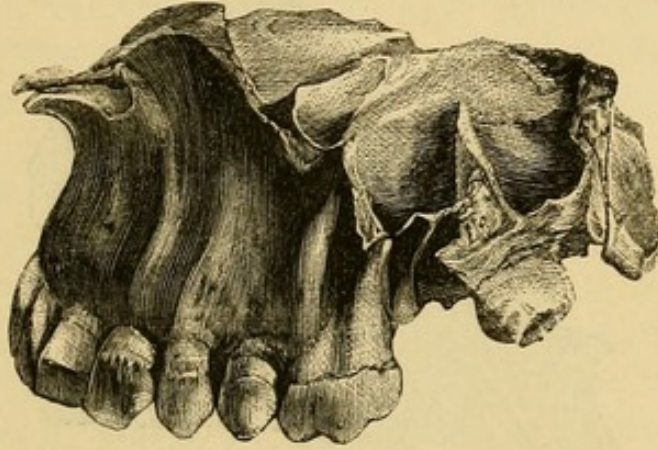
FIG. 67.





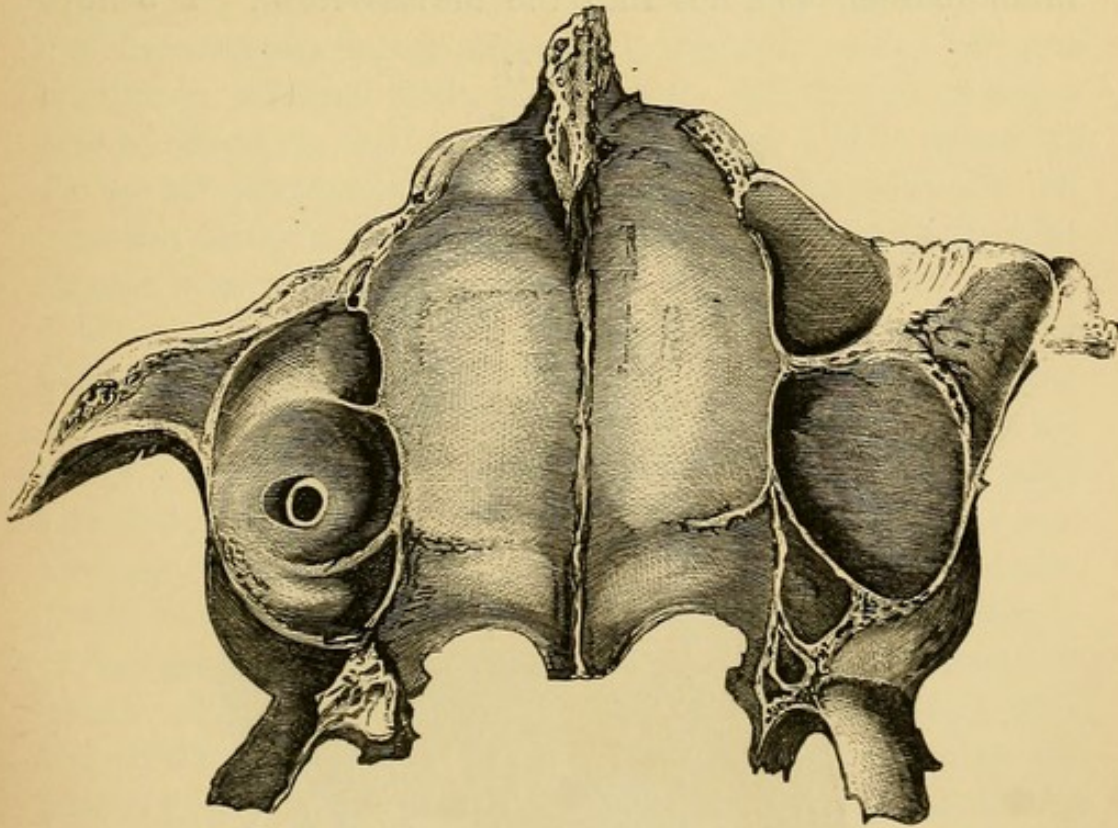
behind the infundibulum. It should be observed, that this opening is at the upper part of and not near the floor of

FIG. 68.



the antrum, and that it opens into the *middle* meatus of the nose. Occasionally a second small aperture is found

FIG. 69.

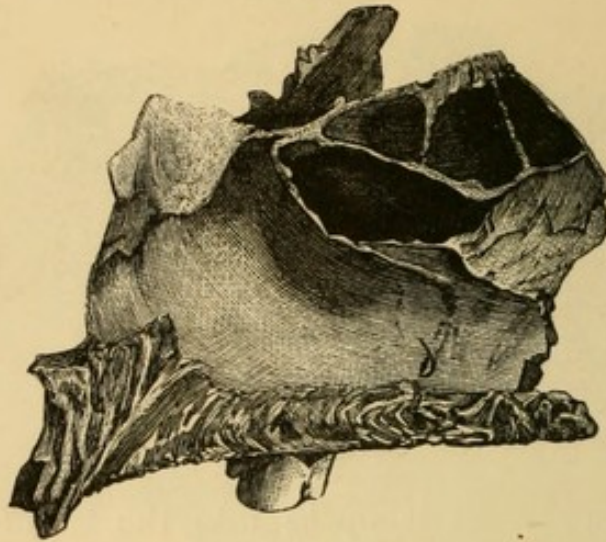


behind this, and nearer to the floor of the sinus, which has been always regarded as a natural formation. M. Giraldès



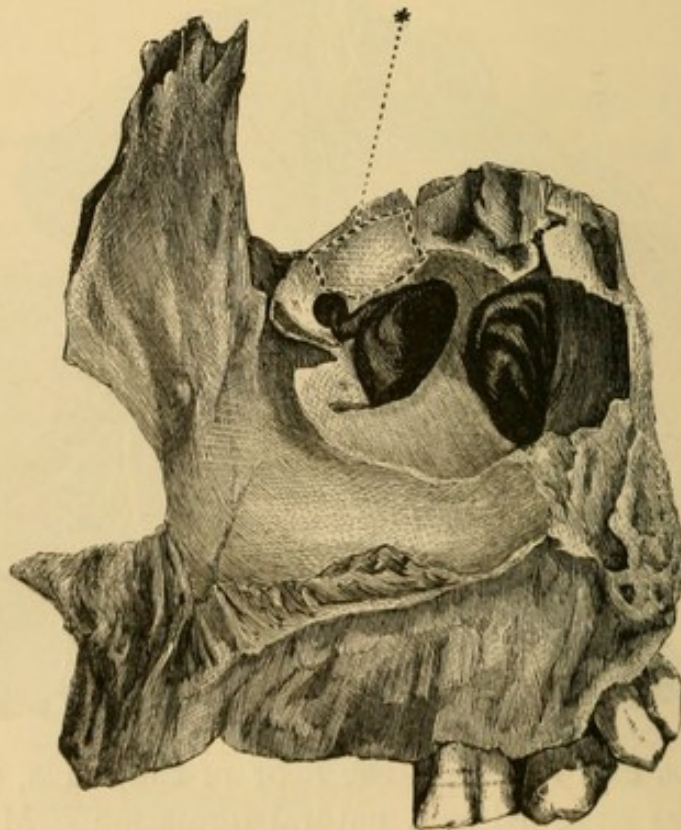
however, in his "*Recherches sur les Kystes Muqueux du Sinus Maxillaire*" (Paris, 1860), maintains that the pos-

FIG. 70.



terior opening, when it exists, is always the result of pathological change, and that the anterior opening is into the infundibulum, and not into the meatus itself. I believe

FIG. 71.





that slight variations in the position of the opening exist ; but it is undoubted that the aperture is very minute, and quite inaccessible from the nose.

*Suppuration in the antrum*, or, as it is sometimes termed, *abscess*, is ordinarily the result of inflammation extending from the teeth to the lining membrane of the cavity ; and the disease might therefore be not incorrectly termed an empyema, as proposed by O. Weber. The roots of the first and second molar teeth often, and the bicuspid and canine occasionally, form prominences in the floor of the antrum ; and when these teeth become carious, the thin plate of bone covering their fangs not unfrequently becomes affected, and disease is set up in the cavity. The fangs of the first molar tooth are occasionally found in health to be uncovered by bone, and to project beneath the lining membrane of the antrum ; and under these circumstances, irritation and inflammation would be still more likely to occur. But an abscess may be formed in the alveolus, and eventually burst into the antrum, though connected originally with teeth not usually in relation with the cavity. Of this an example will be found in the Appendix, in a case (VII.) given to me by Mr. Margetson, of Dewsbury, where the teeth affected were the canine and incisors. This perforation of an alveolar abscess is seen also in fig. 69.

Other causes besides disease of the teeth have been known to induce suppuration in the antrum, such as a violent blow on the face ; and Dr. Rees has recorded an example, in an infant a fortnight old, as the result of pressure during birth (*Medical Gazette*, vol. iv.). It is probable also that the disease may result from catarrhal or other inflammation of the lining membrane ; and it has been excited by the entrance of foreign bodies either from without or from within the mouth, after the extraction of a tooth communicating with the cavity. In the 3rd volume of the *Transactions of the Clinical Society*, Mr. Moore recorded a case of abscess in the superior maxilla, which he believed to be due to the ingress of particles of food by the side of a tooth, though the facts might possibly bear a different interpretation.



The symptoms of suppuration in the antrum are at first simply those of inflammation of the lining membrane—dull, deep-seated pain shooting up the face and to the forehead, tenderness of the cheek, with some fever and constitutional disturbance ; but occasionally the pain is most acute, and of a sharp, stabbing, neuralgic character. A slight rigor may usher in the formation of matter, which will find its way into the nostril when the patient is lying on his sound side, either through the normal aperture or through an opening caused by absorption, as maintained by M. Giralès. An offensive odour is now sometimes perceptible to the patient, though not to those around him—thus differing markedly from what occurs in ozaena—and a sudden discharge of matter from the nostril when blowing the nose may relieve all the symptoms for the moment. The more common course of events is, however, that without any acute pain the patient notices that he has a purulent discharge from the nose when blowing it, and perhaps is aware that, when lying down, the discharge finds its way into the throat. This latter point is often overlooked, however, though there may be a complaint of a very disagreeable taste in the mouth, and a tendency to nausea in the morning, with a hawking up of pellets of inspissated pus.

With all this there is no distension of the antrum, and it is this fact which frequently misleads the practitioner. It is certain, however, that in health there is invariably an opening between the antrum and the nostril, and that, even when this is closed, the wall is very thin and readily absorbed, and it is quite exceptional, therefore, when the antrum is so distended with pus as to give rise to any prominence of the cheek. Undoubtedly cases of this kind have been recorded, but it may be doubted whether some of them were not examples of cyst, the contents of which had become purulent, for we know that cysts in the wall of the antrum readily produce great deformity. The natural opening into the nose is not at the level of the bottom of the cavity of the antrum, and hence there is always a small residuum of discharge, which the patient



can only partially get rid of by holding the head on one side.

Given, a patient who complains of purulent discharge from the nostril, with occasionally a disagreeable smell, and the case is too apt to be put down as one of ozæna, and treated by nasal douches, snuffs, &c. But, as already mentioned, the offensive smell is perceived only by the patient, and not by his friends, the reverse being the case in ozæna; and, again, the discharge is only occasional, is determined by the position of the head, and is simply purulent, whereas in ozæna the discharge is constant, and mixed with offensive crusts from the nasal cavities. Again, the dull ache, varied occasionally by acute pain, is apt to be referred to the teeth alone, and the most careful examination may fail to detect any special tenderness in any one tooth. Hence, after exhausting the usual routine remedies for neuralgia, I have known wholesale extraction of useful teeth undertaken with no benefit, unless it should fortunately happen that the tooth which has perforated the antrum should be extracted early, when the discharge of pus at once clears up the nature of the case.

The more ordinary consequence, however, of an unrecognised empyema of the antrum is the damage done to the digestive organs, by the constant swallowing of purulent fluid during sleep. Under these circumstances, the patient is always ailing, is unable to take food in the morning, and may be reduced to a state of great prostration, even dangerous to life. The usual remedies for indigestion are likely to be of little service so long as the purulent drain continues.

In exceptional cases the pus, not finding an exit, distends the antrum, causing partial absorption of the walls, and thus both bulging out the cheek and thrusting up the floor of the orbit. Fig. 72 shows the prominence of the cheek thus produced in a patient under the care of Sir William Fergusson. Under these circumstances the affection is readily recognised by the peculiar crackling which is perceived when the thinned bone is pressed upon, and the matter, if not evacuated, will shortly find a way out for



itself, either by the side of the teeth, through the front wall of the antrum, or through the floor of the orbit; in either of which cases considerable necrosis and ultimate scar are likely to be the consequences.

The possibility of both antra being affected either simultaneously or consecutively, must not be overlooked. I have a patient now under my care whose right antrum I emptied

FIG. 72.



some years back, and who has now symptoms which point to the presence of matter in the opposite antrum, and Mr. C. Tomes has met with the same occurrence.

The elevation of the floor of the orbit already described may simply displace the eyeball and render it temporarily blind, as in a case recorded by Mr. J. Smith, of Leeds, (*Lancet*, Feb. 14, 1857), or it may lead to permanent amaurosis—a point to which Mr. Salter called especial attention in the *Medico-Chirurgical Transactions* for 1862. Mr. Salter's patient, a young woman, twenty-four years of age, was attacked with violent toothache in the first right upper



molar, which was followed by enormous swelling of the side of the face and intense pain. The eyeball then became protruded, and she soon after perceived that the eye was blind. Shortly after the establishment of these symptoms, "abscess" of the antrum pointed at the inner and then at the outer canthus, and a large discharge of pus at both orifices followed; these orifices soon closed, but the general symptoms of the part continued unchanged—the swelling of the face, protrusion of the globe, and blindness. This state of things lasted for about three weeks, when the patient was sent to Guy's Hospital, and admitted. At this time the patient exhibited hideous disfigurement from swelling of the face, cedema of the lids, and lividity of the surrounding integument. Upon examining the mouth, it was found that the carious remains of the first right upper molar appeared to be associated with, and to have caused the disease. Together with the other contiguous carious teeth, this was removed, and led by an absorbed opening into the floor of the antrum. The hæmorrhage which followed the operation was discharged partly through the nose, and partly through the orifices in the cheek, as well as from the tooth-socket, showing a common association of these openings with the antrum. The condition of the eye constituted the most important symptom, and the most distressing. The sight was utterly gone; the globe prominent and everted. There was general deep-seated inflammation of the fibrous textures of the eye. The pupil was large and rigidly fixed; it did not move co-ordinately with the other under any circumstances. Some abatement of the symptoms followed the extraction of the tooth; but it was soon found that there was a considerable sequestrum of dead bone, which was removed. The necrosis involved the front part of the floor of the orbit, the cheek surface of the superior maxilla, with the infra-orbital foramen, and a large plate of bone from the inner (nasal) wall of the antrum. The removal of the dead bone was followed by the immediate and complete cessation of all inflammatory symptoms; but the eye remained sightless, and the pupil rigidly fixed. About five weeks after the removal



of the dead bone, it was noticed that the pupil of the affected eye moved with that of the other, under the influence of light, though vision in it had not returned. Mr. Charles Gaine, of Bath, has recorded (*British Medical Journal*, Dec. 30, 1865) a very similar instance in a young woman of twenty-two. In Mr. Salter's paper will be found the case of a gentleman, aged thirty-five, under the care of Mr. Pollock, who had amaurosis following inflammation without abscess, and one by Dr. Brück, where amaurosis followed abscess, in the person of a man of forty-five. Sir Thomas Watson, in his "Lectures on Physic," alludes also to two cases of temporary amaurosis, the result of diseased teeth in the upper jaw.

But even more serious results have followed neglected suppuration in the antrum, for Dr. Mair, of Madras, has recorded, in the *Edinburgh Medical Journal* for 1866, the case of a gentleman in whom suppuration in the antrum was followed by death in sixteen days, from suppuration within the cranium accompanied by epileptic convulsions. The full details of the case, with the most interesting post-mortem appearances, will be found in the Appendix (Case VIII.).

The treatment of suppuration of the antrum consists, in the first place, in the extraction of all decayed teeth or stumps in the affected jaw, and with this object in view those teeth which are apparently sound should be tested by a sharp knock with some metal instrument, when, if tender, they should be extracted. If the cause of the mischief is removed in time, the inflammation will subside under fomentation and the application of a leech to the gum; but if matter has formed it must be evacuated without delay. If the extraction of a tooth is followed by the flow of pus, the enlargement of the aperture in the socket by the introduction of a trocar is at once the readiest and simplest mode of evacuating the matter; but if all the teeth are apparently sound, it will be advisable to perforate the alveolus above the gum with a trocar, gimlet, or strong pair of scissors, and similar treatment would be required in the rare case of suppuration occurring after loss of the teeth in old people. If it is



determined to sacrifice a tooth the first molar is to be preferred for extraction, both on account of the depth of its socket and also because, as mentioned by Salter, it is more liable to decay than the other teeth. In puncturing through the socket of a tooth with a trocar it is well to gauge the depth to which the instrument may safely go with the fingers of the hand which grasps it, lest injury should be unwittingly inflicted on the orbital plate by the trocar entering unexpectedly, or a trocar with a stop may be employed if preferred.

After considerable experience of both methods I prefer the puncture above the alveolus, except when a tooth obviously requires extraction, because I find that the aperture is less liable to close up than when made through the alveolus, and because food is less likely to find its way into the antrum. It is necessary, however, not to direct the trocar quite horizontally but a little upwards, lest in a case of highly arched palate the floor of the antrum should be injured, as I have known on one occasion, but then fortunately with no permanent damage, except the exfoliation of a minute portion of the palate.

Whatever method may be adopted for emptying the antrum, it is important that the cavity should be thoroughly cleansed by the forcible injection of warm water until it runs freely from the nostril. For this purpose an ordinary glass syringe is quite insufficient, but I have satisfactorily employed an ordinary Eustachian catheter for the purpose, to which an india-rubber injecting-bottle is adapted. After a time, and with a little instruction, patients can learn to dispense with the syringe by forcing a mouthful of water through the antrum by the action of the buccinator muscles. After thoroughly cleansing, some detergent and slightly astringent lotion should be injected, to restore the healthy condition of the mucous membrane, and for this purpose weak solutions of permanganate of potash or sulphate of zinc answer admirably; but these cases are exceedingly tedious, as a rule, and take many months for their cure. If the perforation has been made through the socket of a tooth,



care must be taken that particles of food do not gain admission to the antrum, and this may be accomplished by plugging the hole with cotton wool, or, as suggested by Salter, by fitting a metal plate to the mouth with a small tube to fill the aperture, which can be corked at pleasure, and will serve as a pipe for injection.

Ordinarily the pus is readily evacuated through the nostril, but I have seen large masses of offensive inspissated pus block up the opening into the nose and require very forcible and repeated syringing for their removal, and the same thing applies to clots of blood, which occasionally give trouble. A still more serious event is when a mass of inspissated pus gives rise to symptoms closely resembling those of a tumour of the upper jaw and without producing that absorption which gives rise to the crackling characteristic of the presence of fluid. The following case of this kind occurred in my own practice, and Mr. Mason published a very similar one. A woman, aged forty-three, was admitted under my care, complaining of pain and swelling of the left side of the face. There was an ill-defined swelling over the region of the left upper jaw, and the angle of the mouth on that side was drawn downwards. The swelling was both hard and tender; the skin over it appeared unaffected. In the mouth there was a tense, elastic, and tender swelling over the left half of the hard palate, displacing the alveolar process downwards. Slight discharge oozed from a small opening in the mucous membrane opposite the last upper molar tooth, the swelling being softer about this spot than elsewhere. The left nostril was blocked, its external wall being pushed inwards, and the patient complained of some discharge from it. The neighbouring lymphatic glands were not enlarged, and with the exception of occasional pain in the tumour the patient suffered no inconvenience, her general health being excellent.

She had noticed the swelling for about two years, and its commencement was attributed to exposure to cold. At times the swelling increased, and became more troublesome, especially after prolonged overwork. No history of syphilis could be obtained, and her family history was good.



Believing that I had to deal with a solid tumour of the jaw, I made an incision through the upper lip in the median line, prolonging it into the nostril of the affected side. The alveolus and hard palate having been divided with saw and bone forceps, a way was made into the latter, and a pul-taceous offensive mass, about the size of a hen's egg, was turned out with the finger. On microscopical examination this was found to consist of fatty débris, granular pus cells, and acicular crystals. As the larger portion of the left half of the hard palate was partially loosened and absorbed it was removed with the forceps. The cavity of the wound was stuffed with a strip of lint, and the patient made an uninterruptedly good recovery.

The possible subdivision of the floor of the antrum by bony septa, already described, must be borne in mind in operating upon this cavity, and especially if there is reason to suspect the presence of any foreign body which may be keeping up irritation. In his paper already referred to, Mr. Cattlin narrates the case of the fang of a tooth lodging in one of these subdivisions, from which it was extracted with difficulty.

Suppuration in the antrum may assume a more chronic form than that above described, and from the slow expansion of the jaw which results may be mistaken for a solid growth. Weber describes a form of chronic subperiosteal abscess proceeding from a tooth, which is surrounded by an osseous plate or shell formed from the periosteum, while it is separated from the antrum by the maxillary wall itself; and believes that the occurrence of suppuration commencing in the bone, either from this cause or from the suppuration of a dentigerous cyst, is much more common than in the antrum itself, but in this I do not agree, though recognizing the occasional occurrence of the form of abscess described. The diagnosis of these several forms of abscess is by no means easy, and errors have been made by excellent surgeons in mistaking them for solid growths: thus, Liston mentions ("Practical Surgery," p. 303) having seen a surgeon have his hands covered with purulent matter in attempting to remove a supposed tumour of the jaw. This is more



especially likely to happen when, as is sometimes the case, considerable hypertrophy of the osseous wall has taken place in consequence of the irritation the bone has been subjected to. Stanley (p. 285) mentions a case of the kind which occurred in the practice of Sir W. Lawrence :—"A woman, aged twenty-four, was admitted with a large, hard, round swelling of the cheek in the situation of the antrum ; it was free from pain, and the soft parts covering it were healthy ; such was the solidity and hardness of the swelling that it was supposed that it might be an osseous growth from the antrum, and the history appeared to confirm this view of its nature, as the woman stated that about five months previously she had received a blow on the cheek, and that soon afterwards the swelling commenced, and had slowly increased to its present magnitude, which was about that of a middle-sized orange. A scalpel was thrust into the tumour immediately above the sockets of the molar teeth, and healthy pus flowed from the opening ; the discharge continued in gradually decreasing quantity, and the swelling subsided as the walls of the antrum receded to their natural limits."

This thickening of the bone may remain permanently, long after the cure of the abscess, and may necessitate operative interference : thus, in 1850, Sir William Fergusson met with a case of osseous tumour of the size of a pigeon's egg, projecting from the superior maxilla of a man aged fifty, who had been the subject of abscess, and whose antrum was still distended, though containing no fluid. Here it became necessary to remove the tumour with the anterior wall of the antrum, by which the deformity was quite got rid of. The case will be found in the *Lancet*, June 29, 1850. A case, under the care of Mr. Henry Smith, in which an abscess consequent on necrosis of a portion of the jaw closely simulated a tumour of the antrum, will also be found in the *British Medical Journal*, March 2, 1867.

*Hydrops Antri*, or "dropsy of the antrum," is an old name (which should, I think, be abandoned) for a disease which has long been recognised, though, within the last few years, opinions have changed as to the exact pathology of



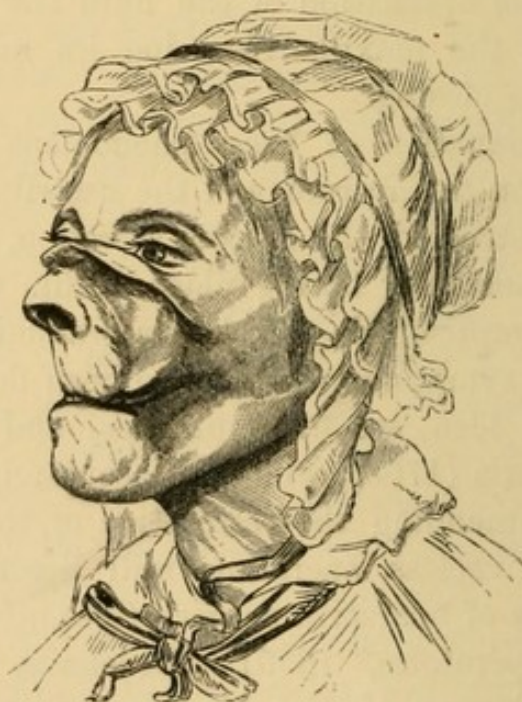the affection. The history of these cases is one of gradual, painless dilation of the upper jaw, until its outer wall becomes so thin as to crackle like parchment upon pressure being made, or at certain points being so absorbed that fluctuation is readily perceptible. Occasionally the other walls of the jaw yield, though more slowly, to the persistent pressure, the palate becoming flattened, and the nostril blocked by the bulging of the internal wall. On the extraction of a molar tooth and perforation through its socket, as described under the previous section, or more frequently by an incision through the osteo-membranous wall of the cyst, a quantity of clear, or yellowish serous fluid is evacuated, which frequently contains flakes of cholesterine floating in it. After the evacuation of the fluid the swelling ordinarily subsides, the maxilla resuming its normal relations, and the opening closing.

The old explanation of these phenomena was, that the aperture between the antrum and the nostril having become accidentally obstructed, the mucous secretion, which was presumed to be constantly taking place within the cavity, was thought to be imprisoned, and, by its gradual accumulation, to produce the symptoms which have been described. Following up this idea, we find surgeons, and among others Jourdain, of Paris (1765), who very accurately described the affection, recommending the restoration of the nasal orifice by probing—a useless operation, still described in many foreign manuals of operative surgery (see Guérin's "*Elémens de Chirurgie Opératoire*," 1855). Bordenave, in his "*Observations on Diseases of the Maxillary Sinus*" (Sydenham Society's translation, 1848), gives full details of this method of probing and injecting, but, after showing that there is great difficulty and uncertainty in finding the natural orifice, remarks that "there are very few cases in which the employment of injections through the natural openings, in the manner above described, would effect a complete cure." It is certain, however, that some of these cases, and very probably all of them, originate in the growth of a cyst, or cysts, within the antrum, or more commonly in the wall of



the antrum, which either grow to such a size as to be mistaken for the cavity of the antrum when opened, or break into the antrum by absorption of the cyst-wall, so that on subsequent examination no evidence of cyst formation can be discovered. This explanation is, as pointed out by Coleman, supported by the fact that in these cases of so-called *hydrops antri*, the contained fluid in no respect resembles ordinary mucus, but is invariably a clear, more or less yellow fluid, frequently containing cholesterine in considerable quantity. In these respects it closely resembles that found in well-marked cases of cystic growth, which have been examined in various stages of development.

FIG. 73.



A remarkable case of distension of the antrum is narrated by Sir William Fergusson, and the preparation is preserved in the King's College Museum. It was taken many years ago from a subject in the dissecting room, and from the person of an old woman. The tumour, which was of very large size, had burst shortly before death, leaving the remarkable deformity shown in fig. 73 (taken by permission from Sir W. Fergusson's work on Surgery), which is due to the complete absorption of the front wall of the antrum



and its collapse, by which a prominent horizontal ridge of bone, formed by the upper wall of the antrum, has been left immediately below the orbit. The preparation shows great distension of the antrum, the diameter of which varies in different parts from two to two and a half inches, and the bony wall is so thinned out as to resemble parchment. The gums are edentulous. There is no communication between the nose or mouth and the cavity, which is lined with a membrane covered with laminated deposit. (For these particulars I am indebted to Dr. Trimen, the late Curator.) Whether this was originally a case of cystic growth, or a chronic abscess, it is impossible now to decide, but it is, so far as I am aware, a unique post-mortem specimen of this distension.

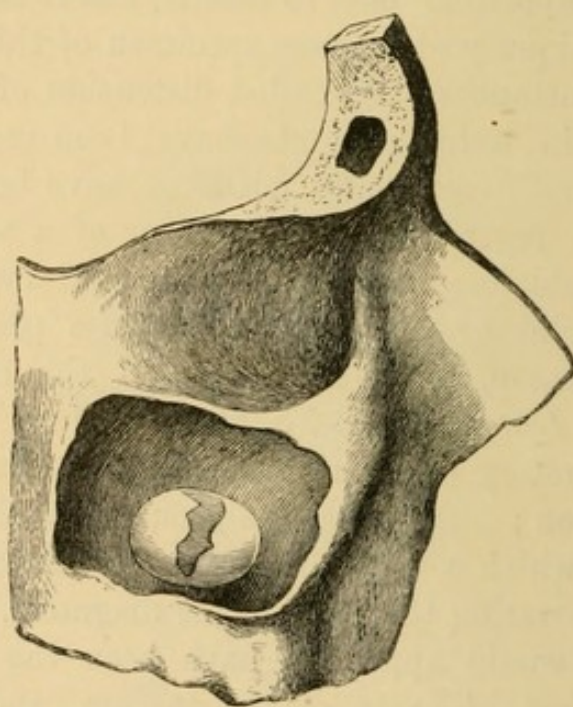
Numerous instances of so-called distension of the antrum by clear fluid in living patients, have been recorded from time to time, and occasionally mistakes have been made by the surgeon in regarding the tumour as of a solid nature. A very remarkable case, in which a distended antrum closely simulated a solid growth, occurred in the practice of Sir William Fergusson, and the details of the case will be found in the *Lancet*, June 29, 1850. Here the surgeon made an exploratory puncture before commencing the more serious operation; but a case has occurred within my own knowledge, in which a very able surgeon removed the upper jaw before discovering the error of his diagnosis.

M. Giraldès would appear to have been the first author upon the subject of cysts of the antrum, and his thesis gained the Montyon prize in 1853: but Mr. W. Adams may fairly claim priority of investigation, as shown by specimens preserved in St. Thomas's Museum—as indeed is acknowledged by M. Giraldès. Luschka subsequently investigated the subject, and in sixty post-mortem examinations found cystic growths in the antrum five times, some of them being two centimetres in length. A careful examination of the antra of thirty subjects, made for me by Mr. Marcus Beck, then Demonstrator of Anatomy of University College, during the winter of 1867-68, failed to discover an instance of the kind.



Mr. Adams' specimens, from one of which the drawing (fig. 74) was made, show each a cyst of oval outline, attached to the inner wall of the antrum, and measuring rather more than an inch, and three-quarters of an inch respectively, in their long diameters. These, of course, are too small to have produced any symptoms during life. The specimens given by M. Giraldès in his "*Recherches sur les Kystes Muqueux du Sinus Maxillaire*," from one of which the illustration (fig. 75) is taken, show very varying degrees of cystic growth in the mucous membrane of the antrum. In

FIG. 74.



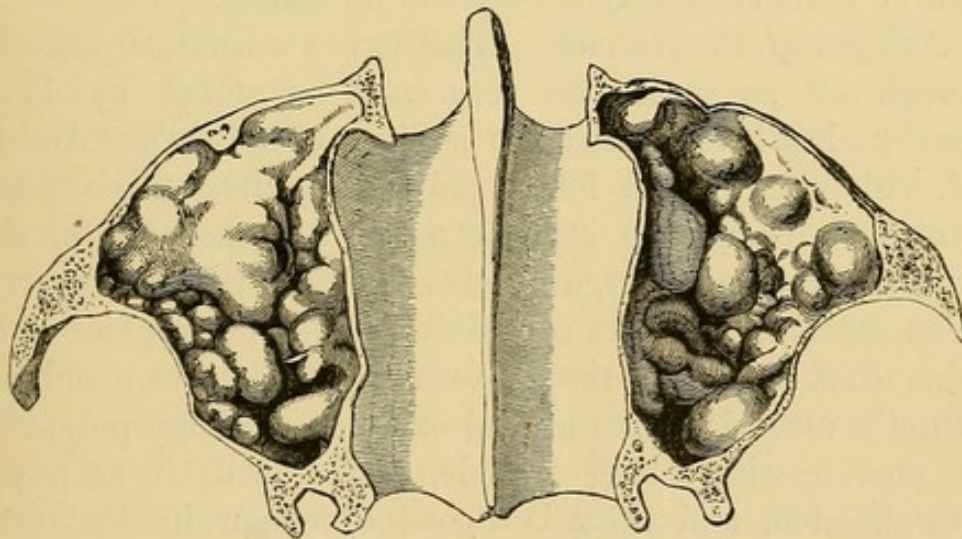
one instance there is a single cyst at the floor of the antrum, into which an opening has been made, whilst in the others the cysts are very numerous and of very variable sizes, depending, apparently, upon a cystic degeneration of the entire mucous membrane. M. Giraldès explains the formation of these cysts as being due to the dilatation of the glandular follicles of the mucous membrane, and urges that the ordinary operation of tapping the antrum would be useless in such cases, but that it would be necessary to open up the antrum, so as to get at the seat of the disease. Fortunately these numerous cysts appear to be of slower



growth than the single cysts, for it would be impossible to extirpate such numbers as are here seen (fig. 75), without removing the entire jaw.

The contents of these cysts appear to be at first clear fluid, but of a viscid nature; when more fully developed, the fluid becomes flaky, from the presence of cholesterine, and occasionally assumes a greenish tint; it may also become purulent, and Maisonneuve has recorded (*Gazette des Hôpitaux*, Jan. 6, 1855) a case where pressure on the cheek produced a flow of butter-like fluid from the nose in a young woman who, for a year, had suffered from a tumour of the right upper jaw, which had been pronounced malignant, the

FIG. 75.



face being enlarged and the nostril obstructed. Here puncture from the nostril, combined with pressure and injections, effected a cure, and the case must be considered as one of cyst of the antrum, but whether a mucous cyst, the contents of which had undergone solidification, or a separate formation, must remain doubtful.

*Treatment.*—The treatment of cystic disease of the jaw is generally sufficiently simple. The bony wall being most commonly, to some extent, absorbed, it is only necessary to incise the distended membrane and evacuate the fluid. The finger then passes readily into the cyst and can examine its interior, searching for any growth or tooth which may be



lodged within. With curved scissors the opening can then be enlarged by cutting away the membranous wall, sufficiently to allow a free passage for any discharge. The use of a simple stimulating lotion with a syringe is then all that is required to effect a cure, which, though slow, is permanent. I have treated a considerable number of cases of cyst of the jaw in this manner, and with uniformly good results.

Broca ("Tumeurs," vol. ii. p. 37) recommends to remove the membrane covering the inner wall of the cyst, and gives a case in which Nélaton discovered a plate of bony tissue derived from a malformed tooth on the inner aspect of a cyst, but this is in most cases a quite unnecessary complication of what is usually a very simple matter.

*Polypus of the Antrum.*—This is not a common affection, though by no means so very rare as stated by Paget. Luschka has investigated the subject (Virchow's "Archiv," Bd. viii. p. 419), and found polypi five times in sixty subjects, some being two centimetres in length. He gives a drawing, showing a large number of these polypoid growths in an antrum, which he considers to be hypertrophies of the submucous connective tissue, covered with mucous membrane. Billroth also describes a good example of large polypus of the antrum with a long pedicle, and regards it as a very rare affection, and there is a good specimen in University College Museum.

These polypi are closely allied apparently to the small cystic growths in the mucous membrane of the antrum, described by Giraldès. Both affections consist essentially in hypertrophy of some elements of the mucous and submucous tissues. When the connective or areolar tissue predominates, the fleshy polypus is produced; when the glandular element is especially affected we have the cystic form produced. Intermediately, when the fibrous element is very loose and we have some glandular hypertrophy, the semi-gelatinous polypus is produced, which closely resembles the nasal polypus.

Polypi of the antrum are well supplied with blood-vessels,



and bleed freely when interfered with. In some instances they appear to have a malignant character, or at least are the forerunners of malignant disease occurring in the antrum and jaw. Vidal de Cassis, who (*Traité de Pathologie Externe*, tom. iii. p. 492) totally denies the existence of any true polypoid growths in the antrum, says that what have been mistaken for them most frequently are colloid tumours of the periosteum, but believes that many of the examples are cases of cystic growth. Syme also, following the example of John Bell, maintains that polypi in the antrum always intrude from the nose, and are never developed in the antrum itself. (*Lancet*, May 10, 1855.)

Sir James Paget has put on record (*Clinical Soc. Trans.* xii.) a case of polypus of the antrum in which a constant flow of clear watery fluid from the nose was the only symptom. At the post-mortem examination "the floor of the antrum was covered with two broad-based convex polypoid growths, deep clear yellow with the fluid infiltrated in their tender tissue, and covered with exceedingly thin smooth membrane traversed by branching blood-vessels. They were of rounded shape, about two-thirds of an inch in diameter and half an inch in depth; they looked like very thin-walled cysts, but were formed of very fine membranous or filamentous tissue, infiltrated with serum."

Ordinarily the symptoms of polypi, no less than of cysts of the antrum, only become developed when the growth is of sufficient size to encroach upon the neighbouring cavities, or produce distension and absorption of the front of the antrum. The most common situation for the polypus to show itself is, as might be expected, the nose, since the tumour readily induces absorption of the thin nasal wall of the antrum. Here it closely resembles the ordinary nasal polypus, and Sir William Fergusson mentions (*Practical Surgery*, p. 561) two cases of the kind in which this had occurred, one being in his own practice. In that instance he soon found that he had attacked a tumour of the antrum, which, in consequence of its deep and firm attachment, and the great hæmorrhage attending it, he did not entirely



remove. The disease returned, and he again operated, on this occasion using great force, and wrenched out the whole mass, not without some fear of the consequences. The case, however, did well, and after ten years the disease had not returned.

In the *Medical Times and Gazette*, March 18, 1860, is a report of another case in which the same surgeon removed a vascular fibrous polypus of the antrum which had projected into the nostril, by laying open the front wall of the cavity, and with strong forceps tearing out the tumour bit by bit.

I had, during 1866, the opportunity of watching the case of a patient who had had a polypus partially removed by the nose on several occasions, and from whom Mr. Holthouse removed an entire growth a year and a half before that date. He re-appeared with a swelling of the jaw, evidently due to distension of the antrum by some soft growth, and he had also a soft tumour on the forehead. These were doubtless cancerous, for his strength failed, and he sank after some months, but unfortunately his relations would not permit a post-mortem examination to be made.

Hypertrophy of the glandular tissue of the mucous membrane appears capable of producing tumours of a friable description, which may fill up the antra on both sides, as in a case recorded by M. Demarquay (*Gazette Médicale de Paris*, November 4, 1857). Here the patient had a large tumour on each side of the nose, the passages of which were completely obstructed, and his right eye was protruded from the orbit. M. Demarquay removed the front walls of the antra, and extirpated two masses of very friable tissue of a greyish-white colour, in which the vascular tissue was not abundant. M. Robin, who examined the growths, pronounced them to be the result of an hypertrophy of the glandular element of the mucous membrane of the antrum.

A curious, and I believe, unique case of falling in of the antrum, recorded by Mr. White Cooper, may be conveniently mentioned here, since the depression of the wall of the cavity depended, no doubt, upon some alteration going on



in its interior—possibly the absorption of some fluid which had previously induced thinning of the bones. The patient was brought before the Medical Society of London in 1851, and Mr. Cooper has kindly given me the following details of her case :—

“I first saw Margaret Ryan (aged twenty-seven) May 22, 1849.

“Complained of the tears running over the left cheek, first perceived about a week previously.

“Seven years ago first observed a black mark round the lower part of the left eyelid; without pain, weakness of eye, or toothache. Gradually and almost imperceptibly flattening of the cheek came on.

“The appearance presented was that of a deep depression between the malar bone and nose, precisely as if a portion of the superior maxillary bone had been cut away.

“It was bounded superiorly by the inferior margin of the orbit, which partook of the depression; inferiorly by the base of the alveolar process; and externally by the malar bone. As compared with the other cheek, the dimensions were as follows :—From bridge of nose over deepest point of depression, one inch four-tenths, or nearly an inch and a half; right side to corresponding point just one inch.

“There was a peculiar dusky hue about the depression, especially towards the upper part. The cuspid and bicuspid teeth were removed with considerable difficulty, the roots showing thickening of periosteum.

“No change was visible at the expiration of twelve months.”



## CHAPTER XII.

## CYSTS OF TEETH—DENTIGEROUS CYSTS.

CYSTS in connection with the teeth may be classed under two heads :—1st, cysts connected with the roots of fully developed teeth, and 2ndly, cysts connected with imperfectly developed teeth—to which the term “Dentigerous cysts” has been applied in modern times. Both kinds may occur in either jaw, and, in the case of the upper jaw, may be confounded with collections of fluid in the antrum, or may secondarily involve that cavity.

Cysts, of small size, in connection with the fangs of permanent teeth, are frequently found on their extraction, but give rise to no symptoms demanding surgical interference, though sometimes they cause pain from pressure on the dental nerves. Occasionally, however, they grow to a large

FIG. 76.

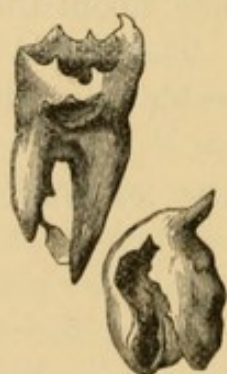

FIG. 77.

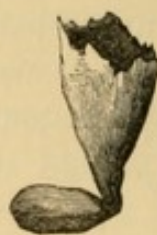
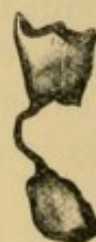
FIG. 78.



size, in which case they produce absorption of the containing alveolus, and give rise to a prominent swelling. They lie beneath the periosteum of the fang, and hence have been named by Magitôt (*Arch. Gen. de Médecine*, 1872–73) periosteal cysts. The contained fluid is rich in cholesterine.

Three specimens of cyst connected with the fangs of teeth,



for which I was indebted to Mr. Holborow King, accompanied this essay, and are now in the Museum of the College of Surgeons (2161). Two of them (figs. 77, 78) are quite small (one being remarkable for the length of its pedicle), the third (fig. 76) is of the size of a hazel-nut, and was torn in extraction. The contents of the cyst were found on microscopic examination to consist of degenerating pus; their walls were formed of fibrous and granulation tissues, and they had no epithelial lining. This would confirm the view of Mr. Tomes, that the morbid process is probably identical with that resulting in the formation of alveolar abscess, but being less acute, a serous cyst is formed instead of a suppurating sac. In the Museum of the College of Surgeons is another specimen of a vascular thick-walled cyst, attached to one side of the fang of an incisor tooth (2161A).

Large cysts, which produce more or less absorption of the outer wall of the maxilla, are, in my experience, very common consequences of the retention of diseased teeth, but seem to give surprisingly little inconvenience to the patients, even when of large size and producing considerable deformity of the face. They are commonly confounded with cystic distension of the antrum.

Dupuytren remarks that "morbid changes in the roots of the teeth give rise to the formation of serous cysts, which are most frequently met with in the alveoli of the upper canines, and in some instances acquire a very large size, even equal to that of the antrum. In such cases the root of the tooth is found diseased and inclosed within the cyst, which adheres to the alveolar cavity, and (when small enough) usually accompanies the tooth in its extraction; but if left behind, a suppurative process is established, which continues for a long time. The fluid yielded by these cysts is sometimes very thick, and in other instances of a serous character, and their inner surface is as smooth as that of the serous membranes" ("On Diseases of Bone," Sydenham Society's Translation, p. 440).

Of this kind probably also was the case mentioned by



Sir J. Paget ("Surgical Pathology," p. 402), of a woman, aged thirty-eight, who had a tumour simulating a collection of fluid in the antrum, but which projected beneath the mucous membrane of the upper jaw above the teeth, and had existed six years. An incision evacuated an ounce of turbid brownish fluid, sparkling with crystals of cholesterine, and it then appeared that there was no connection with the antrum, but that it rested in a deep excavation in the alveolar border of the jaw. So also the case mentioned by the same author in connection with the incisor teeth.

Delpech relates a case in which a membranous cyst contained three ounces of fluid, but its interior bore no resemblance to the interior of the antrum; and Stanley (p. 300) narrates a case of Sir W. Lawrence's of large cyst projecting in the situation of the antrum, and containing a glairy fluid with shining particles in it, and regards both cases as instances of cysts connected with the teeth, although it appears more probable that they were examples of cyst in the antrum, such as have been already described.

A case, which I have little doubt originated in a cyst in connection with the incisor teeth, but in which the antrum had become secondarily involved, has lately been under my own care. The patient, a woman aged forty, had a fluctuating swelling, noticed for two years, immediately above the incisor teeth, which were decayed even with the gum. On incising it, a quantity of yellowish glairy fluid exuded, and a probe, when introduced, evidently passed into the antrum. From the position of the cyst, and its close proximity to the incisor teeth, I have no doubt it originated from them, and found its way into the antrum by absorption of the bony wall. The patient would not consent to any operation for the cure of the disease, which gave her little inconvenience.

Fischer, of Ulm (Gurlt's "Jahresbericht," 1859, p. 154), has narrated three cases of cyst connected with the fangs of teeth, in one of which he had the opportunity of making a post-mortem examination. After the removal of the facial wall of the antrum, there appeared a cyst connected with



the apex of the posterior molar tooth, which filled the whole antrum without, however, adhering to the mucous membrane. This consisted of a perfectly closed serous bag of  $\frac{1}{8}$ " thickness, with a smooth inner surface, and containing a yellowish serous fluid, which grew from the periosteum of the apex of the root of the tooth.

The clinical history of cysts connected with the teeth is that of painless expansion of the alveolus of either jaw, but more frequently of the upper, with crackling of the bone on pressure and ultimate absorption of the bony wall. The cyst then presents a bluish appearance through the distended mucous membrane, and if large, gives distinct evidence of fluctuation.

*Treatment.*—An incision into the cyst evacuates a dark-coloured clear fluid, unless inflammation should have been excited, when the contents become purulent. It is advisable to cut away the thin outer wall of the cyst freely with scissors, or, if necessary, with bone-forceps, so that the cavity may granulate up. If an incision only is made, the edges are apt to fall together and re-unite with a reproduction of the fluid, unless an india-rubber drainage-tube is inserted, which can be attached by a thread to a neighbouring tooth.

*Single Cysts* in the lower jaw as in the upper, may originate in connection with the fully-developed teeth, and as in the case of dentigerous cysts, may give rise to the suspicion of a more severe affection. In April, 1867, a case of the kind occurred in King's College Hospital in the person of a boy aged ten, who appeared to have a solid tumour of the body of the lower jaw on the right side, rather larger than a pigeon's egg. Sir William Fergusson discovered a slight yielding of the osseous wall, which crackled upon being pressed, and upon extracting a neighbouring tooth a quantity of glairy fluid escaped. The treatment was completed by cutting away a part of the expanded outer plate of the bone, and making the wound heal from the bottom.

According to Broca ("Traité des Tumeurs," vol. ii. p. 35) the great majority of cysts of the jaws have their origin in tooth follicles. These are shut sacs, but they do not enclose a true



cavity, for the space between the wall and the outer surface of the dental papilla is occupied by the enamel-organ, an organized body, but very soft and gelatinous, apt to disappear under morbid influences, and thus leaving in the follicle a cavity ready to be transformed into a cyst. Dental cysts may originate in the follicles of the first or second dentition, or in the follicles of supernumerary teeth. Their contents are ordinarily clear fluid, sometimes bloody, occasionally filamentous or gelatinous, and still more rarely they contain a sebaceous matter like mastic, composed almost entirely of epithelium.

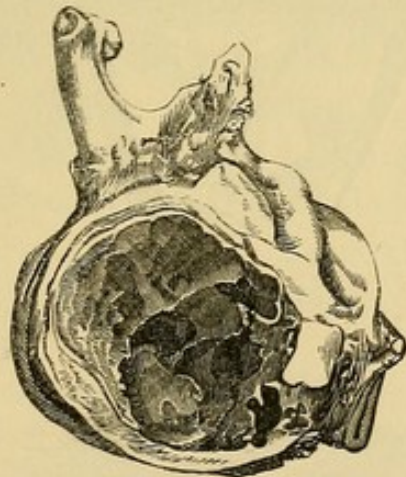
But periosteal cysts occur in the lower jaw without any apparent immediate connection with the teeth, though very possibly some irritation connected with these organs may have been the original cause of the mischief. The patient finds that he has a slowly-growing tumour of the jaw, which is painless, and gives him no trouble except from the deformity. The outer plate yields ordinarily to the pressure of the growing cyst, and thus a prominent smooth tumour is formed, over which the skin is freely movable. When the bony wall is sufficiently attenuated, the peculiar crackling already described may be produced on pressure, and if the disease is still unchecked the bone becomes entirely absorbed, and nothing but a membranous cyst, with particles of osseous matter imbedded in it, remains. Of this a most remarkable specimen from a woman, æt. forty-five, is to be seen in St. George's Hospital Museum (II. 150). The cyst is for the most part single, and contains merely fluid, which may be clear or more or less coloured. Dupuytren narrates several cases of the kind ("Diseases of Bone," Sydenham Society, p. 437), from some of which only reddish-coloured serum escaped on their being opened, whilst in others a fibroid growth, and in one osseous nodules, were found within them. There is a good example of a single cyst for which a piece of the entire thickness of the lower jaw was excised in St. George's Museum, of which the following are the particulars:—The patient had had a tumour, supposed to be an epulis, removed from the same spot



two years before, and the disease had been growing since that time. When admitted the tumour was found to be a firm oval growth, about the size of an orange, connected with the outer surface of the right inferior maxilla. It was evidently cystic, and there was an indistinct sensation of fluctuation. The tumour, as well as the portion of bone from which it grew, was removed by an incision in the median line. The extent of lower jaw removed was from the lateral incisor tooth on the left side to the angle of the jaw on the right.

The accompanying drawings show a case of unilocular cyst of the lower jaw, for which Sir William Fergusson re-

FIG. 79.



moved a large portion of the bone. Fig. 79 shows the growth, and figs. 80 and 81 the patient before and after the operation. (See "Practical Surgery," p. 666.)

*Cysts in connection with undeveloped teeth, or Dentigerous Cysts* (coronary cysts of Magitôt) may occur in either jaw. These, as already mentioned, may suppurate and give rise to abscess, which may be confounded with suppuration within the antrum, or may project into the antrum, filling the cavity or communicating with it.

Dentigerous cysts arise in connection with teeth which from some cause have remained within the jaw, and have undergone a certain amount of irritation. They are almost invariably connected with permanent teeth, though Mr. Salter mentions a case in connection with a temporary molar



FIG. 80.




FIG. 81.





occurring in the practice of Mr. Alexander Edwards, late of Edinburgh; and in a remarkable specimen belonging to Mr. Cartwright, which will be afterwards referred to, the tooth is a supernumerary one. I have also myself met with an example of cyst connected with a temporary tooth in a boy of four years, brought to me by Mr. C. J. Fox. In this case the temporary right canine tooth was wanting, and there was a cyst developed in its situation, on cutting into which I extracted seven small irregular nodules of dentine and enamel, but no complete tooth, this being therefore an example of the odonto-plastic cyst of Magitôt.

Mr. Tomes explains the formation of cysts in connection with retained teeth by referring to the fact that when the development of the enamel of a tooth is completed, its outer surface becomes perfectly detached from the investing soft tissue, and a small quantity of transparent fluid not uncommonly collects in the interval so formed. This fluid ordinarily is discharged when the tooth is cut, but when from some cause the eruption of the tooth is prevented, it increases in quantity, gradually distending the surrounding tissues in the form of a cyst.

For further microscopic details and for a full discussion of Magitôt's views, I may refer to Mr. F. Eve's very able lecture on "Cystic Tumours of the Jaws," delivered at the Royal College of Surgeons, and published in the *British Medical Journal*, January 6, 1883.

Mr. Salter, in his work on "Dental Pathology and Surgery," has collected several cases of dentigerous cyst, which were recognized and treated during life. Thus Jourdain records three cases, one in a girl of seventeen, in whom the first and second right upper permanent molars were inverted and the surrounding cyst had involved the antrum; a second in a man of sixty, connected with a bicuspid tooth of the upper jaw; and the third in a girl of thirteen, connected with an upper lateral incisor. Dupuytren and Bransby Cooper each met with a case in the upper jaw. Dupuytren's case, which was shown to him by M. Loir, being a remarkable instance of a cyst developed between the plates of the

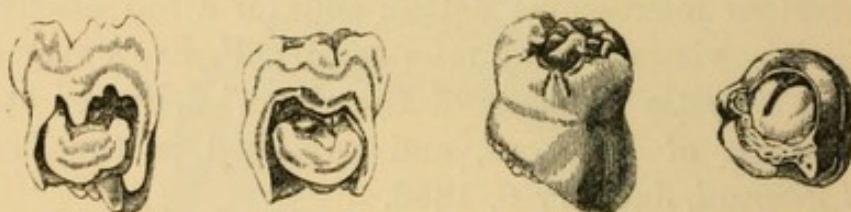


palatine process of the upper jaw (*see* Dupuytren "On Diseases of Bone," Sydenham Society's translation, p. 438.)

Professor Baum also met with an extraordinary case in a woman aged thirty-eight, both of whose antra were enormously dilated by cysts, from one of which a canine tooth, and from the other a molar tooth, was removed. Mr. Salter gives two cases of his own, which will be found at length in the "Guy's Hospital Reports, 1859," one depending upon the impaction of a wisdom tooth in the lower jaw of a man aged twenty-two, and the other in a girl of eighteen, who had an elastic fluid-containing tumour in the incisive region of the upper jaw connected with a permanent incisor tooth, the fang of which was not developed, and whose place was occupied by a temporary tooth.

Inversion of the tooth appears to be a frequent accompaniment, or rather the cause of these cysts, and occurred in one of the cases narrated by Jourdain, and in those of Dupuytren and Bransby Cooper. Mr. Tomes ("Dental Surgery") has recorded a similar case in a girl of sixteen,

FIG. 82.



who had a swelling around the second molar tooth of the lower jaw, which proved to be a cyst. After being tapped, the cyst suppurated, and the extraction of the tooth became necessary, when the inverted crown of the third molar was found lodged between the expanded fangs of the second molar tooth, the two being united by dentine, and having one common pulp-cavity, as seen in the accompanying drawing, fig. 82, from Mr. Tomes' work.

Cases of dentigerous cysts may be mistaken for solid tumours. Thus Gensoul, of Lyons, has recorded the case of a girl of thirteen, whose antrum was distended with a



large collection of yellow fluid and contained a canine tooth attached to its wall, in whom he had made the incisions necessary for the removal of the tumour before he discovered its nature. Mr. Syme also has related (*Edinburgh Medical and Surgical Journal*, 1838) the case of a woman æt. thirty-one, on whom he operated for a tumour of the upper jaw of four months' standing, by laying open the cheek and removing the tumour with the bone-forceps. "The tumour was found to consist of a dense cyst lined throughout with earthy matter in a crystalline form, and containing a clear glairy fluid, together with the crown of a tooth, apparently the lateral incisor." In a cavity beyond the tumour was found a fully formed canine tooth, encrusted with a thin plate of bone. The teeth are said to have belonged to the temporary set.

When dentigerous cysts occur in the lower jaw they form more isolated and prominent tumours than in the case of the upper jaw, and in some cases the projecting bony wall has been removed. In St. Bartholomew's Museum is a specimen of the kind (I. 119), consisting of a portion of a bony cyst, which was removed by Mr. Earle from the external and lateral part of a lower jaw. The cyst is lined with a thick and soft membrane, which has been in part separated from it. The cavity of the cyst was filled with a glairy fluid, and at the bottom of it a canine tooth of the second set was adherent to the lining membrane. The case is referred to by Stanley, who gives an accurate drawing of the preparation. In the Museum of the College of Surgeons there is a very similar preparation (2196) showing a bony cyst of oval shape, one inch in its long diameter, lined with a thick well-formed membrane, containing an imperfectly formed bicuspid tooth, which was removed by Mr. Wormald from the lower jaw of a female aged seventeen, whose case will be found in the *Lancet*, June 22, 1850.

When the cyst occurs in the lower jaw, and is less prominent than in the two cases already mentioned, giving rise rather to a general expansion of the bone than a distinct

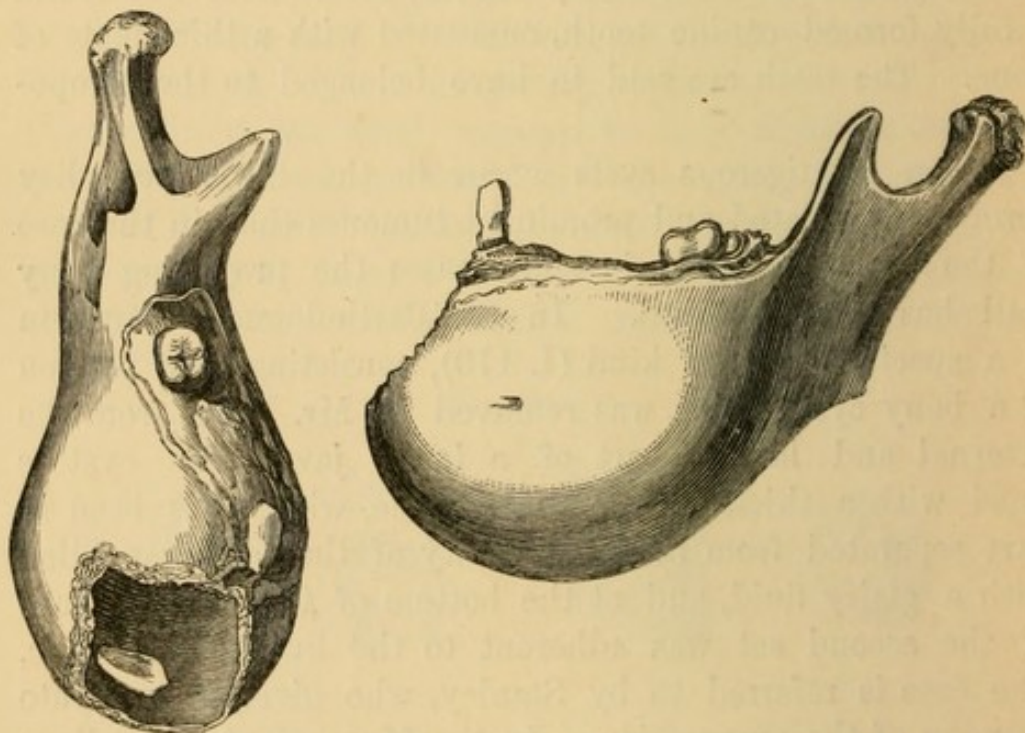


tumour, the disease may be mistaken for a solid tumour of the lower jaw. A case of this kind occurred to that excellent surgeon, the late Mr. S. W. Fearn, of Derby, who had the courage and honesty to publish the case (*British Medical Journal*, Aug. 27, 1864), and to whom I was indebted for the very valuable preparation (College of Surgeons Museum, 2195), from which the drawings, figs. 83 and 84, were made.

Mr. Fearn's patient was a girl of thirteen, who had a large resistant tumour of the left side of the lower jaw,

FIG. 83.

FIG. 84.



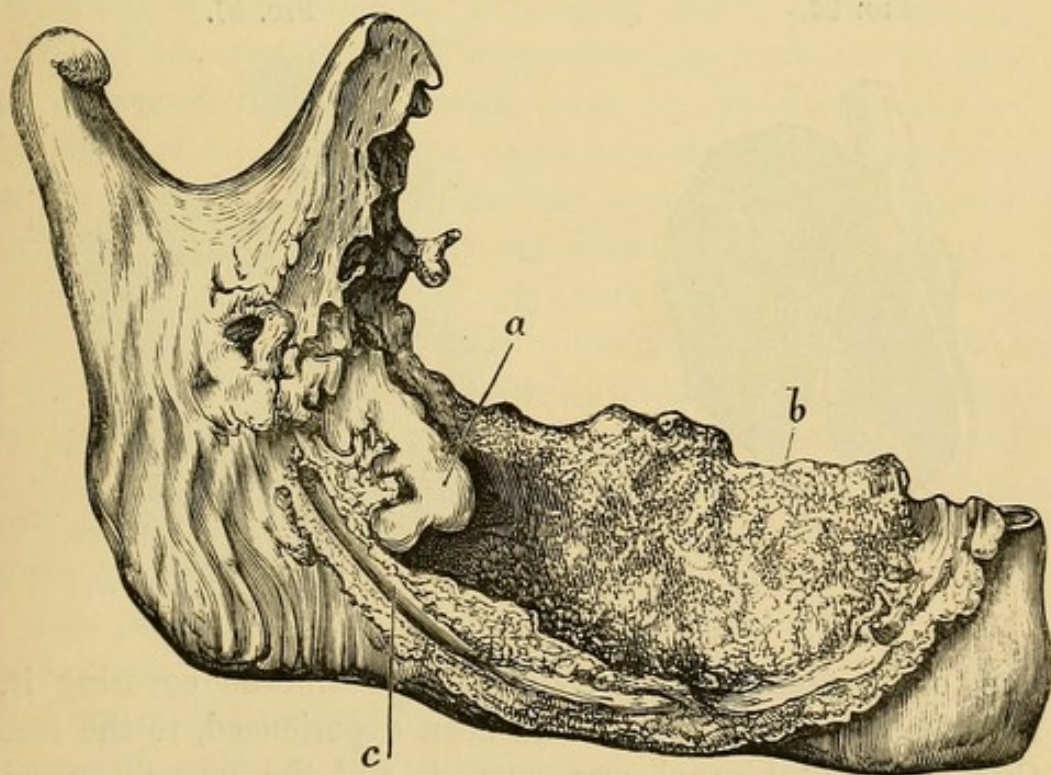
which had been growing six months. There was some enlargement also of the right side, and the teeth there were very irregular. The teeth on the left side had been extracted, with the exception of the second molar and a temporary molar. No opening could be detected in the tumour, though there was a constant offensive discharge from its surface. Mr. Fearn removed the left half of the jaw from the symphysis to the articulation, and on division of the bone with the saw, a quantity of foetid pus escaped. The tumour (fig. 83) proved to be a bony cyst formed by the



expansion of the two plates of the jaw, which extended for some distance to the right of the symphysis (a very unusual occurrence). The cavity is lined with a thick vascular membrane, and at the bottom the canine tooth will be seen projecting from the wall. The case was evidently therefore one of dentigerous cyst, due to the non-development of the canine tooth, the contents of which had, from some cause, become purulent. The mental foramen, with the nerve emerging, is still visible in the preparation and drawing (fig. 84). The patient made a good recovery.

A very similar case is recorded by Dr. Forget, in his essay on "*Les Anomalies Dentaires et leur influence sur la production des Maladies des Os Maxillaires*," 1859, which

FIG. 85.



is translated by Mr. R. T. Hulme, in the *Dental Review*, 1860. The patient was a woman aged thirty, who had a tumour on the right side of the lower jaw, of the size of a hen's egg, extending from the lateral incisor to the base of the coronoid process, which had been growing ten years. M. Lisfranc removed half the jaw, and the patient made a good recovery. An examination of the tumour showed it



to be a cyst, at the bottom of which lay the wisdom tooth, the crown projecting downwards into it, the fang being inverted and fixed in the base of the coronoid process. In the illustration (fig. 85), (for which I am indebted to Mr. Hulme), the cyst has been opened, the internal wall, *b*, being left; *a* marks the position of the tooth, and *c* the inferior dental canal, which has been opened to show its non-communication with the cyst.

M. Legouest brought under the notice of the Société de Chirurgie de Paris, in 1862, a very similar case, which had the peculiarity of pulsating at one point synchronously with the radial pulse. The supposed tumour proved to be a dentigerous cyst containing two teeth, the pulsation having been

FIG. 86.

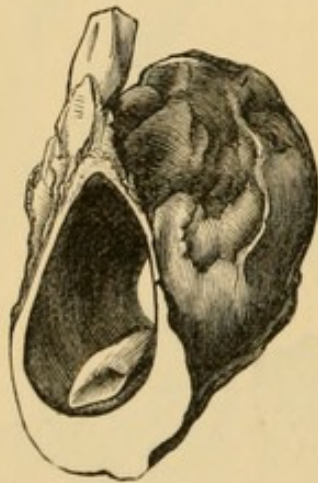
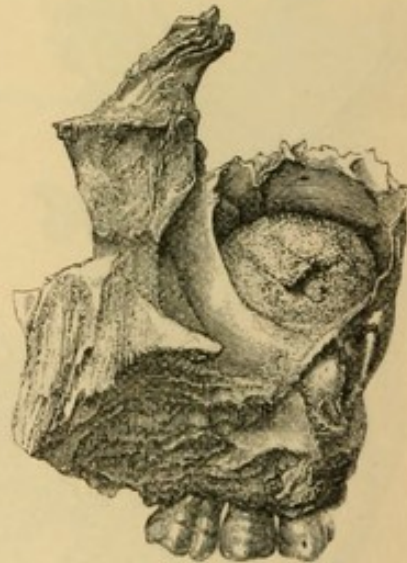


FIG. 87.



due to the great vascularity of the membrane covering it, and the great pain which had been experienced, to the fact that the dental canal was opened, and the nerve pressed upon by the cyst. (*Gazette des Hôpitaux*, Aug. 7, 1862.)

In the *Annali Universali di Medicina* for May, 1867, Sig. Bottini, of Novara, has recorded a case of "subperiosteal and subcapsular disarticulation" of the left half of the lower jaw of a woman æt. twenty-three, for what proved a dentigerous cyst in connection with the wisdom tooth.

Mr. Underwood has allowed me to have the accompany-



ing drawing (fig. 86), taken from the model of a preparation which he possesses, showing very beautifully a cyst of the lower jaw, which was removed by M. Maisonneuve by sawing through the bone at two points. The canine tooth is seen lying horizontally at the bottom of the cyst. The patient, aged fifty-six, had a swelling in the lower jaw near the chin, and an opening formed behind one of his front teeth, from which a saline fluid escaped. The man made a good recovery from the operation. (Vide *British Journal of Dental Science*, 1862, p. 562).

Dentigerous cysts, like other cysts, may undergo alteration, not only of the contents, but of the cyst-wall. The opportunities for recognizing such changes are exceedingly rare, and the only known specimen of the kind is one in the possession of Mr. Samuel Cartwright, which shows calcification of the cyst-wall. The preparation (a reduced drawing of which (fig. 87) is taken from Mr. Catlin's paper on the Antrum) is one of the right superior maxilla, which, having been opened, shows a bony cyst within the antrum and attached to its floor, but unconnected with it elsewhere. The cyst has been opened, and contains a *supernumerary* tooth loose in its cavity, though no doubt originally attached to its base. This is clearly a case of dentigerous cyst which has undergone calcification, and which, had it been expanded to a greater degree before this change took place, would in all probability have been inseparably united with the walls of the antrum.

The diagnosis of dentigerous cysts from other cysts is exceedingly difficult until they are opened, as indeed is the recognition of any form of cyst. A careful examination of the mouth may reveal the absence of a permanent tooth, or, as in one of Mr. Salter's cases, may show a temporary tooth occupying a permanent position, and this would direct the mind of the surgeon to the possible existence of a dentigerous cyst. On the other hand, however, it must be remembered that teeth may be wanting without being connected with any disease; thus I am acquainted with a family who have the hereditary peculiarity of a single bicuspid



tooth on each side. When a cyst is sufficiently expanded for the wall to yield under the finger with the characteristic parchment-like crackle, there can be no difficulty in its recognition, but without this it is impossible in all cases to distinguish between a cyst and a slow-growing solid tumour. Under these circumstances, it is well to insist upon the propriety of making an exploratory puncture in all cases which are not obviously solid growths, and have sprouted so that their nature can be certainly recognized. The puncture being made within the mouth will be of no moment should a more severe operation subsequently be necessary.

The accompanying engraving (fig. 88) shows a cyst of the lower jaw occurring in a man aged thirty-four, who was under

FIG. 88.



my care in 1878. The swelling began nine years before, and was of the size of an ordinary orange, round, very hard, and fixed to the angle of the lower jaw on the right side. Its edges were well defined, there was no fluctuation nor pulsation, except that of the facial artery, which was stretched



over the tumour. Externally the tumour appeared to be solid, but examined from the mouth, the anterior part of the wall yielded slightly to firm pressure. On puncturing from the mouth through the bony wall I entered a large *empty* cavity lined with soft tissue, which on microscopical examination showed portions of hyaline cartilage and cartilage with a faintly fibrous matrix, surrounded by and gradually passing into oval and spindle cells. The bony walls of the cyst were broken down and partially cut away, and this proceeding was repeated a fortnight later. The tumour gradually diminished as suppuration went on, several pieces of bone being removed, and, six weeks after the cyst had been opened, a tooth was felt fixed at the bottom of the cavity, and on being extracted proved to be a bicuspid with a perfect crown and two small fangs. After this the cavity closed and the swelling entirely disappeared. The case is remarkable, both for the age of the patient and also for the fact that the cyst was empty, the fluid which must have been present at one time having become absorbed. A careful search for a tooth was made at the time of the operation, but one could not be found, and its discovery at a later date was probably due to the destruction by suppuration of the lining membrane of the cyst, which had completely enveloped it.

In the Museum of the Royal College of Surgeons is a preparation (2194) of the right side of the body of the lower jaw, completely and uniformly dilated into a large spherical cyst. No tooth or rudiment of a tooth can be discovered in the cyst, but its inner surface is lined by a layer of small epithelial cells and is thrown, in places, into thick projecting folds. Mr. Eve considers it probable that the cyst originated in the enamel-organ of an abortive wisdom or supernumerary tooth, and hence would consider it an example of the follicular cyst developed in the embryonic period (Magitôt).

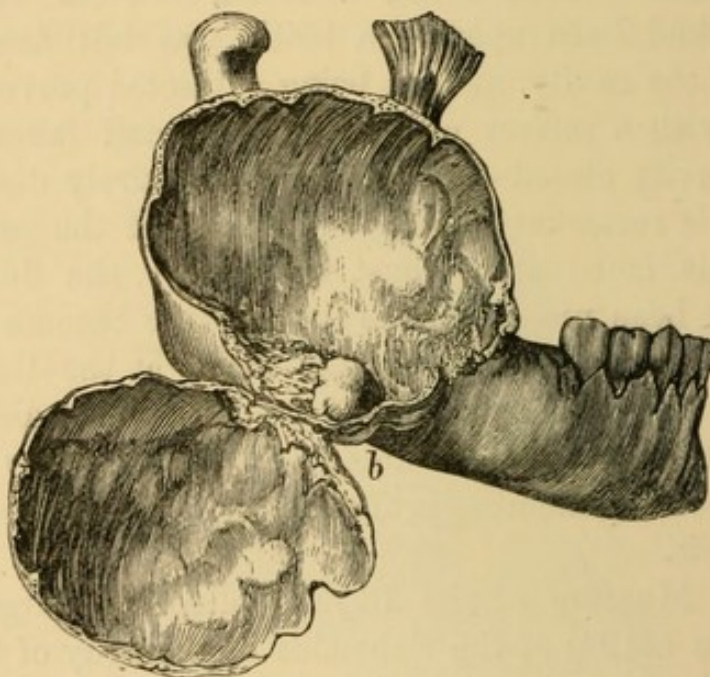
*Treatment.*—The treatment of dentigerous cysts is the same as for ordinary cysts—viz., a free incision; and the subsequent extraction of the contained tooth. For the cure



of many of these cases simple puncture will not suffice, and it will be necessary to remove a portion of the front wall of the cyst, and to fill the cavity with lint so as to induce granulation and gradual obliteration. This may be accomplished in most instances without any incision of the integuments, and in a few more extensive cases by simply dividing the lip, and carrying the incision into the nostril.

In cases where a permanent opening into the antrum is not required, it will be sufficient to turn up a sort of trap-door, as suggested by O. Weber, the periosteum serving as

FIG. 89.



the hinge, so that it may be replaced after the removal of the contained cysts. It can but rarely happen that such an extensive mutilation can be requisite as is shown in a preparation in Guy's Hospital Museum (1087), consisting of the outer wall of the antrum and the palatine plate, containing all the teeth of the left side except the central incisor, which was removed by Mr. Key from a case of very greatly distended antrum.

In the case of dentigerous cysts of the lower jaw it will, after removal of a portion of the wall, be advisable to squeeze the plates together as far as possible, and in the



case of the upper jaw pressure by pads and bandages, as recommended by Liston, will do much to restore the parts to their usual form. Dr. Forget relates the case of a woman, of about thirty, with a hemispherical tumour of the right side of the lower jaw, which was produced by the bulging of the external plate of the ramus of the jaw, the internal having preserved its usual position. M. Nélaton exposed the tumour, and making a hole in the outer wall found a tooth projecting into the cyst. The tooth was extracted with some difficulty, and the patient perfectly recovered, and was well ten years after. The accompanying illustration, (fig. 89), represents the relation of the parts, *b* pointing out the position of the tooth. (*Dental Review*, 1860.)

The cyst should always be reached by dividing the mucous membrane within the mouth, and without incising the cheek; but if necessary, a single line of incision only should be made, so that as little after-deformity as possible may be produced.



## CHAPTER XIII.

## CYSTS OF LOWER JAW—MULTILOCULAR CYSTIC TUMOUR.

DURING the last few years very considerable light has been thrown upon the clinical history and pathology of certain cystic tumours of the jaws, both by cases occurring in my own practice, and by the careful microscopic investigation of these and others by Mr. Frederick Eve, who embodied his results in a lecture given at the College of Surgeons in 1882, and published in the *British Medical Journal* of January 6, 1883. Believing that Mr. Eve's views are confirmed by clinical experience, I have adopted them in the following pages, and shall include, under the head of "multilocular cystic tumour," several tumours which in former editions of this work were classed as "cystic sarcoma"—always an unsatisfactory term—as well as those hitherto regarded as simply multilocular cysts.

Mr. Eve believes that so far from multilocular cysts having a dental origin, they are produced by an ingrowth of the epithelium of the gum. They have frequently followed some form of injury, irritation by decayed teeth, or long-continued inflammation, which has induced an increased supply of blood to the parts. The multilocular cystic tumours are slow of growth, they have very little tendency to implicate surrounding parts or the neighbouring lymphatic glands, and if completely removed rarely recur and still more rarely become disseminated through the system. Their comparative innocence is probably explained by the bony capsule forming their boundary, by their low degree of vascularity, and by the remarkable tendency of the epithelial cells composing them to undergo degenerative changes.

Multilocular cysts may contain other cysts within them,



but this condition must be a rare one, for I can find only two examples of it. One is a congenital cystic tumour in an infant of six months, who was under Mr. Coote's care in 1861, and of which the following brief facts are extracted from the *Lancet* of Aug. 31, 1861:—"The right half of the lower jaw was enormously enlarged, and occupied a prominent position in the neck, extending downwards as far as the chest. It appeared to invade the entire bone, but was really confined to the right side. Its increase had been rapid since birth, and as it was still enlarging it became necessary to do something to afford a chance for life, as, if left alone, suffocation would have ensued in a short time. Accordingly, chloroform being given, an incision was made by Mr. Coote upon its outer part, and a thin shell of the expanded jawbone reached. This was opened, and the interior was found to be filled with a regular nest of cysts, one placed within the other, all of which were removed, and the cavity closed with lint. Very little blood was lost during the operation, and for a few days afterwards the child improved very much in health, although necessarily weak, and the great swelling of the neck was much diminished. Suppuration became freely established, and the drain shortly after began to tell upon the system, for the child became weaker and weaker, although well supplied with wine and good nourishment, and finally died from exhaustion."

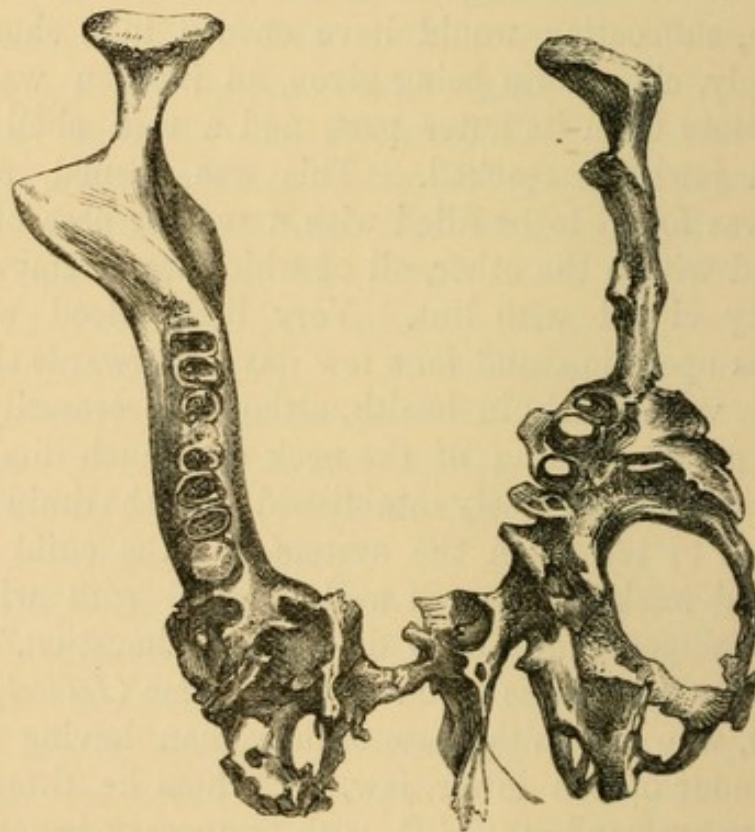
The other instance is given by Mr. Syme (*Lancet*, March 10, 1855), who quotes the case of a woman having a large cystic tumour of the lower jaw, in whom he three times opened the cyst and stuffed it, with temporary benefit. He was obliged eventually, however (five years after the first operation), to remove one-half of the bone, when the cyst was found to be compound, there being four cavities, the walls of which were studded with smaller cysts.

Multilocular cysts are more often found in the lower than in the upper jaw, and in most cases in direct connection with teeth or stumps. In the *Guy's Hospital Reports* for 1847 is the notice of a case of the kind by Dr. Wilks, in a girl of eighteen, in whom there had been an enlargement of



the right side of the lower jaw for twelve years. The tumour, on removal, proved to be a cystic growth: "there being four or five large cells between the internal and external plates of bone, which appeared like expanded alveoli, all of them containing fangs of teeth. The cells contained a glairy fluid." Very considerable alteration in the form of the maxilla may be produced by growths of this kind, of which a good example is seen in the drawing (fig. 90) from a macerated specimen in St. Bartholomew's Museum (I. 308.)

FIG. 90.



Here the bone is irregularly expanded in great part, to form septa between cysts. These, which were independent of one another, had their origin in the interior of the bone, were lined by a highly vascular membrane, and contained thin serous, or grumous, blood-tinged fluid. The walls of some of the cysts were thin and yielding, but others were thick and resisting, and this was particularly the case with the most posterior cyst on the left side, which had pressed upon and caused absorption of the left ramus and coronoid process.



The preparation was taken after death from an old man aged seventy-five, who had noticed the enlargement for five years when he came under Mr. Coote's care in St. Bartholomew's Hospital in 1857. The following brief account of the case is taken from the *Lancet* of Oct. 10, 1857:—"The origin of the affection Mr. Coote attributed to the irritation produced by the stumps of decayed teeth. He punctured some of these cysts with a trocar, and gave exit to a sero-purulent fluid from one, and fluid like the white of egg from two others. On the 5th of September he pulled out a couple of bodies of teeth, with scarcely any remains of fangs, but in their stead some irregular fibrous-like projections. The removal of these permitted the flow of a sero-albuminous fluid, the teeth having acted like stoppers. Since the man had been in hospital, the size of the tumour had most certainly diminished one-third under the plan of treatment of puncturing. The age of the patient precluded the possibility of attempting any more severe measures than those already adopted. On the 21st the swelling had somewhat increased, and three or four of the cysts were again punctured, with the discharge of a thick, clear, yellow fluid, and several of these were run into one internally. This was done under partial anæsthesia from chloroform. One of the cysts discharged a good deal in the mouth; this was partly swallowed, and had caused indigestion."

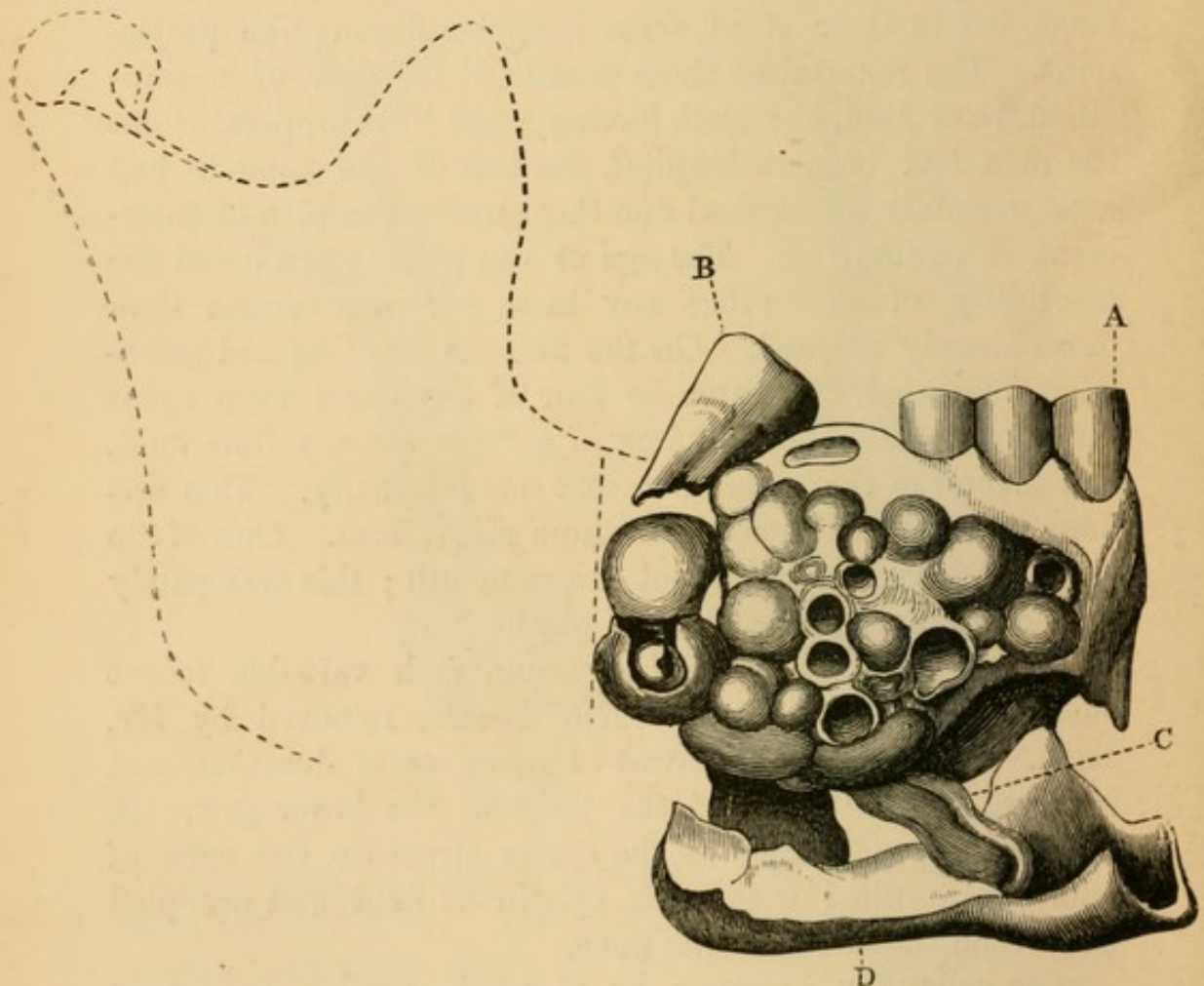
In St. Mary's Hospital Museum is a valuable recent specimen (A. d. 50) of the same disease, removed by Mr. Lane. Here the growth was of seven years' duration, and involved the left side of the body of the lower jaw. A longitudinal section shows the cystic structure, the cells of which were filled with dark gelatinous fluid, and occupied the whole thickness of the bone.

The cells may, however, be of much smaller size; thus Dr. Robert Adams records, in the *Dublin Hospital Gazette* for 1857, the case of a man from whom he removed a portion of the body of the jaw from the symphysis to the molar teeth, about two inches in length. "The mucous membrane covering it was here and there raised into small rounded



eminences of the size of peas, though some were larger and purple in colour (fig. 91). The tumour was composed of bony cells of a texture as fine as the ethmoid bone. The cells generally were of such a size that each might be capable of receiving within it a garden pea. They communicated with each other, and amounted to no less than twenty-six in number. They were all lined by a pulpy, very red, vascular membrane, and contained an albuminous fluid tinged of a reddish colour, apparently from blood held dissolved in it."

FIG. 91.



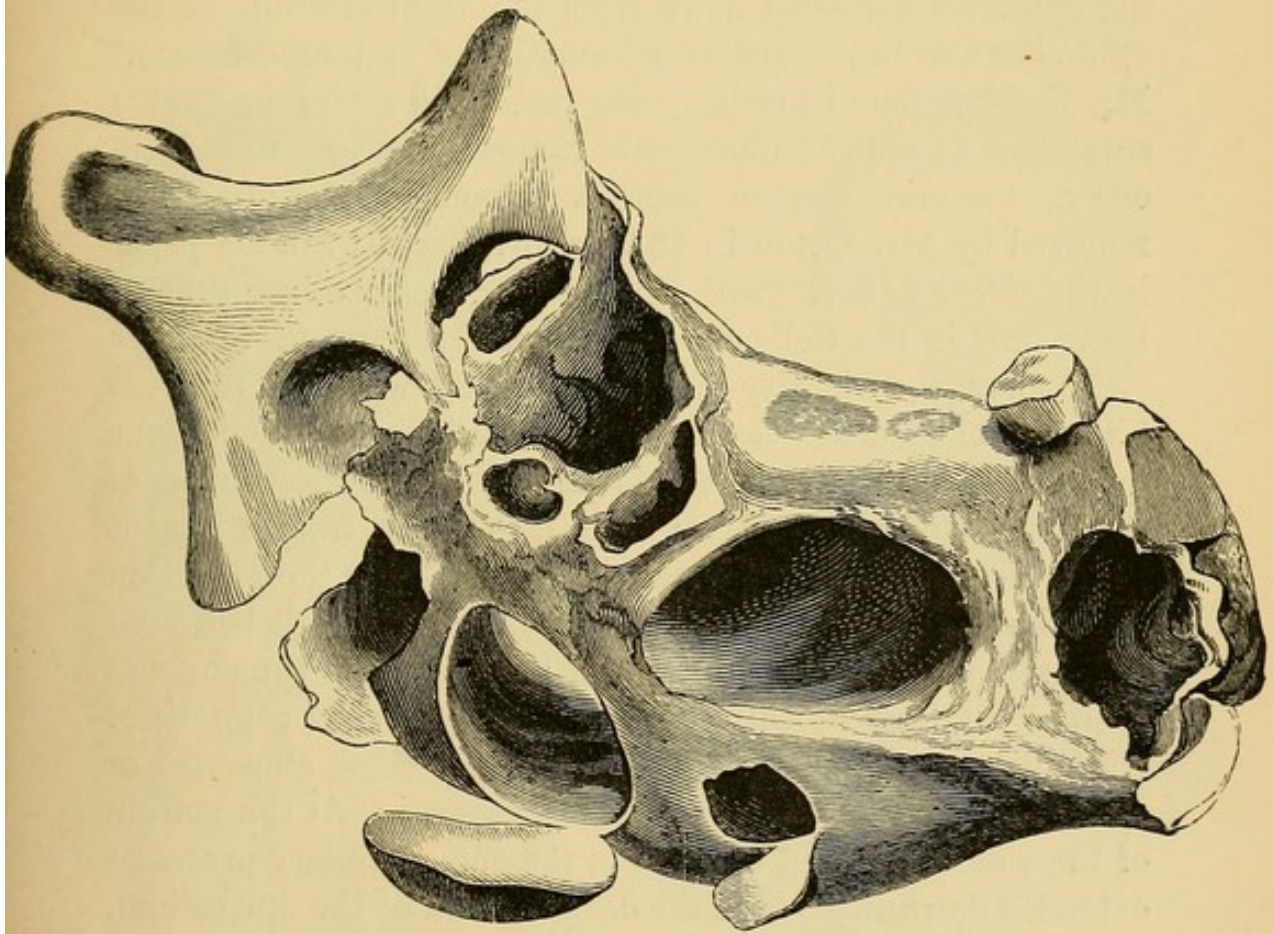
A, Canine; B, Second molar; C, Anterior portion of dental nerve;  
D, Remains of the base of horizontal branch of jaw excavated on its  
upper surface, on which lay the tumour.

Again, in cases of long-standing disease the cysts become greatly distended, and the septa, in great part, absorbed, so that the cysts communicate very freely.



Of this kind was a tumour (fig. 92) removed by Mr. Cusack, in 1826, from a woman named Kenny, whose case will be found in detail in Mr. Cusack's well-known essay in the *Dublin Hospital Reports*, vol. iv. Dr. Adams, in his paper already referred to, supplies an account of the tumour in this case. "The portion of bone removed comprises the entire right half of the lower jaw. The horizontal ramus is

FIG. 92.



expanded into an oblong hollow shell with bony walls, and its interior is subdivided into many cells of various sizes, which are all lined by a fine polished membrane, and communicate freely with each other."

The microscopic character of the solid material found more or less in all cases of multilocular cyst is well given in the following report by Mr. Eve upon a very well-marked recent specimen of the disease, contributed to the St. Bartholo-



mew's Hospital Museum (I.536) by Mr. Keetley:—"The solid portion of the tumour was composed of columns of cells and nuclei of the epithelial type, which, when cut transversely, presented the appearance of alveoli; similar small columns branched out from the side of the larger. The cells in the centre of the columns had in many places undergone a colloid change, and by the complete metamorphosis of the cells the cysts were formed. From the buccal mucous membrane covering the tumour, in certain parts, club-shaped and branching cylinders extended down from the deep stratum of the epithelium, as in the ordinary formation of epithelial cancer." Mr. Eve has found precisely the same characters in twelve specimens of multilocular cystic tumours he has examined, one of the most marked being a tumour of the *upper* jaw removed by Mr. Liston in 1836, and referred to in his paper in the *Medico-Chirurgical Transactions*, vol. xx., the tumour being now in the College of Surgeons' Museum (2202).

To show the identity of the foregoing with the tumours hitherto classed as "cystic sarcomata," I may quote the description of the microscopic appearances of a tumour of the latter kind removed by myself, in 1871, from a patient æt. twenty-two, whose portrait before and after the operation is given in figs. 93 and 94, and whose case will be found in detail in the Appendix (Case IX.):—"The tumour was composed microscopically of straight or tortuous columns of epithelial cells, those forming the margin being elongated or cylindrical and radiating towards the centre. At the margin of the small ulcerated opening in the gum, papillary processes extended downwards from the deep stratum of the epithelium, and were continuous with the columns forming the tumour" (College of Surgeons' Museum, 2203). The half of this tumour, deposited in the Museum of University College, is described in the valuable catalogue by Mr. Marcus Beck as a "gland-like tumour of bone," and its structure is identical with that of a tumour described by Mr. Wagstaffe in the *Pathological Society's Transactions*, vol. xxii. Mr. Wagstaffe found that the growth was composed of innumerable cysts and a solid matrix, through which a certain amount of bone



was scattered ; that the cysts were lined by a layer of large globular epithelium ; that into the interior of the larger cysts other smaller cysts projected, and these endogenous cysts took their origin in the epithelial lining, and not in the matrix of the growth. Other cysts were also freely scattered throughout the structure, but the endogenous formations were so marked that they could be discovered as little balls by the naked eye, and removed for examination by the point of a needle. The solid structure consisted of a very peculiar

FIG. 93.

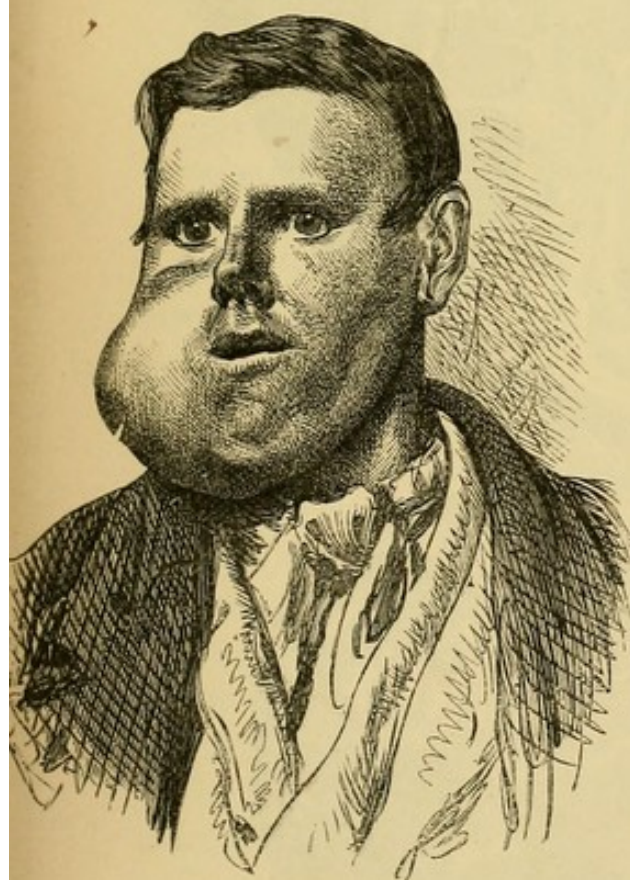



FIG. 94.



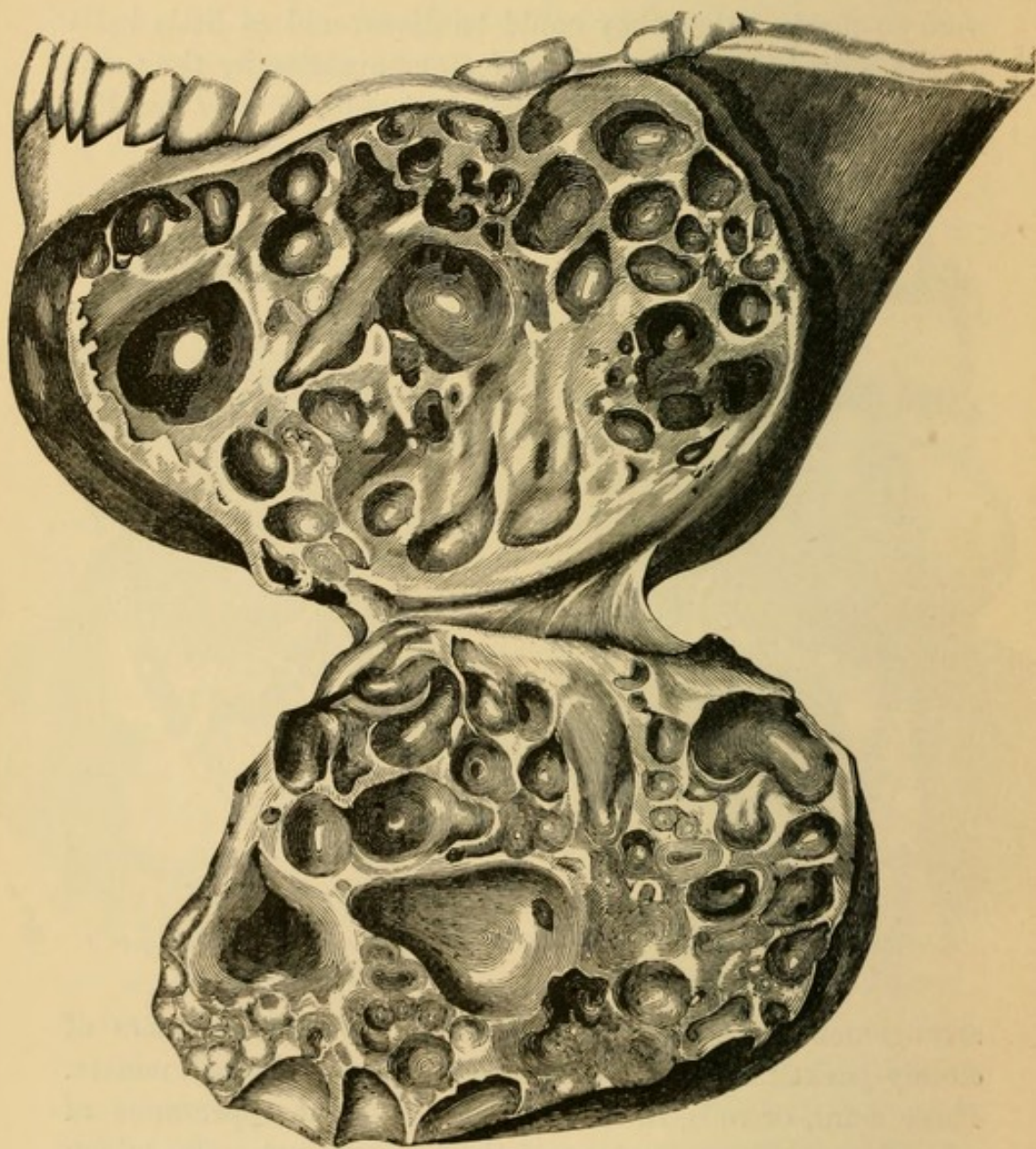
arrangement of what appeared to be acini or cylinders of closely-packed cells, supported by a fibro-nucleated matrix. These acini, or rods, in many places gave the appearance of tubes from the arrangement of their component cells, which resembled very curiously that of columnar epithelium, or of the epithelium of gland follicles. The cut ends, however, showed no central canal. The constituents of these rods were nuclei embedded in plastic matter, and these separated



by manipulation into small tailed or so-called spindle cells, of similar size and character to the corpuscles of an ordinary sarcoma.

The best example of the disease, hitherto known as cystic

FIG. 95.



sarcoma, with which I am acquainted, is in the Museum of the Richmond Hospital, Dublin, and was removed by the late Dr. Hutton. It is represented in the accompanying woodcut (fig. 95), for which I am indebted to Dr. R. Adams,



and shows very beautifully the development of cysts of various sizes in a growth of a benign character, involving the whole of one side of the body of the jaw and extending to an inch beyond the symphysis. The patient was a young woman of twenty, and the tumour had existed nine years, but had only recently made rapid progress, and produced great distress by its pressure on the tongue and mouth. Dr. Hutton removed the jaw from the right of the symphysis to the left angle, and the patient made a good recovery (*Dublin Hospital Gazette*, 1860). In this case the disease invaded only the body of the bone, but the ramus is also liable to it, a specimen in King's College Museum, removed by the late Mr. J. H. Green, being an instance in point.

The contents of these cysts vary in consistency and colour; in some cases being clear and limpid, in others almost gelatinous and of a dark colour.

My attention was first directed to the fact that multilocular cystic disease is not always a simple local ailment, by the case of a patient who was able to give me a "Thirty-five years history of a maxillary tumour," which I communicated in 1880 to the Association of Surgeons practising Dental Surgery (*British Medical Journal*, May 22, 1880). The patient, when he first came under my notice in 1877, was a healthy country gentleman, who said that, as long as he could remember, there had been some enlargement of the right side of the lower jaw. In 1845 this enlargement increased very rapidly, and in 1847 Sir W. Fergusson removed a tumour of the right side, sawing through the ramus horizontally, and the body of the jaw close to the right canine tooth. The tumour was apparently of a fibroid character, having a large cyst developed in it, and is now in the Museum of King's College. He continued in good health for fifteen years, and then noticed the formation of a cyst in the incisor region, which had frequently been tapped by Sir W. Fergusson. In July, 1877, I found cystic disease of the left side of the body of the jaw extending to the molar region, and operated by extracting all the teeth, opening up the cysts freely, and clearing out some solid growth with the gouge. From this



the patient made a good recovery, with considerable consolidation of the bone, but, in the following November, one cyst was found to have developed anew in the incisor region, and this was treated in a similar manner. A year later a fresh development of cysts had taken place and the operation was repeated with a good result, so that in February, 1879, the jaw was completely consolidated, and the patient was advised to have some artificial teeth fitted. In November, 1879, the patient reappeared with a large solid tumour, involving the left side of the body of the jaw, which, noticed first in June, had grown rapidly of late, and now involved the skin for an area of a square inch. On December 2nd I removed the tumour by sawing through the bone immediately in front of the left masseter, and also removed a piece of infiltrated skin from the left of the median line. The wound was brought together with harelip-pins and sutures, and only one artery (facial) was ligatured. The patient made a good recovery, took food with a spoon, and was able to talk intelligibly after the first week, although deprived now of the entire body of the jaw. The lower end of the wound being left open afforded a thorough drain for discharge. The patient returned early in February, when the skin near the wound was found to be increasingly infiltrated, and a tumour of the size of an orange was found beneath the right deltoid. He had strained the right arm in getting into a hip-bath, but was quite clear that the humerus had not been struck. The tumour was painful, but the bone was sound, the head moving with the shaft. A week later the patient was found to have a tumour in the pelvis, pressing upon the rectum, and springing from the interior of the right innominate bone. From this time he gradually lost strength, and died at the end of March. The second tumour was pronounced by Mr. Doran to be a round-celled sarcoma, and the same growth was found in the piece of skin which was removed. The earlier tumour appeared to be a fibroid or a spindle-celled sarcoma. No post-mortem examination of the internal growths could be obtained.

The specimen is preserved in the Museum of the College



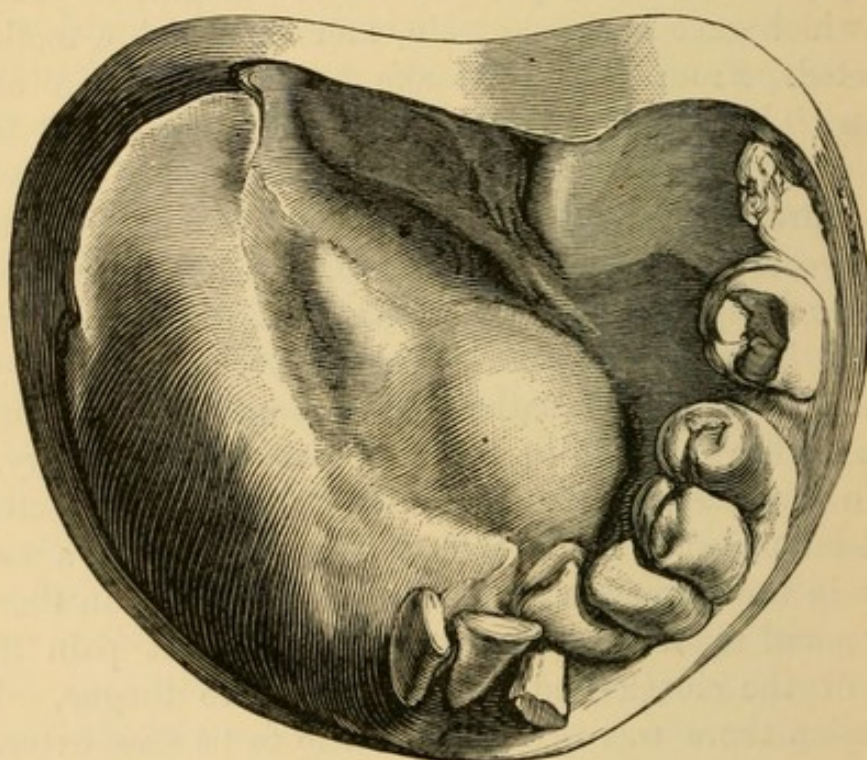
of Surgeons (2204), and Mr. Eve's further examination confirms the fact that the bulk of the tumour is round-celled sarcoma, but in addition the upper portion of the tumour contains isolated masses composed of tortuous closely-crowded columns of small epithelial cells.

The second case bearing upon the same question was in a woman of forty-four, who was admitted into University College Hospital, on November 3, 1875, with the following history :—About nine years before, the patient first noticed a lump of the size of a pea beneath the tongue, on the right side, which gave her some pain, and for which a tooth was extracted. From that time she had a succession of abscesses (?) in the lower jaw, some of which discharged in the mouth, and one externally, and for which she had had several teeth extracted. Dr. Parsons, of Dover, had sent her to me three years before, and I then recommended her to come into the hospital; but she declined, and went on with a steadily increasing tumour of the lower jaw on the right side. About nine months before admission the tumour seems to have begun to increase with some rapidity, and within the last two months, the following characteristic event happened. While eating, the patient felt a sudden crack in the lower jaw, and this occurred twice in the same week; and upon each occasion she felt great pain in the floor of the mouth and upon moving the tongue. Upon admission there was really very little to be seen externally, and a photograph taken at the time shows that, excepting a very small projection beneath the skin in front of the angle of the jaw, there was nothing to call attention to the patient's face. On looking into the mouth, however, the tumour was at once obvious, and is seen in a cast taken from the jaw at that time (fig. 96). The right side of the lower jaw is seen to be greatly expanded from immediately in front of the ramus to beyond the median line, the tumour measuring two inches across at the broadest part, and reaching under the tongue. Its surface was lobulated and rounded, firm and osseous in the greater part, but yielding distinctly on pressure in two or three places. The mucous membrane



was entire over the tumour, except at one point where there was an opening, from which a discharge constantly exuded. The incisor teeth of the right side were displaced over to the opposite side, and were loose. The central incisor of the left side was displaced completely in front of the other teeth. The left canine and bicuspid were firmly fixed. Notwithstanding the size of the tumour, the outline of the lower border of the jaw was scarcely interfered with, the disease

FIG. 96.



being mainly confined to the alveolar portion of the bone ; and I, therefore, decided to operate from within the mouth, so as to avoid, if possible, all external scar.


On November 10 the patient was put under chloroform, and, a gag having been introduced on the left side, I first extracted the four incisors, and then made a free incision with a stout scalpel along the upper surface of the tumour, cutting easily through the thin bone and thick membrane forming its upper wall. A quantity of dark-coloured cystic fluid at once escaped, and I then cleared out the semi-solid contents with the finger and gouge. The finger introduced



into the cavity passed completely under the canine and bicuspid teeth of the opposite side without disturbing them. I next cut away a portion of the cyst-wall with scissors, and crushed together the remainder, as far as I could, with my fingers and thumb. The actual cautery was applied to one spouting vessel in the margin of the alveolus, and the cavity was stuffed with lint dipped in a solution of chloride of zinc (twenty grains to the ounce).

The patient had very little constitutional disturbance; the plugs were gradually removed from the cavity of the jaw, which was carefully syringed out frequently with Condyl's fluid, and soon began to granulate and fill up. She was discharged a month after the operation, when the two plates of the lower jaw had come together, and the cavity was filled up almost completely by granulation-tissue, there being only a shallow cavity half an inch long still to be filled up midway between the angle and the symphysis.

FIG. 97.



This patient again presented herself in October, 1878, nearly three years after the first operation, with a recurrence of the



cysts, which were treated again by gouging and crushing in. In August, 1882, she again appeared with a formidable tumour of the lower jaw, which had already sprouted through the chin at more than one point (fig. 97). There could be no question now of the necessity for excising the portion of jaw involved, and this I accordingly did, removing from an inch in front of the angle on the left side to the right temporo-maxillary articulation. The patient made a good recovery, and has remained well.

FIG. 98.



The occurrence of solid epitheliomatous growths, as a sequel of multilocular cystic disease, being now sufficiently illustrated, I may refer again to the case of "cystic sarcoma" described at p. 202, and illustrated by figs. 93 and 94. It will be found on referring to the details of the operation (Case IX.), that I left *in situ* the coronoid process and condyle with part of the posterior border of the lower jaw, in June, 1872. In October, 1883, this patient reappeared in the condition shown in fig. 98, with a typical epithelial ulcer of the skin of the cheek. On proceeding to cut this away freely, I



found that it was attached to the remains of the lower jaw, which I was obliged to remove in order to get rid of the whole of the growth. One half of this secondary growth is in the Museum of the College of Surgeons (2203A), and its microscopic characters correspond precisely to those of the former growth, p. 202.

There can, then, I think, be no doubt that under the term "multilocular cystic epithelial tumour," as proposed by Mr. Eve, we may include the old multilocular cysts and cystic sarcomata, both having a distinct tendency to be reproduced locally, and in certain cases to become disseminated.

*Treatment.*—Mr. Butcher, of Dublin, has for some years treated cases of multilocular cyst of the lower jaw through the mouth, by dividing the mucous membrane over the cyst freely, and then with gouge and bone-forceps removing the expanded external plate of the bone, with the contents and lining membrane of the cyst. In this operation, the teeth are interfered with as little as possible, and appear to remain firm. Granulations rapidly spring up from the denuded bone, and fill the wound made in the mouth; the cheek resumes its ordinary appearance, and no deformity or scar is left. In his work on "Operative and Conservative Surgery," Mr. Butcher narrates three cases treated in this manner, and remarks, that "the proceeding according to this plan is troublesome and difficult, but its value to the patient in having no deformity left is priceless." A valuable caution is here given respecting the facial artery, which might, without care, be divided from within the mouth in a position where it would be very difficult to secure it. Mr. Butcher also narrates and gives a drawing of a case in which, finding the disease too extensive to be treated from the mouth, he adopted Dupuytren's external incision, and then levelled the projection to the line of the healthy bone with the best results, the incision being completely hidden behind the bone.

Dr. Mason Warren has also (*Boston Medical and Surgical Journal*, 1866) written upon the treatment of cysts of the jaws, and strongly recommends a milder and even



more conservative practice than that followed by Mr. Butcher, which he thus summarizes:—"The treatment consisted in the puncture of the sac within the mouth, evacuating its contents, and at the same time obliterating its cavity by crushing in its walls; and lastly, in keeping up, by injections, &c., a sufficient degree of irritation to favour the deposition of new bone."

I have now treated a considerable number of simple and multilocular cysts by Mr. Butcher's method, and, as has been noted, with recurrence in at least two of the latter. Mr. Butcher does not appear to have met with further trouble in his cases, and this may depend upon his "carrying out the gouging fearlessly and far wide of the disease." I should in future be guided by the age of the patient, and the amount of solid material found in the cysts. In young persons with cysts having fluid contents and little growth in the bone, I should be still inclined to adopt palliative measures and to gouge very freely, carefully watching the case with a view to a more radical proceeding, should further development take place. In cases of much solid deposit in connection with multilocular cysts, and still more in cases of solid tumour with one or more large cysts, there should, I think, be no doubt as to the removal of one-half or more of the lower jaw, or of any portion of the upper jaw involved.

In his well-known essay on "Diseases of the Jaw" (Calcutta, 1844) Mr. O'Shaughnessy narrates a case of large cystic disease of the jaw which would appear to have been originally a multilocular cyst, in which the septa had undergone almost complete absorption, so that "the tumour after maceration was found to be a hollow shell of bone, containing in its centre a quantity of a gelatinous and fluid substance, and a few particles of bone like pieces of honeycomb. The coronoid process was hollowed out like the rest of the bone, and so thick, that it must have completely filled the temporal fossa, which accounts for the difficulty experienced in trying to divide the temporal muscle."

This difficulty of clearing the coronoid process has been noticed also in cases where the bone has been expanded by



a solid growth within it, or is wedged in by a portion of tumour springing from the ramus. Dr. Robert Adams narrates (*Dublin Hospital Gazette*, April 15, 1857) a case of the former kind, and Mr. Cusack (*Dublin Hospital Reports*, vol. iv.) two cases of the latter, in all of which the difficulty was overcome by sawing through the ramus of the jaw and subsequently removing the coronoid process and condyle. The possible occurrence of this difficulty is to be borne in mind in cases of cystic growth requiring disarticulation; and I experienced it in the case of large "cystic-sarcoma," already referred to.

The difficulty is best got over by the division of the coronoid process with the bone-forceps, and the piece thus cut off should afterwards be dissected out.



## CHAPTER XIV.

## TUMOURS CONNECTED WITH TEETH AND ODONTOMATA.

IRREGULAR development of the teeth is of little interest from a surgical point of view, except when, from their abnormal positions, they give rise to tumours of the jaw. The relation of cysts to undeveloped teeth has been discussed under the head of "Dentigerous Cysts," but the solid growths directly connected with the teeth also require investigation.

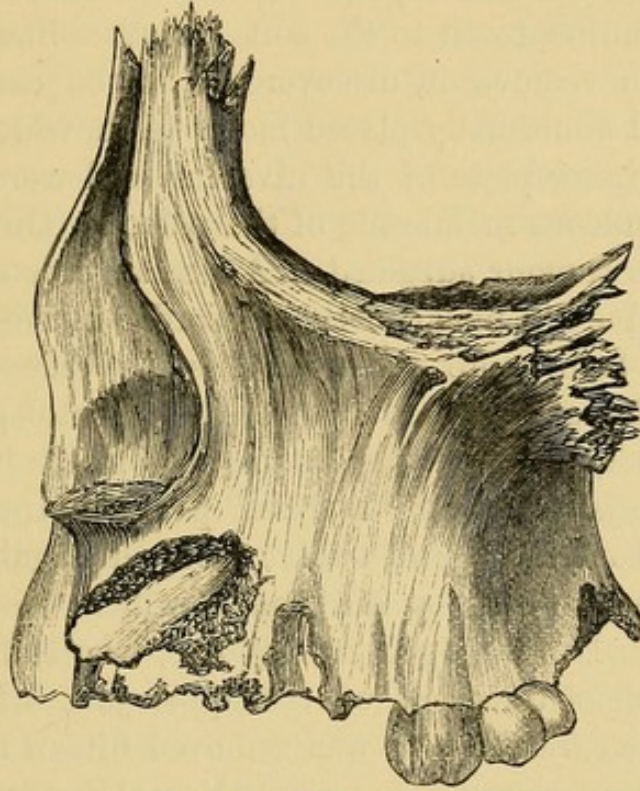
The irregularities of the teeth which are fully cut come into the province of the dental surgeon, and in Mr. Tomes' valuable work on Dental Surgery, numerous drawings are given of the abnormal positions in which various teeth have appeared. It is the uncut teeth, however, which are of interest surgically, and these may be divided into two classes. In the first, the tooth which has deviated from its normal position is still contained within the alveolus, where by its presence it may give rise to a more or less distinct tumour. Of this fig. 99 gives an example from the work of Dr. Forget, on Dental Anomalies, for permission to use which I am indebted to Mr. R. T. Hulme, the translator of Dr. Forget's papers in the *Dental Review* of 1860. In the second class of cases the misplaced tooth is situated in a part of the jaw more or less distant from the alveolus, and of this fig. 100 presents an example, the canine tooth being placed horizontally in the floor of the nasal fossa, in the interior of which it formed a considerable projection.

The molar teeth of the upper jaw, and particularly the wisdom teeth, seem especially liable to misplacement. Mr. Tomes (*op. cit.*) gives numerous illustrations of this irregularity, and in the Museum of the College of Surgeons is



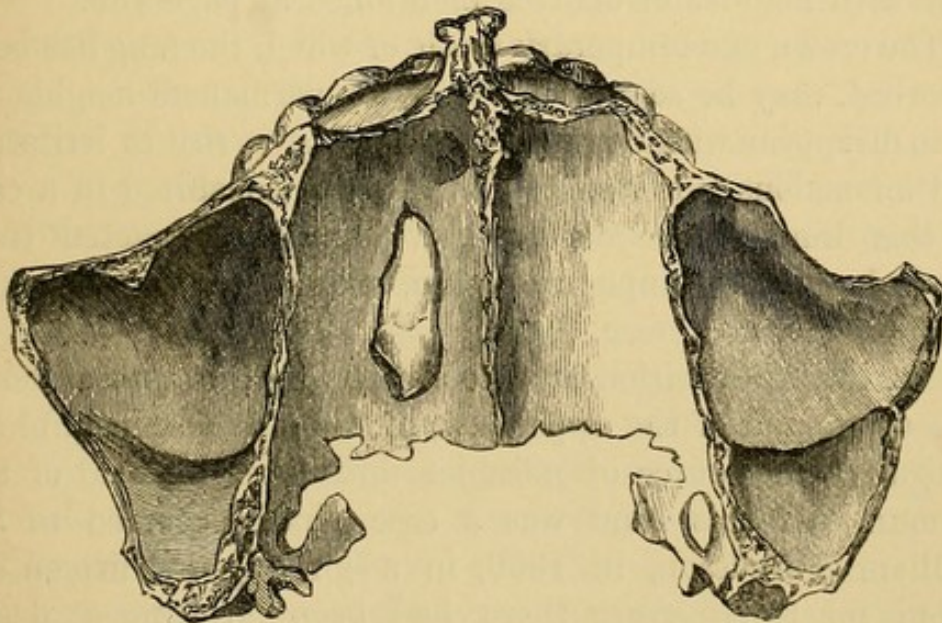
a cast of a case in which a wisdom tooth projected through the cheek. The wisdom teeth of the lower jaw are also

FIG. 99.



prone to assume an abnormal position in relation to the coronoid process, and in either position a tumour may be

FIG. 100.





formed which may be difficult of diagnosis. Dr. Forget (*op. cit.*) quotes the case of a woman who had, on the left side of the hard palate, a tumour of the form and size of a nut, which reached beyond the median line, and extended from the canine tooth to the soft palate. Blandin, on attempting to remove it, discovered it to be caused by two dwarfed and abnormally-placed molar teeth, which had penetrated the inner plate of the alveolus, and were lodged beneath the mucous membrane of the palate. On the removal of these the tumour subsided. A similar case of tumour of the palate, due to a molar tooth, is recorded in Tomes' "Dental Surgery." Still more remarkable is the case narrated by Mr. Tellander, of Stockholm, before the Odontological Society, in December, 1862, of supernumerary teeth imbedded in the upper jaw, causing a hard painless tumour, which appeared about the age of twelve; and this again is eclipsed by the case recorded by Mr. Tomes, which occurred in the person of a Hindoo, aged twenty-five, who suffered from a large tumour of the front of the upper jaw. Mr. Mathias, under whose care the man was, removed fifteen masses of ill-formed and supernumerary teeth ("Dental Surgery," 2nd ed.). It is possible, however, that both these last cases may have been examples of dentigerous cyst which had ruptured before the patient came under observation, resembling the case of cyst with nodules of dentine mentioned at page 185.

The crown of a temporary tooth, of which the fang has been absorbed, may be so crowded in by its permanent neighbours as to disappear within the alveolus and give rise to irritation and anomalous symptoms. I was once consulted in a case of this kind, when Mr. Edgelow skilfully extracted from some depth the temporary crown, which proved to contain a stopping!

But the malposition of a tooth may give rise to a dense osseous tumour of the upper jaw, in which it is impossible to recognize the source of mischief until after removal of the tumour. Of this kind was a case which occurred to Sir William Fergusson, in 1856, in a girl aged thirteen, in whom for three years there had been growing a dense



tumour of the left superior maxilla, which, upon section after removal, proved to contain a tooth imbedded in its centre.

Even more remarkable, however, than mere malposition, are certain modifications which the molar teeth occasionally undergo during their development, giving rise to most interesting tumours of the jaw, which have been specially studied and described under the name *Odontomes* by M. Broca ("Traité des Tumeurs," 1869). These tumours depend upon some modification of the germ of the tooth before the formation of the cap of dentine, and belong to Broca's second class, *odontomes odonto-plastiques* or *odontomes bulbaires*. The result is the formation of an irregular mass of dental tissues in no way resembling a tooth in shape.

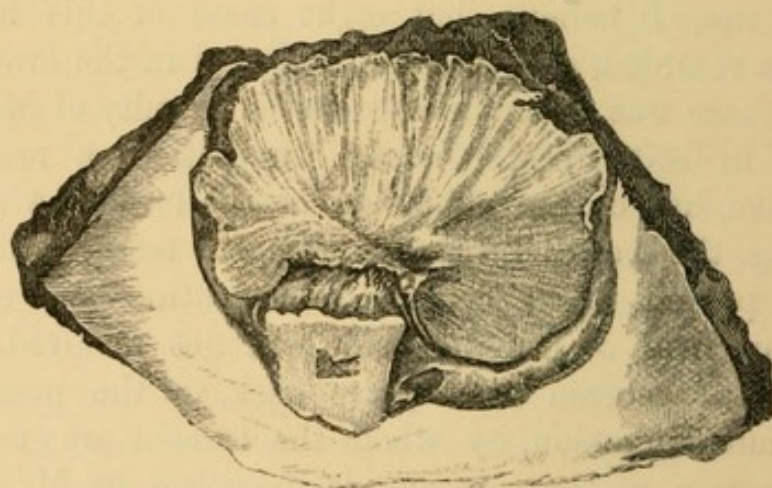
There are, I believe, but eight cases of this form of odontoma recorded, and these all occurred in the lower jaw. The first case was communicated to the Faculty of Medicine of Paris in 1809 by M. Oudet. The patient, a man aged twenty-five, had on the right side of the lower jaw a mass occupying the position of the premolar teeth, which on removal proved to be composed of dentine and enamel. A similar mass on the left side was not removed. The second case occurred some years back, in the practice of Sir William Fergusson, by whom the tumour was removed with a portion of the jaw, and is described by Mr. Tomes ("Dental Surgery"), from whose work a drawing of a section of the tumour is taken (fig. 101). "The second molar of the lower jaw was represented by an irregularly flattened mass, composed of enamel, dentine, and bone derived from calcification of remnants of the dentine pulp, thrown together without any definite arrangement, by which the wisdom tooth was held down. The dental mass, when removed from its receptacle in the bone, presented no resemblance to a tooth. Little beads of enamel here and there projected from the surface, which was generally rough and irregular. The naked-eye appearance of the section is accurately given in the woodcut, the radiate character in which shows the arrangement of the component tissues, which, by the aid of



the microscope, are seen at places to alternate. The alternation is mainly effected by the dentine and bony tissue, and these, indeed, form the great bulk of the mass. . . . The appearances presented, prior to the operation, consisted in enlargement of the jaw posterior to the first permanent molar tooth, with a hard, brown-looking body projecting but slightly from the surface of the gum. This projecting portion was, in fact, the upper surface of the aberrant tooth; and the nodules of enamel were, for the most part, situated in this part of the mass.

The third case occurred to Dr. Forget (*op. cit.*), in the person of a young man, aged twenty, who presented himself

FIG. 101.

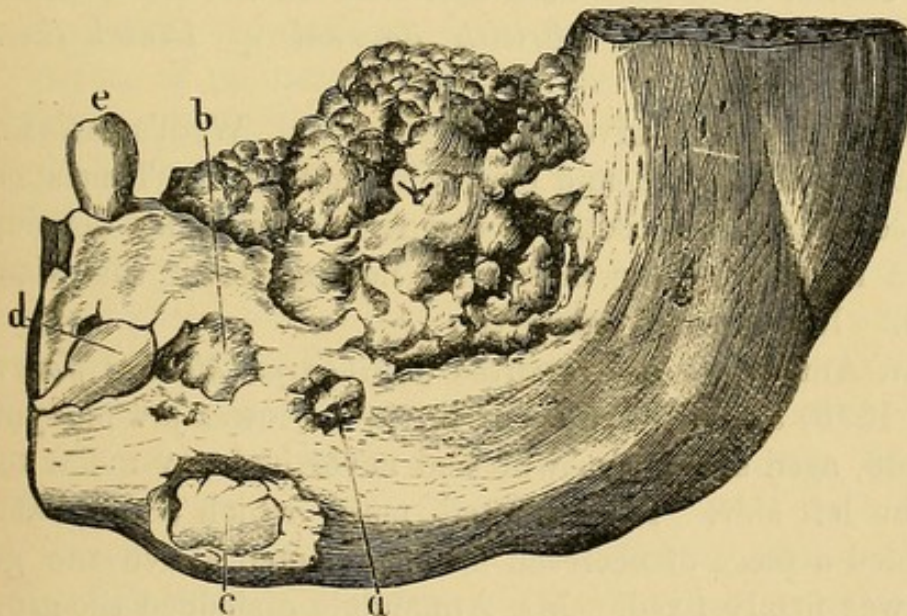


in 1855 with a disease of the lower jaw, from which he had suffered since he was five years old. Upon looking into the mouth, a round, smooth tumour, hard and unyielding, was seen occupying nearly the whole of the left side of the jaw. None of the teeth beyond the first bicuspid were present. Dr. Forget removed the portion of the jaw involved by sawing through it in front of the bicuspid tooth, and also through the ramus at the level of the inferior dental foramen. The portion removed is seen in the accompanying drawing (fig. 102). An examination of the portion which had been removed, showed that the portion of the jaw between the ramus and the first bicuspid tooth was converted into a cavity,



which was occupied by a hard oval mass, of the size of an egg, having an uneven surface covered here and there with minute tubercles, which were invested by a layer of enamel, penetrating into the substance of the bone, and easily recognizable by its shining appearance and peculiar colour. A section of the tumour showed that it consisted of a compact tissue of the consistence of ivory, of a greyish-white colour, in the interior of which it was possible to perceive, with the naked eye, a kind of regular arrangement of the elements which entered into its composition. Between the tumour and the osseous cyst was a thick membrane, apparently of a

FIG. 102.



fibro-cellular structure. At the anterior extremity of the base of the tumour was a depression in which the crown of an inverted molar tooth was wedged in between it and the maxilla. This tooth is seen in fig. 102, *c*, where a portion of bone has been cut away; *a* and *b* mark portions of the tumour projecting through the jaw, and *d* is the second bicuspid tooth lying below the first, *e*.

The microscopic examination of the tumour showed it to be composed principally of dentine, with enamel on the surface and dipping into the crevices, at the bottom of which, as well as in other parts, portions of cementum were found.



Dr. Forget regards the case as one of fusion and hypertrophy of the last two molars.

The fourth case of the kind was brought under the notice of the Odontological Society of Great Britain, in December, 1862, by the late Mr. W. A. Harrison, F.R.C.S. The specimen closely resembled those already described, and came from the left side of the lower jaw of a lunatic, where it occupied the space between the incisor and molar teeth. It came away spontaneously, leaving a long deep groove, large enough to receive the last joint of the thumb, which soon granulated and contracted. The specimen is in the Museum of the Dental Hospital, Leicester Square. Cases of a similar kind have been met with in the lower animals, especially the horse. (*British Journal of Dental Science*, December, 1862).

The fifth case is given in Heider and Wedl's *Atlas zur Pathologie der Zähne*, and closely resembles Mr. Tomes' case, the second molar tooth of the right side being developed into a large irregular mass, and holding down the wisdom tooth. It was easily removed.

Mr. Annandale has reported (*Edinburgh Medical Journal*, Jan. 1873) a sixth case occurring in the lower jaw of a young woman, aged seventeen, who had never had any molar teeth on the left side. A nodulated mass, which somewhat resembled a piece of necrosed bone, projected above the gum, and was firmly fixed. Mr. Annandale dislodged the growth and removed it through the mouth. It measured  $1\frac{1}{2}$  by  $1\frac{1}{4}$  inches, and weighed 300 grains, and on section showed "that a cap of enamel, varying in thickness, was arranged over a portion of the irregular surface of the mass. Beneath this, well-formed dentine, forming a considerable thickness, was met with; and still deeper in the substance of the mass, true bone, containing lacunæ, canaliculi, and Haversian canals, was seen to be intermingled in a confused manner with portions of dentine, so as to form the substance called by histologists "osteo-dentine."

The seventh case occurred in the practice of Dr. Goodwillie, of New York, and is mentioned in Agnew's "Surgery,"



vol. ii. It appears to have been removed with the angle of the jaw.

An eighth case has been recorded by myself in the *Clinical Society's Transactions*, vol. xv. All these specimens were met with in young adults, and only the first, fifth, sixth, and eighth were extracted from the jaw by the surgeon, in Mr. Harrison's case the mass coming away spontaneously, and in Mr. Tomes' and M. Forget's cases a considerable portion of the lower jaw being removed by such experienced surgeons as Sir William Fergusson and M. Maisonneuve. In my own case I must confess that I did not appreciate at first the nature of the tumour, and recommended removal of a portion of the jaw, and that it was only during a subsequent operation undertaken for supposed necrosis that the true nature of the case became apparent.

Miss C., aged eighteen, the daughter of a dental surgeon, was brought to me in July, 1881, with a considerable swelling of the right side of the lower jaw, some of which was evidently inflammatory, and partly the result of previous treatment; but there was, I thought, sufficient evidence of expansion of the jaw to warrant the opinion that a tumour was present, and I therefore recommended the removal of a portion of the jaw. Suppuration was then present, and with the finger a rough surface of apparently exposed bone could be felt, but this I regarded as the result of inflammatory action excited by the injudicious irritation of a periosteal growth, since partial necrosis of a jaw involved by cartilaginous or malignant growths, which have been irritated by exploratory measures, is in my experience by no means uncommon. The patient had the advantage of the opinion of Sir James Paget, who was not perfectly satisfied as to the existence of a tumour, and expressed a hope that the case might prove to be one of necrosis. Under these circumstances the operation was postponed.

On my return to town in September I found the patient improved in health and the swelling diminished by the subsidence of the inflammation, but a considerable enlargement of the lower jaw still present, with a sinus opening externally.



From the mouth a white mass was visible, which, appearing among granulations, looked like necrosis, and I agreed that an attempt should be made to remove this, although I could not think it accounted for the expansion of the jaw. On September 8, with the assistance of Dr. Snow, the patient was put under chloroform, and I proceeded to examine the mouth with my finger. I soon found that the white mass was not bone but tooth, and yet was unable to make out its outline. I was unable to make any impression with a chisel or gouge, but at last with an elevator succeeded in lifting out of its bed a mass of dental structures, forming the odontoma shown in figs. 103 and 104.

FIG. 103.

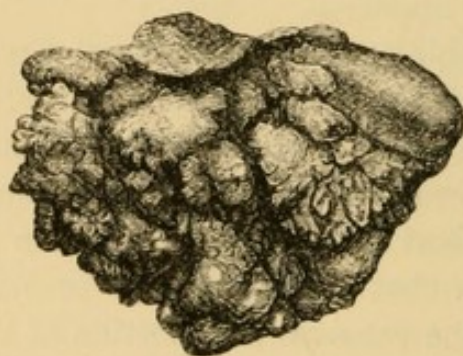
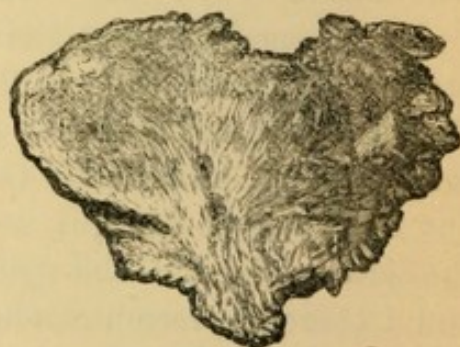


FIG. 104.



The mass measured  $1\frac{1}{2}$  inches antero-posteriorly, 1 inch transversely, and  $1\frac{1}{4}$  inches from above downwards. It weighed 315 grains = 3v. gr. xv.

A section of the odontoma has been made, and it has been submitted to Mr. Charles Tomes, who has kindly furnished the following report:—

“The whole surface of the odontoma is nodulated and roughened by stalactitic excrescences, and there is at no point any form recalling the character of a tooth crown.

“The surface of a section presents a complicated marbled pattern, due to the admixture of several dental tissues, and it bears a general resemblance to that form of dentine known as ‘plici-dentine,’ or ‘labyrintho-dentine.’ On the whole the mass is of tolerably uniform structure throughout, though there is an area of somewhat simpler structure in its upper



and central portion, from which folds of dentine appear to radiate. So far as it goes, this would seem to point to the whole mass being the product of a single tooth germ rather than of several fused together, a matter which was left in some doubt by the absence of an accurate history of the case.

"The excrescences of the surface, as well as the greater part of the interior, are made up of folds of dentine, in which dentinal tubes are very abundant, and which surround flattened remnants of pulp chambers; between and intimately blended with this comparatively well-formed dentine, is a more coarsely calcified material, containing numerous lacunæ, and permeated by vascular channels—in fact, osteo-dentine.

"Enamel is present upon some of the nodules of the surface, but it does not by any means form a complete investment; where present it dips in folds, following the convolutions of the dentine, and it is to be met with in the very centre of the mass, though not very abundantly. It is nowhere well formed, being brownish and opaque.

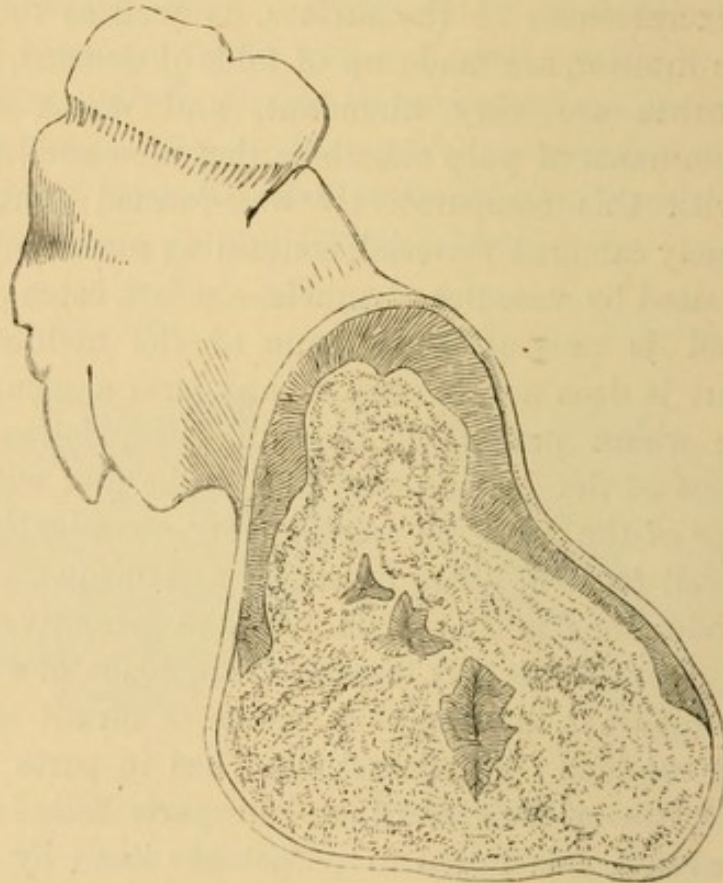
"This odontoma is the product of the formative dentine pulp of a tooth (or teeth) which has, in place of remaining simple, budded out innumerable processes on all sides, and finally has calcified; its enamel pulp has in parts followed the complexities of its surface, and in parts failed to do so, or, at all events, has failed to perpetuate itself by calcification."

Another form of tumour connected with a tooth consists in an outgrowth from a more or less perfect tooth, depending upon some modification of the dentinal pulp, after the formation of the dentinal cap. These growths belong to the *Odontomes coronaires* of Broca, and have been described as *warty teeth* by Salter. The smaller warty teeth have no special surgical interest, but occasionally the outgrowth takes place after the completion of the crown of the tooth, and is large enough to form a tumour requiring surgical interference. The rare examples of this form the class *Odontomes radiculaire*s of Broca. A remarkable specimen of the kind, in the Museum of the College of Surgeons of England



(2168), has been especially investigated by Mr. Salter (*Guy's Hospital Reports*, 1869), who believes that the outgrowth is due to "hypertrophy and dilatation of a fang, and not, as was formerly supposed, to hypertrophy of the cementum. Fig 105, from Mr. Salter's paper, illustrates the

FIG. 105.



structure of the tumour, and fig. 106 shows the relation of the growth to the tooth. The outer layer is composed of

FIG. 106.

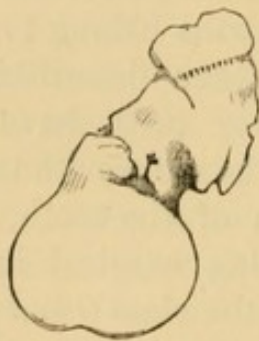
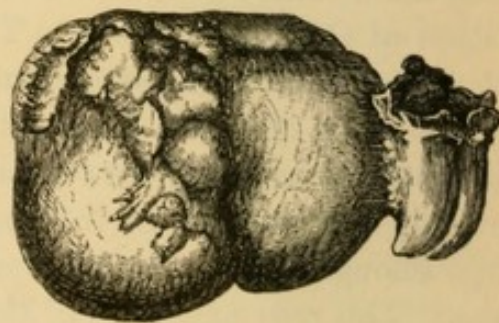

FIG. 107.



cementum, or tooth-bone, and within this is a layer of true dentine, which is wanting below ; and within this again is the



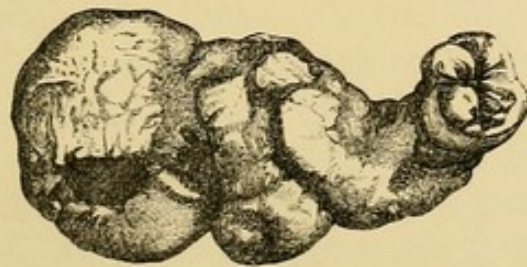
"nucleus" of calcified tooth-pulp. This last is "composed of a confused mass of bone-structure and dentine-structure, arranged around and separating an elaborate vascular network of the same character as that of the dentinal pulp."

Almost synchronously with, but independently of, Salter, Professors Heider and Wedl (*Atlas zur Pathologie der Zähne*) described a tooth-tumour resembling in many respects that at the College of Surgeons.

A still larger specimen in connection with the side of a molar tooth is given in fig. 107, from a case recorded by Dr. Forget (*op. cit.*). It occurred in the practice of M. Maisonneuve, and in the person of a man aged forty. The tumour occupied the left side of the lower jaw, causing both its surfaces to project, but especially the outer. At the smaller end of the tumour was a decayed molar tooth, and upon extracting this the tumour came away with it. The growth, which was larger than a pigeon's egg, was attached to the tooth by a kind of pedicle, a section showing a line of separation between it and the root of the tooth. Under the microscope the specimen was seen to contain no dentine, but to consist exclusively of osseous tissue.

In April, 1863, Mr. Tomes exhibited to the Odontological Society an extraordinary specimen of so-called exostosis, shown in the illustration (fig. 108), which I have been per-

FIG. 108.



mitted to borrow from the *Transactions of the Odontological Society* (vol. iii.). The molar tooth, to which it is attached, was removed by Mr. Hare, of Limerick, from the upper jaw of a man aged forty-one, who had long suffered pain in the jaw, from which a fistulous passage led through the cheek. The growth is more or less hollowed out, and on this account



it has been suggested that it may possibly be an instance of calcified dental cyst. The specimen has, however, recently undergone careful microscopic examination by Mr. Charles Tomes, who found that it closely resembled Forget's specimen already described (fig. 107), of which a microscopic section is given by Broca. Mr. C. Tomes brought the preparation before the Odontological Society in January, 1872, and has shown that the outgrowth is not connected with the fangs of the tooth, but had sprung from the dentinal pulp. This latter he believes to have undergone partial destruction before becoming calcified, and hence the cavity formed in the tumour. (*Transactions of the Odontological Society of Great Britain*, Jan. 1872.) Whatever its nature, it must, from its size, have either invaded or obliterated the antrum.

It will be obvious, from a consideration of the preceding cases, that every effort should be made to extract an odontoma from the jaw without removing any portion of the bone itself. In the case recorded by Mr. Harrison, the tumour was enucleated spontaneously, in four cases it was removed without difficulty, and in two other cases its removal was readily effected after the containing portion of jaw had been excised. Where the growth is presumably connected with a tooth, the rule of removing all neighbouring teeth which may possibly be connected with it, should be invariably followed before any more serious operation is undertaken.



## CHAPTER XV.

## DISEASES OF THE GUMS.—EPULIS.

*Hypertrophy of the Gums* is a by no means common affection. Mr. Salter has recorded ("System of Surgery," ii.) a remarkable case which occurred in St. George's Hospital in 1859, in a girl of eight years, in whom there was precocious development of the teeth, accompanied by hypertrophy of the gums. A large, pink, smooth mass projected from the mouth, slightly corrugated or indistinctly lobed, which consisted of an expansion of the alveolus, immense hypertrophy of the fibrous gum, and an exuberant growth of the papillæ of the mucous membrane. Dr. Gross has narrated a very similar case in his "System of Surgery" (1862). In April, 1867, I had the opportunity of seeing a case of the kind, under the care of Mr. Erichsen, in University College Hospital. A child of two and a half years had hypertrophy of the gums, which were prolonged in front of and behind the teeth so as almost to conceal them. The disease affected only the incisive portions of both jaws, and it was remarkable that the temporary teeth had undergone hypertrophy also, being considerably larger than normal. The affection first showed itself at the age of seven months, when the teeth began to appear, the gums increasing in size and bleeding on the least touch. Mr. Erichsen removed the exuberant growth, extracting some of the teeth, and freely cauterized the cut surfaces. In Mr. Salter's case it was necessary to clip away portions of the alveolus as well. The excised portions in Mr. Erichsen's case were examined by the late Mr. A. Bruce, who gave the following report upon them:—"On section the mass was found to consist of a firm fibrous stroma, containing much



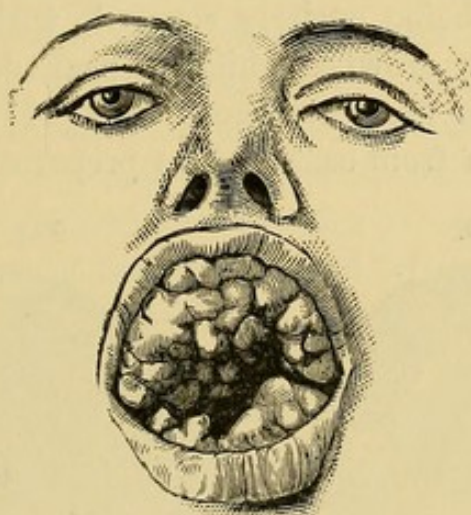glandular tissue in its interstices, and covered on its surface by very large and vascular papillæ. The epithelial layer was of unusual thickness, but no abnormal epithelial structures were found in the growth, which was an example of true hypertrophy." These characters agree closely with those observed by Mr. Salter, and it may be remarked that though in his case the temporary teeth do not appear to have been hypertrophied, yet that the permanent teeth exposed in the alveoli by the operation were excessively large, especially the superior central incisors. I am able now to supplement my report of Mr. Erichsen's patient operated upon in 1867 when  $2\frac{1}{2}$  years old, from the *Medico-Chirurgical Transactions*, vol. lvi., to which the late Dr. John Murray, of the Middlesex Hospital, contributed a paper "On three Peculiar Cases of Molluscum Fibrosum in Children of one Family." The eldest of these was Mr. Erichsen's patient, now seven years of age, and she presented peculiarities of the skin, subcutaneous connective tissue, periosteum and ends of the fingers and toes. Dr. Murray's description of the oral cavity is as follows :—"The appearance of the gums is very remarkable. They are everywhere greatly hypertrophied, and they almost completely bury the teeth. They form in parts numerous papillomatous or polypoid-looking growths, and in other situations present a peculiar fungating appearance, indeed this latter characteristic of the growth is at once observed. The teeth, although almost buried by the hypertrophied gum, are still in every case visible, and are, in some measure, serviceable for the purposes of mastication. The enlargement of the gums is most marked at their upper and free surface, where they are mostly flattened out and in parts hardened by the pressure of the opposing gum. They present the natural colour, and although they are in parts somewhat soft, vascular, and spongy-looking, they mostly feel firm and fibrous to the touch, the disease being distinctly limited to the gums."

The patient's brother, aged four, in whom the growth was first observed when he was three months old, and her sister, aged two, have a similar condition of the gums.



It is remarkable that in all cases recorded there was a defective mental condition, and the hypertrophy of the gums had been noticed quite early in life, and seemed to have been general, affecting equally both jaws, and the whole extent of the alveolar arch. A case of hypertrophy of the gums, in a woman aged twenty-seven, was published by Dr. Waterman, of Boston (*Boston Medical and Surgical Journal*, April 8, 1869); but the most remarkable instance of the disease on record, also occurring in the adult, is given in the *Australian Medical Journal*, for August, 1871, by Mr. MacGillivray, surgeon to the Bendigo Hospital, to whom I am indebted for photographs of the patient (fig. 109). The

FIG. 109.



patient, a woman aged twenty-nine, seemed to have suffered from the affection in both jaws at or soon after birth. At the age of ten portions of the gum were cut away, and several teeth extracted, and she had herself in later life cut off portions of the projecting gum with a razor. All these operations gave rise to severe hæmorrhage. The enormous growth shown in the drawing seemed to have originated mainly from the palatal portion of the gums, the labial surface being comparatively sound. Mr. MacGillivray removed the hypertrophied gums and alveoli with perfect success.

In December, 1878, I brought before the Odontological



Society of Great Britain two cases of hypertrophy of the gums which I had treated successfully by operation, one in a child, and the other in an adult.

The first case was that of Amy B., æt. four years and a half, who was admitted into University College Hospital, May 6, 1878. She is one of five children; the other four are healthy. Two years ago the swelling of the gums began by the side of the temporary molars, which were just coming through, and from them the swelling has spread right round the jaw. At this time she had fits about once a week; the fits have continued up to the present time, but with longer intervals. They appear to be epileptic.

The patient is a very tractable child; her general health appears to be good. The gums are enormously hypertrophied, the teeth being entirely covered, with the exception of the tips of the crowns, which appear depressed in the gums. The lower gums are shown in fig. 110, and the upper in fig. 111, taken from casts. The preparation is in Univer-

FIG. 110.

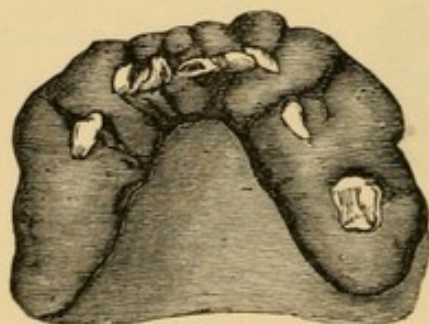
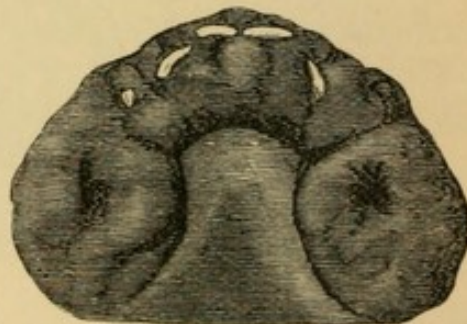


FIG. 111.



sity College Museum (1010 A). The hypertrophy of the gums is so great that the cheeks are bulged out on each side, and the cavity of the mouth is almost filled with them. The teeth are irregular and slightly carious. The child is always biting and putting cold things in her mouth. She can bite nothing hard, and has been fed entirely on liquid or pulpy food. Her breath is very offensive.

On May 9, under chloroform, I removed the hypertrophied gums and the alveolar margin of the lower jaw in two pieces. On one side the first permanent molar came away; on the other side it was left, not being quite erupted.



Hæmorrhage, which was free, was stopped with the actual cautery.

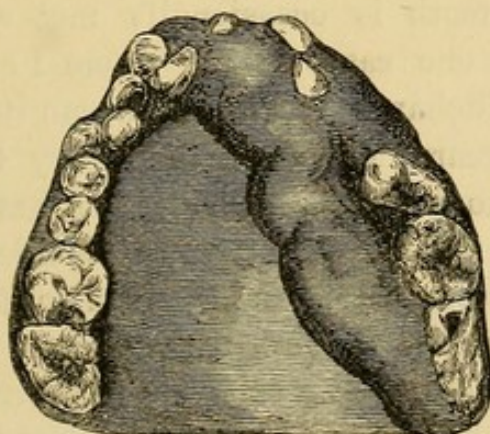On May 23, under chloroform, I detached the hypertrophied gums and alveolar border of the upper jaw in one semi-circular piece. Roots of the permanent teeth left.

On June 3 the patient was discharged well.

A microscopic examination by Mr. Charles Tomes, showed that the structure of the growth closely resembled that of the small polypi which are sometimes found occupying the cavity of carious teeth: it was a true hypertrophy of the gum, and chiefly of the fibrous portion. It sprang from the periosteum round the neck of the teeth, just within the margin of the alveoli. From this point a dense stroma of interlacing fibres, covered by a thin mucous and epithelial layer, grew up round the tooth, the growths from opposite sides meeting over it and coalescing, so as almost to cover it. The attachment within the socket was important, for this explained how it was that a successful result could not be obtained without removing part of the alveolus. Unless this was done, the base of the growth was left behind, and recurrence soon took place.

The second patient, Mr. L., æt twenty-six, came under my care in June, 1877, with hypertrophy of the gum and alveoli

FIG. 112.



of the right side of the lower jaw, extending from the right wisdom-tooth to the left canine. The affection had been noticed from early childhood, and gave no pain. The condition of the gum is seen in fig. 112.



On June 19, the patient being under chloroform, I removed the affected alveolus with Liston's powerful cross-cutting forceps. The wisdom-tooth was left, but the other teeth were necessarily sacrificed up to the left canine. The hæmorrhage was free, but was controlled with the actual cautery freely applied, and the patient made a good recovery in a fortnight. Mr. Ibbetson subsequently fitted some artificial teeth; the patient is now in much greater comfort than before.

The growth is fibrous in structure, and is an example of pure hypertrophy. The preparation is in University College Museum (1010).

In conclusion, I would say that nothing less than complete removal of the affected alveolus seems to offer any hope of alleviating these cases. Mr. Erichsen in 1867 thoroughly pared off the exuberant growth of the girl Ellen S., but in 1872 there was complete reproduction of the disease. In the child operated upon by me, the condition of the gums was such as mechanically to interfere with taking food, so that there was no hesitation in sacrificing the temporary teeth; and it may be hoped that many of the permanent teeth escaped injury, and may be erupted in due course.

Hypertrophy of the gums from the irritation of badly fitting artificial teeth is occasionally met with in elderly patients, and in one case, a lady whom I saw in consultation with Mr. Richardson, and in whom the disease had existed for ten years, I found it necessary to remove with Paquelin's thermo-cautery a considerable amount of tissue, before it became possible to have fresh artificial teeth fitted.

*Polypus of the gum* is the name given to a simple hypertrophy of the portion of gum between two teeth, which is ordinarily dependent upon the irritation caused by those organs, and may be sessile or pedunculated. It is often connected with accumulations of tartar around the necks of the teeth, and with a generally unhealthy condition of the mouth, and if cut away with scissors and freely cauterized with the nitrate of silver, or better, Paquelin's



thermo-cautery, does not recur. In one case of large polypus over a central incisor which had been pivoted, and was doubtless a source of irritation, I thought it safer to remove a small piece of alveolus with the bone-forceps after extraction of the tooth, but this is exceptional. Mr. Salter describes a condylomatous form of disease of the gum which is of a syphilitic character.

*Vascular growths* are occasionally met with in connection with the gum, and especially in the region of the incisor teeth. These bleed freely when rubbed with the tooth-brush, and may, if neglected, grow to some size, resembling a naevus in their colour and appearance. Stanley, in his work "On Diseases of the Bones," has narrated and drawn a case in which there was a vascular growth in the region usually occupied by these growths, but in that instance the tumour sprang from the interior of the jaw and necessitated removal of a portion of it.

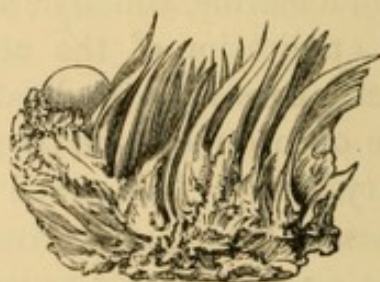
Mr. Tomes has successfully treated the three or four examples of the disease he has met with, by the frequent application of powdered tannin. Mr. Salter narrates in the "System of Surgery," a case in which hæmorrhage arose from a growth of the size of a marble, which he successfully treated by excision and the application of the actual cautery, after having failed to effect a cure with the ligature. I have also met with an example of pedunculated tumour of the gum in a woman aged twenty-five; it bled when touched, and the pedicle apparently passed through the alveolus. I removed it in June, 1869, by tearing through the pedicle with the finger nail, and applied the actual cautery to the spot from which it grew, which bled freely. I have twice met with a very vascular and hypertrophied condition of the gums in patients the subjects of "port-wine stain" of the face. In a young married woman of twenty-four, the gums of both jaws on one side were affected, and became more developed and vascular during each pregnancy, so that she lost a good deal of blood. I twice removed the growth, arresting the hæmorrhage, which was not severe, with the actual cautery. In the other case, of a young lady of seventeen, the lip



and upper gum were affected, and I was able to bring about a cure by drilling with a sharp-pointed cautery.

*Papilloma of the Gum.*—Mr. Salter has, in the *Guy's Hospital Reports* (1866), called attention to a rare form of disease in connection with the jaws, which appears to consist essentially in a hypertrophy of the papillæ of the mucous membrane. The disease was first noticed by Sir William Fergusson, in the lower jaw of an old man of eighty, and “looked like vegetable matter, or greatly elongated papillæ,” as described in some clinical observations on the case by that surgeon in the *Lancet*, September 6, 1862. It was removed by Sir William Fergusson, and is described by Mr. Salter as “a curious white mass, consisting of coarse detached fibres, pointed and free at one extremity, and attached at the other; in fact it was a mass of papillæ, many of them nearly an inch long, and similar in shape to the ‘filiform’ papillæ of the tongue; their surface was shreddy and broken; among these elongated processes were a few rounded eminences like ‘fungiform’ papillæ, and these had a smooth unbroken surface.” The accompanying drawing (fig. 113) for which, as well as for

FIG. 113.



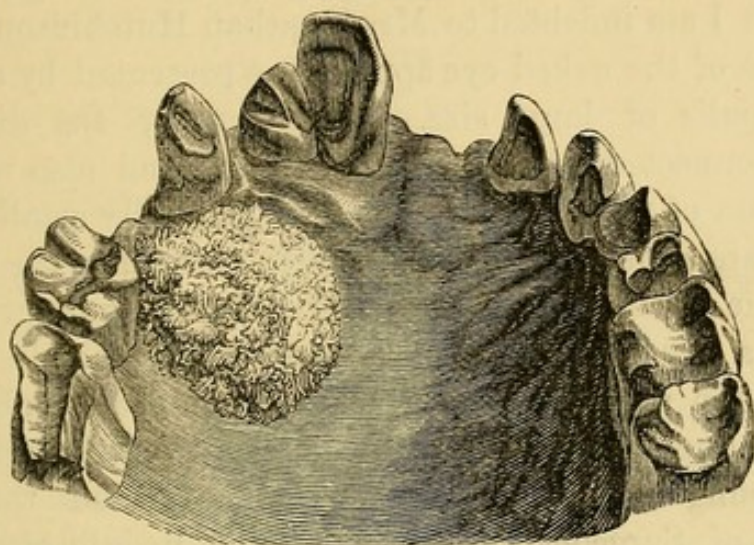
those that follow, I am indebted to Mr. Salter, represents a portion of the tumour of the natural size. Microscopically the mass consisted almost entirely of epithelium.

Mr. Salter met with a second case in the practice of Mr. Cock, at Guy's Hospital. It consisted in a growth of the size of a split chestnut attached to the hard palate of the right side, and extended from the edge to near the median line, as seen in fig. 114, and had been growing about eight months. Mr. Cock extirpated the growth, which consisted of a hard mass of fibrous tissue, surmounted by papillæ,



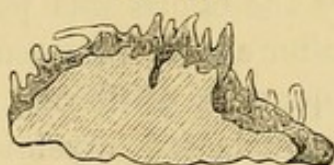mainly composed of dense coherent epithelium; and met with considerable difficulty in arresting the free hæmorrhage which ensued. Fig. 115 represents a section of the growth

FIG. 114.



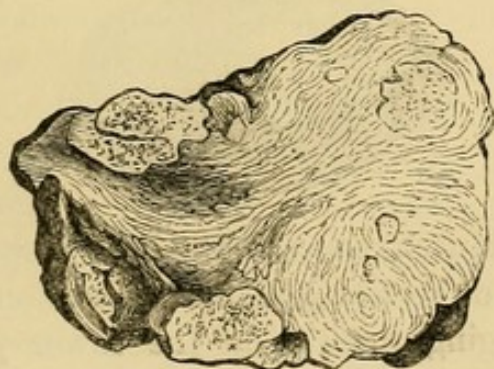
of the natural size. The growth recurred after some time, and took a malignant form, which proved fatal.

FIG. 115.



*Epulis.*—The growths connected more or less closely with the gums vary somewhat in their nature, but are

FIG. 116.



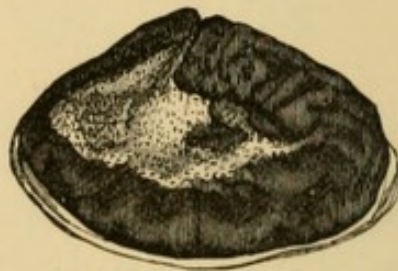conveniently classed together under the term epulis. The ordinary form of the disease is a firm fibrous tumour, of



slow growth, in which, in many instances, some fibroplastic cells are intermingled. Hence modern pathologists regard epulides as examples of ossifying sarcomata (Cornil and Ranvier). The accompanying drawing (fig. 116), for which I am indebted to Mr. Jonathan Hutchinson, gives a good idea of the naked-eye appearance presented by a section of an epulis of large size. This form of the disease is closely connected with the fibrous gum, and also with the periosteum of the alveolus, and very generally small spicula of bone are prolonged into it from the maxilla; the mucous membrane of the gum is stretched over the growth. Occasionally a development of true bone takes place in distant parts of the growth, as in the specimen drawn above; so also in a large epulis which I removed from the upper jaw of a young woman, and which accompanied this essay (College of Surgeons' Museum, 2191), a nodule of bone of considerable size is developed near the surface of the growth and quite unconnected with the alveolus. Mr. Cæsar Hawkins mentions (*Medical Gazette*, 1846) a similar occurrence in a case where the epulis was pedunculated.

The myeloid, or softer and more vascular form of epulis, is composed of a small quantity of fibrous tissue, holding in its meshes the true polynucleated myeloid cells, or "myeloplaxies." The drawing from which fig. 117 was taken (also

FIG. 117.



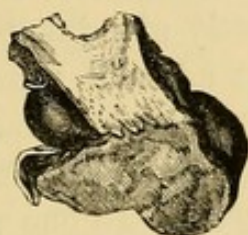given me by Mr. Hutchinson), showed the vascular appearance of such a tumour on section, the one in question having formed a large overhanging mass upon the lower jaw, which was excised by Mr. Curling in 1864.

In fig. 118 is seen a section of a well marked myeloid epulis, removed by Mr. Wilkes, of Salisbury (College of Surgeons'



Museum, 2192). The tumour consists of a semi-globular firm elastic mass attached by its base to the margin of the alveolus, from within which it springs. Its surface is smooth and uniform, and of a dark grey colour, mottled with purplish

FIG. 118.



spots. On section it can be traced into the bone, the cut surface being for the most part of a greyish yellow, with patches of pink and purple. The microscopical examination shows interspersed among the fine fibrous tissue some large irregular disc-like cells, containing numerous bead-like nuclei, and the growth may therefore be considered similar to that described by Otto Weber, as "giant-celled sarcoma."

This form of epulis is more commonly connected with the interior of the alveolus than the fibrous variety; and this fact may possibly account for its being more closely allied to the endosteal than the periosteal structures. In fact, many of the so-called myeloid epulides are really only out-growths from myeloid tumours of the interior of the jaw, and hence their great tendency to recur if insufficiently removed. It is this form which, when irritated and ulcerated, presents an appearance somewhat resembling malignant disease. Irregular nodules of bone may be scattered through the myeloid as through the fibrous variety, and the occasional occurrence of a cyst in connection with an epulis must not be overlooked. I have recently had a case of the kind under my care, in which the presence of a cyst by the side of a fibrous epulis gave a formidable appearance to a simple disease.

A form of epulis possessing some of the characters of epithelioma is occasionally met with. A specimen which was sent to me in a perfectly fresh state by Mr. Hutchinson, who had removed it from the lower jaw of a lady aged fifty-

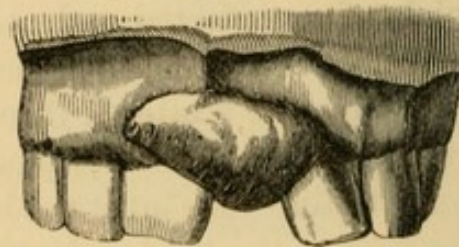


five, where it had been growing a year, was examined by the late Mr. Bruce with the following report:—"The surface of the tumour is covered with healthy mucous membrane. The interior of the tumour is whiter, firmer, and more compact than the surface; but there is no line of demarcation between the tumour and its mucous covering. The structure of the growth is distinctly glandular, very much resembling some forms of compact adenoid tumour of the breast. At the point of attachment of the tumour to the parts beneath, a remarkable transformation of the glandular into the epitheliomatous structure is seen. In one part of the section may be seen the cut ends of gland tubules, whilst in their immediate neighbourhood are most distinct nests of true epithelioma, consisting evidently of concentrically arranged cells compressed from the centre outwards."

Mr. Eve has also placed in the Museum of the College of Surgeons an epulis (2193 A) which microscopically had the character of an epithelioma, but contained no "cell-nests."

Epulis appears to be generally connected with the presence of teeth, and in some cases to depend upon the irritation caused by them; but I have once seen a small fibrous epulis in a newly-born child. The simplest form is often found growing between two perfectly sound teeth, which become widely separated, as seen in the illustration (fig. 119), taken from a

FIG. 119.



patient of Dr. Langston, in whom I was obliged to sacrifice the central incisors in order to remove the growth; in some instances the pedicle attaching the growth may be so slender as to be broken by the tongue of the patient or the finger of the surgeon, of which Sir William Fergusson gives examples. The teeth may be unsound and broken, and in these cases



*Tabular Statement of Twenty-eight Cases of Epulis.*

| No. | Sex | Age | Duration.  | Position. | Result.    | Remarks.   |
|-----|-----|-----|------------|-----------|------------|--|
| 1   | F.  | 35  | ...        | Upper.    | Recovered. | Rigors followed the operation, and death from pyæmia on the 15th day.                        |
| 2   | M.  | 39  | 15 months. | ...       | Recovered. |  |
| 3   | F.  | 60  | 7 months.  | Upper.    | Recovered. |  |
| 4   | F.  | 50  | 3 months.  | Upper.    | Died.      |  |
| 5   | M.  | 16  | 3 years.   | Lower.    | Recovered. | Very large indeed. It had returned after removal 8 years before.                             |
| 6   | F.  | 60  | 20 years.  | Upper.    | Recovered. |  |
| 7   | F.  | 26  | 9 months.  | Lower.    | Recovered. | Large, ragged, and fungating. It was fibro-cartilaginous.                                    |
| 8   | M.  | 36  | ...        | Upper.    | Recovered. | It was thought after removal to be of cancerous nature.                                      |
| 9   | M.  | 27  | 7 years.   | Upper.    | Recovered. | The tumour was thought to be cancerous after removal.  |
| 10  | F.  | 28  | 6 years.   | Lower.    | Recovered. | The tumour consisted of hardish bone, and had encapsuled completely the stumps of two teeth. |
| 11  | F.  | 11  | ...        | Lower.    | Recovered. | Caused by a decayed tooth.   |
| 12  | F.  | 36  | 18 months. | Lower.    | Recovered. |  |
| 13  | M.  | 24  | ...        | ...       | Recovered. |  |
| 14  | F.  | 30  | ...        | Upper.    | Recovered. | Two bicuspid teeth were buried in it. It was of myeloid structure.                           |
| 15  | F.  | 23  | 14 months. | Lower.    | Recovered. |  |
| 16  | F.  | 22  | 2 years.   | ...       | Recovered. | It involved two teeth.   |
| 17  | M.  | 16  | 1 year.    | Lower.    | Recovered. | It involved the last bicuspid and first molar.   |
| 18  | F.  | 31  | ...        | Lower.    | Recovered. | The tumour was soft and fungoid.   |
| 19  | F.  | 30  | ...        | Lower.    | Recovered. | It was ulcerated, and considered to be malignant. As large as a walnut.                      |
| 20  | M.  | 9   | ...        | ...       | Recovered. |  |
| 21  | F.  | 22  | ...        | Lower.    | Recovered. |  |
| 22  | M.  | 40  | ...        | ...       | Recovered. |  |
| 23  | M.  | 40  | ...        | ...       | Recovered. |  |
| 24  | M.  | 10  | ...        | Lower.    | Recovered. | The bleeding which followed required the actual cautery for its arrest.                      |
| 25  | M.  | 51  | ...        | Upper.    | Recovered. |  |
| 26  | F.  | 47  | 5 months.  | Upper.    | Recovered. |  |
| 27  | F.  | 24  | ...        | Lower.    | Recovered. |  |
| 28  | F.  | 73  | ...        | ...       | Recovered. | The tumour was pedunculated, and was removed by ligature.                                    |



the growth often completely envelops the stumps and hides them from view, or in the progress of the growth a fang of a tooth may be pushed forward, and be eventually found imbedded in its centre, as narrated by Mr. Tomes.

The accompanying statistics respecting epulis (p. 239), founded upon twenty-eight cases observed in the London Hospitals, are taken from the *Medical Times and Gazette*, Sept. 3, 1859.

“Of these twenty-eight cases in which tumours growing from the gum were of the character usually designated as ‘Epulis,’ we may make the following summary:—In but one instance did the operation cause the death of the patient, whilst in all the others the parts implicated are stated to have healed soundly. It would appear that the female sex is more liable to this disease than males, in the proportion of five to three, the numbers in the list being seventeen females and eleven males. This may perhaps be explained by reference to the fact, that stumps of decayed teeth are by far the most frequent exciting causes of these growths. Now, women are, for several reasons, more likely to retain useless stumps of teeth than men. They are far more patient as regards severe, unavoidable pain, such as that of toothache, and at the same time much more afraid of surgical pain, as that of tooth extraction; besides, it must be remembered, that the conditions either of pregnancy or lactation prevent many women from having their decayed teeth taken out at the time when they ache.

“As it regards *age*, we find that the youngest patient was a boy of 9, and the next to him a girl of 11, whilst the oldest was a woman of 73, and the next to her another woman of 60. Five were under the age of 20; eight between those of 20 and 30; seven between 30 and 40; three between 40 and 50; two between 50 and 60; and three above 60. The average age of the whole number is 33.”

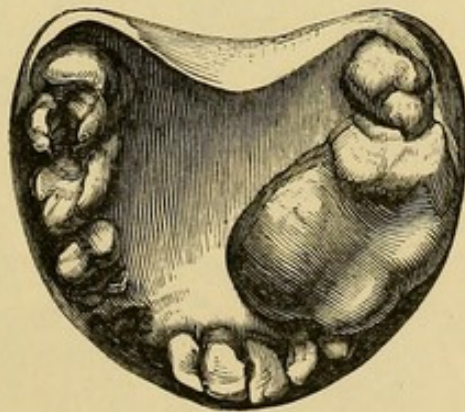
The two jaws appear to be equally liable to the disease, but its position and extent are subject to great variation. In the simplest form it may be connected with only the outer plate of the alveolus, or may be attached at a slight depth



within the socket of a tooth. In other instances it is attached solely to the posterior plate of the alveolus, and protrudes the teeth or appears behind them; in the more severe cases of myeloid disease it involves the whole thickness of the jaw, and either envelops or carries the teeth before it. Of this a case of Dr. Fleming's (*Dublin Quarterly Journal*, Feb. 1866), gives a good example at an unusually early age, the boy being between five and six, and the disease occurring between the first and second temporary molar teeth of the lower jaw, both of which were displaced and imbedded in the morbid growth.

When the tumour attains a moderate size, if it be on the upper surface of the alveolus it is apt to be pressed upon by the teeth of the opposite jaw, and this not only gives rise to pain and inconvenience, but causes also indentations and possibly ulcerations on its surface. Fig. 120 is reduced from a cast of the upper jaw of a young woman, a patient of Mr.

FIG. 120.



Warn, of the Highgate Road, from whom I removed a large epulis containing bone, which has been already referred to. The patient was twenty-seven years of age, and the growth had existed two years, and it will be seen that the surface is grooved and indented by the teeth of the lower jaw. In this case the fangs of the first and second molar teeth were found in the alveolus beneath the epulis.

A fibrous epulis, if allowed to grow to a large size, will produce external deformity of the face, and although attached to the upper jaw may hang down so as to simulate disease



of the lower jaw. This was well seen in a woman, aged twenty-seven, who had an epulis of the upper jaw of seven years' growth, which hung down to the level of the angle of the jaw, and who was under the care of Mr. Erichsen, by whom the tumour was removed in 1861, with perfect success. Perhaps the most remarkable case of epuloid growth on record, however, is Mr. Liston's well-known patient, Mary Griffiths, from whom, in October, 1836, he removed the growth shown in the accompanying drawing (fig. 121).

FIG. 121.



The case is reported at length in the *Lancet* of November 5, 1836, and is also referred to in Mr. Liston's "Practical Surgery," from which both the illustrations are taken. The following summary of it is from a note to Mr. Liston's paper on Tumours of the Jaw in the *Medico-Chirurgical Transactions*, vol. xx.

"The patient had laboured under the disease for eight years, and had been subjected to a partial removal of the growth when of inconsiderable size. The tumour was of the



same nature as those of the third and fourth cases related in the paper (*i.e.*, fibroid), as regards its disposition, form, and intimate structure. It differed somewhat, however, in outward appearance, in consequence of its exposed situation. The growth sprang originally from the gums and sockets of the incisors and canine tooth of the left side; at an early period it protruded from the mouth, unconfined and uninfluenced by the pressure of the lips or cheek. It had assumed a most formidable size and appearance, concealed the palate and pharynx, and gave rise to great inconvenience and continued suffering. The surface had been broken by ulceration, but upon a close inspection of the projecting part and of that covered by the cheek, it was found to possess a firm consistence, and to present the same peculiar botryoidal arrangement of its parts as the others of a simple and benign nature. The operation proved perfectly successful."

FIG. 122.



Fig. 122 shows the after-condition of the patient, the scars in the upper lip being the result of the previous unsuc-



cessful attempt to remove the disease. The preparation is in the Museum of the College of Surgeons (2193).

A case, very similar in many respects to the preceding one, was successfully operated upon in 1869 by Professor Kinloch, of Charleston. The patient was a negress aged twenty-five, and presented much the appearance shown in fig. 121, the mouth being enormously distended by a protruding growth, which appeared to have originated in the alveolus, but to have involved the superior maxilla. Dr. Kinloch removed the mass, which weighed nearly two pounds, and the patient made a good recovery.

*Treatment of Epulis.*—No treatment less radical than removal of the growth is of the slightest advantage. In the case of a small epulis growing between or close to the incisor teeth, after removal with the knife, an attempt may be made to check the reproduction of the disease by the application of nitrate of silver, or a fine cautery, but usually without success. An epulis attached to the outer surface of the alveolus only, may be broken away with the nail, and the surface be thoroughly cauterized, but, as has been already said, the growth is connected with the periosteum, and will often be reproduced from it. It is essential then to remove the periosteum, and this may be done with a chisel or gouge, by which a small scale of the alveolus with its covering can be cut away. Those who object to such a proceeding may produce the same result by the application of such a powerful caustic—either potassa fusa, nitric acid, or the hot iron—as shall destroy the surface of the bone and cause its exfoliation, but with some tediousness and inconvenience to the patient. In cases of large fibrous epulis, a tooth must be extracted on each side, and the whole thickness of the alveolus cut away with bone forceps, of which Liston's cross-cutting forceps, shown in figs. 123 and 124, are very serviceable; the straight ones for the incisor, and the angular for the molar region. The same radical treatment will be advisable when the disease springs from the posterior plate, and in all these cases I make an invariable practice of applying the actual cautery to the surface of bone exposed by the operation, which has



the advantage of stopping hæmorrhage, and of causing the exfoliation of any diseased portions of bone which may have been left. In all operations of the kind, any roots of decayed teeth which may be discovered at the time of the operation should be extracted with the forceps or elevator, and the surface of the bone rendered as smooth as may be.

FIG. 123.

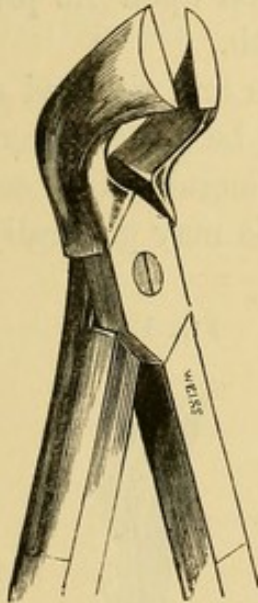
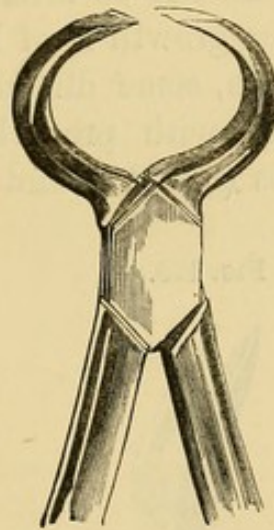


FIG. 124.



When the epulis is connected with the lining membrane of the socket of a tooth, and dips down into the interior of the jaw, it is probably myeloid, and no superficial operation can effect a cure, since it is in this class of cases that repeated reproductions are met with. The neighbouring teeth, although sound, must generally be sacrificed, and the alveolus be thoroughly cleared out with the gouge, so that nothing but the shell of compact bone is left. The hæmorrhage is usually free, and is best controlled by stuffing the cavity with lint. In 1875 I saw a young gentleman, aged nineteen, with Mr. Braine, in whose lower jaw there was a small myeloid growth, which I freely removed. Recurrence took place, however, and I operated a second time, clearing out the alveolus very thoroughly, but fortunately being able to preserve the teeth, and the patient is now quite well, eight years afterwards.

When the epulis is very extensive, it may be conveniently removed with the alveolus to which it is attached, by making



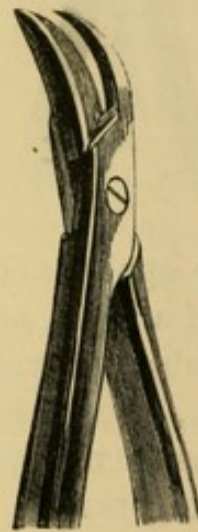
a vertical incision with a small saw at each extremity of the disease, and then connecting the cuts by a horizontal one with cross-cutting bone forceps. Under no circumstances, except when the growth is of a malignant character, can it be necessary, I believe, to cut through the whole thickness of the lower jaw, since it has been shown repeatedly that common epulis never involves the base of the bone, and the contour of the face depends so much upon its preservation, that it should not be interfered with.

When the growth is of large size and situated at the side of the mouth, some difficulty may be experienced in extirpating it, but with properly made angular and semicircular bone-forceps (figs. 125 and 126) this may generally be over-

FIG. 125.

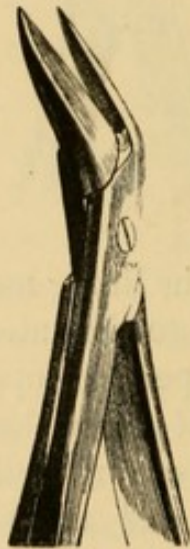

FIG. 126.



come. It may be necessary, however, to incise the face, and if so, the suggestion and practice of Sir William Fergusson ("Lectures on Progress of Surgery," p. 239) cannot be too strictly followed—viz., to restrict the incision to the middle line of the lip, which will ordinarily give abundance of room; or, if not, to carry it into the nostril of the affected side, by the stretching of which so much additional room will be gained as to render any incision at the angle of the mouth perfectly unnecessary. When this limited incision is adhered to, the scar is so slight as to be imperceptible



except upon the closest investigation. In instances of such enormous growths as in the case of Mary Anne Griffiths, more extensive incisions, resembling those for excision of the jaw, would be required; but such cases are now-a-days few and far between. Mr. Liston considered it necessary to remove the left and a portion of the right maxilla, but subsequent examination showed that these bones, though overlain by the disease, were not implicated in it except at their alveolar borders.



## CHAPTER XVI.

## TUMOURS OF THE PALATE.

*Tumours of the Hard Palate* are for the most part closely allied to epulis, and may therefore be conveniently considered here. A case of papilloma of the hard palate has been already described under the section of Papilloma of the Gum. In the Museum of St. Bartholomew's Hospital is a preparation (XII. 1800), to which the following description is appended—"An elongated oval tumour removed from the palate, to which it appears to have been attached by a broad base. It is composed of a firm, very closely-textured, obscurely-fibrous substance, with interspersed specks of bone, like the epulis which more commonly grows from the gums."

Of this same character was a tumour of the hard palate removed by Mr. Keate, which Mr. Cæsar Hawkins speaks of as essentially the same as epulis. Mr. Syme also narrates a case (*British Medical Journal*, April 19, 1862) occurring in a woman aged forty-six, which had been growing two years, was of a circular form, and "presented a convex surface extending from side to side and stretching from the anterior third of the palate to the posterior edge of its hard portion." The growth was soft at its centre, but hard at the base and evidently connected with the bone. Unfortunately no more detailed account of the structure of the growth is given in the lecture in question.

Tumours of the palate of a softer consistence have been met with, however; thus in St. Bartholomew's Museum (XII. 1799) are sections of a tumour removed from the palate, to which it was attached by a base of much less



extent than its circumference. Its surface is covered by thick, but apparently healthy, mucous membrane, and its interior is lobulated.

Encysted tumours of the palate have also occurred; thus Dr. Cabot showed to the Boston Society for Medical Improvement a small round tumour, which he had removed from the roof of the mouth of a soldier. It had existed for eighteen months, and was situated on the posterior and left part of the hard palate, extending as far as, but not involving, the gum. Although the patient had suffered severe pain in the left side of the face and temple of a neuralgic character, yet he was not sure that it had its origin in the tumour. It was somewhat tender on pressure, but not painful. The capsule which contained it being incised, it was easily shelled out. It was two-thirds of an inch in diameter, of a yellowish-white colour, and mostly smooth; but in one part it had a warty appearance.

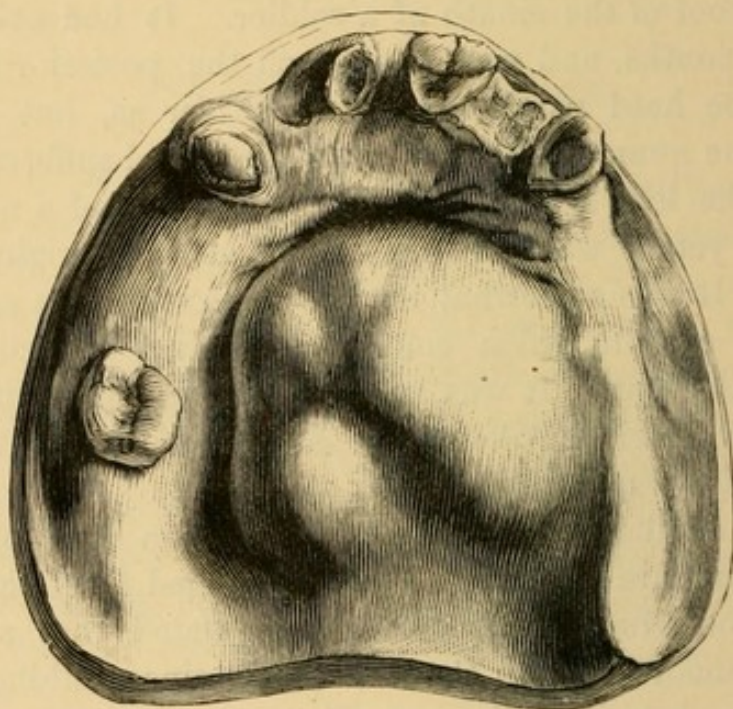
A very similar case was under my care in 1876, of which the following are the details:—S. E—, aged forty-eight, was admitted on August 29, 1876. She stated that she had noticed a small lump on the hard palate since childhood, but it gave her no inconvenience until about two years ago, when it began to enlarge, and from this time it steadily grew, and soon began to interfere with her articulation. Her health had, however, always been good. There was no history of tumour in the family. The tumour filled up the hollow in the hard palate, being more attached to the left side, where the mucous membrane was continued directly over it, than on the right, where a probe could be passed between the tumour and the palate. It was about the size of a horse-chestnut, slightly lobed on the surface, elastic, but not fluctuating; the mucous membrane over it was not adherent to it, and was normal in appearance. The tumour moved slightly over the bone. There were no enlarged lymphatic glands in the neck. The accompanying woodcut (fig. 127) was made from a plaster cast taken by a dentist.

I removed the tumour by making an incision round the left side of the growth, which then readily shelled out from



a distinct capsule ; the capsule itself was afterwards removed with the fingers. Bleeding was stopped by the actual cautery. The wound granulated, but left a part of the hard palate bare. A small portion of this was loose when the

FIG. 127.



patient left the hospital, and she stated that when she drank fluid came into the left nostril.

The tumour was examined microscopically, and found to be a small round-celled sarcoma.

A very similar tumour, removed by Sir W. Fergusson, is preserved in the Museum of the College of Surgeons (2284), being a round-celled sarcoma, half an inch in diameter, removed from a woman of thirty-five, in whom it had been growing four years.

In the same Museum (2284 A) is a carcinomatous tumour, one inch in diameter, consisting of septa bounding alveoli, which contain collections of epithelial cells, removed by Mr. Bryant ; and in the Museum of King's College is a specimen of the kind, in which the greater part of the right side of the hard palate is involved in a soft tumour, the surface of which is very irregular and broken down, whilst the soft palate



appears to be free from disease. This was removed from the body after death, and no history is appended to it.

A case of epithelial tumour of the palate in a young woman, aged sixteen, occurred in the London Hospital in 1856, under the care of Mr. Curling, who successfully removed the growth with a large portion of the jaw ; the case will be found in the *Lancet*, July 26, 1856.

Sir Andrew Clark's report of the tumour is as follows :—  
“ The tumour is about the size and of the shape of a hen's egg. It is invested by a condensed layer of areolar tissue, and loosely connected with the periosteum of the adjacent bones. At one point—the posterior and inferior edge of the zygomatic surface of the superior maxillary bone—it had a limited but distinct osseous attachment. The tumour therefore might have been shelled out at all points but this. The tumour lies between the naso-palatine portion of the right maxilla and the mucous membrane. The mucous membrane over the tumour is hypertrophied, and exhibits an oval ulcer with thick, rounded, white margins, and a reddish, smooth base. The naso-palatine part of the superior maxilla is elevated and thinned ; the periosteum is loosely attached to it, and at one point the bone is a little ‘ opened up ’ in texture. The tumour is soft, slightly elastic, and vascular. The cut surface is of a dead-white colour, distinctly granular, like rough honey, crumbly-looking, and studded with red or pink blotched parts sunk below the general level. On further examination it appears to be permeated by a kind of glairy substance (colloid matter), which helps seemingly to give coherence to the tumour. To the naked eye the tumour resembles, in some respects, a cephaloid or myeloid mass. To the latter it bears the greatest resemblance in general character, seat, and structure. The microscopic characters are those of epithelial cancer ; epithelial cells in all stages of development and of the most various forms, together with a few nest-cells and fat. The mucous membrane over the tumour, though not continuous with it, presents the same structural characters. This decides the doubt between epithelioma and myeloma.



The tumour has been wholly removed." (*Lancet*, July 26, 1856.)

But epitheliomatous ulceration of the hard palate is very often the result of extensive epithelioma of the antrum, the floor of which has become perforated, this being in some cases the first evidence of the disease. The consideration of these cases will be found in a subsequent chapter.

*Treatment.*—When the disease is of the epuloid character the treatment should be the same as for that disease—viz., complete removal and destruction of the periosteum, from which the growth springs. When the bone is implicated too deeply for the disease to be effectually removed with the gouge, the plan adopted by Mr. Syme in the case already referred to may be adopted. He removed the growth and the subjacent bone with a trephine large enough to embrace the whole tumour, leaving an aperture with healthy edges, which granulated and was much contracted when the patient was dismissed. When the disease is too extensive to be dealt with in this way, it will be necessary to remove a portion of the jaw, as in Mr. Curling's case. Under these circumstances the limited incision already insisted upon for cases of epulis should be had recourse to, and the jaw should be divided horizontally immediately above the palatine plate, so as to do as little damage as possible to the appearance of the face.

*Tumours of the Soft Palate* may be dermoid and congenital, as in a case shown at the Pathological Society in April, 1881, by Dr. Hale White, in which Mr. Marrant Baker removed the growth with a ligature; or may be papillomatous, as in the case of a healthy girl, aged eighteen, who came to the Dental Hospital, Leicester Square, to have some teeth stopped; on examining her mouth, Dr. Arkovy noticed a growth attached to the soft palate. It was pedunculated, hanging down beyond the margin of the left velum, and had a warty appearance; he snipped it off with scissors and rather free hæmorrhage followed.

The growth was about half an inch long by one-sixth of an inch broad, the pedicle being about one-eighth of an inch



thick; it was of the same colour as the surrounding mucous membrane, and the surface was composed of enlarged fungiform and filiform papillæ. On a longitudinal section it was seen to be composed of compound papillæ branching off from a common root or base, each offshoot being composed of dilated blood-vessels, surrounded by a very small amount of connective tissue, and enclosed by a thin layer of mucous membrane, on which were several layers of epithelium cells of the pavement variety.

In 1879, I had under my care a lady with a very suspicious tumour of the soft palate, which I feared would prove to be sarcomatous. On incising it, however, I was able to enucleate with the finger what proved to be an adenoma or hypertrophy of the glands of the soft palate, contained in a distinct cyst, which I was also able to withdraw. The patient has remained in perfect health to the present time.

In the following year I saw, with Sir J. Paget, a child aged seven, with a tumour presenting almost precisely similar appearances, but upon cutting into the growth it proved to be a sarcoma with extensive attachments which did not admit of removal. The growth steadily increased and destroyed life in six months.

Looking back at these two cases, I find it impossible to give any symptom by which they might have been distinguished; but the duration of the growth, if it can be accurately ascertained, would doubtless help at arriving at a just conclusion.

A case of medullary tumour of the soft palate in which the tumour was excised with temporary relief, is recorded by Mr. Langton in the *Clinical Society's Transactions*, vol. iii.



## CHAPTER XVII.

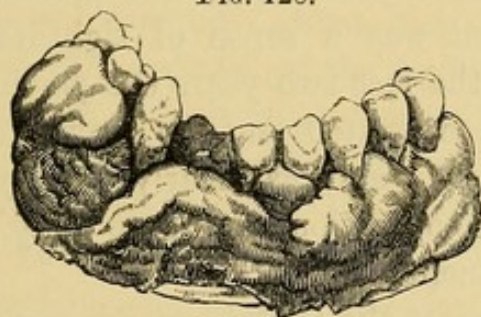
## EPITHELIOMA OF THE GUMS AND ANTRUM.

*Epithelioma* of the gums, as commonly met with, cannot properly be included among the epulides, since it is the exception for there to be any out-growth or tumour in the early stage of the disease. A ragged ulceration of the gum, supposed to be dependent upon some tooth, and probably the direct result of long-continued irritation, is noticed, but the pain is not marked and the inconvenience is slight. Careful observation will soon detect a tendency of the ulceration to spread both towards the tongue and the cheek, and by this time, probably, induration of the base of the ulcer may be detected where it touches the softer tissues. The importance of prompt and thorough interference cannot be too strongly impressed upon members of the dental profession, by whom cases of epithelioma are most generally seen in the early stage. In a recent case of ulceration of the gum, simple treatment may fairly be tried for a week or ten days, but if the ulcer still remains unhealed, and more particularly if it is increasing, surgical aid should at once be summoned. The frequent application of the solid nitrate of silver to an ulcer which fails to heal readily, is worse than useless. The treatment of an epitheliomatous ulcer consists in thoroughly destroying it, with the tissue around for some distance. In slight or doubtful cases thorough application of the strongest nitric acid, the acid nitrate of mercury, or better, the actual cautery, may be sufficient to ensure a healthy cicatrization; but even then the part will require careful watching, in order that any fresh development may be promptly attacked. Unfortunately the disease has,



in the majority of cases, already invaded the alveolus, as is shown by the swelling of the gum and the loosening of the teeth, and, when this is the case, free removal of the bone must be undertaken. A vertical cut with a narrow saw being made through the whole depth of the alveolus well beyond the disease, the cross-cutting bone-forceps may be used, or the saw applied horizontally to remove the diseased portion, as is shown in fig. 128, taken from Fergusson. The danger of course is that the disease may

FIG. 128.



have penetrated more deeply than appears into the bone, so that recurrence is apt to take place rapidly from the epitheliomatous elements left behind. Should this occur, there must be no hesitation in removing the whole thickness of the bone, and in the incisor region the resulting inconvenience is much less than might be anticipated, the muscles attached to the two halves of the jaw forcing them together, so that tough fibrous, if not bony, union takes place in the position of the original symphysis.

Some years ago a man was sent to me by Mr. Harding with an undoubtedly epitheliomatous growth springing from the gum in the incisor region. This I removed by sawing the lower jaw horizontally below the level of the alveolus, but, the section not proving quite healthy in appearance, I thought it advisable to take away the whole thickness of the jaw in this region. The patient made a good recovery, with firm union between the two segments of the jaw, and I have not heard of any further recurrence.

An equally satisfactory case has come under my frequent



observation during the last three years, in the person of a retired officer of the army, who in 1879, after wearing a lower dental plate for some years, developed epithelioma of the gums and cheek. Professor Bowen Partridge, of Calcutta, removed the left half of the body of the jaw in December, 1879, and recurrence taking place at the chin, Dr. McLeod removed the right half in March, 1880, with the submaxillary glands of both sides. I first saw this gentleman in July, 1881, when the central portion of the jaw was of course gone, and there was a space of  $1\frac{1}{2}$  inches between the halves of the bone. The tissues around were contracted, but perfectly healthy, and his only complaint was a sense of tightness and want of saliva. During the last two years the portions of jaw have become more approximated, and the growth of a beard hides the want of chin; and as nearly four years have now elapsed since the operation, the cure may, I presume, be considered permanent.

In the Museum of the College of Surgeons are two specimens (2249 & A) of epithelioma of the alveolus in which a less satisfactory result followed. The patient was a gentleman, aged fifty-four when he was sent to me by Mr. Weiss, with a well-marked epitheliomatous condition of the right lower alveolus, between the first molar and the canine teeth, which had been noticed six months. In addition, a well-marked ichthyotic condition of the mucous membrane of the floor of the mouth extended along the inner side of the body of the jaw and beneath the tongue. In September, 1880, I burnt away the whole of the affected mucous membrane with Paquelin's cautery, and having deeply notched the alveolus with the saw, I clipped out the affected portion with bone-forceps. Two months later the disease began to show itself on the inner side of the jaw, and in April, 1881, I removed the part affected very freely, cutting away the whole thickness of the bone from the second molar of the right to the second incisor of the left side, with the adjacent lymphatic gland, the section of bone being apparently healthy. Recurrence took place, however, shortly, and in November I removed a further portion of the left side of the



lower jaw up to the first molar tooth (College of Surgeons' Museum, 2249). Notwithstanding this complete removal of the disease, it returned in the soft parts beneath the tongue, large masses protruded into the mouth, and the patient sank in November, 1882.

Both in this and in other similar cases I have been disappointed with the operation of removing solely the alveolus, and am inclined to adopt more radical measures at first in future, being encouraged to do so both by the great success of the officer's case already mentioned, and by a case occurring in University College Hospital, the details of which will be found in the Appendix (Case X.).

*Epithelioma of the Antrum*, of the squamous variety, is a very insidious disease, which gives rise to the formation of no tumour of the face, but slowly destroys the antrum and spreads thence in all directions. It was first described, from the clinic of M. Verneuil, by M. Reclus ("Progrès Médical," 1876), who termed it very aptly *épithélioma térébrant* (boring or boring epithelioma), and attention was called to it by Mr. Butlin in 1881. I had at the time two cases of the kind under observation, one in hospital, which was at first thought to be epithelioma of the palate, but in which the antrum was found extensively affected, and the other in private, which was a good typical example of the disease. The patient, aged sixty-six, had a troublesome and loose upper molar tooth, for which he consulted a well-known dental surgeon in the West of England, who extracted it, bringing away a soft growth attached to the fangs. The opening was found to communicate with the antrum, and shortly a fungus growth protruded, and there was a good deal of discharge. The case was regarded as one of disease of the antrum, which was well syringed out, but the palate became more involved and the cheek somewhat swollen. When I saw the patient in September, 1881, a month after the extraction of the tooth, there could be no doubt of its serious nature. Under chloroform I was able to pass my finger through the fungus completely into the antrum, which was widely affected. Turning up the lip without incising



it, I was able with saw and bone-forceps to remove the floor of the antrum, which shows very well the disease (College of Surgeons' Museum, 2247). I then removed the back of the antrum, but the orbital plate being apparently healthy, I contented myself with scraping it freely and applying the chloride of zinc paste, the age of the patient forbidding removal of the whole upper jaw. Recurrence took place, and I again scraped away the growth and applied the zinc paste, but the disease again made progress, and the patient died, worn out, within a year of the first appearance of the disorder.

Mr. Butlin's case is very similar (*Pathological Society's Transactions*, 1881), and was that of a man aged sixty-two, who, after pain in the jaw, found a fistulous opening in the palate, from which a foul discharge proceeded. The finger was passed easily into the antrum, and the cavity was cleared out, and, upon recurrence taking place, the upper jaw was removed, but the patient sank on the fifth day. Mr. Butlin has recorded another case under Mr. M. Baker (*Path. Trans.*, 1882), in a woman of fifty-eight, with a bulging out of the right cheek and an opening from the palate into the antrum. The upper jaw was removed, but the disease was found to have already spread beyond it, and the patient died exhausted after a few days.

The disease appears so insidiously and spreads so rapidly to the deeper parts that its prompt recognition is of the greatest importance, and it may, I think, be held that the attachment of any growth to the fangs of extracted teeth should excite suspicion as to the presence of serious disease within the antrum. M. Reclus, in the paper referred to, goes so far as to suggest that the disease originates in one of the periosteal cysts of the fangs of the teeth already described, but it seems more probable that it starts from the socket of a tooth, and derives its squamous character from the palate.

The treatment is unsatisfactory, because the age of the patient forbids extensive operations, such as would be necessary for the removal of the upper jaw. In my own cases,



in which I was content to operate from the mouth, the patients survived for some months, whereas in the two cases recorded by Mr. Butlin, in which the jaw was removed, the patients rapidly sank.

Mr. G. Lawson has recorded (*Clinical Society's Transactions*, 1873) a case of this disease, in which he adopted a bolder, and apparently more successful treatment—viz., to destroy the skin over the growth and the disease itself with the actual cautery, and then to apply caustic paste freely so as to obtain large sloughs. The patient was sixty-five, and made a good, and it is believed, permanent recovery. Of course there is the permanent deformity to be considered, but, after all, this is a slight drawback if a cure can be obtained, and, as regards immediate danger to life, Mr. Lawson truly remarks, "it must be borne in mind that patients advanced in life stand cutting operations very badly, whilst they will bear, with but little shock, the destruction of large growths by escharotics."



## CHAPTER XVIII.

## NON-MALIGNANT TUMOURS OF THE UPPER JAW.

*Fibroma, Enchondroma, Osteoma.*

WITH regard to the statistics of tumours of the upper jaw, I shall content myself with quoting O. Weber, who has collected 307 cases from the following sources:—183 cases tabulated by Heyfelder; 36 recorded by Lücke from Langenbeck's clinique; 17 reported in the *Medical Times and Gazette* (Sept. 3, 1859); and 71 cases either observed by himself in Wutzer's clinique, or occurring in his own practice. Of the above cases there were:—

|                                   |       |
|-----------------------------------|-------|
| Osseous tumours . . . . .         | 32    |
| Vascular tumour . . . . .         | 1     |
| Fibrous tumours . . . . .         | 17    |
| Sarcomatous tumours . . . . .     | 84    |
| Enchondromatous tumours . . . . . | 8     |
| Cystic tumours . . . . .          | 20    |
| Mucous polypi . . . . .           | 7     |
| Carcinoma . . . . .               | 133   |
| Malanosis . . . . .               | 5     |
|                                   | <hr/> |
|                                   | 307   |

In commenting upon this table, Weber very justly remarks that doubtless the list of cancerous cases is exaggerated, and suggests that a fair estimate would be gained by allotting rather more than a third of the whole number to sarcomatous (simple) tumours; less than one-third to the cancerous; and the remainder to the osseous tumours, cysts, &c.



It must be borne in mind, however, that modern methods of investigation have shown that the old classifications are frequently based upon erroneous data, so that a re-arrangement of tumours of the jaws has become necessary, and will be attempted in the following pages.

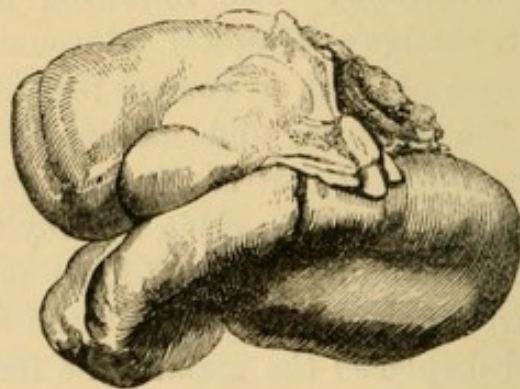
*Fibroma*.—This closely resembles the fibrous tumours found in other parts of the body, and especially in connection with the uterus. It is dense in structure but not unfrequently lobulated, and on section, slender bundles of intersecting fibres may occasionally be traced in them, of which there are good examples in the Museum of the College of Surgeons. The fibrous tumour usually springs from one of two situations, either the interior of the antrum or from some portion of the alveolus. In both cases it is intimately connected with the periosteum, in this respect resembling epulis. Occasionally the growth appears to follow some slight injury, as in the case of a lady, a patient of Dr. Neale, from whom, in 1870, I successfully removed a fibrous tumour occupying the interior of the antrum, which had followed a blow given by her child, and which may have been a fibrous odontoma (p. 267). The fibrous tumour grows slowly but surely, involving in its progress the surrounding structures. When arising in the antrum, it first expands the walls of that cavity, bulging out the face and forming tumours in the palate and floor of the orbit, and subsequently produces absorption of the osseous walls and spreads unchecked in all directions. The following description of a specimen in St. George's Hospital Museum gives a good idea of the ravages of such a tumour:—"Fibrous tumour growing from the antrum, and making its way by the absorption of the walls of that cavity in different directions. It projects upwards into the orbit, destroying the floor of that cavity, and protruding from its inner margin forwards on to the cheek. It has also destroyed the anterior wall of the antrum, and displaced the malar bone forward and outward; inwards it projects into the nose beneath the middle turbinated bone, and downwards it makes its appearance on the under surface of the alveolar process in the form of a



rounded mass, destroying the floor of the antrum in the neighbourhood of the front molar tooth. Behind, the tumour appears in the zygomatic fossa by the absorption of the outer part of the tuberosity of the superior maxillary bone. The tumour is composed of circular nuclei of various sizes, and spindle-shaped fibres. The patient from whom the specimen was taken, William H., died of arachnitis, and softening of the corresponding part of the brain."—*Catalogue of St. George's Hospital Museum* (II. 160).

When it arises from the alveolus, a fibrous tumour may encroach on both the facial and the palatine surfaces of the jaw, crushing in the antrum although not involving its interior. Of this a good example is seen in a preparation (2238) in the College of Surgeons, of an upper jaw removed by Mr. Liston. Here the tumour which is affixed to the alveolar border, near the molar teeth, extends inwards so as to cover the palatine portion of the jaw, and outwards so as to conceal all the bicuspid and molar teeth, with the exception of the last. The walls of the antrum are pressed inwards, but its interior is healthy. The patient was a woman, thirty years old, and the tumour was observed four years before its removal, which was successful. On the other hand, fibrous tumours, though commencing in the alveolus, may secondarily involve the antrum when they have attained considerable size, producing complete absorp-

FIG. 129.



tion of its walls, and projecting into the nose and through the palate. Of this a preparation in the College of Sur-



geons' Museum (2236), of an upper jaw, also removed by Mr. Liston, affords a good example. Here the patient was only twenty-one, and the growth first appeared on the outer side of the gum of the left upper jaw four years before the operation. It was cut off six months after its first appearance, but returned, and eighteen months after was removed, with a portion of the alveolar process, but reappeared in a few weeks. Fig. 129, from Liston's "Practical Surgery," shows the growth after its removal, and figs. 130 and 131 show the patient before and after the operation. It may be noticed here, as in the case of a large epulis, that disease of the upper jaw often closely resembles, externally, a tumour of the inferior maxilla.

FIG. 130.



FIG. 131.



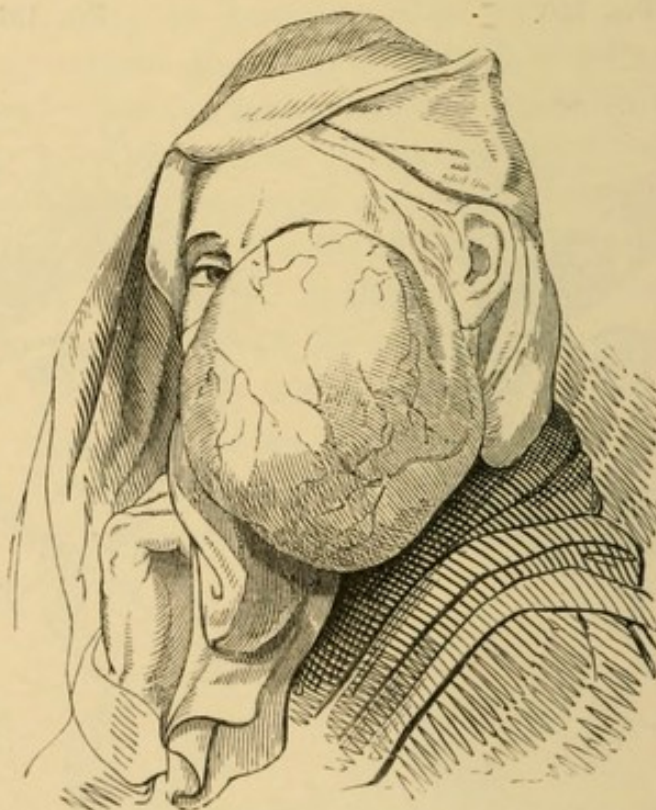The case is given by Mr. Liston in his paper on Tumours of the Jaw, in the *Medico-Chirurgical Transactions*, vol. xx.

The enormous size to which fibrous tumours of the upper jaw may grow without destroying the patient, is well seen in the accompanying drawing (fig. 132) of Mr. Liston's celebrated case of Mrs. Frazer, from whom that eminent surgeon successfully removed the growth. The tumour is



preserved in the Museum of the College of Surgeons (2241), and its diameters are, vertically, seven inches ; transversely, seven inches ; from before backwards, nearly six inches. Contrary to the ordinary practice, a portion of the integument was removed with the tumour, measuring twelve inches in length and ten in breadth, and this left a gap in the skin of the face upon the patient's recovery, a point which will be again referred to. The growth of this tumour was connected apparently in a curious way with the performance of the uterine functions. The patient was forty years old, and the tumour began to grow six years before its removal, in consequence of a blow in the region of the antrum. Its

FIG. 132.



progress at first was slow and not painful, but at the end of two years a distinct tumour was felt in the cheek. During the next two years it grew rapidly, especially during a period of gestation, but still without much pain. In the fifth year of its growth she bore a second child, after which the catamenia ceased to flow, and the tumour was subject to monthly augmentations of its vascularity, and slight hæmorrhages



occurred from its inner, though not ulcerated, surface, and from the adjacent parts of the gum. The case is given in detail in Mr. Liston's paper already referred to.

A remarkable feature, noticed in a case of fibrous tumour of the antrum, in a young man of eighteen, under the care of Sir J. Paget, in 1860, was a distinct pulsation in a portion of the tumour which projected into the orbit. The pulsation was slight but decided, and was synchronous with the radial pulse. The case was clearly not one of malignant disease, but proved to be an ordinary fibrous tumour upon removal. No satisfactory explanation seems possible of the case, which I believe to be unique. Suppuration has occurred in connection with fibrous tumours of the jaw, but only, I believe, when they have been punctured with a view to exploration and diagnosis. Of this the tumour removed from Janet Campbell and preserved in the Museum of the College of Surgeons (2239), is an example. Simple fibrous tumours occasionally recur after removal, but it is doubtful whether in these cases the whole of the disease has been eradicated. According to O. Weber they are usually connected with the lining of the Haversian canals of the surrounding bone, and though he believes that these processes may sometimes be effectually detached, he advises the practice ordinarily followed of removing a portion of bone.

I think it right to mention here that all the specimens removed by Mr. Liston, and referred to in the foregoing pages, have, in the new catalogue of the College of Surgeons' Museum, been placed among the sarcomata, on what I cannot but regard as insufficient grounds. In the first place, forty years' soaking in spirit prevents anything like a reliable microscopic examination, and the presence of a few cells scattered among the fibres of a tumour are no proof that it is not a fibrous tumour; and, secondly, the clinical history of all these cases is that of a simple growth, which once removed did not recur. I have therefore included them among the fibrous tumours, and if they are not so, it is very remarkable that there is no specimen of the true fibrous tumour of the upper jaw among the large number removed



by Liston and preserved in the College of Surgeons' and in University College Museums.

Fibrous tumours of the jaw, like those in other parts of the body, and especially in the uterus, are liable to calcareous degeneration, or, as is sometimes incorrectly stated, to ossific deposit. A good specimen of the kind is preserved in the Museum of St. Thomas's Hospital (I. 18), which is thus described in the Museum catalogue:—

“An osteo-fibrous tumour of the antrum, removed by Mr. Solly. The tumour entirely filled the cavity of the antrum, the bony parietes of which have been absorbed to a considerable extent; it protruded the cheek anteriorly, projected into the fauces posteriorly, pressed down the palate inferiorly, and extended to the septum nasi internally. Its firmest point of attachment is to that part of the antrum corresponding to the roots of the first molar, canine, and incisor teeth. The tumour is of a rounded form, and has a smooth external surface; its section presents very much the appearance of a fibrous tumour of the uterus of slow growth, and contains an abundance of bony deposit.

“From a boy, aged seventeen. The existence of the tumour was discovered only ten months previous to its removal, when the face began to swell, the swelling being accompanied by pain. No untoward circumstances followed the operation, and the boy left the hospital quite well. The deformity was very slight. Five years after the operation the boy was in capital health.” More complete details of the case will be found in Mr. Solly's “Surgical Experiences,” lecture 41.

A thin section of this tumour has been dried and preserved, in order to show the amount and distribution of the calcareous matter (I. 19).

A remarkable example of calcareous degeneration of a fibrous tumour occurred in the practice of Sir W. Fergusson, and the preparation is now in the Museum of the College of Surgeons (2242). It is a fibrous tumour of the left upper jaw, of some years' growth, from a woman aged fifty, containing numerous calcareous particles and acicular crystals, and in addition, enclosing a suppurating cavity, in which was



a mass about an inch in diameter, found by Dr. Goodhart to consist of acicular crystals of mineral matter, entangling in places nucleated and shrivelled cells. This is clearly an example of extreme calcareous degeneration undergoing necrosis.

With regard to the causes giving rise to fibrous tumours of the upper jaw there is much obscurity, though there is little doubt that they in many cases originate in some irritation due either to a blow, or more frequently to the presence of decayed teeth; and the latter may give rise to a tumour commencing in the alveolus itself or within the antrum, the lining membrane of which is irritated by the fangs of the diseased teeth. Bordenave strongly insisted upon this, and since his time most surgeons have taken the same view. Stanley mentions a case which occurred to Mr. Luke, in which a black, carious tooth was found imbedded in a fibrous tumour of the upper jaw, and other cases of the kind have occurred, although the event is more common in the case of the lower jaw.

Since the publication of the first edition of this work M. Broca, in his "*Traité des Tumeurs*" (Paris, 1869), put forward the view that many cases of fibrous and fibro-cellular tumour of both upper and lower jaw depend upon the growth of a tooth-germ, and these are included by him under the head of *odontomes embryo-plastiques*. There is no difference in structure by which these fibrous odontomata can be distinguished from the ordinary fibrous tumour, but according to M. Broca they are always encysted, and they occur only in young subjects, and before the last tooth is formed. Owing to their ready enucleation, these tumours show no tendency to recur. I have met with but one case which seemed in any way to support the views above given. A young married lady, a patient of Dr. Neale, had a tumour of the upper jaw, evidently due to expansion of the antrum, the walls of which crackled under pressure. Believing the swelling to be due to fluid, I punctured it, giving exit to only a small quantity of fluid, and discovered a tumour within. On laying open the antrum, I was able to enucleate



with the finger a tumour which had very slight attachments, presented all the appearance of a fibroma, and on examination by Dr. Bastian, was pronounced to be very rich in cell elements, and therefore likely to recur. Nevertheless, the patient is now in perfect health, fourteen years after the operation.

*Enchondroma* of the upper jaw is of uncommon occurrence, but the jaw may become involved in cartilaginous tumours springing from other bones of the face. Of this there is an example in St. George's Hospital Museum (XVII. 66), taken from a young woman, who, seven years before her death, began to suffer from soft elastic tumours on the inner side of the orbits. Two years after, the right maxillary bone was fuller below the orbit than the left, and the right half of the bony palate was larger and more depressed than the other; but in neither of these parts was there any softening. Gradually the eyeballs were protruded, and the sight was lost. Two years later, it was noticed that the superior maxillary bones projected nearly an inch beyond the inferior, so that she had some difficulty in masticating. A portrait of this patient is preserved in St. George's Museum. The tumour was found to project into the cranium, the orbits, the antra, and the nasal, zygomatic, and pterygo-maxillary fossæ. All the fossæ were quite filled up by the growth, and the bones of the face and orbits extensively absorbed. The hard palate was pressed downwards, so that the teeth on the two sides deviated from their natural line, and the left central incisor crossed that of the right side. Microscopical examination of the tumour showed it to be composed principally of cartilage. A full description, with a lithograph of the preparation, will be found in the *Pathological Society's Transactions*, vol. x.

In the Museum of St. Bartholomew's Hospital is another post-mortem specimen of cartilaginous tumour of the face, from a lad of sixteen (XII. 1773), occupying the situation of the superior maxillary bones, which are completely absorbed. Above, the tumour has extended through the left side of the base of the skull into its cavity, where it forms a large pro-



jection in the situation of the anterior lobes of the cerebrum ; below, it is united to the soft palate ; in front, it protrudes and distends the left nostril, and has caused the ulceration of a part of the integuments of the face. The outer surface of the tumour is nodulated, its interior, shown by the section, is formed of close-set nodules and masses of cartilage, partially and irregularly ossified, and in some parts intersected by layers of a softer, probably fibrous tissue. A portion of its external surface projecting below the left nostril has sloughed. This case is drawn in Mr. Stanley's illustrations to his work on "Diseases of the Bones ;" and both it and the preceding preparation illustrate very well the tendency of cartilaginous tumours to invade all the surrounding structures, and to fill the several cavities.

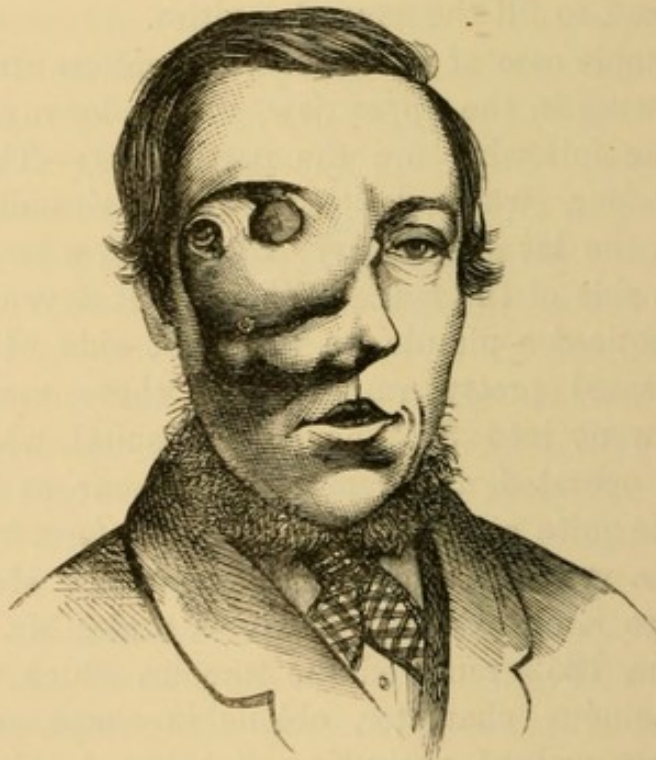A remarkable case of recurrent cartilaginous tumour of the face, originating in the upper jaw, was under my own care, of which the following are the particulars:—The patient, aged thirty-four, was admitted into University College Hospital on the 1st of January, 1868, with a large tumour of the right side of the face. When about seventeen years of age he noticed a pimple on the right side of the nose, which increased pretty rapidly, and three months after (1851) he went into St. Thomas's Hospital, when Mr. Le Gros Clark operated, and removed a tumour as large as a walnut. He quite recovered, and was well for a few months, but within a year the tumour had returned. He was then admitted into King's College Hospital, under Mr. Partridge, who, in June, 1852, removed the tumour, which was of an osteo-cartilaginous character, oblong in shape, and of the size of a large walnut, projecting slightly into the antrum, and involving the nasal process of the superior maxillary bone, but in no way implicating the mouth or orbit. From this operation the patient made a good recovery, except that a small fistulous opening was left in the cheek. The man continued in good health until 1857, when he went to America, and soon after arriving there he found the tumour beginning to appear again, and in 1860 Professor Gunn operated at Anne Harbour, in the state of Michigan, and



removed the entire right upper jaw. The tumour, however, began to grow again rapidly, and projected on the face. The surgeons at Maple Rapids, where he lived, wanted to operate again, but the patient declined, and returned to England in 1865. Soon after this an abscess formed in the upper part of the tumour, which was lanced with great relief, but the incision thus made had never closed, owing to the stretching of the skin by the tumour.

The patient's appearance on admission was most unsightly (fig. 133), the right side of the face being greatly disfigured by a large tumour, by which the eye was thrust completely

FIG. 133.



aside, but without loss of vision. Immediately to the inner side of the eye was an open granulating sore of the size of a florin, the result of the incision for the evacuation of matter already referred to. The tumour appeared externally to consist of two portions, separated by a horizontal sulcus, at the bottom of which the fistulous opening resulting from the second operation was still visible. The upper, and more prominent portion had invaded the orbit, reaching to its



upper border, and extending beyond the middle line of the nose. A small portion of this had, within the previous two months, projected through the left nasal bone. The lower portion of the tumour involved the ala of the nose and adjacent portion of the cheek, both of which were much distorted; on a small projecting portion of this the skin was adherent. Both nostrils were completely blocked, and had been so for months. Within the mouth it was seen that the whole of the right side of the hard palate had been removed; and in its place there was a smooth, red, oval mass, coming down to the level of the teeth of the opposite side. The scars in the middle line of the lip and on the cheek, resulting from former operations, were still visible. The tumour was solid and not tender to the touch, the most prominent point being apparently osseous. There was no enlargement of the glands in the neck or elsewhere, and the man appeared in good health. The tumour had made decided progress within the previous few months, and he was anxious to have it removed, to which, after a consultation with my colleagues, I agreed.

On January 8, under chloroform, I made a curved incision below the eye to the side of the nose, from the extremity of which a vertical incision was carried down the face and round the ala of the nose; and the lip was divided in the cicatrix of a former operation. The flap was then dissected back, and with it a hard prominent nodule of bone, which became detached from the bulk of the tumour. The tumour being thus exposed, I proceeded to enucleate it with the fingers, and by successive efforts removed in this way the upper part of the growth. The portion projecting into the mouth was found to be held by a firm band of tissue in the position of the gum, and after dividing this I was able to tear out the growth, and also a portion projecting through the posterior nares into the pharynx. The wound having been well sponged out and the hæmorrhage having abated, the portion at the inner side of the orbit was removed, and was found to project into the frontal sinuses, which (particularly the right) were considerably expanded. With one of



Langenbeck's palate spatulæ I carefully cleared these out, scraping the walls, and then introduced a pledget of lint covered with a paste of chloride of zinc (to which a string was attached), in order to destroy any remaining portion. This was the only part from which the growth appeared to have arisen, the remainder of the huge cavity left by the removal of the growth being perfectly smooth and healthy. The septum narium was found to be completely pushed over to the left, and to have been destroyed at the upper part by a projecting lobule of the growth, which had pushed through the nasal bone. The ala of the nose included a small portion of the growth, which was removed, and also the bony nodule attached to the flap, the upper corner of which, being very thin and closely involved in the growth, was cut off. The wound was sponged out with solution of chloride of zinc, and all hæmorrhage having ceased without the application of any ligatures, the lip was brought together with hare-lip pins, and the remainder of the wound with wire sutures. The edges of the gap caused by the opening of an abscess some months back were brought together, but finding that this prevented the patient closing his eye, I subsequently removed these sutures. Collodion was painted over the wound, and the patient, who had a good pulse, was carried to bed.

The patient made an uninterruptedly good recovery from the operation. The wound was kept clean by syringing with Condyl's fluid; the plug of lint in the frontal sinus was removed on the third day after the operation, and the sutures on the eighth day, the incision being well united. The right eye, which had been much displaced, began gradually to recover its proper position. A fortnight after the operation, the patient was up and about the ward, and on Feb. 1 he went out for a walk. On Sunday, Feb. 2, he again went out, the house-surgeon not being aware that there was a bitter east wind. This he felt a good deal, and the next day his face was noticed to be swollen and red. This had increased on the following day, when I saw him, and it was evident that an attack of erysipelas was coming



on. The patient was at once placed in a separate ward, and active treatment adopted. The erysipelas spread, however, and affected the throat, so that on Feb. 7 he was able to swallow but little, and was becoming rapidly exhausted. By the frequent use of the stomach-pump nourishment was introduced into the stomach, and he rallied for a day or two. Symptoms of pyæmia, however, now manifested themselves, and the patient rapidly lost ground, and after lingering for a week, died on Feb. 17.

At the post-mortem examination, the incisions in the face were cicatrized; but the site of the tumour was granulating, and encrusted with mucus in parts. On removing the brain, it and the membranes were found perfectly healthy; but the plate of bone between the frontal sinus and the cranial cavity was so thin, that it broke in the removal of the brain. There was no appearance of any remnant of tumour either in the frontal sinus or elsewhere, the walls of the large cavity left by its removal being healthy. In the thorax there was abundant evidence of pyæmia, the lungs being filled with pyæmic abscesses. The tumour weighed nine ounces, and consisted of a loose cartilaginous material enclosed in a bony cyst, from which spicula were sent into the interior. At two points, and particularly at the most prominent portion of the tumour, the bone was of considerable thickness. The tumour was exhibited at the Pathological Society, and was referred to a committee of investigation, which pronounced it to be an enchondroma undergoing ossification, and presented the following report upon it:—"The portions examined consisted of a thin incomplete bony shell, coated by a fibrous membrane, and enclosing a soft tissue penetrated by bony spicula. The external membrane is composed of wavy bundles of common connective tissue, interwoven in planes generally parallel to the surface of the underlying bone, and enclosing groups of fat cells. Beneath this outer stratum there is a deeper layer, immediately resting upon the bone, composed chiefly of small, closely-packed cells, evidently the equivalent of the osteogenic layer of periosteum, and ministering as this does



to the growth of the bony shell. This latter is lamellated parallel to its outer surface, and it has a true osseous structure. The enclosed soft tissue consists in greatest part of cartilage, the characters of which, though varying considerably, are everywhere unmistakable. The cartilage capsules in some situations are very large, and so crowded as nearly to exclude the intercellular substance, approximating to a colloid structure; while in other parts the two tissues exist in nearly equal quantities, and here many of the capsules exhibit the concentric rings indicative of successive layers, which are not uncommonly seen in old and slow-growing enchondromata. The tumour belongs, no doubt, to the category of enchondromata."

Probably the largest enchondroma of the upper jaw ever submitted to operation is one recorded by Mr. O'Shaughnessy, in his essay on Diseases of the Jaws (1844). The patient was a Hindoo, aged twenty-one, who had a tumour of the upper jaw, of a year's growth (?) which had attained an enormous size, as shown in the illustrations of the work in question, looking nearly as big as the patient's head. Mr. O'Shaughnessy removed the tumour, which weighed four pounds, and was nearly globular in form, having at its inferior surface a deep groove into which the lower jaw sank. On section it proved to be of dense fibro-cartilaginous structure, surrounded by a thin shell of bone in the greater part of its extent. The patient made a good recovery.

These cases will serve to illustrate the leading features with regard to enchondroma. The disease appears ordinarily early in life, springing from the surface of the bone, or from the antrum, and then making steady progress either externally, as in the last-mentioned case, or internally, as in the former ones. It produces absorption of the bone of the maxillæ in its progress, and protrudes beneath the skin, which, however, it rarely, if ever, involves. Its rate of increase is ordinarily slow, and there must, I fancy, be some error in the statement of Mr. O'Shaughnessy's patient, since it is difficult to imagine that a growth of that enormous size



could have been produced in one year. In the early stage, the enchondromatous tumour may possibly be got rid of by absorbent applications ; thus, Mr. Stanley (p. 147) mentions the case of a female, aged twenty-eight, who had a round tumour of the size of a hazel-nut on the front of the maxilla, which had been growing some months. This was ascertained, by the introduction of a needle, to be composed of cartilage with particles of bone dispersed through it. Under the local use of iodine two-thirds of the growth disappeared in the course of a few weeks.

Such a result cannot be hoped for when the tumour has attained any size, but provided it is still confined to the maxilla, a cartilaginous tumour is a favourable one for removal, owing to its solidity and rounded form, and the ease with which it is isolated. The first case in which M. Gensoul removed the superior maxilla was for a tumour of this kind. Ordinarily perfect immunity from return is obtained, provided the whole disease has been extirpated.

In many cases of enchondroma a certain amount of fibrous tissue is found mixed with the cartilage, and in some cases, particularly those of slow growth and of long standing, the fibrous has, to the naked eye, almost replaced the cartilaginous element. Of this an enchondromatous tumour, removed by Mr. Square, of Plymouth, in November, 1866, and kindly given me by that gentleman, is an excellent example.

The tumour was of the size of an orange, and occupied the right superior maxilla of a woman, aged forty-seven. It had been growing ten years, and Mr. Square successfully removed it. The preparation, now in the Museum of the College of Surgeons (2216), and of which a section has been made, shows a surface closely resembling a fibrous tumour, but in which cartilage cells are readily found under the microscope. The preparation shows a deep groove in the buccal surface of the tumour caused by the teeth of the lower jaw.

The ossific deposit, beginning at several separate points, which is not unfrequently found in connection with enchondromata of other parts of the body, may take place in



enchondroma of the upper jaw. A very excellent example of this was published by the late Mr. Maurice Collis, of Dublin (*Dublin Quarterly Journal*, Aug. 1867), and the appearance of the patient is well shown in the lithographic illustrations which accompany that paper. The patient was fifty years of age, and the disease dated from his fourteenth year. It grew slowly at first, but latterly had increased with considerable rapidity. The tumour was firm and hard, but painless until recently, when brow-ague was complained of. The sight of the left eye was lost, the left nostril occluded, and hearing on that side somewhat dull. The tumour had expanded the cheek, pushed up the floor of the orbit, and depressed the hard palate, Mr. Collis successfully removed the growth, and the patient made a rapid recovery. The following is Mr. Collis's description of the tumour :—

“ Much of its posterior part was removed piecemeal, but what remained was composed of two kinds of bone. The centre, which may be supposed to correspond to the antrum, is remarkably hard and close—white, with fine concentric rings, like ivory, which it also resembled not a little in its hardness. All round this, except above, lay a much larger mass of bone, distinctly and coarsely laminated, softer in texture, and enveloped in a very thin and strong layer of hard bone. This external mass was divided into two by a fissure which ran in an oblique curve upwards and outwards into a very small, irregular space, filled with a mass of lining membrane, gathered up and jammed together. These two masses evidently corresponded to the middle and inferior spongy bones ; and the fissure and cavity represented that portion of the nostril which normally lies between these two bones. The growth commenced in the antrum, filled it, implicated its walls, extended to the spongy bones, developing itself layer over layer, until the entire nasal cavity was filled. It then continued to grow, producing the immense deformity already described. Originally it had probably been an enchondroma, but as years advanced it ossified, beginning from the centre. The outer layers of the new growth were



probably the most recent, as they contained some fragments of imperfect or degenerate cartilage. The whole was enclosed within a real bony layer, derived from the proper tissue of the spongy bones and of the walls of the antrum."

In St. Thomas's Hospital Museum is a section of a skull (C. 196), showing a large tumour in connection with the superior maxilla, which appears to be an ossified enchondroma. Superiorly the growth encroaches considerably upon the cavity of the orbit, and posteriorly it fills nearly the whole of the zygomatic fossa, extending as far back as the glenoid cavity. On the inner side it has involved the upper part of the nasal and the lower part of the sphenoidal sinuses; whilst below it projects through the hard palate into the cavity of the mouth.

During the winter session of 1867-68, my colleague, Mr. Beck, then Demonstrator of Anatomy at University College, found in the antrum of a subject an osseous mass filling up the cavity and attached to its outer wall, but giving rise to no external tumour either on the face or in the nares. On section the bone was white and dense, and upon microscopic examination the late Mr. Bruce considered it to be an instance of ossified enchondroma, the calcareous matter being more granular than in ordinary osseous growths, and the lacunæ and canaliculi imperfectly developed. The preparation is in my possession, and will serve to elucidate some points in connection with osseous tumours to be subsequently referred to.

*Osteoma*.—The simplest form of osseous tumour of the upper jaw is an hypertrophy of the whole or of some portion of the bone. A case of Sir William Fergusson's has already been referred to (p. 216), in which this result was due to the presence of a tooth imbedded in the jaw; but the same thing may happen without obvious cause. The tumour is slow of growth and painless, and upon removal shows no deviation from the ordinary structure of healthy bone. An example occurring in a girl of sixteen, from whom Sir William Fergusson successfully removed a growth of the kind, will be found in the *Lancet*, July 26, 1856.



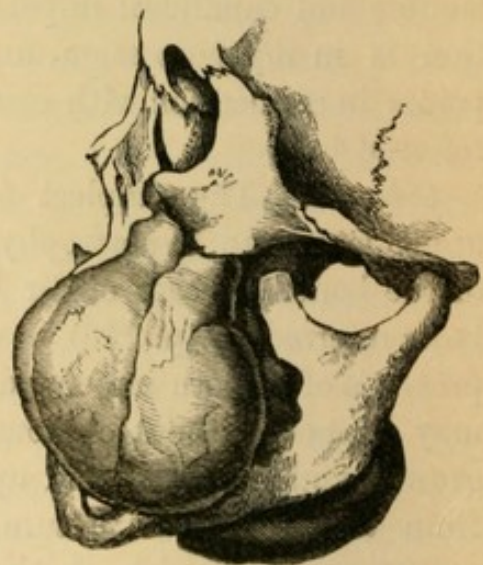
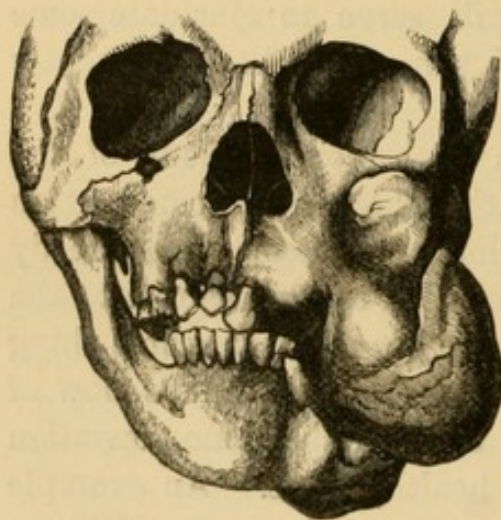
In October, 1883, I had under my care in University College Hospital, a young woman, aged twenty-five, in whom a painless enlargement of the right upper jaw had been noticed for ten years, encroaching upon the palate and bulging out the cheek. I successfully removed the whole upper jaw, and on section the tumour was found to be simple bone, very dense, but otherwise healthy. One half of the specimen is in University College and the other in the College of Surgeons' Museum.

In the Museum of Charing Cross Hospital is a remarkable specimen of osseous tumour of the upper jaw, removed by Mr. Hancock. The whole jaw seems expanded anteriorly, and the outer compact plate is perfect, except at the part immediately below the infra-orbital foramen, where it has given way, and the cancellous structure forming the interior of the tumour is seen. Mr. Hancock, in referring to this specimen (*Lancet*, Jan. 13, 1855), specially calls attention to the fact that the bone yielded to pressure to such an extent as to lead to some doubt as to its osseous nature.

A still more remarkable specimen of the same kind is preserved in the Musée Dupuytren at Paris, which is shown in figs. 134 and 135 from the "*Traité de Pathologie*

FIG. 134.

FIG. 135.



Externe," by M. Vidal de Cassis. It is connected with the left superior maxilla, being limited internally by the inter-



maxillary suture, behind by the pterygoid process, above and externally by the malar bone. The tumour encroaches considerably upon the cavity of the mouth, and reaches back as far as the front of the spine. Its form is bi-lobed, and in the deep sulcus between the lobes can be seen a molar tooth. All the other teeth of the jaw have disappeared, and there is no trace of their alveoli. The left orbit and nasal fossa are not sensibly diminished in size, but the cavity of the mouth is almost entirely occupied by the posterior lobe of the tumour. The lower jaw has, in this case, undergone several remarkable alterations. It must at first have pressed upon the growth and produced the deep sulcus between the lobes, but in its turn the tumour has reacted upon the lower jaw with the following effect:—It has caused a double luxation of the jaw, the left condyle resting against the root of the zygoma and the glenoid cavity being filled with soft material. The teeth of the left side of the lower jaw have disappeared, and absorption of part of the coronoid process and the whole of the alveolus has taken place, so that only the base of this part of the bone is left. The outer surface of the tumour is smooth, and presents numerous vascular grooves of good size; at many points it is perforated with holes. The vascularity of the other bones of the face does not appear augmented.

In the Museum of Netley Hospital, which includes the preparations formerly at Fort Pitt, Chatham, there is a specimen of large osseous tumour of the upper jaw closely resembling that last described, but of smaller size.

Besides this form of bony tumour, due apparently to an increase of the cancellous structure of the bone, specimens of tumour as hard as ivory have from time to time been met with. Perhaps the most remarkable of these is one described by Mr. Hilton, in the *Guy's Hospital Reports*, vol. i. p. 493, from the fact that the tumour separated spontaneously from the face. The patient was a man aged thirty-six, who, twenty-three years before Mr. Hilton saw him, noticed a pimple below the left eye, close to the nose, which he irritated, and from that spot the tumour appears



to have originated. The tumour in its growth displaced the eyeball, giving rise to excruciating pain, which subsided on the bursting of the ball. It began to loosen by a process of ulceration around its margin six years before it fell out, which event was unattended by either bleeding or pain. The tumour weighed  $14\frac{3}{4}$  ounces. It was tuberculated externally, and an irregular cavity existed at the posterior part. A section presented a very hard polished surface resembling ivory, and exhibited lines in concentric curves enlarging as they were traced from the posterior part. The huge cavity left by the tumour was bounded below by the floor of the nose and antrum, above by the frontal and ethmoid bones, internally by the septum nasi, and externally by the orbit, which had been considerably encroached upon by the tumour. This patient was alive in 1865, thirty years after the prolapse of the tumour.

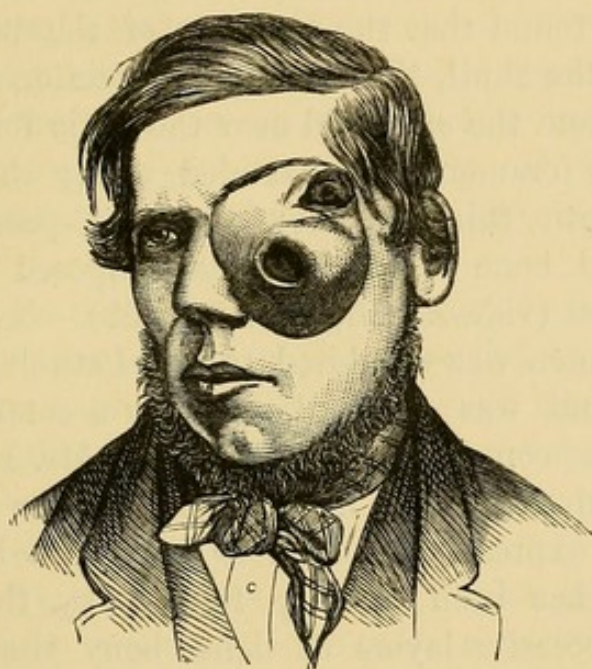A case in many respects resembling Mr. Hilton's case was under the care of Sir William Fergusson, whom I had the opportunity of seeing operate upon it. The patient was a young man of twenty-one, who had first noticed the swelling on the left side of the face twelve years before. It grew for six or seven years, and then remained stationary. Two years before he had consulted a quack, who attempted to destroy the growth with caustic, and produced the large hole seen in the lower part of the tumour (fig. 136).

On admission into King's College Hospital there was a swelling on the left side of the face about the size of an apple, extending from the eyebrow to a line less than one inch above the mouth. Internally, it encroached upon the nose, displacing it a little, the nasal bone being pushed forwards and the left ala flattened on the columna; the mass was felt by the finger in the mouth above the gums. The nostril on the same side was perfectly blocked up, the patient being totally unable to breathe through it. The right nostril, however, was quite free. Outwards, the tumour extended to the angle of the orbit; the arch was, however, not displaced, but the tumour extended slightly above it. The floor of the orbit seemed displaced. The eyeball was seen imbedded



in the most prominent and central part of the tumour, and removed more than an inch from its natural position in the orbit, which was entirely blocked up by the mass. There was no extension into the pharynx. The tumour was every-

FIG. 136.



where hard, with a slight blush over the surface. In its centre was a round opening, produced by the caustic applied two years previously, of about the size of a shilling, deep, and displaying in its floor black necrosed bone, and discharging pus. The patient said he had suffered neither headache nor pain in the tumour since its commencement, twelve years before, and that his sight had been unaffected. Sir William Fergusson operated upon this patient on November 30, 1867, and succeeded in removing the whole of the prominent tumour, weighing  $10\frac{1}{2}$  ounces, which consisted in all its anterior part of nodulated bone as hard as ivory, and posteriorly, of very dense ordinary bone mixed with a small amount of cartilage. A section showed an ivory-like mass closely resembling Mr. Hilton's specimen, connected with a mass of very much condensed bone. The tumour sprang apparently, as in the former case, from the upper part of the maxilla, and had invaded the antrum, orbit, and



nostril. The palate was in no way involved in the growth, and was preserved entire at the operation, Sir William Fergusson sawing horizontally immediately above it. Unfortunately the patient sank rather suddenly, from inflammation of the lungs, on the fourth day.

At the post-mortem examination, after removal of the brain, it was found that the affection of the bone involved the base of the skull, there being a projection of the size of a hazel-nut from the sphenoid near the optic foramen. This involved the foramen and extended along the sphenoidal fissure, the optic, third, and fourth nerves passing through the condensed bone of which it was composed. The brain was unaffected (*vide Lancet*, Feb. 8, 1868).

This specimen was exhibited to the Pathological Society of London and was reported upon by a committee. The report of this committee, drawn up by Mr. Hulke, which will be found *in extenso* in vol. xix. of the *Pathological Transactions*, expresses an opinion that "the hard part of the tumour has been directly formed by the exogenous growth of successive layers of dense bony tissue under the periosteum, which opinion is confirmed by the absence from the hard tissue of the regular Haversian systems so characteristic of secondary bone."

The reporters "did not find anywhere along the meeting line of the hard and spongy bony tissues anything resembling cartilage, and are disposed to regard the splitting of the tumour along this line as the result of violence, the place of the separation being determined by the different resistances of the two kinds of bony tissue. The intrusion of masses of the spongy tissue with the hard along the meeting line, and the occurrence of minute specks of spongy tissue in the midst of the hard tissue, suggest the direct continuity of the two tissues, and the microscopic appearances prove not only that this actually occurs, but also that the spongy tissue is formed by the rarefaction of the hard. For near its deep limits absorption spaces begin to appear in the hard tissue, and these, increasing in number and size and coalescing, produce large medullary spaces and cancelli.



These are filled with a soft medulla carrying blood-vessels, and their walls consist of remnants of the hard primary bone and of new lamellæ formed from the young medulla."

It seems to me difficult to imagine that the condensed bone which extended into the skull, could at any time have been of an ivory nature, as this report implies. Presuming the ivory-like growth to have been deposited from the periosteum on the surface of the original maxilla, it is conceivable that the same action which led to this result may have led to a thickening and induration of the subjacent bone, which, in process of years, by simple extension, may have reached the sphenoid bone.

In both these cases the tumour appears to have taken its origin in the upper wall of the antrum and to have grown forwards; but tumours of the same kind have been found completely within the superior maxilla, the anterior wall of which has been merely expanded by the growth behind it. Of this, two cases reported within the last few years by M. Michon and Dr. Duka are good examples, and they will be elucidated by reference to a case recorded by M. Demarquay.

M. Michon's case is reported in the 2nd volume of the *Mémoires de la Société de Chirurgie de Paris* (1851); his patient being a man of nineteen, who had a large tumour of the right upper jaw, which had existed for three years. The tumour was rounded and hard, and had pushed up the eyeball considerably, and closed the right nostril, but the palate was not affected. M. Michon operated in Jan. 1850, by turning up a triangular flap of skin. He had intended to have removed the entire upper jaw, but having with considerable difficulty removed the front wall of the antrum, he found the tumour lying in the cavity, and connected only with the floor of the orbit and the vomer. After an operation extending over an hour and six minutes, and without anæsthetics, the tumour was at length removed. The whole of the vomer and a part of the maxilla came away with the tumour, which was a flattened sphere, or somewhat resembled a heart in shape. It weighed 120 grammes (1,800

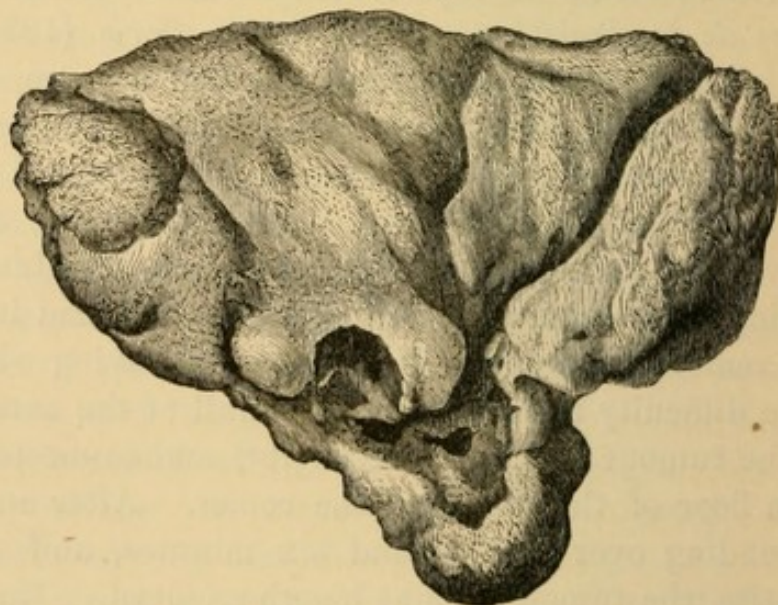


grains), and was deeply lobulated, particularly on the posterior aspect. A section showed concentric markings upon a surface of ivory, and microscopic examination demonstrated the lacunæ and canaliculi of true bone. The patient made a good recovery.

Dr. Duka's case is reported in the *Pathological Society's Transactions*, vol. xvii., and occurred in a female native of Bengal, aged twenty-six, and on the right side of the face, which was not much deformed. There was a discharge from the right nostril, which was obstructed, and on examination a hard tumour was found within it, *which was movable*, but could not be extracted, and which had existed six years.

Dr. Duka, failing to extract the tumour by laying open the nostril, resorted to the somewhat unusual proceeding of cutting a wedge out of the hard palate, and thus, after an operation of three-quarters of an hour, without chloroform, succeeded in removing the growth. The patient recovered. The tumour is preserved in St. George's Hospital Museum, and is figured in the *Pathological Transactions*, from which the accompanying illustration (fig. 137) is by permission

FIG. 137.



taken. It has an oblong shape, and is not unlike a middle-sized potato, with depressions and elevations passing irregularly over it. The upper part, which is believed to have



been in contact with the cribriform plate of the ethmoid bone, exhibits corresponding delicate depressions, with other deeper sulci in front, behind, and on the sides, probably for the passage of blood-vessels. At the lower surface is a large nipple-like process, smooth throughout. This lay in contact with the palatine process, and it has the same dark appearance as the anterior part of the body which presented at the nostril. At the base of this process is a large hole piercing it quite through, and allowing the tip of the little finger to enter it. In this lacuna was a polypoid mass which contained a nucleus of cartilage, round and flat like a small-sized lentil. It was this nipple-like prominence impinging upon the nasal process which prevented the removal of the tumour, without interfering with the superior maxillary bone. The whole bony mass, which is of a compact ivory-like character, weighs 1,060 grains: its long diameter is nearly three inches, the short one an inch and two lines, and the longest circumference seven inches. The microscope gives evidence of structure closely resembling that of M. Michon's tumour. There are no distinct Haversian systems, but abundance of lacunæ arranged around vascular canals. In some parts of the tumour the characters are very much those of simple ossified cartilage, clusters of large ossified cells being packed closely together.

This case is remarkable from the fact that the attachment of the tumour had given way, and that it was therefore loose in the antrum. It would have appeared to be unique in this particular, but for the publication in the *Gazette Médicale de Paris* (April 20, 1867), of a very similar case of non-adherent exostosis, or osteoid tumour, by M. Demarquay, of which the following are the leading features:—

A gentleman, aged fifty-three, in good health, but the subject of syphilis, had a swelling of the left side of the face, which had existed for twenty years. It gave no inconvenience except the disfigurement, until six months before he applied to M. Demarquay, when an abscess formed and burst, leaving a fistula. After this neuralgia came on, and other abscesses formed, rendering the face swollen and



red. On examination several fistulæ were found both within and without the mouth. There was evidently suppuration within the antrum, probably due to a sequestrum.

At the operation, on Jan. 4, 1867, it was found impossible to extract the sequestrum, and M. Demarquay therefore removed the entire maxilla, and the patient recovered.

The jaw showed an increase of size and density; the front wall of the sinus was thrown forward, so as to present the segment of a sphere, and was thickened so that its resistance was increased. The posterior part was also enlarged, and had projections upon it, one of which also pushed up the floor of the orbit. There were numerous sinuses in various parts, through which pus escaped.

On section, a white osteo-cartilaginous substance was found filling up the whole cavity of the antrum, but not attached to its walls. In some parts this was of a more fibrous character, whilst in others it was dense bone. In the centre was a large fragment of bone, of a blackish colour, and closely resembling a sequestrum. This was surrounded by some smaller portions, and by a cavity containing a quantity of pus, into which the sinuses could be traced. It was impossible to tell from which part of the wall the tumour had sprung.

Here it will be observed that we have apparently an earlier stage of a growth, which if it had continued to increase, would no doubt have developed into a dense osseous tumour, since it consisted in great part of cartilage in which ossification had already partially occurred. Dr. Duka's specimen also had some cartilage mixed with it, and its microscopic appearances showed evidence of ossification of cartilage. The post-mortem specimen of ossified enchondroma within the antrum in my possession, and already referred to (p. 277), shows how slight the attachment of the growth to the wall of the antrum in these cases is.

I think, therefore, it may be concluded that this class of bony tumours depends upon a form of ossification occurring in cartilage or enchondroma.



## CHAPTER XIX.

## SARCOMATOUS TUMOUR OF THE UPPER JAW.

*Spindle-celled Sarcoma, Myeloid Sarcoma, Chondro-Sarcoma, Ossifying Sarcoma.*

UNDER the term Sarcoma, modern pathologists include all tumours composed of tissue, which is either purely embryonic, or is undergoing one of the primary modifications seen in the development of adult connective tissue (Erichsen).

In connection with the jaws various forms of sarcoma are found, many of which have hitherto been known by other names, and many recurrent growths formerly called cancers come properly into this class.

The *Spindle-celled Sarcoma* is of frequent occurrence in the upper jaw, forming many of the specimens formerly indiscriminately named "osteosarcoma." It is usually of a yellower colour than the fibrous tumour and of softer consistence, and on section it exudes a serous fluid. The spindle-shaped cells are often of great length and size, and each cell contains one or more oval nuclei, the intercellular substance being homogeneous.

Under the name of "albuminous sarcoma," Mr. Liston has described a case which appears to be of this kind, in the *Lancet*, Nov. 26, 1836, which proved fatal after removal of the tumour. The patient was twenty-four years of age, and the disease appeared to have originated in a blow, and grew with tolerable rapidity. The tumour, which is preserved in the College of Surgeons' Museum (2202), is oval in form, its chief diameters being about three inches by two inches, and contained spaces in which was a glairy fluid,



coagulable by heat. Mr. Lane successfully removed, in 1861, both upper jaws, together with the vomer, &c., which were involved in an "albuminous sarcoma," from a man aged forty-eight, whose case will be found in the *Lancet*, Jan. 25, 1862. The tumour implicated both superior maxillary bones and filled both nostrils. It formed an extensive convex irregular swelling in the mouth, which pressed down the tongue. Very little bony material could be distinguished in the position of the palatine processes of the maxillary or palate bones, and the growth which occupied their place was soft and elastic, and was ulcerated in two or three spots of the size of a fourpenny-piece. The growth first showed itself within the left nostril three or four years previously, presenting the appearance of a nasal polypus, and was removed three times.

In the same number of the *Lancet* is the report of a case of tumour, also removed by Mr. Lane, from a child of nine years, which presented much the same characters. The report states that portions of the growth, placed under the microscope, presented the characters of a fibro-nucleated structure, being composed of minute fibres, in which were disseminated numerous small oval nuclei about the size of blood globules, measuring from the four-thousandth to the three-thousandth part of an inch in diameter.

In the *Lancet* for August 31, 1861, is the report of a remarkable case of fibro-cellular tumour of the jaw, under the care of Sir William Fergusson, in which the patient was the subject of two tumours, one situated in the right cheek, the other in the antrum and roof of the mouth. The growths were, however, perfectly distinct from one another, and both were removed at a single operation, which was attended with the best results. Sir William Fergusson had seen the patient twelve months before, and the disease then presented so malignant an aspect that he dissuaded her from undergoing any operation. Some months later, the disease in the mouth was found to be an ulcerated, sloughy-looking mass, and the finger could be readily passed alongside of it into the antrum. Perceiving that its progress had been slow,



and that it was within the reach of surgical aid, he thought he would give her a chance of relief, more especially as there was no development of disease in any other situation, and the tumour in the cheek was quite distinct from that in the jaw.

The report states that the softer part of the disease appeared, on microscopical examination, to consist mainly of a fibro-granular matrix, containing numerous corpuscles, round, regular, of uniform size, granular, and with no appearance of nuclei. The much firmer tumour of the cheek contained corpuscles of a similar character, with a large proportion of the fibrous element.

The tendency to ulceration which was exhibited in this case is a marked feature of this form of disease, and not unfrequently leads to difficulty in solving the question of malignancy. It is seldom that in the case of the upper jaw the skin becomes involved in the disease, but in the lower jaw this frequently happens, and large fungous protrusions occur which may be mistaken for open cancer. The history of the case, together with the absence of any enlargement of the lymphatic glands, is sufficient to mark the nature of the growth.

In his paper on Osteo-sarcoma, in the fourth volume of the *Dublin Hospital Reports*, Sir Philip Crampton says that "in the earlier stages of the disease the tumour consists of a dense elastic substance resembling fibro-cartilaginous structure, but the resemblance is more in colour than consistency, for it is not nearly so hard, and is granular rather than fibrous, so that it '*breaks short*.' On cutting into the tumour the edge of the knife grates against spicula, or small grains of earthy matter with which its substance is beset." The tumours described above correspond very closely to this definition, especially that of Mr. Liston, which is said to be "chiefly composed of a firm substance like fibro-cartilage, with spicula of bone."

In his work on the "Diseases of the Bones" (p. 283), Mr. Stanley mentions "fatty" tumours of the superior maxilla. He refers (p. 104) to a specimen in St. Bartho-



lomew's Hospital Museum (I. 151), of which the following is the description :—

“Sections of a tumour which occupied the situation of the superior maxillary bone, and was removed by operation. The whole of the natural structure of the superior maxillary bone has disappeared. The mucous membrane which covered the palatine surface of the bone extends over a part of the tumour. The morbid growth consists of a moderately firm fatty-looking substance, with minute cells and spicula of bone dispersed through it.

“From a man, aged forty-six. The disease returned after the operation, and the patient died in consequence of hæmorrhage from ulceration of the internal carotid artery, which became involved in an extension of the disease.”

This, as far as can be judged, would appear to have been an example of spindle-celled sarcoma or osteo-sarcoma, which had undergone fatty degeneration; and the same may, I imagine, be said of the cases referred to by Von Siebold as osteo-steatomata. The disease would appear to be a rare one, as it is not mentioned by most authors.

The modern spindle-celled sarcoma includes both the cases formerly classed as recurrent fibroid tumours, and those which have been termed fibro-sarcomata, from containing numerous young cells, round or oat-shaped, between the fibres.

It is an undoubted fact that fibrous tumours do recur in the upper jaw after complete removal; of this Mr. Liston's series of specimens, already referred to, gives more than one example, and it is probable that careful microscopic examination would prove that some of them exhibit the peculiar “oat-shaped nucleated cells,” described by Sir J. Paget as characteristic of the recurrent tumour. It is not surprising that these tumours should have been considered as examples of the ordinary fibrous tumour, since Sir J. Paget himself observes, in speaking of a well-marked specimen, “without the microscope, I should certainly have called it a fibrous tumour.”

In connection with this subject I may quote the following extract from the report upon diseases of the jaw, in the



*Medical Times and Gazette*, Sept. 3, 1859:—"The only example which we have to quote of recurrent fibroid tumour developed in connection with the jaws, is one in which the diagnosis of that variety of tumour and true cancer is by no means positive. It is that of a woman, aged thirty-four, under Mr. Cock's care, in Guy's Hospital, at different times, for two or three years (1854 and 1856). The growth occupied the right antrum, and extended into the nose; on several occasions Mr. Cock dissected up the cheek in front, laid bare the cavity, and gouged out the tumour and the bone to which it was attached. The parts always healed quickly, but the disease soon returned. The tumour had the microscope features of a recurrent fibroid, as distinct from those of a true cancer, and the fact that it continued to recur in the same place, but did not cause disease of the glands, is confirmatory of that diagnosis. The woman was very pallid and cachectic, but her cachexia did not exactly resemble that of cancer. We lost sight of her towards the end of 1856, and do not know the final result of her case. Probably she has since died of her disease."

In March, 1867, I had the opportunity of seeing a patient of Mr. Lawson's, a lady aged thirty-three, from whom, in the preceding May, that gentleman had removed a recurrent fibroid tumour of the left orbit. From this operation she perfectly recovered, but, four months before I saw her, the patient had found a small hard swelling of the left side of the hard palate. This rapidly increased, spreading backwards into the soft palate, and forwards so as to press upon the incisor teeth. The swelling was irregular in outline, but with a perfectly smooth surface, and was so soft and elastic that it conveyed the impression of fluid, and had been punctured. Mr. Lawson removed the whole of the left side of the hard palate and as much of the soft palate as was involved in the disease, and the patient made a perfect recovery. Four months afterwards the patient again appeared, the disease having recurred on the right side of the hard palate. There was also a fibroid tumour in the parotid region, which had been present some years, and had now begun to increase



in size. Mr. Lawson removed the tumour of the palate with the gouge, including all the periosteum involved by the growth, and excised the parotid tumour. The patient recovered, and has had no further return up to the present time. The growths gave unmistakable microscopic evidence of their recurrent fibroid nature.

*Myeloid Sarcoma* is found in the upper as well as in the lower jaw, in which latter position the specimen first described by Sir J. Paget arose. The occurrence of myeloid cells in specimens of epulis has been already referred to, and it might naturally be expected therefore that the same characters might be discovered in tumours of the jaw. In fact, Dr. Eugène Nélaton, in a valuable treatise, published in 1860, "*Des Tumeurs à Myéloplaxes*," says "*la siége d'élection des tumeurs à myéloplaxes est, sans contredit, dans les os maxillaires, particulièrement au niveau de leur bord alvéolaire*," and supports his statement by quoting twenty-nine cases of the disease in this situation.

The diagnosis of myeloid tumours of the jaw is by no means easy, since the bone is slowly expanded, much as it would be by a cyst, or by any benign tumour. If the disease originate on the exterior of the bone, or when springing from the interior, if sufficient absorption of the bone have taken place to allow the tumour to appear beneath the mucous membrane, the characteristic dark maroon colour of the tumour may be perceived. Cysts occasionally form in the substance of a myeloid tumour, and an exploratory puncture of these may yield fluid in which the characteristic myeloid cells may be discovered microscopically.

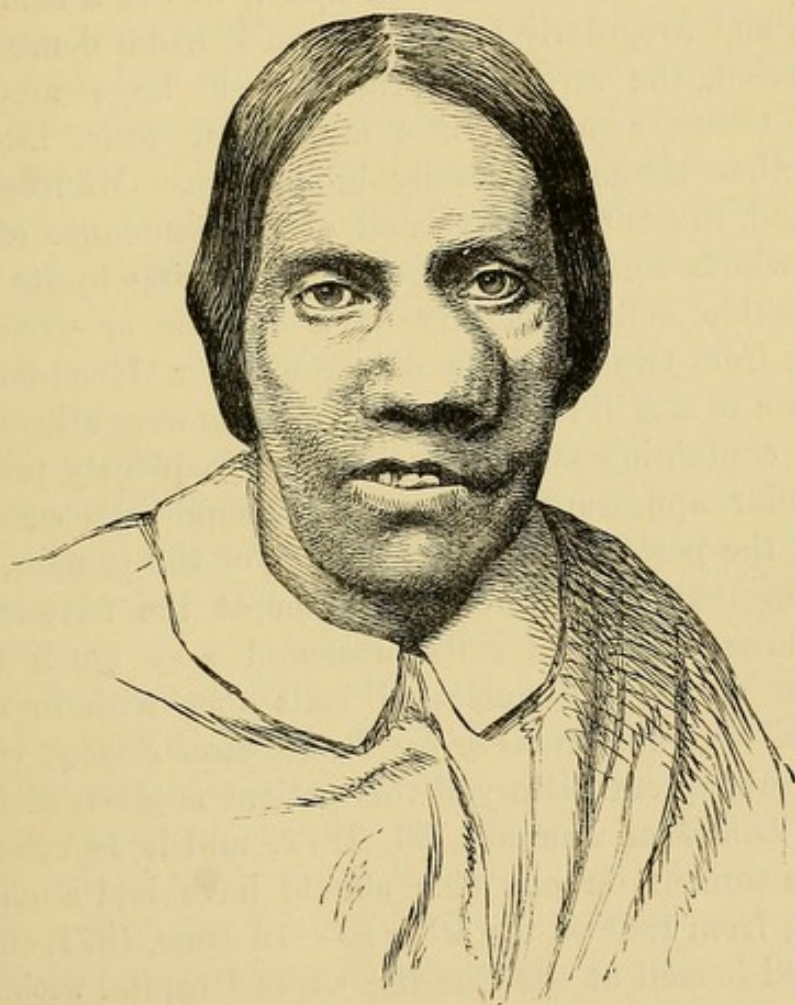
Myeloid disease occurs mostly before the age of twenty-five. Sir J. Paget ("*Surgical Pathology*," p. 524) quotes two cases of Sir William Lawrence's, occurring in the upper jaws of women of twenty-one and twenty-two years of age, the latter of which illustrates extremely well the recurrence of myeloid growths (of which there can be no question), and also the very curious fact that a tumour on the opposite side to that removed, and which presented appearances



exactly corresponding to it, spontaneously subsided. The specimen is in St. Bartholomew's Hospital Museum (I. 459).

Fig. 138 shows a patient from whom Mr. Canton removed a myeloid tumour in 1864. She was thirty-five years old, and the tumour appeared to have followed a blow. It had been twice removed before she came under Mr. Canton's care, and that gentleman successfully removed the left

FIG. 138.



superior maxilla with the tumour, a portion of which hung down into the pharynx. The tumour was brought before the Pathological Society of London, in December, 1865, and the following is a description of the tumour, by Messrs. Bryant and Adams, to whom the specimen was referred:—  
“ The parts placed in our hands for examination consisted of



the left superior maxillary bone, including its orbital plate, from the inferior surface of which appeared to grow a large tumour, which filled the cavity of the antrum, and projected forwards and inwards into the nasal cavity. There was also a second and loose portion, the size of a walnut, which appeared to have been broken off during the operation, and was said to have projected posteriorly towards the pharynx. The external wall of the antrum was not expanded so fully as is usually found in tumours of the antrum. The tumour, which had been some time in spirit, was of a firm fibrous nature, and irregularly lobulated, and it had a dense capsule. On section, the structure presented a large amount of fibrous tissue, arranged in a curvilinear form, intermixed with other tissue not easily broken up. Microscopically examined, the tumour consisted of an abundance of fibrous tissue, which formed the stroma, containing in its meshes innumerable cells, generally of a circular or ovoid form, varying from two to three diameters of a blood-corpuscle, and some of a still larger size. The cells were all nucleated, usually containing several nuclei, and frequently presenting a granular appearance. Large compound cells were abundant in the posterior and softer lobe of the tumour, and a few elongated cells were seen amongst the fibrous tissue. These large compound cells presented very much the appearance of the polynucleated cells met with in myeloid tumours."—*Transactions of the Pathological Society*, vol. xvii.

The subsequent history of this patient is given as follows, in the *Lancet* of January 26, 1872, and it is remarkable that the tumour on one side should have had a character differing from that on the other:—"In June, 1871, she again presented herself at the Charing Cross Hospital with a large tumour filling up the antrum of the right upper maxilla, and extending forwards, causing a projection of the upper lip. Mr. Canton accordingly removed the remaining upper maxilla. The operation was perfectly successful, and presented in itself no points of particular interest. The edges of the incision were brought together with silver sutures, and no dressing of any kind was used, the mouth being



simply kept perfectly clean and sweet by the frequent use of Condy's fluid. Within a week of the operation she left her bed, and within three weeks she was discharged from the hospital. Five months later the patient wrote to say that she had enjoyed perfect health since she had left the hospital. On microscopic examination the tumour proved to be simply fibrous. It had been growing for a year before removal. Notwithstanding that a great part of the framework of the face had been taken away, and that a portion of the orbital plate was removed at both operations, there was remarkably little deformity of the face. The patient had lost all power of muscular expression, but beyond this there was nothing to attract attention, except a slight falling in of the upper lip on the right side. There was no falling in of the nose, the raphe of what was the roof of the mouth deriving great support from a firm pseudopalate, which had formed of cicatricial tissue after the first operation. The cicatrices of the incisions were scarcely noticeable, as they followed the natural lines of the face."

Mr. Canton has obliged me with the portrait and history of a case of still more marked myeloid disease of the upper jaw, which was also under his care. The patient was forty-six years of age, which is decidedly advanced for the disease, and the tumour grew with unusual rapidity. Mr. Canton removed the jaw in Dec. 1866, and I had the opportunity of seeing the patient in Jan. 1867, when he was quite well, but had still a small fistulous opening on the face. Dr. Tonge carefully examined the tumour (which is preserved in the Museum of Charing Cross Hospital), and has kindly furnished me with the following report upon it and upon the microscopic appearances it presented:—"The tumour was about the size and shape of a large hen's egg that had been flattened slightly in the transverse direction, and measured (after being in moderately strong spirit for some days) about two and three-quarter inches in length, from one and three-quarters to two inches transversely, and about one and a half inch in thickness. It was of firm consistence throughout, and on section presented a whitish appearance, with



a small pink patch or two, and a whitish, creamy-looking juice could be scraped from the cut surface. The microscopical appearances of a portion of a thin section of the tumour, that had been preserved in glycerine and coloured with carmine, are represented in the accompanying drawing, which was taken with the aid of the camera lucida. The fibrous element was much less abundant than the cellular, and consisted of white fibrous tissue, with numerous fine curling fibres of yellow elastic tissue, and many small oval and rounded nuclei were imbedded in the fibrous structure. The greater portion of the tumour seemed to be composed of cells. These were mostly of an irregularly-rounded form, often with pointed processes, and some shuttle-shaped and spindle-shaped, of a somewhat trapezoidal form, were not uncommon, while a few cells presented the character of those distinctive of myeloid tumours. All the cells contained one, and often two, very large and generally oval nuclei, with one, two, or three nucleoli, and a variable number of oil globules. The myeloid cells observed were of irregular outline, and contained from three to five nuclei, with single or double nucleoli—one very large cell contained six nuclei.

“These cells were not very numerous, but appeared sufficiently so to justify the application of ‘myeloid’ to the tumour, though, to the naked eye, and on a superficial microscopical examination, it presented many of the appearances of cancer.”

In the Museum of the College of Surgeons are two specimens (2245 and A), the two superior maxillæ of a woman, aged twenty-one, which were given me by Messrs. Andrews and Coates, of Salisbury, who removed them. The left upper jaw has been macerated, showing a calcified tumour springing from the anterior part; the right jaw has a growth involving the anterior portion extending into the nasal fossa. The growth in these cases was regarded by the operators as an example of scirrhus, but I am enabled by the kindness of Dr. Lush, of Weymouth, to correct this statement, by a record which he has of the microscopic details observed when the tumours were recent, as follows:—



"A section showed numerous spheroidal cells with one, two, or more nuclei, free matter and some compound cells." The tumour should therefore doubtless properly be regarded as myeloid. The history of the patient is the following:—Jane F., aged twenty-one, was admitted into the Salisbury Infirmary, July 24, 1858, for a tumour of the left upper jaw. The operation of removal of the left upper jaw was performed by Mr. Andrews, and she was made an out-patient Aug. 28, 1858. She was readmitted on Oct. 1, 1859, under Mr. Coates, having a fortnight before perceived a small growth occupying the edge of the alveolar process at the site of the left upper incisor, which became rapidly exquisitely painful, and involved the alveolus of the right side, and also the upper lip. Mr. Coates removed the remaining right superior maxilla under chloroform, Oct. 13, 1859. The portion of the lip covering the small tumour (which was about the size of a hazel-nut) was also removed, and found to be infiltrated with disease. The patient was discharged cured Nov. 5, 1859, and was in perfect health in 1866.

Vascular tumours of a non-malignant character, but closely resembling erectile tumours in other parts of the body, have been occasionally met with in the upper jaw, though the majority of the pulsating tumours of bone are examples of vascular sarcoma. Mr. Liston, in 1841, successfully removed a specimen of the kind, which is preserved in University College, from a young man aged twenty-one. The tumour was of more than three years' growth, and projected into the nares and pharynx, forming a tumour beneath the cheek; but the preparation shows that the alveolus and all the lower and anterior part of the maxilla were not involved in the disease. The tumour was not painful, but frequent hæmorrhages had taken place from its surface. The case will be found in the *Lancet*, Oct. 9, 1841. Mr. Liston removed the jaw, cutting completely beyond the disease, and remarks concerning it (*Lancet*, Oct. 26, 1844):—"It was a curious-looking tumour, and it struck me that it was of a fibrous character, not growing from the jaw, but involving it. Mr. Marshall some months afterwards discovered that



the whole mass was erectile. . . . You will see that it is as complete and beautiful a specimen of an erectile tumour as any that I have yet shown you."

The tumour, which is in the Museum of University College (684), is described as follows in the catalogue by Mr. Marcus Beck:—"A large tumour of the pterygo-maxillary fossa removed with the upper jaw. The specimen includes the whole of the maxilla except a narrow strip of its palatine process, and small portions of the nasal and malar processes, the whole of the lower part of the palate bone, and the lower portions of both pterygoid plates of the sphenoid, and the inferior turbinated bone.

"The tumour, which measures about three inches in the antero-posterior direction, has grown from the posterior surface of the maxilla, and filled the spheno-maxillary and lower part of the temporal fossæ, and has passed far backwards under cover of the ramus of the inferior maxilla so as, on the inner side, to have projected within the pharynx; and from the anterior part of the tumour a portion has grown forwards beneath the hard palate into the mouth. The posterior half of the tumour is deeply cleft into lobes. On the inner aspect of the parts a piece of the tumour has been cut away; the divided surface has a uniformly open, cavernous structure, like that of the corpus spongiosum penis, the meshes of which are nowhere occupied by a solid substance, and probably allowed of the circulation of blood through them. The tumour is everywhere bounded by a dense layer of fibrous tissue. The cavity of the antrum is entirely unaffected."

M. Gensoul also met with an erectile tumour springing from the antrum, in one of the cases from which he successfully extirpated the upper jaw.

Mr. Butcher, of Dublin, has described ("Operative and Conservative Surgery," p. 249) a case of successful removal of the right upper jaw, on account of a large fibro-vascular tumour springing from the antrum of a lad of sixteen. Nine months before admission he had had a polypoid growth removed from the nostril, giving rise to severe hæmorrhage. It



reappeared in a month, and increased, so that when he came under Mr. Butcher's care there was considerable deformity of the face, and the nostril was filled with the tumour, which projected behind the soft palate. After the boy had been in hospital a few days the tumour suddenly increased with great rapidity, and interfered so much with respiration and deglutition that Mr. Butcher at once removed the jaw, and the patient made a good recovery.

The following is the description given of the tumour:—  
“The structure of the tumour presented many interesting peculiarities. Its attachment and origin sprang from the outer part of the antrum. Not only was it incorporated with the lining membrane, but it likewise implicated the osseous wall. The surface from which it sprang in the recent state was softened, vascular, and pulpy, the upper surface of the tumour was lobulated where it encroached upon the orbit, and elevated its floor; the lobules were of various sizes—some very small, but each consistent in structure, and invested by a dense capsule in a similar way to the larger masses of the growth. The entire tumour was remarkable for its great vascularity, which was more particularly confined to the posterior and upper surface; while on section the structure was dense by comparison, pale, eminently firm, and partaking of a fibrous matted nature. This integral arrangement was very manifest under close examination with the microscope, and cleared away the suspicion which, on superficial inspection, might have been created of encephaloid disease being the synonym most applicable to the growth. There was a total absence of all nucleated cells, either globular, caudate, or spindle-shaped; and, above all, the section of any part only yielded a minute quantity of serum or blood on pressure, and not the true succus of cancerous tissue. The tumour, though destructive to the neighbouring parts by pressure, yet did not appropriate or incorporate them in its structure. This peculiarity of non-malignant growths was strikingly manifest in the present instance; for by pressure, producing interstitial absorption, the cancellated structure of the ethmoid and infe-



rior spongy bones was attenuated and removed; and by the same process the vomer was detached from its position—a few shreds of it being spared and hanging loosely on the sinistral surface of the tumour. The vascularity of the growth, though remarkable on the surface, yet did not permeate its texture; hence a tendency to degenerate by assumed depravity of action was lessened. Again, the vascularity of the surface will readily account for the repeated and profuse losses of blood—a point of great practical value, because placing the surgeon on his guard as to the importance which should be attached to those repeated losses, in constituting a diagnostic feature confirmatory of malignant disease.”

*Chondro-sarcoma*, in which spindle- or round-celled sarcomatous elements are mixed with the cartilage forming the bulk of the tumour occurs occasionally in the upper jaw, and is apt to be followed by secondary deposits in the lungs, this clinical fact distinguishing it from the ordinary enchondroma. In 1879, I was consulted respecting a young lady who, two years before, had had removed from the floor of the orbit a small growth which grew from the orbital plate and displaced the eyeball. The growth recurred, and when I saw the patient both nostrils were completely blocked; there was slight bulging of the antrum, and nobbly swellings of the size of a sixpence on the raphe of the hard palate on the left side, and another on the right side of the palate. The frontal bone also seemed affected. I advised against an operation, but another surgeon removed the upper jaw, and was unable to take away the whole of the disease, which proved to be chondro-sarcoma.

*Ossifying Sarcoma* and *Osteoid Chondro-sarcoma* imply the occurrence of ossification in tumours containing sarcomatous elements, and include the cases hitherto described as “osteoid cancer.” A good specimen of the kind is preserved in the Museum of the College of Surgeons (1712), of which the history with an accompanying drawing is recorded in Mr. Howship’s “Surgical Observations.” The specimen has been macerated, and the part which remains consists of an oval



mass of light cancellous bone, about five inches in its chief diameter, and very slightly connected with the remaining bones of the face. At its lowest part it preserves somewhat of the form of the alveolar border of the upper jaw, and the incisor, canine, and bicuspid teeth are implanted in it.

The patient was a woman, aged thirty, who died in the Westminster Hospital from hæmorrhage, consequent upon the extraction of some teeth from the tumour in question, which is described as "fleshy," and of a florid red colour where it appeared in the mouth. The tumour had been growing five years. No details are furnished by Mr. Howship as to the post-mortem examination of this patient, but the skull shows a very important feature—a circular portion of the frontal bone just above the right temple, which is thin and perforated by several small apertures, apparently in consequence of the growth of a tumour from the dura mater. There is thus evidence of a secondary growth within the skull; and taking the history of the case together with the specimen, I am inclined to regard this as an example of sarcomatous disease.

O. Weber quotes from Titman (1757) a remarkable case which he considers of the same kind. The tumour was in a youth of fourteen, and had been growing for four years, and finally occupied the entire face. It had displaced the eye, the nose, and the lower jaw, and projected in such a way into the mouth and fauces that the patient died of inanition. The mass weighed six pounds, and on being cut through was quite white, and very hard, and had radiating masses of bone interspersed through its substance.



## CHAPTER XX.

## MALIGNANT TUMOURS OF THE UPPER JAW.

*Round-celled Sarcoma and Epithelioma.*

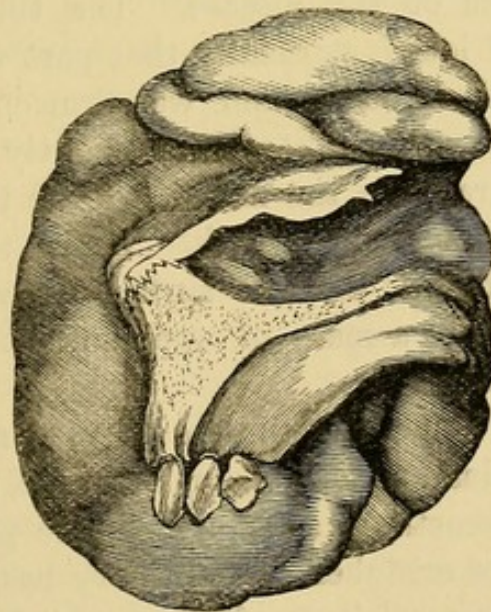
*Round-celled Sarcoma* or medullary sarcoma is of frequent occurrence in the upper jaw, and from its vascularity and rapidity of growth it has often been mistaken for medullary cancer, which in its clinical history it closely resembles. In the majority of cases the disease begins in the antrum, for the protruding masses, which are found in the nose or mouth, are but secondary to a formation within that cavity. One of Mr. Liston's cases is conclusive on the point, the preparation being preserved in the College of Surgeons (1059), with the following description :—"The greater part of a left superior maxillary bone, with a tumour formed in the antrum, removed by operation. The tumour measures about two inches in its greatest diameter, and projects forwards over the right canine and bicuspid teeth. It is pale, soft, and homogeneous, and the surface of its section is like that of brain. At the upper part its tissue is broken, and was mixed with blood: in its recent state it was more brain-like. The patient, William Thomson, was sixteen years old. The disease had been observed for two years. He had often suffered pain in the situation of the first molar tooth, which had been in a decayed state for a considerable time previous to his discovering any swelling of the cheek. During the two months preceding the operation the tumour had grown rapidly. Three years and a half after its removal the patient was in good health."—See Liston's paper, *Medico-Chirurgical Transactions*, vol. xx. In this case,



which was fortunately submitted to operation at a very early period, the disease was still confined to the antrum, and the removal of the jaw therefore included the whole of it. Unfortunately, in too many cases the disease is much more advanced before it is brought under the notice of the surgeon, when therefore the possibility of complete extirpation is much reduced.

Medullary sarcoma of the jaw closely resembles the same disease in other parts of the body, rapidity of growth, with softness, and a tendency to fungate on the part of the tumour itself, being the main characteristics. The direction which the disease takes, and the effects therefore which it produces, will vary in different examples. Frequently it forms a considerable projection on the cheek, causing epiphora from closure of the nasal duct, and œdema of the lower eyelid; and in the later stages enlargement of the facial veins, without the least invasion of the hard palate, and with but slight interference with the nostril. The specimen of medullary sarcoma represented in fig. 139 (College of Sur-

FIG. 139.



geons' Museum, 2243), illustrates the point, a large tumour being developed externally. The patient was a man, aged forty-four, who came under the care of Mr. Craven, of Hull, in 1863, with a large rounded tumour of the right cheek, of



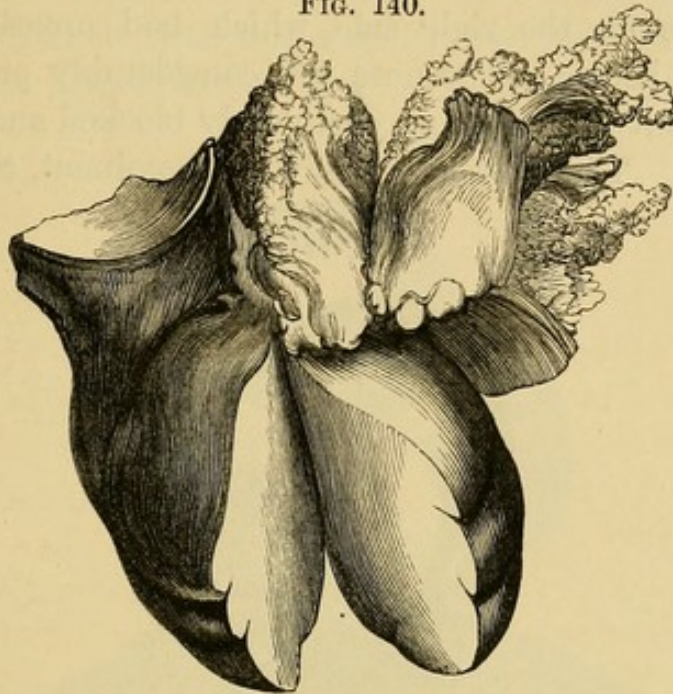
the size of an orange, extending from the external process of the frontal bone and zygoma above, to the angle of the mouth below (almost completely closing the right eye), and from the side of the nose to the ramus of the lower jaw. The colour of the integument was natural, except at the upper part below the eye, where it presented a rather livid appearance, and several veins, not of large size. It was very firm to the touch, but elastic, especially at the outer part. Pressure and handling caused little or no pain. The interior of the mouth on the right side, from the alveolar process (which was concealed by the growth or embraced in it) to the inside of the distended cheek, presented a large excavated sore of a greyish sloughy aspect and foetid odour. This part of the tumour was softer to the touch than that which showed itself externally. It did not encroach on the palate, which was of the natural width. There were no enlarged glands beneath the jaw. The patient seemed a pretty healthy man. The tumour had been growing seventeen weeks. Mr. Craven excised the tumour, and the patient made a good recovery, but died fifteen months afterwards from a recurrence of the disease. The tumour (fig. 139) was rounded and lobed, especially that part which occupied the pterygo-maxillary fossa, and was firm on section. The cut surface was smooth, becoming slightly granular after prolonged exposure. To the naked eye the tumour had the appearance of a malignant growth. Under the microscope, the juice scraped off the cut surface showed no fibrous element, but simply a mass of apparently broken-up cells and granular matter.

On the other hand, the disease may at an early period involve the alveolus and palate, or the nose, and it is these cases which are sometimes attributed to the presence of decayed teeth, or are mistaken for ordinary nasal polypi. Of this, a preparation (College of Surgeons' Museum, 2248), which is shown in fig. 140, and was also from a patient of Mr. Craven (to whom I was indebted for both valuable preparations), is an instance. Here the disease showed itself first in the gums, where it formed a fungating mass, and



soon obstructed the nostril. This last symptom was due to a fungus, almost papillary in appearance, which springs from the nasal surface of the tumour. Mr. Craven removed

FIG. 140.



the tumour in March, 1866, but within a year the disease returned and proved fatal.

The disease may extend across the median line, and involve portions of both maxillæ, especially the palatine plates. This is not necessarily a bar to operative interference, provided other circumstances are favourable, but when the disease exhibits the appearance shown in fig. 141, the case is obviously one beyond the aid of surgery. The patient, aged twenty-four, was sent to me in January, 1868, by Mr. Harding, to whom he had applied for the extraction of some teeth, thinking to obtain relief thereby. Four and a half years before he had got a blow on the face from a cocoa-nut, which broke the left canine tooth, and a year before I saw him, the left side of the face swelled up, but subsided again. In August, 1867, he first noticed a growth below the left eye, which rapidly increased, but even before this the interior of the mouth was tender, and felt swollen and soft to the touch. He had good advice in the



country, and subsequently was in a London hospital, but operative interference was declined by the surgeon under whose care he was. When I saw him, some months later, there was a large soft tumour of the left upper jaw, and a smaller one on the right side, which had appeared about four weeks before. The nose was considerably projected by these, the left nostril being completely blocked and the right slightly so. The alveolus was very prominent, so that the

FIG. 141.



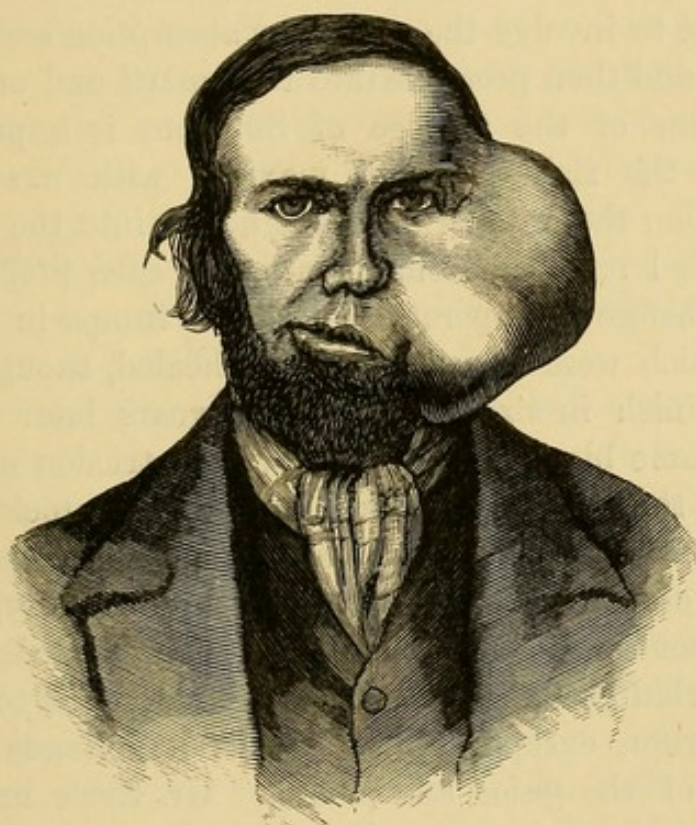
incisor teeth sloped backwards, and there were soft masses of disease on each side of the palate. Within a week or ten days of my seeing the patient the lymphatic glands in the neck had become enlarged, particularly on the right side, where a considerable tumour existed. This melancholy case was obviously totally unfitted for operation at the time I saw it, whatever might have been its prospects at an earlier date. I could therefore hold out no hope of alleviation to the unfortunate patient, who returned to the country.

Round-celled sarcoma occasionally involves both upper and lower jaws, beginning, I believe, mostly in the upper and extending to the lower. Fig. 142 shows a good instance



of this in a man who was under my care in 1877, with an enormous swelling of the left side of the face. I ventured, under chloroform, to introduce my finger into the mouth to explore the extent of the growth, but I found it so extensively attached to both upper and lower jaws that removal was clearly impossible. The examination gave rise to

FIG. 142.



sharp hæmorrhage, due to the great vascularity of the growth and this was checked with some difficulty with the persulphate of iron.

I met with the same implication of the lower jaw, though to a lesser extent, in a lady, from whom I removed the upper jaw in consultation with Dr. Cæsar. In this case the coronoid process was involved and was removed with bone-forceps, but recurrence of the disease took place and the patient did not survive the operation four months.

*Epithelioma* occurs in the upper jaw in two forms, the squamous and columnar; and the former, which always begins in the gum or palate, has already been described



(p. 257) in connection with the antrum. Columnar epithelioma always begins in the antrum, which it often fills, and then secondarily involves the palate; or it may attack the outer wall only of the antrum, and then protrude on the face. Occurring usually in patients over forty years of age, the disease begins very insidiously, the patient complaining, perhaps, of neuralgia or of uneasiness in the face, but of little more. When the antrum has become distended, the epithelioma is apt to involve the palate by absorption and eventual fungation, and then protrude into the nostril and orbits. In the Museum of the College of Surgeons is a preparation (2235) of the right superior maxilla, with a soft white tumour filling the antrum and protruding into the nose and orbit, which I removed from a gentleman aged fifty-one, who five years before the operation, noticed "lumps in the hard palate," which were lanced, but never healed, though appearing to diminish in size. About four years later his right nostril became blocked, and there was protrusion of the eye. I removed the jaw very freely, but recurrence took place at the back of the orbit, and it became necessary to remove the eyeball in order to clear out the growth effectually, but even now it is not certain that a cure has been effected.

The morbid growth in this case is unattached to the wall of the antrum, except behind, where it extends into the substance of the gums and palate. Mr. Eve's microscopic examination shows it to consist of closely packed and very tortuous columns of small round epithelium; a few of them had a lumen, around which the cells were arranged in a regular manner, as in tubular glands. The stroma was composed of sarcomatous tissue. This case is one of unusual duration for an example of pure epithelioma, and the fact that the tumour is a mixture of epithelioma and sarcoma probably gives the clue to it, although the subsequent history is distinctly that of epithelioma.

The more usual rapidity of growth of epithelioma of the upper jaw is well illustrated by a case I attended with Mr. Sams, of Blackheath, in the latter part of 1871. A lady aged fifty-two, had noticed a small growth in the gum of the



left upper jaw, which gradually overlapped the hard palate. This was removed by another surgeon in May, 1871, but the growth reappeared almost immediately. In November I found a fungus-looking mass involving the greater part of the left half of the hard palate, the bone of which was absorbed, and bulging up beneath the cheek. I removed the left half of the hard palate, with the whole of the growth, on November 24. In ten days the growth reappeared on the apparently healthy section of the hard palate and also in the cheek. A fortnight after the first operation I therefore again operated very freely, applying, as on the former occasion, a strong solution of the chloride of zinc to the entire wound. Again, within ten days, the disease reappeared and rapidly filled up the cavity left by the operation, blocking the nostril and mouth, and eventually suffocating the patient in her sleep, on December 29.

Even when the disease is far advanced, however, so that the tissues of the face and mouth are much involved, it is sometimes possible for the surgeon to give relief, if not permanent cure, by completely excising the morbid structures.

A case intermediate between the two foregoing in rapidity, and illustrating the advantage of operating in cases of epithelioma where a cure cannot be hoped for, was under my care during 1882-3. A lady, aged fifty-two, was sent to me in March, 1882, by Sir Spencer Wells, with the following history:—A month before Christmas, 1881, she had noticed a swelling of the left cheek, and when I saw her had a uniformly elastic swelling involving the left upper jaw, and spreading up the margin of the left orbit. The skin was tense and reddened, but not involved apparently, and the palate was healthy. I recommended removal, with the view of prolonging life, and in this view Mr. Erichsen coincided, but two eminent surgeons had given a contrary opinion.

On March 24 I turned back a flap of the cheek, and found the tumour well covered with fascia and the skin healthy. I opened the temporal fascia, so as to isolate the growth behind, and divided the zygoma afterwards, clearing the malar bone, and sawing the external angular process of the



frontal bone. The palate was then sawn through, and the jaw readily removed. The remains of the hard palate were removed with bone-forceps quite up to the pterygoid process, which was healthy, and the parts were freely cauterized to make doubly sure. The patient made a good recovery, and left town much relieved on April 19.

In September I saw her again, when there was an epitheliomatous fungus at the outer angle of the wound measuring  $1\frac{1}{2}$  inches across. No glands were enlarged, and the patient's health continued good. On September 28, I removed the growth and surrounding skin freely with Paquelin's cautery, and applied chloride of zinc paste. The mouth and cavity left by removal of the upper jaw were quite healthy, but the mouth could not be opened freely because the surface of the lower jaw had become involved by the disease in the cheek. On October 10 a recurrence of disease at the bottom of the otherwise healthy wound was noticed, and the caustic paste was re-applied.

In November the patient returned with one small spot of epithelioma at the bottom of the wound, involving the mucous membrane of the mouth. This was thoroughly destroyed with caustic paste, and the parts were quite sound when the patient went home. In February, 1883, there was a fresh recurrence in the cheek, but the patient was too weak to bear treatment, and she died in April, having survived the first operation more than a year in comparative comfort, and with no formidable external tumour.

The preparation from this case (College of Surgeons' Museum, 2246) shows a growth springing from the mucous membrane of the antrum, which in places is ragged and has a papillary appearance. Mr. Eve reported that under the microscope the mucous membrane of the antrum was observed to be exceedingly thickened by an overgrowth of epithelium, for the most part of an elongated form.

This condition corresponds very closely to that of another upper jaw removed by me in 1866, and now in the Museum of the College of Surgeons (2247 A.), which in former editions of this work I described as an example of "fibroid

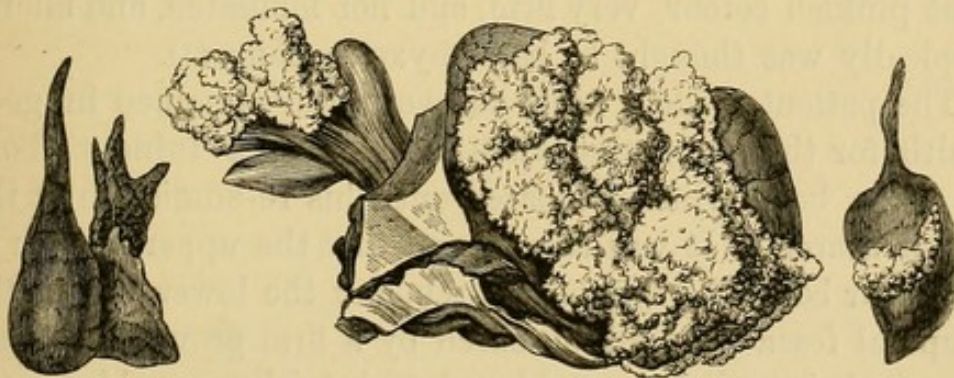


disease," but which is, I believe, really epitheliomatous. In September, 1866, Dr. Whitmarsh, of Hounslow, brought to me a gentleman who, two years before, had perceived some growth in the right nostril, which gave no pain, but kept up a constant discharge, especially at night. In the early part of the year this had been removed in part by a surgeon, and since that the discharge had much increased. There was a fungous growth in the right nostril, and the whole right maxilla was swollen and discharged thin pus at one or two points near the eye. There was a fungous-looking growth in the molar region, and a probe passed by its side into the antrum.

I removed the disease on September 23, clearing away the whole of the growth, which was very friable, and leaving the posterior wall of the antrum and the infra-orbital plate untouched. In the course of the operation I found a distinct polypoid growth filling the posterior nares, which I removed. The patient rallied well from the operation, but unfortunately got congestion of the lungs and died on the fifth day.

The preparation is in the College of Surgeons' Museum (1052 B), and the appearance of a part of the disease is shown in fig. 143. It will be seen that the interior of the

FIG. 143.



antrum is covered with a remarkable papillary or villous growth, resembling some forms of cauliflower excrescence. A quantity of broken-down loose fibroid tissue lies at the bottom of the bottle of the preparation, and a portion of it, with the adjacent mucous membrane, is given in the sketch; the



other portion being the polypoid growth extracted from the posterior nares. Mr. Bruce favoured me with the following report upon the specimen:—

“It appears to consist of a fine soft fibrous stroma, in which very numerous nuclear bodies and a few elongated fibre cells are distributed. Its structure resembles that of the upper strata of a mucous membrane, from which it is probably an outgrowth.”

I have at present under my care a very interesting case of epithelioma, beginning in the outer plate of the upper jaw in an otherwise healthy man, aged fifty-three, who in October, 1882, came into University College Hospital with a swelling of the right cheek about  $1\frac{1}{2}$  inches broad, extending from the nose to the zygoma, and clearly connected with the superior maxilla. The mouth and nostril were in no way involved, and I therefore determined to remove only the part of the maxilla affected—viz., its anterior surface. This I did by reflecting the skin and prolonging the infra-orbital incision to the malar bone, which I sawed through. Then dividing the nasal process, I was able to break away the anterior wall of the antrum with the tumour, leaving the palate untouched. The tumour was 3 inches long and 2 broad, and grew from the outer wall of the antrum, which it had not penetrated. The substance of the growth was of a faint pinkish colour, very firm, and not lobulated, and microscopically was thought to be a myxo-sarcoma (?).

The patient made a rapid recovery and remained in good health for three months, when he noticed a fulness above the malar bone, which increased until his re-admission at the end of March. It was then found that the upper margin of the malar bone, the zygomatic arch, and the lower part of the temporal fossa were all obscured by a firm growth, the skin over it being slightly reddened and fairly movable. On March 29, 1883, I exposed the new growth and isolated the bone to which it was attached, by dividing the zygoma far back and the external angle of the frontal bone; but on breaking the malar bone away with the tumour I found that the antrum was now filled with new growth, and therefore



removed the superior maxillæ in the usual way, afterwards applying caustic paste to the exposed surface. The soft material now filling the antrum was clearly epitheliomatous. The patient again made a good recovery, but in June it became necessary to remove the eyeball,<sup>6</sup> which had suppurated. In November the patient again presented himself with a perfectly healthy cicatrix in the mouth and wearing an artificial palate, but with the lower and part of the upper eyelids infiltrated with epithelioma which had sprung up in the neighbourhood of the old cicatrix below the eye. This I removed freely with Paquelin's cautery, and subsequently applied caustic paste freely, the disease being entirely outside the cavity of the mouth.

In some cases of epithelioma it is impossible at the time of the operation to remove the whole of the disease. Of this an example will be found in the Appendix (Case XI.), where the tissues of the orbit were found to be extensively involved. This case also illustrates the fatal consequences to which elderly and feeble patients seem specially liable after operations on the mouth—viz., to a low form of broncho-pneumonia, by some considered to be septic in its nature, which is rapidly fatal. The careful record of the post-mortem examination of this patient by Mr. Barker gives a typical example of the pathology of this disorder.



## CHAPTER XXI.

## DIAGNOSIS AND TREATMENT OF TUMOURS OF THE UPPER JAW.

THE diagnosis of tumours of the upper jaw is by no means simple. Even the distinction between fluid tumours due to cystic enlargement of the jaw and solid growths, is, as has already been pointed out, not always easy; and it is still more difficult, and in some cases impossible, to decide as to the malignancy or otherwise of a tumour previous to its extirpation.

The fibrous, cartilaginous, and osseous tumours are all of slow growth, painless, and more or less hard to the touch. They do not affect the general health, nor do they show any tendency to involve the surrounding tissues or the skin, except by mechanical interference. The fibro-sarcomatous and myeloid tumours are more rapid in their growth, and softer than those already mentioned; both are more vascular in appearance at points where they are covered only by mucous membrane. They occasionally ulcerate, but do not fungate, and may, under these circumstances, discharge blood in considerable quantities. The medullary-sarcomatous and epitheliomatous tumours are the most rapid in their growth, and their tendency to involve surrounding structures is early manifested. Its softness and tendency to fungate are the chief characteristics of epithelioma, but these must not be relied on too implicitly. This last variety is ordinarily more painful than the others, the patient frequently complaining of neuralgic or gnawing pains in the head and face.

In examining a case of tumour of the upper jaw, a careful inspection should be made of the face, mouth, and nares. The consistency of the projection beneath the cheek should



be tested with the finger both outside and inside the cheek itself. The condition of the hard and soft palate should be particularly investigated, and the finger should be carried behind the soft palate, if there is any suspicion that the tumour extends towards the posterior nares. The removal of a tooth may assist in the diagnosis, either by evacuating fluid, or by bringing away with it a small portion of growth which may be submitted to microscopic examination. The condition of the nostril will require especial examination, particularly in those cases where the disease shows itself at an early period in that cavity, and doubt arises as to its nature. The careful introduction of a probe whilst a good light is thrown into the nostril, will enable the surgeon to decide whether the tumour is merely a polypus springing from the turbinate bones, or whether it is a portion of an antral tumour showing itself in the nostril, or possibly some growth springing from the base of the skull and simulating maxillary disease.

*Prognosis.*—But little can be hoped from medicine in the treatment of tumours of the upper jaw. The application of iodine has been said by Mr. Stanley to have affected the removal of a small enchondroma, and no harm will be done by resorting to such measures and to the internal administration of absorbent medicines, for a short time whilst the progress of the disease is watched, provided no chemical agent be applied to the growth itself, by which it might be irritated or caused to inflame. Removal by surgical operation is, however, the only effectual means of treatment, and the sooner an operation is undertaken the better in all cases, since even a benign tumour may, by its size or by its attachments, put a patient's life in danger if allowed to grow unchecked for a series of years. In malignant disease the only hope for the patient is early and complete removal, whilst the disease is confined to the bone and before the surrounding structures have become affected.

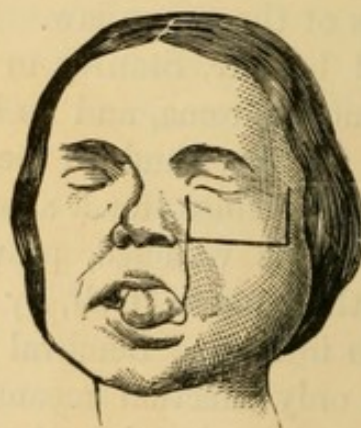
*Operations on the Upper Jaw.*—From early times portions of the upper jaw, and particularly the alveolus, were occasionally removed on account of some disease, and with more



or less permanent success. Mr. Butcher, who has laboriously investigated the subject, puts the earliest case in 1693, the operator being Akoluthus, a physician at Breslau. Desault, Garengeot, Jourdain, and others in the last century removed growths from the jaw, gouging them out with chisels with partial and temporary success; and Dupuytren especially advocated this mode of treatment in his "*Leçons Orales*," and frequently practised it, removing in this manner the greater part of the upper jaw in 1824. Charles White, of Manchester, appears also to have successfully operated on a patient, from whom he removed, piecemeal, nearly the whole of the upper maxilla during the last century.

The late Mr. John Lizars, of Edinburgh, appears to have been the first to propose removal of the entire superior maxilla as a whole in 1826, when, in his "*System of Anatomical Plates*," he showed how, anatomically, it would be possible to remove the bone without injury to important

FIG. 144.



and vital parts, and recommended the previous deligation of the common carotid artery, with a view of preventing hæmorrhage. Mr. Lizars did not have an opportunity of carrying his proposition into effect until December, 1827, when, notwithstanding the ligature applied to the carotid, the hæmorrhage was so fearful as to necessitate a discontinuance of the operation (*Lancet*, 1829-30). M. Gensoul, of Lyons, had, however, forestalled Mr. Lizars quite independently and without being aware of his proposition, for



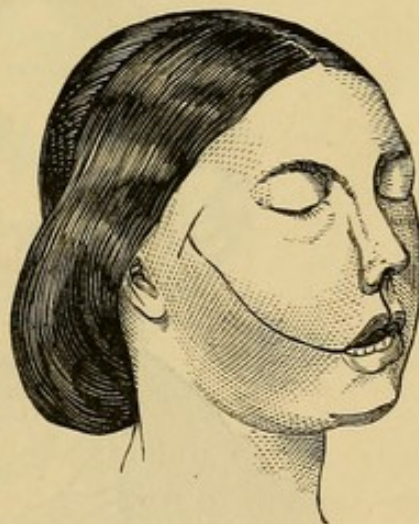
in May, 1827, he removed the entire superior maxillary bone, with a part of the palate, from a boy of seventeen, on account of a large fibro-cartilaginous tumour. The incision employed by Gensoul (fig. 144) was a vertical one from the corner of the eye to the lip, joined midway at right angles by a transverse incision, which was again met by a small vertical incision ascending to the malar bone. By the employment of the mallet and chisel the jaw, with the tumour, was dislodged and removed by the division of the palate. Although the carotid was not tied the hæmorrhage was not very great, and the patient recovered.—(*Lettre Chirurgicale sur quelques Maladies Graves du Sinus Maxillaire*, par A. Gensoul).

Mr. Syme operated successfully in May, 1829 (*Edinburgh Medical and Surgical Journal*, 1829), and Mr. Lizars also operated again in 1829, for a medullary tumour, which was completely removed with the exception of a small portion attached to the pterygoid processes. The patient had

FIG. 145.

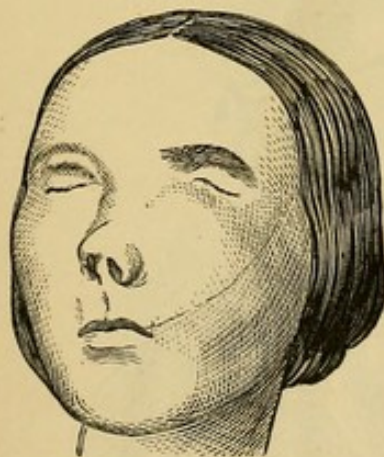

FIG. 146.



become quite convalescent, when she died suddenly on the nineteenth day (*London Medical Gazette*, vol. v. p. 92). His third and successful operation was in 1830 (*Lancet*, 1829-30), and from that time removal of the upper jaw became an established operation in surgery. Mr. Lizars used an incision across the cheek from the angle of the



mouth to the malar bone (fig. 145), or when the tumour was very large, employed in addition an incision through the lip into the nostril, with a vertical cut at the malar bone (fig. 146). With the saw and bone-forceps the maxilla was separated from its attachments and removed.

Lizars' example was followed by most of the leading surgeons of the day, but Mr. Liston requires especial notice, since he performed some of the earliest and most important operations of the kind, and in his essay, which has been frequently referred to (*Medico-Chirurgical Transactions*, vol. xx.), brought the subject and its relations to various forms of disease prominently under the notice of the profession. Mr. Liston seems to have been strongly impressed with the notion that malignant disease of the jaw should not be interfered with, but this idea does not prevail among operating surgeons of the present day, for it is felt that it

FIG. 147.



is better to act upon the principle which guides operations upon cancerous growths in other parts of the body—to



remove the growths, if feasible, in the hope of giving at least relief if not a permanent cure.

Syme, Mott, Velpeau, Dieffenbach, O'Shaughnessy, Heyfelder, Fergusson, and Butcher may be mentioned as having performed the operation of excision of the superior maxilla repeatedly and successfully, and to Sir William Fergusson especially is due the proposal of modifications of the greatest moment in the method of procedure. Noticing the considerable deformity resulting from an incision from the angle of the mouth, which necessarily divides the facial nerve (fig. 147), and still more when a flap of skin has been reflected from the face by a double incision (fig. 56), Sir William Fergusson devised the plan of carrying the

FIG. 148.



incision solely through the median line of the lip into the nostril. By dissecting up the tissues of the nose and taking advantage of the stretching of the skin of the nostril, room may thus be obtained for the removal of any tumour not of large size; but supposing this to be found impracticable,



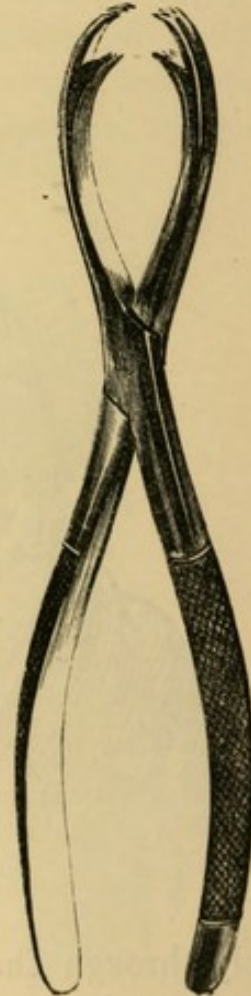
it is still open to the operator to prolong the incision round the ala and up the side of the nose, and in the case of large tumours, to carry it in a curve below the orbit to the malar bone, as seen in fig. 148. The great advantages of these methods are that the facial nerve and facial artery are divided at points where their size is of no consequence, and consequently the loss of blood and the subsequent deformity are much diminished; and also that the scars fall in such positions as to be hardly noticeable.

The method of proceeding which I recommend when it is necessary to remove the entire upper jaw is as follows:—

FIG. 149.

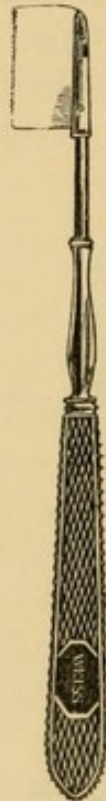

FIG. 150.



The skin having been reflected in the manner described above, the incisor teeth of the side to be removed are extracted and a narrow saw with a movable back passed into



the nostril. With this the alveolus and hard palate are divided, and a small saw (fig. 149) is then applied to the malar bone in a line with the spheno-maxillary fissure, and to the nasal process of the superior maxilla, so as to notch both these points of bone, the division being completed with the bone-forceps. With the "lion-forceps," devised by Sir William Fergusson for the purpose (fig. 150), the jaw can now be grasped and broken away from the pterygoid process and palate bone, any detaining point being severed with the bone-forceps. Lastly, when the bone is quite loose, the infra-orbital nerve is to be severed, and the soft palate divided at its attachment to the bone, so as to leave as much of it as possible uninjured, and any remaining portions of disease are then to be removed with the bone-forceps and gouge. Hæmorrhage is to be arrested by ligatures and the application of the actual cautery to the deep tissues, and, finally, the lip and incision are to be brought together and carefully adjusted with hare-lip pins and interrupted sutures of fine wire or silk.

When the disease is of less amount, and the orbital plate is not involved, this should be preserved by carrying a saw horizontally below it; and if the palate is not involved, this may be advantageously kept intact by making a similar cut immediately above it. Under these circumstances the incisions through the skin need only be very limited, and the bone-forceps and gouge will be requisite to clear out all the disease from the antrum.

Sir William Fergusson has, in his "Lectures on Anatomy and Surgery," strongly urged the pursuance of a less heroic plan than that which has hitherto been followed, in going completely beyond and not interfering with the diseased tissues. According to that eminent surgeon, it is better to cut into the disease and to clear it out by working from the centre to the circumference, so as not to remove healthy structures unnecessarily, and this may be accomplished by means of curved and angular bone-forceps of various sizes, and by the use of the gouge. Mr. Syme (*British Medical Journal*, Aug. 12, 1865) denounced this method as a return



to "the old system with its chisels and gouges;" but the practice, as regards non-cancerous tumours at least, has recently received the strong support of Sir James Paget, who in a paper in the *Medico-Chirurgical Transactions*, vol. liv., has urged the propriety of enucleating simple tumours growing in the interior of bones, and among other cases gives one of a lad of nineteen, from whose antrum he successfully removed a large mass without injury to the palate or orbit. A similar instance, under my own care, is given at p. 267. The case, is, however, different when the disease is of a malignant character, and, after some considerable experience, I am decidedly of opinion that the surgeon must go well beyond the boundaries of the tumour if he hopes to give the patient permanent relief. The practice of cutting into a malignant growth gives rise to considerable hæmorrhage, which renders it very difficult to be certain as to the removal of the entire disease. It is better, therefore, I think, to cut into the healthy bone beyond, so as to be quite certain of removing the entire growth, though it is by no means necessary to remove large portions of healthy structure.

In cases of epithelioma, where even the whole of the diseased structures have been removed, I would strongly advise the application of the chloride of zinc paste, made with hydrochloric acid and opium, after the formula of the Middlesex Hospital. Applied on the end of a strip of lint to the doubtful part, the rest of the lint can be packed in and covered over with a pledget of cotton-wool, so as to prevent the escape of the chloride of zinc into the mouth; and I have found it very advantageous to plug the posterior nostril on the affected side from the front with another strip of lint, so as to obviate the escape of fluid into the throat. After three days the plugs are easily withdrawn from beneath the cheek, and free syringing will keep the parts sweet while the sloughs caused by the caustic are separating. For washing out the mouth there is nothing better than the syphon nasal-douche with a soft nipple.

In cases of epithelioma in which the skin is involved, the



portion so diseased must be sacrificed if a cure is to be hoped for. This may be effected with the knife or the actual cautery, and I may refer to a very successful example of this method of treatment by Mr. Lawson, recorded in the *Clinical Society's Transactions*, vol. vi.

As a local antiseptic nothing is equal to powdered iodoform, freely applied to the raw surfaces both of bone and soft parts. In this way the cavity left by removal of the upper jaw may be kept sweet for days after the operation, and the patient be spared the risks of purulent infection or septic bronchitis.

It has been mentioned that in the earlier operations for removal of the upper jaw, it was customary to apply a ligature to the common or external carotid artery. Although this practice has now been quite abandoned, it has in a few cases been necessary to secure the main vessel after the operation, on account of secondary hæmorrhage. Thus Mr. Field, of Brighton, tied the common carotid two days after removal of the upper jaw, in 1858, and the patient recovered (*Medical Times and Gazette*, Aug. 28, 1858). In a patient of Mr. Holmes Coote, at St. Bartholomew's, in 1866, the house-surgeon, Mr. Orton, tied the vessel on the nineteenth day, but the patient sank (*Lancet*, Oct. 13, 1866). In his recent work on Cancer, Mr. O. Pemberton mentions a case which occurred in 1848, when he was house-surgeon at the Birmingham General Hospital, which also proved fatal.

As a rule, however, patients who have been submitted to removal of the upper jaw recover with wonderful rapidity. Of course the primary shock of such an operation is severe, but when this is once got over the convalescence is ordinarily rapid.

Removal of *both* upper jaws has occasionally been performed. A case in which Mr. Lane removed the greater part of both jaws has been referred to in this essay (p. 288), and the operation has been performed by Rogers, of New York (1824), Heyfelder (1844, and twice afterwards), Diefenbach, Maisonneuve, and others. Heyfelder made two incisions from the outer angles of the eyes to the corners of



the mouth, and reflected this quadrilateral flap to the forehead, taking the nose with it. He then passed a chain-saw through the spheno-maxillary fissure on each side, and thus separated the jaws and the malar bones. The junctions with the nasal bones and vomer were then divided with bone-forceps, and the soft palate separated from the margin of the hard. Lastly, powerful traction upon the bones was exerted, and the bones were displaced. Dieffenbach, Maisonneuve, and others, employed a median incision, beginning at the root of the nose and ending in the median line of the lip, so as to divide the skin of the face into two lateral flaps. This appears an unnecessary complication however, since division of the lip and free dissection of the nostrils would afford sufficient room for the removal of the jaw in two halves. A paper on Total Double Resection of the Upper Jaws, by H. Braun, of Heidelberg, will be found in Langenbeck's Archiv, xix. 1876.

In 1872, Mr. Dobson, of Bristol, removed both superior maxillæ of a woman, aged fifty-two, by dividing the lip in the middle line and carrying an incision up each side of the nose (*British Medical Journal*, Oct. 11, 1873), and Mr. Bellamy informs me that he has recently removed the greater part of both upper jaws by simply reflecting the lip without any external incision.

Dr. Charles Brigham, of San Francisco, has reported in his "Surgical Cases with Illustrations" (1876), an instance of successful removal of the entire upper jaw for malignant disease, after performing tracheotomy and plugging the pharynx with sponge. In a case of such extensive disease the preliminary tracheotomy was, no doubt, admirable, but for ordinary cases of removal of tumours of the upper jaw the proceeding seems to me uncalled for, as I have never employed it, and have only seen it employed on one occasion. Professor Trendelenburg's proposal to perform a preliminary tracheotomy, and to plug the trachea by a special expanding tampon in all serious operations about the mouth, was made in 1871, and will be found described at length in the *Medical Times and Gazette* for May, 1872. I have employed the



tampon once in operating on the tongue, and once (unnecessarily as it turned out) in operating on the palate; but the objection to it is, that the pressure exerted on the trachea is apt to produce great embarrassment of breathing and cough. Plugging the pharynx with a sponge, to which a string is attached, is a far preferable plan, and I strongly advise that the preliminary tracheotomy, if considered necessary, should be done a couple of days beforehand, so that the patient's windpipe may have become accustomed to the presence of the tube. A much more satisfactory plan, if it prove generally feasible, is that practised by Dr. McEwen, of Glasgow (*British Medical Journal*, July 24, 1880)—viz., to introduce a tracheal tube through the mouth for the administration of chloroform during operations in the mouth, the pharynx being plugged around the tube with sponge.

The fear of hæmorrhage in cases of removal of the upper jaw is exaggerated, I think, for there is no large vessel implicated until the last stage of the proceeding, when the bone is forcibly displaced; and then, if the operator is rapid in his movements and his assistants are prompt, pressure can be made with a sponge thrust into the cavity quite sufficient to prevent blood flowing into the fauces, until the operator is ready to pick up the bleeding vessel. I always provide myself with a small sponge, which I thrust into the posterior nostril of the affected side the moment the larger sponge held by an assistant is removed. This prevents any blood flowing into the pharynx, and allows of deliberate examination and the arrest of bleeding by the ligature or the cautery.

As regards the position of the patient I always have him recumbent, with the head fairly raised on pillows, and invariably employ chloroform as the anæsthetic, both because it is impossible to keep a patient under the influence of ether when air must necessarily be admitted very freely by the manipulations of the surgeon, and because of the danger of ignition of the vapour of ether in the patient's mouth by the application of the actual cautery.



Since it is unadvisable that a patient about to have a jaw removed should take food for four hours beforehand, lest sickness should be induced by chloroform or swallowing blood, I am inclined to recommend a practice, which I have lately followed, on the suggestion of Dr. Prince, of Jacksonville, Illinois (*St. Louis Medical and Surgical Journal*, Feb., 1883)—viz., to inject into the colon, shortly before a severe operation, a quantity of hot brandy and water, suited to the age and requirements of the patient. The ingenious rectal obturator devised by Dr. Prince, or a very similar invention of Mr. Edward Lund (*Lancet*, April 7, 1883), is by no means necessary, for the fluid, if injected with a fairly long enema tube while the patient is recumbent in bed, has little tendency to escape.



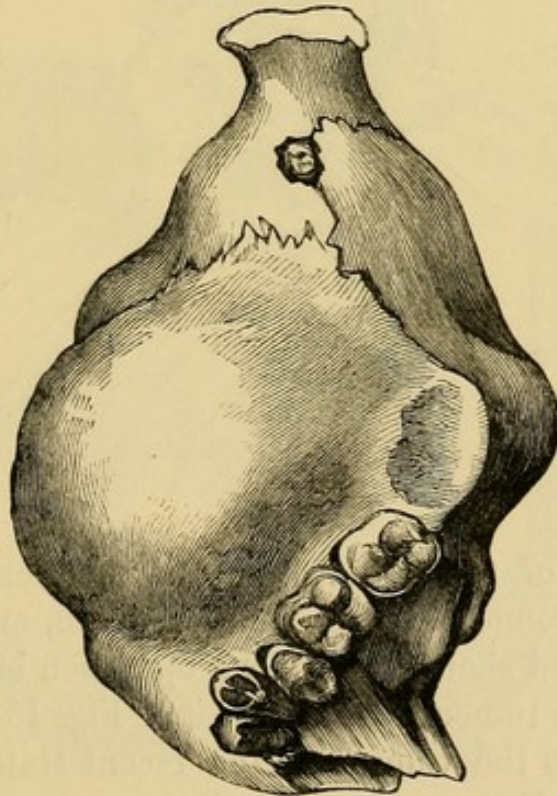
## CHAPTER XXII.

## NON-MALIGNANT TUMOURS OF THE LOWER JAW.

*Fibroma, Enchondroma, Osteoma.*

*Fibrous Tumour* is the commonest form of growth in the lower jaw, and, as pointed out by Paget, this may take the *endosteal* or *periosteal* form. The formation of fibrous

FIG. 151.

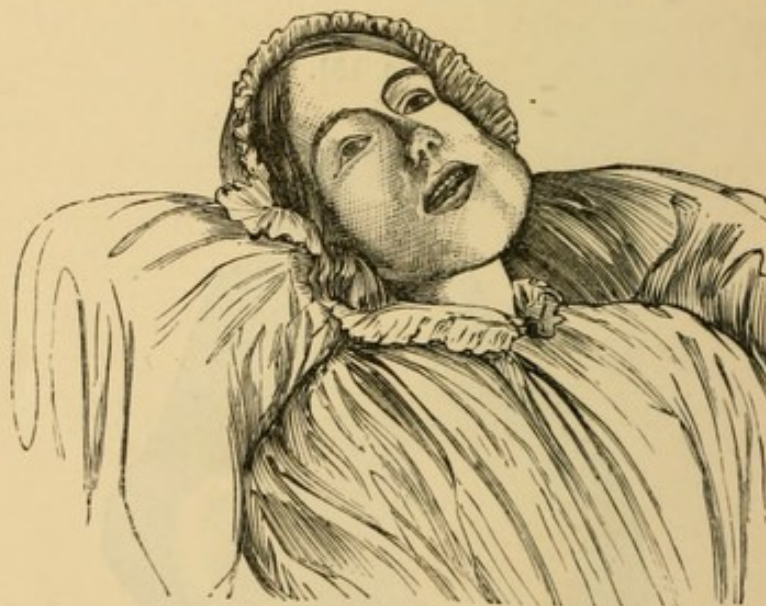

tumours between the plates of the lower jaw has been already referred to under the head of Inflammation (p. 98), and originates, I believe, in the majority of cases in some



inflammatory deposit due to the irritation of decayed teeth. By the slow growth of the tumour the jaw is expanded, the outer plate yielding more readily than the inner, as is well seen in a preparation in University College Museum (fig. 151), which also shows a curious transportation of the wisdom tooth close up to the condyle of the jaw by the growth of the tumour, being probably connected with it in some way. In the College of Surgeons' Museum (2219) is a good specimen of endosteal fibrous tumour, which Sir Spencer Wells removed with the jaw from the symphysis to the angle, in a woman aged twenty-seven, whose condition at the time of the operation is represented in fig. 152, from a photograph by the late Dr. Wright. The tumour occupied

FIG. 152.



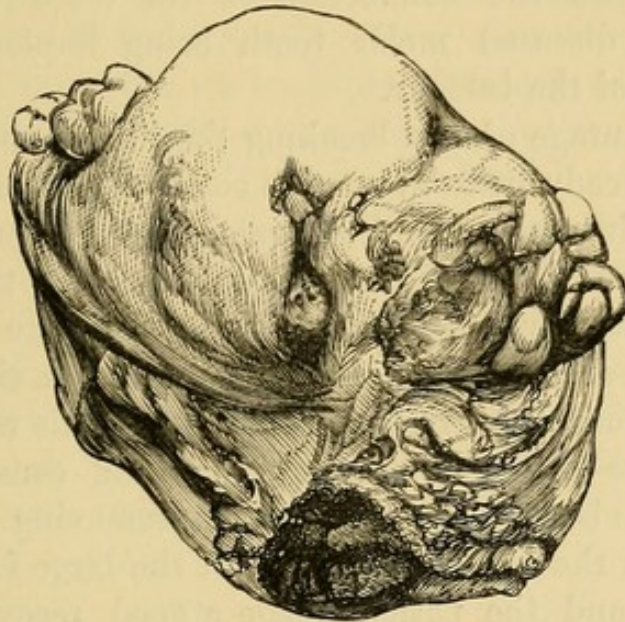
the left side of the lower jaw, and had existed for four years, being connected with decayed teeth, one of which on being extracted shortly before the operation brought a small portion of the tumour away with it. Fig. 153, also by Dr. Wright, shows the tumour in the recent state (see *Pathological Society's Transactions*, vol. xii.).

It may, I think, be doubted whether a milder treatment than that of removal of the whole thickness of the bone containing tumours of this description might not sometimes



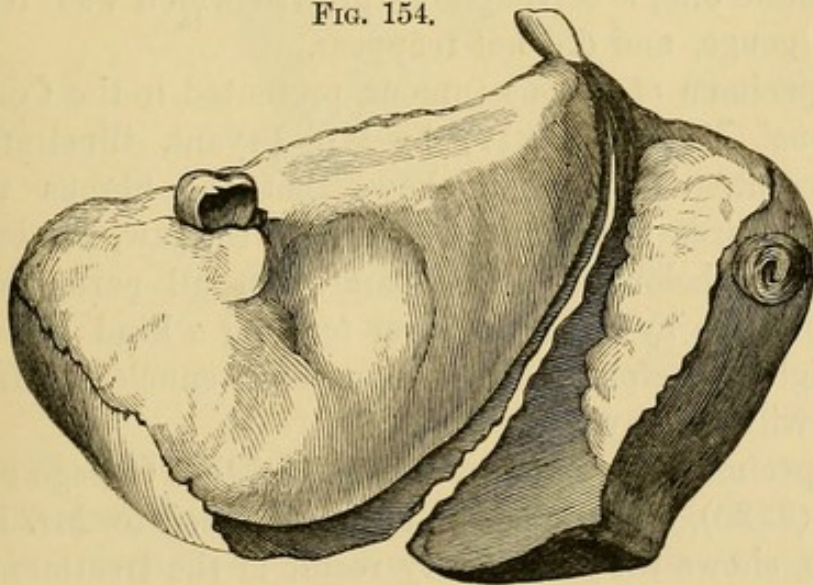
be adopted with advantage. A specimen in the Museum of King's College (132-19), which is represented in fig. 154, admirably illustrates this view. It is a fibrous tumour re-

FIG. 153.



moved, when I happened to be present, by Sir William Fergusson, from a woman who had undergone two previous operations. Having sawn the jaw partly through on each

FIG. 154.



side of the tumour, the operator applied the bone-forceps to complete one of the sections, when the outer plate of the jaw with the greater part of the tumour came away, leaving



only a small portion of it adhering to the inner plate. Owing to the jaw being already divided, it was considered better to complete the operation as originally intended, and the patient made a good recovery. The preparation referred to illustrates also the connection of the teeth with fibrous tumours, a diseased molar tooth being implanted in the upper part of the tumour.

The advantage of not breaking the line of the lower jaw has been already insisted upon in connection with epulis, and the same advantage would be gained by preserving, where possible, the inner plate of the jaw in cases of tumour.

I have recently had a patient under my care who had a fibrous tumour of the size of a large marble, in the lower jaw, in the position of the right molar tooth. This was imbedded between the plates of the jaw, and had considerably expanded the bone. I succeeded in removing the growth from within the mouth by means of the large forceps shown in fig. 123, and the patient made a good recovery. Sir J. Paget, in the paper already referred to (p. 322), gives two cases in which he successfully removed tumours from within the lower jaw, one, a bony tumour, and the other, and more remarkable one, a cartilaginous growth which was removed by the gouge, and did not reappear.

A specimen of fibrous tumour, presented to the College of Surgeons' Museum (2217) by Mr. Bryant, illustrates the same point. The section shows that the fibrous tumour is free towards the alveolar border of the jaw, but enclosed in the bone below. It is separated at all parts from the osseous tissue by a fibrous layer forming a kind of capsule, and might therefore probably have been enucleated from its cavity without any great difficulty.

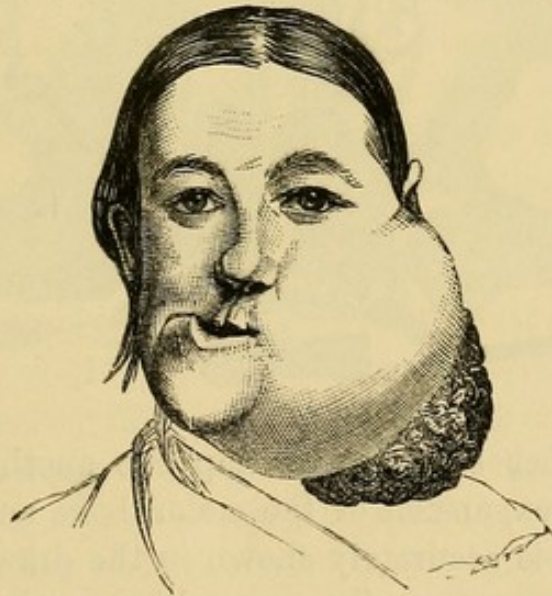A specimen, now in the Museum of the College of Surgeons (2220), and for which I was indebted to Mr. Buxton Shillito, shows the satisfactory result of the treatment here recommended. The case is reported, with drawings, in the *Pathological Transactions*, vol. xvi., and the tumour was removed by Mr. Shillito from near the angle of the lower jaw of a young woman aged twenty-six, where it had been



growing fifteen months, being of the size of a walnut. It was removed by reflecting a flap of skin from its surface, cutting through the thin shell of bone, and enucleation. It left a perfectly smooth cavity into which the fang of the second molar tooth projected, which doubtless was the original cause of the mischief. The tumour was gritty on section, and furnished an example of calcification, to which change fibromata of the lower jaw are liable no less than those of the upper jaw.

Though of slow growth under ordinary circumstances, a fibrous tumour of the jaw, if irritated by the injudicious application of useless remedies with the view of producing absorption of the growth, may assume enormous proportions, and destroy life by the irritation and continuous discharge it gives rise to. A preparation in King's College Museum, shows a fibrous tumour of large size, involving nearly the

FIG. 155.



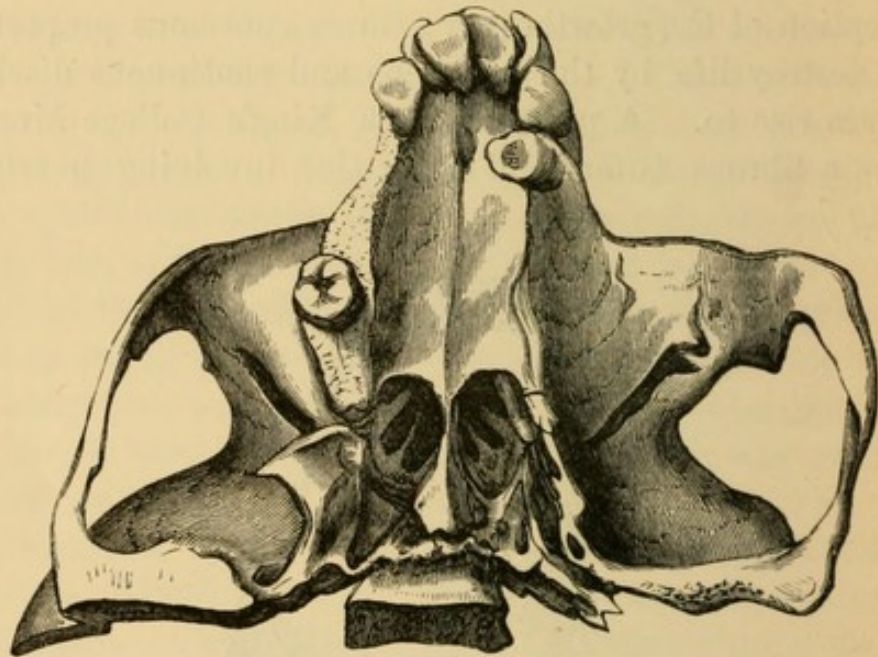
whole of the left side of the lower jaw. Its interior is hollowed out into a large cavity with sloughing walls, and there is a large aperture communicating with it surrounded by healthy skin. The patient's portrait, taken about six weeks before her death, is seen in fig. 155. The case was evidently one of ordinary fibrous tumour depending originally upon diseased teeth, which, by dint of incisions



and injections of iodine into the growth, followed by a seton introduced through the skin, was brought into such a condition that, upon the receipt of a blow, it rapidly brought the patient to her deathbed.

A remarkable and unique feature in connection with the case of large fibrous tumour above referred to, is seen in fig. 156, which shows the front of the base of the skull of the patient. The long-continued pressure of the tumour of the lower jaw has given rise to a remarkable contraction of the hard palate and alveolus, the teeth being

FIG. 156.



crushed together so as to overlap one another, and at the same time an expansion of the malar bone and zygoma has ensued, which is accurately shown in the drawing.

A large tumour of the same kind, weighing eighteen ounces, which has encroached upon the condyle and coronoid process, and projected into the mouth as well as on the surface, is preserved in University College Museum (652), and was removed by Mr. Liston in 1846; and a similar growth, successfully removed by Prof. William Beaumont, of Toronto, from a boy of seven, which is considerably infiltrated with calcareous matter, is in the Museum of the College of



Surgeons (2218), and was originally considered to be cartilaginous (*Medico-Chirurgical Transactions*, vol. xxxiii.). It weighed eight ounces avoirdupois, with a long diameter of  $3\frac{4}{10}$  inches, and a short diameter of  $2\frac{8}{10}$  inches, and involved the whole of the left side of the bone.

The patient, a child aged seven years, was admitted into the Toronto Hospital, Sept. 17, 1849. The tumour, on his admission, extended upwards to the zygoma and malar bone, almost covering the temporo-maxillary articulation; it reached downwards to fully an inch below the angle of the jaw, extending inwards into the mouth as far as the mesial plane; backwards beyond the ramus of the jaw, and forwards to the posterior bicuspid. It pushed the tongue quite to the right of the mesial plane, concealed the velum, and almost completely filled the isthmus faucium; the molar teeth of the upper jaw were deeply imbedded in the tumour, which kept the mouth at all times open, with a constant dribbling of saliva, the upper and lower incisors not meeting by fully half an inch. The tumour had been first observed three months before. On Sept. 25, 1849, Professor Beaumont performed the operation for its removal, commencing by making a curved incision (the concavity upwards), extending from the lobule of the ear to the angle of the mouth, dissecting off the integuments from the tumour. The tumour was firmly wedged in under the malar bone; the outer wall of the jaw was cut vertically through with a small straight saw; the section was then at one stroke completed with a strong bone-forceps; the condyle was disarticulated by being firmly grasped in a forceps, the joint being opened by dividing the external lateral ligament and capsule. The patient did very well; a small salivary fistula was formed in the cheek, which eventually healed, and on Dec. 1, 1849, the patient was quite well. The right half of the lower jaw was drawn a very little towards the left side, about an eighth of an inch; the external cicatrix was a mere line.

Fibrous tumour is most frequently developed in the side of the lower jaw, where the space between the plates is



larger than elsewhere, and may occupy the dental canal, as in a case of Mr. Cock's, in which the dental nerve passed through the tumour, necessitating its removal in two parts (Guy's Hospital Museum, 1091, 25). Occasionally, however, fibrous tumour invades the symphysis, and here, owing to restricted amount of expansion of which the bone is capable, absorption of the anterior surface takes place at an early date, and the tumour projects, involving also the adjacent bone. A preparation in University College (655) shows the symphysis affected in this way, which was removed, with a portion of healthy bone on each side, by Mr. Liston. A section shows the structure very well, and at the lower part a small cyst has been developed. In connection with this subject, another preparation in the same museum (654) is deserving of notice, being a fibrous tumour, of the size of an orange, connected with the back of the symphysis, and apparently, therefore, of the periosteal variety.

The *periosteal variety* of fibrous tumour is not distinguishable from epulis except by its size. Like epulis it has spicula of bone springing from the jaw, permeating it for a short distance, and beyond them radiating lines may be seen in the fibrous tissue. Preparation 2221 in the Museum of the College of Surgeons, which accompanied this essay, and for which I was indebted to Mr. Lee, of the Salisbury Infirmary, illustrates this form of disease very well, the fibrous growth being closely connected with the periosteum of the front of the jaw. The disease may, however, almost completely surround the jaw, as the preparation in St. Bartholomew's Hospital, drawn by Sir J. Paget in his "Surgical Pathology."

*Enchondroma* of the lower jaw is not common, but is found of two forms, the endosteal and periosteal, thus resembling fibroma. The disease generally occurs early in life, and makes slow but steady progress, the periosteal variety acquiring a very large size. A specimen in Guy's Hospital Museum (1019, 15, and 16) shows very well the relation of the endosteal variety to the bone, the growths occupying the space between the plates of the jaw, and the



teeth being imbedded in it. The specimen was removed by Mr. Key from a woman aged twenty-nine, in whom it had been growing nine years, by sawing through the bone on each side of the tumour.

A somewhat similar case is recorded by Sir Astley Cooper, in his "Essay on Exostosis," and is remarkable both for the sound pathological views and strictly conservative treatment he therein advocates. The patient was nineteen, and had had a growth in the side of the lower jaw for three years. Sir Astley exposed the tumour and gouged it away, exposing the dental nerve, and the patient made a good recovery. He remarks respecting it (p. 177), "With regard to the cause of the disease, it was evidently the irritation of the decayed tooth, the fangs of which projected into the cartilage which was effused within the bony cavity, and which, instead of producing suppuration and ulceration, as it frequently does, kept up a degree of irritation that did not pass beyond the stage of adhesive inflammation, and a cartilaginous deposit took place in the first instance, to which succeeded an ossific effusion. As to the treatment of this disease, it consists in first seeking the source of the irritation and removing it as soon as discovered, in order to prevent the further progress of the disease; and, indeed, it may be probable that the removal of the source of irritation might sometimes, even when the disease has advanced to a considerable extent, succeed in producing a cure, and therefore it is desirable to wait the event before any further operation is undertaken. Should this, however, prove insufficient, it will be necessary that the external shell of the bone be removed by means of a saw, and that the cartilage which it contains be dislodged by an elevator. If the integuments be carefully preserved, little deformity follows; and thus, by a simple operation, destruction otherwise inevitable is prevented." Sir James Paget has recorded (*Medico-Chirurgical Transactions*, 1871), a very similar case of cartilaginous tumour in the lower jaw of a lady forty-five years old. It had been growing during two or three years, extended along the space between the first bicuspid and last molar



teeth, was deep set in the jaw, expanding both the walls, and rising to almost the level of the molar teeth. He gouged it out, leaving the base of the jaw untouched, and not cutting any part of the cheek or lip. The patient had no return of the disease.

The periosteal form of enchondroma springs from the membrane covering any portion of the bone, but most frequently affects the body. It grows to an enormous size, and may cause death either by interfering with respiration, as in Sir Astley Cooper's case, or with deglutition, as in the case from which the preparation in the College of Surgeons was taken.

Sir Astley's patient was a girl of thirteen, in whom the tumour had made its appearance near the chin a year before she came under that surgeon's notice. The tumour increased until it measured five inches and a half from side to side, and four inches from the incisor teeth to its anterior projecting part. The circumference of the swelling was sixteen inches. The tongue was thrust back into the throat and to the right side, where it rested in a hollow between the angle of the jaw and the tumour. The epiglottis was bent down upon the rima glottidis so as to produce great difficulty in swallowing and breathing. The mental foramen was large enough to admit the little finger, and, owing to the elongation of the bone, was directed backwards. The preparation is preserved in the Museum of St. Thomas's Hospital (C. 201), and a section, which has been macerated, shows very well the ossific spicula from the surface of the bone projecting into the mass.

In the Museum of the College of Surgeons is a still more remarkable specimen of the same disease (2215), the tumour measuring six inches in depth and about two feet in circumference, and involving the whole of the lower jaw except the right ramus and angle. The patient, when thirty-two, had a small hard tumour on the right side of the lower jaw, just below the situation of the first molar tooth, which had decayed. This gradually increased, and ultimately proved fatal at the end of eight years, by inducing inability to swallow.



A specimen of enchondroma, weighing three and a-half pounds (German), removed by disarticulation by Chelius, is preserved in the Heidelberg Museum, and is figured by Otto Weber (*op. cit.*).

A remarkable case of enchondroma of the lower jaw has been recorded by Mr. Lawson (*Pathological Society's Transactions* xxxiv.), in which there were ten operations for as many recurrences during eighteen years. The report of a committee on some of the more recent recurrences goes to show, however, that these are more of the nature of spindle-celled sarcoma.

The history of the case goes back to 1865, when the patient came under Sir William Fergusson's care on account of a large tumour, bulging below the jaw, and pushing into the mouth. He then removed the tumour, and at the same time took away five teeth from the lower maxilla, which appear to have been displaced by it. She made an excellent recovery, and for a time remained well, but the tumour recurred, and after two or three years was again removed by Sir William Fergusson. Unfortunately the patient had kept no account of the dates of the different operations she had undergone. She was only able to say that she was operated on twice between the years 1865 and 1872, and three times between 1872 and 1876; the last operation being in November, 1876, when Sir William apparently succeeded in getting away the whole of the growth.

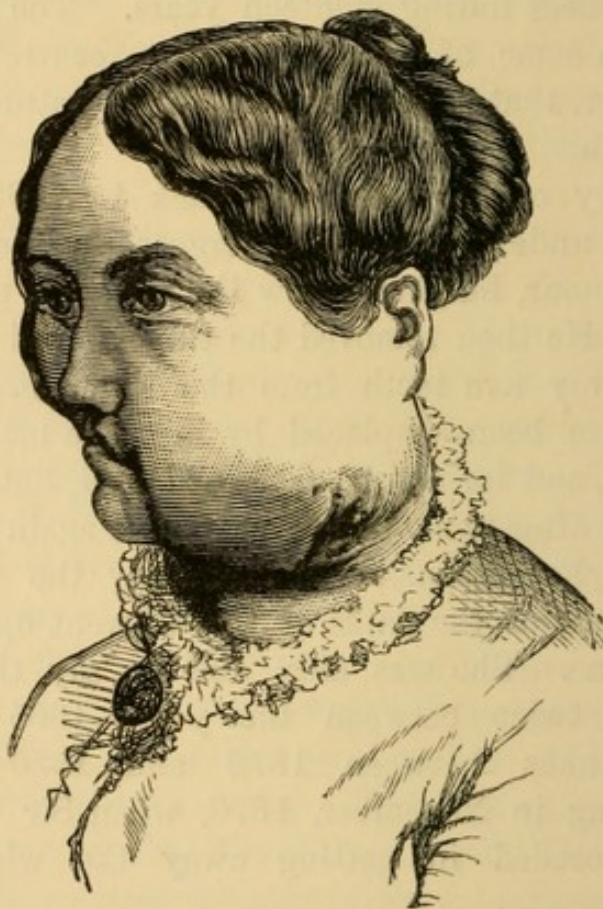On December 26, 1877, the patient, aged fifty-seven, a stout healthy-looking woman, was admitted into the Establishment for Invalid Ladies, under Mr. Lawson, for the purpose of having the tumour again removed. Since the last operation the tumour had recurred, and, as she could not have the benefit of Sir William Fergusson's assistance, she had allowed the growth to remain until it had attained such dimensions that she was compelled to seek relief.

On admission, the tumour presented the external appearance shown in the woodcut (fig. 157). It extended upwards



to the level of the lower part of the ear, downwards in the neck to within two fingers'-breadth of the clavicle, and forwards it was bulging close up to the nose. Looking within the mouth, the tumour was seen to occupy the greater portion of that cavity; and it extended across the pharynx against which and the soft palate it pressed. The mouth

FIG. 157.



could be closed, and she could take food without much difficulty, but her breathing was at times troublesome, and especially at night.

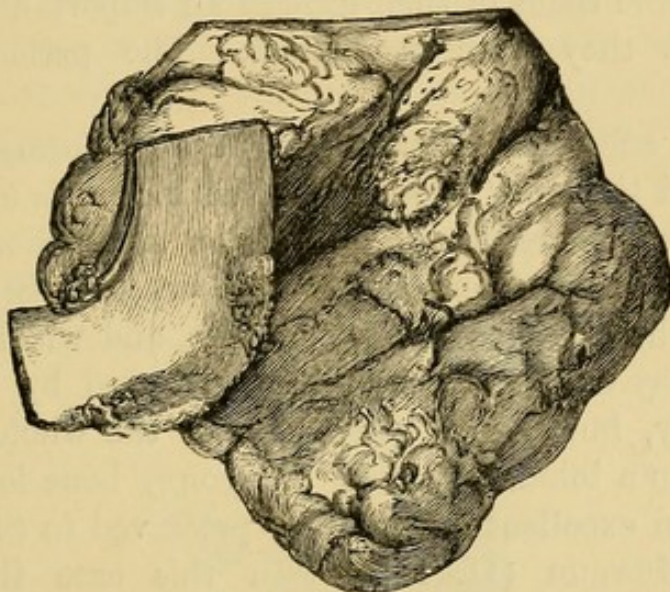
On Jan. 7, 1878, Mr. Lawson removed the tumour with the portion of the lower jaw from the inner surface of which it grew (fig. 158), and the patient rapidly recovered.

The tumour weighed close upon eighteen ounces. It was of a firm consistence, but easily cut with the knife. It was intimately connected with the periosteum on the inner side of the lower jaw, from which it apparently sprang. A por-



tion of the tumour was given, immediately after its removal, to Dr. Thin, who supplied the following report of his microscopical examination:—"I examined microscopically the portion of the tumour kindly given me by Mr. Lawson, and I believe the growth to be a chondrome of the class

FIG. 158.



named by Cornil and Ranvier *chondromes hyalins lobulés*. It has the peculiarity that the cartilaginous tissue is of a very low type, so much so that the determination of the exact nature of the growth was a matter of some difficulty. Successful preparations, however, show that, except in the degree of development of the cartilaginous substance proper, the structure is identical with that described by pathologists as characteristic of these tumours."

Dr. Coupland, the lecturer on Pathology at the Middlesex Hospital, examined the specimen of the growth prepared by Dr. Thin, and concurred in the report.

Since the operation in 1878 there have been five operations for extensive recurrence of the disease, and on each occasion similar masses of cartilage were removed. The recurrences have been in the neck and in the temporo-maxillary region, extending from the glenoid fossa of the temporal bone towards the base of the skull, and in the



cheek, between the mucous membrane and the external integument. At each operation the tumour was found to be composed of large isolated masses of cartilage, varying in size from that of the closed fist to a small nut, packed tightly together, and each portion enclosed in a distinct capsule, from which it could with little difficulty be enucleated. The masses of cartilage were of sufficient density to push before them in their growth all important structures with which they were in contact. The patient is still living.

*Osteoma* affects the lower jaw in two forms—the cancellated and the ivory exostosis. The former is no doubt in many cases the result of ossification of enchondroma, as for instance, a specimen (C. 203) preserved in St. Thomas's Museum, which is of a spongy texture, and which is stated by Sir Astley Cooper to have been removed by Mr. Cline. Occasionally, however, a conversion of the whole thickness of bone into a lobulated mass of spongy bone is met with, of which an excellent example is preserved in St. George's Hospital Museum (II. 185). In this case the tumour, which was of the size of the fist, had been growing for five years, and had been on one occasion partially removed. Mr. Tatum successfully removed the entire portion of jaw affected. A case in which a circumscribed bony tumour, measuring from two-thirds to three-fourths of an inch in diameter, and composed of hard, finely cancellous bone, was lodged in the interior of the angle of the jaw, is given by Sir J. Paget in the *Medico-Chirurgical Transactions*, vol. liv.

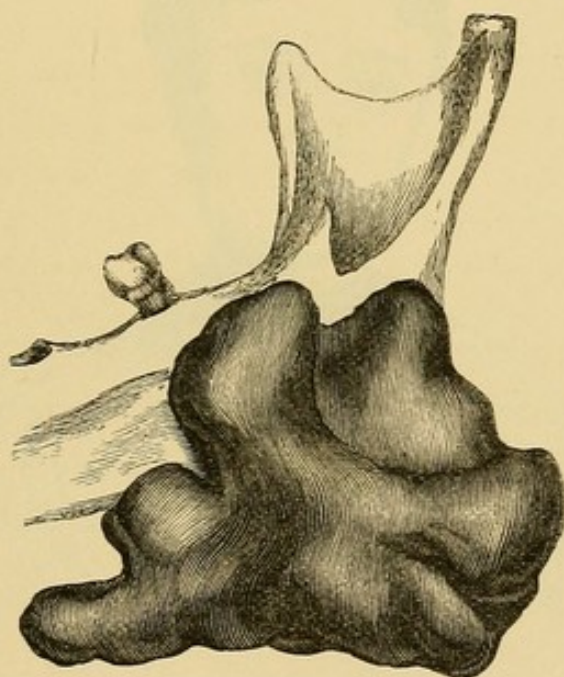
Ivory exostosis appears to affect by preference the angle of the jaw. Of this a good specimen is preserved in St. George's Hospital (II. 191); and O. Weber figures a section of a large ivory exostosis in the same region removed by Chelius. The best example of the kind, however, is in the College of Surgeons (2212), having been presented by Mr. J. F. South. The preparation (post-mortem) shows part of the right side of the lower jaw, with sections of a large bony tumour at its angle. The angle of the jaw rests in a deep groove on the middle of the upper surface of the tumour,



and in some situations their respective substances are continuous. The tumour projects both below and on each side of the jaw, is of irregular shape, measures nearly three inches in its chief diameter, and is deeply nodulated. It is composed throughout of bone, uniform in texture, and as hard and heavy as ivory (fig. 159).

In the Museum of St. Bartholomew's Hospital is the lower jaw of a young person (I. 3257) with two symmetrical eburnated exostoses springing from the inner surface of the alveolar portion of the bone on either side of the symphysis, corresponding in position to the bicuspid and first molar

FIG. 159.



teeth. The markings and slight lobulations of the bony outgrowths are more or less symmetrical. The rami of the jaw are unusually widely separated.

In May, 1870, I removed an ivory exostosis from a young woman aged thirty-two, a patient of Mr. Ceely, of Aylesbury, whose portrait is given in fig. 160. There had been a painless enlargement of the left side of the lower jaw for five years, and there was also a smaller enlargement of the right side. A small exostosis also existed on the left pubes. I made an incision behind the jaw and sawed off the growth



level to the bone, removing a dense ivory growth measuring two inches in length by one inch in width, and three-eighths of an inch thick in the centre (University College Museum 635). The exterior of the growth presented a finely reticulated appearance, and at the upper part was a small depression filled with cartilage in the recent state. Two years after the operation I was informed by Mr. Ceely that there had been no reappearance of the growth, and that the other

FIG. 160.



exostosis remained *in statu quo*, and four years later I saw the patient, who continued quite well.

When the exostosis forms a distinct and circumscribed growth, whether it be of the cancellous or ivory character, it should be sawn off the bone at the level of the healthy surface, and will in all probability not recur. When, however, the whole thickness of the bone is involved, as in Mr. Tatum's or Mr. South's case, it will be necessary to remove a portion of the bone. Should the tumour be imbedded between the plates of the jaw, it should be enucleated if possible without any external incision, as in Sir J. Paget's



case given above. A remarkable case of exostosis of the ramus of the jaw, reaching to the styloid process, has been recorded by Mr. Syme, in his "Contributions to the Pathology and Practice of Surgery," in which he removed the ramus of the jaw, with the growth, by an external incision, without opening the cavity of the mouth.



## CHAPTER XXIII.

## SARCOMATOUS TUMOURS OF THE LOWER JAW.

*Spindle-celled Sarcoma, Myeloid Sarcoma, Chondro-Sarcoma, Ossifying Sarcoma.*

*Spindle-celled sarcoma.* This, the old-fashioned *osteo-sarcoma*, frequently attacks the lower jaw, and may prove fatal, by obstruction either to respiration or deglutition, if allowed to grow unchecked for many years. Some of the earliest removals of portions of the lower jaw were for growths of this description which had attained a large size, and the names of Crampton, Cusack, and Syme are connected with these operations. The Museum of the College of Surgeons of Ireland is especially rich in tumours of this class, and possesses also a cast of the head of a patient who died with a large tumour of the lower jaw, which has been injected and divided. The following is the description of this preparation (I. a. 361), kindly extracted for me by Dr. Barker, the Curator:—"A singularly beautiful preparation of the osteo-sarcoma of the lower jaw, of which the preceding cast gives an outline. The patient was a middle-aged woman. The disease commenced as a fungus in the alveoli of the front teeth. This fungus was removed by operation at an early period, but speedily grew again, and in the course of about two years had acquired its size, which is equal to that of an infant's head, without bursting at any part. It was firm, but elastic to the feel, and inconvenienced the patient more by its bulk than by its malignancy. The woman, who was naturally of a delicate frame, gradually sank from exhaustion. No preparation could exhibit more satisfactorily the circumscribed local



nature of this affection than that here shown. It is globular, four inches in diameter, and enveloped in an osseous wall which has connection, exclusively, with the front central portion of the lower jaw, and which completely insulates the disease. The maxillary bone is perfectly sound beyond the points of adhesion of the tumour. The centre of the tumour is divided by bony partitions into several chambers, the surfaces of which are lined by a pulpy vascular membrane, which has received injection in great profusion. The contents of these chambers were various—some gelatinous, some bloody, and some of a gristly nature, interspersed with bony stalactites. Plate 11, in the fourth volume of the *Dublin Hospital Reports*, was taken from this preparation.—Professor Wilmot."

The central portion of this tumour is of such a distinctly cystic character that modern pathologists would probably have classed the disease among the cystic sarcomata, but I prefer to leave it in the place assigned to it by the Irish pathologists.

In the same fine museum are the historically interesting tumours removed by Sir Philip Crampton and Mr. Cusack, in 1824, the details of which cases will be found in the valuable papers by those two gentlemen, in the fourth volume of the *Dublin Hospital Reports* (1827). Sir Philip Crampton was the first to insist upon the non-malignancy of this form of osteo-sarcoma, and to distinguish it from the medullary form—up to that time confounded with it. His description of the whole course of the disease, as witnessed in the jaw, is so perfect that I cannot do better than reproduce it:—"The first indication of this formidable disease is the appearance of merely a small swelling or projection of the gum, between two of the teeth. The teeth, however, soon become loose and dislocated, being forced inwards upon the tongue, or outwards against the cheek; as the tumour enlarges it assumes a tuberculated appearance, the tubercles varying in colour from a light pink to a deep purple; they are firm in structure, perfectly indolent, and do not readily bleed even when roughly handled. As the morbid growth



extends in all directions, the mouth is soon filled by the tumour, the lower jaw is forced downwards upon the fore part of the neck, the tongue is pushed backwards into the pharynx, the mouth is carried to the side of the face opposite to the tumour, and before the patient sinks under his sufferings, a tumour is sometimes formed which nearly equals the bulk of the head itself. It is gratifying, however, to be able to state that even under such deplorable circumstances life has been preserved, and the hideous deformity removed by an operation which must be considered as one of the boldest and most successful of which modern surgery has to boast. But it is from the *internal structure* of osteo-sarcomatous tumours, as developed in the course of operations undertaken for their removal, or by dissection after death, that the true and distinctive characters of these affections are to be traced. In the benign form of osteo-sarcoma, the local and, I might almost say, the encysted character of the disease is evinced by the distinct line which separates the morbid growth from the soft parts with which it is in contact. It becomes apparent that as the tumour has enlarged, it has pushed the soft parts before it, or insinuated itself into their interstices, and that, so far from becoming incorporated with the surrounding structures, and assimilating them to its own nature (as invariably happens in the advanced stage of malignant tumours), it has formed attachments so slight, that when the portion of bone from whence the tumour springs is detached, the whole morbid growth may be (as it were) drawn out from the surrounding parts almost without the aid of the knife. The interior of the tumour presents a great variety of structure, but I should say, in general, that the cartilaginous character which the tumour exhibits in its origin prevails to the last. In the early stages of the disease the tumour consists of a dense elastic substance, resembling fibro-cartilaginous structure, but the resemblance is more in colour than in consistency, for it is not nearly so hard, and is granular rather than fibrous, so that it 'breaks short.' On cutting into the tumour the edge of the knife grates against spicula, or small grains of earthy matter, with



which its substance is beset. If the tumour acquires any considerable size, it is usually found to contain cavities filled with fluids differing in colour and consistency, but in general the fluid is thickish, inodorous, and of the colour of chocolate. Sometimes the growth of the tumour, or the secretion of fluid within its substance, is so slow that the deposition of bony matter keeping pace with the absorption, the bone becomes expanded into a large and thick bony case, in which the tumour is completely enclosed. There is a beautiful

FIG. 161.

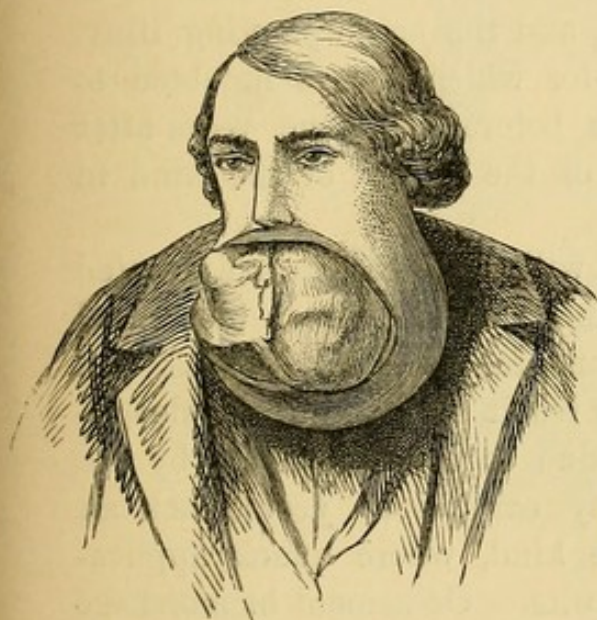



FIG. 162.



preparation of this form of the disease in the Museum of the Royal College of Surgeons. But in general the walls of the cavity consist of cartilaginous structure mixed with bone, the bone bearing but a small proportion to the cartilage. The extent to which this description of tumour may increase without materially affecting the general health, is one of the most extraordinary circumstances connected with its history" (p. 541).

The "cartilaginous" appearance here referred to, relates only to the naked-eye appearance of the structure, which is characteristically said to "break short." Microscopic exami-



nation, as I have had the opportunity of observing in a large tumour of the kind, shows a dimly granular stroma, closely resembling the *matrix* of cartilage, but containing no true cartilage-cells. Though parts of the tumour may show structure of this kind, the greater part is usually of a distinctly spindle-cell character.

In 1828 Mr. Syme removed a very large tumour of this description (probably the largest which has ever been removed), weighing  $4\frac{1}{2}$  lbs., which, no doubt, for the reason given above, he refers to in a lecture published in the *Lancet*, Feb. 3, 1855, as a fibro-cartilaginous tumour. The patient made a good recovery, and the accompanying illustrations, figs. 161 and 162, for which I was indebted to Mr. Syme, show his condition before and some years after the operation, which was one of the earliest of the kind in this country.

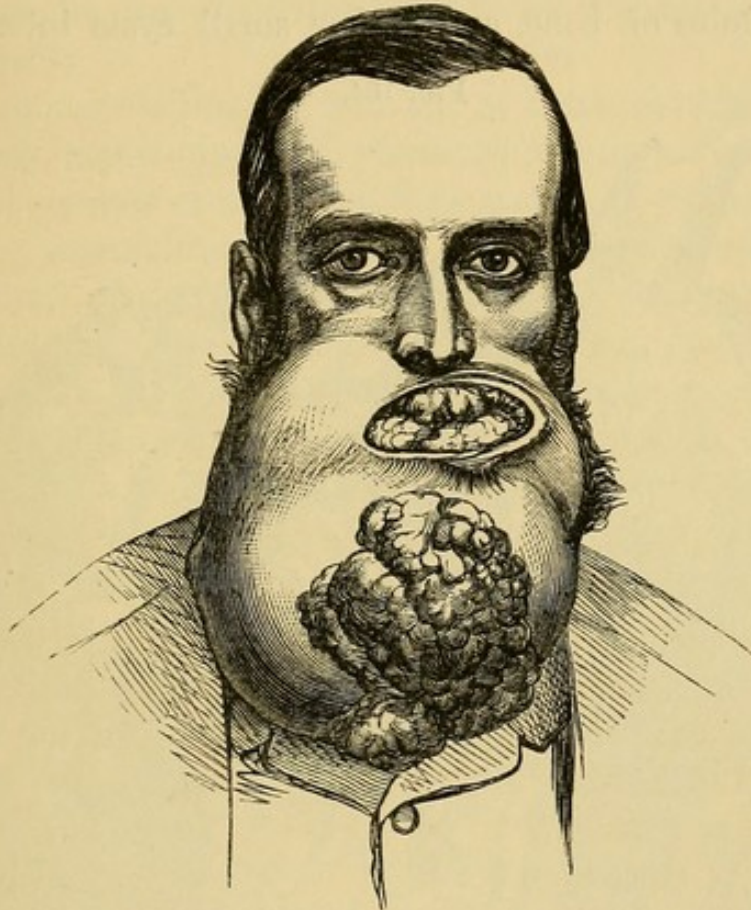
The spindle-celled sarcoma will, if its surface be irritated by caustics, &c., throw out fungus masses, which bleed, and may be mistaken for malignant fungus. Mr. Cusack (*loc. cit.*) gives an example of this result occurring from sloughing of the skin of the face, due to over-distension by the tumour, and I had under my care some years back an extraordinary instance of the kind, where quack applications had produced similar results. Occasional hæmorrhage from such surfaces led to these cases being massed together with cancer as examples of *fungus hæmatodes*, and doubtless Sir William Fergusson's observation is correct, that the rarity of fungus hæmatodes in the present day, is due to the early treatment to which cases of this kind are submitted.

The portrait of the patient formerly under my own care, to whom I have alluded, is shown in fig. 163, taken from a photograph, and his case will be found in detail in the Appendix (Case XII.). The enormous size of the tumour can be best appreciated by the figure, the measurements being as follows:—From the lobule of one ear round the chin to the lobule of the other was  $19\frac{1}{2}$  inches; from the edge of the lower lip over the chin to the *pomum Adami*



13 inches; and the width of the face was 14 inches. The circumference of the lips was  $9\frac{1}{2}$  inches. The patient was only thirty-two, and the disease appeared to have commenced

FIG. 163.

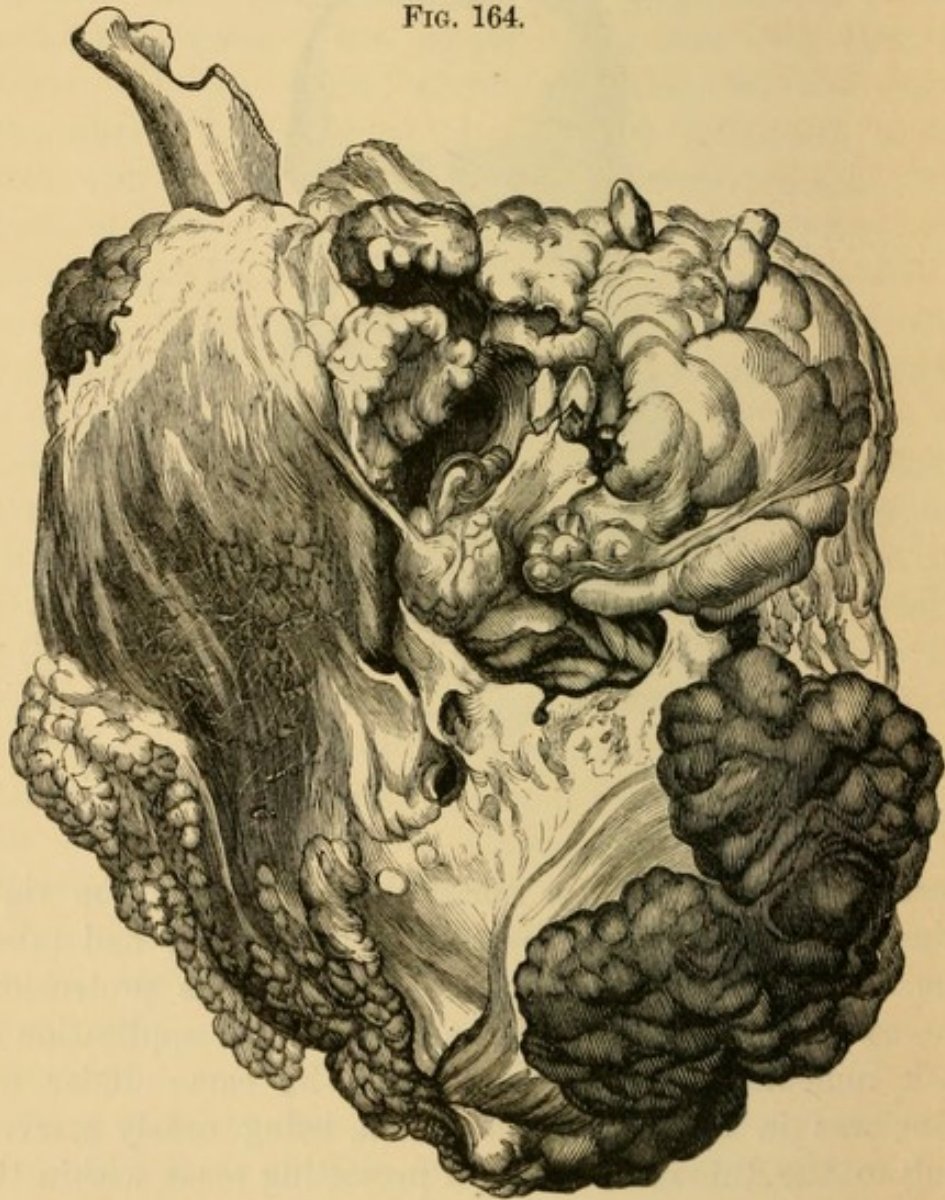


eleven years before, in a small swelling below the right canine tooth, but the whole of the large growth had taken place within four or five years. The fungous protrusions were, as has been mentioned, the result of the application of quack remedies. The patient, when he came under my notice, was in a miserable condition, being nearly starved, owing to the tumour forming a projecting mass within the mouth, which completely concealed the tongue, and was nearly in contact with the palate. I succeeded in removing the tumour by sawing in front of the left angle and disarticulating on the right side, with very little loss of blood, but the patient died exhausted on the sixth day. The tumour weighed 4lb. 6oz., and is now in the Museum of the



College of Surgeons (2234). Its appearance (reduced to about one-third) is shown in fig. 164. A section has been made to show its structure, which is precisely that described by Sir P. Crampton, the mass being made up of fibro-cellular tissue of different degrees of density, with here and there small nodules of bone, and a few small cysts interspersed

FIG. 164.



through its structure. The tumour evidently commenced in the interior of the jaw, the outer plate being considerably expanded and destroyed in parts, while the inner remains perfect, and can be seen in the condition in which it was left at the operation. The mass in growing has carried up



the teeth with it, and they project from it at irregular intervals, a considerable portion of the growth, and probably the most recently formed part, being posterior to them, occupying as it did the mouth and lying among the muscles beneath the tongue. The fungoid masses are covered with granulations, but otherwise differ in no way from the rest of the growth.

I was indebted to the late Mr. A. Bruce for the following elaborate report upon the structure of this tumour:—"The tumour consists of a lobulated mass of soft but elastic consistence, resembling in parts a recent decolorized fibrinous coagulum. It is for the most part of a pale straw-colour, with here and there patches of a flesh-tint, and mottled in spots with deep crimson. In front is a prominent fungating mass, which had penetrated through the skin at the time of the operation. The structure consists of a fine fibrinous stroma, varying in different parts in its degree of fibrillation; in some portions there are very distinct fibres, in others only imperfect ones, as is frequently seen in rapidly growing parts, whilst in others again the stroma is dimly granular, and closely resembles the matrix of cartilage, but differs from it in its softness; this latter character is limited to the parts in the interior in immediate connection with the bone. Imbedded in this stroma are numerous cells, lying for the most part with their axes parallel to one another, but in many places without any apparent uniformity in this particular. The cells are small in size, at first sight more resembling elongated nuclei, but in all cases a cell-wall may be distinctly traced when a sufficiently high power is employed. The majority are elongated fusiform or fibre cells, with a considerable proportion, however, of oval, rounded, or even polygonal cells. Their size varies from to  $\frac{1}{2000}$  to  $\frac{1}{900}$  inch in diameter. The nuclei are proportionately large and prominent, and contain one or two very distinct glistening nucleoli. The cell contents, when any exist, are granular. Some of the rounded and polygonal cells closely resemble those found in malignant growths, especially in the irregularity of their arrangement and their large eccentric nucleus;



one cannot, however, lay much stress upon these characters in the present case, considering the small proportion which these cells bear to the whole mass of the tumour. Fragments of bone and of calcareous matter are found scattered throughout the tumour, and appear to be in part derived from the jaw itself, and in part to be a new development. The general structure of the tumour is that usually described under the head of osteo-sarcoma, and it belongs evidently to the group of simple fibro-plastic tumours, but differs from the myeloid fibro-plastics in the equal proportion existing between the cellular and fibrous elements."

Mr. Eve has recently re-examined this tumour, and has found scattered throughout it masses and cylinders of epithelial cells, resembling the epithelial elements of the cystic tumours of the lower jaw already described (p. 196). They were composed of large irregularly shaped or branched masses, and of small columns composed of round epithelial cells, with a layer of peripheral elongated cells. (For drawing, see Lecture by Mr. Eve, *British Medical Journal*, Jan. 6, 1883.)

Under the head of Spindle-celled Sarcoma must be included the following two cases, which have hitherto been classed as "recurrent fibroid."

The first occurred in the Westminster Hospital, under the care of Mr. Holt, in 1858, in a young woman aged eighteen, who had a soft fungoid mass covering the molar teeth of the right side of the lower jaw, of ten weeks' duration. It apparently sprang from the angle of the jaw or the base of the ascending ramus, and had pushed the mucous covering before it. The molar teeth were firmly fixed in their sockets; the wisdom tooth was covered with gum. The rapid growth of the fungus, and the absence of any material pain, led to the conclusion that it was probably a form of epulis of a malignant type. Mr. Holt therefore thought it advisable to remove the whole mass, and examine the bone prior to removal of the jaw itself. This being done, its attachments were found to be connected with the posterior part of the body and anterior



part of the ascending ramus, the bone being hard and of its ordinary density. Mr. Holt did not feel warranted in doing that which he was prepared to do—namely, remove the bone at its articulation at this time—but preferred removing with the cutting pliers all the bone to which the growth had been attached. Mr. Clendon having then extracted the molars and wisdom tooth, Mr. Holt cut through half the thickness of the jaw corresponding to those teeth, and, going further back, included the coronoid process, with more than half of the sigmoid notch. The disease was found to be intimately connected with the periosteum, which readily peeled off, leaving the bone somewhat roughened. (See *Lancet*, Jan. 28, 1858.)

The disease reappeared in a few weeks, when Mr. Holt was compelled to remove it again, including this time the remaining part of the ramus of the jaw. The disease now was not confined to the covering of the bone, but extended into the pharynx, and was evidently attached to the mucous lining of the whole of one side of the mouth.

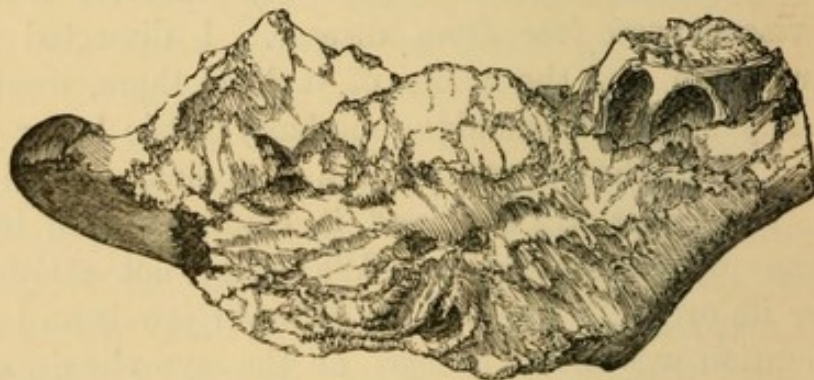
The poor girl left the hospital and went to Reading, and died on the 3rd of February. An autopsy was performed by Mr. Walford, the particulars of which are given in his own words :—

“ Fanny S—— died on the 3rd, and assisted by Mr. G. May, jun., and Mr. Fernie, I made a post-mortem examination. I did not open the head. The thoracic and abdominal viscera were free from disease. I dissected out the tumour, which, had the whole of it been there, would have completely encircled one side (one-half) of the lower jaw ; it extended up to the zygomatic arch and downward into the neck. The gullet was free, and it evidently grew into, not from, the pharyngeal region. We could not satisfactorily discover its origin. The portion of lower jaw-bone left after the operation was sawn through at the symphysis, and exhibits the margins of the tumour on the periosteum, which I think, must be considered its starting-point, and that, as regards treatment, would be practically the bone.” (See *Lancet*, March 6, 1858.)



The second case occurred at the Great Northern Hospital, in the practice of Mr. George Lawson, who performed three operations with the hope of eradicating the disease, which, however, eventually proved fatal, as in the preceding instance. The patient was a young woman aged seventeen, and the first operation was performed October 4, 1858. She had then what might be termed a large epulis growing from the anterior and inner surface of the ascending ramus of the lower jaw on the left side, extending from a point near the angle to close upon the condyle. Mr. Lawson removed the tumour with bone-forceps, cutting away apparently all its bony attachments. About six weeks after the first operation a small elastic mass appeared in the temporal fossa of the affected side, but the jaw was apparently free. This Mr. Lawson excised, but found that the growth had evidently sprung from its original site, and extending upwards, had passed beneath the zygoma into the temporal fossa. The third operation was in June, 1859, when, in consequence of the great size the tumour had attained, the inability of the girl to open her mouth, and the great difficulty she experienced in deglutition, Mr. Lawson removed a portion of the inferior maxilla, sawing through the bone in front of the angle, and then disarticulating. Upon the removal of this portion of bone (fig. 165), it was found that

FIG. 165.



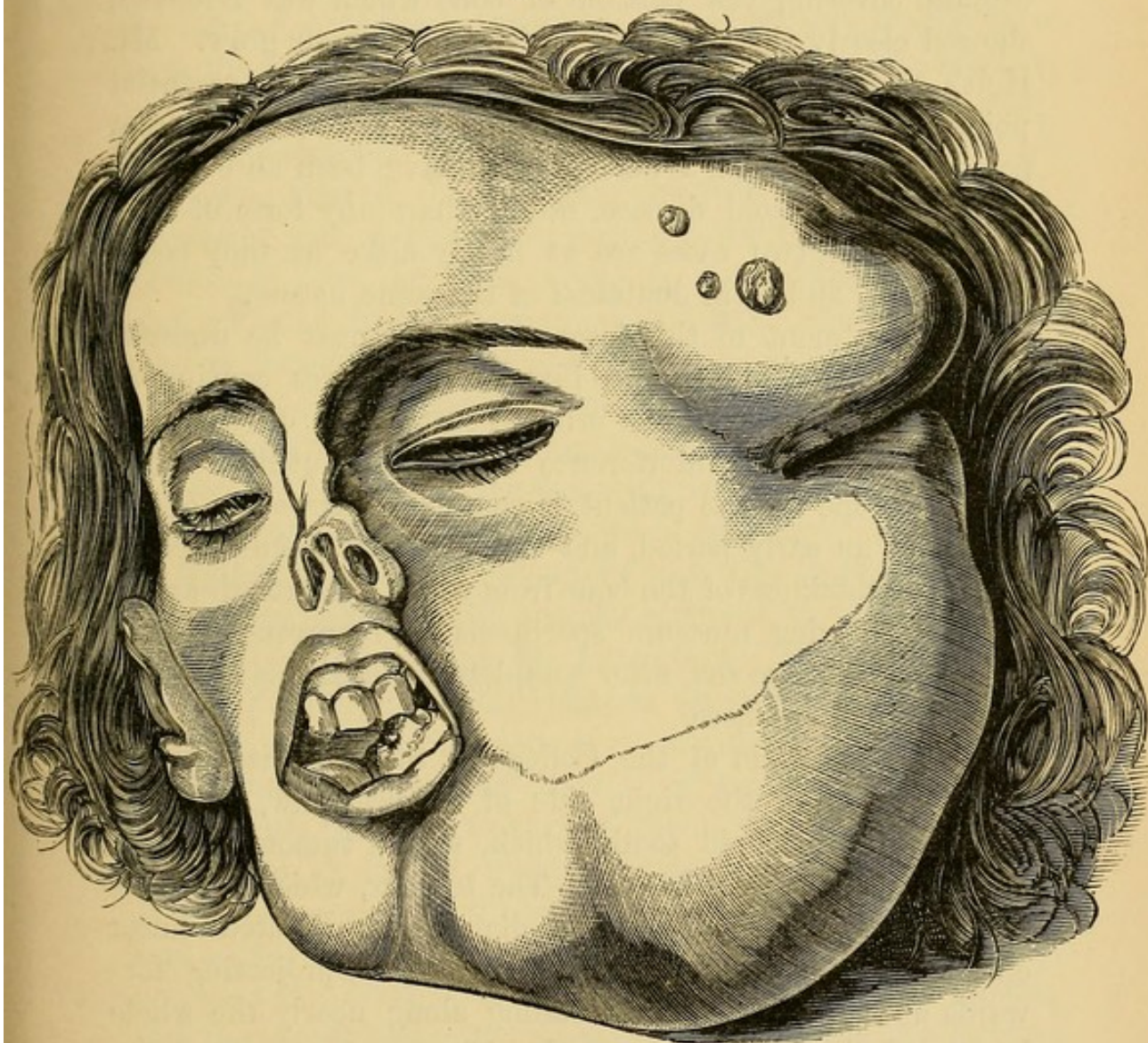
the tumour had formed so many attachments to the periosteum of the bones forming the base of the skull, that the operator was compelled to leave some of the disease behind.

By the end of November, 1859, the tumour had again



grown to a large size, and from the space it occupied in her mouth interfered much with her taking nourishment. It now began to soften and to ulcerate on its surface, both externally and within the mouth, and occasionally very alarming

FIG. 166.



hæmorrhages would take place, so as to threaten immediate dissolution, but from all these she rallied; within the mouth large sloughs would occasionally separate, allowing her to recruit her health by enabling her to take additional nourishment. She died early in 1860, worn out and greatly emaciated. The drawing (fig. 166), for which I am indebted to Mr. Lawson, shows the terrible deformity as seen after



death. The preparation is in the Museum of the College of Surgeons (2230 A). (See *Pathological Transactions*, xi.)

In Mr. Lawson's case, repeated careful examinations of the tumour proved it to be of the so-called recurrent fibroid character, and the rough and thickened condition of the periosteum covering the portion of bone which was removed, showed clearly the site from which the tumour grew. Mr. Holt's case, which is remarkably similar in all essential points, is reported as one of malignant disease; but from personal observation, I believe it to have been an example of recurrent fibroid disease, rather than any form of true cancer. The two cases are as nearly alike as they could possibly be, and were doubtless of the same nature.

The treatment of this form of disease must be unsatisfactory. The tendency to invade the tissues continuous with and contiguous to the original seat of the disease, renders any operative interference of doubtful utility. Still the only hope for the patient is complete extirpation of the disease at an early period, and the operation should include the entire thickness of the bone from which the growth arises.

The following museum specimens of recurrence of the spindle-celled sarcoma, after complete removal, may be conveniently noticed here.

In the Museum of the College of Surgeons is a preparation (2224) of the right side of a lower jaw, from the angle to the bicuspid tooth, which, with a tumour upon it, was removed by Mr. Liston. The tumour, which measures about two inches in its greatest diameter, is situated almost entirely on the anterior surface of the jaw, projecting forwards and upwards, and extending along nearly the whole length of the portion removed. The greater part of the tumour consists of a pale, firm, and compact substance: at its base it is osseous, and so closely attached to the anterior surface of the jaw, from which it appears to have risen, that the outline of the latter can scarcely be made out. The patient was a woman of thirty, who had had a blow on the cheek nine years before the tumour appeared. Its growth was accompanied by lancinating pain in the jaw and con-



tinual headache. It was removed five months after its first appearance. No portion of the disease appeared to have been left, but the growth reappeared in the ramus, and necessitated its removal by disarticulation ten months afterwards (2225).

In St. Bartholomew's Hospital Museum is a specimen (I. 442) of a tumour, for which the right side of the jaw from the angle to the symphysis was removed. The morbid growth consists of a grey, dense, fibrous substance originating from the alveolar border, and from the outer surface of the jaw. Part of the alveolar border of the jaw has been absorbed; and in this situation the morbid growth appears to extend into the bone, which is harder than usual. It was removed from a woman aged thirty. Subsequently a tumour formed in the side of the neck immediately below the seat of the operation, which ultimately proved fatal by the ulceration and sloughing which took place in it. A portion of this was connected with the jaw, and a section shows it to consist of a firm fibrous substance.

*Myeloid Sarcoma* is frequently met with in the lower jaw, and it was here that the disease occurred in the case from which Sir J. Paget drew his description. The case is quoted by Mr. Stanley (*op. cit.* p. 184) as an example of "tumour of bone, composed of a soft, very vascular substance, having the characters of erectile tissue," but his general description corresponds precisely to that of Sir J. Paget. Figs. 1 and 2 of Plate 13 in Mr. Stanley's atlas show the tumour *in situ* and a section of the jaw after removal. "The patient was a boy in St. Bartholomew's Hospital, and the growth occupied the symphysis of the lower jaw, and protruding into the mouth presented a very vascular surface of a mottled red and purple colour, resembling the exterior of some nævi. The tumour was not tender to the touch, and had not been accompanied by pain; it was once destroyed by caustic to the level of the alveolar border of the jaw, but was quickly reproduced; it was then wholly removed with the portion of the jaw in which it originated, and the cure was permanent. The morbid substance was found imbedded in the cancellous



texture of the jaw ; it was soft, of a dark red colour, *closely resembling the tissue of healthy spleen.*" (Stanley, p. 185.)

Stanley mentions a case, very similar to his own, recorded by Dupuytren in his *Leçons Orales* ; and in the Museum of St. Thomas's there is a very good specimen of myeloid disease, which was described by Sir Astley Cooper ("Surgical Essays") as "a fungous exostosis of the lower jaw, which

FIG. 167.

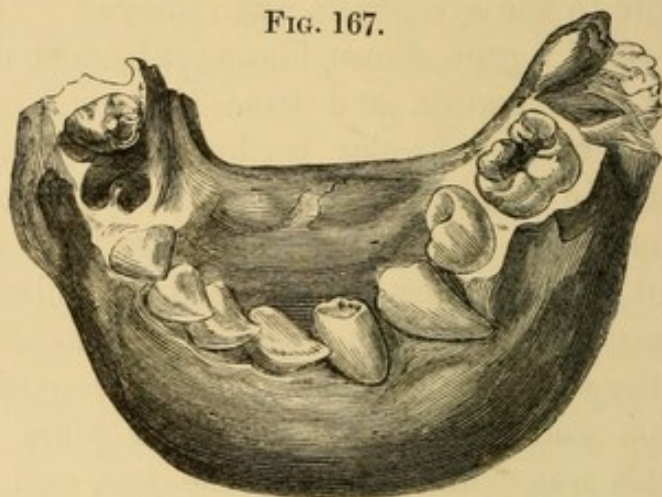
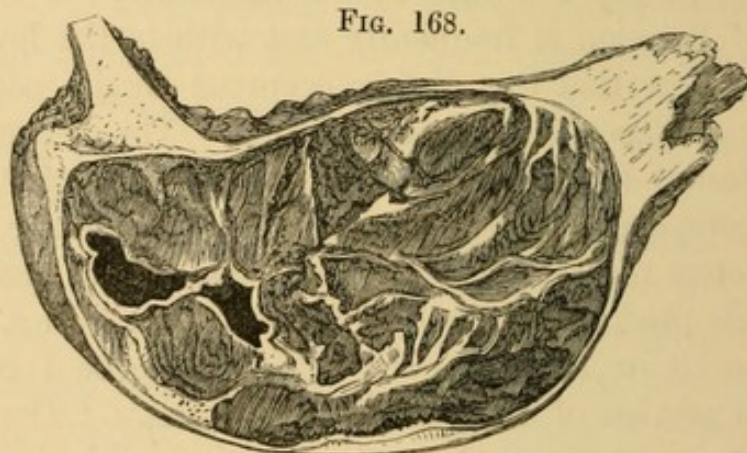


FIG. 168.



formed a large prominence on the chin" with "purple *fungi* of the gums," occurring in a woman aged thirty-two. The preparation shows at the back part a small portion of firm, healthy bone, having a well-defined margin and not sending out any spicula, from which the tumour projects. Around its base the tumour is covered with integument ; but in front the latter has ulcerated, allowing the growth to fungate through the ulcerated aperture.

A valuable preparation is in the College of Surgeons'



Museum (421) of myeloid tumour of the symphysis and body of the jaw, removed by Mr. Craven, of Hull, from a young woman of eighteen, who made a good recovery after the operation. Figs. 167 and 168 show very satisfactorily the appearance of the specimen, which has been divided horizontally. The tumour was of between two and three years' growth, and was covered with healthy mucous membrane. Its section shows a well-marked specimen of myeloid disease imbedded between the plates of the lower jaw ; its tissue is of the ordinary friable character, resembling spleen, but somewhat decolorized by immersion in spirit, and it is intersected by fibrous septa. Two cysts may be seen in the section ; these, as mentioned by the late Mr. H. Gray (*Medico-Chirurgical Transactions*, xxxix.), being of frequent occurrence in myeloid growths. The microscopic examination of Mr. Craven's specimen was unsatisfactory, owing to its previous immersion in spirit, but there can be no question, from the naked-eye appearances, of the nature of the growth.

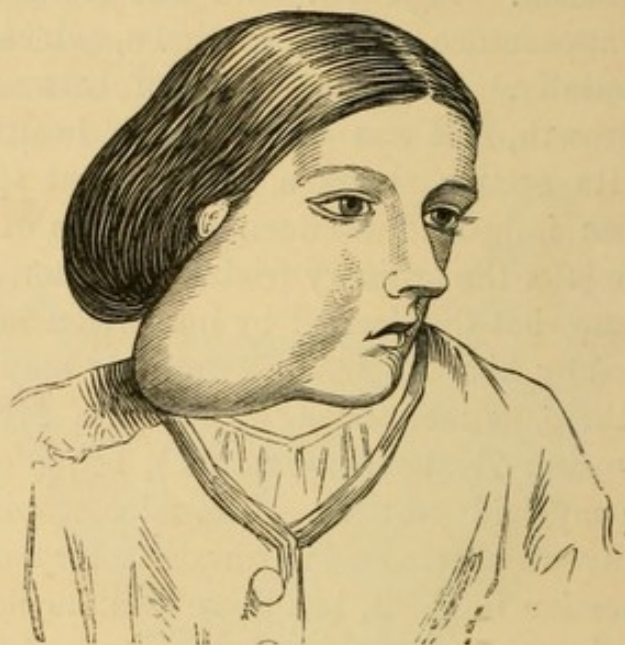
In the Museum of St. George's Hospital are four specimens of myeloid disease affecting the lower jaw (II. 166, 167, 168, 169), two of which have no history ; the others were removed from girls of eight and five years respectively, of whom the first was known to be well two and a half years afterwards. In the Museum of University College are three excellent specimens, removed by Liston (680, 1, 2), and there are three in St. Bartholomew's Hospital, all from young persons.

Myeloid disease, if not very freely removed, may recur, however, as in a case of Sir William Fergusson's, which occurred whilst I was his house-surgeon, and of which the particulars will be found in the *Lancet*, June 13, 1857. The patient, a young woman of twenty-three, had undergone a previous operation, but it was doubtful if the whole of the disease had then been removed. She presented a tumour of the right side of the lower jaw (fig. 169). Sir William Fergusson removed the tumour by sawing through the jaw at the canine tooth and disarticulating, but the patient unfortunately sank on the following day from exhaustion. The following is a



description of the tumour, which proved to be myeloid, extracted from the published report, but it may be remarked

FIG. 169.



that the colour hardly bears out the diagnosis of myeloid disease as ordinarily met with:—"It has been developed within the bone, which it has expanded into a thin envelope of compact bony tissue clothing its exterior. A section showed a surface of a clear white colour, bathed with clear serum (not milky when scraped), of considerable firmness, and presenting numerous osteoid deposits.—*Minute structure:* It is almost wholly built up of small cells, whose prevalent form is oval, either free in a dimly granular matrix, or, here and there, contained in large parent cells, resembling those of foetal marrow. Very delicate fibres occur sparingly."

A remarkable, and I believe unique, example of disease of both sides of the lower jaw, the microscopic characters of which were decidedly myeloid, was formerly under my own care, of which the following are the brief particulars. The patient, a boy of seven and a half, whose portrait is shown in fig. 170, presented a remarkable enlargement of both sides of the lower jaw, giving his face a very square appearance. The affection had come on gradually and painlessly from the age of a year and a half, and at the time I

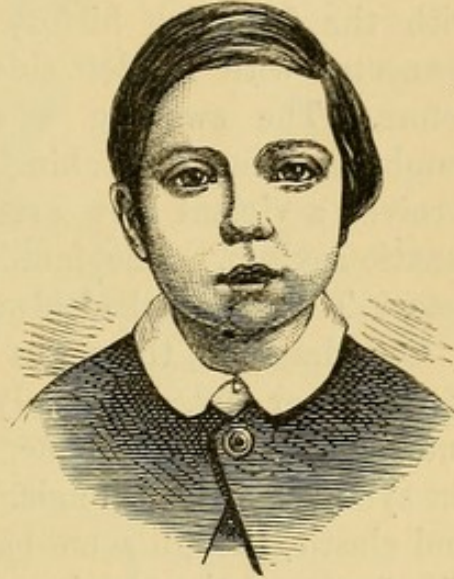


operated upon him the width of the jaw, as measured with callipers, was five inches, the width of an average adult jaw being only four inches. The growths were evidently projections from the outer surfaces of the angles of the jaws, the inner surface of the bone being natural, and the

FIG. 170.



FIG. 171.



mucous membrane of the mouth not interfered with. In September and October, 1867, I removed the right and afterwards the left tumour through incisions behind the margin of the jaw, and without opening into the mouth. The main part of each projection was sawn off the jaw, and are now in the College of Surgeons' Museum (2232), closely resembling large mussel-shells filled with a cartilaginous-looking substance, which, however (and especially some darker portions) gave distinct microscopic evidence of myeloid structure. A good deal of this material, which seemed to fill the interior of the bone, was gouged away, and the symmetry of the face restored as far as possible. The boy made a good recovery, and fig. 171, from a photograph, shows his condition three months after the second operation, and there appears to have been no tendency to recurrence. The case is given in detail in the Appendix, Case XIII.

*Chondro-sarcoma* is characterized by rapidity of growth



and by early recurrence after removal. The primary tumour is mainly enchondroma, but the recurrent growths are chiefly composed of small round-celled sarcoma, which tend to produce internal deposits through the vascular system.

The following good illustration of the disease occurred under my own care. A woman, aged forty-four, was admitted into University College Hospital on April 11, 1877, with the following history:—She first noticed a swelling connected with the left side of the lower jaw nine months before. The swelling was painful, and accompanied by numbness over the chin. Twenty years before she had received a violent blow over the jaw, when attendant in a lunatic asylum. The family history threw no light on the case. The patient had always enjoyed good health.

On admission, there was a large tumour over the left side of the lower jaw, and firmly connected with the inner and outer surfaces of the bone, extending from an inch behind the symphysis to the angle. The growth generally was firm and elastic, though some parts were much softer than others. The border of the tumour was well defined, and the skin was freely movable over it. A nodule, the size of a walnut, projected between the teeth into the cavity of the mouth. The patient complained of shooting pains in the tumour, which ran along the lower lip. There was no enlargement of lymphatic glands, and no other tumour. The general health was good. The patient's appearance is shown in fig. 172.

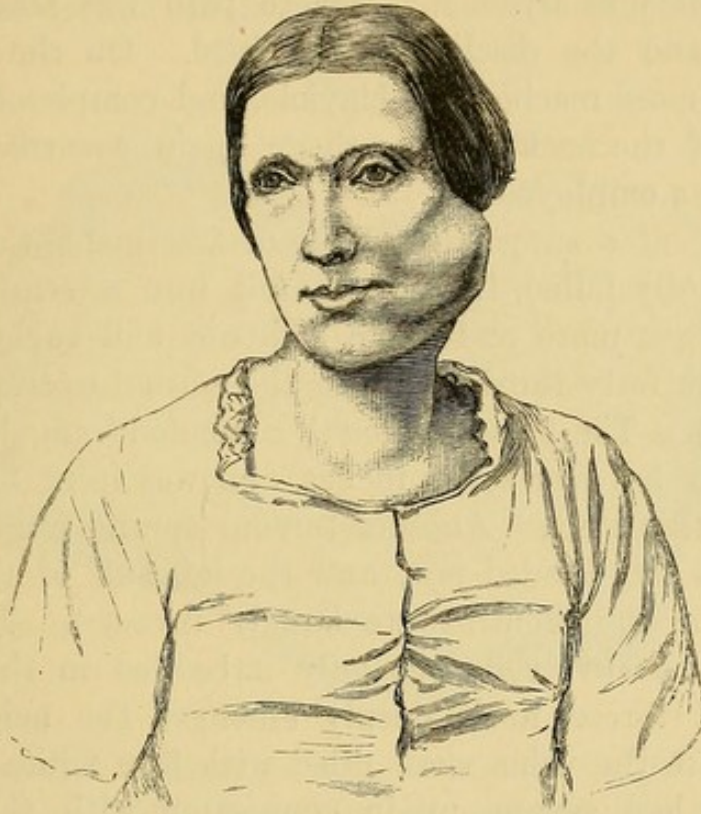
On April 14th I removed the tumour with the bone involved, from the left of the symphysis to an inch above the angle, and the patient made a good recovery.

Eleven weeks after discharge she was readmitted. The lower borders of the segments of the previously divided jaw had united by fibrous union, but a V-shaped notch existed at the upper border large enough to admit the tip of the finger. Recurrence of the growth had taken place in connection with both divisions of bone. There was a tumour as large as a hen's egg beneath the chin, but this could not be felt through the mouth, whilst a second and larger one caused bulging of the left cheek, and was mainly situated



over the ramus of the jaw ; it projected into the oral cavity and rendered articulation indistinct, although there was no

FIG. 172.



difficulty in deglutition. The skin was freely movable over both masses ; there was merely a linear cicatrix at the line of the old incision. The lymphatic glands were not enlarged, and the general health was good.

A second operation was done on August 1, 1877. It being found impossible to remove the tumour by the mouth, I made an incision along the lower border of the jaw, from two inches to the right of the symphysis for a distance of six inches. The lower lip was dissected from the bone and turned upwards, and the jaw sawn through at the symphysis, which allowed a piece on the left to be removed with growth attached. It was found that the whole of the posterior mass could not be removed, as it extended deeply into the pterygoid region, so after enucleating as much as possible, the operation was not further proceeded with. The wound was syringed out with strong solution of chloride of zinc, and then plugged with lint.



For the first fourteen days the wound continued to heal rapidly, but at this time it commenced to fungate, and on the twentieth day sharp bleeding ensued, which required the actual cautery to arrest it. Severe pain was more or less constant, and the discharge very fetid. On the 28th the fungating mass reached the clavicle, and completely hid the left side of the neck; hæmorrhage again occurred, and the cautery was employed.

In spite of a supporting plan of treatment the general health rapidly failed, the patient fell into a semi-comatose condition, got more and more asthenic and cachectic, and died on the forty-third day after the second operation.

*Autopsy.*—The mass of growth extended from the zygoma downwards for over seven inches, and was from five to six inches in thickness. Another tumour sprang from the right segment of the divided jaw, and the left side of the tongue and floor of the mouth were largely invaded. The upper jaw was not involved, but only imbedded in the growth, which had forced itself deeply amongst the neighbouring parts, where the veins were filled with firm white clots, but no growth had sprung up in connection with their walls. The tumour, on section, varied in colour, being yellowish-white in some parts, whilst it was red and vascular in others, and mottled with patches of extravasated blood. It weighed 2 lb. 3 oz. There were two nodules of secondary growth in the left lung, and three larger ones in the right lung. One of these was distinctly seen to be lying in the course of a good-sized branch of the pulmonary artery, whose walls were expanded over it. It did not completely block the lumen of the vessel, and on its surface was a white fibrinous deposit.

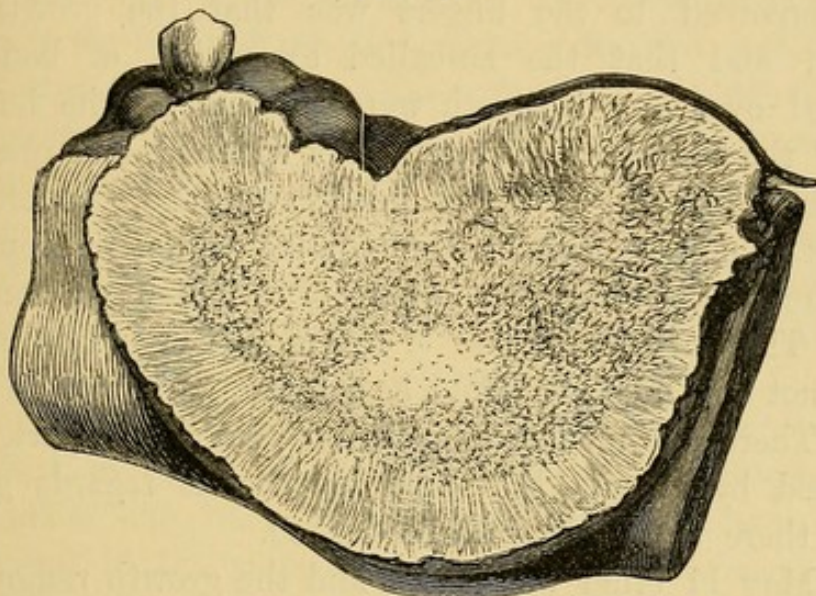
The mass removed at the first operation consisted chiefly of enchondroma, with a dim hyaline and fibrous matrix, but interspersed with islets of round-celled sarcoma. The recurrent masses were made up chiefly of round and spindle-celled sarcoma, whilst scattered throughout were isolated portions of cartilaginous tissue, with fibrous matrix.

*Ossifying sarcoma*, in which ossification takes place ex-



tensively in a matrix of sarcomatous tissue, occurs in the lower jaw, and, as in the following case, presents at first most of the characters of an ordinary osteoma. Fig. 173 shows the portion of lower jaw at first removed, with a

FIG. 173.



section of the tumour, which it is difficult to distinguish from ordinary bone, except by the striation seen best at its margins. The rapid recurrence of the disease in a soft form showed the true nature of the case, and the patient died exhausted within a year of the first operation.

W. G—, aged fifty, was admitted into University College Hospital on May 9, 1881. About five months previously he noticed a pricking pain about the left side of the lower jaw, and soon a lump appeared outside the bicuspid teeth; it grew steadily but slowly, until one month before admission. At this time the patient had several teeth extracted, and the increase in the size of the growth became rapid after this interference; there was constant gnawing pain. The patient believed exposure to cold to have been the cause of the swelling. Both his parents died of "old age," and had no kind of tumour.

On admission the lower part of the left cheek was bulged outwards considerably by a very hard rounded swelling, which covered the outer side of the left half of the lower jaw



from a short distance in front of the angle almost to the left canine; the lower edge of the bone was concealed by slight projection of the mass below it; and on pressing upwards in the submaxillary region a considerable swelling could be felt on the inner side of the bone. Altogether the impression conveyed to the fingers was that the growth was central, and that the so-called expansion of bone had occurred over it. No teeth were present on the left side behind the canine, the alveolus was widened, and presented posteriorly several low, rounded swellings, covered by mucous membrane, soft or even cystic; whilst in front lay a large crater-like ulcer, at the bottom of which no bone was bare. The tongue and floor of the mouth were normal. A small, not tender, gland could be felt behind the angle of the jaw. There was moderate constant pain in the part, much increased by hanging the head down. As regards general health there was nothing to be desired.

On May 11 ether was given, and the growth removed by an incision from the left angle to the symphysis; the jaw was sawn through to the left of the symphysis, the soft parts stripped from the growth, and then the bone was divided near the angle. The wound was closed by wire sutures, and dressed with cotton wool.

The wound was all but healed on the eighth day, quite so on the twentieth, when the man left the hospital feeling quite well.

The growth was smooth on the surface, and covered by a thin layer of fibrous tissue; it was subperiosteal, not central, and on the inner side of the jaw lay two long oval masses, parallel to the mylo-hyoid ridge—one above, one below it. A section of the large outer mass showed it to consist of solid bone, much denser than ordinary cancellous tissue, surrounded by a margin of soft greyish-yellow tissue, nowhere more than a quarter of an inch thick. Vertical striation was plain in this border, and was in part due to spicules of bone. On the alveolar border was a layer of similar soft growth, one-third to half an inch thick. Microscopically the growth consisted of rather large round and



polygonal cells, surrounded by bands of spindle cells, and tracts of fairly developed connective tissue; so that to the naked eye a section, seen by transmitted light, was made up of distinct lobules. The above description refers to the thin soft layer on the surface, and even in its substance dots of bone were numerous; whilst at its base lay a large mass of deep yellow bone, fairly dense, having large lacunæ and ill-developed canaliculi; tumour cells occupied the cancellous spaces.

Soon after leaving the hospital the patient's face swelled a good deal, and it was thought that recurrence of the growth had occurred; but a sequestrum worked out, and the swelling subsided. In three months, however, he was readmitted, having had a distinct recurrence for six weeks, with much constant pain. His health was still very good.

On September 6, 1881, the left side of the face was now swollen from two inches below the line of the jaw to above the level of the ala nasi, and from the symphysis to the lower end of the ramus of the jaw. On looking into the mouth, two large firm masses of growth were found—one above the old scar, lying in the cheek, and running back almost to the anterior pillar of the fauces; the other, below the scar, occupied the floor of the mouth. They were separated by a deep groove, at the bottom of which was a little ulceration; elsewhere, the surfaces of the growths were slightly lobulated and covered by mucous membrane.

No large glands were felt. On the following day the whole of this mass, together with the ramus, coronoid process, and condyle of the jaw, were removed by the ordinary incision for the removal of half the lower jaw.

The patient again recovered, without any bad symptoms. The hinder part of the wound gaped widely, but it was healing steadily, and there was no obvious recurrence on October 8, when the patient left the hospital.

The left angle and ramus of the jaw were surrounded on all sides by masses of new growth, in which there was very little bone, as far up as the base of the coronoid process. In the mass which lay below the scar, unconnected with the jaw, there was a large proportion of bone. Microscopically,



the growth was very similar to the primary one; there was less division into lobules, and the cells were, perhaps, smaller; the bits of bone seen were much less perfect.

On January 30, 1882, the patient was again admitted, having noticed a recurrence of the growth two months. The left cheek was now enormously swollen, and the angle of the mouth pushed forwards by a mass of new growth, fungating into the mouth along the line of the jaw, but elsewhere covered by mucous membrane. The old wound was healed, but for an ulcer an inch and a half by half an inch, round which there was a good deal of firm infiltration at its posterior end. The growth was firm and elastic at some points, bony at others, adherent to the symphysis, but not very firmly. The whole face was cedematous; the left temporal fossa rather full, and the seat of much pain. The man was still pretty strong.

On February 2 the old incision was opened up, and the main part of the growth turned out. As the skin was stripped up, the hair-bulbs could be seen springing out of the tumour; then a piece in the floor, on either side of the frænum, was removed, and the two ranine arteries cut and tied. When the tongue had been drawn forwards by a string, the symphysis was removed to just beyond the right canine tooth; and, finally, an attempt was made to remove the posterior end of the tumour; but, as it here seemed to involve the tonsil and carotid vessels, and to spread into the temporal fossa, much had to be left.

Again the patient made a good recovery. The anterior part of the wound healed, but the posterior gaped widely, and he went out with a large hole here. Pain in the temporal region continued. He died at home on April 5, having been able to walk up and down stairs to the last. The total duration of the disease would, therefore, seem to have been about seventeen months. A section from the second recurrence was more densely round-celled than either of the preceding specimens; slight traces of lobulation remained, and there was a large amount of rudimentary bone. Throughout the vessel-walls were formed by cells of the new growth.



## CHAPTER XXIV.

## MALIGNANT TUMOURS OF THE LOWER JAW.

*Round-Celled Sarcoma and Epithelioma.*

*Round-celled* or *Medullary Sarcoma* begins usually in the interior of the bone, producing rapid expansion of it, and ultimately breaking through into the mouth, and also through the skin of the face if allowed to proceed unchecked. A specimen in University College Museum (666) is a good example of the disease. The morbid growth projects chiefly on the outer side, and its most prominent part has protruded through the skin, forming an overhanging nummular projection which has an open reticular surface. On the inner side the tumour has invaded the jaw, in places destroying its entire thickness; the growth, however, scarcely projects into the mouth. As seen on the divided surface, it is composed of a soft, granular, yellowish basis, supported and parted into small polyhedral masses by narrow lines of fibrous tissue; its limit is everywhere definable. Microscopic examination shows the tumour to have all the characters of a large round-celled sarcoma.

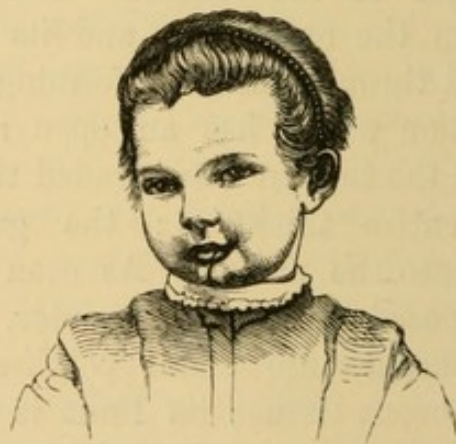Many of the museum specimens hitherto described as medullary cancer are really examples of round-cell sarcoma, and the following case of Mr. Liston's, in the College of Surgeons (2230), may be quoted as an instance of the size to which round-celled sarcoma may grow. "Part of a lower jaw, including the left condyle, the alveolus of the right first molar tooth, and all the intermediate parts which, with an enormous tumour upon them, were removed by operation. The left ascending portion and side of the jaw, as far as the



canine tooth, are completely enclosed by the tumour, and it covers both surfaces of the jaw as far as the right canine tooth. A round lobulated mass projects downwards and forwards, and in the opposite direction the tumour projects into the mouth with a rough fungous surface, in which a displaced molar tooth is seen. The interior of the tumour is indistinctly lobulated, composed of round masses connected by cellular tissue, and of a soft texture; it is invested by a thick capsule."

I had under my care a very interesting case of medullary sarcoma of the lower jaw, in a little girl, aged five—one of a numerous and healthy family, who was in perfect health until seven weeks before I saw her. The mother then noticed that the second temporary molar tooth on the right side was loose, and the gum swollen; and a tumour developed so rapidly, that when I saw her the side of the face

FIG. 174.



was considerably enlarged, and a large fungous mass protruded into the mouth. On September 10, 1867, I removed the right side of the jaw from close to the symphysis to the articulation, and the preparation is now in the Museum of the College of Surgeons (1057 A). The structure of the growth was distinctly medullary. The child made a perfect recovery, and was well for six weeks, when a small growth was noticed within the cheek, which made such rapid progress that in four days, when she was brought up to me again, there was a tumour filling the cheek, and



involving the remaining portion of the jaw as far as the canine tooth, and a fungus had been thrown out through a portion of the old cicatrix.

On Oct. 26, 1867, I removed the whole of the disease again, cutting the jaw on the left side immediately in front of the second molar tooth, and removing the whole of the skin involved in the fungus. The patient made a good recovery, and fig. 174, drawn from a photograph taken seven weeks after the second operation, shows her then condition, which was quite satisfactory, there being no evidence whatever of return, and very slight deformity, considering the amount of jaw removed.

The second growth, which was even more markedly medullary than the first, is preserved with it.

The child continued in perfect health to the end of the year, but early in January, 1868, the disease reappeared, both at the symphysis and in the masseteric region on both sides. Coupled with this there was loss of appetite, great exhaustion, and irritability of the system; and the poor child gradually sank, and died on Feb. 9, a little more than six months after the first appearance of the disease. The full particulars of this case will be found in the Appendix (Case XIV.).

This case appears to me of considerable interest, since it shows the advantage of surgical interference, even under desperate circumstances. If the first growth had not been removed, the patient would have been shortly destroyed by the fungus in the mouth, whereas the operation gave her six weeks' immunity from suffering. The return of the disease was of such a rapid nature, that it would in a very few days have destroyed the patient by hæmorrhage from the fungus which had already begun to form in the skin; but the second operation again relieved her, and restored her to comfort and apparent health for more than two months. When the disease finally appeared on both sides of the face, it was obviously beyond surgical control, and rapidly destroyed the patient. The relief which the operations afforded was, however, gratefully acknowledged by the friends of the little patient.



*Epithelioma* occurs in the lower jaw in two forms, the columnar and the squamous. Columnar epithelioma occurs in connection with multilocular cysts and with single cysts, and has been already fully discussed (p. 205). Squamous epithelioma is the more common form of disease, and is found both in connection with ulceration of the gums (p. 254) and as a tumour of the jaw. The following, under my own care, is a typical case of the latter form of the disease. A man, aged fifty-six, first noticed a swelling in his face four months before his admission; he used to have toothache, and had lost all the teeth behind the left lateral incisor in the lower jaw. When first noticed, the tumour was about the size of a small walnut, and was situated on the left ramus near the angle of the jaw. It was not painful or tender to the touch, but grew steadily. On admission to University College Hospital there was on the left side of the lower jaw a rounded, smooth swelling, which extended from the middle of the vertical ramus of the jaw to the level of the hyoid bone below, and forwards nearly to the symphysis. The swelling was firm and inelastic, and the skin over it was normal, except that it was slightly reddened over the anterior half of the growth. Inside the mouth the growth projected as a large red roundish mass, with the surface flattened and sloughy. It reached as far backward as the vertical ramus, and encroached upon the floor of the mouth. I removed the tumour, with the portion of the lower jaw implicated, by dividing the lower lip in the median line and carrying an incision beyond the angle of the jaw. The jaw was sawn to the right of the median line, between the incision and the canine teeth, and the tongue being secured with a thread, the bone was disarticulated on the left side with some little difficulty, owing to the tumour breaking away from the upper part. Consequently the coronoid process was nipped off with bone-forceps, and an elevator was used to lift the condyle out. There was very little bleeding, and only one or two ligatures were applied. The wound was sprinkled with iodoform, and brought together with wire sutures, drainage being provided for.



The patient made an uninterruptedly good recovery and left the hospital in thirty days.

The part removed consisted of the remains of the left half of the bone, the part between the vertical ramus and the central incisors being almost entirely destroyed by the growth, only a shell of bone remaining at each end. On section the growth was of a dead white colour where oldest, with a firm margin advancing into the surrounding tissues. It consisted of a fibrous stroma, in which were scattered numerous leucocytes and spindle cells, with large masses of squamous epithelium cells, many of which were collected into bird's-nest groups. The specimen is in University College Museum.

The general characters of squamous epithelioma of the jaw are well seen in the foregoing case. Rapidity of growth, with destruction of the bone, and fungation into the mouth, are the leading characteristics, and nothing but early and free removal offers any chance of relief. In the above case the jaw in its upper part was apparently healthy, but I had no hesitation in disarticulating so as to be thoroughly beyond the disease, and I also went well into healthy bone at the point of section so as to avoid, as far as possible, all risk of recurrence.

The question of the necessity for the removal of large portions of bone in cases of cancer of the lower jaw may be here referred to. Some surgeons maintain that, in a case of cancer, it is necessary to amputate at the joint above the disease in order to obtain immunity. But, if this doctrine is to be carried out fully, the *entire* lower jaw should be removed for disease of one side, for though the bone was originally developed in two halves, there is nothing to prevent malignant disease spreading across the symphysis, as was seen in the case of epithelioma under my own care.

It certainly is essential that in dealing with cancer of the lower jaw the surgeon should go beyond the disease, and not meddle with the growth itself. A preparation (College of Surgeons' Museum, 2231 A), is an instance in point. It was removed, post-mortem, from a man who



died under my care, with periosteal medullary sarcoma of the right side of the lower jaw. He had a swelling of the gum in the region of the molar teeth, which was thought by a dentist of repute to depend upon the irritation of some stump of a tooth. The growth was therefore incised, and a prolonged search made for the suspected fang, without result. The effect of this treatment was to excite very considerable action in the parts, the tumour rapidly increased in size, discharging large quantities of fetid matter, and a considerable piece of necrosed bone could be detected with the probe. The patient, when he came under my notice, was not in a condition to bear any operative interference, and shortly died. The preparation shows a malignant tumour surrounding the greater part of the right side of the jaw, the bone within being in a state of necrosis, and the condyle and part of the coronoid process having entirely disappeared.

The lower jaw is liable to be invaded by epithelioma spreading to it from the tongue and lip, and may be affected by both epithelioma and sarcoma developed in the neighbouring lymphatic glands.

On more than one occasion I have found epithelioma of the anterior part of the tongue attached to and infiltrating the central portion of the lower jaw, and have been obliged to cut out the incisive region with good result. The most remarkable case was one, the details of which will be found in the Appendix (Case XV.), of a man, aged fifty-two, who was under my care in 1875 with extensive epithelioma of the front of the tongue, which was firmly fixed by its tip to the lower jaw, with great enlargement of the submaxillary glands and infiltration of the submaxillary tissues. He suffered acutely from occipital pain, which it is difficult to explain, and was willing to submit to any operation for relief. I divided the jaw on each side  $1\frac{1}{2}$  inch from the symphysis and then removed the front of the tongue, the centre of the jaw, and all the sublingual structures with the galvanic *écraseur* (University College Museum, 1023). The patient made a rapid recovery, the two portions of jaw fell




together, and are now united at an angle by tough fibrous tissue, and the man, who was alive and well in 1883, has covered the deformity by growing a beard.

In January, 1879, I performed nearly as extensive an operation on a man, aged sixty-eight, removing the lower jaw from the right incisors to the left angle, for extensive epithelioma of the jaw and floor of the mouth, the patient making a good recovery and being in perfect health two years later, but dying with recurrence of the disease eventually (*Lancet*, November 20, 1880).

In the cases of recurrent epithelioma of the lip, when the disease shows itself in the submental glands, which become adherent to and implicate the bone, it is possible to give relief, for a time at least, by sawing out the portion of

FIG. 175.



bone involved, as I did in an old man in May, 1876. In two instances I have sawn off the chin only, without breaking the line of the alveolus, or opening the cavity of the mouth. Fig. 175 shows the first patient on whom I per-



formed the operation, and the details of the case will be found in the Appendix (Case XVI.).

Sarcomatous growths in the submaxillary lymphatic glands tend, after a time, to implicate the lower jaw, of which it may be necessary to remove a portion with the tumour. A specimen (2254) in the Museum of the College of Surgeons is the left half of a jaw-bone, the body of which has been, to a great degree, destroyed by the growth of a firm substance, which appears to have been developed on the exterior of the bone, and to have gradually produced ulceration and necrosis of it. At the angle of the jaw, adjacent to the growth, the bone is deeply and irregularly ulcerated, and near the symphysis several portions of it are completely detached. The patient was a man of forty-five, and the disease began in a hard enlargement in the situation of the submaxillary gland. After increasing for a year it extended into the mouth, where a fungous growth protruded, and subsequently the integuments of the cheek sloughed and rapidly ulcerated, and the patient died exhausted. After death secondary growths were found in the lungs and liver.

By the kindness of Mr. Wilkes, of Salisbury, I was enabled to send to the College of Surgeons' Museum (2251) a tumour near the angle of the jaw, for which that gentleman amputated one-half of the bone, which was exhibited to the Pathological Society of London, in May, 1862. The patient was a man of fifty, who had a globular mass below the middle of the horizontal ramus of the jaw, adherent to the bone, but movable. The angle of the jaw was roughened near the growth. After removal of the half of the jaw the tumour was found to be enclosed in a thick fibrous capsule, connected with the periosteum. Microscopically the tumour was composed of very small round cells, with very little stroma. It was probably a lympho-sarcoma, and may have originated in the submaxillary lymphatic glands.

Mr. Coates, of Salisbury, was also kind enough to place at my disposal another specimen of growth connected with the lower jaw, which is also in the College of Surgeons'



Museum (2252). The patient, a man aged sixty-seven, was admitted into the Salisbury Infirmary in November, 1863, with a tumour of the right side of the lower jaw, for which amputation of one-half of the bone was performed by Mr. Coates. The patient unfortunately sank eleven days after the operation. The tumour is closely connected with the periosteum on the inner surface of the jaw. It is of the size of a chestnut, and on section shows a small cavity in the interior. In minute structure it consisted of rounded masses of coalescent round or oval epithelium with large nuclei, and not of the pavement-cell type. The stroma was not abundant, and was of a distinctly fibrous nature. The growth probably arose in some structure external to the jaw.

I have recently had under my care a man of sixty-six, who noticed some stiffness of the neck for about six months before he discovered a tumour near the left angle of the jaw. When he came under my care, three months later, there was on the left side of the face a new growth involving the angle and horizontal ramus of the jaw, and reaching to the sterno-mastoid behind and the level of the thyroid cartilage below. The skin was reddened and adherent, and at one point had given way. There was no ulceration of the mucous membrane of the mouth, and the glands in the neck were not enlarged. I isolated the growth by a curved incision, including the implicated skin, and then sawed through the lower jaw behind the second bicuspid tooth, and immediately above the angle. The patient vomited persistently after the operation, and sank on the seventh day.

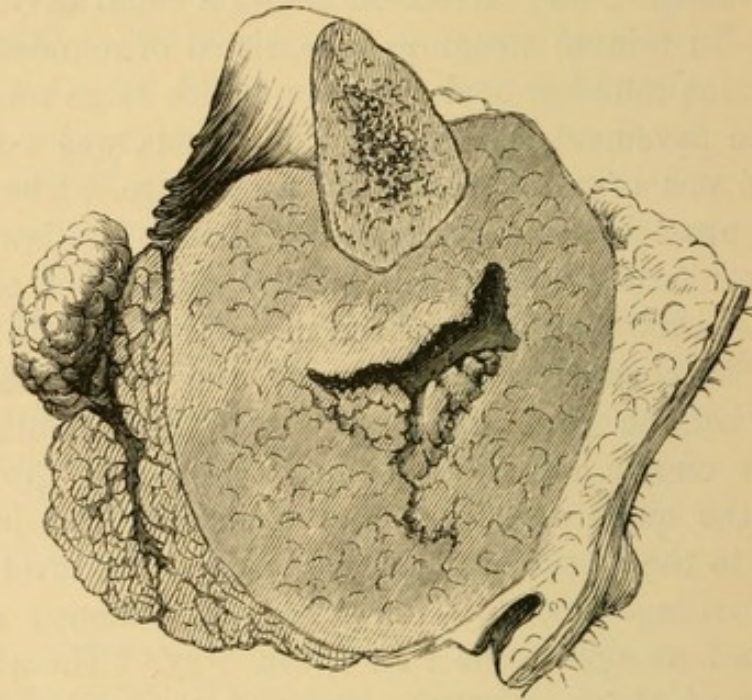
The specimen shows that the lower jaw is surrounded by a new growth which clings tightly to the periosteum, but does not reach up to the edentulous alveolar border. The hard bone of the lower border of the jaw is destroyed, and the growth penetrates into the cancellous tissue. The sub-maxillary gland lying on the inner surface of the mass is being gradually absorbed, the growth pressing on its inner surface. The surface of the tumour (fig. 176) is surrounded by a distinct outline, separating it from the neighbouring



fat. It appears to have commenced in the lymph-gland on the parotid, for of this there is no trace whatever; the remains of the submaxillary salivary gland appear perfectly healthy.

Microscopically the growth proved to be squamous epithelioma, consisting of the ordinary stroma, through which

FIG. 176.



were scattered ordinary squamous epithelial cells with "bird's-nest" fairly well marked. It is a little difficult to explain this occurrence of squamous epithelioma, since the mouth was in no way involved, and so far as could be made out there was no primary disease elsewhere.



## CHAPTER XXV.

DIAGNOSIS AND TREATMENT OF TUMOURS OF THE  
LOWER JAW.

*Diagnosis.*—The diagnosis of tumours of the lower jaw is easier than is the case in the upper jaw. Slowness of growth, hardness, and isolation point to a non-malignant tumour, and this will be confirmed if there is no tendency to fungate within the mouth, and no enlargement of the neighbouring lymphatic glands. Simple tumours of the lower jaw, if allowed to grow unchecked, may after a time burst through the skin, and thus give rise to a fungating mass, which, however, is of slower growth and more healthy appearance than the malignant fungus. Rapidly growing tumours are almost invariably cancerous, and the only chance for the patient is their early removal, with the portion of bone implicated.

The *prognosis* after removal of tumours of the lower jaw is more favourable than elsewhere, since, owing to the anatomical relations, it is easy to get rid of the whole disease. The question of the return of cancer being influenced by removal of one-half of the bone is, as already mentioned, still an open one.

The successful recoveries following removal of large portions of the lower jaw are very remarkable, operations on the lower jaw being as a rule attended by little constitutional disturbance. Mr. Cusack removed large portions in seven cases, with only one fatal result, which was due to erysipelas and œdema of the glottis. Dupuytren operated in twenty cases, with only one death resulting from the operation, and that from the same cause as in Mr. Cusack's fatal case. The experience of modern surgeons is equally



favourable. When the disease is of ordinary dimensions, and the patient is in fair health, the results are exceedingly satisfactory.

*Operations on the Lower Jaw.*—Small tumours, involving the alveolus, may be removed with bone-forceps without any incision through the skin, and even a considerable portion of the central part of the lower jaw may be removed without incising the lip, if the mucous membrane between it and the bone be freely divided and the lip drawn well down. The large forceps figured at page 245 are particularly useful in attacking tumours situated in the molar region without external incision, and the gouge and chisel should be freely employed for the enucleation of benign tumours in the interior of the lower jaw.

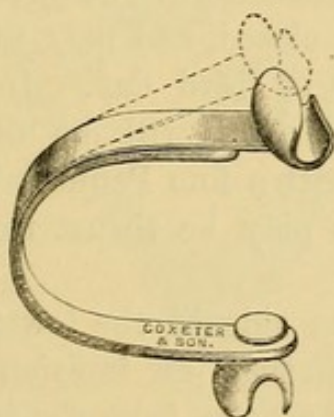
The late Mr. Maunder (*Medical Times and Gazette*, July, 1874) removed two fibrous tumours of the lower jaw of considerable size without any external incision, separating the soft parts with a raspatory, and sawing the bone in front of and behind the tumour. The principal difficulty in these operations was not so much the separation of the tumour as its "delivery" through the mouth, which was slightly split in one instance. Fortunately the hæmorrhage in both cases was slight and the patients did well, but another surgeon who adopted the proceeding was less fortunate, and lost his patient by secondary hæmorrhage, which, considering the close proximity of the facial artery and the necessary division of the inferior dental artery, is not very surprising. For my own part, I do not think the extra trouble and risk of the proceeding are balanced by the absence of a scar, which, in the majority of cases, need not involve the lip, and if properly placed will be nearly invisible afterwards. The same may be said of the so-called "sub-periosteal resections" of the lower jaw. In cases of necrosis it is, of course, advisable to preserve all the periosteum, and in extracting a sequestrum it may be occasionally necessary to turn aside soft parts with a raspatory, but any systematic stripping of periosteum from a jaw involved in a tumour, is not only impossible, but, if undertaken, will surely leave



shreds of periosteum with, possibly, some portion of disease attached.

In order to operate satisfactorily within the mouth it is essential that the jaws should be kept fully asunder, and I have found nothing so convenient for the purpose as a simple vulcanite "prop" similar to that used by dentists, placed in position on the side opposite to the disease before the administration of chloroform. A string attached to it obviates any danger of its being swallowed. The ingenious gag contrived for dental operations by Mr. S. J. Hutchinson (fig. 177) may also be employed for the same purpose.

FIG. 177.



When a large portion of the body and ramus has to be removed, a curved incision may be advantageously carried along the posterior margin of the tumour, so that the scar may be well out of sight afterwards. In this the facial artery will be necessarily divided at the anterior border of the masseter muscle, and it is advisable to secure both ends immediately with ligatures, or the patient may lose a considerable quantity of blood. The tissues being then dissected off the tumour, a careful examination of it should be made to see if it be possible to extract the tumour by removing the external plate of bone with the gouge and bone-forceps, and no harm can come of such an attempt, even if it prove abortive, since no vessel of importance is interfered with. If necessary, however, a small saw can be applied in front of and behind the affected portion, which can then be readily isolated and removed.



In making these sections of the lower jaw it is better not to complete one before the other is begun, because of the loss of resistance consequent upon breaking the continuity of the bone; but both cuts, being carried nearly through the bone with the saw, may be conveniently completed together with the bone-forceps.

When the central portion of the lower jaw is removed, it is well to take precautionary steps to avoid the possibility of the tongue falling back and suffocating the patient. A ligature should therefore be passed through the tip of the tongue, which will enable a trustworthy assistant to keep it drawn forward until the operation is completed. The ligature should then be attached to one of the hare-lip pins with which the wound is closed, and may safely be cut and removed on the second or third day. In all cases in which the inferior dental artery will be divided, the operator should be provided with a fine Paquelin's cautery or a small plug of wood, which may be thrust into the dental canal to stop all bleeding.

Amputation of one side of the lower jaw can be conveniently performed through an incision running along the posterior margin of the bone, from the level of the lobule of the ear to the median line, where, if the size of the tumour renders it necessary, a vertical incision may be carried through the lip (fig. 178). The facial artery having been secured, the tissues of the cheek and the masseter are dissected up, without injuring the flap and without prolonging the incision upwards, by which the facial nerve would be of necessity divided. A tooth having been extracted at the point where the bone is to be divided, this is effected with a small straight-backed saw, and the bone having been grasped with the "lion forceps," is drawn forcibly outwards, whilst the knife is run along its inner side, care being taken to keep close to the bone, so as not to endanger the submaxillary gland or lingual nerve. The internal pterygoid muscle having been carefully separated from the bone, forcible traction is to be made upon the jaw, so as to depress the coronoid process, which by a few touches of the knife is



freed from the fibres of the temporal muscle. The joint being now in view, the knife is to be applied to the front of it, when the condyle will be at once dislocated, and the knife can be carried cautiously behind it, so as to isolate it. A forcible wrench of the bone will now tear through the few remaining fibres of the external pterygoid muscle, and the

FIG. 178.



bone can be removed. At the same time care must be taken not to twist the jaw outwards, so as to force the condyle and neck of the bone against the internal maxillary artery, which might thus be torn.

In order to obviate the difficulty which often occurs at this stage of the operation, Dr. Gross recommends a flat bone-elevator, to clear the coronoid process and condyle, and thus avoid all danger to the artery. Having employed this plan on several occasions I can strongly recommend it. Mr. Bryant has in some cases dissected up the periosteum and slipped the condyle out of it, but there appears to be a



danger of leaving disease behind in many cases, if this plan were generally adopted.

In the case of small tumours, removal of one-half of the lower jaw is sufficiently easy, but, when the tumour is large, it may so completely wedge in the upper part of the bone as to hinder the freeing of the coronoid process, and prevent dislocation. Under these circumstances the best plan is to use the bone-forceps to cut off the coronoid process, or to re-apply the saw and cut off the tumour as high as may be, and subsequently to remove the remaining portion of jaw, if the disease is malignant, but not otherwise. Another complication is when the tumour breaks away from the upper part of the jaw during the operation, thus rendering it difficult to dislocate the condyle, owing to the want of leverage. The "lion-forceps" of Sir William Fergusson is exceedingly useful here, as I have experienced in several cases.

When one-half of the lower jaw has been removed, some inconvenience is experienced from the remaining portion being drawn inwards by its muscles. To obviate this, Mr. Nasmyth, of Edinburgh, originally contrived some metallic caps to fit the teeth of the upper and lower jaws, and thus keep the bone in position. Mr. Liston speaks highly of this apparatus, and a similar contrivance made by Mr. Cartwright was of great service in the case of the patient of Sir W. Fergusson, whose portrait is shown at page 184. I have employed a double vulcanite cap for the teeth for the purpose, as being more cleanly, but have found so much pain caused by the constant tension of the muscles of the unaffected side which are left without opponents, that I have abandoned the method altogether, and am content to allow the remaining portion of jaw to be thrust inwards, as it certainly will be sooner or later.

In the case of very large tumours, necessitating the removal of the greater part of the lower jaw, the direction of the incision is a matter of considerable importance. Figs. 179 and 180 show the incision recommended by Sir William Fergusson in cases of the kind; the great advantage being

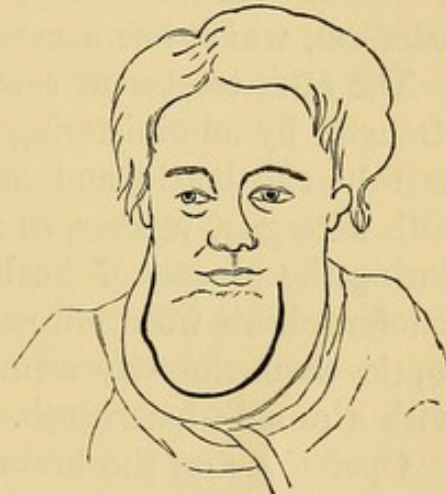


the non-interference with the lip (which is dissected up with the integuments of the chin), and the fact that the scar is completely hidden afterwards. On the other hand, this incision necessitates the division of both facial arteries, and if disarticulation on one side is requisite, will not afford good room for the proceeding without danger to the facial nerve. In a case of very large osteo-sarcoma of the lower jaw, already described, I preferred an incision through the median line of the lip, and was able to dissect the flaps back with great ease and rapidity, and to avoid cutting either of the facial arteries. The median line is, after all, the best position for a

FIG. 179.

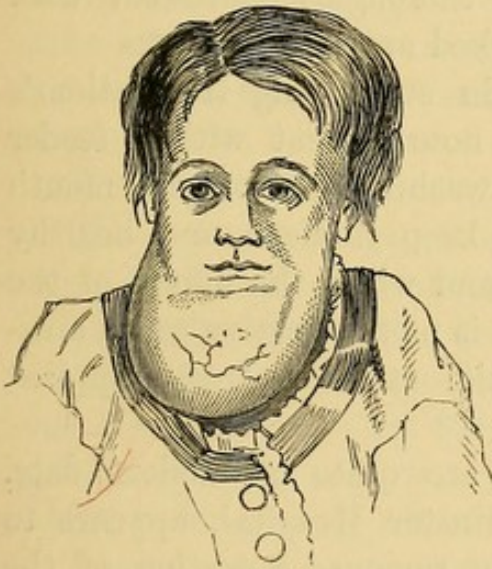

FIG. 180.



cicatrix, and I regard the division of the lower lip, which always readily unites again, as a very unimportant matter.

The case in which Mr. Syme removed the ramus and condyle of the jaw without opening the mouth, through an incision in front of the ear, has been already referred to, and Professor Humphry adopted a similar incision in the case in which he excised the condyle of the lower jaw, which will be found in the *Association Medical Journal* for 1856.

Whatever the operation which has been performed, care should be taken to secure all bleeding vessels, and when there are bleeding points deep in the wound which cannot thus be treated, the actual cautery should be applied to them. The dental artery, necessarily divided in sawing the



jaw, is sometimes troublesome if its mouth is not touched with the cautery, or the dental canal plugged with a small piece of wood. The incision in the skin should be carefully adjusted with fine wire sutures, and the lip brought together with hare-lip pins and a twisted suture, a fine silk suture being put in the red mucous-membrane. Care must be taken to provide for the drainage of the wound by leaving an opening at the most dependent part, into which a drainage tube may be put, and if necessary a light bandage may be applied to support the parts. At the time of the operation the wound may be thoroughly sponged out with a solution of chloride of zinc (gr. 40 ad ℥j), or better, the whole of the wound may be thoroughly sprinkled with iodoform, which has a most marked antiseptic effect.

The after-treatment consists in supporting the patient's strength by administering fluid nourishment with a feeder or tube and bottle, and careful washing out of the mouth with detergent washes, so as to keep it clean and healthy during the process of healing; and when the effects of the iodoform have worn off, nothing is more effective as an antiseptic than the *Glycerinum acidi carbolici* freely applied with a camel's-hair brush.

Operations on the lower jaw are quite of modern date. Anthony White, of the Westminster Hospital, appears to have been the first surgeon who removed a portion of the lower jaw (1804). He was followed by Dupuytren (1812), Mott and Gräfe (1821), and Sir P. Crampton in 1824. Cusack's celebrated cases of disarticulation occurred immediately afterwards, and the operation became an established one. The names of Liston, Syme, and Fergusson have been prominent in connection with the operation in this country, whilst abroad Lisfranc, Lallemand, Maisonneuve, Gensoul, and other eminent men, have given it their support.

It has been already noticed how little deformity often results from the removal of portions of the lower jaw. Although the bone is never reproduced, a development of firm fibrous tissue takes its place, which affords support to artificial teeth, and to which the muscles gain a firm attach-



ment. In February, 1855, Mr. Spence, of Edinburgh, brought before the Medico-Chirurgical Society of Edinburgh a preparation illustrating this point in a marked manner. Eighteen years before the patient's death, Sir William Fergusson had removed the greater part of the right side of the lower jaw. Five years later Mr. Spence had removed the left side of the jaw from within half an inch of the symphysis to the articulation, and the condition found at death, thirteen years after, is thus described (*Edinburgh Medical Journal*, April, 1855) :—"A dense fibrous texture connected the small portion of the ascending ramus of the right side with the remaining portion near the symphysis, whilst on the left side a similar texture occupied the place of the disarticulated bone, on both sides affording firm attachments to the masseters and other muscles, so that the patient during life had considerable use of the mouth."

The tendency of the muscles to force the remaining portion of the jaw out of place has been already referred to. In cases in which the central portion of the jaw has been removed, the force of the muscles on both sides being equally exerted, the rami of the jaw become closely approximated, and are united by very firm fibrous tissue. This, of course, gives a peculiar narrowness to the lower part of the face, which is fortunately concealed in men by wearing a beard.

The supplying of artificial teeth to a patient who has undergone removal of a portion of the lower jaw will tax the ingenuity of the dentist considerably, for when the muscles have forced the remaining portion out of position, it becomes necessary to employ means to bring the parts into their normal relation so as to obtain a proper "bite." The vulcanite rubber forms a most useful base for the artificial teeth, and if firmly attached to the remaining portion of jaw it moves very satisfactorily with it, lying in the hollow of the cheek and resting upon the dense fibrous tissue of the cicatrix.



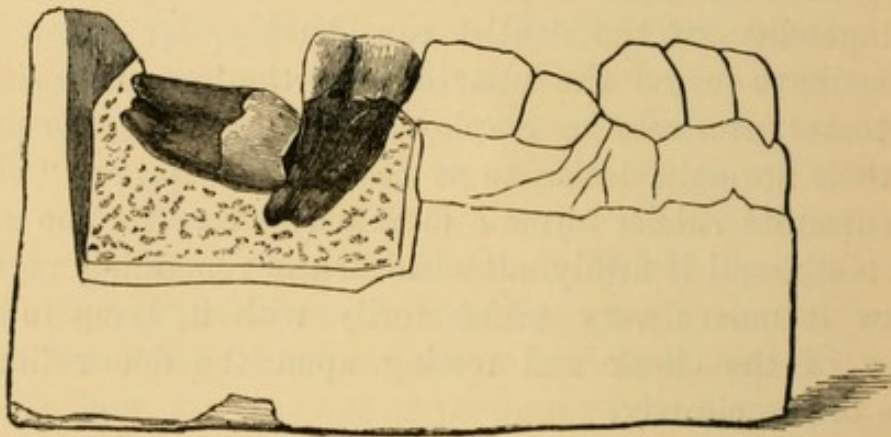
## CHAPTER XXVI.

## CLOSURE OF THE JAWS.

*Spasmodic Closure of the Jaws*, which may be of several weeks' duration, is almost invariably connected with the eruption of the wisdom teeth of the lower jaw. Owing to want of room between the second molar and the ramus of the jaw, or owing to some malposition of the tooth itself, the wisdom tooth is unable to assume its normal position, and by the pressure which it exerts on the neighbouring structures, sets up irritation, which induces a state of tonic spasm of the masseter and internal pterygoid muscles. This fact has long been known to dental surgeons, and is especially alluded to by Mr. Salter in his essay on "Surgical Diseases connected with the Teeth" (*System of Surgery*, vol. ii.).

The accompanying engraving (fig. 181), for which I am indebted to Mr. Felix Weiss, shows the condition of parts

FIG. 181.



found by him in a gentleman aged forty-three, who suffered long and severely from pain and spasmodic closure of the



jaws, due to the irritation caused by the wisdom tooth lying imbedded horizontally in the alveolus, and pressing against the fang of the second molar. It was only after the extraction of the second molar that the wisdom tooth was found and removed, with complete relief of the symptoms (*Trans. Odontological Society*, 1876).

In a discussion which took place at the Odontological Society, in May, 1861, and is reported in the *British Journal of Dental Science* of the same month, Mr. Tomes mentioned a case of retarded eruption of the wisdom tooth with closure of the jaws, which had been allowed to go unrelieved for more than two years, and was immediately cured by the removal of the second molars, so as to allow the wisdom teeth to assume their proper position. Mr. Coleman, Mr. Mummery, and Mr. Ibbetson narrated on the same occasion very similar cases treated in the same manner; and Mr. Drew mentioned a case in which extraction of the half-cut wisdom tooth itself gave immediate relief.

The majority of these cases occur about the age of twenty, when the eruption of the wisdom tooth is to be expected, and the diagnosis is readily made. The treatment is obvious. The mouth must be opened by a screw gag, or by a spiral screw wedge of boxwood, under chloroform, and either room must be made for the wisdom tooth by extracting the second molar, or, if it can be reached, the wisdom tooth itself may be removed.

The impeded eruption of wisdom teeth gives rise to various and apparently anomalous symptoms, which are often not traced to their true source, such as persistent neuralgia, not always referred to the part involved; but the most serious result is the formation of extensive abscesses, which burrow extensively about the angle of the jaw and cheek, leading to great scarring and permanent deformity. In a young lady, seen by me in consultation some months back, the mischief resulting from an impacted wisdom tooth was sufficient to put her life in some jeopardy, and has left her face permanently scarred by extensive abscesses.



*Permanent Closure of the Jaws.*—Cases of permanent closure of the jaw from cicatrices within the mouth, &c., are not of very rare occurrence; but their description and treatment seem to have been very generally neglected by modern English authors. Samuel Cooper, in the last edition of his "Surgical Dictionary" which he revised, merely refers to a case treated by Valentine Mott, who, in 1831, operated on a case of sloughing of the cheek, with subsequent closure of the jaws, by transplanting a piece of skin (see *American Journal of Medical Science* for Nov. 1831); but he enters no farther into the treatment. In the new edition of "Cooper's Dictionary, 1861, vol. i., the only passage I can find, bearing on the question, is the following, under the head of "Cicatrization:"—

"In the mouth, after sloughing of the cheek and gums from profuse salivation, the cicatrized surface is so rigid as scarcely to allow of the separation of the teeth, but it becomes more pliant in time." This latter statement, however, is not borne out by general experience.

Sir William Fergusson, in the fourth edition of his "Practical Surgery," p. 602, says:—

"The lower jaw occasionally becomes so closely bound to the upper, that the teeth cannot be sufficiently separated to admit of solid food. This condition may arise from inflammation and adhesion of the gums, more especially after necrosis of the alveolar processes; sometimes it is the result of chronic contraction of a muscle; occasionally it has been accompanied with ankylosis, both here and in other joints, of which there is a remarkable specimen in the possession of M. Dubreuil, of Montpellier, in which, however, a similar condition was not present in any other part of the same skeleton; and in certain examples it is difficult to say what is the cause. Some years ago I had a patient with the mouth thus contracted, and in whom there was a portion of the lower jaw in a state of caries: the disease was not in such a condition that I could, with propriety, attempt its entire removal. A portion of bone, however, was excised, but little benefit resulted, and what there was might probably be attri-



buted more to the use of a screw-dilator than to the partial removal of what I considered a source of irritation. Mott has succeeded, in two instances, in relieving such permanent adstrictions; and in the first volume of the *Provincial Medical and Surgical Journal* there is a case recorded wherein I was fortunate enough to produce a similar effect, by dividing the masseter on one side with a narrow knife, passed from the mouth between that muscle and the skin. If ankylosis be the cause of closure, it is doubtful if the surgeon would be justified in interfering. In the course of my experience I have seen many instances of the kind above referred to, but feel bound to state that most of my attempts at improvement have utterly failed."

By far the most complete account of this affection is given by Dr. Samuel Gross, of Philadelphia, in his large work on surgery, from which I take the following quotation:—

"*Ankylosis, or Immobility of the Jaw.*—This distressing affection, which may be produced in a variety of ways, may exist in such a degree as to render the patient entirely unable to open his mouth, or to masticate his food.

"The most common cause, according to my observation, is profuse ptyalism, followed by gangrene of the cheeks, lips, and jaw, and the formation of firm, dense, unyielding, inodular tissue, by which the lower jaw is closely and tightly pressed against the upper. Such an occurrence used to be extremely frequent in our south-western States during the prevalence of the calomel practice, as it was termed, but is now, fortunately, rapidly diminishing.

"Children of a delicate, strumous constitution, worn out by the conjoint influence of mercury and scarlatina, measles, or typhoid fever, are its most common victims; but I have also seen many cases of it in adults and elderly subjects. In the worst cases there is always extensive perforation of the cheeks, permitting a constant escape of the saliva, and inducing the most disgusting disfigurement.

"Secondly, the affection may depend upon ankylosis of the temporo-maxillary joints, in consequence of injury, as a severe sprain or concussion, or arthritic inflammation, lead-



ing to a deposition of plastic matter, and the conversion of this substance into cellulo-fibrous, cartilaginous, or osseous tissue. I have met with quite a number of such cases, several in very young subjects.

“Thirdly, the immobility is occasioned by a kind of osseous bridge, extending from the lower to the upper jaw, or from the lower jaw to the temporal bone; such an occurrence, however, is not common, and is chiefly met with in persons who have suffered from chronic articular arthritis.

“Finally, immobility of the jaw may be caused by the pressure of a neighbouring tumour, especially if it occupies the parotid region, so as to make a direct impression upon the temporo-maxillary joint.

“However induced, the effect is not only inconvenient, seriously interfering with mastication and articulation, but it is often followed, especially if it occur early in life, by a stunted development of the jaw, exhibiting itself in marked shortening of the chin, and in an oblique direction of the front teeth.

“When complicated with perforation of the cheek and destruction of the lips, the patient has little or no control over his saliva, and is so terribly deformed as to render him an object at once of the deepest disgust and the warmest sympathy.

“The treatment of this affection must depend upon the nature and situation of the exciting cause. When the difficulty is in the joint, occasioned by the formation of cellulo-fibrous adhesions, the only thing that can be done is to break up the adhesions, upon the same principle as in ankylosis of any other joints. For that purpose—the patient being thoroughly under the influence of chloroform—the jaw is forcibly depressed, either by a wedge made of cedar-wood, or by an instrument constructed on the lever-and-screw principle, and figured by Scultetus in his ‘*Armamentarium Chirurgicum*.’

“When the immobility depends upon the presence of inodular tissue, the proper remedy is excision of the offending



substance—an operation which is both tedious, painful, and bloody, and, unfortunately, not often followed by any but the most transient relief, owing to the tendency in the parts to reproduce the adhesions, however carefully and thoroughly they may have been removed. There is the same remarkable disposition in these cases to the contraction and regeneration of the inodular tissue, as in the case of burns and scalds.

“During my residence in Kentucky I had a large share of such cases; and, although I never failed to make the most thorough work—not unfrequently repeating the operation several times at intervals of a few months—it is my duty to state that few of them were permanently relieved. After the excision is effected, the patient must make constant use of the wedge, wearing it for months and years, so as to counteract the tendency to reclosure.

“Immobility of the jaw, caused by the formation of an osseous bridge, might possibly be remedied by the removal of the adventitious substance by means of the saw and pliers. The great difficulty, however, in such an event, is the obscurity of the diagnosis.”

I must now refer to an essay by Dr. Frederic Esmarch, Professor of Surgery in the University of Kiel, on “The Treatment of Closure of the Jaws from Cicatrices,”\* in which he investigates the pathology of the affection, and describes an operation for its relief by the formation of an artificial joint in the lower jaw—an operation which has given most satisfactory results in cases under my own treatment.

Professor Esmarch says :

“Injuries to the mucous membrane of the cheek damage the mobility of the lower jaw in a greater or lesser degree by their cicatrization, as is well known.

“The cause of this ankylosis of the lower jaw is often thought to be a growing together of the inner surface of the cheek with the bones or gums; this is not a correct view,

\* “Die Behandlung der narbigen Kieferklemme durch Bildung eines künstlichen Gelenkes um Unterkiefer.” Kiel, 1860.



however, and has, in many cases, led to improper treatment. In order to clear up this error it is necessary to examine the conditions which, in health, make movements of the lower jaw within the mouth possible. The cavity of the mouth is divided by the alveoli and teeth into an inner and outer space; the latter is closed in front by the cheeks and lips, which form an elastic dilatable sac; within this the rows of teeth can be separated from each other, even with the lips shut, and much further when the mouth is opened. The inner surface of this sac is covered by a mucous membrane which is also very dilatable and elastic, and which forms a duplicature at the upper and lower boundaries of the outer cavity of the mouth, where it is reflected on to the outer surface of the bone, and ends on the edges of the alveolus as gum. This membrane is so elastic that when the mouth is open to its widest extent it is still by no means put on the stretch; whilst, when the mouth is closed, it presents no folds.

“It is clear that as soon as this dilatable sac shrinks together, loses its elasticity, or is replaced by a rigid substance, the mobility of the jaw must either be injured or entirely cease. This happens most frequently through the formation of cicatrices which follow ulceration or sloughing of the mucous membrane of the mouth, as from mercurial stomatitis or noma.

“The occurrence of what we call secondary cicatrix-atrophy, or cicatrix-contraction, is sufficiently well known. As soon as the cure commences, the movable parts of the neighbourhood, so far as they can be, are drawn by the shrinking of the newly formed tissue towards the cicatrising spot; slowly, it is true, but with almost irresistible power.

“If there are no parts in the neighbourhood which can be drawn together to repair the loss of substance, there necessarily follows a cicatrification of the surface; but the cicatrix remains thin, tender, and stretched to a great extent for some time at least after its formation; it is only after it has existed for a long time that it assumes a more ductile con-



dition, so as to become something more like the natural skin or mucous membrane.

"If, therefore, the mucous membrane of the cheek be completely destroyed from one alveolus to the other, on both, or merely on one side, the resulting cicatrix must necessarily tend to press the jaws more and more closely against one another, the depressor muscles of the lower jaw being quite incapable, as experience has shown, of preventing the contraction of the cicatrix. When cicatrization is complete, the elastic ductile mucous sac of the cheek is found to have disappeared, and instead of it the cicatrix tissue stretches so tightly from one alveolar edge to the other, that it is scarcely possible to put the finger between it and the rows of teeth; and the teeth themselves can be separated only a little, if at all, or only shifted from side to side very slightly.

"Just the same immobility of the lower jaw follows cicatrization after sloughing involving the whole thickness of the cheek, although here the opening of the mouth is widened as far as the anterior edge of the masseter muscle, or still farther; and in this case, too, the cheek sac is entirely destroyed. In these cases it is the *quasi* lip or posterior margin of the gap which stretches tightly from one jaw to the other. If, in such cases, one is successful in covering the loss of substance by dividing the skin, or by transplantation of a flap, the cicatrization of the inner surface of the flap (being uncovered by mucous membrane) necessarily has the effect of increasing the immobility of the lower jaw.

"As far as is known there are few or no means available to check the shrinking of cicatrices. It is one of Dieffenbach's great services to surgery that he gave this theory its full value; it was he who first taught us to place a proper value upon this action of Nature, and showed how to make it available for operative procedures under certain circumstances. Thus, he first taught how to cure the closure of the mouth by covering the margin with mucous membrane; to form eyelids which do not adhere to the globe or roll inwards after cicatrization; and many other methods which we now consider self-evident in plastic surgery.



“Also, for the treatment of the worst cases of cicatrised contracted jaw, Dieffenbach has given the most rational advice when he suggests, after the separation of the cicatrix from the bones, to lay over the surface of the wound a sound flap of mucous membrane. Unfortunately, in most cases, this cannot be done, because, just in the neighbourhood of the cicatrix, it is impossible to find more healthy mucous membrane. Instead of the mucous membrane one can undoubtedly do as Jaesche did (*Med. Zeitung Russlands*, xxvii. 1858), viz., make use of a flap of skin for a lining; still it is difficult in many cases to get such a flap from the immediate neighbourhood. I would not hesitate, however, in desperate cases—as, for instance, where there is a great deficiency on both sides—to take a flap from the skin of the arm.

“All the hitherto received methods, such as the freeing or cutting through of the cicatrix from the mouth—the separation of the whole cheek, in order to accomplish this perfectly—the extirpation of the mass of cicatrix—the application of mechanical apparatus in order to drag the jaws asunder by degrees, &c. &c., can only be of avail in those cases where, in some angle or other, there is found a remnant of mucous membrane. If one succeeds after separation of the cicatrix, in preventing, by the application of mechanical means for a long time, the cicatrification in the undesirable direction, the contraction will take place in another direction, and by degrees will drag the remnant of mucous membrane up to the skin. In every case it takes years before such methods can be properly estimated; for, as far as is known, the secondary shrinking of a cicatrix takes place very late, even after complete or sufficient healing over has occurred. Putting aside the more favourable cases, there still remains a number of patients of this kind, in whom the usual methods produce no lasting cure, just because there is no more old mucous membrane left; and for these cases I recommend the formation of an artificial joint *in front of* the contraction, in order to give, at least, the other half of the jaw some, although a limited, motion, and so to lessen considerably the sufferings of these unfortunate patients.



"The formation of an artificial joint in the ramus of the jaw has already been recommended and tried by Dieffenbach ('Opérative Chirurgie,' i. 435), but *behind* the contraction, and naturally without any good result, since the impediment to motion lies more forward, and thus is not removed. Von Brüns has also operated in this manner without success."

This proposal of Professor Esmarch to form a false joint in front of the cicatrix was suggested to him by a case which came under his care in 1854, in which considerable destruction of the cheek and contraction of the cicatrix had occurred, together with immobility of the lower jaw and necrosis of a portion of it. The necrosed portion was fortunately in front of the cicatrix. The bone having been removed, it was found that mobility was restored, and a useful amount of movement obtained. Professor Esmarch therefore suggested, at the Congress of Göttingen, in 1855, the removal of a piece of bone in cases of contracted cicatrix; but did not happen to meet with a case suitable for the operation until after it had been successfully performed by Dr. Wilms, of Berlin, in 1858, shortly after which he himself operated upon a case at Kiel, and with the best results. The operation was subsequently performed by Dittl, of Vienna (*Oest. Zeitschrift für praktische Heilkunde*, vol. v. p. 43, Vienna, 1859); and by Wagner, of Königsberg (*Annali di Medicina di Koenigsberg*, vol. ii. p. 100, 1859).

Shortly after this proposal of Esmarch, it would appear that Professor Rizzoli, of Bologna, quite independently conceived a somewhat similar idea, but modified the proceeding by merely cutting through the jaw, without removing any portion of bone. He operated in this way first in 1857, and subsequently had three other successful cases. In Rizzoli's cases no external incision appears to have been made, but the section was accomplished from the mouth with powerful forceps. This proceeding has been followed by Professor Esterle, from whose essay in the *Annali Universali di Medicina* (Omodei, vol. clxxvi.), I have extracted these particulars.

Esmarch's operation appears to me to possess a decided



advantage over that of Rizzoli, in the fact that a piece of bone is removed, by which the formation of a false joint is facilitated, as we know by experience in cases of resection of the elbow, &c.; and the external incision can never be a matter of any importance, whilst it admits of the application of the saw, and so avoids risk of splintering the bone.

Mr. Mitchell Henry was, I believe, the first surgeon to put Esmarch's operation into practice in this country, he having performed it a few weeks before myself. The patient was a female, on whom a variety of operations had been performed (among others, division of the masseter), and whom I had had under my own care at the St. George's and St. James's Dispensary, two years before, when I divided the cicatrices freely and screwed the mouth open, but without permanent benefit. Mr. Henry employed the chain saw, and removed about half an inch of bone. The patient, unfortunately, sank a few days afterwards, apparently from pyæmia and exhaustion. In my own cases I used an ordinary narrow saw, in preference to the chain, and was enabled to remove sufficient bone to give free movement, through a small incision along the edge of the jaw.

The subject of the contraction of cicatrices in the mouth, and their treatment, though it has attracted little notice among British authors, in Paris, on the contrary, has excited much attention, and has furnished the topic of frequent discussions at the Société de Chirurgie. Since the date of the publication of a paper upon the subject by M. Verneuil (*Archives Générales*, 1860), several operations have been performed by French surgeons, but apparently with but little success, since in cases operated on both by the method of Esmarch and of Rizzoli reunion of the divided jaw has taken place.

Thus, on the 4th of February, 1863, M. Boinet brought before the Society a little girl on whom he had previously performed what he terms Esmarch's operation (but which appears to have consisted in the simple division of the jaw, recommended by Rizzoli, and not the removal of a wedge of bone, as originally proposed by Esmarch), and in whom



the bone had reunited. M. Deguise thereupon quoted a case in which he had removed a centimetre and a half of bone with the same unsatisfactory result, and expressed a doubt whether a single successful case could be produced. On the 11th of February, 1863, M. Deguise brought the case he had alluded to before the Society, and showed that the failure "depended upon the formation of an osseous callus at the level of the resected portion." At the same meeting M. Bauchet showed a young Syrian girl in whom contraction of the left side had taken place, together with a loss of substance of the cheek and commissure of the lips, equalling a five-franc piece in size. In this case a centimetre and a half of the jaw was removed; and though extensive suppuration and necrosis of the jaw ensued, the girl made a good recovery, and at that date (February 4) a very satisfactory amount of movement and power of mastication had been obtained.

On the 29th of July, 1863, M. Verneuil communicated to the Société de Chirurgie the histories of several cases operated upon by M. Rizzoli himself, the results of which were most satisfactory. In the first the operation (simple division of the jaw from within the mouth) was performed in 1857, and after six years the boy was able to eat solid food most satisfactorily; the second case, operated upon in the same year, was equally good. In the third case, operated upon in 1858, the mouth could not be widely opened, and the child had some difficulty in speaking. The fourth case, operated upon in 1860, was most satisfactory. M. Verneuil also mentioned a fatal case which occurred in M. Rizzoli's practice, and alluded to my paper in the *Dublin Quarterly Journal* of May, 1863.

It would appear that M. Rizzoli had adopted the plan of inserting a foreign body, such as a piece of gutta-percha, between the cut surfaces of bone, with the view of preventing their reunion, and the possibility of doing this was roundly denied by one of the speakers at the Société de Chirurgie. There appears to me, however, to be no difficulty in effecting this, provided the section be made from within the mouth



and without external incision, as proposed by M. Rizzoli, but I cannot speak with certainty, having no experience of his operation.

One observation of M. Verneuil's is, I think, worthy of special notice—viz., that all Rizzoli's successful cases have been examples of contraction within the mouth without loss of substance of the cheek, whereas the unsuccessful cases of the operation which have occurred in Paris had suffered considerable damage in the soft tissues; and he suggests that in these cases Esmarch's operation may be more properly applicable. In one of my cases the loss of substance in the cheek had been replaced by a dense cicatrix, which it would have been unwise to interfere with from within the mouth, and at the same time, owing to its firm contraction, it would have been impossible to have performed Rizzoli's operation in the way he recommends—viz., without any external incision. I therefore resorted to Esmarch's proceeding, with the results of which I have every reason to be satisfied.

The first case in which I performed Esmarch's operation was in a boy aged fifteen, who was sent to me by Mr. Martin, of Portsmouth, in 1862, with complete closure of the jaws, the result of the contraction of cicatrices within the mouth following extensive necrosis. The cicatrices had been divided, and his mouth screwed open in 1856, but without permanent benefit, and he obtained his food by rubbing it between his teeth, or by putting it through an aperture between the teeth on the right side. The mouth was firmly closed, the teeth overlapping; there was a cicatrix at the right angle of the mouth, and a dense band could be felt within the mouth on the same side. Fig. 182 shows his condition on admission. I made an incision two inches long upon the lower border of the jaw, in front of the right masseter, and removed a wedge of bone measuring rather more than a quarter of an inch along the upper, and half an inch along the lower border. The piece contained the mental foramen. The mouth could now be freely opened, and the boy was discharged at the end of a month able to



open his mouth, as seen in fig. 183; the distance between the teeth being seven-eighths of an inch.

FIG. 182.

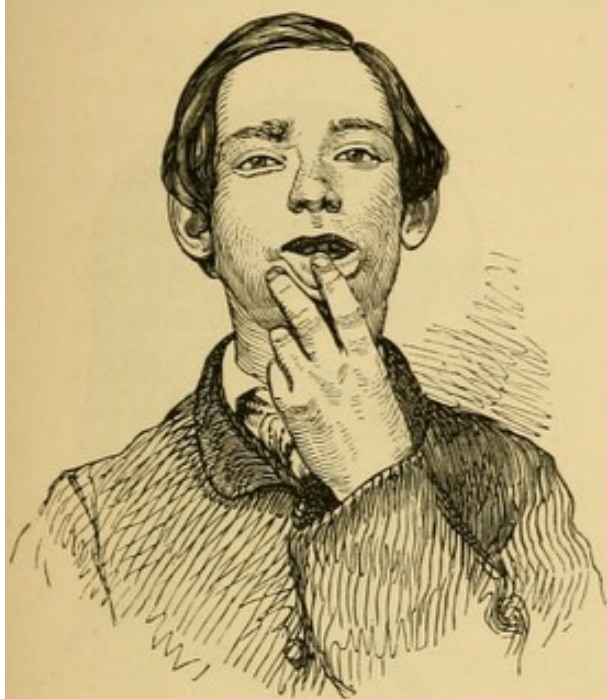



FIG. 183.



The second case in which I operated in the same manner was complicated by the presence of a dense cicatrix, occupying nearly the whole of the cheek of the affected side. The angle of the mouth had also given way during a recent attack of fever, and the patient presented the unsightly appearance shown in fig. 184. The patient was twenty-three years old, and the sloughing and contraction occurred at the age of six. She was sent to me by Mr. Bullen, of the Lambeth Infirmary, in January, 1864. I made an incision along the border of the jaw, and, as in the former case, removed a wedge of bone measuring seven-eighths of an inch along its lower border. This also contained the mental foramen. The patient's mouth could now be opened to the extent of half an inch. I made two subsequent attempts to remove the deformity of the cheek by plastic operations, but only succeeded in restoring the commissure of the lips, the vitality of the cicatricial tissue being too low to admit of its uniting with other tissues. At the time of her dis-



charge the commissure of the lip was half an inch in breadth ; and with a piece of black plaster over the opening which was left behind it, the patient was very comfortable.

FIG. 184.

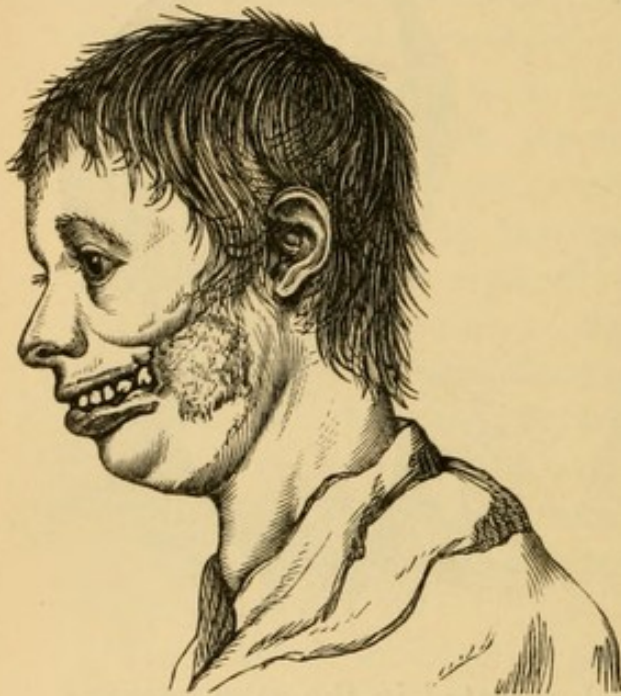

FIG. 185.

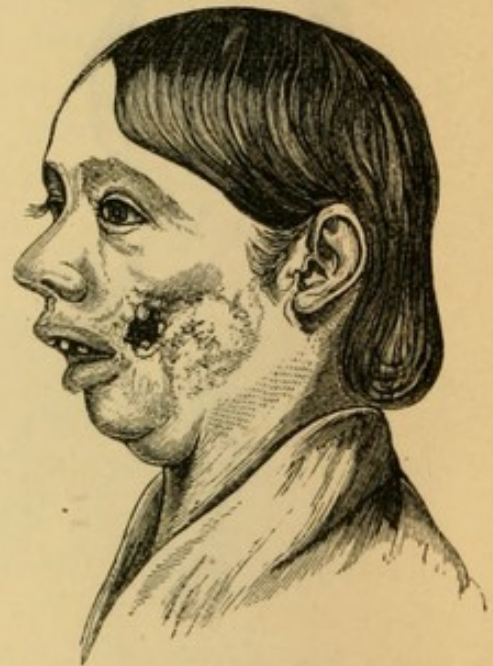

Fig. 185 shows her condition at this time with the mouth open.

With regard to the permanency of the relief afforded in these cases, I may mention that Barton B., the boy on whom I operated in July, 1862, continued in perfect health, and able to take plenty of nourishment, although the movements of the jaw had very decidedly diminished, owing apparently, to contraction of the fibrous tissues around the new joint, due, as the patient and his mother believe, in the first instance, to the cold of the severe winter following the operation, from which he suffered considerably.

In March, 1865, I had the boy up from the country, and found that the space between the left molar teeth had diminished from seven-eighths to one-eighth of an inch, and that between the left lateral incisors from five-eighths to two-eighths of an inch. The movement was still free enough to show that osseous ankylosis had not taken place in



the new joint; but whether the contraction was due simply to changes at that point or to the contraction of some band it was impossible to determine, as the boy positively refused all interference, either with or without chloroform.

In this case, however, I believe that I was not sufficiently careful to make the section of the bone entirely in front of the cicatrices, a point I bore in mind in the second operation.

The second patient, Ellen Johnson, is in perfect health, and has good use of her jaw. I saw her at Plymouth in August, 1866, and have heard since that she continues perfectly well. She called on me in July, 1880, in good health and with perfect movement of the joint. The opening in the cheek remained the same.

Mr. Bernard, of Clifton, performed Esmarch's operation with the greatest success, upon a young man of twenty-one, in January, 1865. The case was one of great destruction of the cheek by sloughing, and the alveoli of the upper and lower jaw projected considerably through the aperture thus left. Mr. Bernard cut away the alveoli, and then removed a wedge from the lower jaw in front of the contraction with the most satisfactory results.

In the *Medical Times and Gazette*, 1876, will be found cases of Esmarch's operation performed successfully at St. Thomas's Hospital by Sir W. MacCormac and Mr. Francis Mason; at the Middlesex Hospital, by Mr. Lawson; and at the Hotel Dieu, Paris, by M. Richet. In 1883 I again performed the operation in University College Hospital, on a woman, aged thirty-two, who was kicked by a horse on the right side of the face when eleven years of age, since which she had had more or less closure of the jaws. The teeth were firmly closed, the lower incisors being forced outwards. It was clearly a case of ankylosis of the temporo-maxillary articulation, and I should have preferred to operate in that region, but for the patient's anxiety to be relieved as soon as possible in order to return to her family. She recovered with good use of the jaw.



In connection with this subject, and to show the pathological result of the proceeding, I may refer to the following account of the post-mortem examination of a case of Esmarch's operation, read before the Société Impériale de Chirurgie, September 5, 1866.

M. Boinet showed the lower jaw of a girl who had closure of the jaws from cicatrices resulting from cancrum oris. Rizzoli's operation had been performed at the beginning of 1860, but failed at the end of twelve months. In 1863 a wedge was removed with perfect success. She died of phthisis in 1866.

"The right ramus of the jaw is deformed, being shorter and broader than on the opposite side. The condyle and the coronoid process are less separated and shorter than on the left side, and the sigmoid notch is shallower. The left temporo-maxillary articulation has lost much of its mobility, and the ligaments are shortened. The sections had been made in the middle of the body of the bone, the angle being intact. The lower border of the jaw presents a difference in length of  $1\frac{1}{2}$  centimetre between the two sides, which corresponds to the breadth of the wedge of bone removed at the operation. The osseous tissue of the ascending ramus appeared reddened, the dental nerve was natural at its entry into the inferior dental foramen. Between the two portions of the jaw there exists a very complete false joint, which is permanent three years after the operation; it is very mobile, and the parts which serve as the hinge are fibrous and stretched so that the middle portion of the jaw can fall; during life this was sufficient to allow easily the introduction of the forefinger into the mouth. The fibrous tissue which unites the bones occupies the whole interval left between the bones, and extends for the whole depth of the jaw. Its breadth appears to be quite a demi-centimetre, and its strength uniform." — *Gazette Hebdomadaire*, October 12, 1866.

In a few cases of bilateral ankylosis it has been thought advisable to perform Esmarch's operation on both sides of the jaw. Thus Dr. Maas, of Breslau, relates in the *Archiv*



*für Klin. Chirurg.* (Band xiii, Heft 3) the case of a man, aged twenty-seven, who was admitted into hospital with ankylosis of the jaw on both sides. It had come on after an attack of scarlet fever when he was seven years old, being preceded by severe pain in the part; and since the age of ten he had not been able to move the jaw at all. The secondary dentition was attended with great difficulty in the removal of the milk teeth; and the new teeth were irregularly developed, and for the most part were displaced laterally. The patient, on admission, was of anæmic appearance, though in moderately good condition; the lower jaw was imperfectly developed. Speech was somewhat muffled, but was quite intelligible. Not the least movement of the jaw could be produced under anæsthesia. Herr Middeldorpf operated on the right side, removing a wedge-shaped piece of bone, as recommended by Esmarch, near the angle. The result of this was the formation of a false joint, with power of opening the mouth passively to the extent of about an inch. Between four and five months later, Dr. Fischer performed a similar operation on the left side; four months after this the patient could voluntarily open his mouth without pain to the extent of about an inch and a quarter, and his general condition was much improved.

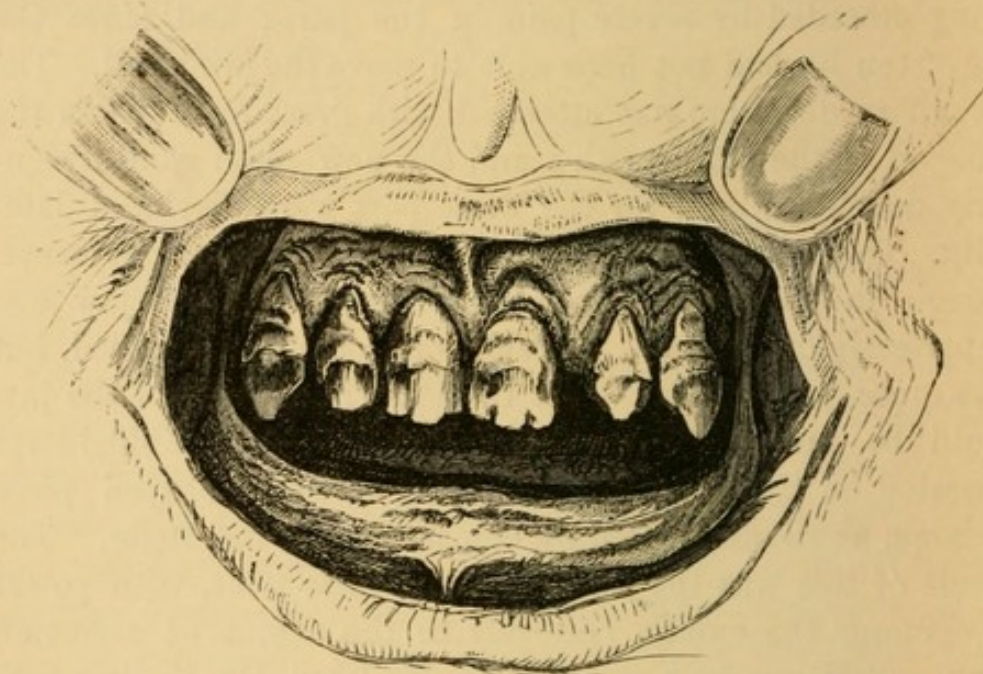
The treatment of cicatricial contraction within the mouth by simple division has been proved over and over again to be perfectly useless; but when suitable apparatus is adapted to the jaws, so as to prevent re-contraction, a very good result may, with patience, be produced in cases uncomplicated by destruction of the cheek itself.

Fig. 186 shows a sketch of the mouth of a woman who had cicatricial bands on each side, binding the cheeks and gums together so that she was able only to separate the lips, and in whom division of the cicatrices had been practised in childhood. The lower jaw was edentulous, but the upper front teeth remained, and Mr. Felix Weiss succeeded in adapting a small lower denture so as to antagonize the upper teeth and prevent the further contraction which appeared imminent, at the same time greatly improving the



patient's power of articulation (*British Journal of Dental Science*, May, 1880).

FIG. 186.



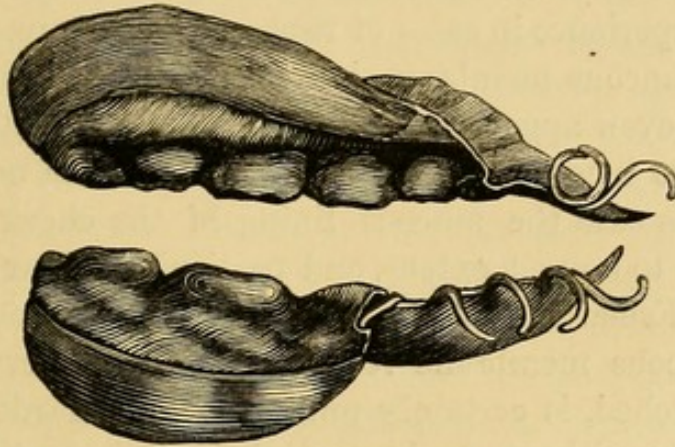
The great drawback to treatment by division of bands, and one with regard to which it contrasts unfavourably with Esmarch's proceeding, is the amount of pain which the patient must, of necessity, undergo during the after-treatment. It requires no small amount of courage on the part of the patient, and some determination on the part of the attendant, to carry out the necessary manipulations within the mouth, more particularly during the first few days after the operation; and even after the shields are fitted to the mouth they cause some pain and inconvenience, which only those who have arrived at years of discretion will submit to.

Fig. 187 shows the form of the silver "shields" adapted to the upper and lower jaws by the late Mr. Clendon, formerly dental surgeon to the Westminster Hospital, in a case of Mr. Barnard Holt's. The patient was a girl of seventeen, and was under Mr. Holt's care in 1862, having five years before had fever, with an abscess of the cheek on the right side, which led to such contraction and adhesion of the mucous membrane to the jaw as to cause great difficulty in opening



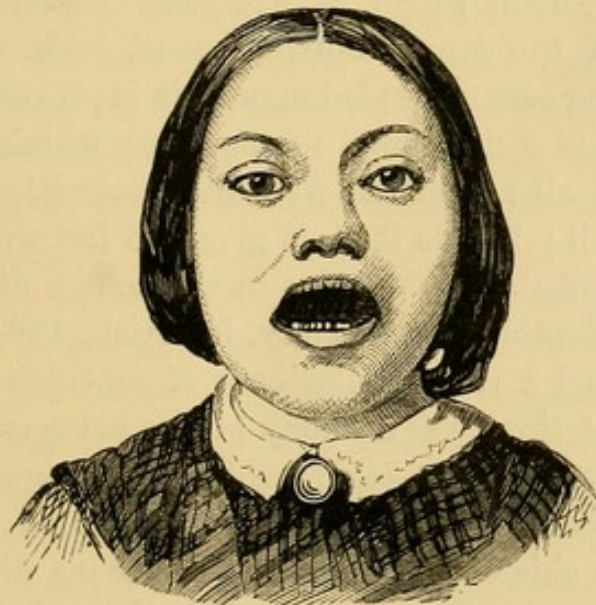
the mouth. Some attempts had been made to open her mouth by the screw, &c., and in 1860 Mr. Holt divided some of the cicatrix with temporary benefit. Mr. Holt now divided

FIG. 187.



the cicatrix within the cheek freely under chloroform, and encountered a firm plate of bone extending between the alveoli of the two jaws, which necessitated the use of a saw for its division. Mr. Clendon subsequently fitted the above-mentioned shields to the teeth, and wedges were gradually

FIG. 188.



introduced between them to separate the jaws. This treatment was continued for three months, when she was able to open the mouth to the full extent, as seen in fig. 188.



The effect of the use of the shields seems to have been, not merely to prevent adhesions between the inside of the cheek and the alveolus, but to re-establish, to a great extent, the sulcus of mucous membrane at the base of the alveolus, upon which so much stress is laid by Professor Esmarch. Surgical experience in cases of ruptured perineum, &c., shows how soon mucous membrane is reproduced where it has once existed, or even appears on adjacent parts where its presence gives rise to inconvenience ; and there can be no question that in this case the mucous lining of the cheek has been reproduced to a great extent, and particularly near the lower alveolus. Esmarch's theory, that there must be some portion of old mucous membrane remaining which afterwards becomes stretched, is certainly untenable as regards this case at least, for without doubt the whole lining of the cheek and the outside of the alveoli were perfectly raw, owing to the division of the firm cicatrices.

The cause of non-success in former attempts at mechanical appliances is to be found, I think, in the fact that they have all been directed simply to keeping the jaws apart, without any reference to the re-establishment of the mucous lining of the cheek, upon which, as Professor Esmarch says, the movements of the jaw so much depend. That the success in the foregoing case depended upon this is proved, I think, by the existence of a firm band in the cheek which would effectually control all movement were its extremities attached to the two alveoli ; but as it is, it gives no inconvenience, and will, in all probability, atrophy in the course of time.

At the Odontological Society, in June, 1864, Mr. Cartwright narrated a very similar case of contraction (with the exception that there was no bony bridge between the alveoli), in a woman, aged thirty-eight, which he successfully treated by similar means, using wedges of vulcanized india-rubber affixed to the shields to obtain the necessary distension.

The occurrence of an osseous lamella or bridge between the two jaws is a rare but not unique occurrence. In the *Medical Gazette*, of July 4, 1845, Mr. J. G. French has reported and figured an excellent example of ankylosis pro-



duced by a bridge of bone, which occurred under his care at the St. James's Infirmary.

The patient was twenty-two at the time of his death, and the closure of the jaws dated from infancy. He was fed through an aperture made by the removal of the incisors on the left side. At the age of fourteen an operation for his benefit had been undertaken by an eminent surgeon, and incisions in the mouth had been made with this object, but without any good result. On post-mortem examination the jaws were perfectly united on the left side, and only the smallest degree of motion was possible on the right; the soft parts were removed and the base of the skull was macerated, when ankylosis was discovered to exist between the upper and lower jaws on the left side, the ramus of the inferior maxilla, immediately internal to the mental foramen, extending upwards by a broad thin plate, and uniting with a corresponding plate of the superior maxilla, a cartilaginous material forming the bond of union. The articulation of the jaw was normal.

Mr. Trueman also mentioned in the discussion which followed the narration of Mr. Cartwright's case (*British Journal of Dental Science*, June, 1864) that he remembered seeing in the Museum at Berlin a very curious case where cicatrices existed on both sides of the mouth, which were completely ossified, so that the preparation showed the two jaws united by filaments of bone, on either side of the jaw externally.

Subsequently to Mr. Holt's case, I had under my care a patient with a very severe form of contraction—viz., on both sides of the mouth. The patient was eighteen, and the contraction dated from her fifth year, when she had fever. Various attempts had been made to give her relief by dividing the cicatrices and using wedges, &c., without benefit; and when she came under my care she had no power of separating the jaws at all, and the cheeks were firmly attached to the alveoli from the angles of the mouth. Having secured Mr. Clendon's co-operation, I freely divided the cicatrices, and after repeated trials that gentleman suc-



ceeded in fitting in shields resembling those used in Mr. Holt's case, but reaching over both sides. It was found necessary to extract all the teeth, and after more than three months' assiduous care and frequent modification of the shields, the patient being constantly placed under the influence of chloroform for the purpose, a very satisfactory result was obtained, there being exactly one inch between the metal shields in the incisive region, which would have left about half an inch if the teeth had been *in situ*.

In order to contrast the permanent results of this method of treatment with that by removal of a portion of the jaw, I may mention that three years after the operations, I ascertained the following facts respecting these patients:—

Frances H., the girl treated by Mr. Holt by internal division and the application of metal shields, wore the shields for some months after leaving the hospital, but discontinued them after some eighteen months. The contraction had returned to some extent, the band which existed in the cheek having shortened so as to diminish the extent to which she could separate the teeth one-half—viz., from three-fourths to three-eighths of an inch. The cheek was slightly tucked in owing to the contraction; but the girl was perfectly well and comfortable, and would not allow any interference with the parts.

Isabella M'Nab (my patient treated by metal shields), whose case was remarkable owing to the adhesions being present on both sides of the mouth, was seen by Dr Crockett, of Dundee, in the middle of 1864, and that gentleman has kindly sent me the following report of her condition:—“The jaws can be opened with ease to the extent of half an inch; she has begun to articulate distinctly within the last two months, and within the last fortnight is able to chew a crust of bread, having some lateral motion of the jaw. A fetid muco-purulent discharge continues to come from the mouth, but her general health is much improved.”

Having thus shown that cases of closure of the jaws by cicatrices are amenable to two modes of treatment with most



satisfactory results, and having had personal experience in carrying out both methods, I shall venture to draw a brief comparison between them.

Esmarch's operation is a comparatively easy proceeding; and in cases where only *one* side of the jaw is affected, restores the patient a very useful, though one-sided, amount of masticatory power in two or three weeks, and with very little suffering or annoyance. One side of the jaw is, however, rendered permanently useless (its previous condition), and there is a necessarily resulting deformity, which is not however, of a very distressing character. The paralysis, from the division of the nerve, is so slight as not to be worthy of mention.

The treatment by internal division and the use of metal shields, is applicable to all cases in which the entire thickness of the cheek is not involved, and can, with due care and attention, be made to yield most satisfactory results—the patient enjoying the full use of both sides of the jaw, and having no deformity or loss of sensation. On the other hand, the operation itself is difficult and bloody, and the after-treatment is tedious and troublesome; and it is essential for success to have the co-operation of a dental practitioner fully conversant with the frequent modifications which the metal shields must necessarily undergo. The age of the patient is an important element also, since it would be impossible, I imagine, to carry out the treatment with any hope of success, unless the patient were of an age to assist, or at least not to resist, the surgeon. In my own case chloroform was resorted to on every occasion of real operative interference, but the intermediate treatment was much hindered by the timid character of the patient.



## CHAPTER XXVII.

## DISEASES OF THE TEMPORO-MAXILLARY ARTICULATION.

THE temporo-maxillary articulation is, like other joints, the subject of inflammation due to constitutional and local causes, to which latter its exposed position would seem to render it particularly liable. Yet it is remarkable that acute disease of the temporo-maxillary joint is hardly recorded, and I think the explanation is to be found in the fact that it is often confounded with acute affections of the ear, and that mischief beginning in the articulation may induce purulent discharge from the meatus in children.

My colleague, Mr. Arthur Barker, in his valuable article on Diseases of the Joints (*System of Surgery*, vol. ii.), mentions that in cases of suppuration of the middle ear, the temporo-maxillary articulation may become involved through the floor of the meatus, in which a hiatus often exists in children. He quotes in proof of this a case which I had long under my care, a child, from whose meatus the condyle of the jaw was extracted ; but I should rather regard it as a case in which, from disease of the temporo-maxillary joint, perforation had ensued, and the condyle had found its way into the meatus.

That destructive disease of this articulation is not very infrequent, is evident from the number of museum specimens extant of complete ankylosis, and of the numerous cases of fibrous ankylosis which have been met with in practice.

In his "Practical Observations in Surgery" (1816), Mr. John Howship describes a case of "scrofulous inflammation of the face followed by ankylosis of the jaw" in a man of fifty-six years of age, who dated the origin of the disease

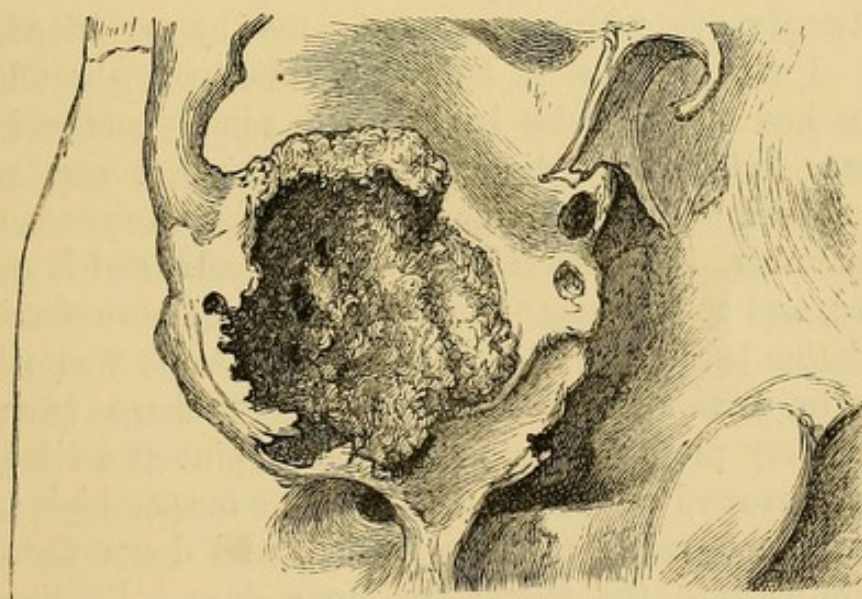


from a cold taken at the age of four. The original illustration shows complete bony ankylosis of the lower jaw to the temporal bone on the left side. On the right side the shape of the joint is considerably modified, as may be seen in the specimen in the College of Surgeons' Museum (1949).

In Guy's Hospital Museum is the skull of a negro who had disease of the cervical vertebræ, and complete osseous ankylosis of the temporo-maxillary articulation, coming on after a wound in the neck from a fork. The history of the man, with a drawing of the skull, will be found in Mr. Hilton's "Lectures on Rest and Pain."

In the Museum of University College is another specimen (849) showing an earlier stage of the same condition. The condyle is immovably united to the corresponding part

FIG. 189.



of the temporal bone, the contiguous surfaces being very irregular but mutually adapted, and separated in part by a thin line of shrunken fibrous tissue. Considerable portions of each of the surfaces have been destroyed, the condyloid part of the jaw is much enlarged in the antero-posterior direction, so as to lie in contact both with the glenoid fossa and the articular eminence in front of it. Also, in St. Bartholomew's Hospital Museum is a specimen (I. 664), of which I have been allowed to take a drawing (fig. 189),



showing the results of disease of the right articulation for the lower jaw, a quantity of rough new bone having been formed, from which the condyle appears to have forcibly broken away.

Cases of fibrous ankylosis of the temporo-maxillary articulation, recognized and treated as such during life, have been recorded by several surgeons, but I would especially refer to two published by Mr. Spanton, of Hanley (*Lancet*, April 16, 1881), because that gentleman proved the correctness of his diagnosis by dividing the fibrous bands with a tenotome passed into the articulation, and then succeeded in screwing open the mouth. The patients were girls, aged ten and nine respectively, and in both cases the disease of the temporo-maxillary joint had followed scarlet fever.

I have had the opportunity of watching a case which I fear will terminate in ankylosis of the jaw, in a gentleman aged twenty-five, who was sent to me by my friend, Mr. Bate. I saw him first in February, 1866, when he told me that he had the measles badly when nine years old, and this was followed by discharge from the left ear, which became deaf. The discharge had ceased for two years, when in September, 1864, he caught a severe cold, and it recommenced, and at the same time the left temporo-maxillary articulation became swollen and stiff, so that he was obliged to live by suction for some time. The discharge from the ear was very profuse, as much as half a pint at a time, and matter burrowed under the tissues of the face as high as the orbit, where a small opening formed, and down the neck, discharging into the throat for three days. Finding the left lower wisdom tooth cut awry and very far back, I thought that this might possibly be connected with the disease, and therefore had it extracted, with some difficulty, by Mr. Mummery. In the following July I found that he had derived no benefit from the extraction, and the jaws were as firmly closed as before. The space between the incisors was  $\frac{1}{4}$  inch, and rather more between the bicuspid on the left side. The mouth did not open so widely as it had done eighteen months before, but he had perceived no



difference during the preceding six months. There was no external deformity, but he said he heard a grating sound on moving the jaw, which was not audible externally.

This would appear to have been a case of inflammation and destruction of the temporo-maxillary articulation, which was undergoing cure by ankylosis, as would happen with other joints under similar circumstances. It cannot be classed with the cases of chronic rheumatic arthritis of the joint, since the patient had none of the symptoms of that disorder.

The only disease of the temporo-maxillary joint hitherto generally recognized by surgical authors, has been the so-called "sub-luxation" of Sir Astley Cooper. It is an affection occurring principally in delicate women, and has been thought to depend upon relaxation of the ligaments of the joint permitting a too free movement of the bone, and possibly (though this is conjecture) a slipping of the inter-articular cartilage. From a considerable acquaintance with this affection, I believe that it is in many cases, at least, unconnected with any slipping of the cartilage, but is due to rheumatic or gouty changes in the articulation. The fact that these patients suffer most in damp weather and when the general health is feeble, shows that it depends upon an arthritic diathesis, and the relief that is obtained from counter-irritation and the exhibition of anti-rheumatic or anti-gouty remedies, proves that the complaint cannot be due to purely mechanical causes.

The researches of the late Dr. Robert Adams and Dr. R. W. Smith, of Dublin, have shown that rheumatoid arthritis occasionally affects the temporo-maxillary articulation, and the former author has, in his "Atlas," figured the remarkable hypertrophy of the neck of the condyle of the jaw, occurring in the case of a woman, aged thirty, to which I shall have occasion to refer more particularly later on.

Cruveilhier, who first described an example of rheumatoid arthritis of the temporo-maxillary articulation ("Anatomie Pathologique," liv. ix.), says:—"I have never seen the disease I call wearing away of the articular cartilages better marked than it was in this case. The condyle of the lower jaw did



not exist; it might be supposed to have been sawn off horizontally at the line of junction of the head with the neck, and that which remained of the neck had been flattened. The articular part of the glenoid cavity was repre-

FIG. 190.

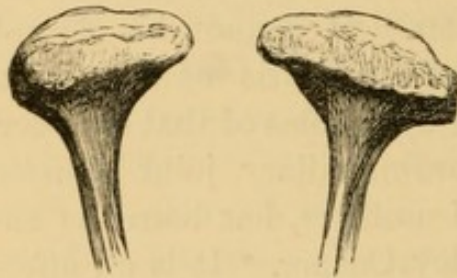
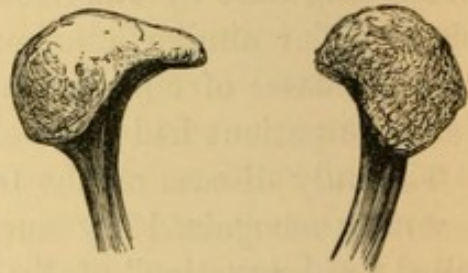
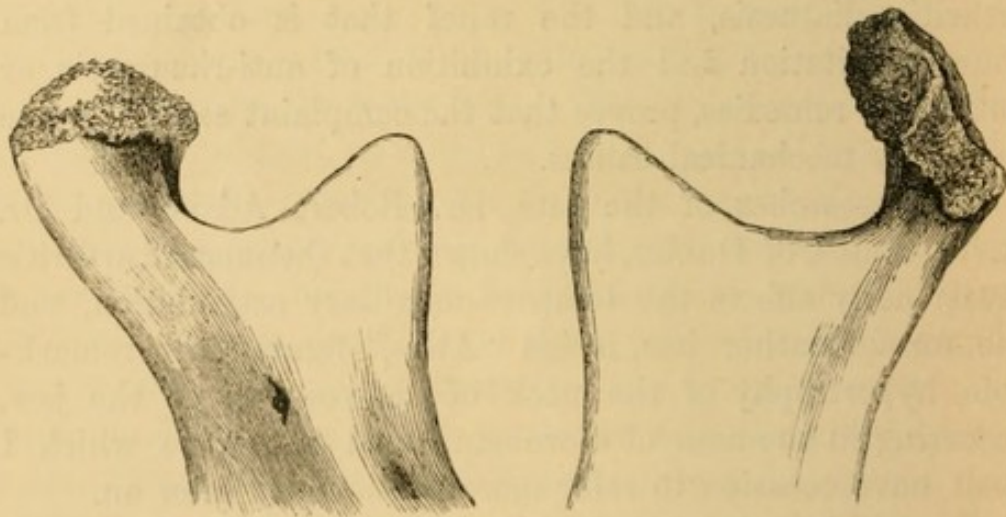
FIG. 191.



sented merely by a plane surface; no trace of inter-articular cartilage or cartilage of incrustation existed. Both surfaces of the altered articulation were remarkably red."

I have never had the opportunity of examining a recent example of this disease, but as far as can be judged from museum specimens, the articular surface of the condyles is flattened and somewhat altered in direction in the less marked instances (fig. 190), and absorption of the neck,

FIG. 192.



with complete wearing away of the articular surfaces (fig. 191), occurs in the older and more advanced cases. I agree with Dr. Adams, that eburnation of the articular surfaces, or the occurrence of porcellanous deposit in the temporo-

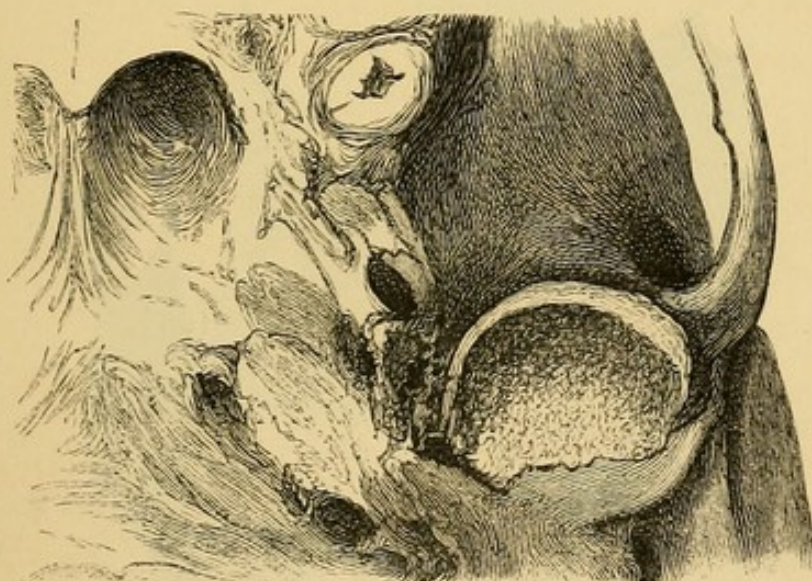


maxillary articulation, is very rare. The description quoted from the St. Bartholomew's Catalogue by Dr. Adams refers to preparation No. 551 in that museum (fig. 192), and is as follows :—

“There has been disease in one of the articulations of the jaw, producing absorption of the articular cartilage, with a deposit of bone around the circumference of the glenoid cavity. The corresponding condyle is in part removed by absorption; its surface is rough, except at one point, where it is highly polished and has an ivory-like texture.”

Enlargement of the glenoid cavity is common in these cases, and is well seen in fig. 193, taken from the same specimen in St. Bartholomew's Hospital. Absorption of bone

FIG. 193.



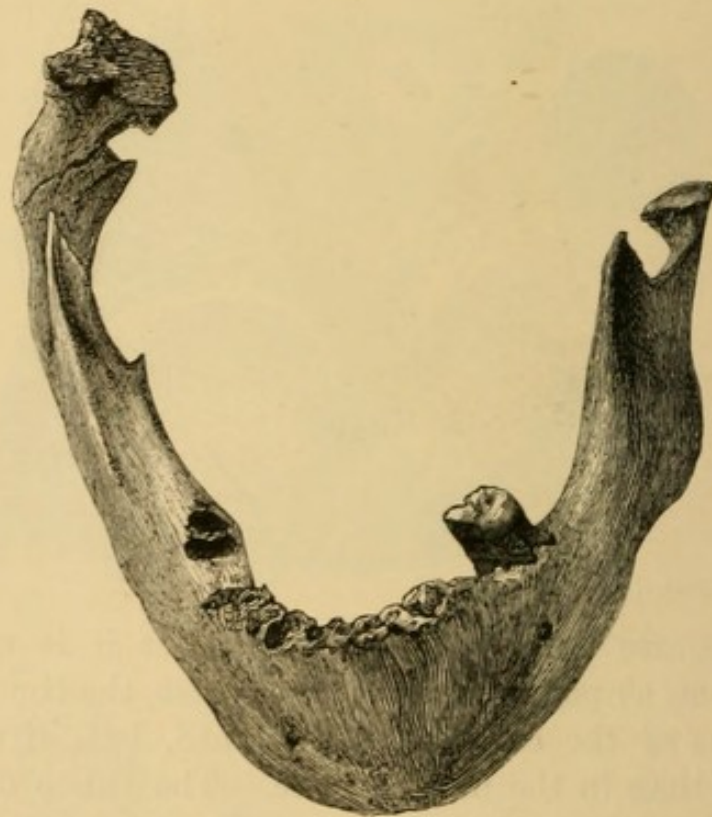must of course occur in these cases, but it is worthy of remark that, as pointed out by Dr. Adams, the bone forming the fundus of the cavity is not thinned, but, if anything, is thicker than in the normal state. The entire disappearance of the inter-articular fibro-cartilage is, apparently, an early event in chronic disease of the temporo-maxillary articulation. It had entirely disappeared in all the few recorded post-mortem examinations, and was absent in a case of hypertrophy of the condyle in the living subject which I successfully operated upon.



*Hypertrophy of the Neck and Condyle* was observed by Dr. Adams in the case of rheumatoid arthritis of the temporo-maxillary joint already referred to, and is beautifully shown in Plate 1 of his admirable "Atlas." Though occurring in a woman of only thirty, there can, I think, be no doubt, from the description and drawings of her hand and feet, that the patient was the subject of rheumatoid arthritis. It is by no means certain, however, that the hypertrophy of the neck and condyle must be considered to be the results of that disease, for, as I shall show, this same rare deformity has been found in patients otherwise healthy.

Fig. 194 shows a lower jaw so like that figured in Adams' "Atlas" in every respect, that the preparations are evidently

FIG. 194.



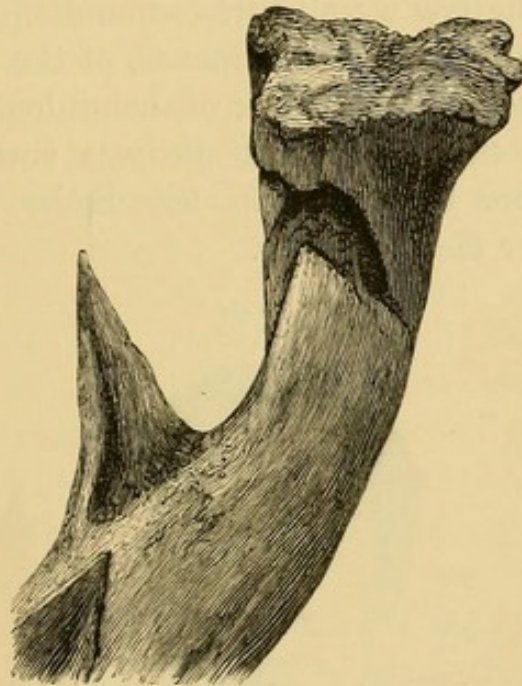
identical in their nature. It was presented to the College of Surgeons' Museum (2205) by Mr. Jeremiah McCarthy, and is thus described by Mr. Eve :—

"A lower jaw with a mass of bone, having somewhat the form of an inverted pyramid, attached to the thickened neck



of the right condyloid process. The upper surface of the mass, corresponding to the base of the pyramid, is flat and smooth as if it had been covered with fibro-cartilage (fig. 195). Upon its inner side is a deep indentation, from which a fissure extends outwards and downwards nearly to the external surface of the bone. The indentation and the fissure constitute the upper boundary of a portion of bone which,

FIG. 195.



from its form and position, might be taken for an enlarged condyle. The right half of the jaw is larger in all its dimensions than the left half, the breadth of the horizontal ramus in front of the angle being double that on the left side, which, from the slenderness of the coronoid and condyloid processes, appears atrophied. From a middle-aged man, who died with apoplexy. There was a remarkable deformity of the face from the deviation of the symphysis from the middle line; and the projection of the enlarged condyle was considerable. The base of the skull was not examined, and nothing was found in the post-mortem examination except atheroma of the vessels. Nothing unusual had been noticed about his mouth in childhood, nor could any account of an



injury be obtained." (See *Pathological Society's Transactions*, vol. xxxiv., 1883.)

In the same volume of the *Pathological Society's Transactions* will be found the record of a remarkable specimen of hypertrophy of the neck and condyle of the jaw, removed by myself from a woman, aged thirty-six, whose face had for ten years become gradually more deformed, by the increasing displacement of the chin to the right side and the projection outwards of the left condyloid process. The movements of the jaw were restricted, and the length of the left ascending ramus was three inches, of the right one inch and a half. She had an attack of hemiplegia, implicating the left side of the face, when she was twenty-five years of age, and from this affection her limbs had recovered perfectly and her face partially.

FIG. 196.



The appearance of the patient (who was sent to me by Dr. Williams, of Sherborne) is seen in fig. 196, and the piece of bone removed is accurately drawn in the lithographic plate (*v. frontispiece*), the hypertrophied condyle measuring one



inch and three-quarters from before backwards, and one inch across, and being covered with fibro-cartilage. A section of the preparation shows it to be composed of cancellous bone with large rounded spaces, and its walls are formed of a thin layer of compact bone. The fissure observed in Mr. McCarthy's does not exist in this specimen. If the condyle thus shown is compared with fig. 195, which represents the condyle of Mr. McCarthy's case, of the natural size, there can be little doubt that my preparation, Mr. McCarthy's, and Dr. Adams's all belong to the same category; and yet in Mr. McCarthy's probably, and certainly in my own case, this was the only joint affected. It must be concluded then, I think, that hypertrophy of the neck and condyle may occur in otherwise healthy patients, and I believe that I saw, in consultation with Mr. Nathaniel Stevenson, the early stage of this curious condition in a young healthy lady of about twenty, in whom the lower teeth had gradually become displaced from no known cause, so as to disarrange the normal bite. I here detected, what was then new to me, some hypertrophy of the neck of the jaw on one side, and recommended blistering and a course of iodide of potassium without any marked benefit, except that the deformity has not increased. In the patient, whose portrait is given in fig. 196, the deformity was so great as to warrant surgical interference, and the result has been very satisfactory, the face being brought straight and the patient having free movement of the jaw.

The *Treatment* of inflammation of the temporo-maxillary joint has hitherto been, in chronic cases, the application of blisters and the use of a bandage—particularly an elastic bandage at night. Dr. Goodwillie, of New York, has, however, contrived an ingenious method of fixing the lower jaw effectually in cases of arthritis, which will be best described in his own words (*Archives of Medicine*, New York, June, 1881):—

“The method that I employ is as follows: In this case the patient is under the anæsthetic effect of morphine and nitrous oxide. If there is any rigidity of the muscles, cautiously force open the mouth and take an impression of either the upper or lower teeth, and a rubber splint is made



from the cast to cover over all the teeth in one jaw. Upon the posterior part of this splint is made a prominence or fulcrum (*D*), so that when the mouth is closed the most posterior teeth close upon it, while all the anterior teeth are left free. The next step is to take a plaster of Paris impression of the chin, and from this make a splint (*A*). On each end of the splint is made a place for fastening elastic straps (*B*) that pass up on each side of the head to a close-fitting skull-cap (*C*). See fig. 197.

“When the apparatus is in place and the elastic straps tightened so as to lift the chin, then pressure is brought to bear on the fulcrum at the posterior molar tooth, and so by this means extension is made at the joints, and the inflamed surfaces within the joints are relieved from pressure; then immediate relief is experienced.”

FIG. 197.



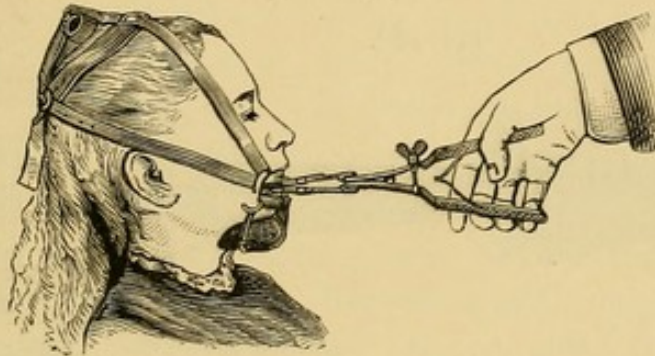
I have no experience of this method, but it appears to be based upon sound surgical principles, and the cases illustrative of its use given by Dr. Goodwillie attest its usefulness.

In the cases of fibrous ankylosis resulting from the cure of arthritis, it is open to the surgeon to have recourse to mechanical means to break down the adhesions, and to illus-



trate the difficulties to be overcome, I may refer to another case of Dr. Goodwillie's (*New York Medical Journal*, July, 1875):—The patient was a girl of ten, who, five years before, had fallen over the bannisters, breaking and dislocating the jaw, with the result of the jaws being firmly closed. The apparatus employed is seen in fig. 198.

FIG. 198.



One of the chief sources of interruption in treatment is periodontitis from the great amount of force used on the teeth. To prevent this, Dr. Goodwillie protects them with an interdental splint of hard rubber. These splints at first are necessarily very small, and confined to the front teeth; but, as the case progresses, longer and more perfect ones are made. In this case the rubber splints were enclosed in metal splints made of German silver, as this metal is tough and unyielding. These splints were made fast to the teeth by straps that passed from strong wire arms at the sides to a skull-cap, and the lower one was strapped to a pad on the chin. This pad was also attached to the lower splint by means of a ratchet and spring.

From the point of each splint an arm, three-fourths of an inch broad, extends out one and a quarter inch, and to these is clasped the oral speculum when in use (fig. 198). The inclined planes of the speculum pass in between these arms, and they are held by clasps. The inclined planes are attached by movable joints to a distending forceps, so that when the handles are approximated, the inclined planes are separated at their attached ends. Each handle is made



in two sections, and the spring that separates the handle is enclosed between them to protect them from injury.

In forcing the speculum between the splints, the instrument is grasped by one of the handles, and when in place both handles are approximated. If more force is desired, or the mouth is to be held open at any point, the screw at the handle may be used.

In stretching the masseter and temporal muscles, Dr.

FIG. 199.

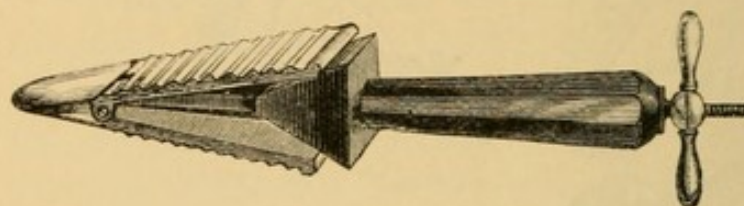
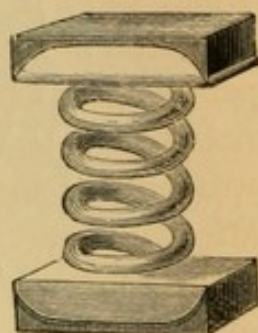


FIG. 200.



Goodwillie uses an oral speculum, devised by him some years ago (fig. 199). It consists of a shaft, to the flat end of which are attached two wings or inclined planes, upon which the teeth rest. The other end of the shaft has a thread cut on it, and a screw; this passes through a handle, one end of which is wedge-shaped. By turning the screw on the other end of the handle, the inclined planes diverge or converge. Fig. 200 represents a spiral-spring speculum for the patients to employ by placing it between the teeth and biting upon it. Longer springs are used as the mouth gradually opens.

It need hardly be said that treatment by this method would extend over many months, and would severely try the endurance of both patient and surgeon.

A simpler method is the division of adhesions formed between the condyle and glenoid cavity, as practised by Mr. Spanton in the cases already referred to, in both of which, as I learn from that gentleman, a good result ensued. I have no experience of the proceeding, and it has its difficulties, but these may doubtless be overcome.

Lastly, there is in cases of fibrous ankylosis the possibility



of removing the condyle, as has been done by Mr. Davies-Colley, and probably by others; or, as proposed by Dr. Ewing Mears (*American Journal of Medical Science*, Oct. 1883), to divide the ramus of the jaw and excise the condyle with the coronoid process and sigmoid notch.

A case of removal of *both* condyles for fibrous ankylosis is quoted by the *Wiener Med. Wochenschrift*, of July 6, 1872, from the proceedings of the Royal Academy of Medicine in Bologna. It occurred in the practice of Dr. Bottini. The patient was a lad, aged seventeen, who, at the age of seven, had fallen on the jaw, and had gradually lost the power of opening his mouth, so that at last for some months he was unable to separate the jaws to any extent. Dr. Bottini introduced wedges, but these were very irksome to the patient, and were removed. Resection of the articular head of the bone was then performed on one side; this had no noticeable result, but on the operation being repeated on the other side, the jaw could be moved freely. At the end of six weeks the wound had healed, and the motion of the jaw was normal. The only morbid change that could be discovered was absence of the inter-articular fibro-cartilage.

In cases of rheumatoid arthritis in which the suffering is great, and in cases of osseous ankylosis of the temporo-maxillary articulation, excision of the condyle seems to offer the best means of giving relief. The first removal of the condyle was by Professor Humphry, of Cambridge (*Association Med. Journal*, 1856), and was undertaken for chronic rheumatic arthritis. He exposed the condyle by a curved incision from the side of the orbit across the zygoma to the ear, passing a little above the temporo-maxillary articulation, and a second incision from the termination of the first directly upwards in front of the ear across the zygoma again, avoiding the temporal artery. The flap thus made was reflected, and the neck of the condyle cut through with a narrow saw.

In cases of complete synostosis, resection of the condyle appears to offer the best and safest method of treatment. In 1874 Dr. Gross, of Philadelphia, resected the condyle with a



portion of the neck of the jaw in a girl of seven, but does not mention the method he pursued. Mr. Croft has shown me the photographs of a child in whom he resected the condyle on both sides consecutively, with very good results, and no doubt the operation has been performed by other surgeons. In 1883 I exposed the ankylosed joint in a boy of seven by an incision in front of the ear, and with a chisel divided the neck of the bone, and removed half an inch of bone in the situation of the condyle, with very good results as regards movement, and with no obvious damage to the facial nerve.

A case of complete synostosis of the jaw was successfully treated by a different method by Dr. James Little, of New York, in 1873 (*Trans. New York State Med. Soc.*, 1874). The patient was nineteen years of age, and had some years before suffered from suppuration of the temporo-maxillary articulation, leading to ankylosis. Dr. Little made an incision along the lower border of the jaw, and turned up the masseter, when the neck of the condyle was seen to be very much enlarged, and continuous with the temporal bone.

A trephine half an inch in diameter was then applied, and a button of bone  $\frac{3}{8}$  of an inch in thickness was removed. The portion of bone on each side of the opening was then cut through with a chisel, and the neck of the condyle cut away piece by piece, so as to leave no portion projecting from the temporal bone. The result was quite satisfactory.

A similar operation, but performed by a different method, was successfully undertaken by Dr. Robert Abbe, of New York (*New York Medical Journal*, April, 1880), in a boy of ten, who had suffered from otitis media and suppuration of the joint some years before. A vertical incision was made in front of the ear, and a horizontal one meeting its upper end was carried along the lower border of the zygoma. The parotid with the facial nerve was drawn down, and with a periosteal elevator the posterior fibres of the masseter were cleared away, and the articulation exposed. A narrow osteotomy chisel was now applied to the neck of the condyle, and carefully driven half through the bone, and by forcibly



opening the mouth the bone was broken through. The neck of the condyle was then carefully removed piecemeal, but the condyle was left *in situ*. The result was satisfactory.

Sédillot mentions ("Médecine Operat.," ii. p. 30) that in a case of true ankylosis of the temporo-maxillary articulation, M. Grube, in 1863, carried a straight chisel through the mouth to the neck of the jaw, which broke by hammering. Some months later he divided the masseter subcutaneously, and the cure, by the formation of a false joint, was permanent. In 1879, I performed the same operation in a child of six, but the results were unsatisfactory. Suppuration was set up, and required an external opening, and the movement, which was free at first, became as limited as before the operation. It would appear, therefore, that mere division of the neck of the bone does not offer such good prospect of a permanent false joint as removal of the neck or the condyle, though these operations are necessarily more severe.

Esmarch's operation performed in front of the masseter is of course as applicable to cases of ankylosis from disease of the joint as to cases of cicatrix, and Fischer (*British Med. Journ.*, June 1, 1872) appears to have performed the operation on both sides of the jaw in a case of bilateral ankylosis of the temporo-maxillary articulation with very good result, the patient obtaining complete and useful control over the central movable portion of the jaw.



## CHAPTER XXVIII.

## DEFORMITIES OF THE JAWS.

THE scope of this work does not embrace those congenital deformities of the gum and palate which are familiar to the surgeon in combination with hare-lip, but there are certain examples of deformity, the result of disease, which may be conveniently grouped together here.

In describing the tumours of the jaw, mention has been made and drawings given of cases of deformity the result of pressure upon the opposite jaw of some growth of large size ; thus, at page 332 will be found an instance of deformity of the upper jaw, due to the pressure of a large fibrous tumour of the lower jaw ; and at page 278 an example of deformity of the lower jaw, due to the pressure of a large osseous tumour of the superior maxilla. Tumours within the mouth, unconnected with the jaws, may, however, induce deformity mechanically, hypertrophy of the tongue being the disease most frequently met with, of which several instances will be found in vol. xxxvi. of the *Medico-Chirurgical Transactions*, in papers upon that disease, by Dr. Humphry, of Cambridge, and Mr. Joseph Hodgson. Dr. Humphry's patient was a girl of eleven years, who had had a much hypertrophied and prolapsed tongue for eight years. " Owing to the constant pressure of the tongue on the mental portion of the lower jaw a curvature had taken place in that bone, just in front of the masseter muscles, in such a manner that a wide interval always existed between the incisors and bicusps of the two jaws. Even when the mouth was closed—that is to say, when the corresponding molar teeth were in contact—



this interval between the incisors measured nearly two inches, being increased by the horizontal direction which the inferior incisors and the alveolar process of the lower jaw had assumed. These were so placed as to form a wide channel in which the tongue rested. Moreover, the teeth, especially the two central incisors, were further apart than natural, and encrusted with tartar, which in some measure filled up the spaces between them, and prevented their sharp edges from injuriously pressing upon the tongue." The deformity, therefore, closely resembled that seen in fig. 201, which was due, however, to external causes. Dr. Humphry removed the anterior part of the tongue successfully, and then endeavoured to remedy the deformity of the jaw by fitting a cap of calico and metal to the head, with a hooked bar of iron projecting from it like a horn over the forehead. The bar was attached to the hinder part of the framework of the cap by a hinge and to the forepart by a screw, which enabled the surgeon to alter its elevation according to circumstances. A thick belt of india-rubber passed from the hook beneath the chin, and exerted considerable pressure upon it. The apparatus was worn for several hours at a time. When its use was commenced, on January 18, four months after the operation on the tongue, the interval between the maxillary alveoli was  $1\frac{5}{8}$  inch, having decreased about a quarter of an inch. On February 22 it was  $1\frac{1}{4}$  inch, and in August  $\frac{7}{8}$  of an inch. After this the change took place very slowly, though the deformity was at length almost removed.

A very similar condition of the lower jaw, but in an earlier stage, existed in a child aged three, from whom Sir J. Paget successfully removed the hypertrophied portion of the tongue, in February, 1864. (*Lancet*, April 16, 1864.)

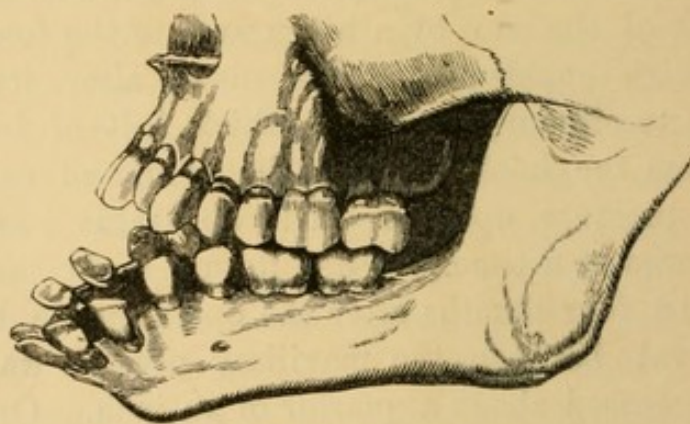
Mr. Oliver Chalk has also narrated, in the *Pathological Transactions*, vol. viii., a case of deformity of the jaw dependent upon enlargement of the tongue in which he considered that a partial dislocation of the jaw was produced, and where benefit was derived from the use of an elastic support.



The influence of the habit of sucking the thumb upon the position of the front teeth is generally acknowledged, and the practice if persisted in, may produce very considerable deformity of the jaws. Some drawings illustrating a paper on this subject, by Mr. Vasey, in the *Pathological Transactions*, vol. vi., show the resulting deformity extremely well. Dr. Thomas Ballard has also called attention to the deformity resulting from the habit of "tongue-sucking," to which he attributes many of the ailments of children.

The influence of cicatrices outside the mouth in producing deformity of the jaw by their contraction in early life is well ascertained, and every surgeon must have met with painful examples of the kind. Fig. 201, from Mr.

FIG. 201.



Tomes' work, shows the condition of the lower jaw in a young woman twenty-two years of age, her chin having been drawn down towards the sternum by a broad cicatrix, consequent upon a burn received when five years old.

In all these cases the deformity partakes of the same character, and if seen early enough is to some extent amenable to treatment. The slighter cases depending upon thumb-sucking are usually treated by the dental surgeon, who in rectifying the position of the teeth necessarily improves the condition of the jaw. In the more severe cases, constant support by an elastic band making traction upon the jaw will be of much service, as in the cases of Dr.



Humphry and Mr. Chalk. The cases depending upon the contraction of cicatrices can only be relieved by treating the cicatrices, and the pressure of a screw-collar, worn for the purpose of extending these, will do much to restore the shape of the jaw, if the case is not one of too long standing.

Disease originating within the mouth may lead to ultimate deformity of the jaws; thus *cancerum oris*, in addition to leading to closure of the jaws, as described in a previous chapter, may lead to very considerable deformity of the alveoli. A case of closure with deformity thus caused,

FIG. 202.



successfully treated by Mr. Bernard, of Clifton, has been already referred to (p. 403); but a still more remarkable case was under the care of my friend, the late Mr. W. Harrison, to whom I am indebted for the accompanying engravings of it. The patient, aged thirty-six, had suffered in childhood from *cancerum oris*, which had destroyed the greater part of the right cheek. His appearance is shown in fig. 202, and it will be seen that the lips were widely separated, and that a considerable protrusion of the alveolar processes of both jaws, with their teeth, had taken place



between them. Behind this point the jaws were united by a bridge of bone, and the patient, who was totally unable to open his mouth, fed himself through an aperture between the teeth on the left side. In October, 1867, Mr. Harrison extracted the seven teeth which projected, and reflected the gums from the adjacent alveoli, when as much of them as was thought desirable was removed with the bone-forceps.

FIG. 203.



The molar teeth, which had been driven into the interior of the mouth, were then extracted with some difficulty, when a pillar of bone, about the size of an ordinary lead-pencil, connecting the alveoli, was brought into view, but was not interfered with. The gums were brought together with stitches, and the operation was concluded. The appearance of the patient some weeks afterwards is shown in fig. 203.

The patient having been transferred to the care of Mr. James Lane, that gentleman proceeded to perform a plastic operation for the improvement of the condition of the lips. A very long V-shaped incision was made, extending from the extremities of the lips (which were firmly attached to the alveoli) to a point about an inch in front of the ear,



thus embracing within it the cicatrix of the original disease. The tissues were freely dissected from the upper and lower jaws, and were brought together over the old cicatrix. An incision, two inches long, was made along the lower border of the jaw, to enable this to be done without too great tension, and the parts were held together with hare-lip pins and

FIG. 204.



sutures. The operation was perfectly successful, and the subsequent appearance of the patient is shown in fig. 204.

The interesting details of this case will be found in a paper read by Mr. Harrison, before the Odontological Society, in May, 1868 (*British Journal of Dental Science*, May, 1868).



## APPENDIX OF CASES.

---

CASE I.—*Compound Comminuted Fractures of both Upper and Lower Maxillæ, with Extensive Laceration of Face, &c.—Recovery.* Under the care of Mr. E. STAMER O'GRADY, F.R.C.S.I., M.B., &c., Mercer's Hospital, Dublin.

A strong healthy man was admitted a few minutes after receiving severe injuries by the wheel of his vehicle, in which was some heavy machinery, passing over his face. Both upper jaws were smashed away from all their osseous attachments, and completely detached from one another; the left one being severely comminuted, and the molar teeth pinched together in pyramidal form. The left side of the soft palate, and for some distance down along the side of the tongue, were extensively torn. The parts here gaping widely, and forming a large chasm, the sides of which were tags of muscular tissue and tendinous fibre. The lower jaw was also broken in different places, one fracture running obliquely down to the left of the incisors, another branching off from it, and breaking away the portion of bone bearing these teeth. There was also comminuted fracture of the mental prominence. The left ear was nearly off, and considerable damage was done to the face generally, more especially to the region of the nose, which was fractured, and the forehead distended with air, which, with the effused blood, speedily weighed down the upper eyelids, and totally blinded the patient. The upper lip beneath the nares was entirely cut through. Hæmorrhage from the mouth was free and persistent; the flow coming from behind the displaced teeth. No ligaturable spot could be found. Careful and long sustained digital pressure by Mr. Finlay, one of the resident pupils, failed to check it, the comminuted and loosened state of the jaw affording no stay against which to exercise effective pressure. With considerable difficulty the molar teeth were wired into line, and then a long strip of lint,



which had previously been steeped in an aqueous solution of perchloride of iron and dried, was carefully packed up behind them. This stopped the further loss of blood, which in the aggregate had been great. The lower jaw was wired into position, suitably bandaged, and the superficial wounds attended to. Five hours after the accident, and as it so happened, at a moment when Mr. O'Grady was in the ward, he suddenly threw his arms up, and after a few paroxysmal efforts, ceased to breathe. Bronchotomy was immediately practised; the tube being opened above the isthmus of the thyroid, and resuscitation soon effected. Shortly thereafter over a pint of clotted blood was vomited. At midnight respiration was quite free, and the eyelids could be partially opened. The tracheotomy tube, after having been experimentally corked for some hours, was removed at the beginning of the third day. Next day there was some difficulty of breathing; there was now considerable redness, swelling, boggy, and tenderness at the root of the neck. This local inflammatory attack proved to be one of severe type, attended with profuse cellulitis, and required numerous incisions on the neck and front of the thorax to evacuate the pus and sloughs. Its course was attended with delirium and much prostration. Twelve days after the accident one of the dislocated incisor teeth fell out. The condition of the neck was now improving, and from the cuts the discharge was healthy pus. Still the man was slow to recover strength, it being three weeks before he could sit up. Occasional flying abscesses continued to form, and from one of these, forty-two days after the accident, a necrosed piece of the lower jaw was picked out. The wires from the upper jaw were removed at this time; union being good, and the teeth firm. No union had occurred in the lower jaw, which, too, had sedulously been kept wired and maintained in good position. Patient, now fairly well and strong, was allowed to go to his home in the suburbs. He attended regularly as an extern, and sixty-one days after the accident the wiring was removed from the lower jaw, union being then firm. A good deal of contraction and bad shape of the fauces existed where the parts had been torn. As time advanced this toned down, and in another month, during which two further abscesses required opening, the man, now in perfect health, was dismissed from treatment.—*Medical Press and Circular*.



CASE II.—Mr. Holmes' *Case of Fracture of the Neck of the Condyle of the Lower Jaw, with Displacement of the Lower Fragment into the Meatus Auditorius Externus.—Serous Discharge from the Ear.*

J. L., aged fifty, was admitted into St. George's Hospital on July 20, 1860. It seemed that he had been sleeping in a hay-loft, and being drunk, had walked out of the window during the night. He was found lying on the ground, and was brought to the hospital at half-past four A.M. He was then sensible, but seemed to be stupid from drink. There were several cuts about the face, and one beneath the chin. Blood was flowing from the right ear. There was some ecchymosis about the right temporo-maxillary articulation, and crepitation was detected in that neighbourhood, though not very distinctly. He was unable to move his jaw, and complained of intense pain in trying to do so. The mouth was drawn to the right side. The pupils were natural. On the following day considerable serous discharge was noticed to flow from the ear. In the evening he was very restless and feverish; but no head-symptoms were observed. Next day (the third) the discharge continued, mixed with blood, and there was great pain in the head. He had considerable difficulty in speaking. On the fourth day from the accident the symptoms of delirium tremens became more marked, and he sank rapidly, dying in the evening. Other extensive injuries existed of which no mention need be made here. It is sufficient to say that the skull, the brain, and the cerebral membranes were perfectly healthy.

On examining the tympanum, traces of blood were found in the mastoid cells, but hardly a drop in the tympanum itself. A probe passed into the tympanum through the external meatus without resistance, and after dissection a large rent was seen at the upper part of the membrana tympani. This was probably, in great part, produced by the dissection. The meatus externus was full of clotted blood, and serous fluid could be seen exuding from the ear. The temporal bone was carefully examined, but no fracture was found. The lower jaw was fractured in two places—viz., through the base of the coronoid process, separating that process from the rest of the bone, and through the neck of the condyle. The condyle remained in position, and the joint seemed in all respects healthy. The lower fragment was somewhat displaced, and had produced laceration of the meatus, separating the



cartilaginous from the osseous portion for nearly half of its circumference. A large quantity of blood lay around the fracture, and in the neighbourhood of the bone there was some fluid of a sero-purulent appearance. The preparation submitted to the Society consisted of three fragments of the lower jaw, and the greater part of the temporal bone, showing the laceration of the meatus auditorius. In consequence of the dissection that had been undertaken in order to open the tympanum and mastoid cells, the integrity of the petrous portion of the temporal had been destroyed, but the absence of fracture and the course which the blood had taken were still shown by the contrast between the meatus, which was lined with clotted blood, and the mastoid cells and tympanum, in which hardly a trace could be found.—*Transactions of the Pathological Society*, vol. xii.

CASE III.—*Ununited Fracture and Necrosis of the Lower Jaw, with Salivary Fistula, from old Gunshot Injury—Operation—Satisfactory Result.* Under the care of the AUTHOR.

James P., aged thirty-two, was admitted, August 19, 1862, into the Westminster Hospital, under the care of the author, for necrosis of the lower jaw.

*History.*—In March, 1860, when in the 64th Regiment, and whilst marching through Central India, he was struck on the right side of the lower jaw by a spent bullet, fired by some hill robbers. He was stunned for a few moments, and had hæmorrhage for half an hour. He went to the rear, but was able to continue the march. The following day he went into camp hospital, under the regimental surgeon, at which time the parts about the wound were much swollen. The wound was bathed with warm water, and the swelling was rubbed with soap liniment. At this time he was able to open his mouth and eat on the left side without pain; but three weeks afterwards, having attempted to eat on the right side, he felt a grating sensation and much pain, and told the surgeon his jaw was broken; but the surgeon did not believe him. The last molar tooth was found to have been displaced and to be lying horizontally, and attempts were made to extract it, but unsuccessfully. It gave him extreme pain, and the surgeon then admitted that the jaw was splintered. A gutta-percha splint was now moulded on, and a bandage applied for eight days, the wound having by this time closed. On April 9, 1860, he was admitted into the Kurrachee Hospital, and



another splint was applied, and kept on three or four days, when a large abscess formed. It was opened, and a large quantity of matter discharged, and the wound then healed. Another abscess began to form immediately behind the opening, and just below the original wound; and this also was opened and poulticed, and has never closed. The regiment arrived at Dover, on August 6, 1861, and the man was doing duty; but the cold weather coming on, the wound inflamed and swelled up again, and he was sent into Fort Pitt, on May 14, 1862. During the whole of this time he felt a numbness over the chin and all round the mental foramen. Various attempts had been made to extract the last molar tooth, which Dr. Longmore removed with some difficulty. After the patient had been in the hospital for twenty-one days, he was, on June 26, 1862, invalided and discharged from the service.

*Present Condition.*—There is an open sinus on the right angle of the jaw, leading down to dead bone and into the mouth, and he can blow air through the aperture. He can bite perfectly with the left side, and can open his mouth as wide as most people. He does not complain of any pain in the part, and his general health is good. He has never had syphilis. A small piece of bone has worked out into the mouth since admission. On looking into the mouth, a good deal of swelling about the ramus of the jaw is seen. The second molar tooth is *in situ*, but loose.

*Operation, Aug. 26.*—Chloroform having been administered, the author proceeded to enlarge the external opening, and removed, with the gouge, several pieces of necrosed bone. He found that the jaw had been fractured, that it had not united, and that the upper fragment was tilted forwards by the temporal muscle, thus causing the projection in the mouth before noticed. The wound was filled with lint, and a compress applied.

28th.—Face considerably swollen, but pain slight; wound discharging freely; can blow air easily through the wound from the mouth.

Sept. 10.—Wound has much decreased in size; two or three small particles of bone have worked out through the mouth.

20th.—The last molar tooth of the right side being quite loose, was extracted.

28th.—Says that the opening from the mouth has appeared larger since the extraction of the tooth, so that he is unable



to hold fluid on that side of his mouth ; external wound very much diminished in size.

Nov. 4.—The wound having degenerated into a small fistula, and there being no evidence of further disease of the jaw, the author determined to attempt to close it. For this purpose, he introduced a narrow knife into the opening, and, by rotating it, pared the surface, including the skin, and then brought the edges together with a curved needle and twisted suture, over which collodion was applied.

7th.—One end of the needle having cut its way out, it was removed altogether. The wound was not united. The edges were now brought together with a strap and pad and bandage.

14th.—Wound much diminished in size ; the edges touched with nitrate of silver.

22nd.—No fluid now passes through the fistula, and he says that he can feel with his tongue that the internal wound has healed.

26th.—External wound closed.

Dec. 9.—Discharged cured. The movements of the jaw are much freer than they were, and he can eat on the wounded side without pain or inconvenience. The false joint does not appear to affect in any way the powers of mastication or articulation.—*Medical Times*, January, 1863.

CASE IV.—*Fracture of the Jaws—Wire Suture.* Under the care of Mr. RUSHTON PARKER.

A boy, aged twelve, was brought to the Stanley Hospital on September 4, 1875, having half an hour previously fallen a depth of about six feet into a neighbouring sandstone quarry, some of the loose stones of which had crushed and injured his face. The left cheek was raw from general abrasion, and the lower lip split and ragged all over the red margin. The left upper jaw was obviously depressed, its front teeth and their alveolar margin driven in, and a perceptible difference of level between the hard palate of this and the right side.

The lower jaw was fractured at the first left bicuspid tooth, the break passing obliquely downwards and backwards, the inner margins of the fragments being exposed, rendering the fracture compound. The displacement here was considerable. There was, in addition, free bleeding from the right ear.

In about an hour later the jaw was drilled and wired. He



was now much blanched, and his pulse very feeble and quick ; the bleeding continued from the ear, but he was quite conscious and not in pain. Intense ecchymosis of the eyelids had now come on, greatly increasing the disfigurement. The bicuspid tooth at the seat of fracture was first withdrawn, as a precaution to ensure union. I then held the jaw with the left hand, and the handle of an Archimedean drill with the right, while the house-surgeon worked the drill. Two drill-holes were made, one in front of, and the other behind, the fracture, both being directed below the level of the inferior dental canal, so as to avoid wounding the nerve.

The front drilling was performed simply through the jaw after turning down the lower lip ; but that of the posterior fragment, being behind the corner of the mouth, was performed by piercing the cheek from the outside, drilling the bone there, and passing the wire through bone and cheek ; the wire was then picked up from inside the cheek by incising the mucous membrane under which it lay, the hole in the cheek being then done with and left to heal.

Each end of the wire was then twisted into a coil by means of the key devised by Mr. Hugh Owen Thomas, of Liverpool, which is simply a steel rod with a slit at the end, the coil in each case lying on the outside of the bone, but inside the lip and cheek. In returning the wire from the inside through the drill hole, a straight hollow needle was used ; this being easily introduced from the outside, and taking the tip of the wire which is then withdrawn with the needle. When the wire was twisted up the apposition of the fragments was perfect, and the only subsequent treatment adopted was frequent washing and wiping of the mouth and injured parts.

No dressing or bandages of any description were used, and the depression of the upper jaw was disregarded. The bleeding from the ear ceased the same evening, and the boy never had any particular discomfort, and slept well each night afterwards.

On the following day the key was introduced into one of the coils of wire to tighten it up, and about a quarter of a turn given ; after which the wire was not again interfered with until withdrawn.

He was kept in bed about a week, and fed on liquid diet for about a fortnight, by which time distinct union had taken place, as exhibited by an almost complete absence of tenderness on straining the fragments.

He lost three upper incisor teeth and the left canine, and their alveoli necrosed, during his convalescence. The left



lower second milk molar was shed during this period, and the permanent bicuspid appeared in its place.

The wire was cut and withdrawn twenty-six days after being put in, consolidation being firm, and some periosteal callus having formed.

An abscess formed in the cheek at the seat of fracture, and left a sinus leading to bone; this, however, was healed completely in ten weeks.

His appearance more than three months after the accident is somewhat peculiar, as the injury to the upper jaw has imparted a curious vacant expression to his face, the lips, too, being a little apart. This is mainly due to the absence of his front teeth and their alveoli, the place of which has granulated up and cicatrised; the deformity due to the depressed maxilla alone being now but slight; when complete contraction of the cicatrix has taken place he will be able to have a plate and some artificial teeth, which will probably restore his natural expression. The lower jaw is in every respect satisfactory, strong, and without any deformity.

CASE V.—*Extensive Injury to the Jaws by Shell—Secondary Hæmorrhage—Ligature of Common Carotid Artery—Death from Cholera.* By Dr. D. LLOYD MORGAN, R.N. (Notes by Dr. BIRCH, R.N.)

William Howden, aged twenty-six, a marine of H.M.S. *Euryalus*, was in the Japanese war, and was struck on the 15th of August, 1862, by a portion of a ten-inch shell. The right side of the neck and face was frightfully shattered, the wound extending from the corner of the mouth as far back as the zygoma superiorly, and the sterno-mastoid a little below the angle of the jaw inferiorly, the mouth being laid open. The body of the jaw on the right side, from within an inch of the symphysis to the angle was shattered. The zygoma was fractured in two places, and the alveolar process of the upper jaw was crushed at the roots of the first two molar teeth. The fragments which were loose were removed; there was no bleeding from the wound, which was searched in vain for divided vessels; the jagged edges were brought together, and water dressing was applied.

On the evening of the 19th, sudden arterial hæmorrhage came on, and about two pints of blood were lost. The bleeding ceased almost as suddenly as it commenced, only slight oozing continuing.



20th.—Return of bleeding to nearly same extent as before, but ceased under pressure applied to carotid.

21st, 4 A.M.—The hæmorrhage recurred to an alarming extent, the patient being almost pulseless. Dr. Morgan proceeded to cut down upon and tie the common carotid artery above the omo-hyoid, meeting with considerable difficulty owing to the matting together of the tissues. There was no return of hæmorrhage, and the ligature came away safely on September 3, and the patient was doing well, several small pieces of the jaws having come away, when, on the 17th of September, he was attacked with symptoms of cholera, and died at midnight.

*Autopsy.*—On reflecting back the soft parts from the chin, several fragments of the lower jaw were found loose, one spiculum projecting downwards, and giving rise to an external swelling, and another containing an incisor and bicuspid tooth. The zygomatic arch was fractured at both extremities. The lower jaw was wanting on the right side from the symphysis to the ramus; the upper jaw was fractured.

The common carotid was found to have been obliterated about two inches below the bifurcation, a mass of fibro-cellular tissue extending from that spot to the bifurcation, through the upper half of which was a small tortuous canal. A clot extended from the point of ligature down to the bifurcation of the innominata, and another clot extended for three-quarters of an inch into the internal carotid artery. The source of the hæmorrhage was not discovered.

CASE VI.—*Necrosis of nearly the whole of the Lower Jaw—Removal of the Dead Bone, including one Condyle—Recovery with perfect Movement of Jaw.* Under the care of the AUTHOR.

Egbert H., aged twenty-two, from Aylesbury, was sent to Mr. Heath by Mr. Ceely with necrosis of the lower jaw.

In August, 1868, he had typhus fever in Walsall Union, and during the attack the face became swollen, and discharged both externally and into the mouth. His teeth were all loosened, but none were extracted. In December he was passed on to Aylesbury, and came under Mr. Ceely's care.

On February 24, 1869, patient was admitted into University College Hospital under Mr. Heath's care. The right side of the lower jaw was immensely swollen, and two inches below the angle was a sinus through which a probe passed up towards the base. Another sinus existed below the right canine



tooth, and there had been a third below the left angle, which was now closed. The teeth were all more or less loose, and there were several openings in the gums, from which a most offensive discharge passed into the mouth. The man was well nourished and otherwise in good health, though he had when a child suffered from hip disease. On the day of admission, under chloroform, Mr. Heath extracted the molar teeth of the right side which were loose, and, having divided the gum, extracted a very large sequestrum, comprising the right side of the body of the jaw from the canine tooth to the angle, and containing the mental foramen. The hæmorrhage was very free, but was checked by plugging the shell of new bone from which the sequestrum was taken. The plugs were removed on the second day, and the mouth syringed out daily with disinfecting lotion.

On March 3, 1869, under chloroform, Mr. Heath cleared out some small fragments of necrosed bone left in the right angle of the jaw, and then proceeded to remove the necrosed portion on the left side, which extended as far as the second molar tooth. Mr. Heath attempted to save the incisor teeth, it appearing at first that the alveolus of that part of the jaw was not involved. It proved, however, that the disease had affected the whole thickness of the bone, and the teeth were necessarily sacrificed. Upon removal of the sequestrum there was left a complete framework of new bone, with a deep groove extending from the right angle (which was quite hollowed out) to the second molar tooth of the left side. The mouth bled freely, but this was checked as before by stuffing with lint. The patient made a good recovery, and was able to return to the country in a week, the discharge having almost entirely ceased, and there being a deep groove in the new structures of the jaw from which the sequestrum had been extracted.

On June 16, the patient returned, there being a portion of diseased bone on the right side. This Mr. Heath extracted, under chloroform, with some difficulty, through the mouth, when it was found to include the angle and a great part of the ramus of the jaw. From this operation also the patient made a speedy recovery, and returned to the country, and was not seen again by Mr. Heath until October, when he returned with yet more necrosis, involving the remainder of the right ramus. This was removed with difficulty on October 30, and the man has not since suffered from pain or discharge, so that it seems that the whole of the dead bone has now been taken away.

Perhaps the most singular feature in this case is the fact



that the man has now (December) as perfect movement of the jaw as if no disease had existed, notwithstanding that at the last operation the whole of the right condyle was removed entire, with about a third of the ramus. The repair has, in fact, been as complete as possible. When we saw the patient five weeks after the last operation, there was some fulness and prominence about the right angle of the jaw, and when the mouth was widely opened the lower jaw was drawn slightly to the right side; but otherwise all the jaw movements were perfectly performed without any pain or inconvenience, a deep groove in the gum, reaching from the right angle to the second left molar, alone remaining to show the former seat of such extensive disease.—*Medical Times and Gazette*, Dec. 18, 1869.

CASE VII.—*Abscess in the Right Upper Maxilla, communicating with the Antrum.* By Mr. MARGETSON, of Dewsbury.

Mrs. M., aged about forty, called to consult me about an enlargement of the right side of her face.

Found a hard swelling of the gums, extending from the median line to the right canine, and considerable bulging of the palate. She was wearing a badly made partial set of teeth over the roots of the incisors and left canine; the right canine was the only tooth left in the upper jaw. Three years ago had some swelling after pain in right lateral incisor, and abscess formed in the socket of that tooth. Her medical attendant tried unsuccessfully to extract the roots. The swelling decreased after a time, but never disappeared entirely, and for the last four months it has steadily increased. She has had no pain or tenderness, and only feels a sort of heaviness, and is anxious about the facial disfigurement.

On attempting to remove the root of the lateral incisor, it crumbled under the instrument. Trying a second time, and using a little more pressure, in order to seize the root a little higher, the forceps suddenly slipped upwards and were buried to the joint in a cavity in the bone. A gush of thin brownish fluid was the result, and free bleeding from the gum; there was also a discharge from the right nostril. Passing up a probe, I found a cavity extending from the alveolus of the right central incisor, behind the canine, to the position of the first bicuspid—which had been extracted some years. At the posterior extremity of the roof of the cavity there was



a pretty large opening into the antrum, through which the probe passed without meeting with any resistance. After satisfying myself that there was no tumour in the antrum, and removing a small piece of dead bone from the lower cavity, I syringed well with warm water, and dismissed my patient.

The only treatment required, after the extraction of the roots, was syringing with warm water for three or four days. No stimulating injection was used, showing that there was no disease in the antrum, or alteration in the secretion from the lining membrane.

CASE VIII.—*Disease of the Maxillary Antrum, involving the Brain.* By R. S. MAIR, M.D., F.R.C.S.E., Madras.

I was first called to see Mr. J. L., aged thirty years, on the 22nd of March, 1861. He complained then, and for some days previously, of a copious fetid discharge from the left nostril, severe pain in the left cheek, extending upwards round the corresponding orbit. There was no swelling over any part of the nose or cheek; the third molar tooth of the left side was loose and painful, and oozing from its side was a free fetid discharge the same as from the nostril.

Suspecting these symptoms to be probably produced by some mischief in the maxillary antrum, the loose tooth was without difficulty removed, and with immediate relief. The discharge from the nostril disappeared, and the pain in the cheek and round the orbit almost entirely ceased.

Four days afterwards (26th) the same severe pain returned, but of distinctly intermittent character; there was still no discharge from the nostril or tooth socket.

On the following day (27th) the patient had a sharp rigor, followed by fever, which continued for some hours, and the pain in the face and round the orbit continued unabated, notwithstanding the local application of anæsthetic anodynes.

On the evening of the 31st, Dr. J. Shaw saw the case with me, and suspected abscess deep in the cellular tissue of the upper eyelid, behind the eyeball; an incision was made in the upper eyelid close under the supra-orbital ridge, which gave vent to a discharge of some sanguineo-purulent matter.

There was immediate relief to the sense of fulness in the eye; the eyeball could be moved more easily, though vision was not perceptibly improved. The patient slept better



that night than he had done for several nights previously, but otherwise, on the following morning (April 1), his symptoms were most unfavourable. The eyeball was enlarged to nearly double its natural size, and was protruding considerably forwards, while the upper eyelid was again very much swollen, and the lower one everted, exposing the chemosed conjunctiva, and leaving about one-half of the eye itself uncovered and exposed.

The patient complained of little pain, and remained tranquil up to eleven o'clock forenoon of April 2, when suddenly, and without a single premonitory symptom, he had a most violent convulsive fit, of an epileptic form and tetanic character. This fit, which was followed by two others of the same kind on the same day, was preceded by a peculiar scream or howl, followed immediately by rigidity of the whole body, opisthotonos, foaming at the mouth, and complete unconsciousness. These fits each lasted about five minutes, but consciousness did not return till some time after.

This was the first indication of cerebral complication. It should be here noted, that prior to the first fit, in consequence of the great distension of the eyeball, and as no matter was found in the incision, which was made deep into the cellular tissue of the orbit, a seton was introduced into the left temple, and, subsequently to the fits, a cantharides blister was applied to the nape of the neck.

On April 5 the eye continued much swelled, and some pus escaped from the wound over the eyelid. The probe was again introduced to give free vent to the matter, but none came away. During this day the patient had a recurrence of the same fits as before, and while in one of them the pulse flickered and fluctuated so much as to threaten extinction every moment.

He continued in the same condition all the 7th and up till the evening of April 8, when he became completely comatose. From this he never rallied, but gradually sank, and died early on the morning of April 9, sixteen days after he first consulted me.

The eye during the last three days of his life remained unchanged; a small quantity of pus escaped from the wound in the eyelid, but there was little or no decrease in the swelling of the globe. The discharge from the nostril ceased after the globe began to swell, and that from the tooth-socket disappeared after the tooth was extracted.

The patient had always enjoyed good health prior to his



last illness. He had none of the usual indications of the strumous diathesis, and there was no reason to suppose that he had any syphilitic taint in his constitution.

*Post-mortem appearances.*—Head only examined. Purulent matter in considerable quantity flowed from the cavity of the arachnoid, and from between the hemispheres, on the removal of the falx. There was a layer of more consistent pus on the visceral surface of the arachnoid in some parts of both hemispheres, which, on removal, did not leave the arachnoid roughened.

At the anterior margin of the left hemisphere, there was a rugged, excavated, and ulcerated surface, rather larger than a florin, covered with thick purulent matter, and appearing to be the source of the pus found in the arachnoid; but on turning up the anterior edge of the hemisphere from the roof of the orbit, there was found on its lower surface, about an inch from its anterior extremity, a small opening, with dark-coloured edges, from which a thin serous and discoloured fluid was exuding. This opening led to a cavity large enough to contain a good-sized walnut, lined with a dark-greenish, investing membrane, of at least half a line in thickness, which could easily be peeled off from the surrounding cerebral substance.

The brain was now removed, and was perfectly healthy.

On introducing the finger into the orbit, and passing it along its inner boundary, the latter was found diseased—the ethmoid bone crumbling before the finger, which passed readily into the upper part of the nose. Here all the osseous structures yielded readily to the touch of the nail, and portions of the ethmoid bone were removed by it with great facility.

They were in a state of caries, of very fetid odour, and bathed in pus; broken-down serofulous matter on both.

The contents of the orbit being removed, the antrum was opened from above, when its cavity was found filled with a white, soft substance of the appearance and consistence of firm blancmange, and also very fetid. This substance, subsequently examined under the microscope, was found to consist mainly of tuberculous matter, interlaced with very delicate fibres, and showing an abundance of pus-corpuscles. The membrane lining the antrum was entire, considerably congested, and streaked with red lines. The cavity of the antrum did not appear to be enlarged.—*Edinburgh Medical Journal*, May, 1866.



CASE IX.—*Removal of large Cystic-sarcoma of Lower Jaw—*  
*Recovery.* Under the care of the AUTHOR.

The patient is a native of Cumberland, and has been a carter ever since he was eight years old. His parents are living and healthy. When a child he suffered from suppurating glands in the neck and submaxillary region, which were opened: otherwise he has always enjoyed good health. Never had syphilis; has lived well; drinks beer freely; is often drunk (*i.e.*, on an average once a week). Has followed his occupation up to the time of admission. About six years ago he first noticed a small, hard swelling, about the size of a marble, situated in the right cheek, attached to the gum and lower jaw, but movable under his fingers. From the first it had an aching pain, dull and constant. The tumour continued to increase in size, and four years ago it was lanced in the gum; it then began to discharge, and has continued to do so slightly ever since. He has noticed that the discharge is more abundant after drinking much. It has been lanced twice since, and within the last six months it has been twice tapped by Mr. Watson, of Lancaster: the first tapping just before Christmas; the second, five weeks before admission. Mr. Watson says that at each tapping about four ounces of fluid were drawn off. From the displacement inwards of the two anterior molars and the second bicuspid tooth by the increased growth of the mass, these teeth were extracted two years ago. Since Christmas the tumour has grown with increased rapidity, and has become more tender. During this time the patient says he has lost a stone and a half in weight, and that his appetite has diminished. The patient cannot assign any cause for the origin of the growth. He has had no bad teeth in that jaw. Remembers having had a blow on the jaw with a pitchfork handle before the tumour appeared.

July 10, 1872.—The patient is fairly built, florid, and sunburnt. He does not look ill. Tongue clean; appetite better than it has been; pulse 76, full and bounding.

The right side of the face presents a large, smooth, globular swelling, which occupies the whole side. It extends in front to the angle of the mouth; behind, to a distance of about an inch behind the lobule of the ear, measuring in this diameter  $7\frac{1}{2}$  in. Above, it extends from the tragus of the ear along the lower margin of the orbit to the side of the nose; below, on a level with the hyoid bone. It measures from above



down, over the greatest prominence,  $8\frac{1}{2}$  in. The circumference of the mass measures 18 in. The right angle of the mouth is drawn slightly upwards and outwards; but the contour of the lower lip is unaffected, and the contour of the chin quite preserved. The upper part of the mass is more vascular in appearance than the lower. On the under surface are some cicatrices from the abscesses which were opened when he was a child. The rest of the surface of the tumour is quite smooth, not ulcerated. Temperature of the cheek,  $99\cdot7^{\circ}$ . The tumour is more tender posteriorly than elsewhere. Its lower two-thirds feel hard and resisting, the skin being quite movable over the mass. The posterior portion of the tumour is also solid, as well as a portion which extends in front of the ear for about an inch. The rest of the mass is soft and fluctuating, evidently containing fluid, and the upper margin of the solid portion can be distinctly felt across the tumour; inside the mouth the alveolar border of the right side of the lower jaw is much widened, extending inwards, so as to diminish the cavity of the mouth behind the first bicuspid. The second bicuspid and first and second molar teeth are wanting. The patient says the third molar is present; but it is not visible, nor can it be felt. On the widened alveolar border is an ulcerated surface, covered with a layer of thin purulent fluid, which is continually oozing. The tumour evidently arises from this part of the lower jaw; for, anteriorly, a thin shell of bone can be felt continuous with the jaw and with the surface of the tumour. The upper jaw does not seem to be implicated in the growth. The teeth in it are all present; but the alveolar border has been displaced inwards from the growth of the tumour, so that the roof of the mouth appears contracted (fig. 93).

July 12.—Chloroform having been administered, Mr. Heath proceeded to remove the tumour. He first extracted the right canine and second incisor teeth of the lower jaw, a piece of the jaw coming away with the teeth. He then made a vertical incision to the right of the symphysis through the lip down to the base of the jaw; from the lower end of this incision he cut upwards and backwards over the tumour towards the ear as far as one inch above the angle of the jaw; in making this cut he divided the facial artery. Ligatures were applied before the incision was completed. The whole length of the incision was about nine inches. The superficial tissues were then dissected off the tumour, the large upper flap being first raised; and the tumour was carefully shelled



out. In dissecting up this flap the facial artery was again cut and ligatured. The cyst at the upper part of the tumour being now fully exposed, it was laid open by a free incision extending right across it, and about ten ounces of fluid escaped. Mr. Heath then continued to separate the mass from the skin at the lower part, and, having cleared it as far as the anterior incision, he sawed through the jaw where the teeth had been extracted. He then cut through the mucous membrane and muscles attached to the jaw, and here again some vessels had to be secured. Having completely separated the mass, he attempted to forcibly depress the jaw so as to disarticulate it; but, the coronoid process becoming caught against the malar bone, he had to detach the process by the bone forceps. On depressing the jaw, he found that a small portion of the condyle was free from the growth. As he was proceeding to disarticulate, the remains of the lower jaw gave way just below the condyle, the tumour shelling out from the expanded bone round it. The posterior part of the jaw was left nearly down to the angle; a small piece of this was afterwards cut off with the bone forceps. About four ligatures were applied to bleeding vessels, and the rest of the hæmorrhage was arrested by the actual cautery. The wound was then thoroughly sponged out and sewn up; for the incision through the lip hare-lip sutures were employed, and a very fine suture for the mucous membrane of the lip, the rest of the incision being closed by silver wire sutures; the whole of the wound was then painted with collodion. There was not very much blood lost during the operation. The patient was not thoroughly under the influence of chloroform the greater part of the time.

After removal the tumour was almost globular in form. It measured  $3\frac{1}{2}$  inches in diameter at its widest point. It was slightly lobular on the surface. It weighed  $13\frac{1}{2}$  oz.; but at the upper and outer aspect was a large cyst capable of containing about 6 oz. of fluid. The lower part of the wall of the cyst was bony, but the whole of the upper part was free from bone. The whole of the inner wall of the cyst was formed of a thin layer of bone. Just anterior to this large cyst was a smaller one containing about  $\frac{1}{2}$  oz. of thick fluid, in which was a large quantity of cholesterine. Its walls were bony everywhere. Both cysts were lined by a smooth thin membrane. On the inner side of the tumour were two openings about  $\frac{3}{4}$  in. in diameter, which had opened into the



mouth. They communicated with a large cavity in the centre of the tumour, into which the finger could be pushed as far as the second joint. On making a section right through the mass, this central cavity was found to be about 2 inches long. The inner surface was very irregularly lobulated. The lobules varied in size from a pea to a filbert. They were covered by a smooth membrane. The tumour was moderately firm, of a whitish colour, and small points of bone were scattered through it. On scraping, it yielded a whitish fluid mixed with fragments of the substance of the tumour. Under the microscope this was found to consist of a few spindle cells and a vast number of free oval nuclei, containing one, two, or three shining nucleoli. Some of the nuclei were perfectly circular. The average diameter was about  $\frac{1}{1500}$  inch.

On examining sections made from one of the lobules from the central cavity of the tumour, it was found to consist chiefly of a dense fibrous tissue, amongst which were oval and irregularly shaped spaces, having an appearance much resembling acini and ducts of glands. They were completely filled with oval nuclei, each containing one or more bright shining nucleoli. They were arranged along the walls of the spaces so as to look like epithelium, but they had not the distinct cell and nucleus characteristic of epithelium. The relative proportion of the spaces and fibrous tissue varied greatly. At some parts it was almost firmly fibrous, and at others the spaces formed the greater part of the growth. The patient made a quick and uninterrupted recovery.—*Lancet*, March 23, 1872.

CASE X.—*Case of Extensive Epithelioma of the Lower Jaw and Floor of the Mouth—Removal.—Satisfactory state two years later.* Under the care of the AUTHOR.

John S., aged sixty-eight, plumber, was admitted on the 9th of January, 1879, with epithelioma of the left lower jaw and contiguous mucous surfaces of the floor of the mouth and cheek. In the early part of October, 1878, the patient noticed that his three left lower molar teeth were loose, and they were accordingly extracted. About the beginning of November he noticed, for the first time, a small sore on the left side of the floor of the mouth, corresponding in position to the teeth removed. This gradually and almost painlessly increased in size. The patient began to suffer likewise from



nausea, especially in the morning. A medical man who was consulted ordered red wash for the mouth. Three weeks later he began to apply caustics, which he did six or eight times altogether. About a fortnight before admission the sore began to bleed, and continued to do so. There was no history or evidence of syphilis, and the patient alleged he had always been healthy. He was a smoker. He did not know the cause of death of either of his parents, both of whom, he said, had lived to old age. His brothers all died at comparatively early age, ascribed, by the patient, to their unhealthy occupation as masons. He was unable to give an account of the nature of their last illness.

On admission he was a corpulent but very anæmic man, looking younger than his real age, and had general tremors. He was losing flesh, because the condition of his mouth allowed him to take but little food. The bowels were regular, and the general health fair. He suffered from sleeplessness, and pains about the affected side of the face of a radiating and lancinating kind.

On opening the mouth an ulcerating mass of new growth was observed, involving the left half of the floor of the mouth and adjoining alveolar process of lower jaw, the surface of which was composed of large vascular granulations, ragged and covered at the posterior part with small sloughs. To the feel it was soft and extremely tender, extending backwards as far as the ascending ramus of the jaw, inwards to the middle line, and in front, beyond this, to the right as far as the right canine tooth, which was very tender when pressed upon, although on the outer side—*i.e.*, between the gums and lips—it was not evident beyond the mid-line. The structures at the floor of the mouth were involved to a considerable depth, but the tongue was free. Externally it involved the alveolar process of the lower jaw on the left side, and extended to the junction of its gingival mucosa with that of the cheek. The teeth of both upper and lower jaw were discoloured; the left lower molar and the right lower molars and bicuspid were absent.

No enlargement of lymphatic glands could be felt in the neck, nor was there any induration or tenderness beneath the jaw. There was a sanious fetid discharge from the growth, and slight stomatitis. The tongue was furred, especially at the back, and red at the edges.

Urine: sp. gr. 1018, neutral, high coloured, no albumen or sugar.



The heart and lungs were healthy. Neither spleen nor liver was enlarged.

On January 22, at 3 P.M., the patient was put under the influence of chloroform, and Mr. Heath extracted the right lateral incisor tooth, and then cut through the lip and soft structures down to the lower border of the jaw. The jaw was then sawn through at the point where the tooth had been extracted. A string was now passed through the tongue by which that organ might be drawn out if necessary in case of impediment to breathing (which did occur once or twice during the operation). Mr. Heath next divided the structures beneath the lower border of the jaw, beginning at the lower end of his first incision, and ending just in front of angle of jaw, the facial artery being secured by hare-lip pin ligature. Turning back the cheek flap the jaw was sawn through about an inch and a half in front of the angle, and the piece of bone included between the two saw-cuts, together with the greater part of the growth attached, removed by dividing the soft parts of floor of mouth attached to it. At this stage much hæmorrhage occurred, chiefly from the lingual artery and its branches, which were all ligatured. The dental foramen in the portion of jaw left behind having been closed with a spigot of wood, the remainder of the growth was dissected off the flap. The parts were then mopped out with a strong solution of chloride of zinc; all suspicious particles removed; the flap was brought down and secured by four or five fine wire sutures, two hare-lip pins and twisted sutures being employed to secure the lip, with an additional suture of fine silk at the upper part at the verge of its mucosa. At the posterior part of the wound a small opening was left, through which the end of the ligature applied to the facial artery was allowed to protrude, acting instead of a drainage-tube. The edges of the wound were finally painted over with collodion, and covered with dry lint, and the patient put to bed. The string in the tongue was allowed to remain, and kept out of the mouth in case its use should become necessary.

On examining the growth removed it presented all the naked-eye appearance of an ulcerating epithelioma, involving the alveolar process as far back as the last molar tooth, while forwards it was co-extensive with the excision. It spread outwards to the adjacent part of the cheek, but involved only the mucosa, and not the deeper structures. Inwards it reached along the floor of the mouth as far as mid-line. The tongue was not involved. The posterior section of the face



showed two questionable-looking spots of probably an extension of the growth.

The patient's pulse became irregular and feeble after the operation, and he appeared somewhat collapsed; but brandy was administered, and he had ice to suck. There was little trouble with the tongue, and he slept well during the night. Next morning the pulse was still feeble, but regular, and the patient seemed to be in good spirits.

On the 24th, patient complained of headache. He had slept fairly during the night. The pulse was very weak, 92; temperature 99°; respiration 24. As he had not taken his food well, an enema of beef-tea and brandy and eggs (of each one ounce) was administered. The mouth was carefully washed out with a good quantity of warm solution of Condyl's fluid lotion. Discharge not very offensive.

On the 25th he had slept fairly well. He complained of pains in the lower lip and up the left side of the face. The pulse was still very weak, 92; temperature 99°. The parts were well syringed out.

On the 27th the patient was looking quite bright. The parts were doing very well. The sawn surfaces of the bone could be seen covered with granulations.

On the 29th the temperature was normal, and the patient had thoroughly recovered from the effects of the operation. The discharge from the mouth drained through the lower opening, and was only slightly offensive.

From this time the patient made a rapid and steady recovery, and was discharged on February 21 to go to Eastbourne. He returned in March with the mouth quite healed. In November, 1880, the patient visited the hospital in perfect health, having grown stout and strong for his age. The mouth was perfectly sound, the gap in the jaw being filled by firm, dense cicatrix, covered with healthy mucous membrane, the right side of the jaw being drawn inwards by the action of the muscles, as is usual in cases of division of the mandible.—*Lancet*.

CASE XI.—*Epithelioma of the Antrum—Pneumonia—Death.*  
Under the care of the AUTHOR.

R. M., aged fifty-nine, a shoemaker, was admitted on May 30, 1879. At the beginning of the previous month he had noticed that his right nostril was obstructed; a week or two afterwards the lower lid of the right eye became



inflamed, and a swelling which commenced here rapidly extended over the right cheek. About this time a painful swelling of the hard palate appeared, and the patient consulted a dentist, who extracted a tooth. Shortly afterwards he applied at the hospital. His brother was stated to have died of cancer of the kidney. The other members of his family were, so far as he knew, healthy.

He was a pale but well-nourished and well-preserved man for his age, though he had, he stated, lost flesh latterly. Temperature varied from 99° to 100° F. He complained of a feeling of stuffiness in his jaw, but of no pain.

The skin of the right side of the face was reddened, œdematous, and tender, and the cheek was projected outwards by the tumour beneath it. The right eyelids were closed and œdematous, but could be opened slightly, displaying chemosis of the conjunctiva, a clear cornea, and a somewhat sluggish iris. The right nostril was obstructed, and there was a purulent discharge from it; the nasal duct on the right side also appeared to be obstructed, giving rise to overflow of tears. To the touch the tumour gave the idea of a soft solid rather than of fluid. Most of the right half of the hard palate was absorbed, a soft elastic swelling occupying the roof of the mouth, the mucous membrane of the latter being congested and swollen. The teeth of the upper jaw were carious or absent, but the alveolar process was neither displaced nor softened. Owing to the resistance of the patient, an examination of the posterior nares could not be made. The lymphatic glands in the posterior triangle of the neck were enlarged, but free from tenderness. The mouth could not be opened to its full extent, and speech was slightly affected. The tongue was broad, pale, and marked by the teeth.

On the 31st a fine trocar with canula was inserted into the swelling on the roof of the mouth, and a few drops of stinking pus evacuated. The opening made by the trocar was subsequently enlarged, and a drainage-tube was passed into the antrum.

It soon became evident that the growth was malignant, and as the man's condition became worse daily, removal of the upper jaw offered the only chance of prolonging his life. This was accordingly done on June 4. The floor of the orbit was taken away, but it was impracticable to wholly extirpate the growth in this direction, as the orbital structures were infiltrated. The somewhat free bleeding was



restrained by the actual cautery, and the cavity of the wound was stuffed with strips of lint soaked in a strong solution of chloride of zinc.

The growth appeared to have commenced in the antrum, the walls of the latter being partially absorbed, the anterior almost wholly, thereby allowing invasion of the orbit, the mouth, and the pharynx. Several pieces of dead bone, surrounded by offensive pus and débris of broken-down growth, were found in its cavity, thus accounting for the inflammatory condition of the superjacent skin, and the purulent discharge from the mouth and nostrils. In other parts the growth was of a yellowish colour, translucent, gelatinous, and vascular. Several ordinary soft gelatinous polypi were extracted from the right nostril during the operation.

In sections taken from the margin of the growth near the gum, the microscope showed cylinders of epithelium cells, irregular in form and sinuous in outline, sometimes anastomosing, set in a stroma made up of fibrous tissue and spindle-shaped cells. Epithelium "nests" were observed here and there, but these were few, small, and ill-developed. The papillæ of the mucous membrane covering the gum, where the latter was infiltrated, were hypertrophied. The histological characters of the growth appeared to correspond with those of the "*épithéliôme tubulé*" of Cornil and Ranvier.

On June 13 pneumonia was present at the base of the right lung, and on the following day friction sounds were audible over the affected area. The edges of the skin wound had united, except at the inner angle of the orbit.

On the 16th there were dulness, extremely weak breath sounds, diminished vocal fremitus, and resonance to the angle of the right scapula, with bronchial respiration above. The lymphatic glands, which had become larger and very tender in the right posterior triangle, had diminished in size after treatment with belladonna and poulticing.

On the 18th the physical signs of pneumonia at the left base became evident, and the general condition of the patient worse, though he wanted to "be up and about." The fœtor from the cavity of the wound was now almost intolerable, and one or two sloughs had separated.

From this time the chest symptoms increased in severity, and he died on June 26.

*Necropsy* (by Mr. BARKER) *twenty-five hours after death.*—



Rigor mortis well marked. Body well nourished. The serum in the pericardium was normal in amount and characters. The heart was somewhat enlarged, and rigor mortis was well marked; a good deal of fat was noticed, chiefly on the anterior surface. The superficial veins were somewhat loaded. The right auricle contained firm post-mortem clot. The right ventricle was also engorged with clot, part of this having evidently formed during several hours before death. The left ventricle was firmly contracted, and contained a small quantity of tough coagulum. The cardiac valves were healthy. The left lung was extremely emphysematous anteriorly, and posteriorly it was covered with recent lymph, hardly adherent. There were six ounces of serum in the left pleural cavity. The inferior lobe was considerably congested, and some small portions were collapsed. Section showed general congestion, and grey hepatization with softening at numerous points, but the lung was not gangrenous. The bronchi were intensely congested in patches down to the small ramifications, and full of dirty brown sero-mucous fluid. The right lung was adherent to a large extent of the ribs, particularly over the lower lobe, and by more recent lymph above. A large abscess opened on removing lower lobe from chest wall. This abscess, occupying a large portion of lower border of upper lobe, upper border of lower lobe, and extending deeply into the substance of the lung, was a ragged, ill-defined space, full of black, very fetid, broken-down lung tissue, and was surrounded by blackened, sloughing, very soft lung tissue. The bronchi, as in the left lung, were intensely congested, increasingly so towards the finer ramifications, and full of foul sero-pus. The bronchial glands were much enlarged at root of both lungs. The tongue was covered with a thick covering of foul material, apparently dropping down from the roof of the mouth. There were enlarged papillæ at the base, the size of millet seeds, raised, pedunculated, and deeply pigmented. The œsophagus was normal. The mucous membrane of the larynx and trachea was inflamed throughout. There was a quantity of grey mucus in the ventricles of the larynx. The anterior surface of hard and soft palate was covered with foul, tenacious pus. The operation cavity extended back beyond orbit to the pterygoid fossa and upwards to sphenoid bone. The septum of the nose was carious, and giving way. The orbit and eyeball had not been particularly injured by the operation. The liver was apparently



normal. There was no post-mortem staining in the great vessels, nor extravasation in the mucous membrane of the intestines.—*Lancet*.

CASE XII.—*Large Osteo-sarcoma of the Lower Jaw—Removal—Death.* Under the care of the AUTHOR.

W. T., aged thirty-two, was admitted into University College Hospital, Nov. 13, 1867, with an enormous tumour of the lower jaw. About eleven years before he had a severe pain in the right jaw resembling toothache, and after some little time he perceived a small hard swelling about the size of a nut just below the right canine tooth, which was not decayed, nor were any of the teeth in its immediate vicinity diseased. This swelling continued about the same size for five or six years, during the latter part of which time it was entirely free from pain. Four years ago it began to enlarge, and two years afterwards he was thrown from a cart and fell on his face, when he had profuse bleeding from the gums. The tumour now grew rapidly, spreading along its anterior surface, and involving the whole of the right side of the jaw. About twelve months ago it began to involve the left side of the jaw, and extended up to the angle. He had been seen by various medical men at his native place, and also by one London hospital surgeon, and the question of an operation had been discussed, but nothing had been done. Two years before, one quack burnt the inside of his mouth with acid, and another put a white ointment upon the surface of the tumour, which caused the skin to give way at the point where the protrusion appeared. About a year before admission, the portion of the tumour near the right angle of the jaw rapidly increased, and in a short time the skin gave way, and a quantity of offensive pus was discharged, but there was no diminution in the swelling. Latterly, owing to the difficulty in swallowing, he had been able to take little but milk and brandy, and this in small quantities at a time, so that he had become much reduced in strength. His family had all been healthy and long-lived.

On admission, the patient presented an extraordinary appearance, the mouth and all the lower part of the face being occupied by an enormous tumour. The measurements of this were as follows:—From the lobule of one ear round the chin to the lobule of the other ear,  $19\frac{1}{2}$  inches; from the border of the lower lip across the chin to the pomum Adami, 13



inches ; from the angle of the jaw across to the same point on the opposite side, 14 inches. When the man was sitting the tumour rested upon the top of the sternum ; but it moved freely when he opened and closed the mouth. Between the lips, of which the lower was much stretched, so that the circumference of the mouth measured  $9\frac{1}{2}$  inches, there was a red, granulating mass of disease, which came in contact with the upper lip ; but when the mouth was opened, a space intervened through which a second mass, covered with the mucous membrane of the floor of the mouth, could be seen almost in contact with the roof of the cavity, and completely hiding the tongue. Between these two masses some of the teeth could be felt and seen. Fig. 161, taken from a photograph, shows the patient with his mouth shut. From beneath the cheek on the right side a foul, yellowish discharge constantly exuded. An inch below the lower lip was a large red, fungous mass covered with healthy granulations ; this extended to the lower border of the tumour, and the skin was adherent around it. On the right side, just below the angle of the jaw, there was another smaller fungous projection ; but the skin on the left side was perfectly healthy, though much stretched. The right ramus of the jaw could not be defined, though the angle could be distinctly perceived. The articulation, however, was not involved. The tumour, though overlying the neck, in no degree involved its tissues, and there were no enlarged glands either below the jaw or in the neck. On the left side the whole of the ramus and angle could be clearly made out, the disease stopping short of the latter point.

From the time of his admission the patient was well fed with strong beef-tea, milk, eggs, and brandy ; and considerably improved in appearance. Mr. Heath's colleagues agreeing with him as to the advisability of an operation, this was undertaken on Nov. 20, 1867. The patient being seated in a chair, Mr. Clover administered chloroform at first with the ordinary mask, and during the operation with a smaller one, enclosing only the nose. As soon as the patient became partially unconscious he was carefully secured in the chair with bandages, and his head was held firmly against the breast of an assistant. Perfect anæsthesia having been induced, Mr. Heath, standing on the right hand of the patient, divided the lower lip in the median line, and carried the incision round the right side of the fungous protrusion to the lower extremity of the tumour. The skin was then rapidly dissected back with the assistance of Mr. Marshall,



who took up the vessels of the flap. Returning to the middle line, Mr. Heath made a second incision on the left side of the fungus, meeting the former one above and below, and dissected back the skin off the tumour, as far as the jaw. The bone being isolated with the assistance of Mr. Erichsen, the second molar tooth was drawn, and a narrow saw applied at that point; but before complete division was effected the weight of the tumour caused it to break away. As had been pre-arranged, Sir H. Thompson then grasped the tongue, which was now seen for the first time, and transfixed the tip with a stout needle and ligature, by which it was held until the operation was concluded. On dividing the mucous membrane beneath the tongue, a large lobulated mass came into view imbedded among the sublingual muscles; and this being dragged forward, the muscles were divided close to the tumour, and one or two bleeding vessels were promptly secured by Mr. B. Hill. The tumour being then turned over to the right side, Mr. Heath carried the knife upwards, so as to clear the coronoid process, which was healthy; but this appeared to be driven forward against the malar bone, and tightly jammed, so that forcible traction made on the tumour failed to clear it. Grasping the process itself with the lion forceps, Mr. Heath succeeded, however, in wrenching it out, when the condyle of the jaw, also healthy, immediately came forward without any dissection. A little dissection round the posterior margin of the tumour now completely disconnected it, and it was removed. About half a dozen bleeding vessels were now tied, none of them of large size, the two facial arteries having been preserved uncut. Finding the bone on the left side where the tumour had broken away rough and irregular, Mr. Heath sawed it cleanly through, close in front of the wisdom tooth.

There was now an enormous gap; the fauces, tongue, and front of the larynx being fully exposed, and the flap of skin on each side being pendulous and superabundant. The right was somewhat ragged, owing to the perforation which had taken place, and also owing to its being so adherent to the tumour that it had been perforated at one or two points; Mr. Heath therefore removed a portion of it, adapting the opposite flap to it. The lip was then brought together with three hare-lip pins and a twisted suture, and the remainder of the incision was held together with four silver sutures, placed some distance apart so as to allow discharge to escape. The thread holding the tongue was next secured to the hare-



lip pins, so as to bring the apex of it close to the lip; and some lint was placed in the large cavity, and a bandage externally, so as to check oozing and maintain the shape of the part. The patient was then carried to bed. Not more than three ounces of blood were lost.

Half an hour after the operation the patient had some brandy by the mouth, and one-third of a grain of morphia was injected beneath the skin. He dozed during the afternoon, but was well supplied with beef-tea and brandy both by the mouth and per rectum. He had a second dose of morphia at night, and got some sleep, being warm and comfortable, and with a fair pulse.

On the two following days the patient's condition was as comfortable as could have been hoped for; he took plenty of nourishment and stimulants by the mouth, and also had nutrient enemata.

On the evening of the third day his breathing and pulse became more rapid, and he had a slight rigor. Mr. Heath now removed the ligature holding the tongue, which was giving him some inconvenience, and ordered him quinine in ten-grain doses.

On the 23rd his condition was more satisfactory again. The pledgets of lint in the chin were removed, and the wound well washed out with Condyl's fluid. He passed a comfortable day, and on Sunday (fifth day) he was apparently gaining ground, and was well enough to write his want of some stout upon a slate, and took plenty of nourishment. In the evening, however, he suddenly became worse, the pulse failing and the skin becoming cold; and notwithstanding the most solicitous attention on the part of the house-surgeon, Mr. Shoppee, he died early on Monday morning (sixth day).

At a post-mortem examination, all the viscera were found healthy, and there was no evidence of pyæmia. The wound had so contracted that the outline of the face was quite restored. The skin at one point was a little discoloured, as by a bruise.

The tumour weighed 4 lb. 6 oz., and was a good example of fibro-cellular growth, springing up between and expanding the plates of the lower jaw. The disease extended from the junction of the body with the ramus of the left side to half-way up the ramus of the right side. The right condyle was perfectly healthy, and the coronoid process had been broken off in the operation. Mr. Heath showed the preparation at the Pathological Society on Dec. 3, and a wax model of it in



the recent state has been placed in the Museum of University College.—*Lancet*, Dec. 21, 1867.

CASE XIII.—*Case of Symmetrical Enlargement of both sides of the Lower Jaw—(Myeloid?)* Under the care of the AUTHOR.

William Henry Hogan, aged seven and a half, was brought to me, Feb. 12, 1867, by Mr. C. J. Fox, with remarkable enlargement of both sides of the lower jaw. When a year and a half old the mother first noticed an enlargement, first of one side (right?), and then of both, which has been gradually increasing. He has never complained of any pain, but had a good deal of difficulty with his teeth. He was rickety in his legs, and was at Ormond Street Hospital for some time.

He is now a well-nourished boy, with a remarkably broad face, due to the symmetrical development of a tumour on each side of the lower jaw, involving the posterior half of the body on each side. The tumours are smooth on the outer and lower part, but slightly nodulated at the upper. Within the mouth they come up to the level of, but do not encroach upon, the teeth. He has cut his permanent first molars and incisors. The temporary canines and molars are still present, and somewhat decayed.

April 3.—He came to University College Hospital. Ordered ung. iodin. co. to apply to one side. The boy attended for a short time at the hospital without improvement, and then ceased to come.

In September I saw him, and found that both tumours had considerably increased, and I persuaded his parents to send him into the hospital, where he was admitted on Sept. 9, 1867. A photograph and cast were now taken (fig. 170).

*Operation*, Sept. 11.—I made an incision over the right or larger tumour, and having divided and tied the facial artery, exposed and scraped the periosteum off the tumour. It was bony externally, but felt spongy on pressure. With a narrow saw I then removed the most prominent portion, which cut very easily; then a second slice, and afterwards, with the bone forceps and gouge, removed as much of the semi-cartilaginous structure as I could without interfering with the teeth or opening the mucous membrane. As the surface of the bone bled freely, it was touched lightly with the cautery, and the wound was filled with lint. The growth appeared to



be an enchondroma, expanding the outer plate and undergoing ossification, but is pronounced myeloid by Mr. Bruce. The inner plate of the jaw was perfectly even, and at the end of the operation not more than the normal thickness of jaw remained.

The wound suppurated healthily, and soon contracted, the boy being about again in a few days.

Oct. 2.—I removed the growth on the left side in the same manner as before. This growth appeared of precisely the same character as the other. The boy made a rapid recovery, and was discharged with the wounds nearly healed on Oct. 10.

The boy came to me in December quite well, and a second photograph (fig. 171) was then taken. He continues well at the present time.

CASE XIV.—*Medullary Sarcoma of Lower Jaw in a Child—Two successful Operations—Return of the Disease—Death.*  
Under the care of the AUTHOR.

Miss M. R., aged five, was sent to me by Mr. Edward Randall, of Finsbury Square, on Sept. 9, 1867, with a tumour of the lower jaw. She was the tenth of a family of eleven healthy children, and her parents are strong and robust. She was fat and well-nourished, though thinner than she had been, and in good health until the last week in July (seven weeks before), when her mother noticed that the second temporary molar tooth on the right side was raised above the others, and the gums looked swollen. Her mother took out the tooth, which was quite loose: but the swelling increased, and the first permanent molar became loose, and was extracted by Mr. Cole, of Ipswich. She was under the care of Mr. Mumford, of Ipswich, who used nitrate of silver lotion without benefit, since the growth continued to increase rapidly, so that she has been unable to eat solid food for a fortnight.

The whole of the lower jaw on the right side was considerably enlarged, and on opening the mouth, a large, irregular, reddish mass was seen filling up all the cheek on the right side, the extent of which it was impossible to define. The tumour had a semi-elastic feel, and there were apparently no enlarged glands. There could be no question as to the propriety of, and necessity for, immediate operative interference, which I arranged to undertake on the following day.



On Sept. 10, 1867, the patient being under the influence of chloroform, I got my finger into the mouth, and then ascertained that the jaw was completely involved in the tumour, the elastic feeling being communicated through the bone. I divided the lower lip in the median line, and carried the incision round the border of the tumour to the level of the lobule of the ear. I then dissected back the flaps, and having divided the facial artery, tied it. Having extracted a loose tooth, I then sawed through the jaw immediately to the right of the symphysis, and detached the tissue on the inner side. On making traction, the tumour came away, leaving a rough irregular piece of the jaw and a small portion of the tumour behind. These I subsequently extracted, including the condyle and coronoid process, which latter broke off and was removed separately. The internal maxillary artery was not wounded, and there was no great hæmorrhage, four ligatures being applied and cut short. The lip was brought together with two hare-lip pins, and the remainder of the wound closed by wire sutures, a silk suture being put in the red of the lip. Collodion was painted over all. No further dressing was applied. The child rallied, and took some brandy-and-water. In the afternoon she was quite comfortable and the pulse was good. There was a little oozing from the wound. In the evening she had had some sleep, and had taken a little soup. She drank water frequently. There was no bleeding. The tumour proved to be of soft consistence, and had destroyed all the body of the jaw, and a portion of the ramus; the condyle, coronoid process, and upper portion of the ramus being healthy. The point of section of the bone was healthy, and close to it were the canine and first temporary molar. In the upper and posterior part of the growth was the crown of the second permanent molar, carried quite out of position. To the naked eye the tumour presented a loose fibroid appearance. Mr. Bruce kindly examined a portion microscopically for me, and reported numerous fibres, with here and there development of cells, seemingly medullary.

Sept. 11.—She had had a comfortable night. The mouth syringed out with Condy's fluid three times. The child took some milk and soup, and was quite comfortable all day.

13.—Child quite comfortable and happy, and takes liquid food well. I removed the hare-lip pins.

14.—I removed the sutures. The wound was healed except at the junction of the vertical with the horizontal incision,



where there is a minute opening. The patient to be dressed and get up to-morrow.

23.—She went home to the country quite well, with the exception of one spot at the angle of the cicatrix, which still discharged slightly.

Oct. 21.—I heard that she was quite well.

26.—The child was brought to town on account of a return of the growth. The mother says she first noticed something wrong on the 22nd, when there was a small lump in the mouth. This grew very rapidly, and Mr. Mumford advised her coming up at once.

I found a mass within the mouth on the right side, nearly as large, and of precisely the same appearance, as the former growth. It involved a portion of the jaw left, and extended to the canine tooth on the left side, the incisors being loose. The cicatrix was sound except at the junction of the vertical with the horizontal incision, where the skin was ulcerated and there was a fungous protrusion of the size of a cherry. I explained the serious nature of the case to the parents, and said that an immediate operation was the only hope, as, if left, the growth would rapidly fungate and destroy the child, and they consented to the operation proposed.

On Oct. 27, 1867, I divided the lip and opened up the old cicatrix to a great extent, surrounding, however, the portion involved in the fungus. I then dissected back the flap, and found the growth extended to what would have been half way up the ramus. I isolated it, and then dissected back the left half of the lip. I next removed the first molar, and sawed the jaw close in front of the second molar. Having put a string in the tongue for safety, I then divided the sublingual muscles, and got the growth and piece of jaw away entire. Two or three large vessels were tied, principally under the tongue, and a few small ones. I washed the entire wound carefully with a solution of chloride of zinc (forty grains to the ounce), brought the lip together with two hare-lip pins, and the remainder of the wound with sutures, and then fastened the string attached to the tongue to the upper pin in the lip. The child bore the operation very well. In the evening she was cold and restless, but rallied with the use of hot bottles and a little brandy.

Oct. 28.—Patient had had a good night, and was asleep when I saw her at nine o'clock, and warm and comfortable. She passed a quiet day, taking a good deal of milk and a



little wine. She was a little distressed by the ligature in the tongue.

31.—I removed the hare-lip pins and three of the stitches, leaving those near the angle of the wound for the present. A little pus was pent up in the upper part of the old cicatrix, which I evacuated.

Nov. 1.—I removed the remaining stitches. The wound was healing well, except at the point where the skin was implicated and removed, and there it gaped.

3.—The child was up and dressed. She was able to close her lips and move her tongue very satisfactorily. She takes her food fairly, and has sucked a chicken-bone.

She continued to improve rapidly, and by the 10th, when she returned to the country, the wound was perfectly healed with the exception of a small spot where the portion of skin had been removed. She had perfect control over her tongue and lips, and could move the tissues of the chin very satisfactorily. There was no appearance of any return of the growth at this date.

Dec. 16.—I heard from the father that the child was perfectly well, and that there was no appearance of return of the growth. He sent me her photograph, from which fig. 174 was taken, to show how little deformity resulted from the double operation.

On Jan. 8, 1868, I heard from Mr. Mumford that the disease had reappeared at the symphysis, and also in the masseteric region on both sides, there being loss of appetite, exhaustion, and general irritability of system. The poor little patient lingered for a month, and died on Feb. 9, just five months after I first saw her.

CASE XV.—*Epithelioma of the Tongue, involving the Lower Jaw—Removal of the Growth and three inches of the Lower Jaw—Recovery.* Under the care of the AUTHOR.

E. J., aged fifty-two, was admitted Sept. 21, 1875. He was unable to move his tongue, and saliva trickled down his chin; articulation was very indistinct; he was quite unable to chew, but could swallow fluids readily; the breath was very offensive. The front teeth of both jaws were worn down and decayed, and all the teeth in the lower jaw were very loose. The gums on the left side of the lower jaw were swollen, thickened, and irregular, the surface being covered with firm, solid granulations; this tissue extended



between the teeth, into the floor of the mouth, and to the tip of the tongue, which was fixed to the lower jaw, being blended with this growth on the gums. The growth in the gums did not extend beyond the middle line. Under the right angle of the jaw there was one enlarged hard gland; on the left side there was a mass of hard tender glands. The patient complained of pain in the lower jaw, and of a very severe shooting pain and tenderness in the occipital region. This latter pain was so severe as to make him writhe in great agony at times. The patient was thin, looked worn out with pain, and expressed himself willing to undergo any operation for relief. The history he gave was that in January, 1874, he noticed one of the glands, under the jaw on the right side become tender and swollen, and a few days after a sore appeared under the left side of the tongue, which soon went away; he also had an ulcerated throat at this time. The gland was painted with iodine, and became considerably smaller and ceased to trouble him, but in September following it swelled again and broke, discharging pus. About this time (twelve months before admission) he noticed difficulty in articulation, his tongue being stiff; this rapidly got worse, and at Easter, 1875, his tongue was quite fixed to the jaw. He then went into St. Bartholomew's Hospital, where a part of the tongue was removed, which greatly relieved him for a time, but he soon began to get worse again, and then was sent into University College Hospital. He stated that he had been a great smoker, generally using a clay pipe. He had been quite unable to take solid food for a year before admission. No history of syphilis, tubercle, or cancer. He was ordered spoon diet, four eggs, and four ounces of brandy. Hypodermic injections of morphia were given for relief of pain.

On September 29 Mr. Heath proceeded to operate. The patient was placed under chloroform, and the incisor canine, and first bicuspid teeth were extracted; two pairs of clamp forceps were applied to the under lip about three inches apart, so as to compress the coronary vessels, and a vertical incision along the middle line was made down the lip and continued to the hyoid bone; the healthy integuments were dissected back from the jaw on each side, and the bone was sawn through on each side an inch and a half from the symphysis. The wire of the galvanic *écraseur* was then applied round the mass thus loosened, which was drawn forwards by *vulsellum* forceps, and included nearly the whole of the tongue and all the sublingual tissues. For eight



minutes a low current was passed, which was then increased a little, the whole process occupying twelve minutes. A piece of whipcord was passed through the stump of the tongue, which was gently drawn forwards and sponged with perchloride of iron. The edges of the wound were then brought together by three hare-lip sutures, and a fine silk thread through the mucous membrane. The lower part of the wound was left open to serve as a drain; the whipcord ligature was fastened to one of the pins to prevent the tongue falling back. A hypodermic injection of one-quarter of a grain of morphia was given, and the patient was then carried back to bed.

The patient passed a good night, sleeping a great deal. At 4 A.M. and at 7.30 A.M., an enema of egg, beef-tea, and brandy was administered. A good deal of saliva and blood-stained serum escaped through the opening into the floor of the mouth. Next morning the temperature was  $99^{\circ}$ ; pulse 72, regular, and fairly strong; he said that the pain at the back of the head was less. He was fed through a catheter passed into the œsophagus every two hours during the day, and had two nutrient enemata at night, but afterwards he was fed only every four hours, taking six ounces of brandy in the twenty-four hours. He complained of a painful swelling under each angle of the jaw.

On October 1 a swelling as large as half an orange was noticed over the manubrium; it pitted on pressure, had a distinct edge, not tender, and was movable over the bone. The tongue was unfastened from the lip, but the whipcord was left in the tongue for a few days longer, to enable the patient to draw it forward when he was fed and whenever he felt a choking, which usually came on when he lay down. At night, as he was found to be weaker, brandy was increased to nine ounces. On Oct 3 the two upper pins were removed from the lip, and strapping applied across the jaw and lip. The stump of the tongue was covered by a black eschar, and on the tonsils and anterior pillars of the palate was a white exudation. There was a free discharge of saliva and turbid foul-smelling fluid through the drain under the chin; the patient wore an oakum bib to catch this. There was considerable swelling on each side of the neck below the jaw, and the swelling was tender and very painful. The mouth was washed out with Condy's fluid several times a day, and the sloughs painted with glycerine of carbolic acid. Next day the lowest pin was removed, and the incision in the lip



was found to be entirely healed, except at the lowest part, which was purposely left open.

Oct. 4.—Temperature  $98.5^{\circ}$ ; pulse 80, much stronger. The swelling over the sternum had almost entirely disappeared. The pain in the head was as bad as ever.

For the next week the patient slowly improved; the slough and exudation cleared off the tongue and mouth; the swelling in the neck gradually subsided and became less, as did also the pain in the head; the temperature was not above the normal. As the Condy's fluid failed to keep the mouth sweet, it was syringed out with a dilute solution of terebene, which was followed by a most marked improvement in this respect. After the 4th the nutrient enemata were discontinued.

On Oct. 11 it is noted that he was better, with less pain in throat and head, and that he looked more cheerful; the whole of the stump of the tongue was free from slough; a little slough was still adherent to the surfaces of the bone; the ends of the bone had approximated a good deal, and on the 15th were only half an inch apart. After Oct. 16 the pain in the head disappeared, and only very occasionally returned slightly; he began to pick up his strength fast, slept well, was cheerful, but complained of pain behind the thyroid cartilage when the catheter was passed; pressure over the thyroid also gave pain, and a hard tender lump under each angle of the jaw troubled him. He had poultices applied to these on Oct. 20, which relieved him very much, so that on the 26th it was noted that no lump was to be felt on either side, and that he was quite free from pain except in the pharynx. On Oct. 29 the two pieces of the jaw were in contact, though not united; there was still slight discharge through the opening into the mouth, but this healed up by Nov. 4.

On Nov. 8 the patient was sent to Eastbourne, and returned to London on Dec. 11, when he was seen at the hospital. He was very cheerful, and very pleased with the result of the operation. He was able to drink out of a feeder, and swallow without difficulty. The two pieces of the jaw were in close contact, and only very slight movement could be obtained between them. Patient could make himself understood, though his articulation was very indistinct. The chin was behind the upper jaw, but the disfigurement was not very conspicuous. There was no recurrence of the growth, and no enlarged glands under the jaw. He had had no return of the occipital pain.



The growth was examined by Mr. Gould, and found to be undoubted epithelioma, cylindrical processes of large oval fleshy epithelial cells being seen, without any of the ordinary concentric "globes" of cells, though in the above-described cylinders a concentric arrangement of some of the cells in the middle, approaching that of the "globes," was found. This tissue was found under the tongue, just extending up into it; in the gums, and extending back quite to the line of removal. This patient was perfectly well in Nov. 1883.

CASE XVI.—*Epithelioma involving the Chin and Lower Jaw—Removal of Growth by section of bone and galvanic écraseur, without opening the mouth—Recovery.* Under the care of the AUTHOR.

T. E., aged fifty-five, a fisherman, admitted Nov. 6, 1875. In February, 1872, he had an epitheliomatous growth on the lower lip removed at the Monmouth Hospital, and he recovered completely from the operation. But twelve months ago—November, 1874—he noticed a small hard lump under the lower jaw, to the left of the symphysis; this lump gradually increased in size, and in August, 1875, it ulcerated at one spot; poultices were then applied, but more ulcers appeared. From that time the growth rapidly increased, and was the seat of constant pain.

On admission, the patient was a dark, healthy-looking, strong man, though he stated that he had lost flesh lately. There was a rounded tumour fixed to the left side of the body of the lower jaw, about the size of a small cocoa-nut, measuring six inches by five and a half, extending two and a half inches to the right and three and a half inches to the left of the middle line, reaching down to the hyoid bone. Most of the skin over the tumour was adherent to it, but it was free at the edge; the surface was lobulated, firm, and elastic; and on the under part there were six openings in the centre of projecting nodules, from which a stinking fluid escaped. There was a linear cicatrix on the left side of the lower lip. No part of the growth could be detected from the mouth; the alveolus of the jaw was not enlarged. There was no dyspnœa nor dysphagia.

Nov. 10.—The patient was put under the influence of chloroform, and Mr. Heath proceeded to remove the tumour. He first made a curved incision over the back of the tumour beyond the line where the skin was adherent, and dissected



this off the tumour quite readily. He then united the ends of this incision by a straight cut along the body of the jaw. The body of the jaw to which the tumour was attached was then sawn through below the alveolus, and without wounding the mucous membrane of the mouth. An additional piece of bone was then removed from the left angle of the jaw with the bone forceps. The galvanic *écraseur* was then applied in the lines of incision, and the mass removed in nine minutes. The tissue about the hyoid bone was white and opaque, and was therefore freely cauterized with the heated *écraseur*. The submaxillary and sublingual glands and the hyo-glossus muscles were freely exposed in the wound, and looked healthy. The wound was washed out with solution of zinc chloride, twenty grains to the ounce, and lint dipped in this was applied, and kept in place by cotton-wool and a bandage.

The patient slept well through the night, being perfectly free from pain, but only able to swallow liquids; the next morning his temperature was 100° F.; pulse 96. In the evening the lint was removed from the wound, and a dressing of carbolized oil applied. His temperature gradually fell, and on Nov. 15 it was 98·3°; pulse 84. The submaxillary gland and the tissue about the hyoid bone were seen to be sloughing; the upper part of the wound was granulating; complained of headache. The next two days an oakum fomentation was applied to hasten the separation of the sloughs, and on Nov. 18 the surface was quite clean except over the submaxillary gland, and the headache quite gone. On the 22nd the wound was dressed with red lotion; the last slough had come away; the wound was two-thirds its previous size. Patient could swallow solid food well. On the 26th five skin-grafts were put on. On Dec. 2 twelve more were put on; the granulation was much slower over the site of the submaxillary gland than elsewhere. On Dec. 8 the wound was about one-third the size it was originally; the granulations were pale and flabby, edges firm and rather callous; to be dressed with a solution of nitrate of silver, two grains to the ounce.

The wound continued to heal well, and the patient gained strength and lost all pain, which had not returned since the operation. There was no appearance of any recurrence of the growth several weeks after the operation. The patient went home on Dec. 23 with the wound nearly healed.

*Examination of Tumour* (by Mr. Gould).—"The tumour is



very firmly adherent to the section of the body of the jaw, but the bone looks healthy, the line of it being unbroken. On cutting into the under surface of the tumour, a cavity as large as an ordinary apple is opened, full of fetid ichorous fluid, with irregular walls in which are six sinuses. Examined microscopically, the growth is seen to be a typical example of globular epithelioma; this tissue extends quite to the lower edge of mass removed (by hyoid bone), but is half an inch from the surface in front (where attached to jaw)."

This, though a formidable-looking case, was a remarkably favourable one for operation, the disease, although extensive, involving none of the lymphatic glands at the angle of the jaw or in the neck. By sawing off the chin, without opening the mouth, the whole of the bony attachment of the growth was isolated, and the subsequent removal of the soft tissues down to the hyoid bone with the galvanic *écraseur* was entirely bloodless. The patient made a thoroughly good recovery, and it was hoped had been effectually relieved, at least for a long time.

The disease recurred and the patient died some months after.



# INDEX.

|  | PAGE      |
|--|-----------|
| ABSCCESS after fracture . . . . .                      | 20        |
| „ of jaw . . . . .                                     | 99        |
| „ of antrum . . . . .                                  | 159       |
| Adams, Mr. W., on cysts of antrum . . . . .            | 172       |
| „ Dr. R., on cysts of lower jaw . . . . .              | 199       |
| Alveolus, fracture of . . . . .                        | 1, 17, 56 |
| Amaurosis from diseased antrum . . . . .               | 148       |
| Ankylosis of temporo-maxillary joint . . . . .         | 413       |
| Antrum, diseases of . . . . .                          | 152       |
| „ suppuration in . . . . .                             | 159       |
| „ dropsy of . . . . .                                  | 168       |
| „ cysts of . . . . .                                   | 171       |
| „ epithelioma of . . . . .                             | 257       |
| „ polypus of . . . . .                                 | 174       |
| „ falling in of . . . . .                              | 177       |
| Articulation, temporo-maxillary, diseases of . . . . . | 412       |
| Author's case of fractured alveolus . . . . .          | 17        |
| „ „ necrosis of lower jaw . . . . .                    | 118, 128  |
| „ „ hyperostosis of jaw . . . . .                      | 149       |
| „ „ dentigerous cyst . . . . .                         | 192       |
| „ „ cystic sarcoma of lower jaw . . . . .              | 203, 210  |
| „ „ multilocular cystic tumour . . . . .               | 205, 207  |
| „ „ odontoma . . . . .                                 | 221       |
| „ „ hypertrophy of gums . . . . .                      | 230       |
| „ „ epulis . . . . .                                   | 241       |
| „ „ tumour of palate . . . . .                         | 249, 253  |
| „ „ epithelioma of gums . . . . .                      | 256       |
| „ „ „ antrum . . . . .                                 | 257       |
| „ „ fibroma of upper jaw . . . . .                     | 267       |
| „ „ enchondroma of upper jaw . . . . .                 | 269       |
| „ „ osteoma . . . . .                                  | 278       |
| „ „ round-cell sarcoma of upper jaw . . . . .          | 305       |
| „ „ epithelioma . . . . .                              | 309, 312  |
| „ „ ivory exostosis of lower jaw . . . . .             | 341       |
| „ „ spindle-cell sarcoma of lower jaw . . . . .        | 348       |
| „ „ myeloid of both sides . . . . .                    | 360       |
| „ „ chondro-sarcoma . . . . .                          | 362       |
| „ „ ossifying sarcoma . . . . .                        | 365       |
| „ „ medullary sarcoma . . . . .                        | 370       |



|  | PAGE     |
|--|----------|
| Author's case of epithelioma of lower jaw . . . . .                    | 372      |
| "    "    "    of chin . . . . .                                       | 375      |
| "    "    "    of gland adherent to jaw . . . . .                      | 377      |
| "    "    Esmarch's operation for closure . . . . .                    | 400, 401 |
| "    "    closure of jaws treated with shields . . . . .               | 409      |
| "    "    disease of temporo-maxillary joint . . . . .                 | 414      |
| "    "    hypertrophy of neck of condyle . . . . .                     | 420      |
| BEAN's interdental splint . . . . .                                    | 48       |
| Beaumont, Mr., enchondroma of lower jaw . . . . .                      | 333      |
| Boinet, M., post-mortem examination after Esmarch's operation. . . . . | 404      |
| Broca, M., on odontomata . . . . .                                     | 217      |
| Bryant, Mr., necrosis of inter-maxillary bones . . . . .               | 114      |
| Butcher, Mr., on cysts of lower jaw . . . . .                          | 211      |
| "    "    vascular tumour of upper jaw . . . . .                       | 298      |
| CANCER, osteoid, of upper jaw . . . . .                                | 300      |
| "    of upper jaw . . . . .  | 307      |
| "    of lower jaw . . . . .  | 372      |
| Cannon-ball, injury to jaws by . . . . .                               | 72, 80   |
| Canton, Mr., myeloid tumour of upper jaw . . . . .                     | 293      |
| Cap for fractured jaw . . . . .  | 43       |
| Caries of jaw . . . . .  | 108      |
| Cartilaginous tumours of upper jaw . . . . .                           | 268      |
| "    "    lower jaw . . . . .  | 334      |
| Cattlin, Mr., on the antrum . . . . .                                  | 152      |
| Chalk, Mr. O., deformity of jaw . . . . .                              | 429      |
| "    "    reproduction of teeth . . . . .                              | 113      |
| Chin, silver . . . . .   | 80       |
| Chondro-sarcoma of upper jaw . . . . .                                 | 300      |
| "    "    lower jaw . . . . .  | 361      |
| Closure of the jaws . . . . .  | 388      |
| Coates, Mr., myeloid tumour of upper jaw . . . . .                     | 296      |
| "    "    epithelioma of lower jaw . . . . .                           | 376      |
| Collis, Mr., enchondroma of upper jaw . . . . .                        | 276      |
| Complications of fractured jaw . . . . .                               | 15       |
| Condyle, fractured neck of . . . . .                                   | 12, 19   |
| Congenital dislocation . . . . .                                       | 93       |
| Cork wedges for fractured jaw . . . . .                                | 42       |
| Couper, Mr., case of old dislocation . . . . .                         | 91       |
| Craven, Mr., medullary sarcoma of upper jaw . . . . .                  | 303      |
| "    "    myeloid of lower jaw . . . . .                               | 359      |
| Curling, Mr., epithelioma of palate . . . . .                          | 251      |
| Cystic sarcoma . . . . .   | 202      |
| Cysts of antrum . . . . .  | 171      |
| "    of teeth . . . . .  | 178      |
| "    dentigerous . . . . .   | 183      |
| "    in lower jaw . . . . .  | 181      |
| "    multilocular of lower jaw . . . . .                               | 196      |
| DEFORMITIES of the jaws . . . . .                                      | 428      |
| Dentigerous cysts . . . . .  | 183      |
| Dentinal tumours . . . . .   | 217      |



|  | PAGE |
|--|------|
| Diagnosis of tumours of upper jaw . . . . .            | 314  |
| "                    lower jaw . . . . .               | 379  |
| Dislocation of teeth . . . . .                         | 16   |
| " with fracture . . . . .                              | 22   |
| " of jaw . . . . .                                     | 83   |
| " " symptoms of . . . . .                              | 88   |
| " " old standing . . . . .                             | 90   |
| " " rare forms . . . . .                               | 92   |
| " " congenital . . . . .                               | 93   |
| " " treatment of . . . . .                             | 93   |
| Dropsy of antrum . . . . .                             | 168  |
| Duka, Dr., case of ivory tumour of upper jaw . . . . . | 284  |
| ENCHONDROMA of upper jaw . . . . .                     | 268  |
| " lower jaw . . . . .                                  | 334  |
| Epithelioma of gums . . . . .                          | 254  |
| " of antrum . . . . .                                  | 257  |
| Epulis . . . . .                                       | 235  |
| " myeloid . . . . .                                    | 236  |
| " giant-celled . . . . .                               | 237  |
| " epitheliomatous . . . . .                            | 237  |
| " table of cases of . . . . .                          | 239  |
| " treatment of . . . . .                               | 244  |
| Esmarch, Professor, on closure of jaws . . . . .       | 393  |
| Extraction of teeth causing fracture . . . . .         | 2    |
| FALLING in of antrum . . . . .                         | 177  |
| False joint after fracture . . . . .                   | 25   |
| " treatment of . . . . .                               | 53   |
| Fearn, Mr., dentigerous cyst . . . . .                 | 188  |
| Fergusson, Sir W., case of hyperostosis . . . . .      | 146  |
| " case of hydrops antri . . . . .                      | 170  |
| " cysts in lower jaw . . . . .                         | 183  |
| " odontoma . . . . .                                   | 217  |
| " epithelioma . . . . .                                | 255  |
| " ivory tumour of upper jaw . . . . .                  | 280  |
| " myeloid tumour of lower jaw . . . . .                | 359  |
| Fibrous tumours of upper jaw . . . . .                 | 261  |
| " lower jaw . . . . .                                  | 327  |
| Forceps, Fergusson's . . . . .                         | 246  |
| " Liston's . . . . .                                   | 245  |
| " Stromeier's . . . . .                                | 95   |
| Forget, Dr., on dentigerous cysts . . . . .            | 189  |
| " on odontoma . . . . .                                | 218  |
| Four-tailed bandage . . . . .                          | 33   |
| Fracture of lower jaw . . . . .                        | 1    |
| " " museum specimens of . . . . .                      | 4    |
| " " symptoms of . . . . .                              | 8    |
| " ramus of lower jaw . . . . .                         | 11   |
| " neck of condyle of lower jaw . . . . .               | 12   |
| " coronoid process . . . . .                           | 14   |
| " of lower jaw, complications of . . . . .             | 15   |
| " teeth . . . . .                                      | 16   |



|  | PAGE   |
|--|--------|
| Fracture of alveolus . . . . .   | 17     |
| "    of glenoid cavity . . . . .                                       | 19     |
| "    of lower jaw, treatment of . . . . .                              | 33     |
| "    of upper jaw . . . . .  | 56     |
| "    complications of . . . . .  | 61     |
| GENSOUL on removal of upper jaw . . . . .                              | 316    |
| Giraldès, M., on cysts of antrum . . . . .                             | 171    |
| Goodwillie, Dr., on temporo-maxillary disease . . . . .                | 421    |
| Gracfe's apparatus for fractured upper jaw . . . . .                   | 64     |
| Gross, Dr., on closure of jaws . . . . .                               | 391    |
| Growths within antrum . . . . .  | 174    |
| Gums, diseases of . . . . .  | 227    |
| "    epithelioma of . . . . .  | 254    |
| "    hypertrophy of . . . . .  | 227    |
| "    polypus of . . . . .  | 232    |
| "    papilloma of . . . . .  | 234    |
| Gunning's interdental splints . . . . .                                | 44     |
| Gunshot injuries of jaws . . . . .                                     | 66     |
| Gutta-percha splint . . . . .  | 34     |
| "    wedges for fracture . . . . .                                     | 42     |
| HÆMORRHAGE after fracture . . . . .                                    | 15, 62 |
| Hamilton's sling for fracture. . . . .                                 | 35     |
| Hammond's wire-splint . . . . .  | 36     |
| Harrison, Mr., odontoma . . . . .                                      | 220    |
| "    "    deformity of jaws . . . . .                                  | 431    |
| Hart, Mr., necrosis of upper jaw . . . . .                             | 117    |
| Hayward, Mr., cap for teeth. . . . .                                   | 43     |
| Hepburn, Mr., case of angular union . . . . .                          | 21     |
| Hill, Mr. B., modification of Lonsdale's splint . . . . .              | 51     |
| Hilton, Mr., ivory tumour of upper jaw . . . . .                       | 279    |
| Holt, Mr., recurrent fibroid of lower jaw . . . . .                    | 352    |
| "    closure of jaws . . . . .   | 406    |
| Humphry, Dr., prolapse of tongue, producing deformity of jaw . . . . . | 428    |
| Hydrops antri . . . . .  | 168    |
| Hyperostosis . . . . .   | 142    |
| Hypertrophy of gums . . . . .  | 227    |
| "    neck and condyle . . . . .  | 418    |
| INFLAMMATION . . . . .   | 98     |
| Interdental splint (Gunning's) . . . . .                               | 44     |
| "    "    (Bea's) . . . . .  | 48     |
| Irregular union after fracture . . . . .                               | 24     |
| Ivory tumour of upper jaw . . . . .                                    | 279    |
| "    "    lower jaw . . . . .  | 340    |
| JAWS, gunshot injuries of . . . . .                                    | 66     |
| "    inflammation of . . . . .   | 98     |
| "    abscess of . . . . .  | 99     |
| "    periostitis of . . . . .  | 106    |
| "    caries of . . . . .   | 108    |
| "    necrosis of . . . . .   | 110    |



|   | PAGE |
|---|------|
| Jaws, necrosis of, exanthematous . . . . .            | 114  |
| "      "      syphilitic . . . . .                    | 120  |
| "      "      phosphorus . . . . .                    | 122  |
| "      deformities of . . . . .                       | 428  |
| Jaw, upper, fractures of . . . . .                    | 56   |
| "      "      treatment of . . . . .                  | 62   |
| "      tumours of . . . . .                           | 260  |
| "      fibrous . . . . .                              | 261  |
| "      cartilaginous . . . . .                        | 268  |
| "      osseous . . . . .                              | 277  |
| "      spindle-cell sarcoma . . . . .                 | 287  |
| "      recurrent fibroid . . . . .                    | 290  |
| "      myeloid sarcoma . . . . .                      | 292  |
| "      vascular . . . . .                             | 297  |
| "      chondro-sarcoma . . . . .                      | 300  |
| "      ossifying sarcoma . . . . .                    | 300  |
| "      round-celled sarcoma . . . . .                 | 302  |
| "      epithelioma . . . . .                          | 307  |
| "      diagnosis of . . . . .                         | 314  |
| "      prognosis of . . . . .                         | 315  |
| "      operations on . . . . .                        | 315  |
| Jaw, lower, fractures of . . . . .                    | 1    |
| "      "      treatment of . . . . .                  | 33   |
| "      "      suture of . . . . .                     | 39   |
| "      dislocation of . . . . .                       | 83   |
| "      cysts in . . . . .                             | 181  |
| "      tumours of . . . . .                           | 327  |
| "      fibrous . . . . .                              | 327  |
| "      cartilaginous . . . . .                        | 334  |
| "      osseous . . . . .                              | 340  |
| "      spindle-celled sarcoma . . . . .               | 344  |
| "      recurrent fibroid . . . . .                    | 352  |
| "      myeloid sarcoma . . . . .                      | 357  |
| "      chondro-sarcoma . . . . .                      | 361  |
| "      ossifying sarcoma . . . . .                    | 364  |
| "      round-celled sarcoma . . . . .                 | 369  |
| "      epithelioma . . . . .                          | 372  |
| "      diagnosis of . . . . .                         | 379  |
| "      operations on . . . . .                        | 380  |
| LAWSON, Mr., recurrent fibroid of upper jaw . . . . . | 291  |
| "      "      "      lower jaw . . . . .              | 354  |
| "      "      enchondroma of lower jaw . . . . .      | 337  |
| Ligature of teeth . . . . .                           | 35   |
| Liston, Mr., case of large epulis . . . . .           | 242  |
| "      fibrous tumours of upper jaw . . . . .         | 262  |
| Lonsdale's splint . . . . .                           | 50   |
| Lower jaw, fracture of . . . . .                      | 1    |
| "      dislocation of . . . . .                       | 83   |
| "      tumours of ( <i>see</i> Tumours)               |      |
| MACGILLIVRAY, Mr., hypertrophy of gum . . . . .       | 229  |
| Maisonneuve on dislocation . . . . .                  | 85   |



|   | PAGE     |
|---|----------|
| Margetson, Mr., case of fracture and dislocation of tooth . . . . . | 17       |
| Medullary tumour of upper jaw . . . . .                             | 302      |
| "                    lower jaw . . . . .                            | 369      |
| Moon, Mr., splint for fracture . . . . .                            | 52       |
| Multilocular cysts of lower jaw . . . . .                           | 196      |
| "                    cystic tumour . . . . .                        | 205      |
| Myeloid epulis . . . . .  | 236      |
| "          sarcoma of upper jaw . . . . .                           | 292      |
| "          "          lower jaw . . . . .                           | 357      |
| NECK of condyle fractured . . . . .                                 | 12, 19   |
| Necrosis of jaw . . . . .   | 110      |
| "          exanthematous . . . . .                                  | 114      |
| "          syphilitic . . . . .                                     | 120      |
| "          phosphorus . . . . .                                     | 122      |
| "          symptoms of . . . . .                                    | 124      |
| "          repair after . . . . .                                   | 127      |
| "          treatment of . . . . .                                   | 137      |
| "          after fracture . . . . .                                 | 20       |
| "          "          of symphysis . . . . .                        | 22       |
| Nélaton, on dislocation. . . . .                                    | 86, 95   |
| Neuralgia after fracture . . . . .                                  | 17, 62   |
| Nicholson, Mr., necrosis of alveolus . . . . .                      | 112      |
| Non-union of fracture . . . . .                                     | 25       |
| ODONTOMATA . . . . .  | 217      |
| Old-standing dislocations . . . . .                                 | 90       |
| Operations on upper jaw . . . . .                                   | 315      |
| "          lower jaw . . . . .                                      | 380      |
| Ossifying sarcoma . . . . .   | 300, 364 |
| Osteoma of upper jaw . . . . .                                      | 277      |
| "          lower jaw . . . . .                                      | 340      |
| PAGET, Sir J., polypus of antrum . . . . .                          | 175      |
| Palate, tumours of the . . . . .                                    | 248      |
| Paralysis of dental nerve . . . . .                                 | 17, 62   |
| Periostitis of jaw . . . . .  | 106      |
| Permanent closure of jaws . . . . .                                 | 390      |
| Phosphorus-necrosis . . . . .                                       | 122      |
| Polypus of antrum . . . . .   | 174      |
| RAMUS of lower jaw fractured . . . . .                              | 11       |
| Recurring-fibroid of upper jaw . . . . .                            | 290      |
| "          "          lower jaw . . . . .                           | 352      |
| Repair after necrosis . . . . .                                     | 127      |
| Rheumatoid arthritis, temporo-maxillary . . . . .                   | 415      |
| Rizzoli, on closure of jaws . . . . .                               | 397      |
| SALIVARY fistula after fracture . . . . .                           | 20       |
| Salter, Mr., case of fractured upper jaw . . . . .                  | 56       |
| "          on exanthematous necrosis . . . . .                      | 114      |
| "          on dentigerous cysts . . . . .                           | 185      |
| "          on odontomata . . . . .                                  | 223      |



|   | PAGE          |
|---|---------------|
| Salter, Mr., on hypertrophy of gum . . . . .                  | 227           |
| "    on papilloma of gum . . . . .                            | 234           |
| Savory, Mr., on repair after phosphorus-necrosis . . . . .    | 128           |
| Shillito, Mr. B., fibrous tumour of lower jaw . . . . .       | 330           |
| Smith, Mr. Cox, case of gunshot injury of upper jaw . . . . . | 70            |
| "    "    case of injury to symphysis . . . . .               | 77            |
| "    Prof. R. W., on dislocation . . . . .                    | 89            |
| "    Mr. T., on phosphorus-necrosis . . . . .                 | 130           |
| Spasmodic closure of jaws . . . . .                           | 388           |
| Specimens of fractured jaw . . . . .                          | 4             |
| Splint, interdental (Gunning's) . . . . .                     | 44            |
| "    "    (Beau's) . . . . .                                  | 48            |
| "    Lonsdale's . . . . .                                     | 50            |
| "    "    Hill's modification . . . . .                       | 51            |
| "    for lower jaw . . . . .                                  | 34            |
| Square, Mr., enchondroma of upper jaw . . . . .               | 275           |
| Stromeyer's forceps . . . . .                                 | 95            |
| Sub-luxation of jaw . . . . .                                 | 415           |
| Sub-periosteal resection . . . . .                            | 139           |
| Suppuration in antrum . . . . .                               | 159           |
| Suture of lower jaw . . . . .                                 | 38            |
| Syme, Mr., tumour of hard palate . . . . .                    | 248           |
| "    "    osteo-sarcoma of lower jaw . . . . .                | 348           |
| Symphysis, necrosis of . . . . .                              | 22            |
| Symptoms of fractured jaw . . . . .                           | 8             |
| Syphilitic necrosis . . . . .                                 | 120           |
| <br>TAY, Mr. W., necrosis of lower jaw . . . . .              | <br>115       |
| Teeth, fracture of . . . . .                                  | 16            |
| "    dislocation of . . . . .                                 | 16            |
| "    ligature of . . . . .                                    | 35            |
| "    tumours connected with . . . . .                         | 214           |
| Temporo-maxillary articulation, diseases of . . . . .         | 412           |
| Thomas's wire-suture . . . . .                                | 39            |
| Tomes, Mr., on hypertrophy of gums . . . . .                  | 231           |
| "    "    dentigerous cysts . . . . .                         | 186           |
| "    "    odontomata . . . . .                                | 217, 222, 225 |
| Treatment of fractures of lower jaw . . . . .                 | 33            |
| "    "    upper jaw . . . . .                                 | 62            |
| Tumours connected with teeth . . . . .                        | 214           |
| "    papillary, of gum . . . . .                              | 234           |
| "    of palate . . . . .                                      | 248           |
| "    of upper jaw . . . . .                                   | 260           |
| "    "    fibrous . . . . .                                   | 261           |
| "    "    cartilaginous . . . . .                             | 268           |
| "    "    osseous . . . . .                                   | 277           |
| "    "    spindle-celled sarcoma . . . . .                    | 287           |
| "    "    recurrent-fibroid . . . . .                         | 290           |
| "    "    myeloid . . . . .                                   | 292           |
| "    "    vascular . . . . .                                  | 297           |
| "    "    malignant . . . . .                                 | 302           |
| "    "    diagnosis of . . . . .                              | 314           |
| "    "    treatment of . . . . .                              | 315           |




|  | PAGE |
|--|------|
| Tumours of lower jaw . . . . .                                       | 327  |
| "    "    cystic-sarcomatous . . . . .                               | 202  |
| "    "    fibrous . . . . .  | 327  |
| "    "    cartilaginous . . . . .                                    | 334  |
| "    "    osseous . . . . .  | 340  |
| "    "    spindle-celled sarcoma . . . . .                           | 344  |
| "    "    recurrent-fibroid. . . . .                                 | 352  |
| "    "    myeloid . . . . .  | 357  |
| "    "    malignant. . . . .   | 369  |
| "    "    diagnosis of . . . . .                                     | 379  |
| "    "    treatment of . . . . .                                     | 380  |
| UNION of fracture after necrosis . . . . .                           | 21   |
| "    irregular, of fractured lower jaw . . . . .                     | 24   |
| United States' Army Museum, specimens of gunshot injury in . . . . . | 76   |
| Ununited fracture of lower jaw . . . . .                             | 25   |
| "    "    treatment of . . . . .                                     | 53   |
| Upper jaw, fractures of . . . . .                                    | 56   |
| "    tumours of ( <i>see</i> Tumours)                                |      |
| VASCULAR tumours of upper jaw . . . . .                              | 297  |
| Vasey, Mr., deformity of jaw . . . . .                               | 430  |
| Verneuil, M., on closure of jaws . . . . .                           | 400  |
| WARREN, Dr. Mason, on cysts of lower jaw . . . . .                   | 211  |
| Weiss, Mr. F., closure by cicatrix . . . . .                         | 405  |
| Wells, Sir S., fibrous tumour of lower jaw . . . . .                 | 328  |
| Wheelhouse's method of wiring jaw . . . . .                          | 40   |
| Wilkes, Mr., epithelioma of lower jaw . . . . .                      | 376  |
| Wire splint, Hammond's . . . . .                                     | 36   |
| Wiring lower jaw . . . . .   | 39   |
| Wounds of the face . . . . .   | 15   |
| <hr/>  |      |
| APPENDIX OF CASES . . . . .  | 434  |


THE END.

12





















RD526

H35

1884

Heath

COLUMBIA UNIVERSITY LIBRARIES (hsl, stx)

**RD 526 H35 1884 C.1**

Injuries and diseases of the jaws.



2002242915



