

Injuries and diseases of the jaws : the Jacksonian prize essay of the Royal College of Surgeons of England, 1867 / By Christopher Heath, edited by Henry Percy Dean.

Contributors

Heath, Christopher, 1835-1905.
Dean, Henry Percy.
Augustus Long Health Sciences Library

Publication/Creation

Philadelphia : P. Blakiston, Son, 1894.

Persistent URL

<https://wellcomecollection.org/works/w9rzcavu>

License and attribution

This material has been provided by This material has been provided by the Augustus C. Long Health Sciences Library at Columbia University and Columbia University Libraries/Information Services, through the Medical Heritage Library. The original may be consulted at the the Augustus C. Long Health Sciences Library at Columbia University and Columbia University. where the originals may be consulted.

This work has been identified as being free of known restrictions under copyright law, including all related and neighbouring rights and is being made available under the Creative Commons, Public Domain Mark.

You can copy, modify, distribute and perform the work, even for commercial purposes, without asking permission.



Wellcome Collection
183 Euston Road
London NW1 2BE UK
T +44 (0)20 7611 8722
E library@wellcomecollection.org
<https://wellcomecollection.org>

COLUMBIA LIBRARIES OFFSITE
HEALTH SCIENCES STANDARD



HX64063658

RD526 H35 1894 Injuries and disease

RECAP

RD 52.6 H35

Columbia University
in the City of New York


1894

School of Dental and Oral Surgery



Reference Library

B. A. Burns
W. A. D. "92"
W. A. D. "92"
W. A. D. "92"



INJURIES AND DISEASES
OF
THE JAWS

BY THE SAME AUTHOR.

A Course of Operative Surgery. With 20 Plates drawn from Nature, by M. LÉVEILLÉ, Coloured. Second Edition, large 8vo.

Practical Anatomy: A Manual of Dissections. With 329 Wood Engravings. Eighth Edition, edited by WILLIAM ANDERSON, F.R.C.S., 8vo.

A Manual of Minor Surgery and Bandaging, for the Use of House-Surgeons, Dressers, and Junior Practitioners. With 158 Engravings. Tenth Edition. 8vo.

The Student's Guide to Surgical Diagnosis. Second Edition. 8vo.

Clinical Lectures on Surgical Subjects. 8vo.

INJURIES AND DISEASES
OF
THE JAWS

THE JACKSONIAN PRIZE ESSAY OF THE ROYAL COLLEGE
OF SURGEONS OF ENGLAND, 1867.

BY
CHRISTOPHER HEATH, F.R.C.S.,
HOLME PROFESSOR OF CLINICAL SURGERY IN UNIVERSITY COLLEGE, LONDON, AND
SURGEON TO UNIVERSITY COLLEGE HOSPITAL; CONSULTING
SURGEON TO THE DENTAL HOSPITAL.

FOURTH EDITION.
WITH NUMEROUS WOOD ENGRAVINGS.

EDITED BY
HENRY PERCY DEAN, M.S., F.R.C.S.,
ASSISTANT SURGEON TO THE LONDON HOSPITAL;
SURGEON TO THE NORTH-EASTERN HOSPITAL FOR CHILDREN

PHILADELPHIA:
P. BLAKISTON, SON & CO.
1012 WALNUT STREET.
1894.

[All rights of Translation and Reproduction are reserved.]

RD 526
H35
1894

PREFACE TO THE FOURTH EDITION.

IN preparing a fourth edition of this book I have been able to avail myself of the able assistance of Mr. Percy Dean, a former distinguished student of University College, and now Assistant-Surgeon to the London Hospital. Mr. Dean has had occasion to modify the arrangement of some of the material so as to bring it into more correct relation with modern pathology, whilst I have exercised a general supervision, and have endeavoured to incorporate the experience of another ten years of active professional life.


CHRISTOPHER HEATH.

36 CAVENDISH SQUARE,

February 1894.

TABLE OF CONTENTS.

CHAP.	PAGES
I. FRACTURE OF THE LOWER JAW	1— 8
II. COMPLICATIONS OF FRACTURE OF THE LOWER JAW	9— 25
III. TREATMENT OF FRACTURED LOWER JAW	26— 42
IV. FRACTURE OF THE UPPER JAW	43— 52
V. GUNSHOT INJURIES OF THE JAWS	53— 71
VI. DISLOCATION OF THE LOWER JAW	72— 88
VII. INFLAMMATORY DISEASES, PERIOSTITIS, AND ABSCESS	89—102
VIII. NECROSIS OF THE JAWS	103—117
IX. REPAIR AFTER NECROSIS; TREATMENT	118—129
X. HYPEROSTOSIS	130—140
XI. DISEASES OF THE ANTRUM	141—169
XII. CYSTS OF THE JAWS; DENTAL CYSTS; DENTIGEROUS CYSTS	170—209
XIII. ODONTOMATA AND CERTAIN IRREGULARITIES OF THE TEETH	210—225
XIV. DISEASES OF THE GUMS; EPULIS	226—248
XV. TUMOURS OF THE PALATE	249—256
XVI. NON-MALIGNANT TUMOURS OF THE UPPER JAW	257—280
XVII. MALIGNANT TUMOURS OF THE UPPER JAW	281—302
XVIII. DIAGNOSIS AND TREATMENT OF TUMOURS OF THE UPPER JAW	303—315
XIX. NON-MALIGNANT TUMOURS OF THE LOWER JAW	316—329
XX. MALIGNANT TUMOURS OF THE LOWER JAW	330—359
XXI. DIAGNOSIS AND TREATMENT OF TUMOURS OF THE LOWER JAW	360—369
XXII. PARASITIC DISEASES OF THE JAWS	370—374
XXIII. DISEASES OF THE TEMPORO-MAXILLARY ARTICULATION	375—388
XXIV. CLOSURE OF THE JAW	389—414
XXV. DEFORMITIES OF THE JAWS	415—420



ILLUSTRATIONS.

FIG.		PAGE
1.	Fracture with overlapping after <i>Malgaigne</i>	4
2.	" with displacement "	5
3.	" of condyles and coronoid process . . . <i>Fergusson</i>	7
4.	Fracture united at an angle, from St. George's Hospital Museum <i>Original</i>	15
5.	" " (Hepburn) "	15
6.	" " " " " " " " " " " "	15
7.	Displacement with fibrous union after <i>Malgaigne</i>	18
8.	Ununited fracture after gunshot injury . . . <i>Cox Smith</i>	22
9.	" " " " " " " " " " " "	22
10.	Fibrous union, from "University College" Museum . . . <i>Original</i>	24
11.	Four-tailed bandage for lower jaw "	27
12.	Hamilton's apparatus after <i>Hamilton</i>	27
13.	Gutta-percha splint <i>Erichsen</i>	28
14.	" " " " " " " " " " " "	28
15.	Hammond's wire splint <i>Original</i>	29
16.	" " " " " " " " " " " "	30
17.	Model showing displacement of fragments . . . <i>Newland-Pedley</i>	31
18.	The same reduced with Hammond's splint . . . "	31
19.	Gunning's interdental splint <i>Gunning</i>	33
20.	" " " " " " " " " " " "	34
21.	" " " " " " " " " " " "	35
22.	Angle's method of acting on the teeth . . . <i>Angle</i>	35
23.	" " " " " " " " " " " "	36
24.	" " " " " " " " " " " "	37
25.	Hayward's mouth-piece <i>B. Hill</i>	38
26.	Lonsdale's apparatus "	39
27.	Thomas's wire-suture <i>Erichsen</i>	41
28.	" " " " " " " " " " " "	41
29.	Fracture of upper jaw <i>Salter</i>	44
30.	Plate for ditto "	45
31.	Gunshot injury of jaw <i>Debout</i>	62
32.	Silver chin "	63
33.	Dissection after loss of jaw "	63
34.	Gunshot injury of face "	65
35.	Dislocation of lower jaw <i>Astley Cooper</i>	74
36.	" " " " " " " " " " " "	76
37.	Dissection of dislocation of lower jaw . . . <i>Original</i>	77
38.	Dislocation of lower jaw <i>Fergusson</i>	78
39.	" " " " " " " " " " " "	79
40.	" " " " " " " " " " " "	81
41.	Stromeyer's forceps after <i>Goffres</i>	86
42.	Necrosis of intermaxillary bones <i>Bryant</i>	113

FIG.			PAGE
102.	Epulis, myeloid (Hutchinson)	Original	236
103.	" giant-celled (Wilkes)	"	236
104.	" (Author)	"	238
105.	" "	"	239
106.	" case of Mary Griffiths	Liston	240
107.	" "	"	241
108.	Cross-cutting forceps	"	243
109.	" "	"	243
110.	Bone-forceps	Fergusson	244
111.	" "	"	244
112.	Epithelioma of gum	"	246
113.	Sarcoma of hard palate (Author)	Original	253
114.	Fibrous tumours of upper jaw	Liston	259
115.	Ann Struther before operation	"	260
116.	" " after operation	"	260
117.	Mrs. Frazer	"	261
118.	Large recurrent enchondroma (Author)	Original	267
119.	Osseous tumour (Dupuytren)	after V. de Cassis	273
120.	" "	"	273
121.	" " (Fergusson)	Original	275
122.	" " (Duka)	Pathological Society	278
123.	Myeloid of upper jaw	Canton	283
124.	Round-celled sarcoma (Craven)	Original	294
125.	" " "	"	296
126.	Double round-celled sarcoma (Author)	"	297
127.	Round-celled sarcoma of both jaws	"	298
128.	Epithelioma of antrum	"	301
129.	Incisions for removal of upper jaw	Liston	307
130.	" " "	Original	308
131.	Saw for jaw	Fergusson	309
132.	Lion forceps	"	309
133.	Second stage of removal of upper jaw	Original	310
134.	Third stage	"	310
135.	Patient after removal of jaw and eyeball (Author)	"	314
136.	Fibrous tumour of lower jaw (University College)	"	317
137.	" " between plates (King's College)	"	318
138.	Large fibrous tumour of lower jaw (Fergusson)	"	320
139.	Upper jaw of same patient	"	321
140.	Recurrent enchondroma of lower jaw	Lawson	325
141.	" "	"	326
142.	Ivory exostosis of lower jaw (South)	Original	327
143.	" " (Author)	"	328
144.	Myeloid tumour of symphysis (Craven)	"	332
145.	" " section of	"	332
146.	Myeloid tumour of both sides of jaws (Author)	"	333
147.	Patient after operation	"	333
148.	Girl, after removal of round-celled sarcoma of lower jaw	"	335
149.	Spindle-celled sarcoma of lower jaw	Syme	339
150.	Patient, after its removal	"	339
151.	Spindle-celled sarcoma of lower jaw	Lawson	342
152.	" " "	"	343
153.	Chondro-sarcoma of lower jaw (Author)	Original	344
154.	Ossifying sarcoma (Author)	"	347
155.	Large epithelioma of lower jaw (Author)	"	351
156.	" " after removal	"	352
157.	Epithelioma of chin following lip cancer (Author)	"	356
158.	" of lower jaw following lip cancer	"	357
159.	" of gland attached to jaw	"	358
160.	Gag for mouth (Wingrave)	"	362

THE INJURIES AND DISEASES OF THE JAWS.

CHAPTER I.

FRACTURE OF THE LOWER JAW.

FRACTURE of the lower jaw is usually the result of direct violence, though Professor Pancoast met with a case in which fracture of the neck of the bone had resulted from a violent fit of coughing, in an old man upwards of seventy years of age (Gross's "Surgery," p. 964). Blows received on the jaw in fighting, or a kick from a horse, are the most common causes of the accident; but falls from a height upon the face also produce some of its most serious forms, owing to the comminution resulting. The unskilful application of the dentist's "key" has been known to cause a complete fracture of the bone, but more frequently in former years than at the present time, when that instrument has been almost entirely superseded by the forceps.

Fractures of the alveolus are frequently unavoidable during the extraction of the molar teeth, even in the most skilful hands, since the position assumed by the fangs is occasionally such that extraction without displacement of the bone to some extent is impossible. These cases ordinarily give, however, little inconvenience, since the removal of the alveolus only hastens the absorption which must necessarily ensue upon the removal of the teeth, unless indeed the fracture should be so extensive as to affect the alveoli of the neighbouring teeth, in which case exfoliation

of a troublesome character may be produced. Unavoidable accidents of this kind have on several occasions been made the ground for legal proceedings against the operator; but most unfairly so, since the exercise of the greatest skill and care cannot on all occasions prevent mishaps due to the natural conformation of the parts.

Mr. James Salter, in his valuable work on "Dental Pathology and Surgery" (1874), devotes a chapter to "The casualties which may arise in the operations of tooth-extraction," in which he mentions that, in extracting an incisor tooth from the upper jaw, the whole mass of bone corresponding to the intermaxillary bones broke away, and was merely held in place by the soft tissues. Fortunately the bone reunited without an untoward symptom. Mr. Salter also refers to a case in which a most able operator broke the horizontal ramus of the lower jaw completely through, in extracting a tooth with the forceps.

Gunshot injuries to the face may produce the most terrible injuries of the lower jaw, by splintering and removing large portions of it; and the mere explosion of gunpowder in its immediate neighbourhood, as when a pistol is fired into the mouth by a would-be suicide, will produce a fracture of the bone. (See chapter on "Gunshot Injuries.")

Fractures of the lower jaw are remarkable from the fact that they are almost always *compound* towards the mouth, though the skin is rarely involved except in gunshot injuries. The fibrous tissue of the gum being very inelastic, tears readily when the bone is broken across, and thus the saliva and the air come in contact with the fractured surfaces. Examples have been described, however, where the presence of fracture was discovered without injury either to the periosteum or the mucous membrane. When the ramus, or still more when the coronoid process or condyle is broken, the bone is too deeply seated for injury to extend into the mouth.

Position of the Fracture.—Fracture may occur at various points in the lower jaw, and the *body* of the bone is that most frequently injured (in fifty-two out of fifty-five cases

recorded by Hamilton). The fracture appears to occur most frequently in the neighbourhood of the canine tooth, this position being determined probably by the greater depth of its socket, and the consequent weakness of the bone at that point ; but the fracture may happen at any other point, and has been known to occur exactly at the symphysis in cases too old to admit of separation of the two portions of the bone. Fracture through the symphysis has often been described as taking place chiefly in infancy or childhood, but in the cases that have been recorded the ages vary from ten years to sixty years (average thirty-two years, Hamilton). Of the fifty-two cases of fracture of the body recorded by Hamilton, four were perpendicularly through the symphysis and eighteen of the remainder were known to be oblique, whilst of the whole number no less than sixteen were examples of double and triple fractures. In thirty examples of fracture through the body, not including fracture of the symphysis, the line of fracture was twenty times at or very near the mental foramen ; three times between the first and second incisor ; four times behind the last molar ; and three times between the last two molars.

The line of fracture, except at the symphysis, is usually oblique, and, according to Malgaigne, the thickness of the bone is also divided obliquely, so that generally the fracture is at the expense of the outer plate of the anterior fragment and the inner plate of the posterior fragment, though this rule is not without exception.

The *ramus* of the lower jaw is, from its position and coverings, much less liable to injury except from extreme violence, such as the passage of a wheel over the face or a gunshot injury, and Hamilton states that he has seen only two cases of fracture in this situation.

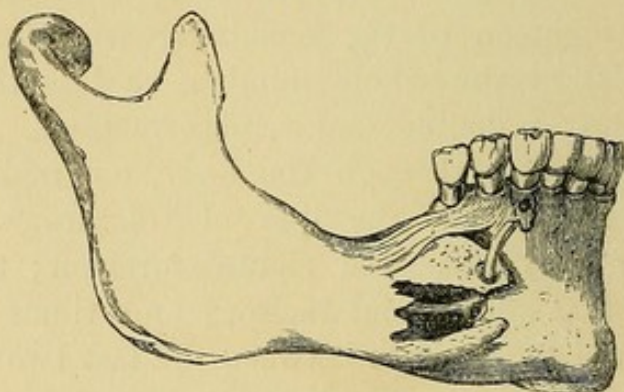
The *coronoid process*, owing to the protection afforded to it by muscles, is only occasionally fractured, and is always accompanied by the fracture of some other part of the lower jaw.

The *condyles* are fractured usually below the attachment of the external pterygoid muscles, and Malgaigne divides these

fractures into two classes : one class caused by falls or blows upon the chin, the other class caused by direct injury to one side of the face, and in these latter cases there is generally a fracture of the body of the lower jaw on the opposite side.

Symptoms.—As a rule, these are well marked. Even in simple vertical fracture of the symphysis the patient will be conscious of pain and slight grating on pressing the jaws together ; and the surgeon will readily perceive the irregularity of the teeth, due to alteration in the level of the fragments. The position of a patient with fracture of the

FIG. 1.

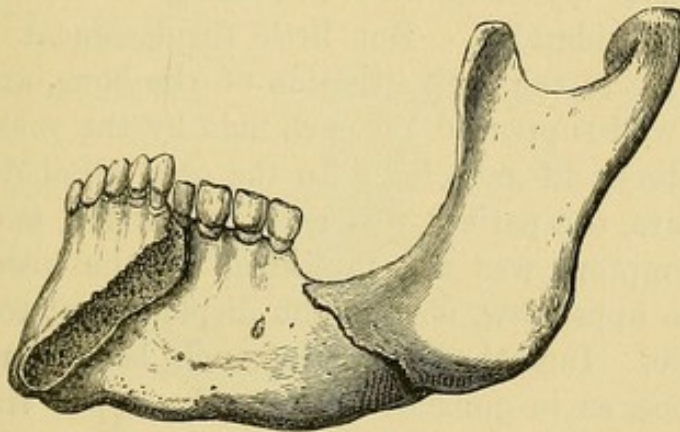


jaw is very characteristic. He endeavours to support and steady the fragments with his hands in the most careful manner, and his anxiety for relief is often most ludicrously complicated by his inability to explain by word of mouth what his ailment is. Where the laceration of the gum has permitted displacement of the fragments, manipulation on the part of the surgeon is unnecessary for the establishment of the diagnosis ; but when any doubt exists he should grasp the jaw on each side, with the forefingers introduced into the mouth, and will have no difficulty in perceiving the movement and crepitus between the fragments.

Fracture of the *body* of the lower jaw may occur in one or several places. When a single fracture occurs on one side of the median line, the small fragment is liable to displacement by muscular action, being drawn outwards and at the same time a little forwards, so as to overlap the larger

fragment. This is due to the action of the temporal and masseter muscles, but principally to the latter, and is favoured by the generally oblique direction of the line of fracture and consequent tendency of the bones to override, as pointed out by Malgaigne (Fig. 1). An instance of the obliquity of the fragment being reversed is given by Dr. Kinloch in the *American Journal of Medical Sciences* for July, 1859. Here the patient, who was fifty years of age, met with a compound fracture of the right side of the jaw, in front of the masseter muscle. "The line of frac-

FIG. 2.



ture divided the bone obliquely through its thickness, the obliquity being at the expense of the external plate of the small posterior fragment, and of the internal plate of the large or anterior fragment." Hamilton has seen two cases in which the posterior smaller fragment was internal to the anterior larger fragment.

In double fractures of the body of the jaw, one being on each side of the median line, the displacement is necessarily greater, since the muscles attached to the chin tend to draw the central loose piece downwards and backwards towards the hyoid bone, whilst both lateral portions are drawn forwards and outwards, as described in the previous paragraphs. When, as is probably the case in most instances of the kind, the obliquity of the fracture is the same on the two sides—*i.e.*, at the expense of the outer surface of both extremities of the central fragment, no difficulty is experienced in reducing

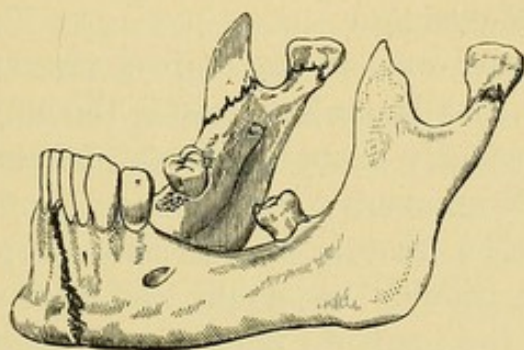
the fracture, and it is only necessary to see that the posterior fragments are sufficiently approximated to the central portion; but when the obliquity is different on the two sides, the fracture being at the expense of the outer plate of the posterior fragment on the right side, and the reverse on the left side (consequent, no doubt, upon the blow having been struck to the left of the median line), it is obvious that great difficulties will be encountered both in reducing and maintaining the apposition of the fragments (Fig. 2).

Fracture of the *ramus* is usually produced by some crushing force, such as the wheel of a carriage, as in a case recently under my care, and the bruising of the soft parts is therefore considerable. But little displacement ordinarily occurs, owing to the deep situation of the bone, and the fact that it is well supported on each side by the masseter and internal pterygoid muscles. In the case alluded to under my own care, the patient was a boy of twelve, and the prominent symptom was the projection of the lower incisors beyond the upper jaw, with slight displacement towards the injured side. But when there is much laceration and loss of substance, as in gunshot injuries, the upper fragment is apt to be tilted forward by the temporal muscle, as was noticed in a case under my own care.

Fracture of the *neck of the condyle* is not so rare an accident as has been stated by some authors, judging from the number of museum specimens of the accident which exist. Fig. 3, from Sir William Fergusson's "Practical Surgery," shows very well the ordinary appearance of the fracture, though in some specimens the line of fracture is more obliquely placed. The cause, in all the recorded cases, is the same—viz., a fall from a considerable height. The symptoms are obscure, there being pain and difficulty of movement on the affected side, and crepitus perceived by the patient. The condyle is drawn inwards and forwards by the pterygoideus externus, as can be ascertained by passing the finger into the mouth, and the jaw-bone is apt to become slightly displaced, so that the chin is turned *towards* the affected side and not *from* it, as is the case in dislocation.

Dr. Fountain has recorded in the *New York Medical Journal*, January, 1860, a case of fracture of the neck of the left condyle with fracture through the body on both sides, caused by a fall from a height, in which the following symptoms were present. The jaw was displaced backwards and laterally on the left side—a displacement which was temporarily rectified as long as traction was made at the symphysis, which the connections of the middle fragment with the membranous and muscular tissues permitted. As soon as this traction was removed the lateral deformity was reproduced, and every contrivance resorted to failed to

FIG. 3.



maintain a permanent reduction of the fracture of the neck, until the upper and lower teeth were wired together so as to keep up traction on the lower jaw. The case did well, and recovered without any deformity.

When double fracture of the neck occurs, the violence must have been so great as in most cases to lead shortly to fatal results. Mr. Newland Pedley, however, has recorded a case of double fracture caused by the passage of a cart-wheel, in which, three weeks after the accident, the face showed separation of the upper and lower front teeth to the extent of about three-fourths of an inch, and the lower jaw receded greatly. The mouth could be opened, and there was no deviation of the median line. Examination of the oral cavity revealed no fracture through the dental arches. Pressure over both condyles produced pain and some slight crepitus, more marked on the right side. (*British Journal of*

Dental Science, April 15th, 1889.) Watson, of New York, has also recorded a case of recovery in the person of a man who fell from the yard-arm of a vessel, breaking his thigh and arm bones and both condyles of the lower jaw. (*New York Journal of Medicine*, October, 1840.)

Reduction of a fracture of the neck of the jaw, should complete displacement have occurred, can only be effected by acting upon the condyle and the jaw at the same time. The finger carried far back into the mouth should throw the condyle out, whilst the jaw is brought into its proper relation with the other hand. The fragments must then be pressed firmly together, and against the glenoid cavity, with a bandage. Ribes, to whom this plan is due, applied it with success (Malgaigne).

Fracture of the *coronoid process* is a rare accident. Thus Hamilton says that Houzelot's case is the only one which he has found. Curiously enough, however, he employs the illustration from Fergusson's "Practical Surgery" a few pages before, in which a fracture of the coronoid process is seen. The fragment would, no doubt, be drawn upwards and backwards by the temporal muscle, and might be felt in its new situation, though this displacement would probably be limited by the very tough and tendinous fibres which are so closely connected with the bone, forming the insertion of the temporal muscle, and reaching down to the last molar tooth. According to Sanson, fractures of the coronoid process do not admit of union, but there is no evidence in support of this view.

Considerable inflammation frequently follows a fracture of the jaw, even of a simple kind, particularly if it has been neglected or overlooked for some hours. The face becomes swollen, and the tissues beneath the chin infiltrated with serum, which is sometimes converted into pus, giving rise to troublesome abscesses. These will be considered in the next chapter among the complications of fracture of the lower jaw.

CHAPTER II.

COMPLICATIONS OF FRACTURE OF THE LOWER JAW.

Wounds of the Face are rare accompaniments of fracture of the lower jaw, except in cases of gunshot injury, and when found are usually the result of a kick from a horse. The wound itself requires treatment on ordinary principles, and is of little moment as regards the fracture (which is doubtless "compound" also into the mouth), except as interfering with the application of a necessary retentive apparatus. In a case of extensive fracture of the lower jaw, the result of a kick from a horse, which I saw in the Westminster Hospital, under Mr. Holthouse's care, the lip and chin were extensively torn; and in a case of the late Mr. Berkeley Hill's, in University College Hospital, the result of a fall, the wound beneath the chin very much interfered with the application of a modified form of Lonsdale's apparatus, which it was found necessary to employ.

Hæmorrhage, beyond that resulting from laceration of the gums, is rarely met with, since, although theoretically one might imagine that the inferior dental artery would frequently be torn across, this appears not to be the case; a result due, no doubt, to the fact that the elasticity of the artery allows of its stretching sufficiently to avoid rupture. In the *Lancet* of October 12th, 1867, a case of fractured jaw is reported, under the care of Mr. Maunder, in which severe hæmorrhage into the mouth occurred through a fissure in the gum behind the last molar tooth. This was effectually controlled by digital compression of the carotid artery, which was maintained for two hours and a half, after which no further bleeding occurred. Secondary hæmorrhage has also

been met with, for Stephen Smith, of New York, reports a case of double fracture in which about a pint of blood was lost from the seat of fracture on the twentieth day. Injury of the soft parts about the jaws may give rise to severe hæmorrhage, requiring prompt treatment; thus Mr. Lawson has reported (*Medical Times and Gazette*, 1862) a case in which it became necessary to lay open the face in order to secure the facial and transverse facial arteries, torn by the wheel of a cart, which had fractured both the upper and lower jaws.

Mr. O'Grady published a case of compound comminuted fractures of both upper and lower maxillæ, with extensive laceration of the face, in which tracheotomy became necessary, owing to the urgent dyspnœa supervening a few hours after the accident, due, probably, to blood becoming infiltrated into the tissues about the base of the tongue. A case of death during the administration of chloroform, which occurred at St. Bartholomew's Hospital in 1882, seems to have been due to injury of the larynx and extravasation of blood into the muscles of the root of the tongue, accompanying a fracture of the lower jaw caused by a blow in fighting.

Dislocation and fracture of the teeth are not unfrequently met with, the former being the direct result of a blow, or the consequence of a fracture running through the socket, and the latter the result of direct violence; or, in the molar region particularly, in consequence of indirect force through the neighbouring teeth, or from the teeth being forcibly driven against those of the upper jaw (Tomes). Where the fracture has passed through the socket, the tooth may fall between the edges of the bone and prevent their proper coaptation, and this should be borne in mind when a tooth is missing and difficulty is experienced in setting a fracture, since Erichsen mentions a case where union was prevented until the tooth was removed. In the molar region the crown of the tooth may be broken off, one fang remaining *in situ* and the other dropping into the fracture, as was the case with a patient under my own care. Teeth which are

merely *loosened* generally become re-attached and useful, and should therefore not be removed.

I am indebted to Mr. Margetson, of Dewsbury, for a case in which double fracture of the jaw occurred, with dislocation of several of the teeth, and fracture of the left second bicuspid, the crown of which was embedded for more than two years in the tissues of the mouth, behind the incisor teeth. Mr. Margetson removed the crown from its abnormal position and also the fang; and both, together with a plaster cast, showing very well the deformity resulting from the fracture of the jaw, are in the Museum of the College of Surgeons.

The front teeth may be broken off, with the portion of the alveolus containing them, by a horizontal fracture, either alone or in combination with a vertical fracture through the thickness of the bone. A specimen in University College shows a vertical fracture through the symphysis, with a horizontal fracture running through the alveolus on the right side, separating the portion containing the right lateral incisor, the canine, and first bicuspid teeth. Such a fragment may be made to re-unite if treated at once, but when some days have elapsed, and the fragment is only attached by a portion of gum, removal must necessarily be performed. A case of the kind was recently under my own care, in the person of a man, aged sixty, who had had a blow on the left side of the jaw six days before I saw him. I found a loose piece of alveolus three-quarters of an inch in length, and containing the left incisors and canine teeth, which was merely held by a portion of gum, there being no other injury to the jaw. The preparation is now in the Museum of the College of Surgeons.

In fracture of the lower jaw in children—a very rare accident—when the fracture happens to involve the cavity in which a permanent tooth is being developed, exfoliation of the tooth, with a portion of the alveolus, is almost certain to ensue, as was noticed by Mr. Vasey in a case occurring in St. George's Hospital.

Paralysis and Neuralgia from injury to the inferior dental

nerve may be the immediate result of the accident, or be caused at a later period by some pressure arising from the development of callus. In by far the greater number of cases no injury of the nerves occurs, and this may be partly explained, as Boyer originally pointed out, by the fact that "the greater part of these fractures takes place between the symphysis and the foramen by which the nerve comes out."

A case was recorded by Mr. W. G. Spencer in the *Transactions of the Pathological Society*, 1887, in which a woman, aged fifty, met with a fracture between the first and second molar teeth on the left side, from direct violence. She complained of much pain, which was limited to the area of distribution of the inferior dental nerve. There was no displacement at the seat of fracture when the patient was seen, nor was there any bleeding from the inferior dental artery. There were no changes in the skin of the cheek beyond bruising.

A case of paralysis of the inferior dental nerve, from a gunshot wound of the ramus, which was under my care some years ago, will be subsequently referred to; and Malgaigne describes a specimen in the Musée Dupuytren, also the result of gunshot injury, in which the dental nerve was ruptured, and its canal obliterated at the seat of fracture (see Fig. 7).

Temporary paralysis of the inferior dental nerve must be of rare occurrence, since Malgaigne did not meet with it; and Hamilton thinks that "the explanation may be found in the fact that the fragments seldom overlap to any appreciable extent, and that even the displacement in the direction of the diameters of the bone is generally inconsiderable, or, if it does exist, it is easily and promptly replaced." He thinks, moreover, that temporary anæsthesia of the chin might not improbably be overlooked at first, and would have ceased by the time the apparatus was removed. A. Bérard saw a case of vertical fracture without displacement between the second and third molar teeth, in which complete temporary anæsthesia of the lip and chin as far as the median

line existed (*Gazette des Hôpitaux*, August 10th, 1841). A case of temporary paralysis of the dental nerve, from fracture, is mentioned also by Robert (*Gazette des Hôpitaux*, 1859, p. 157), occurring in a woman, aged sixty-four, who was run over by a carriage, and who also suffered from fracture and displacement of the malar bone, with *permanent* anæsthesia of the infra-orbital nerve.

An instance of neuralgia, consequent upon old fracture of the lower jaw, occurred in St. Bartholomew's Hospital in 1863. Mr. Wormald, under whose care the patient was, opened up the dental canal and excised a portion of the inferior dental nerve with the most satisfactory result. (*Medical Times and Gazette*, April 4th, 1863.)

Injury to Base of Skull and Brain.—The cases of convulsions coincident with fracture of the jaw, recorded by Rossi and Flajani, would appear to have been due to injury of the brain, the result of the original accident and unconnected with the fracture; but it may happen that direct injury may be inflicted on the skull by the broken jaw. Thus, Dr. Lefèvre (*Journal Hebdomadaire*, 1834) gives the case of a sailor, aged twenty-two, who fell from a height upon his chin, with the following result. There was almost complete inability to open the mouth, the jaws being tightly closed and the lower drawn backwards and a little to the left. There were tenderness and ecchymosis in the left temporo-maxillary region, and a little blood flowed from the left ear. The case was diagnosed to be one of fracture of the neck of the condyle. The man died six months after with brain symptoms, and, on opening the head, the left glenoid cavity was found driven in, with a starred fracture of the temporal bone, between the fragments of which the condyle of the jaw was found. There was a large abscess in the brain.

Similarly, in the Museum of St. George's Hospital, there is a temporal bone with the unbroken condyle of the inferior maxilla driven through the glenoid cavity, producing a fracture of the middle fossa of the base of the skull, in a case where there was an extensive comminuted fracture of the

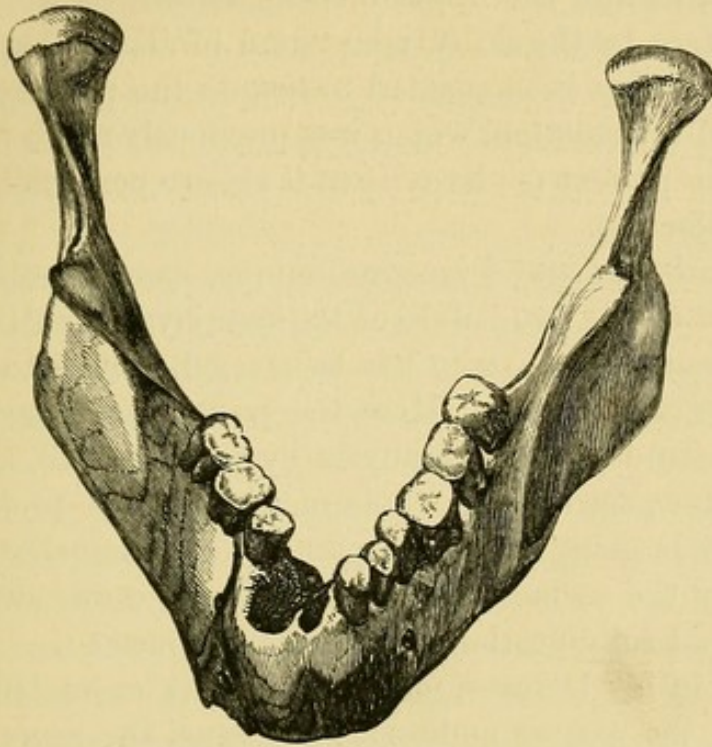
jaw itself, which, however, is not preserved. In contrast with this may be mentioned another case which also occurred in St. George's Hospital, where, the neck of the condyle and the base of the coronoid process having been broken through, the lower fragment was displaced and had produced laceration of the meatus auditorius externus, separating the cartilaginous from the osseous portion for nearly half its circumference. In this case considerable serous discharge flowed from the ear, leading to the suspicion of injury to the skull, but there were no brain symptoms, and the patient dying with *delirium tremens*, the skull, the membranes, and the brain were found perfectly healthy.

In connection with these cases may be mentioned those recorded by M. Morvan (*Archives Générales*, 1856), who gives two cases of his own, and one by Montezzia, where a blow on the chin was followed by bleeding from the ear; and one case by Tessier, where a double fracture of the jaw from a kick by a horse was followed by bleeding from both ears. In all these instances the patients recovered.

Abscess and Necrosis.—Inasmuch as nearly all fractures of the lower jaw are compound into the mouth, it is evident that the seat of fracture cannot be kept free from septic infection, and, as a consequence, a certain amount of suppuration nearly always ensues. In the majority of cases the suppuration remains limited to the injured part, the pus escaping readily into the mouth through the lacerated gum. This suppuration may spread to the alveolar portion of the bone, and cause the necrosis of a small portion of the alveolus, without producing any permanent deformity. In other cases, however, the pus tends to accumulate, forming abscesses of varying extent, which usually point below the jaw. As a consequence of this, portions of the lower jaw become necrosed. In some cases the whole thickness of the bone may become necrosed, especially when the fracture is comminuted, leading to considerable deformity. Of this a specimen in St. George's Hospital Museum (Fig. 4) affords a good example, a loss of substance to the right of the symphysis having occurred, leading to the union of the

halves of the bone at an acute angle. A still better example of the same kind of deformity, and from a similar cause, is seen in Fig. 5 taken from a model lent to me by

FIG. 4.



Mr. Hepburn. The patient several years ago received a kick from a horse, which produced a compound comminuted fracture of the lower jaw. The central portion became

FIG. 5.

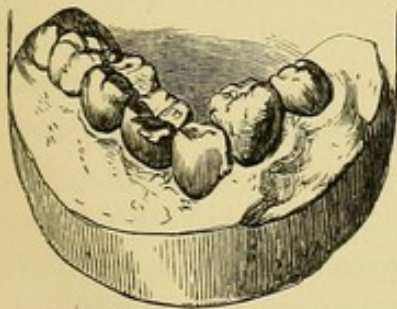
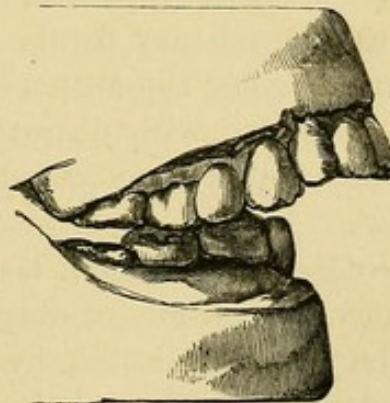


FIG. 6.



necrosed and was removed by the late Mr. Aston Key, and appears to have extended from the second bicuspid tooth of the right side to the first molar on the left, the intervening

teeth being wanting. The result, as seen in the model, is that the two halves of the jaw are united at an angle, of which the second bicuspid tooth forms the apex, the jaw being so much contracted that this tooth is three-quarters of an inch behind the upper incisors, as can be well seen in Fig. 6. Here, by the skilful adaptation of artificial apparatus, Mr. Hepburn has been enabled to restore the power of mastication and articulation, which was previously much impaired, so that the patient (a clergyman) is able to perform his duties with satisfaction.

A remarkable, and I imagine unique, case of necrosis and exfoliation of the two halves of the symphysis menti occurred to Mr. Henry Power, who has been good enough to give me the details of the case. Here the patient sustained a compound fracture of the symphysis by a severe fall, and some months after, during the whole of which time profuse supuration was going on in the part, two thin lamellæ of bone, apparently the surfaces of the symphysis, came away, after which rapid solidification of the fracture ensued.

Boyer, in his lectures, mentions having extracted from a fistula in the meatus auditorius externus, the necrosed condyle of a man who had had a fracture of the neck of the bone seven or eight months before.

Salivary fistula may result from a compound fracture of the lower jaw, or from an abscess bursting externally in the case of a simple fracture. The treatment would of course be that for salivary fistula arising from other causes. A case occurred under the author's care, in which a salivary fistula was connected with necrosis and false joint in the ramus of the jaw, following a gunshot injury, and was successfully closed.

Dislocation.—I have been able to find, in the standard authors, the records of only two cases of fracture of the body of the jaw complicated by dislocation of the condyle from the glenoid cavity, and the accident must of necessity be a rare one, for the fact of fracture having occurred would tend to prevent the dislocation, since the leverage necessary would thus be interfered with. The cases in question are

given by Malgaigne in his work on "Dislocations," one being recorded by Delamotte, who saw a fracture of the body of the jaw with double dislocation produced by the kick of a horse, in a girl of between eleven and twelve years. The other was a more remarkable case, recorded by Robert, who saw a dislocation of the left condyle *outwards*, with fracture of the jaw in front of the right ramus, in a man who was knocked down on his left cheek, the wheel of a carriage passing over the right.

A third case, however, is reported by Mr. Croker King (*Dublin Hospital Gazette*, 1855), and occurred in a boy of eight, who suffered a fracture at the symphysis with dislocation of the left condyle upwards and backwards. There was bleeding from the ear, and the chin was much retracted and turned to the left; the mouth was open, but could be closed, and it was then observed that the lower molars overlapped the upper, but that the lower incisors were at least one inch *behind* the upper. Reduction was easily effected, and the case did well. (Owing to an obscurity and apparent contradiction in the report, this case has been put down by Weber as an instance of unusual dislocation *without* fracture.)

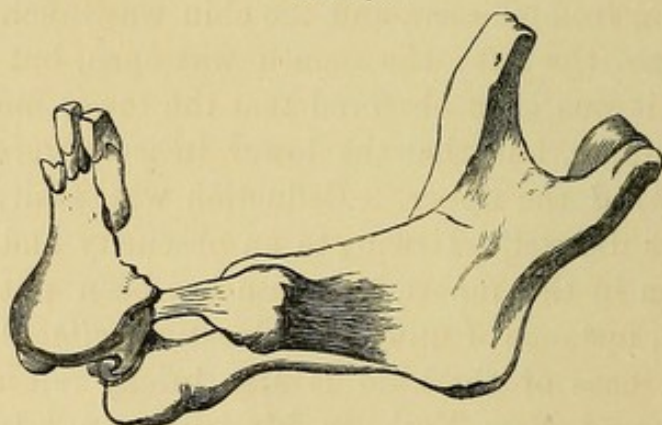
A fourth case of the kind is also briefly referred to by Mr. Gunning, of New York, in his paper on "Interdental Splints" (*New York Medical Journal*, 1866): "The patient was thirty-six years old; the jaw was fractured through the symphysis and the right condyle dislocated *outward and backward*, February 10th, 1866, in falling down stairs and striking the chin on a small desk." The dislocation was reduced before Mr. Gunning was called in.

The case of fracture of the glenoid cavity by the displaced condyle in St. George's Hospital, already referred to, cannot be regarded as one of true dislocation. The treatment in these cases would of course be reduction of the dislocation before setting the fracture.

In fractures of the neck of the jaw the condyle itself has been found displaced. Thus Holmes Coote (in his article on Injuries of the Face, Holmes' "System of Surgery," vol. ii) mentions that Bonn, writing in 1783, gives an account of

a case of the kind. There was a longitudinal fracture in the middle of the bone, and at the same time the right condyle was broken off and dislocated forwards and inwards, lying united by callus near the foramen ovale. The pointed upper extremity of the neck of the lower jaw articulated with the glenoid cavity, and the separated head with the lateral part of the tubercle of the temporal bone. There was motion in the false joint. The same author mentions a case of fracture and dislocation of both condyles of the lower jaw, in a young man who had numerous injuries and lived five weeks. The condyles were found to be broken off, and fixed near the foramen ovale on either side.

FIG. 7.



Irregular Union.—Where the displacement of the fragments has been great, it may be impossible to keep them in proper position, and the result may be an irregular union of the bone, interfering more or less with its functions in after-life. This is particularly liable to occur in cases of double fracture, where the central portion of the jaw is much displaced by the muscles attached to it; and Malgaigne gives a drawing from a specimen of the kind in the Musée Dupuytren (Fig. 7), in which the middle fragment is displaced downwards and backwards, and has also undergone such a change of position that its lower border is inclined forward, and its anterior surface looks almost directly upwards, the union on one side being partly fibrous.

An almost precisely similar state of things existed in a case of double fracture which came under Mr. Bickersteth's

care, and which will be found in detail under the head of "Treatment of Ununited Fracture," the central portion of the jaw having become much depressed, and united on one side, so that when the molars were in contact the incisor teeth were separated more than half an inch, the opposite fracture being still ununited. Here Mr. Bickersteth remedied the deformity by sawing through the bone at the seat of the united fracture, and replacing the fragment in its proper position.

The specimen of united fracture in University College Museum illustrates very well the effect of irregular union upon the teeth, and the masticatory power of the jaw. The fracture was in the right molar region, and appears to have led to the loss of all the teeth on that side except the last molar. The irregular union has resulted in a contraction of the alveolar arch, so that the left teeth have been thrown within those of the upper jaw, with the result of wearing away the opposed surfaces of the two sets—viz., the lower teeth on their outer and the upper on their inner surfaces. Hamilton expresses an opinion, "that time and the constant use of the lower jaw in mastication will gradually effect a marked improvement in the ability to bring the opposing teeth into contact." The specimen above referred to illustrates the only mode in which such an improvement could, in my opinion, occur.

The deformity resulting from loss of a portion of the bone near the symphysis, has been already referred to under the head of "Necrosis." Loss of substance in other parts of the jaw is apt to result in fibrous union or false joint, and this is especially the case in gunshot injuries.

Ununited Fracture.—Fractures of the lower jaw ordinarily unite with great rapidity and certainty, notwithstanding the difficulties often met with in maintaining perfect apposition of the fragments. Hamilton has noticed one instance, in an adult person, in which the bone was immovable at the seat of fracture on the seventeenth day, and says that in no instance under his own observation has the bone refused finally to unite, although union has been delayed as long

as eleven weeks. Cases of non-union and false joint have, however, been recorded and treated by Physick, Dupuytren, and others ; and a case has already been referred to, which occurred under my own care, in which false joint followed a gunshot injury of the ramus of the jaw. The liability of the lower jaw to false joint, as compared with other bones, may be gathered from a table of 150 cases drawn up by Norris (*American Journal of Medical Sciences*, January, 1842). Of these 150 cases 48 occurred in the femur, 48 in the humerus, 33 in the leg, 19 in the forearm, and two in the lower jaw.

Non-union may be simply the result of neglect of treatment, and union may take place readily as soon as the parts are placed under favourable circumstance. Thus, a patient was under Mr. Wormald's care who, five weeks before admission into St. Bartholomew's Hospital, had fractured his jaw between the canine and bicuspid teeth on the left side, for which he had not been treated. There was some little necrosis, and sinuses had already formed beneath the chin ; but under appropriate treatment the bone thoroughly united in five weeks. (*Medical Times and Gazette*, Jan. 17th, 1863.) And yet, on the other hand, fracture of the jaw has no doubt been occasionally untreated, and still has united. Thus, Boyer saw consolidation occur, though not without deformity, in a water-carrier who would not endure any dressing, nor abstain from either speaking or chewing when the pain did not prevent him. Notwithstanding the most careful treatment, however, the jaw may fail to unite if the case has been complicated in any way. Thus, the late Mr. Berkeley Hill mentioned a case (*British Medical Journal*, March 2nd, 1867) of double fracture, where great difficulty was experienced in adapting suitable apparatus, and where one fracture united perfectly, but the other remained ununited. And again, on the other hand, over-solicitous attention appears occasionally to interfere with union ; for A. Bérard relates the singular case of a child whose fracture made no progress towards recovery till the apparatus, an ordinary bandage, was removed ; and Mr.

Hill's case, mentioned above, illustrates the same point, for he informs me that the second fracture became consolidated without any treatment.

The occurrence of necrosis at the point of fracture is the most probable cause of non-union, and a small amount of this may prevent, or at least delay, the union taking place, as in Mr. Power's case, where two thin lamellæ exfoliated from the symphysis; and, moreover, callus is not thrown out so copiously for the repair of fractures of the jaw as it is in the long bones. Gunshot injuries seem especially liable to produce ununited fractures of the lower jaw, probably by inducing necrosis; and of this an example under the author's care has been already alluded to. On this subject the late Dr. Williamson, of Fort Pitt, has made the following observations in his work on "Military Surgery," p. 22:—

"Ununited fracture of the lower jaw does not seem to have been of such frequent occurrence amongst the wounded from the Crimea as those from India. Six were admitted from India with fracture of the lower jaw. Of these three were invalided, two sent to duty, and one to modified duty. Of these six cases, three were instances where the fracture remained still ununited, though the ends of the bone were in contact. In one case the ball struck one side of the lower jaw, and was cut out on the opposite side one month after, fracturing the bone on both sides. In one, the ball was cut out from below the tongue. In one case, from a shell wound, there was a double fracture, one on the right side of the ramus, and also another near the symphysis, with great laceration of soft parts, and resulting deformity; the first-named fracture remained ununited. In another case, there was a double fracture from a musket-ball; the fracture at the entrance of the ball still remains ununited, that at the exit has become united. In one case, from round shot, the whole of the left ramus of the lower jaw had been extracted at the time, or came away by exfoliation, leaving a large chasm and great deformity on this side of the cheek from laceration of the soft parts. In one case there was a fracture on the left side, at the angle of the jaw, still ununited."

A remarkable case of ununited fracture in the mental region, the result of gunshot injury in the Crimea, is recorded by the late Mr. Cox Smith, of Chatham (*Dental Review*, 1858-9), and was satisfactorily treated mechanically by that gentleman. The condition of the parts was briefly as follows:—The symphysis with the incisors, right canine, and one bicuspid tooth, having been carried away, the jaw was divided into two unequal portions, which fell together when at rest; but upon opening the mouth the left only was fully acted upon by the muscles and the right rode over it, as shown in the illustration. (Fig. 8.) Much pain was

FIG. 8.

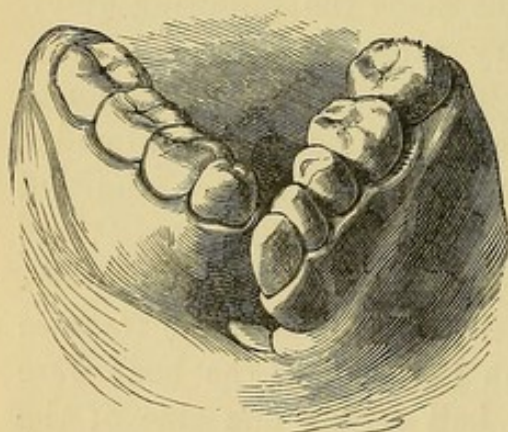
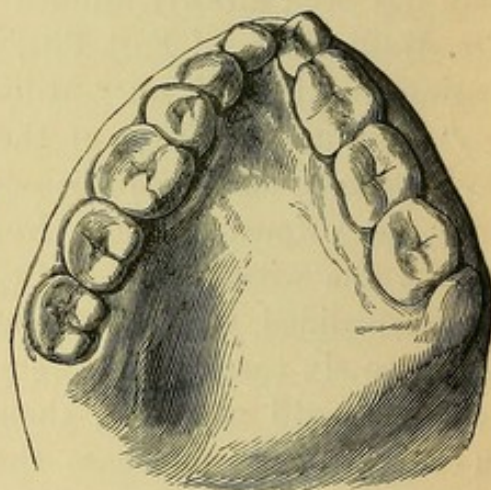


FIG. 9.



caused by any attempt to separate the two fragments so as to make them correspond to the teeth of the upper jaw; hence mastication was impossible, articulation was much interfered with, and the patient could only sleep on his back, since lying on either side caused displacement of the corresponding section of the jaw. Fig. 9 shows the model first taken by Mr. Smith, and its resemblance to cases of united fracture with loss of substance in the incisor region previously described, will be at once noticed. The treatment of this interesting case will be referred to under another section.

The case of ununited fracture successfully treated by Dupuytren was also the result of a gunshot injury, and the following was the condition of the parts when the patient came under that surgeon's care, four years after the receipt

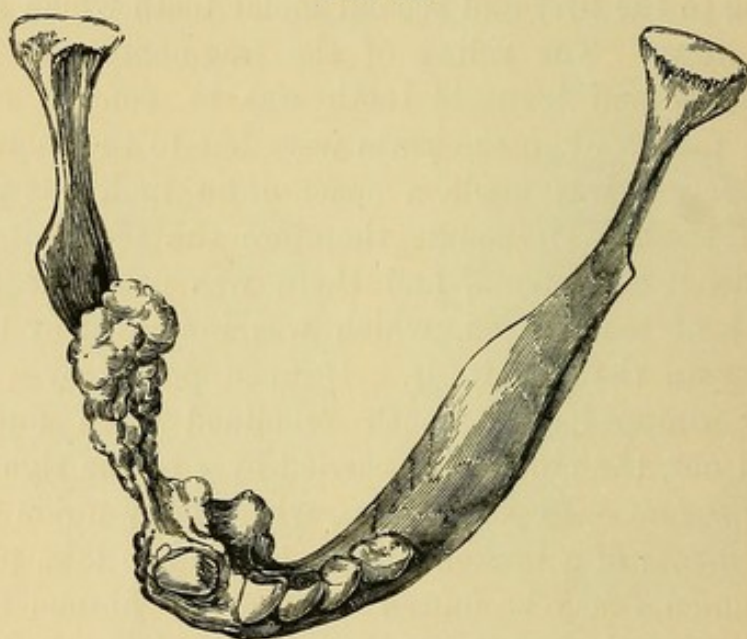
of the injury (Dupuytren's *Leçons Orales*, vol. iv). The ball had struck the right side of the jaw just in front of the masseter, and had carried away a portion of the bone at the junction of the body with the ramus. The posterior fragment, which contained the wisdom tooth, was twisted so that the tooth looked towards the tongue, and at the same time was drawn outwards into the cheek. The anterior fragment formed by the remainder of the bone was displaced, so that its fractured end was carried to the right side and below the other, an interval of an inch intervening, corresponding to the first and second molar teeth which had been carried away. The riding of the fragments was so great that the second bicuspid tooth was in contact with the wisdom tooth, when the parts were left to themselves; but, when traction was made, a space of an inch was produced between them. Of course therefore the teeth of the two jaws did not correspond, and there was consequently great difficulty of mastication, which was increased by the want of power in the jaw itself. If unsupported by a bandage the jaw dropped, the mouth remained open and saliva dribbled out, the chin being carried over to the right side.

False Joints.—In some cases, where bony union between the fragments of a broken bone has failed to take place, the two fragments may be united together by fibrous tissue in two ways, forming what are termed false joints. First, the union may more or less resemble a synarthrosis, the fractured ends being held together by ligamentous tissue. Secondly the union may closely resemble in arrangement a diarthrodial joint. A ligamentous capsule is formed, and is lined by a smooth membrane which secretes synovia. The only museum specimen of false joint in the lower jaw I have met with is in University College (Fig. 10), and belongs to the first kind, since it is a good example of fibrous union filling the interval between the right canine tooth and the ramus of the jaw, there having evidently been considerable loss of bony substance at the seat of fracture. A very similar specimen is, I am informed, in the Museum of the Royal College of Surgeons in Edinburgh, the fibrous tissue extending from

the symphysis to the left bicuspid teeth. I have no doubt, however, that the other form, the true false joint, does occur in the lower jaw, both as the result of violence (and particularly in the ramus of the jaw), and as the result of operative interference, having had the opportunity of watching the formation of a false joint in cases in which I performed Esmarch's operation for closure of the jaws, which will be referred to in another part of this essay.

The amount of inconvenience which the patient experiences

FIG. 10.



from an ununited fracture of the jaw will vary according to the position of the false joint. In the ramus it appears to give very little, if any, inconvenience, the new joint performing the function of the temporo-maxillary articulation; and the same may be said, according to my experience, of the false joints purposely made for the relief of closure of the jaws, although in the body of the bone, since the portion of the jaws posterior to the joint is immovably fixed by the cicatrices. When, however, a false joint occurs in the body of an otherwise natural bone, great inconvenience results, the patient being unable to masticate properly; and his health is apt to suffer, as was the case with Dr. Physick's patient, who was successfully treated by the use of a seton eighteen

months after the accident. Here the fracture, originally double, united on the right side, but the left, which was broken obliquely, remained ununited. (*Philadelphia Journal of Med. and Phys. Sciences*, vol. v, p. 116.) A case is related also by Horeau (*Journal de Médecine*, par Corvisart, x, p. 195), which shows the inconveniences experienced. A colonel received a gunshot wound which broke the right side of the body of the jaw some lines from its junction with the ramus, resulting in a false joint between the first and second molar teeth. In the ordinary condition of things these two teeth were on the same level, and they were not deranged even by pushing the fragments from behind forward or from before backward. But if the posterior fragment was raised and the anterior depressed, the second molar tooth was several lines above the level of the first. The result was great difficulty in chewing on the injured side, and consequently the food was habitually carried to the left molar teeth, and its trituration was neither easy nor complete. The digestion became impaired, and the patient suffered from pain after food, &c. I have recently seen a gentleman whom I attended some years ago with Mr. Moger, of Highgate, and who had received most serious injuries of the face from the pole of a waggon. In this case the patient barely escaped with his life, owing to erysipelas and great constitutional disturbance. There was double fracture with extensive necrosis of the lower jaw, which has resulted in a false joint on the right side; but for this the patient has declined all treatment, whether surgical or mechanical, and though he is quite incapacitated for mastication, he is well nourished by means of food passed through a mincing-machine.

CHAPTER III.

TREATMENT OF FRACTURED LOWER JAW.

THE treatment of fractured lower jaw after the reduction of any displacement, the occasional difficulties of which have been alluded to in a previous section, is usually of a simple character; but cases sometimes arise in which the most carefully adapted mechanical contrivances fail to effect a good union. The apparatus employed for the maintenance of the fractured portions in apposition may be conveniently divided into the following groups:—

1. Bandages or slings.
2. Splints, which may be external to the mouth, inside the mouth, or a combination of the two.
3. Ligature of the teeth.
4. Wiring of the bony fragments.

It may be advisable in some cases to combine two or more of these methods.

1. *Bandages or Slings.*—The simplest form of external apparatus consists of the ordinary four-tailed bandage or sling, with a slit for the chin to rest in (Fig. 11). This is made of a piece of bandage about a yard long and three inches wide, which should have a slit four inches long cut in the centre of it, parallel to and an inch from the edge. The ends of the bandage should then be split to within a couple of inches of the slit, thus forming a four-tailed bandage with a hole in the middle. The central slit can be readily adapted to the chin, the narrow portion going in front of the lower lip, and the broader beneath the jaw; and the two tails corresponding to the lower part of the bandage are then to be carried over the top of the head,

while the others are crossed over them and tied round the nape of the neck. The ends of the two bandages may then be knotted together, as seen in the illustration.

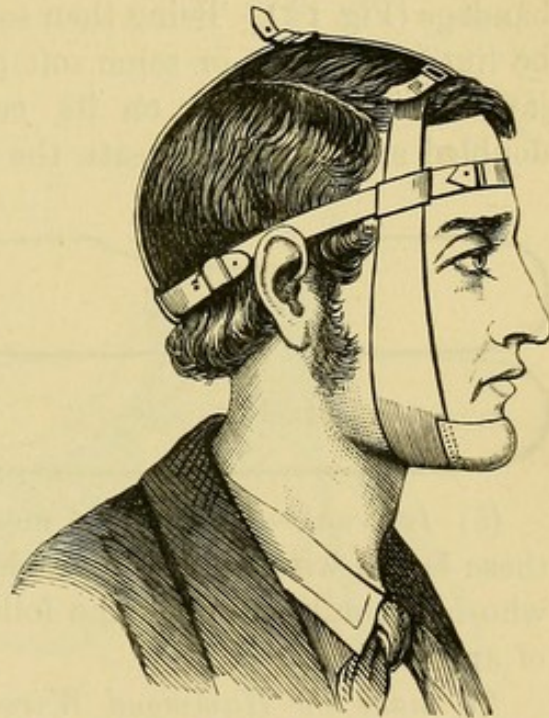
A single roller may be employed to support the jaw, as recommended by the American surgeons Gibson and Barton ; but this is more difficult of application, and is more apt to become disarranged.

Hamilton states that he has frequently noticed the tendency of the sling, as ordinarily constructed, to carry the

FIG. 11.

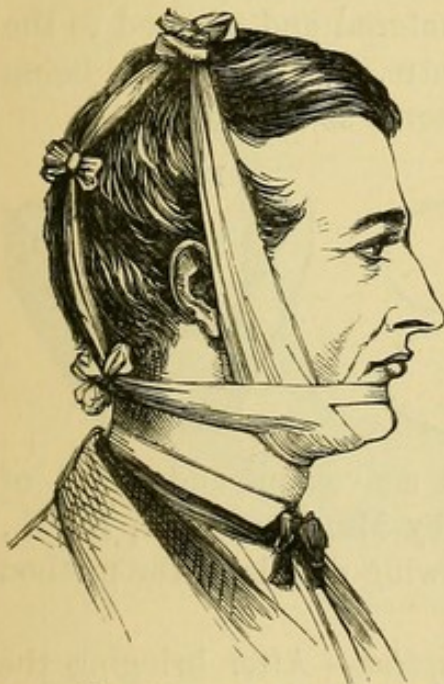

FIG. 12.



anterior fragment backwards, especially when there is a double fracture. He has devised a special form of apparatus (Fig. 12), for which he claims the following :—"The advantage of this dressing over any which I have yet seen, consists in its capability to lift the anterior fragment vertically ; and, at the same time, it is in no danger of falling forwards and downwards upon the forehead. If, as in the case of most other dressings, the occipital stay had its attachment to the chin, its effect would be to draw the central fragment backwards. By using a firm piece of leather as a maxillary band, and attaching the occipital stay above the ears, this difficulty is completely obviated."

2. *Splints*.—An enormous variety of splints has been designed to treat fractures of the lower jaw. It would be impossible to give anything like a complete account of them in this work, and therefore only a few methods illustrating the various principles will be described.

(a) *External*.—This splint is very frequently used in combination with the four-tailed bandage. It is made of paste-board, gutta-percha, or some similar material. This being cut long enough to pass well up to the sides of the jaw, is to be divided at the ends so as to resemble the four-tailed bandage (Fig. 13). Being then softened in warm water it can be lined with lint or some soft material and adapted to the jaw, the chin resting on its centre, and the sides being doubled around and beneath the bone, as in Fig. 14.

FIG. 13.

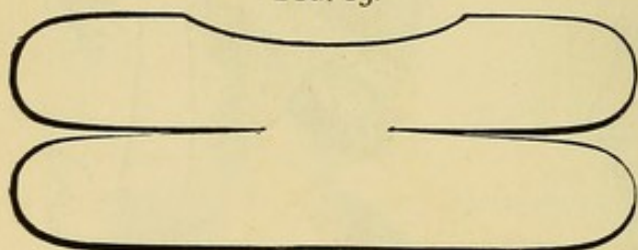
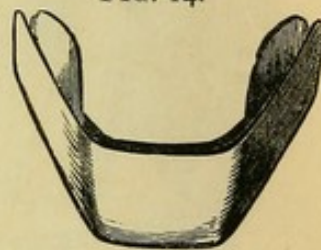

FIG. 14.



(b) *Internal*.—One of the most convenient and useful of these is the wire splint, devised by Mr. Hammond, L.D.S., who has kindly supplied the following details of the method of applying it.

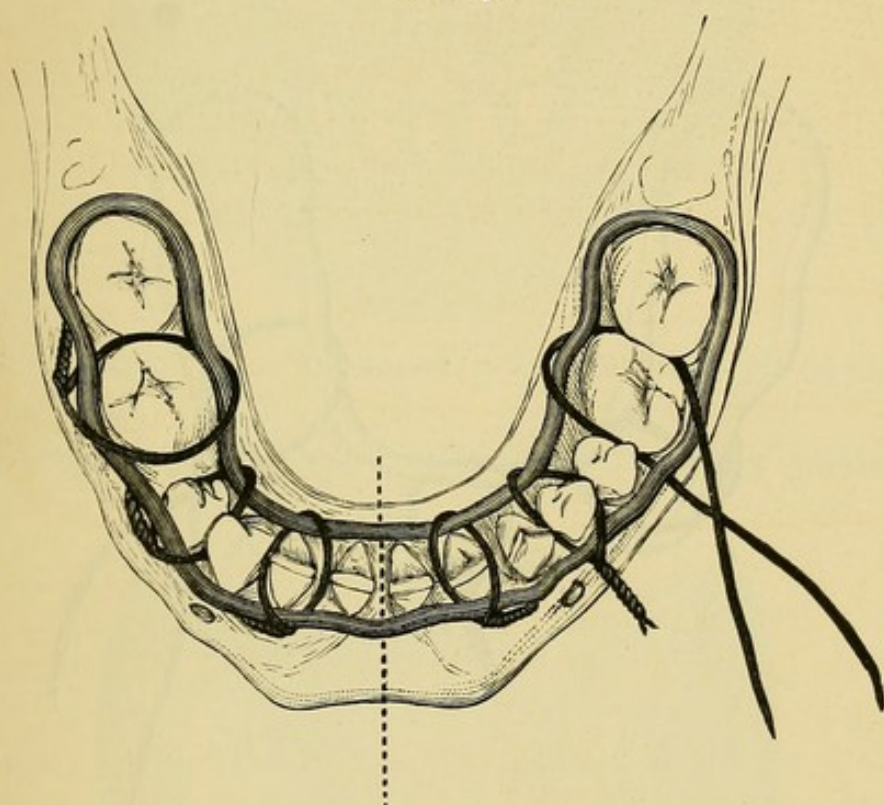
To make the Hammond Wire-splint.—After bringing the broken parts into apposition, tie them temporarily together with silk passed outside the second tooth on each side of the line of fracture.

With a suitable "tray" and very soft wax, take an impression of the mouth (which need not be deeper than the teeth), supporting the chin while doing so with the left hand.

Make a model of this in plaster of Paris in the usual way. If there has been any displacement of the parts, saw down between the teeth corresponding to the fracture, adjust the several pieces to the proper "bite," and fix in position.

Now take a length of iron wire (stout hair-pin size) and carefully make a frame to fit round the teeth, soldering the ends together with silver solder. Cut several five-inch lengths of fine soft iron binding wire—both ends of which should be cut to points, which will greatly facilitate the passing of them through the tartar between the teeth. Should there be much tartar a fine "broach" may be necessary.

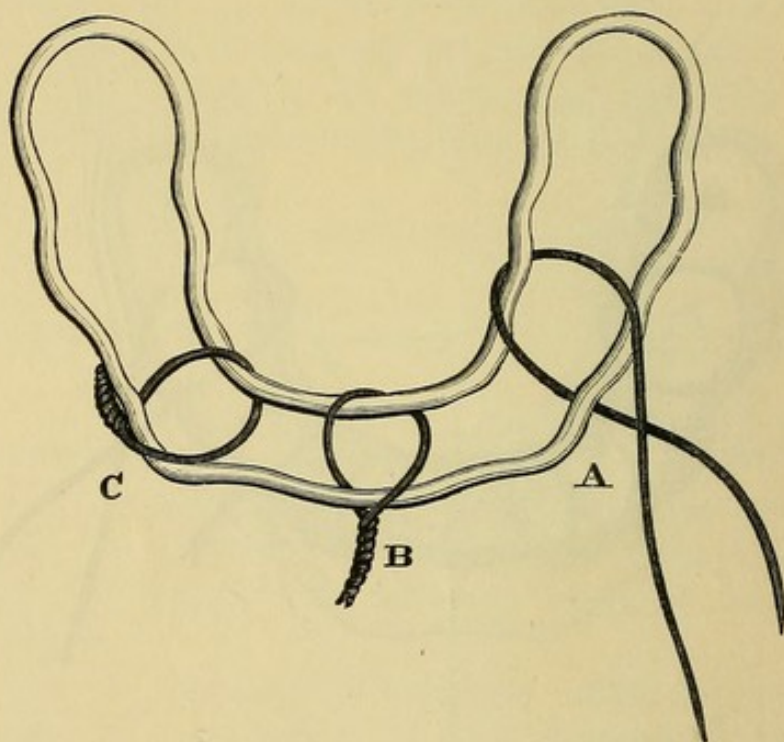
FIG. 15.



To apply the Splint.—Place the patient upright in a high-back chair, and rinse the mouth. Slip the frame over the teeth, holding it gently in place with the left hand, and with the right hand take one of the pointed wires and pass it between the first and second molars on the left side, directing it slightly downwards so that the end will come out under the inner bar of the frame. Have the forefinger of the left hand inside to feel for the point, and with it turn the wire upwards and outwards so as to avoid wounding the tongue. Then bring this wire back, as shown in Fig. 16, *i.e.*, over the inner bar of the frame, and under the outer;

cross the ends and turn them aside—repeat this on the right side of the mouth. When all the ligatures are passed, seize the ends of the first wire with a small pair of pliers, and twist them on each other nearly tight, doing the same on the left side, and when the pressure is equalized cut off the wires about half an inch from the frame, as at B. Now twist all the ligatures quite tight, and tuck them away under the frame, as at C. The jaw will now be found perfectly

FIG. 16.

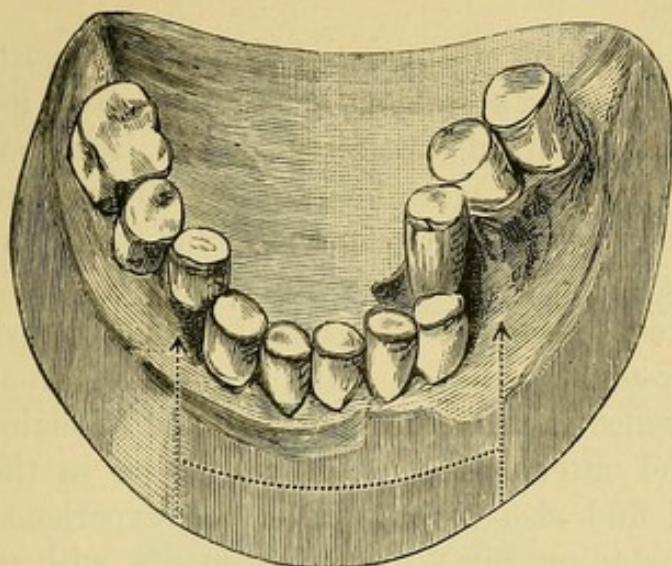


firm, and the patient able to bite steadily on it without pain.

It will be found after a few days that the ligatures will require twisting a little tighter (owing to the movement of the teeth in their sockets); this can easily be done if care be taken to follow the directions given, and never on any account to put one wire round more than one tooth. The attempted employment of one long wire for all the teeth by some operators has very injuriously affected the reputation of this splint for firmness and solidity, by virtue of which qualities good results can always be obtained.

Dissimilar metals must not be used in the construction of the frame and wires, owing to the galvanic action set up

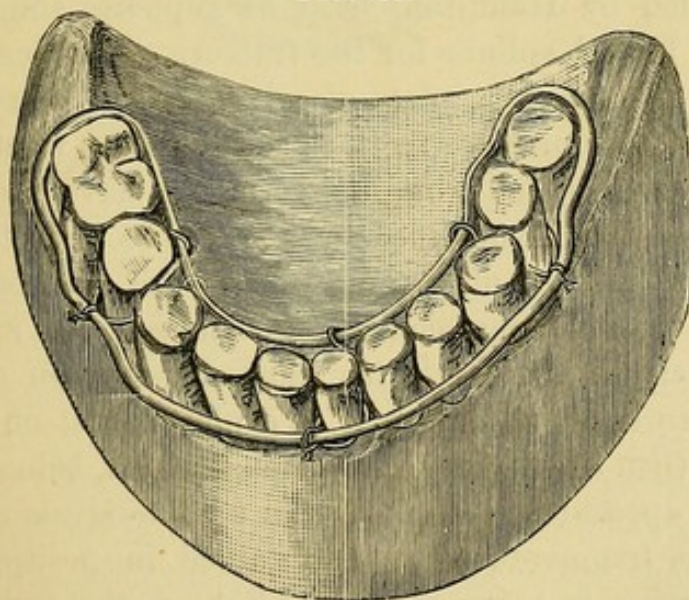
FIG. 17.



and unpleasant taste produced, not to mention the irritation to the teeth.

A very successful case treated in this way was published

FIG. 18.



by Newland-Pedley (*B. J. Dent. Sci.*, 1889), and Fig. 17 shows the deformity of the lower jaw caused by the fractures, one on each side of the incisors and a third running longitudinally beneath them. Fig. 18 shows the

fractures adjusted, and the deformity corrected, by sawing through the lines of fracture in the model and re-articulating with a model of the upper jaw, Hammond's splint being then applied.

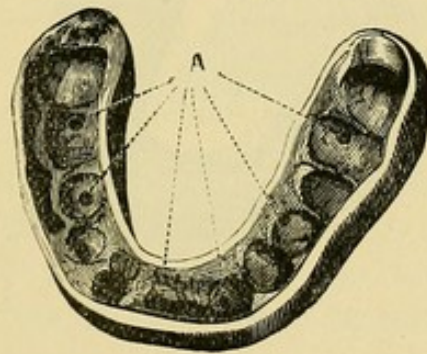
The simplest form of apparatus *within* the mouth consists of wedges of cork, about an inch and a half long and a quarter of an inch in thickness at the base, but sloping away to a point, as recommended by Boyer and Miller. These may be placed between the molar teeth, and, if they can be kept in position, will maintain the regularity of the teeth and keep the incisors separated for the introduction of food, a four-tailed bandage being applied externally. My own experience is that the corks cannot be maintained in position, and after a few hours roll about in the mouth; and this I find also to have been the experience of other surgeons, including Sir William Fergusson, with whom also I fully agree, that the majority of cases do well with merely the simple bandage, not very tightly applied.

Wedges of gutta-percha, introduced warm into the mouth, so as to become moulded to the teeth and gums, are highly recommended by Hamilton, both as supports and, in some degree, as lateral splints for the fracture. Mütter's clamp, consisting merely of a plate of silver, folded over the tops and sides of two or more teeth adjacent to the fracture, is a contrivance which, in its original form, can have been but of little service, but as modified by Mr. Tomes and others is a very efficient method of treating fractures of the body of the jaw. The modification consists in making the silver cap fit accurately to the teeth, for some distance on each side of the fracture, by moulding it to a plaster cast of the jaw. The cap is then lined with gutta-percha, which, being warmed when the apparatus is applied, fills up interstices and fixes the cap, the fragments being maintained in position whilst the application is being made. Although the assistance of a dentist would be required for the proper preparation of the cap, it may not be out of place to notice the best method of obtaining a satisfactory model upon which the cap is to be formed, for which I am indebted to Mr. Tomes. When

the displacement of the fragments is great (as is invariably the case where such apparatus is required), it is best to take a cast of the jaw in wax, without attempting to bring the fragments into proper relation. Into this the plaster is poured, and, when set, a fac-simile of the displaced fracture is of course produced. By now sawing out the piece of plaster between the extremities of the fragments, these can be brought together, and a model of the perfect jaw will be produced, upon which the metal can be carefully fitted. When all is prepared, by carefully adjusting the fracture, the cap will of necessity fit and will maintain the fracture in its normal position.

Mr. Barrett, dental-surgeon to the London Hospital, has

FIG. 19.



kindly shown me models of cases in which he has obtained most satisfactory results, by both metal and vulcanite interdental splints, secured in the mouth by small screws passing between the necks of the teeth. One of his cases was in a child, and here the delicate temporary teeth suffered no damage from the screws.

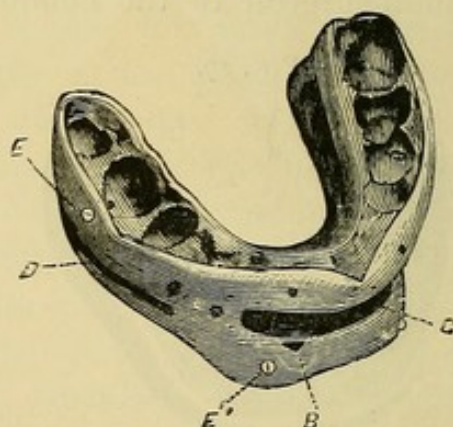
Mr. Gunning, of New York (*New York Medical Journal*, and *British Journal of Dental Science*, 1866), has contrived a form of interdental splint, composed of the vulcanite-rubber now in common use among dentists, which has yielded very satisfactory results in his hands, and of which the following is a condensed description.

Fig. 19 represents the inner surface of a splint which incloses all the teeth and part of the gum of the lower jaw, and merely rests against the upper teeth when the jaws are

closed. This splint is adapted to the treatment of all cases which have teeth on both sides of the fracture, except those with *obstinate* vertical displacement. The holes marked *A* go through the top of the splint, for the purpose of syringing the parts within with warm water during treatment. The dark round spots in all the cuts represent holes for similar purposes.

Mr. Gunning has generally used this splint without any fastenings, but in children, or even adults, it is sometimes advisable to secure it by packthread wire screws passing into or between the teeth, or by the wings and band of Fig. 21.

FIG. 20.



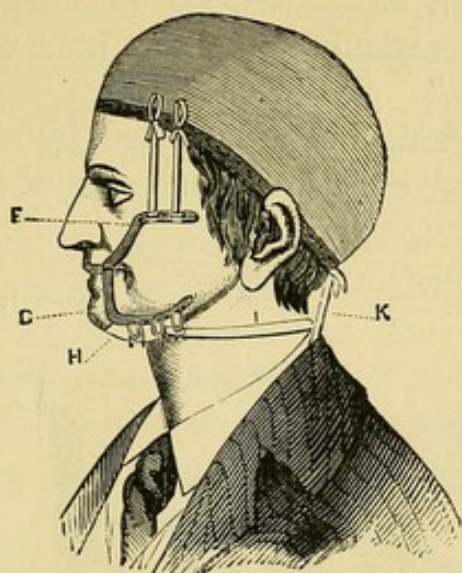
In cases with obstinate vertical displacement, the splint, in addition to fitting the teeth and gum of the lower jaw, must also enclose the upper teeth, as shown in Fig. 20, where screws may be seen opposite both the lower and upper teeth.

By this arrangement the fragments of the lower jaw are secured, not only relatively to each other, but also to the upper jaw. *B* is a triangular opening, of which one side corresponds to the cutting edge of the lateral incisor, which stood in the end of the fragment most displaced before the splint was applied. *C*, an opening for food, speech, &c. *D*, a channel for the saliva from the parotid gland to enter the mouth, its fellow being seen on the other side of the splint. *E*, a screw opposite the lower canine tooth, the end of the fellow screw being just discernible. *F*, the head

of a screw opposite the upper first molar tooth, the end of its fellow being seen on the other side.

This method can be used in cases where there are no

FIG. 21.



teeth, but has to be modified. Attached to the splint are metal wings, coming out of the mouth by means of which the splint can be firmly fixed to the head (Fig. 21). In such cases, however, it is probably better not to employ an interdental splint.

FIG. 22.

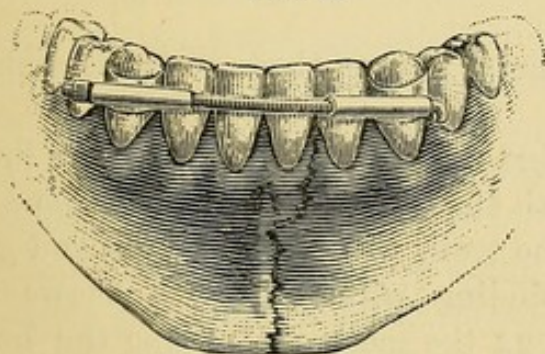
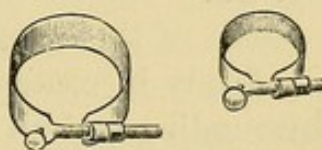


FIG. 23.



An ingenious method has been devised by Dr. Angle, of Minneapolis, but it could be employed only by those thoroughly practised in mechanical dentistry. He divides cases of fracture into two chief classes.

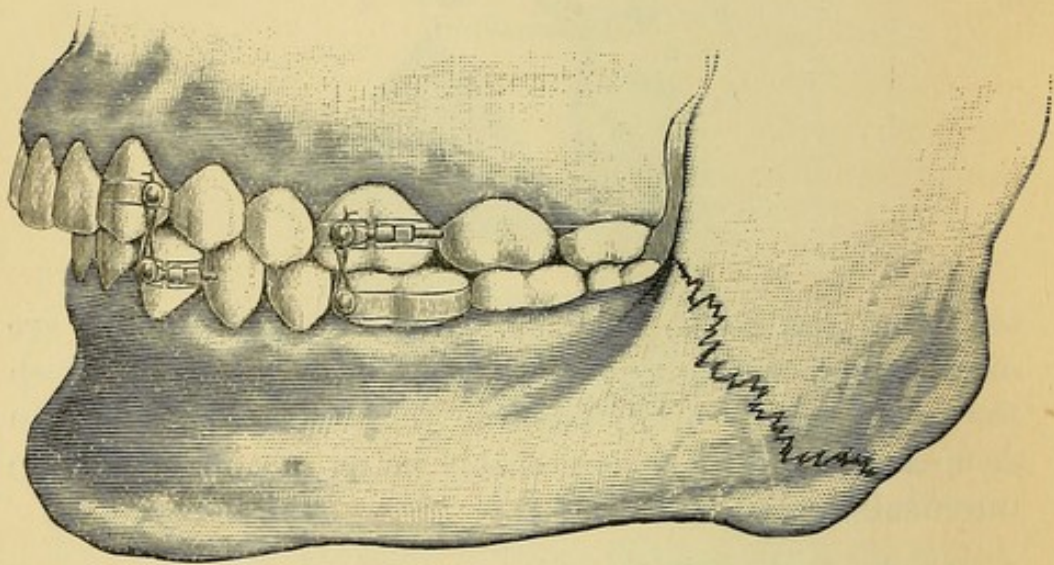
"The first class comprises all cases of simple fracture in which the teeth are good, especially on each side of the

region of the fracture. They should be sufficiently sound and firm in their attachments to afford good anchorage for the appliance which supports the fracture.

"The second class comprises all fractures where the teeth are unsuited, from any cause, for anchorage, but sufficient to give a correct articulation of the jaws when they are in proper apposition."

Cases of the first kind are treated by carefully fixing a silver band around a tooth on each side of the fracture, and

FIG. 24.



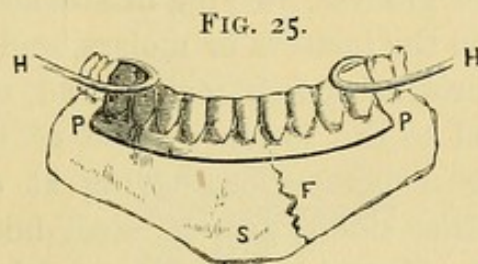
then soldering a small metal pipe to those bands as seen in Fig. 22.

Cases of the second kind are treated by keeping the lower jaw firmly in contact with the upper jaw. This is done by surrounding certain of the teeth with metal bands, and connecting them by fine binding wire. Fig. 23 shows the fracture bands, and Fig. 24 the method of fixing the lower jaw.

"It might be urged, as an argument against this method, that the teeth being closed, and the jaws being firmly bound together, the patient would be unable to take sufficient nourishment. This, however, is untrue; for it rarely happens that a patient is found without some teeth missing,

thereby leaving abundance of space for the passage of the liquid foods ; and, even if all the teeth were sound and in perfect position, it has been proven there is plenty of space between the teeth, and behind the molars, and between the upper and lower incisors, for taking all nourishment necessary. Of course, in such rare cases, much more time would be necessary in taking nourishment." For further particulars of Dr. Angle's method the reader is referred to his paper in the *New York Medical Record*, May 31, 1890.

(c) *Combination of External and Internal Splints.*—The great difficulty, in using any form of rigid splints to the jaw, is the tendency of the support for the chin to produce abscess and ulceration by pressing upon the sharp border of the bone ; and the cases in which a simple interdental splint would not effect a cure must be rare.



Mr. Howard Hayward has been very successful in treating cases of fracture of the jaw, of both recent and old date, by silver caps, fitted accurately to the teeth on each side of the fracture, and also over the gum to the depth of half an inch in front and a quarter of an inch behind them (Fig. 25). To the upper surface of the plate two pieces of stout curved wire are soldered, so as to turn round the angles of the mouth without touching them, and these are attached to a simple gutta-percha splint, moulded externally to the jaw, and retained in position by an ordinary four-tailed bandage. Holes drilled in the metal cap, opposite the point of fracture, permit of the exit of any discharge, but this is usually insignificant in quantity when the fracture is once properly set. Mr. Hayward prefers metal to vulcanite or gutta-percha for the cap, on account of its small bulk, and the consequent small interference with the natural closure of the mouth—a

point of some importance, on account of the retention of the saliva.

Mr. J. B. Bean, of Atlanta, Georgia, appears to have employed a vulcanite interdental splint very similar to Mr. Gunning's, but with the addition of a mental compress, with great success among the wounded soldiers of the Confederate army, and his apparatus is very favourably reported upon by Inspector-General Covey (*Richmond Medical Journal*, and *British Journal of Dental Science*, 1866). Hamilton also speaks well of the apparatus in the fourth edition of his work on "Fractures," and gives an illustration.

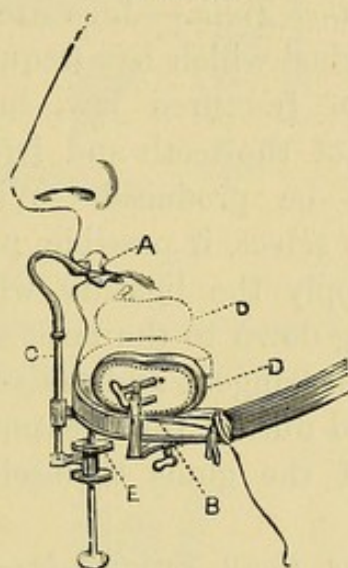
A combination of external and internal splints was invented by Rutenick, a German surgeon, in 1799, and improved by Kluge. It is thus described by Dr. Chester (*Medico-Chirurgical Review*, vol. xx, p. 471): "It consists, 1st, of small silver grooves, varying in size according as they are to be placed on the incisors or molars, and long enough to extend over the crowns of four teeth; 2nd, of a small piece of board, adapted to the lower surface of the jaw, and in shape resembling a horse-shoe, having at each horn two holes, one on either side; 3rd, of steel hooks of various sizes; each having at one extremity an arch for the reception of the lower lip, and another, smaller, for securing it over the silver channels on the teeth, and at the other end a screw to pass through the horse-shoe splint, and to be secured to it by a nut and a horizontal branch at its lower surface; 4th, of a cap or silk nightcap to remain on the head; and 5th, of a compress corresponding in shape and size with the splint. The net or cap having been placed on the head and the two straps fastened to it on each side, one immediately in front of the ear and the other about three inches farther back, which are to retain the splint in its position by passing through the two holes in each horn; a silver channel is placed on the four teeth nearest to the fracture, on this the small arch of the hook is placed, and the screw end having been passed through a hole in the splint, is screwed firmly to it by a nut, after a compress has been placed between the splint and the integuments below the jaw. If there is a

double fracture, two channels and two hooks must of course be used."

Bush invented a similar apparatus in 1822, and Houzelot in 1826; since which the apparatus has been variously modified by Jousset, Lonsdale, Malgaigne, and perhaps others.

Lonsdale's apparatus, as the late Mr. Berkeley Hill remarked (*British Medical Journal*, March 2, 1867), "is only suited to cases of fracture between the incisors, as its ivory cap is too short to reach far along the arch of the teeth. It

FIG. 26.



is also very cumbrous; and causes great pain by the pressure under the chin necessary to keep the fragment in place, and by the jogging of the vertical part against the sternum."

Fig. 26 shows this apparatus somewhat modified by Mr. Hill. In the ordinary Lonsdale's apparatus, the rod carrying the ivory cap (A) for the incisors slides freely up and down a bar projecting downwards from the chin-piece (B), and, when in the required position, is fixed by a pin. Mr. Hill had a screw thread cut on the bar, on which a nut (E) travels so as to force down the rod carrying the cap (A), and thereby approximate the cap on the incisors to the chin-piece.

When this apparatus is to be applied, the fragments are placed in position by the hands, the ivory cap set on the incisors, and the chin-piece, which should be well padded

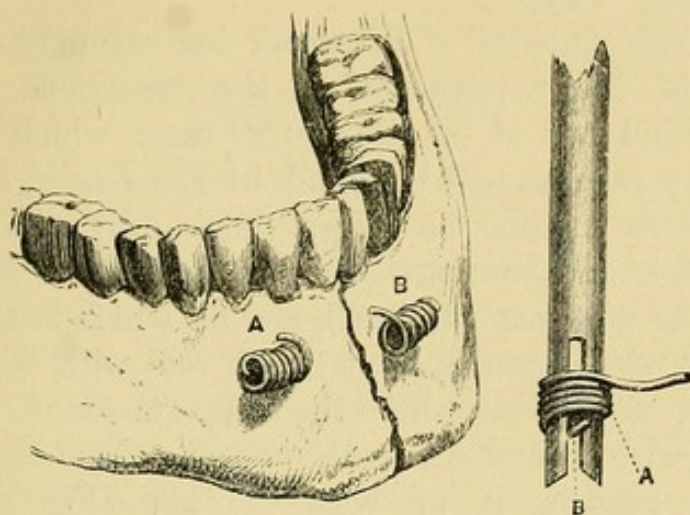
with lint or wool stitched in wash-leather, brought up into place under the jaw, and the two made fast. The two cheek-pieces are then adjusted so as to press lightly on the jaw at each side, to prevent the apparatus from swaying aside out of place; and a tape is fastened to a hole at each end of the horse-shoe, and carried behind the neck, to keep the instrument from slipping forwards. So applied, Lonsdale's apparatus permits opening of the mouth for eating and speaking; and, if the fracture be single and between the incisors, it keeps the fragments in position very fairly.

3. *Ligature of the Teeth*.—Ligature of the teeth, with silk or wire, is a method which has frequently been employed for the treatment of fractured jaw, but is unsatisfactory, from the loosening of the teeth and irritation of the gums which are apt to be produced. When employed, care should be taken to select, if possible, perfectly sound teeth around which to apply the ligature, which should be prevented from sinking down to the neck of the tooth so as to cut the gum. An astringent and antiseptic wash should be frequently employed during the treatment, to maintain the healthy firmness of the gums themselves and to prevent decomposition.

4. *Wiring of the Bony Fragments*.—Suture of the jaw itself has been employed from time to time for the treatment of both recent and old fracture, and to insure the union of the two halves of the bone after its division for removal of the tongue by Syme's method. Dr. Kinloch of Charleston treated, in 1858, a case of compound oblique fracture of unusual form, which has been already referred to (p. 5), by this method, after other means had failed. "A semi-lunar incision, about two inches long, was made upon the side of the face, the middle of the incision reaching under the base of the jaw. With Brainard's smallest-sized drill a perforation was made through each fragment, the drill being entered on the outside, close to the base of the bone, and about one-eighth of an inch from the rough extremity of each fragment, and made to traverse the bony

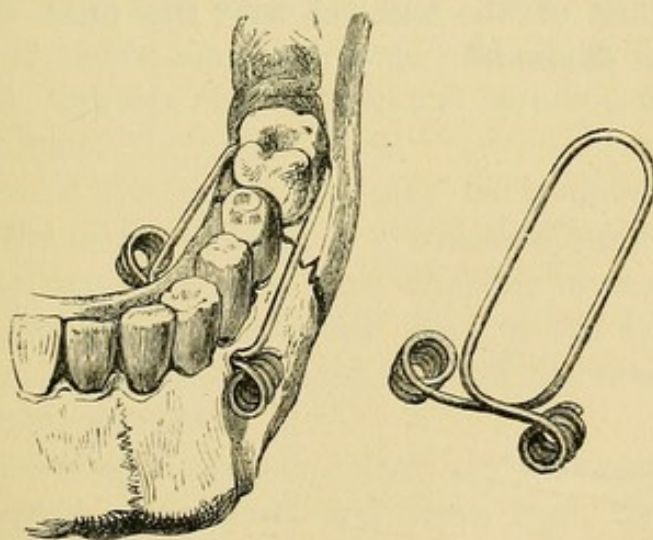
tissue and the mucous membrane covering it within the buccal cavity. The drill was afterwards thrust between the fragments and turned about, so as to lightly lacerate the

FIG. 27.



intermediate connecting tissue. A stout silver wire was then passed through the perforations in the bone, from without inwards through the posterior fragment, and in the

FIG. 28.



contrary direction through the anterior one ; and their ends were tightly twisted together, so as to bring the fragments into secure apposition.

“By the 26th of September good consolidation was effected

and the suture, which had occasioned but little suppuration, was untwisted and removed. On the 15th of October the patient left the hospital, with the fistulous opening healed and a good use of the jaw."—*American Journal of Medical Sciences*, July 1859.

Mr. Hugh Thomas of Liverpool has strongly advocated the use of the wire-suture in the treatment of recent fractures, and two of his illustrative cases, which had most satisfactory results, will be found in *The Lancet*, Jan. 19th, 1867. This method has been more fully elucidated in a pamphlet, and consists either in drilling the fragments and passing a copper wire, each end of which is then coiled upon a "key" formed by a steel rod with a slit in it (Fig. 27); or, in cases where the teeth are sound, in passing a loop of wire around the teeth on each side of the fracture, and then twisting it up with the key (Fig. 28). The advantage of this method is that the wire can be tightened from time to time, as may be required during the treatment, without liability to breakage. I have employed it in a case of division of the jaw for removal of the tongue, with advantage; and my friend Mr. Rushton Parker of Liverpool speaks highly of the method as "the most simple and effectual yet devised."

CHAPTER IV.

FRACTURE OF THE UPPER JAW.

FRACTURES of the upper jaw are not nearly so common as those of the lower, though their results are often more serious, owing to the great violence necessarily undergone. As in the lower jaw, fractures of the alveolus may result from the extraction of teeth, and particularly from the use of the "key;" and so well ascertained was this fact, that in former days even, when the key was recommended and employed extensively, Mr. Thomas Bell ("On the Teeth," p. 301) proscribed its use in extracting the upper wisdom teeth, on account of the danger of producing fracture of the tuberosity of the maxilla, against which the fulcrum would rest. A fracture thus produced may extend to the palatine process, and even to the palate bone, and might, if extensive, give rise to necrosis and subsequent exfoliation of large portions of bone.

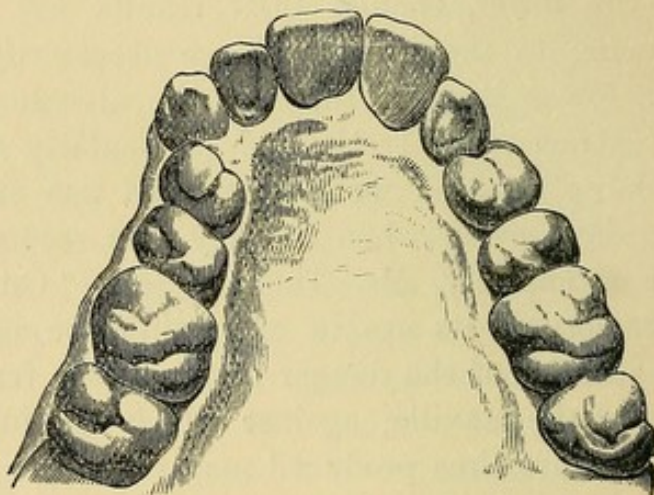
Fractures of the upper jaw may be produced indirectly by falls on the face; thus Liston ("Practical Surgery," p. 55) narrates the case of a man who, slipping on a slide in the street, fell and struck the *malar* bone of the left side; he had sustained a vertical fracture through the orbital process of the superior maxilla.

Direct blows upon the bone itself are, however, the most frequent causes of fracture, and these, from the nature of the injury, are often compound.

Mr. James Salter has recorded a case (*Lancet*, June 16th, 1860) of a young gentleman who sustained a fracture of the upper jaw from violent contact with a fellow-cricketer's forehead. Here fortunately none of the incisor teeth were

knocked out, as so frequently happens in accidents of the kind; but a fracture of the bone was produced immediately behind the right canine tooth, which extended backwards so as to include the alveoli of the bicuspid and first molar teeth, which were driven inwards towards the median line to the extent of about one-third of an inch, as seen in the drawing (Fig. 29). There was a corresponding depression on the outer side of the jaw, and this was somewhat apparent also on the face. Very little swelling followed the injury, and there was not much pain except on manipulation. The

FIG. 29.



Drawing from the plaster cast of the upper jaw, inverted.

principal inconvenience was due to the want of proper apposition of the teeth of the two jaws, and the mouth consequently could not be closed satisfactorily. On endeavouring to force the displaced bone into its proper situation, considerable pain was produced; it could not be completely reduced, and resumed its former position as soon as pressure was withdrawn. Distinct crepitus was felt during this manipulation.

Mr. Salter succeeded in overcoming the tendency of the fragments to displacement by the adaptation of a gold plate (Fig. 30) to it and to the adjacent teeth, and a complete cure was the result.

The kick of a horse often inflicts most serious injuries upon the upper jaw, and of this the classical case recorded

by Richard Wiseman, in his "Chirurgical Treatise" (1794), is a good example. Here a boy, eight years old, received such a blow on the middle of his face, that he appeared at first dead, and afterwards lay in a prolonged coma. "When I first saw him," says Wiseman, "he presented a strange aspect, having his face driven in, his lower jaw projecting forward; I knew not where to find any purchase, or how to make any extension. But after a time he became sensible, and was persuaded to open his mouth. I saw then that the bones of the palate were driven so far back that it was

FIG. 30.

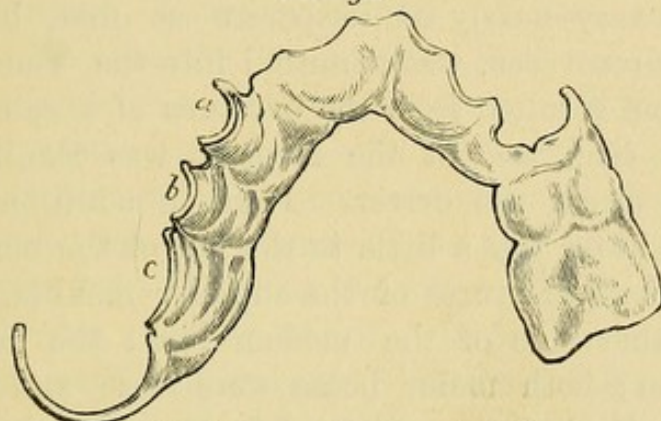


Illustration of the gold plate or splint; *a*, *b*, and *c* corresponding to the first and second pre-molars and first molar respectively.

impossible to pass my finger behind them, as I had intended, and the extension could be made in no other way. I extemporised an instrument, curved at its extremity, which I engaged behind the palate, and having carried it a little upward used it to draw the bone forward, which I did without any difficulty; but I had hardly withdrawn the instrument when the fractured portions went back again. I then contented myself with dressing the face with an astringent cerate to prevent the afflux of the humours; I likewise prescribed bleeding; and some hours afterwards I had an instrument better constructed to reduce the large mass of displaced bone to its proper position. I had it held by the child's hand, by that of its mother, or of an assistant, each for a certain time. Nothing else was done. Thus by our united attention the tonicity of the parts was maintained; the callus was developed, and in proportion as it became

solidified the parts became stronger, the face assumed a good appearance, certainly better than could have been hoped for after such marked displacement, and the child was entirely cured."

The most frightful injury to the face (except from gunshot wounds) I ever witnessed, was from the passage of a waggon wheel over the face of a man who fell in the street. Here the bones were completely shattered and the maxillæ were torn from one another, and death was instantaneous. A cast of this frightful deformity is in the museum of the Westminster Hospital.

A case very nearly as desperate at first, but which fortunately recovered, was admitted into the same hospital in 1860, and resulted from the overturn of a cab upon the face of its fare, who at the moment was leaning out of window to direct the driver. Here, in addition to a fracture of the lower jaw a little to the left of the median line, there were two fractures of the superior maxilla, about an inch on either side of the median line; the nasal bones were broken; both malar bones were loose and separated from their attachments, and the left bone was fractured, as also the external angular process of the frontal bone. Though not positively ascertained, the vomer was no doubt fractured, and probably the vertical plate of the ethmoid too. In Dr. Fyffe's report of the case (*Lancet*, July 18th, 1860) which I can confirm by personal observation, it is well noticed; "It was remarkable to observe how movable the bones of the face were. On watching the patient's profile whilst he was in the act of swallowing food, the whole of the bones of the face were observed to move up and down upon the fixed part of the skull, as the different parts were brought into motion; it appeared as if the integuments only retained them in their position. It was a curious feature in the case that notwithstanding the very extensive injury done, and the violent character of the force which caused them, not a single tooth was fractured or misplaced." This patient made a perfect recovery, and his treatment will be alluded to under another section.

Fracture of the upper jaw extending into the antrum may give rise to subsequent suppuration in that cavity, as remarked by Liston, but this is by no means a necessary consequence. A remarkable case of transverse fracture of the upper jaw, which communicated with the nose and with both antra, was formerly under Mr. Hutchinson's care in the London Hospital, in which perfect recovery took place without exfoliation of any part of the bone, although the alveolus containing all the teeth was completely separated and depressed about half an inch. Here the injury was the result of a "jam" between a "lift" and a cross-bar. (*Medical Circular*, February, 1867.) A very similar case occurred to Dr. Guentha, when a workman was struck in the face by the angle of a large mass of stone. Here there was complete separation of the alveolar process of the upper jaw, the entire arch in an unbroken state lying on the lower jaw, only suspended by some shreds of the gum and soft palate. This man also made a perfect recovery (*British and Foreign Quarterly Review*, October, 1860). In the summer of 1871 two patients were admitted into University College Hospital within a few hours of each other, in both of whom the superior maxillæ were fractured and freely movable. In one case perfect recovery ensued and death in the other, the post-mortem examination proving that there was no injury to the base of the skull.

In cases such as these, when there is obvious displacement, there can be no difficulty in the diagnosis of the fracture, but cases have no doubt frequently occurred where a fracture without displacement has been overlooked. Dr. A. Guérin has elaborately investigated this subject (*Archives Générales de Médecine*, July, 1866), and has shown from a preparation taken from a fatal case and from experiments upon the dead body, that violent blows below the orbits fracture not only the maxillary bones, but that the fracture usually extends to the vertical portion of the palate bone and the pterygoid process of the sphenoid, without producing the slightest displacement. The diagnosis of the injury cannot be established by any external manipulation, but by

carrying the finger into the mouth and pressing against the internal pterygoid plate, pain will be produced and mobility of the process will be ascertained. The diagnosis was confirmed in one of Dr. Guérin's cases which recovered, by an ecchymosis beneath the mucous membrane of the palate. In his fatal case he found fracture of the vertical plate of the ethmoid, in addition to the other injuries.

The nasal process of the superior maxilla has been fractured by blows which have also driven in the nasal bone, and in these cases emphysema of the cellular tissue of the face is not uncommon, and is best checked by the application of collodion. A complication of this form of fracture which has been met with, is permanent obstruction of the nasal duct, leading to subsequent troublesome epiphora, of which I have seen an instance.

Separation of the two maxillæ in the median suture has been seen in cases of fatal injury to the face, &c., on many occasions, but Malgaigne gives a case of the kind where the patient recovered. The patient, a man aged twenty-one, owing to a fall from a height sustained, in addition to other injuries, "a separation of the upper maxillary and palate bones in their median suture to the extent of nine millimetres, with depression of the entire left side of the face without any alteration of the soft parts." The parts came together spontaneously, and the patient recovered without deformity.

Hamilton, however, quotes a case from Harris, of New York, in which a child, two years of age, had separation of the maxillary and palate bones in the median line, the separation being sufficient to admit the little finger, and here the bones were still open six weeks after the accident.

Complications.—The teeth of the upper jaw may be broken or dislocated, as in the case of fracture of the lower jaw; but if merely loosened, should never be removed, since they will probably become again firmly attached.

Splintering of the bone is much more common in the upper than the lower jaw, particularly after gunshot injuries and here modern experience has shown the advisability of

leaving the fragments to become consolidated, as they almost invariably do, and the non-necessity for the performance of dangerous operations of resection of the fragments—a subject which will be again referred to.

Hæmorrhage is much more frequent and copious in fractures of the upper than in those of the lower jaw, as might be anticipated from the greater vascularity of the part. A case of fracture of both upper and lower jaws, where profuse hæmorrhage was caused by division of the facial artery, has been already referred to, but the hæmorrhage not unfrequently comes from the internal maxillary vessel and may be immediately fatal. Secondary hæmorrhage in case of severe injury to the upper jaw is by no means uncommon, and according to the Surgeon-General of the American Army (Circular No. 6, Washington, November 1st, 1865) was the principal source of fatality in these cases, ligature of the carotid artery having been frequently performed with the result of only postponing for a time the fatal event.

Nervous Affections.—Injury to the infra-orbital nerve and its branches must necessarily ensue in cases of severe fracture and comminution of the superior maxilla, and consequent numbness or modification of sensation will be the result. A lady, recently under my care, who fell down a flight of stairs and sustained severe injuries to the head and face, although no fracture of the jaw could be detected, suffers from partial anæsthesia and a pricking sensation in the skin below the orbit. Robert mentions (*Gazette des Hôpitaux*, 1859, p. 157) the case of a woman who was run over, and sustained a fracture with permanent paralysis of the infra-orbital nerve. Serious brain symptoms may ensue when the fracture runs back to the sphenoid bone as described by M. Guérin (p. 47), since the fissure may extend to the cranium, and this is especially likely to happen when the whole of the septum narium is driven back with the jaws.

Treatment of Fracture of the Upper Jaw.—Fractures of the upper jaw require but little treatment compared with those of the lower jaw, since the part is naturally so much more fixed that there is little difficulty in keeping the frag-

ments in position. The hæmorrhage, which is often free, must be arrested by cold, the application of styptics, and, as a last resource, the actual cautery. The operation of deligation of the carotid artery in these cases has yielded such unsatisfactory results as to render the surgeon unwilling to resort to it except under the most desperate circumstances, and he would in my opinion be justified in laying open the face and removing large fragments of bone so as to apply the cautery more satisfactorily, rather than resort to a dangerous and doubtful operation. When, as is most commonly the case, the soft tissues of the face are lacerated and the hæmorrhage arises from them, the bleeding vessels must be secured with ligatures in the ordinary manner.

All authorities are agreed as to the non-advisability of removing the fragments of a broken upper jaw, since, owing to the vascularity of the part, they almost invariably unite readily. Malgaigne says: "In common fractures of the upper jaw there is one principle which surgeons cannot too carefully bear in mind—that is, that all splinters, however slightly adherent, should be scrupulously preserved, as they become reunited with wonderful facility. This remark was made by Saviard; Larrey has strongly insisted on it, and we have seen that M. Baudens, who so much urges the extraction of splinters, has likewise made a special exception of these cases" (Packard's translation, p. 304). Hamilton remarks that the experience of American surgeons during the war confirms these observations. "Owing to the extreme vascularity of the bones composing the upper jaw, the fragments have been found to unite after the most severe gunshot injuries with surprising rapidity, the amount of necrosis and caries being usually inconsiderable compared with the amount of comminution" (p. 106).

Notwithstanding this, however, Hamilton gives a lengthy account of a case of fracture of the upper jaw, in which he, in conjunction with Dr. Potter, thought it necessary to remove a fragment, which included the floor of the antrum and had been drawn down and displaced in an attempt to extract a loose tooth. "The time occupied in this operation

was at least one hour, during which we were every moment in the most painful apprehension lest we should reach and wound the internal carotid artery, which lay in such close juxtaposition to the knife that we could distinctly feel its pulsation. After its removal the hæmorrhage was for an hour or more quite profuse, and could only be restrained by sponge compresses pressed firmly back into the mouth and antrum" (p. 103). Such dangerous operations are much to be deprecated, and cases already quoted prove that even after greater separation the bone will thoroughly reunite.

Mention has been made of the difficulty Wiseman experienced in reducing the fragments to their proper position in his case, and the means he adopted to overcome it. In the majority of cases the finger introduced into the mouth and passed around the alveoli will readily restore any irregularity, being aided, if necessary, by the introduction of a strong elevator or pair of dressing forceps into the nostril. The teeth in adjacent fragments may be advantageously wired together to keep them in position, or, where there is great comminution and irregularity of the alveoli, a piece of soft gutta-percha may be adapted to them so as to hold and support the fragments. The lower teeth should not be allowed to come in contact with this until it is thoroughly hardened, or they would become imbedded and thus cause its displacement. In very complicated cases, as in examples of fractures of both jaws, the vulcanite interdental splints of Mr. Gunning (described under Fractures of the Lower Jaw) might be employed, these having an aperture for the introduction of food.

Graefe employed an apparatus, of which the following description is given by Malgaigne (Packard's translation, p. 301): "A curved steel spring, properly padded, is applied over the forehead, and kept in place by a strap buckled around the occiput. This steel has at each side a hole with a screw for making pressure; and a steel brace to which it affords a *point d'appui*, for acting steadily on the dental arch. Now these braces, descending to the level of the free edge of the upper lip, curve backward so as to go around

the lip without wounding it; getting thus at the dental arch, they again curve so as to apply themselves to it. But as the pressure of the braces should have the effect of keeping the detached teeth in proper relation with the rest, a silver trough duly padded is made to fit over both to a sufficient length; and upon this trough the braces exert their pressure. It is easy to see how, by altering their height as regards the spring over the forehead, the pressure may be regulated to the right degree."

A somewhat similar apparatus, but with the addition of a pad which can be applied externally so as to support the cheek, was brought before the Surgical Society of Paris, in September, 1862, by M. Goffres.

In the rare cases of separation of the maxillæ, a spring passing behind the head and making pressure upon the maxillæ, after the manner of Hainsby's hare-lip apparatus, might be advantageously employed.

CHAPTER V.

GUNSHOT INJURIES OF THE JAWS.

GUNSHOT injuries of the jaws have necessarily been incidentally referred to in considering fractures of those bones separately, but it will be convenient to class the injuries of the two maxillæ by fire-arms together, since these accidents affect both bones in the majority of cases. Laceration of the soft tissues and consequent hæmorrhage are almost constant accompaniments of wounds of the face, and the mortality attending them is high, both from the immediate effects of the injury, and from the frequent occurrence of secondary hæmorrhage. The effects of the modern arms of precision contrast unfavourably in this respect with those of the round bullet of the old fire-lock, for though the latter frequently lodged in one of the cavities of the face for an indefinite time, the irregular mass of metal driven with tremendous velocity by the modern rifle commits greater havoc, splintering the bones and lacerating the soft tissues most extensively.

The Surgeon-General of the American army reported in November 1865 (Circular No. 6, Washington), that from the commencement of the war to October, 1864, of 4167 wounds of the face reported to him, there were 1579 fractures of the facial bones; and of these 891 recovered and 171 died, showing a mortality of 11 per cent.—the terminations being still to be ascertained in 517 cases. Secondary hæmorrhage was the principal cause of mortality in these cases, and the carotid had frequently been tied with the result of postponing for a time the fatal result.

The Crimean returns from the 1st of April, 1855 to the

end of the war, show 533 wounds of the face, of which the bones were injured in 107 instances; 445 patients returned to duty, 74 were invalided, and 14 died.

Here the mortality was about 13 per cent.

The following table is compiled from the experience of the Franco-Prussian war of 1870-71. Here the mortality was only about 8 per cent. among the German troops :

*Gunshot Wounds of Face in Franco-Prussian War,
1870-71. (German troops.)*

	Total Number of Cases.	Deaths.	Percentage Death-rate.
A. Soft parts of face . . .	647	7	1
B. Bones of face	1422	104	8

B. Bones of Face.	Total Number of Cases.	Deaths.	Percentage Death-rate.
Upper jaw	789	58	8
Lower jaw	400	35	9.3
Upper and lower jaw together	66	8	13.8
Nasal bones	89	0	0
Malar bones	64	3	5
Palate	14	0	0
Lachrymal			
Vomer			

It must be remembered that in all these wars antiseptic methods of treating wounds were not employed, and a large proportion of the deaths was due to septic processes taking place both inside and outside the mouth. Then, again, secondary hæmorrhage, a not infrequent cause of death in the past, occurs but rarely after surgical operations upon, or wounds of the jaws, at the present day. There is every reason to hope, therefore, that in any future war the death rate after gun-shot wounds of the jaws would be much smaller than 8 per cent.

Wounds of Upper Jaw.—In nearly all cases of gunshot wounds of the upper jaw, the soft parts of the face are

wounded as well. The only exception is in the case of suicidal wounds, where the weapon is fired through the open mouth.

In some cases the injury is limited to the upper jaw and the soft parts covering it, but very often the injury is much more extensive, involving the greater part of the face, the nasal and orbital fossæ, or even the cranial cavity.

When the injury is limited to the upper jaw, the alveolar process and the antrum are the parts usually involved, but sometimes the palate may be affected. Thus, Mr. Cox Smith, of Chatham, records the case of a soldier who came under his care, in whom the jaw and palate had been extensively fractured and the incisor teeth driven in, so that the patient was unable to masticate or speak. By extracting these teeth, Mr. Smith was able to adapt a set of artificial teeth, so as to restore to the patient the use of his mouth for all purposes.

Missiles, striking from without, occasionally lodge for a considerable time in the antrum or nose, and sometimes without their presence being suspected. In the "Medical and Surgical History of the Crimean War" will be found the case of a soldier who received a severe wound of the face. A grapeshot, weighing seventeen ounces, lodged in the jaw, having displaced the palate, with a portion of the maxilla and all the molar teeth of the right side, into the mouth. Here it was found necessary to enlarge the wound and remove the fragments (contrary to the general rule of practice) before the ball could be extracted, but the patient made a good recovery, notwithstanding severe secondary hæmorrhage. Still more remarkable, however, are cases which have occurred in civil practice, where the breech of a burst fowling-piece has lodged for years in the antrum. A remarkable case of this kind was reported in the *Edinburgh Medical Journal*, of September, 1856, by Dr. Fraser, of Newfoundland, who removed a piece of metal, weighing more than four ounces, and measuring nearly three inches in length, from the jaw of a man who had sustained an accident seven years before. A still more extraordinary case is recorded in the Museum of Guy's Hospital, which possesses a model of the breech of a gun which had been lodged in

the face of a man for twenty-one years! "The patient was shooting birds when the gun burst, the right eye was knocked out and the roof of the orbit destroyed, and through it the brain protruded; the latter sloughed, and, after a long illness, the man recovered. At the latter end of 1856 he was suddenly seized with symptoms of choking, as from a foreign body in the throat, and, on putting his finger in his mouth to remove it, he drew forth the breech of a gun, much oxidised and covered with purulent matter. It is supposed that the piece of iron broke through the floor of the orbit, and had been lodging in the antrum ever since."

In connection with this subject may be mentioned the case of a knife-blade lodged in the antrum for forty-two years, and finally coming out of the nostril, reported in the *Bulletino di Bologna*, May, 1864.

Gunshot wounds of the upper jaw through the mouth are usually of suicidal origin, and of this a specimen, presented by myself, is now in the Museum of the College of Surgeons, being the skull of a man who fired a pistol into his mouth. The red lines on the preparation mark the outline of the fracture, and it will be seen that a great part of the hard palate was driven in, and that the bullet, after fracturing extensively the base of the skull, carried away a considerable portion of the vault of the cranium. The malar bone, with the outer wall of the antrum, is broken off on the right side, and the malar bone on the left is separated from the maxilla at the articulation. In a second case of the kind, which I also had the opportunity of examining immediately after death, the injuries were similar in extent.

In the preparation referred to there is an oblique fracture of the lower jaw on the left side, running backwards through the socket of the first molar tooth, and an oblique crack has been produced on the inner surface of the right side of the bone, in an exactly corresponding position. Fracture of the jaw had occurred also in the second case alluded to, and has been frequently noticed under similar circumstances, the fracture depending upon the concussion of the explosion and the rapid development of gas within the mouth. This

is not without exception, however, since, in the University College Museum, there is the skull of a man who fired a pistol into his mouth, in which the palate is extensively damaged, but the lower jaw perfect. When the bullet actually enters the mouth the injury is usually immediately fatal, but Otto Weber has recorded (*Handbuch der Allgemeinen und Speciellen Chirurgie*, Part III., 1866) a case of recovery :—"The patient, through despair arising from pecuniary embarrassments, determined to shoot himself in the churchyard. He held the pistol before his open mouth, and, after firing, fell senseless to the ground. After some time he came to himself, looked for his spectacles, which had fallen off his face, and made the gravedigger bring him to me. The palatal vault was simply perforated, and the ball, completely flattened, was sticking in the body of the sphenoid bone, where it could be felt by the index finger introduced into the hole by which it had entered. After some fruitless attempts to extract it, it fell into the patient's throat and he spat it out. Subsequently the hole in the palate completely closed up again, and the patient recovered both physically and morally." In this case the lower jaw does not appear to have suffered, but Mr. Barrett has shown me the model of a case in which a pistol bullet, fired at the open mouth, glanced off an incisor tooth, and ran up the side of the face, emerging near the malar bone, and where nevertheless the lower jaw was broken by the explosion.

I was once called in by Dr. Whitmarsh, of Hounslow, to see a patient who had fired a pistol, loaded with small shot, into his mouth, smashing the palate and fracturing the lower jaw in two places by the explosion, but who eventually made a good recovery; and in the *Lancet*, Nov. 7th, 1868, will be found a remarkable case under the care of Mr. Sydnev Jones, of recovery after a similar injury, complicated by division of one optic nerve and injury to the brain.

Because a bullet has entered the mouth, and inflicted injury upon the bones of the palate, &c., it does not necessarily lodge there; thus, in the "Medical and Surgical History of the Crimea," is the case of John Collins, 97th

Regiment, who was wounded on Sept. 8th and sent to hospital on the 14th, having been struck by a musket-ball, which had entered the mouth, slightly cutting the upper lip, and had comminuted the palate plate of the superior maxilla, and appeared to be lodged somewhere among the ethmoid cells. There was but little constitutional disturbance. All the incisor teeth of the upper jaw became dead, and had to be removed, as well as some fragments of the palate plate, but the wound slowly healed and finally filled up, leaving the man but little the worse, except for the loss of his teeth. Various careful examinations, made at different times, failed to detect the presence of any foreign body, and the man himself afterwards stated that he had always fancied the bullet fell out during his progress from the trenches to the regimental hospital.

Complications of gunshot wounds of the upper jaw may be divided into immediate and remote. The most serious immediate complication is hæmorrhage, which usually takes place from the internal maxillary artery. The next, in order of severity, is suppuration, both intra- and extra-buccal. One of the gravest dangers in suppuration is the poisoning produced by the constant swallowing of foul pus. By the assiduous use of antiseptics this danger can be much lessened.

Other less important complications are injuries to branches of the facial nerve or of the infra-orbital nerve. In some cases Stenson's duct is wounded, and may cause trouble by the salivary fistula that forms.

In an interesting paper by Dr. Ludwig Brandt (*Beiträge zur Behandlung der Schussverletzungen der Kiefer und deren benachbarten Weichtheile*. Berlin, 1892) it is pointed out that a very frequent result of gunshot wounds of the upper jaw is deficient mobility of the lower jaw, the condition known as "closure of the jaws" (chap. xxvii). This fixation of the lower jaw is brought about by the healing of extensive wounds of the mucous membrane of the mouth or of the external soft parts. The contraction of the cicatricial tissue draws the lower jaw up

towards the upper jaw and prevents the proper opening of the mouth.

We may say that this is the most serious remote complication of gunshot wounds of the upper jaw.

Wounds of the Lower Jaw.—Fracture of the lower jaw alone may be produced by bullets, and in this case the hæmorrhage is often severe from the divided facial artery, which vessel is generally involved. In the *Edinburgh Medical Journal*, September, 1860, Dr. John Brown, of the Bengal Medical Service, records four cases of the kind, which are good examples of the variety of injury inflicted by a bullet :

1. Was a gunshot injury of the jaw, attended by profuse hæmorrhage. The facial artery was secured, and a large portion of the comminuted bone removed. The patient did well.

2. Was a gunshot wound at the symphysis. There was a depression in the bone at the spot, but the ball had not perforated it. Did well.

3. Occurred in Lucknow. A Sikh was shot in the right side of the lower jaw ; there was great arterial hæmorrhage from the facial artery, with a small wound over the angle and a larger one over the symphysis. Both were laid into one, fragments were removed, and the facial artery tied. Died on twelfth day.

4. Ball traversed the mouth and fractured both sides of the lower jaw near the angles. Died from pyæmia on twenty-first day.

The catalogue of the Surgical Section of the United States Army Medical Museum (1866) contains numerous records of injuries of this kind, from which the following may be quoted as most remarkable :

“ 3350. The right half of the inferior maxilla fractured by a musket-ball, a small portion of which is attached. The missile entered the mouth, struck the alveolar ridge at the molar teeth, comminuting it, and causing oblique fracture of the body of the bone. The patient died the same day from hæmorrhage, from rupture of the internal maxillary artery.

"1451. Wet preparation of the right side of the body of the inferior maxilla, fractured and comminuted by a musket-ball at the angle. A fragment containing the molar teeth is driven inward, and other fragments remain *in situ*, the total amount of bone shattered being two inches. The ball lodged in the thyroid cartilage, causing death by suffocation on the nineteenth day.

"3542. The inferior maxilla fractured and comminuted by a musket-ball. The alveolar ridge and the teeth are entirely removed; there is a horizontal fracture of the left ramus passing through the inferior dental foramen; on the right side there is a transverse fracture of the body of the bone at the last molar, and an oblique vertical fracture at the symphysis. The patient died from the effect of the wound of the tongue, causing hæmorrhage, for which the left common carotid was ligated."

A fracture may possibly be produced indirectly without the bullet actually striking the jaw; of this the following extraordinary instance occurred at the battle of Balaclava. A man of the 4th Light Dragoons received a compound fracture of the lower jaw by a grape-shot striking the flat of his sabre, while at the slope, and driving it against the side of his face and head. The blade was bent, but not broken, and the missile did not touch the man.

Fragments of the jaw have been driven into other parts of the body, and even into that of a neighbour. In the "Medical and Surgical History of the Crimean War" is reported the case of a soldier who was shot in the right cheek, the ball glancing downwards and lodging in the neck, from which it was extracted. Subsequently a foreign body was detected behind the right clavicle, which was cut down upon and proved to be a portion of the lower jaw. Hamilton, also, in his "Military Surgery" (p. 255), mentions the case of a Confederate soldier, who was kneeling and bending forward when he received a rifle ball upon his four lower incisor teeth. The ball and teeth disappeared, but were subsequently removed from beneath the skin at the top of the sternum.

As in the case of the upper jaw, the most serious immediate complication of gunshot wounds of the lower jaw is hæmorrhage. It has been already mentioned that this frequently takes place from the facial artery, but it may also take place from the inferior dental, lingual, or transverse facial vessels. In the American war it was especially noted that by no means infrequently the carotid vessels were wounded.

Septic inflammation again, occurring after wounds of the lower jaw, may be just as serious as in the case of the upper jaw.

When the middle part of the lower jaw is fractured, the tongue tends to fall backwards, and may cause asphyxia. This can be easily prevented by passing a ligature through the tongue, and so fixing it that the tongue is prevented from falling backwards.

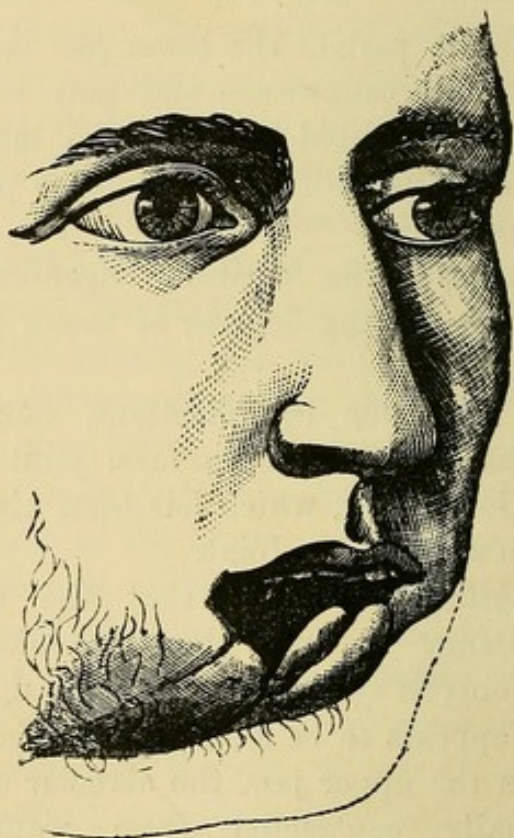
Further, branches of the facial or trigeminal nerve may be divided, causing varying degrees of motor paralysis or of anæsthesia.

As regards the later complications, one of frequent occurrence is the formation of a false joint after gunshot injuries of the lower jaw, which has been already adverted to in the section upon False Joint.

Another important result is that the muscles have a constant tendency to draw the two sides of the jaw together. Not only is this effect produced upon the lower jaw, but there appears to be a secondary effect produced in these cases upon the upper jaw, the alveolar arch of which becomes gradually contracted from want of proper antagonism. M. Debout, in the paper already referred to, gives the case of a French corporal, who, during the Italian campaign, was wounded by a fragment of shell, which fractured the lower jaw and severely lacerated the integuments. The comminuted fragments were removed, and the soft parts brought together with sutures, so as to restore as far as possible the floor of the mouth. All that could be obtained, however, was to form a sort of channel concealed by the beard, as shown in Fig. 31, by which the saliva flowed in great abundance.

Complete or nearly complete destruction of the lower jaw by a cannon-ball has more than once occurred, the patients surviving for many years, and the deformity being palliated by the use of a silver chin (Fig. 32). The accompanying illustration (Fig. 33) from M. Debout's paper, shows the dissection of a case of the kind more than thirty years after the receipt of the injury, the history being as follows:—At the battle of Jena, Vernet had the body and left ramus of

FIG. 31.

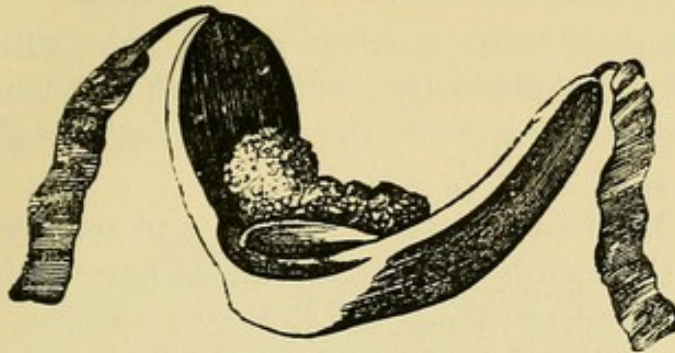


the lower jaw carried away by a cannon-ball. The soft parts, bruised and torn, hung down in front of the neck, and the tongue was much injured from the tip along the left side. At the ambulance the parts were adjusted as well as possible, and the dressing completed. An abundant suppuration ensued; splinters were detached from the extremities of the bones, and the whole was healed in three months.

Ribes, in 1818, described thus the condition of the parts when Vernet had attained the age of forty-four:—"The soft

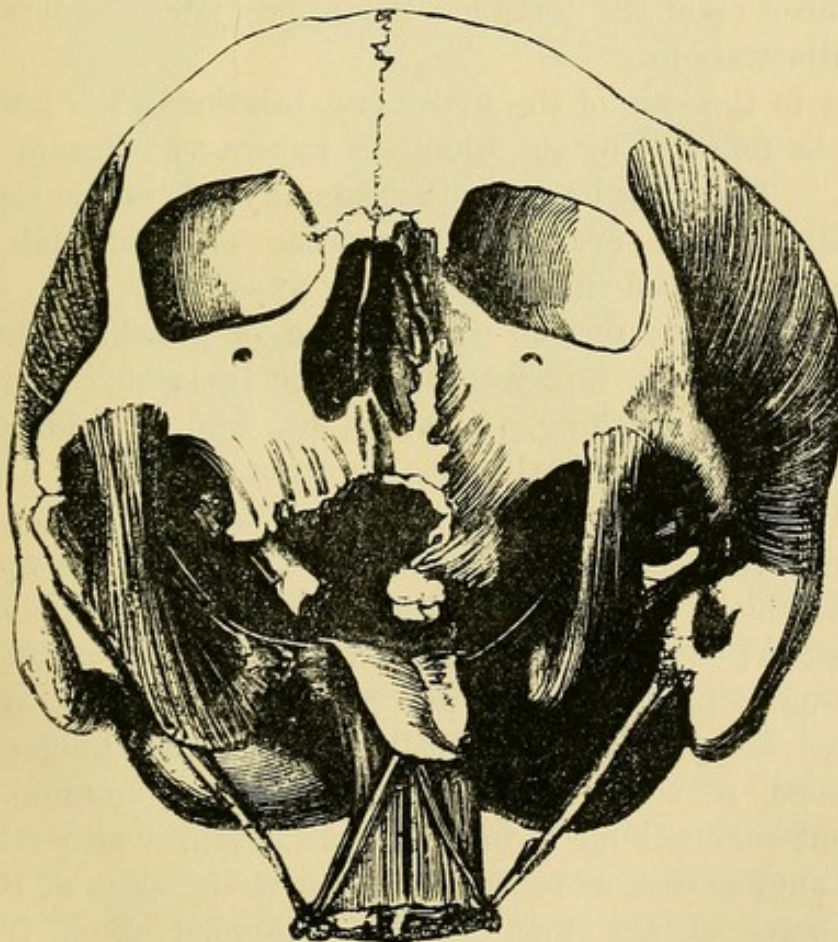
parts and loose flaps of the lips, chin, and cheeks have become agglutinated at the upper part of the neck, above

FIG. 32.



and to the side of the larynx at the root of the tongue, where they form by their adhesion divers folds and cicatrices.

FIG. 33.



The opening—the mouth—is situated beneath the arch of the palate; the tongue lies concealed in the soft parts, and

retracted towards the pharynx; the lower part of the tongue is closely adherent, and in a manner fixed to the parts beneath it, so that the tip can be projected only to the left and not forwards.

"The patient wears a silver double chin, with which he can speak pretty distinctly; but is much inconvenienced by the incessant escape of the saliva."—*Dict. des Sciences Médicales*, tom. xxix, p. 425.

Vernet lived twenty years longer; and some years before his death the mouth-opening became so narrow that, instead of being obliged to change the cloths or sponges, into which the saliva used to flow, five or six times a day, he scarcely wetted one.

In this case the steady contraction of the cicatricial tissues of the mouth had a beneficial tendency. The effect produced upon the teeth of the upper jaw is well seen in the illustration.

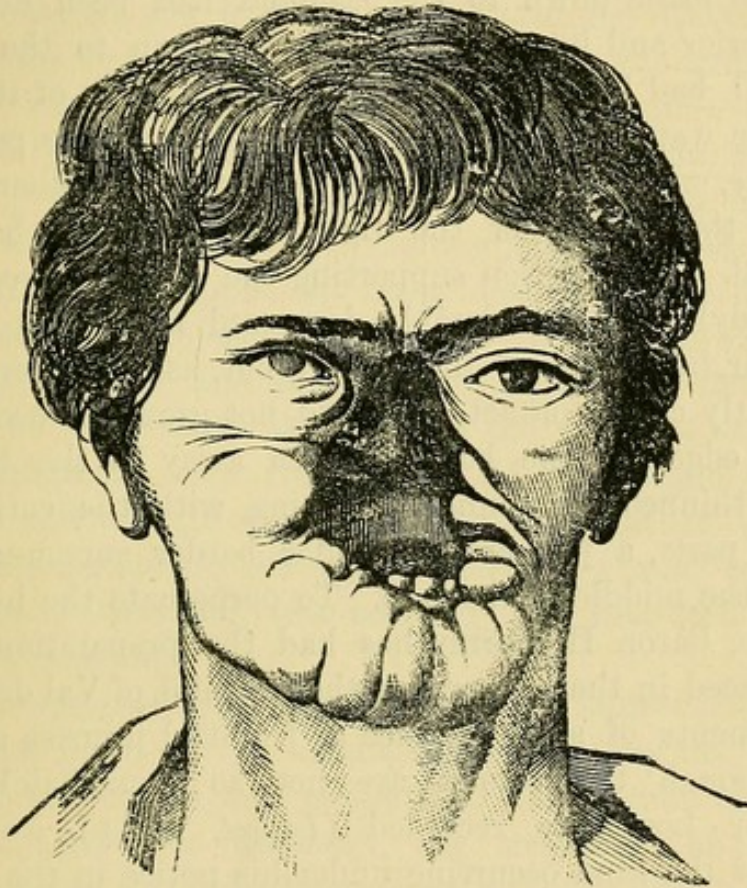
As in the case of the upper jaw, injuries of the lower jaw may be followed by the condition known as "closure of the jaws." This may be due either to ankylosis of the temporo-maxillary joint or to the formation of cicatricial bands, already described in wounds of the upper jaw.

Another very serious complication of gunshot wounds of the lower jaw is injury to the lower lip, which may cause difficulty in speaking, in eating, &c., and in addition the saliva may be constantly escaping from the mouth.

Wounds of Upper and Lower Jaws.—Cannon shot, striking the face, inflict the most frightful injuries upon the jaws, which are usually fatal; thus, Professor Longmore mentions ("System of Surgery," vol. i) the case of an officer of Zouaves in the Crimea, who had the whole face and jaw carried away by a cannon-ball, the eyes and tongue being included, so that there remained only the cranium. The patient survived for twenty hours. Guthrie also relates a very similar case, as having occurred at the siege of Badajoz. The wars of the first Napoleon afforded some frightful examples of injury to the jaws, which the unfortunate patients survived for years in one of the military asylums of

Paris. The accompanying drawing (Fig. 34), taken from an able paper by M. Emile Debout, "On the Mechanical Restoration of the Maxillæ" (*British Journal of Dental Science*, April, 1864), shows the condition of a corporal who was struck by a cannon-ball at the siege of Alexandria, in 1800. The shot carried away the greater part of the face, including three-fourths of the lower jaw and part of the

FIG. 34.



tongue, and the man was thought to be dead. Under the solicitous care of Baron Larrey he recovered however, and lived for more than twenty years. "It can be seen at a glance that speech and mastication were impossible. Poor Vauté concealed the deformity by wearing a mask, gilt inside, and imitating the colour of the skin outside. He could even by means of this cover make himself a little understood, but his greatest distress arose from the incessant escape of the saliva, which was so great as to saturate in succession a number of linen compresses in the course of the

day. After supporting his misfortune heroically for so many years, he put an end to his misery in 1821. In order to complete the history of a case in which he had felt so deep an interest, Larrey, on learning the death of Vauté, procured his head, the state of which he described.

"The loss of substance occasioned by the ball was limited to the elliptic segment seen in the portrait. The left malar bone had been carried away. The arch of the palate and the nasal fossæ down to the ethmoid had been destroyed. The inferior and internal orbital walls, down to the base of the skull, had been also destroyed. Two-thirds of the lower jaw were wanting. The right half of the middle portion of this bone, with three of the teeth, was found adherent to a part of the surface of the right ramus, which had been fractured. The portion supporting the coronoid process and the condyle was considerably depressed backwards to meet the other fragments of this bone; but, as they were not in sufficiently close contact, they had not grown to each other. All the edges of the bones broken away by the ball had become thinned and rounded, forming, with the corresponding soft parts, a puckered, irregular border surrounding the gulf in the middle of the face. To perpetuate the history of the case, Baron H. Larrey has had the preparation of the head placed in the museum of the Hospital of Val de Grâce."

Fragments of shell produce as frightful injuries as round shot, though the results are not so immediately fatal. Professor Longmore recorded (*Lancet*, 1855), a case of injury of the kind occurring under his notice in the Crimea, in which the right half of the palate was jammed in, and fixed at right angles to the other half, and the whole superior maxilla was much comminuted. The lower jaw was broken in three places, and there was extensive laceration of the soft parts. Great difficulty was met with, at first, in unlocking the parts of the palate which had been driven into each other, and when they were separated the right half hung down loosely in the mouth. The parts were carefully restored to position, and the patient made a good recovery without deformity.

A charge of small shot, if fired near enough to the face to do more than lodge in the skin or jaw-bone (of which there is a good example in the Middlesex Hospital Museum), will produce as serious injuries to the jaws as a bullet. In the *Lancet* of November 10th, 1860, is the report by Mr. Swete, of Wrrington, of a case of very severe injury to the jaws from a charge of "dust-shot," fired at a distance of four feet from the patient, a boy aged nine years. The charge entered the left side of the face, and passed out in front of the right ear, carrying away with it the greater part of the lower lip and jaw, and the whole of the chin. Several pieces of bone and teeth were picked up in an adjoining field, at a distance of ten yards. There was an extensive ragged wound of the face, extending nearly to the ear, the right half of the upper lip being destroyed, and the teeth and alveolus of the same side carried away. The lower jaw was shot away at the angle on the right side, and on the left, about an inch of the body of the jaw and one molar tooth remained. Mr. Swete trimmed the ragged edges of the jaw and brought the lacerated parts together, and, contrary to expectation, the patient recovered and, by means of a plastic operation, was restored to a condition of considerable comfort.

Treatment.—Owing to the enormous improvement that has taken place in the healing of wounds by the employment of antiseptics, and to the vast strides that have been made in prothetic dentistry, the treatment of gunshot wounds of the jaw has advanced considerably during the past twenty years.

It is, therefore, of great interest to read the following extract, taken from the official "Medical and Surgical History of the British Army in the Crimea," vol. ii, p. 305, as it illustrates the experience gained in that war, an experience that was to a considerable extent confirmed by that of the later American war:

"Wounds of the face, though presenting often a frightful amount of deformity, are not generally of so serious a nature as their first appearance might lead the uninitiated to

expect. The reason of this, apart from the fact that the face contains no vital organ, seems obviously to be the very free supply of blood which this part receives. From this cause the fleshy structures readily heal, and even the bones are so supplied that extensive necrosis rarely happens. The bone tissues, also, are softer than the long bones of the extremities, and we therefore but seldom here meet with long fissures and extensive necrosis as a result of concussion of bone, so often seen in them. This leads us to the very important practical inference, not in this situation, as a rule, to remove bony fragments, unless the comminution be great, or the fragment completely detached from the soft parts. Even partially detached teeth will often be found not to have lost their vitality and, if carefully readjusted, will become useful. There is indeed no great object beyond, perhaps, the present comfort of the patient to be attained in removing either fragments of bone or loosened teeth in the great majority of instances. If they die they become loose, and are readily lifted away without trouble to the surgeon, and but little pain to the patient. This observation is especially applicable to fractures of the lower jaw. Surgeons in this war have seen so many cases of badly-fractured instances of this kind unite, and that with a very small amount of deformity, that men of experience are now excessively chary of removing any portion of this bone, unless it has become dead, or the fragment is so situated as to interfere considerably with the adjustment of the remainder, or the bone so much comminuted as to give no probable hope of its becoming consolidated, or so sharply angular as to threaten further injury to the soft parts, or to interfere materially with their adjustment and retention *in situ*. In these fractures of the lower jaw, much less support and adjustment than we are in the habit of thinking advantageous in ordinary cases of fracture of it, will frequently be found necessary, or even admissible. A complicated apparatus cannot be borne at first, on account of the condition of the soft parts, and the application of slight support by a gutta-percha or Startin's wire splint, and a

split bandage, is all that can be done. Any attempt at ligaturing the teeth is very generally not only useless, but injurious, and it is surprising how the parts often as it were adjust themselves, with but little aid from the surgeon. One interesting case may be mentioned where the whole of the bone, from angle to angle, was so comminuted by gunshot that no choice was left but to remove the fragments. The injury to the soft parts was very considerable, and one difficulty, occasioned by the loss of all support in front—viz., the tendency of the tongue to fall backwards and close the opening of the glottis, well illustrated. The man, however, generally remedied this himself with his fingers, and nothing was done, or required to be done, on this account beyond carefully watching him. He naturally, as it were, adopted a position on his side, resting mainly on his forehead, so as to have the face as much in the prone posture as possible, and thus the weight of the organ assisted in keeping it in position."

The strong protest, in this report, against the extensive "trimming up" of comminuted fractures of the jaws was aimed at the treatment recommended by Dupuytren and Baudens. It must be borne in mind, however, that the advice of these surgeons in recommending the removal or rounding off of all fragments, was designed to prevent as much as possible the profuse and offensive suppuration that so often occurred when comminuted pieces of bone were left in the wound. At the present day, by the use of antiseptics this suppuration can be much diminished, and therefore the radical treatment recommended by the French surgeons is no longer necessary,

In the treatment of gunshot wounds of the jaws there are three essential points for our consideration :

1. *The Treatment of Loose Fragments.*—In cases where the fragments are quite separated from the jaw and are small in size it is better to remove them, but if the fragment be a large one, bearing as it often does one or more teeth, efforts should be made to preserve it by fixing it to the rest of the jaw, although the fragment may be com-

pletely separated. Where the fragments are united to the jaw or soft parts by shreds of tissue they should be preserved. The fractured surfaces of the jaw should not be rounded off, unless a very sharp spicule of bone is injuriously pressing into the soft parts.

2. *The Fixation of the Seat of Fracture* is usually a very simple matter if the fracture is not comminuted. A four-tailed bandage or a simple jaw splint generally answers admirably.

In cases of extensive fracture with comminution, the fixation may be a very difficult matter. Any complicated method, such as Hammond's wire splint, or the treatment recommended by Dr. Angle (see chap. iii. p. 35), is out of the question in the conditions under which military surgery is carried out. Probably the best method, under such circumstances, is a rapidly improvised gutta percha splint as recommended by Hamilton.

The application of a ligature of silk or wire to sound teeth on either side of the fracture may be advisable in some cases, but unless great care be taken the teeth may become loose, and undue mobility between the fragments ensue. When this method is employed, an external gutta-percha splint should be used also.

In many cases the injury to the soft parts may complicate the treatment very much and no definite rules can be laid down. The successful treatment of such cases depends upon the ingenuity and care bestowed upon them by the surgeon in charge.

3. *The after-treatment* of the case is concerned with the healing of the wound and the feeding of the patient. The wound must be irrigated or syringed out frequently during the day with antiseptic lotions, such as carbolic acid, permanganate of potassium, boracic acid, &c., and should be dusted over with a powder, a very useful one being a mixture of iodoform, creolin, and boracic acid in equal parts. The patient must be fed with liquid food, introduced, if necessary, into the pharynx by a tube.

The after-results of gunshot wounds of the jaws are

often very unsatisfactory. The great deformity produced by the contraction of the cicatricial tissue is very difficult to prevent, and it is only of recent years that attempts to obtain a better result have been followed by success.

For the advance of the knowledge in this direction we are chiefly indebted to MM. Preterre and Claude Martin. The principle adopted by these dentists is to insert a mechanical contrivance into the mouth as soon as possible after the infliction of the wound, in order to prevent the cicatricial tissue pulling the remaining portions of the jaw out of their place during the processes of healing. When the wound is sufficiently healed a suitable plate, bearing teeth if necessary, is fitted to the mouth. We thus see that the mechanical treatment is divided into two stages: immediate or temporary prosthesis, and secondary or permanent prosthesis. This method has not received a sufficient trial in this country for us to come to any definite conclusion, but it has been employed in France, apparently with excellent results. (*De la Prothèse Immédiate appliqué à la resection des Maxillaires*, par Claude Martin. Paris: Masson, 1889; *Traité de Chirurgie de Guerre*, par Delorme, vol. ii. Paris: Baillière, 1893.)

CHAPTER VI.

DISLOCATION OF THE LOWER JAW.

DISLOCATION of the lower jaw may be unilateral or bilateral, the latter being the more frequent variety, since of 28 cases of dislocation given by Giraldès, 15 were of both condyles; and of 76 cases given by Malgaigne, 54 were the same, 31 of these last being in women. Bilateral dislocation occurs most frequently in middle age, though it is not unknown in youth and old age; thus Sir Astley Cooper gives the case of a child, who experienced the accident from forcing an apple into his mouth, and both Nélaton and Malgaigne have met with it in old people of sixty-eight and seventy-two years of age. The possibility of dislocation of the jaw following traction on the chin with the finger or hook in delivery need be only alluded to, since the occurrence must be unknown, or nearly so, in the case of living children. The less frequent occurrence of the accident in the extremes of age may be explained, partly by the smaller liability of children and old people to external violence, and also by the fact that, owing to the obtuseness of the angle formed between the ramus and the body of the bone at those ages, the leverage of the jaw is diminished, and the muscles do not act in such vertical lines as in middle age. The explanation offered by M. Nélaton — viz., that in youth the coronoid processes are too short, and in old age directed too far back, to impinge upon the malar process of the upper jaw—appears to be untenable, and will be referred to in describing the pathology of dislocation.

Etiology.—In the majority of cases the immediate cause has been muscular action alone. By no means infrequent

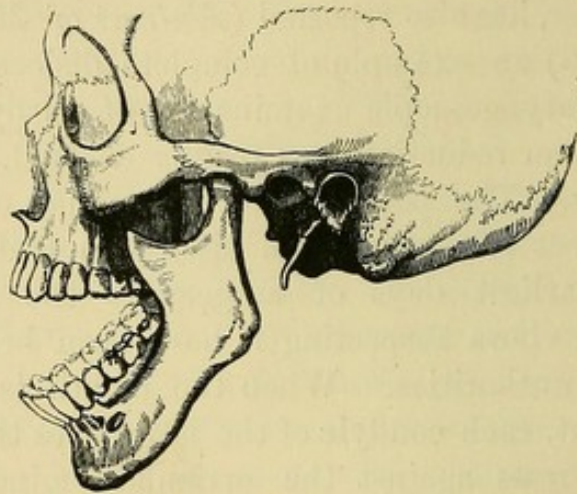
causes are yawning, vomiting, or shouting, in all of which actions the patient's mouth is opened to its fullest extent; or it may result from blows or the kicks of animals, and this is particularly the case with the unilateral form of the affection. Causes acting within the mouth may also produce dislocation—*e.g.*, the introduction of an apple, as in Sir Astley Cooper's case, already alluded to, or the introduction of the stomach-pump. Extraction of teeth, even in the most skilful hands, has been known to produce the accident, which has also been caused by the ordinary dental operation of taking a model of the lower jaw. (Salter, *British Journal of Dental Science*, July, 1871.) Dr. Guignier, of Montpellier, has also reported (*Abstract of Medical Sciences*, vol. ii, 1866) an example of complete dislocation occurring during the laryngoscopic examination of a lady, aged thirty-eight, in whom reduction was readily effected.

Pathology.—The pathology of dislocation of the jaw has been a subject of considerable discussion and investigation from the earliest days of surgery to the present time, and various views respecting it have been brought forward by different authorities. When the mouth is opened to its fullest extent, each condyle of the jaw leaves the true glenoid cavity and rests against the articular eminence and the inter-articular fibro-cartilage, which is drawn forward by the pterygoideus externus, the same muscle which advances the jaw itself. The articular eminence is covered by articular cartilage and by the synovial membrane reflected between it and the cartilage, and a second synovial membrane being placed between the cartilage and the condyle of the jaw, the necessary freedom of movement is insured. A cavity is thus left immediately behind the condyle, which can be readily felt in the healthy living subject, and which is only exaggerated in cases of dislocation. This forward movement of the condyle has been proved experimentally by C. E. Luce (*Boston Medical and Surgical Journal*, 1889), who has shown that the condyle may reach the summit of the eminentia articularis, or even get in front of it. This is contrary to the teachings of Morris, Humphrey, and

others, who state that the condyle never quite reaches the summit.

When the jaw is in this position, but a very slight force is needed to carry the condyle over the articular eminence and produce a dislocation, and this is brought about, either by a force applied to the chin, when, owing to the length of the lever, the result is readily induced; or by a spasmodic contraction of the external pterygoid muscles, which, as has been stated, are already in action. The lateral ligaments of the joints have no power to check this, and the few fibres

FIG. 35.



which surround the synovial membrane and form a loose capsule are easily stretched, but never tear. The accompanying illustration (Fig. 35) from Sir Astley Cooper's work on "Dislocations," shows the position of the bone at this period, but is wanting in the ligaments and inter-articular cartilage, which latter is ordinarily carried forward with the condyle. Immediately that the condyles are dislocated the masseter and internal pterygoid muscles contract, and draw the jaw forwards and upwards so as to produce the projection of the chin characteristic of the accident. This last muscular action was originally described by Petit, and has been denied; but has recently been confirmed by Heinlezn and Busch, who found experimentally on the dead body, that by replacing the muscles by india-rubber bands acting in the same direction as the muscles, the luxation could be in-

variably maintained and the characteristic deformity produced.

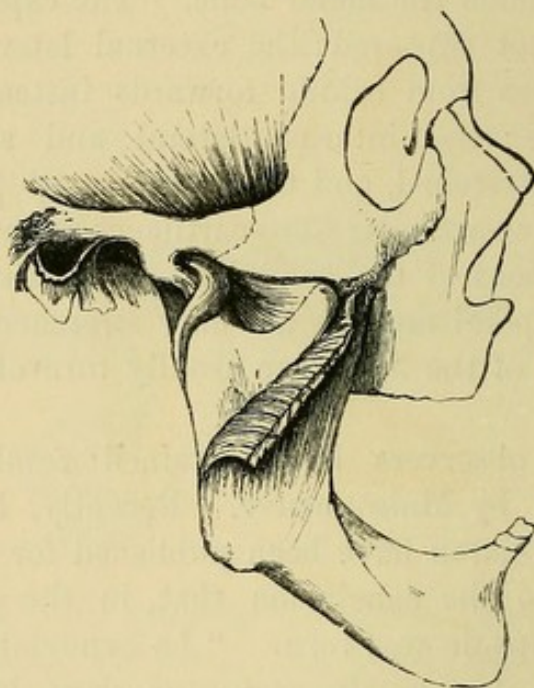
Both Maisonneuve (*L'Union Médicale*, 1863) and Otto Weber (*op. cit.*), have experimented upon the dead body, and have succeeded in producing dislocation of the jaw by imitating the three movements already described, when the following is the condition of the parts found upon dissection: The condyles are in front of the root of the zygoma, the coronoid processes are completely surrounded by the tendons of the temporal muscles, and are quite below and scarcely ever touch the malar bone. The capsular ligament is tense, but not ruptured; the external lateral ligament is tense, and passes from behind forwards instead of from before backwards; the internal lateral and stylo-maxillary ligaments are stretched, and this is increased by raising the chin. The inter-articular fibro-cartilages are attached to and follow the motions of the condyles. According to Maisonneuve, the temporal muscles are only stretched; but Weber says that some of the fibres are usually torn off the coronoid process.

Nearly all observers have obtained results similar to those obtained by Maisonneuve. Recently, however, some researches of Nélaton have been published for the first time, and he came to the conclusion that, in the great majority of cases, the capsule was torn. "La synoviale est déchirée en avant et au dessous du menisque dans la très grande majorité des cas, bien qu'on l'ait rencontrée intacte dans deux autopsies" (*Traité de Chirurgie*, Duplay et Reclus). On the other hand, Dr. Julius Snitzler has quite recently produced the dislocation on the dead body, and in no case did he find any tearing of the capsule (*Centralblatt für Chirurgie*, 1891).

The fixation of the dislocated jaw has received a different explanation, and has been attributed to the catching of the coronoid process against the malar bone, or the malar process of the superior maxilla. This view was originally maintained by Fabricius ab Aquapendente, by Monro, and more recently by Nélaton (*Revue Médico-Chirurgicale*,

tom. vi), who is followed by Malgaigne in his treatise on "Dislocations" (1855). Nélaton maintains that in his experiments on the dead body he constantly found the coronoid process fixed against the malar bone; and he appeals also to a unique preparation of a pathological dislocation, which he dissected and presented to the Musée Dupuytren. The accompanying illustration (Fig. 36), reduced from Malgaigne's Atlas, is from the preparation in question. The coronoid process in this certainly touches

FIG. 36.

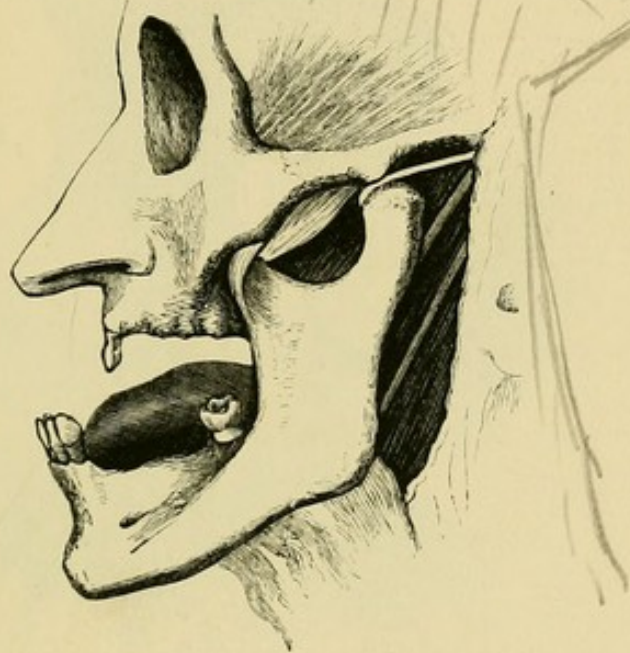


the malar bone, and the relations of the inter-articular cartilage and external lateral ligaments are well seen.

Ribes and Monteggia agree with Maisonneuve and Weber in believing that in most jaws the coronoid process is not long enough to reach the malar bone; and the last-named author mentions that Roser was unable to reduce an old dislocation of eight weeks' standing, even after cutting through both coronoid processes from within the mouth by means of bone forceps. From experiments I have myself instituted, I believe the view of Maisonneuve and Weber to be correct—viz., that the coronoid process does not become fixed against the malar bone. In the macerated skull it is

easy to dislocate the condyle so far in front of the articular eminence as to cause the coronoid process to be hooked against the malar bone; but this is by no means easy on the subject, even when the parts are dissected, and can only be accomplished by tearing the structures of the joint very considerably. Besides, the position the jaw assumes when the condyles are so driven forward, is not that of the ordinary form of dislocation, the jaws being too widely separated, and the chin drawn back instead of being

FIG. 37.



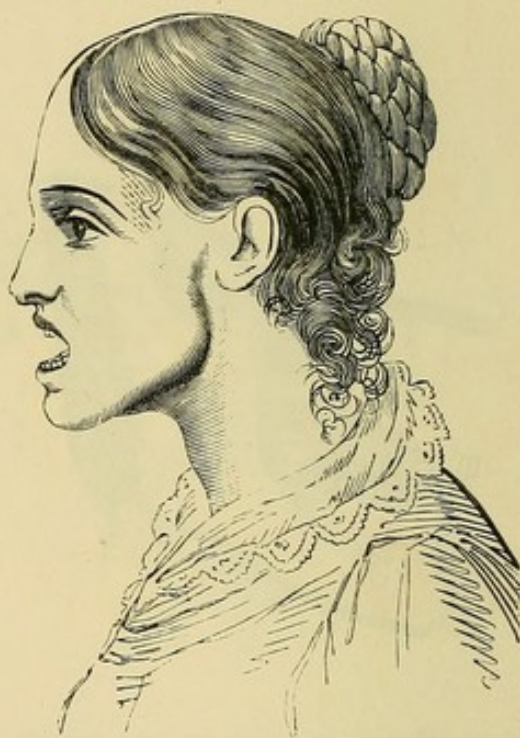advanced. Were the coronoid processes fixed against the malar bones, it would be impracticable to effect a reduction by elevating the chin, as is frequently done; and, moreover, the gradual improvement noticed in old-standing cases of dislocation would be impossible.

A preparation, illustrating the anatomy of dislocation, was dissected for me by my friend the late Mr. Marcus Beck, and from one side of it the drawing (Fig. 37) was made.

Symptoms of Dislocation.—When the dislocation is bilateral, the deformity is so evident as at once to attract attention. The mouth is open and the jaw fixed, with the lower teeth

carried beyond those of the upper jaw, as seen in Fig. 38, from Fergusson. Speech and deglutition are much interfered with, since the lips cannot be approximated; and, for the same reason, the saliva dribbles from the mouth. On examining the neighbourhood of the temporo-maxillary joint, a distinct and unusual hollow will be seen immediately in front of the ear, and the condyle may be both seen and felt in front of this. The coronoid process forms a projection immediately behind and below the malar bone,

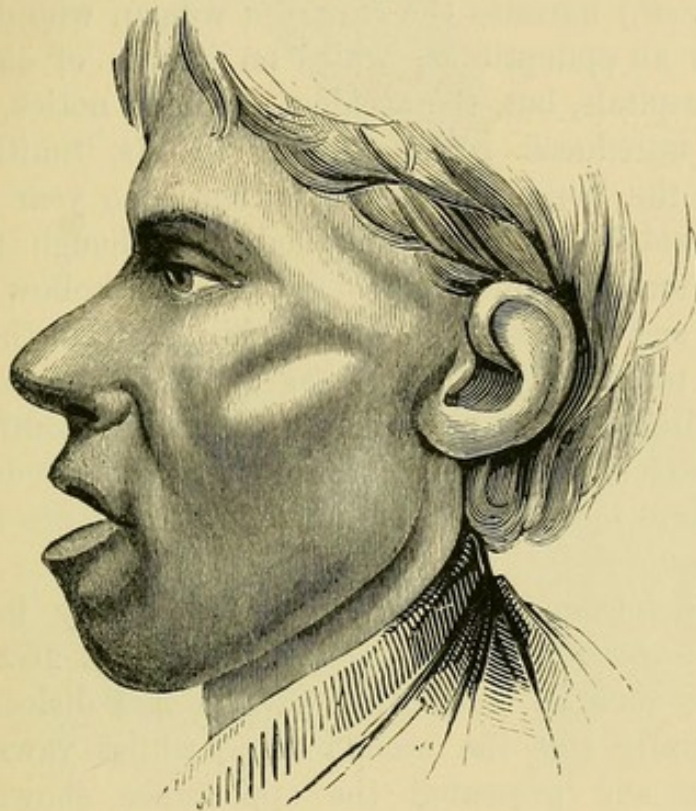
FIG. 38.



and may be readily felt in its abnormal position from the mouth. The masseter is firmly contracted and strongly prominent. R. W. Smith, in his work on "Fractures and Dislocations," has also specially called attention to a prominence immediately *above* the zygoma, which has not been usually described, and which he believes is due to the condyle pressing forward and stretching the posterior fibres of the temporal muscle, but which I believe to be caused by their spasmodic contraction. The accompanying drawing (Fig. 39), taken, by permission, from the work referred to, illustrates both these points.

In dislocation of only one condyle the signs are less manifest, and may possibly be overlooked or misinterpreted. The chin is usually directed towards the *sound* side instead of toward the *injured* side, as is the case in fracture of the neck of the bone; the hollow in front of the ear is equally visible in this as in the double form of dislocation, and speech and deglutition are similarly to some degree interfered with. The obviousness of the direction of the chin to one side will

FIG. 39.



depend in some degree upon the original prominence of that feature in the individual, and too much stress must not be laid upon the symptom: thus Hey, in his "Practical Observations in Surgery" (1814), remarks: "One would expect, from a consideration of the structure of the parts, and from the description given in systems of surgery, that the chin should be evidently turned towards the opposite side; but I have repeatedly seen the disease (accident) where I could discern no alteration in the position of the chin. The symptom which I have found to be the best guide in this

case, is a small hollow which may be felt behind the condyle that is dislocated, which does not subsist on the sound side." R. W. Smith also mentions that, in a case of luxation of the right condyle, he had seen the efforts at reduction applied to the left side.

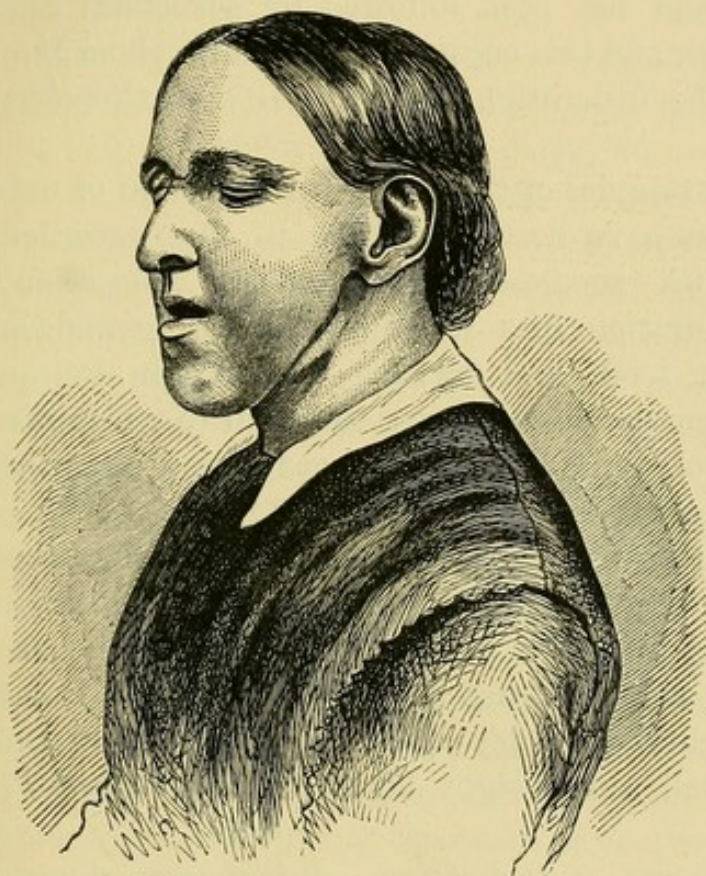
Old-standing Dislocations.—From various causes dislocations of the jaw have been from time to time overlooked, and have not been brought under the notice of the surgeon for weeks or even months after the accident. Thus R. W. Smith (*op. cit.*) narrates the case of a woman who dislocated her jaw in an epileptic fit, whilst an inmate of one of the Dublin Hospitals, but, the accident escaping notice, the bone remained unreduced. The drawing in Mr. Smith's work represents the condition of the patient one year after the accident, and it is to be remarked that though the signs of dislocation are sufficiently obvious in the hollow in front of the ear and the projection of the chin, yet that the patient was able to close the lips so as to retain the saliva and speak intelligibly, but was able to open the mouth only to a limited extent. Indeed in these cases of unreduced dislocation there seems to be no great inconvenience from the displacement.

Mr. John Couper has recorded an equally interesting case in the *London Hospital Reports*, vol. i, p. 262. More than three months before, the patient had dislocated her jaw bilaterally (for the second time) whilst yawning, and when seen she presented the appearance shown in the illustration (Fig. 40), for which I am indebted to the editors of the *Reports*. Mr. Couper found that the jaw had recovered a certain amount of mobility, so that the incisors of the two jaws could be approximated to within an inch, and separated for an inch and a half, the molar teeth being nearly in contact during extreme closure. The chin was depressed and carried forward, and the hollow in front of the ear was well marked. The patient's utterance was slightly, if at all, impaired, and the labial consonants were pronounced as distinctly as other sounds, and the saliva was retained. Mr. Couper made attempts, under chloroform,

both with levers and forceps, to reduce the dislocation but without success, but the effect of the operation was to increase the range of motion of the jaw.

A second case of old double dislocation of the jaw occurred in the London Hospital in the year following Mr. Couper's, and, being of only two months' standing, was reduced with some little difficulty by Mr. Hutchinson, who

FIG. 40.



says (*London Hospital Reports*, vol. ii, p. 33): "The woman was unable to shut her mouth, and her chin stuck forward, giving her face an awkward, lantern-jawed expression; but there was no wide gaping and she could easily shut her lips." The readiness with which the accident may be overlooked is illustrated by the concluding observation of Mr. Hutchinson: "We had fancied at first that there was but little facial deformity, but this impression was corrected at once when we had her natural expression before us by way of contrast."

Brockway reported an interesting case of unreduced bilateral dislocation of thirteen months' duration. Under ether unsuccessful attempts at reduction were made. An incision was then made over each joint and the condyles were replaced. The mouth was kept closed for seven days, and the patient was discharged on the tenth day with good movement.

Probably the longest period which has elapsed after the accident and has been followed by successful reduction, is ten months, and this occurred in a man in whom Mr. McArdle reduced the dislocation (*Med. Press and Circular*, London, 1885).

Other examples of the successful reduction of old-standing dislocations have been from time to time recorded. Thus, Mr. Pollock successfully reduced a dislocation of four months' duration in a woman, by inserting wedges between the molar teeth and drawing up the chin by means of a strap tourniquet passed over the head (*St. George's Hospital Reports*, vol. i). A slightly longer period than this elapsed in Mr. Golding Bird's case (see p. 87).

Sir Astley Cooper ("Fractures and Dislocations") gives a case in which Mr. Morley reduced a dislocation after a month and five days. Stromeyer had a similar case. Spät was successful in a case fifty-eight days old; Demarquay in one of eighty-three days (Weber, *op. cit.*); and Donovan in one of even ninety-eight days (*Dublin Medical Press*, May, 1842).

Rare Forms of Dislocation.—A few cases of rare forms of dislocation with fracture have been described. The cases recorded by Robert of dislocation outwards with fracture on the opposite side, and by Mr. Croker King and Mr. Gunning of New York, of dislocation outwards and backwards with fracture of the symphysis, have been already referred to under the head of "fracture complicated by dislocation." It might be supposed from the anatomy of the parts that dislocation backwards would be impossible without fracture of the front wall of the meatus auditorius externus or of the glenoid cavity, and the specimen in St. George's Museum

is an instance in point. In Mr. King's case there can be little doubt that there was some injury to the meatus, from the hæmorrhage which occurred.

M. Baudrimont has reported a case of dislocation of both condyles backwards, in which the anterior inferior wall of the auditory meatus on each side was fractured, and the auditory passage was almost completely obliterated by the projection of the condyle into it (*Bulletin et Mém. Soc. de Chirurg. de Paris*, 1882).

From cases reported by Coe (*American Medical Journal*, 1889) and Thiene (*Berl. Klinische Wochenschrift*, 1888) it seems that this dislocation can take place without any injury to the auditory meatus. The condyle may slip into a temporary receptacle bounded in front by the tympanic tubercle, behind by the mastoid process, and internally by the styloid process (*fosse tympanico-stylo-mastoidienne*). In the young and old, owing to the alteration in the maxillary angle, the masseter and internal pterygoid muscles become solely elevators, losing their forward action.

All the cases recorded by these observers occurred in women, generally at the end of the act of gaping.

Congenital Dislocations.—Cases of congenital dislocation of the lower jaw, with more or less malformation, have been recorded by Guérin (*Gazette Médicale de Paris*, 1841) and R. W. Smith ("On Fractures in the Vicinity of Joints"), who gives elaborate drawings of the dissections of the case. Mention may be made also of the cases of congenital smallness and arrest of development recorded respectively by Langenbeck (*Archiv für Klin. Chir.*, Bd. i), by Mr. Canton (*Pathological Society's Transactions*, vol. xii), and Dr. Ogston's elaborate paper on "Congenital Malformation of the Lower Jaw" (*Glasgow Medical Journal*, 1875); but these subjects do not properly come within the scope of this work.

Sub-luxation of the jaw was first described by Sir Astley Cooper, and has been generally recognised by surgical writers since his time. It will be described in the chapter on diseases of the temporo-maxillary joint.

Recurring Dislocation.—Cases are occasionally met with in which there is a great tendency for the dislocation to recur, it may be several times during a year. Such a case will be mentioned when the treatment of dislocation is dealt with.

Dislocation of Inter-articular Fibro-cartilage.—Henry Lee, in the *Lancet*, 1890, describes a case of this kind. There was dribbling of saliva and enlargement of the left sub-maxillary gland. This condition of the gland was considered by Lee to be due to injury of the chorda tympani nerve.

Treatment of Dislocation.—Although ordinarily requiring the assistance of the surgeon, dislocations of the jaw have been known to become reduced spontaneously, or with the aid of the patient alone. Nélaton mentions a case of spontaneous reduction occurring in his own practice; and Sir Astley Cooper narrates the case of a lady who reduced a dislocation of one side, induced by sea-sickness, with the help of an oyster-knife. Levison also gives the case of an old man who, suffering from recurring dislocation, especially when waking from sleep, "would pull his jaw and press it backwards, when, after about half an hour's work, bang it seemed to go, and all was right again."

In recent cases of dislocation, reduction may usually be accomplished with facility by various methods of manipulation, but cases of long standing may require some instrumental assistance. The simplest mode is for the head of the patient to be held firmly against the breast of an assistant, while the operator, having protected his thumbs with lint or a towel twisted round them, presses them as far back as possible upon the molar teeth, grasping the jaw at the same time with his fingers. Pressure is then made downwards and backwards, so as to free the condyles from the articular eminence, and as soon as this is done the chin is elevated and the condyles slip into place. This plan may be advantageously modified by reducing the condyles successively though at the same operation, care being taken that the condyle first reduced is not again dislocated, as has

happened more than once. The proceeding is thus rendered easier, because one condyle forms a point of support or fulcrum for the other, so that the entire jaw is used as a lever, instead of the thumbs forming the fulera, as in the other method. This latter method also obviates the danger of the jaw suddenly closing upon the thumbs, though this is probably somewhat exaggerated.

Hamilton considers that the method described by Hippocrates might often be tried with advantage. By this method the chin is greatly depressed, and then pressed backwards in the direction of the articulation.

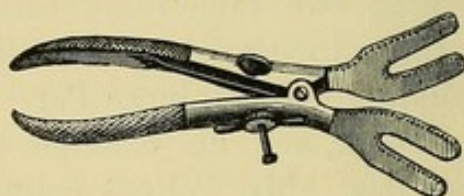
Sir Astley Cooper recommended the introduction of two corks (or one in the case of single dislocation) between the molar teeth to act as fulera, the chin being then drawn upwards; and narrates the case of a madman, where, for his own safety, he used two table-forks with a handkerchief wrapped round them to act as fulera. The same method was originally employed by Ambrose Paré, who used wedges of wood instead of cork, and his example has been followed by numerous surgeons. Mr. Pollock employed this method successfully in 1866, in a case of dislocation of four months' standing; a gag being placed between the molar teeth, and the strap of an ordinary tourniquet being applied round the head and beneath the jaw, so that the screw might exert its power upon the dislocated bone (*St. George's Hospital Reports*, vol. i).

Instead of mere fulera having been inserted between the molar teeth, levers have been employed to depress the lower jaw in cases of difficulty; thus, Sir Astley Cooper narrates that Mr. Fox, the dentist, "placed a piece of wood a foot long upon the molar tooth of one side, and raising it at the part at which he held it, depressed the point at the jaw on that side, and succeeded in reducing the condyle. He then did the same on the other side, and thus replaced the bone." Here, of course, the upper jaw formed the fulcrum, and the advantage of acting upon one condyle at a time is seen. This method is not invariably successful, however, for in the case of old dislocation under Mr. Couper's care, already

related, that gentleman employed levers of pine wood six inches long without success.

A more powerful leverage action is obtained by the forceps invented by Stromeyer, which is shown in the illustration (Fig. 41). The forceps consists of two blades expanded at the extremities, so as to fit pretty accurately the dental arches of the upper and lower jaws, and covered with leather. A spring between the handles tends to keep the blades closed, and a screw and nut, acting upon the handles, is able to close them so as to make the blades diverge forcibly; at the same time a movable pin loosens this, so that the blades may be closed again the moment they have done their work. The blades being closed, and introduced between the teeth as far as possible, are then separated by

FIG. 41.



means of the nut and screw, until the condyles are disentangled from the articular eminences, when, being suddenly closed, they are withdrawn, an assistant at the same time pressing the jaw backwards, so as to bring the condyles into the glenoid cavities. In this way Stromeyer reduced a dislocation of thirty-five days' standing.

Nélaton, whose view with regard to the locking of the coronoid processes against the malar bones has been already referred to, advocates acting directly upon these processes, in order to force them and the condyles backwards. The surgeon may stand in front of the patient, and, with his thumbs pressing against the coronoid processes, within or without the mouth, may grasp the mastoid processes with his fingers, and thus have a firm *point d'appui* to act from; or, sitting behind the patient, he may place his thumbs on the nape of the neck, and endeavour to draw the jaw backwards with his fingers.

Maisonneuve, though differing from Nélaton with regard

to the pathology of the affection, agrees with him in the propriety of acting upon the coronoid processes. The following were the conclusions he arrived at from numerous experiments on the dead body:—Blows on the cheeks or chin (which have been recommended in bygone days) were useless; pressure with the thumbs on the back teeth, combined with elevation of the chin, succeeded only a few times; depression of the chin at the same time that the thumbs pressed away the masseters from the interior of the mouth was rather more successful; depression of the chin and pressure on the coronoid processes from before backwards, with the thumbs in the mouth, effected reduction constantly and with ease.

In November, 1883, Mr. Golding Bird brought before the Clinical Society a man, aged twenty-two, in whom an unreduced dislocation of both condyles had existed for eighteen weeks. After breaking down adhesions, Mr. Bird succeeded in reducing the right condyle, and subsequently the left, by Nélaton's method of pressing directly upon the coronoid processes, followed by drawing up the chin.

In all cases of dislocation the administration of chloroform will facilitate the reduction, but it is not necessary in recent cases. In old-standing cases it should invariably be had recourse to, since the operation will necessarily be both painful and prolonged, in consequence of the formation of fibrous adhesions.

When reduction has been effected, the precaution should be taken to limit the movements of the jaw for a week or two, by the use of the four-tailed bandage used in cases of fracture of the jaw.

After a week or ten days passive movements should be carefully employed to prevent the danger of any degree of ankylosis. Massage over the region of the joint might in some cases be useful.

In the *Lancet* of April 14, 1883, Mr. Pughe, of Liverpool, has reported the case of a boy of four years, in whom the condyle was dislocated by a blow on the chin two years before, and in whom ankylosis between the condyle and

the zygoma had taken place, causing complete closure of the jaws. Mr. Pughe resected the condyle, with the result that the patient could open his mouth to the extent of an inch, but had no lateral movement.

Treatment of Recurring Dislocation.—In individuals liable to recurring dislocation of the jaw (like the woman mentioned by Putégnat, whose jaw was dislocated once a month), some elastic support for the chin should be employed, and care be taken not to open the mouth too widely.

Borison of Algiers (*Gaz. Médicale de Nantes*) reports a case of bilateral dislocation which recurred twenty-two times in one year. The patient was radically cured by keeping the jaw absolutely immobile, with milk diet and faradization of the temporal and masseteric regions.

In some cases an operation may be necessary. Thus F. Marsh (*Brit. Med. Journ.* 1892) reports a case of recurring bilateral dislocation treated by operation. He cut down upon the left joint, and stitched the fibro-cartilage to the periosteal attachment of the capsule to the zygoma, a method previously adopted by Mr. Annandale for the treatment of cases of sub-luxation of the temporo-maxillary joint (see "Diseases of Temporo-maxillary Articulation"). Four months afterwards the right side was similarly treated. Both wounds healed well, and eighteen months afterwards the patient had had no recurrence of the dislocation.

CHAPTER VII.

INFLAMMATORY DISEASES OF THE JAWS.—PERIOSTITIS AND ABSCESS.

INFLAMMATORY diseases of the jaws are very common, in fact, inflammation occurs more frequently in these bones than in any others, and the reason for this is not far to seek. The relation of the teeth to the jaws is a most intimate and important one. Between each tooth and the jaw, lining the tooth-socket, is a layer of tissue frequently termed the alveolar or alveolo-dental periosteum. It is in this periosteum, situated between the teeth and the lower jaw that the large majority of inflammatory affections of the jaws commence. In some cases the alveolar periosteum of all the teeth is affected simultaneously, whereas in other cases the periosteum of only one or two teeth may be affected. Hence we may divide the cases into *diffused* and *localised*.

(a) *Diffused inflammation of the alveolar periosteum.*

1. A striking, and at one time very common, example of this diffused periostitis occurs in persons exposed to the fumes of phosphorus. It is well known that this form of periostitis can only arise in those persons whose teeth are in an unhealthy condition, so that the fumes can reach the alveolar periosteum. In all cases of so-called phosphorus-necrosis the trouble always commences in the alveolar periosteum, and it is by the extension of the inflammation to the rest of the jaw that the death of a greater part or of the whole of the bone takes place. It will be more convenient to consider this subject at greater length in the chapter on necrosis (see Chap. VIII.).

2. A condition very similar to this may be brought

about by the administration of mercury in doses large enough to produce salivation. In this case it is quite probable that the excessive ptyalism is the real cause, as other drugs causing salivation have been followed by similar results.

3. In strumous children we sometimes see a diffused periostitis, generally of the lower jaw, which may lead to very extensive necrosis. It is very doubtful, however, whether this is a tubercular periostitis. In all probability it is not similar to the periostitis which may occur in other parts of the body in strumous children.

Mr. Stanley, in his work on "Diseases of the Bones" (p. 71), alludes to cases of this kind, although he does not appear to connect them with a strumous diathesis. He says: "A large portion of the lower jaw in young persons occasionally perishes without any previous derangement of health, local injury, or other apparent cause. But in some cases an aching in the bone has preceded the death of it. Such examples of necrosis usually occur in early life, between the fourth and twentieth years, but rarely later."

4. In persons subject to rheumatism, attacks of diffused periostitis are by no means uncommon. In such cases the periostitis does not tend to go on to suppuration and necrosis, but organises and forms a thickening of the jaw.

5. Chronic suppuration may occur at the necks of the teeth, leading to progressive necrosis of the alveolar margin. In this way the fang of the tooth is exposed, and finally the tooth falls out. This condition is termed "pyorrhœa alveolaris," or sometimes "Rigg's disease." Its pathology is very obscure, and the reader is referred to the excellent discussion on the subject in Tomes' "System of Dental Surgery." According to most observers, the inflammation commences in the alveolo-dental periosteum, and is probably septic in its nature, and caused by the deposit of tartar.

6. Magitôt, in a paper read before the Academy of Medicine of Paris (1882), has described a form of alveolar periostitis which he considers pathognomonic of diabetes. Without going so far as this, Dr. Pavy recognises the affection in the following extract from his work on diabetes:

"The teeth are not unfrequently observed to become loosened in diabetes, and it may be even to such an extent as easily to drop out. There is evidently some direct connection between this phenomenon and the disease. It seems as if the morbid condition of the system prevailing interfered with the nutritive action going on in the fang and its socket, and so led to the result. It is only when the symptoms are allowed to run on in a severe form that it is noticed, and, supposing the teeth to have become already loosened, I have known them to again become firm upon the disease being controlled by treatment."

Symptoms.—In cases of diffused alveolar periostitis, the earliest symptom is an uneasy sensation in the teeth. This gradually becomes worse, and the least pressure upon them causes excruciating pain. The pain is often worse at night. There is redness and swelling of the face, together with a general constitutional disturbance. On examination, the teeth are found to be raised somewhat from their sockets and loosened. The subsequent course of events will depend to a great extent upon the cause of the inflammation. Thus in the periostitis due to phosphorus fumes or to mercury salivation, extensive suppuration and necrosis may result. In strumous patients a similar though usually less extensive necrosis may take place. In rheumatic cases suppuration is very unusual. As a rule a general thickening of the jaw takes place.

Treatment.—As this affection often depends upon a general unhealthy condition, our attention must be directed to this state. Thus in rheumatic periostitis the treatment of rheumatism should be carried out. In strumous subjects cod-liver oil, preparations of iron and of the hypophosphites, and suitable climate, should be recommended.

Local treatment is also very important. In the early stages counter-irritation with tincture of iodine or tannin powder may be beneficial. Local depletion by leeches may be useful. It is most important to wash out the mouth frequently with antiseptic mouth-washes. These are especially indicated where there is chronic suppuration around the necks of the

teeth. In severe cases incisions through the gums and periosteum may be beneficial, and in cases where suppuration has commenced it is most important to make free incisions to relieve tension.

(b) *Localised inflammation of the alveolar periosteum.*

These cases very naturally fall into two groups: the acute inflammation, which frequently goes on to suppuration, and forms an ordinary alveolar abscess or an abscess in the substance of the jaws; the chronic inflammation, rarely proceeding to abscess, but causing suppuration along the necks of the teeth, where the gum and alveolar periosteum meet.

Alveolar Abscess.—As a rule this arises in connection with some carious changes in a tooth, and is probably, in the great majority of cases, due to the introduction of micro-organisms. The germs may spread from the carious patch through the pulp, to the alveolar periosteum, or they may gain their entrance at the junction of the alveolar periosteum and gum around the neck of the tooth. In some cases an abscess appears to arise without any morbid condition of the teeth, and at present it is impossible to account for the origin of such abscesses satisfactorily.

The progress of an alveolar abscess is thus described by Tomes: "If the progress of the disease be unarrested, the periosteum becomes detached from the cementum, and the point of separation usually commences at and extends from the foramen in the root of the tooth. Into the interval thus formed pus is poured from the separated surface of the periosteum. The fang at this part loses its vitality, and is bathed in pus, the quantity of which is gradually increased, space being gained in the alveolus for the dilatation of the abscess at the expense of the bone. The extent to which the alveolus becomes excavated will vary with each case. It may be hollowed out to a very limited extent around the apex of the root, or a large cavity may be formed. The size of the abscess will depend upon the activity of the symptoms, the time the pus is pent up, and the state of the health of the patient. So soon as suppuration is established

a process is set up for liberating the secretion. Either the periosteum becomes detached from the neck of the tooth, and the pus finds its way by the side of the socket and passes out at the edge of the gum, or a perforation is made in the wall of the alveolus, through which the contents of the abscess pass into the substance of the gum. If the disease is left to run its own course, the contents of the abscess will sooner or later find their way to the surface and escape."

The direction which the pus of an alveolar abscess may take is very variable. According to Salter the commonest position for the matter to point is "on the outer surface of the jaw at a point corresponding, as nearly horizontally as may be, with the extremity of the fang of the affected tooth, and *piercing the gums within the mouth.*" But the matter may find its way in other directions. Thus both Tomes and Salter mention the tendency of pus, derived from an upper incisor tooth, to burrow between the bone and the periosteum of the hard palate and open upon the surface of the soft palate. The former also states that occasionally the pus separates the periosteum from one side of the hard palate, and forces it down to a level with the teeth. Abscesses connected with the upper incisor teeth may also point within the nostrils by small orifices presenting little teat-like elevations, which will be at once detected on a careful examination of the nostrils. The patient's attention will have probably been directed to the occasional discharge of pus from the nose, and the case may be erroneously treated as one of ozæna.

An abscess connected with any tooth may point on the face, and in the case of the lower jaw beneath the chin. It may burst into the antrum, but this is only likely in cases where the disease commenced in the bicuspid or molar teeth of the upper jaw. Tomes, however, mentions the case of an abscess in the antrum being due to a central incisor of the upper jaw. According to Tomes, collections of matter, formed about the wisdom teeth, pass between the muscles and bone and escape at the angle of the jaw, or may pass

forwards inside the mouth and open near the canines; on the other hand they may pass backwards and open into the fauces.

Abscesses in connection with the molar teeth may burrow extensively in the neck, no doubt assisted by gravity, and may even open below the clavicle.

Symptoms.—There is at first a dull, uneasy sensation which can scarcely be called pain. This is relieved by biting upon the tooth, but as soon as the pressure is withdrawn the uneasy sensation returns. This is soon followed by a dull heavy pain, and the tooth appears to be raised slightly from its socket. The pain soon becomes of an acute throbbing kind, and the constitutional symptoms are occasionally severe, amounting to high fever and delirium. On examination there is found swelling and tenderness of the gum and, according to Tomes, an early but evanescent symptom is a well-defined red ring encircling the neck of the tooth. The jaw becomes rapidly swollen and the face consequently distorted. The acute symptoms continue until the pus has found an exit, and then as rapidly subside.

Complications and Sequelæ.—The large majority of alveolar abscesses, whether treated by a surgeon or allowed to run their own course, terminate favourably without any serious complication. Occasionally, however, in cases that have not been properly treated, very grave results may follow. Thus, Mr. Howse, in the *Medical Times and Gazette* for 1876, relates the history of a case of pyæmia occurring in a child four and a half years old, following an alveolar abscess in the lower jaw.

On two occasions I have known death result from a low form of cellulitis spreading between the muscles of the neck and leading to œdema of the larynx, distinctly traceable to neglected alveolar abscess, in patients whose constitution had been greatly damaged by intemperance. In the first I had made free incisions in the mouth and neck, but œdema glottidis supervened in the night and proved fatal. In the second I took the precaution of freely

scarifying the mucous membrane of the throat, but here again unfortunately I was not summoned when the breathing became urgent. A similar disastrous case is recorded by Dr. Harrison Allen in the *Dental Cosmos* for 1874.

An interesting case is recorded by Mr. Pearce Gould, in which the mischief started in an alveolar abscess of the lower jaw. The pus extended backwards to the pterygoid region, causing thrombosis of the venous plexus there, and later the thrombosis extended to the cavernous sinuses, causing death in a comatose state.

A not uncommon complication of alveolar abscess is inflammation of the submaxillary lymphatic glands, which sometimes goes on to suppuration. This is said to occur with special readiness in strumous individuals.

Treatment.—The first step indicated is to get rid of the source of the inflammatory trouble, which is nearly always a septic focus in the carious tooth. Any stopping should be removed and the pulp cavity and root canals cleared out, or a hole may be drilled into the pulp cavity through the side of the tooth so as to give exit to any accumulated fluid (see paper on "Rhizodontresis," by Mr. Hulme: *British Journal of Dental Science*, April, 1865).

When the dental periosteum becomes involved, local blood-letting may be very beneficial in cutting short the inflammation; one or two leeches should be applied to the gum through a leech-tube, and the subsequent fomentation of the part, by means of hot water held in the mouth, may give relief.

In many cases, in spite of all treatment, suppuration takes place. When matter has formed and is finding a precarious exit by the side of the tooth, which is certainly dead and will only prove a source of irritation, its immediate extraction is the best practice. But when, as frequently happens, the matter has perforated the alveolus and passed into the substance of the gum so as to produce an elastic fluctuating tumour between the teeth and the cheek, a free incision into it is the best and only mode of treatment. If possible the knife should be carried right

through the spongy bone forming the wall of the abscess cavity, and in these cases if the hole in the alveolus is sufficiently large to give free exit to the pus, the teeth may be eventually saved. I know of no reason for delaying the incision until the gum has become distended with pus, though the practice has its advocates. So soon as inflammatory swelling takes place, an incision will do good by relieving congestion and giving exit to exudations; and I have never seen reason to regret an early and free incision in such cases. A sharp scalpel or small bistoury is the best instrument for the operation, the ordinary gum-lancet being unsuitable and inconvenient for the purpose, and no damage to neighbouring parts can happen if the edge of the knife is directed towards the bone. I have once known the facial artery wounded from within the cheek from neglect of this precaution.

There is a popular notion, which has received some support at the hands of certain members of the profession, that extraction of a tooth must not be performed during the stage of active inflammation of the alveolus. I know of no foundation for this statement, which is entirely devoid of truth, and yet it has formed the ground for an action against an eminent member of the dental profession. As a rule, extraction of the teeth is not necessary, and indeed our endeavour should be to save the tooth; but in some cases it is important that the tooth should be removed, either on account of its septic nature or of its interference with the drainage of the abscess cavity. It may be well, therefore, to put on record the statement of the President of the "Association of Surgeons practising Dental Surgery" in answer to the question "Is it right to refuse to extract a carious and aching tooth on account of the acuteness of the pericosteal and maxillary inflammation which its presence has excited?" The president (Mr. Cattlin, F.R.C.S.) "was glad that Mr. Owen had brought under discussion, in his practical paper, an unskilful kind of practice which greatly increased human suffering, and was often very injurious to the patient in after-life. It was the erring practice of some

to wait until the inflammation subsided ; but, if the tooth be retained, the swelling, as a rule, rapidly extends to adjoining parts, and sometimes causes necrosis, occasionally infiltrating into muscle, restricting the movements of the jaw, and often ending in abscess, which, bursting externally, permanently disfigures the face" (*Medical Press and Circular*, January 12, 1881).

In cases of abscess arising from the upper incisor teeth and extending along the palate, a free and early incision is even more necessary than in the ordinary form of abscess, since extensive necrosis and exfoliation of the hard palate, with consequent perforation, may not improbably result from the delay. The same rule holds good also in all cases of matter pointing within the cavity of the mouth ; but where, as has already been mentioned, the matter shows a tendency to point on the skin of the face or neck, every means should be taken to avert, if possible, the opening in this situation, and to insure an exit for the matter within the mouth. It may be well to notice here, that the cause of the abscess in these cases is not unfrequently overlooked, owing to the distance between the tooth and the point where the matter appears, and that in all cases therefore of abscess about the jaw or neck, it is well to investigate carefully the state of the mouth. No greater mistake can be made than to encourage the pointing of an alveolar abscess on the surface of the skin by poulticing. During the early and acute stages of the inflammation, the warmth of a poultice may be grateful to the patient, and if applied for a few hours will do no harm, though I should myself greatly prefer the application of extract of belladonna and glycerine in equal proportions. Even when the skin is already reddened and adherent to the bone, its breaking may be avoided (provided a free exit for the discharge of matter into the mouth has been secured) by painting the surface with flexile collodion or with tincture of iodine, all warm applications being discarded.

The sinuses left after an alveolar abscess has burrowed through the integuments, remain open so long as the cause

of irritation is untouched, and the orifice, though contracted, never closes, being surrounded by granulations which sometimes grow to a large size. I had under my care a girl who was brought to me for the supposed growth of a horn from her chin, and the appearance was not unlike one of the horn-like growths of cuticle occasionally met with. It proved to be nothing more than a growth of epithelium on the top of long granulations around a fistulous opening, due to the presence of a stump in the lower jaw, the bone having been perforated by the abscess. The successful treatment of these sinuses, like those dependent upon the presence of bone elsewhere, can only be insured by the extraction of the offending tooth or stump. In these cases the fang is necrosed and forms a sequestrum in the same way as a piece of bone, and will keep up irritation so long as it is allowed to remain. The distance from the jaw at which an alveolar abscess may occasionally point not unfrequently leads to mistakes in diagnosis and treatment, particularly of the resulting sinus. I have on several occasions known a sinus, at some distance below the lower jaw, treated by injections when the fang of a tooth was keeping up irritation, and Salter has seen openings an inch below the clavicle dependent upon the same cause. I have once found the diseased fang so deeply buried and overlapped by the neighbouring teeth that it could only be detected by careful probing from the mouth, and it was necessary to remove the adjacent teeth in order to reach the cause of the sinus.

Abscesses in the Substance of the Jaws.—Abscesses may form in the substance of the upper or lower jaw as a consequence of decayed teeth, but differing from ordinary alveolar abscess in the absence of any tendency to find an exit by the socket of the tooth. In the upper jaw this affection has been confounded with the so-called "abscess of the antrum," which is more properly an empyema, and which will be subsequently discussed; and Otto Weber (*Allgemeinen und speciellen Chirurgie*, iii) strongly maintains that abscess may form in the wall of the antrum, but perfectly separated

from it, both by the periosteum and the mucous membrane, or sometimes by a plate of bone.

Abscess in the substance of the lower jaw has been more frequently met with than in the upper jaw, and in most cases the abscess is caused by a decayed tooth. Thus, in a lady whom I saw with Mr. G. Bateman, there was a fluctuating swelling of the lower jaw in the incisive region, from which I evacuated by incision a quantity of offensive inspissated pus, due to irritation from incisor teeth which had been extracted some time before I saw the patient.

Another mode in which abscess may be formed in both the upper and lower jaws is by the suppuration of a "dentigerous cyst" connected with non-developed or imperfectly developed teeth. A remarkable case of this kind is reported by Weber (*op. cit.*), in which a woman, aged twenty-five, shortly after the partial eruption of a wisdom tooth, found a tumour forming on the left side of the jaw, which in a year extended from the mental foramen to beyond the angle. The bone gave a crackling sound when pressed upon, and in one or two situations appeared to be entirely absorbed. An incision was made over it, and on opening the tumour three ounces of thick flaky pus poured out. Part of the wall was removed, and the patient made a good recovery.

Probably the case described by Liston in his "Elements of Surgery" (p. 419), in which he mentions that osteo-sarcoma may supervene on "spina ventosa" of the lower jaw, is an instance in point. The case was that of a young man, aged twenty-one, who had an abscess of the lower jaw in the molar region, which was evacuated through the mouth and by means of a seton. Two years after the abscess refilled, and again after another year; osteo-sarcoma then developed, necessitating the removal of half the jaw.

Localised Chronic Inflammation of the Alveolar Periosteum.—This condition is very similar to the diffused inflammation of the alveolar periosteum, but only one or two teeth are affected. The trouble generally commences around the neck of a tooth, being probably a septic inflammation due to the deposit of tartar. The dental periosteum is gradually

involved, and finally the tooth may drop out. This condition comes chiefly within the province the of dental surgeon.

Although the irritation caused by decayed teeth is very prone, as we have seen, to cause acute inflammation terminating in an abscess, yet sometimes the inflammatory process may be much less acute, and may terminate in a different manner. The inflammation, commencing in the alveolar periosteum, spreads through the substance of the jaw to its periosteum. This latter becomes inflamed, and gradually an effusion of lymph infiltrates the bone and periosteum, leading to the formation of a distinct tumour. This is slowly absorbed on the early removal of the tooth, but if the irritation be allowed to continue the effusion will become organised into fibrous tissue, and a very serious affection may be thus produced.

From an attentive examination of numerous examples of fibrous tumour of the lower jaw, both before and after removal, I feel sure that the majority originate in the manner here described. This condition is met with only in the lower jaw. In the upper jaw, owing to the thinness of the bone, the inflammatory exudation readily finds an exit on the surface, and thus the injurious effects of prolonged tension are averted.

The two following cases are examples of this form of chronic inflammation occurring in the lower jaw :

I had in the summer of 1867 a patient under my care—a boy, aged fourteen—who was suffering from an enlargement of the lower jaw, due to an expansion of its wall by a growth evidently connected with a carious permanent first molar tooth. I had the peccant tooth extracted, but the enlargement of the jaw continued. In August some supuration occurred, and an abscess broke behind the angle of the jaw; but this soon healed, and in November he was perfectly free from pain and able to open the mouth thoroughly. I was anxious to perforate the jaw from the mouth, so as to give exit to any fluid contained in it and extract any solid material which might exist, but the parents would not consent to any surgical interference. The face

had in May, 1868, considerably diminished in size, but there was still a difference between the two sides. Two years later, however, I could detect no difference between them.

In a little girl of seven, also, whom I saw in 1872, with great enlargement of the right side of the lower jaw, in six years the part had resumed its natural shape.

It was pointed out, at the commencement of this chapter, that the large majority of the inflammatory affections of the jaws started in the alveolo-dental periosteum. Certain forms of periostitis may arise, however, quite apart from the teeth. *Syphilitic periostitis* is a common example of this, and leads to the formation of nodes here as in other parts. The palate is especially liable to these swellings, which are due to effusion between the periosteum and the bone, and which, if left untreated, will as surely lead to necrosis as the more acute forms. Mercury is inadmissible in these cases, but iodide of potassium in full doses will rapidly remove the swelling, and restore the periosteum to a healthy state.

Tubercular periostitis is occasionally met with in the jaws, and it may resist all medicinal treatment. In such cases an incision should be made into the swelling, and all the diseased periosteum and bone be scraped away with a sharp spoon.

Dr. Gross, of Philadelphia, has called attention to a form of neuralgia occurring in edentulous jaws, and dependent upon thickening and induration of the alveolar margin, by which the remains of the dental nerves become compressed and irritated. He recommends removal of the margin of the alveolus with cutting forceps, and speaks highly of the practice. Having seen the proceeding adopted on several occasions by Mr. Erichsen, and having used it myself, I think that there are undoubtedly cases of neuralgia which are relieved by the treatment, but that it is by no means of universal application in cases of neuralgia of the fifth nerve.

In the *Archiv für Pathologische Anatomie*, xviii, 347,

Dr. H. Senftleben has given an elaborate description of what he terms *acute rheumatic periostitis* of the lower jaw. It is impossible to explain its pathology, or even to say how it differs essentially from the ordinary acute diffused periostitis. He says that it attacks perfectly healthy and robust individuals with good teeth, after severe cold, commencing with violent toothache along one side of the lower jaw, considerable and very often intense fever, swelling of the cheek and gums, difficulty in chewing, &c. Active depletion is recommended, and an early incision if matter forms. Necrosis is a very frequent consequence.

CHAPTER VIII.

NECROSIS OF THE JAWS.

ALTHOUGH it is convenient to consider the subject of necrosis of the jaws in a special chapter, yet it must be clearly understood that necrosis does not in itself constitute a disease, but is a result of previous inflammatory disease of a bone. In nearly all cases of necrosis of the jaws some form of periostitis is the starting-point of the trouble.

The jaws are specially liable to necrosis, consequent upon inflammation, but there is a difference in the frequency with which the upper and lower jaw is attacked. According to Stanley ("Diseases of the Bones," p. 69) the order of frequency of necrosis of the bones of the skeleton is as follows: Tibia, femur, humerus, flat cranial bones, *lower jaw*, last phalanx of finger, clavicle, ulna, radius, fibula, scapula, *upper jaw*, pelvic bones, sternum, ribs; and the greater immunity enjoyed by the upper as compared with the lower jaw is due, no doubt, partly to its less exposed position, but more especially to the fact that necrosis occurs less frequently in cancellous than in compact bone. This difference is probably due to the fact that in cancellous bone the inflammatory products find an easier channel to the surface than in compact bone, and so the injurious effects of tension are prevented. The great difference in the supply of blood to the two bones may also have an influence, the upper jaw being supplied by very numerous branches of the internal maxillary arteries, which inosculate freely from side to side, whilst the lower jaw is supplied by two small branches only, which do not anastomose.

Necrosis of the jaws will vary according to the extent,

situation, and nature of the previous inflammatory trouble, which, as we have seen, is usually a periostitis. It will be convenient, therefore, to classify the varieties of necrosis according to the cause.

1. Necrosis of the alveolus, the inflammation commencing in the alveolo-dental periosteum.
2. The inflammation may spread from the alveolar periosteum to the proper periosteum of the jaw, and cause a more or less extensive necrosis of the jaw.
3. Necrosis resulting from inflammation around an impacted wisdom tooth.
4. Syphilitic necrosis.
5. Necrosis following the administration of certain drugs, especially mercury.
6. Phosphorus-necrosis.
7. Necrosis occurring during the course of certain acute specific fevers. (Exanthematous necrosis.)
8. Necrosis following injuries to the jaws.
9. Necrosis secondary to ulceration of the mouth.
10. Necrosis without apparent cause.

1. *Necrosis of the Alveolus.*—We have already seen that the septic matter in the carious focus of a decaying tooth may reach the alveolo-dental periosteum and set up acute inflammation there. In many cases an alveolar abscess results, and this, if not treated properly, may cause considerable necrosis of the alveolar portion of the jaw. Without the formation of an abscess, however, the inflammation of the dental periosteum may spread to the alveolus and lead to the death of the bone. This necrosis may be limited to one tooth socket, or may involve the sockets of several, or even of all the teeth. In the latter case the trouble probably originates in a general diffused alveolar periostitis, which rapidly spreads to the bone and causes necrosis of the alveolar process.

Sometimes one or more of the tooth sockets may become necrosed without any sign of preceding acute inflammation. Thus, Garretson, in his "System of Oral Surgery," mentions the case of a man who had gradually increasing pain in the

lower jaw, followed by exfoliation of two incisor teeth with their bony sockets. There was no indication of decay in the teeth or of any previous acute inflammation of the dental periosteum.

Necrosis of the alveolus is sometimes caused by the incautious use, on the part of the dentist, of caustics for destroying the pulp of a tooth. Thus, after the employment of arsenic for this purpose, a necrosis, generally slight in extent, of the alveolar margin may follow.

2. The destructive effects of inflammation of the alveolar periosteum caused by decayed teeth may not be limited to the alveolar portion of the bone. The periosteum of the jaw itself may become affected and pus may spread widely between the periosteum and the bone, leading to more or less necrosis of the body or even ramus of the lower jaw. In the case of the upper jaw this destructive effect is but seldom seen as a consequence of decayed teeth.

3. Necrosis caused by an impacted wisdom tooth is by no means uncommon, and nearly always occurs in the lower jaw. Owing to the close approximation of the second molar tooth to the ramus of the jaw the eruption of the wisdom teeth is prevented. This impeded eruption often gives rise to various and apparently anomalous symptoms, which will be considered later (see Closure). The most serious result, however, is the formation of abscesses, which burrow widely about the angle of the jaws and teeth, leading to great scarring and permanent deformity. In a young lady, seen by me in consultation some years ago, the mischief resulting from an impacted wisdom tooth was sufficient to put her life in some jeopardy, and has left her face permanently scarred by the extensive abscesses.

4. *Syphilitic poison* frequently produces necrosis of the jaws; and here we find the observation of Stanley hold good as in other parts of the body. He says (p. 76): "Syphilis produces its effects mostly upon the compact osseous textures, and in portions of bones which have thin soft coverings, as the flat cranial bones;" and it is in the compact tissue of the palatine plate of the superior maxilla, which is thinly

covered by mucous membrane, that we find the ravages of syphilis most frequent. Occasionally the disease leads to necrosis of portions of the compact tissue of the lower jaw, or attacks the alveolus or body of the upper jaw. Of this I have lately had two examples under my own care, one in a medical man, from whom I extracted a large piece of necrosed alveolus, and the other in a discharged soldier, aged twenty-three, in whom also there was extensive necrosis of the alveolus, extending from the lateral incisor to the first molar on the right side. There was no question as to the cause of the disease in either case. In cases of extensive tertiary ulceration of the face also, the bones may become secondarily affected.

The question of the influence of syphilis in producing necrosis of the alveolus, derives additional interest from the recent trial of an action against a dentist for damage due to necrosis, said to have been caused by the unskilful extraction of a tooth some months before. In this case one surgeon swore that necrosis of the jaw from syphilis was unknown, whilst the opposite view was strongly maintained by surgeons of great experience in syphilitic diseases (*British Medical Journal*, August, 1871).

The proper local treatment of any ulceration or necrosis of the palate is to protect the part from contact of the tongue and food, and to close the aperture by a properly fitting plate of metal or vulcanite, attached to the teeth and arching immediately below the palate, without making pressure upon the edges of the hole itself. A caution may be given against any attempt on the part of the surgeon or patient to fill the gap in the roof of the mouth by any form of plug fitting into the hole left, the effect of which is to enlarge the aperture by absorption, so that the size of the plug has to be constantly increased in order to make it effectual. A preparation in St. Bartholomew's Museum shows the extent to which this absorption may be carried in process of years. The following is the description given in the Museum Catalogue :

"The base of a skull from an elderly woman, who

appeared to have been long in the habit of wearing a plug to close an opening in the palate. The opening gradually enlarging, attained such a size that nothing remains of the palatine portions of the superior maxillary and palate bones, and the alveolar border of the jaw is reduced to a very thin plate, without any trace of the sockets of the teeth. The antrum is on both sides obliterated by the apposition of its walls, its inner wall having probably been pushed outwards as the plug was enlarged to fit the enlarging aperture in the palate. Nearly the whole of the vomer also has been destroyed, and the superior ethmoidal cells are laid open. The plug is preserved; it is composed of a large circular cork, with tape wound round it, and measures an inch and three-quarters in diameter, and an inch in depth. The history of the patient is unknown. She was brought from a workhouse to the dissecting rooms, with the plug tightly and smoothly fitted in the roof of the mouth" (*St. Bartholomew's Catalogue*, 14).

Even the employment of a piece of softened gutta-percha is not unattended with risk: thus, several years ago I saw, with Mr. Lawson, a case in which a patient had thrust a considerable quantity of softened gutta-percha through an aperture in the palate into the nostril, where it formed a hard mass, which was extracted only with the greatest difficulty and at the expense of tearing one of the alæ.

5. *Mercurial Necrosis*.—The severe form of mercurial necrosis, of which patients suffering from syphilis were mostly the victims in the days when salivation was looked upon as a necessary part of the treatment, is now practically unknown. It was formerly met with also as a result of the destructive ptyalism produced by the fumes of liquid mercury employed in the manufacture of looking-glasses. When glass plates were converted into mirrors by sliding and compressing them on to sheets of tin-foil covered with pure quicksilver, the men employed were liable to have their teeth drop out, and frequently lost portions of the jaws, their lives being notoriously shortened. Since the introduction of

a chemical process by which the mercury is deposited on the glass, these cases of induced necrosis have become almost unknown.

One of the earliest symptoms is a metallic taste, which is rapidly succeeded by an inflammation of the mucous membrane of the mouth. The tongue becomes slightly swollen, tooth-indented and sore. The affection of the gums is very characteristic. They become swollen, at first around the necks of the teeth, and feel very sore. The inflammation spreads to the alveolo-dental periosteum, and the effusion poured out raises the teeth from their sockets and at the same time loosens them. If the disease is allowed to progress, the alveolar process becomes affected and may ultimately become necrosed. A good example of this is seen in a specimen presented by Mr. Key to Guy's Hospital Museum. It is a sequestrum consisting of two-thirds of the alveolar processes of the lower jaw, the disease having been induced by the use of mercury for ovarian dropsy.

A specimen in the museum of the Dublin College of Surgeons, showing exfoliation of the entire alveolus, was also due to the administration of mercury.

The ravages produced by mercury may not be limited to the alveolar process, but may spread to any part of the jaw. Thus, in the *American Medical Times* of February 23, 1861, Dr. E. S. Cooper records the case of a child, aged seven, in whom necrosis involving the left half of the lower jaw, including coronoid and condyloid processes, had been produced by the administration of calomel. After removal of the sequestrum, reproduction of the jaw took place, the reproduced bone being at first very much larger than the natural bone, but gradually improving in shape.

Mr. Stanley mentions (p. 72), and gives a drawing of a sequestrum preserved in St. Bartholomew's Museum (i, 102), embracing nearly the whole body of the lower jaw, which suffered necrosis after the administration of a few grains of calomel in a case of fever. It might be doubted whether the necrosis was not due as much to the fever as to the calomel

in this case, but that Mr. Stanley mentions that the patient had excessive salivation and severe inflammation in the gums and cheeks.

Drugs, other than mercury, producing profuse salivation, may lead to trouble in the dental periosteum, but in these cases necrosis very rarely follows.

6. *Phosphorus-Necrosis*.—This, which is perhaps the most formidable kind of necrosis of the jaw, is a disease of modern time, having been called into existence only since the introduction of lucifer-matches, into the inflammable material of which phosphorus largely enters. The earliest mention by British writers of disease in connection with the manufacture of lucifers, appears to have been by Dr. Wilks, in the *Guy's Hospital Reports* of 1846-47; but a paragraph from a German author upon the subject is quoted in the *Lancet* of August 29, 1846. The notice in the *Guy's Hospital Reports* is of a case of disease of the lower jaw with exfoliation, occurring in a lucifer-match maker; and the remark is made that the disease had been noticed to be common among workers in lucifer manufactories—a branch of industry which had then been introduced into London some ten years. In Germany, however (where lucifer manufactories were started some years earlier than in England), phosphorus-necrosis was recognised as early as 1839 by Lorinser, who published a paper upon the subject in 1845, and was followed by Strohl, Heyfelder, Roussel, and Gendrin, and by Sédillot in 1846. In 1847 Drs. Von Bibra and Geist, of Erlangen, published a work (*Die Krankheiten der Arbeiter in den Phosphorzündholzfabriken, insbesondere das Leiden der Kieferknochen durch Phosphordämpfe*), which forms the basis of our present knowledge of the subject, and the conclusions of which further experience has fully confirmed.

In London, the lucifer manufactories being principally at the East End, cases of phosphorus-necrosis are most common in St. Bartholomew's, the London, and the Borough hospitals; and their museums, especially that of St. Bartholomew's, are very rich in specimens. The medical officers of these

institutions having thus had special opportunities of study, have not failed to record their experience, and reference may be made to valuable clinical lectures upon the subject by Mr. Simon (*Lancet*, 1850), Sir J. Paget (*Medical Times and Gazette*, 1862); and Mr. Adams (*Medical Times and Gazette*, 1863); and to the essay on Surgical Diseases connected with the Teeth, by Mr. J. Salter ("System of Surgery," vol. ii).

Etiology.—The cause of the disease is, unquestionably, the fumes of the phosphorus which are inhaled by the operatives during the process of "dipping" the matches, and in a lesser degree during the counting and packing them. When the disease first showed itself in Germany, it was thought that it depended upon the admixture of arsenic with the phosphorus; and it is curious that in the Museum of St. Bartholomew's there are some bones of cows from the neighbourhood of Swansea, which, under the influence of arsenical vapour, have become enlarged and covered with a new bone formation closely resembling that around phosphorus-necrosis. It has been proved, however, that arsenic has nothing to do with the disease; and if proof positive were wanting that phosphorus alone is the deleterious agent, it is supplied by a case quoted by Sir J. Paget, in the lecture referred to, of a man who induced necrosis of his jaws by inhaling fumes of phosphoric acid as a quack remedy for "nervousness."

Lorinser and the earlier writers considered the disease to consist in blood-poisoning, the necrosis of the jaw being consequent thereupon, and Mr. Adams (*loc. cit.*) thinks that the theory of blood-poisoning should not be altogether discarded, since the local disease would not account for the constitutional symptoms experienced. This view has recently received the support of the eminent Berlin surgeon Von Langenbeck, who maintains that all the general symptoms of phosphorus-poisoning are present long before the local disease, which he calls periostitis rather than necrosis, manifests itself (*Berliner Klinische Wochenschrift*, Jan. 8th, 1872). The majority of surgeons agree, however, in con-

sidering the affection essentially a local one, the constitutional symptoms being only consecutive, and an interesting account of the post-mortem examination of a case of general poisoning by phosphorus, following necrosis of the jaw, will be found in the *Pathological Society's Transactions* for 1869.

It is found that the phosphorus fumes produce no injurious effects so long as the teeth and gums of the workers are sound, but as soon as the teeth become carious, or if a tooth is extracted so as to leave an open socket, the disease rapidly develops itself. The experiments upon animals, by Geist and Von Bibra, are amply confirmatory of this view, since they found that rabbits exposed to phosphoric fumes suffered no injury so long as the teeth and jaws were uninjured, but that if the teeth were extracted or the jaw broken, periostitis and necrosis rapidly resulted. On the other hand, it may be mentioned that a case has been recorded by Grandidier (*Journal für Kinderkrankheiten*, 1861), of necrosis of the upper jaw from phosphorus fumes in a child but six weeks old, and in whom therefore the teeth were not developed; and Langenbeck is opposed to the notion that carious teeth predispose to the disorder.

The liability of the two jaws to the disease appears to be about the same, or perhaps with a slight preponderance in favour of the lower jaw. Of 52 cases given by German authorities, 21 were of the superior maxilla, 25 of the inferior maxilla; in 5 both jaws were involved, and one case is uncertain (*British and Foreign Medico-Chirurgical Review*, April, 1848). Mr. Salter (*loc. cit.*) says: "In five cases which I have witnessed, the lower jaw was diseased in four, and the upper in one; whereas four which occurred in the practice of a surgical friend were confined to the upper jaw. In seventeen instances of which I have obtained particulars or seen specimens, nine were connected with the superior, and eight with the inferior maxilla. The disease is therefore pretty evenly balanced between the two jaws." The St. Bartholomew's Hospital Museum contains excellent specimens of both jaws affected by this form of disease.

Symptoms.—As the disease commences in the alveolo-

dental periosteum, the early symptoms are those of alveolar periostitis (see p. 91).

Pain referred to the teeth is one of the earliest symptoms of the disease, and this, which was intermittent at first, becomes at length continuous. The teeth become loose, and pus is seen to exude from their sockets. At the same time the gums become swollen and tender, and are detached to a greater or lesser degree from the alveoli, giving constant exit to a purulent discharge. In many cases of necrosis the face is swollen, so that, if only one side of the jaw is affected, a peculiar lop-sided effect is produced. In the cases of phosphorus-necrosis, however, the swelling of the face is much more marked, the soft tissues around the bone being infiltrated and puffy to an extent which is not witnessed in other forms of the disease. One or more openings now form externally, through which pus constantly exudes, and the probe, introduced through these, readily reaches bare and dead bone.

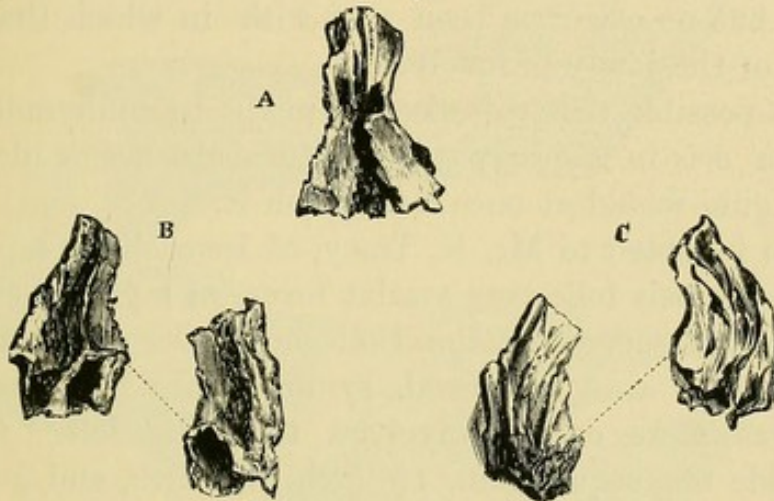
The patient's general health has by this time become seriously affected, owing both to the actual suffering he has undergone, and to the interference with his nutrition which the state of his mouth necessarily involves; it being impossible for him to take any but fluid or semi-fluid food, and that in small quantities. The constant presence of most offensive discharges in the mouth, and mixing with the food, must have an injurious effect upon the patient, though this is questioned by Salter, who remarks that these patients swallow daily many ounces of pus "without any obvious detriment to health." The necrosed portions of bone project more or less into the mouth, and give the patient great inconvenience, and in very severe cases of phosphorus-necrosis gangrene of the cheeks and lips ensues, with a rapidly fatal termination. In less severe cases, the patient may drag on a wretched existence for months, and sink at last from exhaustion, or may occasionally recover with considerable loss of bone and deformity.

Advanced necrosis of the upper jaw may lead to extension of mischief to the brain with a fatal result, as I have

myself seen on one occasion. The patient was a young woman, aged twenty-three, in whom necrosis of the upper jaw had existed for nine months, when head symptoms supervened, and she rapidly sank and died comatose. At the post-mortem examination I found an abscess in the anterior lobe of the cerebrum, evidently originating from the ethmoid bone, the cribriform plate of which was necrosed and perforated.

7. *Exanthematous Necrosis*.—Under this name, Mr. Salter has described (*Guy's Hospital Reports*, vol. iv, and *System of Surgery*, vol. ii) the form of necrosis of the jaw in children

FIG. 42.



A, anterior ; B, external ; C, internal view of inter-maxillary bones.

which depends upon the poisonous effects of some of the exanthematous diseases, and especially scarlet fever. Mr. Salter claims to have been the first to call attention to this form of necrosis and to trace it to its cause, and has met with over twenty instances of the affection. In the *Pathological Society's Transactions* (vol. xi), he has described and figured seven specimens of the exfoliation—four after scarlet fever, two after measles, and one after small-pox. The disease appears to occur most frequently about the age of five or six years, when each jaw contains the whole of the first set, and the germs more or less advanced of the second set of teeth ; but Mr. Bryant has recorded (*Pathological Soc. Trans.*, vol. x) a case of exfoliation of the intermaxillary bones after measles in a child of three (Fig. 42) and the

boy Barton Blackman, already referred to, is an instance of the kind, at the age of ten.

The disease first shows itself, a few weeks after the occurrence of the feverish attack, in tenderness of the mouth and fœtor of the breath, and the gum is seen to be separated from the teeth and alveolus. The inflammation really commences in the alveolar periosteum and is remarkably symmetrical, appearing almost simultaneously on both sides of the jaw, and rapidly denuding the bone, thus leading to necrosis and subsequent exfoliation of considerable portions of it. These usually include the whole depth of the alveolus, together with the partially-developed permanent teeth; but no case has been met with in which the lower border of the jaw was involved.

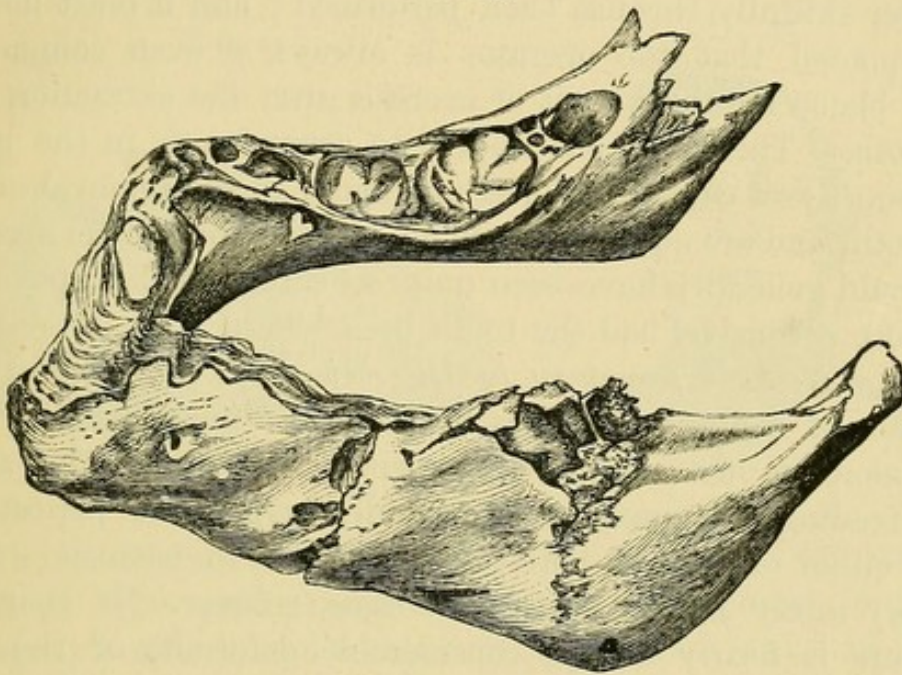
It is possible that this disorder might be confounded with *cancerum oris* in its early stage, but the absence of ulceration of the gum would at once distinguish it.

I am indebted to Mr. N. Tracy, of Ipswich, for a preparation of necrosis following scarlet fever, in a girl of thirteen, which is preserved in the College of Surgeons Museum. The disease was, as usual, symmetrical, but the right side was more deeply involved than the left. On the right side the sequestrum, $1\frac{5}{8}$ inch in length, and $\frac{5}{8}$ inch in depth, contained the permanent first molar and the uncut permanent bicuspid teeth, besides a temporary molar; and involved part of the socket of the second permanent molar behind, and of the canine in front. On the left side the disease involved only a portion of the alveolar border, including a temporary molar tooth. A model, taken three years later, showed the permanent gap left between the canine and the first molar teeth on the right side.

A very remarkable extensive necrosis of the lower jaw, occurring in a child of four, is shown in Fig. 43, taken, by permission, from a specimen brought before the Pathological Society by Mr. Waren Tay (*Pathological Soc. Trans.*, 1874). The sequestrum includes the whole lower jaw, with the exception of one condyle, and the subsequent repair seems to have been very complete. The cause of the mischief appears

to have been doubtful, but may have been due to the trick of sucking lucifer-matches, in which the child is said to have indulged. Mr. Tay brought this patient again before the Pathological Society in November, 1883, when there was a firm ring of new bone present in the situation of the jaw, quite strong enough to give support to artificial teeth if they were supplied. At the posterior part of the left side a sharp-edged tooth has made its appearance lately. He could depress and elevate the jaw vigorously. On the left side,

FIG. 43.



where the condyle was wholly removed, there was good lateral movement, but on the right side, the movements were not so free, though he had no difficulty in chewing food.

Mr. Salter regards necrosis after typhoid fever as of rare occurrence. In the Guy's Hospital Museum, however, is a portion of lower jaw, consisting of condyle, angle, and part of the body of the bone, separated by necrosis after fever, from a boy of fourteen. He recovered with comparatively trifling deformity, and the skin remained sensitive, although a large part of the trunk of the nerve must have been destroyed. In St. George's Hospital Museum also there are specimens of necrosis of the lower jaw and clavicle

in fever. A case of very extensive necrosis occurring after fever, under Mr. Stanley's care, will be referred to further on.

8. *Necrosis following Injuries.*—In the chapter on complications of fracture of the jaws, attention has been drawn to the necrosis that may follow, especially after injuries caused by firearms. The unskilful extraction of a tooth may lead to fracture of more or less of the alveolar margin, followed by necrosis, and, according to Tames, "necrosis of a portion of the bone may follow upon the extraction of a tooth, however skilfully this has been performed; and it must not be supposed that the operator is always, or even commonly, to blame for the advent of necrosis after the extraction of a tooth. The conditions leading to necrosis are, in the great majority of cases, developed previously to the removal of the tooth, and are quite independent of its removal; the necrosis would generally have been quite as sure, and perhaps even more extensive, had the tooth been left in."

9. *Necrosis secondary to Ulceration of the Mouth.*—In cases of cancrum oris it is by no means uncommon to find a more or less extensive necrosis of the jaw. The acute spreading inflammation may rapidly involve the periosteum of either or even of both jaws, and lead to necrosis. It is very rarely indeed that these cases recover. If they do, there is nearly always considerable deformity of the face and interference with the movements of the lower jaw.

Again, necrosis may be secondary to ulceration of the mouth, met with in patients suffering from scurvy. Occasionally ulcerating growths of the face or jaws may lead to necrosis of the jaws.

10. *Necrosis without any Apparent Cause.*—Slight necrosis, limited to a tooth socket, occurring without any apparent cause, has already been alluded to (see p. 104). Much more extensive necrosis than this may occur, however. Thus, Stanley mentions the case of a man, aged thirty, who, twelve months before he saw him, began to suffer pain in his upper jaw, soon after which the teeth fell out of their sockets and matter was discharged into the mouth. When

the dead bone was sufficiently loosened Mr. Stanley drew away the greater part of both superior maxillæ.

A very similar case occurring in a strumous man, aged forty, is recorded by Mr. Ernest Hart, in the *Lancet*, July 19th, 1862, and by the kindness of that gentleman I am enabled to reproduce the drawings of the bones when removed, and of the patient after the operation.

A second case, very similar to the above as respects the absence of cause for the disease, has been recently under my notice, the report of it having been kindly furnished to me

FIG. 44.

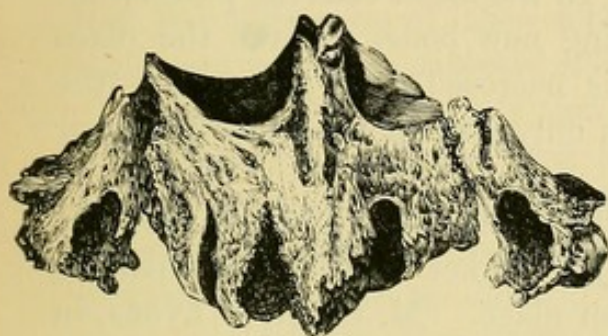


FIG. 45.



by Dr. Garnham, of the Peninsular and Oriental Company's Service. The patient, aged forty, was an engineer in the Company's service, and enjoyed perfectly good health in the tropics for some years, but soon after his return to England his mouth became sore, sloughing of the gums took place, and, when I first saw him, very large portions of the alveolus of the lower jaw were necrosed, and lying exposed in the mouth. Subsequently these came away or were removed by Dr. Garnham, and the patient having been reduced to an edentulous condition, as regards the lower jaw, it became necessary to apply to Mr. C. J. Fox, the dentist, for artificial aid. Dr. Garnham attributes the disease to depression of the vital powers, owing to long residence in warm climates.

CHAPTER IX.

REPAIR AFTER NECROSIS.—TREATMENT OF NECROSIS.

THERE is a striking difference in the amount of repair that takes place after necrosis of the whole or portions of the upper and lower jaws. In the latter case the periosteum is very active in producing new bone, to take the place eventually of that which is necrosed. In the case of the upper jaw, however, there is only a slight tendency for repair to take place.

Upper Jaw.—In adult life, except in rare instances, the periosteum of the upper jaw makes no effort at repairing the mischief which has taken place. M. Ollier, of Lyons, in his very valuable work *La Régénération des Os*, 1867, gives a case of phosphorus-necrosis of the upper jaws where a certain amount of new bone was produced, and also one of necrosis of the upper jaw from other causes in which a development of osteo-fibrous tissue took place in a young woman of nineteen. He quotes also from the practice of Billroth, of Zurich, the case of a man, aged twenty-seven, in whom, after phosphorus-necrosis, a development of plates of bone took place. These cases must be regarded, however, as quite exceptional, Trélat, in his thesis (1857), having failed to discover a case of osseous reproduction of the superior maxilla. In children, on the other hand, a development of tough fibrous tissue takes place, which gradually fills up pretty completely the cavity left, and thus, to a great degree, prevents the falling in of the cheek and consequent deformity which would otherwise occur. In the Museum of King's College is a preparation of the nearly entire upper jaw of a child, which became necrosed as a consequence of small-pox,

and was removed by Mr. Partridge, when surgeon to the Charing Cross Hospital. By the kindness of the late Mr. Canton, I had access to a photograph of this patient, taken within the last few years, which shows the very slight deformity now present, in consequence of this repair of the original mischief.

This statement respecting the repair of a necrosed superior maxilla is, at first sight, in opposition to the opinion of Stanley ("On Diseases of the Bones," p. 72), who says, "under whatever circumstances the necrosis has occurred, it is not, as I believe, ever followed by the slightest reproduction of the lost bone." This I believe to be true *quoad* the reproduction of actual bone, and in the case of adults, but the filling up of the cavity by fibrous tissue I have witnessed in young subjects after the removal of tumours.

Lower Jaw.—The repair that takes place after necrosis of the entire or a portion of the lower jaw may be very complete. As soon as the pus that has formed has been given a free exit, and the acute inflammation has subsided, the periosteum begins to develop new bone, which forms a more or less complete shell around the necrosed portion. Through the cloacæ, or openings, in this new shell of bone, which correspond to the external apertures on the skin, and also from the mouth, the dead bone or *sequestrum* can be readily examined with the probe, and, when sufficiently detached and loosened to be readily extracted, it should be removed if possible through the mouth so as to avoid deformity from an external wound. It is of importance that this removal should not be undertaken until the shell of new bone is sufficiently organised to maintain the shape of the original bone, for if otherwise, the reproduction of the bone will be interfered with, and perhaps prevented. So soon as the sequestrum is removed from the interior of the shell of new bone, the space thus left becomes rapidly filled with granulations springing up from the whole surface of the cavity, and these are soon converted into a fibrous mass, which is ultimately developed into bone. In 1869 I had under my care in University College Hospital a case of

necrosis of nearly the entire lower jaw in a man of twenty-two, from whose mouth I extracted several large sequestra, including the right condyle. In this case, and in others of the kind which I have seen, the repair has been of the most perfect kind, the movements of the jaw being as free as if the articulation had not been interfered with.

In the *Medico-Chirurgical Trans.*, vol. lvii, is a case of phosphorus-necrosis, reported by Sir W. Savory, in which, six months before the death of the patient, a lad of eighteen, the whole of the lower jaw was extracted, and is preserved in St. Bartholomew's Museum. Although "at this time there was not sufficient firmness in any part of the region to indicate the formation of new bone, yet in the course of a week or two afterwards there was distinct evidence of new bone on either side about the angle, which gradually extended." The new lower jaw which had been formed is shown in Fig. 46, and is perhaps one of the most perfect specimens of the kind ever seen. "In size, shape, and development it is very remarkable. The bone is solid and dense, and in two pieces only. The greater portion constitutes the whole of the bone, with the exception of the right ramus. This was united to the body by fibrous tissue, and separated during maceration. In size and form, and especially in the absence of alveolar portions, the jaw very nearly resembles the edentulous maxilla of a very old person, as shown in Fig. 47."

In former years there has been a great deal of discussion concerning the source of this new bone. At the present day there seems no doubt that the new bone can only be formed from the periosteum or from any living bone which may remain, and that if the former is destroyed by the acute inflammatory process which caused the necrosis, no repair can take place. In the majority of instances the periosteum is not completely destroyed, but can form, to a greater or less degree, new bone.

Even when the condyle with a large portion of the ramus of the jaw is necrosed, complete repair has been found in

FIG. 46.

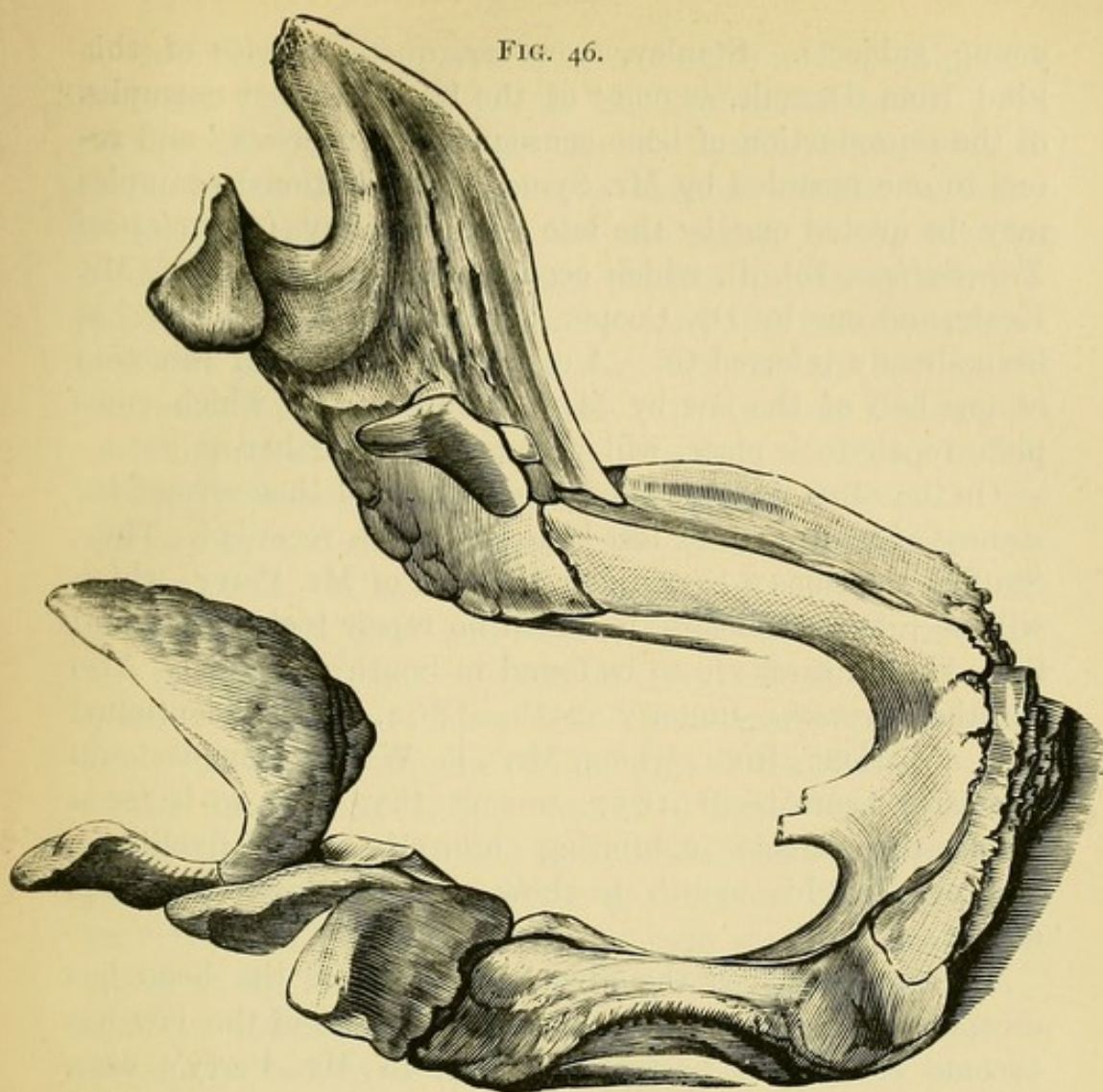
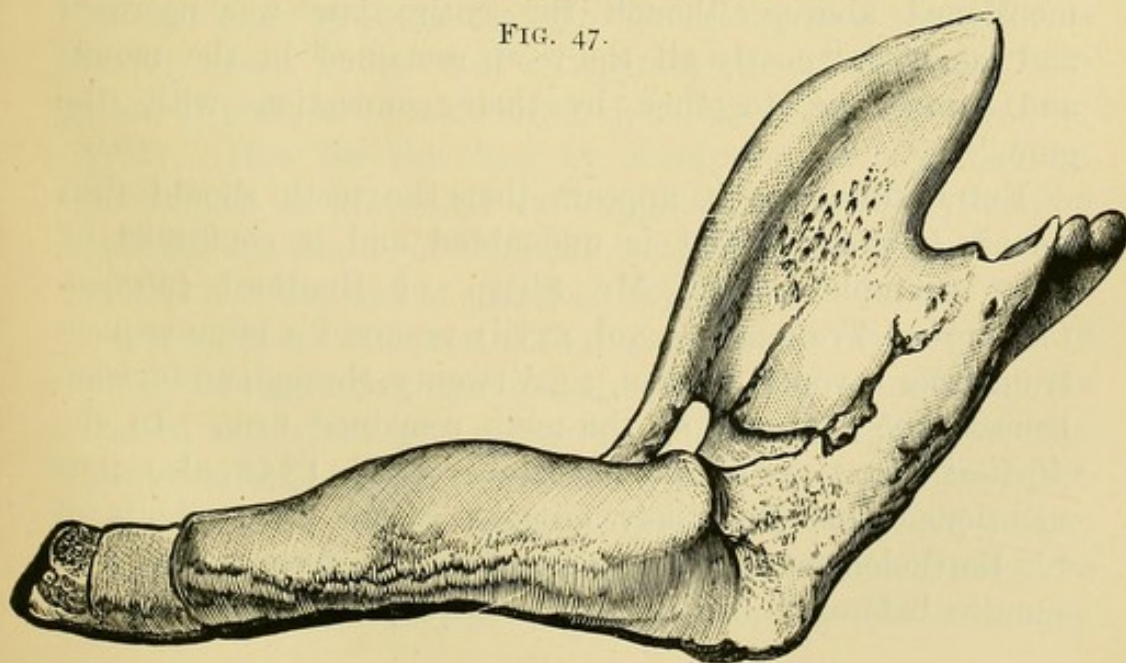


FIG. 47.



young subjects. Stanley, however, quotes a case of this kind from Desault, as one "of the least frequent examples of the reproduction of bone consequent on necrosis," and refers to one recorded by Mr. Syme. As additional examples may be quoted one by the late Mr. H. Gray (*Pathological Transactions*, vol. ii), which occurred in the practice of Mr. Keate, and one by Dr. Cooper, of San Francisco, which has been already referred to. A case of sub-periosteal resection of one half of the jaw by M. Maisonneuve, in which complete repair took place, will be referred to further on.

On the other hand it should be remarked that several instances of non-repair of lost bone have been recorded. Thus, Stanley mentions a case under the care of Mr. Perry, which will be referred to again, in which no repair took place: and three similar cases are to be found in South's *Chelius*. Also in the *Lancet*, January 25th, 1862, it is mentioned that a patient from whom Mr. T. Wakley removed an extensive necrosis in 1857, was at that time to be seen about the streets exhibiting himself for a livelihood, and everting his mouth to show that his lower jaw was absent.

In rare instances the alveolar margin of the bone has escaped death although the whole of the rest of the jaw has become completely necrosed. Thus, in Mr. Perry's case, mentioned above, although the entire jaw was necrosed and removed, "nearly all the teeth remained in the mouth and were kept together by their connection with the gum."

Extraordinary as it appears that the teeth should thus remain *in situ*, the fact is undoubted and is confirmed by other examples: thus, Mr. Sharp, of Bradford (*Medico-Chirurgical Transactions*, vol. xxvii), removed a large sequestrum from a young woman, aged twenty, through an incision beneath the chin, and all the teeth remained firm. In the *Medical Times and Gazette* of October 30th, 1858, also, it is mentioned that Mr. Skey brought before the students of St. Bartholomew's a young man of twenty, from whom, four months before, he had removed a sequestrum including the

entire left side of the jaw from the ramus to the symphysis, and the right side as far as the last molar tooth. The sequestrum showed the sockets of twelve teeth—viz., all those of the left side, and the incisors, canine, and first bicuspid of the right side; but the whole of the alveolar border of the right side was not present in the sequestrum. Instead of coming away with the bone, the incisors, canine, and first bicuspid of the right side, and even the left central incisor, had remained in the gum. The patient now applied to Mr. Skey to have these teeth removed, as, although they evidently possessed vitality and were firmly attached to the gums, they had sunk in position so as to be irregular and inconvenient. I have, however, seen one case in which the teeth remained firm and useful after extensive necrosis; but in this case the sequestrum involved only the outer plate of the jaw, the inner with a great part of each socket being left for the support of the fangs of the teeth.

An observation of Mr. Salter's ("System of Surgery," vol.ii) deserves notice, and it received confirmation from one of the cases recorded by Mr. Chalk in the paper already referred to. He says, "Though it has not been stated in books, this repair of the lower jaw is but temporary, for after a time—often a considerable time—the new bone diminishes by absorption to a mere arch, and ultimately there is scarcely enough bone to keep out the lower lip, and the chin is utterly lost. I have had an opportunity of examining this state of parts after the lower jaw had been removed ten years. How far this loss, by absorption of supplemental bone, may be prevented by supplying it with a function through the means of artificial teeth, is a question of theoretical interest and of practical importance."

One, almost constant, pathological peculiarity in cases of phosphorus-necrosis has been already alluded to, and deserves special notice; it is the deposit of a peculiar, pumice-like, bony material around the necrosed portions of the lower jaw, for it is not found in cases of disease of the upper jaw. This is doubtless derived from the periosteum, although so closely adherent to the sequestrum as to be invariably

brought away with it; and though resembling true bone in some particulars, it is decidedly of a lower development.

According to Von Bibra (*op. cit.*), who has laboriously investigated the subject microscopically, the Haversian canals exhibit in part a larger diameter than those of normal bone and are empty, except where the deposit appears smooth and compact, and is partially covered with periosteum. They are *not parallel* with the general direction of the bone, but are placed *at right angles* to the latter; they interlace with one another, sometimes expanding to form sacs, sometimes contracting, and end with open mouths on the surface. Their mouths are more minute in the most recent deposit, and appear larger in older layers. The bone corpuscles are rounded off or angular, and their circumference is less decided; during the progress of the formation of the deposit they are very large, and their contour proportionably undefined. They appear filled and dark-coloured; at first they are lighter, and they have ramifications like those of normal bone, which increase in number with the age of the deposit. The fundamental structure of the deposit is laminated, and several layers are distinctly seen resting upon one another. It exhibits rents with which the ramifications of the corpuscles are connected, and which may therefore be considered as continuations of the latter. Spots are also visible here and there, which Von Bibra looks upon as accumulations of earthy matter. This matrix of the new deposit is at first very brittle; after the deposit has been exposed to the process of absorption it shows a powdery appearance, as if sprinkled with a coarse powder.

It appears, however, that cases of necrosis other than those due to phosphorus occasionally lead to a deposit of pumice-like bone upon the sequestrum. Mr. Perry's case of necrosis of the entire lower jaw, already alluded to (and which will be found *in extenso* in the *Medico-Chirurgical Transactions*, vol. xxi), is a case in point, the sequestrum, as may be seen from the drawing given of the preparation in St. Bartholomew's Museum, being thickly encrusted with new bone, closely resembling that seen in phosphorus cases.

The disease in this case was attributed to rheumatism, and corresponds very closely to the description given by Dr. Senftleben of the later stages of acute rheumatic periostitis. (See p. 102.) He says, "Spontaneous separation of the sequestrum rarely ensues; it remains to some extent in organic connection with the osteophytes and ultimately, after a number of months, a year, or even more, an operation has to be performed, in which both the sequestrum and the osteophytes are removed together."

Treatment of Necrosis.—Bearing in mind that necrosis is not a disease in itself, but is the result of a previous inflammation, it is evident that the first aim of the surgeon is to prevent this untoward result. With this view, the principles of treatment laid down in the chapter on inflammation and abscess should be carried out. If, however, in spite of treatment the inflammation progresses and necrosis results, we have to consider the best way of dealing with the dead bone. When necrosis has actually taken place and pus has formed, the tendency of the latter is to point either in the mouth or on the surface of the face. In the latter case, one or more sinuses will form, and give rise to great disfigurement. Free incisions should therefore be made through the gums, and a free exit given to the pus. Decomposition of the discharge must be prevented as far as possible, by the frequent use of antiseptic mouth-washes and powders. Solutions of permanganate of potash, carbolic acid or boracic acid, together with iodoform or boracic acid powders are of great value. When the patient is unable to cleanse his mouth satisfactorily by his own efforts, the suppurating cavity should be mopped out with sponges, or washed out with a syringe or suitable irrigator.

Since it is impossible that the patient should masticate solid food, it is important that animal food should be prepared in a suitable manner, and this may be attained by making use of soups or essences of meat, and by reducing well-cooked meat to a mash with pestle and mortar. Milk and eggs form very suitable articles of food, and may be supplemented with wine or stout. At the same time, drugs

having a tonic action may be given, such as quinine and iron.

Most British surgeons agree in counselling non-interference with the sequestra in cases of necrosis until the shell of new bone around is sufficiently developed to maintain the form of the jaw; they are then to be extracted through the mouth, if possible, and if not, through incisions, placed so as to cause as little subsequent deformity as possible. When the sequestrum, although partially detached, is not ready for removal, and greatly inconveniences the patient, a part may be clipped off with the bone forceps, so as to present a smooth surface, and if the teeth are loose and troublesome they had better be removed at once, but if firm they should be left, since, as has been shown, they occasionally become useful. The caution already given, against interfering with the permanent set of teeth in cases of necrosis in children should be borne in mind.

Some Continental surgeons, however, interfere at an early date, and among them Professor Billroth, who, according to the report of the meeting of the Medical Congress at Zurich in 1861 (*Medical Times and Gazette*, June 8th, 1861), "penetrates immediately, with one incision, which he makes parallel to the necrotic part, through the skin down to the bone; he then scrapes off the periosteum with its bony layers upwards and downwards, by means of a raspatorium, and saws smaller or larger pieces of bone out of the jaw: or he nips those pieces off by means of bone-pincers. In a few cases it appeared advisable to disarticulate at once one or both coronoid and condyloid processes of the lower jaw, which was very easily done, as the joint had become very loose in consequence of the long suppuration. Of the six cases shown by the Professor, two were healed, and amongst them was one of total resection of the jaw in a woman of thirty-five years. This case was in so far remarkable, as two apparently healthy teeth had remained in the periosteum, which had become partly ossified, and in the gums, which had remained healthy; and these have now been used for seven months. Mastication is not

impaired, and the woman has a much healthier appearance. The second case in which the resection of one-half of the jaw was performed, is also well healed; but the mouth is, of course, crooked. Two cases, in which a partial resection has been made, are progressing favourably; in another case the treatment with mercury and iodine has been commenced."

When the whole lower jaw is necrosed it is necessary to divide it before it can be extracted. This may be done, as in Mr. Perry's case, by making a section with the saw near the angle on each side; or, better, by dividing with the saw at the symphysis, either without external incision, as in Mr. T. Smith's case, or after reflecting flaps of skin, as in a case of Sir J. Paget's, which will be found in the *Lancet*, 1862. In a case of necrosis of the entire lower jaw, from phosphorus, which was in the London Hospital under Mr. Adams' care, that gentleman preferred to divide the symphysis with a mallet and chisel, and the case is moreover remarkable from the unusual occurrence of secondary hæmorrhage, for which ligature of the common carotid became necessary—the patient eventually recovering. The case will be found in detail in the *Medical Times and Gazette*, 1863.

Under the name of "Sub-periosteal Resection," operations have been described by foreign surgeons, which in no respect differ from the extraction of sequestra as ordinarily practised, and of which the following case, taken from the *Lancet*, of 1863, is a good example: "M. Rizzoli, of Bologna, submitted to the Surgical Society of Paris a case of necrosis of the lower jaw, from the fumes of phosphorus, in a man aged fifty-six years, in which the sequestra were removed through the mouth. M. Rizzoli made incisions on either side of the gums, scraped the thickened periosteum with a spatula from the dead bone, and removed the latter piecemeal. The preserved periosteum generated new bone in the place of the portions taken away, which comprised the body and part of the ramus on each side. It was, however, soon found that the upper part of the ramus and the

condyle were also diseased ; these portions of bone were also removed through the mouth with the same precautions, and the periosteum again acted in the same way. Eventually the man was able to use his jaw and masticate, though deprived of teeth. M. Forget, who reported on the case, observed, very justly, that there was nothing new in the action of the periosteum in necrosis of bones, surgeons having long acted upon this periosteal property in such cases. M. Flourens had pointedly said, 'Take away the bone, preserve the periosteum, and the preserved periosteum will restore the bone ;' but this applies less to cases of necrosis of bone than to cases of experiments on animals, and operations performed on healthy bone and periosteum. And even in these cases it should be remembered that osseous substance is reproduced, but not the actual bone as it existed before the resection."

In some cases, however, incisions have been made at a comparatively early stage, before the shell of the new bone has been formed, and the sequestrum immediately extracted, with good results. It may be doubted, however, whether there is any real gain in such procedures, either in time or result, since the repair is no more rapid than if the sequestrum were left, and there is the additional risk both of the actual operation, and of the deformity which may result from the premature withdrawal of the sequestrum. A case from the practice of M. Maisonneuve, illustrating the practice in the lower jaw, will be found in the *Comptes Rendus*, April, 1861. In his standard work, "La Régénération des Os," M. Ollier, of Lyons, gives two cases of subperiosteal resection, one of the upper and one of the lower jaw, for necrosis, in neither of which was there any osseous development ; and these cannot, therefore, be regarded as very satisfactory examples of a proceeding whose great aim is the development of new bone.

With regard to the prevention of phosphorus-necrosis, the following extract from Mr. Simon's report to the Privy Council (1863), may be quoted with advantage, as giving the results of Dr. Bristowe's careful investigation of the subject : "The dangers to which I have adverted, as

belonging to the phosphorus industry, belong exclusively to working with common phosphorus. Working with amorphous phosphorus is unattended with danger to health. Since, however, it appears that, with reasonable precautions, the use of common phosphorus for match-making need not be an unwholesome occupation, I cannot say that, in my opinion, the substitution of amorphous for common phosphorus in the manufacture is, for sanitary purposes, an object to be unconditionally insisted on. Yet having regard to the fact that amorphous phosphorus not only is manufactured without danger to the worker, but that its use in lucifer boxes also involves infinitely less danger of fire than belongs to common lucifer matches, I think that the substitution is altogether one to be desired. And, of course, with reference to any restriction which the legislature might think of imposing on the utilization of common phosphorus, it would deserve to be remembered that manufacturers would have at their option the alternative of using, without restriction, the innocuous amorphous material."

CHAPTER X.

HYPEROSTOSIS.

UNDER the head of diffused hyperostosis it will be convenient to group together those remarkable examples of hypertrophy of the maxillæ, and more or less of other bones of the face and cranium, which have occurred from time to time, and have been recorded by Howship, Grüber, Astley Cooper, Bickersteth, and others. These cases form a group of diseases of bone of which we know very little as to either their etiology or pathology. They seem to fall into two chief divisions.

1. In this group the hypertrophy is limited to the jaws or the bones of the face or cranium, and may be called *Diffused Hyperostosis*.

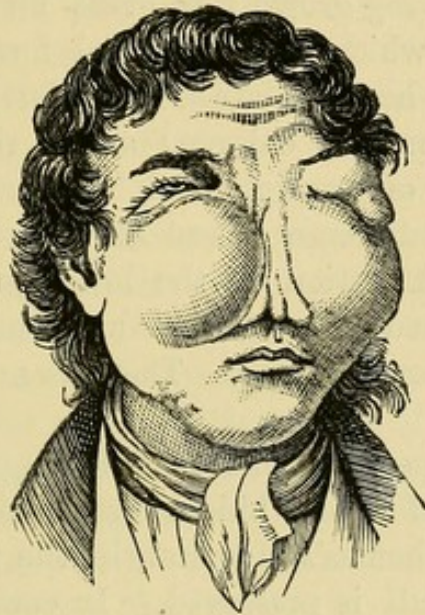2. In some cases the hypertrophy is not limited to the bones of the face or cranium, but may involve other bones, especially those of the extremities. For an accurate description of these cases we are indebted to P. Marie.

Diffused Hyperostosis of Face and Cranium.—In these cases the aspect of the face may be considerably changed, presenting a somewhat leonine aspect, for which reason Virchow applied the term “leontiasis ossea.”

One of the earliest cases was put on record by Mr. Howship in his “Practical Observations in Surgery” (1816). The patient, when about forty-five years of age, and apparently in perfect health, was exposed to a cold wind, immediately after which he perceived an itching and heat in his eyes, and swelling of the face rapidly supervened. A small tumour formed just below the inner angle of each eye, which burst, and, after twelve weeks, he was able to resume

his employment. He suffered from inflammatory attacks in the tumours, with much pain in the head, on more than one occasion, and consulted many medical men, but no treatment relieved the disease or retarded the growth of the tumours, which increased slowly, and were of stony hardness. The eyes were projected from the orbits by the tumours, and the right eye inflamed and burst, while the left was accidentally ruptured by a blow. The patient lived to over sixty years of age, and died of apoplexy, having been occasionally maniacal during the last two years of his life.

FIG. 48.



The accompanying portrait (Fig. 48) is taken from Mr. Howship's work. The skull of this patient is preserved in the College of Surgeons, and shows, as might be anticipated from the portrait, two large masses of almost exactly symmetrical form and arrangement, which have partially coalesced in the median line. The growths are as hard as ivory, and consist of a very close cancellous structure. They project more than three inches in front of the face, and an inch beyond the malar bones on each side: they completely fill both orbits, the cavities of the nose, and, probably, both antra, and they extend as far backwards as the pterygoid plates of the sphenoid bone. In the Catalogue of the Museum it is stated that the man attributed the growths to

repeated blows received on the face in fighting, but Mr. Howship makes no mention of this; and the information was probably derived from Mr. Langstaff, in whose collection the preparation originally was.

A skull of a Peruvian, also in the Museum of the College of Surgeons, exhibits the same form of disease, but of a more diffused character, all the bones of the face, as well as the frontal and the adjacent parts of the sphenoidal and parietal bones, being enlarged and thickened in a remarkable manner. The nasal fossæ and orbits are nearly closed, the superior maxillary bones, and the orbital portions of the malar and frontal bones, having grown into great knobbed and tubercular masses, in which their original form can be hardly discerned. The hard palate is similarly diseased. The lower jaw is enormously enlarged at its right angle, and in the greater part of its right half it measures upwards of five inches in circumference, and all but three of its alveoli are closed up. A section of the lower jaw shows that its interior is composed of an almost uniformly hard and compact, but finely porous, bone. There is no history attached to the specimen.

Sir Astley Cooper's patient was a Billingsgate fish-woman, long remarkable for her hideous appearance, who died of apoplexy in St. Thomas's Hospital, in the museum of which institution the skull is preserved. In connection with each superior maxilla is a rounded bony growth, extending from the lower margin of the orbit to the roots of the alveolar processes. The cavity of each antrum is occupied by the growth, which by its projection has encroached upon the nasal fossæ, and filled the frontal and ethmoidal sinuses. The case, therefore, closely resembles Mr. Howship's specimen.

Mr. Bickersteth's very remarkable specimen was exhibited to the Pathological Society of London in April, 1866, by Dr. Murchison, and its description in the Society's *Transactions* is illustrated with admirable lithographic drawings.

The patient, who died at the age of thirty-four, first

noticed an enlargement of the bones of the face when a boy of fourteen. The swelling of the face gradually increased, and thirteen years after its commencement a similar hard swelling appeared along the course of the left fibula. About two years before death he began to suffer severe pain, which continued to his death, this being the result of emaciation, consequent upon the encroachment of the disease upon the mouth. All the bones of the head are more or less involved in the disease, with the remarkable exception of the occipital bone. The malar bones are developed into dense globular masses, the size of an orange. The palatal processes of the superior maxillæ are also greatly diseased, a rounded mass projecting down on each side so as to fill up the cavity of the hard palate to a level with the alveolar ridge. The lower jaw is enormously thickened in every direction, the right side more so than the left. Little trace can be seen of a condyle, coronoid process, or sigmoid notch, the whole being fused into one uniform globular mass.

A very elaborate account of the specimen, with measurements and microscopical appearances by Mr. De Morgan, will be found in the seventeenth volume of the *Pathological Society's Transactions*, from which the above is condensed.

A fourth specimen is preserved in the Musée Dupuytren, in which both upper and lower jaws are extensively affected; and specimens showing the disease in a lesser degree will be found in the museum of the Dental Hospital, Leicester Square, and elsewhere.

In all these specimens the external surface of the bones affected is more or less coarsely tuberculated; the tissue is hard and dense, and minutely perforated for the passage of blood-vessels. In the case of the lower jaw of the Peruvian skull, the interior is composed of an almost uniformly hard and compact, but finely porous bone. Traces of the original walls of the jaw are discernible nearly an inch beneath the surface of the most enlarged part, but its interior is filled up with the same kind of osseous substance as that which is outside the trace of the wall.

A microscopical examination of the St. Thomas's Hospital

specimen "shows it to consist of two kinds of bony matter ; one firm and compact, while the other is more or less soft and spongy. In the former, Haversian canals occur, having concentric laminae around them, but in the spongy portion cancelli only are present, and the bone exhibits a granular structure, with numerous bony cells arranged in no definite order."

In Mr. Bickersteth's specimen, "The compact structure is traversed in every direction by large branching and communicating vascular canals, forming in some places a close network. . . . The spaces between the canals are filled up by bone-tissue of ordinary character. The lacunae are in general very numerous, but they are small, and for the most part elongated. Very few traces of true Haversian systems are to be seen."

It is stated in the report upon the last specimen, that the microscopical appearances are nearly identical with those of the Peruvian skull in the Hunterian Museum.

In the Museum of St. Bartholomew's Hospital is a specimen showing obliteration of the antra, due to hypertrophy of the bone, of the same character as in the specimen described above, but in an earlier stage. Mr. Stanley ("On Diseases of the Bones," p. 297) gives the case of a girl of fifteen years in whom enlargement of the nasal process of the superior maxillae had been observed for eight years, and was increasing. There was no external deformity, but it was thought advisable to interfere at an early date, when it was found that obliteration of the antrum had already taken place, as in the preceding case. The entire jaw was removed, but the patient unfortunately died of erysipelas.

In the Museum of King's College is another specimen, which shows well the obliteration of the antrum by hypertrophy of its walls. The tumour was removed in 1842, by Sir William Fergusson, from a girl of twelve, in whom some enlargement of the face had been noticed from the age of four, and whose portrait is shown in Fig. 49, taken, by permission, from that eminent surgeon's "Practical Surgery." The patient made a perfect recovery, and the particulars of

the case will be found in the *Lancet* of February and March, 1842. Fig. 50 shows her portrait after recovery from the operation.

In the same museum is a specimen of the disease in the ramus of the lower jaw, removed by the same surgeon from a girl of thirteen, by sawing in front of the molar teeth and disarticulating. The patient made a good recovery.

I have now met with several cases more or less closely

FIG. 49.

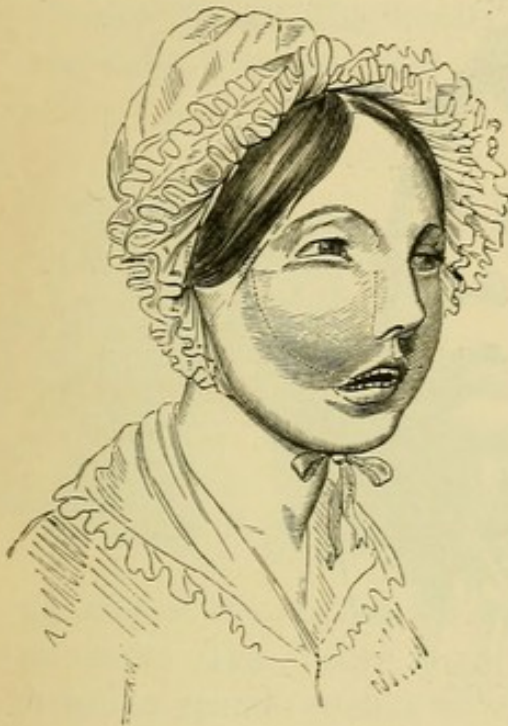
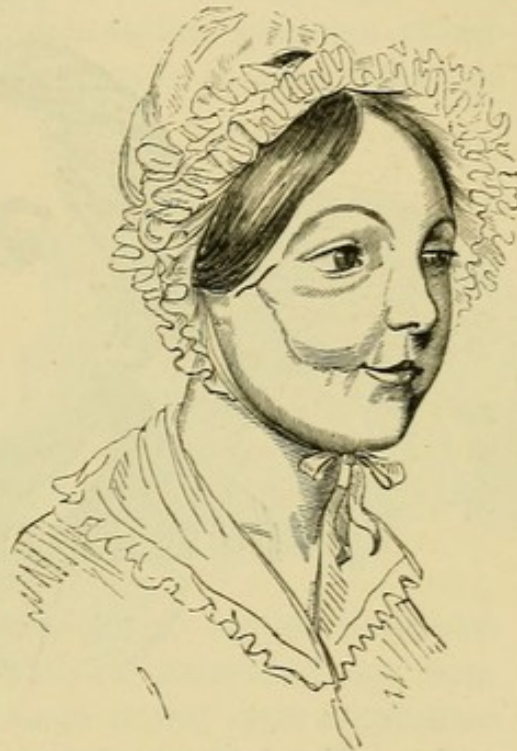
FIG. 50.



resembling those described above. The most marked one was in a lady, aged thirty-nine, who had a blow on the right cheek when fourteen, and noticed an outgrowth when about eighteen. When she was brought to me by Mr. Salzmann, of Brighton, I found a very marked projection of the right cheek, due to an enlargement of the superior maxilla, which was smooth and uniform on its surface. Without any external incision I succeeded in gouging away a quantity of dense bone without opening any antral cavity, and thus reduced the face to a symmetrical appearance. The cure has, I believe, been permanent.

A remarkable case of hyperostosis with hypertrophy of the tissues of the corresponding side of the face has been under my notice for fourteen years. The patient, a healthy boy, aged twelve, was sent to me in November, 1869, by Mr. Giles, of Staunton-on-Wye, under whose care he had been from birth. When three months old the patient's face was noticed to be enlarged on the left side, and this enlargement gradually increased until he presented the appearance shown in Fig. 51, from a photograph taken in

FIG. 51.



1869. The left superior maxilla had shared in the hypertrophy, and the condition of the palate and teeth is shown in Fig. 52, reduced from a cast, where it will be seen that the temporary incisors and canine teeth are still *in situ* on the diseased side, though they have been replaced by the permanent teeth on the healthy side. I removed the left superior maxilla on December 1st, 1869, in the hope that the removal of the bone and the necessary incisions in the cheek would lead to a permanent relief of the deformity. The patient made a perfectly good recovery, and I subsequently endeavoured to open the eye and to destroy a portion of the tissue of the cheek, but without much permanent success,

the patient's condition two years after the operation being as unsightly as before. In 1883 I received from Mr. Giles later photographs of this patient, which show that the hypertrophy of the soft parts has kept pace with the patient's growth.

A section of the removed upper jaw showed considerable condensation of the bone, and the fact that the permanent incisors and canine teeth, together with the uncut molars, were imbedded in the bone, and holding very much their natural relations to the temporary teeth (Fig. 53). Mr. Charles Tomes, who kindly examined the specimen microscopically, reported that "the structure is remarkable on

FIG. 52.

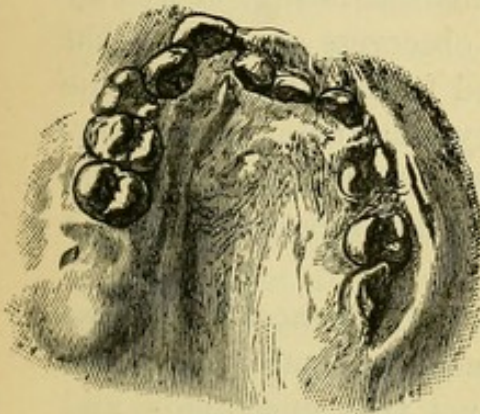
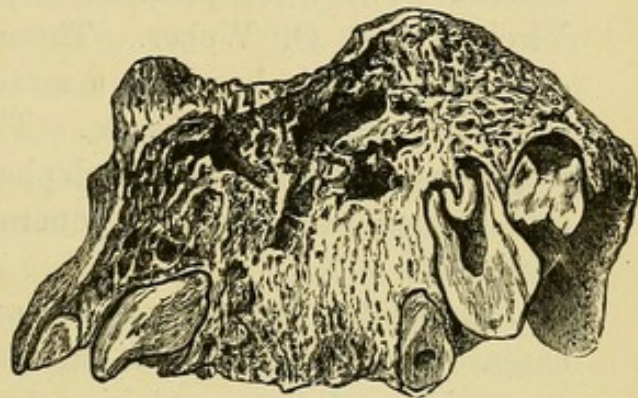


FIG. 53.



account of the absence of well-developed regular Haversian systems. The bone is everywhere excavated by large irregular spaces, around which there is but little appearance of lamination, so that it presents some little resemblance to so-called 'primary bone'; the lacunæ are arranged somewhat irregularly. None of the peculiar branched vascular canals, figured by Mr. De Morgan in his account of the microscopic characters of Mr. Bickersteth's case, were observed in their sections. That the whole of the bone has from an early period participated in the morbid action is indicated by the fact that, although the teeth have attained to something like the stage of development appropriate to the patient's age, the alveolar border has not the development of the jaw in the antero-posterior direction, being insufficient to allow of the second permanent molar coming down and ranging with the

other teeth. The second molar is a small tooth, and the wisdom tooth is greatly stunted."

Etiology.—Most of the cases have presented early in their course symptoms pointing to an inflammatory condition of the bone, affecting probably both the periosteum and the osseous substance. The cause of this inflammatory condition it seems impossible definitely to state. It appears to be entirely unconnected with syphilis or tubercle, and to be completely beyond the control of remedies. Some of the cases have followed a blow, such as a kick from a horse, and it is possible that the inflammation thus caused may have started the disease. There is nothing to support the view of Hushche that the hyperostosis may be a manifestation of rickets. The most probable explanation is that offered by Virchow and O. Weber. These observers consider that erysipelas, which has been a marked feature in some of the cases, has started the disease. They look upon the hypertrophy as analogous to the elephantiasis that may occur in soft tissues, and which is generally closely associated with erysipelas.

Treatment.—Drugs seem to have no influence upon these cases. Lesser degrees of enlargement of both upper and lower jaws of the same kind are not very uncommon, and in one or two patients I have certainly seen good follow the prolonged administration of the syrup of iodide of iron. It is very doubtful, however, whether these were really cases of diffused hyperostosis. In the 31st vol. of the *Pathological Society's Transactions*, Mr. R. W. Parker gives a drawing of remarkable symmetrical hyperostoses of the angles of the lower jaw in a girl of twelve, which he considers to be the result of congenital syphilis, and the subsequent history confirmed the diagnosis, the gummata disappearing under treatment. I have, however, twice been consulted for precisely similar hypertrophy of the angles of the jaws occurring in perfectly healthy young women, one being the daughter of a medical friend, in whom there was no suspicion of congenital taint.

When the disease affects only one of the maxillæ, which

is its favourite seat, operative interference will be advisable. Several cases have been already mentioned where removal of the hypertrophied maxilla was followed by a successful result.

The cases of "Osteitis deformans" described by Sir James Paget (*Medico-Chirurgical Transactions*, vol. li) do not come into the same category as the cases given above, for though the cranium is often affected, the facial bones have a singular immunity from that disease. In several of these cases also there was found cancer in some part of the body. But that cancer may co-exist with hyperostosis of the jaw bones is shown by a case recorded by Dr. Cayley (*Pathological Society's Trans.*, vol. xxix), where cancer of the lung was found together with hyperostosis of the lower jaw, which presented the following appearances: "The lower jaw was uniformly enlarged and the alveolar border projected beyond that of the upper one, with which it could not be brought into apposition. All the molar and pre-molar teeth were wanting, and the sockets of the molar teeth, except that for the first right and the last left one, were filled up with bone; the socket of the first right molar was much enlarged and would admit the tip of the little finger: it was continuous with the socket for the adjacent bicuspid, which had itself ulcerated through the anterior surface of the jaw. The alveolar border of the bone was greatly expanded, especially in the molar regions, where it measured in depth two inches and a half. The rest of the bone was also greatly increased in thickness, the groove and foramen for the inferior dental vessels and nerve were remarkably deep and wide. The condyle on each side had a short thick neck, and the sigmoid notch was wider and less deep than usual. The angle was very obtuse, as in edentulous jaws."

General Diffused Hyperostosis.—P. Marie has divided these cases into two classes.

The form more frequently met with he terms *Acromegaly*. In these cases there is hypertrophy of the soft tissues as well as of the bones. The bones chiefly affected are the distal extremities of the limbs, the lower jaw and the bones of

the cranium. The enlargement of the lower jaw may be a very prominent feature in the case.

In the other class there is no affection of the soft parts, and the jaws are very seldom involved. In exceptional cases the superior maxillæ have been found enlarged. These cases seem to be connected with various chronic pulmonary diseases, and P. Marie looks upon this connection as more than accidental (*Revue de Médecine*, April, 1886).

CHAPTER XI.

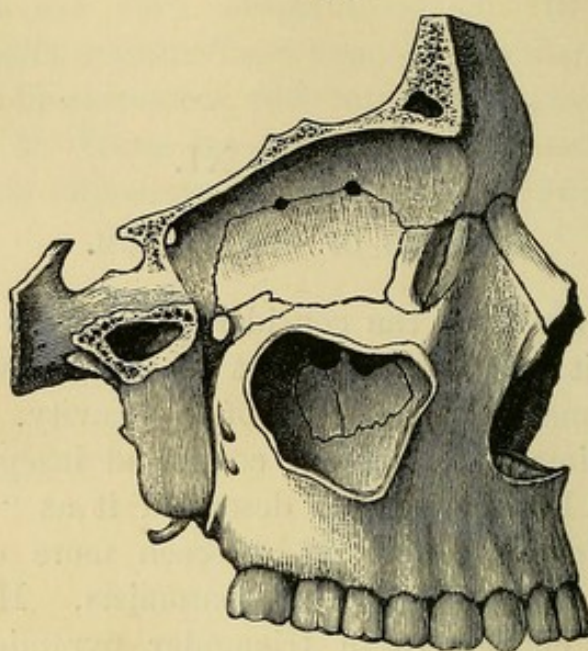
DISEASES OF THE ANTRUM.

BEFORE entering upon the consideration of the diseases of the antrum, it will be convenient to say a few words respecting the anatomical relations of that cavity. Known as early as the time of Galen, but connected inseparably with the name of Highmore, who described it as "conical and somewhat oblong," the antrum has been more or less correctly described by all modern anatomists. Holden compares it aptly enough to "a triangular pyramid, with the base towards the nose and the apex towards the malar bone;" and mentions the occurrence of "thin plates of bone which are often found extending across the antrum." The accompanying illustration, copied from Testuit's *Traité d'Anatomie humaine*, shows the antrum exposed by removal of its outer wall (Fig 54). The most comprehensive account of the antrum in modern times is to be found in a paper by the late Mr. W. A. N. Cattlin, F.R.C.S., in vol. ii of the *Transactions of the Odontological Society of London*, and I am enabled to reproduce some of his valuable illustrations.

As the result of the examination of a hundred specimens, Mr. Cattlin found that, as a rule, the antrum is larger in the male than in the female, and that it diminishes in size with extreme age. In the young subject, likewise, the cavity is small, and its walls comparatively thick. Fig. 55 shows, in a transverse section, both the roof and floor of an adult antrum of the common shape and size, capable of containing two and a half drachms of fluid. The capacity of the antrum varies between one drachm and eight drachms of fluid. The two antra are often unsymmetrical both in size

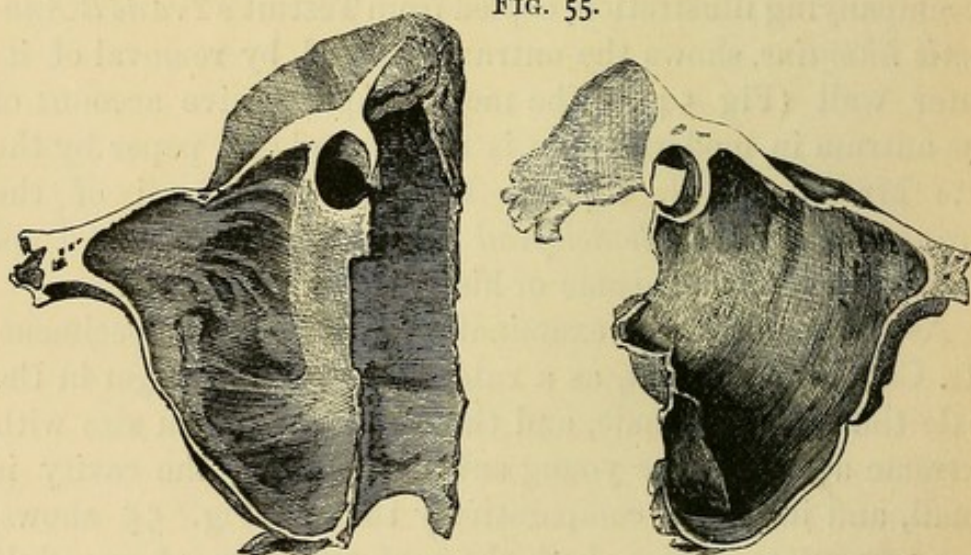
and shape. The antrum may extend into the malar bone, forming an irregular supplementary cavity there. The

FIG. 54.



most remarkable variation, however, is due to the development of ridges of bone which subdivide the antrum into

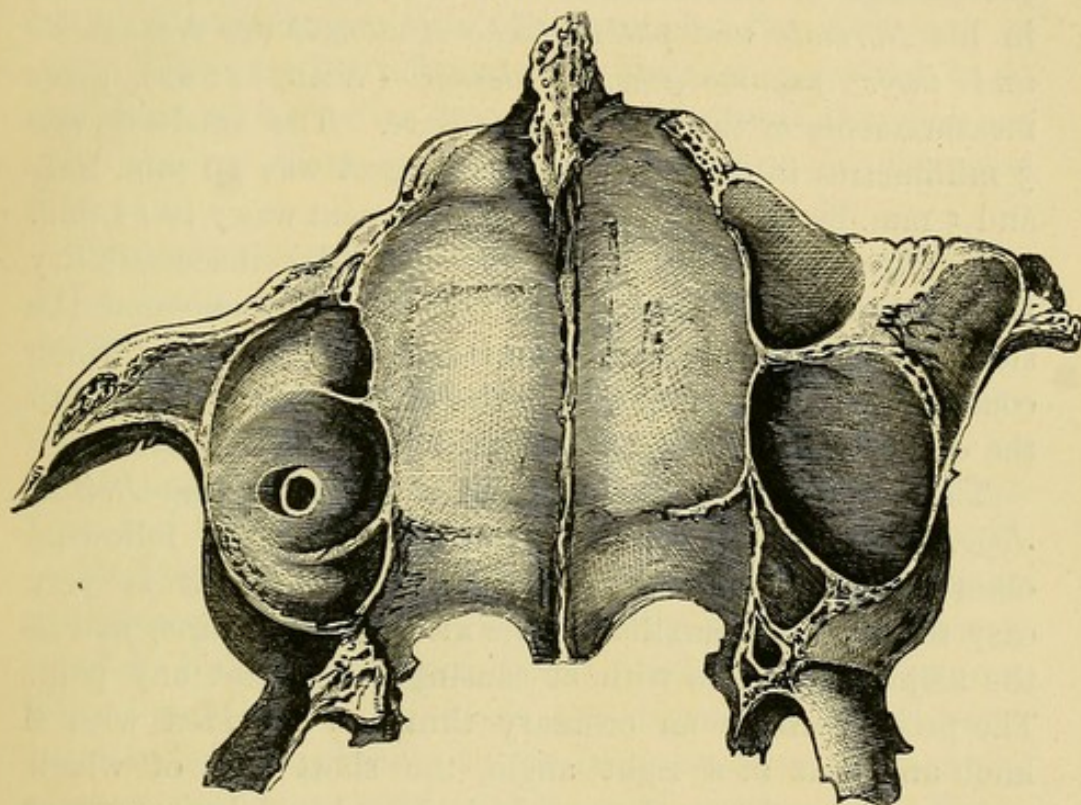
FIG. 55.



cavities of varying size and shape. Fossæ of considerable size are often found in the floor of the antrum, particularly at the anterior and posterior extremities, of which Fig. 56 is a good example, showing on one side a perforation by an

alveolar abscess. A rare form is when fossæ or cells are developed beneath the orbital plate, or a *cul de sac* is formed close to the lachrymal groove. The position and size of the opening between the antrum and the middle meatus of the nose are points of some importance. The size of the aperture found in a macerated superior maxilla gives a very exaggerated idea of the opening in the articulated skull, when it is encroached upon by the palate, inferior turbinated

FIG. 56.



and ethmoid bones, which narrow and subdivide the opening into two. In the recent subject these are covered in by the mucous membrane of the nose, so that as a rule there is only a small oblique aperture left in front of the unciform process of the ethmoid and close behind the infundibulum.

It should be observed that this opening is at the upper part of and not near the floor of the antrum, and that it opens into the *middle* meatus of the nose. Occasionally a second small aperture is found behind this, and nearer to the floor of the sinus, which has been regarded as a natural formation.

M. Giralès, however, in his *Recherches sur les Kystes Muqueux du Sinus Maxillaire* (Paris, 1860), maintains that the posterior opening, when it exists, is always the result of pathological change, and that the anterior opening is into the infundibulum, and not into the meatus itself. I believe that slight variations in the position of the normal opening exist. There is no doubt that the opening is small, frequently guarded by a valvular flap of mucous membrane, and generally considered to be inaccessible to the passage of instruments from the nose. Zuckerkandl, in his *Normale und pathologische Anatomie der Nasenhöhle und ihrer pneumatischen Anhänge* (Wien, 1882), gives measurements of the ostium maxillare. The smallest was 3 millimetres in diameter, and the largest was 19 mm. long and 5 mm. broad. The average measurement was 7 to 11 mm. in length and 2 to 6 mm. in breadth. Its inaccessibility from the anterior nares is due to two causes—one, the situation of the valvular flap of mucous membrane which conceals the orifice from view; the other obstacle is due to the downward projection of the middle turbinated bone.

Theodore Heryng, however, in a paper in the *British Journal of Dental Science* (1889), makes the following observation: "I find that with a little practice it is very easy to probe the maxillary bone after using cocaine, and in the majority of cases without causing the patient any pain. The probe I use is an ordinary thin one provided with a knob and bent at a right angle, the short arm of which must be about 8 mm. long. It is introduced by means of Duplay's speculum for a distance of about two inches into the middle nasal meatus, with the beak looking down. It is then rotated slightly towards the outer wall, and gently drawn forward and inserted sideways into the ostium. If it finds the opening it gets hooked in. It is easy to measure the size of the opening by gently moving the probe backwards and forwards. As a rule it is about 3 or 4 mm. wide. In one case only—one of distension of the antrum with swelling of the cheek—I found it impossible to introduce the probe."

The disease of the antrum may be divided into the following groups :

1. Inflammation and suppuration—*Empyema antri*.
2. Fistulæ of the antrum.
3. Cystic disease—*Hydrops antri*.
4. Tumours of the antrum.

1. *Inflammation and Suppuration*.—Although in practice we only meet with cases of inflammation of the antrum which have gone on to suppuration of the lining membrane, yet there is no doubt that a catarrhal inflammation, probably lasting a considerable time, has preceded the formation of pus. The catarrhal inflammation, however, gives rise to no symptoms so far as we know at present, and therefore we only discover these cases when the antrum is distended with pus.

Formerly abscess of the antrum, or “*Empyema antri*,” as it has been called by O. Weber, was regarded as a rare disease, but of recent years it has been frequently met with, especially since the publication by Ziem of his paper on the subject in 1886. Owing to the difficulty of diagnosis, no doubt many cases were formerly overlooked. Up to 1888 Ziem had treated the astounding number of 227 cases.

Etiology.—So far as we know, the inflammation never commences in the antrum itself, but the lining membrane is invaded by inflammation from neighbouring structures. Hence probably in all cases the disease is secondary to inflammation elsewhere. In the large majority of cases the primary trouble is either in the *teeth* or the *nose*. There is considerable difference of opinion regarding the relative frequency with which these causes act. I believe that inflammatory conditions of the teeth are by far the most frequent cause. The roots of the first and second molar teeth often, and the bicuspid and canine occasionally, form prominences in the floor of the antrum; and when these teeth become carious, the thin plate of bone covering their fangs not unfrequently becomes affected, and disease is set up in the cavity. The fangs of the first molar tooth are occasionally found in health to be uncovered by bone,

and to project beneath the lining membrane of the antrum ; and under these circumstances, irritation and inflammation would be still more likely to occur. But an abscess may be formed in the alveolus, and eventually burst into the antrum, though connected originally with teeth not usually in relation with the cavity. Of this a case was described to me by Mr. Margetson, of Dewsbury, where the teeth affected were the canine and incisors. This perforation of an alveolar abscess is seen also in Fig. 56.

Fränkel is strongly of opinion that the chief cause of abscess of the antrum is to be found in inflammatory conditions of the alveolar periosteum. He also points out that, of all the accessory cavities of the nose, the antrum is the one most commonly affected, a point strongly in favour of the dental origin of the disease.

Zuckerkindl and others, however, believe that the primary trouble more often arises in the nose. There is no doubt that in some cases infection may come from the nose. Thus, Bayer has published several cases of polypoid degeneration of the mucous membrane of the middle meatus leading to empyema antri. Gérard-Marchant, in the *Traité de Chirurgie* of Duplay and Reclus, mentions a case of acute catarrh of the nose in influenza that was followed by abscess in the antrum.

Among rare causes of antral abscess we may mention blows on the face, leading to fracture and suppurative osteitis of the superior maxilla ; operations on the face, as in the two cases of resection of the infra-orbital nerve, mentioned by Langenbeck ; violent blows on the face without fracture of the bone ; syphilitic necrosis of the superior maxilla ; and finally, the entrance of foreign bodies, as in a case recorded by Mr. Moore in the third volume of *Transactions of the Clinical Society*, in which, he believed the abscess to be due to the ingress of particles of food by the side of a tooth, though the facts might possibly bear a different interpretation.

Symptoms.—Owing to the more accurate study of antral abscess of recent years, the description of the symptoms which was generally accepted as characteristic of the disease

has had to be modified. Thus, it was stated in the last edition of this book that "the symptoms of suppuration in the antrum are at first simply those of inflammation of the lining membrane—dull, deep-seated pain shooting up the face and to the forehead, tenderness of the cheek, with some fever and constitutional disturbance; but occasionally the pain is most acute, and of a sharp, stabbing, neuralgic character. A slight rigor may usher in the formation of matter, which will find its way into the nostril when the patient is lying on his sound side."

Although this description applies accurately enough to one form of antral abscess, yet it does not apply to the large majority. For we have to remember that the symptoms vary according to the amount of drainage that can take place through the ostium maxillare, and hence it is convenient to divide cases of *empyema antri* into two classes—one in which there is a free exit for pus into the nose, and one in which the ostium maxillare has become blocked.

(a) *Abscess with patent Ostium Maxillare*.—Pain is by no means a constant or marked symptom. It may be quite absent, or may be referred to the frontal or supra-orbital region. Pain in the malar region is the exception in these cases. Swelling of the cheek is seldom present, and if present probably indicates abscess in the antrum caused by dental cysts. The most characteristic symptom is an intermittent discharge of pus from one nostril (excepting in the rare cases of double empyemata). The periodicity of the discharge is explained in the following way. When the patient lies down the pus trickles backwards to the pharynx, but when he sits up, especially with the head inclined to the healthy side, the pus flows from the nostril corresponding to the antrum affected. Another peculiarity is that the patient notices a distinctly disagreeable odour, compared to rotten fish, but the odour is not perceived by other people.

An important consequence of an unrecognised empyema of the antrum is the damage done to the digestive organs by the constant swallowing of purulent fluid during sleep. Under these circumstances, the patient is always ailing, is

unable to take food in the morning, and may be reduced to a state of great prostration, even dangerous to life. The usual remedies for indigestion are likely to be of little service so long as the purulent drain continues.

(b) *Abscess with blocked Ostium Maxillare*.—In exceptional cases the pus, not finding an exit, distends the antrum, causing partial absorption of the walls, and thus both bulging out the cheek and thrusting up the floor of the orbit. Fig. 57 shows the prominence of the cheek thus produced in a

FIG. 57



patient under the care of Sir William Fergusson. Under these circumstances the affection is readily recognised by the peculiar crackling which is perceived when the thinned bone is pressed upon, and the matter, if not evacuated, will shortly find a way out for itself, either by the side of the teeth, through the front wall of the antrum, or through the floor of the orbit; in either of which cases considerable necrosis and ultimate scar are likely to be the consequences.

In these cases pain is generally a prominent symptom, especially in the cheek, and fever, occasionally with rigors, is sometimes present.

The elevation of the floor of the orbit already described may simply displace the eyeball and render it temporarily blind, as in a case recorded by Mr. J. Smith, of Leeds (*Lancet*, February 14, 1857), or it may lead to permanent amaurosis—a point to which Mr. Salter called especial attention in the *Medico-Chirurgical Transactions* for 1862. Mr. Salter's patient, a young woman, twenty-four years of age, was attacked with violent toothache in the first right upper molar, which was followed by enormous swelling of the side of the face and intense pain. The eyeball then became protruded, and she soon after perceived that the eye was blind. Shortly after the establishment of these symptoms, "abscess" of the antrum pointed at the inner and then at the outer canthus, and a large discharge of pus at both orifices followed; these orifices soon closed, but the general symptoms of the part continued unchanged—the swelling of the face, protrusion of the globe, and blindness. This state of things lasted for about three weeks, when the patient was sent to Guy's Hospital, and admitted. At this time the patient exhibited hideous disfigurement from swelling of the face, œdema of the lids, and lividity of the surrounding integument. Upon examining the mouth, it was found that the carious remains of the first right upper molar appeared to be associated with and to have caused the disease. Together with the other contiguous carious teeth, this was removed, and led by an absorbed opening into the floor of the antrum. The hæmorrhage which followed the operation was discharged partly through the nose, and partly through the orifices in the cheek, as well as from the tooth-socket, showing a common association of these openings with the antrum. The condition of the eye constituted the most important symptom, and the most distressing. The sight was utterly gone; the globe prominent and everted. There was general deep-seated inflammation of the fibrous textures of the eye. The pupil was large and rigidly fixed; it did not move co-ordinately with the other under any circumstances. Some abatement of the symptoms followed the extraction of the tooth; but it was soon found that there was a consider-

able sequestrum of dead bone, which was removed. The necrosis involved the front part of the floor of the orbit, the cheek surface of the superior maxilla, with the infra-orbital foramen, and a large plate of bone from the inner (nasal) wall of the antrum. The removal of the dead bone was followed by the immediate and complete cessation of all inflammatory symptoms; but the eye remained sightless, and the pupil rigidly fixed. About five weeks after the removal of the dead bone, it was noticed that the pupil of the affected eye moved with that of the other, under the influence of light, though vision in it had not returned.

Mr. Charles Gaine, of Bath, has recorded (*British Medical Journal*, December 30, 1865) a very similar instance in a young woman of twenty-two. In Mr. Salter's paper will be found the case of a gentleman, aged thirty-five, under the care of Mr. Pollock, who had amaurosis following inflammation without abscess, and one by Dr. Brück, where amaurosis followed abscess, in the person of a man of forty-five. Sir Thomas Watson, in his "Lectures on Physic," alludes also to two cases of temporary amaurosis, the result of diseased teeth in the upper jaw.

But even more serious results have followed neglected suppuration in the antrum, for Dr. Mair, of Madras, has recorded, in the *Edinburgh Medical Journal* for 1866, the case of a gentleman in whom suppuration in the antrum was followed by death in sixteen days, from suppuration within the cranium accompanied by epileptic convulsions.

Double Antral Abscess.—The possibility of both antra being affected, either simultaneously or consecutively, must not be overlooked. I have a patient now under my care whose right antrum I emptied some years back, and who has now symptoms which point to the presence of matter in the opposite antrum, and Mr. C. Tomes has met with the same occurrence.

Diagnosis.—Given, a patient who complains of purulent discharge from the nostril, with occasionally a disagreeable smell, and the case is too apt to be put down as one of ozæna, and treated by nasal douches, snuffs, &c. But, as already mentioned, the offensive smell is perceived only by

the patient, and not by his friends, the reverse being the case in ozæna; and, again, the discharge is only occasional, is determined by the position of the head, and is simply purulent, whereas in ozæna the discharge is constant, and mixed with offensive crusts from the nasal cavities. Again, the dull ache, varied occasionally by acute pain, is apt to be referred to the teeth alone, and the most careful examination may fail to detect any special tenderness in any one tooth. Hence, after exhausting the usual routine remedies for neuralgia, I have known wholesale extraction of useful teeth undertaken with no benefit, unless it should fortunately happen that the tooth which has perforated the antrum should be extracted early, when the discharge of pus at once clears up the nature of the case.

A still more serious result may ensue if the neuralgia should, as it often does, take the form of frontal headache, and thus lead the surgeon to suppose that the discharge comes from the frontal sinus. I have twice been consulted on cases in which enterprising surgeons had proposed to trephine the frontal sinus, regardless of the serious injury to the patient's good looks, for chronic discharge which I proved to be solely due to suppuration in the antrum.

There are certain methods by which the presence of pus may be positively determined.

(a) *Position of Patient*.—The nasal cavity having been carefully cleaned, the patient is told to go on his hands and knees and to hang the head down, inclining it away from the suspected side. By this means pus may trickle from one nostril, or by examination with a speculum some pus may be seen in the middle meatus.

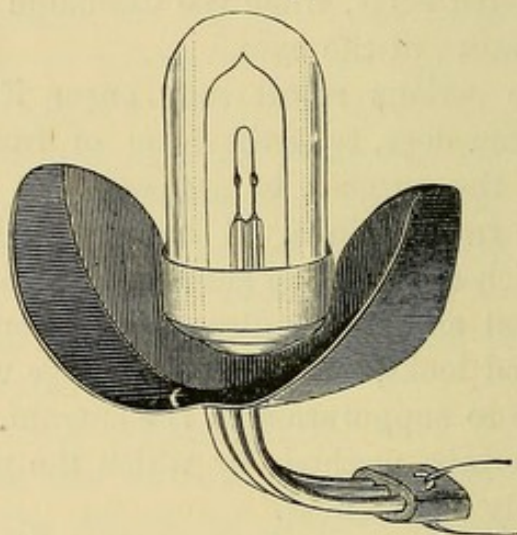
(b) *Catheterisation of the Ostium Maxillare*.—According to many observers this is a very difficult, even impossible proceeding. It has been mentioned above, however, that Heryng considers it a simple and easy method.

(c) *Illumination of the antra* by means of an electric light held in the mouth is considered by some observers to be very useful in diagnosis. A very convenient apparatus for this purpose has been designed by Mr. N. Stevenson. Fig. 58

shows the lamp attached to a vulcanite plate, which is comfortably gripped by the teeth. Undue heating of the lamp is prevented by surrounding it by a glass bulb through which air can freely circulate. By means of a powerful lamp a bright reddish yellow light is thrown through the cheeks and lower eyelids. In purulent collections in the antrum a diminution in the amount of illumination is at once seen, especially in the intensity of the light transmitted through the lower eyelid.

(d) If these methods fail, we may aspirate the antrum in one of the following places : in the region of ostium maxillare,

FIG. 58.



through the inferior meatus of nose, or in the interval between the first and second molar teeth, care being taken to avoid injuring the teeth. The great objection to this method is that inflammation may be started in a previously healthy antrum.

Treatment.—The first indication is to give free exit to the pus. This cannot be done satisfactorily through the ostium maxillare, therefore we must seek another way. Two methods suggest themselves: through the nose and through the mouth.

The Nasal Route.—This can be done by making an artificial opening in the region of the ostium maxillare, as recommended by Storck, or in the inferior meatus as recommended by Mickulicz.

The objections to this method are that it is impossible

to tap the most dependent part of the cavity, and the hæmorrhage is sometimes very free.

The Oral Route.—In many cases, as we have seen, the abscess is caused by a decayed molar tooth. If this be the case, the tooth should be extracted and the antrum opened by boring a hole through the tooth-socket. If, however, the teeth are healthy, or but slightly decayed, it is better to tap the antrum just above the alveolar border.

After considerable experience of both methods I prefer the puncture above the alveolus, except when a tooth obviously requires extraction, because I find that the aperture is less liable to close up than when made through the alveolus, and because food is less likely to find its way into the antrum. It is necessary, however, not to direct the trocar quite horizontally but a little upwards, lest in a case of highly arched palate the floor of the antrum should be injured, as I have known on one occasion, but then fortunately with no permanent damage, except the exfoliation of a minute portion of the palate.

Whatever method may be adopted for emptying the antrum, it is important that the cavity should be thoroughly cleansed by the forcible injection of warm antiseptic lotion until it runs freely from the nostril. For this purpose an ordinary glass syringe is quite insufficient, but I have satisfactorily employed an ordinary Eustachian catheter for the purpose, to which an india-rubber injecting-bottle is adapted. After a time, and with a little instruction, patients can learn to dispense with the syringe by forcing a mouthful of lotion through the antrum by the action of the buccinator muscles. After thoroughly cleansing, some antiseptic and slightly astringent lotion should be injected, to restore the healthy condition of the mucous membrane, and for this purpose weak solutions of permanganate of potash or sulphate of zinc answer admirably; but these cases are exceedingly tedious, as a rule, and take many months for their cure. If the perforation has been made through the socket of a tooth, care must be taken that particles of food do not gain admission to the antrum, and this may be accomplished by plugging

the hole with cotton wool, or, as suggested by Salter, by fitting a metal plate to the mouth with a small tube to fill the aperture, which can be corked at pleasure, and will serve as a pipe for injection.

It is very important that the opening of the antrum into the nose be patent. If the ostium maxillare is blocked the artificial opening into the antrum will not close. In such cases, if the ostium maxillare cannot be probed, an opening should be made from the nose into the antrum, in the region of the ostium or through the inferior meatus.

In favourable cases the opening made into the antrum through the mouth closes within a few weeks, but sometimes the sinus persists for months or even years. The treatment of these chronic cases will be considered under the subject of fistulæ of the antrum.

The possible subdivision of the floor of the antrum by bony septa, already described, must be borne in mind in operating upon this cavity, and especially if there is reason to suspect the presence of any foreign body which may be keeping up irritation. In his paper already referred to, Mr. Cattlin narrates the case of the fang of a tooth lodging in one of these subdivisions, from which it was extracted with difficulty.

Suppuration in the antrum may assume a more chronic form than that above described, and from the slow expansion of the jaw which results may be mistaken for a solid growth. Weber describes a form of chronic sub-periosteal abscess proceeding from a tooth, which is surrounded by an osseous plate or shell formed from the periosteum, while it is separated from the antrum by the maxillary wall itself; and believes that the occurrence of suppuration commencing in the bone, either from this cause or from the suppuration of a dentigerous cyst, is much more common than in the antrum itself, but in this I do not agree, though recognising the occasional occurrence of the form of abscess described. The diagnosis of these several forms of abscess is by no means easy, and errors have been made by excellent surgeons in mistaking them for solid growths: thus, Liston mentions

("Practical Surgery," p. 303) having seen a surgeon have his hands covered with purulent matter in attempting to remove a supposed tumour of the jaw. This is more especially likely to happen when, as is sometimes the case, considerable hypertrophy of the osseous wall has taken place in consequence of the irritation the bone has been subjected to. Stanley (p. 285) mentions a case of the kind which occurred in the practice of Sir W. Lawrence: "A woman, aged twenty-four, was admitted with a large, hard, round swelling of the cheek in the situation of the antrum; it was free from pain, and the soft parts covering it were healthy; such was the solidity and hardness of the swelling that it was supposed that it might be an osseous growth from the antrum, and the history appeared to confirm this view of its nature, as the woman stated that about five months previously she had received a blow on the cheek, and that soon afterwards the swelling commenced, and had slowly increased to its present magnitude, which was about that of a middle-sized orange. A scalpel was thrust into the tumour immediately above the sockets of the molar teeth, and healthy pus flowed from the opening; the discharge continued in gradually decreasing quantity, and the swelling subsided as the walls of the antrum receded to their natural limits."

This thickening of the bone may remain permanently, long after the cure of the abscess, and may necessitate operative interference: thus, in 1850, Sir William Fergusson met with a case of osseous tumour of the size of a pigeon's egg, projecting from the superior maxilla of a man, aged fifty, who had been the subject of abscess, and whose antrum was still distended, though containing no fluid. Here it became necessary to remove the tumour with the anterior wall of the antrum, by which the deformity was quite got rid of. The case will be found in the *Lancet*, June 29th, 1850. A case, under the care of Mr. Henry Smith, in which an abscess consequent on necrosis of a portion of the jaw closely simulated a tumour of the antrum, will also be found in the *British Medical Journal*, March 2nd, 1867.

2. *Fistulæ of the Antrum.*—These vary considerably in position, and may be divided into two classes.

(a) *Fistulæ* opening on to the surface of the face, generally in some part of the cheek, or just below the lower eyelid.

(b) *Fistulæ* opening into the mouth, either through the alveolar process, or just above the alveolar process, or through the hard palate.

Etiology.—*Spontaneous fistulæ* are those resulting from the bursting of an abscess of the antrum. In these cases the sinus is generally situated in the region of the cheek or lower eyelid. It may, however, lead from the antrum on to the hard palate, or on to the alveolar process.

Surgical fistulæ are the result of opening the antrum for the purpose of drainage, and are generally situated in the alveolar process or in the canine fossa.

Traumatic fistulæ may result from various causes. Fractures of the upper jaw and gunshot wounds of the face may be followed by *fistulæ*. Sometimes the antrum is opened when extracting a tooth.

Symptoms.—There are three characteristic symptoms: the passage of air from the fistula when the patient sneezes or blows his nose, the passage into the nose of fluids injected into the sinus, and the escape of pus into the mouth. The pus may vary both in quantity and odour. As a rule it does not smell much, and is scarcely noticed by persons other than the patient. In some cases, however, when the drainage is not free, putrefaction may take place to a considerable extent, and cause a markedly foetid odour.

It must be remembered that the first two symptoms are absent when the ostium maxillare is blocked. In these cases the introduction of a probe through the fistula into the antrum clears up any doubt in the diagnosis.

Treatment.—The chief indications are to obtain perfect drainage for the pus, and to treat the suppurating mucous membrane with antiseptic and stimulating lotions. In the case of the cutaneous *fistulæ* it is important to make another opening into the antrum from below through the mouth, so that the drainage shall be perfect. The cutaneous fistula

will then rapidly heal. Sometimes it is very difficult to get a fistula opening into the mouth to close up. In these cases the cavity of the antrum might be scraped with a small curette, so as to remove any unhealthy granulation tissue. In spite of all treatment, however, some of these fistulæ refuse to heal.

3. *Cystic disease of the antrum*, sometimes and erroneously termed "*hydrops antri*," or "dropsy of the antrum," is a disease which has long been recognised, though, within the last few years, opinions have changed as to the exact pathology of the affection. The history of these cases is one of gradual, painless dilatation of the upper jaw, until its outer wall becomes so thin as to crackle like parchment upon pressure being made, or at certain points being so absorbed that fluctuation is readily perceptible. Occasionally the other walls of the jaw yield, though more slowly, to the persistent pressure, the palate becoming flattened, and the nostril blocked by the bulging of the internal wall. On the extraction of a molar tooth and perforation through its socket, as described under the previous section, or more frequently by an incision through the osteo-membranous wall of the cyst, a quantity of clear or yellowish serous fluid is evacuated, which frequently contains flakes of cholesterine floating in it. After the evacuation of the fluid the swelling ordinarily subsides, the maxilla resuming its normal relations, and the opening closing.

The old explanation of these phenomena was, that the aperture between the antrum and the nostril having become accidentally obstructed, the mucous secretion, which was presumed to be constantly taking place within the cavity, was thought to be imprisoned, and, by its gradual accumulation, to produce the symptoms which have been described. Following up this idea, we find surgeons, and among others Jourdain, of Paris (1765), who very accurately described the affection, recommending the restoration of the nasal orifice by probing (see Guérin's *Elémens de Chirurgie Opératoire*, 1855). Bordenave, in his "Observations on Diseases of the Maxillary Sinus" (Sydenham Society's trans-

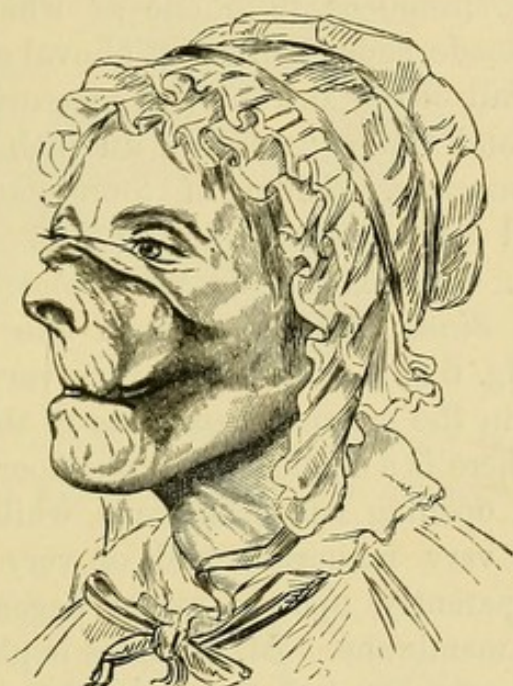lation, 1848), gives full details of this method of probing and injecting, but, after showing that there is great difficulty and uncertainty in finding the natural orifice, remarks that "there are very few cases in which the employment of injections through the natural openings, in the manner above described, would effect a complete cure." It is certain, however, that some of these cases, and very probably all of them, originate in the growth of a cyst, or cysts, within the antrum, or more commonly in the wall of the antrum, which either grow to such a size as to be mistaken for the cavity of the antrum when opened, or break into the antrum by absorption of the cyst-wall, so that on subsequent examination no evidence of cyst formation can be discovered. This explanation is, as pointed out by Coleman, supported by the fact that in these cases of so-called *hydrops antri*, the contained fluid in no respect resembles ordinary mucus, but is invariably a clear, more or less yellow fluid, frequently containing cholesterine in considerable quantity. In these respects it closely resembles that found in well-marked cases of cystic growth, which have been examined in various stages of development.

A remarkable case of distension of the antrum is narrated by Sir William Fergusson, and the preparation is preserved in the King's College Museum. It was taken many years ago from a subject in the dissecting-room, and from the person of an old woman. The tumour, which was of very large size, had burst shortly before death, leaving the remarkable deformity shown in Fig. 59 (taken by permission from Sir W. Fergusson's work on Surgery), which is due to the complete absorption of the front wall of the antrum and its collapse, by which a prominent horizontal ridge of bone, formed by the upper wall of the antrum, has been left immediately below the orbit. The preparation shows great distension of the antrum, the diameter of which varies in different parts from two to two and a half inches, and the bony wall is so thinned out as to resemble parchment. The gums are edentulous. There is no communication between the nose or mouth and the cavity, which is lined with a

membrane covered with laminated deposit. (For these particulars I am indebted to Dr. Trimen, the late curator.) Whether this was originally a case of cystic growth, or a chronic abscess, it is impossible now to decide, but it is, so far as I am aware, a unique post-mortem specimen of this distension.

Numerous instances of so-called distension of the antrum by clear fluid in living patients, have been recorded from time to time, and occasionally mistakes have been made by

FIG. 59.



the surgeon in regarding the tumour as of a solid nature. A very remarkable case, in which a distended antrum closely simulated a solid growth, occurred in the practice of Sir William Fergusson, and the details of the case will be found in the *Lancet*, June 29th, 1850. Here the surgeon made an exploratory puncture before commencing the more serious operation; but a case has occurred within my own knowledge, in which a very able surgeon removed the upper jaw before discovering the error of his diagnosis.

M. Giraldès would appear to have been the first author upon the subject of cysts of the antrum, and his thesis gained the Montyon prize in 1853; but Mr. W. Adams may

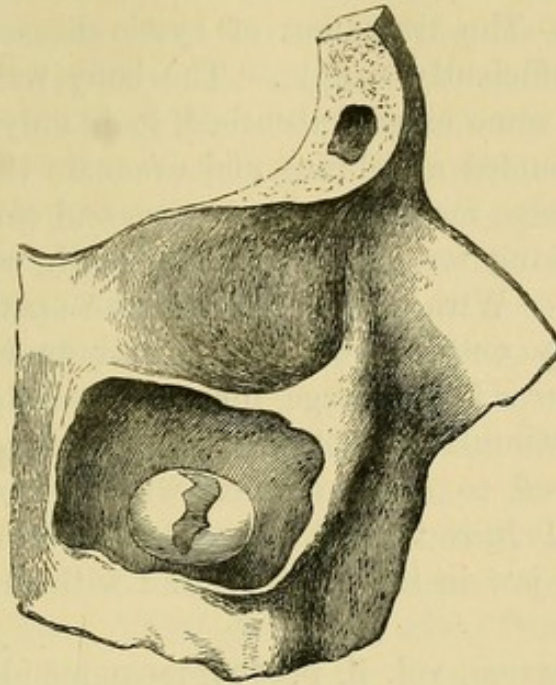
fairly claim priority of investigation, as shown by specimens preserved in St. Thomas's Museum—as indeed is acknowledged by M. Giraldès. Luschka subsequently investigated the subject, and in sixty post-mortem examinations found cystic growths in the antrum five times, some of them being two centimetres in length. A careful examination of the antra of thirty subjects, made for me by the late Mr. Marcus Beck, then Demonstrator of Anatomy of University College, during the winter of 1867-68, failed to discover an instance of the kind.

Mr. Adams' specimens, from one of which the drawing (Fig. 60) was made, show each a cyst of oval outline, attached to the inner wall of the antrum, and measuring rather more than an inch and three-quarters of an inch respectively, in their long diameters. These, of course, are too small to have produced any symptoms during life. The specimens given by M. Giraldès in his *Récherches sur les Kystes Muqueux du Sinus Maxillaire* from one of which the illustration (Fig. 61) is taken, show very varying degrees of cystic growth in the mucous membrane of the antrum. In one instance there is a single cyst at the floor of the antrum, into which an opening has been made, whilst in the others the cysts are very numerous and of very variable sizes, depending, apparently, upon a cystic degeneration of the entire mucous membrane. M. Giraldès explains the formation of these cysts as being due to the dilatation of the glandular follicles of the mucous membrane, and urges that the ordinary operation of tapping the antrum would be useless in such cases, but that it would be necessary to open up the antrum, so as to get at the seat of the disease. Fortunately these numerous cysts appear to be of slower growth than the single cysts, for it would be impossible to extirpate such numbers as are here seen (Fig. 60), without removing the entire jaw.

The contents of these cysts appear to be at first clear fluid, but of a viscid nature; when more fully developed, the fluid becomes flaky, from the presence of cholesterine, and occasionally assumes a greenish tint. It may also

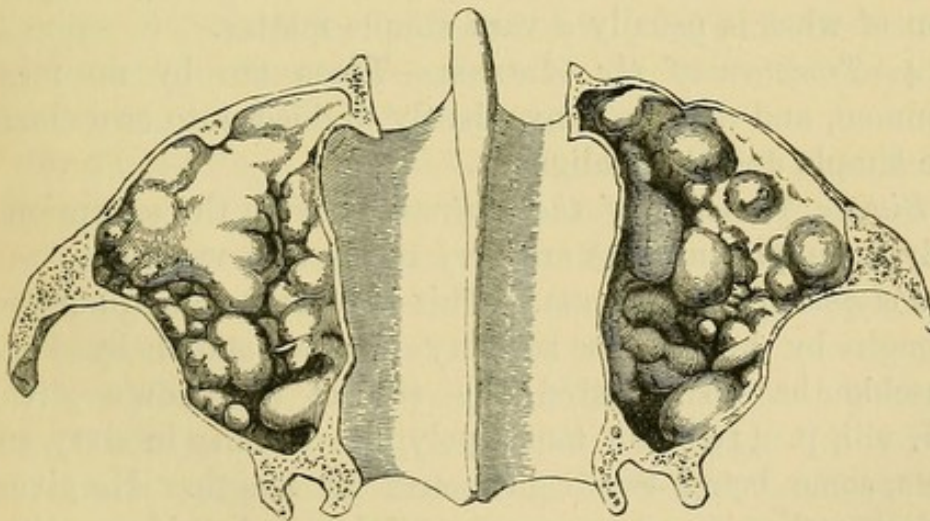
become purulent, and Maisonneuve has recorded (*Gazette des Hôpitaux*, January 6th, 1855) a case where pressure on the

FIG. 60.



cheek produced a flow of butter-like fluid from the nose in a young woman who, for a year, had suffered from a tumour

FIG. 61.



of the right upper jaw, which had been pronounced malignant, the face being enlarged and the nostril obstructed. Here puncture from the nostril, combined with pressure and

injections, effected a cure, and the case must be considered as one of cyst of the antrum, but whether a mucous cyst, the contents of which had undergone solidification, or a separate formation, must remain doubtful.

Treatment.—The treatment of cystic disease of the jaw is generally sufficiently simple. The bony wall being most commonly, to some extent, absorbed, it is only necessary to incise the distended membrane and evacuate the fluid. The finger then passes readily into the cyst and can examine its interior, searching for any growth or tooth which may be lodged within. With curved scissors the opening can then be enlarged by cutting away the membranous wall sufficiently to allow a free passage for any discharge. The use of a simple stimulating lotion with a syringe is then all that is required to effect a cure, which, though slow, is permanent. I have treated a considerable number of cases of cyst of the jaw in this manner, and with uniformly good results.

Broca (*Tumeurs*, vol. ii, p. 37) recommends to remove the membrane covering the inner wall of the cyst, and gives a case in which Nélaton discovered a plate of bony tissue derived from a malformed tooth on the inner aspect of a cyst, but this is in most cases a quite unnecessary complication of what is usually a very simple matter.

4. *Tumours of the Antrum.*—These are by no means common, and may be conveniently divided into two classes, the simple and the malignant.

Simple Tumours of the Antrum.—With the exception of polypi, simple tumours are very rarely met with.

Polypus of the Antrum.—This is not a common affection, though by no means so very rare as stated by Paget. Luschka has investigated the subject (Virchow's *Archiv*, Bd. viii, p. 419), and found polypi five times in sixty subjects, some being two centimetres in length. He gives a drawing, showing a large number of these polypoid growths in an antrum, which he considers to be hypertrophies of the sub-mucous connective tissue, covered with mucous membrane. Billroth also describes a good example of large polypus of

the antrum with a long pedicle, and regards it as a very rare affection, and there is a good specimen in University College Museum.

These polypi are closely allied apparently to the small cystic growths in the mucous membrane of the antrum, described by Giralaldès. Both affections consist essentially in hypertrophy of some elements of the mucous and submucous tissues. When the connective or areolar tissue predominates, the fleshy polypus is produced; when the glandular element is especially affected we have the cystic form produced. Intermediately, when the fibrous element is very loose and we have some glandular hypertrophy, the semi-gelatinous polypus is produced, which closely resembles the nasal polypus.

Polypi of the antrum are well supplied with blood-vessels, and bleed freely when interfered with. In some instances they appear to have a malignant character, or at least are the forerunners of malignant disease occurring in the antrum and jaw. Vidal de Cassis, who (*Traité de Pathologie Externe*, tom. iii, p. 492) totally denies the existence of any true polypoid growths in the antrum, says that what have been mistaken for them most frequently are colloid tumours of the periosteum, but believes that many of the cases are examples of cystic growth. Syme also, following the example of John Bell, maintains that polypi in the antrum always intrude from the nose, and are never developed in the antrum itself (*Lancet*, May 10, 1855).

Sir James Paget has put on record (*Clinical Soc. Trans.*, xii) a case of polypus of the antrum in which a constant flow of clear watery fluid from the nose was the only symptom. At the post-mortem examination "the floor of the antrum was covered with two broad-based convex polypoid growths, deep clear yellow with the fluid infiltrated in their tender tissue, and covered with exceedingly thin smooth membrane traversed by branching blood-vessels. They were of rounded shape, about two-thirds of an inch in diameter, and half an inch in depth; they looked like very thin-walled cysts, but were formed of very fine membranous or filamentous tissue, infiltrated with serum."

Ordinarily the symptoms of polypi, no less than of cysts of the antrum, only become developed when the growth is of sufficient size to encroach upon the neighbouring cavities, or produce distension and absorption of the front of the antrum. The most common situation for the polypus to show itself is, as might be expected, the nose, since the tumour readily induces absorption of the thin nasal wall of the antrum. Here it closely resembles the ordinary nasal polypus, and Sir William Fergusson mentions ("Practical Surgery," p. 561) two cases of the kind in which this had occurred, one being in his own practice. In that instance he soon found that he had attacked a tumour of the antrum, which, in consequence of its deep and firm attachment, and the great hæmorrhage attending it, he did not entirely remove. The disease returned, and he again operated, on this occasion using great force, and wrenched out the whole mass, not without some fear of the consequences. The case, however, did well, and after ten years the disease had not returned.

In the *Medical Times and Gazette*, March 18th, 1860, is a report of another case in which the same surgeon removed a vascular fibrous polypus of the antrum which had projected into the nostril, by laying open the front wall of the cavity, and with strong forceps tearing out the tumour bit by bit.

I had, during 1866, the opportunity of watching the case of a patient who had had a polypus partially removed by the nose on several occasions, and from whom Mr. Holthouse removed an entire growth a year and a half before that date. He reappeared with a swelling of the jaw, evidently due to distension of the antrum by some soft growth, and he had also a soft tumour on the forehead. These were doubtless cancerous, for his strength failed, and he sank after some months, but unfortunately his relations would not permit a post-mortem examination to be made.

Hypertrophy of the glandular tissue of the mucous membrane appears capable of producing tumours of a

friable description, which may fill up the antra on both sides, as in a case recorded by M. Demarquay (*Gazette Médicale de Paris*, November 4th, 1857). Here the patient had a large tumour on each side of the nose, the passages of which were completely obstructed, and his right eye was protruded from the orbit. M. Demarquay removed the front walls of the antra, and extirpated two masses of very friable tissue of a greyish-white colour, in which the vascular tissue was not abundant. M. Robin, who examined the growths, pronounced them to be the result of an hypertrophy of the glandular element of the mucous membrane of the antrum.

A curious and, I believe, unique case of falling in of the antrum, recorded by Mr. White Cooper, may be conveniently mentioned here, since the depression of the wall of the cavity depended, no doubt, upon some alteration going on in its interior—possibly the absorption of some fluid which had previously induced thinning of the bones. The patient was brought before the Medical Society of London in 1851, and Mr. Cooper has kindly given me the following details of her case:

“I first saw Margaret Ryan (aged twenty-seven) May 22nd, 1849.

“Complained of the tears running over the left cheek, first perceived about a week previously.

“Seven years ago first observed a black mark round the lower part of the left eye-lid; without pain, weakness of eye or toothache. Gradually and almost imperceptibly flattening of the cheek came on.

“The appearance presented was that of a deep depression between the malar bone and nose, precisely as if a portion of the superior maxillary bone had been cut away.

“It was bounded superiorly by the inferior margin of the orbit, which partook of the depression; inferiorly by the base of the alveolar process; and externally by the malar bone. As compared with the other cheek, the dimensions were as follows: From bridge of nose over deepest point of depression, one inch four-tenths, or nearly an

inch and a half; right side to corresponding point just one inch.

"There was a peculiar dusky hue about the depression, especially towards the upper part. The cuspid and bicuspid teeth were removed with considerable difficulty, the roots showing thickening of periosteum.

"No change was visible at the expiration of twelve months."

Fibroma of the Antrum.—A few cases of fibromata originating in the wall of the antrum and projecting into its interior have been recorded. They vary considerably in structure. Some are quite firm, consisting of dense fibrous tissue; others are more vascular, presenting a somewhat cavernous structure; and others again may be calcified in places, especially in their centre. They will be considered at greater length in connection with simple tumours of the upper jaw.

Enchondroma of the Antrum.—These are occasionally met with arising in connection with the periosteum lining the antrum. Only one case of pure enchondroma has been described, but mixed tumours containing fibrous or calcified tissue with the cartilage are more common. They will be considered again later on.

Osteoma of the Antrum.—Osseous tumours arising in the wall of the antrum, and projecting either into its cavity or towards the exterior, are occasionally met with. They may lie loosely in the cavity of the antrum or may be connected to the wall by a pedicle. Sometimes they are attached by a broad and firm base to the bony wall. They will be more conveniently considered in the chapter on simple tumours of the upper jaw.

Malignant Tumours of the Antrum.—These are more frequently met with than the simple tumours, and consist of epitheliomata and sarcomata, of which the former are the more common.

Epithelioma of the Antrum.—There are two varieties of this disease; one in which the growth originates in the lining membrane of the antrum, *primary epithelioma*, and

one in which the growth invades the antrum from some neighbouring part, generally from the palate or neighbourhood of the teeth, *secondary epithelioma*. The former variety is very seldom met with; it forms very vascular tumours of a villous nature, gradually distending the antrum and finally perforating the alveolar border of the jaw. The lining membrane of the antrum is composed of cells of two kinds, columnar epithelium cells, many of which are ciliated, and glandular cells, somewhat goblet-shaped, which produce the natural secretion contained in the antrum. Corresponding with this variety in the structure of the cells lining the antrum, we find a difference in the malignant growths that originate in this membrane. One kind of growth is composed of columnar cells, or cells resembling them, and is therefore called a columnar epithelioma; the other kind is composed of glandular cells, and is consequently termed a spheroidal-celled or glandular carcinoma.

Secondary epithelioma of the antrum is usually of the squamous variety. It is a very insidious disease, which gives rise to the formation of no tumour of the face, but slowly destroys the antrum and spreads thence in all directions. It was first described, from the clinic of M. Verneuil, by M. Reclus (*Progrès Médical*, 1876), who termed it very aptly *épithélioma térébrant* (burrowing or boring epithelioma), and attention was called to it by Mr. Butlin in 1881. I had at the time two cases of the kind under observation, one in hospital, which was at first thought to be epithelioma of the palate, but in which the antrum was found extensively affected; and the other in private, which was a good typical example of the disease. The patient, aged sixty-six, had a troublesome and loose upper molar tooth, for which he consulted a well-known dental surgeon in the West of England, who extracted it, bringing away a soft growth attached to the fangs. The opening was found to communicate with the antrum, and shortly a fungus growth protruded, and there was a good deal of discharge. The case was regarded as one of disease of the antrum, which was well syringed out, but the palate

became more involved and the cheek somewhat swollen. When I saw the patient in September, 1881, a month after the extraction of the tooth, there could be no doubt of its serious nature. Under chloroform I was able to pass my finger through the fungus completely into the antrum, which was widely affected. Turning up the lip without incising it, I was able with saw and bone-forceps to remove the floor of the antrum, which shows very well the disease (College of Surgeons' Museum). I then removed the back of the antrum, but the orbital plate being apparently healthy, I contented myself with scraping it freely and applying the chloride of zinc paste, the age of the patient forbidding removal of the whole upper jaw. Recurrence took place, and I again scraped away the growth and applied the zinc paste, but the disease again made progress, and the patient died, worn out, within a year of the first appearance of the disorder.

Mr. Butlin's case is very similar (*Pathological Society's Transactions*, 1881), and was that of a man, aged sixty-two, who, after pain in the jaw, found a fistulous opening in the palate, from which a foul discharge proceeded. The finger was passed easily into the antrum, and the cavity was cleared out, and, upon recurrence taking place, the upper jaw was removed, but the patient sank on the fifth day. Mr. Butlin has recorded another case under Mr. M. Baker (*Path. Trans.*, 1882), in a woman of fifty-eight, with a bulging out of the right cheek and an opening from the palate into the antrum. The upper jaw was removed, but the disease was found to have already spread beyond it, and the patient died exhausted after a few days.

The disease appears so insidiously and spreads so rapidly to the deeper parts that its prompt recognition is of the greatest importance, and it may, I think, be held that the attachment of any growth to the fangs of extracted teeth should excite suspicion as to the presence of serious disease within the antrum. M. Reclus, in the paper referred to, goes so far as to suggest that the disease originates in one of the periosteal cysts of the fangs of the teeth to be

described, but it seems more probable that it starts from the neighbourhood of a tooth, probably from the rudimentary paradental epithelium, described by Malassez. The existence of this epithelium is fully discussed in the chapter on Cysts of the Jaw (see p. 170).

In the cases of epithelioma in which I was content to operate from the mouth, the patients survived for some months, whereas in the two cases recorded by Mr. Butlin, in which the jaw was removed, the patients rapidly sank. Mr. G. Lawson has recorded (*Clinical Society's Transactions*, 1873) a case of this disease, in which he adopted a bolder, and apparently more successful, treatment—viz., to destroy the skin over the growth and the disease itself with the actual cautery, and then to apply caustic paste freely so as to obtain large sloughs. The patient was sixty-five, and made a good and, it is believed, permanent recovery. Of course there is the permanent deformity to be considered, but, after all, this is a slight drawback if a cure can be obtained; and, as regards immediate danger to life, Mr. Lawson truly remarks, "it must be borne in mind that patients advanced in life stand cutting operations very badly, whilst they will bear, with but little shock, the destruction of large growths by escharotics."

Sarcoma of the Antrum.—This variety of growth may originate in the wall of the antrum itself or may spread to the antrum from neighbouring parts. The tumours present the characters of sarcomata in other parts of the body, and the only satisfactory treatment is early and complete removal. They will be considered fully in the chapter on sarcoma of the upper jaw.

CHAPTER XII.

CYSTS OF THE JAWS.

IN order to understand properly the various theories advanced to explain the mode of origin of cystic tumours of the jaws, it is necessary to have a clear idea concerning the manner in which the teeth develop. For the sake of convenience we will describe what takes place in the lower jaw.

About the seventh week of intra-uterine life the epithelium of the gum becomes thickened along the alveolar border of the jaw, and the Malpighian layer sends down a process of epithelium into the subjacent tissue. This downgrowth of epithelium forms the organ from which, ultimately, the enamel is developed; and, as the downgrowth takes place along the entire border of the jaw, it is frequently called the *common enamel germ*. A slight groove on the surface of the gum is formed by the epithelial downgrowth, and this is termed the *primitive dental groove*.

As development proceeds, the changes in the common enamel germ become localised in certain situations—viz., where the milk teeth are eventually developed. At these spots the epithelium grows down in the form of flask-shaped bodies termed the *special enamel germs*, which are connected with the common enamel germ by a narrow band of epithelial cells, the neck of the enamel germ or *funicular band* (*cordon funiculaire*).

As these changes in the epithelium are taking place, we find that the subjacent embryonic connective tissue becomes differentiated into twenty papillæ, each papilla projecting into, and forming a dent in, each enamel germ. From this

papilla are developed the pulp, the dentine, and the cementum, and hence it is termed the *dental papilla*.

The soft embryonic tissue around the papilla and enamel germ becomes fibrillated and forms a kind of capsule. The entire structure—enamel organ, dental papilla and fibrous capsule—is termed a *dental follicle*.

While the development of the milk teeth is progressing, we find that the first rudiments of some of the permanent teeth appear—viz., those of the permanent teeth which actually replace the milk teeth. About the sixteenth week a small epithelial downgrowth projects from the funicular band above described, and develops into the enamel organ of the corresponding permanent tooth. From the funicular band of this permanent tooth another epithelial downgrowth may project, which in some animals forms a third tooth; but in the human subject it very rarely forms a tooth, and merely represents, in a rudimentary condition, a third dentition.

Inasmuch as the permanent molar teeth do not replace any milk teeth, they have a slightly different mode of development. From the posterior end of the common enamel germ, about the fifteenth week of foetal life, a special enamel germ develops, and this eventually forms the first molar tooth. Later on, from the funicular band of this enamel germ the second molar is formed, and still later from the funicular band of this latter the third molar or wisdom tooth is developed.

The permanent teeth are surrounded by bone, excepting where the funicular band remains. In this situation there is a canal in the bone termed the "*iter dentis*" (Alberran). In this canal there is a fibrous band termed the *gubernaculum*, containing columns of epithelial cells which represent the funicular band. As the permanent tooth is being cut, it reaches the surface by travelling along the *iter dentis*. Any obliteration or malformation of this passage might therefore lead to an error in the development of the tooth.

In this account of the development of the teeth it will have been observed that, although the greater part of the

epithelial downgrowth develops into a definite structure, the enamel organ, yet some part of it does not give rise to any permanent or even temporary organ. For instance, certain parts of the common enamel germ, the funicular bands, and epithelial elements from the enamel organ representing a rudimentary third dentition, are destined to form no special structure. The question naturally arises: What becomes of this epithelium? It used to be assumed that the epithelial cells gradually degenerated and finally disappeared. Malassez, however, in an interesting series of papers published in the *Archiv. de Physiol.*, 1885, 3^e série, showed that in the adult jaw these epithelium cells remain and form very definite collections, which may be classified into three groups.

1. A superficial group just beneath the epithelium of the gum.

2. The remains of the neck of the special enamel germ, the funicular band.

3. Groups of cells originating from the enamel organ, and perhaps representing a rudimentary third dentition. Columns of epithelium cells belonging to the last group are found, in adult life, in the alveolo-dental ligament, in that part of the ligament immediately surrounding the tooth. These groups of epithelium cells are termed by Malassez "débris épithéliaux paradentaires."

According to many authors, numerous tumours of the jaws, which may be cystic, fleshy or bony, are formed as the result of some error in the development of the teeth. Many pathologists, and in this country especially Bland Sutton, include these tumours under the generic term *Odontoma*, using this word in its widest sense. Thus, in an interesting paper read by Mr. Bland Sutton before the Odontological Society of Great Britain, he stated: "in the most extended sense an odontoma may be defined as a *neoplasm composed of dental tissues (enamel, dentine and cementum), in varying proportions and different degrees of development, arising from tooth-germs, or teeth still in the process of growth.*"

Under this definition of odontoma would be included,

dentigerous cysts, unilocular cysts, multilocular cysts, fibromata, hard odontomata, etc.

Inasmuch, however, as the mode of origin of many of these tumours is still, more or less, a matter of conjecture, it will be better to restrict the term *Odontoma* to its clinical sense, and include under it only the hard bony tumours originating in connection with the teeth.

The important question arises, In what part of the developing teeth do these various tumours originate? On this point there is considerable divergence of opinion. Thus Broca (*Traité des Tumeurs*) considers that they originate at some stage in the development of a dental follicle, which he divides into four periods.

1st stage. Période Embryoplastique.—At this stage no special tooth-elements have developed. There is simply a dental follicle, without any formation of enamel, dentine, or cementum. Errors of development at this period, according to Broca, may give rise to *fibromata* (fibrous odontomata) or to *unilocular cysts*.

2nd stage. Période Odontoplastique.—Here we find developed the special elements which give rise to the different parts of a tooth, viz., enamel cells, dentine cells, etc. In this stage, Broca considers that there may develop dentigerous cysts, multilocular cysts, and various hard odontomata.

3rd stage. Période Coronaire.—During this stage the actual formation of cement and dentine commences, followed by a cap of enamel, and in this way the crown of a tooth is formed. Any error of development during this stage Broca considers may give rise to the coronary odontomata.

4th stage. Période Radiculaire.—In this stage the formation of the fang and the eruption of the tooth take place. Here we may get the development of *radicular odontomata*.

In all probability Broca is quite correct in ascribing the origin of the hard odontomata to errors in development of the dental follicle itself, but Broca's theory does not satisfactorily account for the formation of the cystic tumours of

the jaw. Malassez, on the strength of his discovery of rudimentary epithelium in the adult jaw, considers that the cystic tumours, and perhaps certain epitheliomata, originate from the *débris épithéliaux paradentaires*. There are many points, as we shall see later on, in favour of Malassez's views, and for a full discussion of them the reader is referred to the papers by Malassez in the *Archiv. de Physiol.* (1885, 3^e série), and to the papers of his pupil Alberran in the *Revue de Chirurgie* (1888).

In this chapter we will confine our attention to the cystic tumours of the jaws, which, although differing in many respects from one another, have one feature in common, that is, their origination in all probability, directly or indirectly, in connection with the development of the teeth. It is proposed to group these cysts of the jaws into the following classes:

1. Cysts originating in connection with fully developed teeth. These have been termed "periosteal cysts" by Magitôt, "alveolo-dental cysts" by Forget. It is convenient to apply to them the term *Dental Cysts*.

2. Cysts originating in connection with imperfectly developed teeth. These are generally termed *Dentigerous Cysts*. They are identical with the "follicular cysts" of Broca.

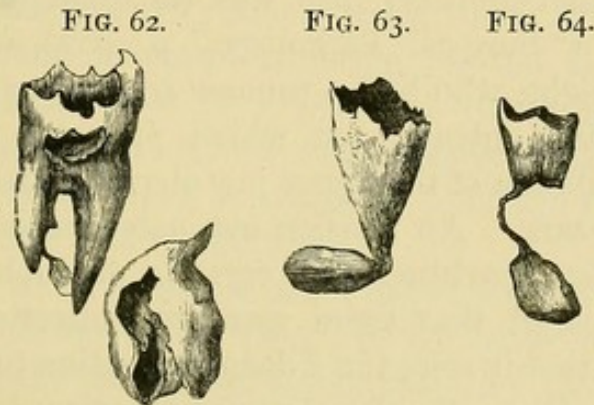
3. *Multilocular Cysts*.—There is considerable divergence of opinion concerning the origin of these cysts, and this point will be fully discussed later on. On the whole it is most probable that they originate in connection with embryonic tooth structures.

1. *Dental Cysts*.—These cysts contain neither a tooth nor the rudiment of a tooth, and are divided by many writers into two groups, one where the cyst is situated beneath the periosteum of the fang of a tooth—"the periosteal cyst" of Magitôt—the other where there is apparently no direct connection between the cyst and a tooth. The majority of cases fall into the first group. They are met with more frequently in the upper than in the lower jaw, and generally in connection with the incisor or canine teeth. They are usually small in size, and may come away with the tooth when it is extracted. I am indebted to Mr. Holborow

King for three interesting specimens, which are now in the Museum of the Royal College of Surgeons.

Two of them (Figs. 63, 64) are quite small (one being remarkable for the length of its pedicle); the third (Fig. 62) is of the size of a hazel-nut, and was torn in extraction. The contents of the cysts were found, on microscopic examination, to consist of degenerating pus; their walls were formed of fibrous and granulation tissues, and they had no epithelial lining.

The absence of an epithelial lining, however, throws considerable doubt upon their nature. Malassez, Alberran, and others have shown that these cysts do possess an epithelial lining which, according to the latter observer, is



composed of cells similar to those of the enamel organ. The contents of the cyst may vary. Usually it is a clear fluid, frequently containing cholesterine crystals; it may, however, be brownish or purulent.

In some cases the cyst may reach a large size, and in these Alberran has shown that the epithelial lining is similar to that of the small cysts.

Large cysts which produce more or less absorption of the outer wall of the maxilla, are, in my experience, very common consequences of the retention of diseased teeth, but seem to give surprisingly little inconvenience to the patients, even when of large size and producing considerable deformity of the face. They are commonly confounded with cystic distension of the antrum.

Dupuytren remarks that "morbid changes in the roots of

the teeth give rise to the formation of serous cysts, which are most frequently met with in the alveoli of the upper canines, and in some instances acquire a very large size, even equal to that of the antrum. In such cases the root of the tooth is found diseased and enclosed within the cyst, which adheres to the alveolar cavity, and (when small enough) usually accompanies the tooth in its extraction, but if left behind, a suppurative process is established, which continues for a long time. The fluid yielded by these cysts is sometimes very thick, and in other instances of a serous character, and their inner surface is as smooth as that of the serous membranes." ("On Diseases of Bone," Sydenham Society's translation, p. 440.)

Of this kind probably also was the case mentioned by Sir J. Paget ("Surgical Pathology," p. 402), of a woman, aged thirty-eight, who had a tumour simulating a collection of fluid in the antrum, but which projected beneath the mucous membrane of the upper jaw above the teeth, and had existed six years. An incision evacuated an ounce of turbid brownish fluid, sparkling with crystals of cholesterine, and it then appeared that there was no connection with the antrum, but that it rested in a deep excavation in the alveolar border of the jaw. So also the case mentioned by the same author in connection with the incisor teeth.

Delpach relates a case in which a membranous cyst contained three ounces of fluid, but its interior bore no resemblance to the interior of the antrum; and Stanley (p. 300) narrates a case of Sir W. Lawrence's of large cyst projecting in the situation of the antrum, and containing a glairy fluid with shining particles in it, and regards both cases as instances of cysts connected with the teeth, although it appears more probable that they were examples of cyst in the antrum, such as have been already described.

A case, which I have little doubt originated in a cyst in connection with the incisor teeth, but in which the antrum had become secondarily involved, has lately been under my own care. The patient, a woman aged forty, had a fluctuating swelling, noticed for two years, immediately above

the incisor teeth, which were decayed even with the gum. On incising it, a quantity of yellowish glairy fluid exuded, and a probe, when introduced, evidently passed into the antrum. From the position of the cyst, and its close proximity to the incisor teeth, I have no doubt it originated from them, and found its way into the antrum by absorption of the bony wall. The patient would not consent to any operation for the cure of the disease, which gave her little inconvenience.

Fischer, of Ulm (Gurlt's *Jahresbericht*, 1859, p. 154), has narrated three cases of cyst connected with the fangs of teeth, in one of which he had the opportunity of making a post-mortem examination. After the removal of the facial wall of the antrum, there appeared a cyst connected with the apex of the posterior molar tooth, which filled the whole antrum without, however, adhering to the mucous membrane. This consisted of a perfectly closed serous bag of $\frac{1}{8}$ " thickness, with a smooth inner surface, and containing a yellowish serous fluid, which grew from the periosteum of the apex of the root of the tooth.

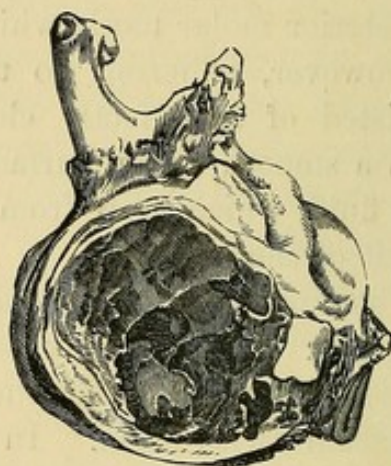
Although more common in the upper jaw, dental cysts are found in the lower jaw. They usually occur in direct connection with the teeth, but sometimes they have apparently no immediate relation with them. In these cases it is very probable that some irritation connected with these organs may have been the original cause of the mischief. Of this a most remarkable specimen from a woman, aged forty-five, is to be seen in St. George's Hospital Museum.

The cyst is for the most part single, and contains merely fluid, which may be clear or more or less coloured. Dupuytren narrates several cases of the kind ("Diseases of Bone," Sydenham Society's translation, p. 437), from some of which only reddish-coloured serum escaped on their being opened, whilst in others a fibroid growth, and in one osseous nodules were found within them. There is a good example of a single cyst, for which a piece of the entire thickness of the lower jaw was excised, in St. George's Museum, of which the following are the particulars: The patient had had a tumour, supposed to be an epulis, removed from the same

spot two years before, and the disease had been growing since that time. When admitted the tumour was found to be a firm oval growth, about the size of an orange, connected with the outer surface of the right inferior maxilla. It was evidently cystic, and there was an indistinct sensation of fluctuation. The tumour, as well as the portion of bone from which it grew, was removed by an incision in the median line. The extent of lower jaw removed was from the lateral incisor tooth on the left side to the angle of the jaw on the right.

The accompanying drawings show a case of unilocular cyst

FIG. 65.




of the lower jaw, for which Sir William Fergusson removed a large portion of the bone. Fig. 65 shows the growth, and Figs. 66 and 67 the patient before and after the operation (see "Practical Surgery," p. 666).

Etiology and Pathology.—Numerous theories have been advanced to explain the origin of these cysts. Tomes and Magitôt consider that their starting-point is an inflammation of the alveolo-dental periosteum, which, instead of forming an abscess, leads to the development of a serous cyst. There are difficulties in the way of accepting this theory, especially as regards the epithelial lining. It is difficult to explain, on the inflammatory theory, the formation of a distinct epithelium. Verneuil, Reclus, and especially Malassez, consider that a more feasible explanation of the occurrence of

FIG. 66.



FIG. 67.



cysts is to be found in their origin from rudiments of the enamel organ, or, as Malassez terms it, "débris épithéliaux paradentaires." This epithelium may begin to hypertrophy as a result of the irritation set up by micro-organisms spreading from a carious focus in a tooth, or as the result of an operation on a tooth.

It is difficult, on the inflammatory theory, to explain the mode of origin of those dental cysts which originate at some distance from the alveolo-dental periosteum. On the theory of Malassez, however, there is no difficulty in explaining that some elements of the primitive enamel germ have remained, but not in immediate contact with the tooth. In favour of this theory also is the fact that, after treatment of these cysts and apparent cure, a recurrence has taken place. This recurrence may be only a unilocular cyst, but a multilocular cyst, and even a more or less solid epitheliomatous growth, has been described.

Symptoms.—The patient finds that he has a slowly growing tumour of the jaw, which at first is painless, and gives him no trouble except from the deformity. The outer plate yields ordinarily to the pressure of the growing cyst, and thus a prominent smooth tumour is formed, over which the skin is freely movable. When the bony wall is sufficiently attenuated, the peculiar crackling already described may be produced on pressure, and if the disease is still unchecked the bone becomes entirely absorbed, and nothing but a membranous cyst, with particles of osseous matter embedded in it, remains. Later on, owing to the tension of the accumulating fluid, more or less pain may be present, radiating into the molar or frontal regions, or even on to the scalp.

The diagnosis and treatment of these cases will be considered in connection with dentigerous cysts.

2. *Dentigerous Cysts.*—These cysts contain one or more teeth in their interior or in their wall. The teeth may be well formed, or may be quite rudimentary, consisting of irregular masses of bone and enamel. They are almost invariably connected with permanent teeth, though Mr.

Salter mentions a case in connection with a temporary molar occurring in the practice of Mr. Alexander Edwards, late of Edinburgh; and in a remarkable specimen belonging to Mr. Cartwright, which will be afterwards referred to, the tooth is a supernumerary one. I have also myself met with an example of cyst connected with a temporary tooth in a boy of four years, brought to me by Mr. C. J. Fox. In this case the temporary right canine tooth was wanting, and there was a cyst developed in its situation, on cutting into which I extracted seven small irregular nodules of dentine and enamel, but no complete tooth, this being therefore an example of the odonto-plastic cyst of Magitôt.

As a rule the cysts are single, but occasionally they consist of two compartments, which may or may not communicate. Their contents are ordinarily clear fluid, sometimes bloody, occasionally filamentous or gelatinous, and still more rarely they contain a sebaceous matter like mastic, composed almost entirely of epithelium.

The tooth may lie free in the cavity of the cyst, or, which is more usual, it may be implanted in the wall of the cyst with the crown projecting into the cavity. In the majority of cases it presents the characters of a molar tooth. Instead of one tooth, several may be found, which are generally more or less rudimentary.

The cyst wall is composed of two parts, an external fibrous layer and an internal layer lined with epithelium, which, according to Alberran (*Revue de Chir.*, 1888), is similar to that of the enamel organ.

Dentigerous cysts are met with more frequently in the lower than in the upper jaw, thus differing from dental cysts.

Etiology and Pathology.—Owing to the difficulty in observing the early stages in the growth of these cysts, it is not surprising to find that observers are by no means unanimous in the theories they advance. According to Broca (*Traité des Tumeurs*, vol. ii, p. 35), dentigerous cysts originate by changes taking place within the tooth follicle. The space between the follicle and the dental papilla is occupied by the enamel organ, an organised body, but very soft and

gelatinous, apt to disappear under morbid influences, and thus leaving in the follicle a cavity ready to be transformed into a cyst. If the cyst begins to develop at an early period, the dental papilla undergoes atrophy as a result of the pressure of the accumulating liquid, and no tooth, or even rudiment of a tooth, is formed. If, however, the dental papilla have reached some development before the cyst forms, some rudiment of a tooth will be found. Finally, in some cases the crown of the tooth may have been completely formed before the development of the cyst.

Mr. Tomes explains the formation of cysts in connection with retained teeth by referring to the fact that, when the development of the enamel of a tooth is completed, its outer surface becomes perfectly detached from the investing soft tissue, and a small quantity of transparent fluid not uncommonly collects in the interval so formed. This fluid ordinarily is discharged when the tooth is cut, but when from some cause the eruption of the tooth is prevented, it increases in quantity, gradually distending the surrounding tissues in the form of a cyst.

Malassez explains the origin of dentigerous cysts in the same manner as he explains the formation of dental cysts—viz., by the hypertrophy of epithelial rudiments of the enamel organ.

Alberran, while supporting the views of Malassez, lays considerable stress upon the part played by the "*iter dentis*"—i.e., a bony canal which leads from the gum to the socket of a permanent tooth. In this canal is a fibrous band, in which can be found columns of epithelial cells, similar to those of the enamel organ. As the fang develops the tooth is pushed along the canal to the surface. If, however, the canal should become blocked, or its direction altered, the tooth might find considerable difficulty in reaching the surface. Under these circumstances the irritation might lead to a proliferation of the rudimentary epithelium.

In the face of these conflicting theories it is impossible at present to account satisfactorily for the origin of dentigerous cysts.

Symptoms.—Although dentigerous cysts are more common in the lower than in the upper jaw, yet Mr. Salter, in his work on "Dental Pathology and Surgery," has collected several cases of dentigerous cyst in the upper jaw, which were recognised and treated during life. Thus, Jourdain records three cases, one in a girl of seventeen, in whom the first and second right upper permanent molars were inverted and the surrounding cyst had involved the antrum; a second, in a man of sixty, connected with a bicuspid tooth of the upper jaw; and the third in a girl of thirteen, connected with an upper lateral incisor. Dupuytren and Bransby Cooper each met with a case in the upper jaw, Dupuytren's case, which was shown to him by M. Loir, being a remarkable instance of a cyst developed between the plates of the palatine process of the upper jaw (*see* Dupuytren "On Diseases of Bone," Sydenham Society's translation, p. 438).

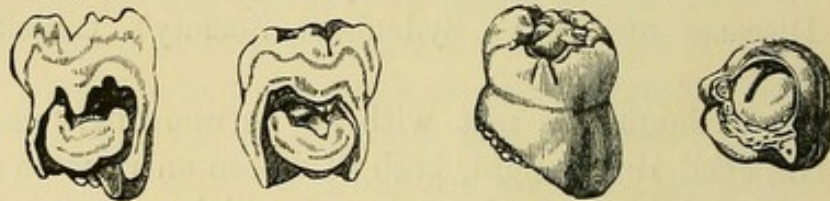
Professor Baum also met with an extraordinary case in a woman, aged thirty-eight, both of whose antra were enormously dilated by cysts, from one of which a canine tooth, and from the other a molar tooth, was removed. Mr. Salter gives two cases of his own, which will be found at length in the *Guy's Hospital Reports*, 1859; one depending upon the impaction of a wisdom-tooth in the lower jaw of a man, aged twenty-two, and the other in a girl of eighteen, who had an elastic fluid-containing tumour in the incisive region of the upper jaw, connected with a permanent incisor tooth, the fang of which was not developed, and whose place was occupied by a temporary tooth.

Inversion of the tooth appears to be a frequent accompaniment, or rather the cause, of these cysts, and occurred in one of the cases narrated by Jourdain, and in those of Dupuytren and Bransby Cooper. Mr. Tomes ("Dental Surgery") has recorded a similar case in a girl of sixteen, who had a swelling around the second molar tooth of the lower jaw, which proved to be a cyst. After being tapped the cyst suppurated, and the extraction of the tooth became necessary, when the inverted crown of the third molar was

found lodged between the expanded fangs of the second molar tooth, the two being united by dentine, and having one common pulp-cavity, as seen in the accompanying drawing, Fig. 68, from Mr. Tomes' work.

Cases of dentigerous cysts may be mistaken for solid tumours. Thus Gensoul, of Lyons, has recorded the case of a girl of thirteen, whose antrum was distended with a large collection of yellow fluid, and contained a canine tooth attached to its wall, in whom he had made the incisions necessary for the removal of the tumour before he discovered its nature. Mr. Syme also has related (*Edinburgh Medical and Surgical Journal*, 1838) the case of a woman, aged thirty-one, on whom he operated for a tumour of the upper jaw of

FIG. 68.



four months' standing, by laying open the cheek and removing the tumour with the bone-forceps. "The tumour was found to consist of a dense cyst, lined throughout with earthy matter in a crystalline form, and containing a clear glairy fluid, together with the crown of a tooth, apparently the lateral incisor." In a cavity beyond the tumour was found a fully formed canine tooth, encrusted with a thin plate of bone. The teeth are said to have belonged to the temporary set.

When dentigerous cysts occur in the lower jaw they form more isolated and prominent tumours than in the case of the upper jaw, and in some cases the projecting bony wall has been removed. In St. Bartholomew's Museum is a specimen of the kind, consisting of a portion of a bony cyst, which was removed by Mr. Earle from the external and lateral part of a lower jaw. The cyst is lined with a thick and soft membrane, which has been in part separated from it. The cavity of the cyst was filled with a glairy fluid,

and at the bottom of it a canine tooth of the second set was adherent to the lining membrane. The case is referred to by Stanley, who gives an accurate drawing of the preparation. In the Museum of the College of Surgeons there is a very similar preparation, showing a bony cyst of oval shape, one inch in its long diameter, lined with a thick well-formed membrane, containing an imperfectly formed bicuspid tooth, which was removed by Mr. Wormald from the lower jaw of

FIG. 69.

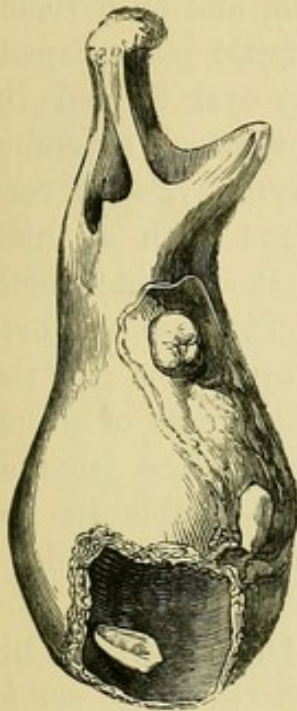
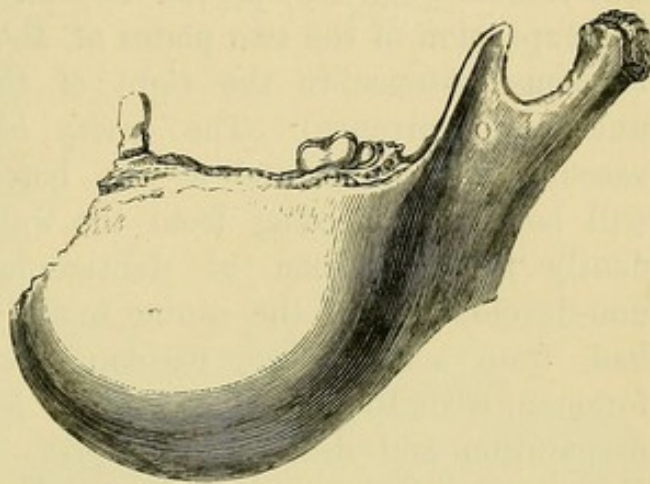


FIG. 70.



a female, aged seventeen, whose case will be found in the *Lancet*, June 22nd, 1850.

When the cyst occurs in the lower jaw, and is less prominent than in the two cases already mentioned, giving rise to a general expansion of the bone rather than a distinct tumour, the disease may be mistaken for a solid tumour of the lower jaw. A case of this kind occurred to that excellent surgeon, the late Mr. S. W. Fearn, of Derby, who had the courage and honesty to publish the case (*British Medical Journal*, August 27th, 1864), and to whom I was indebted for the very valuable preparation now in the College of Surgeons' Museum, from which the drawings, Figs. 69 and 70, were made.

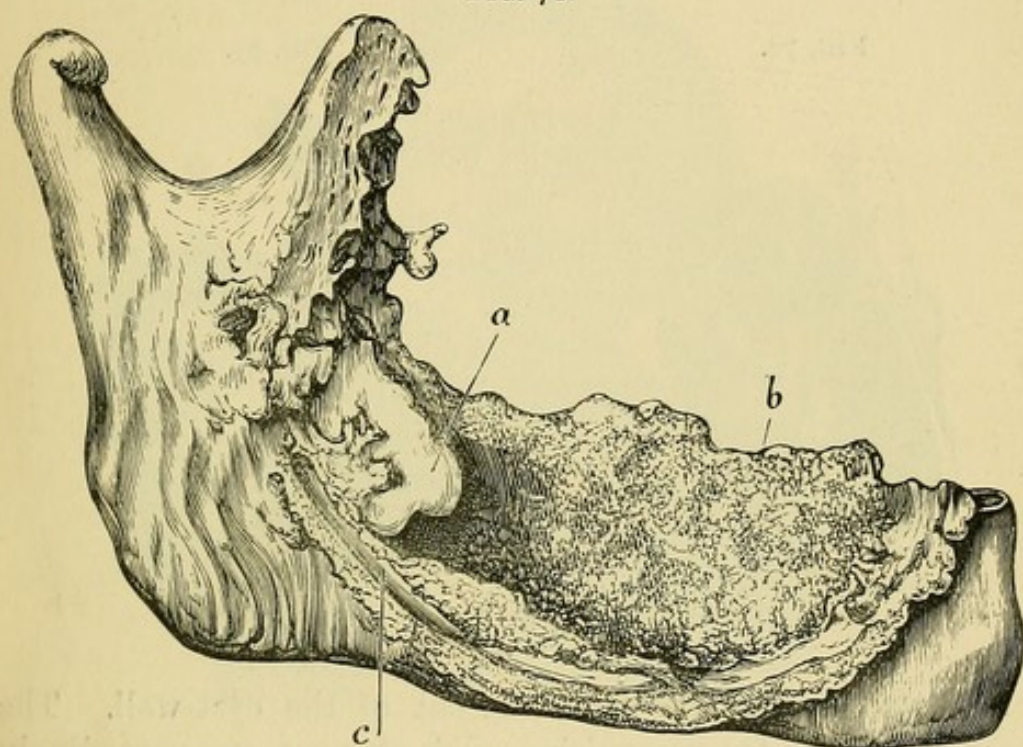
Mr. Fearn's patient was a girl of thirteen, who had a large resistant tumour of the left side of the lower jaw, which had been growing six months. There was some enlargement also of the right side, and the teeth there were very irregular. The teeth on the left side had been extracted, with the exception of the second molar and a temporary molar. No opening could be detected in the tumour, though there was a constant offensive discharge from its surface. Mr. Fearn removed the left half of the jaw from the symphysis to the articulation, and on division of the bone with the saw a quantity of foetid pus escaped. The tumour (Fig. 69) proved to be a bony cyst formed by the expansion of the two plates of the jaw, which extended for some distance to the right of the symphysis (a very unusual occurrence). The cavity is lined with a thick vascular membrane, and at the bottom the canine tooth will be seen projecting from the wall. The case was evidently therefore one of dentigerous cyst, due to the non-development of the canine tooth, the contents of which had, from some cause, become purulent. The mental foramen, with the nerve emerging, is still visible in the preparation and drawing (Fig. 70). The patient made a good recovery.

A very similar case is recorded by Dr. Forget, in his essay on *Les Anomalies Dentaires et leur influence sur la production des Maladies des Os Maxillaires*, 1859, which is translated by Mr. R. T. Hulme, in the *Dental Review*, 1860. The patient was a woman, aged thirty, who had a tumour on the right side of the lower jaw, of the size of a hen's egg, extending from the lateral incisor to the base of the coronoid process, which had been growing ten years. M. Lisfranc removed half the jaw, and the patient made a good recovery. An examination of the tumour showed it to be a cyst, at the bottom of which lay the wisdom tooth, the crown projecting downwards into it, the fang being inverted and fixed in the base of the coronoid process. In the illustration (Fig. 71), (for which I am indebted to Mr. Hulme), the cyst has been opened, the internal wall *b* being

left; *a* marks the position of the tooth, and *c* the inferior dental canal, which has been opened to show its non-communication with the cyst.

M. Legouest brought under the notice of the Société de Chirurgie de Paris, in 1862, a very similar case, which had the peculiarity of pulsating at one point synchronously with the radial pulse. The supposed tumour proved to be a dentigerous cyst containing two teeth, the pulsation having been due to the great vascularity of the membrane cover-

FIG. 71.



ing it, and the great pain which had been experienced, to the fact that the dental canal was opened, and the nerve pressed upon by the cyst (*Gazette des Hôpitaux*, August 7th, 1862).

In the *Annali Universali di Medicina* for May 1867, Sig. Bottini, of Novara, has recorded a case of "sub-periosteal and sub-capsular disarticulation" of the left half of the lower jaw of a woman, aged twenty-three, for what proved to be a dentigerous cyst in connection with the wisdom tooth.

Mr. Underwood has allowed me to have the accompanying drawing (Fig. 72) taken from the model of a preparation

which he possesses, showing very beautifully a cyst of the lower jaw, which was removed by M. Maisonneuve by sawing through the bone at two points. The canine tooth is seen lying horizontally at the bottom of the cyst. The patient, aged fifty-six, had a swelling in the lower jaw near the chin, and an opening formed behind one of his front teeth, from which a saline fluid escaped. The man made a good recovery from the operation. (Vide *British Journal of Dental Science*, 1862, p. 562.)

Dentigerous cysts, like other cysts, may undergo altera-

FIG. 72.

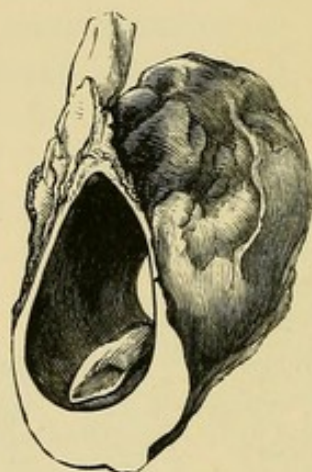
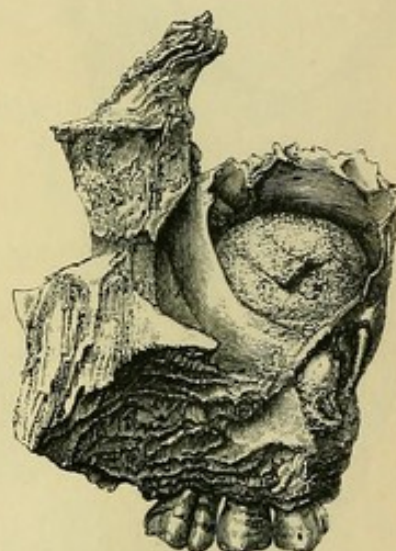


FIG. 73.



tion, not only of the contents, but of the cyst-wall. The opportunities for recognising such changes are exceedingly rare, and the only known specimen of the kind is one presented by Mr. Samuel Cartwright to the Royal College of Surgeons' Museum, which shows calcification of the cyst-wall. The preparation (Fig. 73) is one of the right superior maxilla, which, having been opened, shows a bony cyst within the antrum and attached to its floor, but unconnected with it elsewhere. The cyst has been opened, and contains a *supernumerary* tooth loose in its cavity, though no doubt originally attached to its base. This is clearly a case of dentigerous cyst which has undergone calcification, and which, had it been expanded to a greater degree before this change took place,

would in all probability have been inseparably united with the walls of the antrum.

In some cases the contents of a dentigerous cyst may completely disappear, as in the following case :

The accompanying engraving (Fig. 74) shows a cyst of the lower jaw occurring in a man, aged thirty-four, who was under my care in 1878. The swelling began nine years

FIG. 74.



before, and was of the size of an ordinary orange, round, very hard, and fixed to the angle of the lower jaw on the right side. Its edges were well defined, there was no fluctuation nor pulsation, except that of the facial artery, which was stretched over the tumour. Externally the tumour appeared to be solid, but examined from the mouth, the anterior part of the wall yielded slightly to firm pressure. On puncturing from the mouth through the bony wall I entered a large *empty* cavity lined with soft tissue, which on microscopical examination showed portions of hyaline cartilage and cartilage with a faintly fibrous matrix, surrounded by,

and gradually passing into, oval and spindle cells. The bony walls of the cyst were broken down and partially cut away, and this proceeding was repeated a fortnight later. The tumour gradually diminished as suppuration went on, several pieces of bone being removed, and, six weeks after the cyst had been opened, a tooth was felt fixed at the bottom of the cavity, and on being extracted proved to be a bicuspid with a perfect crown and two small fangs. After this the cavity closed and the swelling entirely disappeared. The case is remarkable, both for the age of the patient and also for the fact that the cyst was empty, the fluid which must have been present at one time having become absorbed. A careful search for a tooth was made at the time of the operation, but one could not be found, and its discovery at a later date was probably due to the destruction by suppuration of the lining membrane of the cyst, which had completely enveloped it.

In the Museum of the Royal College of Surgeons is a preparation of the right side of the body of the lower jaw, completely and uniformly dilated into a large spherical cyst. No tooth or rudiment of a tooth can be discovered in the cyst, but its inner surface is lined by a layer of small epithelial cells and is thrown, in places, into thick projecting folds. Mr. Eve considers it probable that the cyst originated in the enamel-organ of an abortive wisdom or supernumerary tooth, and hence would consider it an example of the follicular cyst developed in the embryonic period (Magitôt).

Diagnosis of Dental and Dentigerous Cysts.—A careful examination of the mouth may reveal the absence of a permanent tooth, or, as in one of Mr. Salter's cases, may show a temporary tooth occupying a permanent position, and this would direct the mind of the surgeon to the possible existence of a dentigerous cyst. On the other hand, however, it must be remembered that teeth may be wanting without being connected with any disease; thus, I am acquainted with a family who have the hereditary peculiarity of a single bicuspid tooth on each side.

If, however, the permanent teeth have been erupted normally, and one or more of them in the region of the cyst be decayed, then the probability is that we are dealing with a dental cyst and not a dentigerous cyst. We should also bear in mind that dental cysts are usually in the upper jaw and connected with canine or incisor teeth, whereas dentigerous cysts are more often in the lower jaw, and connected with the molar teeth.

When a cyst is sufficiently expanded for the wall to yield under the finger with the characteristic parchment-like crackle, there can be no difficulty in its recognition, but without this it is impossible in all cases to distinguish between a cyst and a slow-growing solid tumour. Under these circumstances, it is well to insist upon the propriety of making an exploratory puncture in all cases which are not obviously solid growths, and have sprouted so that their nature can be certainly recognised. The puncture being made within the mouth will be of no moment should a more severe operation subsequently be necessary.

Treatment of Dental and Dentigerous Cysts.—Of recent years it has been noticed that occasionally, after incision and drainage of these cysts, a recurrence has taken place. This recurrence usually takes the form of a unilocular or multilocular cyst, but occasionally an epitheliomatous growth is found. If we accept Malassez's views concerning the mode of origin of these cysts—viz., in rudimentary epithelial structures—it is not difficult to understand how the recurrence may take place.

It is therefore a most important point in the treatment to see that the whole of the cyst wall is removed or destroyed. At the same time any teeth or rudiments of teeth in connection with the cyst must be got rid of. It will usually be necessary to excise a portion of the front wall of the cyst so that the rest of the cyst wall can be removed. If this be impossible, the cavity should be swabbed out with a strong caustic, such as a solution of chloride of zinc, gr. xl. to the oz., or the cyst wall may be cauterized. This may be accomplished in most instances without any incision of the

integuments, and in the few more extensive cases by simply dividing the lip, and carrying the incision into the nostril.

In cases where a permanent opening into the antrum is not required, it will be sufficient to turn up a sort of trap-door, as suggested by O. Weber, the periosteum serving as the hinge, so that it may be replaced after the removal of the contained cysts. It can but rarely happen that such an extensive mutilation can be requisite as is shown in a preparation in Guy's Hospital Museum, consisting of the outer wall of the antrum and the palatine plate, containing all the teeth of the left side except the central incisor, which was removed by Mr. Key from a case of very greatly distended antrum.

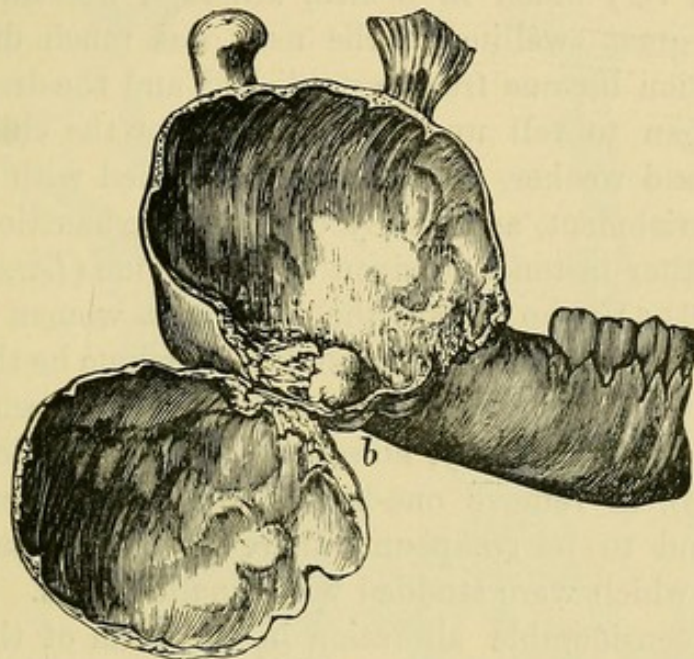
In the case of dentigerous cysts of the lower jaw it will, after removal of a portion of the wall, be advisable to squeeze the plates together as far as possible, and, in the case of the upper jaw, pressure by pads and bandages, as recommended by Liston, will do much to restore the parts to their usual form. Dr. Forget relates the case of a woman, of about thirty, with a hemispherical tumour of the right side of the lower jaw, which was produced by the bulging of the external plate of the ramus of the jaw, the internal having preserved its usual position. M. Nélaton exposed the tumour, and making a hole in the outer wall found a tooth projecting into the cyst. The tooth was extracted with some difficulty, and the patient perfectly recovered, and was well ten years after. The accompanying illustration (Fig. 75) represents the relation of the parts, *b* pointing out the position of the tooth (*Dental Review*, 1860).

The cyst should always be reached by dividing the mucous membrane within the mouth, and without incising the cheek; but, if necessary, a single line of incision only should be made, so that as little after-deformity as possible may be produced.

3. *Multilocular Cysts*.—Since the first case of multilocular cyst of the jaw described by Mr. Cusack in the *Dublin Hospital Reports* for 1826, a considerable number has been recorded, so that in 1885 Bernays was enabled to collect 122 cases (*N. Y. Med. Record*). They may occur at

any age, but most frequently about the twentieth year. They are more often met with in the lower than in the upper jaw in the proportion of 11 to 1. They are of slow growth, have very little tendency to implicate surrounding parts or the neighbouring lymphatic glands, and, if completely removed, rarely recur, and still more rarely become disseminated through the system. Their comparative innocence is probably explained by the bony capsule forming their boundary, by their low degree of vascularity,

FIG. 75.



and by the remarkable tendency of the epithelial cells composing them to undergo degenerative changes.

Multilocular cysts may contain other cysts within them, but this condition must be a rare one, for I can find only two examples of it. One was a congenital cystic tumour in an infant of six months, who was under Mr. Coote's care in 1861, and of which the following brief facts are extracted from the *Lancet* of Aug. 31st, 1861: "The right half of the lower jaw was enormously enlarged, and occupied a prominent position in the neck, extending downwards as far as the chest. It appeared to invade the entire bone, but was really confined to the right side. Its increase had been

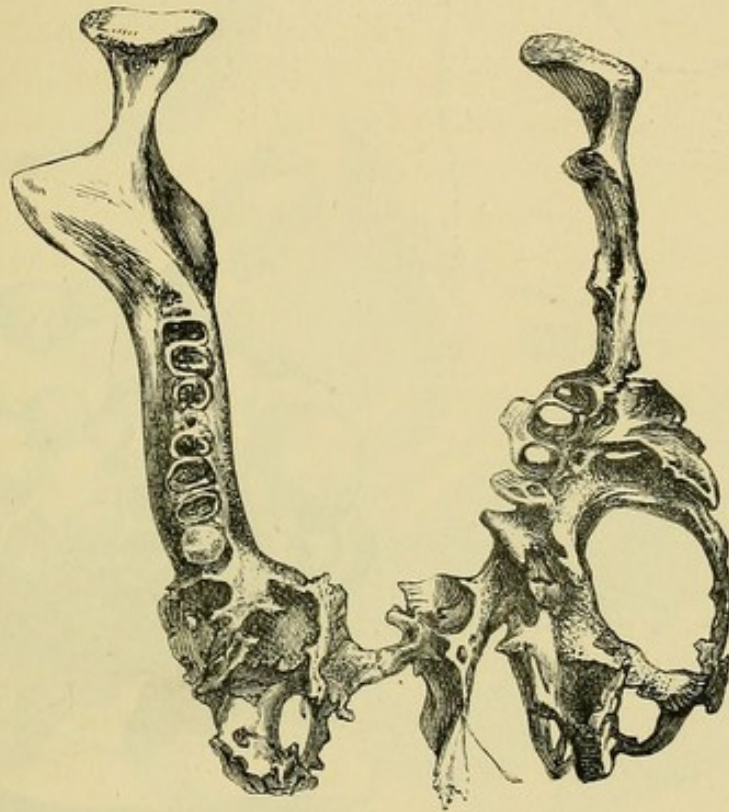
rapid since birth, and as it was still enlarging it became necessary to do something to afford a chance for life, as, if left alone, suffocation would have ensued, in a short time. Accordingly, chloroform being given, an incision was made by Mr. Coote upon its outer part, and a thin shell of the expanded jawbone reached. This was opened, and the interior was found to be filled with a regular nest of cysts, one placed within the other, all of which were removed, and the cavity closed with lint. Very little blood was lost during the operation, and for a few days afterwards the child improved very much in health, although necessarily weak, and the great swelling of the neck was much diminished. Suppuration became freely established, and the drain shortly after began to tell upon the system, for the child became weaker and weaker, although well supplied with wine and good nourishment, and finally died from exhaustion."

The other instance is given by Mr. Syme (*Lancet*, March 10th, 1855), who quotes the case of a woman having a large cystic tumour of the lower jaw, in whom he three times opened the cyst and stuffed it, with temporary benefit. He was obliged eventually, however (five years after the first operation), to remove one-half of the bone, when the cyst was found to be compound, there being four cavities, the walls of which were studded with smaller cysts.

Very considerable alteration in the form of the maxilla may be produced by multilocular cysts, of which a good example is seen in the drawing (Fig. 76) from a macerated specimen in St. Bartholomew's Museum. Here the bone is irregularly expanded in great part to form septa between the cysts. These, which were independent of one another, had their origin in the interior of the bone, were lined by a highly vascular membrane, and contained thin serous, or grumous, blood-tinged fluid. The walls of some of the cysts were thin and yielding, but others were thick and resisting, and this was particularly the case with the most posterior cyst on the left side, which had pressed upon and caused absorption of the left ramus and coronoid process. The preparation was taken after death from an

old man, aged seventy-five, who had noticed the enlargement for five years, when he came under Mr. Coote's care in St. Bartholomew's Hospital in 1857. The following brief account of the case is taken from the *Lancet* of Oct. 10th, 1857: "The origin of the affection Mr. Coote attributed to the irritation produced by the stumps of decayed teeth. He punctured some of these cysts with a trocar, and gave exit to a sero-purulent fluid from one, and fluid like the white

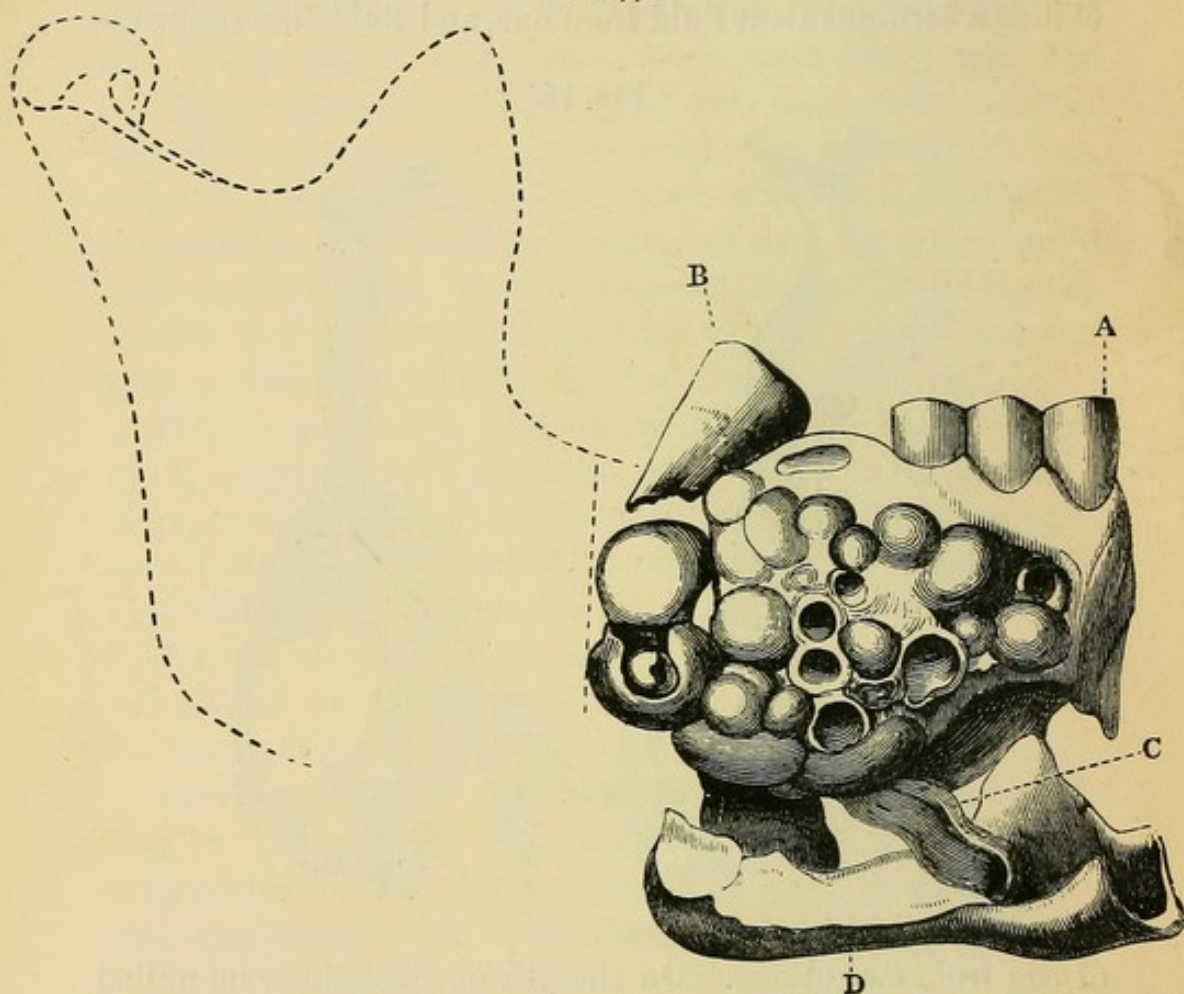
FIG. 76.



of egg from two others. On the 5th of September he pulled out a couple of bodies of teeth, with scarcely any remains of fangs, but in their stead some irregular fibrous-like projections. The removal of these permitted the flow of a sero-albuminous fluid, the teeth having acted like stoppers. Since the man had been in hospital, the size of the tumour had most certainly diminished one-third under the plan of treatment of puncturing. The age of the patient precluded the possibility of attempting any more severe measures than those already adopted. On the 21st the swelling had some-

what increased, and three or four of the cysts were again punctured, with the discharge of a thick, clear, yellow fluid, and several of these were run into one internally. This was done under partial anæsthesia from chloroform. One of the cysts discharged a good deal in the mouth; this was partly swallowed, and had caused indigestion."

FIG. 77.

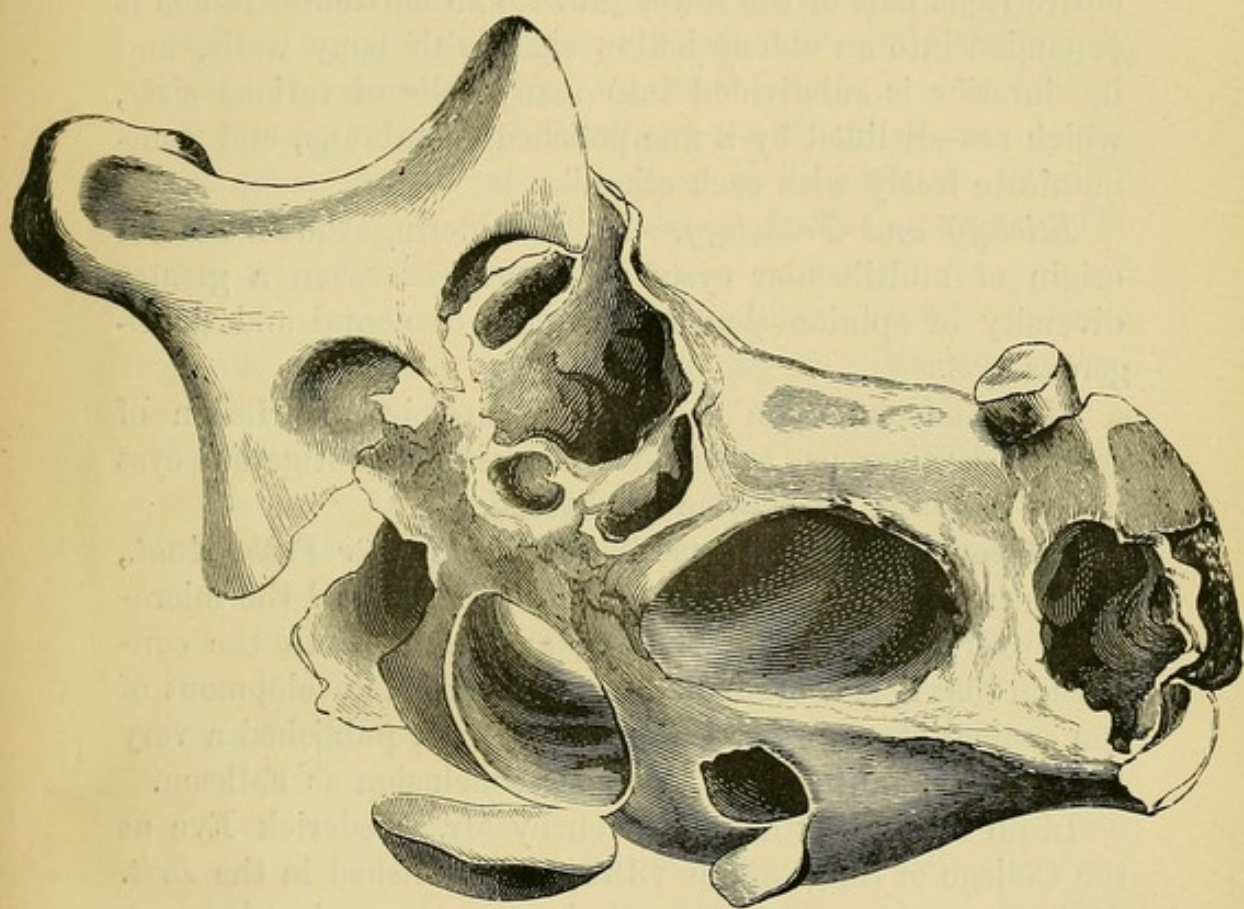


A, Canine; B, Second molar; C, Anterior portion of dental nerve; D, Remains of the base of horizontal branch of jaw excavated on its upper surface, on which lay the tumour.

In St. Mary's Hospital Museum is a valuable recent specimen of the same disease, removed by Mr. Lane. Here the growth was of seven years' duration, and involved the left side of the body of the lower jaw. A longitudinal section shows the cystic structure, the cells of which were filled with dark gelatinous fluid, and occupied the whole thickness of the bone.

The cells may, however, be of much smaller size ; thus, Dr. Robert Adams records, in the *Dublin Hospital Gazette* for 1857, the case of a man from whom he removed a portion of the body of the jaw from the symphysis to the molar teeth, about two inches in length. "The mucous membrane covering it was here and there raised into small rounded eminences of the size of peas, though some were larger and

FIG. 78.



purple in colour (Fig. 77). The tumour was composed of bony cells of a texture as fine as the ethmoid bone. The cells generally were of such a size that each might be capable of receiving within it a garden pea. They communicated with each other, and amounted to no less than twenty-six in number. They were all lined by a pulpy, very red, vascular membrane, and contained an albuminous fluid tinged of a reddish colour, apparently from blood held dissolved in it."

Again, in cases of long-standing disease the cysts become

greatly distended, and the septa, in great part, absorbed, so that the cysts communicate very freely.

Of this kind was a tumour (Fig. 78) removed by Mr. Cusack, in 1826, from a woman named Kenny, whose case will be found in detail in Mr. Cusack's well-known essay in the *Dublin Hospital Reports*, vol. iv. Dr. Adams, in his paper already referred to, supplies an account of the tumour in this case. "The portion of bone removed comprises the entire right half of the lower jaw. The horizontal ramus is expanded into an oblong hollow shell with bony walls, and its interior is subdivided into many cells of various sizes, which are all lined by a fine polished membrane, and communicate freely with each other."

Etiology and Pathology.—In considering the mode of origin of multilocular cysts we meet with even a greater diversity of opinion than in the case of dental and dentigerous cysts.

Magitôt looks upon them as formed by the fusion of several dentigerous cysts, or by a single dentigerous cyst which has later on become subdivided.

Falkson published a case in the *Archiv für Path. Anat.*, 1879, in which he had very carefully examined the microscopic structure of the tumour, and was led to the conclusion that it had originated in an abnormal development of the enamel organ. Soon afterwards Bryk published a very similar case, and came to the same conclusion as Falkson.

In an interesting lecture given by Mr. Frederick Eve at the College of Surgeons in 1882, and published in the *Brit. Med. Journ.* for 1883, an entirely new theory is advanced. Mr. Eve believes that so far from multilocular cysts having a dental origin, they are produced by an ingrowth of the epithelium of the gum.

"After repeated examinations, I have been able to observe, in several specimens, appearances distinctly indicating that they originate by an ingrowth of the epithelium of the gum. Sections of a tumour of the superior maxilla showed pear-shaped ingrowths of epithelium, connected with the epithelium of the gum by their narrow extremities. The

cells composing them had completely undergone degeneration except at the periphery, and two similar ingrowths were continuous with the mass of the tumour."

Many pathologists felt that it was difficult to ascribe this mode of origin to tumours, originating in the substance of the jaw, with the epithelium, of the gum quite intact over the tumour. Again, it is well known that epithelium will often begin to proliferate, when irritated by the proximity of chronic inflammation or of a new growth.

Within two years of the publication of Eve's researches, Malassez announced that he had found in maxillæ of adults, groups of epithelial cells in the neighbourhood of the teeth, *débris épithéliaux paradentaires* (*Archiv. de Physiol.*, 1885). This discovery confirmed strongly Eve's views regarding the epitheliomatous nature of these growths, and explained how such a tumour might originate at some little distance from the gum, and without involving it until late in the course of the disease.

Malassez considers that multilocular cystic tumours have a mode of origin similar to that of dental and dentigerous cysts, ascribing them to an overgrowth of the rudimentary paradental epithelium (see p. 172).

In conclusion, the consensus of opinion is certainly in favour of adopting Eve's views that multilocular cysts are neoplasms of an epitheliomatous nature. In what particular kind of epithelium the growth originates is by no means certain. On the whole, it is most probable that they originate in connection with the ingrowth of epithelium which forms the enamel organ. It is quite possible, therefore, that dental cysts, dentigerous cysts, and multilocular cysts have a similar mode of origin. The exciting cause of this activity of the epithelial structure is probably to be found in diseases of the teeth, especially caries.

The microscopic character of the solid material found more or less in all cases of multilocular cyst is well given in the following report by Mr. Eve upon a very well-marked recent specimen of the disease, contributed to the St. Bartholomew's Hospital Museum by Mr. Keetley: "The solid

portion of the tumour was composed of columns of cells and nuclei of the epithelial type, which, when cut transversely, presented the appearance of alveoli; similar small columns branched out from the side of the larger. The cells in the centre of the columns had in many places undergone a colloid change, and by the complete metamorphosis of the cells the cysts were formed. From the buccal mucous membrane covering the tumour in certain parts, club-shaped and branching cylinders extended down from the deep stratum of the epithelium, as in the ordinary formation of epithelial cancer." Mr. Eve has found precisely the same characters in twelve specimens of multilocular cystic tumour he has examined, one of the most marked being a tumour of the *upper* jaw removed by Mr. Liston in 1836, and referred to in his paper in the *Medico-Chirurgical Transactions*, vol. xx, the tumour being now in the College of Surgeons' Museum.

To show the identity of the foregoing with the tumours hitherto classed among the "cystic sarcomata," I may quote the description of the microscopic appearances of a tumour of the latter kind removed by myself, in 1871, from a patient aged twenty-two, whose portrait before and after the operation is given in Figs. 79 and 80: "The tumour was composed microscopically of straight or tortuous columns of epithelial cells, those forming the margin being elongated or cylindrical and radiating towards the centre. At the margin of the small ulcerated opening in the gum, papillary processes extended downwards from the deep stratum of the epithelium, and were continuous with the columns forming the tumour." The half of this tumour, deposited in the Museum of University College, is described in the valuable catalogue by the late Mr. Marcus Beck as a "gland-like tumour of bone," and its structure is identical with that of a tumour described by Mr. Wagstaffe in the *Pathological Society's Transactions*, vol. xxii. Mr. Wagstaffe found that the growth was composed of innumerable cysts and a solid matrix, through which a certain amount of bone was scattered; that the cysts were lined by a layer of large globular epithelium; that into the interior of the larger cysts other smaller cysts projected, these

endogenous cysts taking their origin in the epithelial lining, and not in the matrix of the growth. Other cysts were also freely scattered throughout the structure, but the endogenous formations were so marked that they could be discovered as little balls by the naked eye, and removed for examination by the point of a needle. The solid structure consisted of a very peculiar arrangement of what appeared to be acini or

FIG. 79.

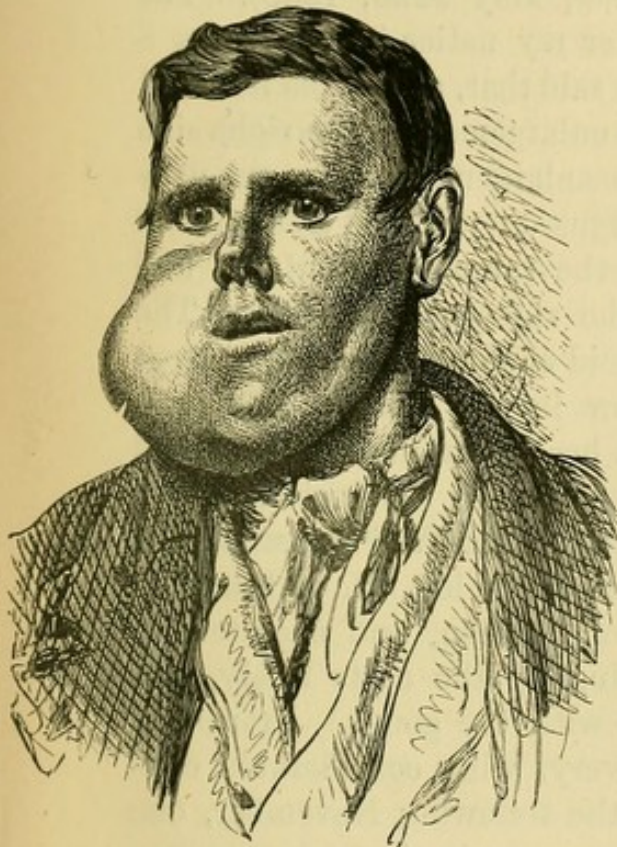
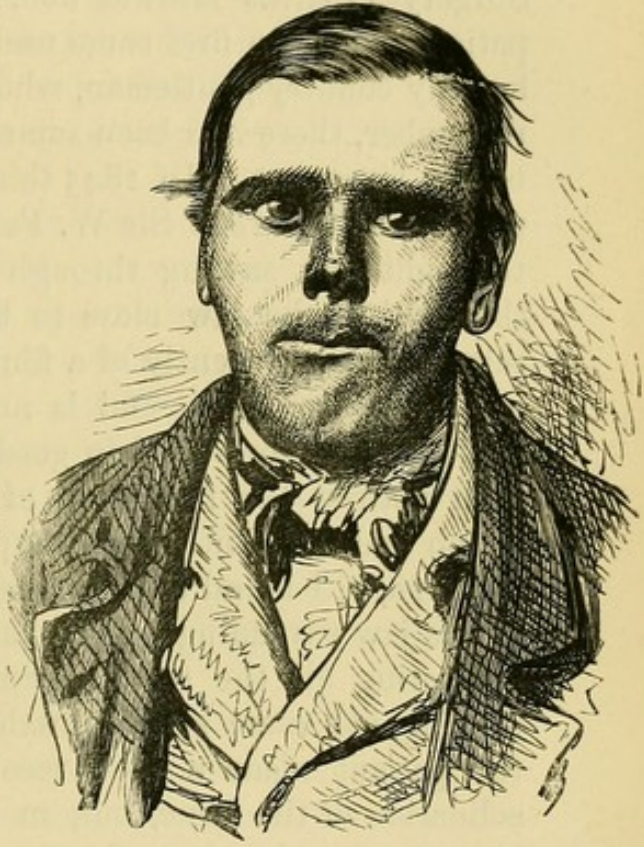


FIG. 80.



cylinders of closely-packed cells, supported by a fibro-nucleated matrix. These acini, or rods, in many places gave the appearance of tubes from the arrangement of their component cells, which resembled very curiously that of columnar epithelium, or of the epithelium of gland follicles. The cut ends, however, showed no central canal. The constituents of these rods were nuclei embedded in plastic matter, and these separated by manipulation into small tailed or so-called spindle cells, of similar size and character to the corpuscles of an ordinary sarcoma.

The contents of these cysts vary in consistency and colour; in some cases being clear and limpid, in others almost gelatinous and of a dark colour.

My attention was first directed to the fact that multilocular cystic disease is not always a simple local ailment, by the case of a patient who was able to give me a "Thirty-five years history of a maxillary tumour," which I communicated in 1880 to the Association of Surgeons practising Dental Surgery (*British Medical Journal*, May 22nd, 1880). The patient, when he first came under my notice in 1877, was a healthy country gentleman, who said that, as long as he could remember, there had been some enlargement of the right side of the lower jaw. In 1845 this enlargement increased very rapidly, and in 1847 Sir W. Fergusson removed a tumour of the right side, sawing through the ramus horizontally, and the body of the jaw close to the right canine tooth. The tumour was apparently of a fibroid character, having a large cyst developed in it, and is now in the Museum of King's College. He continued in good health for fifteen years, and then noticed the formation of a cyst in the incisor region, which had frequently been tapped by Sir W. Fergusson. In July, 1877, I found cystic disease of the left side of the body of the jaw extending to the molar region, and operated, by extracting all the teeth, opening up the cysts freely, and clearing out some solid growth with the gouge. From this the patient made a good recovery, with considerable consolidation of the bone, but, in the following November, one cyst was found to have developed anew in the incisor region, and this was treated in a similar manner. A year later a fresh development of cysts had taken place and the operation was repeated with a good result, so that in February, 1879, the jaw was completely consolidated, and the patient was advised to have some artificial teeth fitted. In November, 1879, the patient reappeared with a large solid tumour, involving the left side of the body of the jaw, which, noticed first in June, had grown rapidly of late, and now involved the skin for an area of a square inch. On December 2nd I removed the tumour by sawing through the bone immediately

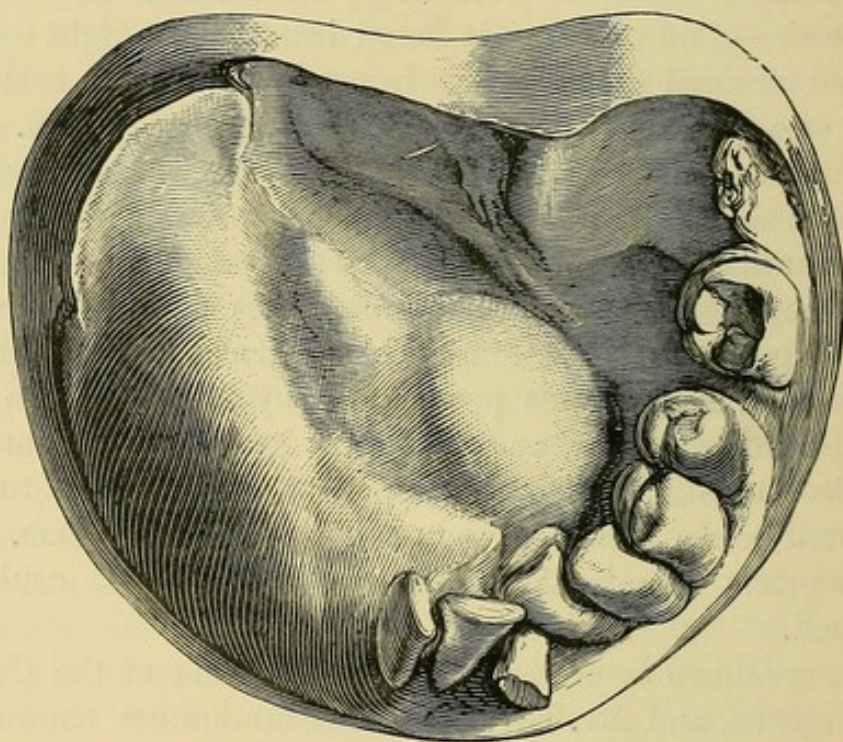
in front of the left masseter, and also removed a piece of infiltrated skin from the left of the median line. The wound was brought together with harelip pins and sutures, and only one artery (facial) was ligatured. The patient made a good recovery, took food with a spoon, and was able to talk intelligibly after the first week, although deprived now of the entire body of the jaw. The lower end of the wound being left open afforded a thorough drain for discharge. The patient returned early in February, when the skin near the wound was found to be increasingly infiltrated, and a tumour of the size of an orange was found beneath the right deltoid. He had strained the right arm in getting into a hip bath, but was quite clear that the humerus had not been struck. The tumour was painful, but the bone was sound, the head moving with the shaft. A week later the patient was found to have a tumour in the pelvis, pressing upon the rectum, and springing from the interior of the right innominate bone. From this time he gradually lost strength, and died at the end of March. The second tumour was pronounced by Mr. Doran to be a round-celled sarcoma, and the same growth was found in the piece of skin which was removed. The earlier tumour appeared to be a fibroid or a spindle-celled sarcoma. No post-mortem examination of the internal growths could be obtained.

The specimen is preserved in the Museum of the College of Surgeons, and Mr. Eve's further examination shows that the upper portion of the tumour contains isolated masses, composed of tortuous closely-crowded columns of small epithelial cells.

The second case bearing upon the same question was in a woman of forty-four, who was admitted into University College Hospital, on November 3rd, 1875, with the following history: About nine years before, the patient first noticed a lump of the size of a pea beneath the tongue, on the right side, which gave her some pain, and for which a tooth was extracted. From that time she had a succession of abscesses (?) in the lower jaw, some of which discharged in the mouth, and one externally, and for which she had had several

teeth extracted. Dr. Parsons, of Dover, had sent her to me three years before, and I then recommended her to come into the hospital; but she declined, and went on with a steadily increasing tumour of the lower jaw on the right side. About nine months before admission the tumour seems to have begun to increase with some rapidity, and within the last two months the following characteristic event happened. While eating, the patient felt a sudden crack in the lower jaw, and this

FIG. 81.



occurred twice in the same week; and upon each occasion she felt great pain in the floor of the mouth and upon moving the tongue. Upon admission there was really very little to be seen externally, and a photograph taken at the time shows that, excepting a very small projection beneath the skin in front of the angle of the jaw, there was nothing to call attention to the patient's face. On looking into the mouth, however, the tumour was at once obvious, and is seen in a cast taken from the jaw at that time (Fig. 81). The right side of the lower jaw is seen to be greatly expanded from immediately in front of the ramus to beyond the median line, the tumour

measuring two inches across at the broadest part, and reaching under the tongue. Its surface was lobulated and rounded, firm and osseous in the greater part, but yielding distinctly on pressure in two or three places. The mucous membrane was entire over the tumour, except at one point where there was an opening, from which a discharge constantly exuded. The incisor teeth of the right side were displaced over to the opposite side, and were loose. The central incisor of the left side was displaced completely in front of the other teeth. The left canine and bicuspid were firmly fixed. Notwithstanding the size of the tumour, the outline of the lower border of the jaw was scarcely interfered with, the disease being mainly confined to the alveolar portion of the bone; and I, therefore, decided to operate from within the mouth, so as to avoid, if possible, all external scar.

On November 10th the patient was put under chloroform, and, a gag having been introduced on the left side, I first extracted the four incisors, and then made a free incision with a stout scalpel along the upper surface of the tumour, cutting easily through the thin bone and thick membrane forming its upper wall. A quantity of dark-coloured cystic fluid at once escaped, and I then cleared out the semi-solid contents with the finger and gouge. The finger introduced into the cavity passed completely under the canine and bicuspid teeth of the opposite side without disturbing them. I next cut away a portion of the cyst-wall with scissors, and crushed together the remainder, as far as I could, with my fingers and thumb. The actual cautery was applied to one spouting vessel in the margin of the alveolus, and the cavity was stuffed with lint dipped in a solution of chloride of zinc (twenty grains to the ounce).

The patient had very little constitutional disturbance; the plugs were gradually removed from the cavity of the jaw, which was carefully syringed out frequently with Condyl's fluid, and soon began to granulate and fill up. She was discharged a month after the operation, when the two plates of the lower jaw had come together, and the cavity was filled up almost completely by granulation-tissue, there being only

a shallow cavity half an inch long still to be filled up midway between the angle and the symphysis.

This patient again presented herself in October, 1878, nearly three years after the first operation, with a recurrence of the cysts, which were treated again by gouging and crushing in. In August, 1882, she again appeared with a formidable tumour of the lower jaw, which had already sprouted through the chin at more than one point (Fig. 82). There

FIG. 82.



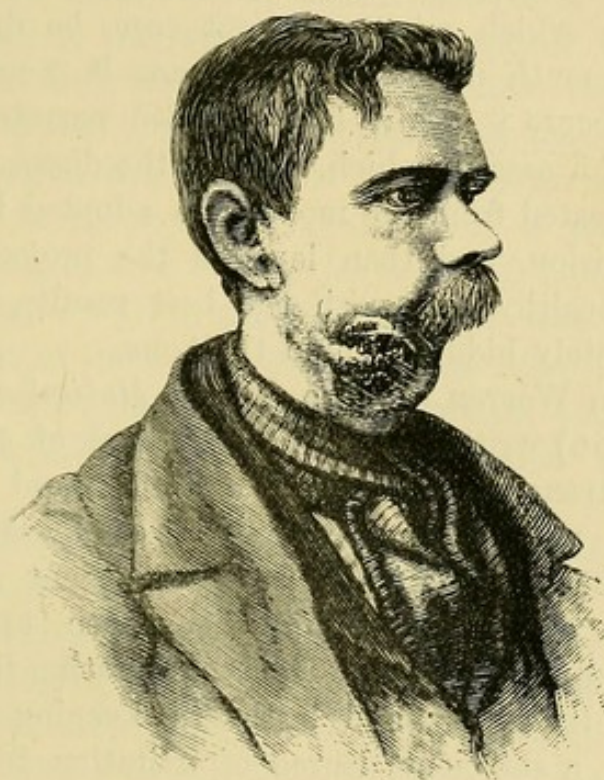
could be no question now of the necessity for excising the portion of jaw involved, and this I accordingly did, removing from an inch in front of the angle on the left side to the right temporo-maxillary articulation. The patient made a good recovery, and has remained well.

As a further contribution to this subject I may refer again to the case of "cystic sarcoma" described at p. 200, and illustrated by Figs. 79 and 80, where I left *in situ* the coronoid process and condyle with part of the posterior border of the lower jaw, in June, 1872. In October, 1883, this patient reappeared in the condition shown in Fig. 83, with a typical

epithelial ulcer of the skin of the cheek. On proceeding to cut this away freely, I found that it was attached to the remains of the lower jaw, which I was obliged to remove in order to get rid of the whole of the growth. One-half of this secondary growth is in the Museum of the College of Surgeons, and its microscopic characters correspond precisely to those of the former growth, p. 200.

There can, then, I think, be no doubt that under the term

FIG. 83.



“multilocular cystic epithelial tumour,” as proposed by Mr. Eve, we may include the old multilocular cysts and cystic sarcomata, both having a distinct tendency to be reproduced locally, and in certain cases to become disseminated.

Treatment.—Mr. Butcher, of Dublin, for many years treated cases of multilocular cyst of the lower jaw through the mouth, by dividing the mucous membrane over the cyst freely, and then with gouge and bone-forceps removing the expanded external plate of the bone, with the contents and lining membrane of the cyst. In this operation the teeth are interfered with as little as possible, and appear to

remain firm. Granulations rapidly spring up from the denuded bone, and fill the wound made in the mouth; the cheek resumes its ordinary appearance, and no deformity or scar is left. In his work on "Operative and Conservative Surgery," Mr. Butcher narrates three cases treated in this manner, and remarks, that "the proceeding according to this plan is troublesome and difficult, but its value to the patient in having no deformity left is priceless." A valuable caution is here given respecting the facial artery, which might, without care, be divided from within the mouth in a position where it would be very difficult to secure it. Mr. Butcher also narrates and gives a drawing of a case in which, finding the disease too extensive to be treated from the mouth, he adopted Dupuytren's external incision, and then levelled the projection to the line of the healthy bone with the best results, the incision being completely hidden behind the bone.

Dr. Mason Warren has also (*Boston Medical and Surgical Journal*, 1866) written upon the treatment of cysts of the jaws, and strongly recommends a milder and even more conservative practice than that followed by Mr. Butcher, which he thus summarizes: "The treatment consisted in the puncture of the sac within the mouth, evacuating its contents, and at the same time obliterating its cavity by crushing in its walls; and lastly, in keeping up, by injections, &c., a sufficient degree of irritation to favour the deposition of new bone."

I have now treated a considerable number of simple and multilocular cysts by Mr. Butcher's method, and, as has been noted, with recurrence in at least two of the latter. Mr. Butcher does not appear to have met with further trouble in his cases, and this may depend upon his "carrying out the gouging fearlessly and far wide of the disease." I should in future be guided by the age of the patient, and the amount of solid material found in the cysts. In young persons with cysts having fluid contents and little growth in the bone, I should be still inclined to adopt palliative measures and to gouge very freely, carefully watching the

case with a view to a more radical proceeding, should further development take place. In cases of much solid deposit in connection with multilocular cysts, and still more in cases of solid tumour with one or more large cysts, there should, I think, be no doubt as to the removal of one-half or more of the lower jaw, or of any portion of the upper jaw involved.

In his well-known essay on "Diseases of the Jaw" (Calcutta, 1844) Mr. O'Shaughnessy narrates a case of large cystic disease of the jaw which would appear to have been originally a multilocular cyst, in which the septa had undergone almost complete absorption, so that "the tumour after maceration was found to be a hollow shell of bone, containing in its centre a quantity of a gelatinous and fluid substance, and a few particles of bone like pieces of honeycomb. The coronoid process was hollowed out like the rest of the bone, and so thick that it must have completely filled the temporal fossa, which accounts for the difficulty experienced in trying to divide the temporal muscle."

This difficulty of clearing the coronoid process has been noticed also in cases where the bone has been expanded by a solid growth within it, or is wedged in by a portion of tumour springing from the ramus. Dr. Robert Adams narrates (*Dublin Hospital Gazette*, April 15th, 1857) a case of the former kind, and Mr. Cusack (*Dublin Hospital Reports*, vol. iv) two cases of the latter, in all of which the difficulty was overcome by sawing through the ramus of the jaw and subsequently removing the coronoid process and condyle. The possible occurrence of this difficulty is to be borne in mind in cases of cystic growth requiring disarticulation; and I experienced it in the case of large "cystic-sarcoma," already referred to.

The difficulty is best got over by the division of the coronoid process with the bone-forceps, and the piece thus cut off should afterwards be dissected out.

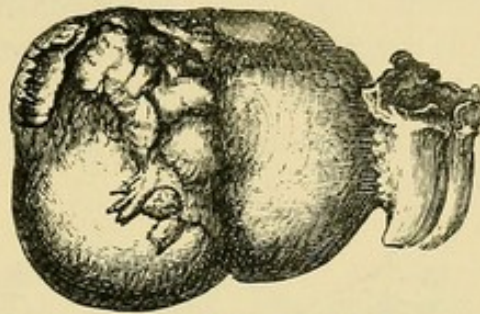
CHAPTER XIII.

ODONTOMATA AND CERTAIN IRREGULARITIES OF THE TEETH.

THE meaning of the term odontoma in its broadest *pathological* sense has already been discussed in the Chapter on "Cysts of the Jaws," and it was there pointed out that, for the present at any rate, it would be more convenient to restrict the term to its generally accepted *clinical* signification—*i.e.*, a tumour composed of enamel or dentine or cementum, or of a combination in varying proportions of any of these three elements. It seems most probable that, in the human subject, all odontomata originate in abnormal development of the *dental papilla*. In the lower animals, however, this is not the case. Bland Sutton has pointed out that tumours composed of cementum only, *cementomata* as they are called, are very common in lower animals, especially in the Ungulata; and this cementum is developed from the wall of the *dental follicle*, not from the *dental papilla*. The same authority claims that one case, at least, from the human subject belongs to the category of follicular cementomata. This case is described by Dr. Forget in his classical work on "Dental Anomalies." It occurred in the practice of M. Maisonneuve, and in the person of a man aged forty. The tumour occupied the left side of the lower jaw, causing both its surfaces to project, but especially the outer. At the smaller end of the tumour was a decayed molar tooth, and upon extracting this the tumour came away with it. The growth, which was larger than a pigeon's egg, was attached to the tooth by a kind of pedicle, a section showing a line of separation between it and the root of the tooth. Under the microscope the

specimen was seen to contain no dentine, but to consist exclusively of cementum (Fig. 84). On a careful re-examination of the tumour, Magitôt found some dentine in the central part of the mass forming the boundary of a large cavity. It is doubtful, therefore, whether to look upon this case as a pure follicular cementoma with remains of dentine and pulp cavity, or as a mixed odontoma consisting of cementum and dentine.

FIG. 84.



Except in the case of this doubtful specimen we cannot do better than adopt the classification suggested by Bland Sutton for hard odontomata, viz.:

A. Aberrations of the dental papilla.

Radicular odontomata.

a. Dentomata.

b. Osteo-dentomata.

c. Cementomata.

B. Aberrations of the whole tooth-germs—*i.e.*, dental papilla, dental follicle, and enamel organ.

Composite odontomata.

C. Anomalous odontomata.

A. *Aberrations of the Dental Papilla.*—The term *radicular odontoma* is applied by Bland Sutton to “odontomata which arise after the crown of the tooth has been completed, and whilst the roots are in the process of formation. As the crown of the tooth, when once formed, is unalterable, it naturally follows that should the root develop an odontoma, enamel cannot enter into its composition, which, for the most part, would consist of dentine and osteo-dentine in varying proportions, these two tissues being the result of

the activity of the papilla. When such a tumour consists mainly or entirely of dentine it may be termed a *radicular dentoma*. If osteo-dentine preponderates, then the tumour may be called a *radicular osteo-dentoma*; or, if cementum, then it is a *radicular cementoma*."

A remarkable specimen of a radicular odontoma in the Museum of the College of Surgeons of England has been especially investigated by Mr. Salter (*Guy's Hospital*

FIG. 85.

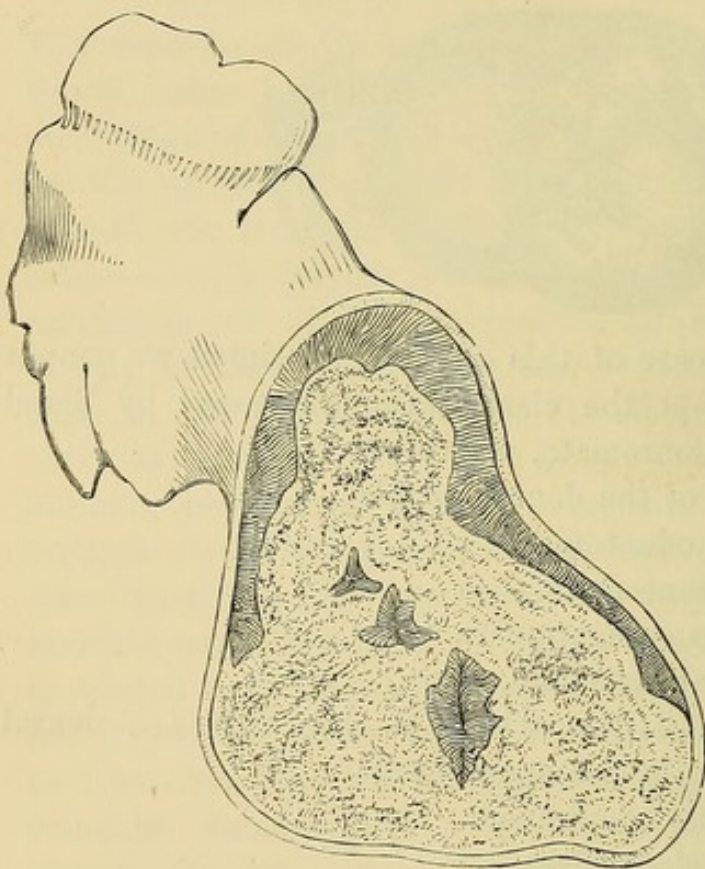
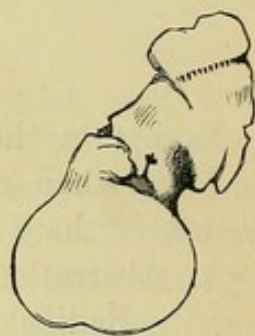


FIG. 86.



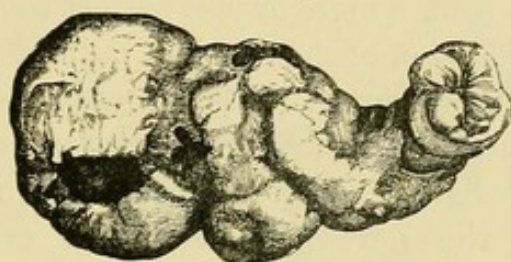
Reports, 1869), who believes that the outgrowth is due to "hypertrophy and dilatation of a fang, and not, as was formerly supposed, to hypertrophy of the cementum. Fig. 85, from Mr. Salter's paper, illustrates the structure of the tumour, and Fig. 86 shows the relation of the growth to the tooth. The outer layer is composed of cementum or tooth bone, and within this is a layer of true dentine, which is wanting below; and within this again is the "nucleus" of calcified tooth-pulp. This last is "composed

of a confused mass of bone-structure and dentine-structure, arranged around and separating an elaborate vascular network of the same character as that of the dentinal pulp."

Almost synchronously with, but independently of, Salter, Professors Heider and Wedl (*Atlas zur Pathologie der Zähne*) described a tooth-tumour resembling in many respects that at the College of Surgeons.

In April, 1863, Mr. Tomes exhibited to the Odontological Society an extraordinary specimen of so-called exostosis, shown in the illustration (Fig. 87), which I have been permitted to borrow from the *Transactions of the Odontological Society* (vol. iii). It is really a radicular odontoma, and is especially interesting, inasmuch as it is one of the few

FIG. 87.



specimens of odontoma removed from the upper jaw in the human subject. The molar tooth, to which it is attached, was removed by Mr. Hare, of Limerick, from the upper jaw of a man, aged forty-one, who had long suffered pain in the jaw, from which a fistulous passage led through the cheek. The growth is more or less hollowed out, and on this account it has been suggested that it may possibly be an instance of calcified dental cyst. The specimen has, however, recently undergone careful microscopic examination by Mr. Charles Tomes, who found that it closely resembled Forget's specimen already described (Fig. 84), of which a microscopic section is given by Broca. Mr. C. Tomes brought the preparation before the Odontological Society in January, 1872, and has shown that the outgrowth is not connected with the fangs of the tooth, but had sprung from the dentinal pulp. This latter he believes to have undergone partial destruction before becoming calcified, and hence the cavity formed in

the tumour. (*Transactions of the Odontological Society of Great Britain*, January, 1872.) Whatever its nature, it must, from its size, have either invaded or obliterated the antrum.

A case of radicular odontoma has more recently been described by Windle and Humphrey in the *Journal of Anatomy and Physiology* (vol. xxi). It occurred in a man aged twenty-five. He had a swelling on the right side of the lower jaw, in the situation of the second molar tooth. Pain became very severe, and then an abscess burst, and pus was escaping from the sinus for some months. Finally, a hard mass became free and escaped into his mouth. The odontoma seemed to be composed chiefly of cementum, but this was not certain, as sections of the tumour could not be obtained.

Another form of tumour connected with a tooth consists in an outgrowth from a more or less perfect tooth, depending upon some modification of the dentinal pulp, after the formation of the dentinal cap. These growths belong to the *Odontomes coronaires* of Broca, and have been described as *warty teeth* by Salter. They occur before the fang is formed, during the development of the crown, so that cementum cannot enter into their composition. The tumour is situated at the neck of the tooth, and is formed by an outgrowth of the pulp, covered by dentine and enamel. If the tumour be large and circumscribed it may prevent the eruption of the tooth, but if the growth be diffused around the neck of the tooth, the latter may be erupted, and is then known as a "warty tooth."

B. *Aberrations of the whole tooth-germ—i.e.*, dental papilla, dental follicle, and enamel organ.

According to Bland Sutton, "composite odontomata is a convenient term to apply to those hard tooth tumours which bear little or no resemblance in shape to teeth, but occur in the jaws, and consist of a disordered conglomeration of enamel, dentine, and cementum. Such odontomata may be considered as arising from an abnormal growth of all the elements of a tooth-germ—enamel organ, papilla, and follicular wall."

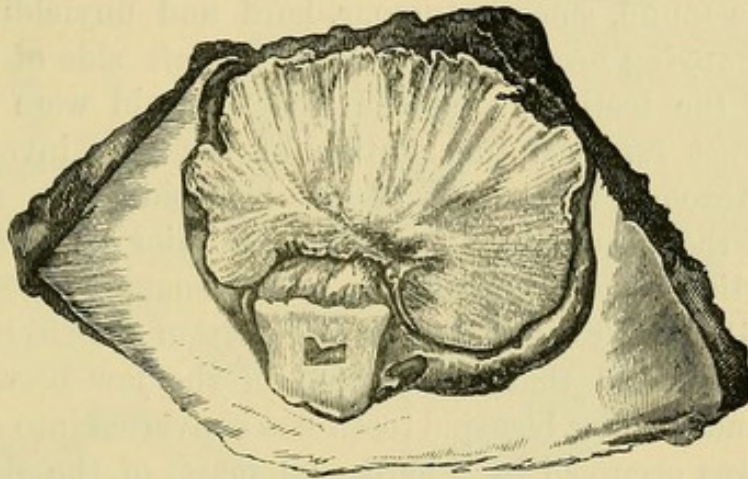
I have been able to collect only eleven cases of composite

odontomata, and all of them, with one exception, occurred in the lower jaw.

The first case was communicated to the Faculty of Medicine of Paris in 1809 by M. Oudet. The patient, a man, aged twenty-five, had on the right side of the lower jaw a mass occupying the position of the premolar teeth, which, on removal, proved to be composed of dentine and enamel. A similar mass on the left side was not removed.

The second case occurred some years back, in the practice of Sir William Fergusson, by whom the tumour was removed with a portion of the jaw, and is described by Mr. Tomes

FIG. 88.



(“Dental Surgery”), from whose work a drawing of a section of the tumour is taken (Fig. 88). “The second molar of the lower jaw was represented by an irregularly flattened mass, composed of enamel, dentine, and bone derived from calcification of remnants of the dentine pulp, thrown together without any definite arrangement, by which the wisdom tooth was held down. The dental mass, when removed from its receptacle in the bone, presented no resemblance to a tooth. Little beads of enamel here and there projected from the surface, which was generally rough and irregular. The naked-eye appearance of the section is accurately given in the woodcut, the radiate character in which shows the arrangement of the component tissues, which, by the aid of the microscope, are seen at places to alternate. The alternation is mainly effected by the dentine and bony tissue,

and these, indeed, form the great bulk of the mass. The appearances presented, prior to the operation, consisted in enlargement of the jaw posterior to the first permanent molar tooth, with a hard, brown-looking body projecting but slightly from the surface of the gum. This projecting portion was, in fact, the upper surface of the aberrant tooth; and the nodules of enamel were, for the most part, situated in this part of the mass."

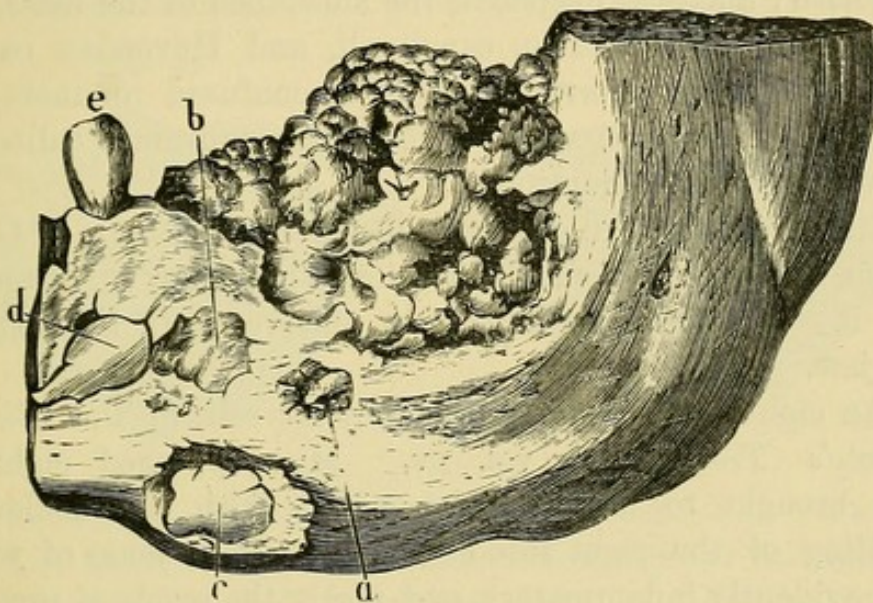
The third case occurred to Dr. Forget (*op. cit.*), in the person of a young man, aged twenty, who presented himself in 1855 with a disease of the lower jaw, from which he had suffered since he was five years old. Upon looking into the mouth, a round, smooth tumour, hard and unyielding, was seen occupying nearly the whole of the left side of the jaw. None of the teeth beyond the first bicuspid were present. Dr. Forget removed the portion of the jaw involved by sawing through it in front of the bicuspid tooth, and also through the ramus at the level of the inferior dental foramen. The portion removed is seen in the accompanying drawing (Fig. 88). An examination of the portion which had been removed showed that the portion of the jaw between the ramus and the first bicuspid tooth was converted into a cavity, which was occupied by a hard oval mass, of the size of an egg, having an uneven surface covered here and there with minute tubercles, which were invested by a layer of enamel, penetrating into the substance of the bone, and easily recognizable by its shining appearance and peculiar colour. A section of the tumour showed that it consisted of a compact tissue of the consistence of ivory, of a greyish-white colour, in the interior of which it was possible to perceive, with the naked eye, a kind of regular arrangement of the elements which entered into its composition. Between the tumour and the osseous cyst was a thick membrane, apparently of a fibro-cellular structure. At the anterior extremity of the base of the tumour was a depression in which the crown of an inverted molar tooth was wedged in between it and the maxilla. This tooth is seen in Fig. 89, *c*, where a portion of bone has been cut away; *a* and *b* mark portions of the

tumour projecting through the jaw, and *d* is the second bicuspid tooth lying below the first, *e*.

The microscopic examination of the tumour showed it to be composed principally of dentine, with enamel on the surface and dipping into the crevices, at the bottom of which, as well as in other parts, portions of cementum were found. Dr. Forget regards the case as one of fusion and hypertrophy of the last two molars.

The fourth case of the kind was brought under the notice of the Odontological Society of Great Britain, in December,

FIG. 89.



1862, by the late Mr. W. A. Harrison, F.R.C.S. The specimen closely resembled those already described, and came from the left side of the lower jaw of a lunatic, where it occupied the space between the incisor and molar teeth. It came away spontaneously, leaving a long deep groove, large enough to receive the last joint of the thumb, which soon granulated and contracted. The specimen is in the Museum of the Dental Hospital, Leicester Square.

The fifth case is given in Heider and Wedl's *Atlas zur Pathologie der Zähne*, and closely resembles Mr. Tomes' case, the second molar tooth of the right side being developed into a large irregular mass, and holding down the wisdom tooth. It was easily removed.

Mr. Annandale has reported (*Edinburgh Medical Journal*, Jan. 1873) a sixth case occurring in the lower jaw of a young woman, aged seventeen, who had never had any molar teeth on the left side. A nodulated mass, which somewhat resembled a piece of necrosed bone, projected above the gum, and was firmly fixed. Mr. Annandale dislodged the growth and removed it through the mouth. It measured $1\frac{1}{2}$ by $1\frac{1}{4}$ inches, and weighed 300 grains, and on section showed "that a cap of enamel, varying in thickness, was arranged over a portion of the irregular surface of the mass. Beneath this, well-formed dentine, forming a considerable thickness, was met with; and still deeper in the substance of the mass, true bone, containing lacunæ, canaliculi, and Haversian canals, was seen to be intermingled in a confused manner with portions of dentine, so as to form the substance called by histologists "osteo-dentine."

The seventh case occurred in the practice of Dr. Goodwillie, of New York, and is mentioned in Agnew's "Surgery," vol. ii. It appears to have been removed with the angle of the jaw.

An eighth case was recorded by myself in the *Clinical Society's Transactions*, vol. xv. Miss C., aged eighteen, was brought to me in July, 1881, with a considerable swelling of the right side of the lower jaw, some of which was evidently inflammatory, and partly the result of previous treatment; but there was, I thought, sufficient evidence of expansion of the jaw to warrant the opinion that a tumour was present, and I therefore recommended the removal of a portion of the jaw. Suppuration was then present, and with the finger a rough surface of apparently exposed bone could be felt, but this I regarded as the result of inflammatory action excited by the injudicious irritation of a periosteal growth, since partial necrosis of a jaw involved by cartilaginous or malignant growths, which have been irritated by exploratory measures, is in my experience by no means uncommon. The patient had the advantage of the opinion of Sir James Paget, who was not perfectly satisfied as to the existence of a tumour, and expressed a hope that

the case might prove to be one of necrosis. Under these circumstances the operation was postponed.

On my return to town in September, I found the patient improved in health and the swelling diminished by the subsidence of the inflammation, but a considerable enlargement of the lower jaw still present, with a sinus opening externally. From the mouth a white mass was visible, which, appearing among granulations, looked like necrosis, and I agreed that an attempt should be made to remove this, although I could not think it accounted for the expansion of the jaw. On Sept. 8th, with the assistance of Dr. Snow, the patient was put under chloroform, and I proceeded to examine the mouth

FIG. 90.

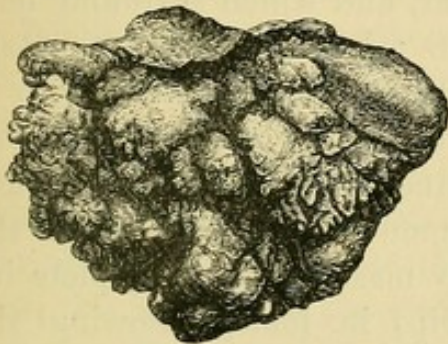
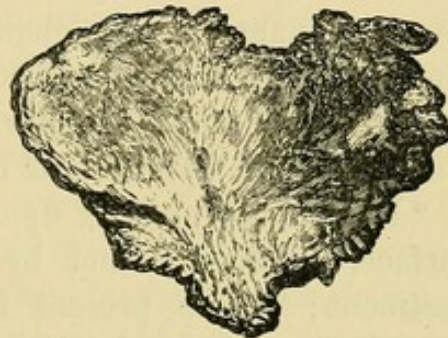


FIG. 91.



with my finger. I soon found that the white mass was not bone but tooth, and yet was unable to make out its outline. I was unable to make any impression with a chisel or gouge, but at last, with an elevator, succeeded in lifting out of its bed a mass of dental structures, forming the odontoma shown in Figs. 90 and 91.

The mass measured $1\frac{1}{2}$ inches antero-posteriorly, 1 inch transversely, and $1\frac{1}{4}$ inches from above downwards. It weighed 315 grains = 5v gr. xv.

A section of the odontoma has been made, and it has been submitted to Mr. Charles Tomes, who has kindly furnished the following report:

"The whole surface of the odontoma is nodulated and roughened by stalactitic excrescences, and there is at no point any form recalling the character of a tooth crown.

"The surface of a section presents a complicated marbled

pattern, due to the admixture of several dental tissues, and it bears a general resemblance to that form of dentine known as 'plici-dentine,' or 'labyrintho-dentine.' On the whole the mass is of tolerably uniform structure throughout, though there is an area of somewhat simpler structure in its upper and central portion, from which folds of dentine appear to radiate. So far as it goes, this would seem to point to the whole mass being the product of a single tooth-germ rather than of several fused together, a matter which was left in some doubt by the absence of an accurate history of the case.

"The excrescences of the surface, as well as the greater part of the interior, are made up of folds of dentine, in which dentinal tubes are very abundant, and which surround flattened remnants of pulp-chambers; between and intimately blended with this comparatively well-formed dentine, is a more coarsely calcified material, containing numerous lacunæ, and permeated by vascular channels—in fact, osteo-dentine.

"Enamel is present upon some of the nodules of the surface, but it does not by any means form a complete investment; where present it dips in folds, following the convolutions of the dentine, and it is to be met with in the very centre of the mass, though not very abundantly. It is nowhere well formed, being brownish and opaque.

"This odontoma is the product of the formative dentine pulp of a tooth (or teeth) which has, in place of remaining simple, budded out innumerable processes on all sides, and finally has calcified; its enamel pulp has in parts followed the complexities of its surface, and in parts failed to do so, or, at all events, has failed to perpetuate itself by calcification."

A case very similar to the preceding was recorded by Dr. Arkovy, of Buda Pesth. The tenth case is especially interesting because it occurred in the upper jaw. It occurred in a man, aged twenty-one, and is fully described by Mr. Jordan Lloyd in the *Transactions of the Odontological Society*, 1888. An eleventh case occurring in the lower jaw has recently been recorded by Dr. Swann (*Lancet*, Dec. 9th, 1893).

All these specimens were met with in young adults, and the majority were extracted from the jaw by the surgeon, but in Mr. Harrison's case the mass came away spontaneously; and in Mr. Tomes's and M. Forget's cases a considerable portion of the lower jaw being removed by such experienced surgeons as Sir William Fergusson and M. Maisonneuve. In my own case I must confess that I did not appreciate at first the nature of the tumour, and recommended removal of a portion of the jaw, and it was only during a subsequent operation undertaken for supposed necrosis that the true nature of the case became apparent.

C. *Anomalous Odontomata*.—Under this heading, Bland Sutton places a few remarkable and interesting cases, and I cannot do better than describe them in his own words:

"A female, aged twenty-seven, applied for advice in consequence of an attack of inflammation of the right upper jaw, due, as she supposed, to the presence of the roots of a temporary molar. The temporary teeth, so far as was known, presented nothing unusual, and were shed and replaced by the permanent set, except that, on the right side of the upper jaw, the first molar, the two bicuspid, and canine, failed to appear. The spot where these teeth should have been became, at the age of twelve, the seat of hard painless enlargement. When the patient applied to Mr. Tellander there was a free discharge of pus from this spot; some stumps were removed, and carious bone detected. Subsequent examination showed that enclosed within this carious bone was a cluster of minute teeth. There were nine single teeth, each one perfect in itself, having a conical root with a conical crown tipped with enamel; also six masses built up of adherent single teeth. The denticles presented the usual characters of supernumerary teeth. About a year afterwards a tooth was found making its appearance in the spot from which the host of teeth was removed.

"A similar case has been recorded by Sir John Tomes, the details of which were communicated to him by Mr. Mathias, whilst on medical service in India. A Hindoo, aged twenty, had a large tumour which occupied the front

part of the mouth, and pressed the upper lip against the nose, thus preventing the closure of the mouth. After a few days of preliminary treatment, a hard body was detected by a probe beneath the surface of the tumour; this eventually turned out to be a number of ill-formed teeth united. Further search was instituted, until at last fifteen masses of supernumerary teeth and bone were removed. The soft parts rapidly healed, the deformity disappeared; the only peculiarity noticeable was the absence of the central and lateral incisors.

"A third example of this remarkable condition has been recorded by Mr. Windle and Professor Humphrey. The case occurred in the practice of Mr. Sims, at the Dental Hospital, Birmingham. The tumour was found in the mouth of a boy aged ten years. It was found that neither the deciduous nor permanent right lateral incisor or canine had erupted. The space thus unoccupied was filled by a tumour with dense unyielding walls, which occasioned no discomfort. On opening this cyst, forty small denticles of curious and irregular forms were removed from the interior. The largest possessed fourteen cusps. Many are caniniform, with fairly well-formed crowns and roots, the former being covered with enamel. Some resembled supernumerary teeth, while others consisted of several small denticles cemented together."

Symptoms.—The course of the disease may be conveniently divided into three stages. In the first stage there may be no symptom or sign of any abnormal condition, but there is sometimes a sense of uneasiness in the jaws or neuralgic pains. In the second stage a tumour is found, generally encroaching upon the alveolar border. It increases in size very slowly, and after some time the bone may be so much expanded that egg-shell crackling may be obtained. The third stage is marked by the onset of inflammatory symptoms, and finally an abscess forms which finds exit, if not opened by the surgeon, by one or more sinuses. The odontoma may become quite loose and finally drop out (see p. 217).

Diagnosis and Treatment.—The *diagnosis* of these growths

is by no means easy. In fact, in all the cases hitherto described the diagnosis was not made until an exploratory operation revealed the presence of the odontoma, or until it separated spontaneously from the jaw.

The *treatment* is clearly enough indicated if the diagnosis has been made. Every effort should be made to extract an odontoma from the jaw without removing any portion of the jaw itself. In the case recorded by Mr. Harrison, the tumour was enucleated spontaneously, in seven cases it was removed without difficulty, and in three other cases its removal was readily effected after the portion of jaw that surrounded it had been excised.

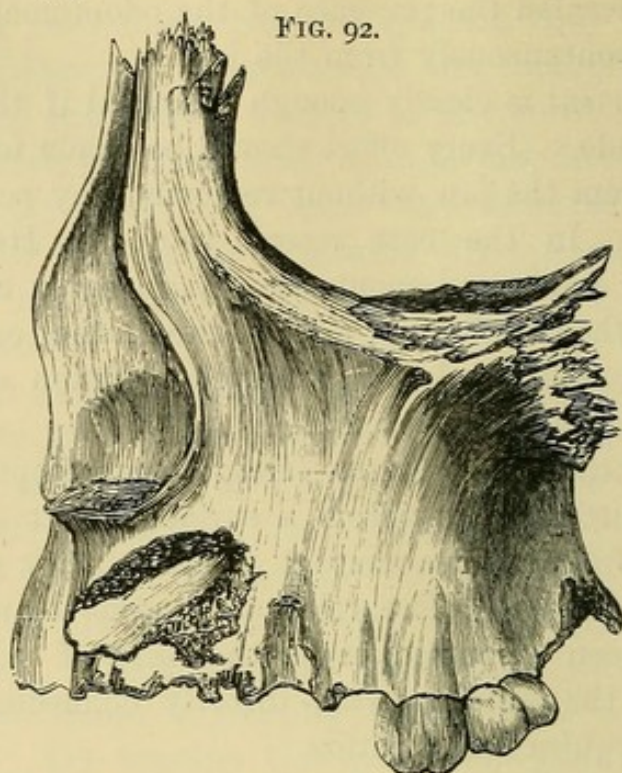
Irregularities of the Teeth.—Irregular development of the teeth is of little interest from a surgical point of view, except when, from their abnormal positions, they give rise to tumours of the jaw. The relation of cysts to undeveloped teeth has been discussed under the head of "Dentigerous Cysts," but the solid growths directly connected with the teeth also require investigation.

The irregularities of the teeth which are fully cut come into the province of the dental surgeon, and in Mr. Tomes's valuable work on Dental Surgery, numerous drawings are given of the abnormal positions in which various teeth have appeared. It is the uncut teeth, however, which are of interest surgically, and these may be divided into two classes. In the first, the tooth which has deviated from its normal position is still contained within the alveolus, where by its presence it may give rise to a more or less distinct tumour. Of this Fig. 92 gives an example from the work of Dr. Forget, on "Dental Anomalies," for permission to use which I am indebted to Mr. R. T. Hulme, the translator of Dr. Forget's papers in the *Dental Review* of 1860. In the second class of cases the misplaced tooth is situated in a part of the jaw more or less distant from the alveolus, and of this Fig. 93 presents an example, the canine tooth being placed horizontally in the floor of the nasal fossa, in the interior of which it formed a considerable projection.

The molar teeth of the upper jaw, and particularly the

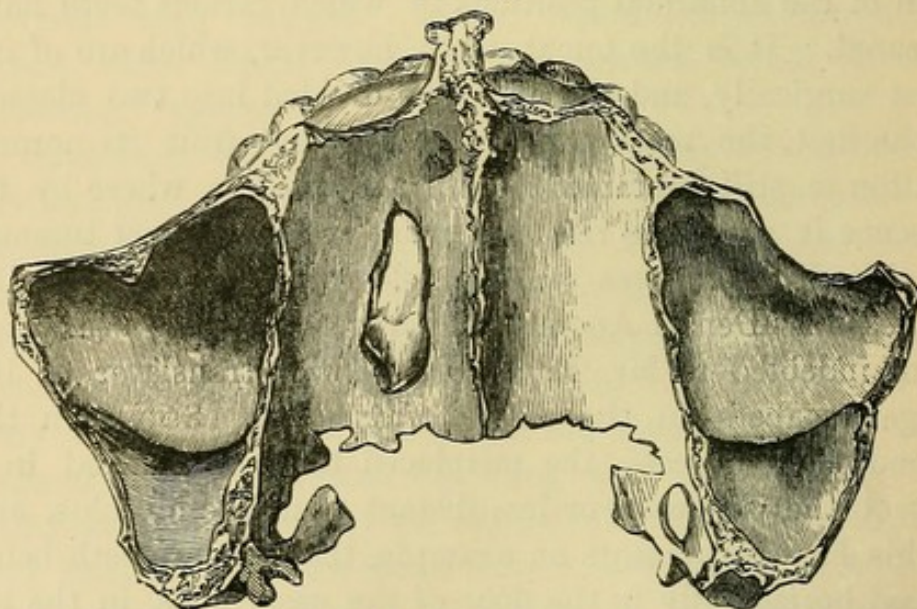
wisdom teeth, seem especially liable to misplacement. Mr. Tomes (*op. cit.*) gives numerous illustrations of this irregu-

FIG. 92.



larity, and in the Museum of the College of Surgeons is a cast of a case in which a wisdom tooth projected through the cheek.

FIG. 93.



The wisdom teeth of the lower jaw are also prone to assume an abnormal position in relation to the coronoid process, and

in either position a tumour may be formed which may be difficult of diagnosis. Dr. Forget (*op. cit.*) quotes the case of a woman who had, on the left side of the hard palate, a tumour of the form and size of a nut, which reached beyond the median line, and extended from the canine tooth to the soft palate. Blandin, on attempting to remove it, discovered it to be caused by two dwarfed and abnormally-placed molar teeth, which had penetrated the inner plate of the alveolus, and were lodged beneath the mucous membrane of the palate. On the removal of these the tumour subsided. A similar case of tumour of the palate, due to a molar tooth, is recorded in Tomes' "Dental Surgery."

The crown of a temporary tooth, of which the fang has been absorbed, may be so crowded in by its permanent neighbours as to disappear within the alveolus and give rise to irritation and anomalous symptoms. I was once consulted in a case of this kind, when Mr. Edgelow skilfully extracted from some depth the temporary crown, which proved to contain a stopping!

But the malposition of a tooth may give rise to a dense osseous tumour of the upper jaw, in which it is impossible to recognise the source of mischief until after removal of the tumour. Of this kind was a case which occurred to Sir William Fergusson, in 1856, in a girl, aged thirteen, in whom for three years there had been growing a dense tumour of the left superior maxilla, which, upon section after removal, proved to contain a tooth imbedded in its centre.

CHAPTER XIV.

DISEASES OF THE GUMS.—EPULIS.

Hypertrophy of the Gums is by no means a common affection. Mr. Salter has recorded (" System of Surgery," ii) a remarkable case which occurred in St. George's Hospital in 1859, in a girl, of eight years, in whom there was precocious development of the teeth, accompanied by hypertrophy of the gums. A large, pink, smooth mass projected from the mouth, slightly corrugated or indistinctly lobed, which consisted of an expansion of the alveolus, immense hypertrophy of the fibrous gum, and an exuberant growth of the papillæ of the mucous membrane. Dr. Gross has narrated a very similar case in his " System of Surgery " (1862). In April, 1867, I had the opportunity of seeing a case of the kind, under the care of Mr. Erichsen, in University College Hospital. A child of two and a half years had hypertrophy of the gums, which were prolonged in front of and behind the teeth so as almost to conceal them. The disease affected only the incisive portions of both jaws, and it was remarkable that the temporary teeth had undergone hypertrophy also, being considerably larger than normal. The affection first showed itself at the age of seven months, when the teeth began to appear, the gums increasing in size and bleeding on the least touch. Mr. Erichsen removed the exuberant growth, extracting some of the teeth, and freely cauterized the cut surfaces. In Mr. Salter's case it was necessary to clip away portions of the alveolus as well. The excised portions in Mr. Erichsen's case were examined by the late Mr. A. Bruce, who gave the following report upon them : " On section the mass was found to consist of a firm fibrous stroma, containing much

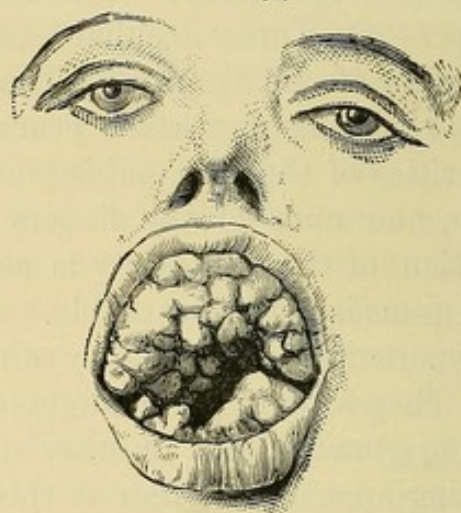
glandular tissue in its interstices, and covered on its surface by very large and vascular papillæ. The epithelial layer was of unusual thickness, but no abnormal epithelial structures were found in the growth, which was an example of true hypertrophy." These characters agree closely with those observed by Mr. Salter, and it may be remarked that though in his case the temporary teeth do not appear to have been hypertrophied, yet that the permanent teeth exposed in the alveoli by the operation were excessively large, especially the superior central incisors.

I am able now to supplement my report of Mr. Erichsen's patient, from the *Medico-Chirurgical Transactions*, vol. lvi, to which the late Dr. John Murray, of the Middlesex Hospital, contributed a paper "On Three Peculiar Cases of Molluscum Fibrosum in Children of one Family." The eldest of these was Mr. Erichsen's patient, now seven years of age, and she presented peculiarities of the skin, subcutaneous connective tissue, periosteum, and ends of the fingers and toes. Dr. Murray's description of the oral cavity is as follows: "The appearance of the gums is very remarkable. They are everywhere greatly hypertrophied, and they almost completely bury the teeth. They form in parts numerous papillomatous or polypoid-looking growths, and in other situations present a peculiar fungating appearance, indeed this latter characteristic of the growth is at once observed. The teeth, although almost buried by the hypertrophied gum, are still in every case visible, and are, in some measure, serviceable for the purposes of mastication. The enlargement of the gums is most marked at their upper and free surface, where they are mostly flattened out and in parts hardened by the pressure of the opposing gum. They present the natural colour, and although they are in parts somewhat soft, vascular, and spongy-looking, they mostly feel firm and fibrous to the touch, the disease being distinctly limited to the gums."

The patient's brother, aged four, in whom the growth was first observed when he was three months old, and her sister, aged two, had a similar condition of the gums.

It is remarkable that in all the cases recorded there was a defective mental condition, and the hypertrophy of the gums had been noticed quite early in life, and seemed to have been general, affecting equally both jaws and the whole extent of the alveolar arch. A case of hypertrophy of the gums in a woman, aged twenty-seven, was published by Dr. Waterman, of Boston (*Boston Medical and Surgical Journal*, April 8th, 1869); but the most remarkable instance of the disease on record, also occurring in the adult, is given in the *Australian Medical Journal* for August, 1871, by Mr. MacGillivray, Surgeon to the Bendigo Hospital, to whom I am

FIG. 94.



indebted for photographs of the patient (Fig. 94). The patient, a woman, aged twenty-nine, seemed to have suffered from the affection in both jaws at or soon after birth. At the age of ten, portions of the gum were cut away and several teeth extracted, and she had herself in later life cut off portions of the projecting gum with a razor. All these operations gave rise to severe hæmorrhage. The enormous growth shown in the drawing seemed to have originated mainly from the palatal portion of the gums, the labial surface being comparatively sound. Mr. MacGillivray removed the hypertrophied gums and alveoli with perfect success.

In December, 1878, I brought before the Odontological

Society of Great Britain two cases of hypertrophy of the gums which I had treated successfully by operation, one in a child and the other in an adult.

The first case was that of Amy B., aged four years and a half, who was admitted into University College Hospital, May 6th, 1878. She is one of five children; the other four are healthy. Two years ago the swelling of the gums began by the side of the temporary molars, which were just coming through, and from them the swelling has spread right round the jaw. At this time she had fits about once a week; the fits have continued up to the present time, but with longer intervals. They appear to be epileptic.

FIG. 95.

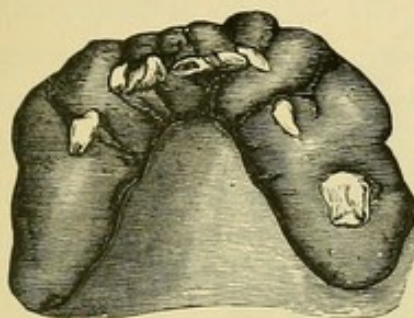
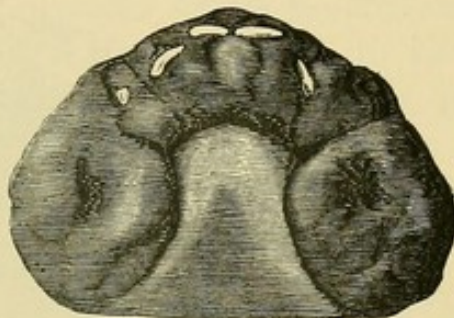


FIG. 96.



The patient is a very tractable child; her general health appears to be good. The gums are enormously hypertrophied, the teeth being entirely covered, with the exception of the tips of the crowns, which appeared depressed in the gums. The lower gums are shown in Fig. 95, and the upper in Fig. 96, taken from casts. The preparation is in University College Museum. The hypertrophy of the gums is so great that the cheeks are bulged out on each side, and the cavity of the mouth is almost filled with them. The teeth are irregular and slightly carious. The child is always biting and putting cold things in her mouth. She can bite nothing hard, and has been fed entirely on liquid or pulpy food. Her breath is very offensive.

On May 9th, under chloroform, I removed the hypertrophied gums and the alveolar margin of the lower jaw in two pieces. On one side the first permanent molar came away; on the other side it was left, not being quite erupted.

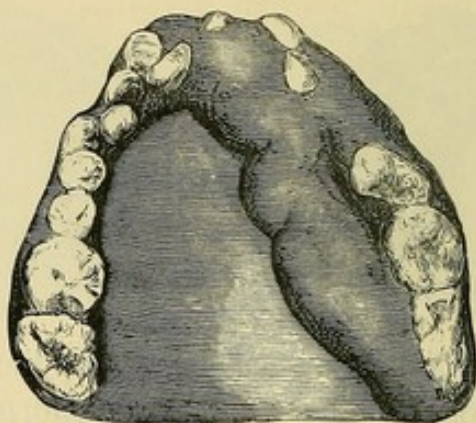
Hæmorrhage, which was free, was stopped with the actual cautery.

On May 23rd, under chloroform, I detached the hypertrophied gums and alveolar border of the upper jaw in one semi-circular piece. Roots of the permanent teeth left.

On June 3rd the patient was discharged well.

A microscopic examination, by Mr. Charles Tomes, showed that the structure of the growth closely resembled that of the small polypi which are sometimes found occupying the cavity of carious teeth: it was a true hypertrophy of the gum, and chiefly of the fibrous portion. It sprang from the periosteum round the neck of the teeth, just within the

FIG. 97.



margin of the alveoli. From this point a dense stroma of interlacing fibres, covered by a thin mucous and epithelial layer, grew up round the tooth, the growths from opposite sides meeting over it and coalescing, so as almost to cover it. The attachment within the socket was important, for this explained how it was that a successful result could not be obtained without removing part of the alveolus. Unless this was done, the base of the growth was left behind, and recurrence soon took place.

The second patient, Mr. L., aged twenty-six, came under my care in June, 1877, with hypertrophy of the gum and alveoli of the right side of the lower jaw, extending from the right wisdom-tooth to the left canine. The affection had been noticed from early childhood, and gave no pain. The condition of the gum is seen in Fig. 97.

On June 19th, the patient being under chloroform, I removed the affected alveolus with Liston's powerful cross-cutting forceps. The wisdom-tooth was left, but the other teeth were necessarily sacrificed up to the left canine. The hæmorrhage was free, but was controlled with the actual cautery freely applied, and the patient made a good recovery in a fortnight. Mr. Ibbetson subsequently fitted some artificial teeth; the patient is now in much greater comfort than before, and has remained perfectly well.

The growth is fibrous in structure, and is an example of pure hypertrophy. The preparation is in University College Museum.

In conclusion, I would say that nothing less than complete removal of the affected alveolus seems to offer any hope of alleviating these cases. Mr. Erichsen in 1867 thoroughly pared off the exuberant growth of the girl Ellen S., but in 1872 there was complete reproduction of the disease. In the child operated upon by me, the condition of the gums was such as mechanically to interfere with taking food, so that there was no hesitation in sacrificing the temporary teeth; and it may be hoped that many of the permanent teeth escaped injury, and may be erupted in due course.

Hypertrophy of the gums from the irritation of badly fitting artificial teeth is occasionally met with in elderly patients, and in one case, a lady whom I saw in consultation with Mr. Richardson, and in whom the disease had existed for ten years, I found it necessary to remove with Paquelin's thermo-cautery a considerable amount of tissue before it became possible to have fresh artificial teeth fitted.

Polypus of the gum is the name given to a simple hypertrophy of the portion of gum between two teeth, which is ordinarily dependent upon the irritation caused by those organs, and may be sessile or pedunculated. It is often connected with accumulations of tartar around the necks of the teeth, and with a generally unhealthy condition of the mouth; and if cut away with scissors and freely

cauterized with the nitrate of silver, or better, Paquelin's thermo-cautery, does not recur. In one case of large polypus over a central incisor which had been pivoted, and was doubtless a source of irritation, I thought it safer to remove a small piece of alveolus with the bone-forceps after extraction of the tooth, but this is exceptional. Mr. Salter describes a condylomatous form of disease of the gum, which is of a syphilitic character.

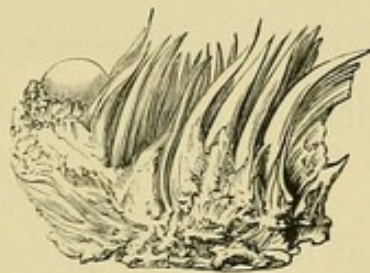
Vascular growths are occasionally met with in connection with the gum, and especially in the region of the incisor teeth. These bleed freely when rubbed with the tooth-brush, and may, if neglected, grow to some size, resembling a nævus in their colour and appearance. Stanley, in his work "On Diseases of the Bones," has narrated and drawn a case in which there was a vascular growth in the region usually occupied by these growths, but in that instance the tumour sprang from the interior of the jaw and necessitated removal of a portion of it.

Mr. Tomes has successfully treated the three or four examples of the disease he has met with, by the frequent application of powdered tannin. Mr. Salter narrates, in the "System of Surgery," a case in which hæmorrhage arose from a growth of the size of a marble, which he successfully treated by excision and the application of the actual cautery, after having failed to effect a cure with the ligature. I have also met with an example of pedunculated tumour of the gum in a woman aged twenty-five; it bled when touched, and the pedicle apparently passed through the alveolus. I removed it in June, 1869, by tearing through the pedicle with the finger-nail, and applied the actual cautery to the spot from which it grew, which bled freely. I have twice met with a very vascular and hypertrophied condition of the gums in patients the subjects of "port-wine stain" of the face. In a young married woman, of twenty-four, the gums of both jaws on one side were affected, and became more developed and vascular during each pregnancy, so that she lost a good deal of blood. I twice removed the growth, arresting the hæmorrhage, which was not severe, with the actual cautery.

In the other case, of a young lady of seventeen, the lip and upper gum were affected, and I was able to bring about a cure by drilling with a sharp-pointed cautery.

Papilloma of the Gum.—Mr. Salter has, in the *Guy's Hospital Reports* (1866), called attention to a rare form of disease in connection with the jaws, which appears to consist essentially in a hypertrophy of the papillæ of the mucous membrane. The disease was first noticed by Sir William Fergusson, in the lower jaw of an old man of eighty, and “looked like vegetable matter, or greatly elongated papillæ,” as described in some clinical observations on the case by that surgeon in the *Lancet*, September 6th, 1862. It was removed by Sir William Fergusson, and is described by Mr. Salter as

FIG. 98.

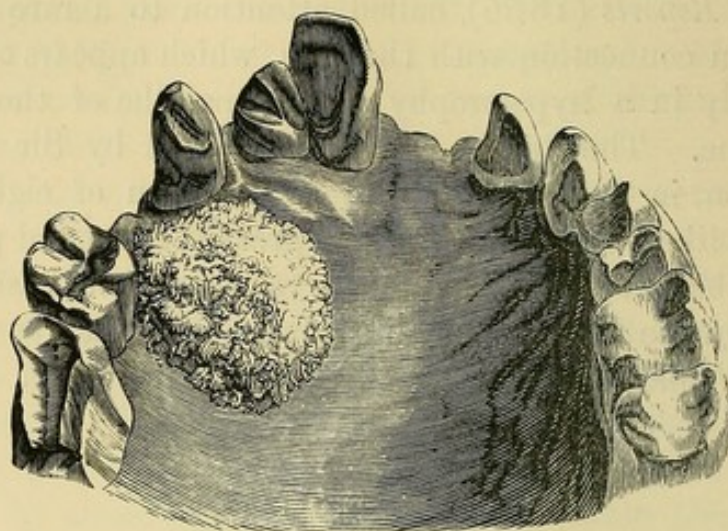


“a curious white mass, consisting of coarse detached fibres, pointed and free at one extremity, and attached at the other; in fact it was a mass of papillæ, many of them nearly an inch long, and similar in shape to the ‘filiform’ papillæ of the tongue; their surface was shreddy and broken; among these elongated processes were a few rounded eminences like ‘fungiform’ papillæ, and these had a smooth unbroken surface.” The accompanying drawing (Fig. 98), for which, as well as for those that follow, I am indebted to Mr. Salter, represents a portion of the tumour of the natural size. Microscopically the mass consisted almost entirely of epithelium.

Mr. Salter met with a second case in the practice of Mr. Cock, at Guy's Hospital. It consisted in a growth of the size of a split chestnut attached to the hard palate of the right side, and extended from the edge to near the median line, as seen in Fig. 99, and had been growing about eight

months. Mr. Cock extirpated the growth, which consisted of a hard mass of fibrous tissue, surmounted by papillæ, mainly composed of dense coherent epithelium; and met

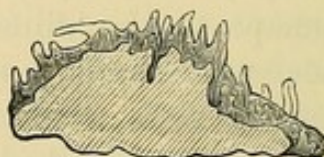FIG. 99.



with considerable difficulty in arresting the free hæmorrhage which ensued. Fig. 100 represents a section of the growth of the natural size. The growth recurred after some time, and took a malignant form, which proved fatal.

Epulis.—It has long been the custom to include certain tumours, under the name of epulis, among diseases of the

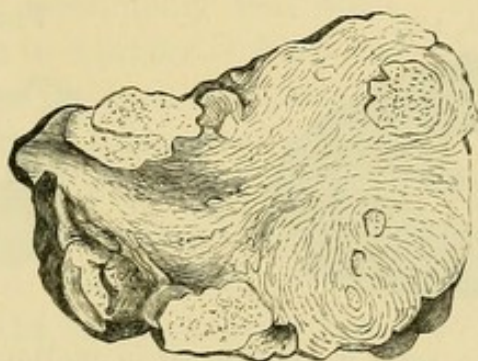
FIG. 100.



gums. This is not correct, however, for these growths, although closely connected with the gums, do not originate in them, but in connection with the alveolar process of the jaws. They really originate either in the bone or in the periosteum, and are essentially *sarcomatous* in nature. In many cases the fibrous element so markedly predominates over the cellular element that they are frequently regarded as fibromata. That they are essentially sarcomata, however, is shown by the tendency they have to recur after removal, unless the portion of bone or periosteum from which they

originated is removed also. In some cases there is a development of bone to a greater or lesser extent in the interior of these growths, and hence the term ossifying or osteo-sarcoma is sometimes applied to them. In other cases we may find that the tumour presents the naked-eye and microscopical characters of a myeloid sarcoma. It is very probable that the growths may originate in one of two situations, either in the periosteum when we get the ordinary fibrous or the osteo-sarcomatous epulis, or in the bone itself when we get the myeloid epulis. Although it is important to recognise the sarcomatous nature of epulis, yet we must remember that the growth differs, clinically, from

FIG. 101.



ordinary sarcomata of bone. Epulides possess a very low form of malignancy, so that if the part of the bone to which they are attached is removed with the growth, there is no tendency to recurrence.

The accompanying drawing (Fig. 101), for which I am indebted to Mr. Jonathan Hutchinson, gives a good idea of the naked-eye appearance presented by a section of an epulis of large size. This form of the disease is closely connected with the fibrous gum, and also with the periosteum of the alveolus, and very generally small spicula of bone are prolonged into it from the maxilla; the mucous membrane of the gum is stretched over the growth. Occasionally a development of true bone takes place in distant parts of the growth, as in the specimen drawn above; so also in a large epulis which I removed from the upper jaw of a young woman, and which accompanied this essay (College of Sur-

geons' Museum), a nodule of bone of considerable size is developed near the surface of the growth and quite unconnected with the alveolus. Mr. Cæsar Hawkins mentions (*Medical Gazette*, 1846) a similar occurrence in a case where the epulis was pedunculated.

The myeloid, or softer and more vascular form of epulis, is composed of a small quantity of fibrous tissue, holding in its meshes the true poly-nucleated myeloid cells, or "myeloplaxies." The drawing from which Fig. 102 was taken (also given me by Mr. Hutchinson) showed the vascular appearance of such a tumour on section, the one in question having formed a large overhanging mass upon the lower jaw, which was excised by Mr. Curling in 1864.

FIG. 102.

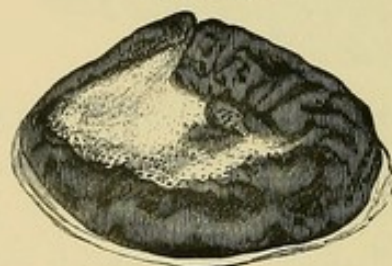
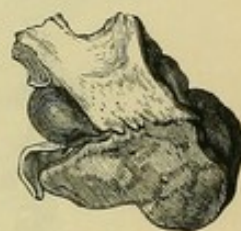
FIG. 103.



In Fig. 103 is seen a section of a well-marked myeloid epulis, removed by Mr. Wilkes, of Salisbury (College of Surgeons' Museum). The tumour consists of a semi-globular firm elastic mass attached by its base to the margin of the alveolus, from within which it springs. Its surface is smooth and uniform, and of a dark grey colour, mottled with purplish spots. On section it can be traced into the bone, the cut surface being for the most part of a greyish yellow, with patches of pink and purple. The microscopical examination shows interspersed among the fine fibrous tissue some large irregular disc-like cells, containing numerous bead-like nuclei, and the growth may therefore be considered similar to that described by Otto Weber as "giant-celled sarcoma."

This form of epulis is more commonly connected with the interior of the alveolus than the fibrous variety; and this fact may possibly account for its being more closely allied

to the endosteal than the periosteal structures. In fact, many of the so-called myeloid epulides are really only out-growths from myeloid tumours of the interior of the jaw, and hence their great tendency to recur if insufficiently removed. It is this form which, when irritated and ulcerated, presents an appearance somewhat resembling malignant disease. Irregular nodules of bone may be scattered through the myeloid as through the fibrous variety, and the occasional occurrence of a cyst in connection with an epulis must not be overlooked. I have recently had a case of the kind under my care, in which the presence of a cyst by the side of a fibrous epulis gave a formidable appearance to a simple disease.

A form of epulis possessing some of the characters of epithelioma is occasionally met with. A specimen which was sent to me in a perfectly fresh state by Mr. Hutchinson, who had removed it from the lower jaw of a lady, aged fifty-five, where it had been growing a year, was examined by the late Mr. Bruce with the following report: "The surface of the tumour is covered with healthy mucous membrane. The interior of the tumour is whiter, firmer, and more compact than the surface; but there is no line of demarcation between the tumour and its mucous covering. The structure of the growth is distinctly glandular, very much resembling some forms of compact adenoid tumour of the breast. At the point of attachment of the tumour to the parts beneath, a remarkable transformation of the glandular into the epitheliomatous structure is seen. In one part of the section may be seen the cut ends of gland tubules, whilst in their immediate neighbourhood are most distinct nests of true epithelioma, consisting evidently of concentrically arranged cells compressed from the centre outwards."

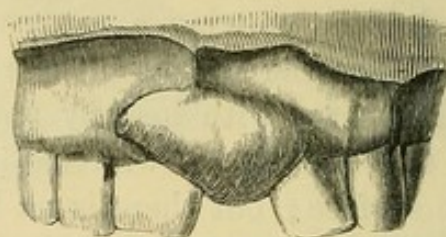
Mr. Eve has also placed in the Museum of the College of Surgeons an epulis which microscopically had the character of an epithelioma, but contained no 'cell-nests.'

It is probable that these epitheliomatous growths originated in the rudimentary epithelial structures discovered by

Malassez and described in the chapter on Cysts of the Jaw (see p. 172).

Epulis appears to be generally connected with the presence of teeth, and in some cases to depend upon the irritation caused by them; but I have once seen a small fibrous epulis in a newly born child. The simplest form is often found growing between two perfectly sound teeth, which become widely separated, as seen in the illustration (Fig. 104), taken from a patient of Dr. Langston, in whom I was obliged to sacrifice the central incisors in order to remove the growth; in some instances the pedicle attaching the growth may be so slender as to be broken by the tongue of the patient or the finger of the surgeon, of which Sir William Fergusson gives examples. The teeth may be unsound and broken,

FIG. 104.



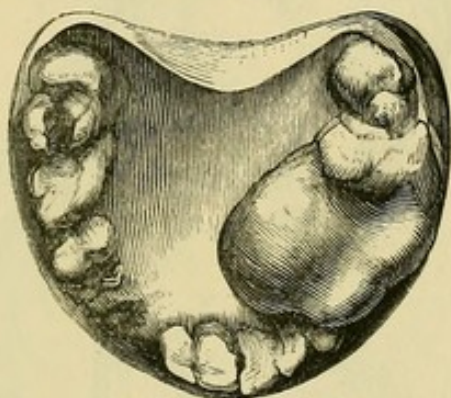
and in these cases the growth often completely envelops the stumps and hides them from view, or in the progress of the growth a fang of a tooth may be pushed forward, and be eventually found imbedded in its centre, as narrated by Mr. Tomes.

The two jaws appear to be equally liable to the disease, but its position and extent are subject to great variation. In the simplest form it may be connected with only the outer plate of the alveolus, or may be attached at a slight depth within the socket of a tooth. In other instances it is attached solely to the posterior plate of the alveolus, and protrudes the teeth or appears behind them; in the more severe cases of myeloid disease it involves the whole thickness of the jaw, and either envelops or carries the teeth before it. Of this a case of Dr. Fleming's (*Dublin Quarterly Journal*, February, 1866) gives a good example at an

unusually early age, the boy being between five and six, and the disease occurring between the first and second temporary molar teeth of the lower jaw, both of which were displaced and imbedded in the morbid growth.

When the tumour attains a moderate size, if it be on the upper surface of the alveolus it is apt to be pressed upon by the teeth of the opposite jaw, and this not only gives rise to pain and inconvenience, but causes also indentations and possibly ulcerations on its surface. Fig. 105 is reduced from a cast of the upper jaw of a young woman, a patient of Mr. Warn, of the Highgate Road, from whom I removed a large epulis containing bone, which has been already referred to.

FIG. 105.



The patient was twenty-seven years of age, and the growth had existed two years, and it will be seen that the surface is grooved and indented by the teeth of the lower jaw. In this case the fangs of the first and second molar teeth were found in the alveolus beneath the epulis.

A fibrous epulis, if allowed to grow to a large size, will produce external deformity of the face, and although attached to the upper jaw may hang down so as to simulate disease of the lower jaw. This was well seen in a woman, aged twenty-seven, who had an epulis of the upper jaw of seven years' growth, which hung down to the level of the angle of the jaw, and who was under the care of Mr. Erichsen, by whom the tumour was removed in 1861, with perfect success. Perhaps the most remarkable case of epuloid growth on record, however, is Mr. Liston's well-known patient,

Mary Griffiths, from whom, in October, 1836, he removed the growth shown in the accompanying drawing (Fig. 106). The case is reported at length in the *Lancet* of Nov. 5th, 1836, and is also referred to in Mr. Liston's "Practical Surgery," from which both the illustrations are taken. The following summary of it is from a note to Mr. Liston's paper on Tumours of the Jaw, in the *Medico-Chirurgical Transactions*, vol. xx.

FIG. 106.



"The patient had laboured under the disease for eight years, and had been subjected to a partial removal of the growth when of inconsiderable size. The tumour was of the same nature as those of the third and fourth cases related in the paper (*i.e.*, fibroid), as regards its disposition, form, and intimate structure. It differed somewhat, however, in outward appearance, in consequence of its exposed situation. The growth sprang originally from the gums and sockets of the incisors and canine tooth of the left side; at an early period it protruded from the mouth, unconfined and uninfluenced by the pressure of the lips or cheek. It had assumed

a most formidable size and appearance, concealed the palate and pharynx, and gave rise to great inconvenience and continued suffering. The surface had been broken by ulceration, but upon a close inspection of the projecting part and of that covered by the cheek, it was found to possess a firm consistence, and to present the same peculiar botryoidal arrangement of its parts as the others of a simple and benign nature. The operation proved perfectly successful."

FIG. 107.



Fig. 107 shows the after-condition of the patient, the scars in the upper lip being the result of the previous unsuccessful attempt to remove the disease. The preparation is in the Museum of the College of Surgeons.

A case, very similar in many respects to the preceding one, was successfully operated upon in 1869 by Professor Kinloch, of Charlestown. The patient was a negress, aged twenty-five, and presented much the appearance shown in Fig. 106, the mouth being enormously distended by a protruding growth, which appeared to have originated in the

alveolus, but to have involved the superior maxilla. Dr. Kinloch removed the mass, which weighed nearly two pounds, and the patient made a good recovery.

Treatment of Epulis.—No treatment less radical than removal of the growth is of the slightest advantage. In the case of a small epulis growing between, or close to, the incisor teeth, after removal with the knife an attempt may be made to check the reproduction of the disease by the application of nitrate of silver or a fine cautery, but usually without success. An epulis attached to the outer surface of the alveolus only may be cut away or detached by the nail, and the surface be thoroughly cauterised, but, as has been already said, the growth is connected with the periosteum and will often be reproduced from it. It is essential then to remove the periosteum, and this may be done with a chisel or gouge, by which a small scale of the alveolus with its covering can be cut away. Those who object to such a proceeding may produce the same result by the application of such a powerful caustic—either potassa fusa, nitric acid, or the hot iron—as shall destroy the surface of the bone and cause its exfoliation, but with some tediousness and inconvenience to the patient.

In some cases the epulis originates in the alveolo-dental periosteum. When such is the case, the tooth should be extracted and the epulis will come away with it. In cases of large fibrous epulis a tooth must be extracted on each side, and the whole thickness of the alveolus cut away with bone-forceps, of which Liston's cross-cutting forceps, shown in Figs. 108 and 109, are very serviceable; the straight ones for the incisor, and the angular for the molar region. The same radical treatment will be advisable when the disease springs from the posterior plate, and in all these cases I make an invariable practice of applying the actual cautery to the surface of bone exposed by the operation, which has the advantage of stopping hæmorrhage, and of causing the exfoliation of any diseased portions of bone which may have been left. In all operations of the kind, any roots of decayed teeth which may be discovered at the

time of the operation should be extracted with the forceps or elevator, and the surface of the bone rendered as smooth as may be.

When the epulis is connected with the lining membrane of the socket of a tooth, and dips down into the interior of the jaw, it is probably myeloid, and no superficial operation can effect a cure, since it is in this class of cases that repeated reproductions are met with. The neighbouring teeth, although sound, must generally be sacrificed, and the alveolus thoroughly cleared out with the gouge, so that

FIG. 108.

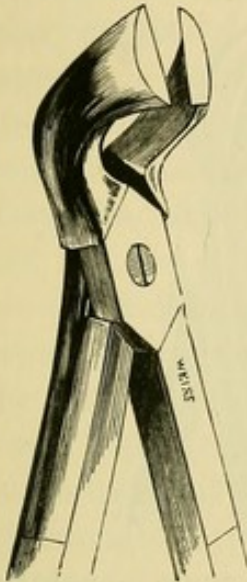
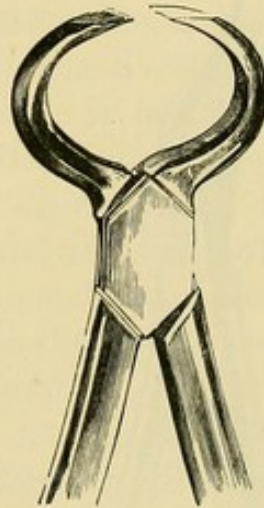


FIG. 109.



nothing but the shell of compact bone is left. The hæmorrhage is usually free, and is best controlled by stuffing the cavity with lint. In 1875 I saw a young gentleman, aged nineteen, with Mr. Braine, in whose lower jaw there was a small myeloid growth, which I freely removed. Recurrence took place, however, and I operated a second time, clearing out the alveolus very thoroughly, but fortunately being able to preserve the teeth, and the patient is now quite well, eighteen years afterwards.

When the epulis is very extensive, it may be conveniently removed, with the alveolus to which it is attached, by making a vertical incision with a small saw at each extremity of the disease, and then connecting the cuts by a

horizontal one with cross-cutting bone forceps. Under no circumstances, except when the growth is of a malignant character, can it be necessary, I believe, to cut through the whole thickness of the lower jaw, since it has been shown repeatedly that common epulis never involves the base of the bone, and the contour of the face depends so much upon its preservation, that it should not be interfered with.

When the growth is of large size and situated at the side of the mouth, some difficulty may be experienced in extirpating it, but with properly made angular and semi-circular

FIG. 110.

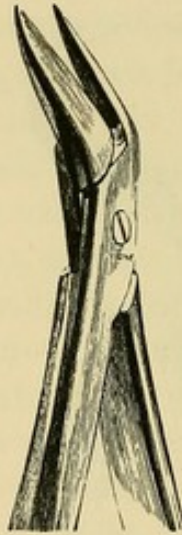
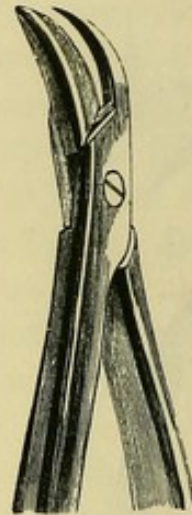


FIG. 111, .



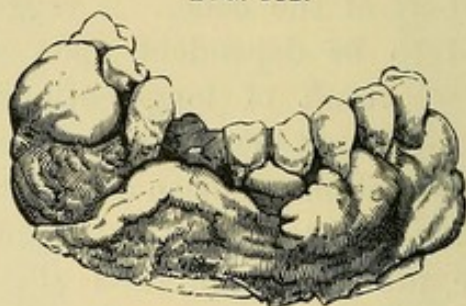
bone-forceps (Figs. 110 and 111) this may generally be overcome. It may be necessary, however, to incise the face, and if so, the suggestion and practice of Sir William Ferguson ("Lectures on Progress of Surgery," p. 239) cannot be too strictly followed—viz., to restrict the incision to the middle line of the lip, which will ordinarily give abundance of room; or, if not, to carry it into the nostril of the affected side, by the stretching of which so much additional room will be gained as to render any incision at the angle of the mouth perfectly unnecessary. When this limited incision is adhered to, the scar is so slight as to be imperceptible except upon the closest investigation. In instances of such enormous growths as in the case of Mary Anne Griffiths, more extensive incisions, resembling those for excision of

the jaw, would be required ; but such cases are now-a-days few and far between. Mr. Liston considered it necessary to remove the left and a portion of the right maxilla, but subsequent examination showed that these bones, though overlain by the disease, were not implicated in it except at their alveolar borders.

Epithelioma.—Some authors are inclined to include epitheliomata among the epulides, but any outgrowth or tumour in the early stage of the disease is quite exceptional, and therefore an epithelioma can scarcely be called an epulis. On pathological grounds, moreover, it would be absurd to classify epithelioma and epulis together. The former is a primary disease of the gums, commencing in the epithelium; the latter is a primary disease of the alveolar process, commencing in some part of the bone. A ragged ulceration of the gum, supposed to be dependent upon some tooth, and probably the direct result of long-continued irritation, is noticed, but the pain is not marked and the inconvenience is slight. Careful observation will soon detect a tendency of the ulceration to spread both towards the tongue and the cheek, and by this time, probably, induration of the base of the ulcer may be detected where it touches the softer tissues. The importance of prompt and thorough interference cannot be too strongly impressed upon members of the dental profession, by whom cases of epithelioma are more generally seen in the early stage. In a recent case of ulceration of the gum, simple treatment may fairly be tried for a week or ten days, but if the ulcer still remains unhealed, and more particularly if it is increasing, surgical aid should at once be summoned. The frequent application of the solid nitrate of silver to an ulcer which fails to heal readily, is worse than useless. The treatment of an epitheliomatous ulcer consists in thoroughly destroying it, with the tissue around for some distance. In slight or doubtful cases thorough application of the strongest nitric acid, the acid nitrate of mercury, or better, the actual cautery, may be sufficient to ensure a healthy cicatrization ; but even then the part will require careful watching, in order that any fresh development

may be promptly attacked. Unfortunately the disease has, in the majority of cases, already invaded the alveolus, as is shown by the swelling of the gum and the loosening of the teeth; and, when this is the case, free removal of the bone must be undertaken. A vertical cut with a narrow saw being made through the whole depth of the alveolus well beyond the disease, the cross-cutting bone-forceps may be used, or the saw applied horizontally to remove the diseased portion, as is shown in Fig. 112, taken from Fergusson. The danger, of course is that the disease may have penetrated more deeply than appears into the bone, so that recurrence is apt to take place rapidly from the epitheliomatous elements left behind. Should this occur, there must

FIG. 112.



be no hesitation in removing the whole thickness of the bone, and in the incisor region the resulting inconvenience is much less than might be anticipated, the muscles attached to the two halves of the jaw forcing them together, so that tough fibrous, if not bony, union takes place in the position of the original symphysis.

Some years ago a man was sent to me by Mr. Harding with an undoubtedly epitheliomatous growth springing from the gum in the incisor region. This I removed by sawing the lower jaw horizontally below the level of the alveolus, but, the section not proving quite healthy in appearance, I thought it advisable to take away the whole thickness of the jaw in this region. The patient made a good recovery, with firm union between the two segments of the jaw, and I have not heard of any further recurrence.

An equally satisfactory case has come under my frequent

observation during the last twelve years, in the person of a retired officer of the army, who in 1879, after wearing a lower dental plate for some years, developed epithelioma of the gums and cheeks. Professor Bowen Partridge, of Calcutta, removed the left half of the body of the jaw in December, 1879, and, recurrence taking place at the chin, Dr. McLeod removed the right in March, 1880, with the sub-maxillary glands of both sides. I first saw this gentleman in July, 1881, when the central portion of the jaw was of course gone, and there was a space of 1 inch between the halves of the bone. The tissues around were contracted, but perfectly healthy, and his only complaint was a sense of tightness and want of saliva. During the next two years the portions of jaw became approximated, and the growth of a beard hides the want of chin; I have recently seen this patient, and, as nearly fourteen years have elapsed since the operation, the cure may now be considered permanent.

In the Museum of the College of Surgeons are two specimens of epithelioma of the alveolus in which a less satisfactory result followed. The patient was a gentleman, aged fifty-four when he was sent to me by Mr. Weiss, with a well-marked epitheliomatous condition of the right lower alveolus, between the first molar and the canine teeth, which had been noticed six months. In addition, a well-marked ichthyotic condition of the mucous membrane of the floor of the mouth extended along the inner side of the body of the jaw and beneath the tongue. In September, 1880, I burnt away the whole of the affected mucous membrane with Paquelin's cautery, and having deeply notched the alveolus with the saw, I clipped out the affected portion with bone-forceps. Two months later the disease began to show itself on the inner side of the jaw, and in April, 1881, I removed the part affected very freely, cutting away the whole thickness of the bone from the second molar of the right to the second incisor of the left side, with the adjacent lymphatic gland, the section of bone being apparently healthy. Recurrence took place, however, shortly, and in November I removed a further portion of the left side of the lower jaw

up to the first molar tooth (College of Surgeons' Museum). Notwithstanding this complete removal of the disease, it returned in the soft parts beneath the tongue, large masses protruded into the mouth, and the patient sank in November, 1882.

Both in this and other similar cases I have been disappointed with the operation of removing solely the alveolus, and am inclined to adopt more radical measures at first in future, being encouraged to do so both by the great success of the officer's case already mentioned, and by a case occurring in University College Hospital.

This case was one of a man, aged fifty-two, who was under my care in 1875 with extensive epithelioma of the front of the tongue, which was firmly fixed by its tip to the lower jaw, with great enlargement of the submaxillary glands and infiltration of the submaxillary tissues. He suffered acutely from occipital pain, which it is difficult to explain, and was willing to submit to any operation for relief. I divided the jaw on each side one inch and a half from the symphysis, and then removed the front of the tongue, the centre of the jaw, and all the sub-lingual structures, with the galvanic *écraseur* (University College Museum). The patient made a rapid recovery, the two portions of jaw fell together, and are now united at an angle by tough fibrous tissue, and the man, who was alive and well in 1893, has covered the deformity by growing a beard.

In January, 1879, I performed nearly as extensive an operation on a man, aged sixty-eight, removing the lower jaw from the right incisors to the left angle, for extensive epithelioma of the jaw and floor of the mouth, the patient making a good recovery and being in perfect health two years later, but dying with recurrence of the disease eventually (*Lancet*, November 20th, 1880).

CHAPTER XV.

TUMOURS OF THE PALATE.

TUMOURS of the palate had not attracted much notice in this country until Mr. Stephen Paget published a very interesting and valuable paper in the *St. Bartholomew's Hospital Reports*, 1886. We cannot do better than quote his remarks introducing the paper: "Tumours of the palate have not attracted much notice, yet they form a group of great interest. They are of many kinds—cystic and solid, innocent and malignant. In the small space of the palate almost every sort and kind of tumour have been observed: cysts, nævi, papillary growths; tumours of bone and of cartilage; glandular, sarcomatous and cancerous growths. As regards their microscopic structure, there is still much to be made out; and, as regards their pathology, it is worth while to observe how closely some of them resemble the tumours of the parotid region. Thus, their structure is uncertain and complex; they may contain cartilage, bone, striped muscle, and glandular and embryonic tissues; the cells may be embryonic, myxomatous, sarcomatous, or epithelial. This same complex and heterogeneous structure is found in tumours of the parotid region. Again, in their slow yet uncertain rate of growth, and in their general behaviour, some tumours of the palate are very like the tumours of the parotid region. If, therefore, Cohnheim's theory holds good of tumours of the parotid region, as Mr. Jacobson has shown in his admirable paper on the 'Enchondromata of the Salivary Glands,' this same theory may also be applicable to tumours of the palate. These, too, may be of embryonic origin, may grow from particles of embryonic tissue which have long lain dormant,

and this theory of the origin of certain tumours of the palate receives some support from the fact, that there is no part of the body which suffers more than the palate from arrest and perversion of development. It is formed by a very complicated folding-in of foetal structures; and it is just in such a region as this that a superabundant formation of embryonic tissue would naturally take place. In one case, indeed, tumour of the palate was associated with perverted development of the palate and mouth. Again, the occurrence of true congenital dermoid tumours and vascular erectile growths in the palate may be taken as evidence that some tumours of the palate have an embryonic origin."

Cysts of the Palate.—A few cases of dermoid cyst have been described. They are usually noticed soon after birth. In the majority of cases the child has been born with the tumour, and in some of them the tumour has been so large at birth that the life of the child was in jeopardy from asphyxia. A typical case is described by Dr. Hale White in the *Pathological Society's Transactions*, 1881.

Simple serous cyst of the palate is very rare, and Stephen Paget, after a prolonged search, was able to find only one case recorded in surgical literature. Dentigerous cysts are occasionally found in the hard palate. They form dense projections from the bony palate, covered by the healthy mucous membrane.

Angiomata.—These may be congenital or acquired. The latter frequently seem to form in the neighbourhood of a carious tooth. They are cavernous naevi, generally situated on the soft palate. They may be excised, or, better still, treated by electrolysis.

Aneurysm.—A few cases of aneurysm of the descending palatine artery have been described, in all instances but one, following an injury. One of these cases occurred in the practice of Gross. The patient was a young army officer who had been accidentally stabbed with a small knife two months previously. A cure was promptly effected by laying open the tumour and tying the artery at both ends.

Papillomata.—These may be of two kinds, pedunculated and sessile. The pedunculated papillomata are delicate polypoid growths, always attached to the soft palate, occurring in adults, generally in men. Such a growth was met with in the case of a healthy girl, aged eighteen, who came to the Dental Hospital, Leicester Square, to have some teeth stopped; on examining her mouth, Mr. Ackery noticed a growth attached to the soft palate. It was pedunculated, hanging down beyond the margin of the left velum, and had a warty appearance: he snipped it off with scissors, and rather free hæmorrhage followed. The growth was about half an inch long by one-sixth of an inch broad, the pedicle being about one-eighth of an inch thick; it was of the same colour as the surrounding mucous membrane, and the surface was composed of enlarged fungiform and filiform papillæ. On a longitudinal section it was seen to be composed of compound papillæ branching off from a common root or base, each offshoot being composed of dilated blood-vessels, surrounded by a very small amount of connective tissue, and enclosed by a thin layer of mucous membrane, on which were several layers of epithelium cells of the squamous variety.

The sessile tumours or warty papillomata may be found on the hard palate, and may extend widely to the whole palate. It is probable that they occur as a result of chronic or syphilitic pharyngitis. The only satisfactory treatment is free removal of the growth (see p. 233).

Adenomata.—According to Stephen Paget, "There is much uncertainty as to these tumours of the palate; it appears to be a name given to any solid indolent innocent sessile tumour, without much regard to microscopic structure. In most of the recorded cases there is no account of microscopical appearances, and the accounts that in other cases are given do not appear to have much in common. In two cases lately reported by the writer to the Pathological Society, where the history, manner of growth, and naked-eye appearances of the tumours made it certain that they were absolutely innocent, there were masses of epithelial cells with

cell-nests. The word 'adenoma' applied to tumours of the palate has only a clinical value; it means only an innocent tumour, very slow in growth, firm, limited, and, as a rule, shelling-out easily."

Dr. Cabot showed to the Boston Society for Medical Improvement a small round tumour, which he had removed from the roof of the mouth of a soldier. It had existed for eighteen months, and was situated in the posterior and left part of the hard palate, extending as far as, but not involving, the gum. Although the patient had suffered severe pain in the left side of the face and temple of a neuralgic character, yet he was not sure that it had its origin in the tumour. It was somewhat tender on pressure, but not painful. The capsule which contained it being incised, it was easily shelled out. It was two-thirds of an inch in diameter, of a yellowish white colour and mostly smooth, but in one part it had a warty appearance.

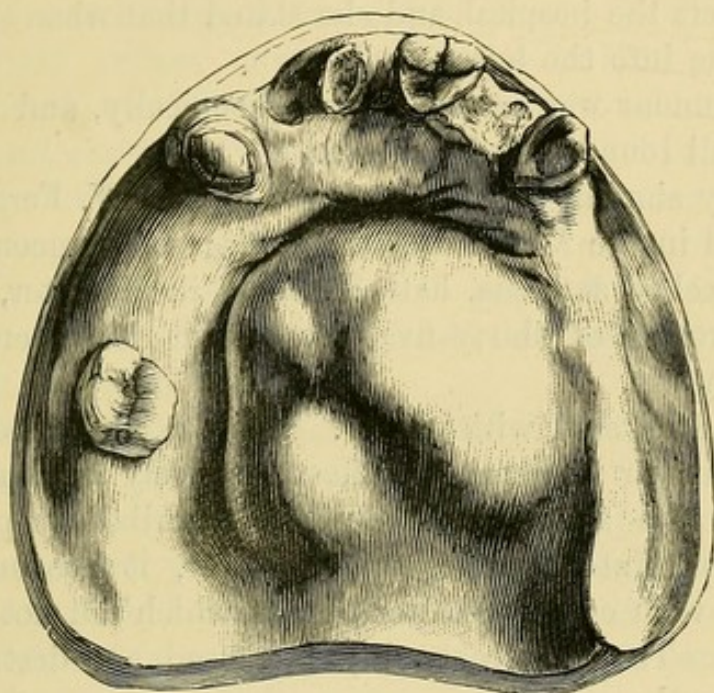
In 1879 I had under my care a lady with a very suspicious tumour of the soft palate, which I feared would prove to be sarcomatous. On incising it, however, I was able to enucleate with the finger what proved to be an adenoma or hypertrophy of the glands of the soft palate, contained in a distinct capsule, which I was also able to withdraw. The patient has remained in perfect health to the present time.

Sarcomata.—Here again we cannot do better than quote an extract from Mr. Stephen Paget's valuable paper. "Though it is impossible to draw a clear line between true sarcoma of the palate and such mixed growths as 'cystic adeno-sarcoma,' and 'adeno-myxoma,' and again between these mixed growths and the 'adenomata'; yet the sarcomata of the palate are a well-marked group. They are more rare than the innocent tumours; they occur equally in men and in women, and more often in the soft palate than in the hard. The average age when the growths were first observed was over forty. The average duration of each tumour before surgical aid was sought was two years, if we

except one case where the tumour began to grow rapidly after many years lying quiet. Here we have two clear differences between the 'adenomata' and the 'sarcomata.' "

A case of sarcoma of the hard palate came under my care in 1876. The patient was a woman, aged forty-eight, and stated that she had noticed a small lump on the hard palate since childhood, but it gave her no inconvenience

FIG. 113.



until about two years ago, when it began to enlarge, and from this time it steadily grew, and soon began to interfere with her articulation. Her health had, however, always been good. There was no history of tumour in the family. The tumour filled up the hollow in the hard palate, being more attached to the left side, where the mucous membrane was continued directly over it, than on the right, where a probe could be passed between the tumour and the palate. It was about the size of a horse-chestnut, slightly lobed on the surface, elastic, but not fluctuating; the mucous membrane over it was not adherent to it, and was normal in

appearance. The tumour moved slightly over the bone. There were no enlarged lymphatic glands in the neck. The accompanying woodcut (Fig. 113) was made from a plaster cast taken by a dentist.

I removed the tumour by making an incision round the left side of the growth, which then readily shelled out from a distinct capsule ; the capsule itself was afterwards removed with the fingers. Bleeding was stopped by the actual cautery. The wound granulated, but left a part of the hard palate bare. A small portion of this was loose when the patient left the hospital, and she stated that when she drank fluid came into the left nostril.

The tumour was examined microscopically, and found to be a small round-celled sarcoma.

A very similar tumour, removed by Sir W. Fergusson, is preserved in the Museum of the College of Surgeons. It is a round-celled sarcoma, half an inch in diameter, removed from a woman of thirty-five, in whom it had been growing for four years.

In 1880 I saw, with Sir J. Paget, a child, aged seven, with a tumour presenting almost precisely similar appearances to the adenomatous tumour described on page 252. On cutting into the growth, however, it proved to be a sarcoma, with extensive attachments, which did not admit of removal. The growth steadily increased and destroyed life in six months.

Looking back at these two cases, I find it impossible to give any symptom by which they might have been distinguished ; but the duration of the growth, if it can be accurately ascertained, would doubtless help at arriving at a just conclusion.

Carcinomata.—True cancers of the palate are but seldom met with. They are of two kinds : one, squamous epithelioma, commencing in the epithelium covering the palate ; the other, glandular carcinoma, commencing underneath the epithelium, originating, in all probability, in one of the numerous glands situated in the palate.

The squamous epithelioma of the palate is often a secondary infection of the palate, the primary growth having commenced in the gum. Such cases are really epitheliomata of the gum, extending later on to the palate. Sometimes, however, a primary epithelioma of the palate is met with. Thus, Brissaud, in the *Bull. Soc. Anatom.*, 1872, relates the case of a man, aged forty-five, who had psoriasis of the palate for fifteen years, probably caused by excessive smoking, in which epitheliomatous ulceration set in.

Glandular carcinoma, or, as it is sometimes termed, medullary carcinoma, of the palate is very rare. Stephen Paget could collect only three cases. The first case was reported by Mr. Shaw in the sixth volume of the *Pathological Society's Transactions*. It occurred in a woman, aged fifty-three, who had noticed the tumour for one year. On examination the growth was found to be inseparably connected with the hard and soft palate, lying in front of the right tonsil; lymphatic glands, extensively involved, rendering operation impossible.

The second case is thus reported by Stephen Paget: "A man, aged fifty-nine. Disease noticed three months. He has a tumour in the left half of his soft palate, the size of a large walnut, pushing down between the pillars of the fauces; soft, almost fluctuating. The mucous membrane over it is slightly congested, and a few large veins can be seen in it. No glands are felt at the angle of the jaw. He has difficulty of breathing, and can only swallow fluids. Mr. Langton made an incision over it, which was followed by profuse hæmorrhage. The growth was easily enucleated, except toward the horizontal plate, where its attachment was more firm. The wound was sutured. Recurrence six weeks after the operation. Death three weeks later.

"*Post-mortem*.—A mass in the palate the size of a Tangerine orange; not found to be connected with the bone. Soft, lobulated, medullary cancer. Cervical and mediastinal glands infiltrated, and cancerous deposits over both lungs. (Mr. Langton, *Clin. Soc. Trans.*, iii)."

The third case was under the care of Mr. Treves. It occurred in a man, aged fifty-six. A tumour had been noticed in the right half of his soft palate for two months. It was the size of a chestnut, and was touching the pharynx. Mr. Treves ligatured the common carotid artery, and removed the right half of the soft palate with the tumour and an enlarged gland from the angle of the jaw. The man recovered. The growth was found to be a 'spheroidal-celled' or glandular carcinoma, partly encapsuled.

CHAPTER XVI.

NON-MALIGNANT TUMOURS OF THE UPPER JAW.

Fibroma, Enchondroma, Osteoma.

WITH regard to the statistics of tumours of the upper jaw, I shall content myself with quoting O. Weber, who has collected 307 cases from the following sources: 183 cases tabulated by Heyfelder; 36 recorded by Lücke from Langenbeck's clinique; 17 reported in the *Medical Times and Gazette* (September 3rd, 1859); and 71 cases either observed by himself in Wutzer's clinique, or occurring in his own practice. Of the above cases there were:

Osseous tumours	32
Vascular tumour	1
Fibrous tumours	17
Sarcomatous tumours	84
Enchondromatous tumours	8
Cystic tumours	20
Mucous polypi	7
Carcinoma	133
Melanosis	5
	307

In commenting upon this table, Weber very justly remarks that doubtless the list of cancerous cases is exaggerated, and suggests that a fair estimate would be gained by allotting rather more than a third of the whole number to sarcomatous tumours; less than one-third to the cancerous; and the remainder to the osseous tumours, cysts, &c.

It must be borne in mind, however, that modern methods of investigation have shown that the old classifications are frequently based upon erroneous data, so that a re-arrangement of tumours of the jaws has become necessary, and will be attempted in the following pages.

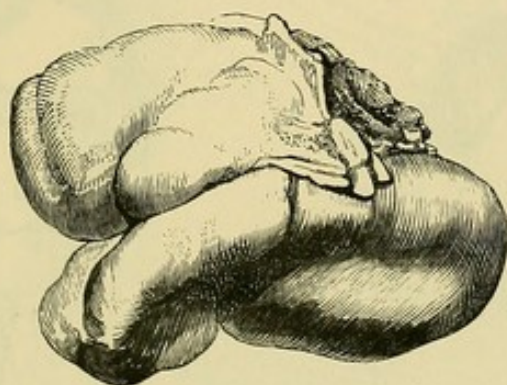
Fibroma.—This closely resembles the fibrous tumours found in other parts of the body. It is dense in structure but not unfrequently lobulated, and, on section, slender bundles of intersecting fibres may occasionally be traced in them, of which there are good examples in the Museum of the College of Surgeons. The fibrous tumour usually springs from one of two situations—either the interior of the antrum or from some portion of the alveolus. In both cases it is intimately connected with the periosteum, in this respect resembling epulis. Occasionally the growth appears to follow some slight injury, as in the case of a lady, a patient of Dr. Neale, from whom, in 1870, I successfully removed a fibrous tumour occupying the interior of the antrum, which had followed a blow given by her child, and which may have been a fibrous odontoma (p. 264).

Fibroma grows slowly but surely, involving in its progress the surrounding structures. When arising in the antrum, it first expands the walls of that cavity, bulging out the face and forming tumours in the palate and floor of the orbit, and subsequently produces absorption of the osseous walls and spreads unchecked in all directions. The following description of a specimen in St. George's Hospital Museum gives a good idea of the ravages of such a tumour: "Fibrous tumour growing from the antrum, and making its way by the absorption of the walls of that cavity in different directions. It projects upwards into the orbit, destroying the floor of that cavity, and protruding from its inner margin forwards on to the cheek. It has also destroyed the anterior wall of the antrum, and displaced the malar bone forward and outward; inwards it projects into the nose beneath the middle turbinated bone, and downwards it makes its appearance on the under surface of the alveolar process in the form of a rounded mass,

destroying the floor of the antrum in the neighbourhood of the front molar tooth. Behind, the tumour appears in the zygomatic fossa by the absorption of the outer part of the tuberosity of the superior maxillary bone. The tumour is composed of circular nuclei of various sizes, and spindle-shaped fibres. The patient from whom the specimen was taken, William H., died of arachnitis, and softening of the corresponding part of the brain."—*Catalogue of St. George's Hospital Museum.*

When it arises from the alveolus, a fibrous tumour may encroach on both the facial and the palatine surfaces of the jaw, crushing in the antrum although not involving its

FIG. 114.



interior. Of this a good example is seen in a preparation in the College of Surgeons, of an upper jaw removed by Mr. Liston. Here the tumour which is affixed to the alveolar border, near the molar teeth, extends inwards so as to cover the palatine portion of the jaw, and outwards so as to conceal all the bicuspid and molar teeth, with the exception of the last. The walls of the antrum are pressed inwards, but its interior is healthy. The patient was a woman, thirty years old, and the tumour was observed four years before its removal, which was successful. On the other hand, fibrous tumours, though commencing in the alveolus, may secondarily involve the antrum when they have attained considerable size, producing complete absorption of its walls, and projecting into the nose and through the palate. Of this a preparation in the College of Surgeons' Museum, of an upper

jaw, also removed by Mr. Liston, affords a good example. Here the patient was only twenty-one, and the growth first appeared on the outer side of the gum of the left upper jaw four years before the operation. It was cut off six months after its first appearance, but returned, and eighteen months after was removed, with a portion of the alveolar process, but reappeared in a few weeks. Fig. 114, from Liston's "Practical Surgery," shows the growth after its removal, and

FIG. 115.

FIG. 116.



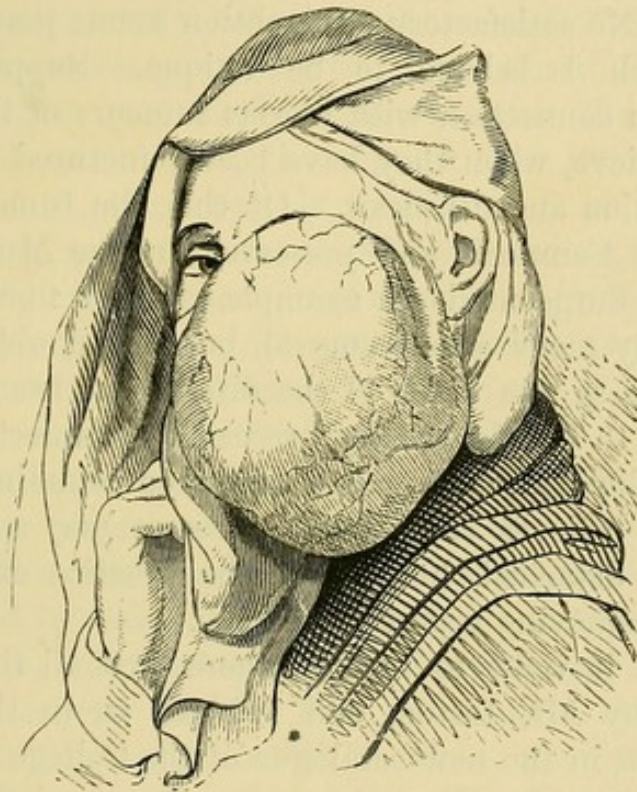Figs. 115 and 116 show the patient before and after the operation. It may be noticed here, as in the case of a large epulis, that disease of the upper jaw often closely resembles, externally, a tumour of the inferior maxilla.

The case is given by Mr. Liston in his paper on "Tumours of the Jaw," in the *Medico-Chirurgical Transactions*, vol. xx.

The enormous size to which fibrous tumours of the upper jaw may grow without destroying the patient, is well seen in the accompanying drawing (Fig. 117) of Mr. Liston's celebrated case of Mrs. Frazer, from whom that eminent surgeon successfully removed the growth. The tumour is preserved in the Museum of the College of Surgeons, and its

diameters are, vertically, seven inches; transversely, seven inches; from before backwards, nearly six inches. Contrary to the ordinary practice, a portion of the integument was removed with the tumour, measuring twelve inches in length and ten in breadth, and this left a gap in the skin of the face upon the patient's recovery, a point which will be again referred to. The growth of this tumour was connected apparently in a curious way with the performance of the

FIG. 117.



uterine functions. The patient was forty years old, and the tumour began to grow six years before its removal, in consequence of a blow in the region of the antrum. Its progress at first was slow and not painful, but at the end of two years a distinct tumour was felt in the cheek. During the next two years it grew rapidly, especially during a period of gestation, but still without much pain. In the fifth year of its growth she bore a second child, after which the catamenia ceased to flow, and the tumour was subject to monthly augmentations of its vascularity, and slight

hæmorrhages occurred from its inner, though not ulcerated, surface, and from the adjacent parts of the gum. The case is given in detail in Mr. Liston's paper already referred to.

A remarkable feature, noticed in a case of fibrous tumour of the antrum, in a young man of eighteen, under the care of Sir J. Paget, in 1860, was a distinct pulsation in a portion of the tumour which projected into the orbit. The pulsation was slight but decided, and was synchronous with the radial pulse. The case was clearly not one of malignant disease, but proved upon removal to be an ordinary fibrous tumour. No satisfactory explanation seems possible of the case, which I believe to be unique. Suppuration has occurred in connection with fibrous tumours of the jaw, but only, I believe, when they have been punctured with a view to exploration and diagnosis. Of this the tumour removed from Janet Campbell and preserved in the Museum of the College of Surgeons, is an example. Simple fibrous tumours occasionally recur after removal, but it is doubtful whether in these cases the whole of the disease has been eradicated. According to O. Weber they are usually connected with the lining of the Haversian canals of the surrounding bone, and though he believes that these processes may sometimes be effectually detached, he advises the practice ordinarily followed of removing a portion of bone.

I think it right to mention here that all the specimens removed by Mr. Liston, and referred to in the foregoing pages, have, in the new catalogue of the College of Surgeons' Museum, been placed among the sarcomata, on what I cannot but regard as insufficient grounds. In the first place, forty years' soaking in spirit prevents anything like a reliable microscopic examination, and the presence of a few cells scattered among the fibres of a tumour is no proof that it is not a fibrous tumour; and, secondly, the clinical history of all these cases is that of a simple growth, which once removed did not recur. I have therefore included them among the fibrous tumours, and if they are not so, it is very remarkable that there is no specimen of the true fibrous tumour of the upper jaw among the large number removed

by Liston and preserved in the College of Surgeons' and in University College Museums.

Fibrous tumours of the jaw, like those in other parts of the body, and especially in the uterus, are liable to calcareous degeneration, or, as is sometimes incorrectly stated, to ossific deposit. A good specimen of the kind is preserved, in the Museum of St. Thomas's Hospital, and is thus described in the Museum catalogue :

"An osteo-fibrous tumour of the antrum, removed by Mr. Solly. The tumour entirely filled the cavity of the antrum, the bony parietes of which have been absorbed to a considerable extent; it protruded the cheek anteriorly, projected into the fauces posteriorly, pressed down the palate inferiorly, and extended to the septum nasi internally. Its firmest point of attachment is to that part of the antrum corresponding to the roots of the first molar, canine, and incisor teeth. The tumour is of a rounded form, and has a smooth external surface; its section presents very much the appearance of a fibrous tumour of the uterus of slow growth, and contains an abundance of bony deposit.

"From a boy, aged seventeen. The existence of the tumour was discovered only ten months previous to its removal, when the face began to swell, the swelling being accompanied by pain. No untoward circumstances followed the operation, and the boy left the hospital quite well. The deformity was very slight. Five years after the operation the boy was in capital health." More complete details of the case will be found in Mr. Solly's "Surgical Experiences," lecture 41.

A remarkable example of calcareous degeneration of a fibrous tumour occurred in the practice of Sir W. Fergusson, and the preparation is now in the Museum of the College of Surgeons. It is a fibrous tumour of the left upper jaw, of some years' growth, from a woman, aged fifty, containing numerous calcareous particles and acicular crystals, and in addition, enclosing a suppurating cavity, in which was a mass about an inch in diameter, found by Dr. Goodhart to consist of acicular crystals of mineral matter, entangling

in places nucleated and shrivelled cells. This is clearly an example of extreme calcareous degeneration undergoing necrosis.

With regard to the causes giving rise to fibrous tumours of the upper jaw there is much obscurity, though there is little doubt that they in many cases originate in some irritation due either to a blow, or more frequently to the presence of decayed teeth; and the latter may give rise to a tumour commencing in the alveolus itself or within the antrum, the lining membrane of which is irritated by the fangs of the diseased teeth. Bordenave strongly insisted upon this, and since his time most surgeons have taken the same view. Stanley mentions a case which occurred to Mr. Luke, in which a black, carious tooth was found imbedded in a fibrous tumour of the upper jaw, and other cases of the kind have occurred, although the event is more common in the lower jaw.

Since the publication of the first edition of this work, M. Broca, in his *Traité des Tumeurs* (Paris, 1869), put forward the view that many cases of fibrous and fibro-cellular tumour of both upper and lower jaw depend upon the growth of a tooth-germ, and these are included by him under the head of *odontomes embryo-plastiques*. There is no difference in structure by which these fibrous odontomata can be distinguished from the ordinary fibrous tumour, but according to M. Broca they are always encysted, and they occur only in young subjects, and before the last tooth is formed. Owing to their ready enucleation, these tumours show no tendency to recur. I have met with but one case which seemed in any way to support the views above given. A young married lady, a patient of Dr. Neale, had a tumour of the upper jaw, evidently due to expansion of the antrum, the walls of which crackled under pressure. Believing the swelling to be due to fluid, I punctured it, giving exit to only a small quantity of fluid, and discovered a tumour within. On laying open the antrum, I was able to enucleate with the finger a tumour which had very slight attachments, presented all the appearance of a fibroma, and on examina-

tion by Dr. Bastian, was pronounced to be very rich in cell elements, and therefore likely to recur. Nevertheless, the patient was in perfect health fourteen years after the operation.

Enchondroma of the upper jaw is of uncommon occurrence, but the jaw may become involved in cartilaginous tumours springing from other bones of the face. Of this there is an example in St. George's Hospital Museum, taken from a young woman, who, seven years before her death, began to suffer from soft elastic tumours on the inner sides of the orbits. Two years after, the right maxillary bone was fuller below the orbit than the left, and the right half of the bony palate was larger and more depressed than the other; but in neither of these parts was there any softening. Gradually the eyeballs were protruded, and the sight was lost. Two years later, it was noticed that the superior maxillary bones projected nearly an inch beyond the inferior, so that she had some difficulty in masticating. A portrait of this patient is preserved in St. George's Museum. The tumour was found to project into the cranium, the orbits, the antra, and the nasal, zygomatic, and pterygo-maxillary fossæ. All the fossæ were quite filled up by the growth, and the bones of the face and orbits extensively absorbed. The hard palate was pressed downwards, so that the teeth on the two sides deviated from their natural line, and the left central incisor crossed that of the right side. Microscopical examination of the tumour showed it to be composed principally of cartilage. A full description, with a lithograph of the preparation, will be found in the *Pathological Society's Transactions*, vol. x.

In the Museum of St. Bartholomew's Hospital is another post-mortem specimen of cartilaginous tumour of the face, from a lad of sixteen, occupying the situation of the superior maxillary bones, which are completely absorbed. Above, the tumour has extended through the left side of the base of the skull into its cavity, where it forms a large projection in the situation of the anterior lobes of the cerebrum; below, it is united to the soft palate; in front, it protrudes

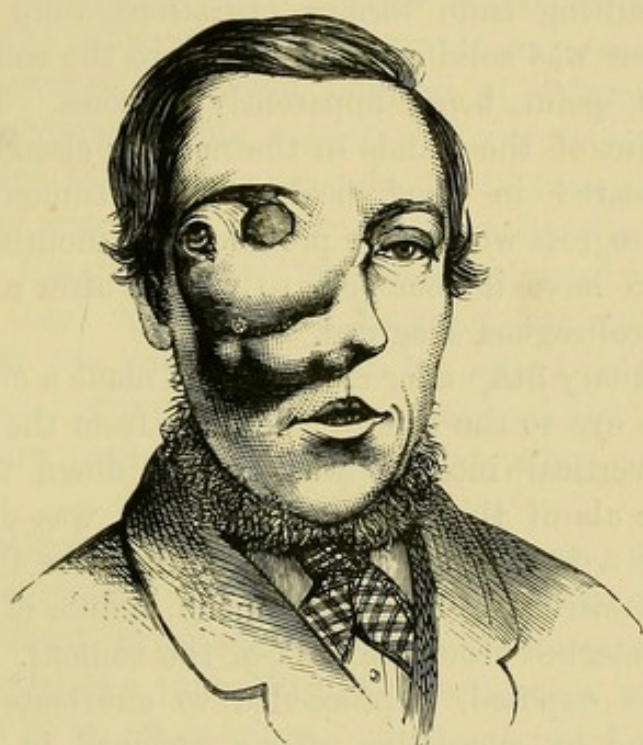
and distends the left nostril, and has caused the ulceration of a part of the integuments of the face. The outer surface of the tumour is nodulated, its interior, shown by the section, is formed of close-set nodules and masses of cartilage, partially and irregularly ossified, and in some parts intersected by layers of a softer, probably fibrous tissue. A portion of its external surface projecting below the left nostril has sloughed. This case is drawn in Mr. Stanley's illustrations to his work on "Diseases of the Bones"; and both it and the preceding preparation illustrate very well the tendency of cartilaginous tumours to invade all the surrounding structures, and to fill the several cavities.

A remarkable case of recurrent cartilaginous tumour of the face, originating in the upper jaw, was under my own care, of which the following are the particulars: The patient, aged thirty-four, was admitted into University College Hospital on the 1st of January, 1868, with a large tumour of the right side of the face. When about seventeen years of age he noticed a pimple on the right side of the nose, which increased pretty rapidly; and three months after (1851) he went into St. Thomas's Hospital, when Mr. Le Gros Clark operated, and removed a tumour as large as a walnut. He quite recovered, and was well for a few months, but within a year the tumour had returned. He was then admitted into King's College Hospital, under Mr. Partridge, who, in June, 1852, removed the tumour, which was of an osteo-cartilaginous character, oblong in shape, and of the size of a large walnut, projecting slightly into the antrum, and involving the nasal process of the superior maxillary bone, but in no way implicating the mouth or orbit. From this operation the patient made a good recovery, except that a small fistulous opening was left in the cheek. The man continued in good health until 1857, when he went to America, and soon after arriving there he found the tumour beginning to appear again, and in 1860 Professor Gunn operated at Anne Harbour, in the State of Michigan, and removed the entire right upper jaw. The tumour, however, began to grow again rapidly, and projected on the face. The

surgeons at Maple Rapids, where the patient lived, wanted to operate again, but he declined, and returned to England in 1865. Soon after this an abscess formed in the upper part of the tumour, which was lanced with great relief, but the incision thus made had never closed, owing to the stretching of the skin by the tumour.

The patient's appearance on admission was most unsightly (Fig. 118), the right side of the face being greatly disfigured

FIG. 118.



by a large tumour, by which the eye was thrust completely aside, but without loss of vision. Immediately to the inner side of the eye was an open granulating sore of the size of a florin, the result of the incision for the evacuation of matter already referred to. The tumour appeared externally to consist of two portions, separated by a horizontal sulcus, at the bottom of which the fistulous opening resulting from the second operation was still visible. The upper and more prominent portion had invaded the orbit, reaching to its upper border, and extending beyond the middle line of the nose. A small portion of this had, within the previous two months, projected through the left nasal bone. The lower

portion of the tumour involved the ala of the nose and adjacent portion of the cheek, both of which were much distorted; on a small projecting portion of this the skin was adherent. Both nostrils were completely blocked, and had been so for months. Within the mouth it was seen that the whole of the right side of the hard palate had been removed; and in its place there was a smooth, red, oval mass, coming down to the level of the teeth of the opposite side. The scars in the middle line of the lip and on the cheek, resulting from former operations, were still visible. The tumour was solid and not tender to the touch, the most prominent point being apparently osseous. There was no enlargement of the glands in the neck or elsewhere, and the man appeared in good health. The tumour had made decided progress within the previous few months, and he was anxious to have it removed, to which, after a consultation with my colleagues, I agreed.

On January 8th, under chloroform, I made a curved incision below the eye to the side of the nose, from the extremity of which a vertical incision was carried down the face and round the ala of the nose; and the lip was divided in the cicatrix of a former operation. The flap was then dissected back, and with it a hard prominent nodule of bone, which became detached from the bulk of the tumour. The tumour being thus exposed, I proceeded to enucleate it with the fingers, and by successive efforts removed in this way the upper part of the growth. The tumour presenting in the mouth was found to be held by a firm band of tissue in the position of the gum, and after dividing this I was able to tear out the growth, and also a portion projecting through the posterior nares into the pharynx. The wound having been well sponged out and the hæmorrhage having abated, the portion at the inner side of the orbit was removed, and was found to project into the frontal sinuses, which (particularly the right) were considerably expanded. With one of Langenbeck's palate spatulæ I carefully cleared these out, scraping the walls, and then introduced a pledget of lint covered with a paste of chloride of zinc (to which a string

was attached), in order to destroy any remaining portion. This was the only part from which the growth appeared to have arisen, the remainder of the huge cavity left by the removal of the growth being perfectly smooth and healthy. The septum narium was found to be completely pushed over to the left, and to have been destroyed at the upper part by a projecting lobule of the growth, which had pushed through the nasal bone. The ala of the nose included a small portion of the growth, which was removed, and also the bony nodule attached to the flap, the upper corner of which, being very thin and closely involved in the growth, was cut off. The wound was sponged out with solution of chloride of zinc, and all hæmorrhage having ceased without the application of any ligatures, the lip was brought together with hare-lip pins, and the remainder of the wound with wire sutures. The edges of the gap caused by the opening of an abscess some months back were brought together, but finding that this prevented the patient closing his eye, I subsequently removed these sutures. Collodion was painted over the wound, and the patient, who had a good pulse, was carried to bed.

The patient recovered from the operation, and progressed well until February 2nd, when erysipelas developed and he died. The tumour was exhibited at the Pathological Society, and was referred to a committee of investigation, which pronounced it to be an enchondroma undergoing ossification.

Probably the largest enchondroma of the upper jaw ever submitted to operation is one recorded by Mr. O'Shaughnessy, in his essay on "Diseases of the Jaws" (1844). The patient was a Hindoo, aged twenty-one, who had a tumour of the upper jaw, of a year's growth (?) which had attained an enormous size, as shown in the illustrations of the work in question, looking nearly as big as the patient's head. Mr. O'Shaughnessy removed the tumour, which weighed four pounds, and was nearly globular in form, having at its inferior surface a deep groove into which the lower jaw sank. On section it proved to be of dense fibro-cartilaginous structure, surrounded by a thin shell of bone in

the greater part of its extent. The patient made a good recovery.

These cases will serve to illustrate the leading features with regard to enchondroma. The disease appears ordinarily early in life, springing from the surface of the bone, or from the antrum, and then making steady progress either externally, as in the last-mentioned case, or internally as in the former ones. It produces absorption of the bone of the maxillæ in its progress, and protrudes beneath the skin, which, however, it rarely, if ever, involves. Its rate of increase is ordinarily slow, and there must, I fancy, be some error in the statement of Mr. O'Shaughnessy's patient, since it is difficult to imagine that a growth of that enormous size could have been produced in one year. In the early stage, the enchondromatous tumour may possibly be got rid of by absorbent applications; thus, Mr. Stanley (p. 147) mentions the case of a female, aged twenty-eight, who had a round tumour of the size of a hazel-nut on the front of the maxilla, which had been growing some months. This was ascertained, by the introduction of a needle, to be composed of cartilage with particles of bone dispersed through it. Under the local use of iodine two-thirds of the growth disappeared in the course of a few weeks.

Such a result cannot be hoped for when the tumour has attained any size, but provided it is still confined to the maxilla, a cartilaginous tumour is a favourable one for removal, owing to its solidity and rounded form, and the ease with which it is isolated. The first case in which M. Gensoul removed the superior maxilla was for a tumour of this kind. Ordinarily perfect immunity from return is obtained, provided the whole disease has been extirpated.

In many cases of enchondroma a certain amount of fibrous tissue is found mixed with the cartilage, and in some cases, particularly those of slow growth and of long standing, the fibrous has, to the naked eye, almost replaced the cartilaginous element. Of this an enchondromatous tumour, removed by Mr. Square, of Plymouth, in November, 1866, and kindly given me by that gentleman, is an excellent example.

The tumour was of the size of an orange, and occupied the right superior maxilla of a woman, aged forty-seven. It had been growing ten years, and Mr. Square successfully removed it. The preparation now in the Museum of the College of Surgeons, and of which a section has been made, shows a surface closely resembling a fibrous tumour, but in which cartilage cells are readily found under the microscope. The preparation shows a deep groove in the buccal surface of the tumour caused by the teeth of the lower jaw.

The ossific deposit, beginning at several separate points, which is not unfrequently found in connection with enchondromata of other parts of the body, may take place in enchondroma of the upper jaw. A very excellent example of this was published by the late Mr. Maurice Collis, of Dublin (*Dublin Quarterly Journal*, August, 1867), and the appearance of the patient is well shown in the lithographic illustrations which accompany that paper. The patient was fifty years of age, and the disease dated from his fourteenth year. It grew slowly at first, but latterly had increased with considerable rapidity. The tumour was firm and hard, but painless until recently, when brow-ague was complained of. The sight of the left eye was lost, the left nostril occluded, and hearing on that side somewhat dull. The tumour had expanded the cheek, pushed up the floor of the orbit, and depressed the hard palate. Mr. Collis successfully removed the growth, and the patient made a rapid recovery. The following is Mr. Collis's description of the tumour:

"The growth commenced in the antrum, filled it, implicated its walls, extended to the spongy bones, developing itself layer over layer, until the entire nasal cavity was filled. It then continued to grow, producing the immense deformity already described. Originally it had probably been an enchondroma, but as years advanced it ossified, beginning from the centre. The outer layers of the new growth were probably the most recent, as they contained some fragments of imperfect or degenerate cartilage. The whole was enclosed within a real bony layer, derived from the proper tissue of the spongy bones and of the walls of the antrum."

Osteoma.—The simplest form of osseous tumour of the upper jaw is a hypertrophy of the whole or of some portion of the bone. A case of Sir William Fergusson's has already been referred to (p. 225), in which this result was due to the presence of a tooth imbedded in the jaw; but the same thing may happen without obvious cause. The tumour is slow of growth and painless, and upon removal shows no deviation from the ordinary structure of healthy bone. An example occurring in a girl of sixteen, from whom Sir William Fergusson successfully removed a growth of the kind, will be found in the *Lancet*, July 26th, 1856.

In October, 1883, I had under my care in University College Hospital, a young woman, aged twenty-five, in whom a painless enlargement of the right upper jaw had been noticed for ten years, encroaching upon the palate and bulging out the cheek. I successfully removed the whole upper jaw, and on section the tumour was found to be simple bone, very dense, but otherwise healthy. One half of the specimen is in University College and the other in the College of Surgeons' Museums.

In the Museum of Charing Cross Hospital is a remarkable specimen of osseous tumour of the upper jaw, removed by Mr. Hancock. The whole jaw seems expanded anteriorly, and the outer compact plate is perfect, except at the part immediately below the infra-orbital foramen, where it has given way, and the cancellous structure forming the interior of the tumour is seen. Mr. Hancock, in referring to this specimen (*Lancet*, Jan. 13th, 1855), specially calls attention to the fact that the bone yielded to pressure to such an extent as to lead to some doubt as to its osseous nature.

A still more remarkable specimen of the same kind is preserved in the Musée Dupuytren at Paris, which is shown in Figs. 119 and 120 from the *Traité de Pathologie Externe*, by M. Vidal de Cassis. It is connected with the left superior maxilla, being limited internally by the intermaxillary suture, behind by the pterygoid process, above and externally by the malar bone. The tumour encroaches considerably upon the cavity of the mouth and reaches back as

far as the front of the spine. Its form is bi-lobed, and in the deep sulcus between the lobes can be seen a molar tooth. All the other teeth of the jaw have disappeared, and there is no trace of their alveoli. The left orbit and nasal fossa are not sensibly diminished in size, but the cavity of the mouth is almost entirely occupied by the posterior lobe of the tumour. The lower jaw has, in this case, undergone several remarkable alterations. It must at first have pressed upon the growth and produced the deep sulcus between the lobes, but in its turn the tumour has reacted upon the lower jaw with the following effect: It has caused a double luxation

FIG. 119.

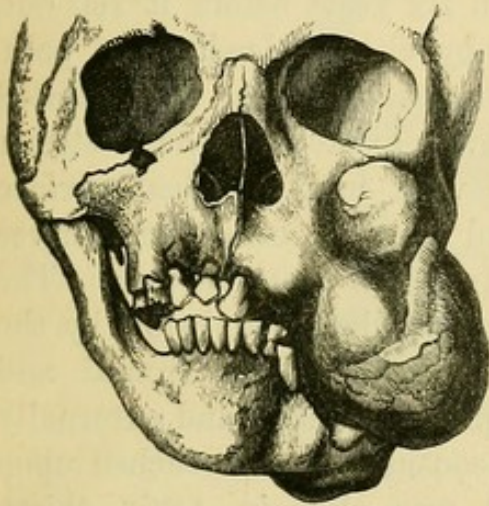
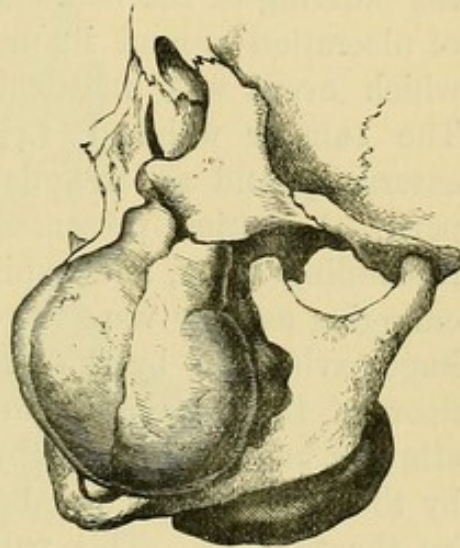


FIG. 120.



of the jaw, the left condyle resting against the root of the zygoma and the glenoid cavity being filled with soft material. The teeth of the left side of the lower jaw have disappeared, and absorption of part of the coronoid process and the whole of the alveolus has taken place, so that only the base of this part of the bone is left. The outer surface of the tumour is smooth, and presents numerous vascular grooves of good size; at many points it is perforated with holes. The vascularity of the other bones of the face does not appear augmented.

In the Museum of Netley Hospital, which includes the preparations formerly at Fort Pitt, Chatham, there is a specimen of large osseous tumour of the upper jaw closely resembling that last described, but of smaller size.

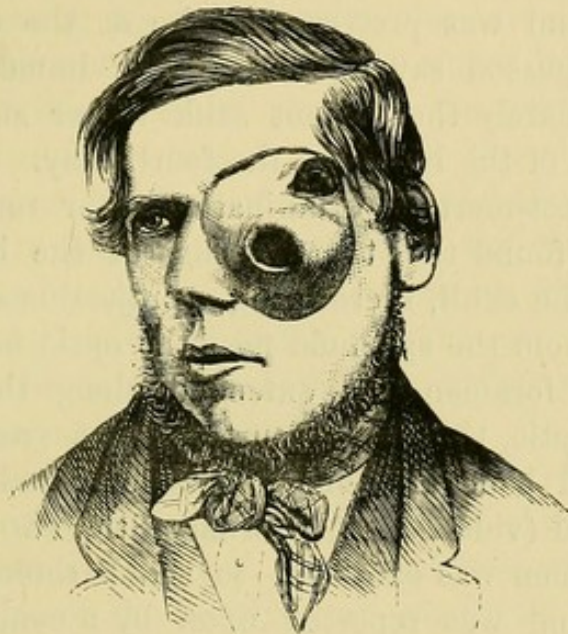
Besides this form of bony tumour, due apparently to an increase of the cancellous structure of the bone, specimens of tumour as hard as ivory have from time to time been met with. Perhaps the most remarkable of these is one described by Mr. Hilton, in the *Guy's Hospital Reports*, vol. i, p. 493, from the fact that the tumour separated spontaneously from the face. The patient was a man aged thirty-six, who, twenty-three years before Mr. Hilton saw him, noticed a pimple below the left eye, close to the nose, which he irritated, and from that spot the tumour appears to have originated. The tumour in its growth displaced the eyeball, giving rise to excruciating pain, which subsided on the bursting of the ball. It began to loosen by a process of ulceration around its margin six years before it fell out, which event was unattended by either bleeding or pain. The tumour weighed $14\frac{3}{4}$ ounces. It was tuberculated externally, and an irregular cavity existed at the posterior part. A section presented a very hard polished surface resembling ivory, and exhibited lines in concentric curves enlarging as they were traced from the posterior part. The huge cavity left by the tumour was bounded below by the floor of the nose and antrum, above by the frontal and ethmoid bones, internally by the septum nasi, and externally by the orbit, which had been considerably encroached upon by the tumour. This patient was alive in 1865, thirty years after the prolapse of the tumour.

A case in many respects resembling Mr. Hilton's case was under the care of Sir William Fergusson, whom I had the opportunity of seeing operate upon it. The patient was a young man of twenty-one, who had first noticed the swelling on the left side of the face twelve years before. It grew for six or seven years, and then remained stationary. Two years before he had consulted a quack, who attempted to destroy the growth with caustic, and produced the large hole seen in the lower part of the tumour (Fig. 121).

On admission into King's College Hospital there was a swelling on the left side of the face about the size of a large apple, extending from the eyebrow to a line less than

one inch above the mouth. Internally, it encroached upon the nose, displacing it a little, the nasal bone being pushed forwards and the left ala flattened on the columna; the mass was felt by the finger in the mouth above the gums. The nostril on the same side was perfectly blocked up, the patient being totally unable to breathe through it. The right nostril, however, was quite free. Outwards, the tumour extended to the angle of the orbit; the arch was, however, not displaced, but the tumour extended slightly above it. The

FIG. 121.



floor of the orbit seemed displaced. The eyeball was seen imbedded in the most prominent and central part of the tumour, and removed more than an inch from its natural position in the orbit, which was entirely blocked up by the mass. There was no extension into the pharynx. The tumour was everywhere hard, with a slight blush over the surface. In its centre was a round opening, produced by the caustic applied two years previously, of about the size of a shilling, deep, and displaying in its floor black necrosed bone, and discharging pus. The patient said he had suffered neither headache nor pain in the tumour since its commencement, twelve years before, and that his sight had been unaffected.

Sir William Fergusson operated upon this patient on November 30th, 1867, and succeeded in removing the whole of the prominent tumour, weighing $10\frac{1}{2}$ ounces, which consisted in all its anterior part of nodulated bone as hard as ivory, and posteriorly, of very dense ordinary bone mixed with a small amount of cartilage. A section showed an ivory-like mass closely resembling Mr. Hilton's specimen, connected with a mass of very much condensed bone. The tumour sprang apparently, as in the former case, from the upper part of the maxilla, and had invaded the antrum, orbit, and nostril. The palate was in no way involved in the growth, and was preserved entire at the operation, Sir William Fergusson sawing horizontally immediately above it. Unfortunately the patient sank rather suddenly, from inflammation of the lungs, on the fourth day.

At the post-mortem examination, after removal of the brain, it was found that the affection of the bone involved the base of the skull, there being a projection of the size of a hazel-nut from the sphenoid near the optic foramen. This involved the foramen and extended along the sphenoidal fissure, the optic, third, and fourth nerves passing through the condensed bone of which it was composed. The brain was unaffected (vide *Lancet*, February 8th, 1868).

This specimen was exhibited to the Pathological Society of London, and was reported upon by a committee. The report of this committee, drawn up by Mr. Hulke, which will be found *in extenso* in vol. xix of the *Pathological Transactions*, expresses an opinion that "the hard part of the tumour has been directly formed by the exogenous growth of successive layers of dense bony tissue under the periosteum, which opinion is confirmed by the absence from the hard tissue of the regular Haversian systems so characteristic of secondary bone."

In both these cases the tumour appears to have taken its origin in the upper wall of the antrum and to have grown forwards; but tumours of the same kind have been found completely within the superior maxilla, the anterior wall of which has been merely expanded by the growth behind it.

Of this, two cases reported within the last few years by M. Michon and Dr. Duka are good examples, and they will be elucidated by reference to a case recorded by M. Demarquay.

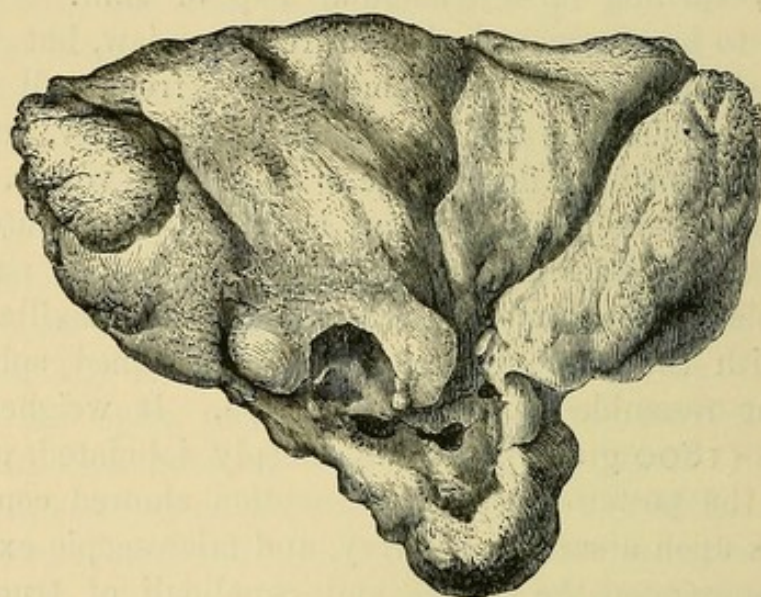
M. Michon's case is reported in the second volume of the *Mémoires de la Société de Chirurgie de Paris* (1851); his patient being a man of nineteen, who had a large tumour of the right upper jaw, which had existed for three years. The tumour was rounded and hard, and had pushed up the eyeball considerably, and closed the right nostril, but the palate was not affected. M. Michon operated in January, 1850, by turning up a triangular flap of skin. He had intended to have removed the entire upper jaw, but having with considerable difficulty removed the front wall of the antrum, he found the tumour lying in the cavity, and connected only with the floor of the orbit and the vomer. After an operation extending over an hour and six minutes, and without anæsthetics, the tumour was at length removed. The whole of the vomer and a part of the maxilla came away with the tumour, which was a flattened sphere, or somewhat resembled a heart in shape. It weighed 120 grammes (1800 grains), and was deeply lobulated, particularly on the posterior aspect. A section showed concentric markings upon a surface of ivory, and microscopic examination demonstrated the lacunæ and canaliculi of true bone. The patient made a good recovery.

Dr. Duka's case is reported in the *Pathological Society's Transactions*, vol. xvii, and occurred in a female native of Bengal, aged twenty-six, and on the right side of the face, which was not much deformed. There was a discharge from the right nostril, which was obstructed, and on examination a hard tumour was found within it, *which was movable*, but could not be extracted, and which had existed six years.

Dr. Duka, failing to extract the tumour by laying open the nostril, resorted to the somewhat unusual proceeding of cutting a wedge out of the hard palate, and thus, after an operation of three-quarters of an hour, without chloroform, succeeded in removing the growth. The patient recovered

The tumour is preserved in St. George's Hospital Museum, and is figured in the *Pathological Transactions*, from which the accompanying illustration (Fig. 122) is, by permission, taken. It has an oblong shape, and is not unlike a middle-sized potato, with depressions and elevations passing irregularly over it. The upper part, which is believed to have been in contact with the cribriform plate of the ethmoid bone, exhibits corresponding delicate depressions, with other deeper sulci in front, behind, and on the sides, probably for the passage of blood-vessels. At the lower surface is a large

FIG. 122.



nipple-like process, smooth throughout. This lay in contact with the palatine process, and it has the same dark appearance as the anterior part of the body, which presented at the nostril. At the base of this process is a large hole piercing it quite through, and allowing the tip of the little finger to enter it. In this lacuna was a polypoid mass which contained a nucleus of cartilage, round and flat like a small-sized lentil. It was this nipple-like prominence impinging upon the nasal process which prevented the removal of the tumour, without interfering with the superior maxillary bone. The whole bony mass, which is of a compact ivory-like character, weighs 1060 grains: its long diameter is nearly three inches, the short one an inch and two lines, and the

longest circumference seven inches. The microscope gives evidence of structure closely resembling that of M. Michon's tumour. There are no distinct Haversian systems, but abundance of lacunæ arranged around vascular canals. In some parts of the tumour the characters are very much those of simple ossified cartilage, clusters of large ossified cells being packed closely together.

This case is remarkable from the fact that the attachment of the tumour had given way, and that it was therefore loose in the antrum. It would have appeared to be unique in this particular, but for the publication in the *Gazette Médicale de Paris* (April 20th, 1867), of a very similar case of non-adherent exostosis, or osteoid tumour, by M. Demarquay, of which the following are the leading features:

A gentleman, aged fifty-three, in good health, but the subject of syphilis, had a swelling of the left side of the face, which had existed for twenty years. It gave no inconvenience except the disfigurement, until six months before he applied to M. Demarquay, when an abscess formed and burst, leaving a fistula. After this neuralgia came on, and other abscesses formed, rendering the face swollen and red. On examination several fistulæ were found both within and without the mouth. There was evidently suppuration within the antrum, probably due to a sequestrum.

At the operation, on Jan. 4th, 1867, it was found impossible to extract the sequestrum, and M. Demarquay therefore removed the entire maxilla, and the patient recovered.

The jaw showed an increase of size and density; the front wall of the sinus was thrown forward, so as to present the segment of a sphere, and was thickened so that its resistance was increased. The posterior part was also enlarged, and had projections upon it, one of which also pushed up the floor of the orbit. There were numerous sinuses in various parts, through which pus escaped.

On section, a white osteo-cartilaginous substance was found filling up the whole cavity of the antrum, but not attached to its walls. In some parts this was of a more fibrous character, whilst in others it was dense bone. In the centre

was a large fragment of bone, of a blackish colour, and closely resembling a sequestrum. This was surrounded by some smaller portions, and by a cavity containing a quantity of pus, into which the sinuses could be traced. It was impossible to tell from which part of the wall the tumour had sprung.

Considerable difference of opinion exists concerning the pathology of these tumours. It has been suggested that they are formed by the ossification of an enchondroma. In no case, however, have typical cartilage cells been found in any stage of the growth of an osteoma. Other observers look upon them as outgrowths from the bone, as exostoses, in fact. The fact that the connection between the tumour and the bone is so slight or may even be absent militates against this view. The microscopical structure of these growths again is not like that of exostoses.

It has been suggested that osteomata found in the antrum originate in the muco-periosteal lining, by the cells of the periosteum depositing calcareous salts in the mucous membrane, or in the fibrous odontomata of Broca.

In the absence of sufficient evidence it is impossible to give the preference to any one of these views, and for the present the question must be considered an open one.

CHAPTER XVII.

MALIGNANT TUMOURS OF THE UPPER JAW.

Sarcoma and Carcinoma.

ACCORDING to the statistics of O. Weber, carcinoma of the upper jaw is much more frequent than sarcoma. In the great majority of cases collected by him the diagnosis was made by the naked eye and not by the microscope, and this fact is sufficient to invalidate his conclusions upon this point. Surgeons at the present day are unanimous in their opinion that the upper jaw is more often the site of sarcoma than of carcinoma.

1. *Sarcoma*.—This is the only malignant growth which commences in the jaw itself. The other malignant tumours, the carcinomata, originate in some neighbouring epithelial structure, and secondarily invade the bone. It is usual, in dealing with sarcomata, to divide them into two main groups; those originating in the bone itself, the central sarcomata, and those originating in the periosteum, the peripheral or periosteal sarcomata.

(a) *The Central Sarcomata*.—These originate in the interior of the bone, and in the great majority of cases present the structure of *myeloid sarcoma*. In a few cases the myeloid structure may be absent or may be largely replaced by round or oval cells, in which case it is called a *round-celled sarcoma*. When the myeloid sarcoma is situated in the alveolar portion of the jaw, it is called a *myeloid epulis*, and this has already been described in the chapter on Diseases of the Gums (p. 236).

The diagnosis of myeloid sarcoma in the upper jaw, in

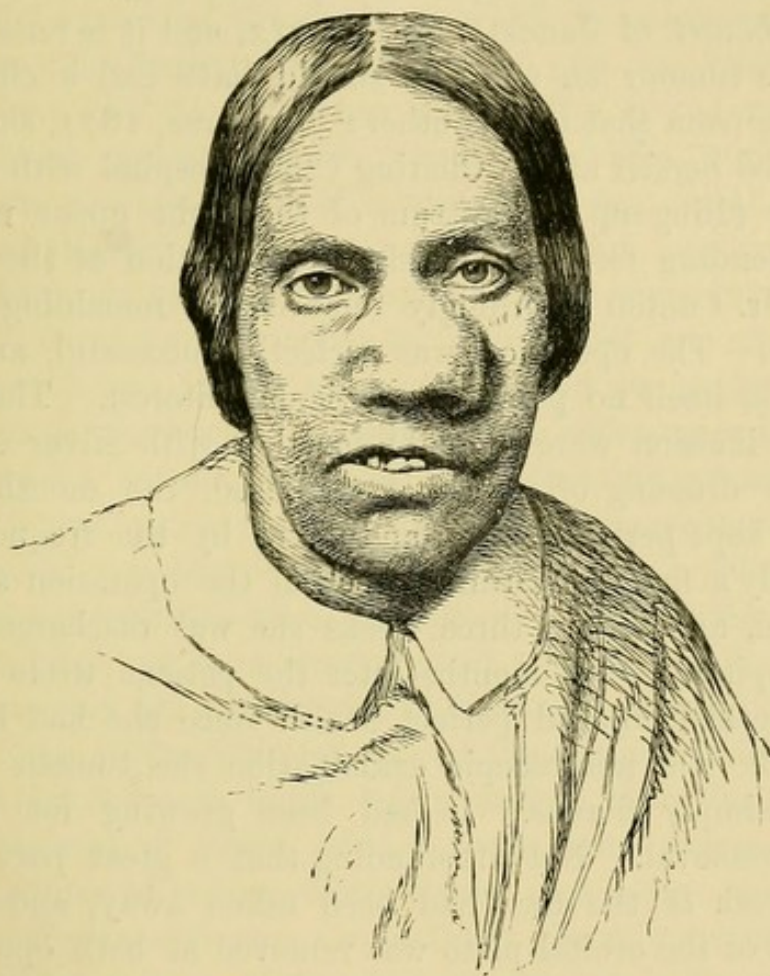
situations other than the alveolar process, is by no means easy. The bone is slowly expanded, much as it would be by a cyst, or by any benign tumour. If the disease originate on the exterior of the bone, or, when springing from the interior, if sufficient absorption of the bone have taken place to allow the tumour to appear beneath the mucous membrane, the characteristic dark maroon colour of the tumour may be perceived. Cysts occasionally form in the substance of a myeloid tumour, and an exploratory puncture of these may yield fluid in which the characteristic myeloid cells may be discovered microscopically.

Myeloid disease occurs mostly before the age of twenty-five. Sir J. Paget ("Surgical Pathology," p. 524) quotes two cases of Sir William Lawrence's, occurring in the upper jaws of women of twenty-one and twenty-two years of age, the latter of which illustrates extremely well the recurrence of myeloid growths (of which there can be no question), and also the very curious fact that a tumour on the opposite side to that removed, and which presented appearances exactly corresponding to it, spontaneously subsided. The specimen is in St. Bartholomew's Hospital Museum.

Fig. 123 shows a patient from whom Mr. Canton removed a myeloid tumour in 1864. She was thirty-five years old, and the tumour appeared to have followed a blow. It had been twice removed before she came under Mr. Canton's care, and that gentleman successfully removed the left superior maxilla with the tumour, a portion of which hung down into the pharynx. The tumour was brought before the Pathological Society of London, in December, 1865, and the following is a description of the tumour, by Messrs. Bryant and Adams, to whom the specimen was referred: "The parts placed in our hands for examination consisted of the left superior maxillary bone, including its orbital plate, from the inferior surface of which appeared to grow a large tumour, which filled the cavity of the antrum, and projected forwards and inwards into the nasal cavity. There was also a second and loose portion, the size of a walnut, which appeared to have been broken off during the operation, and

was said to have projected posteriorly towards the pharynx. The external wall of the antrum was not expanded so fully as is usually found in tumours of the antrum. The tumour, which had been some time in spirit, was of a firm fibrous nature and irregularly lobulated, and it had a dense capsule.

FIG. 123.



On section, the structure presented a large amount of fibrous tissue, arranged in a curvilinear form, intermixed with other tissue not easily broken up. Microscopically examined, the tumour consisted of an abundance of fibrous tissue, which formed the stroma, containing in its meshes innumerable cells, generally of a circular or ovoid form, varying from two to three diameters of a blood-corpuscle, and some of a still larger size. The cells were all nucleated, usually containing several nuclei, and frequently presenting

a granular appearance. Large compound cells were abundant in the posterior and softer lobe of the tumour, and a few elongated cells were seen amongst the fibrous tissue. These large compound cells presented very much the appearance of the poly-nucleated cells met with in myeloid tumours."—*Transactions of the Pathological Society*, vol. xvii.

The subsequent history of this patient is given as follows in the *Lancet* of January 26th, 1872, and it is remarkable that the tumour on one side should have had a character differing from that on the other: "In June, 1871, she again presented herself at the Charing Cross Hospital with a large tumour filling up the antrum of the right upper maxilla, and extending forwards, causing a projection of the upper lip. Mr. Canton accordingly removed the remaining upper maxilla. The operation was perfectly successful, and presented in itself no points of particular interest. The edges of the incision were brought together with silver sutures, and no dressing of any kind was used, the mouth being simply kept perfectly clean and sweet by the frequent use of Condyl's fluid. Within a week of the operation she left her bed, and within three weeks she was discharged from the hospital. Five months later the patient wrote to say that she had enjoyed perfect health since she had left the hospital. On microscopic examination the tumour proved to be simply fibrous. It had been growing for a year before removal. Notwithstanding that a great part of the framework of the face had been taken away, and that a portion of the orbital plate was removed at both operations, there was remarkably little deformity of the face. The patient had lost all power of muscular expression, but beyond this there was nothing to attract attention, except a slight falling in of the upper lip on the right side. There was no falling in of the nose, the raphé of what was the roof of the mouth deriving great support from a firm pseudo-palate, which had formed of cicatricial tissue after the first operation. The cicatrices of the incisions were scarcely noticeable, as they followed the natural lines of the face."

Mr. Canton also obliged me with the portrait and history

of a case of still more marked myeloid disease of the upper jaw, which was also under his care. The patient was forty-six years of age, which is decidedly advanced for the disease, and the tumour grew with unusual rapidity. Mr. Canton removed the jaw in Dec. 1866, and I had the opportunity of seeing the patient in Jan. 1867, when he was quite well, but had still a small fistulous opening on the face. Dr. Tonge carefully examined the tumour (which is preserved in the Museum of Charing Cross Hospital), and has kindly furnished me with the following report upon it and upon the microscopic appearances it presented: "The tumour was about the size and shape of a large hen's egg that had been flattened slightly in the transverse direction, and measured (after being in moderately strong spirit for some days) about two and three-quarter inches in length, from one and three-quarters to two inches transversely, and about one and a half inch in thickness. It was of firm consistence throughout, and on section presented a whitish appearance, with a small pink patch or two, and a whitish, creamy-looking juice could be scraped from the cut surface. The microscopical appearances of a portion of a thin section of the tumour, that had been preserved in glycerine and coloured with carmine, are represented in the accompanying drawing, which was taken with the aid of the camera lucida. The fibrous element was much less abundant than the cellular, and consisted of white fibrous tissue, with numerous fine curling fibres of yellow elastic tissue, and many small oval and rounded nuclei were imbedded in the fibrous structure. The greater portion of the tumour seemed to be composed of cells. These were mostly of an irregularly-rounded form, often with pointed processes, and some shuttle-shaped and spindle-shaped, of a somewhat trapezoidal form, were not uncommon, while a few cells presented the character of those distinctive of myeloid tumours. All the cells contained one, and often two, very large and generally oval nuclei, with one, two, or three nucleoli, and a variable number of oil globules. The myeloid cells observed were of irregular outline, and contained from three to five nuclei,

with single or double nucleoli—one very large cell contained six nuclei.

“ These cells were not very numerous, but appeared sufficiently so to justify the application of ‘ myeloid ’ to the tumour, though, to the naked eye, and on a superficial microscopical examination, it presented many of the appearances of cancer.”

In the Museum of the College of Surgeons are two specimens consisting of the two superior maxillæ of a woman, aged twenty-one, which were given me by Messrs. Andrews and Coates, of Salisbury, who removed them. The left upper jaw has been macerated, showing a calcified tumour springing from the anterior part; the right jaw has a growth involving the anterior portion and extending into the nasal fossa. The growth in these cases was regarded by the operators as an example of scirrhus, but I am enabled by the kindness of Dr. Lush, of Weymouth, to correct this statement, by a record which he has of the microscopic details observed when the tumours were recent, as follows: “ A section showed numerous spheroidal cells with one, two, or more nuclei, free matter and some compound cells.” The tumour should therefore doubtless properly be regarded as myeloid.

The history of the patient is the following: Jane F., aged twenty-one, was admitted into the Salisbury Infirmary, July 24th, 1858, for a tumour of the left upper jaw. The operation of removal of the left upper jaw was performed by Mr. Andrews, and she was made an out-patient Aug. 28th, 1858. She was readmitted on Oct. 1st, 1859, under Mr. Coates, having a fortnight before perceived a small growth occupying the edge of the alveolar process at the site of the left upper incisor, which became rapidly exquisitely painful, and involved the alveolus of the right side, and also the upper lip. Mr. Coates removed the remaining right superior maxilla under chloroform, Oct. 13th, 1859. The portion of the lip covering the small tumour (which was about the size of a hazel-nut) was also removed, and found to be infiltrated with disease. The patient was discharged cured Nov. 5th, 1859, and was in perfect health in 1866.

Vascular tumours, closely resembling erectile tumours

in other parts of the body, have been occasionally met with in the upper jaw.

There is no doubt that the great majority of pulsating tumours of bone are examples of very vascular sarcomata, and the question naturally arises whether certain vascular tumours, met with in the upper jaw, which have hitherto been regarded as non-malignant, ought not to be classed among the sarcomata.

It must be remembered that these vascular growths of the upper jaw were described many years ago, before the methods of diagnosis employed at the present day were available. Of recent years no such growths have been met with, or if they have, they have been regarded as vascular sarcomata.

Mr. Liston, in 1841, successfully removed a specimen of the kind, which is preserved in University College, from a young man, aged twenty-one. The tumour was of more than three years' growth, and projected into the nares and pharynx, forming a tumour beneath the cheek; but the preparation shows that the alveolus and all the lower and anterior part of the maxilla were not involved in the disease. The tumour was not painful, but frequent hæmorrhages had taken place from its surface. The case will be found in the *Lancet*, Oct. 9th, 1841. Mr. Liston removed the jaw, cutting completely beyond the disease, and remarks concerning it (*Lancet*, Oct. 26th, 1844): "It was a curious-looking tumour, and it struck me that it was of a fibrous character, not growing from the jaw, but involving it. Mr. Marshall some months afterwards discovered that the whole mass was erectile. . . . You will see that it is as complete and beautiful a specimen of an erectile tumour as any that I have yet shown you."

The tumour, which is in the Museum of University College, is described as follows in the catalogue by Mr. Marcus Beck: "A large tumour of the pterygo-maxillary fossa removed with the upper jaw. The specimen includes the whole of the maxilla except a narrow strip of its palatine process, and small portions of the nasal and malar processes, the

whole of the lower part of the palate bone, and the lower portions of both pterygoid plates of the sphenoid, and the inferior turbinated bone.

"The tumour, which measures about three inches in the antero-posterior direction, has grown from the posterior surface of the maxilla, and filled the spheno-maxillary and lower part of the temporal fossæ, and has passed far backwards under cover of the ramus of the inferior maxilla so as, on the inner side, to have projected within the pharynx; and from the anterior part of the tumour a portion has grown forwards beneath the hard palate into the mouth. The posterior half of the tumour is deeply cleft into lobes. On the inner aspect of the parts a piece of the tumour has been cut away; the divided surface has a uniformly open, cavernous structure, like that of the corpus spongiosum penis, the meshes of which are nowhere occupied by a solid substance, and probably allowed of the circulation of blood through them. The tumour is everywhere bounded by a dense layer of fibrous tissue. The cavity of the antrum is entirely unaffected."

M. Gensoul also met with an erectile tumour springing from the antrum, in one of the cases from which he successfully extirpated the upper jaw.

Mr. Butcher, of Dublin, has described ("Operative and Conservative Surgery," p. 249) a case of successful removal of the right upper jaw, on account of a large fibro-vascular tumour springing from the antrum of a lad of sixteen. Nine months before admission he had had a polypoid growth removed from the nostril, giving rise to severe hæmorrhage. It reappeared in a month, and increased, so that when he came under Mr. Butcher's care there was considerable deformity of the face, and the nostril was filled with the tumour, which projected behind the soft palate. After the boy had been in hospital a few days the tumour suddenly increased with great rapidity, and interfered so much with respiration and deglutition that Mr. Butcher at once removed the jaw, and the patient made a good recovery.

The following is the description given of the tumour:

"The structure of the tumour presented many interesting peculiarities. Its attachment and origin sprang from the outer part of the antrum. Not only was it incorporated with the lining membrane, but it likewise implicated the osseous wall. The surface from which it sprang in the recent state was softened, vascular, and pulpy, the upper surface of the tumour was lobulated where it encroached upon the orbit, and elevated its floor; the lobules were of various sizes—some very small, but each consistent in structure, and invested by a dense capsule in a similar way to the larger masses of the growth. The entire tumour was remarkable for its great vascularity, which was more particularly confined to the posterior and upper surface; while on section the structure was dense by comparison, pale, eminently firm, and partaking of a fibrous matted nature. This integral arrangement was very manifest under close examination with the microscope, and cleared away the suspicion which, on superficial inspection, might have been created of encephaloid disease being the synonym most applicable to the growth. There was a total absence of all nucleated cells, either globular, caudate, or spindle-shaped; and, above all, the section of any part only yielded a minute quantity of serum or blood on pressure, and not the true succus of cancerous tissue. The tumour, though destructive to the neighbouring parts by pressure, yet did not appropriate or incorporate them in its structure. This peculiarity of non-malignant growths was strikingly manifest in the present instance; for, by pressure producing interstitial absorption, the cancellated structure of the ethmoid and inferior spongy bones was attenuated and removed; and by the same process the vomer was detached from its position—a few shreds of it being spared and hanging loosely on the sinistral surface of the tumour. The vascularity of the growth, though remarkable on the surface, yet did not permeate its texture; hence a tendency to degenerate by assumed depravity of action was lessened. Again, the vascularity of the surface will readily account for the repeated and profuse losses of blood—a point of great practical value

because placing the surgeon on his guard as to the importance which should be attached to those repeated losses, in constituting a diagnostic feature confirmatory of malignant disease."

(b) *The Periosteal Sarcomata*.—These are nearly always either spindle-celled or round-celled sarcomata. It is very rarely that a myeloid growth originates in the periosteum, but they have been met with.

The *Spindle-celled Sarcoma* is of frequent occurrence in the upper jaw, forming many of the specimens formerly indiscriminately named "osteosarcoma." It is usually of a yellower colour than the fibrous tumour and of softer consistence, and on section it exudes a serous fluid. The spindle-shaped cells are often of great length and size, and each cell contains one or more oval nuclei, the intercellular substance being homogeneous.

Under the name of "albuminous sarcoma," Mr Liston has described a case which appears to be of this kind, in the *Lancet*, Nov. 26th, 1836, which proved fatal after removal of the tumour. The patient was twenty-four years of age, and the disease appeared to have originated in a blow, and grew with tolerable rapidity. The tumour, which is preserved in the College of Surgeons' Museum, is oval in form, its chief diameters being about three inches by two inches, and contained spaces in which was a glairy fluid, coagulable by heat. Mr. Lane successfully removed, in 1861, *both* upper jaws, together with the vomer, &c., which were involved in an "albuminous sarcoma," from a man, aged forty-eight, whose case will be found in the *Lancet*, Jan. 25th, 1862. The tumour implicated both superior maxillary bones and filled both nostrils. It formed an extensive convex irregular swelling in the mouth, which pressed down the tongue. Very little bony material could be distinguished in the position of the palatine processes of the maxillary or palate bones, and the growth which occupied their place was soft and elastic, and was ulcerated in two or three spots, of the size of a fourpenny-piece. The growth first showed itself within the left nostril three or four years previously,

presenting the appearance of a nasal polypus, and was removed three times.

In the same number of the *Lancet* is the report of a case of tumour, also removed by Mr. Lane, from a child of nine years, which presented much the same characters. The report states that portions of the growth, placed under the microscope, presented the characters of a fibro-nucleated structure, being composed of minute fibres, in which were disseminated numerous small oval nuclei about the size of blood globules, measuring from the four-thousandth to the three-thousandth part of an inch in diameter.

In the *Lancet* for August 31st, 1861, is the report of a remarkable case of fibro-cellular tumour of the jaw, under the care of Sir William Fergusson, in which the patient was the subject of two tumours, one situated in the right cheek, the other in the antrum and roof of the mouth. The growths were, however, perfectly distinct from one another, and both were removed at a single operation, which was attended with the best results. Sir William Fergusson had seen the patient twelve months before, and the disease then presented so malignant an aspect that he dissuaded her from undergoing any operation. Some months later, the disease in the mouth was found to be an ulcerated, sloughy-looking mass, and the finger could be readily passed alongside of it into the antrum. Perceiving that its progress had been slow, and that it was within the reach of surgical aid, he thought he would give her a chance of relief, more especially as there was no development of disease in any other situation, and the tumour in the cheek was quite distinct from that in the jaw.

The report states that the softer part of the disease appeared, on microscopical examination, to consist mainly of a fibro-granular matrix, containing numerous corpuscles, round, regular, of uniform size, granular, and with no appearance of nuclei. The much firmer tumour of the cheek contained corpuscles of a similar character, with a large proportion of the fibrous element.

The tendency to ulceration which was exhibited in this

case is a marked feature of this form of disease, and not unfrequently leads to difficulty in solving the question of malignancy. It is seldom that, in the case of the upper jaw, the skin becomes involved in the disease, but in the lower jaw this frequently happens, and large fungous protrusions occur which may be mistaken for open cancer. The history of the case, together with the absence of any enlargement of the lymphatic glands, is sufficient to mark the nature of the growth.

Ossification frequently takes place in spindle-celled sarcomata, and when this is the case the terms *ossifying* or *osteoid sarcoma* or *osteo-sarcoma* are often employed.

It is very rare for fatty degeneration to take place in sarcomata; so rare, indeed, that it is not mentioned by most authors.

In his work on the "Diseases of the Bones" (p. 283), Mr. Stanley mentions "fatty" tumours of the superior maxilla. He refers (p. 104) to a specimen in St. Bartholomew's Hospital Museum, of which the following is the description:

"Sections of a tumour which occupied the situation of the superior maxillary bone, and was removed by operation. The whole of the natural structure of the superior maxillary bone has disappeared. The mucous membrane which covered the palatine surface of the bone extends over a part of the tumour. The morbid growth consists of a moderately firm fatty-looking substance, with minute cells and spicula of bone dispersed through it.

"From a man, aged forty-six. The disease returned after the operation, and the patient died in consequence of hæmorrhage from ulceration of the internal carotid artery, which became involved in an extension of the disease."

This, as far as can be judged, would appear to have been an example of spindle-celled sarcoma or osteo-sarcoma, which had undergone fatty degeneration; and the same may, I imagine, be said of the cases referred to by Von Siebold as osteo-steatomata.

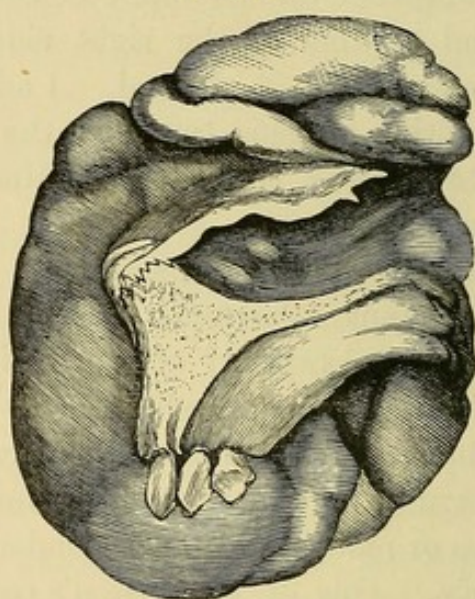
Chondro-sarcoma, in which spindle or round-celled sarco-

matous elements are mixed with the cartilage forming the bulk of the tumour, occurs occasionally in the upper jaw, and is apt to be followed by secondary deposits in the lungs, this clinical fact distinguishing it from the ordinary enchondroma. In 1879, I was consulted respecting a young lady who, two years before, had had removed from the floor of the orbit a small growth which grew from the orbital plate and displaced the eyeball. The growth recurred, and when I saw the patient both nostrils were completely blocked; there was slight bulging of the antrum, and nobbly swellings of the size of a sixpence on the raphé of the hard palate on the left side, and another on the right side of the palate. The frontal bone also seemed affected. I advised against an operation, but another surgeon removed the upper jaw, and was unable to take away the whole of the disease, which proved to be chondro-sarcoma.

The *Round-celled Sarcoma*, medullary, or encephaloid sarcoma is of frequent occurrence in the upper jaw, and from its vascularity and rapidity of growth it has often been mistaken for medullary cancer, which in its clinical history it closely resembles. In the majority of cases the disease begins in the antrum, for the protruding masses, which are found in the nose or mouth, are but secondary to a formation within that cavity. One of Mr. Liston's cases is conclusive on the point, the preparation being preserved in the College of Surgeons, with the following description: "The greater part of a left superior maxillary bone, with a tumour formed in the antrum, removed by operation. The tumour measures about two inches in its greatest diameter, and projects forwards over the right canine and bicuspid teeth. It is pale, soft, and homogeneous, and the surface of its section is like that of brain. At the upper part its tissue is broken, and was mixed with blood; in its recent state it was more brain-like. The patient, William Thomson, was sixteen years old. The disease had been observed for two years. He had often suffered pain in the situation of the first molar tooth, which had been in a decayed state for a considerable time previous to his discovering any swelling

of the cheek. During the two months preceding the operation the tumour had grown rapidly. Three years and a half after its removal the patient was in good health."—See Liston's paper, *Medico-Chirurgical Transactions*, vol. xx. In this case, which was fortunately submitted to operation at a very early period, the disease was still confined to the antrum, and the removal of the jaw therefore included the whole of it. Unfortunately, in too many cases the disease is much more advanced before it is brought under the

FIG. 124.



notice of the surgeon, when therefore the possibility of complete extirpation is much reduced.

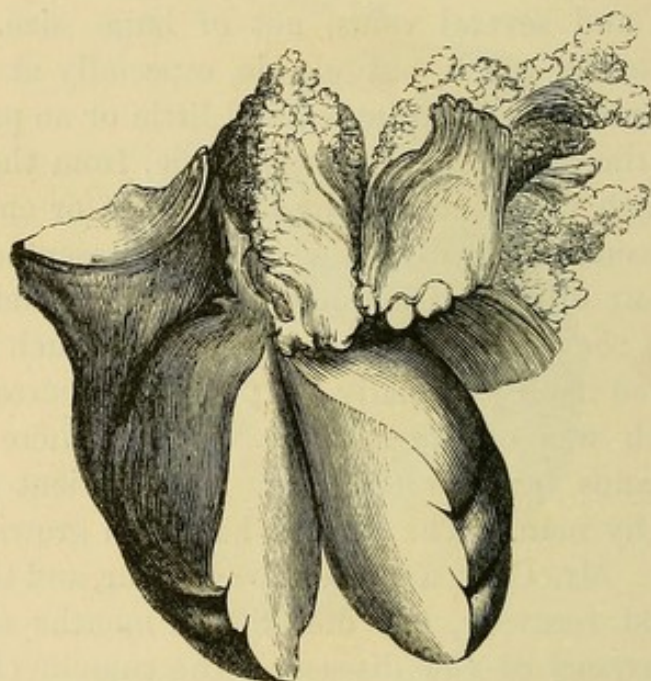
Round-celled sarcoma of the jaw closely resembles the same disease in other parts of the body, rapidity of growth, with softness, and a tendency to fungate on the part of the tumour itself, being the main characteristics. The direction which the disease takes, and the effects therefore which it produces, will vary in different examples. Frequently it forms a considerable projection on the cheek, causing epiphora from closure of the nasal duct, and œdema of the lower eyelid; and in the later stages enlargement of the facial veins, without the least invasion of the hard palate, and with but slight interference with the nostril. The specimen of medullary sarcoma represented in Fig. 124 (College of Sur-

geons' Museum), illustrates the point, a large tumour being developed externally. The patient was a man, aged forty-four, who came under the care of Mr. Craven, of Hull, in 1863, with a large rounded tumour of the right cheek, of the size of an orange, extending from the external process of the frontal bone and zygoma above, to the angle of the mouth below (almost completely closing the right eye), and from the side of the nose to the ramus of the lower jaw. The colour of the integument was natural, except at the upper part below the eye, where it presented a rather livid appearance, and several veins, not of large size. It was very firm to the touch, but elastic, especially at the outer part. Pressure and handling caused little or no pain. The interior of the mouth on the right side, from the alveolar process (which was concealed by the growth or embraced in it) to the inside of the distended cheek, presented a large excavated sore of a greyish sloughy aspect and foetid odour. This part of the tumour was softer to the touch than that which showed itself externally. It did not encroach on the palate, which was of the natural width. There were no enlarged glands beneath the jaw. The patient seemed a pretty healthy man. The tumour had been growing seventeen weeks. Mr. Craven excised the tumour, and the patient made a good recovery, but died fifteen months afterwards from a recurrence of the disease. The tumour (Fig. 124) was rounded and lobed, especially that part which occupied the pterygo-maxillary fossa, and was firm on section. The cut surface was smooth, becoming slightly granular after prolonged exposure. To the naked eye the tumour had the appearance of a malignant growth. Under the microscope, the juice scraped off the cut surface showed no fibrous element, but simply a mass of apparently broken-up cells and granular matter.

On the other hand, the disease may at an early period involve the alveolus and palate, or the nose, and it is these cases which are sometimes attributed to the presence of decayed teeth, or are mistaken for ordinary nasal polypi. Of this, a preparation which is shown in Fig. 125, and which

was also from a patient of Mr. Craven (to whom I was indebted for both valuable preparations), is an instance. Here the disease showed itself first in the gums, where it formed a fungating mass, and soon obstructed the nostril. This last symptom was due to a fungus, almost papillary in appearance, which springs from the nasal surface of the tumour. Mr. Craven removed the tumour in March, 1866, but within a year the disease returned and proved fatal.

FIG. 125.



The disease may extend across the median line and involve portions of both maxillæ, especially the palatine plates. This is not necessarily a bar to operative interference, provided other circumstances are favourable, but when the disease exhibits the appearance shown in Fig. 126 the case is obviously one beyond the aid of surgery. The patient, aged twenty-four, was sent to me in January, 1868, by Mr. Harding, to whom he had applied for the extraction of some teeth, thinking to obtain relief thereby. Four and a half years before he had got a blow on the face from a cocoa-nut, which broke the left canine tooth, and, a year before I saw him, the left side of the face swelled up, but

subsided again. In August, 1867, he first noticed a growth below the left eye, which rapidly increased, but even before this the interior of the mouth was tender, and felt swollen and soft to the touch. He had good advice in the country, and subsequently was in a London hospital, but operative interference was declined by the surgeon under whose care he was. When I saw him, some months later, there was a large soft tumour of the left upper jaw, and a

FIG. 126.




smaller one on the right side, which had appeared about four weeks before. The nose was considerably projected by these, the left nostril being completely blocked and the right slightly so. The alveolus was very prominent, so that the incisor teeth sloped backwards, and there were soft masses of disease on each side of the palate. Within a week or ten days of my seeing the patient the lymphatic glands in the neck had become enlarged, particularly on the right side, where a considerable tumour existed. This melancholy case was obviously totally unfitted for operation at the time I saw it, whatever might have been its prospects at an earlier date. I could therefore hold out no hope of

alleviation to the unfortunate patient, who returned to the country.

Round-celled sarcoma occasionally involves both upper and lower jaws, beginning, I believe, mostly in the upper and extending to the lower. Fig. 127 shows a good instance of this in a man who was under my care in 1877, with an enormous swelling of the left side of the face. I ventured, under chloroform, to introduce my finger into the mouth to

FIG. 127.



explore the extent of the growth, but I found it so extensively attached to both upper and lower jaws that removal was clearly impossible. The examination gave rise to sharp hæmorrhage, due to the great vascularity of the growth, and this was checked with some difficulty with the persulphate of iron.

I met with the same implication of the lower jaw, though to a lesser extent, in a lady, from whom I removed the upper jaw in consultation with Dr. Cæsar. In this case the coronoid process was involved and was removed with bone-forceps,

but recurrence of the disease took place and the patient did not survive the operation four months.

2. *Carcinoma*.—The variety of cancer that occurs in the upper jaw is always epithelioma, which may occur in two forms, the squamous and the columnar. The former, which probably always begins in the gum or palate, has already been described in connection with the antrum, *épithélioma térébrant* (see p. 167). Squamous epithelioma of the upper jaw may be present without the characteristic invasion of the antrum. The rapidity of the growth in such cases is well illustrated by a patient I attended with Mr. Sams, of Blackheath, in the latter part of 1871. A lady, aged fifty-two, had noticed a small growth in the gum of the left upper jaw, which gradually overlapped the hard palate. This was removed by another surgeon in May, 1871, but the growth reappeared almost immediately. In November I found a fungus-looking mass involving the greater part of the left half of the hard palate, the bone of which was absorbed, and bulging up beneath the cheek. I removed the left half of the hard palate, with the whole of the growth, on November 24th. In ten days the growth reappeared on the apparently healthy section of the hard palate and also in the cheek. A fortnight after the first operation I therefore again operated very freely, applying, as on the former occasion, a strong solution of the chloride of zinc to the entire wound. Again, within ten days, the disease reappeared and rapidly filled up the cavity left by the operation, blocking the nostril and mouth, and eventually suffocating the patient in her sleep, on December 29th.

Even when the disease is far advanced, however, so that the tissues of the face and mouth are much involved, it is sometimes possible for the surgeon to give relief, if not permanent cure, by completely excising the morbid structures.

A case illustrating the advantage of operating in cases of epithelioma where a cure cannot be hoped for, was under my care during 1882-3. A lady, aged fifty-two, was sent to me in March, 1882, by Sir Spencer Wells, with the following

history : A month before Christmas, 1881, she had noticed a swelling of the left cheek, and when I saw her had a uniformly elastic swelling involving the left upper jaw, and spreading up the margin of the left orbit. The skin was tense and reddened, but not involved apparently, and the palate was healthy. I recommended removal, with the view of prolonging life, and in this view Mr. Erichsen coincided, but two eminent surgeons had given a contrary opinion.

On March 24th I turned back a flap of the cheek, and found the tumour well covered with fascia and the skin healthy. I opened the temporal fascia, so as to isolate the growth behind, and divided the zygoma afterwards, clearing the malar bone, and sawing the external angular process of the frontal bone. The palate was then sawn through, and the jaw readily removed. The remains of the hard palate were removed with bone-forceps quite up to the pterygoid process, which was healthy, and the parts were freely cauterized to make doubly sure. The patient made a good recovery, and left town much relieved on April 19th.

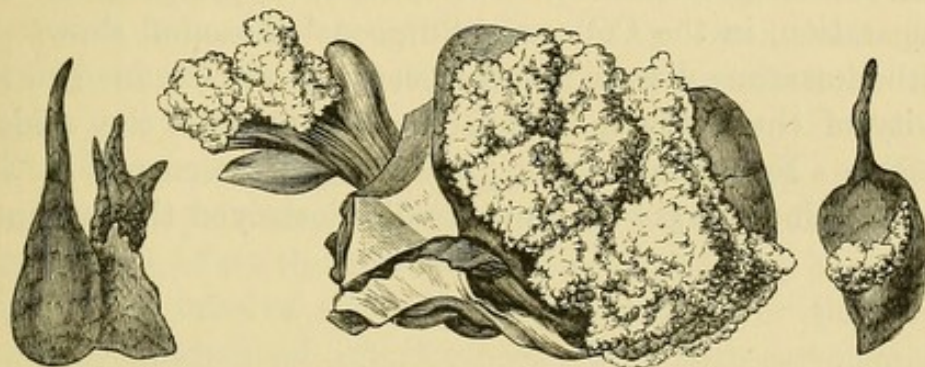
In September I saw her again, when there was an epitheliomatous fungus at the outer angle of the wound, measuring $1\frac{1}{2}$ inches across. No glands were enlarged, and the patient's health continued good. On September 28th, I removed the growth and surrounding skin freely with Paquelin's cautery, and applied chloride of zinc paste. The mouth and cavity left by removal of the upper jaw were quite healthy, but the mouth could not be opened freely because the surface of the lower jaw had become involved by the disease in the cheek. On October 10th a recurrence of disease at the bottom of the otherwise healthy wound was noticed, and the caustic paste was re-applied.

In November the patient returned with one small spot of epithelioma at the bottom of the wound, involving the mucous membrane of the mouth. This was thoroughly destroyed with caustic paste, and the parts were quite sound when the patient went home. In February, 1883, there was a fresh recurrence in the cheek, but the patient was too

weak to bear treatment, and she died in April, having survived the first operation more than a year in comparative comfort, and with no formidable external tumour.

Columnar Epithelioma.—This variety of carcinoma always begins in the antrum, which it often fills, and then secondarily involves the palate; or it may attack the outer wall only of the antrum, and then protrude on the face. Occurring usually in patients over forty years of age, the disease begins very insidiously, the patient complaining, perhaps, of neuralgia or of uneasiness in the face, but of little more. When the antrum has become distended, the epithelioma is apt to involve the palate by absorption and

FIG. 128.



eventual fungation, and then protrude into the nostril and orbits.

A case, which I believe to be of this nature, was brought to me by Dr. Whitmarsh, of Hounslow. The patient was a gentleman who, two years before, had perceived some growth in the right nostril, which gave no pain, but kept up a constant discharge, especially at night. In the early part of the year this had been removed in part by a surgeon, and since then the discharge had much increased. There was a fungous growth in the right nostril, and the whole right maxilla was swollen and discharged thin pus at one or two points near the eye. There was a fungus-looking growth in the molar region, and a probe passed by its side into the antrum.

I removed the disease on September 23rd, clearing away the whole of the growth, which was very friable, and

leaving the posterior wall of the antrum and the infra-orbital plate untouched. In the course of the operation I found a distinct polypoid growth filling the posterior nares, which I removed. The patient rallied well from the operation, but unfortunately got congestion of the lungs and died on the fifth day.

The preparation is in the College of Surgeons' Museum, and the appearance of a part of the disease is shown in Fig. 128. It will be seen that the interior of the antrum is covered with a remarkable papillary or villous growth, resembling some forms of cauliflower excrescence.

In 1888 I saw with Dr. Brace a gentleman aged sixty, who had been treated for a persistent discharge from the nose and a gum-boil. I removed the upper jaw, and the preparation, in the College of Surgeons' Museum, shows the epitheliomatous disease to have been entirely confined to the cavity of the antrum, though protruding into the middle meatus. Nevertheless, the growth rapidly recurred in the parts behind the jaw and eventually destroyed the patient.

CHAPTER XVIII.

DIAGNOSIS AND TREATMENT OF TUMOURS OF THE UPPER JAW.

Diagnosis.—The diagnosis of tumours of the upper jaw is by no means simple. Even the distinction between fluid tumours due to cystic enlargement of the jaw and solid growths, is, as has already been pointed out, not always easy; and it is still more difficult, and in some cases impossible, to decide as to the malignancy or otherwise of a tumour previous to its extirpation.

The fibrous, cartilaginous, and osseous tumours are all of slow growth, painless, and more or less hard to the touch. They do not affect the general health, nor do they show any tendency to involve the surrounding tissues or the skin, except by mechanical interference. The fibro-sarcomatous and myeloid tumours are more rapid in their growth, and softer than those already mentioned; both are more vascular in appearance at points where they are covered only by mucous membrane. They occasionally ulcerate, but do not fungate, and may, under these circumstances, discharge blood in considerable quantities. The medullary-sarcomatous and epitheliomatous tumours are the most rapid in their growth, and their tendency to involve surrounding structures is early manifested. The softness and tendency to fungate are the chief characteristics of medullary sarcoma and epithelioma, but these must not be relied on too implicitly. This last variety is ordinarily more painful than the others, the patient frequently complaining of neuralgic or gnawing pains in the head and face.

In examining a case of tumour of the upper jaw, a careful inspection should be made of the face, mouth, and nares.

The consistency of the projection beneath the cheek should be tested with the finger both outside and inside the cheek itself. The condition of the hard and soft palate should be particularly investigated, and the finger should be carried behind the soft palate, if there is any suspicion that the tumour extends towards the posterior nares. The removal of a tooth may assist in the diagnosis, either by evacuating fluid, or by bringing away with it a small portion of growth, which may be submitted to microscopic examination. The condition of the nostril will require especial examination, particularly in those cases where the disease shows itself at an early period in that cavity, and doubt arises as to its nature. The careful introduction of a probe whilst a good light is thrown into the nostril, will enable the surgeon to decide whether the tumour is merely a polypus springing from the turbinate bones, or whether it is a portion of an antral tumour showing itself in the nostril, or possibly some growth springing from the base of the skull and simulating maxillary disease.

Prognosis.—But little can be hoped from medicine in the treatment of tumours of the upper jaw. The application of iodine has been said by Mr. Stanley to have effected the removal of a small enchondroma, and no harm will be done by resorting to such measures and to the internal administration of absorbent medicines for a short time, whilst the progress of the disease is watched, provided no chemical agent be applied to the growth itself, by which it might be irritated or caused to inflame. Removal by surgical operation is, however, the only effectual means of treatment, and the sooner an operation is undertaken the better in all cases, since even a benign tumour may, by its size or by its attachments, put a patient's life in danger if allowed to grow unchecked for a series of years. In malignant disease the only hope for the patient is early and complete removal, whilst the disease is confined to the bone and before the surrounding structures have become affected.

Operations on the Upper Jaw.—From early times portions of the upper jaw, and particularly the alveolus, were occa-

sionally removed on account of some disease, and with more or less permanent success. Mr. Butcher, who has laboriously investigated the subject, puts the earliest case in 1693, the operator being Akoluthus, a physician at Breslau. Desault, Garengéot, Jourdain, and others in the last century removed growths from the jaw, gouging them out with chisels with partial and temporary success; and Dupuytren especially advocated this mode of treatment in his *Leçons Orales*, and frequently practised it, removing in this manner the greater part of the upper jaw in 1824. Charles White, of Manchester, appears also to have successfully operated on a patient, from whom he removed, piecemeal, nearly the whole of the upper maxilla during the last century.

The late Mr. John Lizars, of Edinburgh, appears to have been the first to propose removal of the entire superior maxilla as a whole in 1826, when, in his "System of Anatomical Plates," he showed how, anatomically, it would be possible to remove the bone without injury to important and vital parts, and recommended the previous deligation of the common carotid artery, with a view of preventing hæmorrhage. Mr. Lizars did not have an opportunity of carrying his proposition into effect until December, 1827, when, notwithstanding the ligature applied to the carotid, the hæmorrhage was so fearful as to necessitate a discontinuance of the operation (*Lancet*, 1829-30). M. Gensoul, of Lyons, had, however, forestalled Mr. Lizars quite independently and without being aware of his proposition, for in May, 1827, he removed the entire superior maxillary bone, with a part of the palate, from a boy of seventeen, on account of a large fibro-cartilaginous tumour. The incision employed by Gensoul was a vertical one from the corner of the eye to the lip, joined midway at right angles by a transverse incision, which was again met by a small vertical incision ascending to the malar bone. By the employment of the mallet and chisel the jaw, with the tumour, was dislodged and removed by the division of the palate. Although the carotid was not tied the hæmorrhage was not very great, and the patient recovered.—(*Lettre*

Chirurgicale sur quelques Maladies Graves du Sinus Maxillaire, par A. Gensoul).

Mr. Syme operated successfully in May, 1829 (*Edinburgh Medical and Surgical Journal*, 1829), and Mr. Lizars also operated again in 1829, for a medullary tumour, which was completely removed with the exception of a small portion attached to the pterygoid processes. The patient had become quite convalescent, when she died suddenly on the nineteenth day (*London Medical Gazette*, vol. v, p. 92). His third and successful operation was in 1830 (*Lancet*, 1829-30), and from that time removal of the upper jaw became an established operation in surgery. Mr. Lizars used an incision across the cheek from the angle of the mouth to the malar bone, or when the tumour was very large, employed in addition an incision through the lip into the nostril, with a vertical cut at the malar bone. With the saw and bone-forceps the maxilla was separated from its attachments and removed.

Lizars' example was followed by most of the leading surgeons of the day, but Mr. Liston requires especial notice, since he performed some of the earliest and most important operations of the kind, and in his essay, which has been frequently referred to (*Medico-Chirurgical Transactions*, vol. xx), brought the subject and its relations to various forms of disease prominently under the notice of the profession. Mr. Liston seems to have been strongly impressed with the notion that malignant disease of the jaw should not be interfered with, but this idea does not prevail among operating surgeons of the present day, for it is felt that it is better to act upon the principle which guides operations upon cancerous growths in other parts of the body—to remove the growths, if feasible, in the hope of giving at least relief if not a permanent cure.

Syme, Mott, Velpeau, Dieffenbach, O'Shaughnessy, Heyfelder, Fergusson, and Butcher may be mentioned as having performed the operation of excision of the superior maxilla repeatedly and successfully. Noticing the considerable deformity resulting due to incision from the angle of the

mouth, which necessarily divides the facial nerve, and still more when a flap of skin has been reflected from the face by a double incision, Sir William Fergusson devised the plan of carrying the incision solely through the median line of the lip into the nostril. By dissecting up the tissues of the nose and taking advantage of the stretching of the skin of the nostril, room may thus be obtained for the removal of any tumour not of large size; but supposing this

FIG. 129.



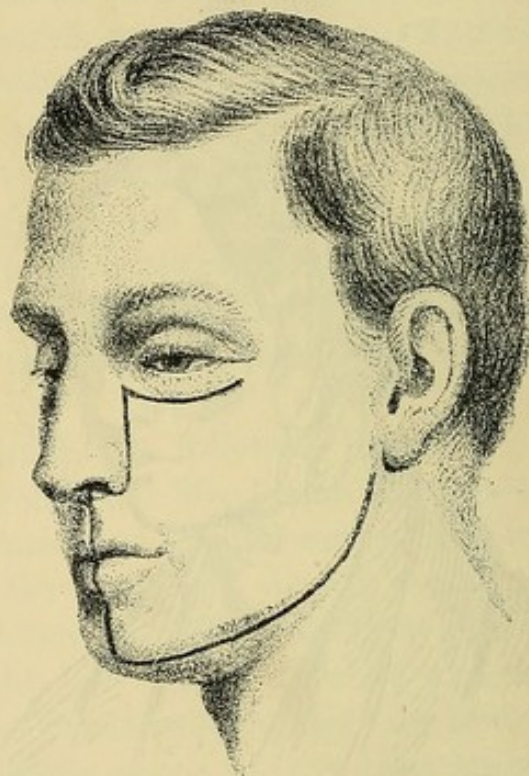
to be found impracticable, it is still open to the operator to prolong the incision round the ala and up the side of the nose, and in the case of large tumours, to carry it in a curve below the orbit to the malar bone, as seen in Figs. 129 and 130. The great advantages of these methods are that the facial nerve and facial artery are divided at points where their size is of no consequence, and consequently the loss of blood and the subsequent deformity are much diminished; and also that the scars fall in such positions as to be hardly noticeable.

This method, adopted by Fergusson, was really a modification of the skin incision recommended by Liston. The

incision through the lip and round the ala of the nose was used by Liston (Fig. 129), but he, in addition, often made another incision from the angle of the mouth towards the outer angle of the orbit. Fergusson found that this second incision was rarely, if ever, necessary.

The method of proceeding which I recommend when it is necessary to remove the entire upper jaw is as follows:

FIG. 130.



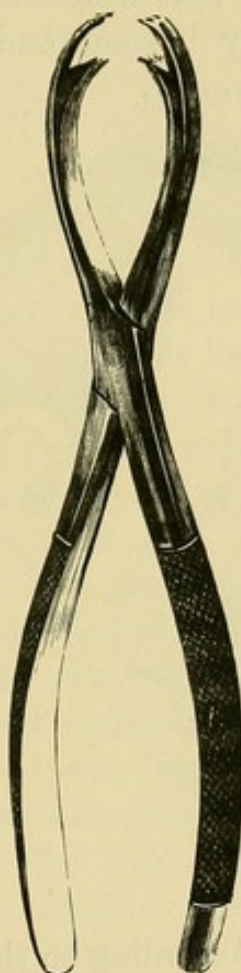
(Fig. 130). The skin having been reflected in the manner described above, the incisor teeth of the side to be removed are extracted and a narrow saw with a movable back passed into the nostril. With this the alveolus and hard palate are divided, and a small saw (Fig. 131) is then applied to the malar bone in a line with the sphenomaxillary fissure, and to the nasal process of the superior maxilla, so as to notch both these points of bone, the division being completed with the bone-forceps. With the 'lion-forceps,' devised by Sir William Fergusson for the purpose (Fig. 132), the jaw can now be grasped and broken away from the pterygoid process and palate bone, any detaining

point being severed with the bone-forceps. Lastly, when the bone is quite loose, the infra-orbital nerve is to be severed, and the soft palate divided at its attachment to the bone, so as to leave as much of it as possible uninjured; and any remaining portions of disease are then to be removed

FIG. 131.

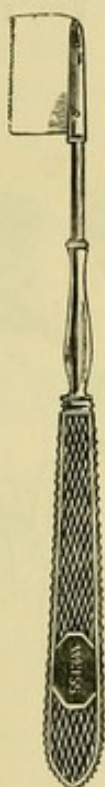

FIG. 132.



with the bone-forceps and gouge. Hæmorrhage is to be arrested by ligatures and the application of the actual cautery to the deep tissues, and, finally, the lip and incision are to be brought together and carefully adjusted with hare-lip pins and interrupted sutures of fine wire or silk. Figs. 133 and 134 show the two stages of the operation.

When the disease is of less amount, and the orbital plate is not involved, this should be preserved by carrying a saw horizontally below it; and if the palate is not involved, this may be advantageously kept intact by making a similar cut

immediately above it. Under these circumstances the incisions through the skin need only be very limited, and the bone-forceps and gouge will be requisite to clear out all the disease from the antrum.

Sir William Fergusson has, in his "Lectures on Anatomy and Surgery," strongly urged the pursuance of a less heroic plan than that which has hitherto been followed, in going completely beyond and not interfering with the diseased

FIG. 133.

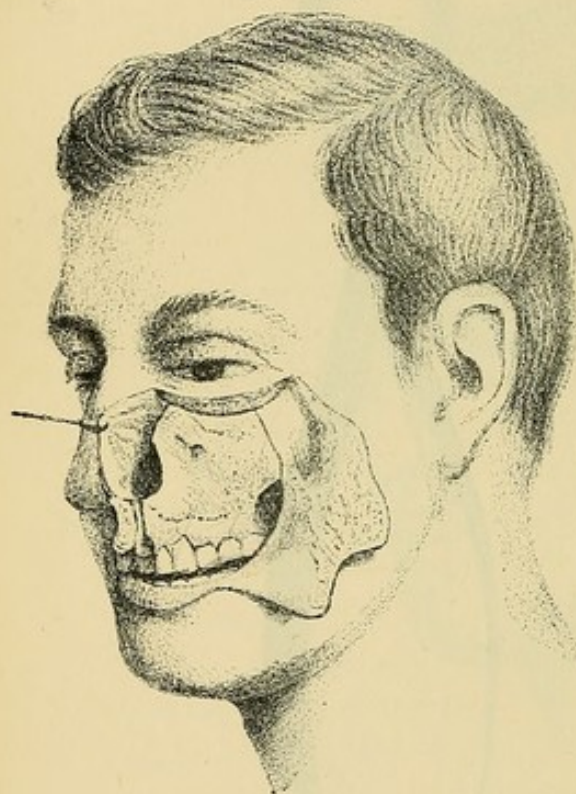
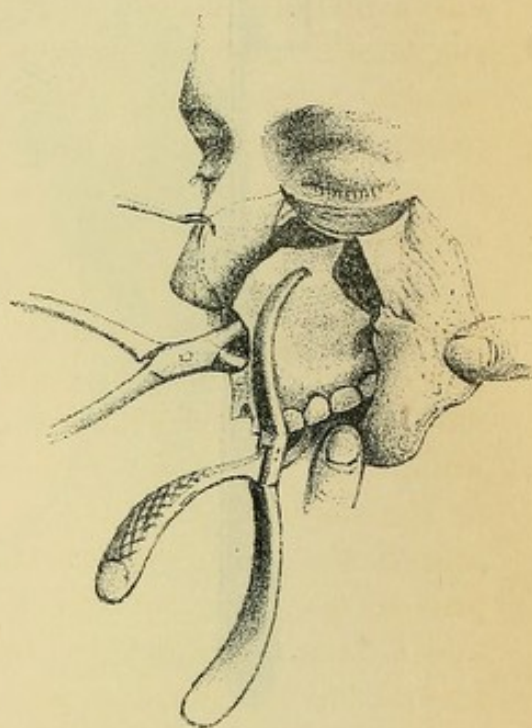


FIG. 134.



tissues. According to that eminent surgeon, it is better to cut into the disease and to clear it out by working from the centre to the circumference, so as not to remove healthy structures unnecessarily, and this may be accomplished by means of curved and angular bone-forceps of various sizes, and by the use of the gouge. Mr. Syme (*British Medical Journal*, Aug. 12th, 1865) denounced this method as a return to "the old system with its chisels and gouges;" but the practice, as regards non-cancerous tumours at least, has recently received the strong support of Sir James Paget, who in a paper in the *Medico-Chirurgical Transactions*, vol. liv,

has urged the propriety of enucleating simple tumours growing in the interior of bones, and among other cases gives one of a lad of nineteen, from whose antrum he successfully removed a large mass without injury to the palate or orbit. A similar instance, under my own care, is given at p. 264. The case is, however, different when the disease is of a malignant character, and, after some considerable experience, I am decidedly of opinion that the surgeon must go well beyond the boundaries of the tumour if he hopes to give the patient permanent relief. The practice of cutting into a malignant growth gives rise to considerable hæmorrhage, which renders it very difficult to be certain as to the removal of the entire disease. It is better, therefore, I think, to cut into the healthy bone beyond, so as to be quite certain of removing the entire growth, though it is by no means necessary to remove large portions of healthy structure.

In cases of epithelioma, where even the whole of the diseased structures have been removed, I would strongly advise the application of the chloride of zinc paste, made with hydrochloric acid and opium, after the formula of the Middlesex Hospital. Applied on the end of a strip of lint to the doubtful part, the rest of the lint can be packed in and covered over with a pledget of cotton-wool, so as to prevent the escape of the chloride of zinc into the mouth; and I have found it very advantageous to plug the posterior nostril on the affected side from the front with another strip of lint, so as to obviate the escape of fluid into the throat. After three days the plugs are easily withdrawn from beneath the cheek, and free syringing will keep the parts sweet while the sloughs caused by the caustic are separating. For washing out the mouth there is nothing better than the syphon nasal-douche with a soft nipple.

In cases of epithelioma in which the skin is involved, the portion so diseased must be sacrificed if a cure is to be hoped for. This may be effected with the knife or the actual cautery, and I may refer to a very successful example of this method of treatment by Mr. Lawson, recorded in the *Clinical Society's Transactions*, vol. vi.

As a local antiseptic nothing is equal to powdered iodoform, freely applied to the raw surfaces both of bone and soft parts. In this way the cavity left by removal of the upper jaw may be kept sweet for days after the operation, and the patient be spared the risks of purulent infection or septic bronchitis.

It has been mentioned that, in the earlier operations for removal of the upper jaw, it was customary to apply a ligature to the common or external carotid artery. Although this practice has now been quite abandoned, it has in a few cases been necessary to secure the main vessel after the operation, on account of secondary hæmorrhage. Thus, Mr. Field, of Brighton, tied the common carotid two days after removal of the upper jaw, in 1858, and the patient recovered. In a patient of Mr. Holmes Coote's, at St. Bartholomew's, the house-surgeon, Mr. Orton, tied the vessel on the nineteenth day, but the patient sank (*Lancet*, October 13th, 1866). In his work on Cancer, Mr. Oliver Pemberton mentions a case which occurred in 1848, when he was house-surgeon at the Birmingham General Hospital, which also proved fatal.

As a rule, however, patients who have been submitted to removal of the upper jaw recover with wonderful rapidity. Of course the primary shock of such an operation is severe, but when this is once got over the convalescence is ordinarily rapid.

Removal of *both* upper jaws has occasionally been performed. A case in which Mr. Lane removed the greater part of both jaws has been referred to in this essay (p. 290), and the operation has been performed by Rogers, of New York (1824), Heyfelder (1844, and twice afterwards), Diefenbach, Maisonneuve, and others. Heyfelder made two incisions from the outer angles of the eyes to the corners of the mouth, and reflected this quadrilateral flap to the forehead, taking the nose with it. He then passed a chain-saw through the speno-maxillary fissure on each side, and thus separated the jaws and the malar bones. The junctions with the nasal bones and vomer were then divided with

bone-forceps, and the soft palate separated from the margin of the hard. Lastly, powerful traction upon the bones was exerted, and the bones were displaced. Dieffenbach, Maisonneuve, and others, employed a median incision, beginning at the root of the nose and ending in the median line of the lip, so as to divide the skin of the face into two lateral flaps. This appears to be an unnecessary complication, however, since division of the lip and free dissection of the nostrils would afford sufficient room for the removal of the jaw in two halves. A paper on Total Double Resection of the Upper Jaws, by H. Braun, of Heidelberg, will be found in Langenbeck's *Archiv*, xix, 1876.


In 1872, Mr. Dobson, of Bristol, removed both superior maxillæ of a woman, aged fifty-two, by dividing the lip in the middle line and carrying an incision up each side of the nose, and the late Mr. Bellamy informed me that he had removed the greater part of both upper jaws by simply reflecting the lip without any external incision.

Dr. Charles Brigham, of San Francisco, has reported in his "Surgical Cases with Illustrations" (1876), an instance of successful removal of the entire upper jaw for malignant disease, after performing tracheotomy and plugging the pharynx with sponge. In a case of such extensive disease the preliminary tracheotomy was, no doubt, admirable, but for ordinary cases of removal of tumours of the upper jaw the proceeding seems to me uncalled for, as I have never employed it, and have only seen it employed on one occasion. Professor Trendelenburg's proposal to perform a preliminary tracheotomy, and to plug the trachea by a special expanding tampon in all serious operations about the mouth, was made in 1871, and will be found described at length in the *Medical Times and Gazette* for May, 1872. I have employed the tampon once in operating on the tongue, and once (unnecessarily as it turned out) in operating on the palate; but the objection to it is, that the pressure exerted on the trachea is apt to produce great embarrassment of breathing and cough. Plugging the pharynx with a sponge, to which a string is attached, is a far preferable plan, and I strongly

advise that the preliminary tracheotomy should be done a couple of days beforehand, so that the patient's windpipe may have become accustomed to the presence of the tube. On two occasions I have been obliged to perform laryngotomy in order to suck blood out of the wind-pipe.

I have twice had occasion to remove the eye-ball in cases in which the disease had spread from the jaw to the orbit. In one desperate case, in which I only

FIG. 135.



operated at the earnest request of the patient, I removed the eye-ball and the eye-lids, and stitched up the opening, the patient being able to return to India, and surviving several months. In a remarkable case of recurrent sarcoma, on which I operated five times with ultimate success, it became necessary to remove the eye-ball after the second operation, as it had suppurated. Fig. 135 shows the appearance of the patient at the present time (1894), ten years after the last operation. The prominence seen in the cavity of the orbit is the top of a vulcanite palate, and ordinarily the deformity is concealed by a black patch.

The fear of hæmorrhage in cases of removal of the upper jaw is exaggerated, I think, for there is no large vessel implicated until the last stage of the proceeding, when the bone is forcibly displaced ; and then, if the operator is rapid in his movements and his assistants are prompt, pressure can be made with a sponge, thrust into the cavity, quite sufficient to prevent blood flowing into the fauces, until the operator is ready to pick up the bleeding vessel. I always provide myself with a small sponge, which I thrust into the posterior nostril of the affected side the moment the larger sponge held by an assistant is removed. This prevents any blood flowing into the pharynx, and allows of deliberate examination and the arrest of bleeding by the ligature or the cautery.

As regards the position of the patient I always have him recumbent, with the head fairly raised on pillows, and invariably employ chloroform as the anæsthetic, both because it is impossible to keep a patient under the influence of ether when air must necessarily be admitted very freely by the manipulations of the surgeon, and because of the danger of ignition of the vapour of ether in the patient's mouth by the application of the actual cautery.

In operating upon cases in which unusual hæmorrhage was anticipated, I have adopted the plan of bringing the patient's head well over the end of the table, and to a lower level than the larynx, so that the blood may pour out of the nostrils. The practice is an inconvenient one, both for the operator and the assistants, but it may be advantageously adopted if necessary in the later stages of an operation.

Since it is unadvisable that a patient about to have a jaw removed should take food for four hours beforehand, lest sickness should be induced by chloroform or swallowing blood, I am inclined to recommend a practice, which I have lately followed, on the suggestion of Dr. Prince, of Jacksonville, Illinois (*St. Louis Medical and Surgical Journal*, February, 1883)—viz., to inject into the colon, shortly before a severe operation, a quantity of hot brandy and water, suited to the age and requirements of the patient.

CHAPTER XIX.

NON-MALIGNANT TUMOURS OF THE LOWER JAW.

THE fallacies that surround statistical tables constructed from cases occurring several years ago have already been mentioned in connection with tumours of the upper jaw, (see p. 257). It is convenient, however, for the sake of comparison, to copy O. Weber's table of tumours of the lower jaw.

Osseous tumours	25
Vascular tumours	2
Fibrous tumours	23
Sarcomatous tumours	132
Enchondromatous tumours	14
Osteo-chondromata	18
Cystic tumours	25
Carcinoma	162
Melanosis	2
	<hr/>
	403

The general opinion is that sarcomata are more common than carcinomata, as in the case of the upper jaw.

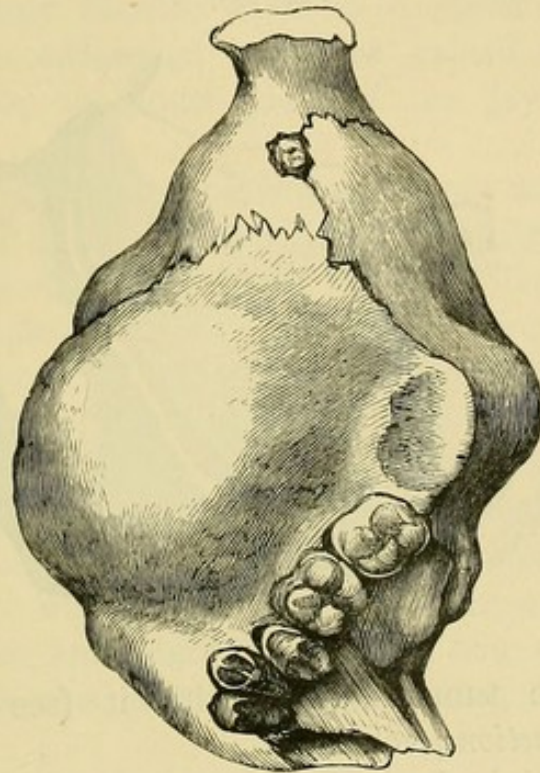
Fibroma.—This is the commonest form of tumour of the lower jaw, and, as pointed out by Paget, it may be central or endosteal, and peripheral or periosteal.

Central or Endosteal Fibroma.—It is very difficult to account for the origin of these growths. According to Broca the great majority, if not all of them, originate in a tooth follicle and are to be classified as odontomata. Virchow, on the other hand, looks upon them as ordinary

fibromata. It is possible that they originate in an inflammatory deposit due to the irritation of decayed teeth.

If we exclude those originating in tooth follicles it is difficult to say in what structure they arise. It is most

FIG. 136.

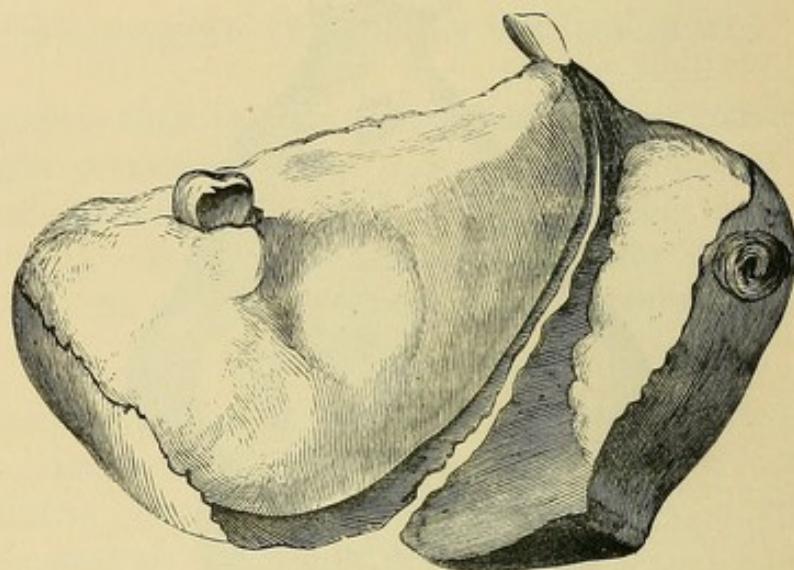


likely that they commence in the alveolo-dental periosteum. The formation of fibrous tumours between the plates of the lower jaw has been already referred to under the head of Inflammation (p. 100), and originates, I believe, in the majority of cases in some inflammatory deposit due to the irritation of decayed teeth.

By the slow growth of the tumour the jaw is expanded, the outer plate yielding more readily than the inner, as is well seen in a preparation in University College Museum (Fig. 136), which also shows a curious transportation of the wisdom tooth close up to the condyle of the jaw by the growth of the tumour, being probably connected with it in some way. In the College of Surgeons' Museum is a good specimen

of endosteal fibrous tumour, which Sir Spencer Wells removed with the jaw from the symphysis to the angle, in a woman, aged twenty-seven. The tumour occupied the left side of the lower jaw, and had existed for four years, being connected with decayed teeth, one of which on being extracted shortly before the operation brought a small

FIG. 137.



portion of the tumour away with it (see *Pathological Society's Transactions*, vol. xii.).

It may, I think, be doubted whether a milder treatment than that of removal of the whole thickness of the bone containing tumours of this description might not sometimes be adopted with advantage. A specimen in the Museum of King's College, which is represented in Fig. 137, admirably illustrates this view. It is a fibrous tumour removed, when I happened to be present, by Sir William Fergusson, from a woman who had undergone two previous operations. Having sawn the jaw partly through on each side of the tumour, the operator applied the bone-forceps to complete one of the sections, when the outer plate of the jaw with the greater part of the tumour came away, leaving only a small portion of it adhering to the inner plate. Owing

to the jaw being already divided, it was considered better to complete the operation as originally intended, and the patient made a good recovery. The preparation referred to illustrates also the connection of the teeth with fibrous tumours, a diseased molar tooth being implanted in the upper part of the growth.

The advantage of not breaking the line of the lower jaw has been already insisted upon in connection with epulis, and the same advantage would be gained by preserving, where possible, the inner plate of the jaw in cases of tumour.

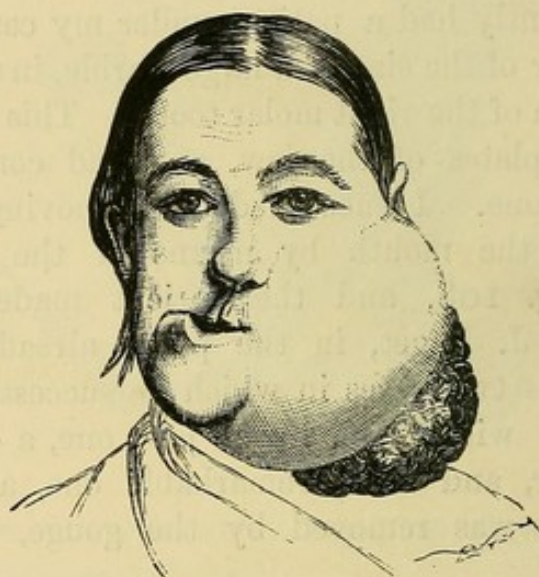I have recently had a patient under my care who had a fibrous tumour of the size of a large marble, in the lower jaw, in the position of the right molar tooth. This was imbedded between the plates of the jaw, and had considerably expanded the bone. I succeeded in removing the growth from within the mouth by means of the large forceps shown in Fig. 108, and the patient made a good recovery. Sir J. Paget, in the paper already referred to (p. 311), gives two cases in which he successfully removed tumours from within the lower jaw, one, a bony tumour, and the other, and more remarkable one, a cartilaginous growth which was removed by the gouge, and did not reappear.

A specimen of fibrous tumour, presented to the College of Surgeons' Museum by Mr. Bryant, illustrates the same point. The section shows that the fibrous tumour is free towards the alveolar border of the jaw, but enclosed in the bone below. It is separated at all parts from the osseous tissue by a fibrous layer forming a kind of capsule, and might therefore probably have been enucleated from its cavity without any great difficulty.

A specimen, now in the Museum of the College of Surgeons, and for which I was indebted to Mr. Buxton Shillito, shows the satisfactory result of the treatment here recommended. The case is reported, with drawings, in the *Pathological Transactions*, vol. xvi, and the tumour was

removed by Mr. Shillito from near the angle of the lower jaw of a young woman, aged twenty-six, where it had been growing fifteen months, being of the size of a walnut. It was removed by reflecting a flap of skin from its surface, cutting through the thin shell of bone, and enucleation. It left a perfectly smooth cavity into which the fang of the second molar tooth projected, which doubtless was the original cause of the mischief. The tumour was gritty on section, and furnished an example of calcification, to which

FIG. 138.



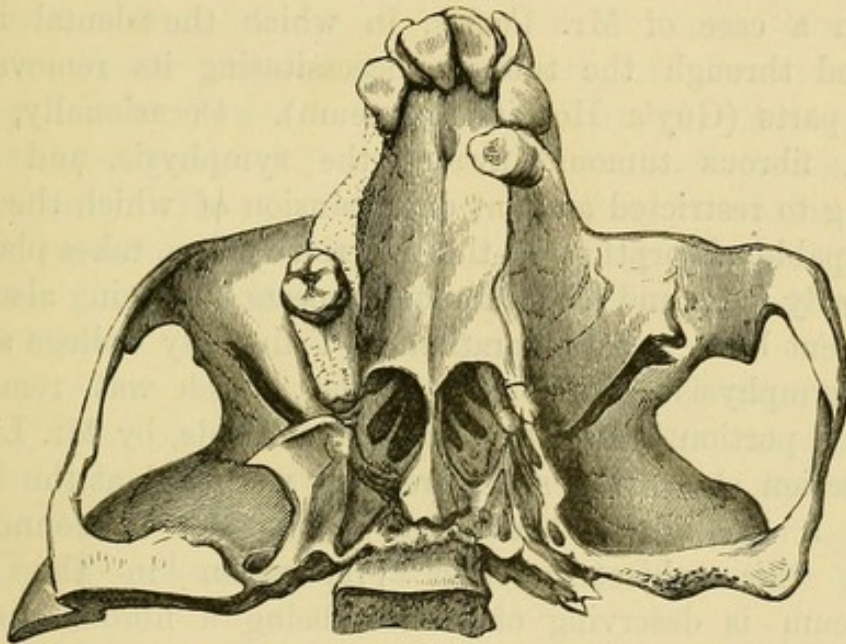
change fibromata of the lower jaw are liable no less than those of the upper jaw.

Though of slow growth under ordinary circumstances, a fibrous tumour of the jaw, if irritated by the injudicious application of useless remedies with the view of producing absorption of the growth, may assume enormous proportions, and destroy life by the irritation and continuous discharge it gives rise to. A preparation in King's College Museum shows a fibrous tumour of large size, involving nearly the whole of the left side of the lower jaw. Its interior is hollowed out into a large cavity with sloughing walls, and there is a large aperture communicating with it surrounded by healthy skin. The patient's portrait, taken about six

weeks before her death, is seen in Fig. 138. The case was evidently one of ordinary fibrous tumour depending originally upon diseased teeth, which, by dint of incisions and injections of iodine into the growth, followed by a seton introduced through the skin, was brought into such a condition that, upon the receipt of a blow, it rapidly brought the patient to her deathbed.

A remarkable and unique feature in connection with the case of large fibrous tumour above referred to, is seen

FIG. 139.



in Fig. 139, which shows the front of the base of the skull of the patient. The long-continued pressure of the tumour of the lower jaw has given rise to a remarkable contraction of the hard palate and alveolus, the teeth being crushed together so as to overlap one another, and at the same time an expansion of the malar bone and zygoma has ensued, which is accurately shown in the drawing.

A large tumour of the same kind, weighing eighteen ounces, which has encroached upon the condyle and coronoid process, and projected into the mouth as well as on the surface, is preserved in University College Museum and was removed by Mr. Liston in 1846; and a similar

growth, successfully removed by Prof. William Beaumont, of Toronto, from a boy of seven, which is considerably infiltrated with calcareous matter, is in the Museum of the College of Surgeons, and was originally considered to be cartilaginous (*Medico-Chirurgical Transactions*, vol. xxxiii). It weighed eight ounces avoirdupois, with a long diameter of 3 inches, and a short diameter of 2 inches, and involved the whole of the left side of the bone.

Fibrous tumour is most frequently developed in the side of the lower jaw, where the space between the plates is larger than elsewhere, and may occupy the dental canal, as in a case of Mr. Cock's, in which the dental nerve passed through the tumour, necessitating its removal in two parts (Guy's Hospital Museum). Occasionally, however, fibrous tumour invades the symphysis, and here, owing to restricted amount of expansion of which the bone is capable, absorption of the anterior surface takes place at an early date, and the tumour projects, involving also the adjacent bone. A preparation in University College shows the symphysis affected in this way, which was removed, with a portion of healthy bone on each side, by Mr. Liston. A section shows the structure very well, and at the lower part a small cyst has been developed. In connection with this subject another preparation in the same museum is deserving of notice, being a fibrous tumour, of the size of an orange, connected with the back of the symphysis, and apparently, therefore, of the periosteal variety.

Peripheral or Periosteal Fibroma.—This growth may be very difficult to distinguish from epulis. It does not tend to recur, however, after removal, as an épulis does, and it attains a much greater size. Like epulis it has spicula of bone springing from the jaw, permeating it for a short distance, and beyond them radiating lines may be seen in the fibrous tissue. A preparation in the Museum of the College of Surgeons, which accompanied this essay, and for which I was indebted to Mr. Lee of the Salisbury Infirmary, illustrates this form of disease very well, the

fibrous growth being closely connected with the periosteum of the front of the jaw. The disease may, however, almost completely surround the jaw, as in the preparation in St. Bartholomew's Hospital, drawn by Sir James Paget in his "Surgical Pathology."

Enchondroma.—This growth is by no means a common one, and is found in two forms, the central or endosteal, and the peripheral or periosteal, thus resembling fibroma.

The disease generally occurs early in life, and makes slow but steady progress, the periosteal variety acquiring a very large size.

Central Enchondroma.—A specimen in Guy's Hospital Museum shows very well the relation of the endosteal variety to the bone, the growth occupying the space between the plates of the jaw, and the teeth being imbedded in it. The specimen was removed by Mr. Aston Key from a woman, aged twenty-nine, in whom it had been growing nine years, by sawing through the bone on each side of the tumour.

A somewhat similar case is recorded by Sir Astley Cooper in his "Essay on Exostosis." The patient was nineteen, and had had a growth in the side of the lower jaw for three years. Sir Astley exposed the tumour and gouged it away, exposing the dental nerve, and the patient made a good recovery.

Sir James Paget has recorded (*Medico-Chirurgical Transactions*, 1871), a very similar case of cartilaginous tumour in the lower jaw of a lady forty-five years old. It had been growing during two or three years, extended along the space between the first bicuspid and last molar teeth, was deep set in the jaw, expanding both the walls, and rising to almost the level of the molar teeth. He gouged it out, leaving the base of the jaw untouched, and not cutting any part of the cheek or lip. The patient had no return of the disease.

Periosteal Chondroma.—The periosteal form of chondroma springs from the membrane covering any portion of the bone, but most frequently affects the body. It grows to

an enormous size, and may cause death either by interfering with respiration, as in Sir Astley Cooper's case; or with deglutition, as in the case from which the preparation in the College of Surgeons' Museum was taken.

Sir Astley's patient was a girl of thirteen, in whom the tumour had made its appearance near the chin a year before she came under that surgeon's notice. The tumour increased until it measured five inches and a half from side to side, and four inches from the incisor teeth to its anterior projecting part. The circumference of the swelling was sixteen inches. The tongue was thrust back into the throat and to the right side, where it rested in a hollow between the angle of the jaw and the tumour. The epiglottis was bent down upon the rima glottidis so as to produce great difficulty in swallowing and breathing. The mental foramen was large enough to admit the little finger, and, owing to the elongation of the bone, was directed backwards. The preparation is preserved in the Museum of St. Thomas's Hospital and a section, which has been macerated, shows very well the ossific spicula from the surface of the bone projecting into the mass.

In the Museum of the College of Surgeons is a still more remarkable specimen of the same disease, the tumour measuring six inches in depth and about two feet in circumference, and involving the whole of the lower jaw except the right ramus and angle. The patient, when thirty-two, had a small hard tumour on the right side of the lower jaw, just below the situation of the first molar tooth, which had decayed. This gradually increased, and ultimately proved fatal at the end of eight years, by inducing inability to swallow.

A specimen of chondroma, weighing three and a half pounds (German), removed by disarticulation by Chelius, is preserved in the Heidelberg Museum, and is figured by Otto Weber (*op. cit.*).

A remarkable case of chondroma of the lower jaw has been recorded by Mr. Lawson (*Pathological Society's Transactions*, xxxiv), in which there were ten operations for as

many recurrences during eighteen years. The report of a committee on some of the more recent recurrences goes to show, however, that these are more of the nature of spindle-celled sarcoma.

The patient, a woman, aged forty-five, came under Sir William Fergusson's care in 1865. He removed the tumour and subsequently operated five times for recurrent growths.

FIG. 140.

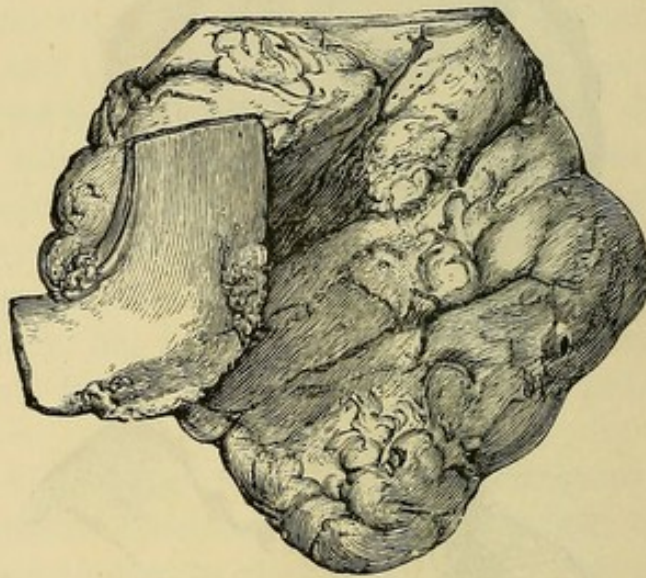


In 1877 she came under the care of Mr. Lawson, and her condition then is shown in Fig. 140. The tumour, together with a portion of the lower jaw, was removed, and is seen in Fig. 141. Since 1877 five operations have been performed for recurrent masses of cartilaginous growth. This is undoubtedly a case of chondro-sarcoma with a very low degree of malignancy.

Osteoma.—This growth occurs in the lower jaw in two forms; the cancellated and the ivory exostosis. The former

may be in many cases the result of ossification of enchondroma, as, for instance, a specimen preserved in St. Thomas's Museum, which is of a spongy texture, and which is stated by Sir Astley Cooper to have been removed by Mr. Cline. Occasionally, however, a conversion of the whole thickness of bone into a lobulated mass of spongy bone is met with, of which an excellent example is preserved in St. George's Hospital Museum. In this case the tumour, which was of the size of the fist, had been growing for five years, and had

FIG. 141.

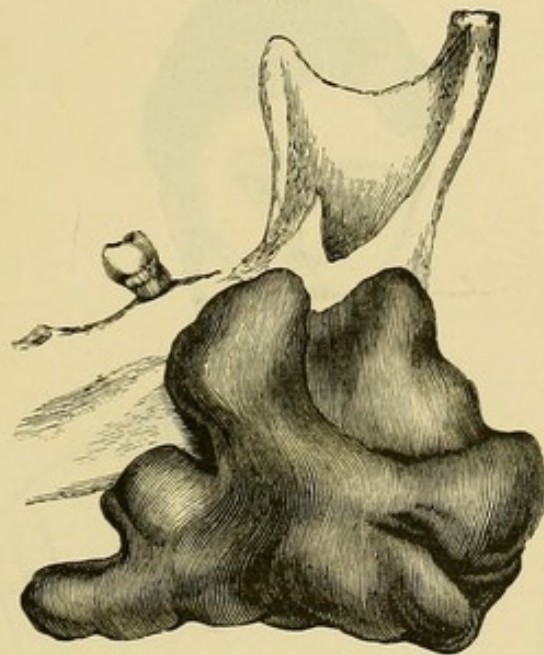

been on one occasion partially removed. Mr. Tatum successfully removed the entire portion of jaw affected. A case in which a circumscribed bony tumour, measuring from two-thirds to three-fourths of an inch in diameter, and composed of hard, finely cancellous bone, was lodged in the interior of the angle of the jaw, is given by Sir J. Paget in the *Medico-Chirurgical Transactions*, vol. liv.

Ivory exostosis appears to affect by preference the angle of the jaw. Of this a good specimen is preserved in St. George's Hospital; and O. Weber figures a section of a large ivory exostosis in the same region removed by Chelius. The best example of the kind, however, is in the College of Surgeons, having been presented by Mr. J. F. South. The

preparation (post-mortem) shows part of the right side of the lower jaw, with sections of a large bony tumour at its angle. The angle of the jaw rests in a deep groove on the middle of the upper surface of the tumour, and in some situations their respective substances are continuous. The tumour projects both below and on each side of the jaw, is of irregular shape, measures nearly three inches in its chief diameter, and is deeply nodulated. It is composed throughout of bone, uniform in texture, and as hard and heavy as ivory (Fig. 142).

FIG. 142.



In the Museum of St. Bartholomew's Hospital is the lower jaw of a young person with two symmetrical eburnated exostoses springing from the inner surface of the alveolar portion of the bone on either side of the symphysis, corresponding in position to the bicuspid and first molar teeth. The markings and slight lobulations of the bony outgrowths are more or less symmetrical. The rami of the jaw are unusually widely separated.

In May, 1870, I removed an ivory exostosis from a young woman, aged thirty-two, a patient of Mr. Ceely, of Aylesbury, whose portrait is given in Fig. 143. There had been a painless enlargement of the left side of the lower jaw for

five years, and there was also a smaller enlargement of the right side. A small exostosis also existed on the left pubes. I made an incision behind the jaw and sawed off the growth level with the bone, removing a dense ivory growth, measuring two inches in length by one inch in width, and three-eighths of an inch thick in the centre (University College Museum). The exterior of the growth presented a finely reticulated appearance, and at the upper part was a small depression filled with cartilage in the recent state. Two years after the

FIG. 143.



operation I was informed by Mr. Ceely that there had been no reappearance of the growth, and that the other exostosis remained *in statu quo*, and four years later I saw the patient, who continued quite well.

When the exostosis forms a distinct and circumscribed growth, whether it be of the cancellous or ivory character, it should be sawn off the bone at the level of the healthy surface, and will in all probability not recur. When, however, the whole thickness of the bone is involved, as in Mr. Tatum's or Mr. South's case, it will be necessary to remove a portion of the bone. Should the tumour be imbedded

between the plates of the jaw, it should be enucleated if possible without any external incision, as in Sir J. Paget's case given above. A remarkable case of exostosis of the ramus of the jaw, reaching to the styloid process, has been recorded by Mr. Syme, in his "Contributions to the Pathology and Practice of Surgery," in which he removed the ramus of the jaw, with the growth, by an external incision, without opening the cavity of the mouth.

CHAPTER XX.

MALIGNANT TUMOURS OF THE LOWER JAW.

Sarcoma and Carcinoma.

THE classification adopted, when describing malignant tumours of the upper jaw, will be employed in dealing with the similar tumours of the lower jaw.

1. *Sarcoma*.—As in the case of the upper jaw, so in the lower jaw, we must distinguish between the central and the periosteal sarcomata; the latter occurring more frequently than the former.

(a) *Central Sarcoma*.—The great majority of central sarcomata are of a myeloid nature, but, occasionally, round-celled sarcomata are met with originating in the centre of the bone.

Myeloid sarcoma is frequently met with in the lower jaw, and it was here that the disease occurred in the case from which Sir J. Paget drew his description. The case is quoted by Mr. Stanley (*op. cit.* p. 184) as an example of "tumour of bone, composed of a soft, very vascular substance, having the characters of erectile tissue," but his general description corresponds precisely to that of Sir J. Paget. Figs. 1 and 2 of Plate 13 in Mr. Stanley's atlas show the tumour *in situ* and a section of the jaw after removal. "The patient was a boy in St. Bartholomew's Hospital, and the growth occupied the symphysis of the lower jaw, and protruding into the mouth presented a very vascular surface of a mottled red and purple colour, resembling the exterior of some nævi. The tumour was not tender to the touch, and had not been accompanied by pain; it was once destroyed

by caustic to the level of the alveolar border of the jaw, but was quickly reproduced ; it was then wholly removed with the portion of the jaw in which it originated, and the cure was permanent. The morbid substance was found imbedded in the cancellous texture of the jaw ; it was soft, of a dark red colour, *closely resembling the tissue of healthy spleen*" (Stanley, p. 185).

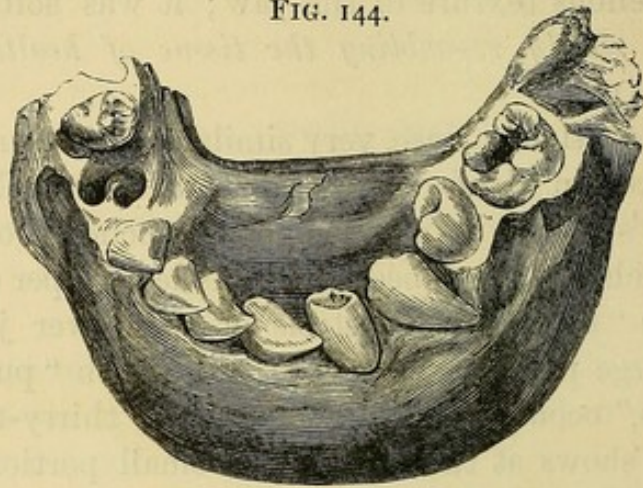
Stanley mentions a case, very similar to his own, recorded by Dupuytren in his *Leçons Orales* ; and in the Museum of St. Thomas's there is a very good specimen of myeloid disease, which was described by Sir Astley Cooper ("Surgical Essays") as "a fungous exostosis of the lower jaw, which formed a large prominence on the chin" with "purple *fungi* of the gums," occurring in a woman, aged thirty-two. The preparation shows at the back part a small portion of firm, healthy bone, having a well-defined margin and not sending out any spicula, from which the tumour projects. Around its base the tumour is covered with integument ; but in front the latter has ulcerated, allowing the growth to fungate through the ulcerated aperture.

A valuable preparation is in the College of Surgeons' Museum of myeloid tumour of the symphysis and body of the jaw, removed by Mr. Craven, of Hull, from a young woman of eighteen, who made a good recovery after the operation. Figs. 144 and 145 show very satisfactorily the appearance of the specimen, which has been divided horizontally. The tumour was of between two and three years' growth, and was covered with healthy mucous membrane. Its section shows a well-marked specimen of myeloid disease imbedded between the plates of the lower jaw ; its tissue is of the ordinary friable character, resembling spleen, but somewhat decolorised by immersion in spirit, and it is intersected by fibrous septa. Two cysts may be seen in the section ; these, as mentioned by the late Mr. H. Gray (*Medico-Chirurgical Transactions*, xxxix), being of frequent occurrence in myeloid growths. The microscopic examination of Mr. Craven's specimen was unsatisfactory, owing to its previous immersion in spirit, but there can be no

question, from the naked-eye appearances, of the nature of the growth.

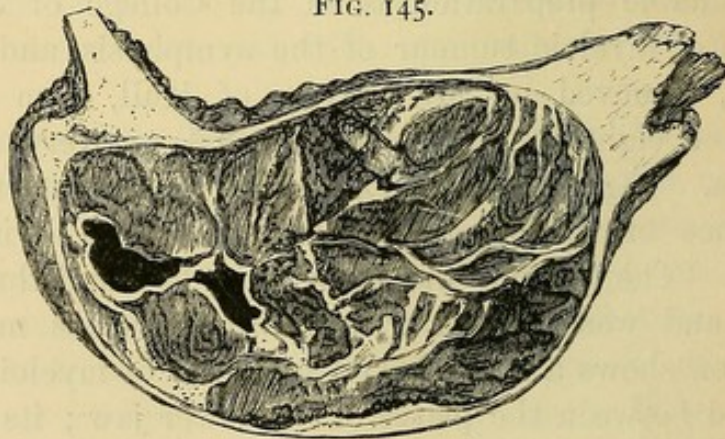
In the Museum of St. George's Hospital are four specimens of myeloid disease affecting the lower jaw, two of

FIG. 144.



which have no history; the others were removed from girls of eight and five years respectively, of whom the first was known to be well two and a half years afterwards. In the Museum of University College are three excellent specimens,

FIG. 145.



removed by Liston, and there are three in St. Bartholomew's Hospital, all from young persons.

A remarkable, and I believe unique, example of disease of both sides of the lower jaw, the microscopic characters of which were decidedly myeloid, was formerly under my own care, of which the following are the brief particulars. The patient, a boy of seven and a half, whose portrait is shown in

Fig. 146, presented a remarkable enlargement of both sides of the lower jaw, giving his face a very square appearance. The affection had come on gradually and painlessly from the age of a year and a half, and at the time I operated upon him the width of the jaw, as measured with callipers, was five inches, the width of an average adult jaw being only four inches. The growths were evidently projections from the outer surfaces of the angles of the jaws, the inner surface of the bone being natural, and the mucous membrane of the mouth not interfered with. In September and October, 1867, I removed the right and afterwards the left

FIG. 146.

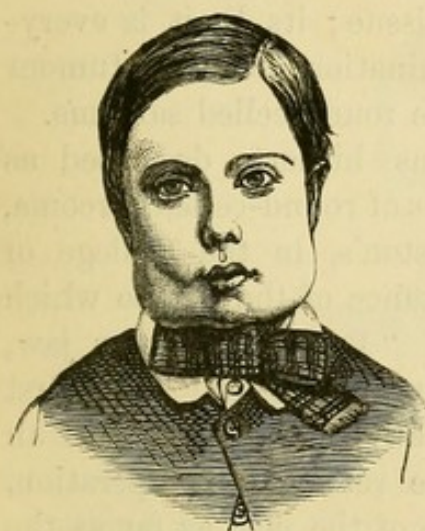



FIG. 147.



tumour through incisions behind the margin of the jaw, and without opening into the mouth. The main part of each projection was sawn off the jaw, and are now in the College of Surgeons' Museum, closely resembling large mussel-shells filled with a cartilaginous-looking substance, which, however (and especially some darker portions) gave distinct microscopic evidence of myeloid structure. A good deal of this material, which seemed to fill the interior of the bone, was gouged away, and the symmetry of the face restored as far as possible. The boy made a good recovery, and Fig. 147, from a photograph, shows his condition three months after the second operation, and there appears to have been no tendency to recurrence.

Round-celled sarcoma may begin in the interior of the bone, producing rapid expansion of it, and ultimately breaking through into the mouth, and also through the skin of the face, if allowed to proceed unchecked. A specimen in University College Museum is a good example of the disease. The morbid growth projects chiefly on the outer side, and its most prominent part has protruded through the skin, forming an overhanging nummular projection which has an open reticular surface. On the inner side the tumour has invaded the jaw, in places destroying its entire thickness; the growth however scarcely projects into the mouth. As seen on the divided surface, it is composed of a soft granular, yellowish basis, supported and parted into small polyhedral masses by narrow lines of fibrous tissue; its limit is everywhere definable. Microscopic examination shows the tumour to have all the characters of a large round-celled sarcoma.

Many of the museum specimens hitherto described as medullary cancer are really examples of round-celled sarcoma, and the following case of Mr. Liston's, in the College of Surgeons, may be quoted as an instance of the size to which round-celled sarcoma may grow. "Part of a lower jaw, including the left condyle, the alveolus of the right first molar tooth, and all the intermediate parts which, with an enormous tumour upon them, were removed by operation. The left ascending portion and side of the jaw, as far as the canine tooth, are completely enclosed by the tumour, and it covers both surfaces of the jaw as far as the right canine tooth. A round lobulated mass projects downwards and forwards, and in the opposite direction the tumour projects into the mouth with a rough fungous surface, in which a displaced molar tooth is seen. The interior of the tumour is indistinctly lobulated, composed of round masses connected by cellular tissue, and of a soft texture; it is invested by a thick capsule."

I had under my care an interesting case of round-celled sarcoma of the lower jaw, in a little girl, aged five—one of a numerous and healthy family, who was in perfect health until seven weeks before I saw her. The mother then

noticed that the second temporary molar tooth on the right side was loose, and the gum swollen; and a tumour developed so rapidly, that when I saw her the side of the face was considerably enlarged, and a large fungous mass protruded into the mouth. On Sept. 10th, 1867, I removed the right side of the jaw from close to the symphysis to the articulation, and the preparation is now in the Museum of the College of Surgeons. The structure of the growth was distinctly medullary. The child made a perfect recovery, and was well for six weeks, when a small growth was noticed within the cheek, which made such rapid progress that in four days, when she was brought up to me again,

FIG. 148.



there was a tumour filling the cheek, and involving the remaining portion of the jaw as far as the canine tooth, and a fungus had been thrown out through a portion of the old cicatrix.

On Oct. 26th, 1867, I removed the whole of the disease again, cutting the jaw on the left side immediately in front of the second molar tooth, and removing the whole of the skin involved in the fungus. The patient made a good recovery, and Fig. 148, drawn from a photograph taken seven weeks after the second operation, shows her then condition, which was quite satisfactory, there being no evidence whatever of return, and very slight deformity considering the amount of jaw removed.

The second growth, which was even more markedly medullary than the first, is preserved with it.

The child continued in perfect health to the end of the year, but early in January, 1868, the disease reappeared, both at the symphysis and in the masseteric region on both sides. Coupled with this there was loss of appetite, great exhaustion, and irritability of the system; and the poor child gradually sank, and died on Feb. 9th, a little more than six months after the first appearance of the disease.

This case appears to me of considerable interest, since it shows the advantage of surgical interference, even under desperate circumstances. If the first growth had not been removed, the patient would have been shortly destroyed by the fungus in the mouth, whereas the operation gave her six weeks' immunity from suffering. The return of the disease was of such a rapid nature, that it would in a very few days have destroyed the patient by hæmorrhage from the fungus which had already begun to form in the skin; but the second operation again relieved her, and restored her to comfort and apparent health for more than two months. When the disease finally appeared on both sides of the face, it was obviously beyond surgical control, and rapidly destroyed the patient. The relief which the operations afforded was, however, gratefully acknowledged by the friends of the little patient.

(b) *Periosteal Sarcoma*.—This variety of growth appears in two forms; the spindle-celled sarcoma and the more malignant round-celled, medullary, or encephaloid sarcoma.

Spindle-celled Sarcoma.—This frequently attacks the lower jaw, and may prove fatal, by obstruction either to respiration or deglutition, if allowed to grow unchecked for many years.

Sir Philip Crampton's description of the whole course of the disease, as witnessed in the jaw, is so perfect that I cannot do better than reproduce it: "The first indication of this formidable disease is the appearance of merely a small swelling or projection of the gum, between two of the teeth. The teeth, however, soon become loose and dislocated, being forced inwards upon the tongue, or outwards against the cheek; as the tumour enlarges it assumes

a tuberculated appearance, the tubercles varying in colour from a light pink to a deep purple; they are firm in structure, perfectly indolent, and do not readily bleed even when roughly handled. As the morbid growth extends in all directions, the mouth is soon filled by the tumour, the lower jaw is forced downwards upon the fore part of the neck, the tongue is pushed backwards into the pharynx, the mouth is carried to the side of the face opposite to the tumour, and before the patient sinks under his sufferings, a tumour is sometimes formed which nearly equals the bulk of the head itself. It is gratifying, however, to be able to state that even under such deplorable circumstances life has been preserved, and the hideous deformity removed by an operation which must be considered as one of the boldest and most successful of which modern surgery has to boast. But it is from the *internal structure* of osteo-sarcomatous tumours, as developed in the course of operations undertaken for their removal, or by dissection after death, that the true and distinctive characters of these affections are to be traced. In the benign form of osteo-sarcoma, the local, and, I might almost say, the encysted character of the disease is evinced by the distinct line which separates the morbid growth from the soft parts with which it is in contact. It becomes apparent that, as the tumour has enlarged, it has pushed the soft parts before it, or insinuated itself into their interstices, and that, so far from becoming incorporated with the surrounding structures, and assimilating them to its own nature (as invariably happens in the advanced stage of malignant tumours), it has formed attachments so slight, that when the portion of bone from whence the tumour springs is detached, the whole morbid growth may be (as it were) drawn out from the surrounding parts almost without the aid of the knife. The interior of the tumour presents a great variety of structure, but I should say, in general, that the cartilaginous character which the tumour exhibits in its origin prevails to the last. In the early stages of the disease the tumour consists of a dense elastic substance, resembling fibro-cartilaginous

structure, but the resemblance is more in colour than in consistency, for it is not nearly so hard, and is granular rather than fibrous, so that it 'breaks short.' On cutting into the tumour the edge of the knife grates against spicula or small grains of earthy matter, with which its substance is beset. If the tumour acquires any considerable size, it is usually found to contain cavities filled with fluids differing in colour and consistency, but in general the fluid is thickish, inodorous, and of the colour of chocolate. Sometimes the growth of the tumour, or the secretion of fluid within its substance, is so slow that the deposition of bony matter keeping pace with the absorption, the bone becomes expanded into a large and thick bony case, in which the tumour is completely enclosed. There is a beautiful preparation of this form of the disease in the Museum of the Royal College of Surgeons. But in general the walls of the cavity consist of cartilaginous structure mixed with bone, the bone bearing but a small proportion to the cartilage. The extent to which this description of tumour may increase without materially affecting the general health, is one of the most extraordinary circumstances connected with its history" (p. 541).

The 'cartilaginous' appearance here referred to, relates only to the naked-eye appearance of the structure, which is characteristically said to 'break short.' Microscopic examination, as I have had the opportunity of observing in a large tumour of the kind, shows a dimly granular stroma, closely resembling the *matrix* of cartilage, but containing no true cartilage-cells. Though parts of the tumour may show structure of this kind, the greater part is usually of a distinctly spindle-celled character.

In 1828 Mr. Syme removed a very large tumour of this description (probably the largest which has ever been removed), weighing $4\frac{1}{2}$ lbs., which, no doubt, for the reason given above, he refers to in a lecture published in the *Lancet*, February 3rd, 1855, as a fibro-cartilaginous tumour. The patient made a good recovery, and the accompanying illustrations, Figs. 149 and 150, for which I was indebted

to Mr. Syme, show his condition before and some years after the operation, which was one of the earliest of the kind in this country.

The spindle-celled sarcoma will, if its surface be irritated by caustics, &c., throw out fungus masses. Mr. Cusack (*loc. cit.*) gives an example of this result occurring from sloughing of the skin of the face, due to over-distension by the tumour. Occasional hæmorrhage from such surfaces led to these cases being massed together with cancer as

FIG. 149.

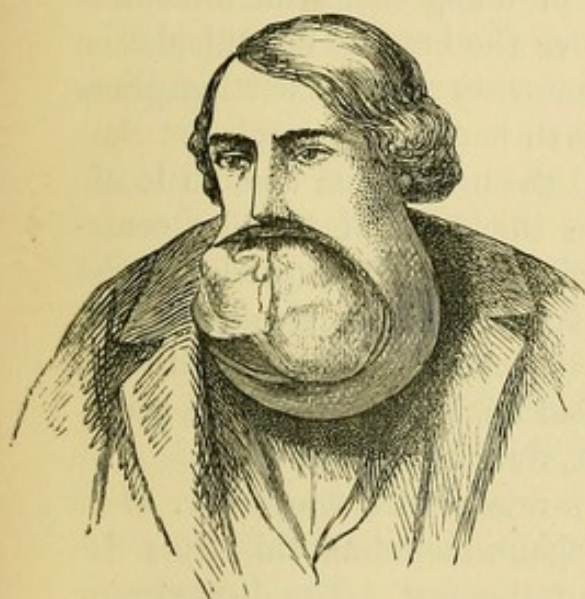



FIG. 150.



examples of *fungus hæmatodes*, and doubtless Sir William Fergusson's observation is correct, that the rarity of fungus hæmatodes in the present day, is due to the early treatment to which cases of this kind are submitted.

Under the head of Spindle-celled Sarcoma must be included the following two cases, which were originally classed as 'recurrent fibroid.'

The first occurred in the Westminster Hospital, under the care of Mr. Holt, in 1858, in a young woman, aged eighteen, who had a soft fungoid mass covering the molar teeth of the right side of the lower jaw, of ten weeks' duration. It apparently sprang from the angle of the jaw,

or the base of the ascending ramus, and had pushed the mucous covering before it. The molar teeth were firmly fixed in their sockets; the wisdom tooth was covered with gum. The rapid growth of the fungus, and the absence of any material pain, led to the conclusion that it was probably a form of epulis of a malignant type. Mr. Holt therefore thought it advisable to remove the whole mass, and examine the bone prior to removal of the jaw itself. This being done, its attachments were found to be connected with the posterior part of the body and anterior part of the ascending ramus, the bone being hard and of its ordinary density. Mr. Holt did not feel warranted in doing that which he was prepared to do—namely, remove the bone at its articulation at this time—but preferred removing with the cutting pliers all the bone to which the growth had been attached. Mr. Clendon having then extracted the molars and wisdom tooth, Mr. Holt cut through half the thickness of the jaw corresponding to those teeth, and, going further back, included the coronoid process, with more than half of the sigmoid notch. The disease was found to be intimately connected with the periosteum, which readily peeled off, leaving the bone somewhat roughened. (See *Lancet*, Jan. 28th, 1858.)

The disease reappeared in a few weeks, when Mr. Holt was compelled to remove it again, including this time the remaining part of the ramus of the jaw. The disease now was not confined to the covering of the bone, but extended into the pharynx, and was evidently attached to the mucous lining of the whole of one side of the mouth.

The poor girl left the hospital and went to Reading, and died on the 3rd of February. An autopsy was performed by Mr. Walford, the particulars of which are given in his own words:

“ Fanny S—— died on the 3rd, and assisted by Mr. G. May, jun., and Mr. Fernie, I made a post-mortem examination. I did not open the head. The thoracic and abdominal viscera were free from disease. I dissected out the tumour, which, had the whole of it been there, would have completely encircled one side (one-half) of the lower jaw;

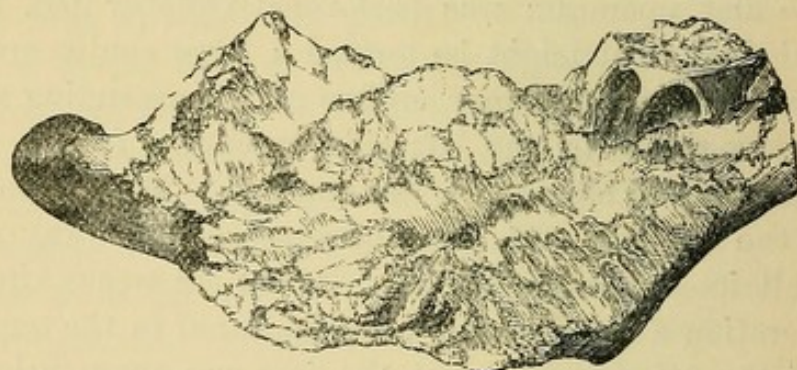it extended up to the zygomatic arch and downward into the neck. The gullet was free, and it evidently grew into, not from, the pharyngeal region. We could not satisfactorily discover its origin. The portion of lower jaw-bone left after the operation was sawn through at the symphysis, and exhibits the margins of the tumour on the periosteum, which, I think, must be considered the starting-point, and that, as regards treatment, would be practically the bone." (See *Lancet*, March 6th, 1858.)

The second case occurred at the Great Northern Hospital, in the practice of Mr. George Lawson, who performed three operations with the hope of eradicating the disease, which, however, eventually proved fatal, as in the preceding instance. The patient was a young woman, aged seventeen, and the first operation was performed October 4th, 1858. She had then what might be termed a large epulis growing from the anterior and inner surface of the ascending ramus of the lower jaw on the left side, extending from a point near the angle to close upon the condyle. Mr. Lawson removed the tumour with bone-forceps, cutting away apparently all its bony attachments. About six weeks after the first operation a small elastic mass appeared in the temporal fossa of the affected side, but the jaw was apparently free. This Mr. Lawson excised, but found that the growth had evidently sprung from its original site, and extending upwards, had passed beneath the zygoma into the temporal fossa. The third operation was in June, 1859, when, in consequence of the great size the tumour had attained, the inability of the girl to open her mouth, and the great difficulty she experienced in deglutition, Mr. Lawson removed a portion of the inferior maxilla, sawing through the bone in front of the angle, and then disarticulating. Upon the removal of this portion of bone (Fig. 151), it was found that the tumour had formed so many attachments to the periosteum of the bones forming the base of the skull, that the operator was compelled to leave some of the disease behind.

By the end of November, 1859, the tumour had again

grown to a large size, and from the space it occupied in her mouth interfered much with her taking nourishment. It now began to soften and to ulcerate on its surface, both externally and within the mouth, and occasionally very alarming hæmorrhages would take place, so as to threaten immediate dissolution, but from all these she rallied; within the mouth large sloughs would occasionally separate, allowing her to recruit her health by enabling her to take additional nourishment. She died early in 1860, worn out and greatly emaciated. The drawing (Fig. 152), for which I am indebted to Mr. Lawson, shows the terrible deformity as seen after death. The preparation is in the Museum of the College of Surgeons. (See *Pathological Society's Transactions*, vol. xi.)

FIG. 151.



Round-celled sarcoma may commence in the periosteum and is much more malignant than the spindle-celled variety. The cases formerly described as medullary cancer are really round-celled sarcomata.

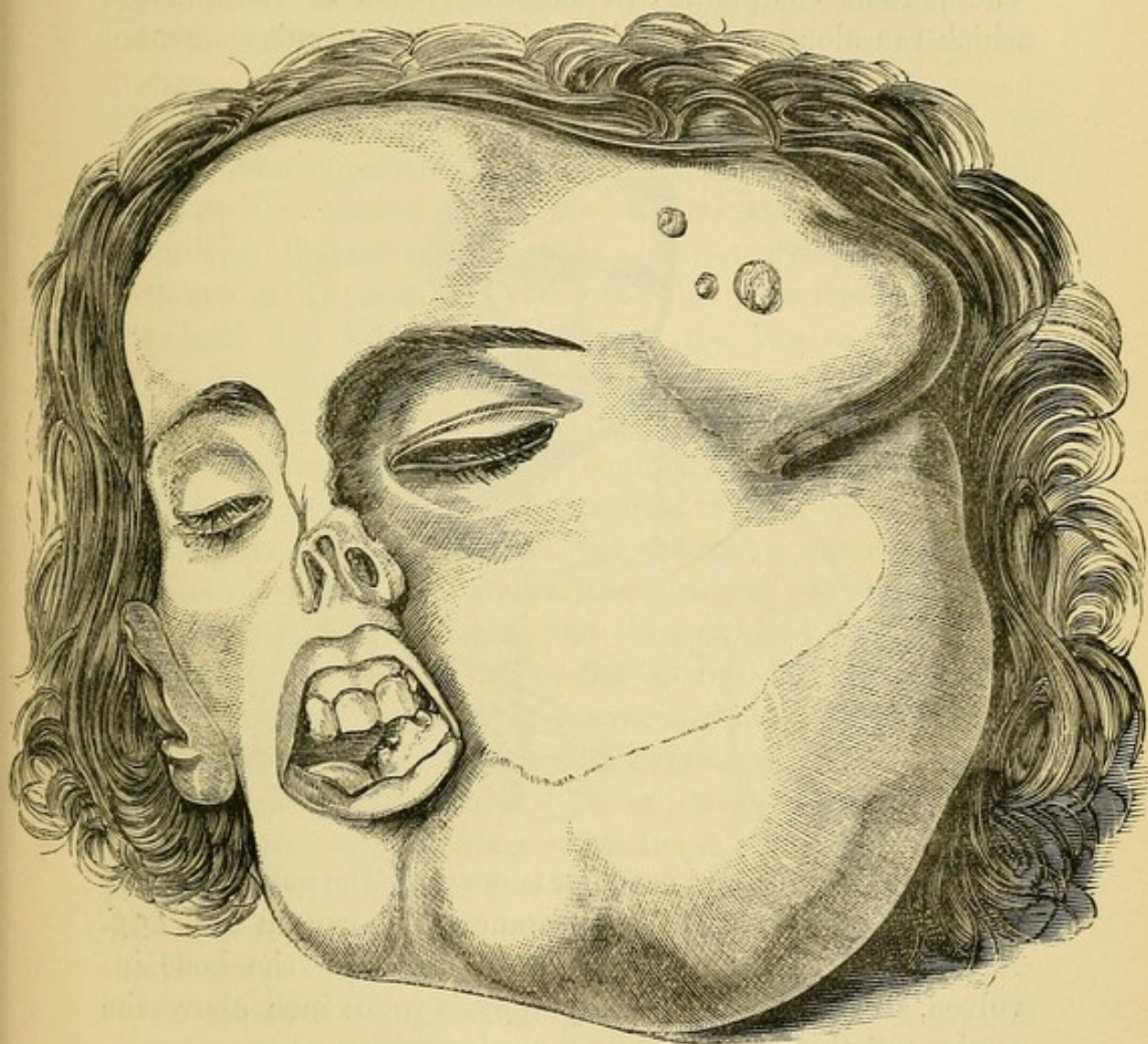
Both in spindle-celled and round-celled sarcomata cartilage cells may be present, or even bone may be deposited. We thus get two mixed varieties, the chondro-sarcoma and the osteo-sarcoma.

Chondro-sarcoma is characterised by rapidity of growth and by early recurrence after removal. The primary tumour is mainly enchondroma, but the recurrent growths are chiefly composed of small round-celled sarcoma, which tend to produce internal deposits through the vascular system.

The following good illustration of the disease occurred under my own care. A woman, aged forty-four, was ad-

mitted into University College Hospital on April 11th, 1877, with the following history: She first noticed a swelling connected with the left side of the lower jaw, nine months before. The swelling was painful, and accompanied by

FIG. 152.



numbness over the chin. Twenty years before she had received a violent blow over the jaw, when attendant in a lunatic asylum. The family history threw no light on the case. The patient had always enjoyed good health.

On admission, there was a large tumour over the left side of the lower jaw, and firmly connected with the inner and outer surfaces of the bone, extending from an inch behind

the symphysis to the angle. The growth generally was firm and elastic, though some parts were much softer than others. The border of the tumour was well defined, and the skin was freely movable over it. A nodule, the size of a walnut, projected between the teeth into the cavity of the mouth. The patient complained of shooting pains in the tumour, which ran along the lower lip. There was no enlargement of

FIG. 153.



lymphatic glands, and no other tumour. The general health was good. The patient's appearance is shown in Fig. 153.

On April 14th I removed the tumour with the bone involved, from the left of the symphysis to an inch above the angle, and the patient made a good recovery.

Eleven weeks after discharge she was re-admitted. The lower borders of the segments of the previously divided jaw had united by fibrous tissue, but a V-shaped notch existed at the upper border large enough to admit the tip of the finger. Recurrence of the growth had taken place in connection with both sections of bone. There was a tumour as large as a hen's egg beneath the chin, but this could not be

felt through the mouth, whilst a second and larger one caused bulging of the left cheek, and was mainly situated over the ramus of the jaw ; it projected into the oral cavity and rendered articulation indistinct, although there was no difficulty in deglutition. The skin was freely movable over both masses ; there was merely a linear cicatrix at the site of the old incision. The lymphatic glands were not enlarged, and the general health was good.

A second operation was done on August 1st, 1877. It being found impossible to remove the tumour by the mouth, I made an incision along the lower border of the jaw, from two inches to the right of the symphysis for a distance of six inches. The lower lip was dissected from the bone and turned upwards, and the jaw sawn through at the symphysis, which allowed a piece on the left to be removed with growth attached. It was found that the whole of the posterior mass could not be removed, as it extended deeply into the pterygoid region, so after enucleating as much as possible, the operation was not further proceeded with. The wound was syringed out with strong solution of chloride of zinc, and then plugged with lint.

For the first fourteen days the wound continued to heal rapidly, but at this time it commenced to fungate, and on the twentieth day sharp bleeding ensued, which required the actual cautery to arrest it. Severe pain was more or less constant, and the discharge very foetid. On the 28th the fungating mass reached the clavicle, and completely hid the left side of the neck ; hæmorrhage again occurred, and the cautery was employed.

In spite of a supporting plan of treatment the general health rapidly failed, the patient fell into a semi-comatose condition, got more and more asthenic and cachectic, and died on the forty-third day after the second operation.

Autopsy.—The mass of growth extended from the zygoma downwards for over seven inches, and was from five to six inches in thickness. Another tumour sprang from the right segment of the divided jaw, and the left side of the tongue and floor of the mouth were largely invaded. The upper

jaw was not involved, but only imbedded in the growth, which had forced itself deeply amongst the neighbouring parts, where the veins were filled with firm white clots, but no growth had sprung up in connection with their walls. The tumour, on section, varied in colour, being yellowish-white in some parts, whilst it was red and vascular in others, and mottled with patches of extravasated blood. It weighed 2lb. 3oz. There were two nodules of secondary growth in the left lung, and three larger ones in the right lung. One of these was distinctly seen to be lying in the course of a good-sized branch of the pulmonary artery, whose walls were expanded over it. It did not completely block the lumen of the vessel, and on its surface was a white fibrinous deposit.

The mass removed at the first operation consisted chiefly of enchondroma, with a dim hyaline and fibrous matrix, but interspersed with islets of round-celled sarcoma. The recurrent masses were made up chiefly of round and spindle-celled sarcoma, whilst scattered throughout were isolated portions of cartilaginous tissue, with fibrous matrix.

One of the cases, described in the chapter on simple tumours of the lower jaw, as pure enchondroma, is really a chondro-sarcoma with a very low degree of malignancy. In that case there were no internal recurrences as in the case just described (p. 325).

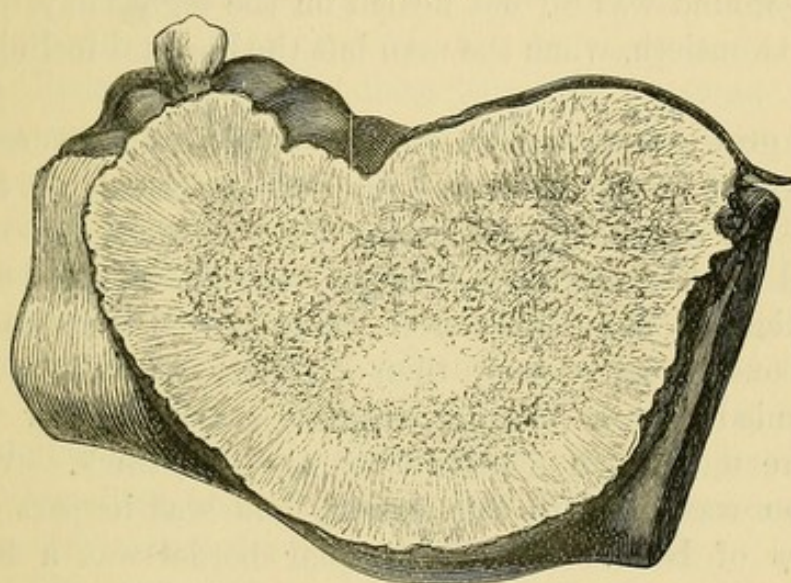
Ossifying sarcoma, in which ossification takes place extensively in a matrix of sarcomatous tissue, occurs in the lower jaw, and, as in the following case, presents at first most of the characters of an ordinary osteoma. Fig. 154 shows the portion of lower jaw at first removed, with a section of the tumour, which it is difficult to distinguish from ordinary bone, except by the striation seen best at its margins. The rapid recurrence of the disease in a soft form showed the true nature of the case, and the patient died exhausted within a year of the first operation.

W. G——, aged fifty, was admitted into University College Hospital on May 9th, 1881. About five months previously he noticed a pricking pain about the left

side of the lower jaw, and soon a lump appeared outside the bicuspid teeth ; it grew steadily but slowly, until one month before admission. At this time the patient had several teeth extracted, and the increase in the size of the growth became rapid after this interference ; there was constant gnawing pain. The patient believed exposure to cold to have been the cause of the swelling. Both his parents died of old age, and had no kind of tumour.

On admission the lower part of the left cheek was bulged outwards considerably by a very hard rounded swelling,

FIG. 154.



which covered the outer side of the left half of the lower jaw from a short distance in front of the angle almost to the left canine ; the lower edge of the bone was concealed by slight projection of the mass below it ; and, on pressing upwards in the sub-maxillary region, a considerable swelling could be felt on the inner side of the bone. Altogether the impression conveyed to the fingers was that the growth was central, and that the so-called expansion of bone had occurred over it. No teeth were present on the left side behind the canine, the alveolus was widened, and presented posteriorly several low, rounded swellings, covered by mucous membrane, soft or even cystic ; whilst in front lay a large crater-like ulcer, at the bottom of which no bone was

bare. The tongue and floor of the mouth were normal. A small, not tender, gland could be felt behind the angle of the jaw. There was moderate constant pain in the part, much increased by hanging the head down. As regards general health there was nothing to be desired.

On May 11th ether was given, and the growth removed by an incision from the left angle to the symphysis; the jaw was sawn through to the left of the symphysis, the soft parts stripped from the growth, and then the bone was divided near the angle. The wound was closed by wire sutures, and dressed with cotton wool.

The wound was all but healed on the eighth day, quite so on the twentieth, when the man left the hospital feeling quite well.

The growth was smooth on the surface, and covered by a thin layer of fibrous tissue; it was sub-periosteal, not central, and on the inner side of the jaw lay two long oval masses, parallel to the mylo-hyoid ridge—one above, one below it. A section of the large outer mass showed it to consist of solid bone, much denser than ordinary cancellous tissue, surrounded by a margin of soft greyish-yellow tissue, nowhere more than a quarter of an inch thick. Vertical striation was plain in this border, and was in part due to spicules of bone. On the alveolar border was a layer of similar soft growth, one-third to half an inch thick. Microscopically the growth consisted of rather large round and polygonal cells, surrounded by bands of spindle cells, and tracts of fairly developed connective tissue; so that to the naked eye a section, seen by transmitted light, was made up of distinct lobules. The above description refers to the thin soft layer on the surface, and even in its substance dots of bone were numerous; whilst at its base lay a large mass of deep yellow bone, fairly dense, having large lacunæ and ill-developed canaliculi; tumour cells occupied the cancellous spaces.

Soon after leaving the hospital the patient's face swelled a good deal, and it was thought that recurrence of the growth had occurred; but a sequestrum worked out, and

the swelling subsided. In three months, however, he was re-admitted, having had a distinct recurrence for six weeks, with much constant pain. His health was still very good.

On September 6th, 1881, the left side of the face was now swollen from two inches below the line of the jaw to above the level of the ala nasi, and from the symphysis to the lower end of the ramus of the jaw. On looking into the mouth, two large firm masses of growth were found—one above the old scar, lying in the cheek, and running back almost to the anterior pillar of the fauces; the other, below the scar, occupied the floor of the mouth. They were separated by a deep groove, at the bottom of which was a little ulceration; elsewhere, the surfaces of the growths were slightly lobulated and covered by mucous membrane.

No large glands were felt. On the following day the whole of this mass, together with the ramus, coronoid process, and condyle of the jaw, were removed by the ordinary incision for the removal of half the lower jaw.

The patient again recovered, without any bad symptoms. The hinder part of the wound gaped widely, but it was healing steadily, and there was no obvious recurrence on October 8th, when the patient left the hospital.

The left angle and ramus of the jaw were surrounded on all sides by masses of new growth, in which there was very little bone, as far up as the base of the coronoid process. In the mass which lay below the scar, unconnected with the jaw, there was a large proportion of bone. Microscopically, the growth was very similar to the primary one; there was less division into lobules, and the cells were, perhaps, smaller; the bits of bone seen were much less perfect.

On January 30th, 1882, the patient was again admitted, having noticed a recurrence of the growth two months. The left cheek was now enormously swollen, and the angle of the mouth pushed forwards by a mass of new growth, fungating into the mouth along the line of the jaw, but elsewhere

covered by mucous membrane. The old wound was healed, but for an ulcer one inch and a half by half an inch, round which there was a good deal of firm infiltration at its posterior end. The growth was firm and elastic at some points, bony at others, adherent to the symphysis, but not very firmly. The whole face was œdematous; the left temporal fossa rather full, and the seat of much pain. The man was still pretty strong.

On February 2nd the old incision was opened up, and the main part of the growth turned out. As the skin was stripped up, the hair-bulbs could be seen springing out of the tumour; then a piece in the floor, on either side of the frænum, was removed, and the two ranine arteries cut and tied. When the tongue had been drawn forwards by a string, the symphysis was removed to just beyond the right canine tooth; and, finally, an attempt was made to remove the posterior end of the tumour, but, as it here seemed to involve the tonsil and carotid vessels, and to spread into the temporal fossa, much had to be left.

Again the patient made a good recovery. The anterior part of the wound healed, but the posterior gaped widely, and he went out with a large hole here. Pain in the temporal region continued. He died at home on April 5th, having been able to walk up and down stairs to the last. The total duration of the disease would, therefore, seem to have been about seventeenth months. A section from the second recurrence was more densely round-celled than either of the preceding specimens; slight traces of lobulation remained, and there was a large amount of rudimentary bone. Throughout the vessel-walls were formed by cells of the new growth.

2. *Carcinoma*.—Carcinoma occurs in the lower jaw in two forms, the columnar and the squamous epithelioma.

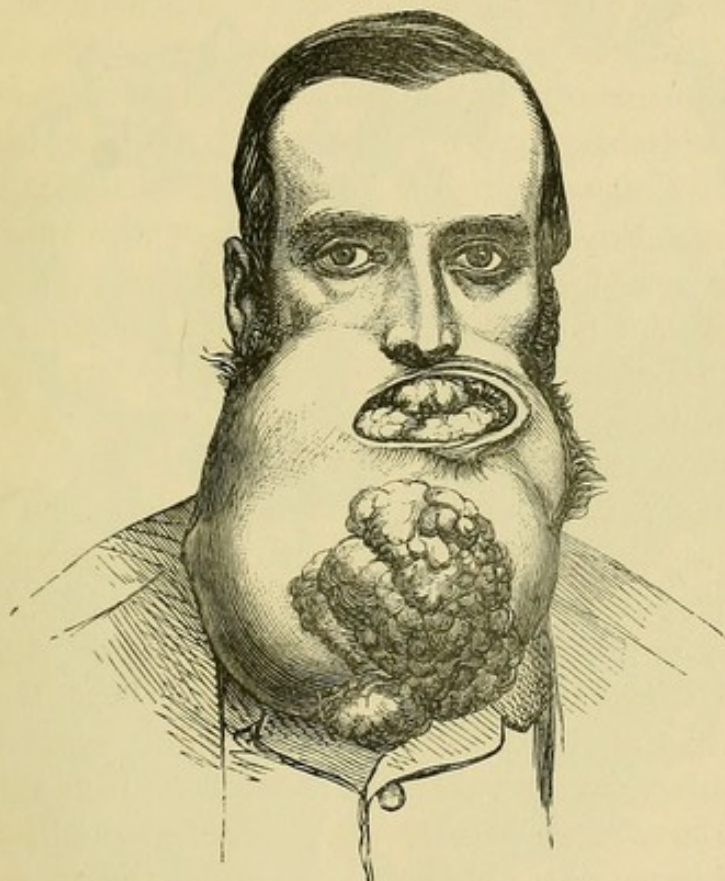
Columnar epithelioma has already been described in one form in connection with multilocular cysts of the lower jaw. One case at least, has been described in which the growth had a distinct columnar structure without the characteristic formation of cysts. For the elucidation of the epithelioma-

tous nature of this case I am indebted to Mr. Eve, to whose lecture on Cysts of the Lower Jaw reference has already been made (p. 198).

The appearance of this tumour is shown in Fig. 155, taken from a photograph.

The enormous size of the tumour can be best appreciated by the drawing, the measurements being as follows : From

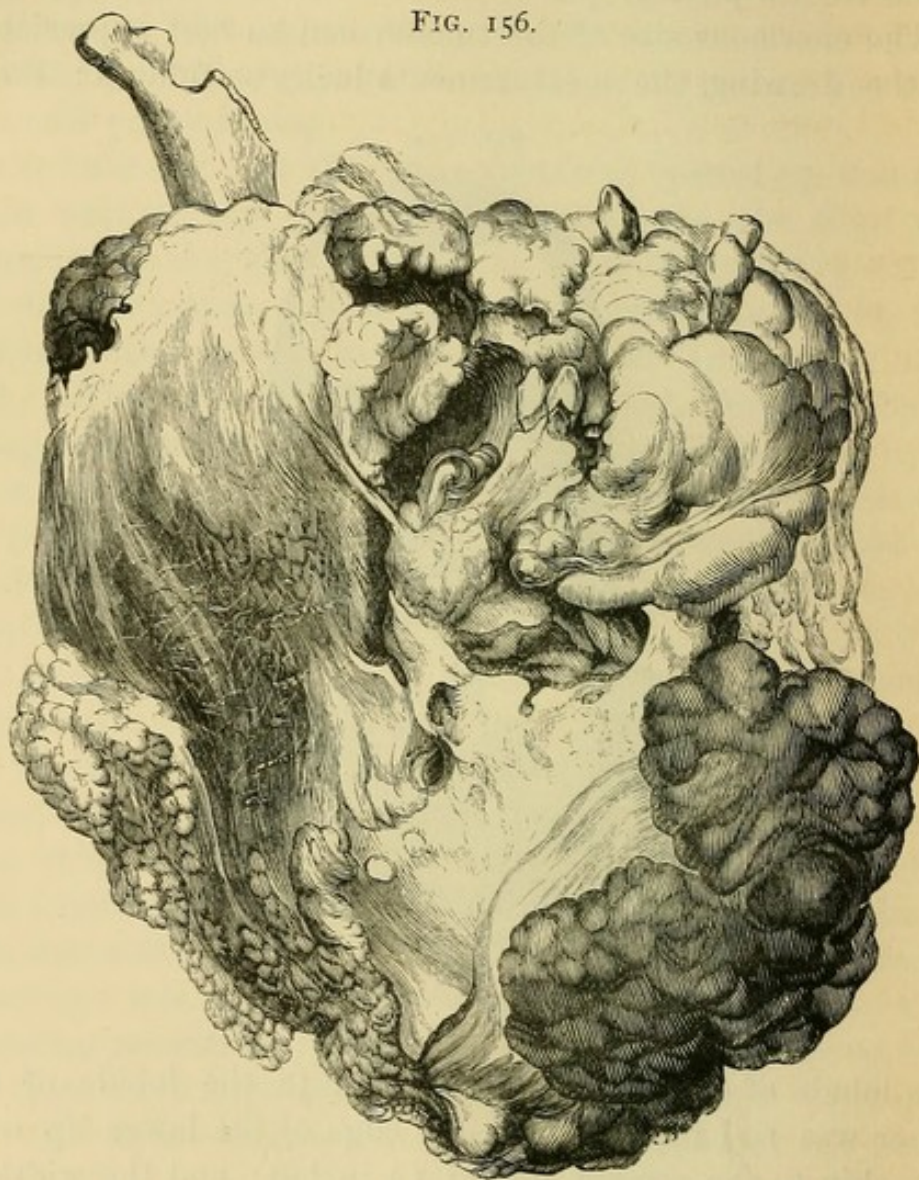
FIG. 155.



the lobule of one ear round the chin to the lobule of the other was $19\frac{1}{2}$ inches ; from the edge of the lower lip over the chin to the *pomum Adami* 13 inches ; and the width of the face was 14 inches. The circumference of the lips was $9\frac{1}{2}$ inches. The patient was only thirty-two, and the disease appeared to have commenced eleven years before, in a small swelling below the right canine tooth, but the whole of the large growth had taken place within four or five years. The fungous protrusions were the result of the application of quack remedies.

The patient was in a miserable condition, being nearly starved, owing to the tumour forming a projecting mass within the mouth, which completely concealed the tongue, and was nearly in contact with the palate. I succeeded

FIG. 156.



in removing the tumour by sawing in front of the left angle and disarticulating on the right side, with very little loss of blood, but the patient died exhausted on the sixth day. The tumour weighed 4lb. 6oz., and is now in the Museum of the College of Surgeons. Its appearance (reduced to about one-third) is shown in Fig. 156. A section has been made to show its structure,

which is precisely that described by Sir P. Crampton, the mass being made up of fibro-cellular tissue of different degrees of density, with here and there small nodules of bone, and a few small cysts interspersed through its structure. The tumour evidently commenced in the interior of the jaw, the outer plate being considerably expanded and destroyed in parts, while the inner remains perfect, and can be seen in the condition in which it was left at the operation. The mass in growing has carried up the teeth with it, and they project from it at irregular intervals, a considerable portion of the growth, and probably the most recently formed part, being posterior to them, occupying as it did the mouth and lying among the muscles beneath the tongue. The fungoid masses are covered with granulations, but otherwise differ in no way from the rest of the growth.

Mr. Eve has examined this tumour, and has found scattered throughout it masses and cylinders of epithelial cells, resembling the epithelial elements of the cystic tumours of the lower jaw already described (p. 198). They were composed of large irregularly shaped or branched masses, and of small columns composed of round epithelial cells, with a layer of peripheral elongated cells. (For drawing, see Lecture by Mr. Eve, *British Medical Journal*, Jan. 6th, 1883.)

In all probability this tumour did not originate from the epithelium of the gum, as it presented no squamous character. It is more likely to have originated in the paradental epithelium already described (see p. 174).

Squamous epithelioma is met with more commonly in the lower jaw than the columnar variety. It always originates in the epithelium of the gum, and may form a typical epitheliomatous ulcer of the gums, which has already been described in the chapter on "Diseases of the Gums."

In other cases, however, it forms a distinct tumour of the jaw. The following, under my own care, is a typical case of the latter form of the disease. A man, aged fifty-six, first noticed a swelling in his face four months before his admission;

he used to have toothache, and had lost all the teeth behind the left lateral incisor in the lower jaw. When first noticed, the tumour was about the size of a small walnut, and was situated on the left ramus near the angle of the jaw. It was not painful or tender to the touch, but grew steadily. On admission to University College Hospital, there was on the left side of the lower jaw a rounded, smooth swelling, which extended from the middle of the vertical ramus of the jaw to the level of the hyoid bone below, and forwards nearly to the symphysis. The swelling was firm and inelastic, and the skin over it was normal, except that it was slightly reddened over the anterior half of the growth. Inside the mouth the growth projected as a large red roundish mass, with the surface flattened and sloughy. It reached as far backward as the vertical ramus, and encroached upon the floor of the mouth. I removed the tumour, with the portion of the lower jaw implicated, by dividing the lower lip in the median line and carrying an incision beyond the angle of the jaw. The jaw was sawn to the right of the median line, between the incisor and the canine teeth, and the tongue being secured with a thread, the bone was disarticulated on the left side with some little difficulty, owing to the tumour breaking away from the upper part. Consequently the coronoid process was nipped off with bone-forceps, and an elevator was used to lift the condyle out. There was very little bleeding, and only one or two ligatures were applied. The wound was sprinkled with iodoform, and brought together with wire sutures, drainage being provided for.

The patient made an uninterruptedly good recovery and left the hospital in thirty days.

The part removed consisted of the remains of the left half of the bone, the part between the vertical ramus and the central incisors being almost entirely destroyed by the growth, only a shell of bone remaining at each end. On section the growth was of a dead white colour where oldest, with a firm margin advancing into the surrounding tissues. It consisted of a fibrous stroma, in which were scattered

numerous leucocytes and spindle cells, with large masses of squamous epithelium cells, many of which were collected into bird's-nest groups. The specimen is in University College Museum.

The general characters of squamous epithelioma of the jaw are well seen in the foregoing case. Rapidity of growth, with destruction of the bone, and fungation into the mouth, are the leading characteristics, and nothing but early and free removal offers any chance of relief. In the above case the jaw in its upper part was apparently healthy, but I had no hesitation in disarticulating so as to be thoroughly beyond the disease, and I also went well into healthy bone at the point of section so as to avoid, as far as possible, all risk of recurrence.

The question of the necessity for the removal of large portions of bone in cases of cancer of the lower jaw may be here referred to. Some surgeons maintain that, in a case of cancer, it is necessary to amputate at the joint above the disease in order to obtain immunity. But, if this doctrine is to be carried out fully, the *entire* lower jaw should be removed for disease of one side, for though the bone was originally developed in two halves, there is nothing to prevent malignant disease spreading across the symphysis, as was seen in a case of epithelioma under my own care.


No definite rule can be laid down concerning this point, excepting that the incisions made for the removal of the growth should go well beyond the disease. In very few cases would it be necessary to remove the entire lower jaw.

The lower jaw is liable to be invaded by epithelioma spreading to it from the tongue, and from the lip or other parts of the face, and may be affected by both sarcoma and carcinoma developed in the neighbouring lymphatic glands.

On more than one occasion I have found epithelioma of the anterior part of the tongue attached to and infiltrating the central portion of the lower jaw, and have been obliged to cut out the incisive region with good result (p. 248).

In the cases of recurrent epithelioma of the lip, when the disease shows itself in the sub-mental glands, which become adherent to and implicate the bone, it is possible to give relief, for a time at least, by sawing out the portion of bone involved, as I did in an old man in May, 1876. In two instances I have sawn off the chin only, without breaking the line of the alveolus, or opening the cavity of

FIG. 157.



the mouth. Fig. 157 shows the first patient on whom I performed the operation.

Fig. 158 shows a somewhat unusual form of recurrence after successful removal of epithelioma of the lip, the growth involving the left side of the lower jaw and implicating the skin over it. I removed the left half of the lower jaw by sawing through the ramus, and included the skin involved; but though the patient made a good recovery, the disease returned before many months, and proved fatal.

Sarcomatous growths in the sub-maxillary lymphatic glands tend, after a time, to implicate the lower jaw, of which it may be necessary to remove a portion with the tumour.

A specimen in the Museum of the College of Surgeons is the left half of a jaw-bone, the body of which has been, to a great degree, destroyed by the growth of a firm substance, which appears to have been developed on the exterior of the bone, and to have gradually produced ulceration and necrosis of it. At the angle of the jaw, adjacent to the growth, the bone is deeply and irregularly ulcerated, and

FIG. 158.

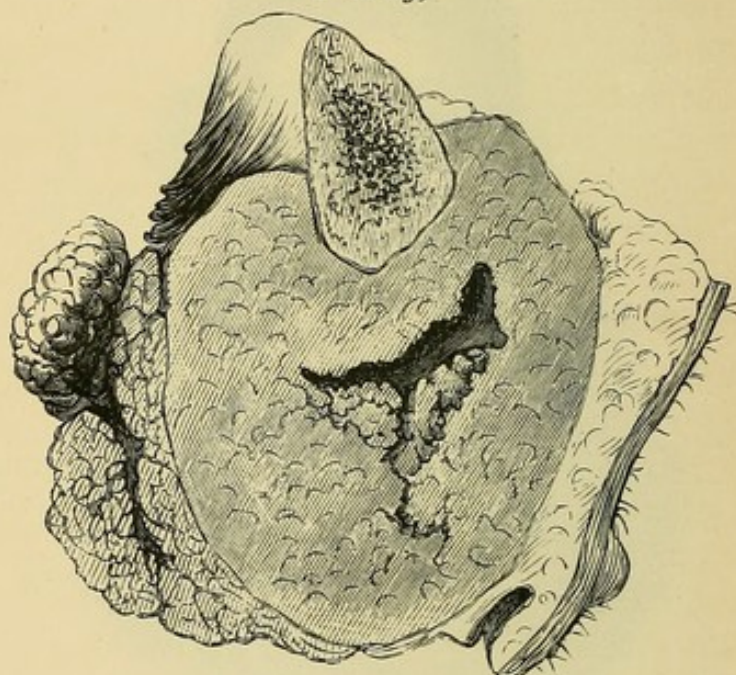


near the symphysis several portions of it are completely detached. The patient was a man of forty-five, and the disease began in a hard enlargement in the situation of the sub-maxillary gland. After increasing for a year it extended into the mouth, where a fungous growth protruded, and subsequently the integuments of the cheek sloughed and rapidly ulcerated, and the patient died exhausted. After death secondary growths were found in the lungs and liver.

By the kindness of Mr. Wilkes, of Salisbury, I was en-

abled to send to the College of Surgeons' Museum a tumour near the angle of the jaw, for which that gentleman amputated one-half of the bone, which was exhibited to the Pathological Society of London, in May, 1862. The patient was a man of fifty, who had a globular mass below the middle of the horizontal ramus of the jaw, adherent to the bone, but movable. The angle of the jaw was roughened near the growth. After removal of the half of the jaw the tumour was found to be enclosed in a thick fibrous capsule,

FIG. 159.



connected with the periosteum. Microscopically the tumour was composed of very small round cells, with very little stroma. It was probably a lympho-sarcoma, and may have originated in the sub-maxillary lymphatic glands.

I have recently had under my care a man of sixty-six, who noticed some stiffness of the neck for about six months before he discovered a tumour near the left angle of the jaw. When he came under my care, three months later, there was on the left side of the face a new growth, involving the angle and horizontal ramus of the jaw, and reaching to the sterno-mastoid behind and the level of the thyroid cartilage below. The skin was reddened and ad-

herent, and at one point had given way. There was no ulceration of the mucous membrane of the mouth, and the glands in the neck were not enlarged. I isolated the growth by a curved incision, including the implicated skin, and then sawed through the lower jaw behind the second bicuspid tooth, and immediately above the angle. The patient vomited persistently after the operation, and sank on the seventh day.

The specimen shows that the lower jaw is surrounded by a new growth which clings tightly to the periosteum, but does not reach up to the edentulous alveolar border. The hard bone of the lower border of the jaw is destroyed, and the growth penetrates into the cancellous tissue. The sub-maxillary gland lying on the inner surface of the mass is being gradually absorbed, the growth pressing on its inner surface. The surface of the tumour (Fig. 159) is surrounded by a distinct outline, separating it from the neighbouring fat. It appears to have commenced in the lymph-gland on the parotid, for of this there is no trace whatever; the remains of the sub-maxillary salivary gland appear perfectly healthy.

Microscopically the growth proved to be squamous epithelioma, consisting of the ordinary stroma, through which were scattered ordinary squamous epithelial cells with 'bird's-nest' fairly well marked. It is a little difficult to explain this occurrence of squamous epithelioma, since the mouth was in no way involved, and so far as could be made out there was no primary disease elsewhere.

CHAPTER XXI.

DIAGNOSIS AND TREATMENT OF TUMOURS OF THE LOWER JAW.

Diagnosis.—The diagnosis of tumours of the lower jaw is easier than in the case of the upper jaw. Slowness of growth, hardness, and isolation point to a non-malignant tumour, and this will be confirmed if there is no tendency to fungate within the mouth, and no enlargement of the neighbouring lymphatic glands. Simple tumours of the lower jaw, if allowed to grow unchecked, may after a time burst through the skin, and thus give rise to a fungating mass, which, however, is of slower growth and more healthy appearance than the malignant fungus. Rapidly growing tumours are almost invariably cancerous, and the only chance for the patient is their early removal, with the portion of bone implicated.

The *prognosis* after removal of tumours of the lower jaw is more favourable than elsewhere, since, owing to the anatomical relations, it is easy to get rid of the whole disease. The question of the return of cancer being influenced by removal of one-half of the bone is, as already mentioned, still an open one.

The successful recoveries following removal of large portions of the lower jaw are very remarkable, operations on the lower jaw being as a rule attended by little constitutional disturbance. Mr. Cusack removed large portions in seven cases, with only one fatal result, which was due to erysipelas and œdema of the glottis. Dupuytren operated in twenty cases, with only one death resulting from the operation, and that from the same cause as in Mr. Cusack's

fatal case. The experience of modern surgeons is equally favourable. When the disease is of ordinary dimensions, and the patient is in fair health, the results are exceedingly satisfactory.

Operations on the Lower Jaw.—Small tumours, involving the alveolus, may be removed with bone-forceps without any incision through the skin, and even a considerable portion of the central part of the lower jaw may be removed without incising the lip, if the mucous membrane between it and the bone be freely divided and the lip drawn well down. The large forceps figured at page 243 are particularly useful in attacking tumours situated in the molar region without external incision, and the gouge and chisel should be freely employed for the enucleation of benign tumours in the interior of the lower jaw.

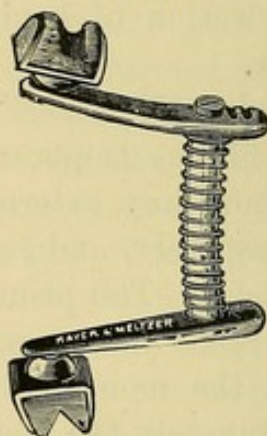
The late Mr. Maunder (*Medical Times and Gazette*, July, 1874) removed two fibrous tumours of the lower jaw of considerable size without any external incision, separating the soft parts with a raspatory, and sawing the bone in front of and behind the tumour. The principal difficulty in these operations was not so much the separation of the tumour as its 'delivery' through the mouth, which was slightly split in one instance. Fortunately the hæmorrhage in both cases was slight and the patients did well, but another surgeon who adopted the proceeding was less fortunate, and lost his patient by secondary hæmorrhage, which, considering the close proximity of the facial artery, and the necessary division of the inferior dental artery, is not very surprising. For my own part, I do not think the extra trouble and risk of the proceeding are balanced by the absence of a scar, which, in the majority of cases, need not involve the lip, and if properly placed will be nearly invisible afterwards. The same may be said of the so-called 'sub-periosteal resections' of the lower jaw. In cases of necrosis it is, of course, advisable to preserve all the periosteum, and in extracting a sequestrum it may be occasionally necessary to turn aside soft parts with a raspatory, but any systematic stripping of periosteum from a jaw involved in a tumour,

is not only impossible, but, if undertaken, will surely leave shreds of periosteum with, possibly, some portion of disease attached.

In order to operate satisfactorily within the mouth it is essential that the jaws should be kept fully asunder, and I have found nothing so convenient for the purpose as a simple vulcanite 'prop,' similar to that used by dentists, placed in position on the side opposite to the disease before the administration of chloroform. A string attached to it obviates any danger of its being swallowed.

The ingenious gag invented by Dr. Wingrave (Fig. 160) may also be employed for the same purpose. It is automatic,

FIG. 160.



opening by means of a spiral spring, and locking by reason of the curved form of the bar.

When a large portion of the body and ramus has to be removed, a curved incision may be advantageously carried along the posterior margin of the tumour, so that the scar may be well out of sight afterwards. In this the facial artery will be necessarily divided at the anterior border of the masseter muscle, and it is advisable to secure both ends immediately with ligatures, or the patient may lose a considerable quantity of blood. The tissues being then dissected off the tumour, a careful examination of it should be made, to see if it be possible to extract the tumour by removing the external plate of bone with the gouge and bone-forceps; and no harm can come of such an attempt, even if it prove abortive, since no vessel of importance is interfered with.

If necessary, however, a small saw can be applied in front of and behind the affected portion, which can then be readily isolated and removed.

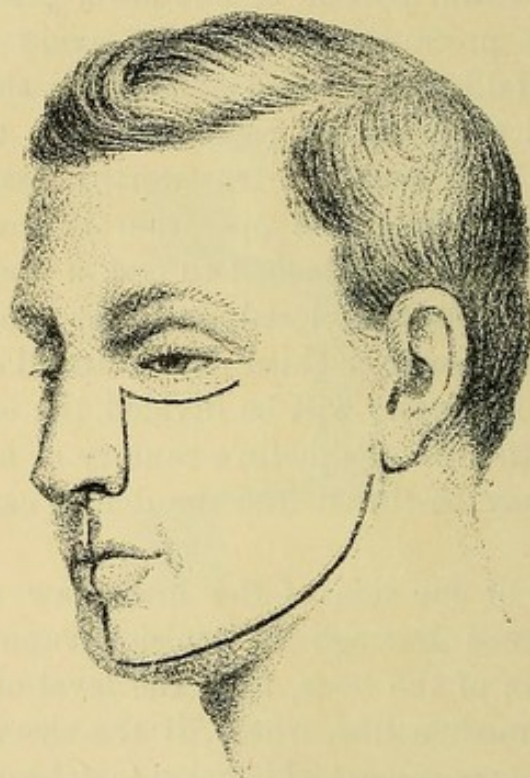
In making these sections of the lower jaw it is better not to complete one before the other is begun, because of the loss of resistance consequent upon breaking the continuity of the bone; but both cuts, being carried nearly through the bone with the saw, may be conveniently completed together with the bone-forceps.

When the central portion of the lower jaw is removed, it is well to take precautionary steps to avoid the possibility of the tongue falling back and suffocating the patient. A ligature should therefore be passed through the tip of the tongue, which will enable a trustworthy assistant to keep it drawn forward until the operation is completed. The ligature should then be attached to one of the hare-lip pins with which the wound is closed, and may safely be cut and removed on the second or third day. In all cases in which the inferior dental artery will be divided, the operator should be provided with a fine Paquelin's cautery or a small plug of wood, which may be thrust into the dental canal to stop all bleeding.

Amputation of one side of the lower jaw can be conveniently performed through an incision running along the posterior margin of the bone, from the level of the lobule of the ear to the median line, where, if the size of the tumour renders it necessary, a vertical incision may be carried through the lip (Fig 161). The facial artery having been secured, the tissues of the cheek and the masseter are dissected up, without injuring the flap and without prolonging the incision upwards, by which the facial nerve would be of necessity divided. A tooth having been extracted at the point where the bone is to be divided, this is effected with a small straight-backed saw, and the bone having been grasped with the 'lion-forceps,' is drawn forcibly outwards, whilst the knife is run along its inner side, care being taken to keep close to the bone, so as not to endanger the sub-maxillary gland or lingual nerve. The internal pterygoid muscle

having been carefully separated from the bone, forcible traction is to be made upon the jaw, so as to depress the coronoid process, which by a few touches of the knife is freed from the fibres of the temporal muscle. The joint being now in view, the knife is to be applied to the front of it, when the condyle will be at once dislocated, and the knife can be carried cautiously behind it, so as to isolate it. A forcible wrench of the bone will now tear through the

FIG. 161.



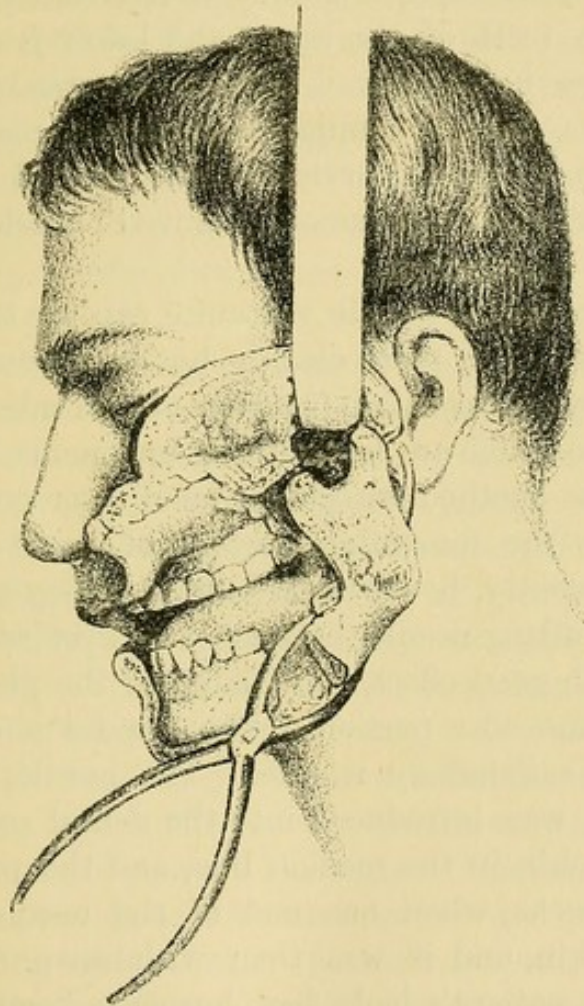
few remaining fibres of the external pterygoid muscle, and the bone can be removed (Fig. 162). At the same time care must be taken not to twist the jaw outwards, so as to force the condyle and neck of the bone against the internal maxillary artery, which might thus be torn.

In order to obviate the difficulty which often occurs at this stage of the operation, Dr. Gross recommends a flat bone-elevator, to clear the coronoid process and condyle, and thus avoid all danger to the artery. Having employed this plan on several occasions I can strongly recommend it. Mr. Bryant has in some cases dissected up the periosteum

and slipped the condyle out of it, but there appears to be a danger of leaving disease behind in many cases, if this plan were generally adopted.

In the case of small tumours, removal of one-half of the lower jaw is sufficiently easy, but, when the tumour is large, it may so completely wedge in the upper part of the bone

FIG. 162.



as to hinder the freeing of the coronoid process, and prevent dislocation. Under these circumstances the best plan is to use the bone-forceps to cut off the coronoid process, or to re-apply the saw and cut off the tumour as high as may be, and subsequently to remove the remaining portion of jaw, if the disease is malignant, but not otherwise. Another complication is when the tumour breaks away from the upper part of the jaw during the operation, thus rendering

it difficult to dislocate the condyle, owing to the want of leverage. The 'lion-forceps' of Sir William Fergusson is exceedingly useful here, as I have experienced in several cases.

When one-half of the lower jaw has been removed, some inconvenience is experienced from the remaining portion being drawn inwards by its muscles. To obviate this, Mr. Nasmyth, of Edinburgh, originally contrived some metallic caps to fit the teeth of the upper and lower jaws, and thus keep the bone in position. Mr. Liston speaks highly of this apparatus, and a similar contrivance made by Mr. Cartwright was of great service in the case of the patient from whom Sir W. Fergusson removed one-half of the lower jaw.

I have employed a double vulcanite cap for the teeth for the purpose, as being more cleanly, but have found so much pain caused by the constant tension of the muscles of the unaffected side which are left without opponents, that I have abandoned the method altogether, and was content until lately to allow the remaining portion of jaw to be thrust inwards. Recently, however, Mr. Stanley Boyd introduced a piece of knitting-needle between the divided ends of a lower jaw with good effect, and I adopted the plan in a case in which I removed a portion of the jaw for non-malignant disease, with satisfactory results. The needle, which was slightly bent, was introduced into the dental canal so as to maintain the chin in the median line, and the patient wore it for some weeks, when one end of the needle protruded through the skin, and it was then withdrawn. The result as regards the patient's looks has, however, been very satisfactory, and I should again adopt the plan in a case of non-malignant disease of the side of the jaw; but when the symphysis is removed it appears to be better to allow the halves of the jaw to fall together and unite.

In the case of very large tumours, necessitating the removal of the greater part of the lower jaw, the direction of the incision is a matter of considerable importance. A semi-lunar incision below the mouth was employed by Sir

William Fergusson in cases of the kind ; the great advantage being the non-interference with the lip (which is dissected up with the integuments of the chin), and the fact that the scar is completely hidden afterwards. On the other hand, this incision necessitates the division of both facial arteries, and if disarticulation on one side is requisite, will not afford good room for the proceeding without danger to the facial nerve. In a case of very large epithelioma of the lower jaw, already described, I preferred an incision through the median line of the lip, and was able to dissect the flaps back with great ease and rapidity, and to avoid cutting either of the facial arteries. The median line is, after all, the best position for a cicatrix, and I regard the division of the lower lip, which always readily unites again, as a very unimportant matter.

Whatever the operation which has been performed, care should be taken to secure all bleeding vessels, and when there are bleeding points deep in the wound which cannot thus be treated, the actual cautery should be applied to them. The dental artery, necessarily divided in sawing the jaw, is sometimes troublesome if its mouth is not touched with the cautery, or the dental canal plugged with a small piece of wood. The incision in the skin should be carefully adjusted with wire or silk sutures, and the lip brought together with hare-lip pins and a twisted suture, fine silk sutures being put in the mucous membrane lining the back of the lip, so as to prevent the access of saliva. Care must be taken to provide for the drainage of the wound by leaving an opening at the most dependent part, into which a drainage tube may be put, and if necessary a light bandage may be applied to support the parts. At the time of the operation the wound may be thoroughly sponged out with a solution of chloride of zinc (gr. 40 ad 3j), or better, the whole of the wound may be thoroughly sprinkled with iodoform, which has a most marked antiseptic effect.

The after-treatment consists in supporting the patient's strength by administering fluid nourishment with a feeder or tube and bottle, and careful washing out of the mouth

with detergent lotions, so as to keep it clean and healthy during the process of healing; and when the effects of the iodoform have worn off, nothing is more effective as an antiseptic than the glycerinum acidi carbolici freely applied with a camel's-hair brush.

Operations on the lower jaw are quite of modern date. Anthony White, of the Westminster Hospital, appears to have been the first surgeon who removed a portion of the lower jaw (1804). He was followed by Dupuytren (1812), Mott and Gräfe (1821), and Sir P. Crampton in 1824. Cusack's celebrated cases of disarticulation occurred immediately afterwards, and the operation became an established one. The names of Liston, Syme, and Fergusson have been prominent in connection with the operation in this country, whilst abroad Lisfranc, Lallemand, Maisonneuve, Gensoul, and other eminent men, have given it their support.

It has been already noticed how little deformity often results from the removal of portions of the lower jaw. Although the bone is never reproduced, a development of firm fibrous tissue takes its place, which affords support to artificial teeth, and to which the muscles gain a firm attachment. In February, 1855, Mr. Spence, of Edinburgh, brought before the Medico-Chirurgical Society of Edinburgh a preparation illustrating this point in a marked manner. Eighteen years before the patient's death, Sir William Fergusson had removed the greater part of the right side of the lower jaw. Five years later Mr. Spence had removed the left side of the jaw from within half an inch of the symphysis to the articulation, and the condition found at death, thirteen years after, is thus described (*Edinburgh Medical Journal*, April, 1855): "A dense fibrous texture connected the small portion of the ascending ramus of the right side with the remaining portion near the symphysis, whilst on the left side a similar texture occupied the place of the disarticulated bone, on both sides affording firm attachments to the masseters and other muscles, so that the patient during life had considerable use of the mouth."

The tendency of the muscles to force the remaining portion of the jaw out of place has been already referred to. In cases in which the central portion of the jaw has been removed, the force of the muscles on both sides being equally exerted, the rami of the jaw become closely approximated, and are united by very firm fibrous tissue, which eventually develops into bone, as in a specimen in University College Museum. This, of course, gives a peculiar narrowness to the lower part of the face, which is fortunately concealed in men by wearing a beard.

The supplying of artificial teeth to a patient who has undergone removal of a portion of the lower jaw will tax the ingenuity of the dentist considerably, for when the muscles have forced the remaining portion out of position, it becomes necessary to employ means to bring the teeth into their normal relation so as to obtain a proper 'bite.' The vulcanite rubber forms a most useful base for the artificial teeth, and if firmly attached to the remaining portion of jaw it moves very satisfactorily with it, lying in the hollow of the cheek and resting upon the dense fibrous tissue of the cicatrix.

CHAPTER XXII.

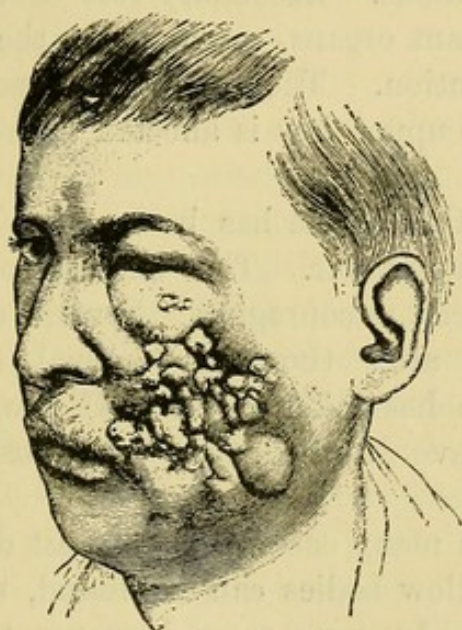
PARASITIC DISEASES OF THE JAWS.

Actinomycosis.

ALTHOUGH actinomycosis may be found in almost any part of the body, yet, in the majority of cases, its primary seat is in the jaws, the lower jaw more frequently than the upper. It is much more common in cattle than in man. It has been settled beyond doubt, that the active agent in producing the disease is a fungus termed *actinomyces* or, from its appearance under the microscope, the 'ray-fungus.' The fungus is taken in through the mouth, and may lodge in almost any part of the alimentary or respiratory tracts. It has been already mentioned that the jaws are the structures most frequently affected, and the explanation of this fact is probably to be found in the intimate relation that exists between the teeth and the jaws. Any breach in the integrity of the teeth, such as is brought about by decay, serves as a gate through which the fungus can enter and penetrate into the interior. We find that the clinical history of the case is in accordance with this view. Thus, the earliest symptom is very frequently tenderness, and sometimes severe pain, localised in one or more of the teeth; on examination the teeth are found to be carious, and the pain is generally attributed to ordinary septic inflammation caused by the focus of decay. Within a few weeks a swelling forms. When the lower jaw is affected the swelling is situated at the angle of the jaw; when the upper jaw is affected a swelling is noticed at some part of the cheek. The tumour is firmly fixed to the jaw, and may be either soft or hard.

As the tumour increases in size the skin over it becomes slightly inflamed, and fluctuation can be readily detected. If the swelling is not opened by the surgeon it will finally burst. In either case a turbid serous liquid escapes, containing in suspension small yellow grains, which have a very characteristic appearance and consist of masses of the fungus. Around this swelling the tissues become affected in diffused areas, which break down in places and form numerous fistulæ, communicating one with the other and opening on

FIG. 163.



the surface by several crateriform apertures. This condition is well shown in Fig. 163 (Albert). On passing a probe into the sinuses bare bone can be readily felt. A slight amount of pus trickles away from the openings of the fistulæ. This diffuse infiltration of the skin and subcutaneous tissues may spread widely, passing downwards along the neck and upwards to the temporal region. Sometimes the sub-maxillary lymphatic glands become inflamed and may suppurate. The spreading inflammation may also cause that condition known as 'closure of the jaw' (p. 389). As a rule the temperature is not raised, but sometimes there is distinct fever if exit is not given to the purulent collections. The constant discharge of pus leads to progressive emacia-

tion and finally to lardaceous disease. In some cases septic poisoning accelerates the course of the disease. In other cases numerous secondary foci develop, especially in the lungs. As a rule, the course of the disease is chronic, lasting one or two years; occasionally, however, the disease takes a very rapid course and may terminate fatally within three months.

Prognosis.—Unless the disease be eradicated at an early period the prognosis is very grave. The progressive emaciation and cachexia render the patient very liable to fatal intercurrent affections. Secondary foci of the disease may appear in important organs, especially in the lungs, and lead to a fatal termination. The prognosis appears to be more serious when the upper jaw is affected than when the lower jaw is attacked.

In rare cases the disease has been cured by incision and drainage of the tumour. The success of more radical treatment has been encouraging. Several cases have been recorded where, after thorough removal of the diseased structures, a cure has taken place. If, however, secondary visceral foci have formed, the prognosis is probably hopeless.

Diagnosis.—In many cases this is most difficult. If the characteristic yellow bodies can be found, any doubt is at once cleared up. In some cases, however, they may not be found, even after a prolonged search. We must then take into consideration other factors. Thus, the occupation should be ascertained; any work necessitating contact with cattle may lead to infection. The chronicity of the disease, the spreading, inflammatory character, and the formation of numerous inter-communicating fistulæ, should be borne in mind.

Treatment.—It is obvious that complete removal of the fungus should be aimed at. In very early cases this might be attained by opening the swelling and thoroughly scraping the walls with a sharp spoon. In more advanced cases, free removal of the skin and deeper structures with the knife, combined with scraping, is necessary. In some cases the

disease is too extensive to be treated in this way. The injection of germicides, especially perchloride of mercury, has been recommended in these cases. Owing to the diffuse character of the secondary lesions in the viscera, operative treatment is out of the question.

Mycosis Aspergillina.

Zarniko (*Deutsche med. Woch.*, 1891) records a case of *mycosis aspergillina* of the antrum of Highmore. The following account is taken from the *Supplement to the British Medical Journal*, 1891:

The patient, a woman, aged fifty, complained of nasal obstruction, with an offensive and copious nasal secretion, frontal headache, and an occasional sense of fulness in the left ear. Rhinoscopy showed that both middle turbinated bones were occupied by irregular tumours attached by a broad base, and almost filling the middle meatus of the nose. On the left side, moreover, was some creamy highly offensive pus, occupying the middle meatus and covering the upper surface of the lower turbinated bone. This pus could be made to ooze freely if the tumour was pushed towards the septum with a probe. The soft palate was shortened by cicatrization and drawn up, especially on the right side, radiating cicatrices being also visible on the hard palate and pharynx. Zarniko removed the tumours by means of a snare, and, as soon as the wounds had healed, passed a curved tube into the left antrum of Highmore, and syringed it out, removing in this way a number of dark brown, more or less friable, lumps as large as peas. On microscopic examination these lumps were found to consist of a fungus, presenting all the characters of *aspergillus fumigatus* (Fresenius). The antrum was regularly washed out with boracic and corrosive sublimate lotions, rapid improvement taking place. The lumps disappeared, together with the offensive smell; the discharge of pus also greatly diminished. Zarniko considers this disease to belong to the same category

as otomycosis. The mucous membrane of the antrum, when healthy, is probably unsuited to be a soil for the aspergillus, but, in this case, it may possibly have become suited as a result of serous catarrh, the growth of the fungus provoking and maintaining the inflammatory condition observed. Zarniko recommends that the disease should be attacked through the middle meatus. This method is simpler than any other.

CHAPTER XXIII.

DISEASES OF THE TEMPORO-MAXILLARY ARTICULATION.

THE temporo-maxillary articulation is, like other joints, the subject of inflammation due to constitutional and local causes, to which latter its exposed position would seem to render it particularly liable. Yet it is remarkable that acute disease of the temporo-maxillary joint is hardly recorded, and I think the explanation is to be found in the fact that it is often confounded with acute affections of the ear, and that mischief beginning in the articulation may induce purulent discharge from the meatus in children.

That destructive disease of this articulation is not very infrequent, is evident from the number of museum specimens extant of complete ankylosis, and of the numerous cases of fibrous ankylosis which have been met with in practice.

The diseases of this joint may conveniently be divided into acute arthritis, chronic arthritis, and tubercular disease.

Acute Arthritis. — The cases of acute arthritis are numerous, and it would be inconvenient to classify them according to their causes. They fall, however, very naturally into two groups, those that do not suppurate and those that do.

The three chief causes of *non-suppurative arthritis* are rheumatism, injury and gonorrhœa. There is swelling and pain in the region of the joint, and sometimes the pain may spread to the temple or ear. The pain causes spasm of the muscles, and hence difficulty or impossibility in opening the mouth. The acute stage lasts from one to two or three

weeks, and may sometimes terminate in partial or complete ankylosis.

The causes of *suppurative arthritis* are various. The inflammation may commence in the joint, or may spread from some neighbouring structure. A severe injury may lead to suppuration, but more commonly it occurs during the course of some specific disease, such as scarlet fever, measles, &c. Mr. Spanton, of Hanley (*Lancet*, April 16th, 1881), reported two cases following scarlet fever. They came under his care for the resulting ankylosis, which he successfully treated by dividing the fibrous bands with a tenotome passed into the articulation. A considerable number of the cases are secondary to suppuration in the neighbourhood. Thus, in Guy's Hospital Museum is the skull of a negro who had disease of the cervical vertebræ, and complete osseous ankylosis of the temporo-maxillary articulation, coming on after a wound in the neck from a fork. The history of the man, with a drawing of the skull, will be found in Mr. Hilton's "Lectures on Rest and Pain."

In some cases, no doubt, the inflammation is secondary to suppurative otitis media. This occurred in a gentleman, aged twenty-five, who was sent to me by my friend, Dr. Bate. I saw him first in February, 1866, when he told me that he had the measles badly when nine years old, and this was followed by discharge from the left ear, which became deaf. The discharge had ceased for two years, when in September, 1864, he caught a severe cold, and it recommenced, and at the same time the left temporo-maxillary articulation became swollen and stiff, so that he was obliged to live by suction for some time. The discharge from the ear was very profuse, as much as half a pint at a time, and matter burrowed under the tissues of the face as high as the orbit, where a small opening formed, and down the neck, discharging into the throat for three days. Finding the left lower wisdom tooth cut awry and very far back, I thought that this might possibly be connected with the disease, and therefore had it extracted, with some difficulty,

by Mr. Mummery. In the following July I found that he had derived no benefit from the extraction, and the jaws were as firmly closed as before. The space between the incisors was $\frac{1}{4}$ inch, and rather more between the bicusps on the left side. The mouth did not open so widely as it had done eighteen months before, but he had perceived no difference during the preceding six months. There was no external deformity, but he said he heard a grating sound on moving the jaw which was not audible externally.

My colleague, Mr. Arthur Barker, in his valuable article on Diseases of the Joints ("System of Surgery," vol. ii), mentions that in cases of suppuration of the middle ear, the temporo-maxillary articulation may become involved through the floor of the meatus, in which a hiatus often exists in children. He quotes in proof of this a case which I had long under my care, a child, from whose meatus the condyle of the jaw was extracted; but I should rather regard it as a case in which, from disease of the temporo-maxillary joint, perforation had ensued, and the condyle had found its way into the meatus.

Chronic Arthritis.—The researches of the late Dr. Robert Adams and Dr. R. W. Smith, of Dublin, have shown that rheumatoid arthritis occasionally affects the temporo-maxillary articulation, and the former author has, in his 'Atlas, figured the remarkable hypertrophy of the neck of the condyle of the jaw, occurring in the case of a woman, aged thirty, to which I shall have occasion to refer more particularly later on.

Cruveilhier, who first described an example of rheumatoid arthritis of the temporo-maxillary articulation (*Anatomie Pathologique*, liv. ix), says: "I have never seen the disease I call wearing away of the articular cartilages better marked than it was in this case. The condyle of the lower jaw did not exist; it might be supposed to have been sawn off horizontally at the line of junction of the head with the neck, and that which remained of the neck had been flattened. The articular part of the glenoid cavity was represented merely by a plane surface; no trace of inter-articular

cartilage or cartilage of incrustation existed. Both surfaces of the altered articulation were remarkably red."

I have never had the opportunity of examining a recent example of this disease, but as far as can be judged from

FIG. 164.

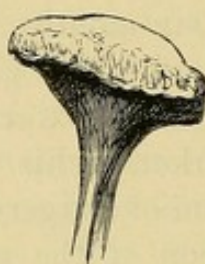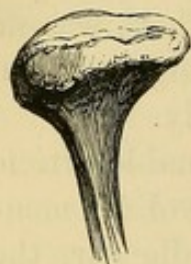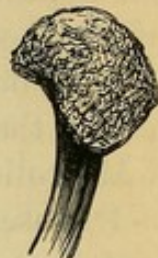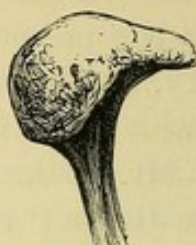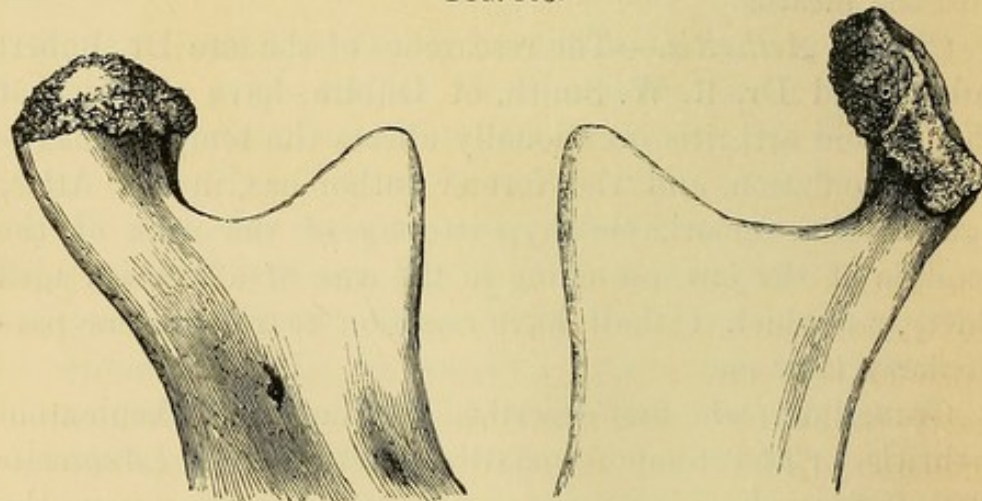


FIG. 165.



museum specimens, the articular surface of the condyles is flattened and somewhat altered in direction in the less marked instances (Fig. 164), and absorption of the neck, with complete wearing away of the articular surfaces (Fig. 165), occurs in the older and more advanced cases. I agree

FIG. 166.



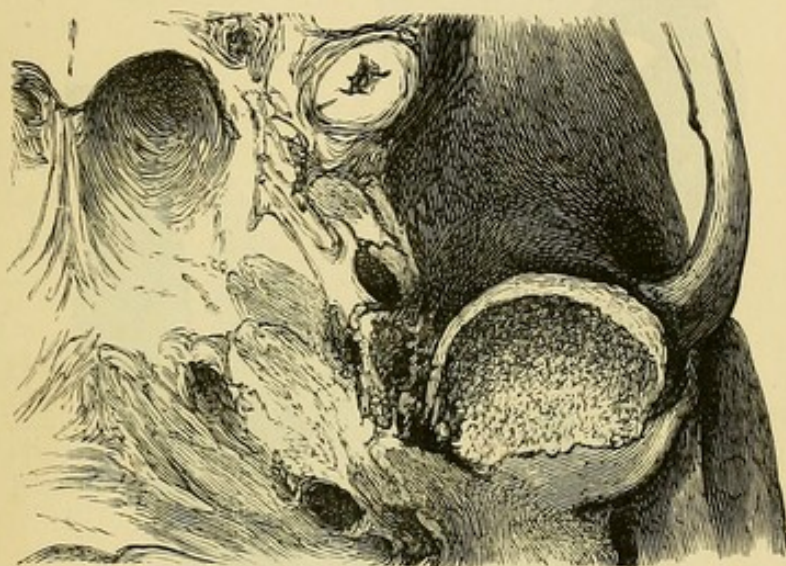
with Dr. Adams, that eburnation of the articular surfaces, or the occurrence of porcellanous deposit in the temporo-maxillary articulation, is very rare. The description quoted from the St. Bartholomew's Catalogue by Dr. Adams refers to preparation No. 551 in that museum (Fig. 166), and is as follows:

"There has been disease in one of the articulations of the

jaw, producing absorption of the articular cartilage, with a deposit of bone around the circumference of the glenoid cavity. The corresponding condyle is in part removed by absorption; its surface is rough, except at one point, where it is highly polished, and has an ivory-like texture."

Enlargement of the glenoid cavity is common in these cases, and is well seen in Fig. 167, taken from the same specimen in St. Bartholomew's Hospital. Absorption of bone must of course occur in these cases, but it is worthy of remark that, as pointed out by Dr. Adams, the bone forming

FIG. 167.



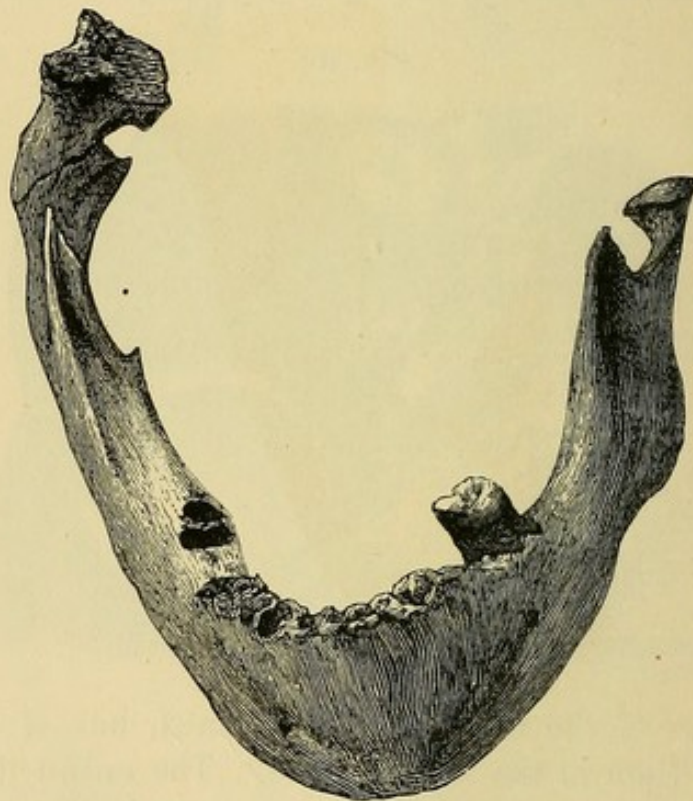
the fundus of the cavity is not thinned, but, if anything, is thicker than in the normal state. The entire disappearance of the inter-articular fibro-cartilage is, apparently, an early event in chronic disease of the temporo-maxillary articulation. It had entirely disappeared in all the few recorded post-mortem examinations, and was absent in a case of hypertrophy of the condyle in the living subject which I successfully operated on.

Hypertrophy of the Neck and Condyle was observed by Dr. Adams in the case of rheumatoid arthritis of the temporo-maxillary joint already referred to, and is beautifully shown in Plate 1 of his admirable 'Atlas.' Though occurring in a woman of only thirty, there can, I think, be

no doubt, from the description and drawings of her hand and feet, that the patient was the subject of rheumatoid arthritis. It is by no means certain, however, that the hypertrophy of the neck and condyle must be considered to be the results of that disease, for, as I shall show, this same rare deformity has been found in patients otherwise healthy.

Fig. 168 shows a lower jaw so like that figured in

FIG. 168.

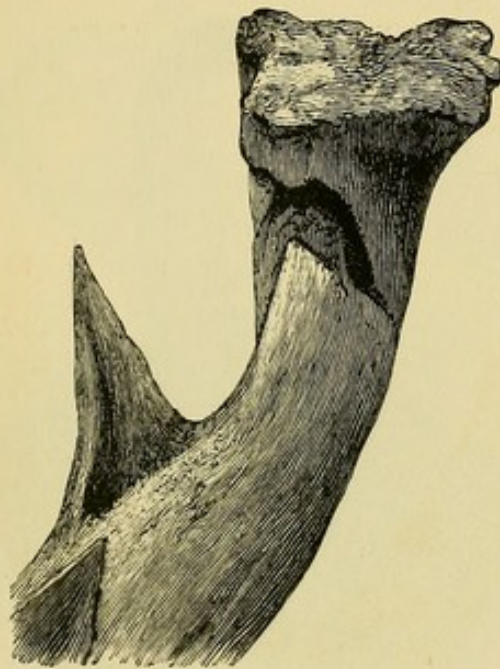


Adams' 'Atlas' in every respect, that the preparations are evidently identical in their nature. It was presented to the College of Surgeons' Museum by Mr. Jeremiah McCarthy, and is thus described by Mr. Eve :

"A lower jaw with a mass of bone, having somewhat the form of an inverted pyramid, attached to the thickened neck of the right condyloid process. The upper surface of the mass, corresponding to the base of the pyramid, is flat and smooth as if it had been covered with fibro-cartilage (Fig. 169). Upon its inner side is a deep indentation, from

which a fissure extends outwards and downwards nearly to the external surface of the bone. The indentation and the fissure constitute the upper boundary of a portion of bone, which, from its form and position, might be taken for an enlarged condyle. The right half of the jaw is larger in all its dimensions than the left half, the breadth of the horizontal ramus in front of the angle being double that on the left side, which, from the slenderness of the coronoid

FIG. 169.



and condyloid processes, appears atrophied. From a middle-aged man, who died with apoplexy. There was a remarkable deformity of the face from the deviation of the symphysis from the middle line; and the projection of the enlarged condyle was considerable. The base of the skull was not examined, and nothing was found in the post-mortem examination except atheroma of the vessels. Nothing unusual had been noticed about his mouth in childhood, nor could any account of an injury be obtained." (See *Pathological Society's Transactions*, vol. xxxiv, 1883.)

In the same volume of the *Pathological Society's Transactions* will be found the record of a remarkable specimen of hypertrophy of the neck and condyle of the

jaw, removed by myself from a woman, aged thirty-six, whose face had for ten years become gradually more deformed, by the increasing displacement of the chin to the right side and the projection outwards of the left condyloid process. The movements of the jaw were restricted, and the length of the left ascending ramus was three inches, of the right one inch and a half. She had an attack of hemiplegia, implicating the left side of the face, when she

FIG. 170.

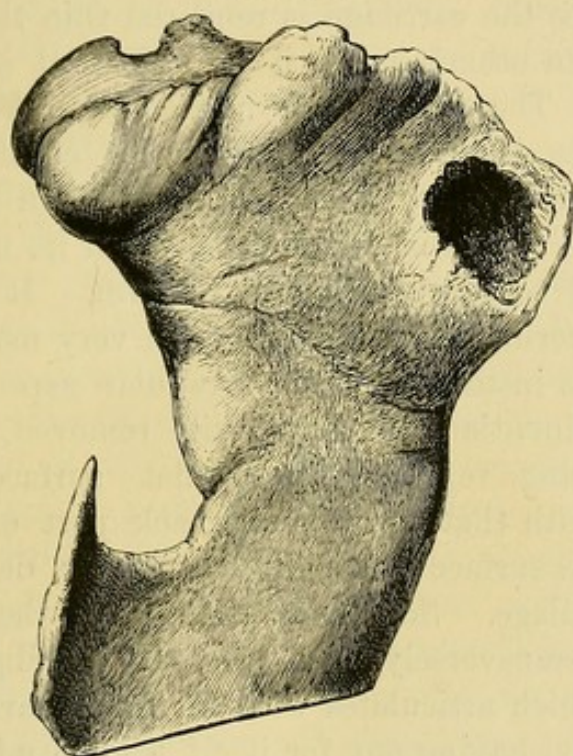


was twenty-five years of age, and from this affection her limbs had recovered perfectly and her face partially.

The appearance of the patient (who was sent to me by Dr. Williams, of Sherborne) is seen in Fig. 170, and the piece of bone removed is accurately drawn in Fig. 171, the hypertrophied condyle measuring one inch and three-quarters from before backwards, and one inch across, and being covered with fibro-cartilage. A section of the preparation shows it to be composed of cancellous bone with large rounded spaces, and its walls are formed of a thin layer of compact bone. The

fissure observed in Mr. McCarthy's does not exist in this specimen. If the condyle thus shown is compared with Fig. 169, which represents the condyle of Mr. McCarthy's case, of the natural size, there can be little doubt that my preparation, Mr. McCarthy's, and Dr. Adams's all belong to the same category; and yet in Mr. McCarthy's probably, and certainly in my own case, this was the only joint affected. It must be concluded then, I think, that

FIG. 171.



hypertrophy of the neck and condyle may occur in otherwise healthy patients, and I believe that I saw, in consultation with Mr. Nathaniel Stevenson, the early stage of this curious condition in a young healthy lady of about twenty, in whom the lower teeth had gradually become displaced from no known cause, so as to disarrange the normal bite. I here detected, what was then new to me, some hypertrophy of the neck of the jaw on one side, and recommended blistering and a course of iodide of potassium without any marked benefit, except that the deformity has not increased. In the patient, whose portrait is given in Fig. 170, the deformity was so great as to warrant surgical

interference, and the result has been very satisfactory, the face being brought straight, and the patient having free movement of the jaw.

In old age, after the teeth have fallen out, certain changes take place in the joint resembling those produced by rheumatoid arthritis. "These changes are frequently very marked. The fibro-cartilage is very often completely removed, the only relic of it to be found being a fimbriated margin attached to the inner aspect of the loose capsule. In other cases the cartilage is rendered thin throughout its extent, and in others, again, it is perforated internally and posteriorly. The appearance presented by the articular surface of the head of the jaw, varies considerably. In some cases the head, while not diminished in breadth, loses its convexity, and is instead flattened on its upper surface, the flat facet being quadrilateral in form. It may present a partial covering of cartilage, but in very many cases the bone presents instead a porous granular aspect. In such cases the eminentia is usually quite removed, the original elevation being replaced by a flat surface, which is continuous with that forming the back part of the glenoid cavity. This surface is usually completely deprived of its articular cartilage. Sometimes the head of the jaw is much constricted transversely, and presents a slight rounded convexity, which articulates with the inner part only of the glenoid cavity, having cut for itself a longitudinal channel through the inner portion of the eminentia articularis, the outer portion of this convex surface of bone presenting but slight changes."

This description is copied from Mr. Arbuthnot Lane, who has published some original views on the mechanical causation and pathology of rheumatoid arthritis. (*Pathological Society's Transactions*, 1886).

These changes, in Mr. Lane's opinion, "are due to the loss of teeth, and to the consequent modification in the normal movements of the temporo-maxillary articulation, and the general atrophy of the muscles of mastication, especially of those that serve to approximate the jaws, namely, the masseter

and internal pterygoid. It is owing to the action of these two muscles that the form of the angle of the jaw varies at different periods of life. As these muscles are used with great vigour during young adult life, the surfaces of bone into which they are inserted become strong and dense, and marked by vertical ridges indicating the attachment of the tendinous insertions of the muscles, especially of the masseter, and it is owing to the action of the latter muscle that the margin of the ramus is everted. As these muscles atrophy and become almost, if not completely, functionless, the portions of the bone into which they are inserted lose their prominent ridges and their everted margin, and become rounded and wasted in a manner similar to that in which the portion of the great tuberosity of the humerus, which receives the insertion of the supra-spinatus, atrophies in feeble old age. It is this atrophy of the angle which causes the appearance of the jaw peculiar to edentulous old age. The atrophy of the fibro-cartilage is due partly to an atrophy common to it and the muscle inserted into it, and partly to the loss of the movements of flexion of the temporo-maxillary articulation, and to their replacement by a simple antero-posterior movement of the opposing surfaces of bone upon one another. After the fibro-cartilage is removed, the articular cartilage is also destroyed, the surfaces of bone being brought into direct contact. By their mutual friction they destroy one another, and the amount of destruction will depend on the amount and character of the movement to which the bones are exposed, and the vitality of the osseous and nervous systems."

Tubercular Disease.—This is a very rare disease and but few cases are recorded. In his "Practical Observations in Surgery" (1816), Mr. John Howship describes a case of "scrofulous inflammation of the face, followed by ankylosis of the jaw" in a man of fifty-six years of age, who dated the origin of the disease from a cold taken at the age of four. The original illustration shows complete bony ankylosis of the lower jaw to the temporal bone on the left side. On the right side the shape of the joint is considerably modified, as may be seen in the specimen in the College of Surgeons'

Museum. Lannelongue has reported a case of tubercular disease in which the condyle became separated from the rest of the bone, passed into the auditory meatus and penetrated into the cranial cavity, causing an abscess of the brain (*Bull. de la Soc. Anat.*, 1866).

Treatment.—The treatment of *acute arthritis* of the temporo-maxillary joint is similar to that of acute arthritis of any other joint. Rest is the first consideration, but absolute rest is very difficult to obtain in the case of the lower jaw. The application of an elastic bandage, except when food is being taken, will be of some service.

Dr. Goodwillie, of New York, has, however, contrived an ingenious method of fixing the lower jaw effectually in cases of arthritis, which will be best described in his own words (*Archives of Medicine*, New York, June, 1881):

“The method that I employ is as follows: In this case the patient is under the anæsthetic effect of morphine and nitrous oxide. If there is any rigidity of the muscles, I cautiously force open the mouth and take an impression of either the upper or lower teeth, and a rubber splint is made from the cast to cover over all the teeth in one jaw. Upon the posterior part of this splint is made a prominence or fulcrum (*D*), so that when the mouth is closed the most posterior teeth close upon it, while all the anterior teeth are left free. The next step is to take a plaster of Paris impression of the chin, and from this make a splint (*A*). On each end of the splint is made a place for fastening elastic straps (*B*) that pass up on each side of the head to a close-fitting skull-cap (*C*). (Fig. 172.)


“When the apparatus is in place and the elastic straps tightened so as to lift the chin, then pressure is brought to bear on the fulcrum at the posterior molar tooth, and so by this means extension is made at the joints, and the inflamed surfaces within the joints are relieved from pressure; then immediate relief is experienced.”

In the non-suppurative cases, after the acute symptoms have subsided, counter-irritation by means of blisters or iodine, and gentle massage over the joint may be useful.

Especial care should be taken to prevent fibrous adhesions forming. This result is best avoided by passive movements of the joint.

In cases of suppurative arthritis it is important to give exit to the pus as soon as possible. If this is not done the pus may burrow widely into neighbouring structures, especially into the ear, causing otitis media. In some cases

FIG. 172.



the pus bursts into the auditory canal externally to the membrane, and discharges itself through the external meatus.

In cases of *chronic arthritis* rest is an important factor in the treatment, and should be combined with counter-irritation.

In *tubercular disease*, after rest has been tried without success, the joint should be opened and all the tubercular material removed—in fact, the operation of arthrectomy should be performed. If the condyle be found seriously diseased it should be removed and, if necessary, the glenoid fossa should be thoroughly scraped.

Sub-luxation of the Temporo-maxillary Joint.—This was the only disease of the joint recognised by the older surgical

authors, and the term 'sub-luxation' was applied to it by Sir Astley Cooper. It is an affection occurring principally in delicate women, and has been thought to depend upon relaxation of the ligaments of the joint permitting a too free movement of the bone, possibly a slipping of the inter-articular cartilage.

From a considerable acquaintance with this affection, I believe that it is, in many cases at least, unconnected with any slipping of the cartilage, but is due to rheumatic or gouty changes in the articulation. The fact that these patients suffer most in damp weather and when the general health is feeble, shows that it depends upon arthritic diathesis, and the relief that is obtained from counter-irritation and the exhibition of anti-rheumatic or anti-gouty remedies, proves that the complaint cannot be always due to purely mechanical causes. Professor Annandale, of Edinburgh, however, believes that, as in the case of the semilunar cartilages of the knee, the inter-articular cartilage of the temporo-maxillary joint may become displaced either by a sudden tearing of its connections or by a gradual stretching of them. In order to remedy the displacement, Mr. Annandale has devised and practised the following operation: An incision, slightly curved, about three-quarters of an inch in length, is made over the posterior margin of the external lateral ligament of the temporo-maxillary joint, and is carried down to its capsule. Any small bleeding vessels having been secured the capsule is divided, and the inter-articular cartilage is seized, drawn into position, and secured to the periosteum and other tissues at the outer margin of the articulation by a catgut suture. (*Lancet*, Feb. 26th, 1887.)

CHAPTER XXIV.

CLOSURE OF THE JAW.

By the term 'closure of the jaw' is meant a condition in which the lower jaw cannot be properly depressed. This inability to move the jaw may vary in degree. In some cases there is complete immobility; in other cases the jaw can be depressed to a varying amount. The causes of this fixation are numerous and differ widely in their nature. They may be conveniently classified in the following manner:

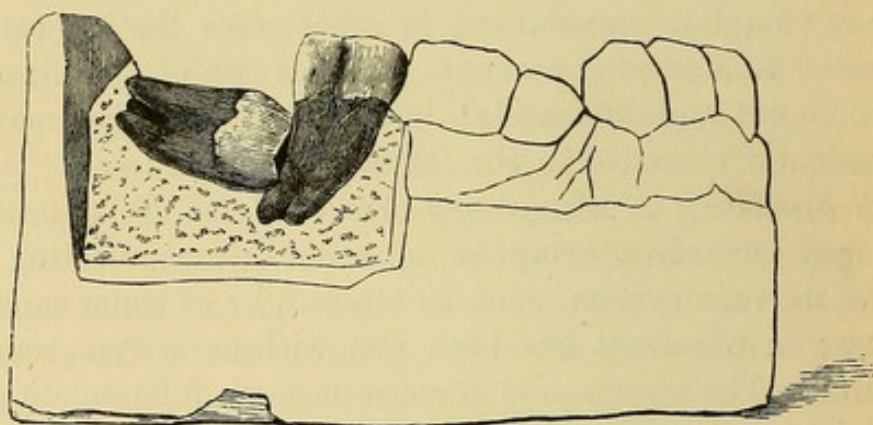
(a) *Spasmodic or Temporary Closure of the Lower Jaw.*—This may be only a symptom of some disease affecting the central nervous system, such as tetanus, or of some cerebral disease; in women it has been met with as a symptom of hysteria. The most common cause is some inflammation in the neighbourhood of the lower jaw, or in the lower jaw itself, thus, mumps and inflammation of the lymphatic glands of the neck are frequent causes. This condition may be caused by impeded eruption of the wisdom teeth of the lower jaw. Owing to want of room between the second molar and the ramus of the jaw, or owing to some malposition of the tooth itself, the wisdom tooth is unable to assume its normal position, and by the pressure which it exerts on the neighbouring structures, sets up irritation, which induces a state of tonic spasm of the masseter and internal pterygoid muscles. This fact has long been known to dental surgeons, and is especially alluded to by Mr. Salter in his essay on Surgical Diseases connected with the Teeth. ('System of Surgery,' vol. ii).

The accompanying engraving (Fig. 173), for which I am indebted to Mr. Felix Weiss, shows the condition of parts

found by him in a gentleman, aged forty-three, who suffered long and severely from pain and spasmodic closure of the jaws, due to the irritation caused by the wisdom tooth lying imbedded horizontally in the alveolus, and pressing against the fang of the second molar. It was only after the extraction of the second molar that the wisdom tooth was found and removed, with complete relief of the symptoms (*Trans. Odontological Society*, 1876).

In a discussion which took place at the Odontological Society, in May, 1861, and is reported in the *British Journal of Dental Science* of the same month, Mr. Tomes

FIG. 173.



mentioned a case of retarded eruption of the wisdom tooth with closure of the jaws, which had been allowed to go unrelieved for more than two years, and was immediately cured by the removal of the second molars, so as to allow the wisdom teeth to assume their proper position. Mr. Coleman, Mr. Mummery, and Mr. Ibbetson narrated, on the same occasion, very similar cases treated in the same manner; and Mr. Drew mentioned a case in which extraction of the half-cut wisdom tooth itself gave immediate relief.

The majority of these cases occur about the age of twenty, when the eruption of the wisdom tooth is to be expected, and the diagnosis is readily made. The treatment is obvious. The mouth must be opened by a screw gag, or by a spiral screw wedge of boxwood, under chloroform, and

either room must be made for the wisdom tooth by extracting the second molar, or, if it can be reached, the wisdom tooth itself may be removed.

The impeded eruption of wisdom teeth gives rise to various and apparently anomalous symptoms, which are often not traced to their true source, such as persistent neuralgia, not always referred to the part involved; but the most serious result is the formation of extensive abscesses, which burrow widely about the angle of the jaw and cheek, leading to great scarring and permanent deformity. In a young lady, seen by me in consultation some years back, the mischief resulting from an impacted wisdom tooth was sufficient to put her life in some jeopardy, and has left her face permanently scarred by extensive abscesses.

The pathology of these spasmodic cases is by no means clear. In some cases it appears to be purely a reflex spasm of the muscles, the afferent stimulus being caused by the inflammatory focus. In other cases, however, the inflammation seems to spread to the muscles, causing a myositis. As a rule this myositis subsides as soon as the inflammatory mischief ceases; in some cases, however, the myositis causes a permanent contraction of the muscles.

The treatment of this condition is obvious. The exciting cause must be determined and dealt with, and later efforts should be made to prevent any permanent changes in the muscles by systematic massage, &c.

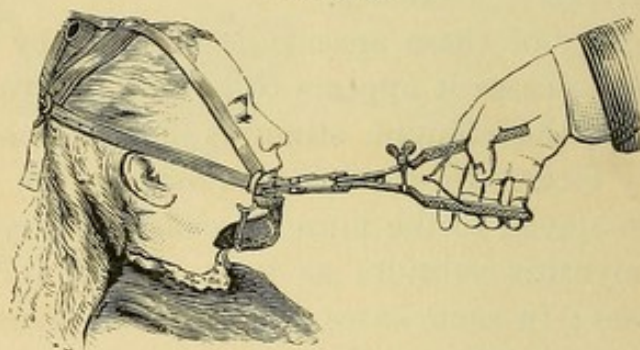
(b) *Permanent Closure of the Lower Jaw.*—The causes of this condition may be divided into two main groups; those caused by diseases of the temporo-maxillary joint, and those caused by cicatricial bands within the mouth.

1. *Ankylosis of the Joint.*—In the cases of fibrous ankylosis resulting from the cure of arthritis, it is open to the surgeon to have recourse to mechanical means to break down the adhesions; and to illustrate the difficulties to be overcome, I may refer to another case of Dr. Goodwillie's (*New York Medical Journal*, July, 1875): The patient was a girl of ten, who, five years before, had fallen over the bannisters, breaking and dislocating the jaw, with the result of the jaws

being firmly closed. The apparatus employed is seen in Fig. 174.

One of the chief sources of interruption in treatment is periodontitis from the great amount of force used on the teeth. To prevent this, Dr. Goodwillie protects them with an interdental splint of hard rubber. These splints at first are necessarily very small, and confined to the front teeth; but, as the case progresses, longer and more perfect ones are made. In this case the rubber splints were enclosed in metal splints made of German silver, as this metal is tough and unyielding. These splints were made fast to the teeth by straps that passed from strong wire arms at the sides to

FIG. 174.



a skull-cap, and the lower one was strapped to a pad on the chin. This pad was also attached to the lower splint by means of a ratchet and spring.

From the point of each splint an arm, three-fourths of an inch broad, extends out one and a quarter inch, and to these is clasped the oral speculum when in use (Fig. 174). The inclined planes of the speculum pass in between these arms, and they are held by clasps. The inclined planes are attached by movable joints to a distending forceps, so that when the handles are approximated, the inclined planes are separated at their attached ends. Each handle is made in two sections, and the spring that separates the handle is enclosed between them to protect them from injury.

In forcing the speculum between the splints, the instrument is grasped by one of the handles, and when in place both handles are approximated. If more force is desired

or the mouth is to be held open at any point, the screw at the handle may be used.

In stretching the masseter and temporal muscles, Dr. Goodwillie uses an oral speculum, devised by him some years ago (Fig. 175). It consists of a shaft, to the flat end of which are attached two wings or inclined planes, upon which the teeth rest. The other end of the shaft has a thread cut on it, and a screw; this passes through a handle, one end of which is wedge-shaped. By turning the screw on the other end of the handle, the inclined planes diverge or converge. Fig. 176 represents a spiral-spring speculum for the patients to employ by placing it between the teeth

FIG. 175.

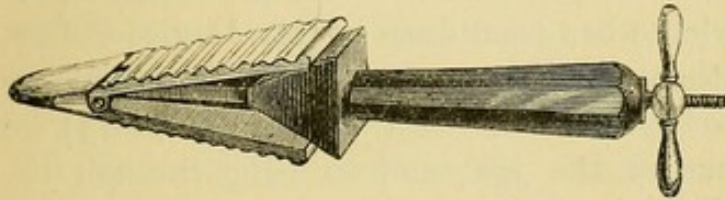
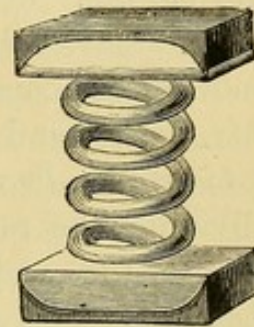


FIG. 176.



and biting upon it. Longer springs are used as the mouth gradually opens.

It need hardly be said that treatment by this method would extend over many months, and would severely try the endurance of both patient and surgeon.

A simpler method is the division of adhesions formed between the condyle and glenoid cavity, as practised by Mr. Spanton. Believing that the immobility was dependent on an ankylosis of the temporo-maxillary joints, with probable contraction of the ligaments surrounding them, and failing to make the slightest impression by means of a gag with any justifiable amount of force, Mr. Spanton passed a very narrow tenotomy knife into the temporo-maxillary joint on each side, immediately in front of the temporal artery, and then carried it freely round the condyle of the inferior maxilla as far as he deemed prudent, dividing completely the external lateral ligament of the joint, and partially the insertion of

the external pterygoid muscle, keeping the back of the knife towards the temporal, and carefully measuring the depth of the incision so as to avoid the middle meningeal artery. Very little hæmorrhage occurred; and as soon as this procedure was effected, Mr. Spanton found that the joints yielded at once to the gag, and that the mouth could be opened to the extent of more than an inch. For a day or two some soreness was complained of, but the gag was used almost daily, and seven weeks afterwards the patient left the infirmary able to open the mouth fairly well and to masticate her food. The result proved, however, disappointing, as re-contraction took place, and, in fact, one of the two patients operated on subsequently came under my own care for closure.

In cases of fibrous ankylosis there is the possibility of removing the condyle, as has been done by Mr. Davies-Colley, Mr. Barker and others; or, as proposed by Dr. Ewing Mears (*American Journal of Medical Science*, October, 1883), of dividing the ramus of the jaw, and excising, through the mouth, the condyle with the coronoid process and sigmoid notch.

Dr. Mears' operation is as follows: a straight sharp-pointed bistoury is introduced beneath the masseter muscle, on a level with the last molar tooth of the lower jaw. Into the wound thus made the blade of an Adams' saw is passed, and the ramus sawn through. The periosteum, with the overlying masseter muscle, is raised by the periosteal elevator, and the wound thus enlarged. The insertion of the temporal muscle is now divided by a probe-pointed bistoury. The tissues on the inner surface are separated by the elevator, the bone seized by the lion-jawed forceps, and an effort made to dislodge it by forcibly twisting it outwards. If it yields at the neck of the condyle, the process is afterwards chiselled out. If sufficient space is acquired without removal of the firmly ankylosed process, it is permitted to remain, the object being to provide ample space for the formation of an artificial joint. Section of the masseter muscle is made, if its tense condition demands it. Hæmorrhage, which arises from the

division of muscular arterial branches and possibly of the inferior dental artery, is controlled by pressure effected by packing the wound cavity with sponges. Wounding of the internal maxillary artery is to be avoided by careful use of the instrument in close contact with the bone in the upper and inner portions.

A case of the removal of both condyles for fibrous ankylosis is quoted by the *Wiener Med. Wochenschrift*, of July 6th, 1872, from the proceedings of the Royal Academy of Medicine in Bologna. It occurred in the practice of Dr. Bottini. The patient was a lad, aged seventeen, who, at the age of seven, had fallen on the jaw, and had gradually lost the power of opening his mouth, so that at last, for some months, he was unable to separate the jaws to any extent. Dr. Bottini introduced wedges, but these were very irksome to the patient and were removed. Resection of the articular head of the bone was then performed on one side; this had no noticeable result, but on the operation being repeated on the other side, the jaw could be moved freely. At the end of six weeks the wound had healed, and the motion of the jaw was normal. The only morbid change that could be discovered was the absence of the inter-articular fibro-cartilage.

In cases of rheumatoid arthritis in which the suffering is great, excision of the condyle seems to offer the best means of giving relief. The first removal of the condyle was by Professor Humphry, of Cambridge (*Med. Association Journal* 1856), and was undertaken for chronic rheumatic arthritis. He exposed the condyle by a curved incision from the side of the orbit across the zygoma to the ear, passing a little above the temporo-maxillary articulation, and a second incision from the termination of the first directly upwards in front of the ear across the zygoma again, avoiding the temporal artery. The flap thus made was reflected, and the neck of the condyle cut through with a narrow saw.

In cases of complete fixation also, resection of the condyle has been frequently adopted by various surgeons. In 1874 Dr. Gross, of Philadelphia, resected the condyle with a portion of the neck of the jaw in a girl, aged

seven, but does not mention the method he pursued. Mr. Croft resected the condyle on both sides consecutively in a child with good results; and Mr. Davy, of the Westminster Hospital, removed a condyle from two patients with the best results. Mr. Davy's first case was in a woman, aged fifty, who had complete closure of the jaws, and from whom the left condyle was removed in October, 1878. She made a rapid recovery, with perfect mastication, but died from the bursting of an aortic aneurysm on December 8th, and the remainder of the jaw was then obtained. Mr. Davy's second case was in a man, aged forty-seven, who perfectly recovered.

In 1883 I exposed the ankylosed joint in a boy, aged seven, by an incision in front of the ear, and with a chisel divided the neck of the bone, and removed half an inch of bone in the situation of the condyle, with very good results as regards movement, and with no obvious damage to the facial nerve. Mr. Barker also published a very successful case with illustrations in the *Lancet*, May 20th, 1893.

A case of complete synostosis of the jaw was successfully treated by a different method by Dr. James Little, of New York, in 1873. The patient was aged nineteen, and had some years before suffered from suppuration of the temporo-maxillary articulation, leading to ankylosis. Dr. Little made an incision along the lower border of the jaw, and turned up the masseter, when the neck of the condyle was seen to be very much enlarged, and continuous with the temporal bone. A half-inch trephine was then applied, and a button of bone three-eighths of an inch in thickness was removed. The portion of bone on each side of the opening was then cut through with a chisel, and the neck of the condyle cut away piece by piece, so as to leave no portion projecting from the temporal bone. The result was quite satisfactory.

A similar operation, but performed by a different method, was successfully undertaken by Dr. Robert Abbe, of New York, in a boy, aged ten, who had suffered from otitis media and suppuration of the joint some years before. A vertical

incision was made in front of the ear, and a horizontal one meeting its upper end was carried along the lower border of the zygoma. The parotid, with the facial nerve, was drawn down, and with a periosteal elevator the posterior fibres of the masseter were cleared away, and the articulation exposed. A narrow osteotomy chisel was now applied to the neck of the condyle, and carefully driven half through the bone, and by forcibly opening the mouth the bone was broken through. The neck of the condyle was then removed piecemeal, but the condyle was left *in situ*. The result was satisfactory.

Sédillot mentions that in a case of true ankylosis of the temporo-maxillary articulation, M. Grube, in 1863, carried a straight chisel through the mouth to the neck of the jaw, which broke by hammering. Some months later, he divided the masseter subcutaneously, and the cure, by the formation of a false joint, was permanent. In 1879 I performed the same operation in a child, aged six, but the results were unsatisfactory. Suppuration was set up, and required an external opening, and the movement, which was free at first, became as limited as before the operation, and I subsequently excised the condyle. It would appear, therefore, that mere division of the neck of the bone does not offer such good prospect of a permanent false joint as removal of the neck or the condyle, though these operations are necessarily more severe.

In 1836 I performed an operation which appeared to me to possess advantages over other proceedings undertaken for ankylosis of the temporo-maxillary articulation, and which consists in the division of the ramus of the lower jaw beneath the masseter by a saw introduced from the mouth. The patient was a young gentleman, aged sixteen, who came under my care with complete closure of the jaws due to ankylosis of the left temporo-maxillary articulation. He had scarlet fever in 1881, and the disease followed upon this. In 1882, and twice in 1883, attempts were made to screw the mouth open, with only partial and very temporary success; and when I saw him, the appli-

cation of a powerful screw-gag produced no effect. In December 1886 I made a small incision within the mouth immediately above the last molar tooth, and having passed a steel director to clear the way, I was able to push an Adams' saw beneath the masseter and to divide the ramus horizontally. No hæmorrhage occurred from the inferior dental artery, though the accompanying nerve was subsequently found to have been damaged.

The patient was able to open his mouth as soon as he recovered from the chloroform, and made a rapid recovery. Unfortunately, he caught cold on the railway journey home, and an abscess formed and pointed behind the jaw, but left only a dimple. The result, however, was not satisfactory, as re-contraction steadily took place, and nearly two years later I repeated the proceeding with more lasting benefit. In 1887 I adopted the same method in a young lady who, by dint of great perseverance in the use of a screw-gag, has maintained a good amount of movement; but in a youth of sixteen, in whom I also operated, the closure became so complete that I had recourse to Esmarch's operation, and removed a wedge of bone with good results.

In a few cases of bilateral ankylosis it has been thought advisable to perform Esmarch's operation on both sides of the jaw. Thus, Dr. Maas, of Breslau, relates in the *Archiv für Klin. Chirurg.* (Band xiii, Heft 3) the case of a man, aged twenty-seven, who was admitted into hospital with ankylosis of the jaw on both sides. It had come on after an attack of scarlet fever when he was seven years old, being preceded by severe pain in the part; and since the age of ten he had not been able to move the jaw at all. The secondary dentition was attended with great difficulty in the removal of the milk teeth; and the new teeth were irregularly developed, and for the most part were displaced laterally. The patient, on admission, was of anæmic appearance, though in moderately good condition; the lower jaw was imperfectly developed. Speech was somewhat muffled, but was quite intelligible. Not the least movement of the jaw could be

produced under anæsthesia. Herr Middeldorpf operated on the right side, removing a wedge-shaped piece of bone, as recommended by Esmarch, near the angle. The result of this was the formation of a false joint, with power of opening the mouth passively to the extent of about an inch. Between four and five months later, Dr. Fischer performed a similar operation on the left side; four months after this, the patient could voluntarily open his mouth without pain to the extent of about an inch.

Mr. W. H. Bennett brought before the Clinical Society in 1889 a very remarkable case of double ankylosis of the jaw, in which another surgeon had unsuccessfully removed both condyles with the chisel some years before. Mr. Bennett removed both angles of the jaw with the saw after Esmarch's method, a week intervening between the two operations, and the patient obtained complete power of opening his mouth, which has been permanent. Mr. Bennett remarks :

"The success of the treatment finally adopted seems to be due partly to the seat of the operation in each instance being as far removed as possible from the temporo-maxillary articulation, but more particularly to the fact that, by the excision of the angles of the jaw, it was easy to be sure that the masseter and internal pterygoid muscles were permanently separated from the central part of the bone, a matter of some importance, in my opinion; since it is obvious that if these muscles be left in any way attached to the lower part of the jaw, after its division, they will tend, no matter how large a piece of bone may be excised, to elevate the lower fragment and approximate the cut surfaces; so inclining, in spite of passive motion, to the direct production of osseous union in cases in which the tendency to bone formation is at all excessive, a circumstance which is, I believe, sufficient to account for the difficulties not infrequently met with in attempts to produce false joints in the lower jaw by operations limited to the portion of that bone situated above the angle." (*Clinical Society's Transactions*, vol. xxii.)

2. *Closure of the Jaw from Cicatrices.*—The majority of cases of permanent closure of the jaw are caused by cicatrices situated within the mouth. The constricting band may be limited to the mucous membrane or may be attached to the bone, forming a firm bond of union between the two jaws. These scars are generally caused by extensive ulcerative or gangrenous conditions of the mouth. According to Dr. Gross, of Philadelphia, the most common cause is profuse ptyalism, followed by gangrene of the cheeks, lips, and jaw, and the formation of firm, dense, unyielding, inextensible tissue, by which the lower jaw is closely and tightly pressed against the upper. Such an occurrence used to be extremely frequent in the south-western States during the prevalence of the calomel practice, as it was termed, but is now, fortunately, rapidly diminishing.

In children, especially of the poorer classes, ulcerative stomatitis and cancrum oris, which may arise during the course of measles or scarlet fever, are the most frequent causes.

In rare cases the cicatrix may be the result of a compound fracture, or a lacerated wound, or may follow some surgical operation on the face or jaws.

The *treatment* of this condition is often very unsatisfactory. Attempts should be made to stretch the cicatricial bands by mechanical means such as have been described in the treatment of fibrous ankylosis of the temporo-maxillary joint (see p. 392).

Division of the cicatricial bands, either by subcutaneous tenotomy or by the open method, is sometimes followed by success; but, in order that the improvement may be permanent, mechanical dilatation should be employed as well.

The treatment of cicatricial contraction within the mouth, by simple division, has been proved over and over again to be worse than useless. The difficulties experienced in these cases, and the failures which so often accompany the methods employed, induced Dr. Ewing Mears, of Philadelphia, to make an effort to effect division of the dense tissue by

means of a ligature, believing that reunion could thus be partially, if not completely, prevented.

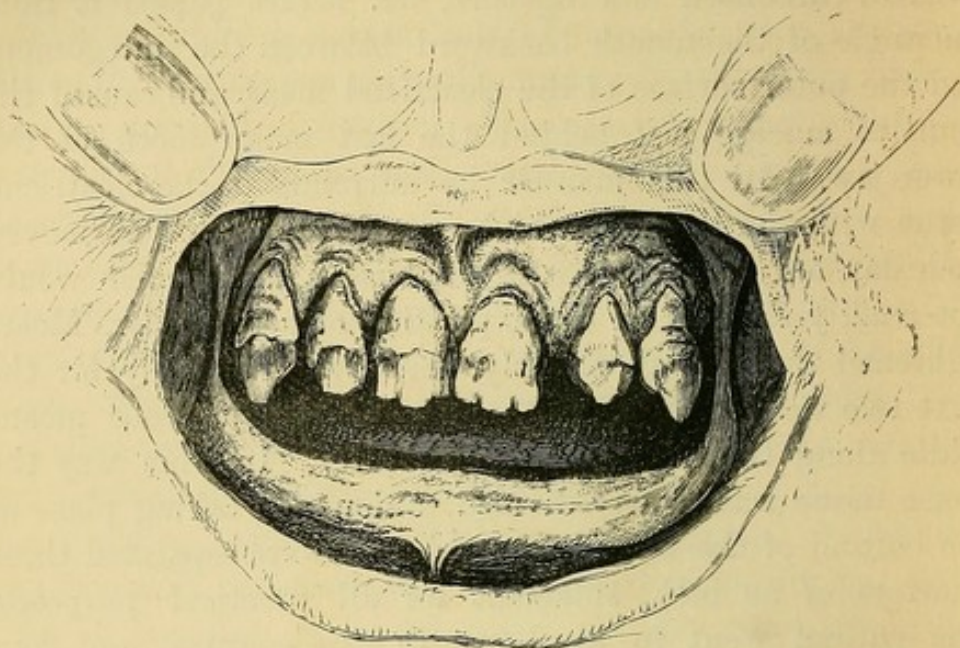
Having armed a strong-handled needle with a double-twisted, carbolised silk ligature, Dr. Mears passed it from the angle of the mouth backward between the integument and the outer surface of the cicatricial mass, and caused the point to emerge just behind the last molar tooth of the lower jaw. In this manner he surrounded the cicatricial tissue with the ligature, which was tied loosely and moved each day for a week, so as to establish a canal which would not readily close. At the expiration of a week, Dr. Mears tightened the ligature slightly, and every third day for the next two weeks made slight torsion, passing a probe meanwhile along the tract of the ligature. In this way the dense tissue was slowly divided, union not taking place at the bottom of the wound, and the jaws were separated three quarters of an inch, sufficient for all practical purposes. The patient went to his home in the country, and four months later returned well.

When suitable apparatus is adapted to the jaws, so as to prevent re-contraction, a very good result may, with patience, be produced in cases uncomplicated by destruction of the cheek itself. Fig. 177 shows a sketch of the mouth of a woman who had cicatricial bands on each side, binding the cheeks and gums together so that she was able only to separate the lips, and in whom division of the cicatrices had been practised in childhood. The lower jaw was edentulous, but the upper front teeth remained, and Mr. Felix Weiss succeeded in adapting a small lower denture so as to antagonise the upper teeth and prevent the further contraction which appeared imminent, at the same time greatly improving the patient's power of articulation (*British Dental Journal*, May, 1880).

The great drawback to treatment by division of bands, and one with regard to which it contrasts unfavourably with Esmarch's proceeding, is the amount of pain which the patient must of necessity undergo during the after-treatment. It requires no small amount of courage on the

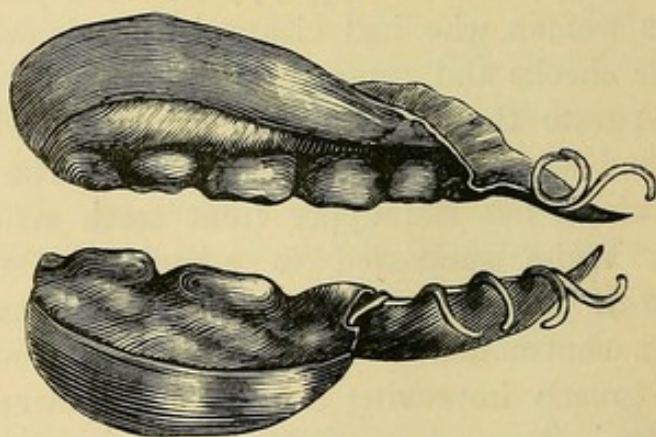
part of the patient, and some determination on the part of the attendant to carry out the necessary manipulations

FIG. 177.



within the mouth, more particularly during the first few days after the operation; and even after the shields are fitted to the mouth, they cause some pain and incon-

FIG. 178.

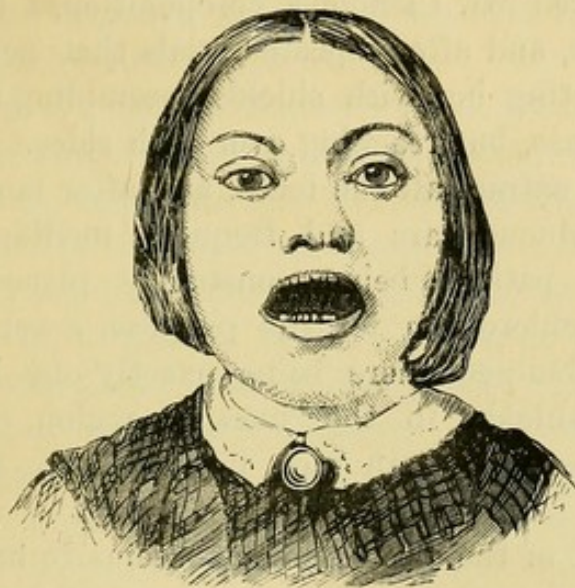


venience, to which only those who have arrived at years of discretion will submit.

Fig. 178 shows the form of the silver 'shields' adapted to the upper and lower jaws by the late Mr. Clendon, formerly dental surgeon to the Westminster

Hospital, in a case of Mr. Barnard Holt's. The patient was a girl, aged seventeen, and was under Mr. Holt's care in 1862, having five years before had fever, with an abscess of the cheek on the right side, which led to such contraction and adhesion of the mucous membrane to the jaw, as to cause great difficulty in opening the mouth. Some attempts had been made to open her mouth by the screw, &c., and in 1860 Mr. Holt divided some of the cicatrix with temporary benefit. Mr. Holt now divided the cicatrix within the cheek freely under chloroform, and

FIG. 179.



encountered a firm plate of bone extending between the alveoli of the two jaws, which necessitated the use of a saw for its division. Mr. Clendon subsequently fitted the above-mentioned shields to the teeth, and wedges were gradually introduced between them to separate the jaws. This treatment was continued for three months, when she was able to open the mouth to the full extent, as seen in Fig. 179.

At the Odontological Society, in June, 1864, Mr. Cartwright narrated a very similar case of contraction (with the exception that there was no bony bridge between the alveoli) in a woman, aged thirty-eight, whom he successfully treated by similar means, using wedges of vulcanised

india-rubber affixed to the shields to obtain the necessary extension.

Subsequently to Mr. Holt's case, I had under my care a patient with a very severe form of contraction, namely, on both sides of the mouth. The patient was aged eighteen, and the contraction dated from her fifth year, when she had fever. Various attempts had been made to give her relief by dividing the cicatrices and using wedges, &c., without benefit; and when she came under my care she had no power of separating the jaws at all, and the cheeks were firmly attached to the alveoli from the angles of the mouth. Having secured Mr. Clendon's co-operation, I freely divided the cicatrices, and after repeated trials that gentleman succeeded in fitting her with shields resembling those used in Mr. Holt's case, but reaching over both sides. It was found necessary to extract all the teeth, and after more than three months' assiduous care and frequent modification of the shields, the patient being constantly placed under the influence of chloroform for the purpose, a very satisfactory result was obtained, there being exactly one inch between the metal shields in the incisive region, which would have left about half an inch if the teeth had been *in situ*.

The effect of the use of shields seems to have been not merely to prevent adhesions between the inside of the cheek and the alveolus, but to re-establish, to a great extent, the sulcus of mucous membrane at the base of the alveolus, upon which so much stress is laid by Professor Esmarch. The cause of non-success in former attempts at mechanical appliances is to be found, I think, in the fact that they have all been directed simply to keeping the jaws apart, without any reference to the re-establishment of the mucous lining of the cheek, upon which the movements of the jaw so much depend.

In cases where the closure is caused by contraction of the masseter muscle, the operation of myotomy, first described by Dieulafois in 1838, may be successful. Le Dentu suggests that, instead of dividing the masseter,

the insertion of that muscle should be re-implanted (*Société de Chirurgie*, 1891).

When the temporal muscle is affected, the operation of myotomy is not recommended because of the severe hæmorrhage that may ensue. In such cases division of the coronoid process is a more satisfactory proceeding.

In cases where the skin of the face is much affected, certain plastic operations may be necessary. The details of the operation would vary so much in different cases that no definite lines could be laid down.

In the majority of cases more radical treatment has to be adopted, and Esmarch was one of the first to describe an operation for the relief of this condition.

The proposal of Professor Esmarch was to form a false joint in front of the cicatrix, and it was suggested to him by a case which came under his care in 1854, in which considerable destruction of the cheek and contraction of the cicatrix had occurred, together with immobility of the lower jaw and necrosis of a portion of it. The bone having been removed, it was found that mobility was restored, and a useful amount of movement obtained. Professor Esmarch therefore suggested, at the Congress of Göttingen, in 1855, the removal of a piece of bone in cases of contracted cicatrix; but did not happen to meet with a case suitable for the operation until after it had been successfully performed by Dr. Wilms, of Berlin, in 1858, soon after which he himself operated upon a case at Kiel, and with the best results. The operation was subsequently performed by Dittel of Vienna, and by Wagner of Königsberg.

Shortly after this proposal of Esmarch, it would appear that Professor Rizzoli, of Bologna, quite independently conceived a somewhat similar idea, but modified the proceeding by merely cutting through the jaw, without removing any portion of bone. He operated in this way first in 1857, and subsequently had three other successful cases. In Rizzoli's cases no external incision appears to have been made, but the section was accomplished from the mouth with powerful forceps. This proceeding has been followed

by Professor Esterle, from whose essay in the *Annali Universali di Medicina* I have extracted these particulars.

Esmarch's operation appears to me to possess a decided advantage over that of Rizzoli, in the fact that a piece of bone is removed, by which the formation of a false joint is facilitated, as we know by experience in cases of resection of the elbow, &c.; and the external incision can never be a matter of any importance, whilst it admits of the application of the saw, and so avoids risk of splintering the bone.

Mr. Mitchell Henry was, I believe, the first surgeon to put Esmarch's operation into practice in this country, he having performed it a few weeks before myself. The patient was a female, on whom a variety of operations had been performed (among others, division of the masseter), and whom I had had under my own care at the St. George's and St. James's Dispensary, two years before, when I divided the cicatrices freely, and screwed the mouth open, but without permanent benefit. Mr. Henry employed the chain saw, and removed about half an inch of bone. The patient, unfortunately, sank a few days afterwards, apparently from pyæmia and exhaustion. In my own cases I used an ordinary narrow saw, in preference to the chain, and was enabled to remove sufficient bone to give free movement, through a small incision along the edge of the jaw.

The subject of the contraction of cicatrices in the mouth and their treatment, though it has attracted little notice among British authors, has, on the contrary, excited much attention in Paris, and has furnished the topic of frequent discussions at the Société de Chirurgie. Since the date of the publication of a paper upon the subject by M. Verneuil (*Archives Générales*, 1860), several operations have been performed by French surgeons, but apparently with but little success, since in cases operated on both by the method of Esmarch and of Rizzoli reunion of the divided jaw has taken place.

Thus, on February 4th, 1863, M. Boinet brought before the Society a little girl on whom he had previously per-

formed what he terms Esmarch's operation (but which appears to have consisted in the simple division of the jaw, recommended by Rizzoli, and not the removal of a wedge of bone, as originally proposed by Esmarch), and in whom the bone had reunited. M. Deguise thereupon quoted a case in which he had removed a centimètre and a half of bone with the same unsatisfactory result, and expressed a doubt whether a single successful case could be produced. On February 11th, 1863, M. Deguise brought the case he had alluded to before the Society, and showed that the failure "depended upon the formation of an osseous callus at the level of the resected portion." At the same meeting M. Bauchet showed a young Syrian girl in whom contraction of the left side had taken place, together with a loss of substance of the cheek and commissure of the lips, equalling a five-franc piece in size. In this case a centimètre and a half of the jaw was removed; and though extensive suppuration and necrosis of the jaw ensued, the girl made a good recovery, and at that date a very satisfactory amount of movement and power of mastication had been obtained.

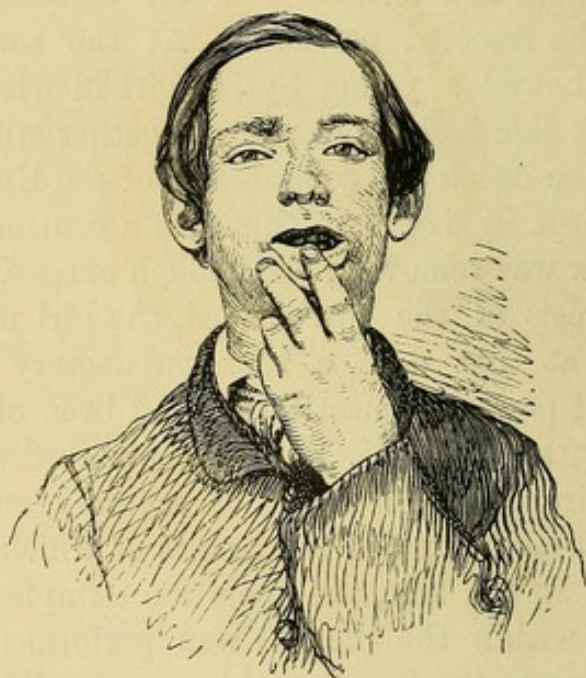On July 29th, 1864, M. Verneuil communicated to the Société de Chirurgie the histories of several cases operated upon by M. Rizzoli himself, the results of which were most satisfactory. In the first, the operation (simple division of the jaw from within the mouth) was performed in 1857, and after six years the boy was able to eat solid food most satisfactorily; the second case, operated upon in the same year, was equally good. In the third case, operated upon in 1858, the mouth could not be widely opened, and the child had some difficulty in speaking. The fourth case operated upon in 1860, was most satisfactory. M. Verneuil also mentioned a fatal case which occurred in M. Rizzoli's practice, and alluded to my paper in the *Dublin Quarterly Journal* of May, 1863.

It would appear that M. Rizzoli had adopted the plan of inserting a foreign body, such as a piece of gutta-percha, between the cut surfaces of bone, with the view of preventing their reunion, and the possibility of doing this was roundly

denied by one of the speakers at the Société de Chirurgie. There appears to me, however, to be no difficulty in effecting this, provided the section be made from within the mouth and without external incision, as proposed by M. Rizzoli, but I cannot speak with certainty, having no experience of his operation.

One observation of M. Verneuil's is, I think, worthy of notice—namely, that all Rizzoli's successful cases have been examples of contraction within the mouth without loss of

FIG. 180.



substance of the cheek, whereas the unsuccessful cases of the operation which had occurred in Paris had suffered considerable damage in the soft tissues; and he suggests that in these cases Esmarch's operation may be more properly applicable. In one of my cases the loss of substance in the cheek had been replaced by a dense cicatrix, which it would have been unwise to interfere with from within the mouth, and at the same time, owing to its firm contraction, it would have been impossible to have performed Rizzoli's operation in the way he recommends—namely, without any external incision. I therefore resorted to Esmarch's proceeding, with the results of which I have every reason to be satisfied.

The first case in which I performed Esmarch's operation was that of a boy, aged fifteen, who was sent to me by Mr. Martin, of Portsmouth, in 1862, with complete closure of the jaws, the result of the contraction of cicatrices within the mouth following extensive necrosis. The cicatrices had been divided, and his mouth screwed open in 1856, but without permanent benefit, and he obtained his food by rubbing it between his teeth, or by putting it through an aperture between the teeth

FIG. 181.

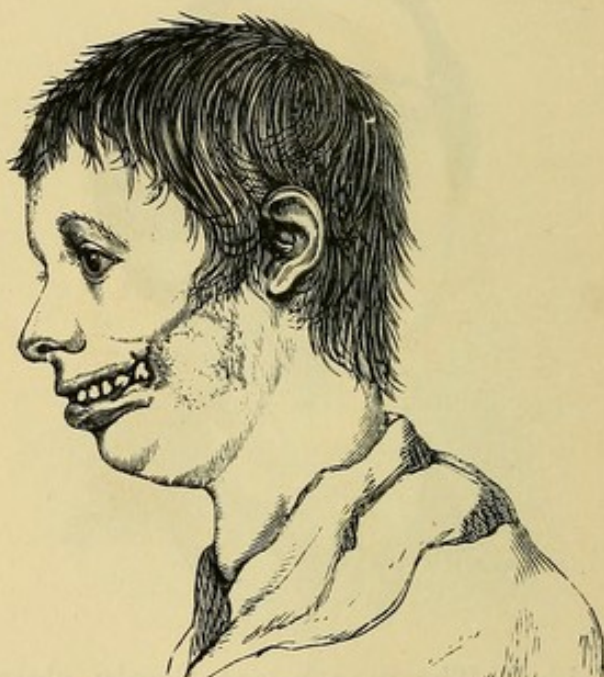

on the right side. The mouth was firmly closed, the teeth overlapping; there was a cicatrix at the right angle of the mouth, and a dense band could be felt within the mouth on the same side. Fig. 180 shows his condition on admission. I made an incision two inches long upon the lower border of the jaw, in front of the right masseter, and removed a wedge of bone measuring rather more than a quarter of an inch along the upper, and half an inch along the lower border. The piece contained the mental foramen. The mouth could now be freely opened, and the boy was discharged at the end of a month, able to open his mouth, as seen in Fig. 181; the distance between the teeth being seven-eighths of an inch.

The second case in which I operated in the same manner

was complicated by the presence of a dense cicatrix, occupying nearly the whole of the cheek of the affected side. The angle of the mouth had also given way during a recent attack of fever, and the patient presented the unsightly appearance shown in Fig. 182. The patient was aged twenty-three, and the sloughing and contraction occurred at the age of six. She was sent to me by Mr. Bullen, of the Lambeth Infirmary, in January, 1864. I made an incision along the border of the jaw, and, as in the former case, removed a wedge of bone

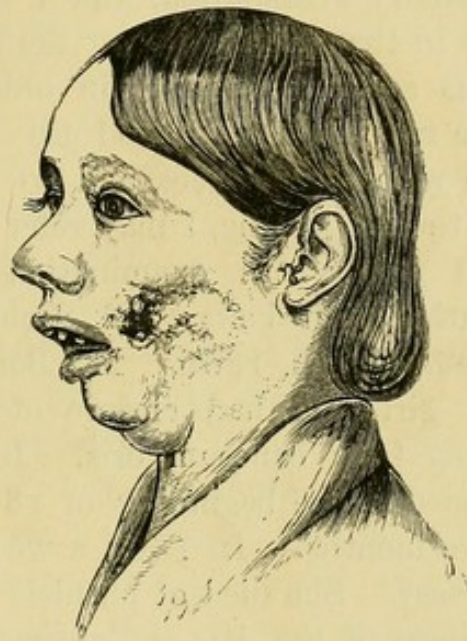FIG. 182.



measuring seven-eighths of an inch along its lower border. This also contained the mental foramen. The patient's mouth could now be opened to the extent of half an inch. I made two subsequent attempts to remove the deformity of the cheek by plastic operations, but only succeeded in restoring the commissure of the lips, the vitality of the cicatricial tissue being too low to admit of its uniting with other tissues. At the time of her discharge the commissure of the lip was half an inch in breadth; and with a piece of plaster over the opening which was left behind it, the patient was very comfortable. Fig. 183 shows her condition at this time with the mouth open.

With regard to the permanence of the relief afforded in these cases, I may mention that B. B., the boy on whom I operated in July, 1862, continues in perfect health, and is able to take plenty of nourishment, although the movements of the jaw have very decidedly diminished, owing, apparently, to contraction of the fibrous tissues around the new joint, due, as the patient and his mother believe, in the first instance, to the cold of the severe winter following the operation, from which he suffered considerably.

FIG. 183.



In March, 1865, I had the boy up from the country, and found that the space between the left molar teeth had diminished from seven-eighths to one-eighth of an inch, and that between the left lateral incisors, from five-eighths to a quarter of an inch. The movement was still free enough to show that osseous ankylosis had not taken place in the new joint; but whether the contraction was due simply to changes at that point or to the contraction of some band it was impossible to determine, as the boy positively refused all interference, either with or without chloroform. In this case, however, I believe that I was not sufficiently careful to make the section of the bone entirely in front of the cicatrices, a point I bore in mind in the second operation. He was alive in 1893.

The second patient, E. J., is in perfect health, and has good use of her jaw. I saw her in December, 1893, in good health, and with perfect movement of the joint. The opening in the cheek remained the same.

In 1883, I again performed the operation in University College Hospital, on a woman, aged thirty-two, who was kicked by a horse on the right side of the face, when eleven years of age, since which she had had more or less closure of the jaws. The teeth were firmly closed, the lower incisors being forced outwards. It was clearly a case of ankylosis of the temporo-maxillary articulation, and I should have preferred to operate in that region but for the patient's anxiety to be relieved as soon as possible, in order to return to her family. She recovered, with good use of the jaw.

In connection with this subject, and to show the pathological result of the proceeding, I may refer to the following account of the *post-mortem* examination of a case of Esmarch's operation, read before the Société Impériale de Chirurgie, September 5th, 1866. M. Boinet showed the lower jaw of a girl who had closure of the jaws, from cicatrices resulting from cancerum oris. Rizzoli's operation had been performed at the beginning of 1860, but failed at the end of twelve months. In 1863 a wedge was removed with perfect success. She died of phthisis in 1866.

"The right ramus of the jaw is deformed, being shorter and broader than on the opposite side. The condyle and the coronoid process are less separated and shorter than on the left side, and the sigmoid notch is shallower. The left temporo-maxillary articulation has lost much of its mobility, and the ligaments are shortened. The sections had been made in the middle of the body of the bone, the angle being intact. The lower border of the jaw presents a difference in length of one centimètre and a half between the two sides, which corresponds to the breadth of the wedge of bone removed at the operation. The osseous tissue of the ascending ramus appeared reddened; the dental nerve was natural at its entry into the inferior dental foramen. Between the two portions of the jaw there exists a very

complete false joint, which is permanent three years after the operation; it is very mobile, and the parts which serve as the hinge are fibrous and stretched so that the middle portion of the jaw can fall; during life this was sufficient to allow easily the introduction of the forefinger into the mouth. The fibrous tissue which unites the bones occupies the whole interval between the bones, and extends for the whole depth of the jaw. Its breadth appears to be quite half a centimètre, and its strength uniform."—*Gazette Hebdomadaire*, October 12th, 1866.

The occurrence of an osseous lamella or bridge between the two jaws is a rare but not unique occurrence. In the *Medical Gazette* of July 4th, 1845, Mr. J. G. French has reported and figured an excellent example of ankylosis produced by a bridge of bone, which occurred under his care at the St. James's Infirmary.

The patient was aged twenty two at the time of his death, and the closure of the jaws dated from infancy. He was fed through an aperture made by the removal of the incisors on the left side. At the age of fourteen, an operation for his benefit had been undertaken by an eminent surgeon, and incisions in the mouth had been made with this object, but without any good result. On *post-mortem* examination, the jaws were perfectly united on the left side, and only the smallest degree of motion was possible on the right; the soft parts were removed and the base of the skull was macerated, when ankylosis was discovered to exist between the upper and lower jaws on the left side, the ramus of the inferior maxilla, immediately internal to the mental foramen, extending upwards by a broad thin plate, and uniting with a corresponding plate of the superior maxilla, a cartilaginous material forming the bond of union. The articulation of the jaw was normal.

Mr. Trueman also mentioned in the discussion which followed the narration of Mr. Cartwright's case (*British Journal of Dental Science*, June, 1864) that he remembered seeing in the Museum at Berlin a very curious case where cicatrices existed on both sides of the mouth, which were

completely ossified, so that the preparation showed the two jaws united by filaments of bone, on either side of the jaw externally.

Having thus shown that closure of the jaws depends upon various causes, and is amenable to various methods of treatment, of which I have had personal experience, I think I may venture to contrast these methods.

In cases of cicatrix, I give the preference to Esmarch's method of removing a wedge from the lower jaw on one or both sides. The operation is a comparatively easy one, and in cases where only one side of the jaw is affected, restores the patient a very useful though one-sided amount of masticatory power in two or three weeks, and with very little suffering or annoyance.

In cases of fibrous ankylosis of the temporo-maxillary joint it may be worth while to try division of the adhesions, and failing that to resect the condyle.

In cases of bony ankylosis of the joint, division of the ramus of the jaw beneath the masseter though satisfactory at first has disappointed me in its permanent results, and I have no experience of Dr. Mears' very severe operation of removing the bone through the mouth. Chiselling out the bone representing the condyle is a difficult and somewhat dangerous proceeding as regards the facial nerve, and I should prefer to remove one or both angles of the jaw by Esmarch's method.

CHAPTER XXV.

DEFORMITIES OF THE JAWS.

THE scope of this work does not embrace those congenital deformities of the gum and palate which are familiar to the surgeon in combination with hare-lip, but there are certain examples of deformity, the result of disease, which may be conveniently grouped together here.

In describing the tumours of the jaw, mention has been made and drawings given of cases of deformity the result of pressure upon the opposite jaw of some growth of large size; thus, at page 321 will be found an instance of deformity of the upper jaw, due to the pressure of a large fibrous tumour of the lower jaw; and at page 273 an example of deformity of the lower jaw, due to the pressure of a large osseous tumour of the superior maxilla. Tumours within the mouth, unconnected with the jaws, may, however, induce deformity mechanically, hypertrophy of the tongue being the disease most frequently met with, of which several instances will be found in vol. xxxvi of the *Medico-Chirurgical Transactions*, in papers upon that disease, by Dr. Humphry, of Cambridge, and Mr. Joseph Hodgson. Dr. Humphry's patient was a girl of eleven years, who had had a much hypertrophied and prolapsed tongue for eight years. "Owing to the constant pressure of the tongue on the mental portion of the lower jaw a curvature had taken place in that bone, just in front of the masseter muscles, in such a manner that a wide interval always existed between the incisors and bicuspid of the two jaws. Even when the mouth was closed—that is to say, when the corresponding molar teeth were in contact—

this interval between the incisors measured nearly two inches, being increased by the horizontal direction which the inferior incisors and the alveolar process of the lower jaw had assumed. These were so placed as to form a wide channel in which the tongue rested. Moreover, the teeth, especially the two central incisors, were further apart than natural, and encrusted with tartar, which in some measure filled up the spaces between them, and prevented their sharp edges from injuriously pressing upon the tongue." The deformity, therefore, closely resembled that seen in Fig. 184, which was due, however, to external causes. Dr. Humphry removed the anterior part of the tongue successfully, and then endeavoured to remedy the deformity of the jaw by fitting a cap of calico and metal to the head, with a hooked bar of iron projecting from it like a horn over the forehead. The bar was attached to the hinder part of the framework of the cap by a hinge, and to the forepart by a screw, which enabled the surgeon to alter its elevation according to circumstances. A thick belt of india-rubber passed from the hook beneath the chin, and exerted considerable pressure upon it. The apparatus was worn for several hours at a time. When its use was commenced on January 18th, four months after the operation on the tongue, the interval between the maxillary alveoli was $1\frac{5}{8}$ inch, having decreased about a quarter of an inch. On February 22nd it was $1\frac{1}{4}$ inch, and in August $\frac{7}{8}$ of an inch. After this the change took place very slowly, though the deformity was at length almost removed.

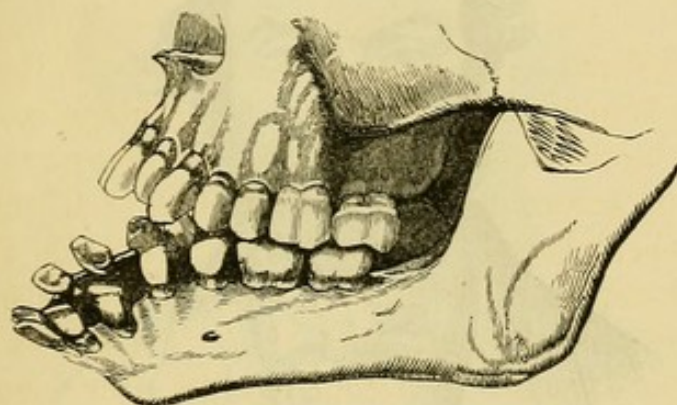
A very similar condition of the lower jaw, but in an earlier stage, existed in a child, aged three, from whom Sir J. Paget successfully removed the hypertrophied portion of the tongue, in February, 1864. (*Lancet*, April 16th, 1864.)

Mr. Oliver Chalk has also narrated, in the *Pathological Society's Transactions*, vol. viii, a case of deformity of the jaw dependent upon enlargement of the tongue in which he considered that a partial dislocation of the jaw was produced, and where benefit was derived from the use of an elastic support.

The influence of the habit of sucking the thumb upon the position of the front teeth is generally acknowledged, and the practice, if persisted in, may produce very considerable deformity of the jaws. Some drawings illustrating a paper on this subject, by Mr. Vasey, in the *Pathological Society's Transactions*, vol. vi, show the resulting deformity extremely well. Dr. Thomas Ballard has also called attention to the deformity resulting from the habit of 'tongue-sucking,' to which he attributes many of the ailments of children.

The influence of cicatrices outside the mouth in producing deformity of the jaw by their contraction in early life is

FIG. 184.




well ascertained, and every surgeon must have met with painful examples of the kind. Fig. 184, from Mr. Tomes' work, shows the condition of the lower jaw in a young woman twenty-two years of age, her chin having been drawn down towards the sternum by a broad cicatrix, consequent upon a burn received when five years old.

In all these cases the deformity partakes of the same character, and if seen early enough is to some extent amenable to treatment. The slighter cases depending upon thumb-sucking are usually treated by the dental surgeon, who in rectifying the position of the teeth necessarily improves the condition of the jaw. In the more severe cases, constant support by an elastic band making traction upon the jaw will be of much service, as in the cases of Dr. Humphry and Mr. Chalk. The cases depending upon the

contraction of cicatrices can only be relieved by treating the cicatrices, and the pressure of a screw-collar, worn for the purpose of extending these, will do much to restore the shape of the jaw, if the case is not one of too long standing.

Disease originating within the mouth may lead to ultimate deformity of the jaws; thus, *cancerum oris*, in addition to leading to closure of the jaws, as described in a previous chapter, may lead to very considerable deformity of

FIG. 185.



the alveoli. Mr. Bernard, of Clifton, successfully treated, by Esmarch's operation, a case of closure with deformity thus caused; but a still more remarkable case was under the care of my friend, the late Mr. W. Harrison, to whom I am indebted for the accompanying engravings of it. The patient, aged thirty-six, had suffered in childhood from *cancerum oris*, which had destroyed the greater part of the right cheek. His appearance is shown in Fig. 185, and it will be seen that the lips were widely separated, and that a considerable protrusion of the alveolar processes of both jaws, with their teeth, had taken place between them. Behind this point the jaws were united

by a bridge of bone, and the patient, who was totally unable to open his mouth, fed himself through an aperture between the teeth on the left side. In October, 1867, Mr. Harrison extracted the seven teeth which projected, and reflected the gums from the adjacent alveoli, when as much of them as was thought desirable was removed with the bone-forceps. The molar teeth, which had been driven into the interior of the mouth, were then extracted with some difficulty,

FIG. 186.



when a pillar of bone, about the size of an ordinary lead-pencil, connecting the alveoli, was brought into view, but was not interfered with. The gums were brought together with stitches, and the operation was concluded. The appearance of the patient some weeks afterwards is shown in Fig. 186.

The patient having been transferred to the care of Mr. James Lane, that gentleman proceeded to perform a plastic operation for the improvement of the condition of the lips. A very long V-shaped incision was made, extending from the extremities of the lips (which were firmly attached to the alveoli) to a point about an inch in front of the ear, thus embracing within it the cicatrix of the original disease,

The tissues were freely dissected from the upper and lower jaws, and were brought together over the old cicatrix. An incision, two inches long, was made along the lower border of the jaw, to enable this to be done without too great tension, and the parts were held together with hare-lip

FIG. 187.



pins and sutures. The operation was perfectly successful, and the subsequent appearance of the patient is shown in Fig. 187.

The interesting details of this case will be found in a paper read by Mr. Harrison, before the Odontological Society, in May, 1868 (*British Journal of Dental Science*, May, 1868).

INDEX.

	PAGE
ABSCCESS, alveolar	92
" after fracture	14
" in substance of jaw	98
" of antrum	145
Actinomycosis of the jaws	370
Adams, Mr. W., on cysts of antrum	160
" Dr. R., on cysts of lower jaw	197
Adenoma of palate	251
Alveolar abscess	92
Alveolus, fracture of	11, 43
" diffused periostitis of	89
" localised chronic periostitis of	99
Amaurosis from diseased antrum	149
Angle, Dr., treatment of fractured jaw	35
Angioma of palate	250
Ankylosis of temporo-maxillary joint	395
Antrum, diseases of	141
" suppuration in	145
" dropsy of	157
" cysts of	159
" polypus of	162
" falling in of	165
" epithelioma of	166
Articulation, temporo-maxillary, diseases of	375
Author's case of fractured alveolus	11
" " necrosis of lower jaw	105, 119
" " hyperostosis of jaw	136
" " dentigerous cyst	189
" " cystic sarcoma of lower jaw	200, 206
" " multilocular cystic tumour	202, 203
" " odontoma	218
" " hypertrophy of gums	228
" " epulis	238, 239
" " tumour of palate	252, 253
" " epithelioma of antrum	167, 302
" " " gums	246
" " fibroma of upper jaw	264
" " enchondroma of upper jaw	266
" " osteoma	272
" " round-cell sarcoma of upper jaw	296
" " epithelioma	299, 301
" " recurrent sarcoma	314
" " ivory exostosis of lower jaw	327

	PAGE
Author's case of myeloid of both sides of lower jaw	332
" " round-celled sarcoma " " 	334
" " chondro-sarcoma " " 	342
" " ossifying sarcoma " " 	346
" " epithelioma of lower jaw	351, 354
" " " of chin	356
" " " of gland adherent to jaw	358
" " Esmarch's operation for closure	405
" " closure of jaws treated with shields	402
" " disease of temporo-maxillary joint	377
" " hypertrophy of neck of condyle	382
 BEAN'S interdental splint	 38
Beaumont, Mr., enchondroma of lower jaw	322
Boinet, M., post-mortem examination after Esmarch's operation	412
Broca, M., on fibrous odontomata	264
Bryant, Mr., necrosis of inter-maxillary bones	113
Butcher, Mr., on cysts of lower jaw	207
" " vascular tumour of upper jaw	288
 CARCINOMA of palate	 254
" of upper jaw	299
" of lower jaw	350
Cannon-ball, injury to jaws by	64
Canton, Mr., myeloid tumour of upper jaw	282
Cap for fractured jaw	37
Cartilaginous tumours of upper jaw	265
" " lower jaw	323
Cattlin, Mr., on the antrum	141
Chalk, Mr. O., deformity of jaw	416
" " reproduction of teeth	123
Chin, silver	63
Chondro-sarcoma of upper jaw	292
" " lower jaw	342
Closure of the jaw	389
Coates, Mr., myeloid tumour of upper jaw	286
Collis, Mr., enchondroma of upper jaw	271
Complications of fractured jaw	9
Condyle, fractured neck of	6, 13
Couper, Mr., case of old dislocation	80
Craven, Mr., medullary sarcoma of upper jaw	295
" " myeloid sarcoma of lower jaw	331
Cystic sarcoma	200
Cysts of antrum	159
" of teeth	174
" dentigerous	180
" multilocular, of lower jaw	192
 DEBOUT on gunshot injuries	 61
Deformities of the jaws	415
Dental cysts	174
Dentigerous cysts	180
Dentinal tumours (<i>see</i> Odontomata)	
Diabetic alveolar periostitis	90
Diagnosis of tumours of upper jaw	303
" " lower jaw	360

	PAGE
Dislocation of teeth	10
" with fracture	16
" of lower jaw	72
" pathology of	73
" symptoms of	77
" old-standing	80
" rare forms	82
" congenital	83
" treatment of	84
Dropsy of antrum	157
Duka, Dr., case of ivory tumour of upper jaw	277
 ENCHONDROMA of upper jaw	265
" lower jaw	323
Epithelioma of gums	245
" of antrum	166
Epulis	234
" myeloid	236
" epitheliomatous	245
" treatment of	242
Esmarch, Professor, on closure of jaw	405
Eve, on pathology of multilocular cysts	198
Extraction of teeth causing fracture	1
 FALLING in of antrum	165
False joint after fracture	23
Fearn, Mr., dentigerous cyst	185
Fergusson, Sir W., case of hyperostosis	134
" case of hydrops antri	159
" cysts in lower jaw	202
" odontoma	215
" ivory tumour of upper jaw	274
" spindle-celled sarcoma of upper jaw	291
" fibrous tumour of lower jaw	320
Fibroma of upper jaw	258
" lower jaw	316
Forceps, Fergusson's	244
" Liston's	243
" Stromeyer's	86
Forget, Dr., on dentigerous cysts	186
" on odontomata	210
Four-tailed bandage	26
Fracture of lower jaw	1
" position of	2
" symptoms of	4
" complications of	9
" treatment of	26
" neck of condyle of lower jaw	6
" ramus of lower jaw	6
" coronoid process	8
" teeth	10
" alveolus	11
" glenoid cavity	13
" with dislocation	16
" upper jaw	43
" complications of	48


	PAGE
GENSOUL, on removal of upper jaw	305
Giraldès, M., on cysts of antrum	160
Goodwillie, Dr., on temporo-maxillary disease	386, 392
Graefe's apparatus for fractured upper jaw	51
Gross, Dr., on closure of jaw	400
Growths within antrum	166
Gums, diseases of	226
" hypertrophy of	226
" polypus of	231
" papilloma of	233
" epithelioma of	245
Gunning's interdental splints	33
Gunshot injuries of jaws	53
Gutta-percha wedges for fracture	28
" splint	53
Guérin, Dr. A., investigations of fracture of upper jaw	47
HÆMORRHAGE after fracture	9, 53
Hamilton's sling for fracture	27
Hammond's wire splint	28
Harrison, Mr., odontoma	217
" deformity of jaws	418
Hart, Mr., necrosis of upper jaw	117
Hayward, Mr., cap for teeth	37
Hepburn, Mr., case of angular union	15
Hill, Mr. B., modification of Lonsdale's splint	39
Hilton, Mr., ivory tumour of upper jaw	274
Holt, Mr., recurrent fibroid of lower jaw	339
" closure of jaws	403
Humphry, Dr., prolapse of tongue, producing deformity of jaw	415
Hydrops antri	157
Hyperostosis	130
Hypertrophy of gums	226
" neck and condyle	379
INFLAMMATORY diseases of the jaws	89
Interdental splint (Gunning's)	33
" (Bean's)	38
Irregular union after fracture	18
Ivory tumour of upper jaw	274
" lower jaw	326
JAWS, gunshot injuries of	53
" inflammation of	88
" abscess of	92, 98
" periostitis of	88, 89
" necrosis of	103
" syphilitic	105
" mercurial	107
" phosphorus	109
" exanthematous	113
" deformities of	415
Jaw, upper, fracture of	43
" treatment of	49
" tumours of	257
" fibrous	258


	PAGE
Jaw, upper, tumours of, cartilaginous	265
" " " osseous	272
" " " myeloid sarcoma	281
" " " vascular sarcoma	286
" " " spindle-celled sarcoma	290
" " " chondro-sarcoma	291
" " " ossifying sarcoma	292
" " " round-celled sarcoma	293
" " " epithelioma	299
" " " diagnosis of	303
" " " prognosis of	304
" operations on	304
Jaw, lower, fractures of	I
" " " complications of	9
" " " treatment of	26
" " " suture of	40
" dislocation of	72
" cysts of	170
" tumours of	316
" fibrous	316
" cartilaginous	323
" osseous	325
" myeloid sarcoma	330
" round-celled sarcoma	334, 342
" spindle-celled sarcoma	336
" chondro-sarcoma	342
" ossifying sarcoma	346
" epithelioma	350
" diagnosis of	360
" operations on	361
 KINLOCH, Dr., wiring of fragments	 40
 LAWSON, Mr., recurrent fibroid of lower jaw	 341
" " " chondroma of lower jaw	324
Ligature of teeth	40
Liston, Mr., case of large epulis	240
" fibrous tumours of upper jaw	260
Lonsdale's splint	39
Lower jaw, fracture of	I
" dislocation of	72
" tumours of (<i>see</i> Tumours)	
 MACGILLIVRAY, Mr., hypertrophy of gum	 228
Maisonneuve on dislocation	75
Margetson, Mr., case of fracture and dislocation of tooth	11
Multilocular cysts of lower jaw	192
" cystic tumour	200
Mycosis aspergillina of the antrum	373
Myeloid epulis	236
" sarcoma of upper jaw	281
" " lower jaw	330
 NECK of condyle fractured	 6
Necrosis of jaws	103

	PAGE
Necrosis of alveolus	104
" exanthematous	113
" syphilitic	105
" mercurial	107
" phosphorus-	109
" following injuries	116
" symptoms of	111
" repair after	118
" treatment of	125
" after fracture	14
" " of symphysis	16
Nélaton, on dislocation	72, 76
Neuralgia after fracture	11, 49
Newland-Pedley, Mr., case of fractured jaw	31
Non-union of fracture	20
 ODONTOMATA	210
Old-standing dislocations	80
Operations on upper jaw	304
" lower jaw	361
Ossifying sarcoma	292, 346
Osteoma of upper jaw	272
" lower jaw	325
 PAGET, Sir J., polypus of antrum	163
" Stephen, tumours of palate	249
Palate, tumours of the	249
Paralysis of dental nerve	11, 49
Parasitic diseases of the jaws	370
Periostitis	89, 92
" diffused alveolar	89
" localised alveolar	92
" " chronic alveolar	99
" tubercular	101
Permanent closure of jaws	
Phosphorus-necrosis	109
Polypus of antrum	162
 RAMUS of lower jaw fractured	3
Repair after necrosis	118
Rheumatoid arthritis, temporo-maxillary	377
Rigg's disease	90
Rizzoli, on closure of jaws	405
 SALIVARY fistula after fracture	16
Salter, Mr., case of fractured upper jaw	43
" on exanthematous necrosis	113
" on dentigerous cysts	183
" on odontomata	212
" on hypertrophy of gum	226
" on papilloma of gum	233
Sarcoma of palate	252
" upper jaw	281
" lower jaw	330
Savory, Sir W., on repair after phosphorus-necrosis	120

	PAGE
Smith, Mr. Cox, case of injury to symphysis	22
„ Prof. R. W., on dislocation	78
Spasmodic closure of jaw	389
Splint, interdental (Gunning's)	33
„ „ (Hammond's wire)	28
„ „ (Bean's)	38
„ Lonsdale's, Hill's modification of	39
„ for lower jaw	28
Stromeyer's dislocation-forceps	86
Sub-luxation of temporo-maxillary joint	387
Sub-periosteal resection	127
Suppuration in antrum	145
Sutton on odontomata	211
Suture of lower jaw	40
Syme, Mr., osteo-sarcoma of lower jaw	338
Symphysis, necrosis of	16
Symptoms of fractured jaw	4
Syphilitic necrosis	105
 TAY, Mr. W., necrosis of lower jaw	 114
Teeth, fracture of	10
„ dislocation of	10
„ ligature of	40
„ tumours connected with	210
„ irregularities of	223
Temporo-maxillary articulation, diseases of	375
Thomas's wire-suture	42
Tomes, Mr., on hypertrophy of gums	230
„ „ dentigerous cysts	182
„ „ odontomata	213, 215, 221
Treatment of fractures of lower jaw	26
„ „ upper jaw	49
Tumours connected with teeth	210
„ papillary, of gum	233
„ of palate	249
„ of upper jaw	257
„ „ fibrous	258
„ „ cartilaginous	265
„ „ osseous	272
„ „ myeloid sarcoma	281
„ „ vascular sarcoma	286
„ „ spindle-celled sarcoma	290
„ „ chondro-sarcoma	291
„ „ round-celled sarcoma	293
„ „ carcinomatous	299
„ „ diagnosis of	303
„ „ treatment of	304
Tumours of lower jaw	316
„ „ fibrous	316
„ „ cartilaginous	323
„ „ osseous	325
„ „ myeloid sarcoma	330
„ „ spindle-celled sarcoma	336
„ „ malignant	350
„ „ diagnosis of	360
„ „ treatment of	361
 UNION of fracture after necrosis	 14
„ irregular, of fractured lower jaw	18

	PAGE
Ununited fracture of lower jaw	19
Upper jaw, fractures of	43
,, tumours of (<i>see</i> Tumours)	
 VASCULAR sarcoma of upper jaw	 286
Vasey, Mr., deformity of jaw	417
Verneuil, M., on closure of jaw	407
 WARREN, Dr. Mason, on cysts of lower jaw	 208
Weiss, Mr. F., closure by cicatrix	
Wilkes, Mr., epithelioma of lower jaw	357
Wire splint, Hammond's	29
Wiring lower jaw	40
Wounds of the face	9





RD526

H35

Heath

1894

Injuries and diseases of the jaws.

1-17-06

called =

1-18-06

COLUMBIA UNIVERSITY LIBRARIES (hsl, stx)

RD 526 H35 1894 C.1

Injuries and diseases of the jaws;



2002242923

