

**A text-book of embryology for students of medicine / by John Clement Heisler.**

**Contributors**

Heisler, John C. 1862-1938.  
Augustus Long Health Sciences Library

**Publication/Creation**

Philadelphia and London : W. B. Saunders & company, 1901.

**Persistent URL**

<https://wellcomecollection.org/works/hu7ge373>

**License and attribution**

This material has been provided by This material has been provided by the Augustus C. Long Health Sciences Library at Columbia University and Columbia University Libraries/Information Services, through the Medical Heritage Library. The original may be consulted at the the Augustus C. Long Health Sciences Library at Columbia University and Columbia University. where the originals may be consulted.

This work has been identified as being free of known restrictions under copyright law, including all related and neighbouring rights and is being made available under the Creative Commons, Public Domain Mark.

You can copy, modify, distribute and perform the work, even for commercial purposes, without asking permission.



Wellcome Collection  
183 Euston Road  
London NW1 2BE UK  
T +44 (0)20 7611 8722  
E [library@wellcomecollection.org](mailto:library@wellcomecollection.org)  
<https://wellcomecollection.org>

COLUMBIA LIBRARIES OFFSITE  
HEALTH SCIENCES STANDARD



HX00008435

QM601

H36

cop. 2.


Columbia University 1901  
in the City of New York

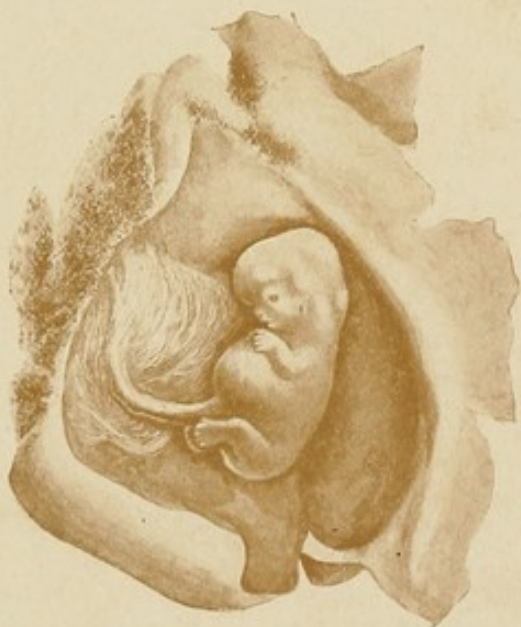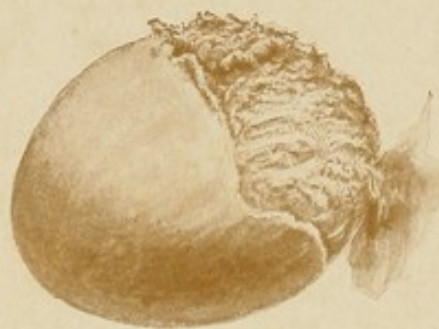College of Physicians and Surgeons



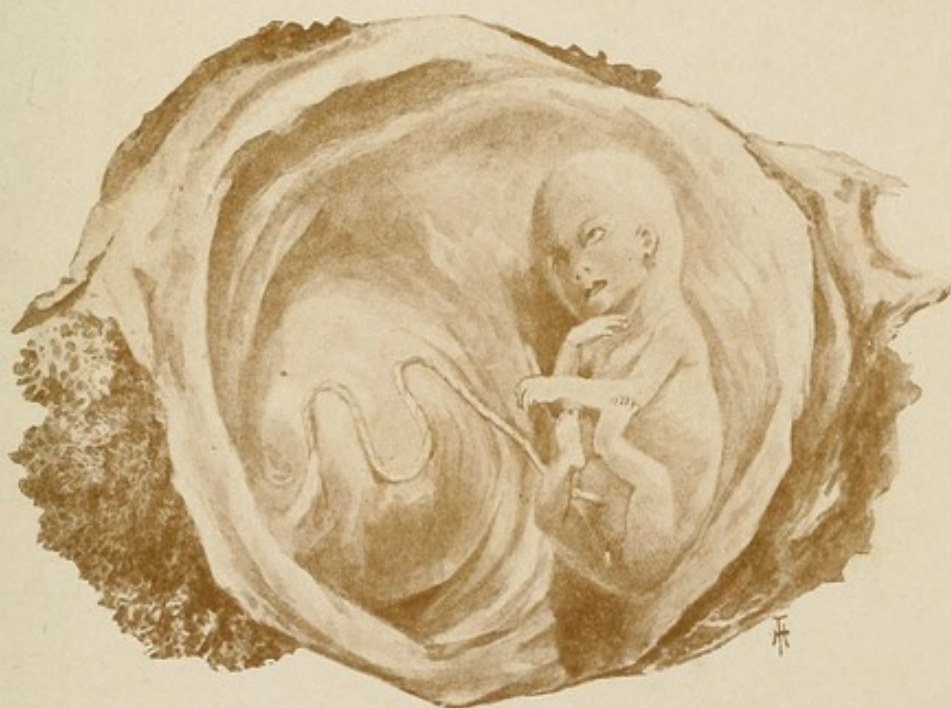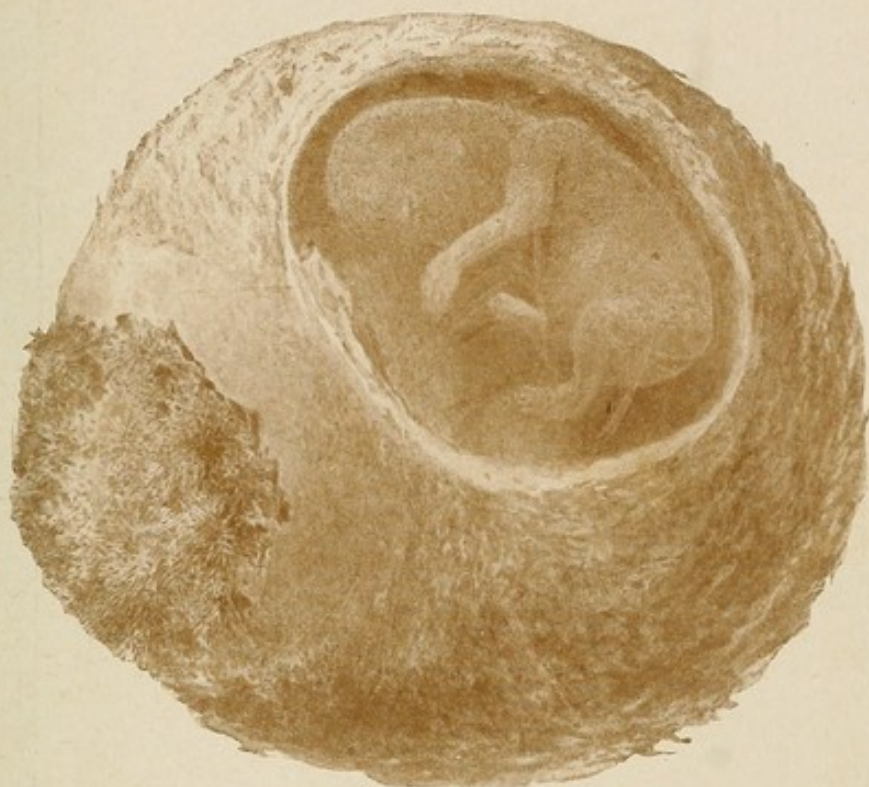Reference Library

Dr. George W. Peabody.






Ovum of about eight weeks, with membranes. In the upper figure (actual size), in the upper right-hand area, the chorion frondosum is apparent. In the lower figure (slightly larger than actual size) the membranes are laid open.



Fetus of third month, with fetal membranes and newly-formed placenta (natural size). In the upper figure the chorion is cut, showing the fetus through the amnion; in the lower figure the membranes are laid open.



A TEXT-BOOK  
OF  
EMBRYOLOGY

FOR STUDENTS OF MEDICINE

BY  
JOHN CLEMENT HEISLER, M.D.  
PROFESSOR OF ANATOMY IN THE MEDICO-CHIRURGICAL COLLEGE,  
PHILADELPHIA

---

WITH 196 ILLUSTRATIONS, 32 OF THEM IN COLORS

---

Second Edition, Thoroughly Revised

PHILADELPHIA AND LONDON  
W. B. SAUNDERS & COMPANY

1902

Copyright, 1899, 1901, by W. B. SAUNDERS & COMPANY.

Reprinted September, 1902.

ELECTROTYPED BY  
WESTCOTT & THOMSON, PHILADA.

PRESS OF  
W. B. SAUNDERS & COMPANY.

## PREFACE TO THE SECOND EDITION.

---

IN the presentation of the second edition of this book the effort has been made not only to make such additions and alterations as the progress of the science rendered necessary, but to correct whatever errors existed in the first edition, and to improve the work generally as much as might be. For kindly suggestions along these lines the author would express his thanks to the various reviewers who have from time to time noticed the work ; he would also express his profound appreciation of the generous spirit in which the book has been received.

The publication of the monograph of Peters upon the embedding of the ovum and the formation of the placenta,<sup>1</sup> followed by the work of Webster,<sup>2</sup> whose researches confirm the results of Peters' investigations, practically setting aside, as it does, the previous views upon these processes, necessitated radical changes in the text. Therefore the chapter treating of the Decidua and the Placenta has been rewritten, as has also the greater part of the section upon the Chorion.

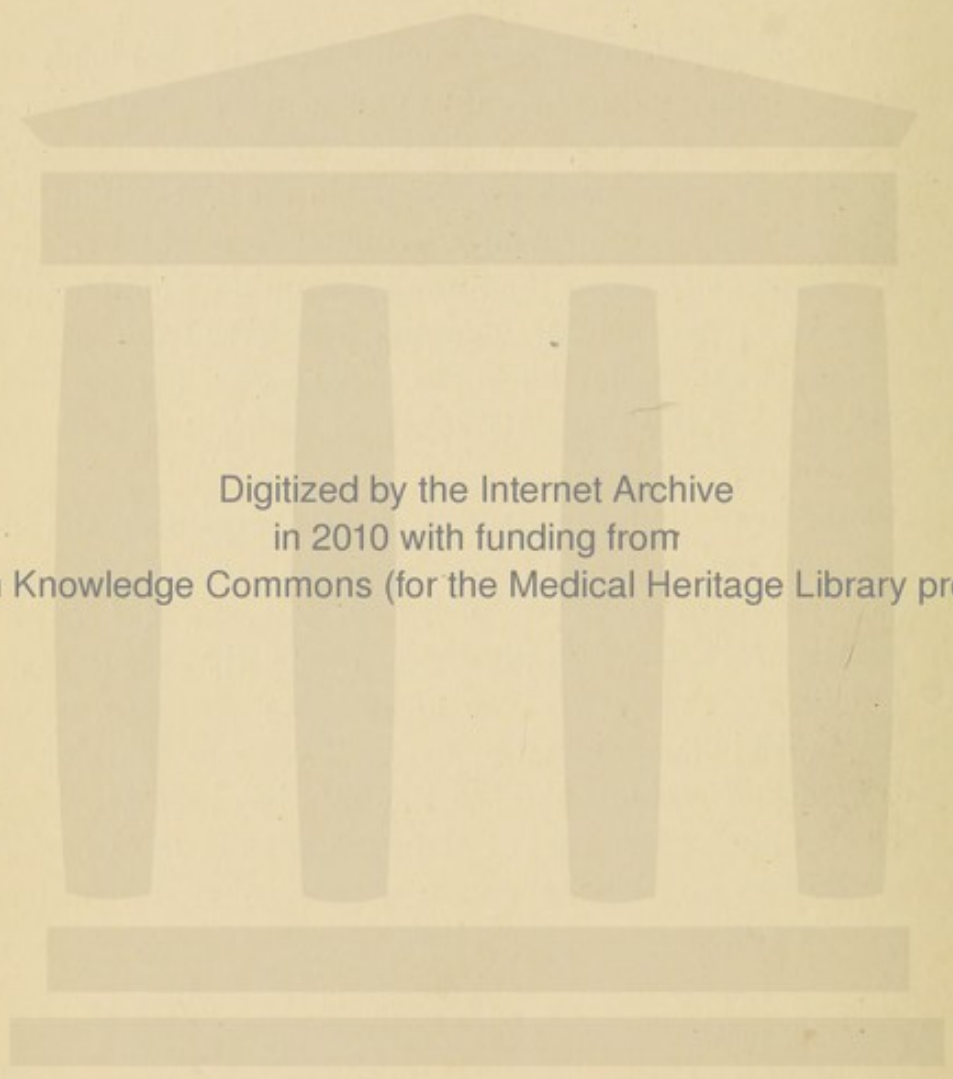
In addition to these changes, several new illustrations have been added.

J. C. H.

AUGUST 15, 1901.

<sup>1</sup> *Die Einbettung des Menschlichen Eies.* H. Peters. Vienna, 1899.

<sup>2</sup> *Human Placentation.* J. Clarence Webster. Chicago, 1901.



Digitized by the Internet Archive  
in 2010 with funding from  
Open Knowledge Commons (for the Medical Heritage Library project)

## PREFACE

---

THE facts of embryology having acquired in recent years such great interest in connection with the teaching and with the proper comprehension of human anatomy, it is of first importance to the student of medicine that a concise and yet sufficiently full text-book upon the subject be available. It was with the aim of presenting such a book that this volume was written, the author, in his experience as a teacher of anatomy, having been impressed with the fact that students were seriously handicapped in their study of the subject of embryology by the lack of a text-book full enough to be intelligible, and yet without that minuteness of detail which characterizes the larger treatises, and which so often serves only to confuse and discourage the beginner.

In the arrangement of the subject-matter of the book, it has been the aim not only to present a connected story of human development, but also to make each chapter as nearly as possible complete in itself, for the sake of convenience of reference. It is for this reason that some repetitions occur in the text. The frequent allusions to certain facts of comparative embryology are rendered necessary by the very nature of the subject, but it has been the writer's aim to make these allusions as simple and as easily intelligible as possible.

In the selection of the illustrations, great care has been exercised to employ those of the greatest teaching value, and to arrange them, with reference to any one chapter, as nearly

as possible in proper chronological sequence. Due acknowledgement is made in each case for every illustration borrowed from other works.

With few exceptions, no attempt has been made to cite authorities in the text, and the author would here express his obligations to the writings of His, O. Hertwig, Kölliker, Schultze, Bonnet, Balfour, Marshall, Piersol, Minot, Tournoux, and many others.

J. C. H.

3705 POWELTON AVE.,  
PHILADELPHIA.

# CONTENTS.

CHAPTER I.		PAGE
<b>The Male and Female Sexual Elements ; Maturation ; Ovulation ; Menstruation ; Fertilization . . . . .</b>		17
THE SPERMATOZOON . . . . .		20
THE OVUM . . . . .		22
The Hen's Egg . . . . .		25
Oogenesis . . . . .		27
MATURATION OF THE OVUM . . . . .		30
OVULATION . . . . .		32
MENSTRUATION . . . . .		35
The Relation of Menstruation to Ovulation and Conception . .		37
FERTILIZATION . . . . .		38
ARTIFICIAL FERTILIZATION . . . . .		40
CHAPTER II.		
<b>The Segmentation of the Ovum and Formation of the Blastodermic Vesicle . . . . .</b>		41
SEGMENTATION . . . . .		41
THE STAGE OF THE BLASTULA . . . . .		45
CHAPTER III.		
<b>The Germ-layers and the Primitive Streak . . . . .</b>		47
THE STAGE OF THE GASTRULA . . . . .		47
The Embryonal Area . . . . .		50
The Primitive Streak . . . . .		51
The Development of the Mesoderm . . . . .		54
The Derivatives of the Germ-layers . . . . .		58
CHAPTER IV.		
<b>The Beginning Differentiation of the Embryo ; the Neural Canal ; The Chorda Dorsalis ; the Mesoblastic Somites</b>		61
The Neural or Medullary Canal . . . . .		62
The Notochord or Chorda Dorsalis . . . . .		65
The Neurenteric Canal . . . . .		66
The Somites or Primitive Segments . . . . .		67

## CHAPTER V.

PAGE

<b>The Formation of the Body-wall, of the Intestinal Canal, and of the Fetal Membranes . . . . .</b>	<b>71</b>
THE FORMATION OF THE BODY-WALL AND OF THE INTESTINAL CANAL OF THE EMBRYO . . . . .	71
THE AMNION . . . . .	74
THE YOLK-SAC . . . . .	78
THE ALLANTOIS . . . . .	80
THE CHORION . . . . .	82

## CHAPTER VI.

<b>The Decidua and the Embedding of the Ovum; the Placenta; the Umbilical Cord . . . . .</b>	<b>85</b>
THE DECIDUA AND THE EMBEDDING OF THE OVUM . . . . .	85
THE PLACENTA . . . . .	88
THE UMBILICAL CORD . . . . .	92
RELATIONS OF THE FETAL MEMBRANES AT BIRTH . . . . .	94

## CHAPTER VII.

<b>The Further Development of the External Form of the Body</b>	<b>95</b>
THE STAGE OF THE OVUM . . . . .	96
THE STAGE OF THE EMBRYO . . . . .	96
The Visceral Arches and Clefts . . . . .	100
THE STAGE OF THE FETUS . . . . .	107

## CHAPTER VIII.

<b>The Development of the Connective Tissues of the Body, and of the Lymphatic System . . . . .</b>	<b>113</b>
THE CONNECTIVE TISSUES . . . . .	113
THE DEVELOPMENT OF THE LYMPHATIC SYSTEM . . . . .	116

## CHAPTER IX.

<b>The Development of the Face and the Mouth Cavity . . . . .</b>	<b>118</b>
The Evolution of the Face . . . . .	118
THE MOUTH . . . . .	122
The Teeth . . . . .	125
The Salivary Glands . . . . .	131
The Tongue . . . . .	131
THE NOSE . . . . .	133

## CHAPTER X.

<b>The Development of the Vascular System . . . . .</b>	<b>135</b>
THE VITELLINE CIRCULATION AND THE ORIGIN OF THE BLOOD	135
THE DEVELOPMENT OF THE HEART . . . . .	138
The Metamorphosis of the Single into the Double Heart . . . . .	142
The Valves of the Heart . . . . .	144

	PAGE
THE ALLANTOIC AND THE PLACENTAL CIRCULATION . . . . .	148
THE FETAL ARTERIAL SYSTEM . . . . .	149
THE FETAL VENOUS SYSTEM . . . . .	153
THE FORMATION OF THE PERICARDIUM, THE PLEURÆ, AND THE DIAPHRAGM . . . . .	158
THE PORTAL CIRCULATION . . . . .	161
THE FINAL STAGE OF THE FETAL VASCULAR SYSTEM . . . . .	165

## CHAPTER XI.

<b>The Development of the Digestive System . . . . .</b>	<b>168</b>
THE MOUTH . . . . .	175
THE PHARYNX . . . . .	176
The Tonsil . . . . .	177
THE ANUS . . . . .	178
THE DIFFERENTIATION OF THE ALIMENTARY CANAL INTO SEP- ARATE REGIONS . . . . .	180
Increase in Length and Further Subdivision . . . . .	184
Alteration in the Relative Position of Parts and Further Devel- opment . . . . .	185
Histological Alterations . . . . .	188
Meckel's Diverticulum . . . . .	190
THE DEVELOPMENT OF THE LIVER . . . . .	190
THE DEVELOPMENT OF THE PANCREAS . . . . .	194
THE DEVELOPMENT OF THE SPLEEN . . . . .	194
THE EVOLUTION OF THE PERITONEUM . . . . .	195

## CHAPTER XII.

<b>The Development of the Respiratory System . . . . .</b>	<b>204</b>
THE THYROID AND THYMUS BODIES . . . . .	207

## CHAPTER XIII.

<b>The Development of the Genito-urinary System . . . . .</b>	<b>212</b>
THE DEVELOPMENT OF THE KIDNEY AND THE URETER . . . . .	212
The Mesonephros or Wolffian Body . . . . .	213
The Metanephros or Permanent Kidney . . . . .	217
THE SUPRARENAL BODIES . . . . .	218
THE DEVELOPMENT OF THE INTERNAL GENERATIVE ORGANS . . . . .	220
The Indifferent Type . . . . .	220
The Male Type . . . . .	222
The Female Type . . . . .	226
THE BLADDER AND THE PROSTATE GLAND . . . . .	232
THE EXTERNAL ORGANS OF GENERATION . . . . .	234
The Female External Genitals . . . . .	236
The Male External Genitals . . . . .	237
SUMMARY . . . . .	240

## CHAPTER XIV.

	PAGE
<b>The Development of the Skin and its Appendages . . . . .</b>	<b>245</b>
THE SKIN . . . . .	245
THE APPENDAGES OF THE SKIN . . . . .	247
The Nails . . . . .	247
The Hair . . . . .	248
The Sebaceous and Sweat Glands . . . . .	250
The Mammary Gland . . . . .	251

## CHAPTER XV.

<b>The Development of the Nervous System . . . . .</b>	<b>254</b>
THE DEVELOPMENT OF THE SPINAL CORD . . . . .	257
THE DEVELOPMENT OF THE BRAIN . . . . .	262
The Fifth Brain-vesicle . . . . .	264
The Hind-brain Vesicle . . . . .	268
The Mid-brain Vesicle . . . . .	270
The Inter-brain Vesicle . . . . .	272
The Fore-brain Vesicle . . . . .	278
THE DEVELOPMENT OF THE PERIPHERAL NERVOUS SYSTEM . . . . .	292
THE DEVELOPMENT OF THE SYMPATHETIC SYSTEM . . . . .	300

## CHAPTER XVI.


<b>The Development of the Sense Organs . . . . .</b>	<b>302</b>
THE DEVELOPMENT OF THE EYE . . . . .	302
The Retina and Optic Nerve . . . . .	304
The Crystalline Lens . . . . .	312
The Vitreous Body . . . . .	314
The Middle and Outer Tunics of the Eye . . . . .	315
The Eyelids and the Lacrimal Apparatus . . . . .	318
THE DEVELOPMENT OF THE ORGAN OF HEARING . . . . .	321
The Internal Ear . . . . .	321
The Middle and External Ear . . . . .	331
THE DEVELOPMENT OF THE NOSE . . . . .	334

## CHAPTER XVII.

<b>The Development of the Muscular System . . . . .</b>	<b>339</b>
THE STRIATED OR VOLUNTARY MUSCLES . . . . .	339
The Muscles of the Trunk Proper . . . . .	339
The Metamorphosis of the Muscle-plate . . . . .	342
The Branchial Muscles . . . . .	344
The Muscles of the Extremities . . . . .	345
THE INVOLUNTARY OR UNSTRIATED MUSCULAR TISSUE . . . . .	346

## CHAPTER XVIII.

	PAGE
<b>The Development of the Skeleton and of the Limbs . . . . .</b>	<b>347</b>
THE AXIAL SKELETON . . . . .	348
The Development of the Trunk . . . . .	348
The Stage of the Chorda . . . . .	348
The Membranous Stage . . . . .	349
The Cartilaginous Stage . . . . .	351
The Osseous Stage . . . . .	354
The Development of the Ribs and Sternum . . . . .	356
The Development of the Head Skeleton . . . . .	358
The Membranous Cranium . . . . .	359
The Cartilaginous Cranium . . . . .	360
The Osseous Stage . . . . .	363
THE APPENDICULAR SKELETON . . . . .	376
The Pectoral and Pelvic Girdles . . . . .	377
The Bones of the Extremities . . . . .	378
THE DEVELOPMENT OF THE LIMBS . . . . .	380
THE POSITION OF THE LIMBS . . . . .	381
<b>Tabulated Chronology of Development . . . . .</b>	<b>383</b>
<b>Index . . . . .</b>	<b>391</b>



## CHAPTER I.

### THE MALE AND FEMALE SEXUAL ELEMENTS; MATURATION; OVULATION; MENSTRUATION; FERTILIZATION:

EMBRYOLOGY is that department of biology which treats of the generation and development of organisms. It may refer to the development of the race or stock—**Phylogeny**—or to that of the individual—**Ontogeny**; again, it may treat of animal or of vegetable development.

Since no observations have been made upon embryos of an age less than four or five days, and but few, indeed, upon those younger than sixteen or eighteen days, we cannot be said to possess definite knowledge of the very earliest processes of development in man. There is, however, sufficient analogy between the known facts of human development and those of corresponding stages in allied groups of animals, as well as between the various groups of animals themselves, to establish certain broad general principles of agreement in essential features. In tracing the history of human development, therefore, frequent recourse must be had to the development of animals, since in this way only is it possible at present to fill up the gaps in our knowledge of human embryology.

That a new individual may be called into existence, the union of the male element, or **spermatozoon**, with the female element, or **ovum**, is necessary. Such union is variously called **fertilization**, **fecundation**, and **impregnation**.

Prior to the beginning of the present century, little or nothing was definitely known concerning reproduction and development. The opinions of the biologists of early times found expression in a theory which was then called the *theory of unfolding* or *of evolution*, but which more recently has

been designated the *preformation theory*. According to this doctrine, the egg or germ contained all the parts of the adult organism in an exceedingly minute condition, and development consisted in the simple growth or unfolding of already formed parts. As the *theory of unfolding* implied the preformation not only of the immediate but of all subsequent offspring, its votaries were able to compute that the ovary of Eve contained 200,000 millions of human germs.

With the discovery of the spermatozoon in 1677 by Hamm, a pupil of Leuwenhoeck, a controversy arose as to whether it was the spermatie filament or the ovum that contained the germ. Those who maintained the former view were known as *animalculists*; those who held the latter, as *ovists*. According to the opinions of the animalculists, the spermatozoon was the complete organism in miniature, and it required for its growth the soil or environment which the ovum alone could furnish.

The enunciation by Wolff, in 1759, of his *doctrine of epigenesis* completely overturned the preformation theory. Wolff maintained that the germ was *unorganized matter*, and that the union of male and female material was essential to reproduction. While Wolff's theory was in the main correct, it remained for later investigators to show that the ovum did not consist of unorganized matter, as he thought, but that it possessed definite structural characteristics. Thus, the germinal vesicle of the hen's egg was discovered in 1825 by Purkinje, and the germinal spot in 1826 by Wagner. Soon after the enunciation of the cell-doctrine by Schleiden and Schwann, it was seen that the ovum was in reality a typical cell, possessing all the parts of such a structure.

It was not, however, until about the year 1840 that it was shown, by Kölliker, Reichert, and others, that the spermatozoa are the active agents in fecundation. Previously it had been held, since the refutation of the preformation theory, that the seminal fluid performed this function, and that the spermatozoa were parasitic organisms.

The **length of time** necessary for the development of the new individual varies according to the species; in man it

occupies nine calendar months or about ten lunar months—that is, from 273 to 280 days. The period of human gestation is arbitrarily divided by His into three stages: (1) The

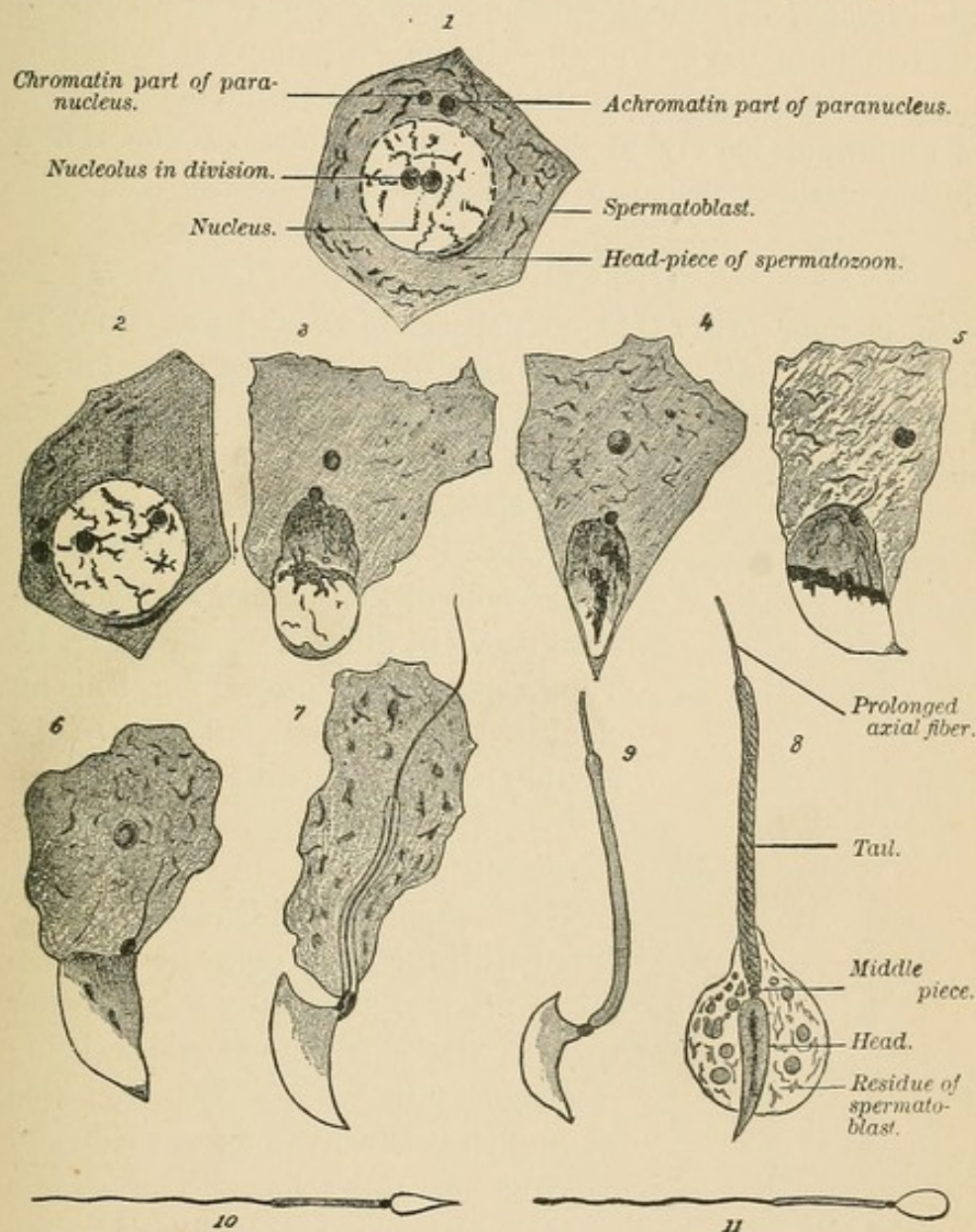


FIG. 1.—1 to 8, Various stages of the development of the spermatozoon of the mouse; 9, the spermatozoon of the mouse (after F. Hermann); 10 and 11, spermatozoa of the dog; 10, as seen from the side; 11, as seen from the broader surface (after Bonnet).

stage of the ovum, comprising the first two weeks of development; (2) The stage of the embryo, extending from the end of the second week to the fifth week, during which time the germ begins to assume definite form; and (3) The stage of

the fetus, which includes the remainder of the term of intra-uterine existence.

It may be pointed out that the term *ovum*, as employed in embryology, has three different significations: it designates the female sexual cell prior to its impregnation; it is used in the sense noted above to designate the fertilized egg; and it is somewhat loosely applied to the product of conception during various stages of development.

### THE SPERMATOZOON.

It is noteworthy that both spermatozoa and ova—that is, both sexual cells—are products of metamorphoses taking place in epithelial structures, the former being derived from the spermatogenic cells found in the seminiferous tubules of the testicle, while the latter come from the germinal epithelium of the ovary.

The form of the seminal filament varies greatly in different species (Fig. 1). The human spermatozoon (Fig. 2) is an elongated body, about 0.05 mm. ( $\frac{1}{500}$  inch) in length, consisting of three parts, a head, a middle piece, and a tail or flagellum.

The head is much thickened as compared with the other segments, appearing egg-shaped as seen upon its broader surface, the smaller extremity being connected with the middle piece; seen in profile, it is convex on one side and concave on the other. The middle piece is somewhat longer and much thinner than the head, while the tail is a slender filament slightly more than four-fifths of the entire length of the spermatozoon. Lying in the center of the spermatozoon, and extending throughout its entire length, is the slender axial fiber, which is prolonged slightly beyond the tail.

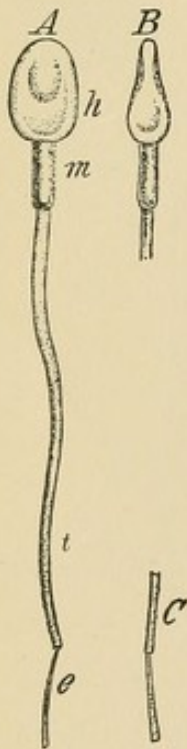


FIG. 2.—Human spermatozoa (after Retzius): A, spermatozoon seen *en face*; h, head; m, middle-piece; t, tail; e, end-piece; B, C, seen from the side.

The **power of locomotion** which the spermatozoon exhibits is conferred by the vibratile movement of its tail, accompanied by a rotation about its long axis through an arc of 90 degrees. The **rate of progression** is about 0.05 or 0.06 mm., or its own length, per second.

Spermatozoa possess remarkable vitality, remaining active in the male genital tract for several days after death. In the genital passages of the female, they may retain their activity for several weeks, and when mounted and protected from evaporation they have been known to show vibratile motion after the lapse of nine days (Piersol). Weak alkaline solutions render them more active, while acids, even quite dilute, destroy them. The spermatozoa of the bat, being deposited in the female genital passages in the autumn, retain their power of fecundating ova until the following spring.

**Spermatogenesis.**—The details of spermatozoon-formation, or **spermatogenesis**, vary in different animals. A cross section of a seminiferous tubule (Fig. 3) shows a layer of

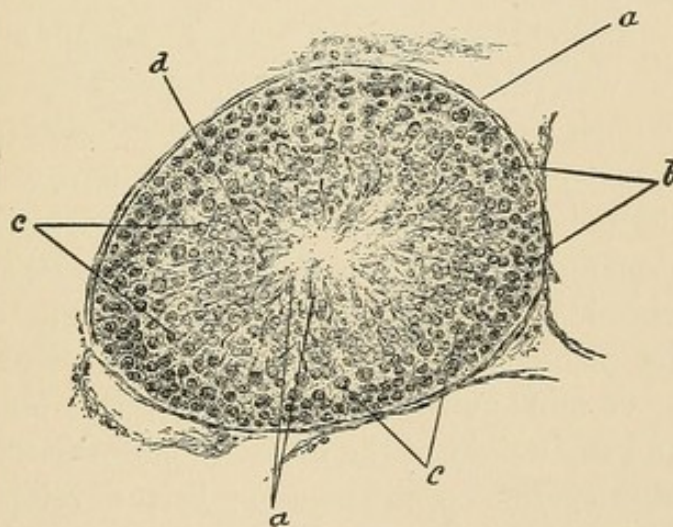


FIG. 3.—Section of testicle of musk-rat; seminiferous tubule seen in cross section: *a*, wall of tubule; *b*, parietal cells; *c*, mother-cells; *d*, spermatoblasts.

cuboidal cells called **parietal cells**, lying in contact with the basement membrane of the tubule wall. This layer consists of the so-called **Sertoli's columns**, or **sustentacular cells**, and of the **spermatogenic cells**. The sustentacular cells are merely supporting; the spermatogenic cells give rise to the spermatozoa. The immediate offspring of the spermatogenic

cells are the **mother-cells**, a group lying in contact with the spermatogenic cells, on the side toward the lumen of the tubule. The multiplication of the mother-cells results in the production of the smaller **daughter-cells**, whose nuclei are the **spermatoblasts**, or spermatids of some authors. The round spermatoblast soon becomes oval, and later pear-shaped, and its chromatin accumulates in the outer half of the nucleus, giving rise to a dark, deeply-staining zone in this position, and a clear zone on the side toward the lumen of the tubule. At the same time the nucleus or spermatoblast escapes from the daughter-cell. A little later the spermatoblast shows three zones—an outer clear band, a middle dark area, in which the chromatin has become localized, and an inner clear region. A slender filament or spine of chromatin, the rudiment of the tail, now grows from the middle dark zone into and through the inner clear area (that is, toward the lumen of the tubule), projecting slightly beyond the limits of the nuclear membrane. With the disappearance of the nuclear membrane and the progress of further changes—which changes consist in the formation of the **head** from the outer clear band, of the **tail** and **middle piece** from the middle dark zone, and of the delicate **sheath** for the tail and the middle piece from the inner clear band—the development of the spermatozoon is practically completed.

The spermatozoon has been regarded as a metamorphosed cell, the head representing the nucleus, and the cilium or tail the protoplasm. This view, however, is controverted by certain authorities (Kölliker, Biondi, Niessing, Piersol), and the weight of the evidence is in favor of regarding the entire spermatozoon as having been developed from a *cell-nucleus*.

#### THE OVUM.

The female sexual cell or **ovum** is remarkable among animal cells for its size, it being a rule, to which there are no known exceptions, that it is much larger than any other cell in the body of the parent. The **human ovum** measures, in the mature state, 0.2 mm. in diameter.

In structure, the ovum presents the parts of a typical cell ;

namely, a cell-wall, here called the **vitelline membrane**, the cell-contents, or **vitellus** or **yolk**, a nucleus or **germinal vesicle**, and a nucleolus or **germinal spot**.

Surrounding the ovum is a somewhat loosely-fitting transparent, elastic envelope, the **zona pellucida**, and outside of this is the **corona radiata**. These two layers are often re-

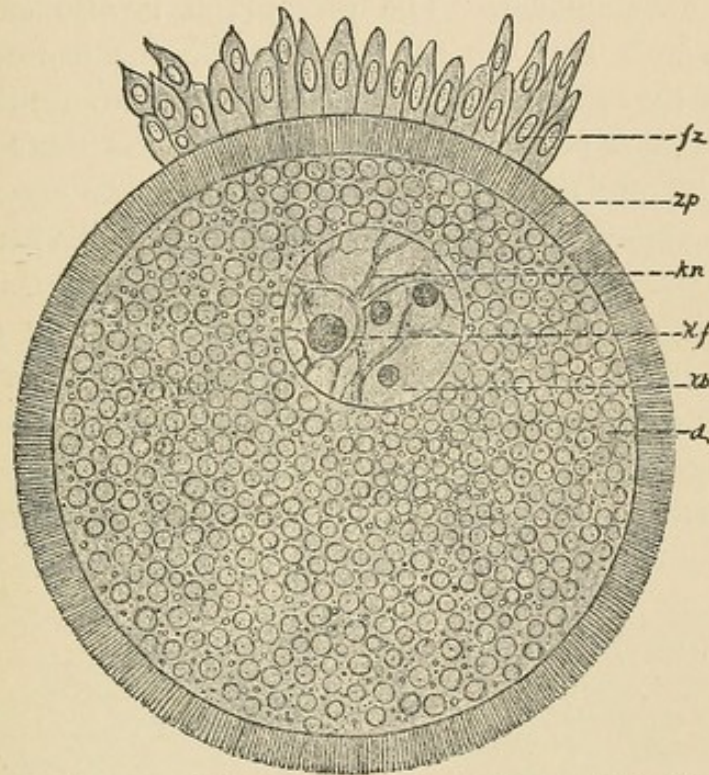


FIG. 4.—Egg from a rabbit's follicle which was 0.2 mm. ( $\frac{1}{125}$  inch) in diameter (after Waldeyer). It is surrounded by the zona pellucida (z. p.), on which there rest at one place follicular cells (f. z.). The yolk contains deutoplasmic granules (d.). In the germinal vesicle (k. b.) the nuclear network (k. n.) is especially marked, and contains a large germinative dot (k. f.).

ferred to as the **egg-envelopes**; and since they are contributed by the discus proligerus of the Graafian follicle, it must be remembered that they are not, properly speaking, a part of the ovum. Between the zona pellucida and the ovum is the small **perivitelline space**. The radial striation of the zona is generally regarded as due to the presence of minute canals opening into this space. The canals are thought by some to facilitate the ingress of spermatozoa, thus corresponding in function to the **micropyle**, a small aperture found in the less easily penetrable egg-envelopes of many invertebrates and of some fishes.

The **vitelline membrane** does not call for extended description. It may be regarded as a slightly specialized condensation of the peripheral part of the cell-contents.

The **vitellus**, or cell-contents, here, as in other cells, is essentially **protoplasm**, to which is added material called **deutoplasm**, designed for the nutrition of the ovum at the beginning of development. The protoplasm is also called the **formative yolk** and the **egg-plasm**, while the deutoplasm is known as the **nutritive yolk**. In the human ovum these elements are more or less uniformly distributed; there is, however, a differentiation into an inner, slightly less clear region, containing more yolk-granules (deutoplasm), and a peripheral, clearer zone. The characteristic transparency of the human egg-cell is due to the fact that the deutoplasmic particles found in it are not cloudy as in the ova of other mammals. The following classification of ova by Balfour is based upon the arrangement of these constituents:

1. **Alecithal ova** are those in which the protoplasm and

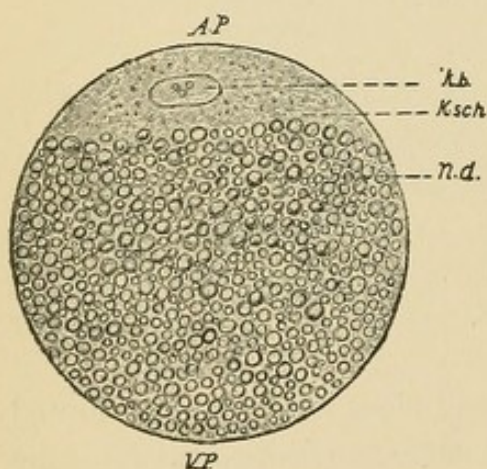


FIG. 5.—Diagram of an egg with the nutritive yolk in a polar position. The formative yolk constitutes at the animal pole (*A. P.*), a germ-disk (*K.sch.*) in which the germinative vesicle (*k.b.*) is enclosed. The nutritive yolk (*n.d.*) fills the rest of the egg up to the vegetative pole (*V. P.*) (Hertwig).

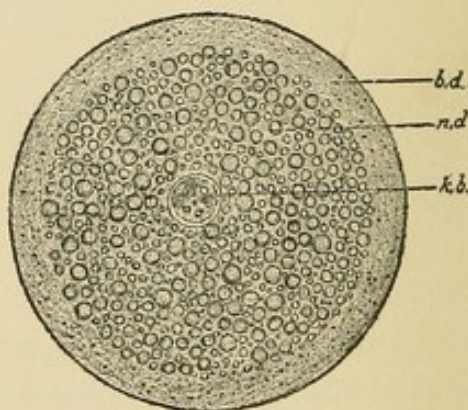


FIG. 6.—Diagram of an egg with the nutritive yolk in the center. The germinative vesicle (*k.b.*) occupies the middle of the nutritive yolk (*n.d.*), which is enveloped in a mantle of formative yolk (*b.d.*) (Hertwig).

deutoplasm are uniformly distributed, as in the ova of *Mammalia*, including man), and of *amphioxus* (Fig. 4).

2. **Telolecithal ova** are those in which the relatively abun-

dant deutoplasm is accumulated at one side of the ovum, called the **vegetative pole**, while the protoplasm appears as a flat **germ-disk** at the **animal pole** on the opposite side. Here belong the eggs of birds, reptiles, and bony fishes (see Fig. 5).

3. **Centrolecithal ova** are those in which the deutoplasm is *central*, the protoplasm completely surrounding it, as in the eggs of arthropods (Fig. 6).

Ova are classified also according to their method of segmentation. This will be described later.

The **germinal vesicle** or nucleus is the most important part of the cell, since, as will be seen hereafter, it is essentially by the conjugation, or more accurately by the fusion, of the nuclei of the male and female parent-cells that generation is effected. As a rule, there is but one nucleus, though there may be two. Its position is usually—if not universally—eccentric, this being more marked where there is a distinct differentiation into animal and vegetative poles, in which case it is found always near the animal pole. It is nearly spherical in shape, and like the nucleus of any other typical cell, it is composed of a network of nuclear fibrils or **chromatin substance**, and nuclear juice or **achromatin**, the former containing the latter within its meshes. Surrounding the nucleus is the well-marked **nuclear membrane**, while within it is the nucleolus or **germinal spot**. The latter may be single or multiple, according to the species, though the number is fairly constant for each species. Nagel ascribes ameboid movement to the germinal spot.

**Polarity.**—The **polarity** of the egg has been incidentally referred to. Apparently it owes its existence to the eccentric position of the nucleus, the animal pole being that point on the surface to which the nucleus is nearest. Polarity bears a significant relation to the specific gravity of the ovum, since the nucleus reaches the surface of the latter at the animal pole and there extrudes the polar globules; and it is also related to the segmentation of the fertilized egg.

**The Hen's Egg.**—As the hen's egg is so largely utilized for the study of development, it will be profitable to consider briefly its structure. The ovum or egg-cell is represented by

the yolk or yellow of the egg, the albumen or white, as well as the shell and shell-membrane, being egg-envelopes contributed by the oviduct. As in other ova, the egg proper is a single cell, having a vitelline membrane and a germinal vesicle. The enormous size of the cell is due to the large quantity of nutritive material or deutoplasm present, this contributing by far the greater part of the bulk, while the much smaller formative yolk or protoplasm, containing the germinal vesicle, is so eccentrically placed that it seems to float upon the surface of the deutoplasm. The little whitish spot on the surface of the yolk, known as the *cicatricula* or **germinative disk**, consists of the germinal vesicle with the surrounding formative yolk. It is in the germinative disk alone that segmentation takes place, and it is for this reason that eggs of this class are designated **meroblastic**, or **partially-dividing eggs**.

The deutoplasm is made up of **white** and of **yellow yolk**

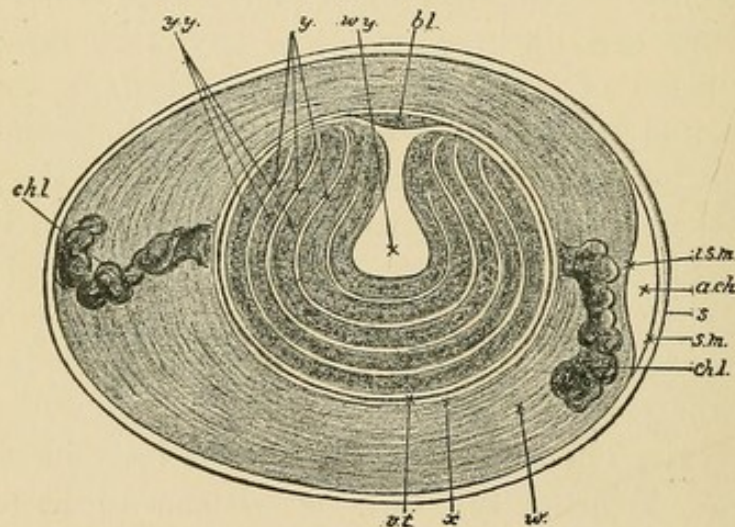


FIG. 7.—Diagrammatic longitudinal section of an unincubated hen's egg (after Allen Thomson). (Somewhat altered): *b.l.*, germ-disk; *w.y.*, white yolk, which consists of a central flask-shaped mass, and a number of concentric layers surrounding the yellow yolk (*y.y.*); *v.t.*, vitelline membrane; *x*, a somewhat fluid albuminous layer which immediately envelopes the yolk; *w.*, albumen, composed of alternating layers of more and less fluid portions; *ch.l.*, chalazæ; *a.ch.*, air-chamber at the blunt end of the egg—simply a space between the two layers of the shell-membrane; *i.s.m.*, inner, *s.m.*, outer layer of the shell-membrane; *s.*, shell.

(Fig. 7). The former consists of a thin layer spread over the surface of the latter; of a small mass, known as **Pander's**

**nucleus**, situated under the germinative disk; of a larger mass, the **latebra**, more deeply placed; and of several concentric layers separated from each other by the yellow yolk.

Such is the egg as it leaves the hen's ovary. In the beginning of the oviduct it is fertilized by the spermatozoa already there. After fertilization it passes into the longitudinally furrowed second part of the tube, where it receives a copious coating of albuminous material, the **white of the egg**; thence it goes into the villous third part of the oviduct, where it acquires a calcareous coating, the **shell**; finally, passing through the fourth part of the canal, it is "laid."

The layer of albumen immediately surrounding the yolk is relatively dense; it is prolonged to either extremity of the egg, somewhat spirally twisted, as the **chalazæ**. Enclosing the albumen is the thin tough **shell-membrane**. This consists of two layers, which separate at the blunt pole of the egg soon after it is laid, giving rise to the **air-chamber**. The **shell**, composed largely of lime salts, is very porous and thus readily permits of the necessary gas-interchange between the contents of the egg and the external air during incubation.

Ova do not possess the remarkable vitality which is characteristic of spermatozoa. An unimpregnated ovum perishes in from seven to nine days.

**Oogenesis.**—The formation of ova takes place throughout the greater part of fetal life and continues for a short time (two years, according to Waldeyer, Bischoff, and others) after birth. Their number is estimated to be about seventy thousand.

The ovum, the direct derivative of the **germinal epithelium** covering the free surface of the ovary, is situated in the cortical part of the latter organ, being enclosed in the Graafian follicle. As a rule, each Graafian follicle or ovisac contains but one ovum, though sometimes two, and more rarely three are present.

The **Graafian follicle**, in its mature condition, is a vesicle from 4 to 8 mm. in diameter, which is surrounded by a sheath, the **theca folliculi** or **tunica vasculosa**, consisting of a condensation of the ovarian stroma. The outer, more fibrous

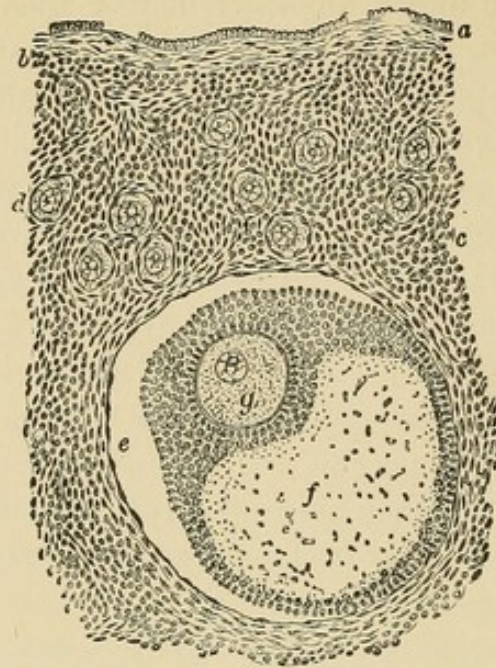


FIG. 8.—Section of human ovary, including cortex: *a*, germinal epithelium of free surface; *b*, tunica albuginea; *c*, peripheral stroma containing immature Graafian follicles (*d*); *e*, well-advanced follicle from whose wall membrana granulosa has partially separated; *f*, cavity of liquor folliculi; *g*, ovum surrounded by cell-mass constituting discus proligerus (Piersol).

zone of the theca, containing large blood-vessels, is distinguished as the **tunica fibrosa**; the inner more cellular layer, rich in small vessels and capillaries, as the **tunica propria**.

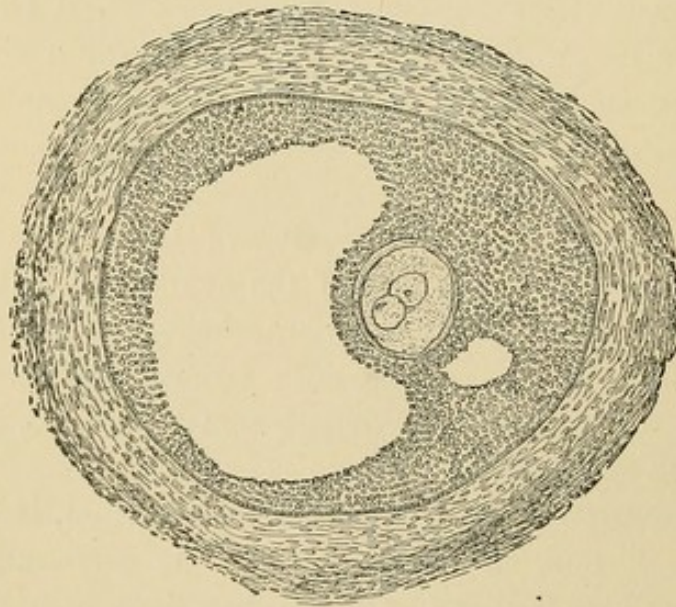


FIG. 9.—Section of well-developed Graafian follicle from human embryo (Von Herff); the enclosed ovum contains two nuclei.

The fibrous wall of the follicle is lined by the **membrana granulosa**, which consists of many layers of epithelial cells; these, at the point of contact with the ovum, project in such a manner as to surround it completely, the cellular envelope thus formed constituting the **discus proligerus**. The inner cells of the discus are arranged in two layers, the individual elements having their long axes radially directed. From the appearance of radial striation, conferred partly by this circumstance, the inner zone has been called the **zona radiata** or **zona pellucida**, and the outer the **corona radiata**. The cavity of the Graafian follicle is filled with fluid, the **liquor folliculi**.

The **stigma**, or **hilum folliculi**, a yellowish-white spot devoid of blood-vessels on the free surface of the Graafian follicle, indicates the point at which rupture will take place. After this event, which occurs when the ovum is "ripe," the latter passes into the Fallopian tube.

The **ultimate origin of the egg** is to be sought in that important group of cells on the surface of the ovary to which Waldeyer gave the name **germinal epithelium**. This first appears at about the fifth week of intra-uterine life, as a localized thickening of the cells of the structure that subsequently becomes the peritoneum. The thickened areas comprise two longitudinal elevations on the dorsal side of the future abdominal cavity, one on each side of the median plane of the body; these are the **genital ridges**. Owing to the development of connective tissue beneath the epithelium, the ridges increase in thickness, and, with the progress of other changes, finally become, in the female, the **ovaries**. At about the sixth or seventh week—the germinal epithelium now consisting of several layers of cells instead of being a single stratum thick, as at first—cord-like processes, the **sexual cords**, or **primary egg-tubes**, or **egg-columns**, grow from the surface into the underlying connective tissue, carrying with them certain of the surface-cells (see Fig. 112). Conspicuous among these are the large **sexual cells**, or **primitive ova**; while smaller cells, likewise from the germinal epithelium, are also present. The sexual cords become divided into groups

of cells, each group containing one or more primitive ova and many of the smaller cells. Gradually, the small cells of the group surround the primitive ovum, at first as a single layer of flattened cells, which are succeeded by several layers of polygonal cells. From these enveloping cells come the *membrana granulosa* and the *theca* of the Graafian follicle.

The **primitive ova** become **fully formed eggs** upon the assumption by their rather ill-defined nuclei of the characteristic shape and structure of typical nuclei, coincidentally with the occurrence of other changes of secondary importance in other parts of the cell.

The youngest ova are found nearest the surface of the ovary, the eggs as they develop advancing toward, but never entering, the medulla of the organ. Finally, in the fully-developed condition of the ovum and the follicle, the size of the latter is such that its diameter equals or exceeds the thickness of the ovarian cortex, its position being usually indicated by a small prominence on the surface of the ovary.

### MATURATION OF THE OVUM.

By **maturation** or **ripening** is meant that series of changes by which the ovum is prepared for fertilization and without which the latter process is impossible. In nearly all mammals, including man, it occurs while the ovum is still in the Graafian follicle; in some other groups it takes place after the egg has reached the oviduct.

Briefly, maturation may be said to consist in the extrusion from the cell of a part of its nucleus and of a small part of its protoplasm. The nucleus undergoes changes practically identical with those of ordinary cell-division. First, the nuclear membrane disappears, the nucleolus disintegrates, the nuclear juice becomes mingled with the surrounding protoplasm, and the nucleus moves toward the periphery of the egg (Fig. 10). There is now formed a nuclear spindle from the achromatin substance of the nucleus. The long axis of the spindle lies parallel with one of the radii, and its direction is determined by the position of the pole-corpuscles. Each pole-corpuscle is surrounded by a radiation, the attrac-

tion-sphere or polar striation. These bodies exercise a controlling influence upon the nuclear spindle, so that it assumes

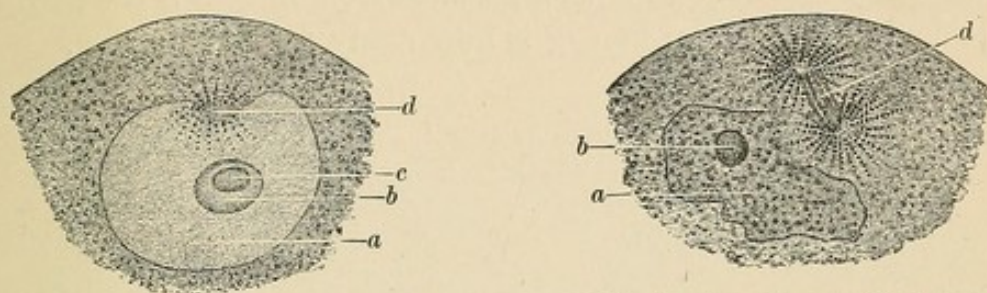


FIG. 10.—Portions of the ova of *Asterias glacialis*, showing changes affecting the germinal vesicle at the beginning of maturation (Hertwig): a, germinal vesicle; b, germinal spot, composed of nuclein and paranuclein (c); d, nuclear spindle in process of formation.

such a position that each of its apices points toward a pole-corpuscle.

The outer extremity of the nuclear spindle, being made to protrude by the continued onward movement of the nucleus, becomes detached (Fig. 11); this separated piece, with the

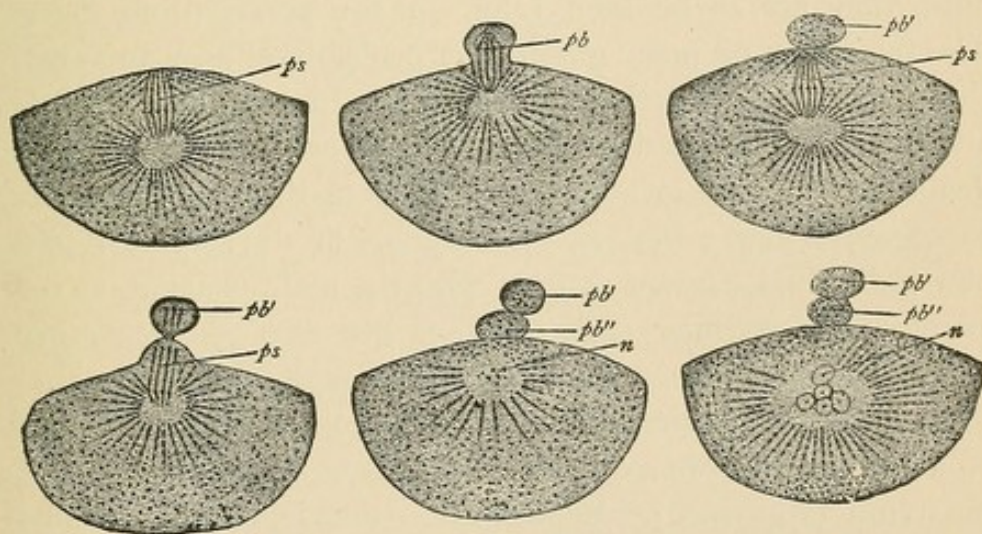


FIG. 11.—Formation of the polar bodies in the ova of *Asterias glacialis* (Hertwig): ps, polar spindle; pb, first polar body; pb', second polar body; n, nucleus returning to condition of rest.

small surrounding constricted-off mass of protoplasm, constitutes the **first polar body**. From the remnant of the first nuclear spindle, a second one is formed, which in the same manner extrudes the **second polar body**. What remains of the nucleus now moves toward the center of the cell and

temporarily disappears, soon to reappear as the **female pronucleus**. The position of the female pronucleus is nearly or absolutely central. The protoplasm surrounding it is radially striated (Fig. 12). The egg is now ready for fertilization.

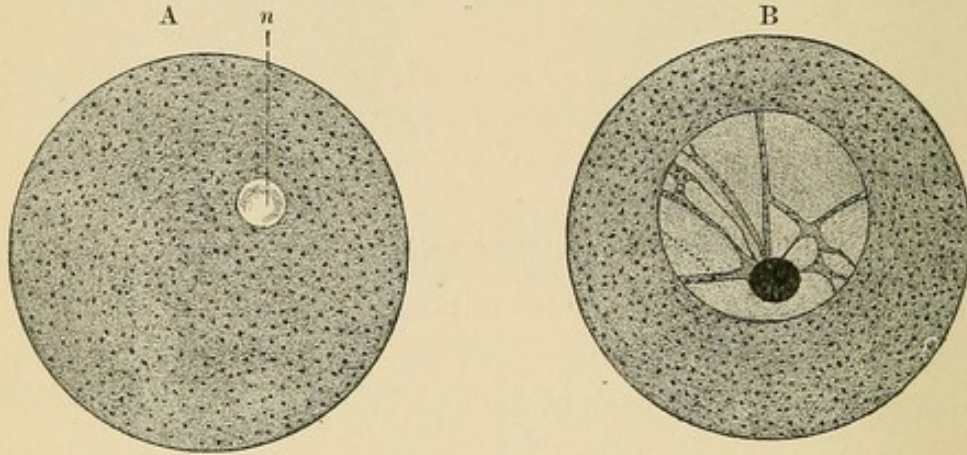


FIG. 12.—A, mature ovum of echinus; *n*, female pronucleus; B, immature ovarian ovum of echinus (Hertwig).

The fate of the polar bodies is undetermined. For some time after their extrusion, and pending their final disappearance, they are to be seen lying in the perivitelline space. The formation of polar globules is probably almost universal throughout the animal world, although in reptiles and birds and in some fishes and amphibians they have not as yet been demonstrated. It is of interest to note that in some **parthenogenetic eggs**—that is, eggs capable of developing into a new individual without contact with the male element, as for example the summer eggs of plant lice and of some other arthropods—only one polar globule is said to be formed.

One of the theories advanced to explain the phenomenon of maturation is that of Minot. This theory assumes that the ovum is at first hermaphroditic—that is, that it contains both male and female elements, and that the extrusion of the polar bodies is a casting-off of the male element. Hertwig and others believe, however, that the formation of the polar bodies is an abortive cell-division, the bodies being aborted cells.

### OVULATION.

Extrusion of the ovum from the Graafian follicle, or **ovulation**, occurs upon the completion of the process of maturation.

tion. As the time for this event approaches, the wall of the follicle at the site of the stigma becomes much thinned and finally ruptures, and the ovum passes into the Fallopian tube (Fig. 13). If, instead of passing into the tube, the

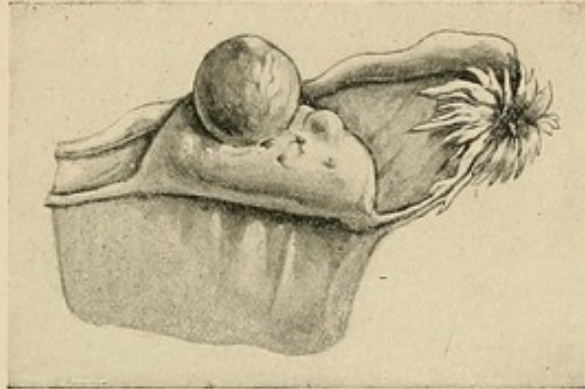

FIG. 13.—Ovary with mature Graafian follicle about ready to burst (Ribemont-Dessaignes).

ovum maintains its connection with the ovary and is fertilized there, it may undergo partial development *in situ*; such a condition constitutes one variety of **extra-uterine pregnancy** or **ectopic gestation**.

Ova are extruded from the ovary, one or more at a time, at regular, generally monthly, intervals, from puberty to the climacteric.

After the escape of the ovum, hemorrhage into the empty follicle occurs, the resulting clot being the **corpus hemorrhagicum**. According to Leopold, if rupture occurs during the intermenstrual period instead of at the time of menstruation, hemorrhage will be small or entirely wanting, the resulting corpus luteum being called then *atypical*, to distinguish it from the *typical* body formed in the ordinary manner.

The blood-clot is soon permeated by cells originating in the wall of the follicle, some of which are fusiform connective-tissue cells, while others are large cells containing the yellow pigment, lutein. Meanwhile, the follicular wall thickens and becomes plicated. Later, upon the replacement of the mass of clot and cells by fibrous tissue and the development of capillaries within it, the body assumes a yellowish cicatricial appearance and is known as the **corpus luteum**. (Fig. 14). The color of the corpus varies considerably in

different species of animals, the yellow color being characteristic for the human subject.

If the ovum is not fertilized, the corpus luteum attains its maximum development in less than a week and begins to shrink at about the twelfth day, becoming completely absorbed in a few weeks. If fertilization occurs, it continues to grow for two or three months and acquires a size one-fourth or one-third that of the entire ovary; persisting till

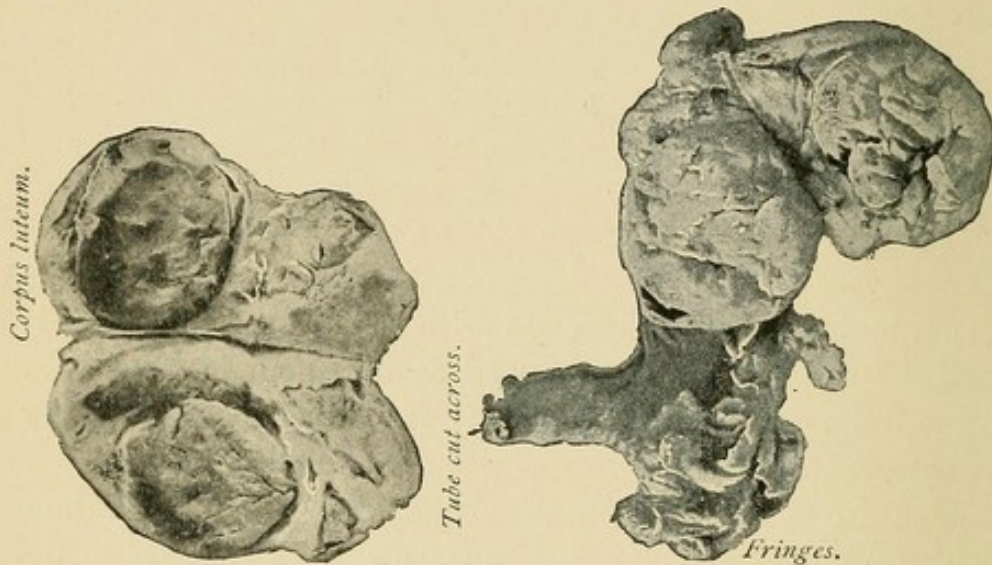


FIG. 14.—Ovaries of two virgins, showing large corpora lutea, resembling those of pregnancy (Hirst).

toward the end of gestation, it finally shrinks to a small white scar, which may not totally disappear until a month or more after labor.

It has been customary to designate the larger, better developed yellow body, the **true corpus luteum**, or the **corpus luteum of pregnancy**, in contradistinction to the so-called **false corpus luteum of menstruation**, and to regard the presence of the former as absolute proof of previous impregnation. This view is no longer tenable, since bodies identical in appearance with true corpora lutea have been found in virgin ovaries (Hirst).

The relation of ovulation to the menstrual function has been much discussed. While the two processes usually occur at the same time, they are not to be regarded as dependent one upon the other. It has been shown by Coste, whose

observations have been confirmed by Leopold, that as a rule Graafian follicles burst during menstruation, though they may rupture before or after this event. It has also been shown that in the rabbit sexual intercourse hastens the rupture of the follicle.

### MENSTRUATION.

Menstruation, or the catamenial flow, is considered here because of its natural association with the function of ovulation.

**Menstruation** may be defined as a periodical discharge of blood and disintegrated epithelium and other structural elements of the mucous membrane of the body of the uterus, mixed with mucus from the uterine glands and the vagina, occurring normally about every twenty-eight days, and associated with more or less disturbance of the entire sexual system. The inauguration of the function marks the **age of puberty**, the beginning of the sexual life of woman; its cessation, known as the **climacteric**, or **menopause**, indicates the termination of the child-bearing period.

In temperate climates, the menses are established between the thirteenth and seventeenth years and cease between the ages of forty and fifty. In the tropics, they appear somewhat earlier; in cold climates, somewhat later. The function is suspended during pregnancy and, usually, during lactation.

The quantity of the discharge, though subject to considerable variation, is usually from 4 to 6 fluidounces. The blood is venous in character, and, owing to admixture of alkaline mucus, does not coagulate unless present in excessive amount.

The **menstrual cycle** of twenty-eight days may be divided into four periods: the **constructive stage**, comprising from five to seven days; the **destructive stage**, lasting about five days; the **stage of repair**, covering a period of three or four days; and the **stage of quiescence**, including the remaining twelve to fourteen days.

In the **constructive stage**, which occupies the six to seven days preceding the discharge, the mucous membrane of the

uterus becomes markedly swollen, the normal thickness of from 1 to 2 millimeters being more than doubled. The uterine glands become wider and longer and also more branched. The blood-vessels, especially the capillaries and veins, undergo great increase in size, and the connective-tissue cells are increased in number. The thickened mucous membrane resulting from these alterations is the **decidua menstrualis**. The term "constructive" is applied to this series of changes for the reason that their apparent purpose is the preparation of the womb for the reception of a fertilized ovum.

The **destructive stage**, corresponding to menstruation proper, lasts from three to five days. It consists essentially in the partial destruction of the hypertrophied mucous membrane, the **menstrual decidua**, accompanied by hemorrhage. The initial step is the infiltration of blood into the subepithelial tissue; according to Overlach, this takes place, not by rupture of capillaries, but by diapedesis. In a day or two the superficial layers of the mucous membrane disintegrate and are cast off, those portions of the enlarged uterine glands included within this stratum sharing the same fate. By the loss of the epithelium and the subjacent strata, the blood-vessels are exposed. Subsequently these rupture, giving rise to the characteristic hemorrhage. Fatty degeneration accompanies the death of the cast-off tissue, and was thought by Kundrat and Engelman to be the direct cause of the hemorrhage; it is probable, however, that fatty degeneration is not present until after the flow of blood has begun.<sup>1</sup>

The **stage of repair**, comprising the three or four days following the period of the discharge, witnesses the return of the uterine mucosa to its usual condition. With the gradual subsidence of the swelling, the superficial layers, which were lost, are replaced by the growth of new tissue from the deeper layers, which persisted. The formation of the new epithelium begins at the mouths of the uterine glands.

The **stage of quiescence** extends from the close of the pre-

<sup>1</sup> Marshall's "Vertebrate Embryology;" Minot's "Human Embryology."

ceding stage to the end of the cycle, or, in other words, to the beginning of the next constructive stage.

Other parts of the sexual apparatus, including the ovaries, the Fallopian tubes, and the mammary glands, show more or less sympathy with the uterus during menstruation, the changes in them consisting chiefly in swelling, hyperemia, and tenderness.

**The Relation of Menstruation to Ovulation and Conception.**—The function of menstruation and the extrusion of ova from the Graafian follicles, though closely associated, are not dependent upon each other. Ovulation occurs perhaps most commonly during the time of the menstrual discharge, but it may take place before or after this event. While it is now generally accepted that the two functions are not mutually interdependent in the sense that one is a necessary part of the other, yet, since the turgescence incident to sexual intercourse has been shown to hasten the rupture of the follicles, it seems reasonable to suppose that the ovarian hyperemia attendant upon the menstrual epoch would exert a like influence.

Since the function of menstruation is normally suspended during pregnancy, the relation between menstruation and ovulation, and of these to conception, are of practical interest in determining the date of labor. The duration of pregnancy is from 270 to 280 days, nine calendar, or ten lunar, months, and it dates from the moment of conception. But since the ovum retains its vitality for about a week after its extrusion from the Graafian follicle, and since the activity of the spermatozoa may continue for several weeks after their entrance into the female genital tract, it is impossible to fix accurately the date of conception even in those cases in which there has been but one coitus. It is now believed by most embryologists that the ovum is fertilizable only while it is in the Fallopian tube, a period probably of about seven days; if this be true, it follows that conception must occur within a week after ovulation, although it may be effected as late as two weeks after coitus. Since the ovum is usually discharged from the ovary during the menstrual period, it is evident that

the time most favorable for conception is the week following menstruation; and inasmuch as the latter function is suspended during pregnancy, it is obvious that the most reliable basis for calculating the probable date of conception is the last menstruation. The method usually employed is to count nine months and seven days from the first day of the last menstruation. After what has been said it is perhaps needless to remind the reader that this can furnish only approximately the date of labor. In a case where conception occurred a few days prior to the first omitted period, there would be a discrepancy of several weeks between the actual, and the calculated, termination of pregnancy.

#### FERTILIZATION.

**Fertilization** is that peculiar union of spermatozoon and egg-cell which initiates the phenomena resulting in the formation of a new individual. As implied in a preceding section, impregnation is possible in the higher organisms only after the completion of maturation, while in others, as for example the maw-worm of the horse, spermatozoa enter the ovum before the extrusion of the polar bodies, and thus one process overlaps the other.

The more primitive method of fertilization is that effected without copulation of the parent organisms, or **external fertilization**; this occurs in osseous fishes, in some amphibians, and in many invertebrates. In these groups, both ova and semen are discharged into the water and there meet. In frogs, however, there is a quasi-copulation, the male embracing the female during the breeding season and depositing semen upon the eggs as they are evacuated. In all higher animals, **internal fertilization** occurs, this being effected by sexual congress.

In man, fertilization normally occurs in the outer third of the Fallopian tube. The semen having been deposited in the vagina, or the uterus, or even upon the vulva, the spermatazoa make their way into the oviduct by the vibratile motion of their tails. Meeting the ovum, they swarm around it, and some of them pass through the zona pellucida into

the perivitelline space. It is believed by many investigators that the canals of the zona constitute the avenues of entrance for the spermatozoa. In the rather firm egg-envelopes of insects and some fishes, there is a small aperture, the **micro-pyle**, through which the spermatozoa gain entrance.

While many spermatozoa may pass through the zona, *only one*—that one whose head first impinges against the vitelline membrane—enters the ovum. Why others do not or cannot enter is unknown; possibly because the egg's power of attraction is annulled (Minot). **Polyspermia**, or the penetration of several spermatozoa, may occur, however, if the ovum is unhealthy; and in some lower types it is said to be normal.

As the spermatozoon is about to strike the vitelline membrane, the protoplasm swells up at the point of contact into the **receptive prominence** (Fig. 15). Through this the sper-

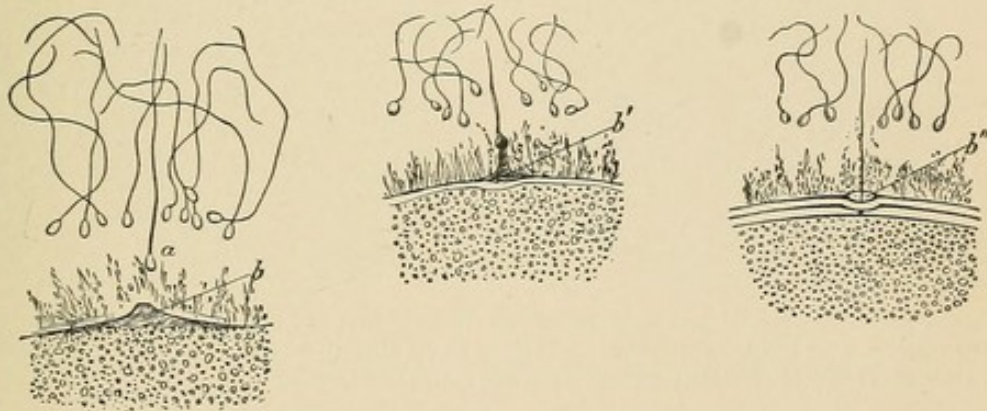


FIG. 15.—Portions of the ova of *Asterias glacialis*, showing the approach and fusion of the spermatozoon with the ovum (Hertwig): *a*, fertilizing male element; *b*, elevation of protoplasm of egg; *b'*, *b''*, stages of fusion of the head of the spermatozoon with the ovum.

matozoon bores its way, losing its tail in the process, and thus becoming the **male pronucleus**. The female pronucleus, it will be remembered, lies in or near the center of the egg. The two pronuclei now approach each other, and, upon meeting, fuse and temporarily disappear. Soon they reappear, and now constitute the **segmentation-nucleus** or **cleavage-nucleus** (Fig. 16).

Since the spermatozoon is the metamorphosed nucleus of a cell formed in the testicle, and since the female pronucleus is a part of the nucleus of the ovum, it follows that the seg-

mentation-nucleus consists of chromatin substance derived from each parent. As this fact has been thought to explain, anatomically, the offspring's inheritance of both paternal and

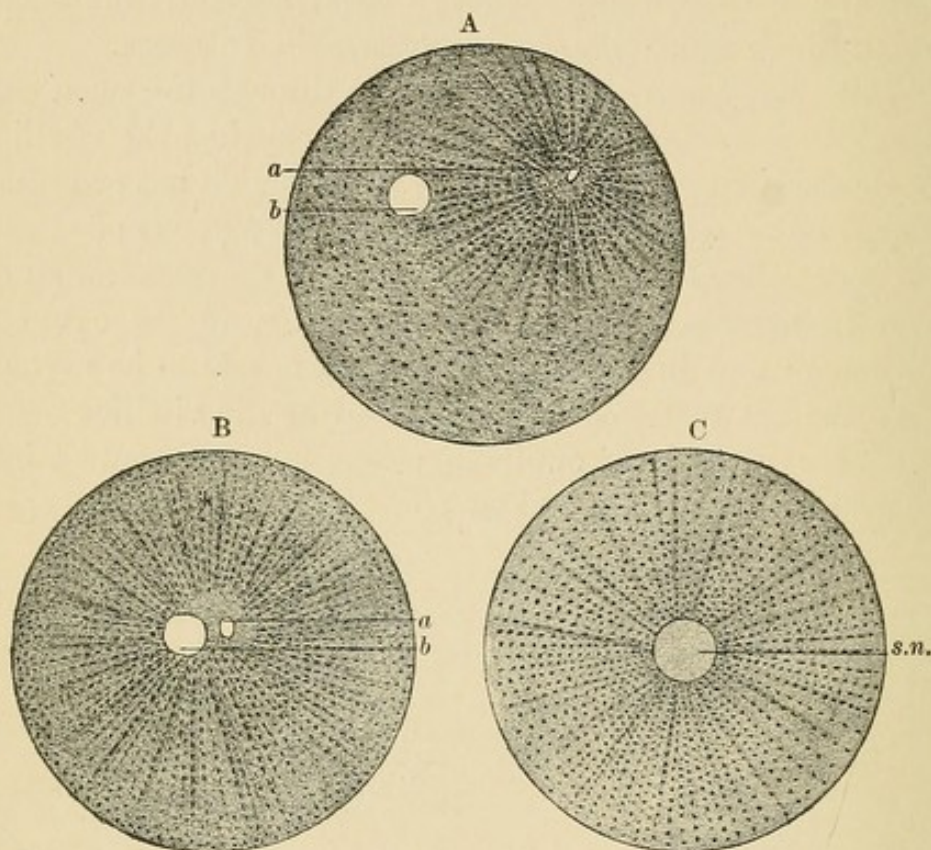


FIG. 16.—A, fertilized ovum of echinus (Hertwig): the male (*a*) and the female pronucleus (*b*) are approaching; in B they have almost fused; C, ovum of echinus after completion of fertilization (Hertwig): *s.n.*, segmentation-nucleus.

maternal characteristics, it has been made the basis of a theory of heredity formulated by Hertwig and independently advanced by Strasburger.

**Artificial fertilization**, or the bringing about of the development of the ovum by artificial (chemical) means, without the participation of the male element, has been recently experimentally effected with the eggs of the sea-urchin by Loeb, of Chicago. These eggs, when first immersed for about two hours in a mixture of sea-water and a weak solution of magnesium chlorid, and then transferred to normal sea-water, were found to undergo complete and normal development, producing perfect larvæ. This artificially induced development differed from that of the ordinary method only in being slower.

## CHAPTER II.

### THE SEGMENTATION OF THE OVUM AND FORMATION OF THE BLASTODERMIC VESICLE.

WHILE the fertilized ovum is passing along the Fallopian tube to the uterus—a journey believed to require seven or eight days in man<sup>1</sup>—it undergoes repeated segmentation, or cleavage, becoming a more or less globular mass of cells or blastomeres. This mass is the **mulberry-mass** or **morula**.

The details of the process of division correspond closely to those of ordinary indirect cell-division, or karyokinesis. The first indication of approaching cleavage is seen in the segmentation-nucleus, just as, in other cells, the sequence of changes leading to cell-division is inaugurated in the nucleus.

The achromatin-substance of the segmentation-nucleus forms a **nuclear spindle** in the ordinary manner, with a **centrosome** or **pole-corpuscle** at each apex. The centrosome is surrounded by the **polar striation** or attraction-sphere. After the usual preliminary changes, the chromatin-substance assumes the form of V-shaped loops arranged around the equator of the spindle in such a manner as to produce the **wreath** or **aster**. Each chromatin loop splits longitudinally, and the resulting halves of each move to opposite poles of the spindle, where they become grouped about the pole-corpuscle to constitute the **daughter-wreaths** of the new nuclei. The vitellus now begins to divide, the first step being the formation of an encircling groove on its surface; this groove deepens more and more until finally division of the cell is complete. In like manner, each daughter-cell divides into two, and each of these two into other two, the cell-division continuing until there results the mass of cells, or morula, already mentioned (Plate I, Fig. 1).

These processes have been followed the most accurately in

<sup>1</sup> Recent investigations by Peters, of Vienna, upon an ovum of three or four days, already embedded in the uterine mucosa, would indicate that less time than this is occupied in traversing the oviduct.

the egg of the sea-urchin; in reptilian eggs, as well as in those of the rabbit and other mammals, they have been studied also and have been found to agree with the former in all essential respects. Certain modifications dependent upon the relations and proportions of formative-yolk and food-yolk will be pointed out hereafter.

While no one has seen the segmentation of the human ovum, there is no reason to suppose that it differs materially from that of other mammals.

An interesting and probably significant modification of the method of cleavage as just described has been observed by Van Beneden in the ova of the maw-worm of the horse. In this case male and female pronuclei do not fuse but merely lie close together. At the beginning of segmentation, the chromatin of each pronucleus assumes the form of a convoluted thread, which divides transversely into two sister-threads. In this manner are produced four loops of chromatin, which become grouped around the equator of the nuclear spindle just formed, and each one of which then splits longitudinally into two threads. In the migration of the segments that now ensues, each pair of sister-threads separates, one thread going to one pole of the spindle, one to the other. Hence, at each pole, and taking part, therefore, in the formation of each new nucleus, are two male and two female threads of chromatin. Thus the male and female pronuclei contribute equal shares of chromatin to each daughter-nucleus.

Very suggestive in this connection is the observation of Nussbaum, that if the same principle should be found to apply to all subsequent cell-division, then every cell of the adult organism would consist of equal amounts of material from each parent.

**Cleavage-planes.**—The direction of the planes of cleavage is determined by certain laws. The direction of the plane of the first cleavage bears a definite relation to the long axis of the nuclear spindle, whose position, in turn, depends upon the manner of distribution of the egg's protoplasm, its direction coinciding with the longest diameter of an oval egg, but lying in any diameter of a spherical one.

The first cleavage-plane always cuts the axis of the nuclear spindle perpendicularly at its center; the second bisects the first, also perpendicularly; and the third is perpendicular to the two others, and passes through the middle of their axis of intersection.

**Kinds of Cleavage.**—The mode of cleavage of the ovum is influenced by the relation of the protoplasm and the deutoplasm to each other, and by their relative proportions. The classification of ova according to their method of cleavage is as follows:

1. **Holoblastic ova** are those in which segmentation is total—that is, the entire ovum undergoes division. If the resulting cells are of equal size, there is said to be

(a) **Total equal cleavage**; to this class belong the alecithal ova of mammals (Fig. 4) and of amphioxus, to the segmentation of which the above description may be said to apply. Strictly speaking, the cells are not of exactly equal size, those in the region of the vegetative pole of the egg being slightly larger than those at the animal pole. Contrasted with this is

(b) The **total unequal cleavage** of amphibian ova, whose segments are of unequal size (Fig. 17). These eggs being

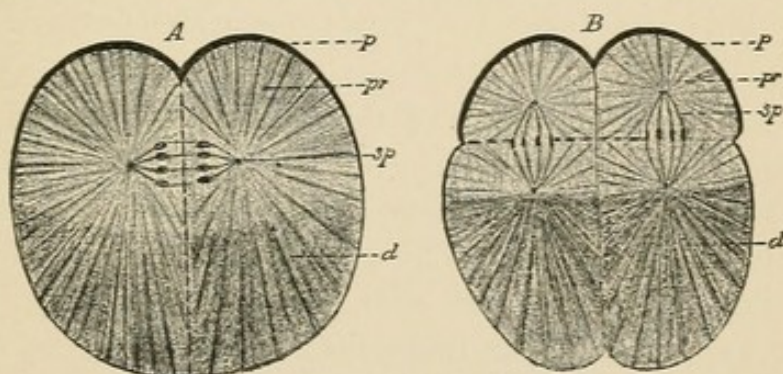


FIG. 17.—Diagram of the division of the frog's egg: A, stage of the first division. B, stage of the second division. The four segments of the second stage of division are beginning to be divided by an equatorial furrow into eight segments; *p*, pigmented surface of the egg at the animal pole; *pr*, the part of the egg which is richer in protoplasm; *d*, the part which is richer in deutoplasm; *sp*, nuclear spindle (Hertwig).

telolecithal, the lighter protoplasmic animal pole is directed upward, while the deutoplasmic vegetative pole is underneath. The inequality of the resulting segments, as well as

the direction of the cleavage planes, may be appreciated by reference to Fig. 17, which represents a frog's ovum.

2. **Meroblastic ova** are those in which the segmentation is partial, division being limited to the formative yolk, or protoplasm.

(a) **Partial discoidal cleavage** is the variety of meroblastic cleavage that occurs in those telolecithal ova having a germ-disk (Fig. 7), to which latter the segmentation is limited. This method of segmentation is seen in the eggs of birds, reptiles, and fishes. In the egg of the bird, which may be taken as a typical example, the germ-disk, in whatever position the egg may be placed, floats on the top of the yolk. The beginning of the first segmentation is indicated by a furrow in the center of the surface of the germ-disk (Fig. 18). This furrow deepens, cutting vertically from the

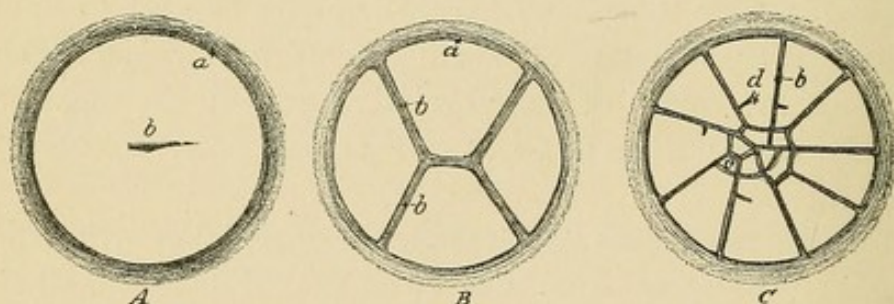


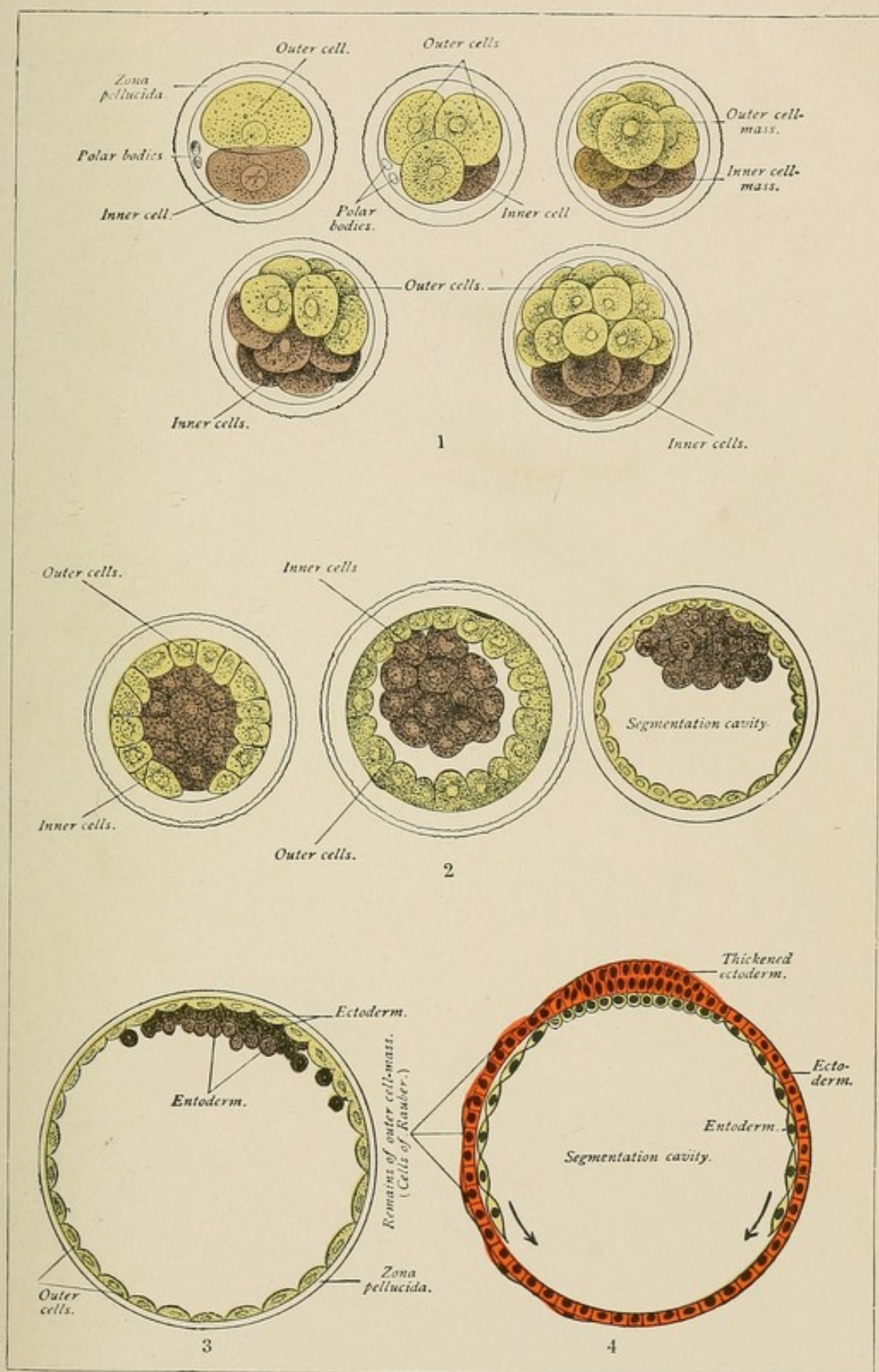
FIG. 18.—Surface view of the first stages of cleavage in the hen's egg (after Coste): *a*, border of the germ-disk; *b*, vertical furrow; *c*, small central segment; *d*, large peripheral segment.

upper to the lower surface of the germ-disk, dividing it into two equal parts. Another groove, crossing the first at a right angle, bisects each of the two segments, and each of these is in turn bisected by a radial furrow, so that the germ-disk now consists of eight sector-shaped cells. Cross furrows, appearing near the center of the disk, cut off the apices of the sectors, adding small central segments. Cell-division continues until the germ-disk consists of a flattened mass of cells, several strata thick, lying on the surface of the yolk.


The second method of meroblastic segmentation is

(b) **Peripheral cleavage**, which occurs in the centrolecithal ova of arthropods (Fig. 6). In these eggs, it will be remem-

PLATE I.



1, 2, 3. Diagrams illustrating the segmentation of the mammalian ovum (Allen Thomson, after van Beneden). 4. Diagram illustrating the relation of the primary layers of the blastoderm, the segmentation-cavity of this stage corresponding with the archenteron of amphioxus (Bonnet).



bered, the nutritive-yolk is centrally placed and is surrounded by the formative-yolk. The segmentation-nucleus lies in the center of the nutritive-yolk, and in this position undergoes division and subdivision. The new nuclei now migrate into the peripherally placed formative-yolk, when the latter divides into as many parts as there are nuclei, and thus the central unsegmented nutritive-yolk becomes enclosed in a sac composed of small cells.

#### THE STAGE OF THE BLASTULA.

Very soon there appears in the interior of the morula or mulberry mass referred to above, a little fissure-like space, called the **cleavage-cavity** or **segmentation-cavity**. When this space has increased somewhat in size, the germ is said to have reached the **blastula stage**, or the stage of the blastodermic vesicle (Plate I., Fig. 2).

What may perhaps be regarded as the primitive form of the blastula is that of the lancelet, or amphioxus lanceolatus, one of the lowest vertebrates, a fish-like animal several inches in length inhabiting the Mediterranean Sea. The blastula in this case is a simple sac composed of cells which surround the cleavage-cavity as a single layer (Fig. 21, A). The cells in the region of the vegetative pole are larger and more turbid, because more deutoplasmic, than those at the animal pole, as shown in the same figure.

The **mammalian blastula** is a hollow sphere, whose wall is a layer of cells, the **outer cell-mass**, and into whose central space, the **cleavage-cavity**, projects an irregular mass of granular cells constituting the **inner cell-mass** (Plate I., Fig. 2). The cleavage-cavity contains an albuminous fluid. It is during this stage that the germ, in the case of mammals, reaches the uterus. As a peculiarity of the mammalian ovum, the blastula now increases greatly in size, the cleavage-cavity becoming dilated. The zona pellucida, which still surrounds the ovum, is by this time quite attenuated, and is called the **prochorion**. The outer cell-mass, likewise much thinned-out, constitutes **Rauber's layer** (Plate I., Fig. 4). The significance of the cells of Rauber's layer is un-

known. After a time they disappear, probably by disintegration (Kölliker). The form of the blastula of amphibians and of the Sauropsida (birds and reptiles) is greatly modified by the relatively abundant nutritive yolk with which their

ova are endowed. An amphibian ovum in the blastula stage is shown in Fig. 19. It will be seen that its walls consist of several layers of cells, and the cleavage-cavity is encroached upon to a considerable extent by the large and abundant cells of the vegetative pole, which are especially rich in deutoplasm. In the eggs of birds and rep-

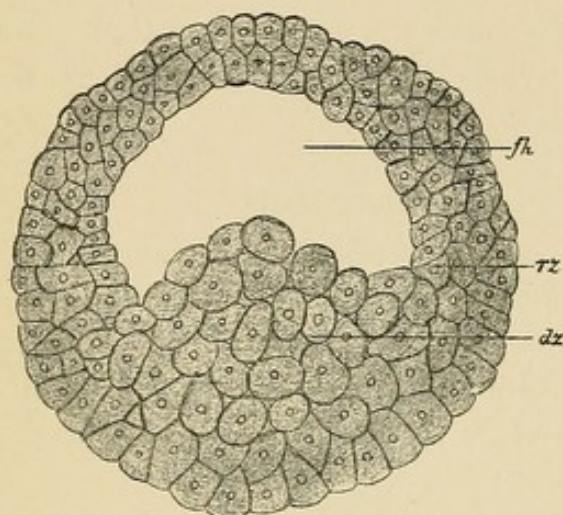


FIG. 19.—Blastula of triton tæniatus: *fh*, segmentation-cavity; *rz*, marginal zone; *dz*, cells with abundant yolk (Hertwig).

tiles—that is, in the telolecithal eggs that undergo partial discoidal segmentation—the blastula form is so markedly modified as to be scarcely recognizable. In this case, as shown in Fig. 20, the cleavage-cavity is a narrow fissure

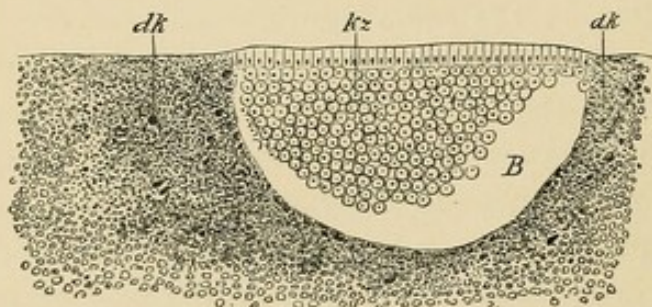


FIG. 20.—Median section through a germ-disk of pristurus in the blastula stage (after Rückert): *B*, cavity of the blastula; *kz*, segmented germ; *dk*, finely granular yolk with yolk-nuclei.

whose roof is the germ-disk, and whose floor is the unsegmented nutritive-yolk, which latter corresponds therefore to the large vegetative cells forming the floor of the amphibian egg shown in Fig. 19.

## CHAPTER III.

### THE GERM-LAYERS AND THE PRIMITIVE STREAK.

#### THE STAGE OF THE GASTRULA.

By the conversion of the one-layered germ, the **blastula**, into the germ with two layers, the **gastrula stage** is attained. The gastrula, in its typical form, consists of two layers of cells surrounding a central cavity, which latter communicates with the exterior by means of a small aperture, the **blastopore**. The cavity is the **archenteron** or **cœlenteron** or **intestino-body cavity**. The outer layer of cells is the **ectoderm** or **epiblast**; the inner layer is the **entoderm** or **hypoblast**. This form of the germ is seen in holoblastic invertebrate, as well as in some vertebrate ova, and is typically exemplified in the development of the amphioxus. The blastula of this animal is a simple sac, the wall of which is a single layer of epithelial cells surrounding the cleavage-cavity (Fig. 21, *A*). By a pushing-in of the vegetative cells, the cleavage-cavity is encroached upon and finally is completely obliterated, being replaced by the archenteron (Fig. 21, *C*). From this it is obvious that gastrulation occurs here by a simple process of invagination. In ova with a large amount of food-yolk, as in those of frogs, birds, and fishes, the process is modified and complicated by this condition.

According to the so-called gastrula theory of Haeckel, all metazoa—that is, multicellular animals as distinguished from protozoa, or unicellular organisms—pass through a typical gastrula stage in the course of their development.

It has been held as a general principle that the higher animals during their development repeat, to a greater or less extent, the embryonic or the larval forms of the lower members of the group to which they belong. Huxley has pointed out the morphological identity of the adult form of the cœlen-

terata with the two-layered gastrula. This principle is one of importance as applying to the developmental history of the various organs.

It must not be understood, however, that we find in mammals such a gastrula as that of amphioxus; some embryologists, indeed, do not employ the term gastrula in connection

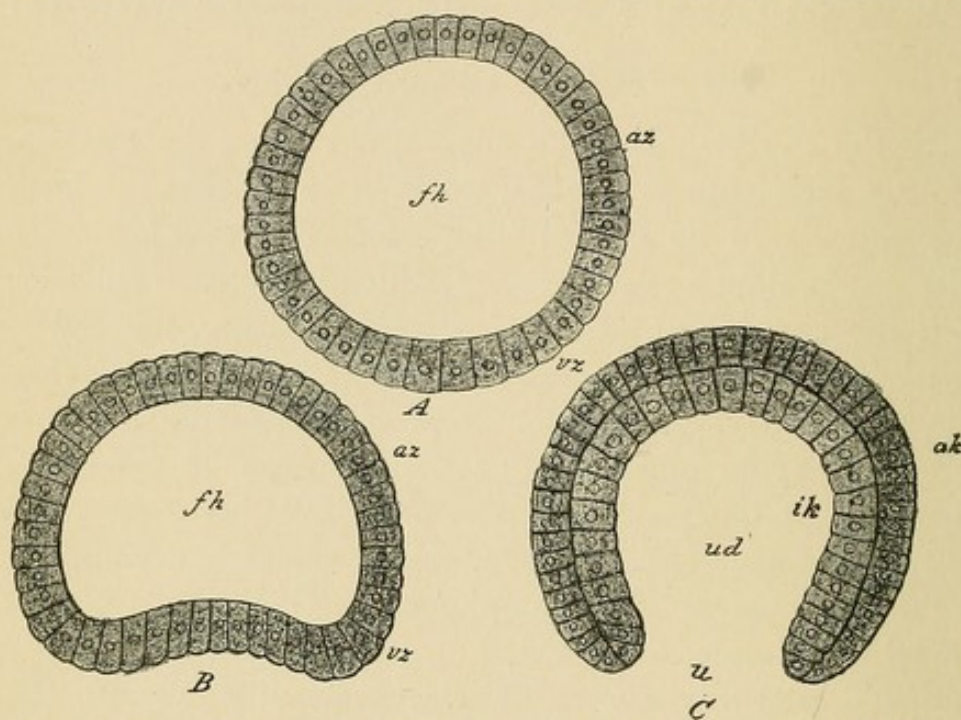


FIG. 21.—Gastrulation of amphioxus (modified from Hatschek). A. Blastula: *az*, animal cells; *vz*, vegetative cells; *fh*, cleavage-cavity. B. Beginning invagination of vegetative pole. C. Gastrula stage, the invagination of the vegetative cells being complete: *ak*, outer germ-layer; *ik*, inner germ-layer; *ud*, archenteron; *u*, blastopore.

with mammalian development, but call the germ a blastodermic vesicle even after it has become two-layered.

The mammalian "gastrula" (Plate I., Fig. 4) is a vesicle whose wall, for the most part, is a single layer of flattened cells, known as Rauber's layer; this layer has been referred to above as the attenuated outer cell-mass of the blastula. Throughout a limited area, the germ-wall is composed of two other layers of cells in addition to the layer of Rauber. The inner of these layers, composed of flattened cells, is the **entoderm**; the outer, lying next to Rauber's layer, and consisting of cubical cells, is the **ectoderm**. At a later stage both layers take part in the formation of the entire wall of the vesicle.

The ectoderm and the entoderm are produced from the inner cell-plate of the blastula. This mass gradually flattens, becoming at first lens-shaped; spreading out peripherally on the inner surface of Rauber's layer, it is at length differentiated into the two primary germ-layers, the ectoderm and the entoderm.

The cavity of the vesicle is the **archenteron**, or **cœlenteron**. As previously stated, the process of gastrulation and the form of the gastrula are modified in the case of ova possessing a large proportion of deutoplasm. In the case of the frog, for example, as well as in other amphibians, the blastula has the form shown in Fig. 19. By an invagination of the blastula-wall at the place of transition from the animal cells to the vegetative cells, all of the latter and a part of the former are carried into the interior of the blastula to form the lining of the archenteron (Fig. 22). Compare this with the amphi-

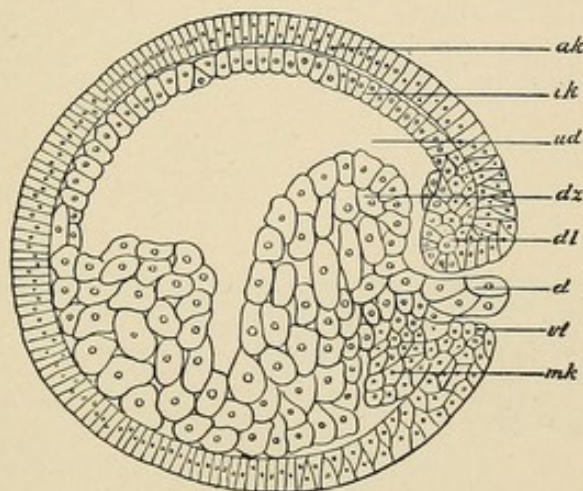


FIG. 22.—Sagittal section through an egg of triton (after the end of gastrulation): *ak*, outer germ-layer; *ik*, inner germ-layer; *dz*, yolk-cells; *dl* and *vl*, dorsal and ventral lips of the cœlenteron; *ud*, cœlenteron; *d*, vitelline plug; *mk*, middle germ-layer (Hertwig).

oxus gastrula as shown in Fig. 21. In the bird's egg, the form of whose gastrula is shown in Fig. 23, an infolding or invagination occurs, as in the frog's egg, at the place of transition from the animal cells to the vegetative cells, or, in other words, at the margin of the germ-disk. The gastrula thus formed is represented in Fig. 23. Its archenteron is a

narrow fissure, and its blastopore, situated at the posterior margin of the germ-disk, is exceedingly small.

**The Embryonal Area.**—Upon the surface of the germ at the beginning of gastrulation—that is, at about the fifth day of development in the case of the rabbit's germ—there is

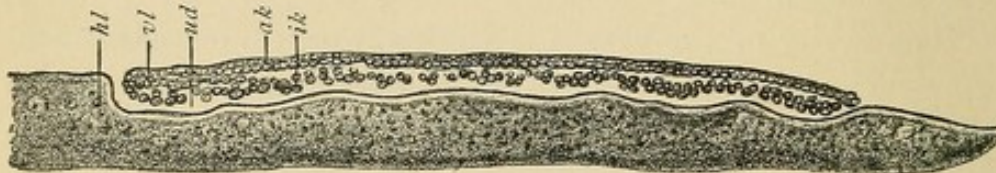


FIG. 23.—Longitudinal section through the germ-disk of a fertilized unincubated egg of the nightingale (after Duval): *ak*, outer, *ik*, inner germ-layer; *ud*, coelenteron; *vl*, anterior, *hl*, posterior lip of the blastopore (crescentic groove).

a round whitish spot, the embryonal area. Its position corresponds to that formerly held by the inner cell-plate of the blastula, as shown in Plate I., Fig. 2. It is only in this region that the wall of the vesicle is, at this particular stage, composed of more than a single layer of cells, the ectoderm and the entoderm not extending much, if at all, beyond its periphery.

The embryonal area, soon becoming oval (Fig. 24) and, later, pear-shaped, exhibits, at its posterior margin, a trans-

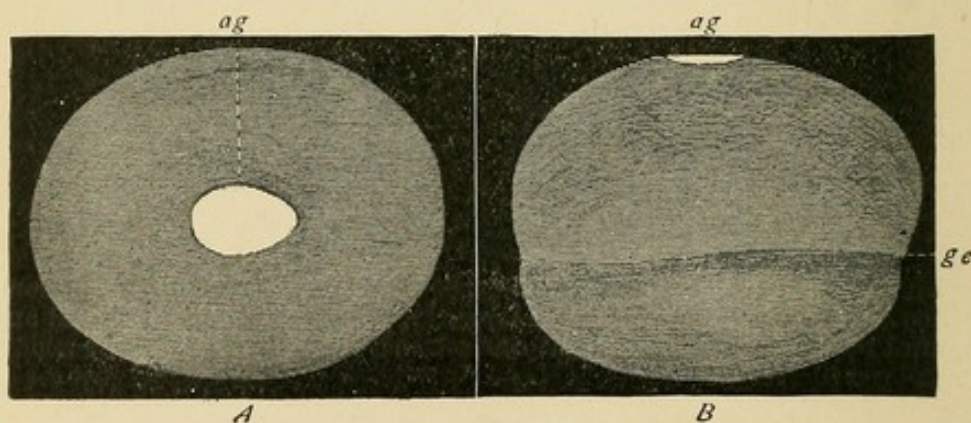


FIG. 24.—Blastula of the rabbit seven days old without the outer egg-membranes. Length 4.4 mm. (after Kölliker). Magnified ten diameters. Seen in *A* from above, in *B* from the side: *ag*, embryonic spot (area embryonalis); *ge*, the line up to which the blastula is two-layered.

verse thickening called the **terminal ridge**, which is believed to be the anterior lip of the blastopore. It may be not amiss to say that the terms anterior and posterior are used with

reference to the future body, the narrow end of the area embryonalis corresponding to the posterior pole or caudal extremity of the fetus.

In the chick's egg, the embryonic area (Fig. 25), or embryonic shield, appears while the egg is yet in the oviduct.

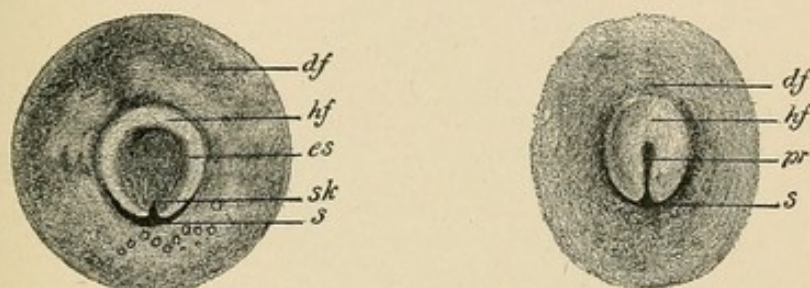


FIG. 25.—Two germ-disks of hen's egg in the first hours of incubation (after Koller): *df*, area opaca; *hf*, area pellucida; *s*, crescent; *sk*, crescent-knob; *es*, embryonic shield; *pr*, primitive groove.

Its **embryonic crescent** corresponds to the mamalian terminal ridge. Segmentation being limited to the germ-disk in the chick's egg, the resulting blastoderm, which is not a vesicle, but a flattened mass (Fig. 23) composed of several layers of cells, rests by its margin upon the partially liquefied yolk. The central region of the blastoderm, which overlies the liquefied portion of the yolk, from its translucence is known as the **area pellucida** (Fig. 25), while the dark opaque rim, resting upon the yolk is the **area opaca**. The inner rim of the area opaca is the **area vasculosa**. These regions are observed also in the mammalian egg.

*It is in the embryonal area alone* that the body of the embryo is developed; the other parts of the germ produce extra-embryonic structures, such as the amnion, the yolk-sac, etc.

Partial longitudinal division of the embryonic area during development results in the production of some form of **double monster**; its complete cleavage gives rise to **homologous** or **homogeneous twins**, which are twins of the same sex and of almost absolutely identical structure. Ordinary twins are developed from separate ova, which may or may not have come from the same ovary.

**The Primitive Streak.**—The **primitive streak** is a linear

median marking lying in the long axis of the embryonal area and containing a median furrow, the **primitive groove** (Fig. 26). A transverse section through the primitive streak

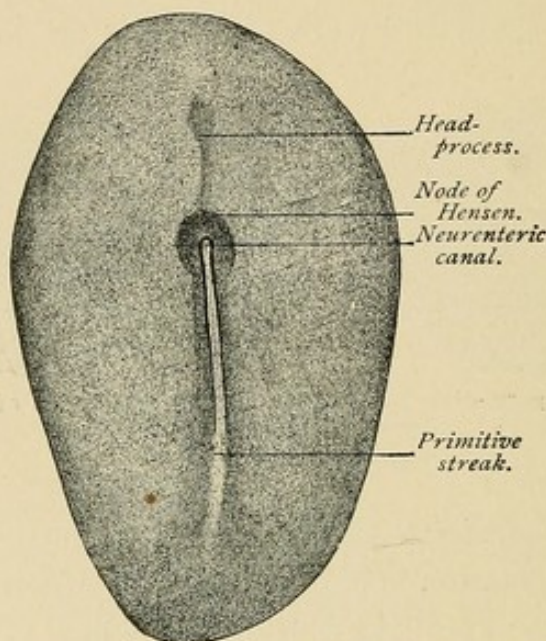


FIG. 26.—Embryonic area of rabbit-embryo (E. v. Beneden): primitive streak beginning in cell-proliferation known as the "node of Hensen."

(Figs. 27 and 28) shows that this surface-marking is produced by a thickening of the ectoderm along the median line, owing to a proliferation of cells from its under side. The length of the streak is about two-thirds of that of the embryonal area. In the rabbit's ovum it is seen at about the seventh day; in the human germ the time of its appear-

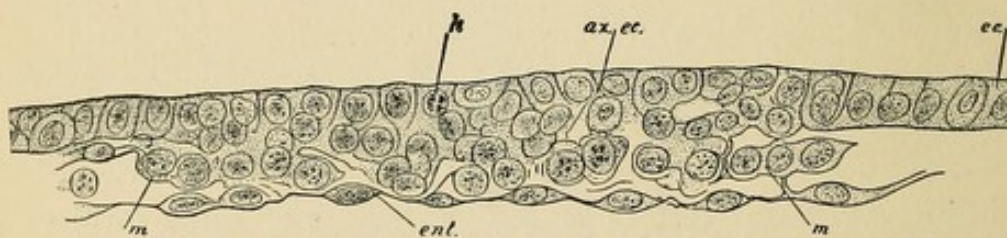


FIG. 27.—Section across the primitive streak of rabbit-embryo (Kölliker): *ec*, ectoderm; *ax. ec*, axial ectoderm undergoing proliferation, as shown by karyokinetic figures (*k*); *ent*, entoderm; *m*, mesoderm.

ance is not known, but is probably about the twelfth or thirteenth day. In the case of such a gastrula as that of the amphioxus (Fig. 21), the lips of the blastopore approach each

other and fuse in a line corresponding to the median longitudinal axis of the future embryonic area, the fusion or concrescence beginning at the anterior extremity of this line and proceeding toward its caudal end. The surface-marking produced by the apposition and partial union of the blastoporic lips was called the primitive streak, and its median furrow was known as the primitive groove, long before their true significance was appreciated. Since the edge of the blastopore marks the place of transition from the entoderm to the ectoderm (Fig. 21), the two germ-layers after the

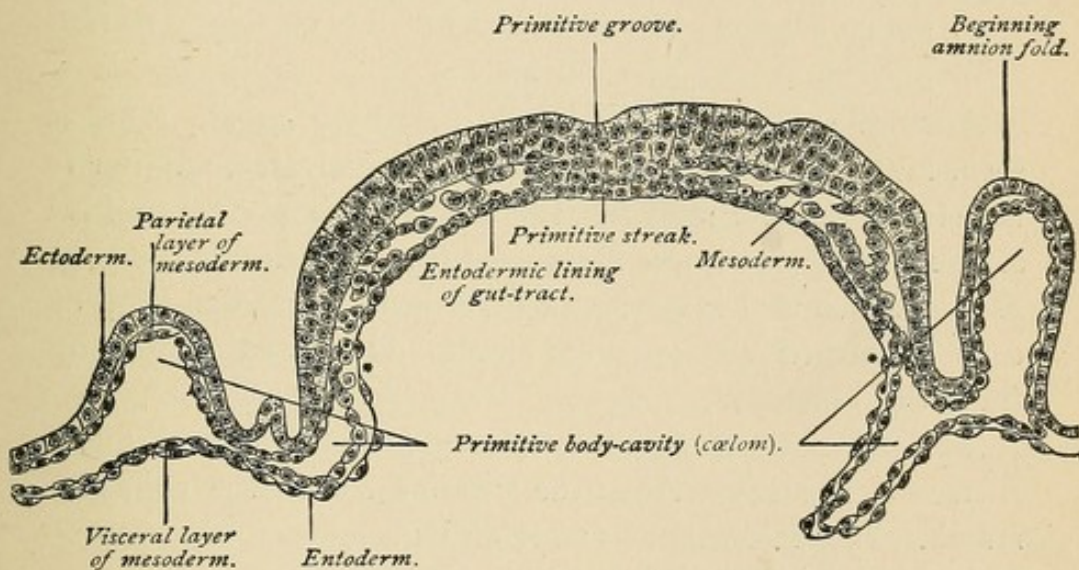


FIG. 28.—Transverse section of the embryonic area of a fourteen-and-a-half-day ovum of sheep (Bonnet).

union of the edges of this opening are in intimate association under the primitive streak, as shown in Fig. 28.

Morphologically the primitive streak of the higher vertebrates is regarded as the fused and extended blastopore of lower types. The terminal ridge of the mammalian embryonic area, as well as the crescent of the embryonic shield of avian and reptilian eggs, represents, as stated above, the anterior lip of the blastopore. Since the embryonal area is increasing in circumference while the lips of the blastopore are undergoing union or concrescence, the transversely directed terminal ridge, which lies at the posterior edge of the embryonal area, and which remains a fixed point, becomes a

longitudinal marking, and this marking or primitive streak comes to lie, therefore, behind the site of the blastopore. Reference to Duval's diagram (Fig. 29) will make this clear.

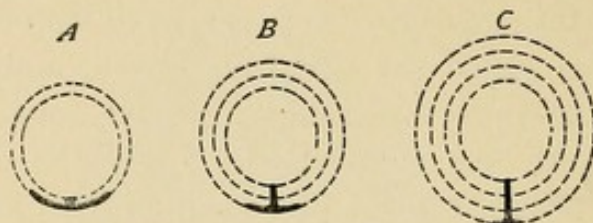


FIG. 29.—Diagram elucidating the formation of the primitive groove (after Duval). The increasing size of the germ-disk in the course of the development is indicated by dotted circular lines. The heavy lines represent the crescentic groove and the primitive groove which arises from it by the fusion of the edges of the crescent.

After the development of the primitive streak, there is seen, in the median line of the embryonal area, anterior to the streak, another marking, the **head-process** of the primitive streak. This is almost identical with the primitive axis of Minot, which that investigator describes as a median band of cells connected with the entoderm and extending forward from the blastopore.

**Hensen's node** is an accumulation of cells on the under surface of the ectoderm at the anterior end of the primitive streak. It is important because of its relation to the neurenteric canal, which will be described later.

Although the primitive streak and blastopore play no part in the later stages of development, it is worthy of note that the former lies in the line of the longitudinal axis of the future body, and that the position of the blastopore marks the posterior or caudal end of the embryo.

**The Development of the Mesoderm.**—The **mesoderm** or **mesoblast** is a structure composed of several layers of cells lying between the ectoderm and the entoderm. It is earliest formed in the vicinity of the front end of the primitive streak, the position formerly held by the blastopore. From this point it grows laterally and posteriorly and, later, anteriorly as well. It is not, however, until other important changes have taken place that it extends completely around the germ.

The terms *gastral mesoderm* and *peristomal mesoderm* are used to designate respectively that portion developing from the region of the head-process of the primitive streak and that portion growing from the region of the blastopore.

Concerning the origin of the mesoderm much difference of opinion prevails. The simpler and more primitive method is seen in the amphioxus, in which it develops as two evaginations from the dorsal wall of the archenteron, one on each side of the mid-line. These entodermic folds, containing each a cavity, the **enterocœl**, grow out laterally between the inner and the outer germ-layers. By transverse constriction, each fold divides into a series of segments, the **somites**, which lie on either side of the median line from the head-end to the tail-end of the embryo. Each somite divides into a dorsal part, the "**protovertebra**," and a ventral part, the **lateral plate**. By the fusion of the lateral plates of each side their several cavities become one, the **body-cavity** or **cœlom**.

The origin of the middle germ-layer in higher vertebrates is far less clearly made out. Some investigators hold that it arises in essentially the same manner as does that of amphioxus—that is, by evagination or outfolding of the entoderm bounding the cœlenteron; the investigations, however, of Bonnet and of Duval respectively upon sheep and chick embryos, point to a different conclusion. Bonnet's observations show that the mesodermic tissue, starting from Hensen's node, grows out laterally between the ectoderm and the entoderm, and that at some distance from the median line of the embryonic area there is a delamination or splitting-off of cells from the entoderm; and, further, that these two primitive areas grow toward each other and unite to form one continuous sheet of mesoderm. It may be said, therefore, that the *mesoderm originates from a double source, chiefly from the entoderm, but also from the ectoderm*, since the cells giving rise to the part that grows from the region of Hensen's node are ectodermic. A section of the germ transverse to the long axis of the embryonic area (Figs. 27 and 28) shows the mesoderm to be a distinct and independent layer, sharply defined from the other germ-layers everywhere except

in the region of the mid-line, in which position the three layers are so closely related as to constitute one structure. The mesoderm does not extend completely around the germ at this stage, being deficient on the side opposite the embryonic area.

The mesoderm, after its formation, grows by the proliferation of its own cells, independently of the ectoderm and the entoderm.

If the expansion of the mesoderm, as indicated by the surface appearance of the germ (Fig. 30), be noted, it will

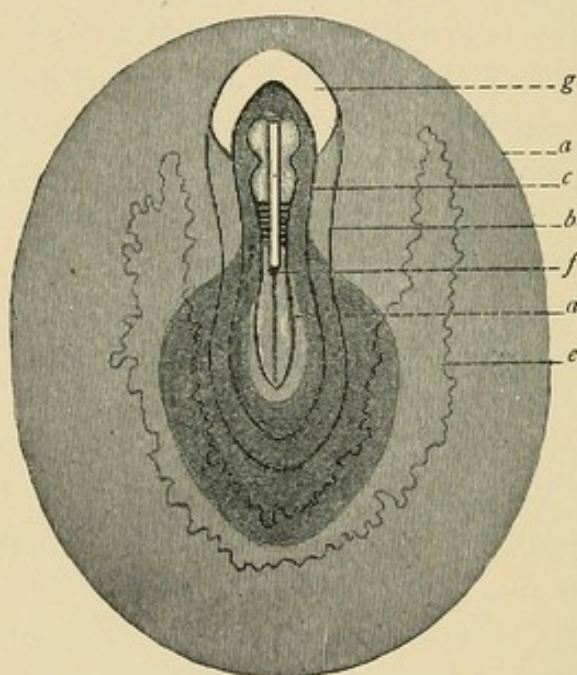


FIG. 30.—Diagrammatic surface view of rabbit's ovum of 205 hours (after Tournoux). The darkly shaded area indicates the extent of the mesoderm. *a*, Peripheral limit of area opaca; *b*, of area pellucida; *c*, of parietal zone; *d*, of stem-zone; *f*, Hensen's node; *g*, proamnion.

be seen that at first it is present throughout a pear-shaped area whose narrow end is directed forward. Somewhat later, two wing-like expansions grow forward from the front end of this area (Fig. 31); these wings, meeting at their tips, enclose a space, the **proamnion**, which is devoid of mesoderm.

Referring again to the transverse section (Fig. 28), it is evident that the middle germ-layer in the vicinity of the median line is composed of a somewhat irregular mass of cells, while farther away it constitutes a lamina on each side.

As development advances, these two portions become more differentiated from each other, although they are not entirely separated until much later. The thick mass adjacent to the median line is the **vertebral plate**, or **primitive segment plate**, or **paraxial mesoderm**; the more flattened lateral portion is the **lateral plate**. The mesoderm at this stage, therefore, consists of four parts—the two paraxial masses, lying one on each side of the median line, and extending from the head-

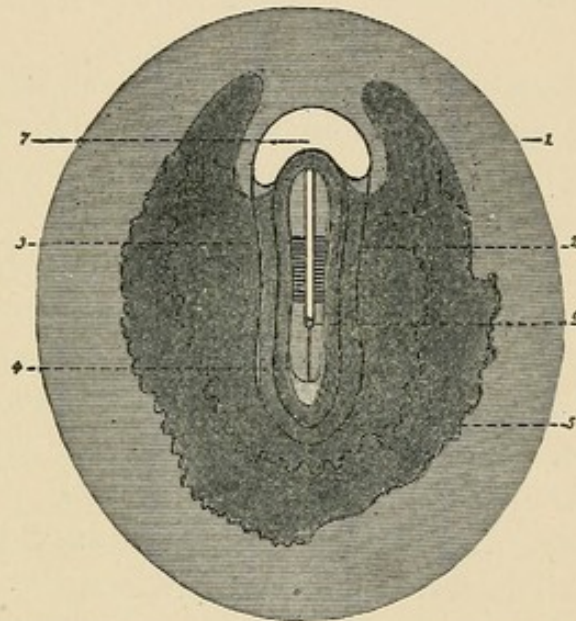


FIG. 31.—Diagrammatic surface view of rabbit's ovum of 211 hours (after Tournoux). The darkly shaded area indicates the extent of the mesoderm. 1, Peripheral limit of area opaca; 2, of area pellucida; 3, of parietal zone; 4, of stem-zone; 6, Hensen's node; 7, proamnion.

end to the tail-end of the embryonal area, and the two lateral plates, situated upon the outer sides of the paraxial columns.

Each **primitive segment plate** undergoes transverse division into a number of irregularly cubical masses, the **mesoblastic somites**, or **primitive segments**, often improperly called the protovertebræ. The presence and position of the primitive segments are indicated by transverse parallel lines on the surface of the germ, which constitute a series on either side of the primitive streak and its head-process (Figs. 31 and 37). The formation of the somites begins at the cephalic end of the embryo and progresses tailward.

The **lateral plate** of the mesoderm splits into two lamellæ,

of which the outer or parietal layer is the **somatic mesoderm**, and the inner or visceral layer is the **splanchnic mesoderm**. The somatic mesoderm unites with the ectoderm, forming the **somatopleure**; the splanchnic mesoderm unites with the entoderm, forming the **splanchnopleure**. The fissure-like cavity between the somatopleure and the splanchnopleure is the **cœlom**, or **body-cavity**, or pleuroperitoneal cavity (Fig. 36). The great serous cavities of the adult body—pleural, pericardial, and peritoneal—are later subdivisions of the cœlom.

The mesodermic cells bounding the body-cavity become flattened and endothelioid in character, and constitute the **mesothelium**; from them are descended the various endothelial cells lining the serous cavities of the mature organism. According to some authorities, among whom Hertwig may be especially mentioned, there develop from the mesothelium at an early stage certain cells whose particular function is the formation of the different kinds of connective tissue, such as bone, cartilage, fibrous tissue, etc.; these elements are often distinguished as **mesenchymal cells**, or collectively, as **mesenchyme**. According to this classification, the importance of which is insisted upon by Minot, the mesenchyme includes all the mesodermic tissue except the flattened cells, the mesothelium, lining the body-cavity.<sup>1</sup>

His claims a double origin for the mesoderm. He maintains that the mesothelium and the smooth musculature of the body are of intra-embryonic origin, and these structures he terms the **archiblast**; while all other parts of the mesoderm, which he designates the **parablast**, have, in his opinion, an extra-embryonic source, being derived possibly from the granulosa cells of the ovary. These views are not shared, however, by the majority of embryologists.

**The Derivatives of the Germ-layers.**—From the three primary germ-layers are developed the various tissues and organs of the body by metamorphoses which may be

<sup>1</sup> Minot holds with Goette that the mesenchymal cells are the product of the mesothelium. Hertwig maintains that the mesenchyma arises from all the other germ-layers by the emigration of isolated cells.

referred to the two fundamental processes of *specialization*, or the adaptation of structure to function, and of *unequal growth*, which latter results in the formation of folds, ridges, and constrictions.

From the **ectoderm** are produced :—

The *epidermis and its appendages*, including the nails, the epithelium of the sebaceous and sweat-glands and their involuntary muscles, the hair, and the epithelium of the mammary glands.

The *infoldings of the epidermis*, including the epithelium of the mouth, with the enamel of the teeth, the epithelium of the salivary glands, and the anterior lobe of the pituitary body :

The epithelium of the nasal tract with its glands and communicating cavities :

The epithelial lining of the external auditory canal, including the outer stratum of the *membrana tympani* :

The lining of the anus and of the anterior part of the urethra :

The epithelium of the conjunctiva and of the anterior part of the cornea, the crystalline lens.

The *spinal cord*, the *brain* with its outgrowths, including the optic nerve, the retina, and the posterior lobe of the pituitary body.

The *epithelium of the internal ear*.

From the **entoderm** are produced :—

The epithelium of the *respiratory tract*.

The epithelium of the *digestive tract*, from the back part of the pharynx to the anus, including its associated glands, the liver, and the pancreas.

The epithelial parts of the *middle ear* and of the *Eustachian tube*.

The epithelium of the *thymus* and *thyroid bodies*.

The epithelium of the *bladder*, and of the *first part* of the *male urethra*, and of the entire *female urethra*.

From the **mesoderm** are developed :—

*Connective tissue in all its modified forms*, such as bone, dentine, cartilage, lymph, blood, fibrous and areolar tissue.

*Muscular tissue.*

*All endothelial cells*, as of joint-cavities, bursal sacs, lymph-sacs, blood-vessels, pericardium and endocardium, pleura, and peritoneum.

The *spleen*.

The *kidney* and the *ureter*.

The *testicle* and its system of *excretory ducts*.

The *ovary*, the *Fallopian tube*, the *uterus*, and the *vagina*.

From the foregoing tabulation it may be seen that, generally speaking, all epithelial structures originate from either the ectoderm or the entoderm, the notable exception to this rule being that the epithelium of the sexual glands and their ducts, and also that of the kidney and of the ureter, proceed from the mesoderm.

## CHAPTER IV.

### THE BEGINNING DIFFERENTIATION OF THE EMBRYO; THE NEURAL CANAL; THE CHORDA DORSALIS; THE MESOBLASTIC SOMITES.

THE germ, in the stages thus far considered, has the form of a hollow sphere or vesicle. It will be seen, in following the further history of development, that the layers of cells constituting the walls of the vesicle give rise to the alterations of external form and to the rudiments of the various organs of later stages by processes which, though seemingly complex, are referable to certain simple fundamental principles. It is, namely, in the unequal growth of different parts of the germ, in outfoldings and infoldings, and in the furrowing and constricting-off of parts, as well as in the adaptation of structure to function, that we find an explanation of the various developmental processes.

The first indication of the formation of the embryo and of its differentiation from the parts of the germ that are destined to produce, wholly or in part, the several extra-embryonic structures, is the marking out of the embryonic area by the thickening of the cells of the vesicle-wall in a definitely circumscribed region. The structures designated as extra-embryonic are the **umbilical vesicle**, the **amnion**, the **allantois**, and the **fetal part of the placenta**. The development of these and the production of the external form of the body of the embryo will be considered in the next chapter.

The **primitive streak** and its head-process have been already described. After their appearance the further evolution of the embryonic body is closely associated with three fundamentally important processes—namely, the formation of the **neural canal**, of the **chorda dorsalis**, and of the **mesoblastic somites**.

**The Neural or Medullary Canal.**—The neural canal is an elongated tube lying beneath the ectoderm in the median longitudinal axis of the embryonic body, its position corresponding to that of the future spinal canal. Its walls are composed of cylindrical epithelial cells.

To follow the development of the medullary canal, it is necessary to study the surface appearance of the ovum at the stage when the mesoderm is beginning to grow out from the region of the head-process of the primitive streak. Upon the surface of such a germ (Fig. 26), one may see the primitive streak and, in front of it, also in the median line of the embryonic area, the **head-process** of the primitive streak. The ectodermic cells overlying the head-process thicken so as to

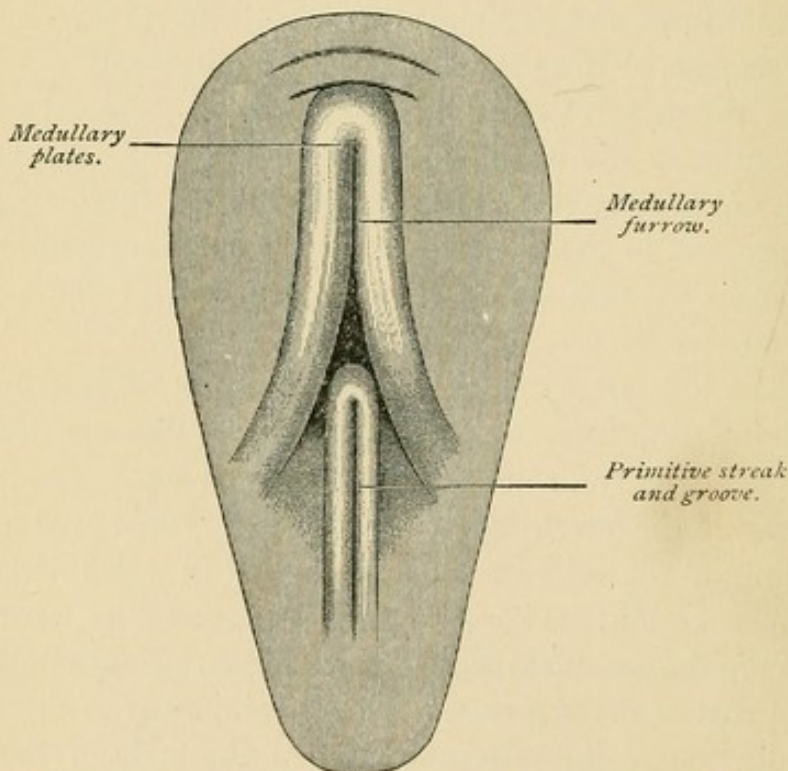


FIG. 32.—Surface view of area pellucida of an eighteen-hour chick-embryo (Balfour).

become columnar, while those on each side of it become flattened. This differentiation results in the production of a relatively thick axial plate of ectoderm, the **medullary plate**, which is present at the beginning of the eighth day in the rabbit's germ, and in the human germ at about the fourteenth

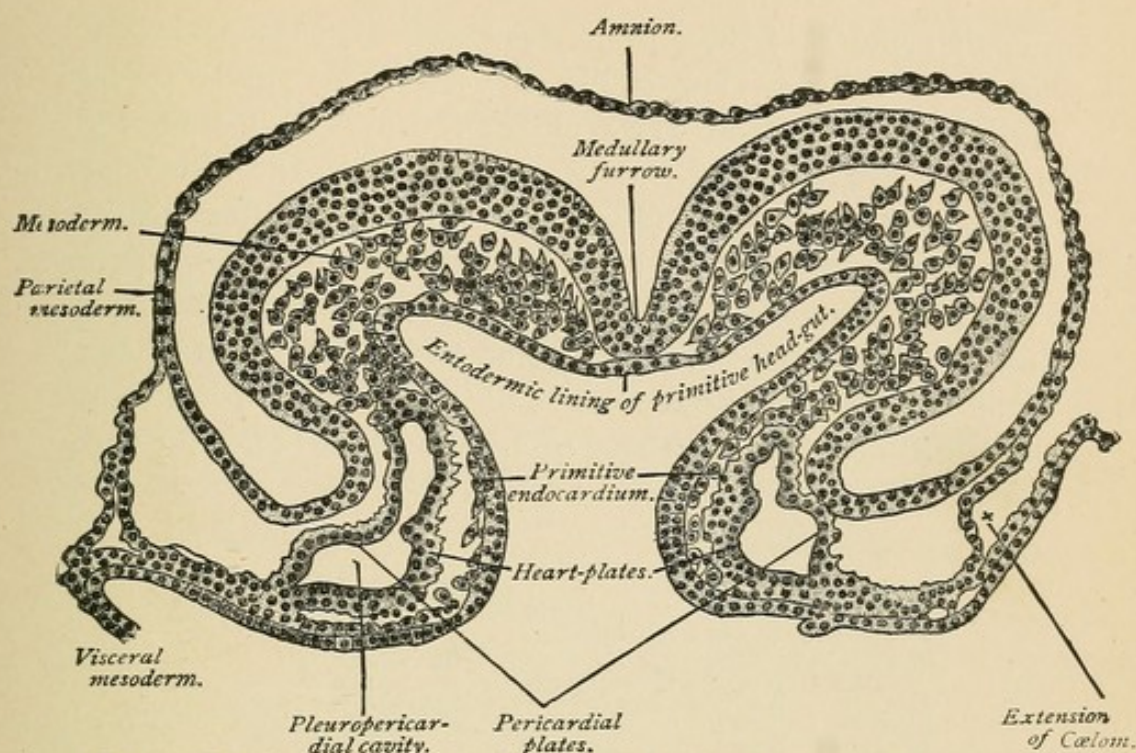


FIG. 33.—Transverse section of a sixteen-and-a-half-day sheep-embryo (Bonnet).

day. Almost as soon as the plate is formed, its lateral and anterior edges begin to curl up, producing the medullary fur-

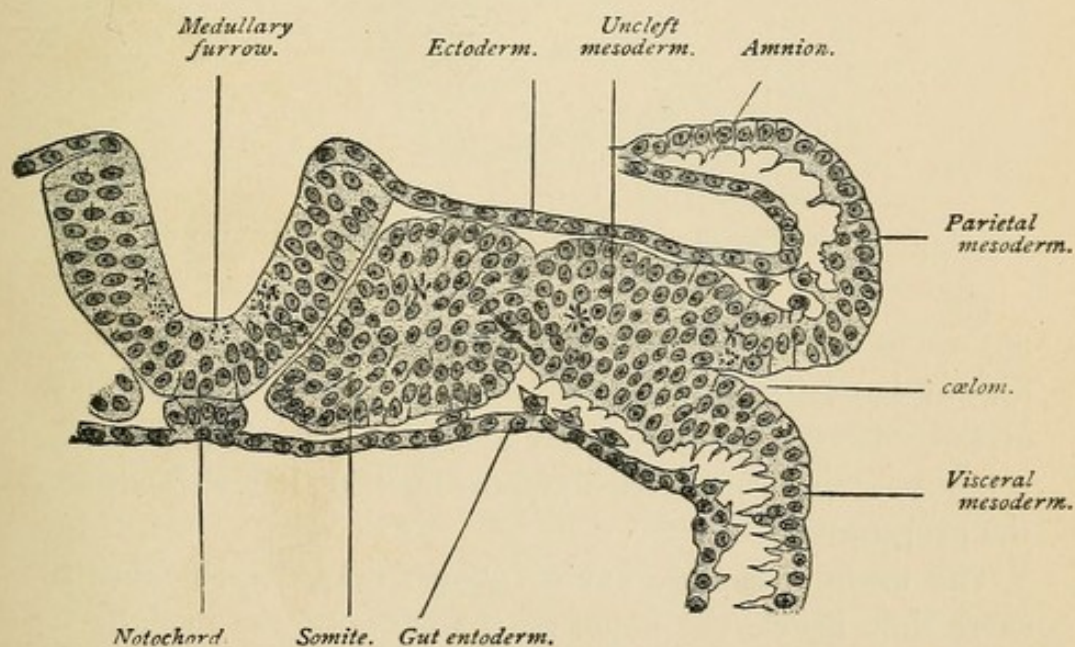


FIG. 34.—Transverse section of a sixteen-and-a-half-day sheep-embryo possessing six somites (Bonnet).

row or groove (Figs. 32, 33, and 34). The curling margins of the plate carry with them, as they rise, the adjacent

thinner ectoderm; these projections constitute the **medullary folds**. A surface view shows the medullary folds to be continuous with each other in front, while their posterior ends are separated and embrace between them the front end of the primitive streak (Fig. 32). Since the formation of these structures is always more advanced in the anterior part of the embryonic area, their posterior extremities are not sharply defined but fade away (Fig. 32). The edges of the medullary plate continue to curl until they meet, when they unite, forming the **medullary or neural canal** (Figs. 35 and

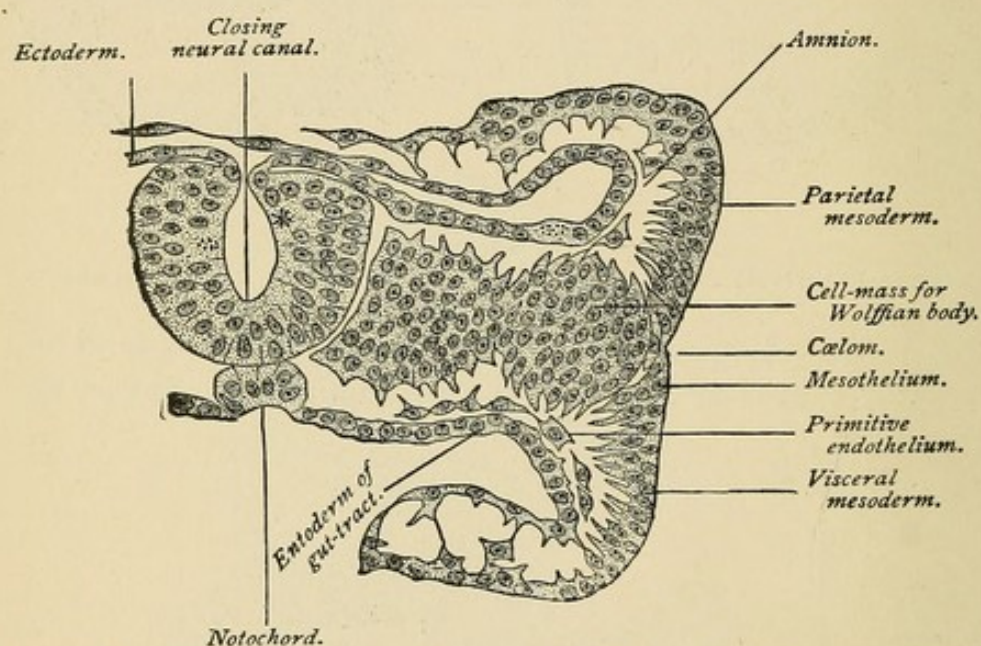


FIG. 35.—Transverse section of a fifteen-and-a-half-day sheep-embryo possessing seven somites (Bonnet).

36). The medullary folds and plate continuing to advance toward the tail-end of the embryonic area, and the closure of the tube taking place from before backward, the entire primitive streak is made to disappear by being included within the neural tube.

The medullary folds having grown toward each other a short time before the union of the edges of the medullary plate now unite over the partially formed neural tube. By the growth of the medullary folds and their subsequent coalescence, the completed neural tube comes to lie under the surface ectoderm, its connection with which is afterward lost.

It is apparent, therefore, that the neural tube is a structure whose walls are composed of ectodermic cells, and that it has originated from the ectoderm by what may be called a process of infolding.

The **medullary canal** is the fundament of the entire adult nervous system. The first step in the conversion of a structure so simple into one so complex consists in the dilatation of the cephalic end of the neural tube and the subsequent division of this dilated extremity into three imperfectly separated compartments, named respectively the **fore-brain**, the **mid-brain**, and the **hind-brain vesicles**. It is by the multiplication and

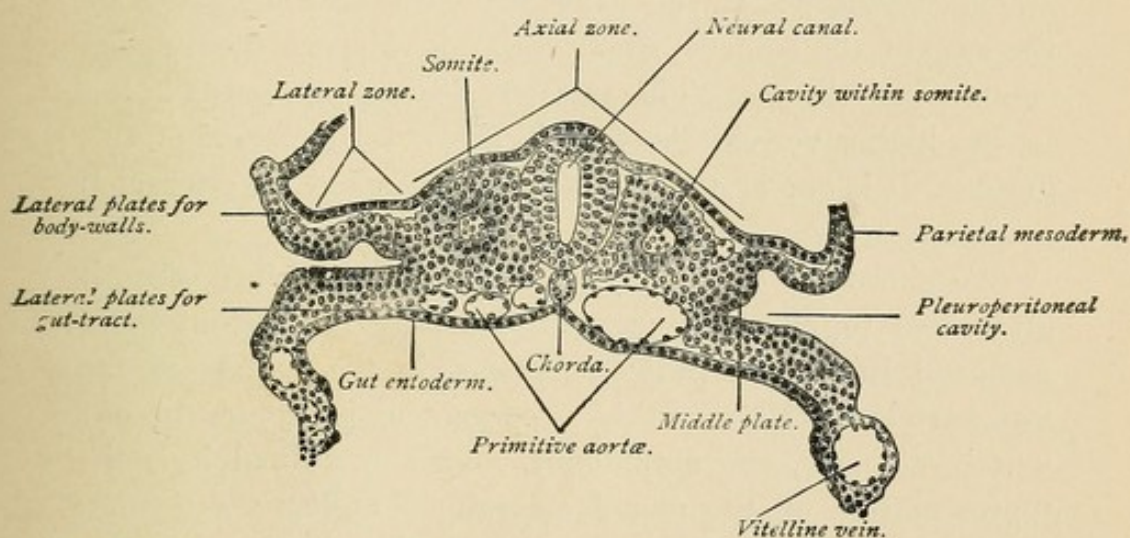


FIG. 36.—Transverse section of a seventeen-and-a-half-day sheep-embryo (Bonnet).

specialization of the cells composing the walls of the medullary tube that the cerebrospinal axis is produced, the brain-vesicles giving rise to the brain-mass, while the remainder of the tube produces the spinal cord. Approximately one-half of the length of the tube is devoted to the formation of the brain, the other half forming the spinal cord.

The neural tube closes first in the future cervical region, the cephalic part of the canal remaining open for a time. From the neck region the closure of the tube progresses toward either end of the embryo.

**The Notochord or Chorda Dorsalis.**—The notochord is a solid cylindrical column of cells lying parallel with the medullary tube, on the dorsal side of the archenteric cavity.

Its position is that of a line passing through the centers of the bodies of the future vertebræ. The development of the chorda occurs at the same time as that of the neural tube, and in a very similar manner. A thickening of the cells of the entoderm in a longitudinal line extending along the dorsal aspect of the cœlenteron produces the **chordal plate**. Along either edge of the chordal plate a small fold of entoderm projects ventralward. By the curling around of the edges of the chordal plate, the latter becomes a solid cylinder of cells, which is separated from the entoderm proper by the union of the chordal folds, as shown in Figs. 35 and 36.

The appearance of the notochord is the first indication of the axis of the embryo, since around it the permanent spinal column is built up. The relative size of the chorda is less in the higher vertebrates than in the lower members of this group. It is one of the distinctive features of a vertebrated animal.

The chorda is essentially an embryonic structure, since it gives rise to no adult organ. Its only representative in postnatal life is the pulpy substance in the centers of the intervertebral disks. It is a permanent structure in one vertebrate only, the amphioxus. In this animal it is the representative of the spinal column of higher vertebrates. The notochord affords another illustration of the principle that higher organisms repeat, in their development, the structure of the lower members of the group to which they belong.

**The Neurenteric Canal.**—The neurenteric canal is closely associated with the development of the medullary canal and with the disappearance of the primitive groove. We have learned that the blastopore is the orifice through which the cœlenteron opens to the exterior, and also that in birds and mammals the position of the blastopore, as indicated by the presence of the terminal ridge, corresponds to the anterior end of the primitive streak, and therefore of the primitive groove. Reference to Fig. 32 will show that the medullary folds have extended so far posteriorly that they embrace between them the primitive groove; therefore when

they unite to form the neural canal, the primitive streak falls within its limits.

In a gastrula with an open blastopore, such as that of the amphioxus and those of amphibians, the blastopore is included between the medullary folds, and, after the completion of the neural canal, it constitutes an avenue of communication between the latter and the coelenteron or primitive enteric cavity; this communication is the **neurenteric canal**. In mammals, as also in birds, reptiles, and selachians, classes in which the primitive streak is the representative of the closed blastopore, a small canal is found at the anterior end of the primitive groove, passing through Hensen's node, and opening into the coelenteron. With the covering in of the primitive groove by the medullary folds, this canal becomes the neurenteric canal. According to Graf Spee, a neurenteric canal is found in the human embryo, as well as in the groups above mentioned. The canal is a temporary structure and gives rise to no organ of the adult.

**The Somites or Primitive Segments.**—The **mesoblastic somites** are cuboidal masses of cells, arranged in two parallel rows, one on each side of the notochord, extending the entire length of the body of the embryo. They are sometimes called *protovertebrae*, but this term if used at all should be restricted to a subdivision of them that appears later.

The development of the somites was incidentally referred to in the description of the mesoderm. As mentioned in that connection, the paraxial plates of mesoderm, lying as parallel longitudinal columns, one on each side of the notochord, break up, each one into its corresponding series of primitive segments. The division throughout the entire length of the body takes place not simultaneously, but consecutively, beginning at the head-end.

The segmentation of the axial mesoderm is indicated by certain surface markings. The surface of the embryonal area, at the stage when the primitive streak and the medullary groove are present, shows a dark zone on either side of the median line, the so-called **stem-zone**, which marks the

limits of the axial plate of mesoderm (Fig. 37); the position of the lateral plates is indicated by the peripheral lighter **parietal zone**. The stem-zone soon exhibits, on each side of the primitive streak and medullary groove, a series of parallel transverse lines, produced by the transverse furrowing of the axial plates, preparatory to their division into the primitive segments. The first pair of somites is formed in the future cervical region, before the medullary folds have united to form the neural tube, and when the primitive streak is yet present. After the appearance of the first pair, the forma-

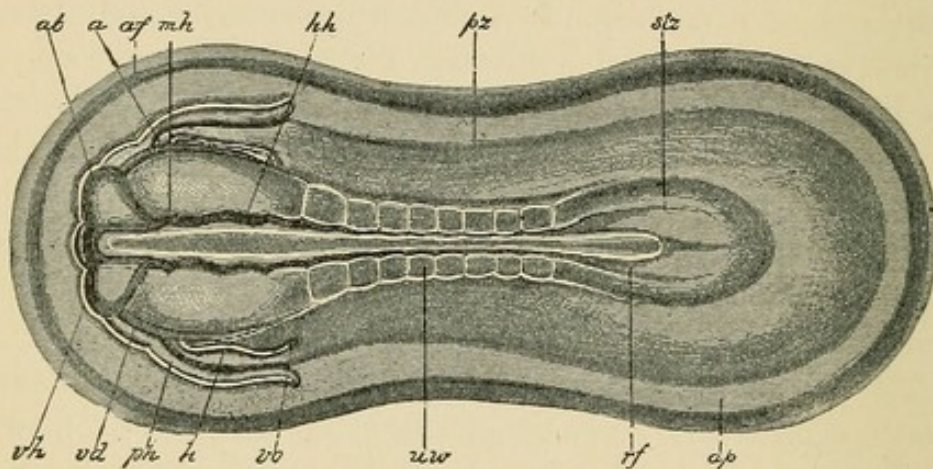


FIG. 37.—Rabbit embryo of the ninth day, seen from the dorsal side (after Kölliker). Magnified 21 diameters. The stem-zone (*stz*) and the parietal zone (*pz*) are to be distinguished. In the former 8 pairs of primitive segments have been established at the side of the chorda and neural tube; *ap*, area pellucida; *rf*, medullary groove; *vh*, fore-brain; *ab*, eye-vesicle; *mh*, mid-brain; *hh*, hind-brain; *uw*, primitive segment; *stz*, stem-zone; *pz*, parietal zone; *h*, heart; *ph*, pericardial part of the body-cavity; *vd*, margin of the entrance to the head-gut (*vordere Darmmpforte*), seen through the overlying structures; *af*, amniotic fold; *vo*, vena omphalomesenterica.

tion of other segments proceeds headward and tailward. In selachians the number of head-segments has been shown to be nine; in higher vertebrates the number is possibly less. The trunk-segments are added in regular order from the neck-region to the tail-end of the embryo.

The first somites appear on the eighth day in the rabbit, and between the twentieth and twenty-second hours in the chick. While they are forming, the neural canal is closing, the notochord is differentiating from the entoderm, and the lateral plates of mesoderm are splitting to form the body-cavity or cœlom.

In structure the primitive segments of lower vertebrates consist of columnar cells arranged around a central cavity (Figs. 34 and 36). The cavity, in the amphioxus, communicates for a time with the coelenteron, since the segments are in this case developed as entodermic evaginations; in selachians, the method of formation of whose primitive segments may be regarded as the primitive method for vertebrates, the cavity is for a time in communication with the body-cavity, since the segments in these animals develop as if by evagination from the dorsal side of the mesoderm after it has separated into its parietal and visceral layers and before it has divided into the axial and lateral plates. The size of the cavity is quite variable; in some cases, as in the Amniota, it is almost if not entirely obliterated by the encroachment of the cells of the walls of the somite.

Belonging to the somite, though not apparent on the surface, is a mass of cells which connects, for some time, the somite proper with the lateral plate (Fig. 36). This is known as the **intermediate cell-mass** or **middle plate**. Later, the separation of these is effected, the mesial part of the somite being the **myotome**, the intermediate cell-mass becoming the **nephrotome**. Each one of these parts contains a cavity, that of the myotome being called the **myocoel**. From the inner, mesial side of the myotome, embryonic connective-tissue cells (mesenchyme) develop, constituting the **sclerotome**, or **skeletogenous tissue**. The sclerotomes, made up of loosely-arranged embryonal connective tissue, grow around the medullary canal and chorda dorsalis, spreading out and fusing with each other. Subsequently this tissue produces the vertebral column and its associated ligamentous and cartilaginous structures. The outer part of the myotome, sometimes called the **cutis plate**, gives rise to the corium of the skin of the trunk. The remaining part of the myotome, that situated dorsolaterally, constitutes the **muscle-plate** or myotome proper; it gives rise to the voluntary musculature of the trunk.

The **segmentation of the body of the embryo** is an embryological process of great significance.

The segmented condition is common to the developmental stage of all true vertebrates, and in some invertebrates it persists throughout adult life. The development of the axial skeleton and of the muscular system, it will be seen later, bears an important relation to the process of segmentation, as does also the evolution of the genito-urinary system.

Upon reflection, it will be seen that in the region of the embryo corresponding to the future neck and trunk, the segmentation affects only the dorsal part of the body, while the ventral mesoderm, the so-called lateral plate, which contains the *cœlom*, remains unsegmented. On the other hand, in the head-region, the segmentation is both dorsal and ventral, the former being in series with the trunk-segments, while the latter, affecting the ventral mesoderm, and therefore also, in the corresponding region, the *cœlom*, produces the structures known as the visceral arches (see Chapter VII.).

The relation of the primitive segments to the differentiation of the skeleton and of the musculature of the trunk, and also of the visceral arches to the muscles of the jaws, will be considered in subsequent chapters.

## CHAPTER V.

### THE FORMATION OF THE BODY-WALL, OF THE INTESTINAL CANAL, AND OF THE FETAL MEMBRANES.

---

THE formation of the fetal membranes occurs coincidentally with the production of the external form of the body of the embryo. These changes mark the division of the hollow sphere or vesicle of which the germ consists up to this stage into two essentially different parts—namely, the **embryonic body** and the **fetal appendages**, the latter of which are destined for the nutrition and protection of the growing embryo. Although the several processes by which are produced the different parts of the embryo and its various appendages go on simultaneously, it is necessary, for the sake of clearness, to consider successively the development of each structure from its inception to its completion.

#### THE FORMATION OF THE BODY-WALL AND OF THE INTESTINAL CANAL OF THE EMBRYO.

In the stages of development thus far considered, the part of the ovum that is to become the embryo—that is, the embryonic area—is represented by a localized thickening of the wall of the blastodermic vesicle, of the shape and relative size shown in Fig. 24, which presents a surface view of the germ. On each side of the embryonic axis, represented by the notochord, is the paraxial mass of mesoderm, which has undergone partial segmentation to form the somites; on the distal side of the paraxial column, the mesoderm has split into the somatic or parietal, and the splanchnic or visceral lamellæ, between which is the body-cavity or cœlom. The cavity of the germ until the occurrence of the transforma-

tions about to be described is one undivided compartment which is bounded by splanchnopleure; and a conspicuous feature of the changes under consideration is the division of this cavity into two by the folding in of the splanchnopleure composing its walls.

The **first indication of the foldings** that lead to the differentiation of the embryo from the fetal appendages is seen upon the surface of the germ at a very early stage. A surface view of the germ—in the case of the chick on the first day of incubation—shows, at what becomes the head-end of the embryonic area, a **transverse crescentic groove**, with its concavity looking backward (Fig. 32); a similar groove is seen at the opposite extremity of the area, and also one at each lateral margin. These marginal grooves are depressions in the somatopleure. The elevated outer edges of the grooves form folds of somatopleure, designated respectively the **head-fold**, the **tail-fold**, and the **lateral folds of the amnion**. As these marginal grooves increase in length they meet each other and now constitute one continuous furrow, which encircles the embryonic area; its outer elevated edge is the **amnion-fold**. This furrow, which may be called an inverted fold composed of splanchnopleure and somatopleure, progressively deepens and at the same time its bottom is carried inward toward a point vertically under the central region of the embryonic area; that is, a fold composed of somatopleure and splanchnopleure grows from all parts of the periphery of the embryonic area toward the point indicated above, a point which corresponds to the site of the future umbilicus. By the ingrowth of the edges of the fold, the cavity of the archenteron is more and more constricted (Plate II., Figs. 2 and 3), until finally, with the completion of the infolding, it becomes divided into two parts of unequal size; the smaller of these spaces is the **gut-tract**, or intestinal canal of the embryo, while the larger is the **yolk-sac** or **umbilical vesicle**. The constricted canal through which the gut-tract communicates with the yolk-sac is the **vitelline duct** (Plate II., Figs. 4 and 5).

While the splanchnopleuric layer of the ingrowing fold

thus outlines and forms the walls of the intestinal canal, the somatopleuric layer, which accompanies it, constitutes the **lateral** and **ventral body-walls** of the embryo. During the progress of this infolding of the splanchnopleure and the somatopleure, the part of the latter membrane that forms the outer wall of the groove becomes lifted up to constitute the **amnion-fold** (Plate II., Fig. 3); by the continued upward growth of this amnion-fold and the simultaneous settling down of the embryo upon the yolk-sac, the margins of the fold come to lie above the embryonic body, and, approaching each other, they fuse over its back, in this manner enclosing it in a cavity. It is obvious that the fold just described is a double layer of somatopleure. After the union of its edges, the two layers become completely separated, the inner one constituting the **amnion**, while the outer layer is the **false amnion**, or **serosa**, or **chorion** (Plate II., Figs. 4-6).

Since the infolding of the splanchnopleure begins at the periphery of the much elongated embryonic area, the resulting gut-tract has the form of a straight tube extending from the head-end to the tail-end of the embryo (Plate III.). When the caudal and the cephalic portions of the splanchnopleuric fold have advanced but a comparatively short distance, in consequence of which the communication between the gut-tract and the umbilical vesicle is still widely open, as shown in Plate II., Fig. 5, there is a cul-de-sac or pocket formed of splanchnopleure at the head-end of the embryo and a similar one at its tail-end; these recesses are respectively the **foregut** and the **hindgut**, the orifices of which are designated the **intestinal portals**. At this particular stage, therefore, the cavity of the gut-tract is incompletely closed off from that of the umbilical vesicle.

It is evident that the **gut-tract**, being a tubular cavity enclosed by splanchnopleure, is lined with entodermal cells; this simple straight tube develops subsequently into the adult intestinal canal and its associated glandular apparatus.

It has already been pointed out that the layer of somatopleure which is folded under the embryonic area in company with the splanchnopleure constitutes the lateral and the ven-

tral walls of the body of the embryo. The fold continues to advance from each side and from each end, and its edges come together and fuse in the median line of the ventral surface of the body.<sup>1</sup> At one place, however, fusion of the edges of the fold does not occur; this region corresponds to the umbilicus and is often designated the **dermal navel**. Here the part of the somatopleure that forms the body-wall is continuous with that part of this membrane which constitutes the amnion (Plate II., Fig. 6). By the infolding of the somatopleure the body-cavity or pleuro-peritoneal space becomes divided into an intra-embryonic and an extra-embryonic portion, the two communicating for a time through the small annular space that encircles the proximal end of the vitelline duct; this is represented in the accompanying figures.

By this simple process of folding, associated with the unequal growth of different parts, the leaf-like fundamen-  
t constituted by the embryonic area is differentiated into the body of the embryo; the ventral portion of this body now consists of two tubes, one within the other, of which the smaller, bounded by the splanchnopleure, is the **intestinal canal**, and the larger, enclosed by the somatopleure, is the **body-cavity**, the walls of which are the walls of the body of the embryo. In the dorsal region is a third tube, the **medullary canal**; between it and the dorsal wall of the intestine is the **notochord**, on each side of which are the **somites** (Fig. 35). The further evolution of this body and the differentiation of its various organs and systems will be described in subsequent sections.

#### THE AMNION.

The **amnion** is a membranous fluid-filled sac, which surrounds the fetus of certain groups of vertebrate animals during a part of their period of development. In man, it is

<sup>1</sup> Failure of union of the somatopleuric folds in the median line of the thorax produces the deformity known as cleft sternum; while lack of fusion of the lateral halves of the abdominal wall results in an extra-abdominal position of the intestines, or, if in lesser degree, in exstrophy of the bladder.

found as early as the fourteenth day,<sup>1</sup> before the medullary groove has closed to form the neural canal; it attains its maximum size by the end of the sixth month and persists until the end of gestation. It constitutes a loose envelope for the fetus, being attached to the abdominal wall of the latter at the margins of the umbilicus, and loosely enveloping the umbilical cord (see Plate III., Fig. 2).

An amnion is found in birds, reptiles, and mammals, these groups being classed together as **Amniota**, while fishes and amphibians, which are without an amnion, constitute the class **Anamnia**.

The **first indication** of the growth of the amnion is apparent at a comparatively early stage of development. A surface-view of the blastodermic vesicle of the first day of incubation in the case of the chick, or of about the eighth day of development in the rabbit, shows a curved line or marking at the anterior edge of the embryonic area (Fig. 32); this is the anterior marginal groove, in front of which is another marking, the **head-fold** of the amnion. Very soon the lateral and posterior marginal grooves appear at the sides and posterior edge respectively of the embryonic area; the outer elevated edges of these marginal grooves constitute the **lateral folds** and the **tail-fold** of the amnion. The grooves and folds increase in length in each direction until they meet, when they form one continuous furrow, which circumscribes the embryonic area, and the outer elevated edge of which is the **amnion fold**. The groove involves both the somatopleure and the splanchnopleure, constituting the inverted fold of these two structures that grows in to form the body-wall and the wall of the gut-tract, while the amnion fold is composed of somatopleure alone (Plate II.). This separation of the somatopleure and the splanchnopleure enlarges the extra-embryonic portion of the body-cavity. The amnion fold continues to grow upward, and finally its edges meet and fuse over the back of the embryo, the line of union being the **amniotic suture**; the suture closes first at the head-end of the embryo and last at the tail-end. After the union of the edges

<sup>1</sup> Recently it has been found complete in an ovum estimated to be four days old.

of the fold, its inner layer, consisting of ectoderm and parietal mesoderm, separates from the outer layer to constitute the **true amnion**, whose enclosed space is the **amniotic cavity**; the outer layer, which is merely a part of the general somatopleure, is the **false amnion** or **serosa**. It is apparent from this description that the amniotic cavity is lined with ectodermal epithelium and that its walls consist of somatopleure—that is, of ectoderm and parietal mesoderm.

While the amnion fold is growing upward, the embryonic area—now undergoing differentiation into the embryonic body—is sinking down upon the yolk-sac. The amnion fold does not grow uniformly in all parts of its periphery. The head-fold is produced first and constitutes a cap or hood covering the head of the embryo, which is forming simultaneously by the ventrad growth of the somatopleure at the bottom of the marginal groove. It is only after the development of the head-fold is well advanced that the lateral, and, later, the caudal, portions of the amnion-fold grow up to meet it. The head-fold is, for a time, destitute of mesodermic tissue, since it corresponds to that region of the wall of the blastodermic vesicle described on page 56 as the proamnion.

The **amnion of man** presents an important variation from that of all other Amniota, since the inner layer of the amnion-fold does not entirely sever its connection with the outer layer, but remains attached to it over the caudal pole of the embryo. In consequence of this attachment the true amnion is connected with the false amnion, and since the true amnion is continuous with the body-wall of the embryo, the caudal end of the embryonic body is attached to the false amnion or chorion by a mass of tissue called the **allantoic stalk** or **belly-stalk**, as seen in Fig. 38. The relation of the belly-stalk to the development of the allantois will be pointed out hereafter.

The space within the amnion—the **amniotic cavity**—is filled with the amniotic fluid or **liquor amnii**.

The amnion at first envelops only the sides and dorsum of the embryonic body, occupying the upper part of the cavity enclosed by the chorion, as shown in Plate II., Figs. 5 and

6; the groove, or furrow, however, of which the amnion fold is the peripheral or outer elevated edge, becomes deeper, and the bottom of the groove is carried toward the middle of the future ventral surface of the embryo, its ventrad growth continuing until it reaches the position of the future umbilicus (Plate II.: Fig. 4, transverse section; Figs. 5 and 6, longitudinal section). The layer of somatopleure constituting the inner wall of the groove—that is, on the side toward the embryonic area—becomes the lateral and ventral walls of the body of the embryo, as described above; in this manner is effected the transition from the flattened or layer-like embryonic area to the definite form of the embryonic body. The ventral body-wall is continuous at the margins of the umbilicus with the amnion, since the somatopleure, forming the outer boundary of the original groove, is a part of that membrane. After its completion, therefore, the amnion envelops the body of the embryo on every side, lying closely applied to it, since the amniotic cavity is at first very small. With the progress of development and the increase of the fluid the amnion requires more room, until, in the third month, it fills out the entire space within the chorion, with the inner surface of which it acquires a loose connection. The umbilical vesicle and the allantois have meanwhile undergone regression. The walls of the amniotic sac contain **contractile fibers**; it is to these that the rhythmical contractions observed in the amnion are due. Its lining is at first a single layer of flattened epithelial cells; at the fourth month the cells are cubical for the most part, but to some extent columnar.

The **liquor amnii** is a watery fluid having a specific gravity of 1.007, and containing about 1 per cent. of solids (albumin, urea, and grape sugar). The origin of the fluid is believed to be in the blood of the mother, the liquid portion of which transudes into the amniotic cavity. The amniotic fluid increases in quantity until the sixth month of pregnancy; from this time until the close of gestation it generally diminishes about one half. A pathological excess of the fluid constitutes the condition of **hydramnios**.

The **function of the amniotic fluid** is two-fold; it serves as

a buffer for the fetus, protecting it from mechanical violence, and it supplies the fetal tissues with water, since portions of it are from time to time swallowed. Evidence that the fetus swallows the fluid is afforded by direct observation of chicken embryos, and by the presence of epidermal cells, hairs, and fatty matter in the fetal alimentary canal. After the development of the bladder, the urine of the fetus is from time to time evacuated into the amniotic cavity.

The epidermis of the child in utero is protected against maceration in the amniotic fluid by the presence of a fatty coating, the **vernix caseosa**, which is a modified sebaceous secretion.

At the end of pregnancy, the amnion is loosely united with the chorion and the deciduæ; during birth it ruptures, and its fluid escapes.

#### THE YOLK-SAC.

The **yolk-sac**, or **umbilical vesicle**, as seen in the higher vertebrates, is a capacious sac attached by a narrow pedicle, the **vitelline duct**, to the ventral surface of the embryonic intestinal canal, the duct passing through the **umbilical aperture** (Plate II., Fig. 6).

In order to appreciate more fully the function and the morphological relations of this structure, it is necessary to glance at the conditions that obtain in the several classes of vertebrate animals. In ova that develop outside of the body of the parent organism, a special dower of pabulum is provided for the nutrition of the embryo; this dower is represented by the deutoplasm so abundant in telolecithal ova. In the case of amphibians, whose cleavage, it will be remembered, is holoblastic or total, the cells richest in deutoplasm are accumulated, after segmentation, in the floor of the archenteron; this accumulation produces on the future ventral surface of the embryo a marked bulging, which constitutes the amphibian yolk-sac. As the embryo grows, it draws upon this store for its nutrition, in consequence of which the sac gradually shrinks, its cells being, for the most part,

liquefied and absorbed, while some of them contribute to the lining of the intestinal canal.

In a **higher type**, as exemplified in sharks and dog-fishes, the yolk-sac is produced by a folding-in of the splanchnopleure and the somatopleure, the walls of the sac being therefore constituted by both of these layers; this folding-in divides the archenteron into a smaller part, the intestinal canal, lying within the body of the embryo, and a larger cavity, the yolk-sac, situated outside of that body. The splanchnopleuric layer of the yolk-sac is continuous with the wall of the intestinal canal, while its somatopleuric layer is continuous with the body-wall. A system of blood-vessels develops upon the yolk-sac, their function being to convey the nutritive material into the body of the embryo. These blood-vessels constitute the so-called **vascular area**, which appears, in surface views, as a zone encircling the embryonic area, and, later, the embryo, since the latter reposes upon the proportionately much larger yolk-sac. As the contents of the sac become absorbed, the latter shrinks, the splanchnopleuric layer slipping into the abdomen of the embryo through the umbilical opening, the somatopleuric layer contracting to close that aperture.

In the **Amniota** (p. 75) the development and structure of the yolk-sac are modified by the presence of the amnion. In these groups the yolk-sac and the gut result from the division of the archenteron by the folding-in of the splanchnopleure alone, since the somatopleure grows away from the splanchnopleure to form the amnion-fold, and thus only partially invests the yolk-sac (Plate II., Fig. 4).

Since the yolk-sac contains the store of food destined for the nutrition of embryos that develop outside of the maternal body, and since the mammalian embryo, which leads an intra-uterine existence, is endowed with a relatively small quantity of such store, the yolk-sac of mammals would seem to indicate the descent of the latter from oviparous ancestors. Further and stronger evidence of such descent is found in the fact that the eggs of the lowest order of mammals, the Monotremata, comprising the echidna and the ornithorhynchus, are "laid" and undergo *extra-uterine* development.

In the **human embryo** the umbilical vesicle is found partially constricted off from the intestinal canal by the end of the second week; by the end of the third week the separation of the two cavities has advanced to such an extent that the vitelline duct is present, the sac attaining its maximum size by about the fourth week.

The **function of the umbilical vesicle**, as above intimated, is to serve as the organ of nutrition for the embryo during a certain period. The manner in which its blood-vessels develop will be considered in Chapter X. Their growth precedes that of the intra-embryonic portions of the vascular apparatus, the vascular area of the yolk-sac being the seat of the earliest blood-vessel formation. The vessels find their way into the body of the embryo along the vitelline duct, and consist of two vitelline arteries and two vitelline veins.

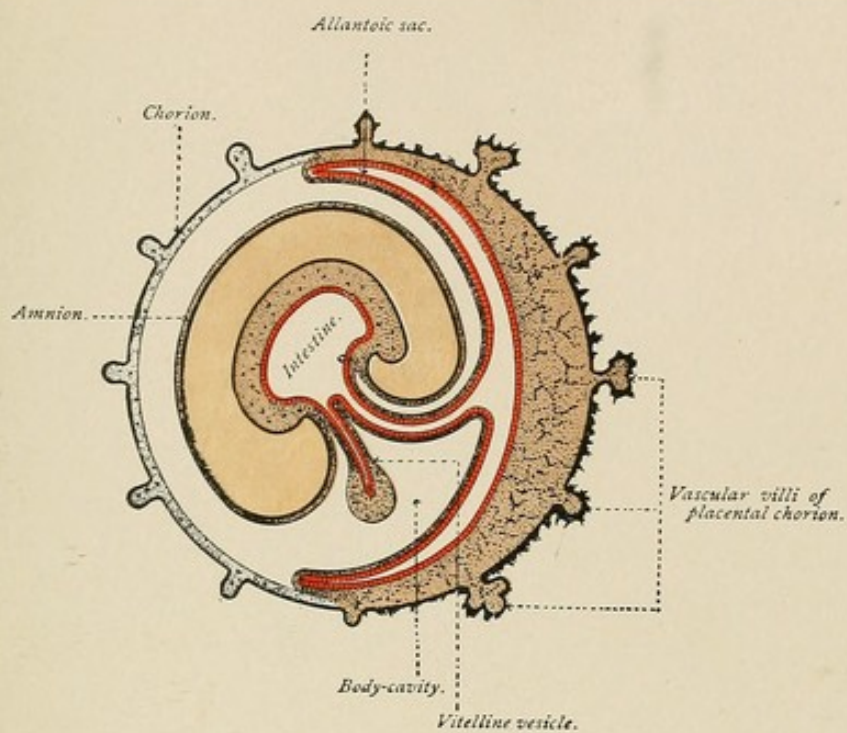
With the development of the allantois the yolk-sac retrogresses, the allantois succeeding it as the organ of nutrition and respiration. By the end of the sixth week the sac has shrunk to a narrow stalk, which is surrounded by the enlarged amnion, and which terminates in a knob; at birth, the knob lies near the placenta (Plate V., Fig. 2), and the atrophic remnant of the stalk is one of the constituents of the umbilical cord.

### THE ALLANTOIS.

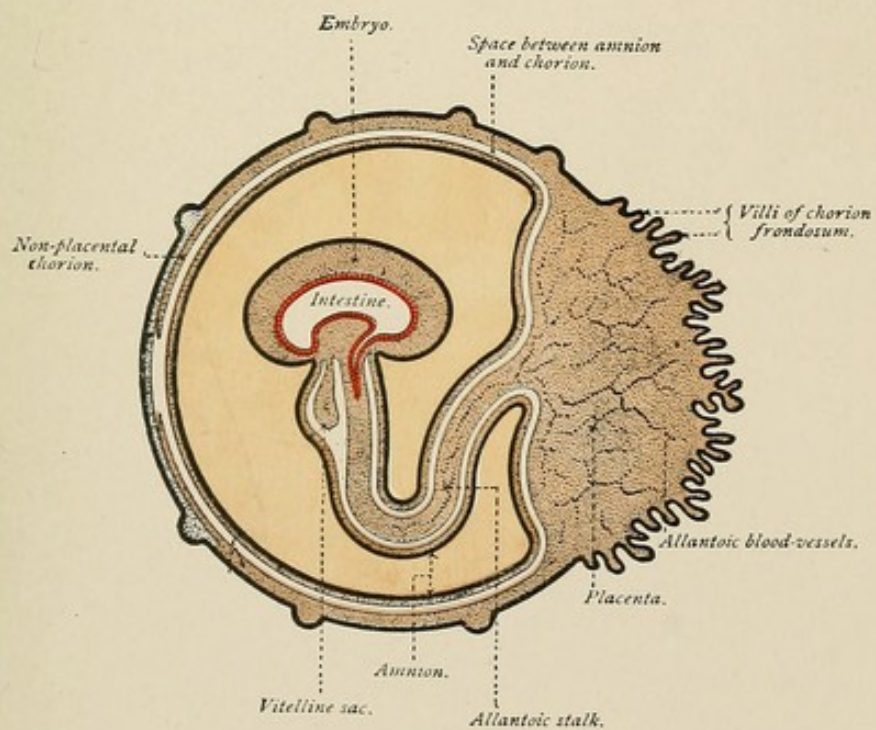
The **allantois** is an embryonic structure which is found in those vertebrates possessing an amnion. Its growth is correlated with the retrogression of the umbilical vesicle, which structure it supplants as the organ of nutrition and respiration for the embryo.

Appearing at first as a little evagination or out-pocketing of the ventral wall of the gut-tract, the allantois finally becomes a pedunculated sac lying in the extra-embryonic part of the *cœlom* (Plates II. and III.), its stalk leaving the body-cavity proper through the umbilical opening. Being an outgrowth from the intestinal canal, the walls of the allantois are made up of *splanchnopleure*—that is, of ento-

PLATE III.




1



2

Diagrams illustrating the later stages of the formation of the mammalian fetal membranes (modified from Roule).



derm and visceral mesoderm. Blood-vessels develop in the mesodermic stratum, the principal trunks, the **two allantoic arteries and veins**, being connected at their proximal ends with the primitive heart; this system of vessels constitutes the **allantoic circulation** and is the avenue through which the growing embryo is supplied with nutritive material and oxygen. As the fundus of the allantois increases in size, it spreads itself out upon the inner surface of the false amnion or chorion (Plate III., Fig. 1), into whose villi its vascular tissue penetrates, and with which it becomes intimately blended. The union of the allantois and the false amnion produces the **true chorion** of some authors.

The **human allantois** presents a striking peculiarity as compared with that of birds and reptiles; in man, the allantois

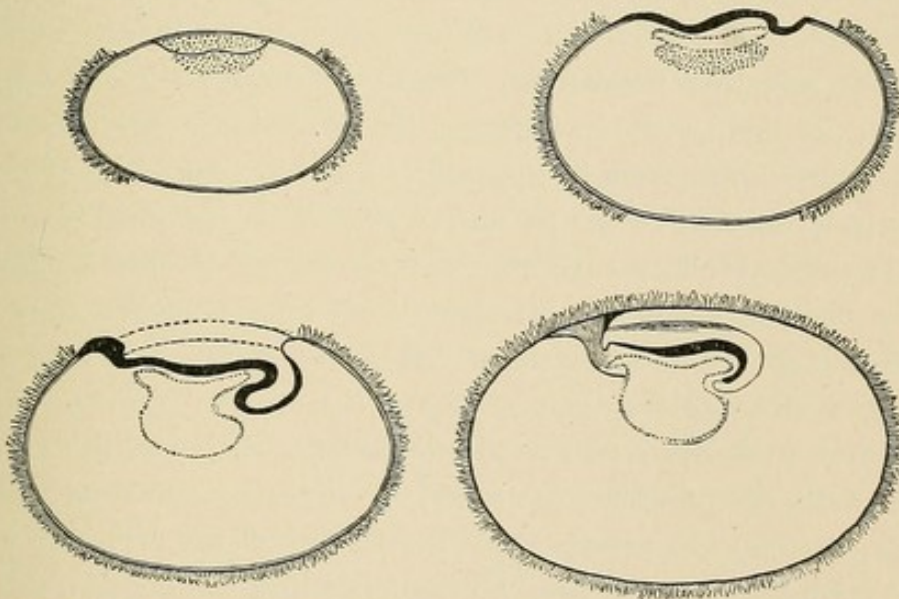


FIG. 38.—Diagrammatic sections representing growth and arrangement of the amnion in the earliest stages of the human embryo (His).

develops not as a free sac projecting into the extra-embryonic body-cavity, but as a mass of splanchnopleuric tissue which contains only a rudimentary cavity and which grows into the abdominal stalk (Fig. 38 and Fig. 47, *bst*), being guided by that structure to the chorion.

The **function of the allantois** in egg-laying animals, and possibly in some others, is to serve as a nutritive and respiratory organ and as a receptacle for the fetal urine; in

man its cavity is exceedingly minute, and its chief function is to furnish a means of conveying blood-vessels from the embryo to the chorion.

The part of the allantois contained within the body of the embryo produces three structures of the adult organism: 1, the **urachus**, an atrophic cord extending from the summit of the bladder to the umbilicus;<sup>1</sup> 2, the **urinary bladder**; and 3, the **first part of the urethra of the male, or the entire female urethra**. The extra-embryonic portion shrinks after the appearance of the placenta and forms one of the constituents of the umbilical cord, its blood-vessels becoming the umbilical arteries and veins.

### THE CHORION.

At the time when the false amnion is forming, the attenuated zona pellucida still surrounds the embryonic vesicle as the so-called **prochorion**, which unites with the false amnion, producing the **primitive chorion**. After the allantois has grown forth from the gut-tract and has spread itself over the inner surface of the primitive chorion, it becomes blended with the latter to constitute the **true chorion** of some authors. The **chorion**, according to the above nomenclature, may be defined as the membrane which encloses the germ at the stage following the appearance of the amnion and the false amnion, and which has resulted from the fusion of the allantois with the primitive chorion; or, ignoring the zona pellucida, the chorion results from the fusion of the allantois and the false amnion. Minot, however, defines the chorion as all that part of the extra-embryonic somatopleure which is not used in forming the true amnion, and hereafter in this work the word will be used in this sense. This definition limits the term to the outermost covering of the germ after the formation of the amnion (Plate III., Fig. 1).

The chorion consists of an outer ectodermic layer and an inner lamella of mesodermic tissue. The mesoblastic layer is thin, being composed of from two to four layers of round,

<sup>1</sup> If the urachus remains patulous instead of becoming impervious, urine may escape at the umbilicus, and the condition is a variety of *urinary fistula*.

oval, or fusiform cells, and is at first devoid of blood-vessels. The latter, in the form of capillaries, make their appearance at some time during the second week, probably as extensions of the blood-vessels of the allantois.

The outer ectodermic or epiblastic cells of the chorion at a very early period, certainly as early as the third day, undergo proliferation to form a layer of tissue called the **trophoblast**, which is from one to several layers of cells in thickness. The trophoblast layer is thickest at the place of attachment of the ovum to the uterine mucosa. The inner cells of the trophoblast are cubical, and have large, finely granular, round or oval nuclei. In the youngest human ovum as yet examined—that of Peters, estimated to be three or four days old—the trophoblast was found to present many little projections in the form of strands and buds, these being the foundations of the future **villi** of the chorion. The trophoblast layer was not solid, but was honeycombed with little spaces or vacuoles filled with maternal blood, which spaces were partly lined with a nucleated protoplasm, the early **syncytium** (Plate IV., *a*). Even at this early stage, therefore, when the trophoblast strands or early villi are as yet devoid of a mesoblastic element, they are bathed with the maternal blood. Very soon the mesoblastic tissue of the chorion grows into the trophoblast strands, thus forming the permanent villus stems; and during the second week capillaries extend into the stems, completing the formation of the fully developed **villi** of the chorion.

The early development of villi is characteristic of the human chorion (Fig. 39 and Plate II., Fig. 6). At first the villi, either covering the entire surface of the chorion or leaving the two opposite poles free, are of uniform size; in the latter half of the first month, however, there begins to be a differentiation into a region containing smaller, and one having larger and more numerous, projections. The difference between the two areas becoming more marked, the relatively smooth part of the membrane, possessed of rudimentary villi, is designated the **chorion leve**, while the region with well-developed villous projections is distin-

guished as the **chorion frondosum** (Plate III., Figs. 1 and 2); the latter acquires a close relation with the mucous membrane of the uterus and becomes the fetal part of the placenta. The **villi** in their earlier condition are somewhat club-shaped elevations, which later become branched to form secondary villi. Each fully developed villus consists of a core of mesoblast, covered with ectodermic epithelium and containing blood-vessels (Fig. 44 and Plate IV., *a*). Their microscopic appearance is so characteristic that they afford a means of positively determining whether a mass discharged

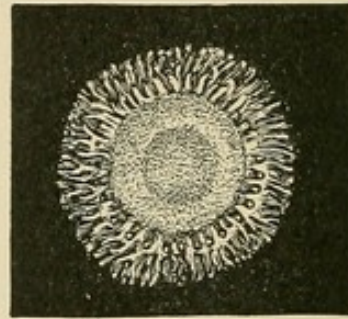
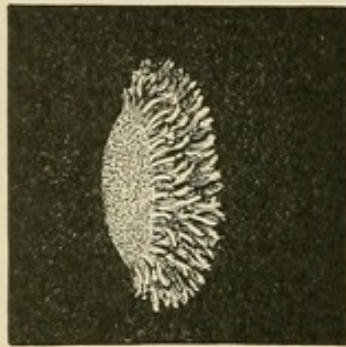


FIG. 39.—Human ovum of about twelve days (Reichert), side view.

FIG. 40.—Front view of ovum shown in Fig. 39.

In both figures the villi are limited in distribution, leaving the poles free.

from the uterus is or is not a product of conception. The further alterations in the villi as well as in the trophoblast in general, including the syncytium, will be considered in Chapter VI.

A chorion is present, as a rule, in those animals whose embryos develop within the uterus; this would include the entire class Mammalia, with the exception of the monotremes, whose eggs undergo extra-uterine development, and the marsupials, whose embryos, though nourished in the womb, never acquire villi on the serosa, nutriment being absorbed by simple contact of the latter with the uterine mucous membrane. The Mammalia are therefore divided into the **Achoria**, comprising the monotremes and marsupials, and the **Choriata**, including all other mammals.

## CHAPTER VI.

### THE DECIDUÆ AND THE EMBEDDING OF THE OVUM. THE PLACENTA. THE UMBILICAL CORD.

#### THE DECIDUÆ AND THE EMBEDDING OF THE OVUM.

THE deciduæ (deciduous or caducous membranes) are the hypertrophied mucosa of the uterus so developed as to form not only a lining for the uterine cavity, but also an envelope enclosing the ovum, and a specially altered part which serves as a bond of connection between the ovum and the womb.

During the four or five days preceding menstruation, the so-called **constructive stage** of the menstrual cycle, the mucous membrane of the womb becomes much thickened and unusually vascular, the purpose of these changes being evidently the preparation of the uterus for the reception of the ovum in the event of impregnation. If impregnation has not occurred, the thickened mucosa, the **decidua menstrualis**, is in great part cast off as a part of the menstrual discharge; if, on the other hand, conception has taken place, the mucous membrane undergoes still greater hypertrophy. On section, it is seen to consist of a **superficial compact stratum** and a **deeper spongy layer** reposing directly upon the muscular wall of the uterus. In the compact layer are the necks of the much

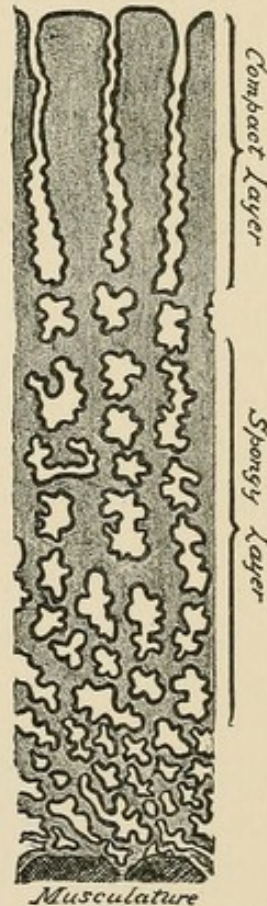


FIG. 41.—Cross section through the mucous membrane of the uterus at the beginning of pregnancy (after Kundrat and Engelmann).

enlarged uterine glands, while in the spongy layer are their greatly branched and often tortuous bodies (Fig. 41). The tortuosity and division of the deeper extremities of the glands produce the characteristic appearance of a section of the spongy stratum.

The alterations necessary to convert the **menstrual decidua** into the **deciduæ of pregnancy** take place in part while the ovum is still in the Fallopian tube; when it reaches the uterus it becomes attached to the mucous membrane of the latter, usually along the upper part of the posterior wall. A portion of the mucous membrane eventually comes to enclose the ovum as in a distinct envelope (Plate V., Fig. 1). The part of the uterine mucosa which thus surrounds the ovum is the **decidua reflexa**; the part still lining the cavity of the womb is the **decidua vera**; the part that is in contact with the chorion frondosum is the **decidua serotina**. The decidua serotina afterward becomes the **maternal part** of the placenta, intimately uniting with the chorion frondosum.

Until recently it was believed that the ovum became implanted *upon the surface* of the mucosa, and that the latter grew up around and over it to form the decidua reflexa. This theory has been completely set aside by the recent investigations of Peters of Vienna, whose results have been confirmed by Webster of Chicago. Peters' observations were made upon the gravid uterus of a suicide, the ovum being embedded in a triangular prominence on the upper median region of the posterior uterine wall. The ovum measured in three diameters respectively 1.6, 0.8, and 0.9 mm., its estimated age being three or four days.

The **embedding of the ovum** (Plate IV.), or its sinking into the mucosa, is quickly accomplished by the erosion of the superficial layers of the latter, presumably by the phagocytic action of the trophoblast. Actual erosion is evident from the absence of the surface epithelium at this place. The ovum is thus brought into relation with the deeper layers of the mucosa. The edges of the excavation are undermined, so that the ovum is partly covered by the mucosa, the area not thus covered being occupied by an organized blood clot,

PLATE IV.

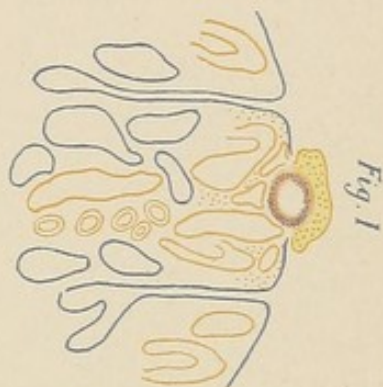


Fig. 1

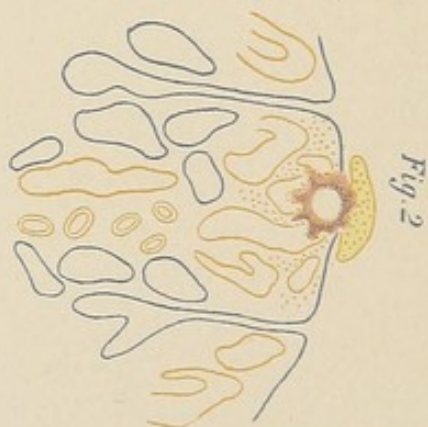
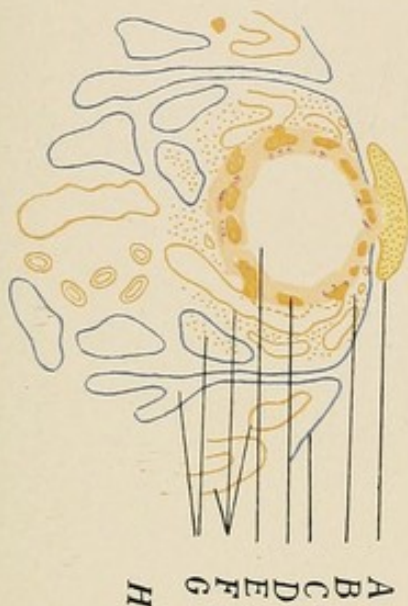

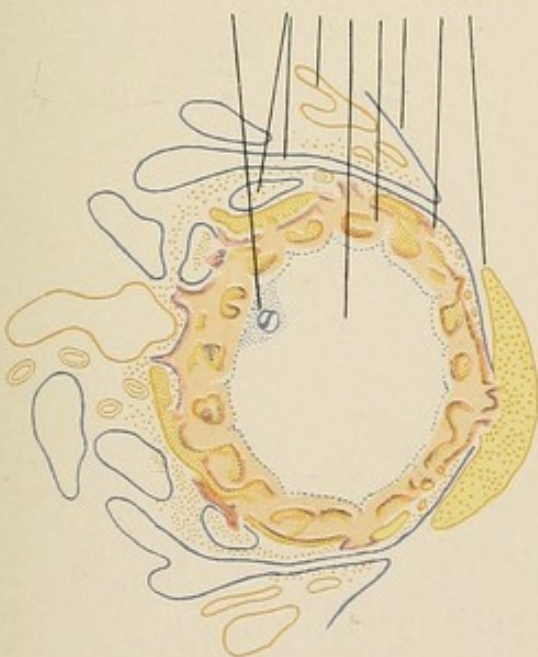
Fig. 2

Fig. 3.




A B C D E F G H

Fig. 4.



Schematic representation of the embedding of the ovum, the figures being enlarged about seven times (Peters): *A*, blood-clot or "tissue fungus" lying in contact with the ovum at the place where the latter has penetrated the mucosa; *B*, overhanging edge of mucosa, *i.e.* decidua reflexa; *C*, uterine surface epithelium; *D*, wall of blastodermic vesicle, consisting in part of trophoblast and syncytium; *E*, cavity of blastodermic vesicle; *F*, enlarged capillaries or "sinuses" of the mucosa; *G*, lumina of enlarged uterine glands, some of which contain blood; *H*, site of embryo.



the **tissue fungus** (Plate IV.). The overhanging edges of the excavation constitute the beginning of the reflexa, which is obviously, therefore, *not* produced by the upgrowth of a circular fold of mucosa. The trophoblast strands or early villi extend toward and into the serotina, to which some of them become attached. It is thought by Webster that they may absorb fluid and nutriment, and that by phagocytic action they open up the blood-spaces of the serotina, thus bringing them into communication with the lacunæ of the trophoblast.

The **blood-lacunæ** of the trophoblast form a system of intercommunicating spaces, the beginnings of the later intervillous spaces of the placenta; they are filled with maternal blood from the serotina, and are lined with syncytium (Fig. 43), the latter being thin in places and resembling an endothelium. There is no extension, however, of the endothelium of the serotinal vessels, either upon the villi or into the spaces (Peters and Webster).

The **syncytium** is the more or less irregular layer of nucleated protoplasm which appears upon the surface of the ovum toward the end of the first week, lining the trophoblast lacunæ, and later penetrating as irregular masses into the serotina, where it is found until the end of pregnancy. No traces of it are found on the vera after the sixth week. The origin of the syncytium has long been in dispute. Peters has shown that it results from the transformation of the superficial part of the trophoblast, probably from contact of the latter with maternal blood, which, he thinks, exercises a blending influence upon the trophoblast cells, so that as individual cells they disappear, the result being a non-cellular but nucleated protoplasm. Peters also believes that corpuscles of the maternal blood are appropriated by the syncytium, and that the latter, covering villi and chorion as it does, has something to do with the interchange of nutriment and waste products between the maternal blood and the ovum. What remains of the early trophoblast after the formation of the syncytium is the **layer of Langhans**.

The ciliated epithelium of the uterine mucous membrane disappears by the end of the first month of pregnancy (Minot);

somewhat later, that of the uterine glands is also lost. By the end of the fifth month the fetus and its appendages have increased in size to such an extent that they completely fill the cavity of the womb, and the space between the vera and the reflexa is obliterated. After the second month the vera becomes progressively thinner and the reflexa undergoes degenerative changes to such a degree that by the end of pregnancy merely remnants of it are present.<sup>1</sup> By the sixth month the vera is intimately blended with the chorion.

### THE PLACENTA.

The **placenta**, in certain groups of mammals, including man, is the organ of nutrition for the fetus during about the latter two-thirds of the period of gestation. In man, it is a discoid structure, attached by one surface to the wall of the womb, and connected on its opposite aspect with the fetus through the medium of the umbilical cord.

The **human placenta** represents the highest specialization of an apparatus for bringing the fetal blood into intimate relation with the blood of the mother. In eggs that develop outside of the body of the mother, such as those of reptiles, birds, and the lowest mammals, the Monotremata, the growing embryo necessarily acquires no connection with the uterine mucosa, but draws upon its original dower of nutriment, the deutoplasm, until its development is completed, when it breaks through the shell and seeks its own food; in these groups the chorion develops no villi. In the marsupials, a group of mammals higher than the monotremes, the ovum, although developing in the uterus, forms no close connection with it, but obtains its nourishment by simple imbibition from the uterine mucosa. On the other hand, in all mammals higher than monotremes and marsupials, the chorion is distinguished by the presence of villi upon its surface.

Between the human placenta and the non-villous chorion of the marsupials, certain gradations exist; for example, in pigs, whales, and some others, there is no proper placenta,

<sup>1</sup> Webster.

the villi being evenly distributed over the surface of the chorion; while in ruminants the villi are grouped into little clusters or tufts called **cotyledons**, which are easily detachable from the mucous lining of the womb. Owing to this loose connection, the uterine mucosa is non-deciduous—that is, it is not cast off after the birth of the young. The foregoing classes are therefore styled **Mammalia indeciduata**, in contradistinction to the **Mammalia deciduata**—including man, rodents, and Insectivora—in which there is a loss of the greater part of the uterine mucous membrane after the

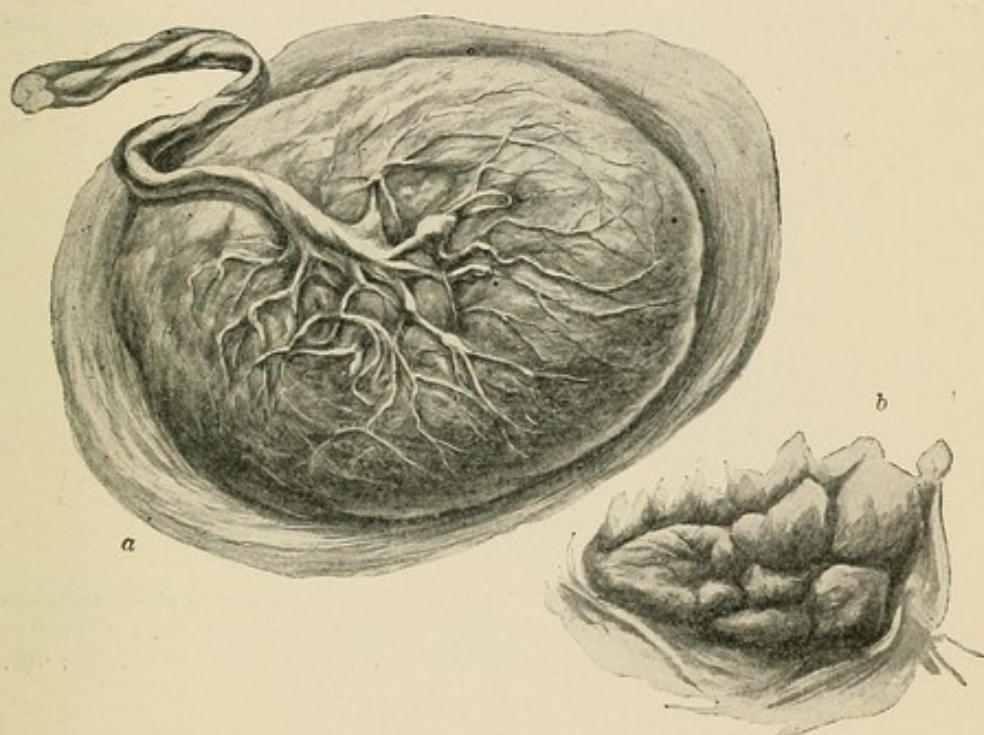


FIG. 42.—Mature placenta: *a*, entire organ, showing fetal surface with membranes attached to the periphery; *b*, a portion of attached surface.

expulsion of the fetus. In the Carnivora the placenta has the form of a zone or ring—**placenta zonaria**—while in man and certain allied mammals, as apes, rodents, and some others, it is discoid in shape—**placenta discoidea**.

The **human placenta** is formed in the third month of pregnancy; since it results from the union of the **chorion frondosum** with the **decidua serotina**, it consists of a **fetal** and a **maternal part**.

Our conceptions of the development of the placenta must be modified to accord with recent investigations. The em-

bedding of the ovum in the uterine mucosa and the modifications occurring in the chorion, including the growth of its villi and its differentiation into the chorion frondosum and the chorion leve, have been considered above. It will be recalled that the ovum eats its way, as it were, into the mucosa, thus causing the superficial layers of the latter to disappear at the site of implantation. It is possibly this process of erosion upon the part of the fetal trophoblast that opens up the already dilated capillaries of the serotina—the **sinuses**—and allows the maternal blood access to the blood-lacunæ of the trophoblast, where it thus bathes the primitive villi. Since the entire trophoblast is vacuolated,

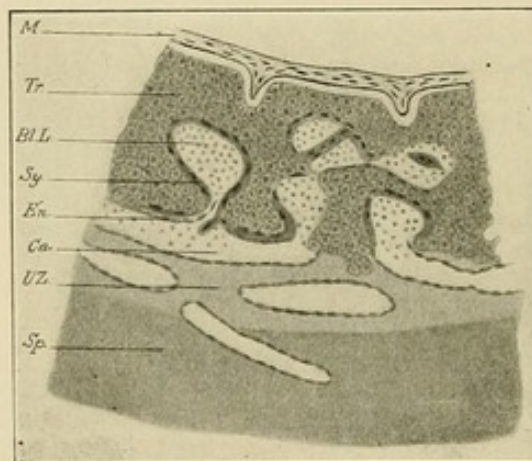


FIG. 43.—Schematic representation of the development of the placenta (after Peters): *M.*, mesoblast; *Tr.*, trophoblast; *Bl. L.*, blood lacunæ; *Sy.*, syncytium; *En.*, endothelium; *Ca.*, maternal capillaries; *UZ.*, circumvallation zone; *Sp.*, spongiosa of serotina.

the maternal blood at this time—the first week—is brought into relation with the whole surface of the chorion. In the latter half of the first month the distinction between chorion frondosum and chorion leve begins to be manifest, the villi of the latter gradually retrograding until, in the sixth week, they are greatly degenerated, many of them being without blood-vessels.

The villi of the chorion frondosum increase in size, number, and complexity, some of them acquiring attachment to the serotina, but not, as a rule, entering the serotinal blood sinuses. The formation of new villi continues throughout pregnancy. The villi acquire capillaries in the second week, these being

extensions of the allantoic blood-vessels. The syncytium of the chorionic lacunæ, now the intervillous spaces, increases in quantity, and not only lines the spaces, but exists in the form of masses, some of which become attached to the serotina between the villi, while others penetrate into it, many being found at the fourth month in the serotinal connective-tissue spaces.

The **decidua serotina** (basal decidua) in the first month is edematous and hyperemic, presenting dilated capillaries and blood-spaces, many of which communicate with the intervillous spaces of the chorion. By the sixth week its surface epithelium is entirely lost, and the parts of its glands contained in the compacta are to a great extent obliterated. In

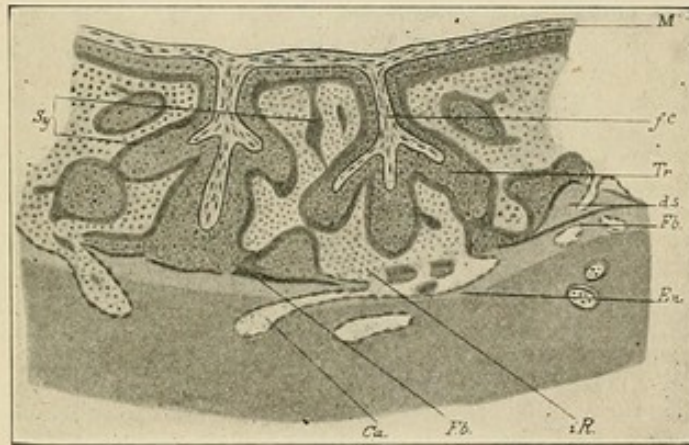


FIG. 44.—Schematic representation of the development of the placenta (after Peters): *M.*, mesoblast; *Tr.*, trophoblast; *Sy.*, syncytium; *En.*, endothelium; *Ca.*, maternal capillaries; *f.c.*, fetal capillaries; *d.s.*, decidua serotina; *Fb.*, fibrin; *i.R.*, intervillous space.

the fourth month it is thinner, more irregular in thickness, contains less sinuses, and shows degeneration in the compacta, with many masses of syncytium. Toward the end of pregnancy the sinuses increase in size, and the irregularity in thickness and the degeneration are more marked.

The **placenta at term** is a discoid mass, *in situ*, but less flattened after its expulsion from the uterus. Its diameter is from 15 to 20 and its thickness from 3 to 4 centimeters. The uterine surface is convex and irregular, and is imperfectly divided into tufts or cotyledons. The somewhat concave fetal surface, rather mottled, is covered by the loosely adherent amnion, and presents, usually near its center,

the attachment of the umbilical cord. The **maternal part** of the placenta, the **decidua serotina**, is of varying thickness, in some places being absent. Its compact layer shows fibrinous degeneration, very few traces of glands, and no epithelium. The blood-spaces, lined with endothelium and representing *greatly dilated capillaries*, are in communication with the intervillous spaces of the fetal placenta (Plate IV., *a*). Scattered throughout the serotina are masses of syncytium. In the shed placenta there is very little of the serotina, since *separation takes place through the compacta*, the spongiosa and a part of the compacta remaining upon the uterine wall.

The **fetal part** comprises almost the entire thickness of the cast-off placenta. It is made up of villi<sup>1</sup> of all ages and sizes springing from the chorion (some attached distally to the serotina, others projecting free into the intervillous spaces), and of masses of syncytium attached to both villi and chorion (Plate IV., *a*). The **intervillous spaces** are a system of intercommunicating cavities through which the maternal blood circulates and which are in communication with the blood-spaces of the serotina. Elevations of the serotina between the villi constitute the **septa placentæ**. The so-called **marginal sinus** at the periphery of the placenta is merely a system of intervillous spaces that intercommunicate more freely because of the relative paucity and small size of the villi in this region.

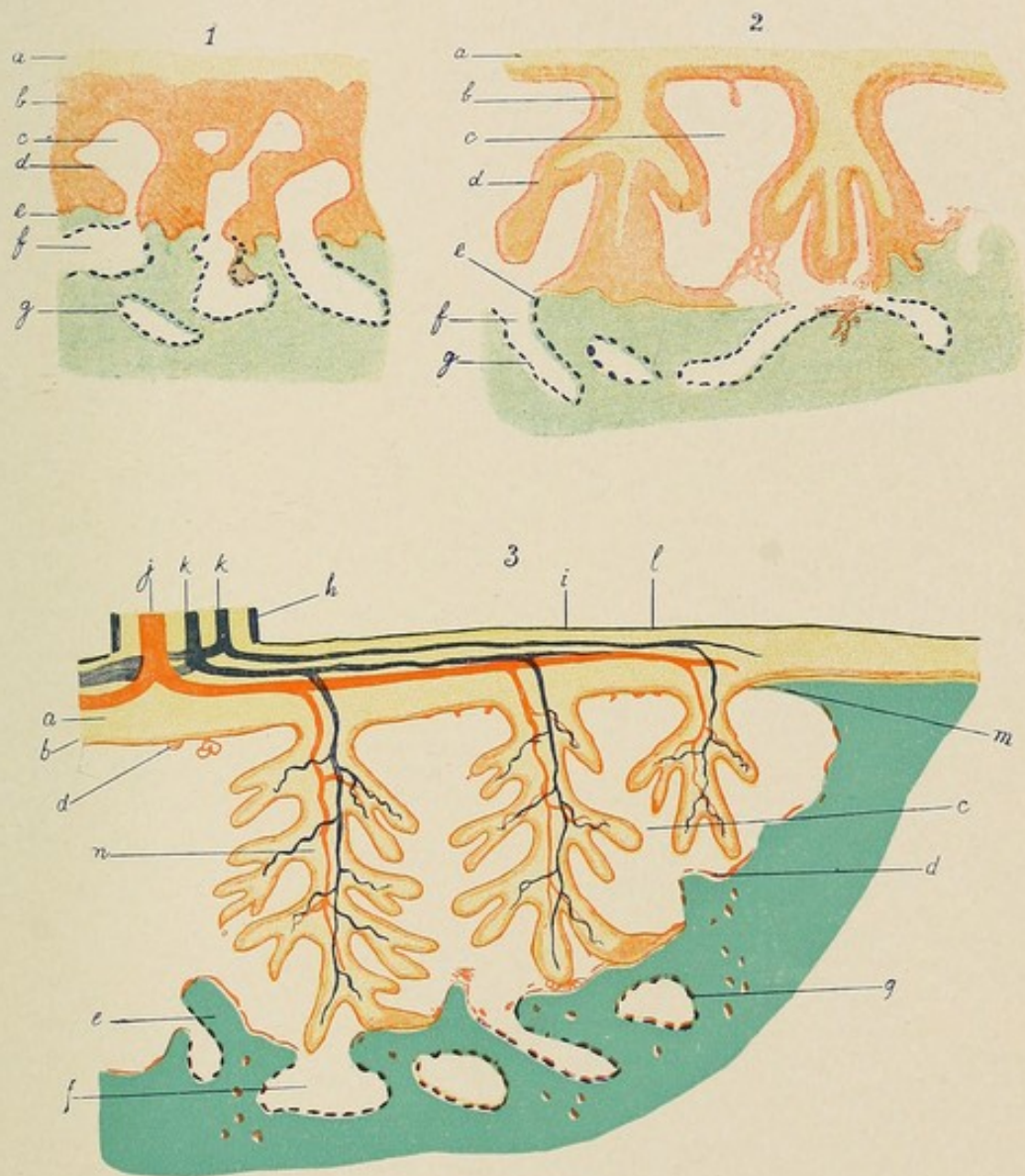
The **site of attachment of the placenta** to the uterus is usually the upper part of the posterior wall. Under certain circumstances it may become attached lower down, even extending partly or wholly over the mouth of the womb, constituting then the condition known as **placenta prævia**.

#### THE UMBILICAL CORD.


The blood-vessels through which the fetal blood finds its way from the fetus to the placenta and back again to the fetus, together with the atrophic vestiges of certain structures associated with the development of these vessels, constitute the structure known as the **umbilical cord**. In considering the growth of the human allantois it was pointed out that the

<sup>1</sup> For structure of villi, see pages 83, 84.

PLATE IV a.



Diagrammatic representation of relationship of ovum to decidua: 1, in latter half of first week; 2, a few days later; 3, a few months later, when placenta is well defined (Webster): *a*, fetal mesoblast, showing indications of beginning extension into trophoblast stalks in 1, actual extension in 2 and 3; *b*, trophoblast, being reduced in 3 and constituting here the layer of Langhans; *c*, trophoblast lacuna in 1, enlarged in 2 and 3 as an intervillous space; *d*, syncytium, seen in its earliest stage in 1; *e*, decidua; *f*, maternal blood-sinus; *g*, endothelium lining maternal sinus; *h*, epiblastic covering of cord; *i*, amniotic epiblast; *j*, umbilical vein; *k*, umbilical artery; *l*, amniotic mesoblast; *m*, extension of decidua on under surface of chorion at edge of placenta; *n*, large villus-stem.



latter structure, as it grows from the ventral wall of the gut-tract into the so-called allantoic or abdominal stalk, becomes the seat of development of the two allantoic arteries and of an equal number of allantoic veins. With the metamorphosis of the chorion frondosum into the fetal placenta, the abdominal stalk becomes more slender and at the same time much elongated, and the allantoic blood-vessels are henceforth the **umbilical vessels**. The two umbilical veins fuse, so that, at birth and for some time before, there is but one vein, though there are still two arteries. The **umbilical vein**, entering the body of the fetus through the umbilicus, passes directly to the under surface of the liver, where it unites with the fetal portal vein and gives off a branch of communication, the **ductus venosus**, to the inferior vena cava, after which it enters the liver through the transverse fissure. The **umbilical arteries**, whose intra-embryonic portions are called the **hypogastric arteries**, are the direct continuations of the superior vesical arteries of adult anatomy. They leave the body of the fetus at the umbilicus.

The umbilical cord, while consisting essentially of the three blood-vessels mentioned, contains also the remnant of the allantoic stalk and of the umbilical vesicle, these structures being surrounded and held together by a quantity of embryonic connective tissue, the **jelly of Wharton**, which makes up the chief part of the mass of the cord; upon the surface is a layer of epithelium, continuous, at the distal end of the cord, with the epithelium of the amnion.

The umbilical cord has an average length of 55 cm., or 22 inches, but varies between the extremes of 15 cm. (6 inches) and 160 cm. (64 inches); its thickness is about 1.5 cm. ( $\frac{3}{5}$  inch). The cord presents the appearance of being spirally twisted; it is probable, however, that the appearance of torsion is conferred by the spiral or coiled arrangement of its arteries, due to their excessive growth, rather than by a twist of its entire mass. There may be one or more true knots in the cord, produced by the slipping of the fetus through a loop.

The **position of attachment** of the cord to the placenta is

usually near, but seldom exactly in, the center of the fetal surface of that organ; rarely it may be found attached to its edge, and still more rarely to the fetal membranes themselves at some little distance from the edge of the placenta, with which, in the latter case, it is connected by its blood-vessels.

The **great length** of the human umbilical cord is thought to be due to the relatively large quantity of amniotic fluid present in the human subject.

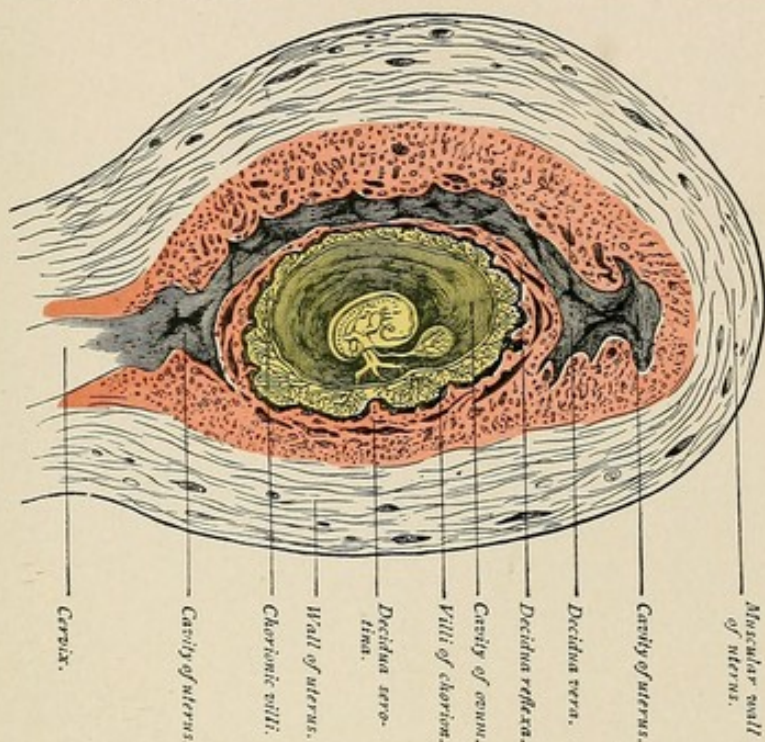
After birth, the portions of the hypogastric arteries extending from the upper part of the lateral wall of the bladder to the umbilicus undergo atrophy, becoming impervious fibrous cords; the intra-abdominal part of the umbilical vein likewise becomes atrophic and impervious, constituting the so-called **round ligament of the liver**.

#### RELATIONS OF THE FETAL MEMBRANES AT BIRTH.

When the amniotic fluid attains its maximum bulk—at about the end of the sixth month—it requires so much space that it presses the amniotic membrane closely against the chorion, which latter, covered by the remnants of the reflexa, is in turn forced into intimate relation with the vera (Plate V.). At term the vera and chorion have become practically one membrane. The amnion, while adhering to the inner surface of the chorion, is so loosely associated with the latter that it may be peeled off from it. The membranes, which constitute a fluid-filled sac surrounding the fetus, are ruptured by the contractions of the uterus at some time during parturition. Through this rent the child is forced during birth, the placenta and the membranes remaining behind. After the expulsion of the child, the vera and the placenta detach themselves from the uterine wall, and, with the chorion and the amnion, constitute the **after-birth**, which is expelled shortly after the expulsion of the child. The **separation** of the after-birth takes place in the compact layer respectively of the decidua vera and of the uterine placenta. The spongy layer and what remains of the compacta serve for the regeneration of the uterine mucosa.

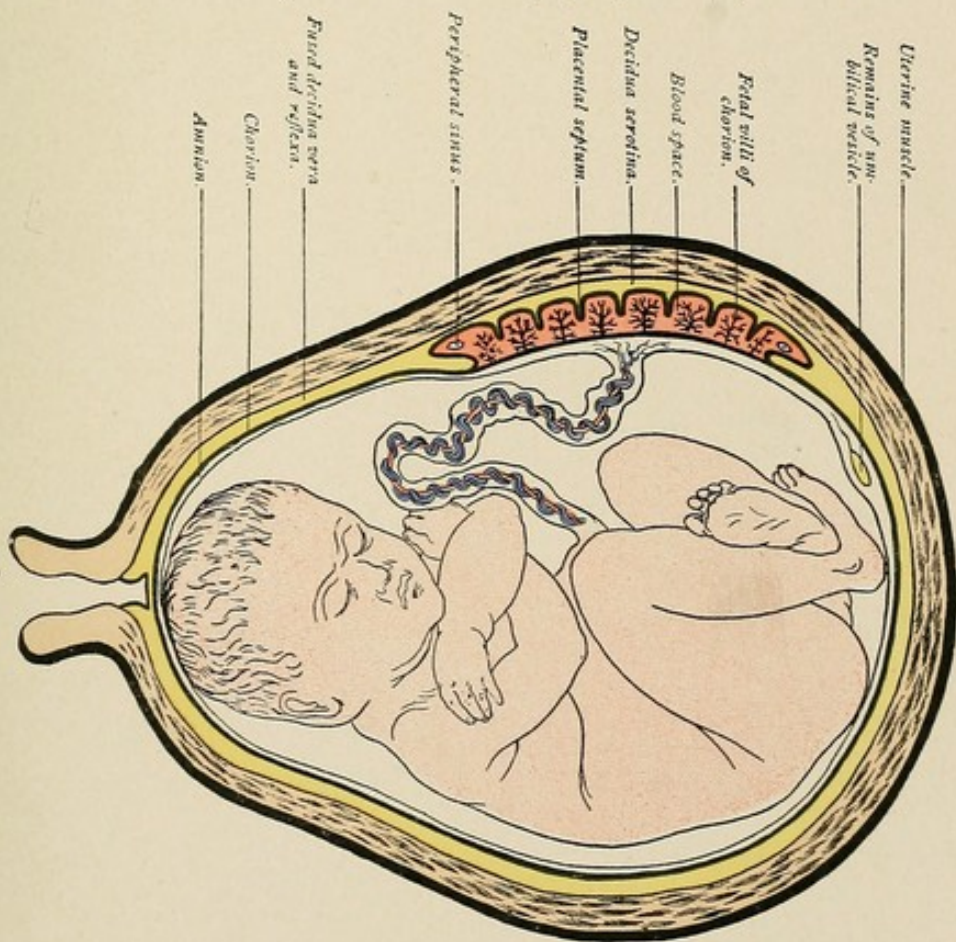
# PLATE V.

1




Muscular wall of uterus.  
Cavity of uterus.  
Decidua vera.  
Decidua reflexa.  
Cavity of ovum.  
Villi of chorion.  
Decidua serotina.  
Wall of uterus.  
Chorionic villi.  
Cavity of uterus.  
Cervix.

2



Uterine muscle.  
Remains of umbilical vesicle.  
Fetal villi of chorion.  
Blood space.  
Decidua serotina.  
Placental septum.  
Peripheral sinus.  
Fused decidua vera and reflexa.  
Chorion.  
Amnion.

1. Semi-diagrammatic section of gravid uterus, showing contained ovum of about five weeks (modified from Allen Thomson). 2. Semi-diagrammatic section of uterus, showing relations of fetal and maternal placenta (Ahlfeld).



## CHAPTER VII.

### THE FURTHER DEVELOPMENT OF THE EXTERNAL FORM OF THE BODY.

HAVING traced the growth of the germ to the time when the body of the embryo becomes definitely differentiated from the embryonic appendages or fetal membranes, the development of the individual organs and tissues may be taken up. The discussion of this latter subject, especially of that part of it pertaining to the structures on the exterior of the body, involves a consideration of the external form of the embryo and fetus during the successive stages of growth.

In the preceding chapters it was pointed out that the cells of the segmented ovum arranged themselves in such a manner as to form a **hollow sphere**, the **blastodermic vesicle** (Plate I.); that this vesicle, having at first a **single-layered wall**, came to consist of **two layers of cells**, the **ectoderm** and the **entoderm**; and that, finally, a third, intervening layer, the **mesoderm**, made its appearance. It was shown, further, that the thickened portion of the vesicle wall, the **embryonic area**, became more and more differentiated from the remainder, and that, by certain processes of folding, this area was made to assume the definite form of the **embryonic body**, while from the other parts of the vesicle-walls the **fetal membranes** were produced (Plate II.). It may be well to remind the reader again that when the body of the embryo has become closed off from the fetal membranes, **this body** is an irregularly tubular structure whose walls are the somatopleure and whose enclosed space is the body-cavity, and that within it are two other tubes, a larger, the gut-tract, formed by the splanchnopleure, and a smaller ectodermic tube, the neural canal.

While, as a matter of convenience, the description of

the individual organs is taken up after tracing the course of development to this stage, it should be borne in mind that the rudiments of some of them are already distinguishable before the germ-layers become infolded to form the body-wall and the gut-tract. It will facilitate a comprehension of the general principles concerned in the origin of the different parts of the body to refer to the tabulated statement of the derivatives of the three primary germ-layers as presented in Chapter III.

In considering the **external form** of the product of conception, one may adopt the classification of His, referred to in the first chapter. This author divides the period of development into three stages, of which the *first*, the **stage of the ovum**, or the **blastodermic stage**, comprises the first and second weeks of intra-uterine growth; the *second*, the **stage of the embryo**, extends from the second to the fifth week; and the *third*, or the **fetal stage**, includes the time between the fifth week and the end of gestation.

#### THE STAGE OF THE OVUM.

During the fortnight allotted to this first stage of development occur the various changes by which the impregnated ovum acquires the form of a hollow sphere, designated the embryonic or blastodermic vesicle. The series of transformations has been described in Chapter II. In this place it will be sufficient to refer to the external characters of the **blastodermic vesicle** as depicted in Figs. 39, 40, which represent the ovum described by Reichert. This ovum was estimated to be about twelve days old, and was one of the youngest human ova ever described. Its **form** was that of a sphere somewhat flattened, its short and long diameters measuring respectively 3.3 mm. and 5.5 mm. The **flattened surfaces** were smooth, while the **equatorial zone** was beset with villi. The early appearance of villi is characteristic of the human ovum.

#### THE STAGE OF THE EMBRYO.

It is during the early part of the second stage, at about the fourteenth day, that the somatopleuric layer of the blasto-

dermic vesicle becomes folded in to produce the walls of the embryonic body. Fig. 46 shows a human embryo of about the fifteenth day, whose form is as yet imperfectly differentiated, the ventral wall of the body being incomplete, since the gut-tract is still in communication with the umbilical vesicle throughout almost the entire length of the embryo. The back and sides of the embryo are enveloped by the amnion, and the dorsal outline is concave. The caudal pole

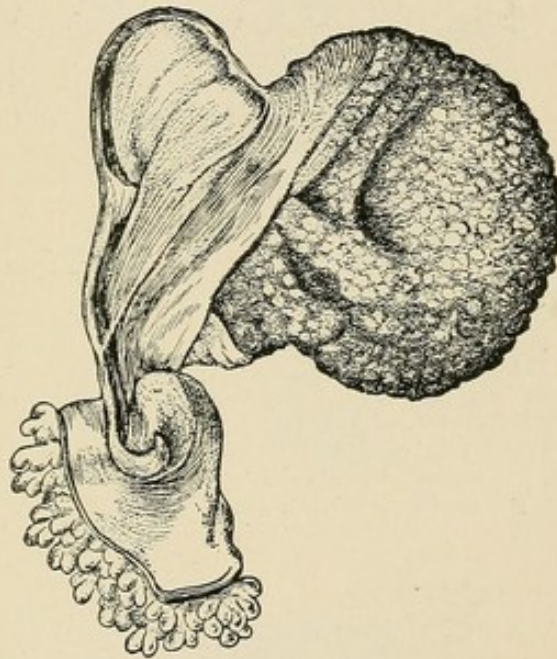


FIG. 45.—Human embryo of about the thirteenth day (His). The caudal pole of the embryo is connected with the blastodermic vesicle by means of the abdominal or allantoic stalk; the amnion already completely encloses the embryo, and the large vitelline sac communicates throughout the greater part of the mitral surface by means of the unclosed gut-tract.

is seen to be connected by means of the allantoic stalk with the primitive chorion, which latter structure, however, is not represented in the figure. The concavity of the dorsal outline is peculiar to the human embryo of this stage. The development of the head is closely associated with the dilatation of the cephalic end of the neural tube and the subsequent division of this dilated extremity into the three primary brain-vesicles, the fore-brain, the mid-brain, and the hind-brain. The oral pit, the first indication of the future mouth, is present in the early part of this stage; it is a depression

between the prominent fore-brain vesicle and the cardiac dilatation (Fig. 47).

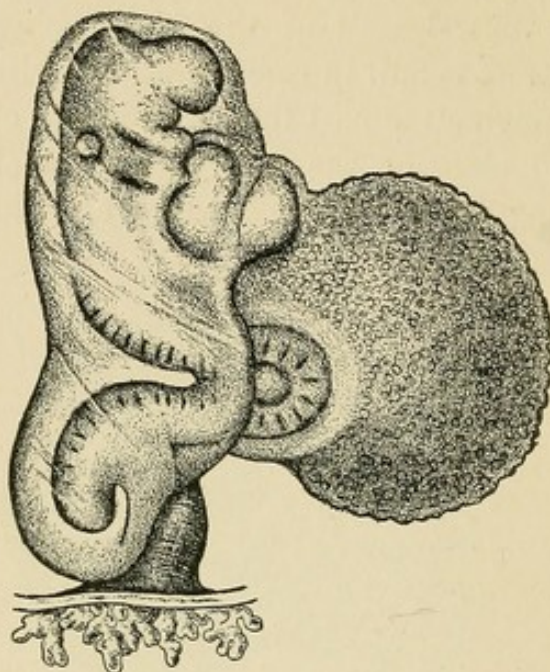


FIG. 46.—Human embryo of about the fifteenth day (His). The embryo is attached to the wall of the blastodermic vesicle by means of the umbilical or allantoic stalk, and is enclosed within the amnion; the large vitelline sac freely communicates with the still widely open gut.

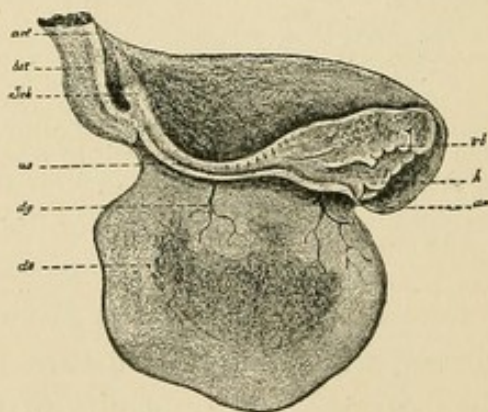


FIG. 47.—Human embryo with yolk-sac, amnion, and belly-stalk of fifteen to eighteen days (after Coste). The chorion is detached at *am'*: *am*, amnion; *am'*, the point of attachment of the amnion to the chorion drawn out to a tip; *bst*, belly-stalk; *Sch*, tail-end; *us*, primitive segment; *dg*, vitelline blood-vessels; *ds*, yolk-sac; *h*, heart; *vb*, visceral arch.

Between the fifteenth and the twenty-first day, the **lens-vesicles** and the **otic vesicles** are formed by invaginations of the surface ectoderm (Fig. 48, 7 and 8), these sacs being

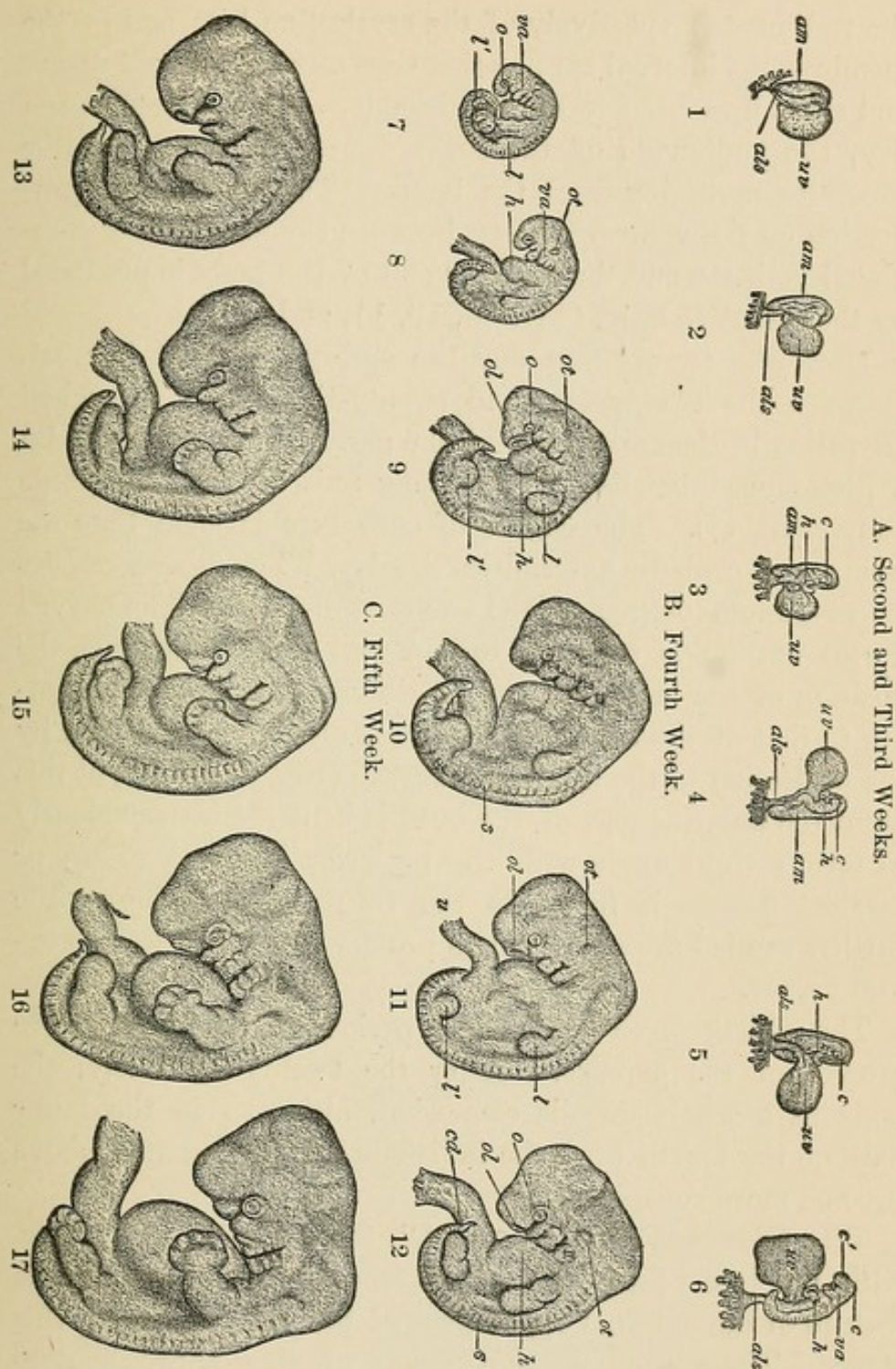


FIG. 48.—Early human embryos, all enlarged about two and a half times (His): 1-4, from twelfth to fifteenth day; 5, 6, from eighteenth to twenty-first day; 7, 8, from twenty-third to twenty-fifth day; 9-12, from twenty-seventh to thirtieth day; 13-17, from thirty-first to thirty-fourth day. *am*, amnion; *uv*, umbilical or vitelline vesicle; *als*, allantoic or abdominal stalk; *c*, *c'*, brain-vesicles; *h*, heart; *va*, visceral arches; *o*, optic vesicle; *ot*, otic vesicle; *ol*, olfactory pit; *l*, *l'*, upper and lower extremities; *s*, somites; *cd*, caudal process; *u*, primitive umbilical cord.

the rudiments respectively of the crystalline lens and of the membranous internal ear; at this time also the **visceral arches** and **clefts** first become distinguishable. On the twenty-first day, the rudiments of the **limbs** appear as little bud-like processes springing from the trunk. The conspicuous projection on the ventral surface between the now almost completed yolk-sac and the cephalic end of the body is produced by the **primitive heart** (Fig. 48, 10, 11, and 12).

Until the twenty-first day the embryonic body is **erect**. Between the twenty-first and twenty-third days a marked alteration in the appearance of the germ is brought about by a pronounced bending of the long axis of the embryonic body (Fig. 48). The degree of curvature is such that the caudal and cephalic extremities overlap. The **flexion** reaches its maximum degree by the twenty-third day. The curved dorsal outline is referable to four well-marked flexions, the position of the most anterior, or **cephalic flexure**, corresponding to that of the future sella turcica and being indicated by the projection of the mid-brain vesicle (Fig. 51, III.); at this point the anterior part of the head is bent almost sufficiently to form a right angle with the posterior half. A second or **cervical flexure** is found in the future neck-region, while further caudad are seen the less pronounced **dorsal** and **coccygeal curves**.

The fourth week marks the period of the most active growth of the embryo. After the twenty-third day, the body as a whole uncoils somewhat, although in the latter half of the fourth week the individual flexures noted above become more conspicuous.

**The Visceral Arches and Clefts.**—The **visceral arches**, with the intervening **visceral clefts**, constitute a conspicuous feature of the external appearance of the embryo during this stage. These arches are a series of five approximately parallel ridges appearing upon each side of the future neck-region and extending obliquely downward and forward toward the ventral surface of the embryo (Figs. 49 and 51). The four furrows lying between the five visceral arches are the **visceral clefts**. A coronal section of the neck-

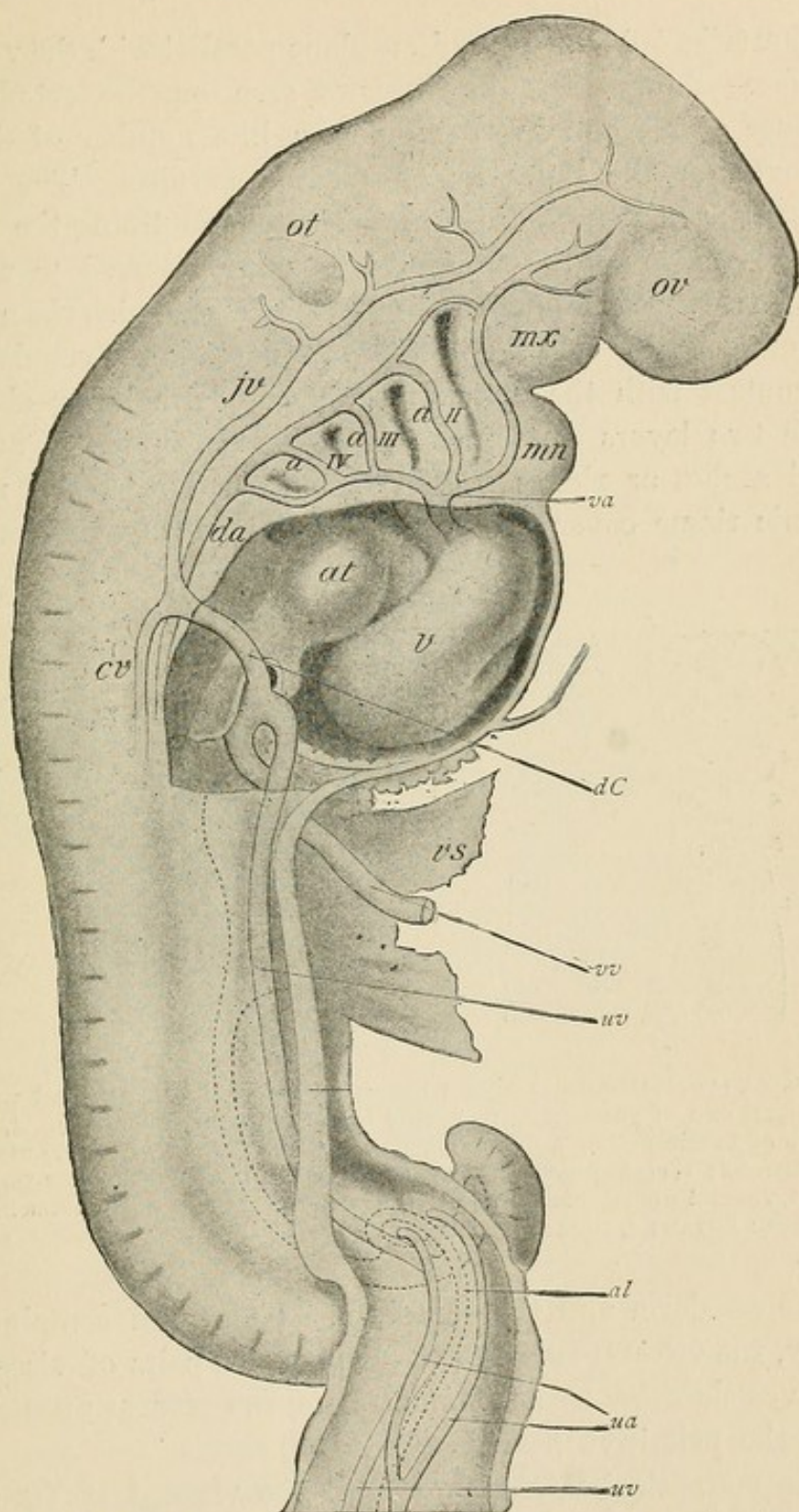


FIG. 49.—Human embryo of about three weeks, showing visceral arches and furrows and their relations to aortic arches (His): *mx*, *mn*, maxillary and mandibular processes of first visceral arch; *a I-a IV*, first to fourth aortic arches; *fv*, *cv*, primitive jugular and cardinal veins; *dC*, duct of Cuvier; *at*, *v*, atrium and ventricle of primitive heart; *vs*, vitelline sac; *va*, *da*, ventral and dorsal aortæ; *ov*, *ot*, optic and otic vesicles; *uv*, *ua*, umbilical veins and arteries; *vv*, vitelline vein; *al*, allantois.

region (Fig. 50)—a section in a plane parallel with the ventral surface—shows that the furrows seen on the ectodermic surface correspond in position to a like number of deeper grooves on the inner or entodermic surface. The inner furrows are out-pocketings of the entoderm lining the pharyngeal region of the fore-gut; they are referred to as the **pharyngeal pouches** or **throat-pockets** to distinguish them from the outer clefts. At the bottom of the clefts the ectoderm is in contact with the entoderm, the mesoderm being absent; these two layers constitute the **closing membrane**. The visceral arches or ridges consist of thickened masses of mesodermic tissue covered outwardly and inwardly respectively

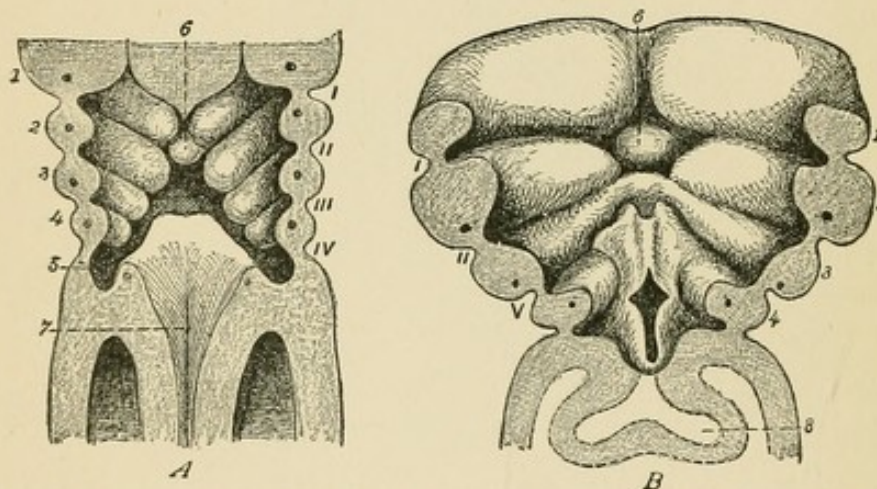


FIG. 50.—Coronal sections of two human embryos, showing ventral wall of pharyngeal end of gut-tract from behind (from Tourneux, after His). *A*, from embryo of 3.2 mm.; *B*, of 4.25 mm. (about 25 to 30 days). *I*, *II*, *III*, *IV*, outer visceral furrows; *V*, sinus præcervicalis, comprising third and fourth outer furrows; 1, 2, 3, 4, visceral arches, each with its visceral-arch vessel; 6, tuberculum impar; 7, orifice of larynx; 8, pulmonary evagination.

by the ectoderm and the entoderm. Each arch contains an artery, the **visceral-arch vessel**. These five pairs of visceral-arch vessels arise by a common stem, the **truncus arteriosus**, from the primitive heart.<sup>1</sup>

The morphological significance of the visceral arches and clefts may be appreciated by a comparison of the conditions obtaining in lower types. While in birds and mammals the

<sup>1</sup> For an account of the metamorphosis of the visceral-arch vessels into the adult arteries of the throat and neck the reader is referred to Chapter X.

number of the clefts is four, in reptiles, amphibians, and bony fishes, five clefts appear, and in some fishes (selachians) the number is six. In all aquatic vertebrates, the thin epithelial closing membranes rupture, thus establishing communications between the alimentary tract and the exterior, through which openings water passes in and out. The margins of the clefts—except the first or hyomandibular cleft—become the seat of a rich supply of capillary blood-vessels, the blood of which obtains oxygen from the water and yields to the latter its carbon dioxid; while the visceral arches, excluding the first and second, become known in these classes as **branchial arches** from their producing bony arches which support the branchiæ or gills. With the exceptions noted, the visceral arches and clefts with their capillary plexuses therefore functionate in these classes as a respiratory apparatus.

When, in the course of evolution, certain of the vertebrates assume an aerial existence, in consequence of which they acquire a breathing mechanism adapted to such a mode of life, the respiratory function of the clefts or branchiæ ceases, and they either disappear entirely or constitute merely rudimentary structures of the adult. The so-called clefts in **man** are never actual openings, the closing membrane always being present (His, Kölliker, Piersol, Born). To express the morphology of the visceral clefts briefly, they are permanent structures in fishes and in tailed Amphibia; they are present during the larval stage of other Amphibia, while in birds and mammals they are found only in embryonic life.

The growth of the visceral arches and clefts bears an intimate relation to the differentiation of the head- and the neck-regions of the embryo. They first make their appearance at about the twenty-third day and attain their greatest development by the end of the fourth week. Both the arches and the clefts appear earliest and are best developed at the cephalic end of the series, the fifth arch being exceedingly ill-defined. During the fifth week the obliteration of the arches and clefts as such begins, since certain of them become metamorphosed into permanent structures while the remainder undergo regression.

**The Metamorphosis of the Visceral Arches and Clefts.**—The first visceral arch becomes divided into an upper part, the **maxillary arch**, and a lower portion, the **mandibular** or **jaw-arch** (Fig. 51). The maxillary arches or processes of the two sides unite, at their anterior ends, with the intervening **nasofrontal process** (Fig. 56), and in this way is formed the upper boundary of the mouth-cavity; the mandibular processes become joined with each other anteriorly and constitute the inferior boundary of this cavity. The maxillary processes become the superior maxillæ, while the mandibular processes become the lower jaws. The mesodermic core of the mass of tissue constituting the mandibular arch divides into three sections, of which the two situated at the proximal end of the arch are quite small and give rise respectively to the incus and the greater part of the malleus; the large distal segment is a slender cartilaginous rod, **Meckel's cartilage**, whose proximal extremity becomes the *processus gracilis* of the malleus (see Chapter XVIII.).

The **second visceral**, or **anterior hyoid arch** becomes obliterated as such, although a bar of cartilage which it contains—**Reichert's cartilage**—gives rise by its proximal extremity to the stapes,<sup>1</sup> while the remaining portion becomes metamorphosed into the styloid process, the stylohyoid ligament, and the lesser cornu of the hyoid bone.

The **third** or **posterior hyoid arch**, which corresponds with the **first branchial arch** of fishes, likewise loses its identity as a surface marking, while the **bar of cartilage** it contains becomes the body and greater cornu of the hyoid bone.

The **fourth** and **fifth arches** coalesce with the adjacent tissues, producing no special structures.

The **first outer cleft**, known as the **hyomandibular cleft**, suffers obliteration except at its dorsal extremity, where the tissues forming its margins produce the external ear. The **remaining three outer clefts** disappear in the following manner: the **fourth outer cleft** becomes covered and hidden by the fourth arch, and the **third** and **second clefts** are successively

<sup>1</sup> Reichert, Gegenbaur, Hertwig; or to the ring of the stapes according to Salensky, Gradenigo, and Rabl.

buried by the growth of the third and second arches. The sinking-in of the lower arches and clefts (Fig. 50) results in

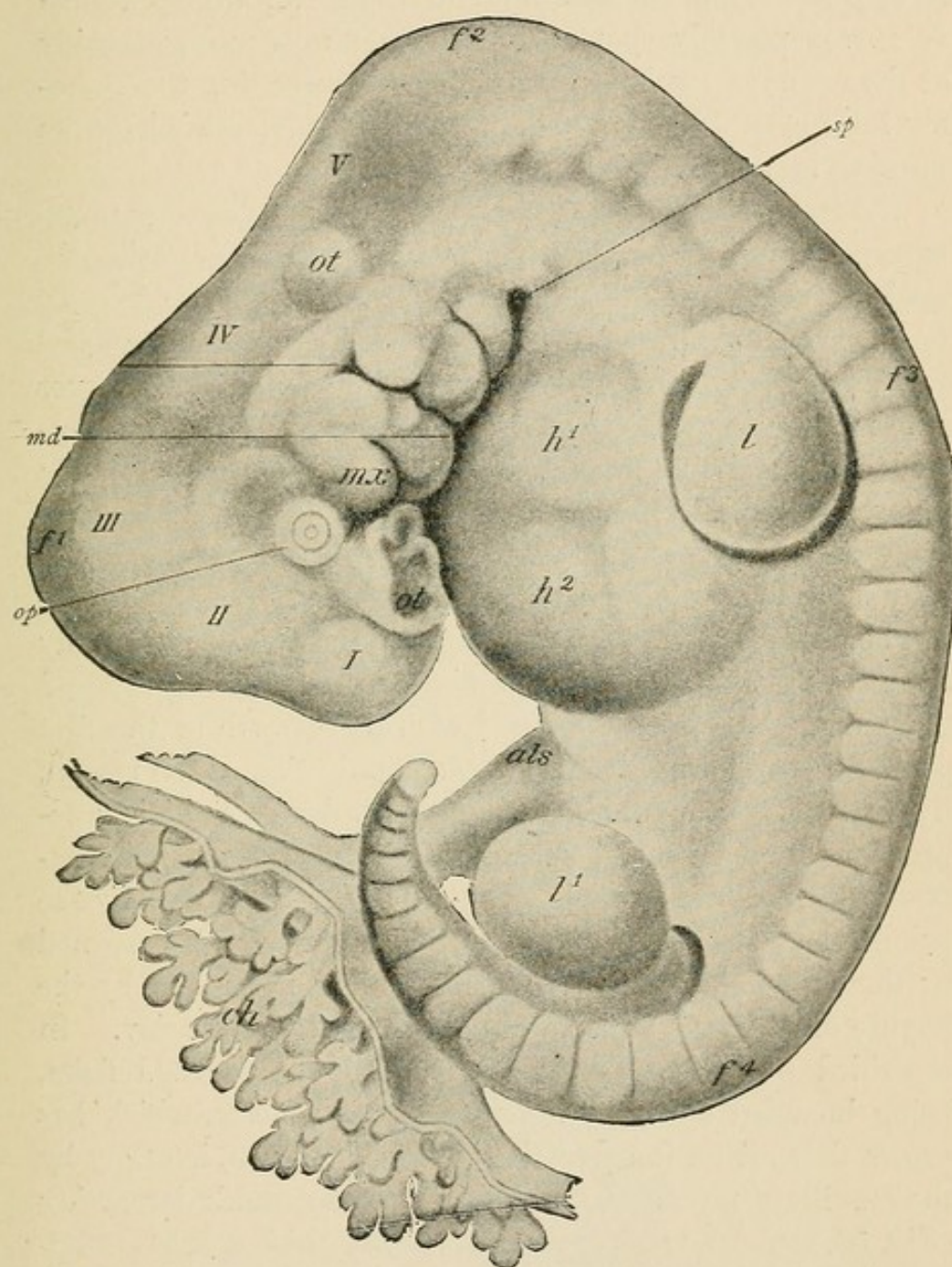


FIG. 51.—Human embryo of about twenty-eight days (His): I-V, brain-vesicles;  $f^1, f^2, f^3, f^4$ , cephalic, cervical, dorsal, and lumbar flexures; *op*, eye; *ot*, otic vesicle; *ol*, olfactory pit; *mx, md*, maxillary and mandibular processes of first visceral arch; *sp*, sinus præcervicalis;  $h^1, h^2$ , heart; *l, l^1*, limbs; *als*, allantoic stalk; *ch*, villous chorion.

the formation of a fossa or fissure on the lateral surface of the neck, the sinus præcervicalis (Fig. 51, *sp*), which subsequently

is made to disappear by the coalescence of its edges. Occasionally this sinus, instead of becoming completely obliterated, persists, and the thin layer of tissue forming its bottom ruptures—possibly spontaneously or perhaps more probably as the result of exploratory probing—constituting the anomaly known as **cervical fistula**. Such a fistula establishes an opening into the esophagus.

The **first inner cleft** or **first pharyngeal pouch** becomes metamorphosed into the middle ear and the Eustachian tube, the **closing membrane**, which separates it from the outer cleft, forming the *membrana tympani*. The **second pharyngeal pouches** produce no special structures, but the adjacent tissues give rise to the epithelial parts of the middle lobe of the thyroid body and to the posterior third of the tongue, in the manner more fully indicated on pp. 131 and 207. The **third inner cleft** produces the thymus body, while from the **fourth** results the lateral lobes of the thyroid body.

The **configuration of the face**, depending as it does so largely upon the development of the boundaries of the nose and of the mouth, is closely associated with the growth of the first pair of visceral arches. The earliest indication of the mouth, the **oral pit**, appears at about the twelfth day as a shallow depression on the ventral surface of the embryonic body between the fore-brain vesicle and the prominence caused by the primitive heart (Fig. 48, 3 to 5). This depression is deepened by the growth of the tissues surrounding it, as also by the flexure of the head, which occurs at the twenty-first day. In the third week, therefore, the oral pit is a five-sided fossa, being bounded above by the nasofrontal process, which has grown down from the elevation of the fore-brain, laterally by the maxillary processes, and below by the mandibular arches (Fig. 56, A). The **pharyngeal membrane**, which consists of opposed ectoderm and entoderm and which separates the primitive oral cavity from the gut-tract (Fig. 55, *rh*), ruptures at the time of the appearance of the third branchial arch.

By the end of the third week, the communication between the yolk-sac and the gut-tract has become reduced to the relatively small vitelline duct. At the twenty-fifth day the

embryo presents a well-developed tail. By the **termination of the fourth week** the yolk-sac has attained its maximum size, and the presence of the somites is indicated by transverse parallel lines on the dorsal surface of the body.

#### THE STAGE OF THE FETUS.

This stage comprises the time between the beginning of the second month and the end of pregnancy.

During **the second month** the rate of growth is far less rapid than in the preceding stage. The marked curvature of the long axis of the body gradually diminishes, the embryo assuming a more erect posture. Owing to the partial disappearance of the cervical flexure, the head becomes raised.

During the **fifth week** the vitelline duct is seen to be long and slender; the umbilical cord has become longer and more spiral, and may contain a coil of intestine; the abdomen is very prominent, and in the neck-region is a characteristic dorsal concavity. At this time also the **nasal pits** become conspicuous as depressions situated on either side of the nasofrontal process (Fig. 56). The **nasofrontal process** meanwhile undergoes differentiation into the **globular processes**, which constitute the inner boundaries of the nasal pits, and the **lateral frontal processes**, which limit these depressions exter-

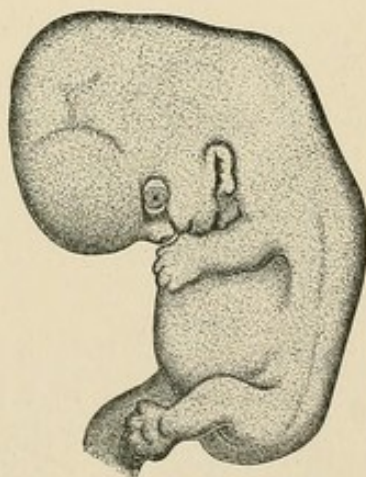


FIG. 52.—Human embryo of about six weeks, enlarged three times (His).

nally and separate them from the depressions for the eyes. The nasal pits are still in communication below with the

primitive oral cavity. The **lacrimal groove** is well-marked at this stage, and the external auditory meatus is indicated. The **mandibles** become united mesially at about the thirty-fourth day. The third and fourth gill-clefts have by this time disappeared in the cervical sinus. The paddle-like **limb-buds** have lengthened and present, at first, a division into two segments, of which the distal is destined to become the hand or foot, while the proximal portion undergoes segmentation a little later into the arm and forearm or thigh and leg; by the **thirty-second day**, the hand, now showing differentiation into a thicker proximal and a thinner terminal part, exhibits the first traces of digitation, in the form of parallel longitudinal markings which soon become grooves and, later, clefts. The development of the upper extremities precedes that of the lower by twelve or fourteen days.

During the **sixth week** the head assumes more nearly its normal position, and for this reason the apparent length of the fetus is considerably increased, the dorsal concavity in the neck-region being almost obliterated; the rudiments of the **eyelids** and of the **concha** become recognizable, and the various parts of the face assume more definite shape. By the **fortieth day** the oral cavity has become separated from the nasal pits by the union of the nasofrontal process with the maxillary processes, and the external boundaries of the nostrils have become marked out by the meeting of each lateral frontal process with the corresponding maxillary process. As a result of these changes, the **nose**, although still very broad, begins to assume characteristic form. During this week also the **fingers** are seen as separate outgrowths, while in the **seventh week** the rudiments of their nails become evident.

Toward the end of the second month—about the **fiftieth** to the **fifty-third day**—the toes are just beginning to separate, the protrusion of the intestine at the umbilicus is at its maximum, the palpebral conjunctiva separates from the cornea, and the rudimentary tail begins to disappear.

The **eighth week** witnesses the total disappearance of the free tail, the formation of the septum that divides the

cloaca into the rectum and the genito-urinary passage, and the presence of the projecting genital tubercle with the accompanying genital folds and genital ridges. The external genitals as yet show no distinction of sex. From the end of the second month to the time of birth, fetal growth is, in great measure, merely the further development of organs already mapped out; it is held by many authorities, therefore, that if malformations are ever due to **maternal impressions**, such impressions could be operative only in the event

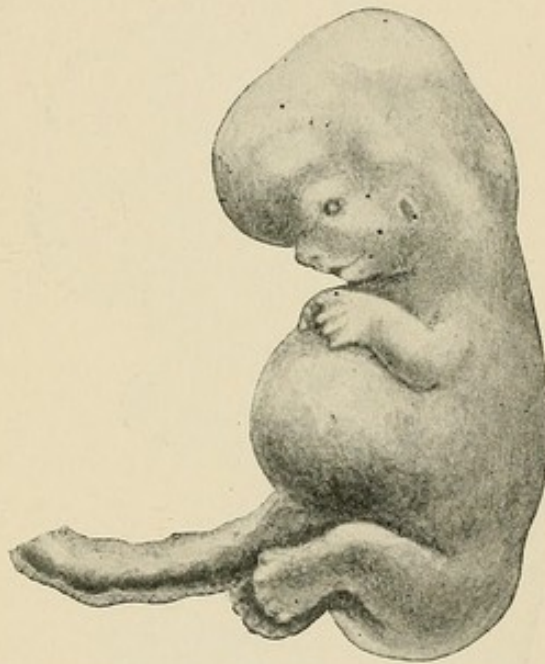

FIG. 53.—Human embryo of about seven weeks, enlarged three times.

of having been received prior to the eighth week of gestation.

During the **third month**, the face, although definitely formed, still presents thick lips, a pointed chin, and a rather broad and triangular nose. At this time the limbs are well-formed and assume a characteristic attitude, and the fingers and toes are provided with imperfect nails. The external genitals, which, until the close of the second month, preserved the indifferent type, now begin to show sexual distinction.

In the **fourth month**, a growth of fine hair, the **lanugo**, appears upon the scalp and some other parts of the body;

the anus opens ; the intestine recedes within the abdomen ; and the external generative organs present well-marked sexual characteristics.

The **fifth month** marks the inauguration of active fetal movements and the appearance of a more plentiful growth of colorless hair.

In the **sixth month** the fetal body becomes coated with the **vernix caseosa**, a modified sebaceous secretion whose func-

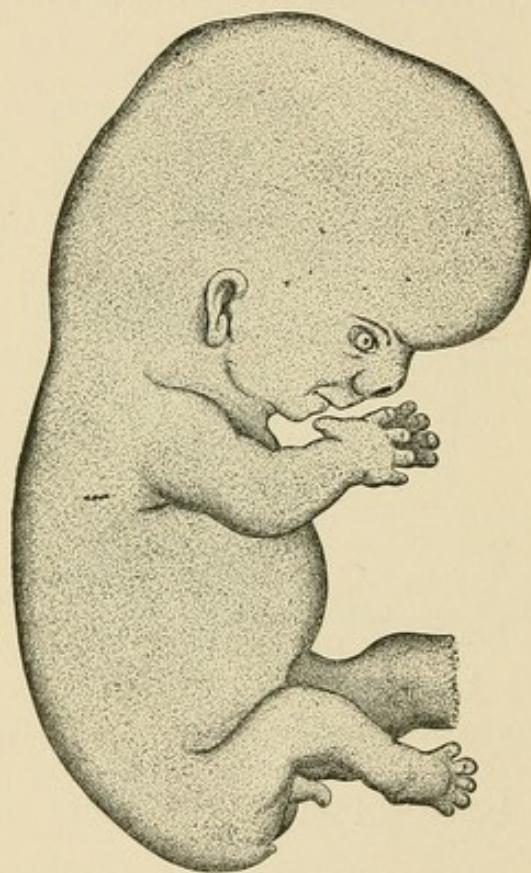


FIG. 54.—Human embryo of about eight and a half weeks, enlarged three times (His).

tion is the protection of the epidermis from maceration in the amniotic fluid. The eyebrows and eyelashes also appear about this time.

The **seventh month** witnesses the appearance of the **lanugo**, or embryonal down, upon practically the entire surface of the body ; the testes of the male fetus are in the inguinal canal or at the internal abdominal ring ; and the nails break through their epidermal covering. Children born at

the end of the seventh month may survive, but usually they do not.

In the **eighth month** the lanugo begins to disappear.

In the **ninth month** the testicles are found in the scrotum, while, in the case of the female, the labia majora are in contact with each other. The contents of the intestinal canal, the **meconium**, consisting of intestinal and hepatic secretions mingled with epidermal cells and hairs swallowed by the fetus, is now of a dark greenish color. The umbilicus is almost exactly in the middle of the body.

The **weight of the fetus** at full term is from 3 to 3.5 kilograms (from 6 to 7 pounds), the average weight of the male child being about ten ounces greater than that of the female. While variations from these figures are not uncommon, statements of excessive weight are to be received with reservation, since it has been found, upon careful observation by competent authorities, that the weight of a new-born infant rarely exceeds ten pounds. The weight of the child, besides depending upon the physical condition of both parents, is influenced by the age of the mother, young women having the smallest, and women between the ages of thirty and thirty-five having the heaviest children; by the number of previous pregnancies, the weight being greater with each succeeding pregnancy, provided the successive children are of the same sex and are not born at too short intervals; and also by the weight (Gassner) and height (Frankenhaüsen) of the mother, the ratio being a direct one. Minot believes that these various influences operate chiefly by prolonging or abbreviating the period of gestation, and that therefore the variations in weight at birth are referable to two principal causes—differences in the age at birth, and variations in the rate of intra-uterine growth.

The **length of the fetus** at the time of birth is about 50 centimeters (20 inches).

The **approximate age of an embryo or fetus** may be estimated by the characters peculiar to each stage as above noted, and also by employing the rule formulated by Haase. According to Haase, up to the end of the fifth month, the

square of the age in months equals the length in centimeters, while after the fifth month, the length expressed in centimeters equals the age in months multiplied by five. Thus a fetus of four months would have a length of 16 centimeters; while one of six months would be 30 centimeters long. Hence, the age in months is the square root of the number expressing the length in centimeters; or, if the length exceeds 30 centimeters, the age in months is one-fifth of the length expressed in centimeters.

Reference has been made in Chapter I., page 37, to the relation between conception and menstruation, and to the manner of estimating the age of the product of gestation, based upon this relation.

## CHAPTER VIII.

### THE DEVELOPMENT OF THE CONNECTIVE TISSUES OF THE BODY AND OF THE LYMPHATIC SYSTEM.

#### THE CONNECTIVE TISSUES.

THE variously modified forms of connective tissue distributed throughout the body, including such diversified tissues as the blood and the lymph, areolar tissue, fibrous and elastic tissue, adenoid tissue, tendon, cartilage, bone, and dentine, as well as the connective-tissue stroma of various organs, all result from alterations affecting the middle germ-layer or **mesoderm**. As pointed out elsewhere (Chapter III.), the inner and the outer germ-layers are concerned in producing the epithelial structures of the body (with the exception of the epithelium of the greater part of the genital apparatus and of the kidney and ureter), the **ectoderm** giving rise not only to the epithelium of the surface of the body, but also, by processes of infolding, to such important structures as the central nervous system and the internal ear, while the **entoderm** differentiates into the epithelial parts of the respiratory and digestive systems with their associated glandular organs.

The proliferation of the cells of the mesoderm goes hand in hand with the differentiations of the inner and outer germ-layers, so that even at an early stage of development the **middle germ-layer**, besides having given rise to the mesothelium of the body-cavity and to the primitive segments, constitutes a loose aggregation of cells that fill the spaces between the germ-layers and spread about the developing embryonic organs. This primitive relation of the mesodermic tissue foreshadows its future office as the supporting framework not only of the body, but of the functionally

active epithelial elements of the glands. Thus, the indifferent mesodermic tissue that comes to surround the notochord and the neural canal specializes into the spinal column and the brain-case; while the parts of this tissue into which protrude the epithelial evaginations of the primitive alimentary canal—as, for example, the evaginations which are the beginnings of its glandular organs, the liver and the pancreas—become intimately associated with these epithelial sacs and tubes to constitute the connective-tissue stroma and the vascular apparatus of the completed glands. All organs of the body, therefore, that have a connective-tissue constituent obtain it from the mesoderm. Owing to the varying degree of differentiation of the mesodermic elements in different localities there are formed tissues of widely different character. The most important factor in the production of these modifications is *the alteration of the intercellular substance*, as to whether it remains soft and homogeneous, whether it acquires a fibrillar or an elastic structure, or whether it becomes dense and hard, as in the case of cartilage and bone. The *cells* undergo comparatively little change, although, according to the kind of tissue produced, they come to be known respectively as **connective-tissue cells**, **tendon-cells**, **cartilage-cells**, or **bone-cells**.

The slightest degree of specialization results in the production of **mucous tissue**. In this case a reticulum is formed by the slender processes which the cells acquire, the spaces of the meshwork being filled with the semifluid or semi-gelatinous intercellular substance.

A further alteration in the intercellular substance, whereby it acquires greater density and becomes permeated by bundles of fibers, some of which are highly elastic, results in the formation of **areolar tissue**. Preponderance of the non-elastic fibrous element produces **white fibrous tissue**, while **elastic tissue**, such as predominates in the ligamentum nuchæ, is formed if the elastic fibers are in excess. Further increase in the density of the intercellular material, with its accompanying conversion into bundles of non-elastic fibers having a characteristic regularity of arrangement, produces the struct-

ure of **tendon**. When the intercellular substance gives rise to a scant amount of fibrous material and the cells become distended with oily or fatty matter, **adipose tissue** results.

A still greater degree of density of the intercellular substance gives the matrix of **cartilage**, the cells being enclosed in spaces, the **lacunæ**, as the **cartilage-cells**. Partial differentiation into either fibrous or elastic bundles confers the character of either **fibrous** or **elastic cartilage** upon the product.

Great condensation of the intercellular substance and its permeation with salts of lime, the cells being fixed in small spaces, results in the production of **osseous tissue** (see Chapter XVIII.).

**Blood** and **lymph** may be looked upon as forms of connective tissue in which the intercellular substance is fluid, constituting the **plasma**, the cellular elements thus remaining free cells, the **blood-** or the **lymph-corpuscles**. The development of both lymph and blood from the mesodermic elements serves to bear out the comparison.

The **endothelium of the body** is related with the connective tissues genetically as well as anatomically. Reference has been made elsewhere to the changes which occur in the mesodermic cells that bound the body-cavity—the fissure between the two layers into which the parietal plate of the mesoderm splits—to constitute the **mesothelium** of the body-cavity. These changes consist in the flattening of the cells and their assumption of the characters of endothelium. Similarly, when other smaller clefts are formed in the mesodermic tissue, clefts which may be the beginnings of small lymph-spaces, or of blood-vessels, or of bursal or articular cavities, the bordering cells of these cavities also assume the endothelioid type.

The mode of **development of the serous membranes** and of the closely allied **synovial**, **bursal**, and **thecal sacs** may be inferred from what has been said about the origin of the endothelium. The connective-tissue stroma of the membrane, upon which the endothelium rests, is simply a condensed and differentiated lamella of connective tissue.

### THE DEVELOPMENT OF THE LYMPHATIC SYSTEM.

The solid elements of the lymphatic system—the “**lymph-glands**,” the **lymph-follicles**, and the **diffuse adenoid tissue**—as well as the **thymus body** and the **spleen**, result from the specialization of mesodermic cells, while the **lymph-vessels** and the various **lymph-spaces** of the economy—that is, the serous sacs, joint-cavities, bursal and thecal cavities, subarachnoid and subdural spaces of the brain and spinal cord—are developed by vacuolation or hollowing out of the mesoderm.

Definite knowledge is wanting as to many of the details of the genesis of the lymphatic system. The various lymph-spaces precede the vessels and the adenoid tissue in development.

The **lymph-spaces** result from clefts in the mesoderm, the earliest formed and most conspicuous space of this sort being the body-cavity or *cœlom*. This large fissure develops, even before the differentiation of the body of the embryo, by the coalescence of numerous small cavities that appear within the middle germ-layer. The body-cavity acquires more definite boundaries by the alteration of the mesodermic cells that border it into flattened endothelioid cells, the **mesothelium** of the body-cavity. When, in the progress of development, the diaphragm and the pericardium are formed, the **body-cavity** is divided into the **peritoneal cavity**, the **pleural sacs**, and the **pericardium**. At a still later period, a diverticulum of the peritoneum protrudes, in the male fetus, through the inguinal canal into the scrotum to constitute the **tunica vaginalis testis**. The **stomata** of serous membranes are merely so many apertures of communication between the serous cavities, which are enormous lymph-spaces, and the lymphatic clefts contained within the stroma of the serous membrane, the clefts themselves being the beginnings of lymph-vessels.

The **large lymph-sacs** surrounding the brain and spinal cord, the subarachnoid and subdural spaces, as well as the spaces within the capsule of Tenon and the sheath of the

optic nerve, and the perilymphatic spaces of the internal ear similarly develop as vacuolations of the mesodermic tissue. The same is true of the **joint-cavities**, **bursal sacs**, **sheaths of tendons**, and the small **lymph-clefts** found in the areolar tissue and throughout most organs.

The **lymphatic vessels** apparently develop, after the manner of blood-vessels, from anastomosing cords of cells that are of direct mesodermic origin. These solid cell-cords are afterward hollowed out, and thus become tubes. The endothelial cells lining the vessels are probably the metamorphosed descendants of the cells of the original cords. The earliest lymphatic vessels formed are the subcutaneous vessels, which are present in a human embryo of 2-3 c.m.<sup>1</sup> At a somewhat later period the deeper vessels appear.

The **lymphoid** or **adenoid tissue** is produced at a later date than the vessels. Observations upon the human lymph nodes seem to have been confined to the inguinal and lumbar nodes. The first indication of an inguinal node is seen in a 3 c.m. embryo, in the shape of little aggregations of lymphoid cells that have migrated from the lymphatic cords or networks into a space hollowed out of the mesoderm. This nodule of lymphoid cells is isolated from the surrounding mesodermic elements by a fissure or space except at one point, the future **hilum** of the node, where strands of embryonal connective tissue connect it with the parent mesoderm. The **reticulum of the node** appears later, as does also the **capsule**, the latter of which results from the condensation of the surrounding mesoderm.

The development of the **spleen** is considered with that of the alimentary system because of its relation to the evolution of the peritoneum, while the account of the development of the **thymus** will be found in the chapter on the respiratory system.

<sup>1</sup> O. Schultze: "Grundriss der Entwicklungsgeschichte des Menschen und der Säugethiere," Leipzig, 1897.

## CHAPTER IX.

### THE DEVELOPMENT OF THE FACE AND OF THE MOUTH-CAVITY.

THE **evolution of the face** depends so largely upon the growth of the parts concerned especially in the production of the mouth and nose that any account of its development must deal for the most part with the development of those structures. In tracing the earliest stages of facial growth, it will be well to consider the face as a whole before proceeding to a detailed description of its several parts. If we seek the principles underlying the conformation of the face, we shall find that its apertures and chief cavities are merely so many provisions for bringing the central nervous system and the alimentary tract into relation with the outside world. It will be seen, for example, that certain small depressions appear upon the surface; that one of these, which is destined to become the mouth and the respiratory part of the nasal cavities, assumes relationship with the alimentary tract and with its offshoot, the respiratory system; that other depressions, which subsequently develop into the olfactory parts of the nasal chambers, come into relation with outgrowths from the brain, the olfactory bulbs; and that still another surface-invagination becomes the lens-vesicle, which likewise meets with an outgrowth from the brain to become a part of a peripheral sense-organ, the eye.

The first step in the differentiation of the face is the formation of the **oral plate**, the earliest indication of the future mouth. The oral plate appears on the twelfth day, and consists of a small area of ectoderm and entoderm, the mesoderm being absent. It is situated on the ventral surface of

the head-end of the embryo, which already presents the enlargement of the cerebral vesicles. The oral plate becomes relatively depressed by the upgrowth of the surrounding tissues, the fossa thus produced constituting the **oral pit** or **stomodæum** (Fig. 46). The oral plate is now the **pharyngeal membrane** (Fig. 55). Reference to the sagittal section will

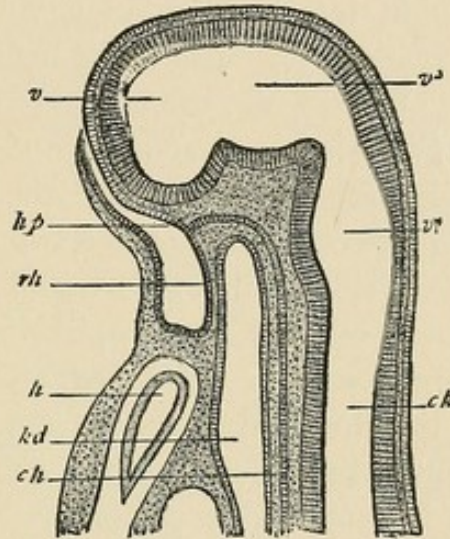


FIG. 55.—Median section through the head of an embryo rabbit 6 mm. long (after Mihalkovics): *rh*, membrane between stomodæum and fore-gut, pharyngeal membrane (Rachenhaut); *hp*, place from which the hypophysis is developed; *h*, heart; *kd*, lumen of fore-gut; *ch*, chorda; *v*, ventricle of the cerebrum; *v*<sup>3</sup>, third ventricle, that of the between-brain (thalamencephalon); *v*<sup>4</sup>, fourth ventricle, that of the hind-brain and after-brain (epencephalon and metencephalon, or medulla oblongata); *ck*, central canal of the spinal cord.

show that the oral pit corresponds in position to the head-end of the gut-tract. The formation of the pit is, in effect, a pushing-in of the surface ectoderm to meet the alimentary entoderm.

A second important factor in the development of the face is the appearance of the first and second visceral arches, which occurs in the third week. As pointed out in a preceding section, the **first visceral arch** divides into the mandibular arch and the maxillary process (Fig. 51), the latter being the smaller and appearing to spring from the mandibular arch. Both the maxillary processes and the mandibular arches grow toward the median line of the ventral surface of the body. Owing to the growth of these struct-

ures and to the sharp flexion of the head and neck that occurs between the twenty-first and the twenty-third day, the oral pit becomes very much deeper and acquires more definite boundaries. During the third week it is a fossa of pentagonal outline. Its upper boundary is formed by the unpaired **nasofrontal** or **nasal process** (Fig. 56, *A*), which is essentially a thickening on the ventral wall of the fore-brain vesicle, brought into close relation with the fossa by the flexion above referred to. The lower boundary is formed by the mandibular arches, while the lateral extent of the fossa is limited by the maxillary process of each side.

Soon after the appearance of the oral pit, the future nares are foreshadowed by the development of the two **olfactory plates**, situated one on each side of the nasofrontal process, widely separated from each other. These epithelial areas, which soon become depressions, the **nasal pits**, are closely united with the wall of the fore-brain vesicle from the first; they develop subsequently into that part of the nasal mucous membrane which is concerned especially with the sense of smell. This fact becomes very significant when it is remembered that the olfactory bulbs, with which the olfactory epithelium assumes intimate relationship, are outgrowths from the brain.

The **nasofrontal process**, during the fifth week, becomes much thickened along its lateral margins, forming thus the **globular processes** (Fig. 56, *A*), which constitute the inner boundaries of the nasal pits. At the same time, there grow downward and forward from the nasofrontal process two ridges, one on each side, the **lateral frontal processes**, which form the outer boundaries of the nasal pits (Fig. 56, *A*). In this manner the pits become much increased in depth. The lateral frontal process projects between the nasal pit and the maxillary process, its line of contact with the latter structure being marked by a groove, the **naso-optic furrow** or **lacrimal groove**. This groove later completely disappears; it is of importance, however, as indicating the position of the now developing nasal duct, which will be referred to hereafter. The nasal pits are widely in communication with

the cavity of the primitive mouth. About the fortieth day, however, the extremities of the maxillary processes have grown so far toward the median line that they have met

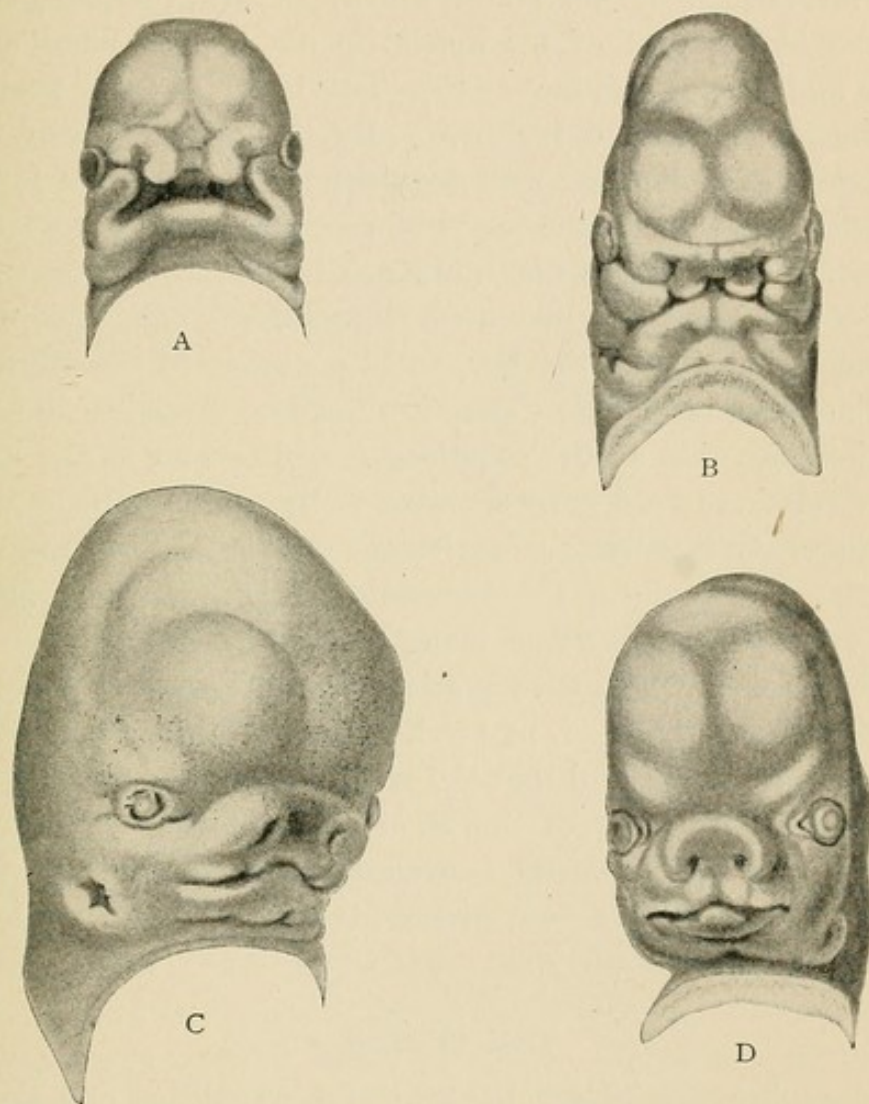


FIG. 56.—Development of the face of the human embryo (His): A, embryo of about twenty-nine days. The nasofrontal plate differentiating into processus globulares, toward which the maxillary processes of first visceral arch are extending. B, embryo of about thirty-four days: the globular, lateral frontal, and maxillary processes are in apposition; the primitive opening is now better defined. C, embryo of about the eighth week: immediate boundaries of mouth are more definite and the nasal orifices are partly formed, external ear appearing. D, embryo at end of second month.

and united with the lateral frontal processes and with the nasofrontal process (Fig. 56, B and C). In this manner the nasal pits become separated from the oral fossa, each of these openings acquiring more definite boundaries. It is

apparent from this description that the upper boundary of the primitive oral cavity is not identical with that of the adult mouth. The **nasofrontal process** is the forerunner of the intermaxillary portion of the upper jaw, including the corresponding part of the upper lip and of the nasal septum and bridge of the nose.<sup>1</sup> The **lateral frontal process** becomes the wing of the nose. By the completion of the changes here noted the face acquires more distinctive form. It will be seen that the **upper jaw** proper results from the metamorphosis of the maxillary processes. The manner in which its sinus, the antrum of Highmore, is added, as well as the ossification of the jaw, will be considered hereafter.

The **development of the eye** will be described in connection with that of the sense-organs. In so far as the eyes have relation to the external form of the face, it will be sufficient to say that the surface ectoderm is invaginated in the fourth week to form the **lens-vesicle**, this sac, which gives rise to the crystalline lens, being covered by two little folds of ectoderm, the **primitive eyelids**; that the organ is situated on the side of the head, in marked contrast to its position in the mature state; and that the **naso-optic furrow**, previously referred to, passes from the inner angle of the eye toward the wing of the nose. The development of the face having been pointed out in a general way, the individual parts may be considered separately.

### THE MOUTH.

To review briefly, for the sake of convenience and clearness, the earlier history of the development of the mouth, we find the first step to be the appearance, at the twelfth day, of the **oral plate**. By the enlargement of the anterior end of the neural tube to form the cerebral vesicles, and by

<sup>1</sup> *Hare-lip* is the deformity resulting from failure of union between the nasofrontal and the maxillary processes. Since the nasofrontal process is an unpaired structure, in which develop the intermaxillary bones, and which unites on either side with the corresponding maxillary process—the latter being the forerunner of the upper maxilla proper—we have an explanation of the lateral position of hare-lip. This defect may be, of course, either unilateral or bilateral.

the development of the visceral arches, this area becomes a depression, the **oral pit**. The pit is at first bounded caudad by the cardiac prominence and cephalad by the fore-brain vesicle (Fig. 46). In the third week the oral pit becomes a five-sided fossa, owing to the growth of several new structures. These are the unpaired **nasofrontal process**, which bounds the fossa above, the **mandibular arches**, which bound it below, and the **maxillary processes**, which form the lateral boundaries (Fig. 56). The mandibular arches do not actually unite with each other until the thirty-fifth day. The angle between the maxillary process and the mandibular arch corresponds to the angle of the future mouth. In the sixth week—about the fortieth day—the oral fossa acquires a new upper boundary, which separates it from the nasal pits, by the growth of the maxillary and lateral nasal processes toward the median line to unite with the nasofrontal process.

The primitive oral cavity, as before mentioned, is at first separated from the gut-tract by the **pharyngeal membrane** (Fig. 55). This structure ruptures at some time during the fourth week, thus bringing the mouth into communication with the upper end of the gut-tract. The exact location of the pharyngeal membrane with reference to the adult pharynx is somewhat difficult to define; it is certain, however, that the primitive mouth includes more than the limits of the adult oral cavity, comprising, in addition to the latter, the anterior part of the adult pharynx. Reference to a sagittal section, as in Fig. 55, shows the relation of the oropharyngeal cavity to the brain-case; in the tissue separating the two the floor of the cranium is subsequently formed. A little evagination from a point (*hp*, Fig. 55) in the back part of the primitive oral cavity becomes the anterior portion of the **pituitary body** or **hypophysis**, the posterior lobe of which develops as an evagination from the floor of the primary fore-brain vesicle. With the development of the floor of the cranium, the hypophysis becomes entirely isolated from the oral cavity. A little pouch or recess usually demonstrable in the median line of the roof of the pharynx of the child,

though not always present in the adult, is the persistent pharyngeal end of the diverticulum that forms the hypophysis; it is known as the **pharyngeal bursa** or **Rathke's pocket**.

Very soon after the formation of the upper jaw in the manner above described, the oral surface of the jaw presents **two parallel ridges**. Of these, the outer, which is the larger, develops into the **upper lip**, while the inner smaller ridge becomes the **gum**. The lip and gum of the lower jaw are produced similarly, at the same time or a little later. So far, the only demarcation between the mouth and the nasal cavity is furnished by the tissue representing the united nasofrontal, lateral nasal, and maxillary processes, the nares opening widely into the cavity of the mouth posterior to this partition.

The formation of the **palate**, however, effects a separation between the two that gives to each space its permanent limitations. On the inner or oral surface of the upper jaw two shelf-like projections appear, one on each side, which are the rudiments of the **future palate**. These gradually grow toward each other, the tongue, which has meanwhile been developing, projecting upward between them. In the eighth week, union of these two lateral halves of the palate begins at their anterior extremities. By the ninth week union has taken place as far back as the extent of the future hard palate, and, by the eleventh week, the constituent halves of the soft palate have united also. As these two halves approach each other the tongue recedes from between them, owing to the growth of the lower jaw, so that, when union occurs, that organ occupies its normal position under the palate. Osseous formation within the soft tissue first formed produces the palate processes of the superior maxillæ and of the palate bones, which processes collectively constitute the hard palate of the adult. The **intermaxillary bones** are formed within the primitive partition between the mouth and the nares. The completion of the palate definitely marks off the nasal chambers from the mouth, thus dividing the early oral cavity into a lower space, the true mouth, and an

upper region, which is essentially a part of the respiratory system.

The **uvula** appears during the latter half of the third month as a small protuberance on the posterior edge of the soft palate.<sup>1</sup>

**The Teeth.**—The **teeth**, morphologically considered, are calcified papillæ of the skin, capped by a layer of peculiarly modified and calcified cells of the epidermis. Although in man and the higher mammals the teeth are found only upon the gums, in certain lower types they have a much wider distribution, occurring upon the roof and floor of the mouth and in the pharynx, and also, in selachians, upon the general skin-surface, in which latter case they are so modified as to constitute scales.

The **dentine** and **cementum** of the tooth, as well as its **pulp**, are derived from the mesoderm; the **enamel** is a direct derivative of the overlying ectodermic epithelium. Mammals are said to be *diphyodont*, since they develop two sets of teeth; while such groups as sharks, which continue to produce and lose new teeth throughout life, are denominated *polyphyodont*.

The **development of the teeth** is inaugurated in the *sixth week* of embryonic life by the multiplication of the epidermal cells covering the surface of the gums to form a linear ridge. The growth of the ridge is away from the surface, so that the new structure projects into the underlying mesoderm. This horseshoe-shaped ridge, which corresponds in direction and extent to the line of the gum, subdivides into two parallel ridges, of which the outer marks the position of the future groove between the gum and the lip; the inner is the **dental shelf** or **dental ridge**, which must be regarded as the *earliest indication* of the future teeth. The dental shelf extends into the underlying mesodermic tissue, not directly

<sup>1</sup> Deficiency of union of the halves of the palate, resulting in a median fissure, constitutes the deformity, *cleft palate*. This deficiency may be limited to the hard or to the soft palate, or it may affect both, or it may be seen in the uvula, either alone—*cleft* or *bifid uvula*—or in conjunction with cleft palate.

downward but in an oblique direction toward the inner or lingual surface of the gum. While the dental shelf is growing, its line of connection with the surface ectoderm is marked by the superficial **dental groove**, which at one time was looked upon as being the first evidence of tooth-formation.

Upon the side of the dental shelf opposite the free or oral surface, individual protuberances develop, corresponding in number to that of the teeth of the temporary set—ten for each jaw. Each little projection consists of a mass of ectodermic cells, which soon becomes expanded at its deep extremity, becoming thus club-shaped and later flask-shaped, and which is called the **enamel-sac** or **primitive enamel-germ**, since the enamel of the tooth is developed from it (Fig. 57).

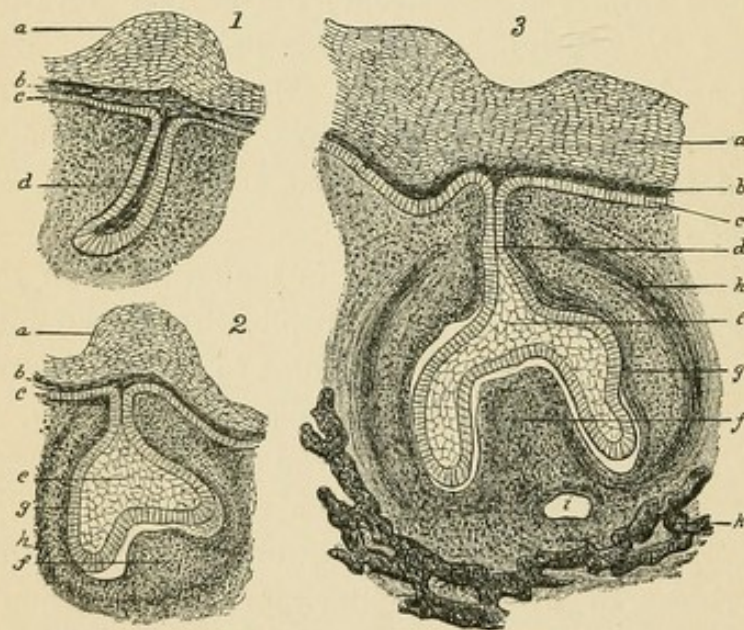


FIG. 57.—Three successive stages in the development of a tooth-germ of a pig embryo (after Frey and Thiersch): *a, b, c*, layers of thickened oral epithelium, showing dental groove on surface in 3; *e*, enamel organ; *f*, dental papilla; *g, h*, internal and external layers of the follicle wall; *i*, blood-vessel; *k*, maxilla; *d*, epithelial ingrowth, the end of which expands into the enamel-sac.

Meanwhile the continuity of the original dental shelf is broken by the disappearance of the cells in the intervals between the individual enamel-germs, each germ becoming thereby isolated from its neighbors. The neck of the flask-

shaped enamel-germ becomes reduced to a slender strand of cells and finally disappears, so that there is no longer any connection between the enamel-sac and the ectodermic cells of the free surface of the gum. While the enamel-sacs for the temporary teeth are growing in this manner, the corresponding structures for the teeth of the permanent dentition bud from the inner side of the dental shelf—that is, the side looking toward the tongue—except those for the three permanent molars, which grow backward toward the articulation of the jaw from the position of the second temporary molar.

As the enamel-germs grow downward into the mesodermic tissue, the latter sends up a number of conical projections, the **dental papillæ**, one for each enamel-organ. This dental papilla, of mesodermic origin, is the parent of the dentine and of the pulp of the tooth. When the dental papilla and the enamel-sac meet, the sac becomes invaginated, its under surface assuming a concave form. The enamel-sac at this stage therefore is a double-walled cup which caps the dental papilla. It is at about this time that the connection of the enamel-organ with the surface ectoderm is lost.

The further evolution of the enamel-organ consists essentially in the arrangement of its constituent cells into **three layers** and the formation, by the deepest of these three layers, of the special elements of the fully-developed enamel—the **enamel-prisms**. The most superficial stratum of the enamel-organ is composed of low columnar or polyhedral cells; the deepest layer, that nearest the papilla, the so-called **membrana adamantina**, consists of beautifully regular columnar cells, the **ameloblasts** or **adamantoblasts**; between the two is a group of less characteristic epithelial elements. The cells of the deep layer, the **enamel-cells**, are alone concerned in the production of the enamel. The enamel-organ for a time covers the entire dental papilla. During the course of development, however, the growth of that part of it covering the future root of the tooth aborts, leaving the crown alone covered with the enamel.

The first step in the formation of the enamel-prisms by the enamel-cells is that the protoplasm of the deep extremity

of each cell becomes homogeneous, and a tuft develops on the end of the cell, projecting toward the papilla. By the

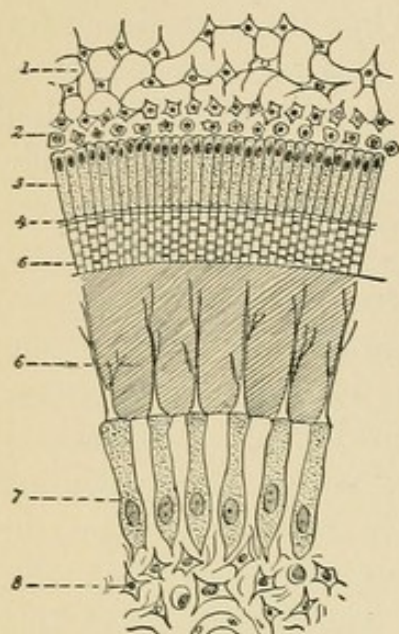


FIG. 58.—Semi-diagrammatic figure showing the several parts of a calcifying enamel-organ (Tournoux): 1, central cells of enamel-organ; 2 and 3, cells of inner layer of enamel-organ, 3 being the enamel cells; 4, zone of young enamel; 5, enamel prisms; 6, young dentine traversed by the dentinal fibers; 7, odontoblasts; 8, central tissue of dental papilla.

calcification of this tuft the formation of an enamel-prism is begun (Fig. 58). The process of calcification continues to advance from the deep or papillary aspect of the enamel-organ toward the surface. From this it comes about that the newest enamel is next to the enamel-cells, or, in other words, nearest the surface, and also that the enamel-prisms are arranged in a direction generally vertical to the free surface of the tooth. **The formation of the enamel of the milk-teeth begins in the latter part of the fourth month.** The middle layer of the enamel-organ becomes greatly altered in constitution, owing to the accumulation of fluid and to the reduction of its cells to the form of thin plates, the appearance being rather that of connective

tissue than of an epithelial structure. The superficial layer of cells undergoes atrophy, their exact fate not being known.

The atrophic remnant of the enamel-organ is found upon the free surface of the tooth for a variable time after its eruption, constituting the **membrane of Nasmyth**.

The **dental papilla** has been referred to as the structure that gives rise to the dentine. It originates from active multiplication of the mesodermic cells. The number of papillæ corresponds to the number of enamel-organs. As the papilla grows toward the enamel-organ it early acquires vascularity. The shape of the papilla, whether that of an incisor, of a canine, or of a molar tooth, is determined by the shape which the enamel-organ assumes. The connective-

tissue cells upon the surface of the papilla assume distinctive character, becoming large and branched, and constitute the so-called **odontoblasts** (Fig. 58). They are virtually modified osteoblasts. Forming a continuous layer, they have been styled the **membrana eboris**. Between this layer of odontoblasts and the enamel-organ a layer of intercellular substance appears, the **membrana præformativa**. The odontoblasts now send out processes toward the enamel-organ, which are known as the **dental processes**. Calcification begins upon the surface of the papilla and progresses toward its center, but is not complete. Small uncalcified areas, corresponding to the **globular spaces** of the completed tooth, remain next the enamel. The dental processes likewise fail to become calcified, and these are the adult **dentinal fibers** occupying the **dentinal tubules** of the finished dentine. The odontoblasts continue the formation of dentine until the dental papilla is entirely surrounded by it. What remains of the papilla, upon the completion of the tooth, constitutes the **pulp**, a highly vascular connective-tissue substance supporting upon its surface the odontoblasts. The deposition of dentine begins in the latter part of the *fourth month*.

During the metamorphosis of the dental papilla the mesodermic tissue immediately surrounding it undergoes slight condensation to form the **follicle** of the developing tooth. As the enamel-organ recedes from the surface, the follicle increases in extent to such a degree as to envelop the entire rudimentary tooth. Only that part of the follicle which covers the future root of the tooth is of subsequent importance, however; undergoing partial transformation into true bony tissue, it gives rise to the **cementum** or **crusta petrosa**, while the unossified external fibrous layer constitutes the lining **periosteum** of the alveolus (Fig. 57).

The **development of the permanent teeth** is precisely analogous to that of the milk-teeth. The **enamel-germs** for the permanent teeth, with the exception of the molars, bud from the lingual side of the dental shelf in the *seventeenth week* (Fig. 59), the germ for the **first permanent molar** appearing about a week earlier at the posterior extremity of the dental

shelf after the manner of a milk-tooth. The germ for the **second molar** buds from the neck of the first molar in the third month after birth, while that of the **third molar**, the wisdom tooth, springs from the neck of the second about the third year. At birth, therefore, the gums contain the

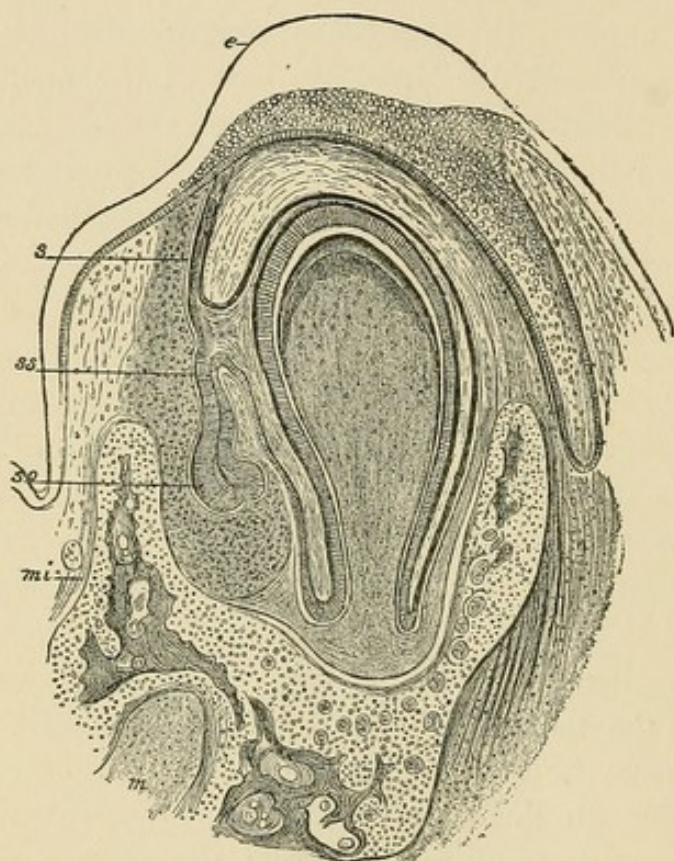


FIG. 59.—Cross-section of the lower jaw of a cat embryo, showing the enamel-germs of a milk-tooth and of a permanent tooth (from Bonnet, after Kölliker): *e*, thickened oral epithelium; *so*, enamel-organ of permanent tooth, which has grown out at *ss* from the neck (*s*) of the enamel-sac of a milk-tooth; *mi*, lower jaw; *m*, Meckel's cartilage.

two sets of teeth except the second and third permanent molars.

The eruption of the temporary teeth begins usually at about five and a half months after birth with the appearance of the central incisors, and is complete at from eighteen to thirty-six months, when the second molars are cut. The first teeth of the permanent dentition are the first molars, which are erupted at about the sixth year. The accompanying table shows the time and the order of eruption of the teeth:

## TEMPORARY DENTITION.

Central incisors . . . . .	5½ to 7 months.
Lateral incisors . . . . .	7 to 10 months.
First molars . . . . .	12 to 14 months.
Canines . . . . .	14 to 20 months.
Second molars . . . . .	18 to 36 months.

## PERMANENT DENTITION.

First molars . . . . .	6th year.
Central incisors . . . . .	7th year.
Lateral incisors . . . . .	8th year.
First premolars . . . . .	9th year.
Second premolars . . . . .	10th year.
Canines . . . . .	11th to 12th year.
Second molars . . . . .	12th to 13th year.
Third molars (wisdom teeth) . . . . .	17th to 21st year.

**The Salivary Glands.**—The salivary glands, which in mammals consist of three pairs, the **parotid**, the **submaxillary**, and the **sublingual**, develop as outgrowths of epithelium from the lining mucous membrane of the mouth. The epithelial elements of the glands are therefore of **ectodermic origin**. The growth of the submaxillary gland begins in the sixth week, that of the parotid in the eighth week. Each epithelial outgrowth is at first a solid cylinder, which undergoes repeated branching and acquires a connective-tissue framework and capsule from the surrounding mesoderm. It is not until the middle of the fifth month that the lumen of the gland appears. This is brought about by the moving apart of the epithelial cells composing the cylinders and their branches. The main duct of the gland first becomes hollow, then its branches, and finally the lumina of the alveoli make their appearance. The respective sites from which the several glands grow correspond in a general way to the positions at which the ducts of the adult glands open into the mouth-cavity.

**The Tongue.**—Although the tongue originates from tissues belonging really to the walls of the pharynx, its development may be conveniently considered in connection with that of the mouth because of its relations in the mature organism. This organ, composed chiefly of muscular sub-

stance, is formed from three originally separate parts, an anterior unpaired fundamen-  
 tal, and two posterior bilaterally symmetrical segments. The line of union of these three parts is indicated approximately in the adult organ by the V-shaped row of circumvallate papillae on the dorsum of the tongue. The **anterior part of the tongue** develops from a small unpaired tubercle, the **tuberculum impar**, which grows from the median line of the floor or anterior wall of the pharynx between the first, or mandibular, and the second, or hyoid, arch (Fig. 60, 6). The **posterior segment** of the tongue results

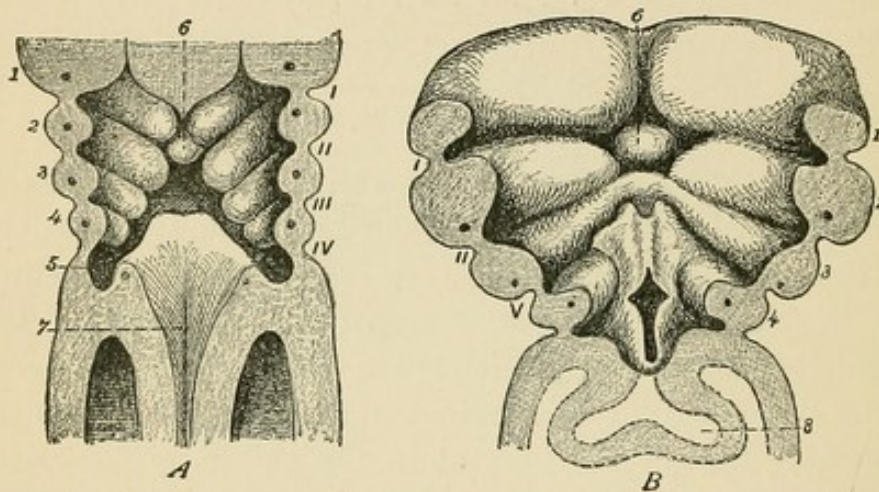


FIG. 60.—Coronal sections of two human embryos, showing ventral wall of pharyngeal end of gut-tract from behind (from Tourneux, after His). *A*, from embryo of 3.2 mm.; *B*, of 4.25 mm. (about 25 to 30 days). *I*, *II*, *III*, *IV*, outer visceral furrows; *V*, sinus præcervicalis, comprising third and fourth outer furrows; 1, 2, 3, 4, visceral arches, each with its visceral-arch vessel; 6, tuberculum impar; 7, orifice of larynx; 8, pulmonary evagination.

from the growing together of two lateral halves, which develop from the anterolateral walls of the pharynx at the position of the second and third visceral arches, but not from the arches themselves. These ridges are sometimes described as the fused anterior (ventral) extremities of the arches just mentioned. The unpaired tubercle increases in size to such an extent as to constitute the major part of the organ. In the median line of the anterior wall of the pharynx, immediately behind the tuberculum impar, the epithelial lining of this cavity pouches forward and downward to develop later into the middle lobe of the thyroid body. As the ridges which are to form the posterior part of the tongue lie laterally and

posteriorly to this median evagination, they completely enclose it in the process of fusing with each other and with the anterior tubercle. In this manner a canal or duct is formed leading from the surface of the tongue at the angle of junction of its three segments down to the middle lobe of the thyroid body, the latter meanwhile having descended from its original position. This canal is the **thyroglossal duct** or canal of His. During the further progress of development, the canal suffers obliteration, its only vestige being the orifice, which is known as the **foramen cæcum** of adult anatomy.

The **papillæ** of the tongue are found exclusively on the part derived from the tuberculum impar; the line of union between the anterior and posterior parts lies therefore behind the row of circumvallate papillæ. The papillæ begin to make their appearance as early as the beginning of the third month.

Prior to the union of the two lateral halves of the hard palate, by which the primitive oral cavity is divided into the mouth proper and the nasal chambers, the tongue projects upward between the palate-shelves, almost completely filling the primitive mouth. As the palate-shelves approach each other, however, the tongue gradually recedes to its subsequent normal position.

#### THE DEVELOPMENT OF THE NOSE.

The nose being an organ of special sense, its development is described in connection with that of the other special-sense organs in Chapter XVI. Owing, however, to its important relation to the other parts of the face, it is desirable to refer to its evolution in this connection. For a more detailed account, the reader is referred to Chapter XVI.

The first indication of the organ of smell is in the form of the two patches of thickened ectoderm, the **nasal areas** or **olfactory plates**, which appear on the headward side of the oral fossa in the third week of development. At the end of the fourth week the areas are depressed and constitute the **nasal pits** (Fig. 56, A). The **nasofrontal process**, a mass of thickened mesodermic tissue, lies between them. During the

fifth week the lateral edges of this process become thick and rounded, forming the two **globular processes**, while growing outward and downward from the sides of its base are the two **lateral nasal** or **lateral frontal processes**. Thus the nasal pits, which correspond with the position of the future anterior nares, become bordered on the mesial side by the globular processes and on the outer side by the lateral nasal processes. Below, the pits are continuous with the oral fossa. Owing to the continued growth of these masses the pits gradually become deeper. The lateral nasal process is separated externally from the maxillary process of the first visceral arch by a groove, the **naso-optic furrow**. The lower extremities of the maxillary and lateral nasal processes soon unite with each other and advance toward the median line below the nasal pit. In the latter part of the sixth week they unite with the nasofrontal process and thus separate the nasal pits from the oral fossa and furnish the basis of the upper lip. The nasal pits are now the **anterior nares**, and the nose is represented by the irregular masses of tissue surrounding them. While the orifices of the nares are separated from the orifice of the primitive oral cavity, their deeper parts are continuous with the latter, there being as yet no hard or soft palate.

In the eighth week the nose first acquires definite form, owing to the continued growth of the masses of tissue referred to above. The **nasofrontal process** forms the bridge of the nose with the nasal septum, and also the intermaxillary part of the superior maxillæ and the connective-tissue parts of the upper lip. The **lateral frontal process** becomes the ala of the nose. The nose is still very broad and flat in the third month, after which time it gradually assumes its characteristic form.

## CHAPTER X.

### THE DEVELOPMENT OF THE VASCULAR SYSTEM.

THE **vascular system**, including the blood, the heart, and the blood-vessels, begins its development very early in embryonic life.

While the heart is formed within the body of the embryo, the blood and the earliest blood-vessels have their origin in an extra-embryonic structure, the yolk-sac. It is noteworthy that all parts of the vascular system proceed from mesodermic tissue, the heart and the vessels originating from clefts within this structure, and being lined, therefore, with endothelial cells.

In correspondence with the varying relations which the embryo sustains toward the fetal appendages at different times, its circulatory system is distinguished successively by certain special features. Thus, during the activity of the yolk-sac as an organ of nutrition, the **vitelline circulation** is present; following and supplanting this is the **allantoic circulation**, which latter, in turn, gives place to, or, in fact, becomes the **placental system** of vessels.

#### THE VITELLINE CIRCULATION AND THE ORIGIN OF THE BLOOD.

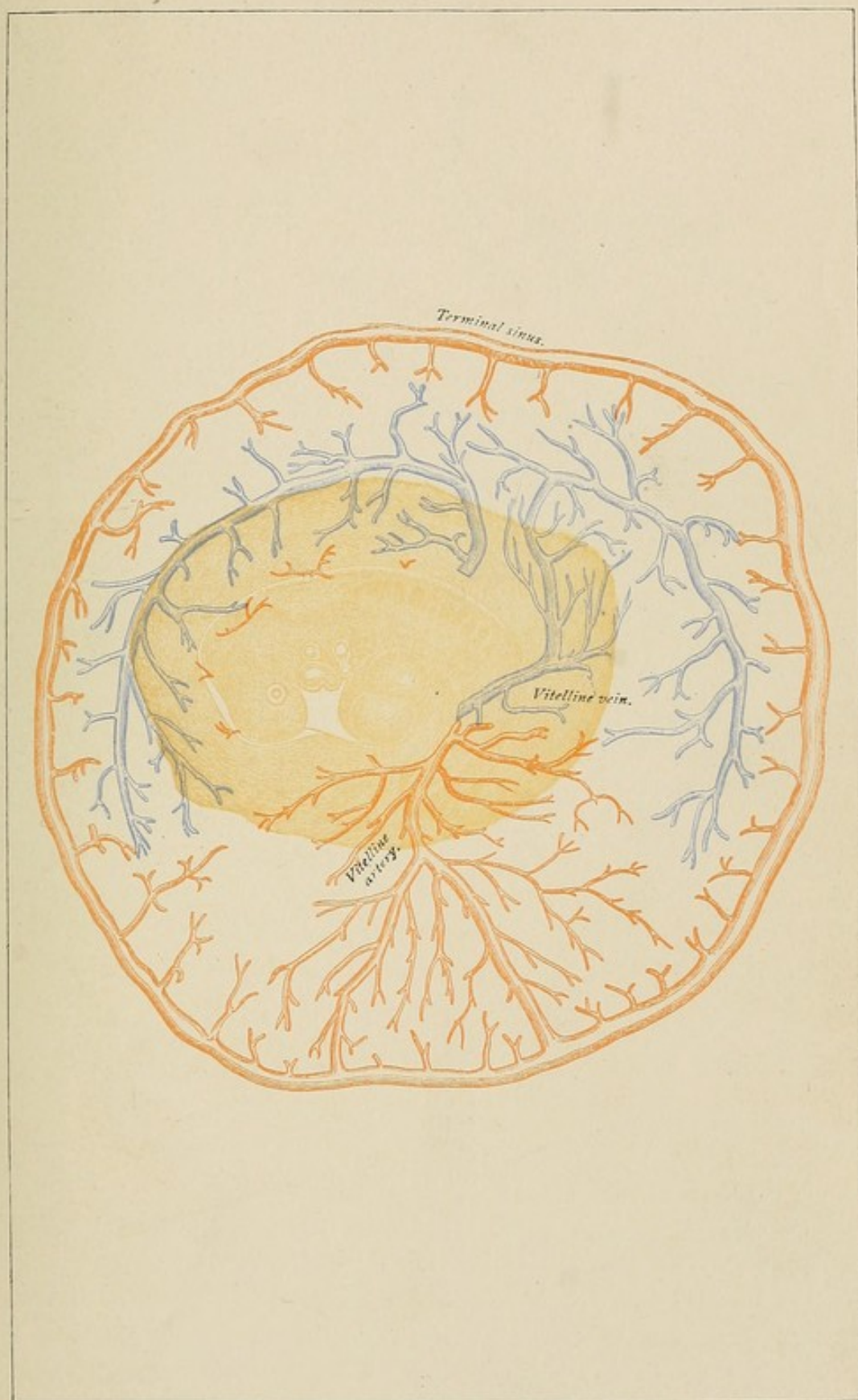The seat of the first formation of the blood-vessels and of the blood is the wall of the yolk-sac, entirely outside of the body of the embryo. The wall of the yolk-sac, the reader may be reminded, consists of the extra-embryonic splanchnopleure covered with a part of the somatopleure. The mesodermic layer of the sac exhibits—at the end of the first day in the chick—a network made up of **CORDS OF CELLS**. Interspersed throughout this network, as part of it, are groups of mesodermic cells known as the **blood-islands** of

**Pander.** Soon the cords composing the network become hollowed out so as to constitute an anastomosing reticulum of **vessels**, the cells which are to compose the walls of these vessels meanwhile acquiring the endothelial type. The remaining component cells of the blood-islands coincidentally undergo partial disintegration and liquefaction, by which their nuclei are set free. These nuclei, surrounded by a very small and inconspicuous envelope of protoplasm, are the **primitive red blood-corpuscles** and are, during the first month, the only corpuscular elements that the fetal blood contains. They differ essentially from the adult red corpuscles in the fact of their being nucleated. Their shape is at first spherical or spheroidal. Subsequently they entirely disappear. Other cells are added to the blood during the second month and afterward. Without discussing the unsettled question of the origin of the adult blood-cells—the **red** and the **white corpuscles** and the **blood-plaques**—it may be pointed out in passing that the liver is a very important source of the red corpuscles during fetal life.


Limiting the first network of vessels on the surface of the yolk-sac is a circular vessel, the **sinus terminalis** (Plate VI.). Since the yolk-sac is relatively so large that the body of the embryo appears to rest upon it, and since the surrounding somatopleure is translucent, a surface view of the ovum at this stage shows a vascular zone encircling the embryonic area and the later body of the embryo. This zone is the **area vasculosa**, or vascular area, the seat of the earliest formation of blood and of blood-vessels of the embryo.

The vessels, by a process of budding, grow from the vascular area along the vitelline duct into the body of the embryo. Here they take their course toward the primitive heart, which has meanwhile been developing. From the anterior and posterior and lateral limits of the vascular area—using these terms with reference to the axis of the embryonic body—four pairs of vitelline veins converge toward the vitelline duct and unite to form the two **vitelline** or **omphalomesenteric veins**. These veins, after entering the body of the embryo, pass headward along the wall of the

PLATE VI.



Vascular area of eleven-day rabbit embryo (E. von Beneden and Julin). The capillaries are not shown; the terminal sinus is seen to be arterial.



intestinal tube and empty into the lower or caudal end of the primitive heart. The trunks which are to constitute the **vitelline arteries**, after entering the body with the vitelline duct, pass upward along the dorsal body-wall, within the dorsal mesentery, to become continuous with large arterial trunks that have proceeded from the primitive heart.

The large trunks referred to are the **visceral-arch vessels**, which unite to form the primitive aortæ. The visceral-arch vessels (see Fig. 49) are a series of five pairs of arteries that arise by a common stem, the **truncus arteriosus**, from the upper end of the primitive heart. They pass along the respective visceral arches toward the dorsal surface of the body where all the vessels of one side unite into a common trunk, the **primitive aorta**. The two primitive aortæ, passing caudalward in the dorsal mesentery, give off, as their largest branches, the two omphalomesenteric or vitelline arteries above referred to. The development and the regression of the visceral-arch vessels correspond with the growth and the decadence respectively of the visceral arches. Not all the vessels are present in a fully-developed condition at any one time, the first pair having begun to atrophy before the fifth pair makes its appearance. The metamorphosis into certain adult vessels of such of them as persist will be considered in a later section.

This system of vessels constitutes the **vitelline circulation**, the manifest function of which is to convey nutritive material from the yolk-sac to the embryo. While the vitelline circulation is of great importance in any ovum provided with abundant nutritive yolk, such as that of the bird, it is of comparatively slight consequence in man and the other higher mammals, and it must be regarded as a vestige of the avian or reptilian ancestry of the mammalian ovum, or, at least, as a reminder that the mammalian ovum was originally provided with an abundant yolk. It must be borne in mind, however, that the mammalian blastodermic vesicle imbibes from the walls of the uterus a richly nutritive albuminous fluid, which may be taken up later and carried to the embryo by the vitelline circulation. This system of yolk-sac

vessels disappears with the regression and disappearance of the yolk-sac—in the human embryo at about the fifth week.

To render the comprehension of the later phases of the vascular system more simple, their consideration is deferred until the development of the heart shall have been described.

### THE DEVELOPMENT OF THE HEART.

The **heart**, when studied in the lower-type animals, is seen to be morphologically a dilated and specialized part of a vascular trunk embedded in the ventral mesentery. In **man**, the first fundament of the heart appears at a very early period—namely, before the splanchnopleure has folded in to

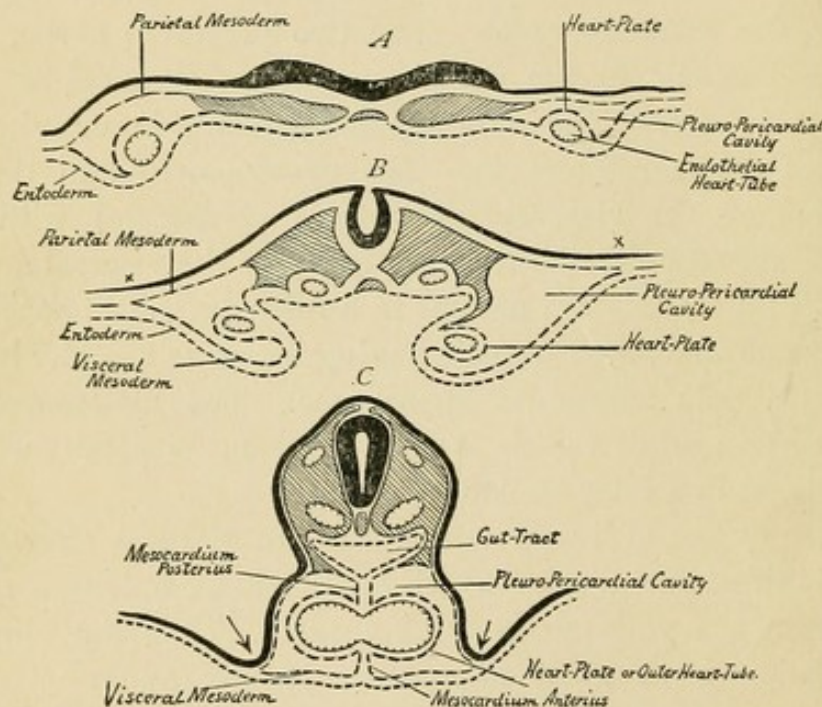


FIG. 61.—Schematic cross-section of rabbit-embryo to show development of heart; *A*, embryonic area with the germ-membranes still spread out; *B*, more advanced stage, the splanchnopleure partly folded in; *C*, splanchnopleure folded in to form gut-tract, the two heart-tubes fused into one (after Strahl).

form the gut-tract, or, in other words, before the end of the second week. This fundament, in all higher vertebrates, is bilateral, having the form of **two tubes** produced by vacuolation of the splanchnic mesoderm and lying widely separated, one in each half of the still spread out splanchnopleure (Fig. 61, *A*). A transverse section through the future neck-

region of a sheep- or rabbit-embryo shows the tubes cut across, since their long axes are parallel with that of the body (Fig. 62). With the folding in of the splanchnopleure and the union of the edges of its folds, the tubes are carried toward each other, and subsequently, by the disappearance of the tissue intervening between them, their cavities become one (Fig. 61, *B* and *C*). After the formation of the gut-

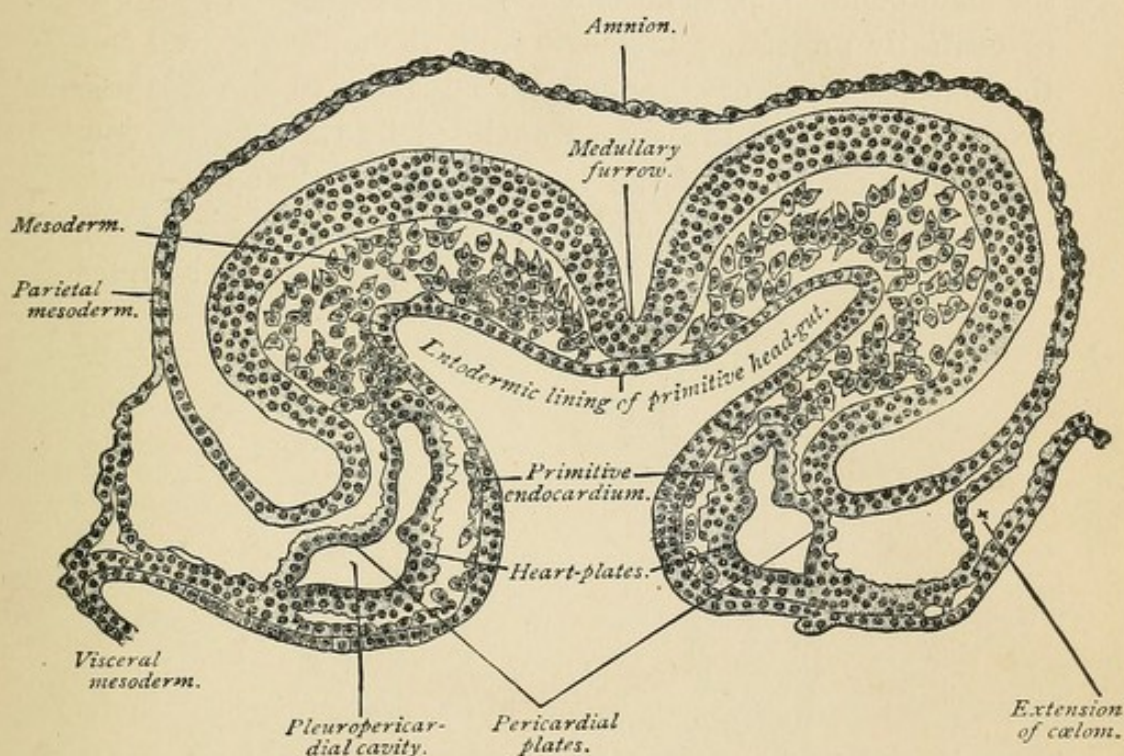


FIG. 62.—Transverse section of a sixteen-and-a-half-day sheep-embryo (Bonnet).

tract, therefore, and the simultaneous appearance of the ventral body-wall, the heart-fundament is a **single straight mesodermic tube**, situated in the pharyngeal region, in close relation with the ventral wall of the body, between the latter and the fore-gut. Reference to Fig. 61, *C*, will show that the heart-tube is separated from the body-cavity (or coelom) on each side by a layer of the mesoderm, and that these two layers connect the heart dorsally with the gut-tract and ventrally with the body-wall, forming respectively the **mesocardium anterius** and the **mesocardium posterius**. These folds temporarily divide the upper portion of the body-cavity into two lateral parts.

The disappearance of the stratum of mesoderm immediately surrounding the heart-tube and the differentiation of the tissue limiting peripherally the space thus formed, results in the production of a **second larger tube** enclosing the first. The cells of the outer tube become specialized into **muscle-cells**, which are to constitute the future heart-muscle, while those of the inner cylinder flatten and assume the endothelioid type to become the **endocardium**. The growth of centrally projecting **processes** from the muscular wall and the outpocketing of the endothelial tube to cover these processes and line the spaces enclosed by them foreshadow the spongy character of the inner surface of the adult heart, with its **columnæ carneæ** and **musculi pectinati**. It is significant, as showing the contractility of undifferentiated proto-

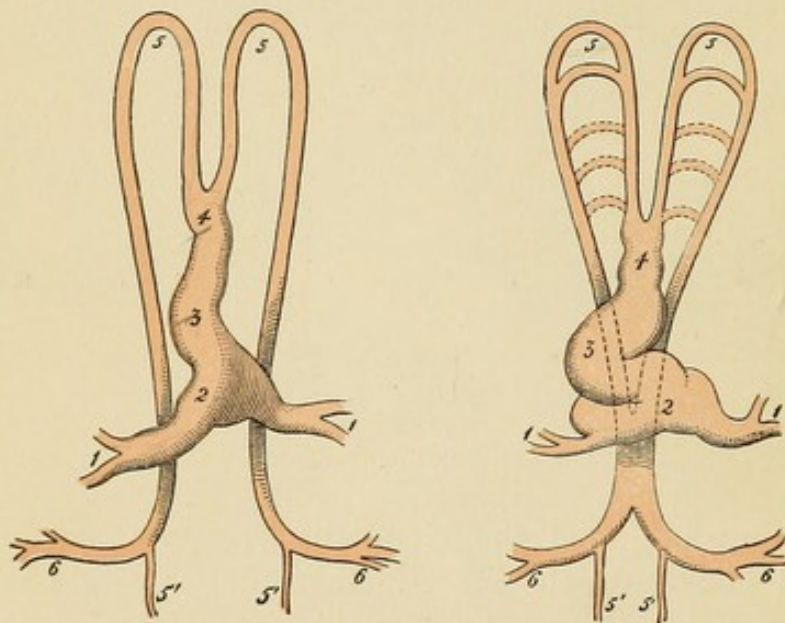


FIG. 63.—Diagrams illustrating arrangement of primitive heart and aortic arches (modified from Allen Thomson): 1, vitelline veins returning blood from vascular area; 2, venous segment of heart-tube; 3, primitive ventricle; 4, truncus arteriosus; 5, 5, upper and lower primitive aortæ; 5', 5', continuation of double aortæ as vessels to caudal pole of embryo; 6, vitelline arteries returning blood to vascular area.

plasmic cells, that the heart begins to pulsate even before the appearance of any muscular tissue in its walls.

The upper end of the heart-tube tapers away into the **truncus arteriosus** (Fig. 63, 4), a vessel which bifurcates into the first pair of visceral-arch vessels, while its lower ex-

tremity receives the vitelline veins above referred to. Excessive growth in length, each end of the tube being more or less fixed in position, necessitates flexion or folding, the form which the heart-tube assumes in consequence being that of the letter S placed obliquely (Fig. 64, A). The venous

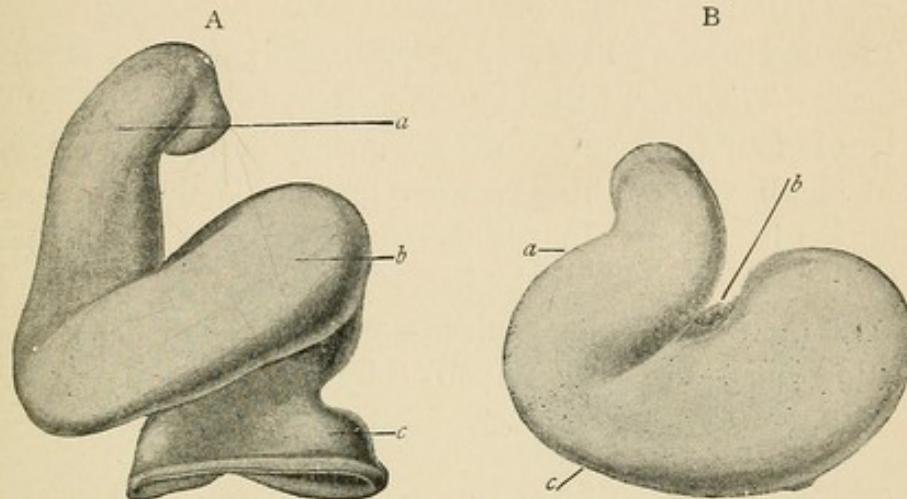


FIG. 64.—A, heart of human embryo of 2.15 mm. (His): *a*, truncus arteriosus; *b*, primitive ventricle; *c*, venous segment. B, heart of human embryo of about 3 mm. (His): *a*, truncus arteriosus; *b*, venous segment (behind); *c*, primitive ventricle (in front).

limb of the S lies caudad and toward the left, the arterial segment being directed headward and toward the right, so that the two lie almost in the same coronal plane. These relations are soon altered by such a rotation around a longitudinal axis that the venous part of the heart comes to lie nearer the dorsal wall of the body, with the arterial portion ventral to it, both being brought at the same time into practically one transverse plane by the headward migration of the venous, and the tailward migration of the arterial, moiety. At this time the heart is relatively so large, and the ventral body-wall covering it so thin, that the organ appears as if situated outside of the embryo's body (Fig. 51, p. 104).

Simultaneously with these alterations in position, the **arterial part** of the heart is being marked off from the **venous segment** by a **transverse constriction**, the former becoming the ventricle, the latter the auricle or atrium (Fig. 64, A). The narrow communication between the two is the **auricular or atrioventricular canal**, which soon acquires the primitive

**atrioventricular valves.** The truncus arteriosus becomes delimited from the ventricle by a circular constriction, the **fretum Halleri**, the proximal part of the truncus arteriosus dilating somewhat to constitute the **bulbus arteriosus**. The truncus arteriosus divides into the visceral-arch vessels, as pointed out in the last section.

**The Metamorphosis of the Single into the Double Heart.**—The heart with but one ventricle and one auricle or atrium is found not only during the early periods of development in all air-breathing vertebrates, but is the permanent condition in fishes. In the development of the individual, as in the evolution of the higher vertebrate type, the appearance of the lungs, which replace the branchiæ of fishes as an aërating apparatus, is accompanied by a division of the heart

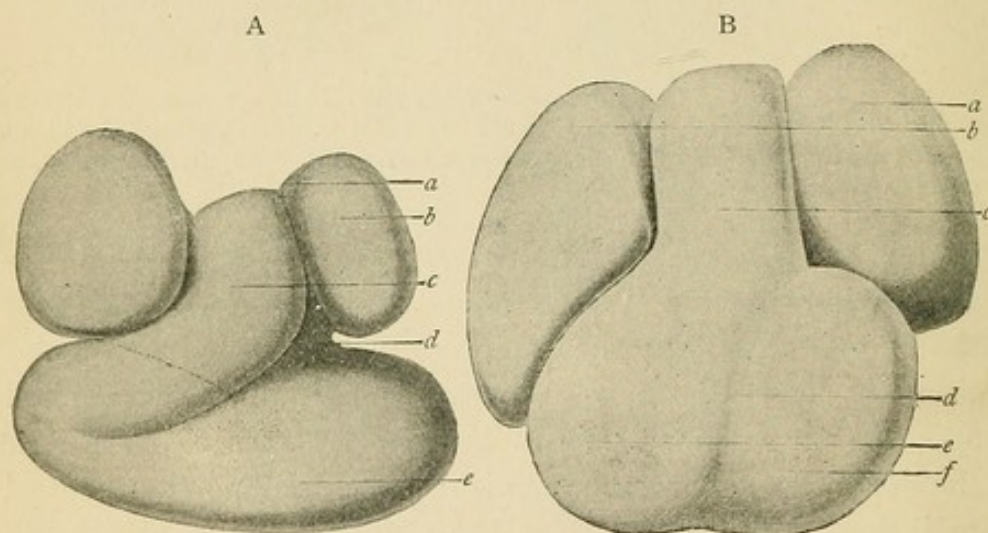


FIG. 65.—A, heart of human embryo of about 4.3 mm. (His): a, atrium; b, portion of atrium corresponding with auricular appendage; c, truncus arteriosus; d, auricular canal; e, primitive ventricle. B, heart of human embryo of about the fifth week (His): a, left auricle; b, right auricle; c, truncus arteriosus; d, inter-ventricular groove; e, right ventricle; f, left ventricle.

into right and left halves for the pulmonary and the general systemic circulation respectively.

The division of the human atrium begins in the *fourth week* with the growth of a perpendicular ridge from its dorsal and cephalic walls (Fig. 66, B), which extends toward the cavity and ultimately divides it into **right** and **left auricles** (Fig. 65). The atrioventricular canal, with its anterior and posterior

ridges or valves, shares in this partition, becoming thereby the right and the left auriculoventricular orifices. The separation of the atrium, however, is not complete, since there remains in the septum an aperture, the **foramen ovale**, which persists until birth or shortly after.<sup>1</sup>

The **division** of the ventricle, which follows that of the auricle and which is completed by the seventh week, is first indicated by a vertical groove, the **sulcus interventricularis**, seen on both the dorsal and the ventral surface (Fig. 65).

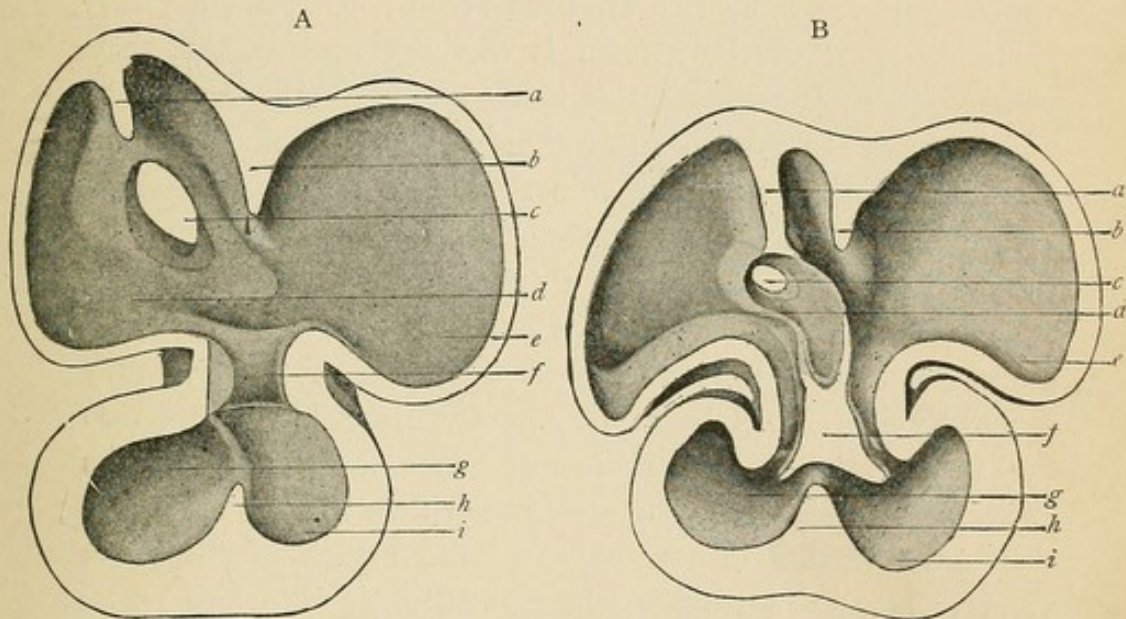


FIG. 66.—A, section of heart of human embryo of 10 mm. (His): *a*, septum spurium; *b*, interauricular septum; *c*, mouth of sinus reuniens; *d*, right auricle; *e*, left auricle; *f*, auricular canal; *g*, right ventricle; *h*, interventricular septum; *i*, left ventricle. B, section of heart of human embryo of about the fifth week (His): *a*, septum spurium; *b*, auricular septum; *c*, opening of sinus reuniens (leader passes through foramen ovale); *d*, right atrium; *e*, left atrium; *f*, septum intermedium; *g*, right ventricle; *h*, ventricular septum; *i*, left ventricle.

From the internal surface, corresponding to the position of the sulcus, a median centrally projecting ridge appears and develops into a septum, thus producing the **right** and the **left ventricles** (Figs. 66 and 67).

The **truncus arteriosus**, after having become somewhat flattened, by the growth of a vertical septum, or partition (Fig.

<sup>1</sup>Occasionally the foramen ovale remains patulous for several weeks or months after birth or even throughout life. As this condition allows the venous blood to mingle with the arterial, the surface of the body is bluish or cyanotic, and a child thus affected is said to be a "blue baby."

67, s), is divided into the **aorta** and the **pulmonary artery**. Though the three septa referred to develop independently of each other there is such correspondence between them, as to position, that the effect is as if they constituted one continuous structure.

Before the division of the atrium into the auricles, its walls pouch out on each side to form the **auricular appendages**, one of which belongs to each future auricle (Fig. 65). While it is still a straight tube, the heart receives at its venous extremity the two vitelline veins. Subsequently this particular part of the atrium is distinguished as the **sinus venosus** or **sinus reuniens**, this being a short thick trunk into which empty, in addition to the vitelline veins, the ducts of Cuvier and the umbilical veins. The mouth of the sinus venosus is guarded by a **valve** composed of two leaflets. In the division of the atrium the sinus venosus falls to the right auricle, while emptying into the left auricle is the single pulmonary vein, which is formed by the union of the four pulmonary veins. Still later, the sinus venosus is merged into the wall of the right auricle, and hence the venous trunks above mentioned empty by separate orifices into its cavity.

The left leaflet of the valve at the mouth of the sinus venosus becomes atrophic; the right divides into two parts, one of which becomes the **Eustachian valve** at the orifice of the inferior vena cava, while the other forms the **valve of Thebesius**, or the **coronary valve**, at the opening of the coronary sinus (the latter being the persistent lower end of the left duct of Cuvier). The Eustachian valve serves to direct the blood from the inferior cava through the foramen ovale so long as that aperture is present. The single pulmonary vein is in like manner incorporated in the wall of the left auricle, the four pulmonary veins in consequence acquiring separate openings into that cavity.

**The Valves of the Heart.**—Before the division of the atrium and the ventricle into right and left halves, the atrio-ventricular canal has the form of a transverse fissure, each lip of which is thickened into a ridge (Fig. 67, A). These ridges or endocardial cushions are the **primitive valves**.

When the atrial partition grows down and the ventricular septum grows up, their free edges meet and unite with the ridges, each ridge being thereby divided, on its atrial surface by the atrial or interauricular septum, and on its ventricular aspect by the ventricular septum, into a right and a left half (Fig. 67, *B*). Since the ridges, at their points of union with

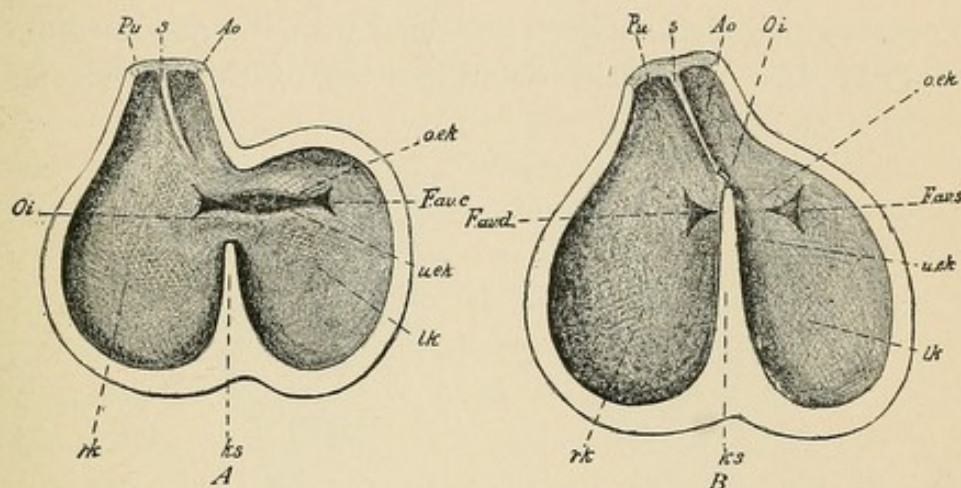


FIG. 67.—Two diagrams (after Born) to elucidate the changes in the mutual relations of the interventricular orifice and the ostium interventriculare as well as the division of the ventricle and large arteries. The ventricles are imagined to have been divided into halves; one looks into the posterior (dorsal) halves, in which, moreover, the cardiac trabeculae, etc., have been omitted for the sake of simplifying the view. *A*, heart of an embryo rabbit, in which the head is 3.5–5.8 mm. long. The ventricle is divided by the ventricular partition (*ks*) into a left and a right half as far as the interventricular orifice (*Oi*). The right end of the foramen atrioventriculare commune (*F. av. c*) extends into the right ventricle; the endocardial cushions (*o. ek*, *u. ek*) are developed. *B*, heart of an embryo rabbit, head 7.5 mm. long. The endocardial cushions (*o. ek*, *u. ek*) of the foramen atrioventriculare commune are fused, and thereby the foramen atrioventriculare commune is now separated into a foramen atrioventriculare dextrum (*F. av. d*) and sinistrum (*F. av. s*). The ventricular partition (*ks*) has likewise fused with the endocardial cushions, and has grown forward as far as the partition (*s*) of the truncus arteriosus. By the closure of the remnant of the ostium interventriculare (*Oi*) the septum membranaceum is formed; *rk*, right, *lk*, left ventricle; *ks*, ventricular partition; *Pu*, arteria pulmonalis; *Ao*, aorta; *s*, partition of the truncus arteriosus; *Oi*, ostium interventriculare; *F. av. c*, foramen atrioventriculare commune; *F. av. d* and *F. av. s*, foramen atrioventriculare dextrum and sinistrum; *o. ek*, *u. ek*, upper and lower endothelial or endocardial cushions.

the septa, fuse likewise with each other, the original orifice is bisected into the **right** and **left auriculoventricular apertures**, the only valves of which are the ridges or cushions in question.

To trace the further development of the fully formed valves, it will be necessary to consider the changes which

now take place in the walls of the heart. It has been seen that the inner surface of the heart acquires a spongy or trabecular structure at a very early stage by the inward projection of muscular processes from the outer tube and the pouching out of the inner endothelial tube to cover these. The wall of the ventricle in consequence is relatively very thick and is made up largely of a network of fleshy columns, the spaces of which network are lined with the endocardium (Fig. 68, *A*). While the outer stratum of the ventricular

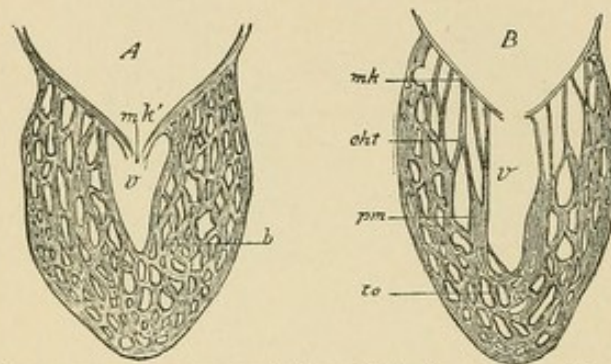


FIG. 68.—Diagrammatic representation of the formation of the atrioventricular valves: *A*, earlier, *B*, later condition (after Gegenbaur): *mk*, membranous valve; *mk'*, the primitive part of the same; *cht*, chordæ tendineæ; *v*, cavity of the ventricle; *b*, trabecular network of cardiac musculature; *pm*, papillary muscles; *tc*, trabeculae carneæ.

wall now becomes more compact by the thickening of the trabeculae—and, to some extent, by their coalescence—the trabeculae in the vicinity of the atrioventricular valves diminish in thickness and lose their muscular character, being replaced by thin connective-tissue cords (Fig. 68, *B*). That part of the ventricular wall which surrounds the atrioventricular orifice and to which the endocardial cushions or primitive valves are attached, likewise becomes deprived of muscle-cells, the remaining connective tissue assuming the form of thin plates. These plates, with the former endocardial cushions attached to their edges, constitute the **permanent auriculoventricular valve-leaflets**. The strands of connective tissue mentioned above as remaining after the degeneration of certain of the muscle-trabeculae are the **chordæ tendineæ** of the adult heart. Attached at one end to the valve-leaflets, their other extremity is continuous

with trabeculæ that have remained muscular, the **adult musculi papillares**.

The **semilunar valves** of the aorta and pulmonary artery appear when the truncus arteriosus divides to form those vessels. The orifice of the truncus arteriosus is provided with a valve having four leaflets (Fig. 69, *A*). By the division of this vessel into the pulmonary artery and the aorta (Fig. 69, *B* and *C*), the lateral leaflets are bisected, the anterior half of each, with the anterior leaflet, going to the anterior vessel—the pulmonary artery—while each posterior or dorsal half, with the dorsal leaflet, falls within the orifice of the aorta. The resulting disposition of the segments of the aortic and pulmonary valves is such that, in the aorta, two leaflets are situated anteriorly and one posteriorly, while in the case of the pulmonary artery these conditions are reversed (Fig. 69, *C*). In the fully developed heart, however, it is found that the aorta has two posterior leaflets and one anterior, and that the pulmonary artery presents one posterior

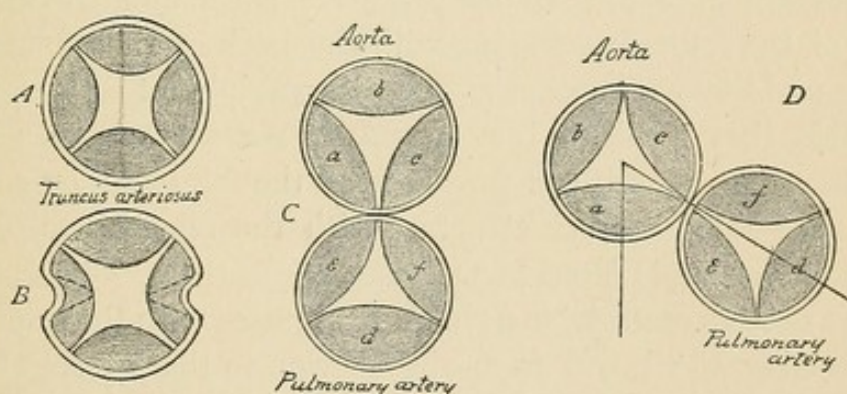


FIG. 69.—Scheme showing division of truncus arteriosus and its valve-leaflets into aorta and pulmonary artery with their leaflets. The division begins in *B*, the lateral leaflets dividing respectively into *a*, *e*, and *c*, *f*. Rotation from right to left shown in *D*.

and two anterior segments. In the division of the truncus arteriosus, the anterior half, or the pulmonary artery, falls to the right ventricle, and the posterior trunk, the aorta, to the left ventricle, the two ventricles lying side by side. In order, therefore, that the ventricles may acquire the relative positions which they hold in the adult there must be such a rotation that the left ventricle comes to lie behind the right.

This rotation of the heart from right to left necessarily alters the relation of the pulmonary artery, causing it to lie not directly in front of the aorta, but in front and to the left. If one conceives of a rotation of the two vessels from right to left through an arc of 60 degrees around a vertical axis, the altered relation of the pulmonary and aortic leaflets becomes at once intelligible (Fig. 69, *C* and *D*).

#### THE ALLANTOIC AND THE PLACENTAL CIRCULATION.

The development of the allantois and its accompanying system of blood-vessels is simultaneous with the decline of the yolk-sac and the vitelline circulation. Since the allantois is an evagination from the gut-tract (see p. 80), it is a splanchnopleuric sac, its walls consisting therefore of an entodermic and a mesodermic layer. Blood-vessels develop within the mesodermic stratum as extensions or branches of previously existing intra-embryonic trunks. These vessels are the **allantoic arteries** and **veins**. The **two allantoic arteries** are branches of the primitive aorta and leave the body of the fetus, in company with the neck of the allantois, at the umbilicus. Having reached the peripheral part of the allantois, they break up into a **capillary plexus**, the extension of which into the villous processes of the false amnion completes the union of that structure with the allantois to form the true chorion (Plate III.).

The **two allantoic veins** develop *pari passu* with the arteries and convey the blood from the chorion to the fetus. Entering the body of the fetus through the still large umbilical aperture, they find their way along the intestinal tube to the **septum transversum**—which structure may be regarded as the primitive diaphragm—to the region of the heart, where they open into the ducts of Cuvier. Each **duct of Cuvier** (Fig. 72, *A*) is formed by the union of the **primitive jugular vein** with the **cardinal vein** of its own side, the cardinal and the jugular veins returning the blood respectively from the lower and upper parts of the trunk. This system of blood-vessels constitutes the **allantoic circulation**; it is of great importance in any ovum that is developed outside of

the body of the mother, as in the case of birds, reptiles, and fishes, in which classes the allantois is the organ of nutrition from the time that the yolk-sac ceases to perform that function until development is complete. In man, however, as in all other mammals except the monotremes and marsupials, the allantoic circulation may be looked upon as, in a measure, rudimentary, since it serves to convey nutriment from the chorion to the fetus only until the formation of the placenta.

The **placental system of blood-vessels**, appearing in the third month with the development of the placenta, includes the principal trunks of the former allantoic system, the allantoic arteries and veins having become the **umbilical vessels**. The **two umbilical arteries** convey impure blood from the fetus to the placenta, where it circulates through the capillaries of that organ and receives oxygen and nutriment from the blood of the mother. As before stated, there is no intermingling of the fetal and the maternal blood, the two currents being separated by the very thin walls of the capillaries, through which osmosis occurs. The purified blood returns to the fetus through the **umbilical veins** and reaches the right auricle through the inferior vena cava, a portion of it having passed through the liver. The two umbilical veins which are present for a time fuse subsequently to form a single vein. The complicated details of the arterial and the venous trunks, and the relation of the latter to the development of the liver and its special system of vessels, may be advantageously considered in separate sections.

#### THE FETAL ARTERIAL SYSTEM.

The **truncus arteriosus**, the large artery which arises from the, as yet, undivided ventricle of the heart, bifurcates into two trunks, the first pair of **visceral-arch vessels** (Fig. 70, 4). These first visceral-arch vessels, also sometimes called the **first aortic arches**, run from the ventral surface of the body along the first visceral arches, toward the dorsum, where they curve downward and pass caudalward, one on each side of the median line, in front of the primitive vertebral column. Very soon there arise from the truncus arteriosus below the

point of origin of the first vessels, four additional pairs of visceral-arch vessels, which similarly pass dorsad along the corresponding visceral arches, and which unite with the dorsal part of the first pair to form the **primitive aorta** of each side. Each primitive aorta results, therefore, from the confluence of all the visceral-arch vessels of its own side

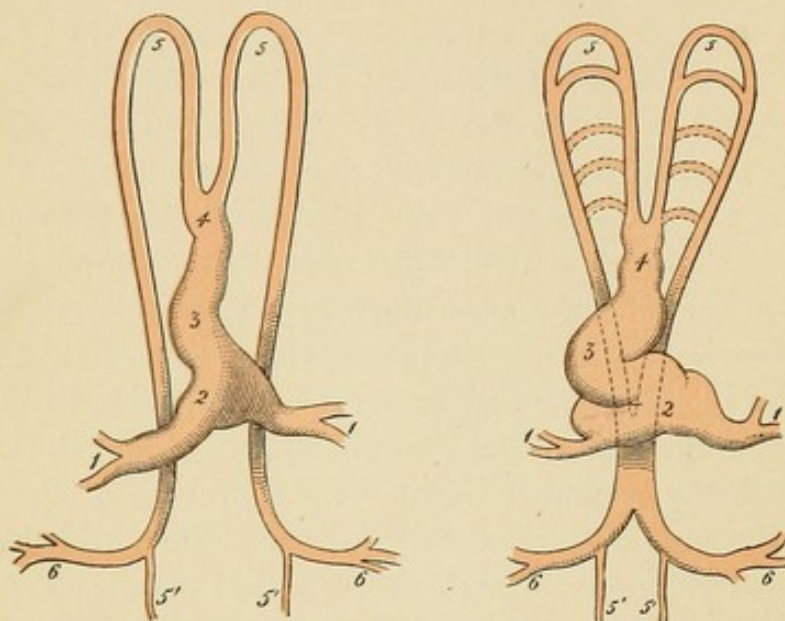


FIG. 70.—Diagrams illustrating arrangement of primitive heart and aortic arches (modified from Allen Thomson): 1, vitelline veins returning blood from vascular area; 2, venous segment of heart-tube; 3, primitive ventricle; 4, truncus arteriosus; 5, 5, upper and lower primitive aortæ; 5', 5', continuation of double aortæ as vessels to caudal pole of embryo; 6, vitelline arteries returning blood to vascular area.

(Fig. 70). The two aortæ afterward become merged into a single trunk. At first the principal branches of the aorta are the vitelline arteries. As these latter vessels become inconspicuous, the allantoic or umbilical arteries come into prominence as the chief branches. Indeed, the umbilical arteries may be said to be the continuation of the aorta, since the largest part of the blood-stream is diverted into them. The aorta proper continues in the median line as the **caudal aorta**, which latter is represented in the adult by the **middle sacral artery**.

So far the arterial system of the fetus presents an absolutely symmetrical arrangement (Fig. 70). Changes very soon occur, however, which lead to the asymmetrical condition

found in the adult. These changes are due to the atrophy of some trunks and the preponderance of others. From the point where the dorsal extremity of the fourth arch joins the fifth, a branch passes to the rudimentary arm (Fig. 71).

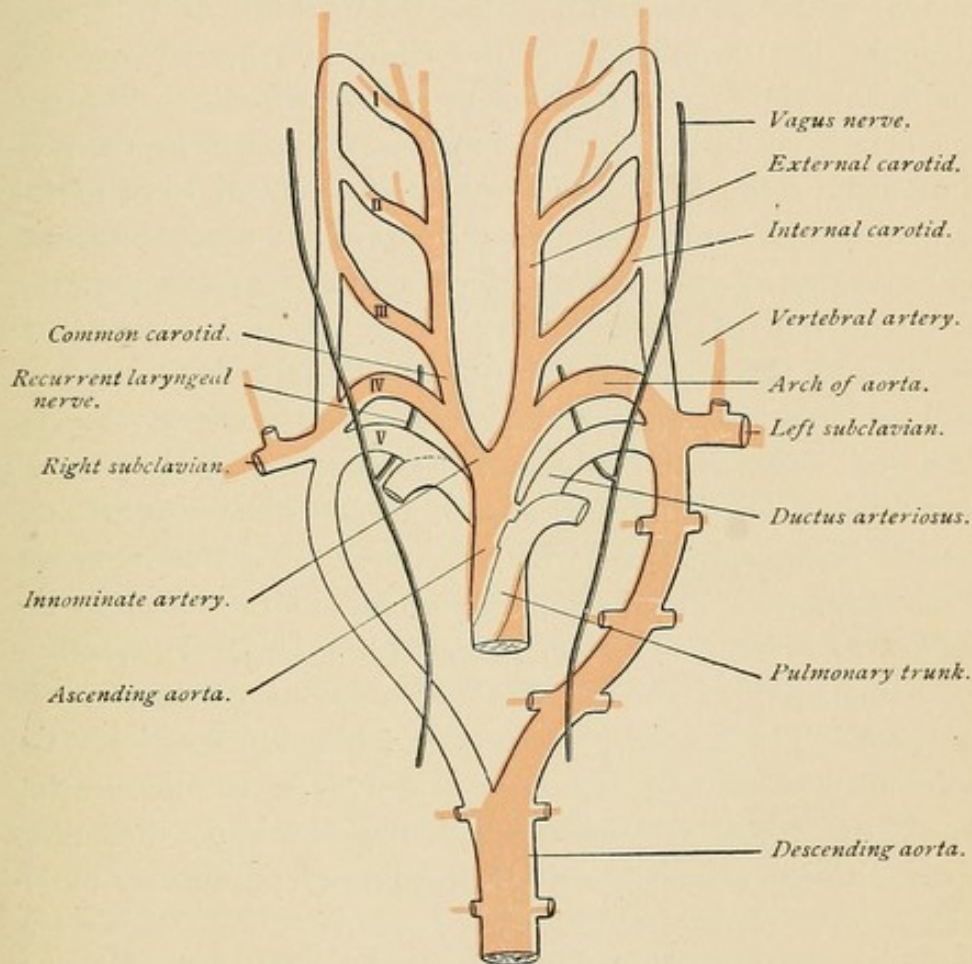


FIG. 71.—Diagram illustrating the fate of the aortic arches in mammals and man (modified from Rathke).

The **first** and **second** arches, except their ventral and dorsal limbs, undergo atrophy. The ventral limbs of the first and second arches persist and become the **external carotid artery**, while their dorsal extremities, with the third visceral-arch vessel, become the **internal carotid artery**. The ventral stem of the **third arch** constitutes the **common carotid**. The **right fourth-arch vessel** becomes the **right subclavian**, its stream of blood being conveyed to the arm by the branch which has taken its origin from the point of junction of the dorsal ends of the fourth and fifth arches. This latter branch is there-

fore the continuation of the subclavian. The ventral segment of the right fourth arch would be represented in the adult by the **innominate artery**. The **fourth arch** of the **left side** assumes a lower position; sinking into the thorax, it becomes the **arch of the aorta**. Since the **right fifth arch** becomes atrophic, the dorsal end of the right fourth-arch vessel—the future right subclavian artery—loses its connection with the primitive aorta, and the latter now appears as the continuation of the *left* fourth arch. The ventral stem of the left third arch, which becomes the future **left common carotid**, and also the **left subclavian**, which arises from the posterior or dorsal end of the left fourth arch, are now branches of the arch of the aorta. When the truncus arteriosus becomes divided into the aorta and the pulmonary artery, the left fifth-arch vessel is the only one of the branches of the truncus that falls to the pulmonary artery, all the other visceral-arch vessels being connected with the aorta. The **left fifth visceral-arch vessel** therefore is represented in the adult by the **pulmonary artery**. The fetal lungs being impervious, only a very small part of the blood of the pulmonary artery is sent to them. The larger portion of the blood passes from the pulmonary artery to the aorta through a communicating trunk, the **ductus arteriosus**, which becomes impervious after birth with the establishment of the proper pulmonary circulation.

These transformations afford an explanation of the different relations of the **recurrent laryngeal nerves** of the two sides. At first they are symmetrically arranged. The pneumogastric nerve, as it crosses the fourth visceral-arch vessel, gives off the recurrent laryngeal nerve, the latter winding around the artery from before backward on its way to the larynx. When the left fourth arch becomes the arch of the aorta and sinks into the chest, the nerve is carried with it; hence after this time, the left nerve is found winding around the arch of the aorta.

**Anomalous arrangements** of the branches of the aortic arch, as well as of the arch itself, are referable to anomalous development of the original system of visceral-arch vessels.

For example, if the right fourth arch, which usually becomes the right subclavian artery, be suppressed from its origin to the point where the artery for the right upper extremity is given off, the blood must find its way into the latter vessel through the dorsal stem of the fourth arch, and this dorsal stem will then become the right subclavian artery. In such case, the right subclavian of the adult will be found to arise from the left extremity of the arch of the aorta and to pass obliquely upward to the right side of the neck behind the trachea and the esophagus.

#### THE FETAL VENOUS SYSTEM.

The **venous system** of the embryo presents several successive phases, corresponding in part with the various stages in the evolution of the arterial system. The first trunks to appear are the **vitelline veins**. These vessels have their origin in the vascular area on the wall of the yolk-sac in the manner already described in connection with the vitelline circulation. The two vitelline or omphalomesenteric veins, which result from the convergence of all the venous trunks of the vascular area, follow the vitelline duct into the body of the embryo through the still widely open umbilical aperture and take their course headward along the intestinal canal to open into the caudal end of the primitive heart-tube (Fig. 70, 1, 1). At a later period they open into the **sinus venosus** of the heart, and still later, when the sinus venosus becomes a part of the general atrial cavity, into the atrium itself. Near their termination these veins communicate with each other by anastomosing trunks that encircle the future duodenal region of the intestinal tube. As the yolk-sac diminishes in size and importance, the vitelline veins decrease in caliber, and the umbilical veins, conveying blood from the allantois and subsequently from the placenta, functionally replace them. The proximal parts of the vitelline veins have an important connection with the circulation of the liver, as will be seen hereafter.

The **umbilical veins**, which are developed in the mesodermic tissue of the allantois, pass from the placenta along the umbilical cord and, entering the fetal body at the umbilicus,

run at first along the lateral, and later along the ventral, wall of the abdomen toward the heart. Meanwhile there have been established a pair of venous trunks, the **primitive jugular veins** (Fig. 72, A), to return the blood from the head and the upper part of the trunk; and a second pair, the **cardinal veins**, which bring the blood from the lower part of the trunk, and especially from the primitive kidneys. The primitive jugular vein—which represents the external jugular of the adult—passing downward along the dorsal region of the neck, meets the cardinal vein of its own side and unites with it near the heart, the short thick trunk thus formed being the **duct of Cuvier**. The right and left ducts of Cuvier converge and open together into the **sinus venosus** (sinus reuniens) of the heart, which also now receives the vitelline veins and the umbilical veins. Upon the development of the upper and the lower limbs, the cardinal vein appears as if formed by the confluence of the internal and external iliac veins; while the primitive jugular below the entrance of the subclavian vein is designated, with the duct of Cuvier, the **superior vena cava**, since, owing to the preponderance of the jugular over the cardinal vein, the Cuvierian duct appears to be a direct continuation of the jugular. At this time, then, there are two superior venæ cavæ, the terminal parts of which, however, are not exactly symmetrical, since the left passes around the dorsal or posterior wall of the atrium, owing to the rotation of the heart from right to left.

The **lower venous trunks** likewise present a symmetrical arrangement. The bilateral symmetry of this stage of the venous system, while permanent in fishes, becomes modified in man to produce the familiar asymmetrical condition of the adult venous trunks by two factors principally—first, the development of an unpaired vessel which is to constitute a part of the inferior vena cava, and second, the atrophy of certain vessels and parts of vessels with a consequent diversion of the major part of their blood-stream into other channels. Associated with these alterations is the evolution of a special set of blood-vessels, the **portal venous system**, for the supply of the developing liver. The development of the

portal system, however, may be deferred for separate consideration (see page 161).

When the sinus venosus becomes a part of the atrium—constituting that part of the wall of the adult auricle which is destitute of *musculi pectinati*—the two ducts of Cuvier, or the superior cavæ, as well as the veins from the abdominal viscera, open by separate orifices into the atrial cavity. An **unpaired vessel** now develops below the heart in the tissue be-

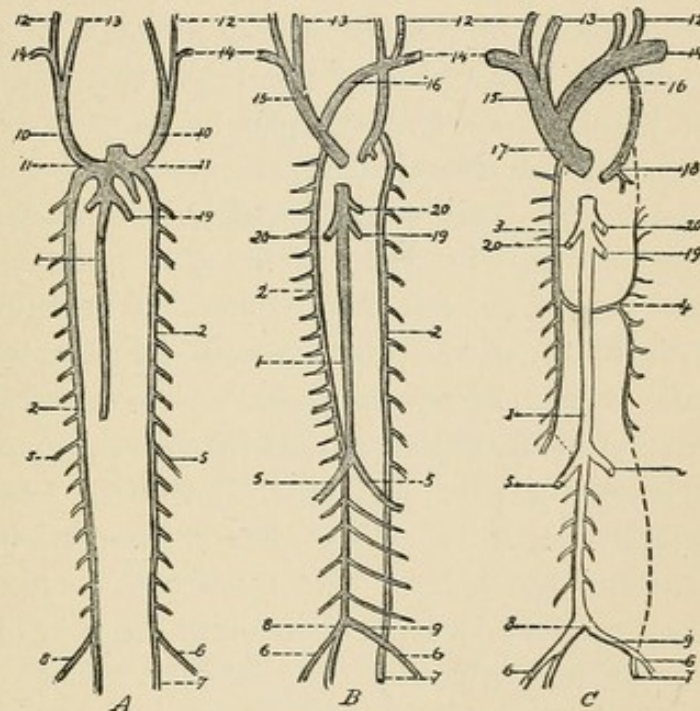


FIG. 72.—Schematic representation of the human venous system, with three successive stages of development (after Hertwig): 1, vena cava inferior; 2, cardinal veins; 3, vena azygos major; 4, vena azygos minor; 5, renal veins; 6, external iliac vein; 7, internal iliac vein; 8 and 9, common iliac veins; 10, early superior venæ cavæ; 11, ducts of Cuvier; 12, primitive jugular vein; 13, internal jugular; 14, subclavian vein; 15 and 16, right and left innominate veins; 17, vena cava superior; 18, coronary vein; 19, duct of Arantius; 20, hepatic veins.

tween the primitive kidneys (Fig. 72, A, 1). This constitutes the upper or cardiac segment of the **inferior vena cava**. The lower extremity of this trunk anastomoses by **two transverse branches** with the right and the left cardinal veins (Fig. 72, B). The cardinal veins of the two sides are further connected by a **transverse trunk** at their lower extremities and by one that passes across the vertebral column just below the heart. In like manner the two superior venæ cavæ commu-

nicate with each other by a transverse vessel, the **transverse jugular vein**, at the upper part of the thorax, above the arch of the aorta. With the exception of the unpaired trunk which is destined to constitute the upper part of the inferior vena cava, the arrangement of the veins at this time is absolutely symmetrical. The apparently meaningless asymmetry of the adult venous trunks is easily accounted for if one notes the alterations in the course of the blood-current which now occur.

The blood-stream of the left superior vena cava gradually becomes entirely diverted into the right cava through the transverse jugular vein, and the part of the left cava below this point, being now functionless, shrivels to an impervious cord (Fig. 72, *C*). This cord or strand of tissue, the remnant of the left superior cava, is found in postnatal life, in front of the root of the left lung, embedded in a fold of the serous layer of the pericardium, the so-called **vestigial fold of Marshall**. Since the left superior vena cava receives, near its termination in the auricle, the large coronary vein, which returns the greater part of the blood from the heart-wall, this proximal extremity of the left cava persists as the **coronary sinus** of the heart. The transverse communicating trunk—the transverse jugular vein—and the part of the left cava above it now constitute the **left innominate vein**, the course of which from left to right is thus explained. The **left superior vena cava of the fetus** is represented in the adult, therefore, by the sinus coronarius, by the atrophic impervious cord lying in Marshall's vestigial fold, by the vertical part of the left innominate vein and by a part of the left superior intercostal vein.

The lowest connecting branch between the cardinal veins enlarges and conveys to the right cardinal vein the blood from the left internal and external iliac veins (Fig. 72), in consequence of which the part of the left cardinal vein below the kidney undergoes atrophy and, finally, complete obliteration. The newly-formed transverse trunk is the **left common iliac vein**. The part of each cardinal vein above the renal region suffers an arrest in growth, in consequence

of which the blood is diverted from these veins into the transverse anastomosing branches before mentioned as connecting the respective cardinal veins with the lower end of the unpaired caval trunk (Fig. 72, *B* and *C*, 5). As a result, the lower half of the right cardinal vein, now receiving at its distal end the two common iliac veins, becomes directly continuous with the unpaired caval trunk, and with it constitutes the **inferior vena cava**. The inferior vena cava, therefore, is partly an independently formed structure and is partly the greatly developed lower half of the right cardinal vein. The upper half of the right cardinal vein, conveying now a relatively small part of the blood-stream, becomes the **vena azygos major**, the termination of which in the superior vena cava is explicable when it is borne in mind that the cardinal and the primitive jugular veins, by their confluence, form the duct of Cuvier.

While no part of the right cardinal vein suffers complete effacement, the left one, in a part of its course, entirely disappears. All the blood of the left external and internal iliac veins being transported to the right side of the body through the lowest transverse trunk—that is, the newly-formed left common iliac vein—the part of the left cardinal vein below the kidney retrogrades and disappears. The part of the left cardinal above the renal region lagging behind in growth, the blood from the left kidney is conveyed to the inferior vena cava by the transverse trunk that connects the cardinal veins in the renal region; this transverse trunk becomes, therefore, the **left renal vein**. Since the **spermatic veins** originally emptied into the cardinal veins, it is found, after these transformations, that the right spermatic opens into the inferior vena cava, while the left spermatic is a tributary of the left renal vein. Some anatomists, indeed, regard the left spermatic vein as the representative of the lower part of the left cardinal vein of the fetus.

As the left renal vein develops into the channel for the major part of the blood from the left kidney, the portion of the left cardinal vein above this point remains an inconspicuous vessel, and that part of it intervening between the

duct of Cuvier and the cross branch (Fig. 72, C, 4) situated immediately below the heart undergoes total obliteration. The blood ascending through the persisting part of the left cardinal vein must therefore pass across to the upper part of the right cardinal vein, now the **vena azygos major**; and the pervious portion of the left cardinal vein, with the transverse trunk referred to, constitutes the **vena azygos minor**.

#### THE FORMATION OF THE PERICARDIUM, THE PLEURÆ, AND THE DIAPHRAGM.

The development of the pericardium is so intimately related with that of the pleuræ and of the diaphragm that an account of it involves a description of the evolution of those structures. By way of facilitating a comprehension of the rather complicated details of the process, the reader is reminded that the tube which constitutes the primitive heart is formed by the coalescence of the two tubes produced within the splanchnic mesoderm, and that this tube and also, for a time, the heart resulting from it, are embedded within the ventral mesentery; and, further, that the part of the ventral mesentery connecting the heart with the ventral

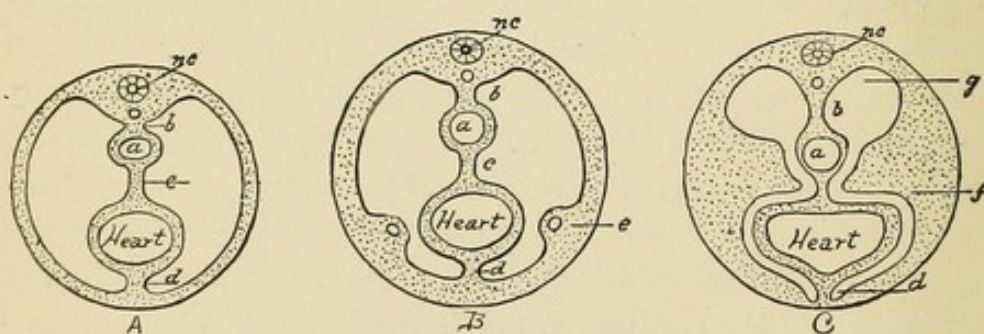


FIG. 73.—Diagrammatic cross-sections of the body of the embryo in the region of the heart at level of future diaphragm: *a*, esophageal segment of gut-tract; *b*, dorsal mesentery; *c*, mesocardium posterius; *d*, mesocardium anterius; *e*, beginning of septum transversum, containing vitelline and allantoic veins; *f*, septum transversum; *g*, thoracic prolongation of abdominal cavity; *nc*, neural canal.

body-wall is the **mesocardium anterius**, while the fold passing from the heart to the gut-tract is the **mesocardium posterius** (Fig. 73, A, and Fig. 61, C). The space between the heart and the body-wall is a part of the body-cavity or cœlom (throat-cavity of Kölliker, parietal cavity of His). The

first indication of the separation of this space from the future abdominal cavity is furnished by the appearance of a **transverse ridge** of tissue growing from the ventral and lateral aspects of the body-wall. This mass is the **septum transversum**. It bears an important relation to the course of the vitelline and the umbilical veins. As the veins diverge from the body-wall to reach the heart, they carry with them, as it were, the parietal layer of the mesoderm in which they are embedded, forming on each side a fold that projects medially and dorsally (Fig. 73, *B* and *C*), the two folds approaching and finally meeting with the ventral mesentery in the median plane. The septum transversum thus formed contains in the region nearer the intestine a mass of embryonal connective tissue which is called the **liver-ridge** or **prehepaticus** from the fact that the developing liver grows into it. Since the septum transversum, exclusive of the so-called liver-ridge, is the primitive diaphragm, it will be seen that the liver, in the early stages of its growth, is intimately associated with the anlage<sup>1</sup> of the diaphragm. The septum transversum partially divides the body-cavity into a pericardiothoracic and an abdominal part, as shown in Fig. 73, *B* and *C*. Near the dorsal wall of the trunk, on each side of the intestine and its mesentery, the septum is wanting, and thus the two spaces communicate with each other by openings that are known as the **thoracic prolongations** of the abdominal cavity. At this stage, then, the four great serous sacs of the body, the **two pleural**, the **pericardial**, and the **abdominal**, are indicated, but are still in free communication with each other.

The **pericardial cavity** is the first one of these to be closed off; subsequently the **pleural sacs** are delimited from the abdominal space. Just as the transverse septum, which partly forms the floor of the thoracic cavity, holds an important relation to the course of the vitelline and the umbilical veins on their way to the heart, so is a vertical septum

<sup>1</sup> *Anlage*, a German word signifying *groundwork*, or, in embryology, the first crude outline of an organ or part, has come into use in English writings upon the subject because there is no exact English equivalent for it.

(Fig. 74, *A, b*) which separates the pericardial space from the pleural spaces associated with the position of a large vein. This vein, the **duct of Cuvier**, formed in the upper part of the thorax by the confluence of the cardinal and the jugular veins, lies at first near the dorsal body-wall and then along its lateral aspect. In the latter position it encroaches upon the pleuropericardial space and is covered by the somatic or parietal mesoderm (Fig. 74, *A*). It is this inwardly project-

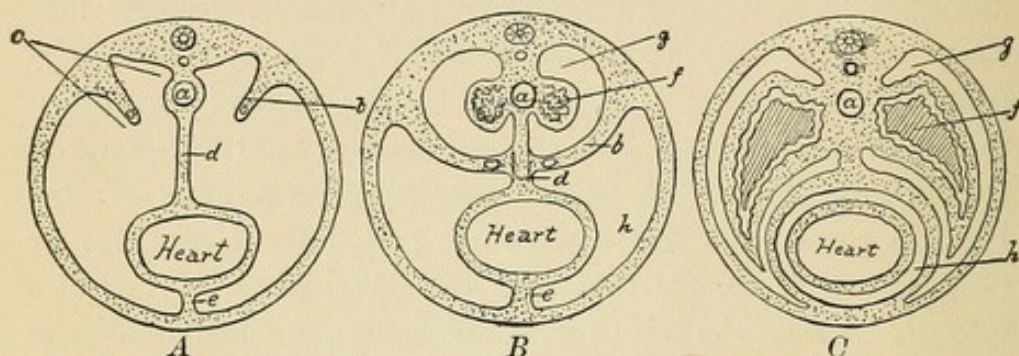


FIG. 74.—Diagrammatic cross-sections of the body of the embryo in the region of the heart entirely above the level of the diaphragm: *a*, esophagus; *b*, pleuropericardial fold containing duct of Cuvier; *c*, pleuropericardial space; *d*, mesocardium posterior; *e*, mesocardium anterior; *f*, lung; *g*, pleural cavity; *h*, pericardial cavity.

ing vertical fold of serous membrane containing the duct of Cuvier which constitutes the **pleuropericardial fold** and the appearance of which initiates the division of the thoracic cavity into two spaces, one for the heart and one for the lungs. The pleuropericardial fold continues to grow toward the median plane of the body until it meets the mesocardium posterior (Fig. 74, *B*), with which it fuses, thus completing the pericardial sac (*h*) and isolating it from the pleural space (*g*).

The heart is still relatively very large and occupies the greater part of the thoracic cavity, leaving only a comparatively small space, situated dorsally, for the accommodation of the developing lungs. This latter space, as previously mentioned, remains for a long time in communication with the abdominal cavity by the two thoracic prolongations of the latter, which lie one on each side of the intestinal tube and its mesentery (Fig. 73, *C*, and Fig. 74, *A, B*). Reference to Fig. 74, *B*, will show that these tube-like spaces are enclosed completely by serous membrane and that they are

entirely distinct from each other. It is evident also, that the mesial wall of each space is constituted by the mesocardium posterius and the dorsal mesentery. The lungs first appear as two little sacs, connected by a common pedicle, the future trachea, with the upper end of the esophagus. As they grow downward in front of the esophagus and in contact with it, they push the serous membrane before them carrying it away from the esophagus (Fig. 74, *B*), and thus they acquire an investment of serous membrane, which is the **visceral layer of the pleura**. The layer of serous membrane in contact with the body-wall is the **parietal layer of the pleura**. The lower extremities of the lungs at length come into relation with the upper surface of the liver, from which organ they are finally separated by the growth of two folds, the **pillars of Uskow**, from the dorsolateral region of the body-wall. These folds or ridges project forward and unite with the earlier formed septum transversum to complete the **diaphragm**. So far, however, the diaphragm is merely connective tissue, the muscular condition being acquired later by the ingrowth of muscular substance from the trunk. Occasionally the dorsal or younger part of the diaphragm fails to unite with the ventral or older fundament on one side of the body, leaving an aperture through which a portion of the intestine may pass into the thoracic cavity. Such a condition constitutes a **congenital diaphragmatic hernia**.

The heart and its pericardial sac occupy the greater part of the thoracic cavity, while the lungs are merely narrow elongated organs lying in the dorsal part of this space as shown in Fig. 74, *B*. As the lungs increase in diameter, they spread out ventrally and gradually displace the parietal layer of the pericardium (Fig. 74, *B*) from the lateral wall of the chest, crowding the pericardium forward and toward the median plane of the body (see Fig. 74, *C*) until finally the adult relationship of these structures is established.

#### THE PORTAL CIRCULATION.

The circulation of the adult liver is peculiar in that the organ is supplied not only with arterial blood for its nutrition

but receives also venous blood laden with certain products of digestion obtained from the alimentary tract, the spleen, and the pancreas. This venous blood enters the liver through the portal vein and is designed to supply to the gland the materials for the performance of its special functions.

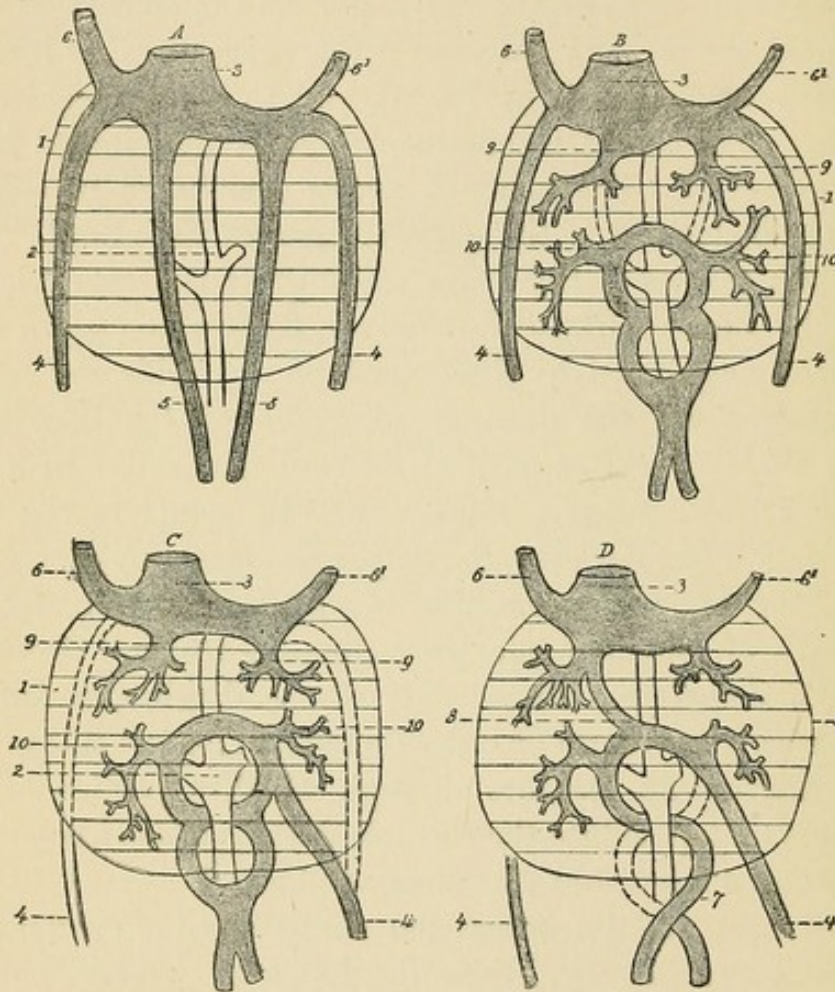


FIG. 75.—Four successive stages in the development of the portal venous system (from Tourneux, after His): 1, outline of liver; 2, duodenum; 3, sinus venosus; 4, 4, umbilical veins; 5, 5, *A*, vitelline veins, which in *B* and *C* are connected by the annular sinus; 6, superior vena cava; 6', coronary vein; 7, portal vein; 8, ductus venosus; 9, 9, *venæ hepaticæ revehentes*; 10, 10, *venæ hepaticæ advehentes*.

As might be expected from the fact that the liver is an appendage of, and a direct outgrowth from, the intestinal canal, it receives its blood-supply, in the early stages of its development, from the vessels that supply the primitive intestine, that is, from the vitelline veins. These veins, on their way to the heart, pass along the intestinal canal and are connected with each other in the region of the future

duodenum by trunks that encircle the bowel, these connecting vessels collectively constituting the **annular sinus** (Fig. 75, *B* and *C*). The liver originates from a small diverticulum which is evaginated from the ventral wall of the intestinal canal. Growing forward between the folds of the ventral mesentery, this little tubular sac divides and subdivides so as to produce a gland of the compound tubular type. The developing liver is from the first in close relation with the vitelline veins and their ring-like anastomosing branches, and receives its blood-supply from the latter through vessels that are known as the **venæ hepaticæ advehentes** (Fig. 75, 10, 10). These afferent vessels break up within the liver into a system of capillaries, from which the blood passes through the efferent vessels, the **venæ hepaticæ revehentes**, into the terminal parts of the vitelline veins. Thus a part of the blood of the vitelline veins is diverted to the liver and, after circulating through that organ, is returned to them further on to be conveyed to the heart. As the liver, with its increasing development, requires more and more blood, the entire blood-stream of the vitelline veins passes to it, and the parts of these veins between the **venæ hepaticæ advehentes** and the **venæ hepaticæ revehentes** become obliterated (Fig. 75, *B* and *C*). The vitelline veins, therefore, leave the intestinal canal at the duodenal region and traverse the liver on their way to the heart. *In this early stage of the development of the liver, then, it receives its nutrition from the yolk-sac, through the vitelline veins.*

When the yolk-sack undergoes retrogression, as it does about the fifth week, the liver must draw upon the allantoic and the placental vessels for its nutrition. To do this it must acquire connection with the umbilical veins. The latter vessels pass upward from the umbilicus along the ventral wall of the body and empty into the sinus venosus of the heart above the site of the liver (Fig. 75, *A*, 4, 4). The two umbilical veins fuse to form one, and this one effects communications beneath the liver with the **venæ hepaticæ advehentes** from the vitelline veins. As the needs of the liver exceed the capacity of the vitelline veins, more and more of the blood of

the umbilical vein is sent to it, until finally all the blood of the latter vein passes into the liver and reaches the heart through the terminal part of the left vitelline vein. (The left vitelline vein very early begins to predominate over the right.) The part of the umbilical vein above the liver undergoes atrophy and disappears. Although, meanwhile, the yolk-sac has dwindled, the vitelline veins persist, in part, since they receive blood from the walls of the alimentary tract. *The liver now, in this second stage of its development, receives blood from two sources, the abdominal viscera and the placenta.*

As previously indicated, the proximal half of the inferior vena cava develops as an unpaired vessel connected with the primitive heart. It opens above into the left vitelline vein. In a short time it far outstrips the latter in growth and, with its extension downward, the point of union of the two vessels is carried downward toward the liver, the vitelline vein becoming larger and constituting now the **hepatic vein**. Meanwhile the volume of blood flowing through the umbilical vein has increased to such an extent that the liver is no longer able to transmit it to the inferior vena cava, and consequently a communication is established between these two vessels on the under surface of the liver. The connecting branch is the **ductus venosus** or **ductus Arantii**. The blood of the umbilical vein is divided, therefore, into two streams—one that enters the inferior vena cava directly through the ductus venosus and one that traverses the liver on its way to the cava.

The **portal vein** results from the persistence of a part of the vitelline veins. The vitelline veins, as we have seen, anastomose with each other by two ring-like branches that encircle the duodenum. The right half of the lower ring and the left half of the upper one atrophy, so that the blood of the vitelline veins makes its way to the liver through the left half of the lower ring and the right half of the upper one (Fig. 75, *D*). This single vessel constitutes the **portal vein**, and its course, therefore, is backward around the left side of the duodenum and then to the right. So long as the yolk-sac is present, the vein receives blood both from it and

from the walls of the intestine. After the disappearance of the yolk-sac, the intestinal and the visceral veins are the sole tributaries of the portal vein.

#### THE FINAL STAGE OF THE FETAL VASCULAR SYSTEM.

The circulation of the fetus at birth and the changes ensuing immediately thereafter may now be easily understood. The fetal blood being sent to the placenta through the hypogastric or umbilical arteries, receives oxygen there and is returned to the body of the fetus through the umbilical vein. The latter vessel takes its course upward along the ventral wall of the abdomen to the under surface of the liver, lying here in the anterior part of the longitudinal fissure. In this position the blood-stream of the umbilical vein is divided into two parts, one of which unites with the fetal portal vein to enter the liver, while the other passes through the ductus venosus directly to the inferior vena cava. The blood which enters the liver, after traversing that organ, reaches the inferior vena cava through the hepatic veins. Thus, in the one case directly, in the other case by passing through the liver, all the placental blood reaches the inferior vena cava and passes on to the right auricle of the heart.

From the right auricle the blood passes through the foramen ovale to the left auricle, and thence, through the mitral orifice, to the left ventricle. Being driven from the left ventricle into the aorta, it is conveyed through the branches of the aortic arch to the head and the upper extremities. Finding its way into the veins of these parts, it is returned, through the superior vena cava, to the right auricle, from which cavity it passes, through the tricuspid orifice, into the right ventricle. From the right ventricle it goes into the pulmonary artery. Since the lungs are not as yet pervious, or but very slightly so, the current is deflected almost entirely through the ductus arteriosus to the descending aorta instead of going to the lungs. Some of the blood of the descending aorta is distributed to the various parts of the body below the position of the heart, while some of it is sent through the hypogastric or umbilical arteries to the pla-

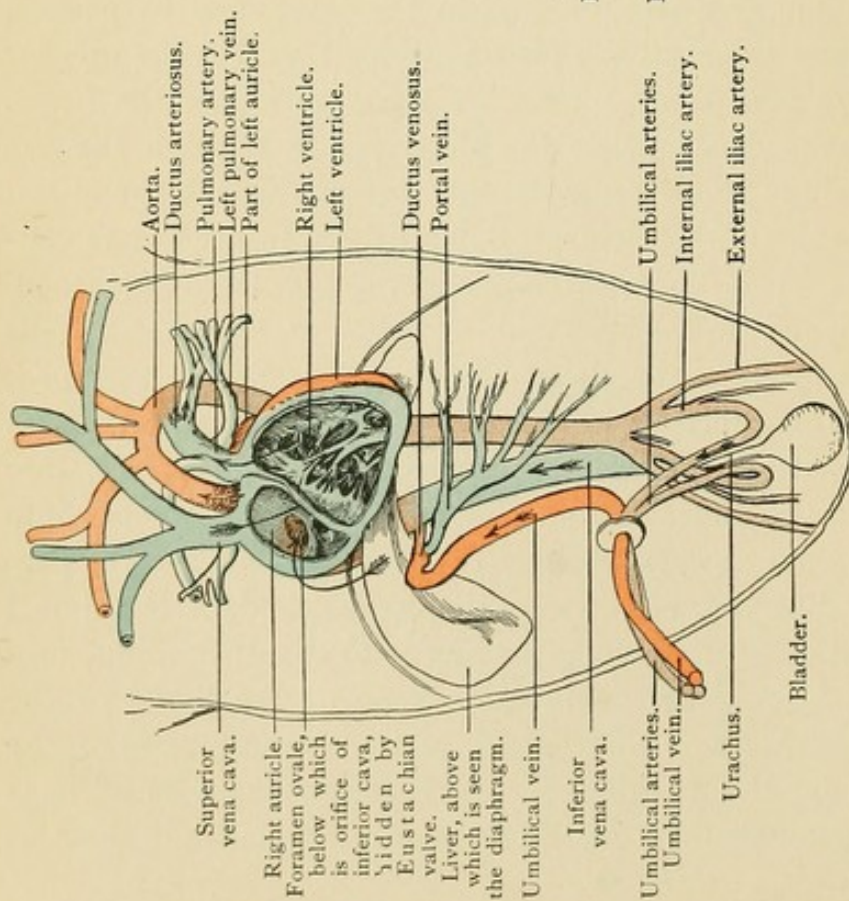


FIG. 76.—Diagram of fetal circulation before birth. The arrows indicate the course of the blood-current; the colors show the character of the blood carried by the different vessels.

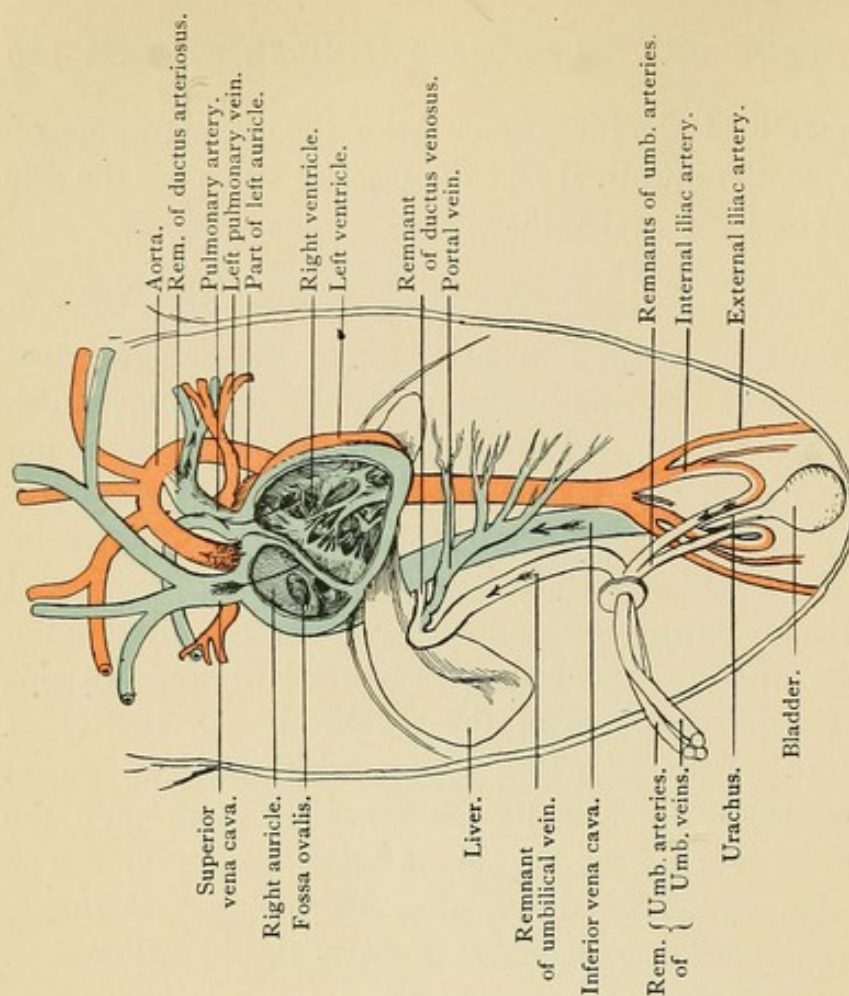


FIG. 77.—Diagram of circulation after birth. The ductus venosus, the foramen ovale, and the ductus arteriosus are now closed, and no longer transmit portions of the blood-current.

centa for aëration. It is evident that no part of the fetal blood, except that in the umbilical vein, is entirely pure, the venous and the arterial blood being always more or less mixed.

With the detachment of the placenta at birth, several marked alterations occur. The circulation through the umbilical vein ceases, that part of this vessel which intervenes between the umbilicus and the portal fissure of the liver becoming, in consequence, an impervious fibrous cord, the **round ligament of the liver**. The ductus venosus likewise suffers obliteration. Since the lungs now assume their proper function of respiration, the communication between the right and the left sides of the heart and also that between the pulmonary artery and the aorta cease. Hence, the respective avenues for these communications, the **foramen ovale** and the **ductus arteriosus**, become obsolete. There being no further need for the hypogastric (umbilical) arteries, the circulation through them ceases, and they become mere cords of fibrous tissue, whose presence is evidenced by two ridges in the peritoneum on the inner surface of the anterior wall of the abdomen. The **proximal parts** of these arteries persist, however, as the superior vesical arteries.

## CHAPTER XI.

### THE DEVELOPMENT OF THE DIGESTIVE SYSTEM.

THE adult digestive system consists of the **mouth** with its accessory organs, the **teeth**, the **tongue**, and the **salivary glands**; of the **pharynx**, the **esophagus**, the **stomach**, and the **small** and the **large intestine**, including also the important glandular organs, the **liver** and the **pancreas**. Notwithstanding the apparent complexity of its structure, the alimentary tract may be regarded as a tube, certain regions of which have become specialized in order to adapt them to the performance of their respective functions, the salivary glands, the liver, and the pancreas being highly differentiated evaginations of its walls. While in man and in the higher vertebrates the tube is thrown into coils by reason of its excessive length, in the lower-type animals it is much more simple in its arrangement. For example, in certain fishes and in some amphibians the alimentary tract has the form of a slightly flexuous tube, the deviations from the simple straight canal being few and insignificant, and the stomach being represented by a local dilatation of the tube.

The simple condition obtaining in the representatives of the animal kingdom referred to above suggests the likewise simple fundamental plan of the human embryonic gut-tract. There is, in fact, a period in development when the gut-tract of the human embryo has the form of a **simple straight tube**. The processes incident to the formation of this tube mark the earliest stages of the development of the alimentary system, the tube itself acquiring definite form simultaneously with the production of the body of the embryo.

The first indication of the alimentary canal appears at a very early period of development, being inaugurated in fact by those important alterations that serve to differentiate the

blastodermic vesicle into the body of the embryo and the embryonic appendages. It will be remembered that, after the splitting of the parietal plate of the mesoderm into its two lamellæ, and the union of the outer of the layers with the ectoderm and of the inner with the entoderm to form respectively the **somatopleure** and the **splanchnopleure**, these two double-layered sheets undergo folding in different directions. Before the folding occurs, the germ is a hollow sphere whose cavity is the archenteron and whose walls are the somatopleure and the splanchnopleure.<sup>1</sup> While the somatopleure in a zone corresponding with the margin of the embryonic area becomes depressed and is carried under that area to form the lateral and ventral body-wall of the embryo (Plate II., Figs. 2, 3, and 4), and also more distally folds up over the area to produce the amnion and the false amnion, the splanchnopleure, likewise in a line corresponding with the periphery of the embryonic area, is depressed and carried inward from all sides toward the position of the future umbilicus. This folding in of the splanchnopleure effects the division of the archenteron into two parts, a smaller cavity falling within the body of the embryo, which latter is forming at the same time, and a larger extra-embryonic compartment, which is the **yolk-sac** or **umbilical vesicle**. The intra-embryonic cavity is the **gut-tract**. The constricted communication between the two is the **vitelline duct**. While the vitelline duct is still a rather wide aperture, the anterior and posterior parts of its intestinal orifice are designated respectively the **anterior** and the **posterior intestinal portals**.

As the somatopleure closes in around the vitelline duct, it forms the wall of the abdomen, the opening left, which is traversed by the duct, being the **umbilical aperture**.

It is evident therefore that the lining of the gut-tract is constituted by the innermost germ-layer, the entoderm, and that all its epithelial elements are consequently of entodermic origin. The folding in of the splanchnopleure begins at about the end of the second week, and is so far advanced

<sup>1</sup> Strictly speaking, the somatopleure and the splanchnopleure are not formed *before* the folding occurs, but the processes go on at the same time.

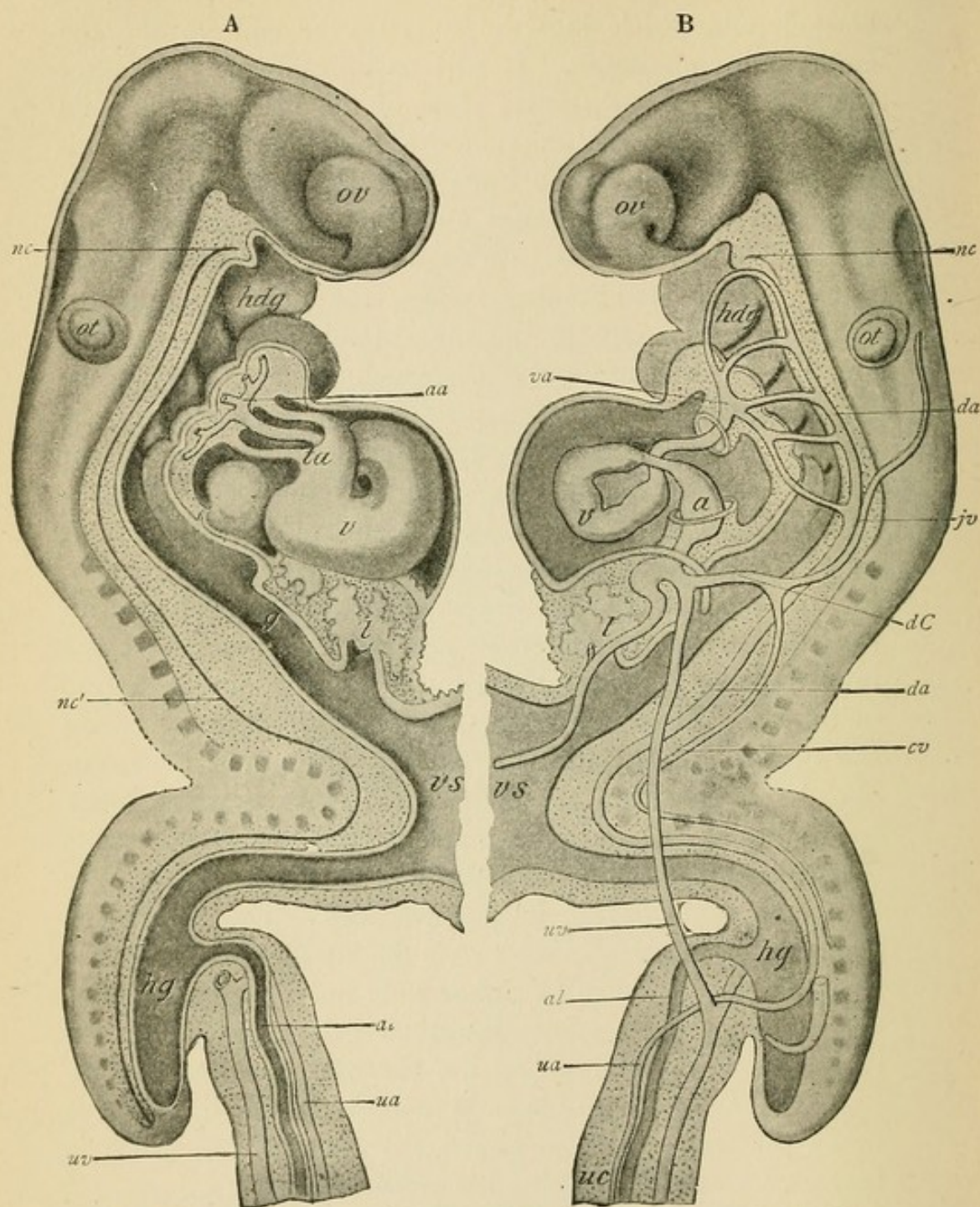


FIG. 78.—Reconstructions of human embryo of about seventeen days (His): *ov*, optic and *ot*, otic vesicles; *nc*, *nc'*, notochord; *hdg*, head-gut; *g*, mid-gut; *hg*, hind-gut; *vs*, vitelline sac; *l*, liver; *v*, *ta*, primitive ventricle and truncus arteriosus; *va*, *da*, ventral and dorsal aortæ; *aa*, aortic arches; *jv*, primitive jugular vein; *cv*, cardinal vein; *dC*, duct of Cuvier; *uv*, *ua*, umbilical vein and artery; *al*, allantois; *uc*, umbilical cord.

before the end of the third week that the archenteron is definitely divided into the gut-tract and the yolk-sac.

In its earliest definite form, then, the **gut-tract** is a tube extending from one end of the embryonic body to the other, which opens widely at the middle of its ventral aspect into the vitelline duct, but which is closed at both ends. It is usual to speak of the primitive gut-tract as consisting morphologically of three parts, the **head-gut**, which is the region on the headward side of the orifice of the vitelline duct; the **hind-gut**, which is the part near the tail-end of the embryo; and the **mid-gut** or intervening third portion (Fig. 78).

The closed head-end of the gut-tube corresponds with the floor of the primitive mouth-cavity, the two spaces being separated by a thin veil of tissue, which consists of the entoderm and the ectoderm and is called the **pharyngeal membrane** (Fig. 79). A considerable proportion of the so-

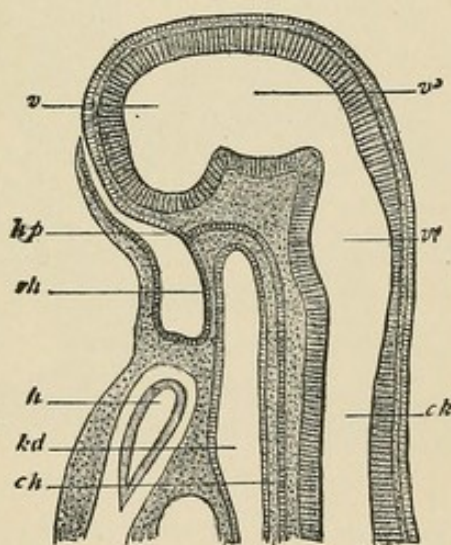


FIG. 79.—Median section through the head of an embryo rabbit 6 mm. long (after Mihalkovics): *rh*, membrane between stomodæum and fore-gut, pharyngeal membrane (Rachenhaut); *hp*, place from which the hypophysis is developed; *h*, heart; *kd*, lumen of fore-gut; *ch*, chorda; *v*, ventricle of the cerebrum; *v*<sup>3</sup>, third ventricle, that of the between-brain (thalamencephalon); *v*<sup>4</sup>, fourth ventricle, that of the hind-brain and after-brain (epencephalon and metencephalon, or medulla oblongata); *ck*, central canal of the spinal cord.

called head-gut constitutes the primitive pharynx. This region of the tube has a relatively large caliber, and presents on its lateral and ventral walls the series of recesses or evaginations known as the **throat-pockets** or **pharyngeal pouches** (Fig. 60).

While the inner, entodermic layer of the gut-tube becomes the intestinal mucosa, the outer, mesodermic stratum produces the muscular and the connective-tissue parts of the bowel-wall, the most superficial layer of the latter with its mesothelial or endothelial cells forming the visceral layer of the peritoneum. Since the mesodermic layer of the splanchnopleure of each side is continuous with the corresponding mesodermic layer of the somatopleure on either side of the embryonic axis, the primitive intestinal canal has a broad area of attachment with the dorsal wall of the body-cavity (Fig. 80). The ventral wall is likewise connected with the

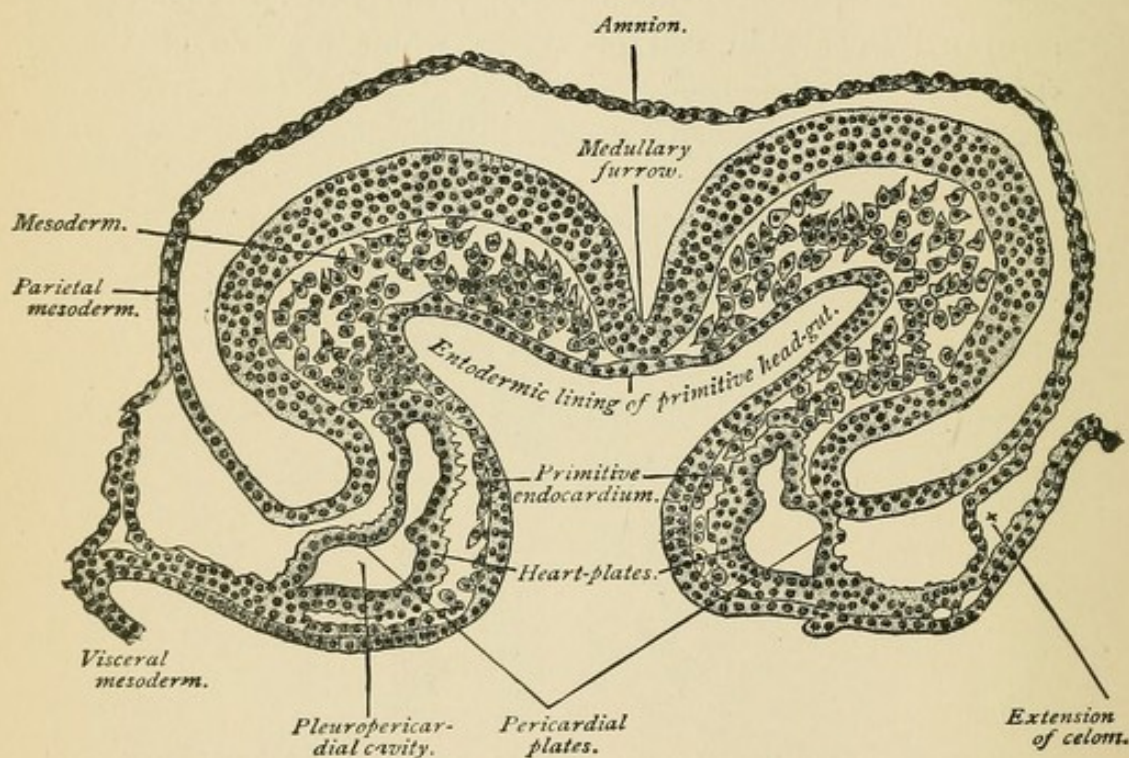


FIG. 80.—Transverse section of a sixteen-and-a-half-day sheep-embryo (Bonnet).

ventral body-wall throughout the anterior or upper part of its extent by the continuity of the splanchnopleuric mesoderm of each side with the somatopleuric mesoderm of the same side. As development advances, the body-cavity increases in caliber more rapidly than does the intestinal tube, so that the interval between the two is augmented, in consequence of which the masses of connective tissue uniting the dorsal and the ventral surfaces of the gut with the corre-

sponding walls of the body-cavity become drawn out so as to constitute in each case a median vertical fold consisting of two closely approximated layers of serous membrane with a little connective tissue between them. These folds are the **dorsal** and the **ventral mesenteries** (Fig. 81). While the

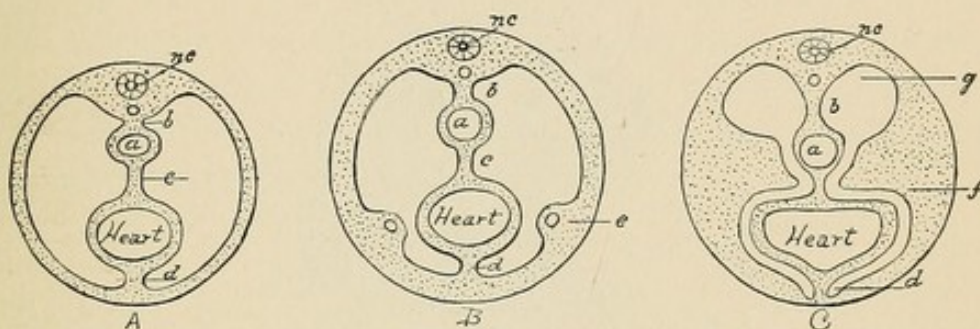


FIG. 81.—Diagrammatic cross-sections of the body of the embryo in the region of the heart at level of future diaphragm: *a*, esophageal segment of gut-tract; *b*, dorsal mesentery; *c*, mesocardium posterior; *d*, mesocardium anterior; *e*, beginning of septum transversum, containing vitelline and allantoic veins; *f*, septum transversum; *g*, thoracic prolongation of abdominal cavity; *nc*, neural canal.

dorsal mesentery extends throughout the entire length of the canal, the ventral fold is present only at its anterior or upper part, corresponding in the extent of its attachment to the digestive tube to that portion representing the future stomach and upper part of the duodenum (Fig. 82). The ventral mesentery at first is present throughout the entire extent of the canal, but very early undergoes obliteration except in the situation above noted. Concerning the reason and the method of its disappearance nothing is definitely known.

The intestinal tube, at a comparatively early stage, presents on its ventral surface near the posterior or caudal end a small evagination that enlarges to form the **allantois** (see p. 80). While a part of the intra-embryonic portion of the allantois dilates and develops into the bladder, the part between this latter and the intestine is known as the **urogenital sinus**. The part of the gut-tube posterior to, caudad of, the origin of the allantois, is a blind pouch known as the **cloaca**. The latter is, therefore, the common termination of the urinary and the intestinal tracts.

To repeat, we have now, in the third week of development, the alimentary canal represented by a single straight tube

(compare Fig. 78), closed at each end, but with mouth-cavity and anus both indicated, the tube lying within a larger tube, the body-cavity, with the walls of which latter it is connected by the dorsal and ventral mesenteries. Along the dorsal wall

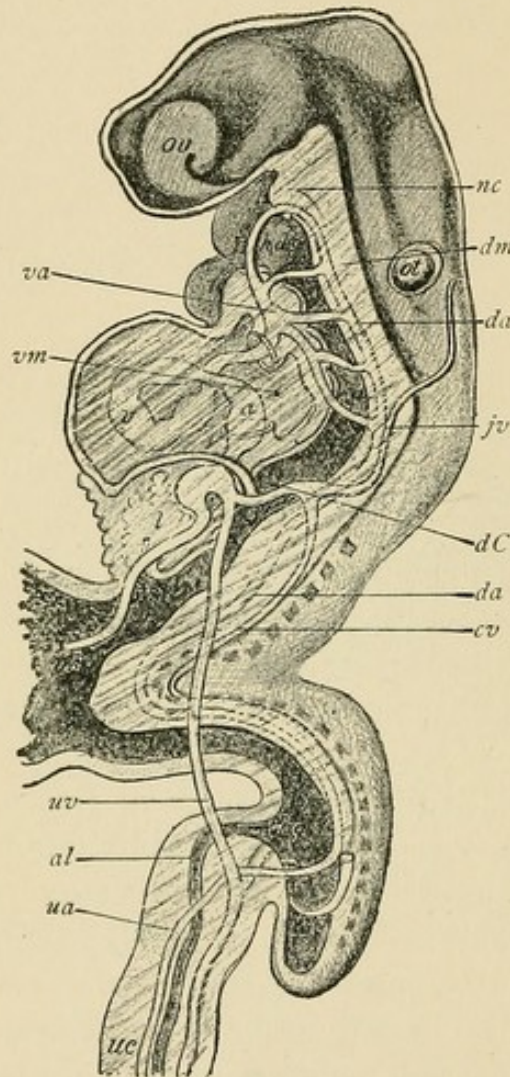


FIG. 82.—Reconstruction of human embryo of about seventeen days (after His): *ov*, optic and *ot*, otic vesicles; *nc*, notochord; *hdg*, head-gut; *g*, mid-gut; *hg*, hind-gut; *vs*, vitelline sac; *l*, liver; *v*, primitive ventricle; *va*, *da*, ventral and dorsal aortæ; *jv*, primitive jugular vein; *cv*, cardinal vein; *dC*, duct of Cuvier; *uv*, *ua*, umbilical vein and artery; *al*, allantois; *us*, umbilical cord; *dm*, dorsal mesentery; *vm*, ventral mesentery (modified from His).

of the body-cavity, dorsad to the parietal peritoneum, pass the two primitive aortæ, and later, the single aorta which results from the fusion of these two. Between the two folds of the dorsal mesentery pass the blood-vessels that nourish the walls of the gut. Within the ventral mesentery are the

vitelline veins, which bring the blood from the yolk-sac and convey it to the primitive heart. On the ventral wall of the gut is the wide aperture of the vitelline duct. Farther caudad, also on the ventral surface of the bowel, is the orifice of the allantois. These conditions may be better understood by reference to Figs. 78 and 82. Before tracing the further development of the abdominal part of the alimentary system, it will be proper to note certain very important processes pertaining to its anterior or head-extremity, and also to consider the formation of the anus.

### THE MOUTH.

The development of the **mouth**, the **tongue**, the **teeth**, and the **salivary glands** has been fully described on pages 122-131. In this connection, therefore, it will be necessary to call attention to only a few of the salient features of their evolution.

The **oral cavity** is produced by a folding in of the surface-ectoderm, the fossa thus formed becoming deeper until it meets the head-end of the gut-tract. From the walls of this fossa the **salivary glands** are developed as evaginations, in the manner already described, while the **teeth** are specialized growths of its ectodermal lining and of the underlying mesoderm (*vide* p. 125). The first intimation of this infolding is apparent at the twelfth day in the form of a localized thickening of the surface-cells on the ventral surface of the body of the embryo near the head-end. The thickened area is the **oral plate**, which speedily becomes depressed, producing the **oral pit** or **fossa**. By the third week, the oral fossa or **stomodeum** is a well-marked pit of pentagonal outline, its boundaries being the nasofrontal process above, the maxillary processes laterally, and the mandibular arches below. The original oral plate, having receded farther and farther from the surface and forming the posterior limit of the mouth-cavity, now separates that cavity from the pharyngeal region of the gut-tube and comes into contact with the anterior wall of the latter. It is called the **pharyngeal membrane** (Fig. 79).

Its disappearance occurs at some time during the fourth week, by which event the gut-tube is brought into communication with the mouth.

The exact position of the pharyngeal membrane is not easily definable. It is certain, however, that it falls farther back than the posterior limit of the adult oral cavity, since the primitive mouth includes the anterior part of the adult pharynx. For example, the diverticulum that gives rise to the anterior lobe of the pituitary body belongs to the primitive mouth, yet its vestige, the pharyngeal bursa or Rathké's pocket, is found in the pharynx of the adult. The primitive oral cavity, by the growth of the palate, becomes divided into the adult mouth and the nasal cavities. The **hard palate** is completed in the ninth week and the **soft palate** in the eleventh week.

### THE PHARYNX.

The **pharynx** is represented in the embryo by the expanded cephalic end of the primitive gut-tract. It is of greater relative length in the earlier stages of development than later, including as it does, almost half the length of the gut-tube in the fourth and fifth weeks. The primitive pharyngeal cavity is widest at its anterior or cephalic extremity and narrowest at the opposite end, tapering here into the esophagus. Until the breaking down of the pharyngeal membrane, which takes place in the fourth week, this structure marks the anterior limit of the pharynx and separates it from the oral cavity.

The **pharyngeal pouches** or **throat-pockets** have been referred to in connection with the **visceral arches** on page 100. They are out-pocketings or evaginations of the entodermal lining of the pharynx, there being four furrows on each lateral wall, and they pass from the ventral toward the dorsal wall of the cavity, each pouch lying between two adjacent visceral arches. The entoderm of the pouches comes into close relation with the ectoderm of the outer visceral furrows (Fig. 60). The mesodermic stratum being

absent from the pharyngeal pouches, the ectoderm and the entoderm are in contact, and constitute the **closing membrane**. As previously mentioned, this closing membrane ruptures in aquatic vertebrates, in consequence of which the pharyngeal cavity in such animals acquires a number of openings. In man, as in other mammals, and in birds, such rupture probably never occurs. Since the visceral arches and clefts are fully considered in Chapter VII., it will be necessary in this connection to refer only to such derivatives of them as pertain directly to the pharynx.

The **first inner cleft** or **pharyngeal pouch** becomes closed off from the pharyngeal cavity, its dorsal end giving rise to the **tympanic cavity** or **middle ear**, while the remaining part constitutes the **Eustachian tube**. Hence, the tympanum and the Eustachian tube are to be regarded as differentiated portions of the primitive pharyngeal cavity. The dorsal part of the closing membrane of this cleft persists as the **tympanic membrane**.

The **third pharyngeal pocket** or **third inner visceral cleft**, by an evagination of its entodermal epithelium, gives rise to the epithelial parts of the **thymus body**, the connective-tissue elements of this "gland" being furnished by the mesodermic cells which surround the epithelial diverticulum and ultimately enclose and isolate its branching processes. In a similar manner, the **fourth pocket** produces the **lateral lobes** of the **thyroid body**.

The ventral wall of the pharynx, between the anterior extremities of the second throat-pockets, evaginates into an entodermic tube which extends caudalward to develop subsequently into the **median lobe** of the **thyroid body**.

The **tongue** (p. 131) also is developed from the walls of the pharynx, the **anterior unpaired segment**, the **tuberculum impar**, growing from the median line of the ventral wall, just below the level of the first visceral arch, while the **two symmetrical segments** that form the **posterior third** of the organ proceed from the ventrolateral walls at the ventral extremities of the second and third visceral arches.

The **tonsil** develops as masses of lymphoid tissue about

an evagination of the lateral wall of the pharynx. In the third month the lateral pharyngeal wall pouches out to form

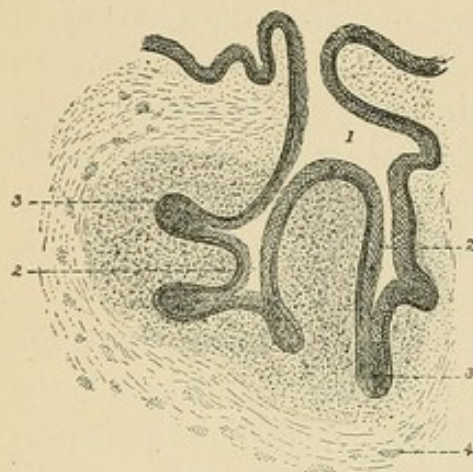


FIG. 83.—Section through anlage of tonsil of a human fetus (Tourneux): 1, tonsillar pit, continuous with mouth-cavity; 2, secondary diverticula; 3, solid epithelial buds; 4, striped muscular fiber.

a little fossa (Fig. 83, 1) which is situated between the second and third visceral arches, the fossa being lined with stratified squamous epithelium continuous with that of the pharyngeal cavity. Little solid epithelial buds (Fig. 83) proceed from this diverticulum into the surrounding connective tissue, the buds subsequently becoming hollowed out. Wandering leukocytes from the neighboring blood-vessels infiltrate the connective tissue

around the young crypts, and these cells becoming aggregated into condensed and isolated groups give rise to the **lymphoid follicles** peculiar to the tonsil. The separate and well-differentiated condition of the follicles is not attained until some months after birth. The place of origin of the tonsil between the second and third visceral arches explains the position of the adult organ between the anterior and posterior palatine arches, since the latter structures represent the deep extremities of the former.

### THE ANUS.

The early stages of the development of the anus are similar to those of the mouth. The so-called **anal membrane** is produced by the growing together of the ectoderm and the entoderm, the mesoderm being crowded aside. The site of the anal membrane, or **anal plate**, is in the median line of the dorsal surface of the embryonic body, at its posterior or caudal extremity. It makes its appearance in the third week. Since the tissue immediately in front—that is, headward, of the anal plate projects and develops into the primi-

tive tail, and since the axis of the body becomes ventrally curved, the anal plate is carried around somewhat toward the ventral aspect of the body. During the following fortnight the anal plate becomes depressed so as to form a small fossa, which is often designated the **anal pit** or **proctodeum**. The position of the anal pit does not correspond, in any vertebrate, to the end of the intestine, but to a point short of it; the gut, therefore, extends beyond the position of the anus. This portion of the bowel is the **postanal gut** of vertebrate morphology. Ultimately it entirely disappears.

While the anal pit is forming, the **allantois** is growing forth as a diverticulum from the ventral wall of the gut (Fig. 84). The intra-embryonic part of the allantois is

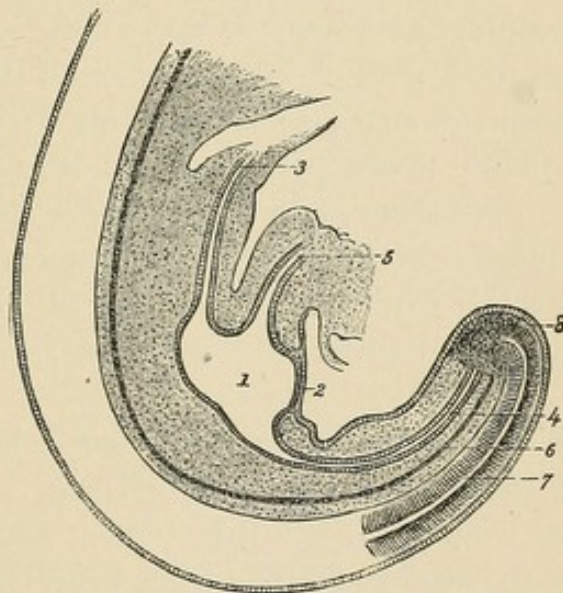


FIG. 84.—Sagittal section of caudal extremity of cat embryo of 6 mm. : 1, cloaca; 2, cloacal membrane; 3, intestine; 4, post-anal gut; 5, allantoic canal; 6, chorda dorsalis; 7, medullary canal (Tourneux).

transformed chiefly into the urinary bladder, but it gives rise also, by its proximal extremity, to a short wide duct, the **urogenital sinus**, which is an avenue of communication with the bowel. The part of the gut on the caudal side of the aperture of the urogenital sinus is the **cloaca**, which is the common termination, therefore, of the genito-urinary system and of the intestinal canal.

The surface depression referred to above as the anal pit is

often called the **cloacal depression** during the time that the cloaca is present. In the lowest mammals, the monotremes, as also in the Amphibia, in reptiles, and in birds, the cloaca is a permanent structure. By the breaking down of the membrane between it and the cloacal depression, it acquires an outlet, through which the feces, the urine, and the genital products find egress. In all higher mammals, however, including man, the cloaca suffers division into an anterior or ventral passage-way, the **urogenital sinus**, and a posterior canal, the **rectum and canal of the anus**. This division is effected by the growth of three ridges or folds, of which one grows from the point of union of the urogenital sinus and the gut, while the other two proceed, one from each lateral wall of the cloaca. The three folds coalesce to form a perfect septum. The division is complete at about the end of the second month (or, according to Minot, at the fourteenth week). The cloacal depression or anal pit shares in this division, so that at about the tenth week, it is separated into the **anal pit proper**, or the **proctodeum**, and the **orifice of the urogenital sinus**. The newly-formed septum continues to thicken, especially near the surface of the body, until it constitutes the pyramidal mass of tissue known as the **perineal body**, or **perineum**.

The anal pit deepens, the anal membrane being thereby approximated to the end of the bowel, and in the fourth month the anal membrane breaks down and disappears. Persistence of the anal membrane after birth constitutes the anomaly known as **imperforate anus**.

#### THE DIFFERENTIATION OF THE ALIMENTARY CANAL INTO SEPARATE REGIONS.

The fourth week marks the beginning of certain important changes in the simple straight alimentary tube. The reader is again reminded that this tube is connected with the dorsal body-wall by the dorsal mesentery and with the ventral wall, for a part of its extent, by the ventral mesentery; that the canal is, as yet, without communication with the exterior; and also that the vitelline duct and the allan-

tois are connected with its ventral surface (Fig. 82). The umbilical vesicle having reached the limit of its development in the fourth week and having begun to shrink, the vitelline duct likewise begins to retrograde and very soon becomes an inconspicuous structure.

The dorsal wall of the tube at a point nearer the head-end begins to bulge toward the dorsal body-wall, forming a somewhat spindle-shaped enlargement (Figs. 85, 86). This di-

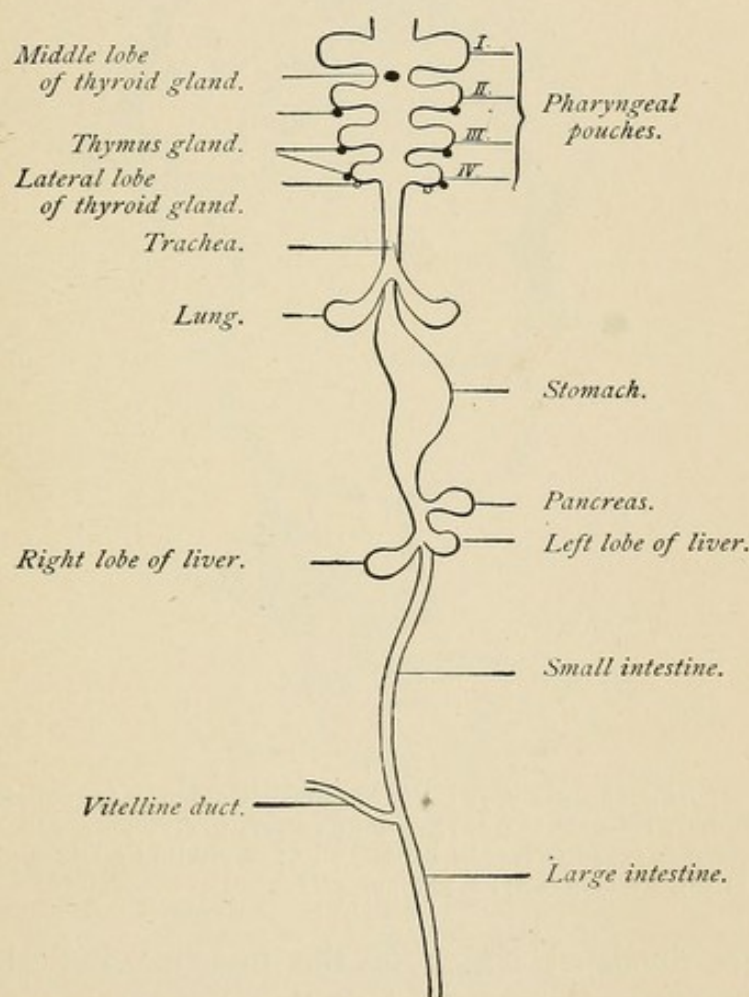


FIG. 85.—Scheme of the alimentary canal and its accessory organs (Bonnet).

latation is the beginning of the future **stomach**. The part of the canal on the cephalic side of the stomach lags behind somewhat in growth, corresponding in this respect with the relatively smaller size of the adult **esophagus**. The esophagus begins to lengthen in the fourth week. At this time, also, the beginning of the **liver** is indicated by a small diver-

ticulum which pouches out from the ventral wall of the intestine just posterior to (below) the stomach—the future duodenal region therefore—and which grows into the ventral mesentery. Very soon after the appearance of the hepatic evagination, a similar out-pouching from the dorsal wall of

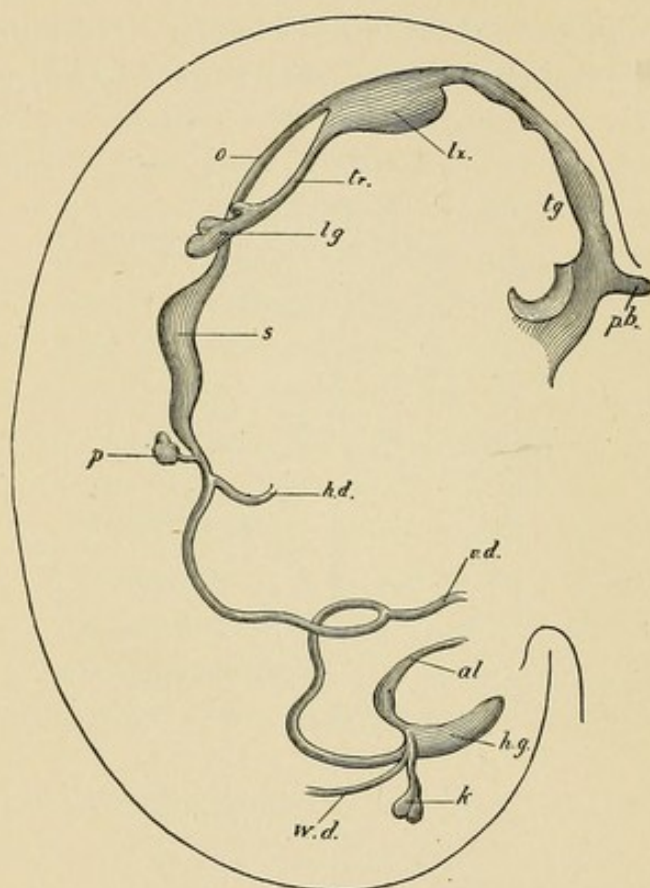


FIG. 86.—Outline of alimentary canal of human embryo of twenty-eight days (His): *pb*, pituitary fossa; *tg*, tongue; *lx*, primitive larynx; *o*, esophagus; *tr*, trachea; *lg*, lung; *s*, stomach; *p*, pancreas; *hd*, hepatic duct; *vd*, vitelline duct; *al*, allantois; *hg*, hind-gut; *wd*, Wolffian duct; *k*, kidney.

the future duodenal region of the intestine indicates the beginning of the development of the **pancreas**.

In the latter part of the third week or in the beginning of the fourth, the esophagus presents a longitudinal groove on the inner face of its ventral wall. This groove increases in depth and caliber and finally becomes constricted off from the esophagus, with which it retains connection only at its pharyngeal end. The tube or tubular sac thus formed is the first step in the development of the **lungs** and the **trachea**.

It may be said then that the gut-tract has now, in the fourth week, reached the stage of differentiation into the **pharynx**, the **esophagus**, the **stomach**, and the **intestine**, with the **liver**, the **pancreas**, the **respiratory system**, and the **allantois** fairly begun.

As heretofore pointed out (p. 81), the **allantois**—which grows directly from the primitive gut-tract, and which con-

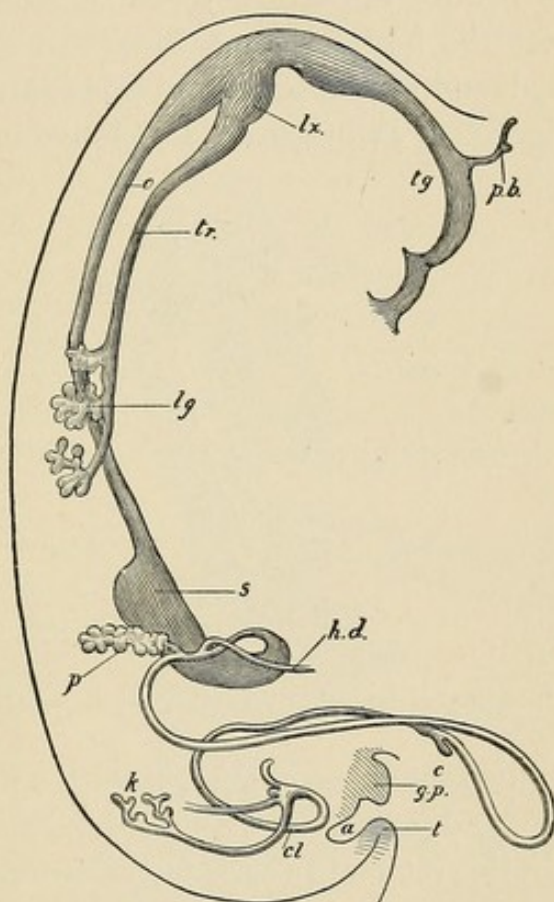


FIG. 87.—Outline of alimentary canal of human embryo of thirty-five days (His): *pb*, pituitary fossa; *tg*, tongue; *lx*, primitive larynx; *o*, esophagus; *tr*, trachea; *lg*, lung; *s*, stomach; *p*, pancreas; *hd*, hepatic duct; *c*, caecum; *cl*, cloaca; *k*, kidney; *a*, anus; *gp*, genital eminence; *t*, caudal process.

sists therefore of the entoderm and the visceral mesoderm—although destined to produce in part the permanent bladder, functionates for a time, after its union with the false amnion to form the chorion, as an organ of respiration; while the permanent respiratory system, as we have seen, likewise develops from the entodermal epithelium of the gut-tract. The entoderm, therefore, sustains an important re-

lation to the nutrition of both the embryonic and the adult organism.

**Increase in Length and Further Subdivision.**—The intestinal canal grows in length much more rapidly than does the embryonic body. It is in consequence of this disproportionate growth that the tube becomes bent and thrown into coils or convolutions. During the fifth and sixth weeks a conspicuous flexure appears at some distance below the stomach. Here the bowel assumes the form of a U-shaped tube, the closed end of the U projecting toward the ventral body-wall (Fig. 88). In other words, the redundant portion

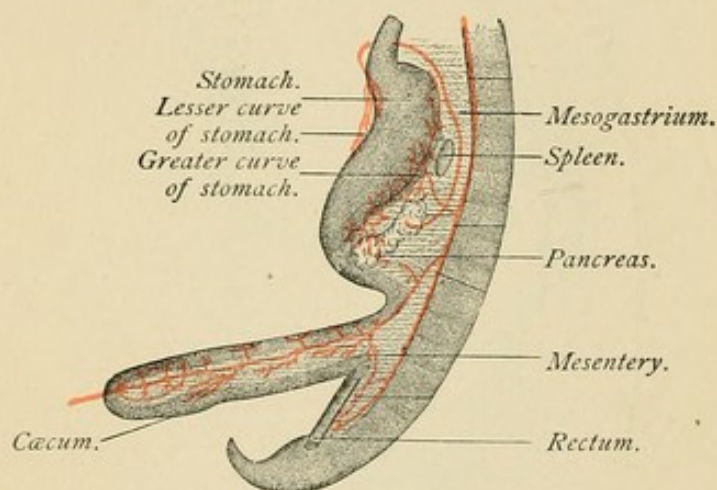


FIG. 88.—Intestinal canal of human embryo of six weeks (Toldt).

of the gut is pulled away, as it were, from the dorsal wall of the body-cavity and, as a consequence, the dorsal mesentery is lengthened in this region to a corresponding extent (Fig. 88). The vitelline duct is attached to the part of the bend nearest the ventral wall (Fig. 86). At a point on the lower limb of the U the bowel abruptly acquires increased caliber. This dilated part is the beginning of the **cæcum** or head of the colon, and its appearance initiates the distinction between the large and the small intestine, since the part of the bowel on the distal side of the point in question becomes also of larger caliber and forms the **colon**.

During the succeeding week or fortnight, the character of the colon and of the cæcum becomes better established. The remaining part of the lower limb of the U-loop, with all of

the tube included between the loop and the stomach, is the **small intestine**, which presents a slight dorsal flexure at its proximal extremity. The stomach meanwhile has increased in size and has almost attained its characteristic shape. By the end of the sixth week, then, the alimentary canal has not only increased in length but has so far differentiated as to have acquired **stomach, duodenum, small intestine, cæcum, and rectum**.

**Alteration in the Relative Position of Parts, and Further Development.**—The most important modification of the alimentary tube as it exists at the end of the sixth week is effected by certain changes of position of some of its parts. The stomach and the large intestine are the portions of the tract most conspicuously affected. The lower limb of the U-segment of bowel, which consists chiefly of the rudimentary cæcum and a part of the colon, is lifted, as it were, over the upper limb and comes to occupy a position above it (Fig. 89, *A*), the cæcum assuming a position in the right

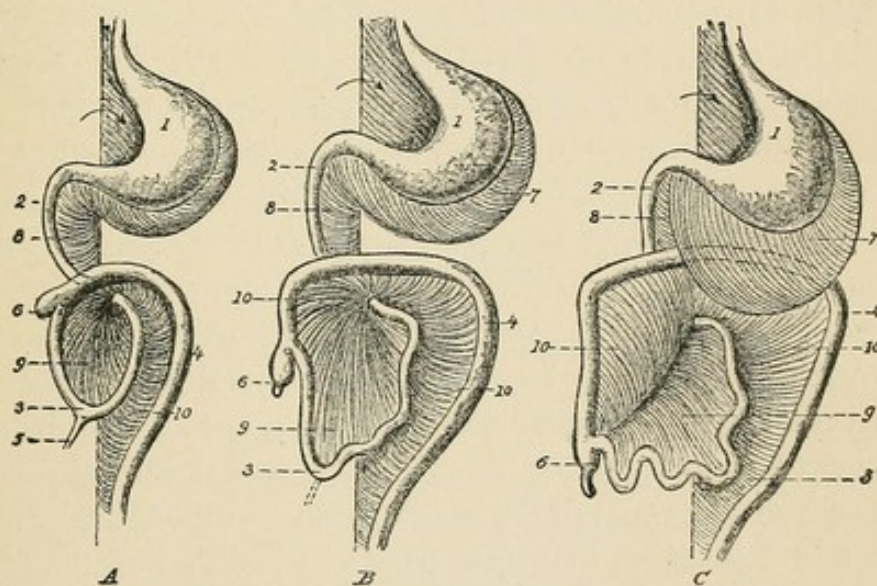


FIG. 89.—Three successive stages showing the development of the digestive tube and the mesenteries in the human fetus (modified from Tournoux): 1, stomach; 2, duodenum; 3, small intestine; 4, colon; 5, vitelline duct; 6, cæcum; 7, great omentum; 8, mesoduodenum; 9, mesentery; 10, mesocolon. The arrow points to the orifice of the omental bursa. The ventral mesentery is not shown.

hypochondriac region, and the colon passing thence transversely across the abdomen ventrad to the duodenum.

This shifting of position on the part of the colon brings

about important complications in the arrangement of the mesentery, since the part of the dorsal mesentery that pertains to the upper part of the colon correspondingly alters its position and line of attachment, becoming adherent to the peritoneum on the ventral surface of the duodenum. The part of the mesentery in question becomes the transverse mesocolon (Fig. 89, *B*). The large intestine, after this change of position, presents **cæcum**, **transverse colon**, **descending colon**, and **rectum**, the ascending colon being still absent.

The **vermiform appendix** in the third month has already acquired the form of a slender curved tube projecting from the cæcum. At the time of its first appearance and for some weeks afterward, the appendix has the same caliber as the cæcum. Subsequently the cæcum outstrips the appendix in growth, the latter appearing in the adult state as a relatively very small tube attached to the much larger cæcum.

The cæcum soon begins again to change its position, gradually moving downward toward the right iliac fossa (Fig. 89). The downward migration of the cæcum is due to the growth of the colon in the same direction. In this manner the **ascending colon** is gradually produced, it having developed to such an extent in the seventh month that the cæcum lies below the right kidney, while in the eighth month it passes the crest of the ilium. Corresponding with the growth of the ascending colon, the mesentery shifts its parietal attachment and increases in extent until the **ascending mesocolon** is produced; and with the descent of the cæcum, the terminal part of the small intestine necessarily alters its position to a like degree.

The **stomach**, up to the third month, is a localized dilatation of the intestinal tube, bulging most in the dorsal direction and having its long axis parallel with that of the body (Fig. 88). In the third month, however, it undergoes an important alteration in position, rotating about two axes. First, it turns about a longitudinal axis, whereby the left side comes to face toward the ventral surface of the body (anteriorly) and the right surface looks toward the spinal column. In addition to the longitudinal rotation, the stomach also rotates upon a dorsoventral (anteroposterior) axis,

by which the lower or pyloric extremity moves somewhat upward and to the right, and the cardiac end goes tailward (downward) and to the left (Fig. 89). By this double rotation the stomach is made to assume approximately its adult position. The longitudinal rotation of the stomach, in which the lower portion of the esophagus takes part, explains the **relation of the vagus nerves** in the adult. The nerves, before the rotation, lie one on each side of the esophagus and stomach, but since the left surfaces of both turn forward and the right surfaces turn backward, the left vagus lies on the anterior surface of the esophagus and of the stomach, while the right nerve is in relation with their posterior surfaces.

The **relations of the mesogastrium** are influenced in an important manner by the rotation of the stomach. As long as the stomach retains its original position and relations, with its greater curvature facing dorsad (or posteriorly), the mesogastrium is a vertical mesial fold of peritoneum (Fig. 88), while the ventral mesentery similarly connects the future lesser curvature or ventral surface of the stomach with the ventral body-wall. At the very beginning of the process of rotation, the mesogaster becomes somewhat redundant and sags toward the left (Fig. 89, A). As this increases in extent, there is formed, between the stomach and the dorsal body-wall, a pouch or pocket, the **omental bursa**, whose opening is toward the right (Fig. 89). In the third and fourth months the original mesogaster, lengthening more and more, and being affected by the increasing torsion of the stomach, projects in the form of a sac considerably below the level of the stomach, in front of (ventral to) the small intestine and the transverse colon. It ultimately becomes the **great omentum**. The mesogastrium, from having been a vertical mesial fold, is now become a transverse fold, so redundant as to be folded upon itself and to constitute a bag.

In like manner the **ventral mesentery** (Figs. 82 and 90), which connects the anterior or ventral surface of the stomach with the ventral body-wall, and in which the liver develops, is altered from a mesial fold to a transverse fold by the rotation of the stomach. As the liver migrates to a position

above the stomach, the part of the ventral mesentery which connects the liver with the body-wall becomes its falciform ligament and coronary ligament, while that portion of this mesentery that connects the originally ventral surface of the stomach, now its lesser curvature, with the liver is the **lesser or gastrohepatic omentum**. The lesser omentum, therefore, is the anterior or ventral boundary of the orifice of the omental bursa referred to above.

The **small intestine** begins to exhibit flexures as early as the fifth week, and by the end of the sixth week the duodenum is well indicated as a segment of the gut-tube passing from the pyloric end of the stomach toward the dorsal body-wall. From this time the development of the small intestine, aside from its histological characters, consists chiefly in increase in length with consequent modification of its mesentery. A striking feature of human development is that, with the growth in length of the small bowel, it is gradually extruded from the abdominal cavity into the tissues of the umbilical cord. The extent to which extrusion takes place increases until the tenth week, after which period the intestine is gradually withdrawn into the abdomen. In the fourth month it lies entirely within the abdominal cavity. Failure of complete restoration of the gut to the cavity of the abdomen constitutes **congenital umbilical hernia**.

The **histological alterations** incident to the development of the alimentary tube, from the beginning of the esophagus to the end of the rectum, consist in the differentiation of the constituent elements of its walls from the two strata, the entoderm and the visceral mesoderm, which compose the walls of the early gut-tube. As an initial step in the process, the **cells of the mesodermic stratum** undergo multiplication and arrange themselves in a narrow loose **inner zone** and a thicker **outer lamella**. The inner layer subsequently becomes the **submucosa** of the fully formed state, while the cells of the outer layer undergo differentiation into unstriped muscular tissue, and constitute the **muscular coat** of the canal. In the case of the esophagus and stomach, at least, this muscular tunic, in the fourth month, exhibits the

distinction between inner circular, and outer longitudinal, layers. The **surface-cells** of the mesodermic stratum of the primitive stomach and bowel become the **endothelium** of the serous coat.

The **glands** of the entire canal are products of the inner, entodermic stratum, and therefore they are intimately related genetically, as well as histologically, with the mucous membrane.

The **glands of the stomach**, both the **peptic** and the **pyloric**, originate from small cylindrical cell-masses that have been produced by local multiplication and aggregation of entodermal cells. By the hollowing out of the cylinders and the branching of the tubes thereby formed, the two varieties of gastric glands are evolved. Both sets make their appearance in the tenth week. Until the fourth month the peptic glands contain cells of but one type; at this period, however, certain cells of these glands become altered by the gradual accumulation of granules within their protoplasm, by which they are transformed into the characteristic **acid** or **parietal** cells of these glands.

The **glands and villi of the intestine** are likewise products of the entodermal lining of the gut. Their evolution begins in the second month, and they are fairly well formed by the tenth week. As in the case of the gastric glands, the glands of the bowel develop from cylindrical masses of entodermal cells which are at first solid, but which later become hollowed out to form tubular depressions or follicles. In the region corresponding to the upper part of the small intestine many of these follicles branch to give rise to the **glands of Brunner**, while unbranched, simple, tubular depressions distributed throughout the entire length of the bowel become the **glands of Lieberkühn**. While the surface entoderm is thus growing into the underlying mesodermic tissue to form the glands, it becomes elevated into minute projections between the mouths of the gland-ducts, forming the **villi** of the intestinal mucosa. The connective-tissue core of the villus is derived from the underlying mesodermic tissue, the cells of which, proliferating, grow forth into the entoderm. The villi at first are

present throughout the large and the small intestine alike, being well developed by the fourth month. While the villi of the small bowel continue their development, those of the large intestine, after the fourth month, begin to retrograde. At the time of birth they are still discernible, but at the end of the first month after birth they are completely obliterated.

**Meckel's Diverticulum.**—The vitelline duct, it will be remembered, is the avenue of communication between the early gut-tube and the umbilical vesicle. In the sixth week the umbilical vesicle has already begun to retrograde, and the vitelline duct is attached to the ventral extremity of the U-loop of the bowel present at this stage. The vitelline duct in most cases suffers complete obliteration in the later stages of fetal life. In some instances, however, its proximal extremity persists in the form of a small blind tube varying in length from one to several inches, which is known as **Meckel's diverticulum**. Since the site of attachment of the vitelline duct is not far from the termination of the small intestine, Meckel's diverticulum, when present, is connected with the lower part of the ileum, at a point from one to three feet from its termination. Should this tube remain attached to the umbilical aperture and retain a patulous orifice, there would result a **congenital fecal fistula**.<sup>1</sup>

#### THE DEVELOPMENT OF THE LIVER.

The essential features of the development of the liver will be more easily apprehended if the reader will not lose sight of the fact that the organ is a compound tubular gland, and if, further, he will recall the method by which glands in general are developed—that is, as evaginations of the wall of the cavity or organ to which they pertain.

The first step in the evolution of the liver is the growth of a **diverticulum** from the ventral wall of the gut-tube at a point corresponding to the region of the future duodenum. This occurs in the third week, since His found the diver-

<sup>1</sup> Meckel's diverticulum is of interest clinically, since by contracting adhesions to adjacent coils of intestine or by entanglement, it may produce acute obstruction of the bowel.

ticulum in a human embryo of 3 mm. The single diverticulum<sup>1</sup> very speedily bifurcates at its distal extremity (Fig. 85). The very short time that elapses between the first appearance of the evagination and its division into two branches explains the statement made in some text-books that two diverticula are present from the first. The hepatic diverticulum is said to grow into the septum transversum (*vide* Development of the Diaphragm, p. 158). The dorsal part of the septum transversum or primitive diaphragm, the region just ventral to the bowel, contains a mass of young connective tissue, rich in cells and blood-vessels, which has been designated the **prehepaticus**, and the **liver-ridge**, by His and Kölliker respectively (Fig. 78). It is into this vascular and cellular mass that the liver diverticulum inserts itself. The septum transversum is united in the median plane of the body with the ventral mesentery, and since the ventral mesentery is connected with the region of the intestine from which the hepatic diverticulum is evaginated, the latter passes between the two layers of the mesentery to reach the liver-ridge (Fig. 90). This fact constitutes the key to the topographical relations of the liver and its peritoneal "ligaments," as will appear hereafter.

The two diverticula resulting from the division of the original single evagination embrace between them the two vitelline veins, and by repeated branching produce the **right** and the **left lobes** of the liver. Before branching, the diverticula become greatly thickened at their distal extremities by

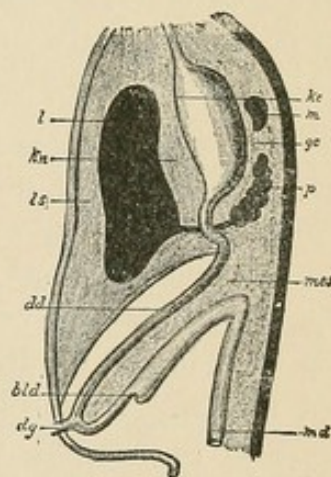


FIG. 90.—Diagram to show the original positions of the liver, stomach, duodenum, pancreas, and spleen, and the ligamentous apparatus pertaining to them. The organs are seen in longitudinal section: *l*, liver; *m*, spleen; *p*, pancreas; *dd*, small intestine; *dg*, vitelline duct; *bld*, cæcum; *md*, rectum; *kc*, lesser curvature; *gc*, greater curvature of the stomach; *mes*, mesentery; *kn*, lesser omentum (lig. hepatogastricum and lig. hepatoduodenale); *ls*, ligamentum suspensorium hepatis (Hertwig).

<sup>1</sup> Single, according to His, Kölliker, Hertwig, Minot, and Piersol.

abundant cell-proliferation. The numerous branches into which they divide are not tubes, but solid cylinders of cells, the **hepatic cylinders**. The secondary branches of these cylinders unite with corresponding branches of adjacent systems, producing thereby a network of inosculating cell-cords, the meshes of which are occupied by young connective-tissue cells and the developing blood-vessels. The connective and vascular tissue of the liver-ridge, thus surrounding and permeating the epithelial cell-cords, produces all the **connective-tissue parts** of the liver, while the liver **parenchyma**—the proper hepatic cells—and the **epithelium of the bile-ducts** originate from the primitive entodermic evagination. The cords of cells are in part hollowed out to form the **bile-ducts** and **bile-capillaries**, and in part become the **cells** of the lobules. The cylinders that are to produce the bile-ducts acquire their lumen by the fourth week.

Until the middle of the fourth month, the right and left lobes of the liver are of equal size, but after this period the right lobe outstrips the left in growth. The liver grows very rapidly and is relatively of much greater size in the fetus than in the adult, almost filling the body-cavity at the third month. In the later months of pregnancy it reaches almost to the umbilicus, while at birth it makes up one-eighteenth of the body-weight.

The **gall-bladder** develops as an evagination from the original diverticulum. It is present in the second month. The pedicle of this evagination lengthens somewhat and becomes the **cystic duct**. The stalk of the hepatic evagination itself becomes the **ductus communis choledochus**.

The **ligaments of the liver**, save the round ligament, are simply folds of the peritoneum which connect the organ with the abdominal wall. Falling into the same category, though not usually designated a ligament, is the **gastrohepatic omentum**, which connects the liver with the stomach. These various peritoneal folds may be looked upon as parts of the ventral mesentery. Since the liver evagination grows between the two layers of the ventral mesentery to reach the

septum transversum, the liver will be found, in the early stages of its development, embedded between the lamellæ of this mesentery, which is a median vertical fold of peritoneum (Fig. 90). The liver is therefore enclosed in the peritoneum and is connected below, by a part of the ventral mesentery, with the lesser curvature of the stomach, which still lies in the median plane of the body, and above and in front, with the diaphragm and the ventral body-wall by the upper and anterior part of the same structure. The latter fold is somewhat modified by the intimate association of the early stage of the liver with the primitive diaphragm, the liver having developed within a portion of the septum transversum, the **liver ridge**. As development advances, a partial separation of the liver and the diaphragm is effected, the peritoneum, as it were, growing between the two from both the ventral and the dorsal edges of the liver. The region which is not invaded by the peritoneum represents the non-peritoneal surface of the adult liver between the lines of reflection of the two layers of the coronary ligament. Since the peritoneum on the under surface of the diaphragm is reflected from that muscle, both in front of and behind this area of contact, to become continuous with the peritoneum on the convex surface of the liver, there are formed two transverse, parallel, but separated, folds which constitute the **coronary ligament** of adult anatomy. The lateral prolongations of these folds to the lateral wall of the abdomen constitute the **lateral ligaments** of the liver.

The rotation of the stomach to assume its permanent relations alters the position of the fold that connects its lesser curvature with the liver, bringing this fold into a plane parallel, approximately, with the ventral wall of the abdomen. This fold is now the **lesser or gastrohepatic omentum**.

The **round ligament** of the adult represents the impervious vestige of the umbilical vein. This vessel, entering the fetal body at the umbilicus and passing to the under surface of the liver, diverges from the abdominal wall to reach that organ and, in doing so, carries with it the parietal peritoneum. The fold thus formed is the **falciform or suspensory ligament**.

The special system of blood-vessels belonging to the liver is described in the chapter on the Vascular System, p. 161.

#### THE DEVELOPMENT OF THE PANCREAS.

Just as the liver is produced by an evagination from the ventral wall of the future duodenum, so is the pancreas originated by an evagination from the dorsal wall of the same region of the gut-tube (Fig. 86). The diverticulum grows between the two layers of the dorsal mesentery (Figs. 86, 88, and 90), where it encounters embryonic connective tissue, the cells and the blood-vessels of which, becoming associated with the epithelial entodermic evagination, give rise to all the **vascular and connective-tissue parts** of the gland. The details of development correspond closely with those of the salivary glands, with which the pancreas is practically identical in structure. The **stalk** of the diverticulum becomes the **duct** of the mature gland. Although the orifice of the duct, in early stages, is on the opposite side of the bowel from that of the common bile-duct, the two apertures are made to approach each other and are finally, in most cases, merged into one by the unequal growth of the lateral walls of the intestine. In the adult, therefore, the duct of the pancreas and that of the liver and gall-bladder open into the duodenum by a common orifice.

Since the pancreas develops between the folds of the dorsal mesentery, it has a complete investment of peritoneum in the early stages of fetal life. The alterations by which this condition is changed, making the pancreas a retroperitoneal organ, will be noted in the account of the peritoneum.

#### THE DEVELOPMENT OF THE SPLEEN.

Although the spleen does not belong to the digestive system, it may conveniently be considered here because of its position and relations.

This organ is differentiated from the **mesodermic tissue** found between the layers of the mesogastrium in close proximity to the developing pancreas (Fig. 90). Primarily, therefore, it is situated behind the stomach. The

first step in its development, recognizable at about the end of the second month, is the **accumulation of numerous lymphoid cells** with large granular nuclei. The mass is augmented by the addition of cells immediately beneath the peritoneal surfaces of the mesogastrium, which cells elongate until they are spindle-shaped and then become aggregated into **fusiform masses**. Blood-vessels penetrate the fundament in the third month and become surrounded by cells of the same spindle-shaped type. From both the cells surrounding the blood-vessels and from those of the fusiform aggregations, processes grow out and unite with each other, and from the **network** thus formed the **trabecular framework** of the organ is ultimately evolved. Accumulations of small nucleated cells, forming dense masses along the arteries, furnish the chief constituent of the **pulp**. The delicate intercellular substance which makes up the remainder of the pulp is filled with blood-corpuscles. The **Malpighian corpuscles** appear before the end of the fourth month. By the sixth month, the spleen attains its characteristic shape and the **fibrous capsule** is clearly indicated.

The spleen undergoes a **change of location** coincident with the rotation of the stomach and the alteration of the mesogastrium. The organ being from the first embedded within the mesogastrium, it follows that peritoneal fold to the left side of the abdominal cavity. Here it lies close to the cardiac end of the stomach, between the two layers of the mesogastrium, but projecting toward the left. The part of the mesogastrium which intervenes between the spleen and the stomach is the **gastrosplenic omentum**; while the part that passes from the spleen to the posterior wall of the abdomen, representing the parietal attachment of the mesogastrium, constitutes the **phrenicosplenic omentum**.

#### THE EVOLUTION OF THE PERITONEUM.

The arrangement of the peritoneum being subordinate to the position and relations of the viscera contained within the abdomen, the development of this complex membrane can be properly described only by tracing the growth of the digestive

system. As the formation of the early gut-tube by the infolding of the splanchnopleure has been pointed out (pp. 169 and 171), we may begin at once with the period when the tract has the form of a straight tube connected with the

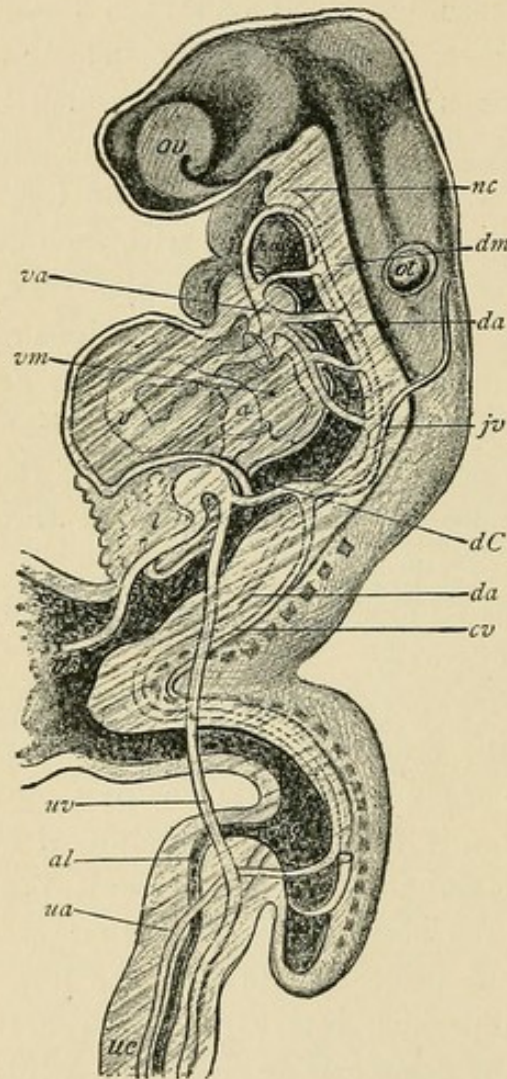


FIG. 91.—Reconstruction of human embryo of about seventeen days (after His): *ov*, optic and *ot*, otic vesicles; *nc*, notochord; *hdg*, head-gut; *g*, mid-gut; *hg*, hind-gut; *vs*, vitelline sac; *l*, liver; *v*, primitive ventricle; *va*, *da*, ventral and dorsal aortæ; *jv*, primitive jugular vein; *cv*, cardinal vein; *dc*, duct of Cuvier; *uv*, *ua*, umbilical vein and artery; *al*, allantois; *us*, umbilical cord; *dm*, dorsal mesentery; *vm*, ventral mesentery (modified from His).

dorsal and the ventral body-wall respectively by the **dorsal** and the **ventral mesentery** (Fig. 91). Covering the tube as a constituent part of its wall, is the splanchnic or visceral layer of the mesoderm, while the somatopleuric or parietal layer of the latter lines the wall of the body. Obviously these

two lamellæ of the mesoderm are continuous with each other through the medium of the mesenteries mentioned above (Fig. 92, *A* and *B*). The space thus enclosed by the mesodermic strata is the **body-cavity** or *cœlom* or pleuroperitoneal cavity. The surface-cells of both strata flatten and assume the character of mesothelial, the later endothelial, cells. If,

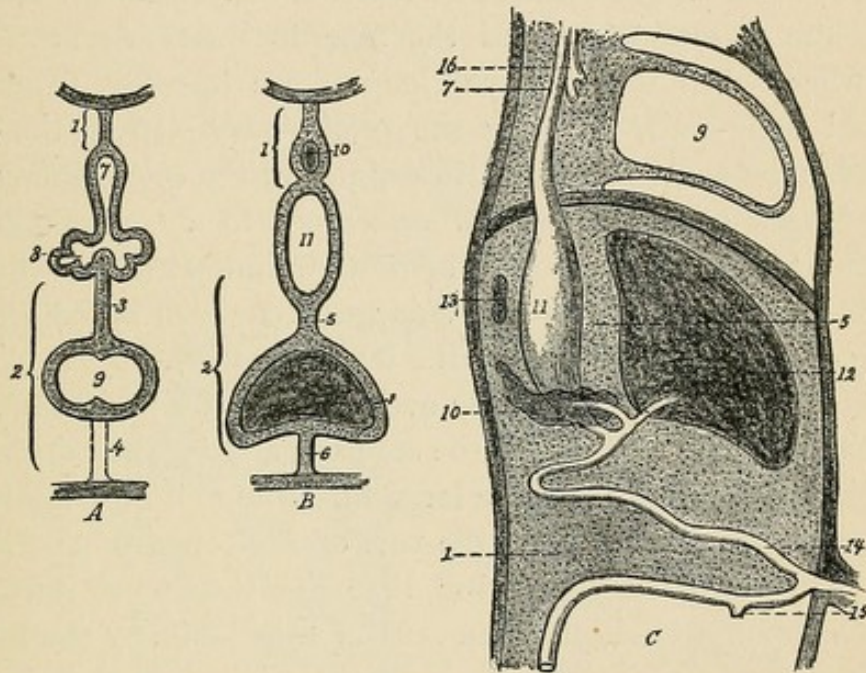


FIG. 92.—*A*, *B*, two transverse sections, *A* through thoracic, *B* through abdominal region; *C*, sagittal section (Tourneux): 1, dorsal mesentery; 2, ventral mesentery; 3, mesocardium posterius; 4, mesocardium antierius; 5, lesser omentum; 6, suspensory ligament of liver; 7, esophagus; 8, lungs; 9, heart; 10, pancreas; 11, stomach; 12, liver; 13, spleen; 14, loop of intestine with vitelline duct; 15, cæcum; 16, trachea.

at this stage, one begins at any point to trace the mesothelial lining of the body-cavity, that lining is found to form practically one continuous sheet.

This simple arrangement of the primitive peritoneum is transformed into the complicated membrane of the adult, primarily, by the increase in length and consequent tortuosity of the alimentary tube; and, secondarily, by the fact that certain opposed portions of the serous membrane, which have been brought into contact by the altered relations of the bowel and the stomach, undergo concrescence or fusion with each other. Simultaneously with these alterations, the original **pleuroperitoneal cavity** suffers division into the ab-

dominal or peritoneal cavity and the thoracic part of the body-cavity by the development of the diaphragm. This is described on p. 158.

The first modification of the original arrangement is effected by the development of the stomach as a spindle-shaped dilatation of the gut-tube, differentiating the tube into the stomach and the intestine, and the common dorsal mesentery into the mesogastrium and the intestinal mesentery. The drawing out of the U-shaped loop of the intestine from the dorsal body-wall, which is the preliminary step to the distinction between the small intestine and the colon, increases the length of the intestinal mesentery to a corresponding extent (Fig. 92, *C*). As heretofore indicated, the lower limb of the loop presents an enlargement which is the beginning of the development of the large intestine.

An important stage in the evolution of the peritoneum is marked by the rotation of the stomach and by the migration of the proximal part of the large intestine to a new location. The change of position on the part of the colon may perhaps be best expressed by saying that the U-loop of intestine rotates upon an oblique dorsoventral axis, whereby the lower limb of the loop, in other words, the termination of the small bowel and the beginning of the colon, is carried to a position above, cephalad to, the upper limb (Fig. 89, *A*). This rotation brings the beginning of the colon into the right hypochondriac region of the abdomen, from which point the transverse colon passes across the abdominal cavity, ventrad to the proximal end of the small intestine or duodenum. As a consequence of the altered situation of the transverse part of the colon, its mesentery shifts its area of attachment by fusing with the peritoneum of the dorsal wall along a horizontal line and also with that of the ventral surface of the duodenum. The descending colon having meanwhile moved to the left, its mesentery likewise acquires a new area of attachment by concrescence with the parietal peritoneum of the dorsal wall of the abdomen on the left side. During the progress of these alterations, the small intestine increases in length, and its mesentery becomes correspondingly more

voluminous both in the extent of its intestinal border and in length. The convolutions of the small intestine now occupy the space below the transverse colon and its mesentery.

The **duodenum**, which in the early stage shares with the gastro-intestinal tube in the possession of the common dorsal mesentery, loses its mesenterial connection with the abdominal wall and becomes thereby a fixed part of the intestine. Mention was made above of the fusion of the transverse mesocolon with the peritoneum of the ventral surface of the duodenum. At about the same time, the duodenal mesentery (Fig. 89, *A*) fuses with the parietal peritoneum of the posterior abdominal wall, the result being that the lower layer of

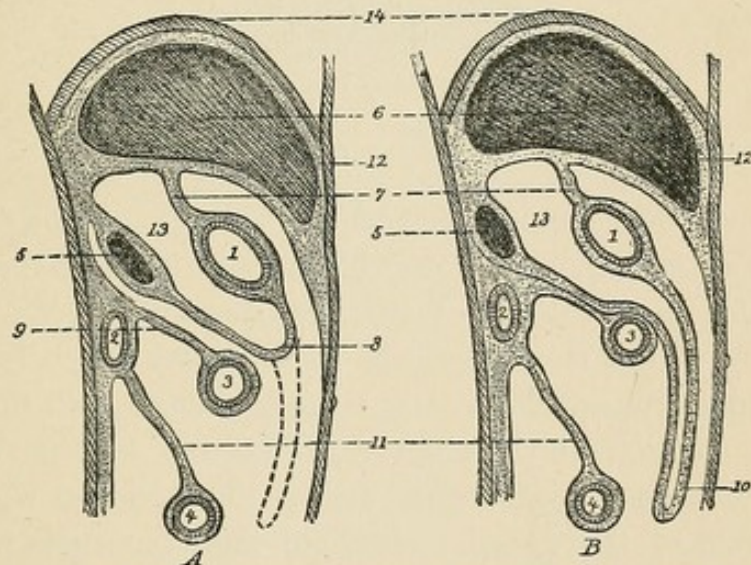


FIG. 93.—*A, B.* Two successive stages of the development of the mesenteries (schematic representation showing sagittal axial section of trunk, after Gegenbaur and Hertwig): 1, stomach; 2, duodenum; 3, transverse colon; 4, small intestine; 5, pancreas; 6, liver; 7, lesser omentum; 8, 10, different stages of great omentum; 9, transverse mesocolon; 11, mesentery; 12, suspensory ligament of liver; 13, cavity of omental bursa or lesser peritoneal sac; 14, diaphragm.

the transverse mesocolon, as it passes downward, is now continuous with the parietal peritoneum, there being no longer any serous membrane between the transverse part of the duodenum and the abdominal wall (Fig. 93, *B*). This part of the duodenum therefore becomes retroperitoneal, there being an investment of serous membrane only on its anterior or ventral surface.

The second modifying factor in the complication of the peritoneum, the rotation of the stomach, initiates alterations in its mesogastrium. The latter membrane, it will be remembered, is a vertical median fold of peritoneum continuous with the mesentery of the duodenum (Fig. 92, *C*). As the stomach moves about its two axes of rotation, the mesogastrium begins to sag toward the left (Fig. 89), so that now it constitutes a pouch or fossa, the **omental bursa**, situ-

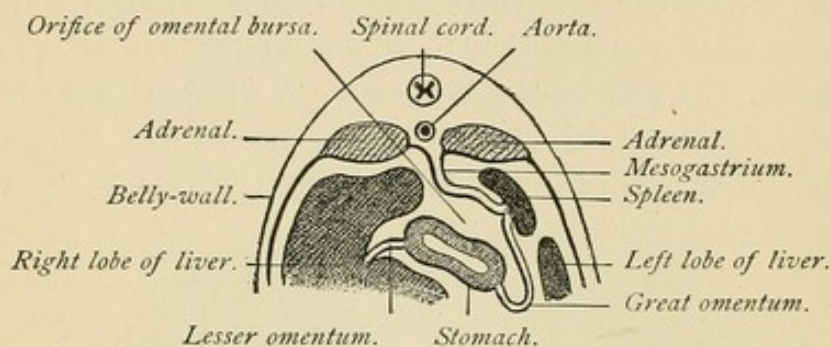


FIG. 94.—Schematic cross-section through body of mammalian embryo in region of stomach, to show development of omental bursa (after Toldt).

ated between the stomach and the dorsal body-wall, the opening of which looks toward the right side of the body (Figs. 93, *A* and 94). With the rapidly increasing redundancy of the mesogastrium, the omental bursa becomes more and more capacious. In correspondence with the progressive rotation of the stomach, what was at first the left surface of the mesogastrium comes into contact with the peritoneum of the dorsal abdominal wall and fuses with it, thus changing its area of parietal attachment from a median vertical line to a transverse one. This change is completed by the time the stomach has attained its normal adult position. The omental bursa now has the position and relations shown in Fig. 93, *A*, 8. A still further increase in the size of the bursa results in its protrusion downward in front of, ventrad to, the transverse colon and the small intestine. Reference to Fig. 93, *B* will show that the dependent part of the bursa very nearly corresponds with the fully formed great omentum. It will be seen, however, that the deeper layer of the bursa, the layer nearer the intestines, may be traced above the transverse colon and its mesentery to the

dorsal wall of the abdomen, where its two lamellæ separate to enclose the pancreas, one lamina passing over the ventral surface of the pancreas to become continuous with the parietal peritoneum, while the other layer passes between the pancreas and the abdominal wall. The latter layer is in continuity here with the parietal peritoneum, which almost immediately leaves the abdominal wall to form the upper layer of the transverse mesocolon.

The further alterations necessary for the attainment of the completed condition consist in the **concrecence of certain opposed peritoneal surfaces**. As a conspicuous example of such concrecence, the deeper lamella of the layer of the omental bursa just described fuses with the ventral peritoneal surface of the transverse colon and with the upper layer of the transverse mesocolon (Fig. 93, *A*), after which event this deeper lamella is practically continuous with the lower layer of the mesocolon, while the superficial lamella is in continuity with the upper layer of the mesocolon (Fig. 93, *B*). Thus the transverse colon appears as if enclosed between the two lamellæ of the deeper layer of the great omentum, while its mesocolon is constituted by a part of the same structure. In other words, the adult transverse mesocolon includes not only the primitive membrane of that name but also a part of the early mesogastrium. Similarly, the opposed surfaces of peritoneum between the pancreas and the dorsal abdominal wall undergo fusion (Fig. 93), the effect of which, after the concrecence of the mesocolon with the deeper layer of the omental bursa, is to make the lower layer of the mesocolon continuous, over the transverse part of the duodenum, with the parietal peritoneum.

The **great omentum** of descriptive anatomy, resulting from the downwardly projecting process of the omental bursa, consists originally of two layers of membrane, each one having two serous surfaces. At the time of birth these two layers are still separate—the permanent condition in some mammals—but during the first year or two after birth they become adherent, the great omentum thus coming to comprise but a single layer.

It remains to note the **metamorphosis of the ventral mesentery**, which, prior to the rotation of the stomach, is a vertical median fold connecting the lesser curvature of that viscus with the ventral abdominal wall. Since the evagination of the gut-tube that gives rise to the liver grows between the layers of the ventral mesentery to reach the septum transversum, the liver is not only enclosed by the mesentery, but is connected by it with the stomach and with the ventral wall of the abdomen and also with the primitive diaphragm (Fig. 92). By the rotation of the stomach, the vertical median fold which connects that organ with the liver becomes so altered in position as to lie in a plane approximately parallel with the ventral surface of the body. This fold is now the **gastrohepatic** or **lesser omentum**. As reference to Fig. 93 will show, it is the anterior boundary, above the position of the stomach, of the sac described above as the omental bursa.

That part of the ventral mesentery that connects the liver with the abdominal wall and with the diaphragm, while originally occupying the median plane, is modified by the relation of the developing liver to the primitive diaphragm. These organs are intimately united with each other (p. 159) in the early stage of their growth, but with their completion a separation takes place. Upon the two separated surfaces, except in a region near the dorsal wall, the cells assume the endothelial type, the opposed surfaces thus acquiring the characters of serous membrane. The peritoneum on the under surface of the diaphragm is continuous with that on the upper surface of the liver, both in front of and behind the non-peritoneal area of contact. Therefore, in the completed condition of the liver and the diaphragm, these two structures are connected by two layers of peritoneum separated from each other by a region containing only areolar tissue. These layers constitute the **coronary ligament** of the liver. If now Fig. 93 is inspected, it will be seen that the posterior layer of the lesser omentum, and the upper layer of the transverse mesocolon, together with that part of the peritoneum with which they are in direct continuity, enclose

a sac which is the so-called lesser bag of the peritoneum or the lesser peritoneal cavity. All other parts of the peritoneum taken together constitute the greater peritoneal cavity. The communication between the two, the foramen of Winslow, situated behind the free right border of the lesser omentum, is the constricted orifice of the early omental bursa.

The position of the kidneys and the ureters as retroperitoneal structures and the relations of the bladder and of the uterus to the peritoneum, encroaching as they do upon the parietal layer of this membrane, and being, therefore, invested by it to a greater or less extent, are easily accounted for when it is recalled that all these organs develop from the somatic or outer layer of the mesoderm.

The peritoneum does not acquire all the characteristic features of a serous membrane until about the third month. The histological alterations begin in the fourth week, from which time until the sixth week the superficial cells, the mesothelium, pass through various phases of transition to reach the condition of somewhat flattened elements. By the eighth week they have acquired the form of true endothelium. It is not, however, until the third month that the subjacent tissue has attained to the condition of a fully-formed basement membrane.

## CHAPTER XII.

### THE DEVELOPMENT OF THE RESPIRATORY SYSTEM.

ALTHOUGH the nasal chambers and the pharyngeal cavity contribute to the formation of the respiratory system, these

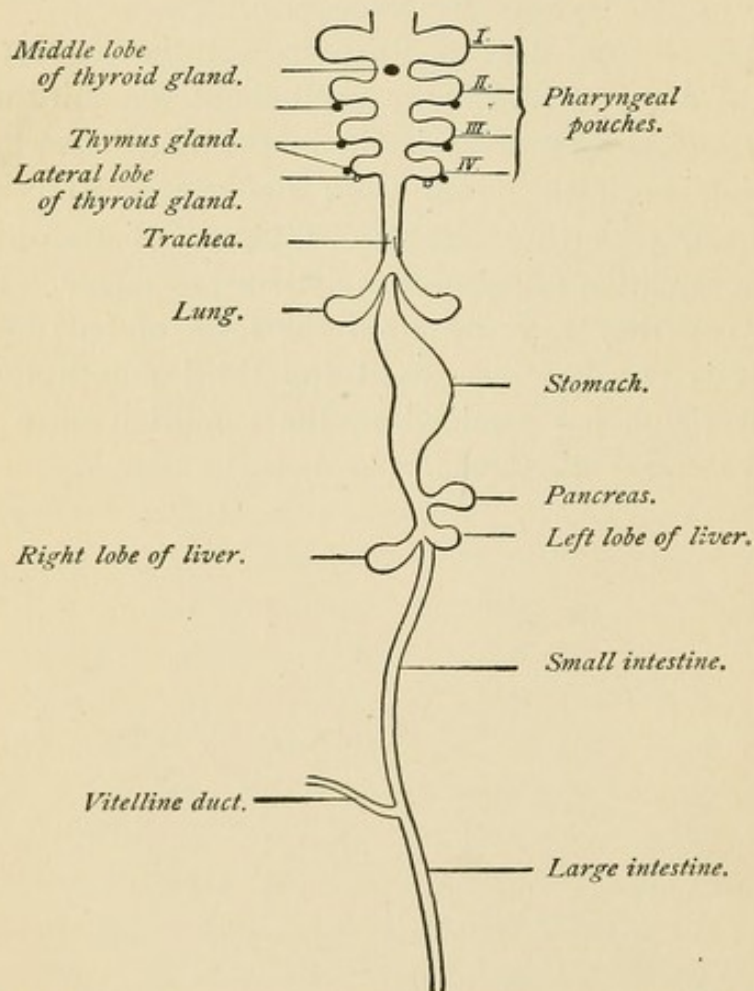


FIG. 95.—Scheme of the alimentary canal and its accessory organs (Bonnet).

parts will not be considered here, since they are described elsewhere.

Anatomically and according to their mode of development, the **lungs** might be looked upon as a **pair of glands** having a **common duct**, the **trachea**, which latter, through the medium of its dilated proximal extremity, the **larynx**, opens into the pharyngeal cavity. In point of fact, these organs are developed as an **outgrowth** from the **entodermal alimentary canal** in a manner similar to the development of the liver and the pancreas.

The first step in the development of the lungs is the outpouching of the ventral wall of the esophagus throughout its entire length. The longitudinal median groove thus formed is the **pulmonary groove**. It makes its appearance when the embryo has a length of 3.2 mm. (0.128 inch) or probably early in the third week. The groove is more pronounced at its lower or gastric extremity. As the groove deepens, its edges approach and finally meet and fuse with each other. In this manner the groove is converted into a tube, which gradually separates from the esophagus, the separation beginning at the end toward the stomach and progressing toward the pharynx. The separation, however, is not complete, stopping short of the upper end of the groove, so that the tube retains communication with the pharyngeal end of the esophagus. Even before the constricting off of this tube or **pulmonary diverticulum** is completed, its free end bifurcates. The pulmonary anlage consists, then, at this stage, of **two short wide pouches** connected by a common pedicle with the primitive pharynx (Figs. 95 and 96), and this condition is present in the fourth week.

Very soon after the end of the first month each of the pouches undergoes division, the right one into three branches,

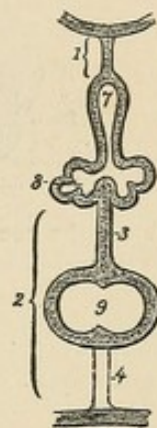


FIG. 96.—Transverse section to show outgrowth of pulmonary anlage from gut-tube (after Tournoux): 1, dorsal mesentery; 2, ventral mesentery including 3, mesocardium posterius; 4, mesocardium antierius; 7, esophagus; 8, diverticulum which becomes the lungs, the trachea, and the larynx; 9, heart.

the left one into two, while at the same time they increase in size (Fig. 97). The further steps toward the attainment

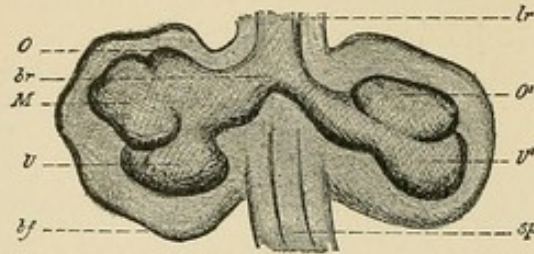


FIG. 97.—View of a reconstruction of the fundament of the lungs of a human embryo (Pr. of His) 10 mm. long, neck measurement (after His): *lr*, trachea; *br*, right bronchus; *sp*, esophagus; *bf*, connective-tissue envelope and serous membrane (pleura) into which the epithelial fundament of the lung grows; *O*, *M*, *U*, fundaments of the upper, middle, and lower lobes of the right lung; *O'*, *V'*, fundaments of the upper and lower lobes of the left lung.

of the completed condition consist largely in the continued repetition of this process of dichotomous division (Fig. 98),

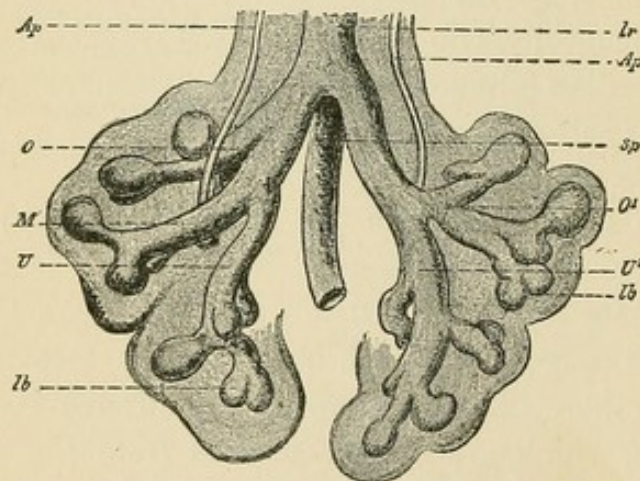


FIG. 98.—View of reconstruction of the fundament of the lungs of a human embryo (N. of His) older than that of Fig. 97 (after His, magnified 50 diameters): *Ap*, arteria pulmonalis; *lr*, trachea; *sp*, esophagus; *lb*, pulmonary vesicle in process of division; *O*, upper lobe of the right lung with an eparterial bronchus leading to it; *M*, *U*, middle and lower lobes of the right lung; *O'*, upper lobe of the left lung with hyparterial bronchus leading to it; *U'*, lower lobe of the left lung.

which latter goes on until the sixth month. The original evagination, consisting of **entodermal epithelium**, gives rise only to the **epithelial parts** of the lungs and air-passages. All the other constituents, the connective tissue, the muscular, vascular, and cartilaginous elements, are products of the **mesodermic tissue** into which the diverticulum grows. Upon their first appearance the "tubes" are always solid

epithelial cylinders, the lumina being acquired later. At first, the lining entodermal cells of the primitive tubes are tall and cylindrical, the tubes themselves having a relatively small lumen. In the fourth month the cells acquire **cilia**. From the anatomical standpoint, the lungs now present the characters of compound saccular glands.

From the sixth month to the end of gestation occur the changes which give to the organs their essential characteristics. Upon the dilated extremity of each terminal tube numerous little evaginations develop. These are the **air-sacs**, or **pulmonary alveoli**, the terminal tubes from which they are evaginated being the **alveolar passages** and the **infundibula**. Their walls remain very thin and their lining epithelium flattens to such a degree as to closely resemble endothelium. The **trachea** is simply the elongated **stalk** of the pulmonary diverticulum.

The **larynx** is the dilated proximal extremity of the pedicle, specially developed to serve as an organ of phonation. One of the earliest changes is the appearance of **two ridges** at the junction of the primitive trachea with the esophagus. These are close together in front, ventrally, but separated behind. They are the first indication of the **vocal cords**. The **arytenoid cartilages** are indicated in the sixth week and the other cartilages soon after. These are not actually cartilaginous, however, until the eighth or ninth week.

The **development of the pleuræ** has been described in connection with that of the pericardium and of the diaphragm (p. 158).

#### THE THYROID AND THE THYMUS BODIES.

These organs may be considered in this connection, as a matter of convenience and because of their embryological relationship to the respiratory system, being developed, like the latter, from the epithelium of the gut-tract.

The **thyroid body**, an organ common to all vertebrates, genetically consists of two parts, a **median lobe** and two **lateral lobes**.

The **median portion** originates from an evagination of the ven-

tral wall of the pharynx, in the median line, posterior, caudad, to the tuberculum impar, and between the ventral extremities of the first and second visceral arches. This median diverticulum is present in the human embryo of 5 mm. It soon pouches out on either side, assuming thereby the form of an epithelial vesicle connected by the constricted pedicle of the diverticulum with the ventral wall of the pharynx (Fig. 99, 3).

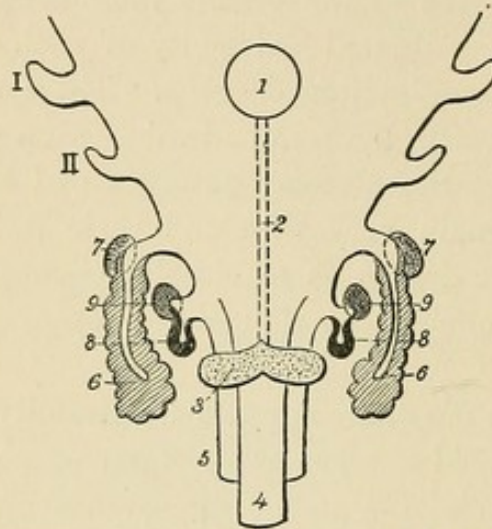


FIG. 99.—Diagrammatic representation of pharynx of human embryo seen from in front (after Tournoux): I, II, first and second pharyngeal pouches; 1, tuberculum impar; 2, course of thyroglossal duct leading from 3, median lobe of thyroid gland; 4, laryngotracheal tube; 5, esophagus; 6, thymus; 7, accessory thymus; 8, lateral lobe of thyroid; 9, accessory thyroid.

From the situation of the original point of evagination behind the tuberculum impar and ventromesial to the two halves of the posterior segment of the tongue, the orifice of the pedicle corresponds to the line of junction of the three parts of the tongue. As a consequence, when these parts unite, the pedicle or duct is prolonged upward and comes to open upon the surface of the tongue. The canal is known as the **thyroglossal duct** or **canal of His**. In the fifth week it begins to atrophy, and usually by the eighth week has become obliterated. Occasionally it persists throughout life. The **foramen cæcum** on the dorsum of the tongue is the vestige of the orifice of the duct. Other vestiges of the thyroglossal duct are sometimes present. For example, the lower part of the duct may persist as a short tube, the **thyroid duct**, leading upward from the median lobe to the

hyoid bone; and again, according to His, isolated persistent segments of the duct constitute the little vesicles in the neighborhood of the hyoid bone which are known respectively as the **accessory thyroid**, and the **suprahyoid** and **prehyoid glands**.

The **lateral lobes** of the thyroid body begin their development somewhat later than does the median lobe. In the embryo of 10 mm., the **fourth inner visceral furrow** or throat-pocket of each side pouches out to form a vesicle (Fig. 99, 8). As the vesicle grows, its pedicle becomes attenuated and finally disappears. After their isolation from the throat-pockets, the vesicles give out small bud-like processes after the usual manner of the development of glands and gradually approach the median lobe (Fig. 100, *B*). The three parts

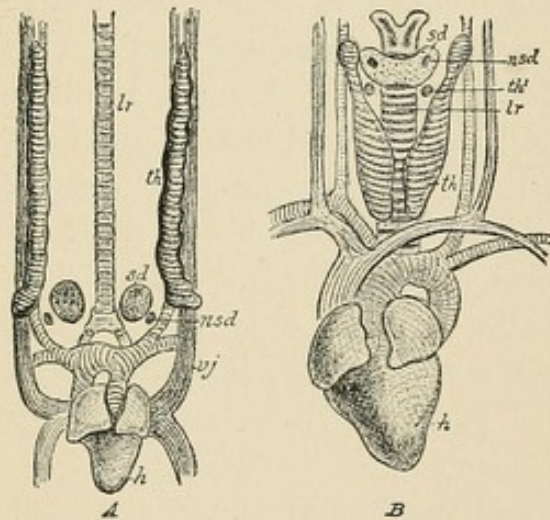


FIG. 100.—Semi-diagrammatic illustrations to show the ultimate position of the thymus, thyroid gland and accessory thyroid gland on the neck of the chick (*A*) and the calf (*B*), after de Meuron; *sd*, thyroid gland; *nsd*, accessory thyroid gland; *th*, thymus; *th'*, accessory thymus; *lr*, trachea; *h*, heart; *vj*, vena jugularis; *ca*, carotid vein.

unite probably in the seventh week. In the vertebrates below mammals the lateral parts of the thyroid do not unite with the median segment, and in certain animals they remain widely separated from it as the **suprapericardial bodies**.

After the union of the three portions of the gland, the latter consists of a network of cords of cells, the meshes of which reticulum are occupied by embryonal connective tissue. Subsequently the cords of cells become hollowed out and exhibit

alternating enlargements and constrictions. By the increase of the constrictions the continuity of the cell-cords is interrupted at short intervals, and so the network is converted into numerous **closed follicles** lined with epithelium, the formation of follicles beginning in the eighth week. The follicles later undergo considerable increase in size on account of the secretion by their epithelial cells of a peculiar **colloid material**, characteristic of the thyroid body. The **embryonal connective tissue**, made up necessarily of mesodermic elements, furnishes the **connective-tissue framework** and the **blood-vessels** of the organ, while the **epithelium** originates in the manner indicated from the **entoderm** of the gut-tract.

**The Thymus.**—What remains of the thymus after the second year of life is made up chiefly of **lymphoid** and **connective tissue**, embedded in which are characteristic little **epithelial bodies**, the **corpuscles of Hassall**.

The **epithelial parts** of the thymus, in all vertebrate animals, are derived from the **entodermal** lining of the pharyngeal region of the gut-tract. In the lower groups, such as reptiles, amphibians, and bony fishes, the epithelium of all the inner visceral clefts or throat-pouches shares in the development; while in birds, only two or three clefts take part. In mammals, however, including man, the thymus body is derived probably from but one throat-pocket, the **third**.

The entodermal epithelium of the third inner pouch becomes evaginated (Fig. 99) to form an epithelial sac whose connection with the pharyngeal cavity is subsequently lost. The isolated and elongated sac soon gives out small lateral buds or processes at the distal extremity. While the original sac has from the first a cavity, the bud-like branches are solid masses of epithelium. The branching continues and affects not only the lower or distal extremity of the thymus sac but also the proximal end, the structure now resembling an acinous gland (Fig. 101). While this growth is taking place, the epithelial mass is being invaded by lymphoid cells and young connective tissue with developing blood-vessels. The encroachment by these elements continues to such an

extent that **lymphoid tissue** becomes the predominant constituent of the thymus, the epithelial parts suffering reduction, relatively, and becoming finally broken up into isolated masses which are the **corpuscles of Hassall** of the mature gland. The breaking down of the epithelial cords is probably responsible also for the irregular cavities of the thymus. Not until after birth do the glands of the two sides of the body unite to form a **single unpaired structure**, and the development of the thymus is not completed until the end of the second year of life. Having attained its full development, the organ begins to retrograde, and at the time of puberty has almost disappeared. Although sometimes persistent throughout life, it usually suffers complete obliteration, or at most, is represented by an insignificant vestige. While the **epithelial parts** of the thymus body, represented in the fully developed organ by the corpuscles of Hassall, are derived from the **entodermal epithelium** of the third inner visceral furrow, all other parts, the **lymphoid tissue, connective tissue, and blood-vessels**, are products of the surrounding **mesoderm**.

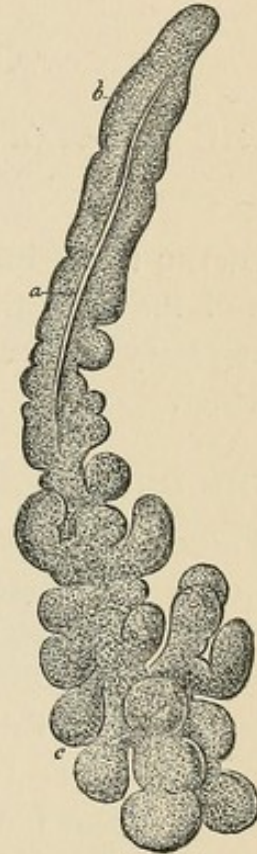


FIG. 101.—Thymus of an embryo rabbit of sixteen days (after Kölliker), magnified: *a*, canal of the thymus; *b*, upper, *c*, lower end of the organ.

## CHAPTER XIII.

### THE DEVELOPMENT OF THE GENITO-URINARY SYSTEM.

OWING to the intimate anatomical and functional association of the generative organs with the urinary apparatus, it is necessary to discuss the development of these two systems together.

#### THE DEVELOPMENT OF THE KIDNEY AND URETER.

The origin of the kidney and ureter of the higher vertebrates is associated with the development of certain fetal structures, the **pronephros** and the **mesonephros**, which represent respectively the kidney of larval amphibians and the permanent kidney of fishes. In man and other allied types, the former structure is of little or no importance functionally, while the latter functionates during a part of fetal life as the organ of urinary excretion, prior to the development of the permanent kidney.

The **pronephros** or **head-kidney** constitutes the most **primitive vertebrate type** of a mechanism for the excretion of urine. This structure has its origin in the mesothelium of the body-cavity, and in the following manner: When the paraxial mesoderm, which subsequently divides into the somites, is about to separate from the parietal plate of mesoderm, the two parts are connected for a time by an intervening thin band of tissue, the **middle plate** (Fig. 102, *mp*). On the outer side of this middle plate, the mesothelial cells of the parietal layer of the mesoderm become invaginated in a line parallel with the axis of the body to form a **cord of cells** which at several points retains its connection with the surface cells. Further changes bring about the hollowing out of the cell-cords so that there results a long tube, the **pronephric** or

**segmental duct**, which has several short transverse tubules opening into it and communicating by their opposite extremities with the body-cavity (Fig. 103). The mesothelium in immediate proximity to the free end of each short tube is invaginated by a tuft of capillary blood-vessels from a branch of the adjacent aorta to constitute a **glomerulus** (Fig. 103, *bb*). The pronephric duct passes tailward and opens into the **cloaca**, a receptacle which receives, in common, the terminal orifice of the primitive bladder and that of the primitive intestine. It is apparent, therefore, that the pro-

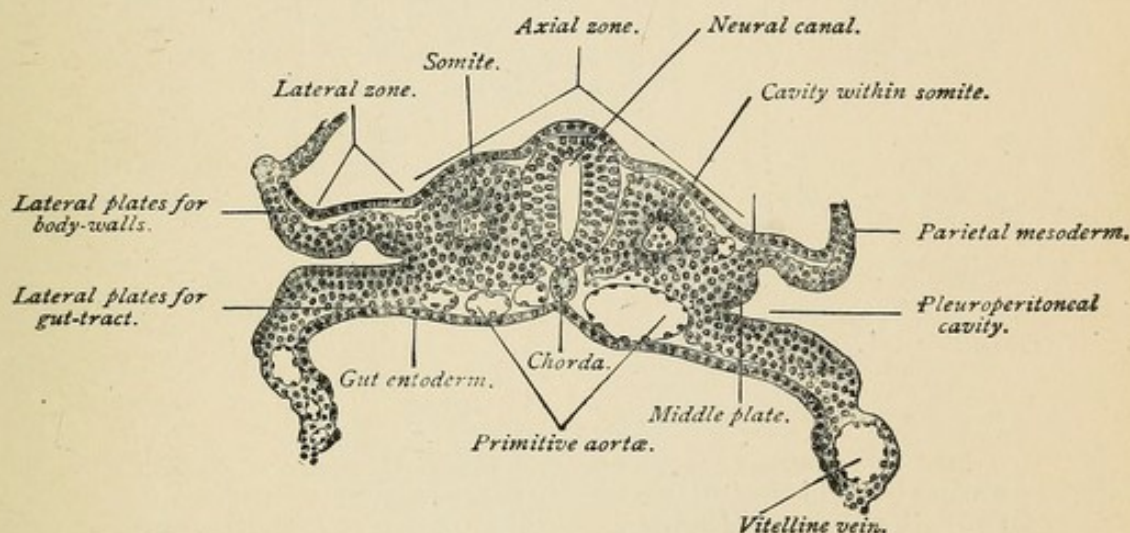


FIG. 102.—Transverse section of a seventeen-and-a-half-day sheep embryo (Bonnet).

nephros or head-kidney is anatomically adapted to the function of removing certain substances from the blood by virtue of the action of the cells surrounding the glomeruli or tufts of capillary blood-vessels, and that these substances may be conveyed away through the duct into the cloaca and thence evacuated from the body. This organ is functionally active, however, only in certain lower classes of vertebrates, as in the Amphibia during the larval stage and in bony fishes. In mammals it is exceedingly rudimentary and very soon gives place to a more important organ, the **mesonephros**.

**The Mesonephros or Wolffian Body.**—As in the case of the pronephros, the origin of the **mesonephros** is to be found in the **parietal mesothelium** of the body-cavity or coelom. Reference has been made, in treating of the primitive segments,

page 69, to the **middle plate** (Fig. 102) as a tract of mesodermic tissue connecting the paraxial tract with the parietal plate. When the paraxial mesoderm segments to form the somites, the middle plate likewise undergoes segmentation, each segment being designated a **nephrotome**. Each nephrotome, in the lower vertebrates, contains a cavity

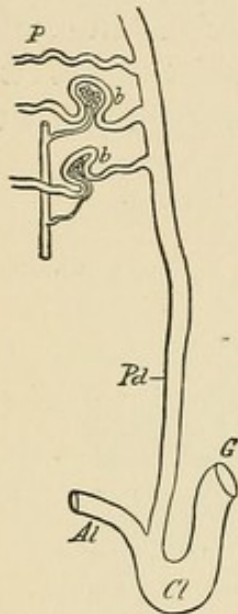


FIG. 103.—Diagram of pronephros (*P*) and pronephric duct (*Pd*): *Al*, allantois; *G*, gut; *Cl*, cloaca; *bb*, glomeruli.

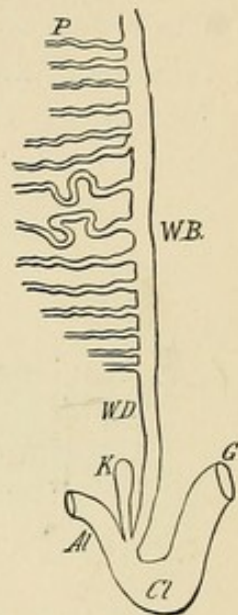


FIG. 104.—Diagram of Wolffian body and duct: *Al*, allantois; *G*, gut; *Cl*, cloaca; *K*, kidney evagination.

which communicates with the general body-cavity and which is therefore, in effect, an evagination of the mesothelium of this space. In mammals, however, as well as in reptiles and birds, the nephrotome is a solid cord of cells. By the hollowing out of these cell-cords or nephrotomes, a series of transversely directed tubules is formed, each nephrotome, in fact, becoming converted into a short canal. These tubes acquire connection by their deeper ends with the previously formed pronephric duct (Fig. 103), which is known hereafter, therefore, as the **mesonephric** or **Wolffian duct** (Fig. 104). The latter duct and the short transverse tubules which open into it constitute the **Wolffian body** or **mesonephros** (Figs. 105 and 106, 1). Hence, in its fully developed condition, which is attained by the seventh week of fetal life in man, the

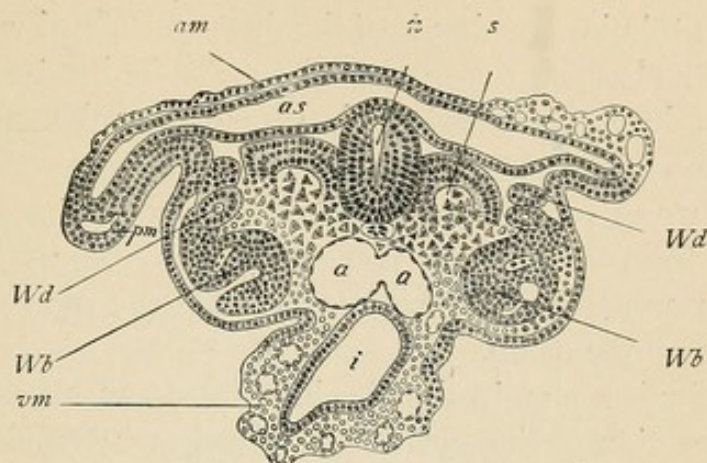


FIG. 105.—Transverse section of seventeen-day sheep embryo (Bonnet): *am*, amnion; *as*, amniotic sac; *n*, neural canal; *s*, somite differentiated into muscle-plate; *Wd*, Wolffian duct; *Wb*, Wolffian body; *pm*, parietal mesoderm; *vm*, visceral mesoderm; *a*, *a*, fusing primitive aortae; *i*, intestine.

Wolffian body consists of a tube or duct lying behind the parietal layer of the mesoderm, parallel with, and lateral to,

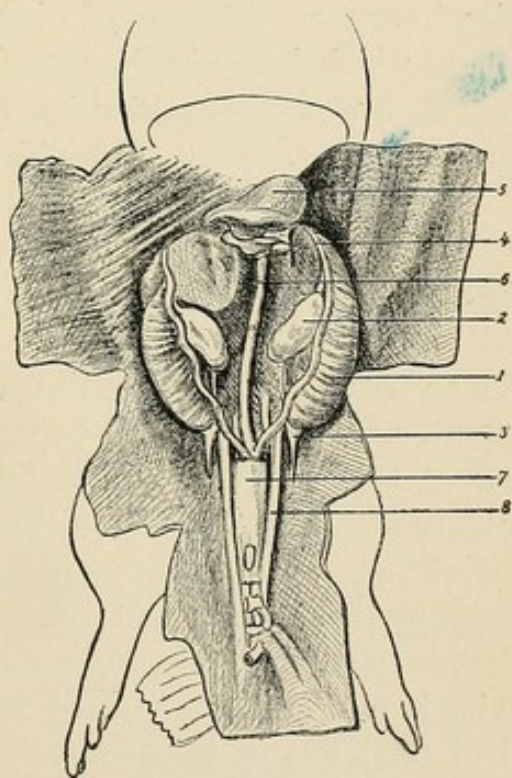


FIG. 106.—Disposition of the genito-urinary organs in the embryo of the hog—5.5 cm (2.2 in.) long (Tourneux): 1, Wolffian body; 2, ovary; 3, inguinal ligament; 4, diaphragmatic ligament; 5, stomach; 6, intestine; 7, bladder; 8, umbilical artery.

the primitive vertebral column, and opening at the caudal end of the embryo into the cloaca; and of a series of transverse

Wolffian tubules opening into the duct and abutting by their opposite ends upon the body-cavity. At the head-end of the Wolffian duct, the now atrophic pronephric tubes are still in connection with it.

It is usual for writers upon embryology to compare the general form of the Wolffian body to a comb, the short tubules representing the teeth, and the duct corresponding to the back of the comb.

As a further step in the development of an organ adapted to the function of the secretion of urine, each Wolffian tubule becomes somewhat saccular midway between its two extremities, and this dilated part of the tubule is invaginated by the capillary branches of an artery from the aorta. In this manner the cells that line the tubules are brought into relation with the blood of the fetus and acquire at the same time the characters of secreting epithelium. Such an invaginating tuft of capillaries, known as a **glomerulus**, with its enveloping **capsule of Bowman**, which latter is the invaginated saccular part of the tubule, constitutes a **primitive Malpighian corpuscle**, a structure analogous to the Malpighian corpuscle of the permanent kidney. The complexity of the organ is increased by the development of secondary tubules and Malpighian corpuscles connected with those first formed.

The **horizontal** or **transverse tubules** of the Wolffian body are divisible into an anterior or upper series, distinguished as the **sexual segment**, and a lower set of **atrophic tubules**—atrophic for reasons that will appear hereafter. In certain vertebrates that are of higher type than those in which the pronephros functionates, such as adult amphibians and fishes, the Wolffian body persists throughout life as an organ of urinary secretion. In birds and mammals, however, its functional activity is but temporary, since it is supplanted, before the end of fetal life, by the permanent kidney. In man it disappears relatively early, retrogression beginning in the eighth week and the Malpighian bodies having almost disappeared by the fifth month. The presence of the mesonephros as a temporarily functioning organ in birds and mammals, while it is a permanent structure in certain lower

members of the vertebrate series, exemplifies the embryological principle elsewhere referred to, that the higher types pass through stages during their development that are permanent in some of the forms below them in the scale of evolution.

**The Metanephros or Permanent Kidney.**—While the Wolffian body is temporarily performing the office of a kidney, a structure is evolving from its caudal extremity which is to form the permanent organ. It has been stated that the duct of the Wolffian body opens into the cloaca. From this cloacal end of the duct, a little **diverticulum** or evagination (Fig. 104) grows forth and soon lengthens into a tube which extends headward toward the position of the Wolffian body. The upper or anterior end of the tube branches to form a number of smaller tubes (Fig. 107). At the same time, the surrounding indifferent mesodermic tissue (Fig. 108) is altered in character, becoming condensed and vascular. The blind end of each little tube, becoming dilated and saccular, is invaginated by capillary blood-vessels. This transformation produces the **Malpighian corpuscles**. The sacculated end of each tubule is now a **capsule of Bowman**, while the tuft of capillaries enveloped by it is the **glomerulus**. It should be borne in mind that the glomerulus is not contained within the cavity of the tubule, but that the dilated end of the latter, still a shut sac, folds around the tuft of capillaries, enclosing it within a two-layered wall.

The tubules, assuming tortuous and convoluted form, owing to excessive growth in length, constitute the **uriniferous tubules** of the adult kidney. According to Minot, the **capsule** of the kidney, which is produced by the sur-

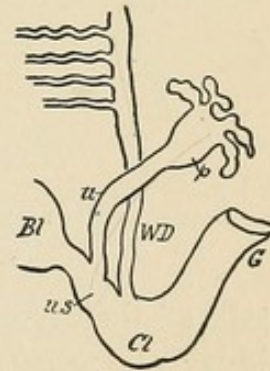


FIG. 107.—Diagram to show extension and branching of kidney evagination and separation of its stalk from the Wolffian duct: *u*, primitive ureter; *p*, pelvis of ureter; *Wd*, Wolffian duct; *Bl*, bladder; *us*, urogenital sinus; *Cl*, cloaca; *G*, gut.

rounding mesodermic tissue, exercises an important influence upon the form of the developing tubules, the resistance it offers to their centrifugal extension being the determining factor in producing the foldings and convolutions of the tubules. The progress of these metamorphoses is such that the kidney acquires its characteristic features by the end of the second month of fetal life. The original canal—that is,

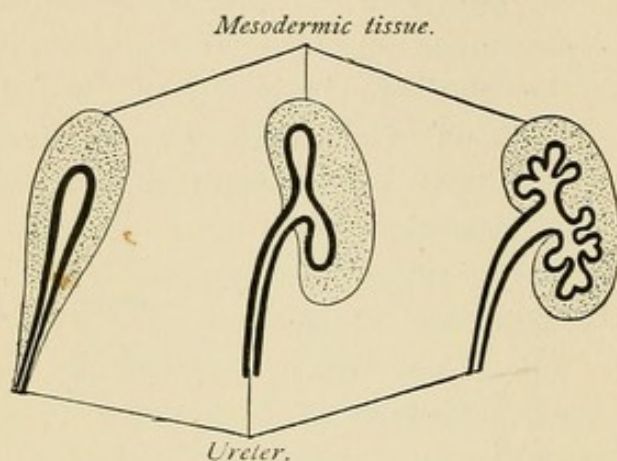


FIG. 108.—Diagrammatic representation of the development of the kidney (after Gegenbaur).

the stalk of the diverticulum—is now the excretory duct of the kidney, the **ureter**, while the dilated and branched upper part of the latter is the **pelvis of the kidney** with its **calyces** and **infundibula**. The connective-tissue **stroma** and **capsule** of the organ, in common with its **blood-vessels** and **lymphatics**, are products of the surrounding **mesodermic tissue**. It is apparent, therefore, that **all parts of the kidney** and its duct, the epithelium as well as the connective tissue, are derived from the **mesoderm**, since the Wolffian duct, from which the tubules and the ureter with their epithelium develop, is itself a product of the mesodermic cells, or mesothelium, lining the body-cavity.

#### THE SUPRARENAL BODIES.

The development of these structures is still involved in some obscurity. Most observers agree that they are genetically connected with the mesonephros or primitive kidney, but whether the organs, as represented in the adult condition,

are derived solely from this source is not as yet definitely made out.

The **origin** of the suprarenal body is variously ascribed by different investigators—1, to a group of connective-tissue cells found at the upper end of the primitive kidney; 2, to the germinal epithelium of the anterior or head-end of the genital ridge; and 3, to epithelial outgrowths from the mesonephros or primitive kidney. The last named is regarded by Hertwig and by Minot as being the most probable source. The epithelial outgrowths referred to bud forth from the glomeruli of the primitive kidney and divide, each into two branches, one of which grows into the indifferent sexual gland to produce a part of its structure (as described in the sections on the ovary and on the testis), while the other turns dorsad and spreads out to form eventually the **cortical part** of the suprarenal body.

The origin of the **medullary part** of the organ is also a disputed point. On the dorsal side of the primitive kidney chains of small cells grow forth from the embryonic ganglia of the sympathetic system. These latter become surrounded by the cells derived from the mesonephros, as well as by embryonic connective-tissue cells, and are divided into small groups. According to Hertwig,<sup>1</sup> who follows Balfour, Braun, and Kölliker, the cells budding from the **sympathetic ganglia** produce the medullary part of the organ. Minot, on the contrary, believes that these cells later entirely disappear and take no part in the formation of the medulla.

In the early stages of fetal life, the suprarenal body is relatively much larger than in the adult condition, and is situated chiefly on the ventral surface of the kidney. At about the third month it begins to assume more nearly its normal position.

The account of the development of the bladder and of the urethra may be deferred until the evolution of the internal sexual system shall have been considered.

<sup>1</sup> *Entwicklungsgeschichte*, fifth edition, Jena, 1896.

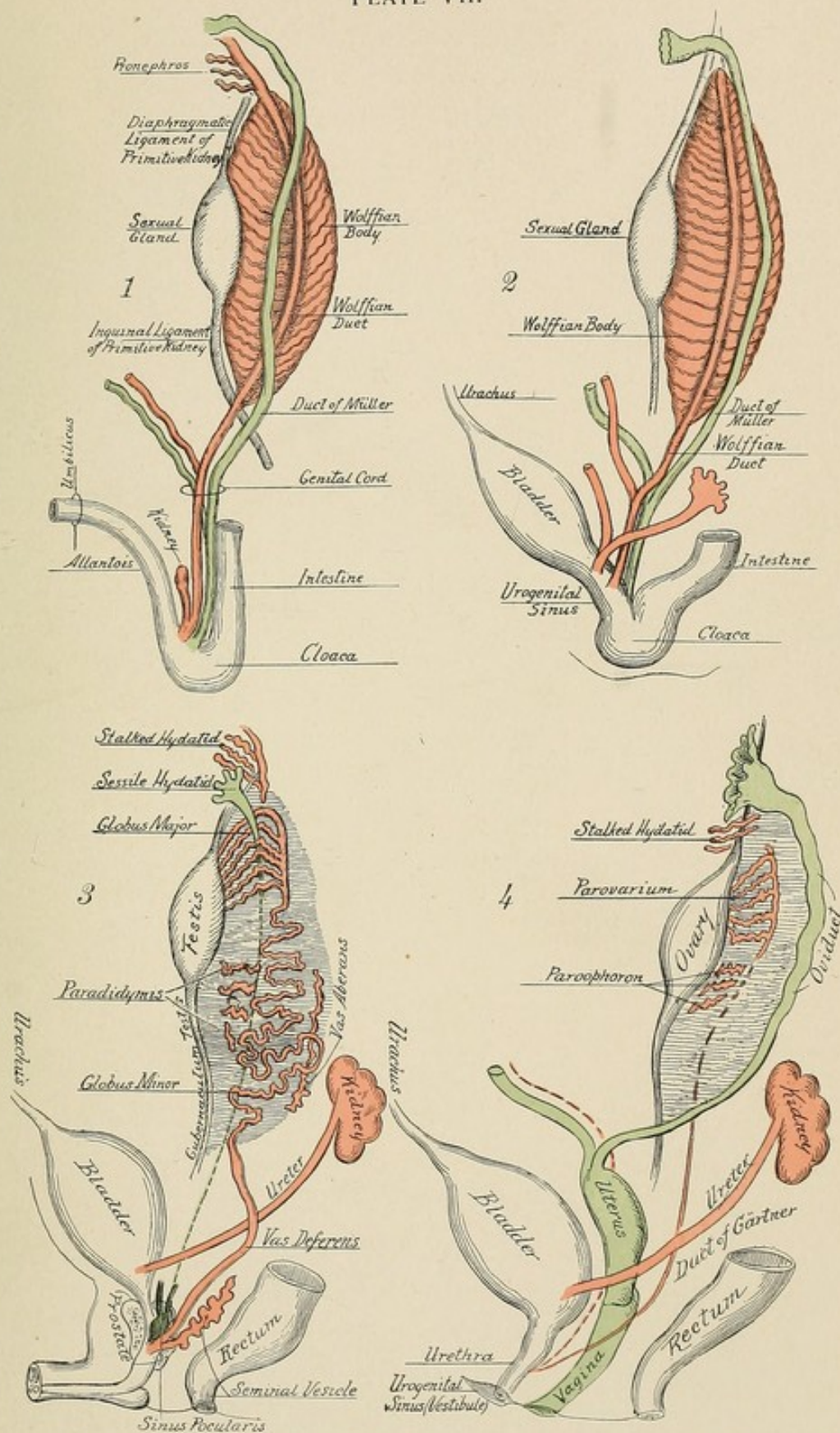
### THE DEVELOPMENT OF THE INTERNAL GENERATIVE ORGANS.

**The Indifferent Type.**—The internal generative organs of both sexes, in the course of their development, pass through a stage in which there is to be found no distinction of sex. This stage is designated, therefore, the indifferent type of sexual apparatus.


While the Wolffian body is attaining its full development, there appears in its vicinity a tube, the **duct of Müller** (Plate VII., Fig. 1), which lies parallel with, and to the outer side of, the Wolffian duct. The exact mode of origin of the duct of Müller has not as yet been definitely made out. According to one view, its upper or cephalic portion is produced by an invagination of the mesothelium of the body-cavity, while the remaining lower segment results from a fission or longitudinal division of the Wolffian duct. In whatever way the duct may be formed, its lower or caudal end opens into the cloaca, which receptacle receives also the termination of the Wolffian duct. The upper end of the duct maintains a communication with the body-cavity or coelom by means of an expanded funnel-shaped mouth. Its lower segment is closely associated with its fellow and with the Wolffian ducts, forming thus the **genital cord**. The function of this canal in lowly organized animals—that of receiving from the body-cavity the female genital products, the ova, and evacuating them from the body—foreshadows its subsequent metamorphosis in most vertebrates.

While the duct of Müller is forming, the mesothelial cells overlying that part of the free surface of the Wolffian body which looks toward the median plane and somewhat forward, its ventro-mesial aspect, undergo multiplication and thickening (Fig. 109, *a*), forming an elongated swelling or ridge. This is known as the **genital ridge**, which produces a projection upon the wall of the body-cavity. The genital ridge is still further thickened by the proliferation of the mesodermic tissue (*E*) beneath the mesothelial cells. The genital ridges of the human fetus appear in the fifth week.

PLATE VII.



Diagrammatic representation of the development of the genito-urinary system, the Wolffian body and its derivatives being colored red, the Müllerian duct and its derivatives, green: 1, indifferent type; 2, indifferent type, later stage, the Wolffian and Müllerian ducts and the primitive ureter now opening into the urogenital sinus; 3, male type, lower ends of Müllerian ducts fused to form the sinus pocularis; 4, female type.



Further differentiation of the genital ridge results in its transformation into the so-called **indifferent sexual gland** (Plate VII., Fig. 1), a structure common to both sexes at this stage. The essential feature of this process is that the thickened mesothelial cells overlying the genital ridge become modified in character and penetrate the ridge in the form of cords or strands of cells. These mesothelial elements were called by

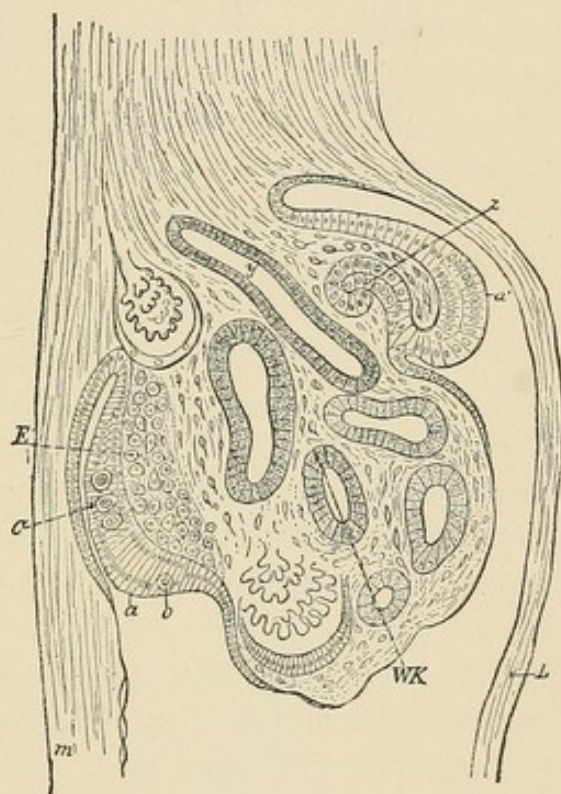


FIG. 109.—Cross-section through the mesonephros, the fundus of the Müllerian duct, and the sexual gland of a chick of the fourth day (after Waldeyer), magnified 100 diameters: *m*, mesentery; *L*, somatopleure; *a'*, the region of the germinal epithelium from which the Müllerian duct (*z*) has been invaginated; *a*, thickened part of the germinal epithelium, in which the primary sexual cells, *c* and *o*, lie; *E*, modified mesenchyme out of which the stroma of the sexual gland is formed; *WK*, mesonephros; *y*, mesonephric duct.

Waldeyer the **germinal epithelium**, because, after their extension into the interior of the ridge or gland, they give rise to the **germ-cells**, namely, the **ova** or the **spermatozoa** as the case may be. The cell-cords include two kinds of elements, the smaller **mesothelial cells** and the **primitive sexual cells**, which latter are larger and less numerous than the mesothelial cells and have large nucleolated nuclei. The **primitive sexual**

or **seminal cells**, or **primitive ova**, are so called because it has been assumed that they develop either into the ova or the seminal filaments according to the sex of the embryo. The cell-cords have been seen in the indifferent gland of the human embryo as early as the fifth week. At this time, although there are no gross sexual distinctions recognizable, it is possible to determine from the histological characters of the organ whether it is to be a testis or an ovary, the large sexual cells being far less numerous relatively in the former case than in the latter (Nagel).

The indifferent sexual gland comes into an especially close relation with the upper or sexual series of the mesonephros or Wolffian body (Plate VII., Fig. 1), the significance of which fact will appear later.

The elements of the indifferent stage of the sexual apparatus are, therefore, the **indifferent sexual gland**, the **Wolffian duct**, and the **duct of Müller** (Plate VII., Figs. 1, 2). From this asexual stage, either the male or the female type is produced by the metamorphosis of the indifferent glands into the testicles or the ovaries and the formation of ducts to provide for the escape of the sexual elements, the spermatozoa, or the ova, produced by them.

**The Male Type of Sexual System.**—The differentiation of the indifferent sexual system into the male type is effected by the further development of some parts and the atrophy or the arrested growth of others.

The **testicle** has a double origin, since the proper **secretory part** of the organ is produced by the metamorphosis of the indifferent sexual gland, while its system of **efferent ducts** is furnished by the Wolffian body. Mention has been made of the cell-cords of the indifferent sexual glands and of their origin from the mesothelium of the body-cavity, and also of the fact that they consist of the smaller mesothelial cells and the larger and less numerous primitive sexual cells.

The **mesothelial cells** increase in number and become so grouped as to form cylindrical masses known as **sexual cords**, each of which includes some of the primitive seminal or sexual cells. By the ingrowth of connective tissue from the

surrounding mesoderm, the sexual cords are divided into roundish masses, each of which is made up of many of the smaller elements and a less number of the large seminal cells. These follicle-like masses become hollowed out to form the **seminal ampullæ**, which afterward, by undergoing great increase in length, are transformed into the **seminiferous tubules**. During fetal life, however, and even to the period of puberty, the "tubules" remain solid cords of cells. The exact relation of the two kinds of cells to the production of the spermatozoa, whether or not the small cells give rise to Sertolli's columns, and the primitive seminal cells to the spermatozoa, is still involved in obscurity.

**Spermatogenesis**, or the development of the spermatozoa from the cells that line the seminiferous tubules of the functioning testicle, has been considered in Chapter I.

While the sexual cords are being transformed into the cylinders that become the seminiferous tubules, the surrounding mesodermic tissue penetrates the genital gland and forms the connective-tissue septa that constitute the **stroma** of the organ and divide it into **lobules**. At the same time, also, marked changes occur in the Wolffian body. From that part of this structure which has been referred to as the **sexual series** of transverse Wolffian tubules, cords of cells grow forth and penetrate the genital gland, their ends fusing with the primitive seminiferous tubules. The conversion of these cell-cords into tubes furnishes the initial part of the system of **excretory ducts** of the testicle, namely, the **vasa recta**, and the **rete testis**. Somewhat later, in the twelfth week, the rete testis is extended to form the **vasa efferentia**, and still later, in the fourth and fifth months, the efferent vessels lengthen and become tortuous, producing thereby the **coni vasculosi** or **head of the epididymis** (Plate VII., Fig. 3; Fig. 110). The upper part of the Wolffian duct develops into a convoluted tube which constitutes the **body** and **tail** of the **epididymis**, while the lower portion becomes the **vas deferens**, thus completing the system of canals provided for the escape of the spermatozoa. Near the caudal end of the Wolffian duct, a little pouch-like evagination grows from its wall and becomes

the **seminal vesicle**, the lower end of the duct, below the orifice of the seminal vesicle, being the **ejaculatory duct**. Since the

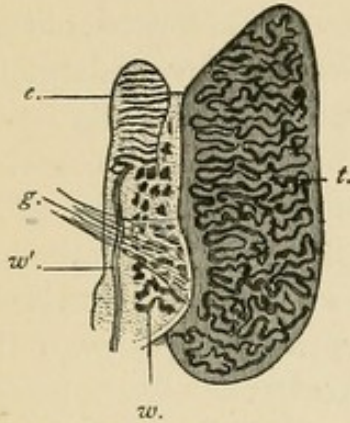


FIG. 110.—Internal generative organs of a male fetus of about fourteen weeks (Waldeyer): *t*, testicle; *e*, epididymis; *w'*, Wolffian duct; *w*, lower part of Wolffian body; *g*, gubernaculum testis.

Wolffian duct terminates in the cloaca, and since the anterior part of the cloaca corresponds to a portion of the later urethra, the termination of the ejaculatory duct in the prostatic part of the urethra is accounted for. Thus it will be seen that while the secreting part of the testicle results from the transformation of the indifferent genital gland, the **secretory cells** having their origin in the **germinal epithelium**, the complicated system

of ducts with which it is provided is furnished by the **mesonephros** or **Wolffian body**.

The series of tubules connected with the upper extremity of the Wolffian duct, the remnant of the **pronephros** or head-kidney, frequently persists as a little pedunculated sac attached to the upper part of the epididymis; it is known as the **stalked hydatid** and sometimes also as the **hydatid of Morgagni**. The posterior or lower set of Wolffian tubules likewise give rise to an atrophic structure, the **paradidymis** or **organ of Giralde's**, which consists of a series of short tubes closed at both ends, lying among the convolutions of the tail of the adult epididymis (Plate VII., Fig. 3).

The duct of **Müller** remains atrophic, in the male, throughout its entire extent, and in fact, with the exception of its two extremities, it usually altogether disappears. Its upper extremity persists as a small vesicle, the **unstaked** or **sessile hydatid**, attached to the upper aspect of the testicle. The lower extremity of the duct, uniting with its fellow, becomes converted into the **sinus pocularis** or **uterus masculinus** of the prostate gland (Plate VII., Fig. 3). If the intervening part

of the tube persists to post-natal life and remains patulous, it is known as the **duct of Rathke**.

The **change of location** which the testicle undergoes is a conspicuous feature of its development. To understand this clearly, it is necessary to recall the relation of the mesonephros and the genital gland to the peritoneum. Since both of these bodies originate from the cells of the outer wall of the body-cavity, or, in other words, from what becomes the parietal peritoneum, necessarily they lie between the body-wall and the parietal peritoneum—that is, behind the peritoneal cavity. With the increase in size of these structures, they project toward the peritoneal cavity, the peritoneum passing over them and forming a “**mesentery**,” which anchors them to the posterior wall of the abdomen. In the case of the testicle, this peritoneal fold or “mesentery” is called the **mesorchium**; in the case of the ovary, the **mesovarium**. It is prolonged upward to the diaphragm as the **diaphragmatic ligament** of the primitive kidney, and downward to the inguinal region as the **inguinal ligament** of the primitive kidney (Fig. 106), since this latter organ is the largest constituent of the projecting mass. When the primitive kidney has disappeared as such, the inguinal ligament mentioned seems to connect the ovary or testicle with the inguinal region of the abdominal wall.

The **inguinal ligament** contains between its folds connective tissue and unstriated muscular fibers. These become the **gubernaculum testis** in the male or the **round ligament** of the uterus in the female. As the body of the fetus continues to grow while the tissues of the ligament remain stationary or grow less rapidly, the testicle is gradually displaced from its position at the side of the lumbar spine, and by the third month reaches the false pelvis. In the fifth and sixth months it is in contact with the anterior abdominal wall, near the inner abdominal ring. In the eighth month it enters the inguinal canal, and near the end of the ninth month, shortly before birth, it leaves the inguinal canal and enters the scrotum.<sup>1</sup>

<sup>1</sup> Non-descent of the testicles, with consequent emptiness and flabbiness

Before the testicle leaves the abdominal cavity, the parietal peritoneum pouches through the inguinal canal into the scrotum, the protruded part being the **processus vaginalis**. Since the testicle is from the first behind the parietal peritoneum, it passes into the scrotum behind the vaginal process, the latter then folding around it as a shut sac of two layers. Subsequently the connection of the sac, now the **tunica vaginalis testis**, with the abdominal peritoneum is reduced to a slender strand of tissue lying in front of the spermatic cord.<sup>1</sup>

The testicle necessarily carries with it, in its descent, its blood-vessels, the spermatic artery and vein; its duct, the vas deferens; as well as its nerves and lymphatic vessels; and these structures collectively constitute the **spermatic cord**.

**The Female Type of Sexual System.**—While the indifferent sexual gland, in the development of the male generative system, undergoes metamorphosis into the testicle, it becomes, in the evolution of the female type, so altered as to constitute the ovary; and while the Wolffian tubules and the Wolffian body become in the male the system of excretory ducts of the testicle, they produce in the female merely atrophic structures. On the other hand, the duct of Müller, which gives rise in the male to atrophic appendages, forms in the female type the Fallopian tube and, by fusing with its fellow of the opposite side, the uterus and the vagina.

The **ovary** results from alterations in the structure of the genital gland analogous to those that occur in the evolution of the testicle. The special features of these changes are better understood, however, than are those of the testicle. As in the case of the development of the testicle, the mesothelial cells on the peritoneal surface of the genital ridge become thickened, these altered cells constituting the **germinal**

of the scrotum, is designated *cryptorchism* (hidden testes). The presence of but one testicle in the scrotum is called *monorchism*.

<sup>1</sup>Occasionally it happens that the *funicular process* of the tunica vaginalis—that is, the stalk of the sac, remains patulous throughout its entire extent, a condition which allows of the easy and sudden protrusion of a segment of the bowel into the cavity of the tunica vaginalis, constituting the so-called *congenital hernia*. Or the funicular process may close only at one or the other end, giving rise to other varieties of hernia.

**epithelium** (Fig. 109). Coincidentally, the primitive connective tissue—mesodermic tissue—underlying the germinal epithelium proliferates, contributing to the thickness of the genital ridge. By the sixth or seventh week, the germinal epithelium consists of several strata of cells, groups of which begin to penetrate the underlying mesodermic tissue in the form of cord-like processes (Fig. 112, *e, sch*). The indifferent mesodermic tissue at the same time increases in quantity, in turn penetrating between the groups of advancing cells, so that what takes place might be described as a mutual intergrowth. The presence of the growing connective tissue accentuates the grouping of the cells into cylindrical masses. These latter are the **sexual cords** or **egg-columns** (Pflüger's egg-tubes). They contain two special kinds of cells, the **large sexual cells** or **primitive ova** (Fig. 112, *ue*), and the smaller but more numerous **mesothelial cells**. The connection of the sexual cords with the germinal epithelium is much more obvious in this case than in the case of the developing testicle, and the primitive sexual cells are much more abundant. The egg-columns, surrounded by young connective tissue, constitute the nucleus of the cortical part of the future ovary. This mass is later sharply marked off from the free or peritoneal aspect of the gland, the region of the germinal epithelium, by a zone of proliferating mesodermic cells which become the **tunica albuginea** of the ovary.

An important change now takes place in the egg-columns; the primitive ova, or large sexual cells, increase in size, their nuclei becoming especially well developed, while the small

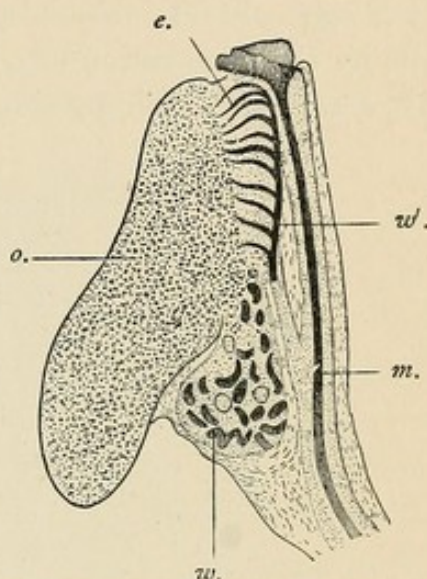


FIG. 111.—Internal organs of a female fetus of about fourteen weeks (Waldeyer): *o*, ovary; *e*, epoöphoron or parovarium; *w'*, Wolffian duct; *m*, Müllerian duct; *w*, lower part of the Wolffian body.

mesothelial cells become smaller and less conspicuous. Several of the large cells fuse into a single mass of protoplasm, while one of the nuclei outstrips the others in growth and, with the surrounding zone of protoplasm, becomes the **ovum**. Each egg-column is now broken up into several groups of cells by the penetration of connective tissue, each group (Fig. 112, *e, sch'*) containing a single ovum but many of the smaller

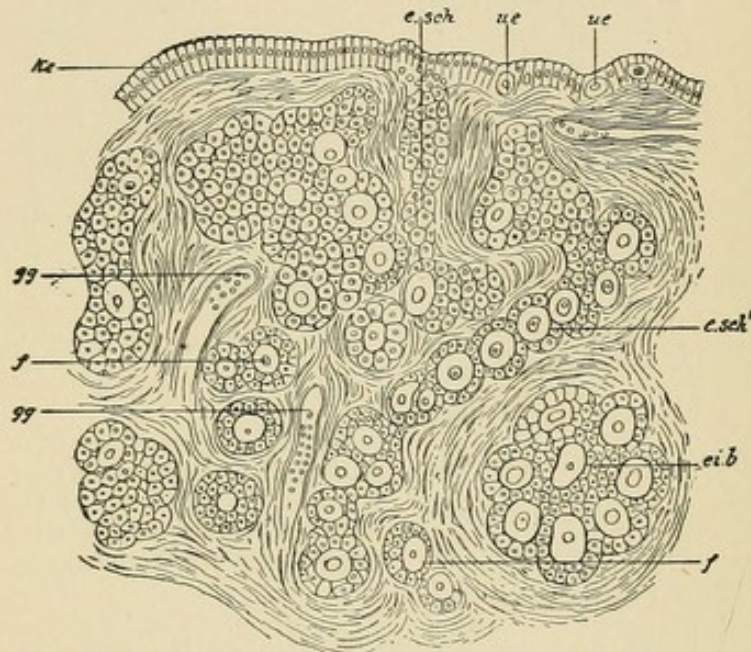


FIG. 112.—Part of sagittal section of an ovary of a child just born (after Waldeyer). Highly magnified: *ke*, germinal epithelium; *e, sch*, Pflüger's egg-tubes; *ue*, primitive ova lying on the germinal epithelium; *e, sch'*, long Pflüger's tubes, in process of being converted into follicles; *ei, b*, egg-balls (nests), likewise in process of being resolved into follicles; *f*, youngest follicle already isolated; *gg*, blood-vessels. In the tubes and egg-nests the primordial eggs are distinguishable from the smaller epithelial cells, the future follicular epithelium.

cells. These groups are the young **Graafian follicles** of the ovary (*f*). The enveloping zone of connective tissue becomes the **theca** of the follicle, while the single large cell constitutes the **ovum**, and the smaller cells are the **membrana granulosa**. At first the granulosa cells surround the ovum as a single layer of flattened cells which gradually assume the columnar type and become so numerous as to form many layers. They secrete a fluid, the **liquor folliculi**, which crowds the ovum to one side of the follicle where it is enveloped by a special group of granulosa-cells, the **discus proligerus** (Fig. 113).

The question of the origin of the follicular cells is still an unsettled one, though it seems probable that they are derived from the cells of the egg-columns, and Minot believes that they are probably descended from the primitive ova.

The **formation of new Graafian follicles**, and consequently of ova, begins in the deeper part of the ovary and advances toward the surface. The production of ova and follicles is

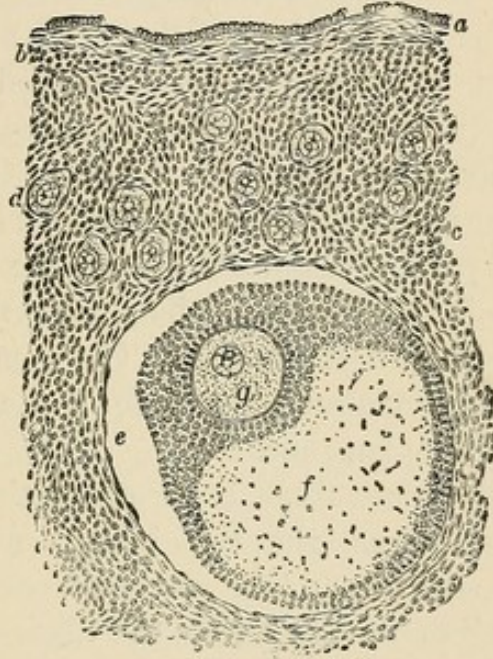


FIG. 113.—Section of human ovary, including cortex: *a*, germinal epithelium of free surface; *b*, tunica albuginea; *c*, peripheral stroma containing immature Graafian follicles (*d*); *e*, well-advanced follicle from whose wall membrana granulosa has partially separated; *f*, cavity of liquor folliculi; *g*, ovum surrounded by cell-mass constituting discus proligerus (Piersol).

limited to the fetal stage and to the early part of post-natal life, their formation not occurring, according to Waldeyer, after the second year.

What has been said above refers to the development of the **cortex** of the ovary. The **medulla** is produced by the growth toward the egg-columns of cord-like processes, the **medullary cords**, from the epithelial walls of the Malpighian corpuscles of the primitive kidney or Wolffian body, the cords becoming surrounded by connective tissue and forming a network. The fetal medullary cords are represented in both the cortex and the medulla of the mature ovary by the groups of **interstitial cells** disposed between the bundles of the stroma-tissue.

**The Oviducts, the Uterus, the Vagina.**—The system of passage-ways that constitute the outlets for the ova and the means of nourishing them and evacuating the product of gestation from the body in the event of impregnation—namely, the **Fallopian tubes**, the **uterus**, and the **vagina**—result from the metamorphosis of the **ducts of Müller**. These ducts, as stated above, lie along the dorsal aspect of the body-cavity, separated from it by the parietal peritoneum, and parallel with the primitive spinal column (Plate VII.). The probable method of their formation has been pointed out (p. 220). Near the lower (caudal) end of the body they approach each other, and finally unite about the second month to form a **single duct** for the rest of their extent (Plate VII., Fig. 4). The upper, ununited parts of the ducts become the **Fallopian tubes** or **oviducts**, while the lower portions, now fused into one, become the **uterus** and the **vagina**. The upper end of each single duct expands trumpet-like to form the **fimbriated extremity** of the Fallopian tube.

Until the fifth month there is no distinction between the vagina and the uterus, the two being represented by a single sac-like structure. The development of a circular ridge in the wall of the sac marks the division between the two organs, the part above the ridge acquiring thick muscular walls, while the part below it, the future **vagina**, remains thin-walled and more capacious. In the third month the **uterus** is bifid at its upper extremity, a condition which is permanent in some animals and occasionally in the human subject.<sup>1</sup>

The **Wolffian duct**, which, in the male, becomes metamorphosed into a part of the epididymis and the vas deferens, remains undeveloped in the female, producing merely atrophic or vestigial structures (Plate VII., Fig. 4). The upper series of Wolffian tubules, the remnant of the pronephros, frequently

<sup>1</sup> The formation of the uterus and of the vagina by the coalescence of two parallel tubes affords an explanation of the *uterus bicornis* or *bifid uterus* and of the condition of *double uterus* sometimes met with, as also of the presence of a *median septum in the vagina*, since by the failure of union of the two tubes in greater or less degree one or other of these anomalies would result.

persists, as in the male, in the form of a small pedunculated sac, the **stalked hydatid** or **hydatid of Morgagni**. When present, it is to be found in the broad ligament, in the neighborhood of the outer extremity of the ovary. The **middle** or **sexual series** of the Wolffian tubules with the adjacent part of the Wolffian duct, which, in the male type, develop into the epididymis, become in the female, an atrophic structure known as the **epoöphoron** or **parovarium**, or **organ of Rosenmüller** (Fig. 111). This structure, which is almost constantly found between the layers of the broad ligament in close proximity to the ovary, consists of a larger horizontal tube representing a segment of the Wolffian duct, and of shorter vertical tubes joining this at a right angle and representing the transverse Wolffian tubules. The **lower set** of small Wolffian tubules, those which, in the male become the paradidymis, give rise in this case to a similar atrophic body, the **paroöphoron**. This is also situated in the broad ligament, usually to the inner side of the ovary. The **Wolffian duct**, with the exception of that portion of it that assists in the formation of the parovarium, usually entirely disappears. Occasionally, however, it persists as a small canal traversing the broad ligament close to the uterus and passing on the dorsal side of the upper part of the vagina to be lost upon the wall of the latter or, more rarely, to open near the urinary meatus. When thus persistent, it is known as the **duct of Gartner**.

The **change of position of the ovaries** is similar to, though less marked than, that of the testes. The **inguinal ligament** in the female (Plate VII.) extends from the primitive position of the ovaries in the lumbar region of the abdominal cavity to the groin, where it passes through the abdominal wall, traversing the inguinal canal, to terminate in the labium majus. The upper part of this ligament, containing involuntary muscular substance, firmly unites with the ovary. In the third month the ovary descends to the lower part of the abdominal cavity and is now connected, by the succeeding portion of the inguinal ligament, with the uterus. This connection may be a factor in the final change of position of the

ovary—that is, its descent into the true pelvis. The part of the inguinal ligament that passes from the ovary to the uterus is the permanent **ligament of the ovary**, while the remaining portion, which passes from the uterus through the inguinal canal to the labium majus of the vulva, is the **round ligament** of the uterus. As the inguinal ligament perforates the abdominal wall, a small diverticulum of peritoneum goes with it. Normally this peritoneal pouch subsequently becomes obliterated. Occasionally, however, it persists and then constitutes the **canal of Nuck**. Should the canal of Nuck be present, the ovary may pass into or through it, thus reaching the labium majus. A patulous canal of Nuck, as in the case of a patulous funicular process of the tunica vaginalis of the male, may permit the sudden occurrence of an inguinal hernia in the female.

The account of the development of the external genital organs will be deferred until after the consideration of the formation of the urinary bladder and of that part of the urethra that originates from the same embryonic structure.

#### THE BLADDER AND THE PROSTATE GLAND.

As stated in Chapter V., the **urinary bladder** and a **part** of the **urethra** are derived from the intra-embryonic portion of the **allantois**. In the same chapter the allantois was described as a sac which developed as a pouching-out of the ventral wall of the gut-tract near its caudal end (Plate II., 5 and 6). The sac protrudes from the still widely open abdominal cavity, enters the extra-embryonic part of the body-cavity, and reaches the inner surface of the false amnion, with which structure it intimately unites to form the true chorion (Plate III.). As the walls of the abdomen gradually close, leaving only the umbilical aperture, it is, necessarily, through this aperture that the allantois protrudes.

We have seen (p. 82) what becomes of the extra-abdominal part of the allantois—in what degree it contributes to the formation of the placenta and of the umbilical cord.

Obviously, with the severing of the umbilical cord after birth, all this extra-embryonic part of the allantois disappears, giving rise to no adult organ.

Its intra-embryonic portion consists of a tube extending from the caudal end of the intestine to the umbilicus (Plate II., 5 and 6). As early as the second month, the middle segment of this tube dilates and assumes the form of a spindle-shaped sac, which becomes the **urinary bladder** (Plate VII.). The part of the tube connecting the summit of this sac with the umbilicus remains small, gradually loses its lumen, and constitutes in the adult the (usually) impervious cord known as the **urachus**. Should the cavity of the urachus persist in its entirety, and should there be at the same time an external opening at the umbilicus, the condition would constitute an **umbilical urinary fistula**. The proximal part of the allantois—that is, the portion intervening between the bladder and the intestine—is designated the **sinus urogenitalis**, while the caudal end of the intestine, which is, in effect, a pouch in which both the allantois and the intestine terminate, is known as the **cloaca** (Fig. 84). The urogenital sinus receives the terminations of both the Müllerian and the Wolffian ducts (Plate VII.).

In the sixth week or slightly earlier, there appears upon the surface of the body, in the region corresponding to the position of the cloaca, a depression, the **cloacal depression** (Fig. 84), which later, except in man and the higher mammals, meets the cloaca, and thus establishes a communication between it and the exterior. In the Amphibia, in reptiles, and in birds, as also in the lowest mammals, the monotremes, the cloaca is a permanent structure, and through it, in these groups of animals, not only the fecal matters and the urine, but also the genital products, the spermatozoa and the ova, are evacuated from the body. In all mammals, however, with the exception of the monotremes, the cloaca undergoes division into a posterior part or **anal canal** and an anterior **urogenital aperture**. This division is brought about by the growth of three ridges or folds, of which one springs from each side of the cloaca and one from the point of union of the uro-

genital sinus and the intestine. These folds coalesce about the eighth<sup>1</sup> week to form a complete septum, which continues to thicken antero-posteriorly up to the time of birth and constitutes the perineum.

It will be remembered that the ureters originally spring from the terminal parts of the Wolffian or mesonephric ducts (Fig. 104). Owing to alterations brought about by processes of unequal growth, the orifices of the ureters subsequently change their position so as to open into the urogenital sinus (Fig. 107), and still later, by the further operation of the same agency, they come to open into the bladder on its dorsal wall, thus gradually assuming their permanent relations (Pl. VII.). After the division of the cloaca the urogenital sinus, as stated above, opens independently upon the surface of the body. In the female it is transformed into a short tube, the **urethra**, and an expanded terminal recess or fossa, the **vestibule of the vulva** (Pl. VII.). In the male it becomes the first or **prostatic part of the urethra**.

In the twelfth or thirteenth week, the future **prostatic urethra** acquires very thick muscular walls, and the original epithelial tube pouches out into the muscular tissue in the form of little sacs, the lining cells of which assume the characters of secreting epithelium. In this way is produced the aggregation of muscular and glandular tissue known as the **prostate gland**. This is a well-developed structure by the fourth or fifth month (Tourneux). The recess in the floor of this part of the urethra, the **sinus pocularis** or **uterus masculinus**, has been previously referred to as the homologue of the uterus, being the persistent caudal extremities of the ducts of Müller (Plate VII.).

#### THE EXTERNAL ORGANS OF GENERATION.

In the early stages of the development of the external genital organs no sexual distinctions are apparent.

Reference has been made to the cloacal depression as a superficial fossa which makes its appearance at the caudal end of the body of the embryo in the sixth week (Fig. 84). At

<sup>1</sup> Fourteenth week, according to Minot.

about the same period an encircling elevation, the **genital ridge** (Fig. 114, A, 4), is seen to surround this depression. Within the genital ridge, at the anterior part of the cloacal fossa, a small tubercle, the **genital eminence**, appears at the same time.

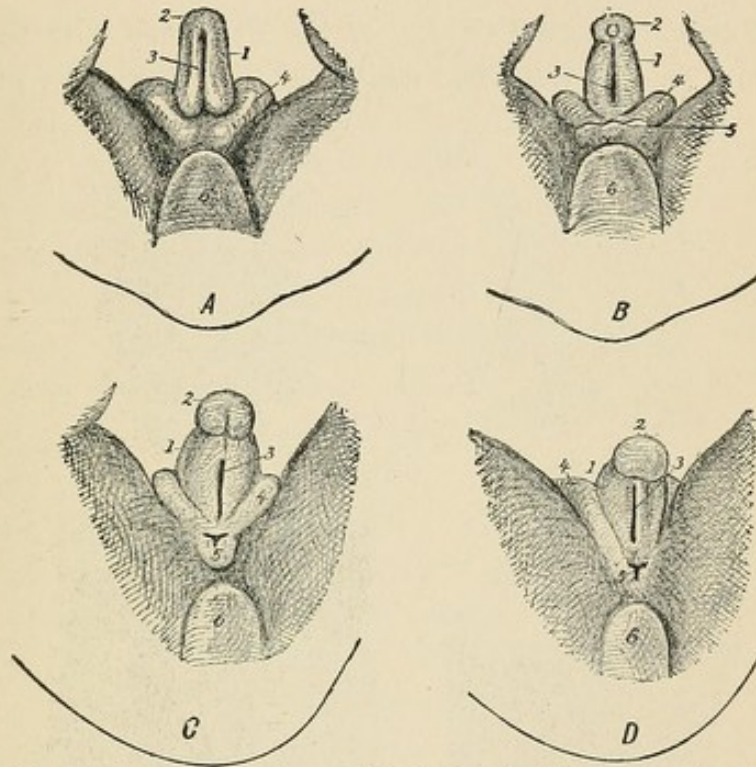


FIG. 114.—Four successive stages of development of the external genital organs (indifferent type) of the human fetus of 24 to 34 mm. (0.95 to 1.35 inch) (Tourneux): 1, genital eminence or tubercle; 2, glans; 3, genital groove; 4, genital ridge; 5, cloacal depression; 6, coccygeal eminence.

On the under aspect of the genital eminence there is soon distinguishable the **genital groove** (Fig. 114, 3), which appears as if a continuation of the fissure-like cloacal depression (5), and the groove very shortly becomes flanked by two ridges, the **genital folds**, one on each side.

The **genital eminence** becomes the **penis** or the **clitoris**, according to the sex of the fetus. It very early acquires a knob-like extremity (2) which is the beginning of the **glans penis** or of the **glans clitoridis**, as the case may be. Further development of the glans is brought about by the appearance of a partially encircling groove which serves to differentiate it from the **body** of the organ.

At this stage of development, the rudimentary organs, as

described above, are precisely alike in the two sexes. Early in the third month—about the ninth week—sexual distinctions begin to become manifest. Since the female organs exhibit the less degree of deviation from the **early indifferent form**, they will be first considered.

**The External Genital Organs of the Female.**—The sexually indifferent **genital eminence** which, as we have seen, presents

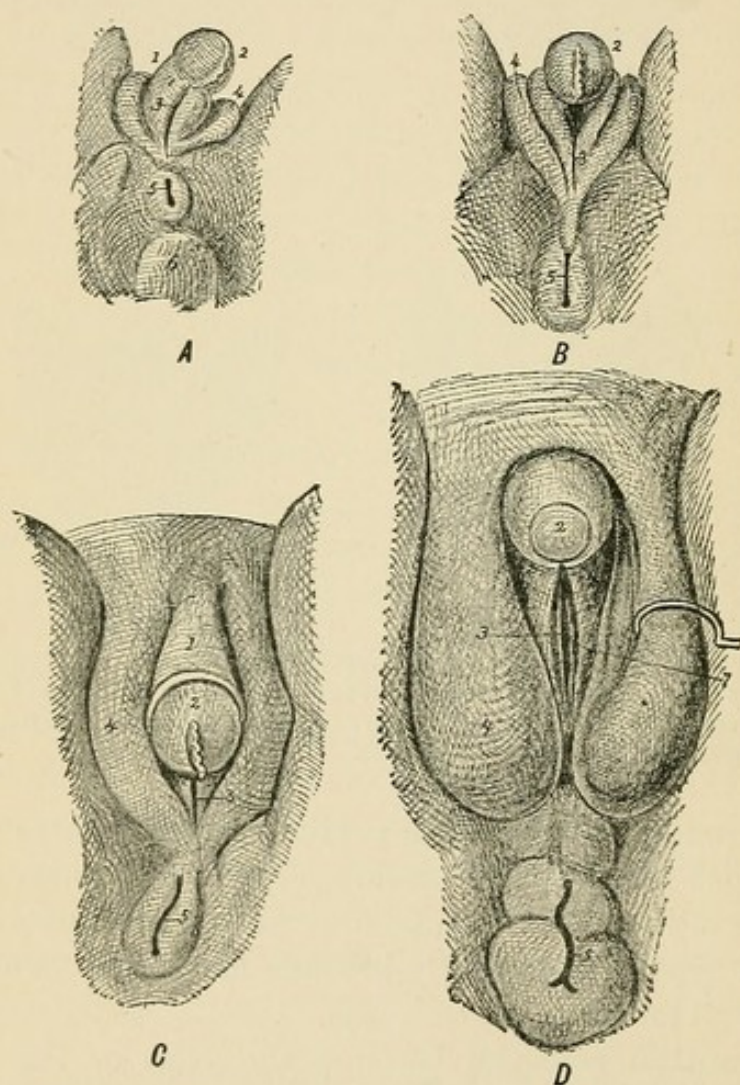


FIG. 115.—Four successive stages of development of the external genital organs of the human female fetus (Tourneux): 1, clitoris; 2, glans clitoridis; 3, urino-genital fissure; 4, labia majora; 5, anus; 6, coccygeal eminence; 7, labia minora.

even by the end of the second month a rudimentary glans and an indication of a prepuce, elongates somewhat and becomes the **clitoris**. The **genital folds** bounding the genital groove on the under surface of the genital eminence (Figs. 114 and

115, *A*) never unite with each other as they do in the male, but become prolonged in the direction of the future anus and constitute, by the fourth month, the lateral boundaries of the orifice of the urogenital sinus, or, in other words, of the **vestibule** of the vagina (Fig. 115, 3). These folds, continuous over the dorsum of the clitoris with its rudimentary prepuce, are the **nymphæ** or **labia minora** (Fig. 115, *D*, 7) of the fully-formed state. The masses of erectile tissue in close relation with each labium minus, the **pars intermedialis** and the **bulbus vestibuli**, are the homologues respectively of a lateral half of the male **corpus spongiosum** and its **bulb**. The **genital ridge**, which, from the first, encircles the genital eminence and the cloacal depression, and, consequently, the later clitoris and the aperture of the sinus urogenitalis, increases greatly in thickness. The part of it situated on the ventral side of the clitoris becomes the **mons veneris**, while the lateral parts of the ridge become the **labia majora** of the vulva. The several parts of the female genitalia develop to such a degree during the fourth month that their sexual characters at this time are well marked.

The reader is again reminded that in the stage when the cloaca is present, the Müllerian ducts terminate in the sinus urogenitalis (Plate VII.). As previously stated, the **sinus urogenitalis** becomes the **female urethra**, its terminal portion expanding into the **vestibulum vaginæ**. The openings of the Müllerian ducts fall within this latter vestibular region of the sinus. The lower portion of the two ducts by this time, however, have fused to form the uterus and the vagina, and hence is established the permanent relationship of these parts—that is, the opening of the vagina and the urethra by separate orifices into the vestibule.

The formation of the **hymen** begins in the fifth month as a little crescentic fold at the posterior margin of the aperture of the vagina.

The **glands of Bartholin** develop as evaginations of the wall of the vestibular region of the urogenital sinus.

**The Male External Genitals.**—The male external organs represent a farther stage of development than the corre-

sponding female parts. The **genital eminence** elongates rather rapidly, its length in the tenth week being 1.5 mm. The knob-like extremity becomes better marked and constitutes the **glans penis**, while the integumentary fold that partially encircles the latter assumes more distinctive character as the **prepuce**. This fold gradually advances over the glans and adheres to it, the adhesion persisting until, or shortly after, birth. All of the rudimentary penis, exclusive of the glans and of the genital folds, becomes the **corpora cavernosa** of the adult organ. The characteristic structure of the corpora

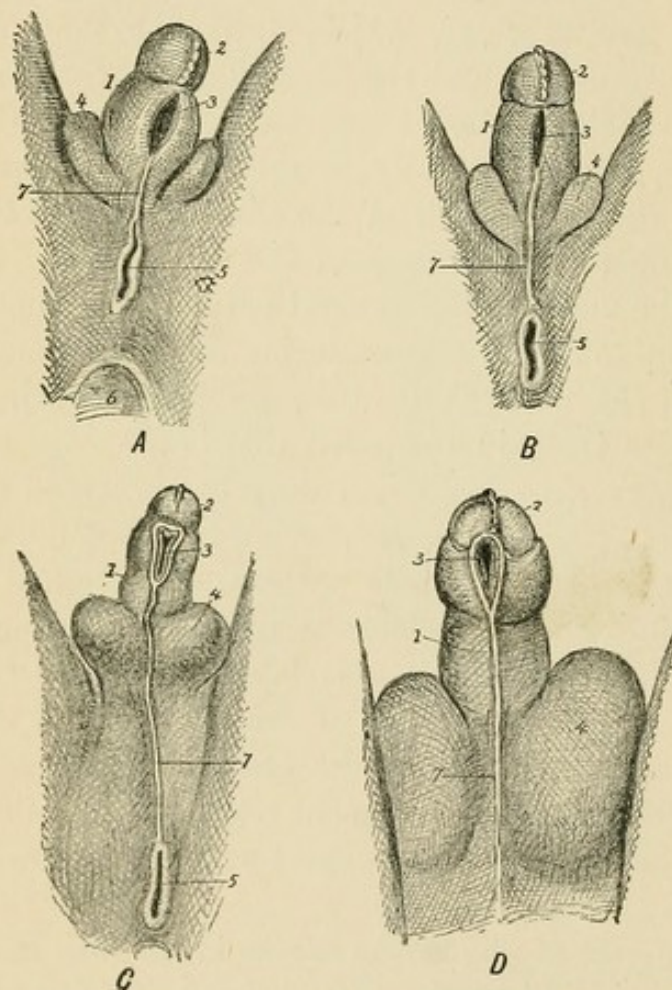


FIG. 116.—Four successive stages of development of the human male fetus (Tourneux): 1, penis; 2, glans; 3, genital groove; 4, scrotum; 5, anus; 6, coccygeal eminence; 7, perineoscrotal raphe.

cavernosa is foreshadowed as early as the third month by the appearance in the penis of capillary blood-vessels, which, in the sixth month, undergo marked dilatation.

The **groove** on the under surface of the penis becomes deeper, and the **genital folds**, which bound the groove laterally, increase in size. This groove extends from the orifice of the urogenital sinus to the glans penis. The genital folds, which in the female, remain distinct and become the nymphæ, unite with each other in the male and convert the groove into a canal, which latter is practically an extension of the urogenital sinus along the entire length of the penis to the glans. The canal thus formed is the **anterior part of the male urethra**, or, in other words, it includes all of the urethra except its prostatic portion, which represents the urogenital sinus. The orifice of this newly-formed canal, situated in the glans, is the **meatus urinarius**. Failure of union of the genital folds, either wholly or in part, results in total or in partial deficiency of the floor of the urethra, this anomaly being known as **hypospadias**. If the defective closure involves only the glans, the condition is denominated **glandular hypospadias**.

The **genital folds** form not only the sides and the floor of the penile urethra, but by an extension of their growth, also its roof, thus completely surrounding it. Upon the acquisition, by the now united genital folds, of blood-vessels and cavernous spaces, they become the **corpus spongiosum** of the penis, and thus is established the permanent or adult relation of these parts.

The **genital ridge** becomes differentiated into two prominent folds or pouches placed one on either side of the root of the penis. In the fourth month these unite to form the **scrotum**, the line of union being indicated by the **raphe**. Failure of union of the two halves of the scrotum is one of the features of certain forms of so-called **hermaphroditism**.

The **glands of Cowper**, which correspond to the glands of Bartholin of the female, are developed, like the latter, as evaginations of the terminal part of the urogenital sinus.

The accompanying tabulation exhibits a comparison of the organs of the two sexes on the basis of their common origin. Male and female parts that develop from the same fetal structure are said to be *homologous* with each other.

## HOMOLOGIES OF THE SEXUAL SYSTEM.

FETAL STRUCTURE.	FEMALE ORGANS.	MALE ORGANS.
Indifferent sexual gland.	Ovary.	Testis.
Wolffian body—		
Its <i>middle series</i> of tubules and	Short tubules of par-ovarium and	Vasa efferentia, rete testis and coni vasculosi.
Corresponding part of Wolffian duct.	Horizontal or long tube of parovarium.	Tube of epididymis.
Remainder of Wolffian duct.	Usually altogether disappears; if persistent, Gartner's duct.	Vas deferens, seminal vesicle, and ejaculatory duct.
<i>Upper series</i> of short tubules (pronephros).	Stalked hydatid of Morgagni.	Stalked hydatid of Morgagni.
<i>Lower series</i> of tubules.	Paroöphoron.	Paradidymis (organ of Giralaldès).
Duct of Müller—		
Its upper extremity.	Fimbria of oviduct.	Sessile hydatid.
Succeeding portion.	Oviduct.	Usually disappears; if persistent, duct of Rathke.
Remaining portion, by fusion with its fellow.	Uterus and vagina.	Uterus masculinus.

## EXTERNAL ORGANS.

FETAL STRUCTURE.	FEMALE ORGANS.	MALE ORGANS.
Genital eminence.	Clitoris.	Penis.
Genital folds.	Nymphæ and bulbi vestibuli.	Corpus spongiosum, enclosing spongy part of urethra.
Genital ridge.	Labia majora.	Scrotum.
Urogenital sinus.	Urethra and vestibule, Glands of Bartholin.	Prostatic urethra, membranous urethra, prostate, Cowper's glands.

## SUMMARY.

1. The male and the female internal generative organs, as well as the kidney and the ureter, originate from the mesothelial lining of the body-cavity, being directly produced from the Wolffian body and the duct of Müller.

2. The bladder and the female urethra, but in the male only the prostatic urethra, result from the metamorphosis of the intra-embryonic part of the allantois, and are therefore to be regarded as of entodermic origin.

3. Before the establishment of the permanent kidney, a

temporarily functioning organ, the mesonephros, performs the office of a kidney during a part of fetal life, and this latter is preceded by the pronephros, an organ which, though represented in the higher vertebrates by a vestigial remnant, is functionally active only in larval Amphibia and in bony fishes.

4. **The Pronephros.**—The mesothelial cells of the outer or parietal wall of the body-cavity become invaginated in a line parallel with the axis of the body, and the cord of cells thus formed becomes hollowed out to constitute the pronephric or segmental duct. At several points this duct retains its connection with the surface-cells by means of cell-cords, which latter become tubes and acquire glomeruli. The long tube and the shorter tubules with their glomeruli constitute the pronephros.

5. **The Mesonephros.**—The transverse segmentation of the middle plate, which connects the paraxial mesoderm with the parietal plate, results in the formation of a series of cell-masses, the **nephrotomes**. Each nephrotome becomes a tube and acquires one or more glomeruli. The deeper ends of the tubes become connected with the pronephric or segmental duct, which latter is known henceforth as the mesonephric or Wolffian duct. These tubes, with the adjacent part of the Wolffian duct, constitute the **mesonephros**, which functionates, for a time, even in the human fetus, as an organ of urinary excretion. The entire Wolffian duct, with the pronephric tubules and the mesonephric tubules, constitutes the Wolffian body. The Wolffian duct opens at its lower or caudal extremity into the cloaca.

6. The **metanephros** or **permanent kidney** develops from a small diverticulum that pouches out from the lower or caudal end of the Wolffian duct. The uriniferous tubules and the pelvis of the kidney correspond to the dilated and subdivided fundus of this diverticulum, while the ureter represents its stalk. The surrounding mesodermic tissue furnishes all the component elements of the ureter-walls and of the kidney except the epithelial parts, which latter, as noted above, proceed from the Wolffian body.

7. The **suprarenal bodies** probably are derived, in part, from epithelial outgrowths which proceed from the mesonephros to form the cortical part of the organ, and, in part, from chains of small cells that bud forth from the embryonic sympathetic ganglia to form its medulla. The surrounding mesodermic tissue contributes the connective-tissue parts of the suprarenal body.

8. The **sexual apparatus** in its earlier stages presents no distinctions of sex. The elements of this early indifferent type are the indifferent genital gland, the Wolffian duct, and the duct of Müller.

9. The **indifferent genital gland** originates in the mesothelium of the body-cavity. The mesothelial cells overlying the ventromesial aspect of the Wolffian body undergo multiplication in the fifth week and thereby produce an elongated elevation, the genital ridge. Further multiplication of its cells and the addition of other elements bring about the transformation of this ridge into the well-defined genital gland, which now lies in close relation with the Wolffian tubules. The mesothelial cells are the "germinal epithelium" of Waldeyer, the cells that produce the ova or the spermatozoa, according to the future sex.

10. The **duct of Müller** makes its appearance soon after the Wolffian duct. It lies parallel with and to the outer side of the Wolffian duct and also terminates in the cloaca. It is of mesodermic origin, being produced either by evagination of the mesothelial cells of the body-cavity, or by a splitting off from the Wolffian duct.

11. The **generative systems of both sexes** result from the metamorphosis of the three structures making up the early indifferent sexual apparatus—namely, the indifferent sexual gland, the Wolffian body, and the duct of Müller.

12. The **male sexual system** is produced by the transformation of the indifferent gland into the testicle, and the conversion of the Wolffian tubules and the Wolffian duct into the system of excretory ducts for that gland, the short tubules becoming the vasa efferentia and coni vasculosi, while the Wolffian duct itself furnishes the body and the globus minor

of the epididymis, the vas deferens, the vesicula seminalis, and the ejaculatory duct. The duct of Müller remains undeveloped and is represented in the adult by the atrophic sessile hydatid and the uterus masculinus.

13. The **female sexual apparatus** is brought about by the development of the indifferent gland into the ovary, and by the metamorphosis of the upper segments of the ducts of Müller into the Fallopian tubes, and the fusion of the remaining portions of the two ducts to form the uterus and the vagina. The Wolffian duct and tubules give rise to atrophic structures in the female, the most conspicuous of which is the parovarium or epoophoron.

14. Both the **male** and the **female external genitalia** are developed from fetal structures common to the two sexes, the genital eminence, the genital ridge, and the genital folds. The genital eminence is situated at the anterior or ventral part of the cloacal depression. The genital ridge is an elevation surrounding this pit and the genital eminence, while the genital folds are on the under surface of the genital eminence, one on each side of a longitudinal groove.

15. The Wolffian ducts and the ducts of Müller open into the cloaca, but when that aperture becomes differentiated into the anus and the urogenital sinus, as it does at the fourteenth week, these ducts fall to the latter apartment. The orifice of the urogenital sinus being at the base of the genital eminence, the sinus comes into continuity with the groove on the under surface of the eminence.

16. The **female external genitalia** are produced by the further development of the three structures mentioned above. The genital eminence becomes the clitoris. The genital folds on the under surface of the clitoris become somewhat prolonged to constitute the labia minora. The genital ridge becomes, anteriorly, the mons veneris and laterally the labia majora. The orifice of the urogenital sinus is represented by the vestibule, and since the Müllerian ducts near their termination in the urogenital sinus fuse to form the vagina, the latter passage opens in the adult into the vestibule. Since, also, the urogenital sinus receives the termination of the

allantois, which becomes the female urethra, the latter canal likewise opens into the adult vestibule.

17. The **male external genitals** represent a further development of the embryonic genital eminence, genital folds, and genital ridge than do the female organs. The genital eminence becomes the penis, the genital folds, uniting with each other so as to surround the groove, producing the corpus spongiosum. The groove itself, being thus converted into a canal which extends the now closed urogenital sinus to the end of the penis, constitutes all of the male urethra except the first or prostatic portion. The prostatic urethra represents the proximal extremity of the allantois. Since the Wolffian ducts open into the urogenital sinus after the division of the cloaca, the terminations of those ducts, represented now by the ejaculatory ducts, open into the prostatic urethra; and since the Müllerian ducts also open into the urogenital sinus, the uterus masculinus, which is the representative in the male of the terminal parts of the Müllerian ducts, is found likewise in the prostatic urethra. The lateral parts of the genital ridge, which, in the female, become the labia majora, fuse with each other in the male to form the scrotum.

18. The condition of so-called **hermaphroditism** may be produced either by an unusual degree of development of the female external genitals, resulting in a clitoris resembling a penis and in labia majora which simulate a cleft scrotum; or by the arrested development of male organs, whereby the genital folds and the genital ridges fail to unite, the urethra in consequence opening at the base of the penis.

## CHAPTER XIV.

### THE DEVELOPMENT OF THE SKIN AND ITS APPENDAGES.

THE appendages of the skin include the **sebaceous** and **sweat glands**, the **mammary glands**, the **nails**, and the **hairs**.

#### THE SKIN.

The **skin**, consisting of the **epidermis** or **cuticle** and of the true skin, or **derm**, or **corium**, is derived from two sources, the epithelial **epidermis** being a product of the **ectoderm**, and the **corium** originating from the **mesoderm**. The **nails** and **hairs** are outgrowths of the epithelial layer, while the various glands are derived from infoldings or invaginations of the same stratum.

The **corium**, the connective-tissue component of the skin, is an outgrowth of the **cutis plates** of the primitive segments or somites (Fig. 117). It first appears in crude form in the second month as a layer of spindle-cells beneath the **ectoderm**. In the third month, the more superficial part of this layer acquires more definite and distinctive character, the rather loose aggregation of cells having differentiated into a tissue which is a mesh-work of bundles of

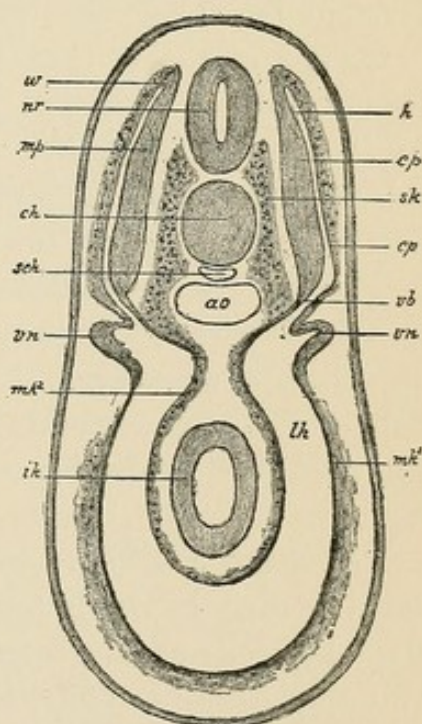


FIG. 117.—Cross-section through the region of the pronephros of a selachian embryo in which the myotomes are in process of being constricted off (Hertwig): *nr*, neural tube; *ch*, chorda; *ao*, aorta; *mp*, muscle-plate; *cp*, cutis plate; *vb*, middle plate; *sk*, skeletogenous tissue; *vn*, pronephros; *mk'*, *mk*<sup>2</sup>, parietal and visceral mesoderm; *lh*, body-cavity; *ik*, intestinal ectoderm; *h*, cavity of somite.

white fibrous connective tissue with some intermingled elastic and muscular fibers ; this constitutes the corium proper. The deeper layer of cells becomes a loose, subcutaneous areolar tissue containing a few scattered fat-cells. About a month later the external surface of the primitive corium loses its smooth character and presents numerous little elevations, the villi, which project into the overlying epidermis. The villi, being highly vascular, play an important part in the nutrition of the epidermis and being also freely supplied with nerves they sustain an equally important relation to the sensitiveness of the skin.

From the middle of fetal life onward, the fat-cells in the subcutaneous tissue increase in number to such extent that there is formed a continuous and well-marked subcutaneous layer of fat, the **panniculus adiposus**.

Certain of the cells of the primitive corium differentiate into unstriated muscular tissue, forming thus the muscles of the hair-follicles, the **arrectores pilorum**, as well as the **subcutaneous muscular tissue** of the dartos of the scrotum and penis, and that of the nipple and of the perineum.

The **epidermis**, consisting of the superficial horny layer and the deeper mucous layer or stratum Malpighii, is entirely an epithelial structure. Its elements are simply the descendants of the early ectodermic cells specially modified to afford the necessary protection to the more sensitive and delicate corium.

The **division into the two strata of the epidermis** is indicated as early as the latter part of the first month, at which time the cells of the ectoderm have become arranged into two single layers, a superficial layer of rather large flattened cells and an underlying stratum of smaller elements. The cells of the outer layer, or **epitrichium**, which probably represents the future stratum corneum, successively undergo degeneration and desquamation, the places of those lost being supplied by the formation of new ones from the deeper layer. As time goes on, both layers increase in thickness and the hairs and the glands of the skin are gradually formed. With increased proliferation there is increasingly

active desquamation of superficial cells, and as the degenerate and cast-off cells become mixed with the products of the sebaceous glands, there is formed a sort of cheesy coating of the skin, the **vernix caseosa** or **smegma embryonum**. This is first easily recognizable in the sixth month, and first covers the entire surface of the body in the eighth month. It serves to protect the epidermis of the fetus from maceration in the amniotic fluid.

The completion of the epidermis, aside from the development of its accessory parts, consists simply in further increase in thickness and in the modification of the superficial cells to produce the characteristic scale-like elements of the **corneous layer** of the skin, accompanied by the differentiation of the deeper cells into those of the **rete mucosum** or **stratum Malpighii**. The extent to which these modifications are carried varies in different regions of the body.

#### THE DEVELOPMENT OF THE APPENDAGES OF THE SKIN.

**The Nails.**—The nails have their beginning in little claw-like projections, the **primitive nails**, that appear upon the tips of the still imperfect fingers and toes in the seventh week.<sup>1</sup> These result from localized proliferation of the cells of the epidermis, being entirely epithelial structures. The rudimentary nails project from the tips of the digits, instead of occupying the dorsal position of the completed structures.

The claw-like primitive nail, between the ninth and twelfth weeks, becomes surrounded by a **groove**, which serves to separate it from the general ectodermic surface. These claw-like rudiments of the human nails are quite similar to the primitive claws of many mammals, the primitive nail in each case including a dorsal part, the **nail-plate**, and a portion which belongs to the ventral surface of the digit, called the **plantar horn** (Fig. 118). The striking difference between the nails of the human adult and the claws and

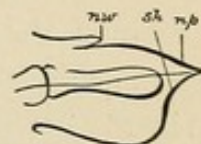


FIG. 118.—Longitudinal section through the toe of a *Ceropithecus*<sup>2</sup> (after Gegenbaur): *np*, nail-plate; *sh*, plantar horn (Sohlenhorn); *nw*, nail-wall.

<sup>1</sup> Or ninth week, Minot.

<sup>2</sup> A genus of long-tailed African monkeys.

hoofs of many animals is due in great measure to the degree of development to which this ventrally situated plantar horn attains. In the hoofed mammals (Ungulata) and the clawed mammals (Unguiculata), the plantar horn undergoes very great development, whereas in man it retrogrades and leaves no trace except the **nail-welt**, or the narrow line of thickened epidermis where the distal end of the **nail-bed** merges into the ordinary skin. After the atrophy of the plantar horn, the dorsally situated nail-plate being alone present, the rudimentary nail bears a greater resemblance to the adult condition.

As the nail-plate gradually acquires more distinctive character, the deeper layers of the skin specialize into a structure adapted to its nutrition. This is the **nail-bed**, a highly vascular and sensitive cushion consisting of the corium and of the stratum Malpighii of the epidermis. It is especially from the proximal part of the nail-bed, representing the **matrix** of the fully-formed condition, that the nail grows. The rate of growth is such that the ends of the nails protrude beyond the tips of the digits in the eighth month.

The **tissue of the fully-formed nail** corresponds to the **stratum lucidum** of the typical epidermis, developed to an unusual degree. The **epitrichium** or future **stratum corneum**, the most superficial layer of the epidermis, does not form a part of the nail, but constitutes a thin covering, the **eponychium**; this is lost in the seventh month, with the exception of a small band over the root of the nail, which persists for a short time as the **perionyx**.

The **nails of the toes** are always somewhat behind those of the fingers in development.

To repeat, the claw-like rudimentary nails appear in the seventh week, the nails are perfectly formed about the twelfth week, and break through their epidermal covering in the seventh month, reaching to or beyond the finger-tips in the eighth month.

**The Hair.**—Each hair consists of the projecting **shaft** and the embedded **root**, with its expanded deep extremity, the **hair-bulb**, the root being embraced by the **hair-follicle**. The

hair is entirely of ectodermic origin, being derived from the epidermal layer of the skin, while the hair-follicle is partly derived from the epidermis and in part is a product of the corium. The hairs are homologous with the feathers and scales of the lower animals.

The development of the hair is initiated in the third fetal month by the appearance of small solid masses of epithelium in the stratum Malpighii of the epidermis. The epithelial plugs or hair-germs grow into the underlying corium and are met by outgrowths or papillæ of the latter, which develop almost simultaneously. The papillæ are very vascular and serve for the nutrition of the developing hair.

The root and the shaft of the rudimentary hair result from the specialization of the axial or central cells of the hair-germ. These cells lengthen in the direction of the long axis of the hair-germ and become hard and corneous, thus constituting the root and the shaft, the cells of the deepest part of the hair-germ forming the bulb. The growth of the hair

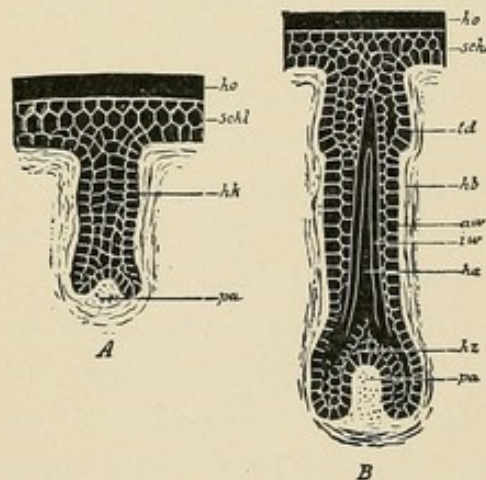


FIG. 119.—Two diagrams of the development of the hair (Hertwig): *A* and *B*, two different stages of the development of the hair in human embryos; *ho*, cornuous layer of the epidermis; *schl*, mucous layer; *pa*, hair-papilla; *hk*, germ of hair; *hz*, bulb of hair; *ha*, young hair; *aw*, *iw*, outer and inner sheaths of the root of the hair; *hb*, hair-follicle; *td*, sebaceous gland.

in length is due to the proliferation and specialization of the cells of the bulb. The papilla of the underlying corium indents the deep surface of the hair-bulb, this close relation of the two structures enabling the papilla the better to fulfil its function of providing nourishment to the bulb.

The **hair-follicle**, consisting of an outer connective-tissue portion or **fibrous layer** and an inner epithelial part, the **inner and outer root-sheaths**, is partly of mesodermic and partly of ectodermic origin. The inner and outer root-sheaths are produced by the peripheral cells of the hair-germ augmented by cells contributed directly by the stratum Malpighii of the epidermis. The outer fibrous constituent of the follicle results from the mesodermic cells of the corium that immediately surround the hair-germ.

Gradually increasing in length by the addition of new cells from the hair-bulb, the primitive hair at length protrudes from the follicle as **free hair**. This first growth of hair is unpigmented and is extremely fine and soft, being known as the **lanugo** or **embryonal down**. This appears upon the scalp and some other parts of the body in the fourth month, gradually extending over the entire surface in the succeeding months. In the eighth month the lanugo begins to disappear, but is not lost as a whole until after birth, when the **permanent growth** of hair takes its place. Upon the face, in fact, the lanugo persists throughout life.

The development of the **secondary hair** is still a disputed point. It is claimed by some authorities (Stieda, Feiertag) that they develop from entirely new hair-germs, while others (*e. g.*, Hertwig) hold that the bulb for the new hair buds off from the atrophic bulb of the hair just lost.

**The Sebaceous and Sweat-glands.**—The sweat-glands, including not only the sweat-glands proper but the **ceruminous glands** of the external auditory meatus and the **glands of Moll** of the eyelids, are derived from the ectodermic epithelium. The glands are of the simple tubular type. Each gland develops from a small accumulation of epidermal cells that grows, in the fifth month, from the Malpighian or mucous layer of the epidermis into the underlying corium. The solid epithelial plugs become tubes in the seventh month by the degeneration and final disappearance of the central cells. The deeper part of the tube becomes coiled and its lining epithelium takes on the characteristics of secreting cells. Some of the cells of the original epithelial plug undergo

specialization into **muscular tissue**, thus producing the **involuntary muscles** of the sweat-glands.

The **sebaceous glands** are developed from solid epithelial processes that originate from the deep layer or rete mucosum of the epidermis in a manner similar to that of the development of the sweat-glands. There is the difference, however, that the epithelial plugs acquire lateral branches and thus usually produce glands of the compound saccular or acinous variety. There is the further difference that the epithelial outgrowths generally develop from the ectodermic cells of the outer sheath of the root of the hair near the orifice of the follicle (Fig. 119, *td*), in consequence of which the ducts of the finished glands usually open into the hair-follicles. In some regions, however—regions devoid of hair, as the prepuce and the glans penis, the labia minora, and the lips—the growth is directly from the stratum Malpighii, as in the case of the sweat-glands.

**The Mammary Gland.**—The mammary gland represents a number of highly specialized sebaceous glands so associated as to constitute the single adult structure. Its origin, therefore, is to be sought in the cells of the epidermis in common with that of the ordinary sebaceous glands.

The development of the milk-glands is begun as early as the second month. At this time the deep layer of the epidermis, in the sites of the future glands, becomes thickened by the multiplication of its cells, the thickened patch encroaching upon the underlying corium (Fig. 120, *A*, *b*). This thickened area enlarges somewhat peripherally and its margins become elevated, owing to which latter circumstance the patch appears relatively depressed (*B*). The depression is known as the **glandular area**, and it corresponds with the **future areola and nipple**.

From the bottom of the glandular area, numerous small masses or **bud-like processes of cells** grow down into the corium. Some of the buds acquire lateral branches. By the hollowing out of these cell-buds the latter are transformed into **tubes** (*c*), which open upon the glandular area. The branching of the cords begins in the seventh month and is carried

on to such a degree that each original cell-cord gives rise to a **tubo-racemose gland**. The hollowing out of the solid processes begins shortly before birth, but is not completed until after that event. Each cell-cord becomes, in the strict sense, a **complete gland**, each such individual structure forming a **lobe** of the mature organ.

This stage of the human mammary gland—that is, a depressed gland-area upon which open individual glands, the

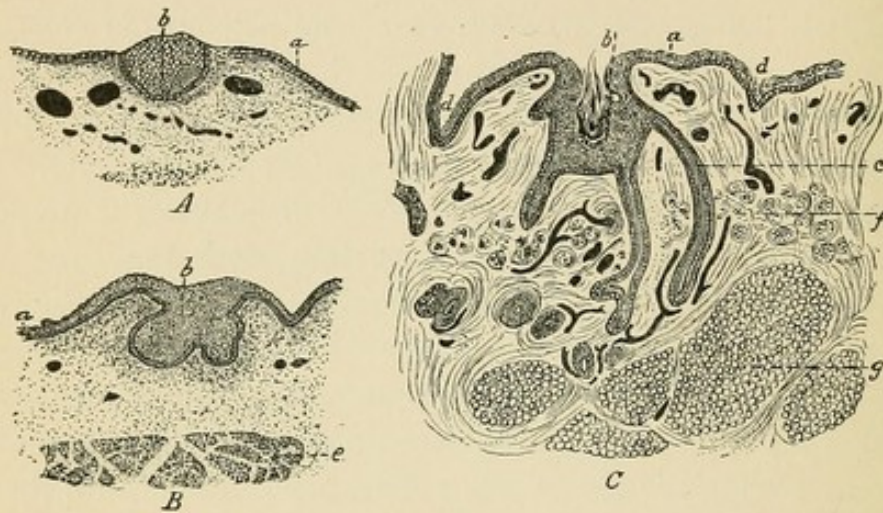


FIG. 120.—Sections representing three successive stages of development of the human mamma (Tourneux): *A*, fetus of 32.40 mm. (1.3 in.); *B*, of 10.16 cm. (4 in.); *C*, of 24.35 cm. (9.6 in.); *a*, epidermis; *b*, aggregation of epidermal cells forming anlage of gland; *c*, galactophorous ducts; *d*, groove limiting glandular area; *e*, great pectoral muscle; *f*, unstriated muscular tissue of areola; *g*, subcutaneous adipose tissue.

nipple being absent—is the permanent condition in some of the lowest mammals, as in the echidna, one of the monotremes. In all higher mammals, however, further metamorphoses occur in the tissues of the glandular area, and in the human fetus these tissues become the **nipple** and the surrounding **areola**.

The **nipple** is partly formed before birth, but does not become protuberant until post-fetal life. The depressed glandular area rises to the level of the surrounding parts, and its central region, which includes the orifices of the already formed or just forming ducts, swells out into a little prominence, the nipple. This prominence is a protrusion of the epidermis and includes the terminal extremities of the

milk-ducts as well as the blood-vessels and connective-tissue elements which surround the ducts. In the dermal constituent of the rudimentary nipple **unstriated muscular** tissue develops. The region of the glandular area not concerned in the formation of the nipple becomes the **areola**.

**At birth**, as above intimated, the mammary gland is still rudimentary, since many of the ducts have not yet acquired their lumina nor their full degree of complexity. Shortly after birth a small quantity of milky secretion, the so-called **witches' milk**, may be expressed from the glands—in the male and female infant alike. This is true milk according to Rein and Barfruth, but according to Kölliker, it is merely a milky fluid containing the débris of the degenerated central cells of those rudimentary ducts that were still solid at birth.

So far, the milk-glands are alike in the two sexes, but while in the male they remain rudimentary structures, they continue to increase both in size and in complexity in the female. The increase affects not only the glandular tissue proper but the connective-tissue stroma as well. At the time of **puberty** the growth of the glands receives a new impetus, which is very materially augmented upon the occurrence of **pregnancy**. There may be said, therefore, to be several distinct phases in the development of the milk-glands, first, the **embryonic stage**; second, the **infantile stage**; third, the **stage of maturity** beginning at the time of puberty; and finally, the stage of **full functional maturity** consequent upon pregnancy and parturition.

## CHAPTER XV.

### THE DEVELOPMENT OF THE NERVOUS SYSTEM.

THE nervous system of the adult, including the **cerebro-spinal axis and nerves**, and the **sympathetic system of ganglia and nerves**, is made up of the essential neural elements, the **neurons**, together with the supporting framework or **stroma**.<sup>1</sup>

The **neurons** and a **part of the stroma** result from the specialization of the **ectodermic layer** of the embryo. The ectodermic origin of the nervous system acquires certain interest in view of the conditions that obtain in some of the lowest and simplest organisms. For example, in the ameba, the single protoplasmic cell which constitutes the entire individual possesses the several fundamental vital properties of protoplasm, such as respiration, metabolism, contractility, motility, etc., in equal degree, no single property being more highly developed than the others, and no particular part of the cell exhibiting greater specialization than the other parts. In other words, the protoplasmic substance of the animal is at once a respiratory mechanism, a nervous apparatus, and an organ for the execution of the various other vital functions.

In somewhat more highly developed creatures, as the infusoria, although there is no differentiation into separate tissues and probably not even into separate cells, there is seen some progress toward the specialization of certain parts of the organism for the performance respectively of the different functions of life. For example, the central part of the ani-

<sup>1</sup> The *neurons* are the units of which the nervous system is made up. Each neuron consists of a nerve-cell with everything belonging to it—that is, with its various processes, including the *axis-cylinder process* or *neurite*, which becomes the axis-cylinder of a nerve-fiber.

mal has digestive functions, while it is by the superficial portion alone that the creature is brought into relation with the outside world, the sensitiveness or irritability of the surface, by which the animal is made responsive to external impressions, being the nearest approach to the function of a nervous system that it possesses.

This primitive function of the surface of the organism is suggestive as to the origin of the nervous system of higher type creatures. It will be seen, indeed, that not only is the nervous system proper derived from the ectodermic cells of the embryo but that the peripheral parts of the organs of special sense, as the **olfactory epithelium**, the **organ of Corti**, and the **retina**, have the same origin.

The alteration of those cells of the ectodermic stratum that are to specialize into nervous elements begins prior to the fourteenth day in the human embryo, in the stage of the blastodermic vesicle. The change consists in a gradual modification of the form of the cells, the cells common to the general surface of the germ assuming the columnar type. The process affects the cells of the median line of the embryonic area in advance of the primitive streak, resulting in the production of a thickened longitudinal median zone. This thickened area is the **medullary plate** (Fig. 32, p. 62). On each side of the plate—which is apparent at the fourteenth day—the adjoining ectodermic cells become heaped up to form the **medullary folds**, which latter therefore bound the medullary plate laterally. The medullary plate becomes concave on the surface, forming the **medullary groove** (Fig. 121). By the deepening of the groove, the lateral edges of the plate approach each other (Fig. 122), and finally they meet and unite, thus producing a tube, the **neural tube or canal**.

Since the medullary folds similarly meet and unite with each other—their union slightly preceding that of the edges of the plate—the neural tube comes to lie entirely beneath the surface-ectoderm and soon loses all connection with it. The closing of the tube and the union of the medullary folds occur first near the anterior end of the embryonic area, in a position that corresponds with the region of the future neck,

and from this point it proceeds both cephalad and caudad. Since the medullary folds at their caudal extremity embrace

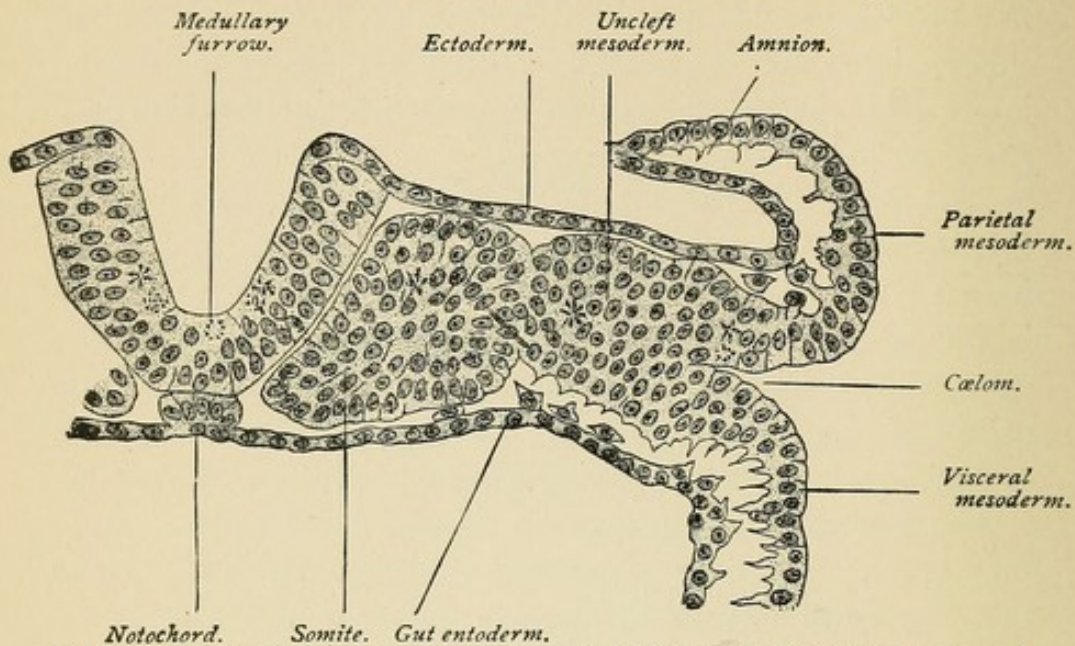


FIG. 121.—Transverse section of a sixteen-and-a-half-day sheep embryo possessing six somites (Bonnet).

the primitive streak (Fig. 32, p. 62), the latter structure is included within the caudal end of the neural tube by the

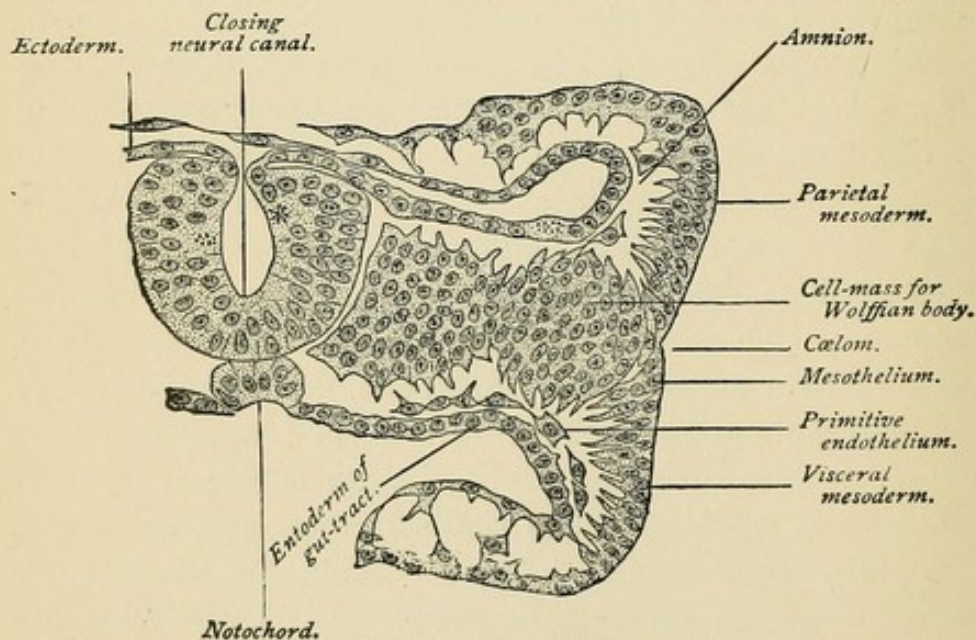


FIG. 122.—Transverse section of a fifteen-and-a-half-day sheep embryo possessing seven somites (Bonnet).

coming together of the folds, and thus the blastopore, which was previously the external aperture of the archenteron,

comes to constitute the **neurenteric canal**, or an avenue of communication between the neural canal and the primitive intestine.

The **neural canal** then is a tube composed of columnar cells, which is formed by the folding in of the ectoderm and which occupies the median longitudinal axis of the embryonic area and consequently of the future embryonic body. *From this simple epithelial canal the entire adult nervous system is evolved.*

The evolution of the highly complex cerebrospinal axis from such a simple structure as the neural canal is referable both to the principle of *unequal growth*—the walls of the tube becoming thickened by the multiplication of the cells—and to the *formation of folds*.

The portion of the neural canal—approximately one-half—that is devoted to the formation of the brain is delimited from the part that produces the spinal cord by the dilatation of the anterior or head-end of the tube, and the subsequent division of this dilated sac-like portion into three communicating sacs called respectively the **fore-brain**, **mid-brain**, and **hind-brain vesicles** (Fig. 126). These three vesicles give rise to the brain, while the remaining part of the neural canal forms the spinal cord.

#### THE DEVELOPMENT OF THE SPINAL CORD.

In the growth of the spinal cord from the spinal portion of the neural canal we have to consider the evolution of a cylindrical mass of nerve-cells and nerve-fibers with the supporting stroma from a simple epithelial tube.

The wall of the neural tube, although consisting at first of a single layer of epithelial cells, is not of uniform thickness throughout its circumference. While the external outline is oval, the lumen of the tube is a narrow dorsoventral fissure (Fig. 36, p. 65). The cavity is therefore bounded on the sides by thickened lateral columns, while the dorsal and ventral walls, which connect the lateral columns with each other, are thinner and are called respectively the **roof-plate** and the **floor-plate**.

After a short time, the walls of the tube having thickened by the multiplication of the cells, the shape of the lumen

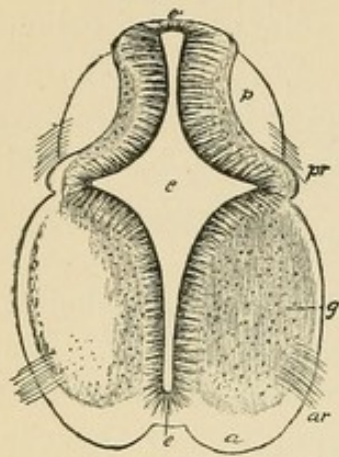


FIG. 123.—Transverse section of the cervical part of the spinal cord of a human embryo of six weeks,  $\times 36$  (from Kölliker): *c*, central canal; *e*, its epithelial lining; *at e'* (superiorly), the original place of closure of the canal; *a*, the white substance of the anterior columns; *g*, gray substance of anterolateral horn; *p*, posterior column; *ar*, anterior roots; *pr*, posterior roots.

alters, two laterally projecting angles being added (Fig. 123). The effect of this change is to partially divide each lateral half into a dorsal and a ventral region. The neural canal at this stage may be said to consist of six columns of cells, the **two dorsal zones** connected with each other by the **roof-plate**, and the **two ventral zones** united by the **floor-plate**. These regions are also distinguishable, with certain characteristic modifications, in the head-region of the tube. They are important in their bearing upon the further development of the structure, since the dorsal and ventral

zones are related respectively to the dorsal or sensory and the ventral or motor roots of the spinal nerves.

The differentiation of the cells of the neural tube into two kinds of elements, one of which gives rise to sustentative tissue or **neuroglia** while the other produces the **nerve-cells**, is observed at about the end of the third week. The single layer of columnar cells which at first composes the wall of the tube, the long axes of the cells being radially arranged, soon exhibits near the lumen a row of **round cells**, probably the first offspring of the columnar cells. The round cells are the **germ-cells** or **germinating cells**, from which are developed the **neuroblasts** or young nerve-cells. All the other cells, known as the **spongioblasts**, are concerned in producing sustentative tissue.

The **stroma** of the central nervous system includes two constituents—a **connective-tissue element**, and a part, the **neuroglia**, which is of epithelial origin, and which is not to

be regarded, therefore, as connective tissue. The connective-tissue portion of the stroma is produced by the ingrowth of the **pial processes** from the pia mater, and is hence of **mesodermic** origin.

The **neuroglia** is derived from the spongioblasts, which result from the specialization of the **large columnar cells** of which the wall of the neural canal is composed. These cells, whose length comprises the entire thickness of the wall of the tube in the earliest stages, undergo partial absorption and disintegration, each cell being transformed into an elongated system of slender processes or trabeculæ, and each such system being a completed **spongioblast** (Fig. 124). The inner ends of

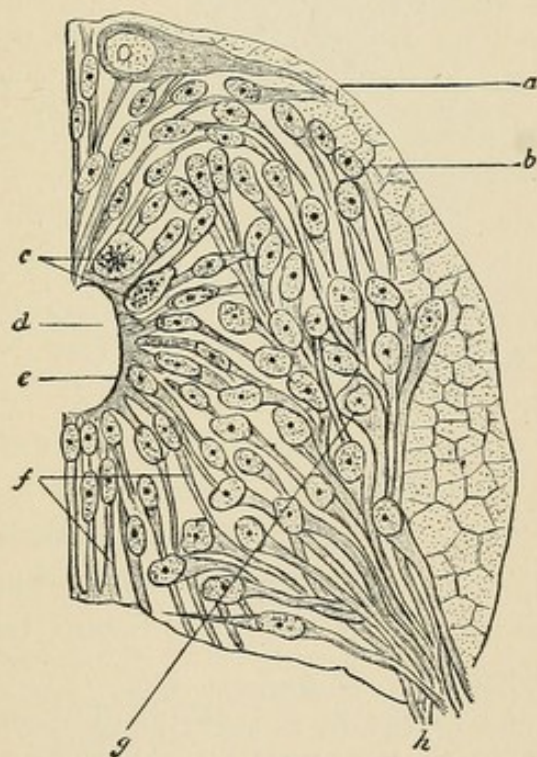


FIG. 124.—Cross-section through the spinal cord of a vertebrate embryo (after His): *a*, outer limiting membrane; *b*, outer neuroglia layer, region of future white matter; *c*, germ-cells; *d*, central canal; *e*, inner limiting membrane or ependymal layer; *f*, spongioblasts; *g*, neuroblasts (mantle layer); *h*, anterior root-fibers.

the spongioblasts coalesce with each other, forming thus the **internal limiting membrane**, while the peripheral extremities interlace with each other to form a close network. As the walls of the neural tube increase in thickness, the spongioblasts become more and more broken up to form the delicate

neuroglial network with interspersed nucleated glia cells. Such of the spongioblasts as border the cavity of the neural tube become the cells of the later **ependyma** of the **central canal** of the spinal cord and of the **ventricles** of the brain. The cells of the ependyma become **ciliated** in the human fetus in the fifth week.

The **nerve-cells** of the spinal cord—as also of the brain—are the specialized descendants of the **germ-cells** referred to above. The proliferation of the germ-cells produces the **neuroblasts**, or young nerve-cells (Fig. 124). The latter elements move away from the primitive position of the germ-cells near the lumen of the tube and develop into the nerve-cells. The transition is effected by the accumulation of the cell's protoplasm on the distal side of the nucleus and its elongation into a process. This process is a **neurite** or **axis-cylinder process** and is the beginning of a nerve-fiber. The **dendrites** or **protoplasmic processes** appear considerably later. Some of the fibers thus produced grow out from the neural tube to constitute the efferent fibers of the peripheral nerves, while others contribute to the formation of the fiber-tracts of the cord.

After the appearance of the neuroblasts and developing nerve-cells, the wall of the neural tube is divisible into three layers (Fig. 124); an inner or **ependymal layer**, next the lumen of the tube; adjoining this, the **mantle layer**, made up of neuroblasts; and a peripherally situated **neuroglia layer**, which occupies the position of the future tracts of white fibers of the cord.

The alterations in the form and size of the spinal cord go hand in hand with the histological changes noted above. While those areas that have been mentioned as the dorsal and ventral zones increase greatly in thickness, the floor-plate and the roof-plate—the ventral and dorsal walls of the neural tube—remain thin (Fig. 125). They are never invaded by the nerve-cells but consist of thin layers of neuroglia which later become penetrated by nerve-fibers that grow from one side to the other. They thus represent the **anterior** and **posterior white commissures** of the cord. These plates remain

relatively fixed in position because of their failure to expand, while the lateral walls of the tube undergo great expansion, in both the ventral and dorsal directions, as well as laterally. In this way a median longitudinal cleft is produced on the ventral wall of the spinal cord and a similar one on the dorsal wall. These are the **anterior** and **posterior median fissures**. Since the so-called posterior median fissure is not a true fissure but merely a septum, it differs from the anterior fissure, and it is held by some authorities that this septum is

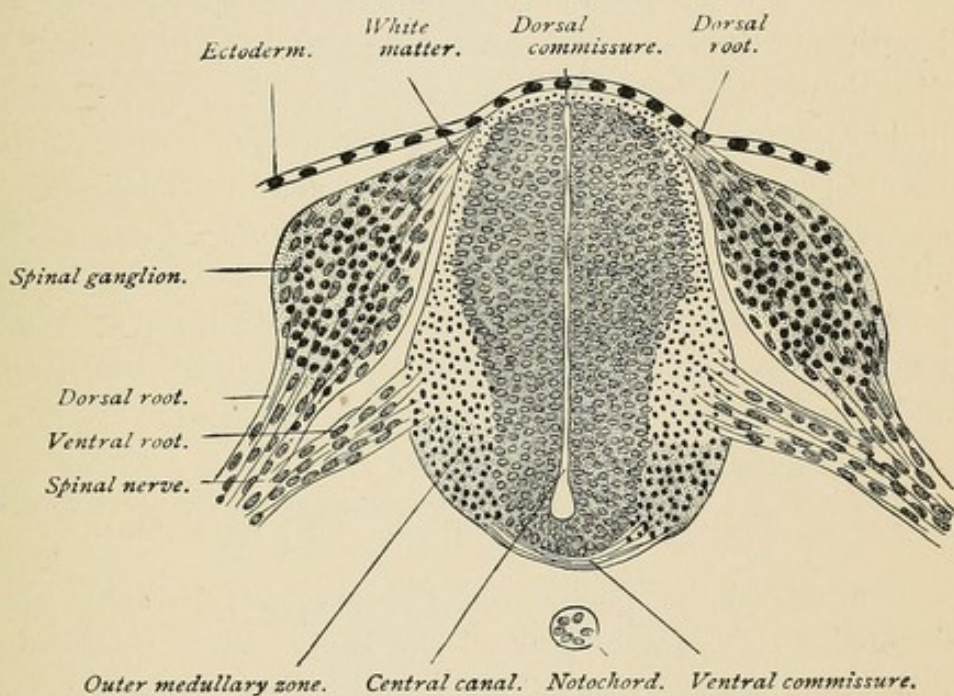


FIG. 125.—Transverse section of developing spinal cord of a twenty-two-day sheep-embryo (Bonnet).

formed by the growing together of the walls of the dorsal part of the central canal.

The **fiber-tracts** or **white matter** of the spinal cord develop in the outer or neuroglia layer, each fiber being the elongated neurite of a nerve-cell. Some of the fibers originate from the nerve-cells of the cord while others grow into the cord from the ganglia of the posterior roots of the spinal nerves. The latter method of origin applies especially to the fibers of the tracts of Burdach and of Goll.

As the walls of the neural canal thicken through the multiplication of the cells, the cavity of the tube is gradually

encroached upon almost to obliteration. When development is complete, all that remains of the cavity is the **small central canal** of the spinal cord.

The **length of the spinal cord** in the fourth fetal month corresponds with that of the spinal column, its lower termination being opposite the last coccygeal vertebra. From this time forward, however, the cord grows less rapidly than does the spinal column, so that at birth, the cord terminates at the last lumbar vertebra, and in adult life at the second lumbar vertebra. This gradually acquired disproportion in the length of the two structures explains the more oblique direction of the lower spinal nerves as compared with those higher up. In the early condition of the cord, each pair of nerves passes almost horizontally outward to the corresponding intervertebral foramina, but as the spinal column gradually outstrips the cord in growth, the lower nerves necessarily pursue a successively more oblique course to reach their foramina, the lower nerves being almost vertical in direction and constituting, collectively, the **cauda equina**.

#### THE DEVELOPMENT OF THE BRAIN.

The encephalic portion of the neural tube—that part devoted to the production of the brain—after undergoing dilatation, becomes marked off into the three primary brain-vesicles, the **fore-brain**, the **mid-brain** and the **hind-brain**, by constrictions in the lateral walls of the tube (Fig. 126). This division occurs at an early stage, before the closure of the tube is everywhere complete. The vesicles communicate with each other by rather wide openings. As in the spinal part of the neural canal, the walls of the primary brain-vesicles consist of epithelial cells, and *it is by the multiplication of these cells in unequal degree in different regions, and by the formation of folds in certain localities* that the various parts of the adult brain are developed from these simple epithelial sacs.

The **stage of three vesicles** is soon succeeded by the **five-vesicle stage**, the primary fore-brain vesicle undergoing divi-

sion into two, the **secondary fore-brain** and the **inter-brain**, and the primary hind-brain vesicle likewise dividing, a little later, into the **secondary hind-brain** and the **after-brain**.

The division of the primary fore-brain is preceded by the appearance upon each of its lateral walls of a small bulged-out area which soon assumes the form of a distinct diverticulum. This is the **optic vesicle**, the earliest indication of the development of the eye (Fig. 126). In the further process of growth the base of attachment of the optic vesicle becomes lengthened out into a relatively slender pedicle, which remains in connection with the lower part of the lateral wall of the brain-vesicle. Following the appearance of the optic vesicle, the anterior wall of the primary fore-brain vesicle

projects as a small evagination, which latter is then distinctly marked off from the parent vesicle by a groove on either side. This anterior diverticulum is the **secondary fore-brain vesicle** or the vesicle of the cerebrum, and the original or primary fore-brain vesicle is now the **vesicle of the inter-brain**.

The division of the primary hind-brain is effected by the development of a constriction of its lateral wall, this resulting in the production of the **secondary hind-brain** or the vesicle of the cerebellum, and the **after-brain** or the vesicle of the medulla oblongata.

While the three primary vesicles at first lie in the same straight line, they begin to alter their relative positions shortly before division. The change of position is coincident with the flexures of the body of the embryo that occur at this time. Three well-marked **flexures** appear, the result being

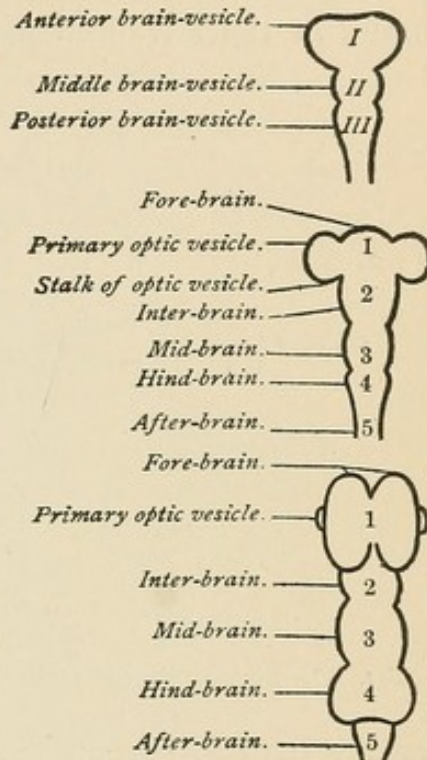


FIG. 126.—Diagrams illustrating the primary and secondary segmentation of the brain-tube (Bonnet).

that the fore-brain is bent over ventrad to a marked degree. The most anterior of these flexures, and the first to develop, is the so-called **cephalic flexure** (Fig. 127), the primary fore-brain, in the advanced state of the curvature, being bent

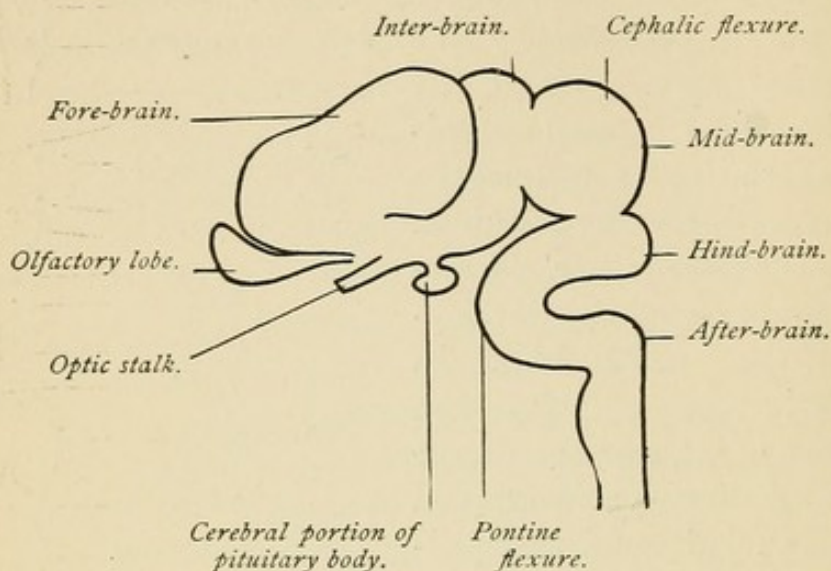


FIG. 127.—Diagram showing relations of brain-vesicles and flexures (Bonnet).

around the termination of the chorda dorsalis so as to form a right angle, and later, after its division, an acute angle with the floor of the mid-brain. This curvature makes the mid-brain very prominent as regards the surface of the embryonic body, producing the **parietal elevation** or the **prominence of mid-brain**.

In the region of the future pons Varolii, on the floor or ventral wall of the secondary hind-brain, is a second well-marked angularity. This is the **pontal flexure**. Its convexity projects forward.

A third bend, the **nuchal flexure**, is a less pronounced curvature at the juncture of the after-brain with the spinal part of the neural tube.

#### **The Metamorphosis of the Fifth Brain-vesicle.—**

The fifth brain-vesicle, the caudal division of the primary hind-brain, differentiates into the structures which surround the lower half of the fourth ventricle, these structures constituting the **metencephalon** (Fig. 128). The **histological changes** correspond essentially with those that occur in the spinal segment of the neural tube, the **nerve-cells** and **fibers**

and the **neuroglia** resulting from the differentiation of the original ectodermic epithelium of which the wall of the tube is composed, and the **connective-tissue stroma** growing into these from the surrounding mesoderm.

There is a marked disproportion between the rate of growth of the tube in different parts of its circumference. The great thickening of the ventral and lateral walls produces the several parts of the **medulla oblongata**. In the dorsal wall

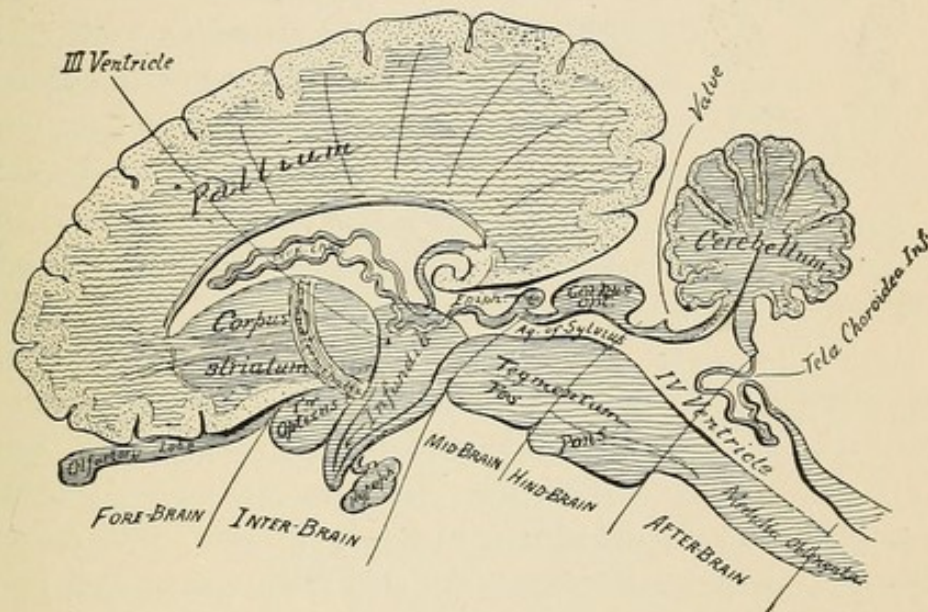


FIG. 128.—Diagram of a sagittal section of the brain of a mammal, showing the type of structure and the parts that develop from the several brain-vesicles (modified from Edinger).

growth occurs to such slight extent that the wall in this region remains a thin layer of epithelium. As a consequence, the cavity of the neural tube is not encroached upon on its dorsal side and the central canal of the spinal cord therefore expands in the metencephalon into a much larger space, the lower half of the future **fourth ventricle**. This relative expansion of the central canal begins to be apparent in the third week in the human embryo, from which period it continues to increase. A cross-section through the lower part of the developing medulla shows a cavity which is narrow laterally but which has a considerable anteroposterior extent. A section at a higher level discloses a triangular space, the base of the triangle being the dorsal wall of the cavity.

At the time when the cavity of the after-brain acquires a distinctly triangular shape—about the third week—each thickened lateral half of the tube is divisible into a ventral and a dorsal segment, these being known respectively as the **basal lamina** and the **alar lamina** (Fig. 129).

The first indication of the **longitudinal fiber-tracts** of the medulla is presented by two bands of fibers which appear upon the surface of the alar lamina and which constitute the **ascending root** of the **fifth nerve** and the **ascending root** (funiculus solitarius) of the **vagus** and **glossopharyngeal nerves**. These are later covered in by the folding over of the dorsal part of the alar lamina (Fig. 130) and thus come to occupy their permanent position in the interior of the medulla.

The parts of the alar laminae that are folded over in the manner referred to differentiate for the most part into the **restiform bodies** or **inferior peduncles**. These are distinguishable in the third month. The **anterior pyramidal tracts** develop from the ventral parts of the basal laminae and are recognizable in the fifth month.

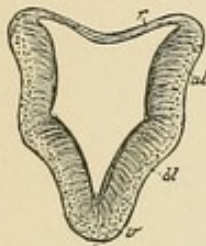


FIG. 129.—Section through upper part (cerebellar region) of the fourth ventricle of an embryo (His): *r*, roof of neural canal; *al*, alar lamina; *bl*, basal lamina; *v*, ventral border.

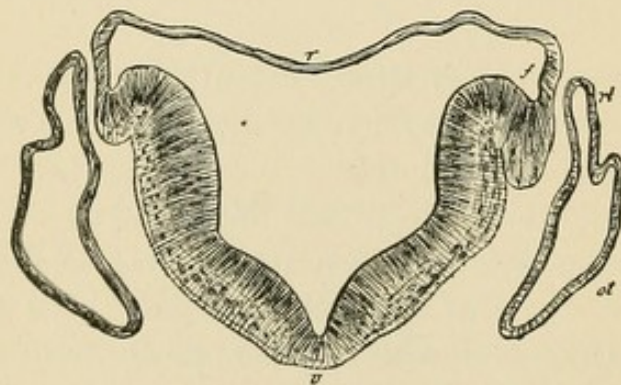


FIG. 130.—Section across the lower half of the fourth ventricle of an embryo, showing gradual opening out of the neural canal, and the commencing folding over of the alar lamina at *f* (His): *v*, ventral border; *t*, tenia; *ot*, otic vesicle; *rl*, recessus labyrinthi.

Coincidentally with the formation of the fibers, the **gray matter** of the medulla assumes its permanent form and arrange-

ment. This gray matter, although in part peculiar to the medulla, is in great measure but the continuation of the gray matter of the spinal cord rearranged and differently related because of the motor and sensory decussations and of the dorsal expansion of the central canal. A notable feature of this rearrangement is the presence of masses of gray matter immediately beneath the floor or ventral wall of the now expanded cavity or fourth ventricle.

As stated above, the dorsal wall of the after-brain vesicle remains an extremely thin epithelial lamina, and the cavity in consequence expands toward the dorsal surface. Owing to the excessive delicacy of this dorsal wall of the cavity, it is easily destroyed in dissection, with the effect of disclosing a triangular fossa (Fig. 135) on the dorsal surface of the medulla, which in connection with a similar depression on the dorsal surface of the pons, constitutes the **rhomboidal fossa**, or the **fourth ventricle of the brain**.

It is often stated in descriptions of the medulla and fourth ventricle that the latter is produced by the opening out of the central canal of the cord to the dorsal surface. It should be borne in mind, however, that the central canal does not, in reality, open out to the surface, although it may appear to do so because of the attenuated condition of its dorsal boundary. The thin epithelial roof or dorsal wall of the after-brain becomes adherent to the investing layer of pia mater, thus forming the **tela choroidea inferior**, which roofs over the lower half of the fourth ventricle (Fig. 128). The pia mater invaginates the epithelial layer to form the **choroid plexuses** of the fourth ventricle. Although apparently within the cavity of the ventricle, the choroid plexuses are excluded from it by the layer of epithelium, the morphological roof of the after-brain, which they have pushed before them.

While, for the most part, the roof of the after-brain consists of the thin epithelial layer referred to above, there are slight linear thickenings, the **ligulæ**, along its lateral margins, and at its lower angle, the **obex**. At the upper margin of the roof, at the place of junction with the hind-brain, there is

also a thickened area, the **inferior medullary velum**. These regions of thicker tissue serve to effect the transition from the thin epithelial layer that helps to form the inferior choroidal tela to the more massive boundaries of the rhomboidal fossa.

**The Hind-brain Vesicle or Epencephalon.**—The epencephalon consists of the **pons**, the **cerebellum** with its superior and middle peduncles, and the **valve** (valve of Vieussens). These structures are produced by the thickening of the walls of the fourth or hind-brain vesicle.

The **pons** is formed by the thickening of the ventral wall of the vesicle. Its transverse fibers become recognizable during the fourth month.

The **cerebellum** grows from the posterior part of the roof or dorsal wall of the vesicle (Fig. 128). The first indication of its development is seen as a thick transverse ridge or fold on the posterior extremity of the dorsal wall (Figs. 131, 132). In the third month the central part of this ridge, now grown larger, presents four deep transverse grooves with the result of dividing the original eminence into five transverse ridges. The grooved part of the ridge is the portion that subsequently becomes the **vermiform process** or **median lobe** of the cerebellum, while the smooth lateral portions become the **lateral hemispheres**. As the vermiform process increases in bulk, two of the ridges come to lie upon its upper surface and three on the inferior aspect. These ridges and furrows persist throughout life as the principal convolutions and fissures of the vermiform process (Figs. 133, 134).

The lateral parts of the primary ridge increase in size and eventually, in the human brain, outstrip the median lobe in growth. They acquire their chief transverse fissures in the fourth or fifth month, and the smaller sulci later.

The thickened cerebellar ridge on the roof of the hind-brain vesicle being continuous with the lateral walls, the continuity of the cerebellar hemispheres with the pons through the middle and superior cerebellar peduncles and with the medulla by means of the inferior peduncles, is easily

understood. These bands of fibers become evident, the inferior in the third month, the middle in the fourth month, and the superior in the fifth month.

While the posterior part of the roof of the hind-brain thickens and develops into the cerebellum, all the remaining part of this roof remains relatively thin and becomes the

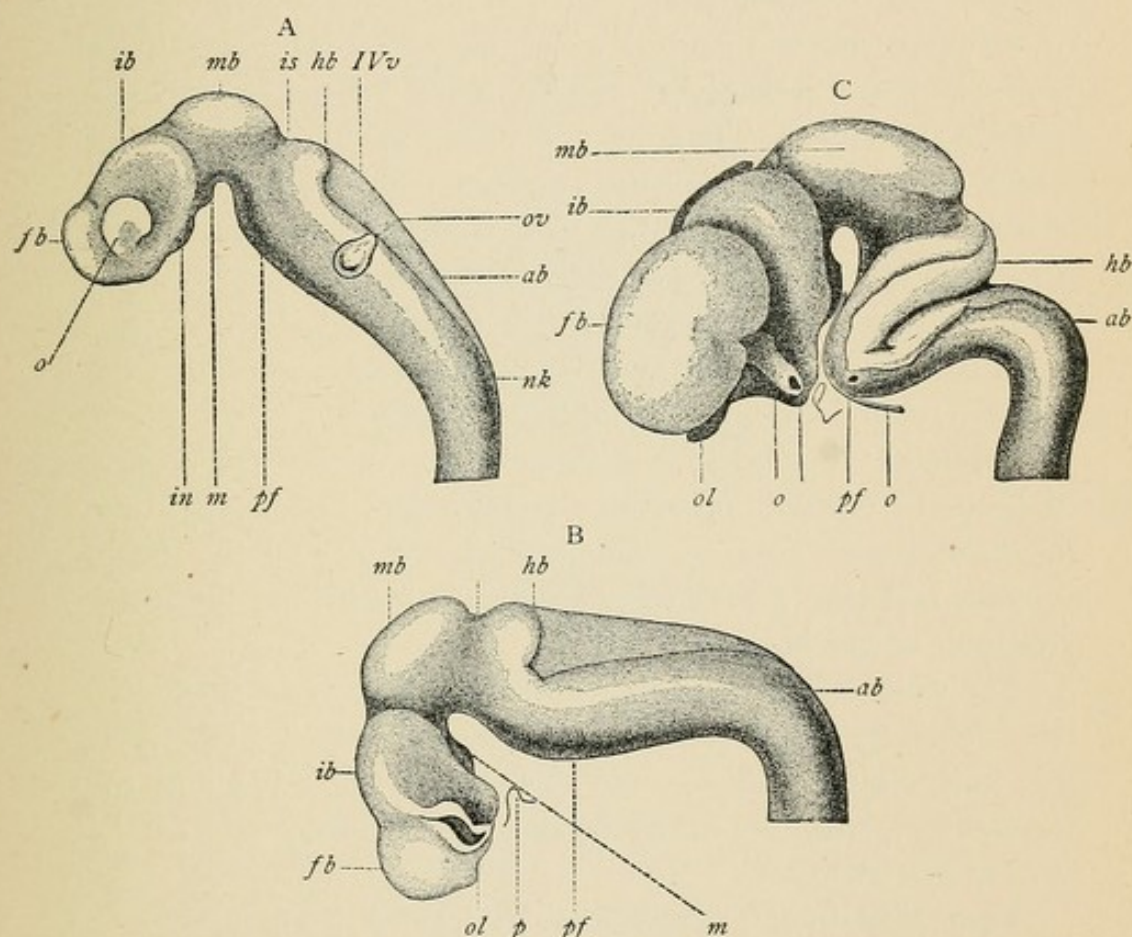


FIG. 131.—Brains of human embryos, from reconstructions by His: A, brain from fifteen-day embryo; B, from three-and-a-half-week embryo; C, from seven-and-a-half-week fetus: *fb*, *ib*, *mb*, *hb*, *ab*, fore-, inter-, mid-, hind-, and after-brain vesicles; *o*, optic vesicle; *ov*, otic vesicle; *in*, infundibulum; *m*, mammillary process; *pf*, pontine flexure; *IVv*, fourth ventricle; *nk*, cervical flexure; *ol*, olfactory lobe; *b*, basilar artery; *p*, pituitary recess.

anterior medullary velum or the valve of Vieussens (Fig. 128). The relations of this structure in the mature brain, stretching across, as it does, from one superior cerebellar peduncle to the other and being continuous posteriorly with the white matter of the cerebellum, are easily explained in the light of the fact that all these parts are but the specialized dorsal and

lateral walls of the hind-brain vesicle. Since the roof of the hind-brain vesicle is continuous with that of the after-brain or fifth vesicle, it will be seen that the cerebellum must be in continuity with the roof of the medullary part of the fourth ventricle. The transition from the cerebellum to the epithelium of the tela choroidea inferior is effected by a pair of thin crescent-shaped bands of white nerve-matter which pass downward from the central white-matter of the cerebellum, and which are collectively known as the **inferior** or **posterior medullary velum**. Thus, as the result of unequal growth, there are produced from the continuous dorsal walls of the fourth and fifth vesicles the thin laminar medullary velum or valve, the massive cerebellar lobes, the thin bands known as the inferior medullary velum, and the single layer of epithelium which, with a layer of pia mater, constitutes the inferior choroidal tela.

Although the fourth and fifth brain-vesicles are at first delimited from each other by a constriction, this constriction, as development goes on, disappears, the cavity of the fourth vesicle and that of the fifth together constituting the **fourth ventricle of the brain**.

The walls of the fourth or hind-brain vesicle then give rise ventrally to the pons, laterally to the superior and middle cerebellar peduncles, and dorsally to the valve and the cerebellum, while its cavity becomes the anterior half of the fourth ventricle.

**The Mid-brain Vesicle.**—The third brain-vesicle or the vesicle of the mid-brain or **mesencephalon** gives rise to the structures surrounding the aqueduct of Sylvius, the persistent part of the cavity constituting the aqueduct itself.

The thickening of the **ventral wall** of the vesicle results in the formation of the **crura cerebri** and the **posterior perforated lamina** or **space** included between them. The crura first become apparent in the third month as a pair of rounded longitudinal ridges on the ventral surface of the vesicle. These remain relatively small until the fifth month, when the longitudinal fibers of the pons begin to grow into them. After this occurrence their increase in size is comparatively

rapid, their ventral parts or *crustæ* becoming separated from each other and including between them the *posterior perforated lamina*.

The *roof* or *dorsal wall* of the mid-brain vesicle undergoes considerable thickening (Fig. 131), especially in the *Sauropsida* (birds, reptiles, fishes). In the fifth week a longitudinal ridge appears upon the dorsal wall, which in the third month is replaced by a furrow. The expansion of the wall on each side of the furrow produces a pair of rounded eminences (Figs. 132-135), which, in birds, attain to a much

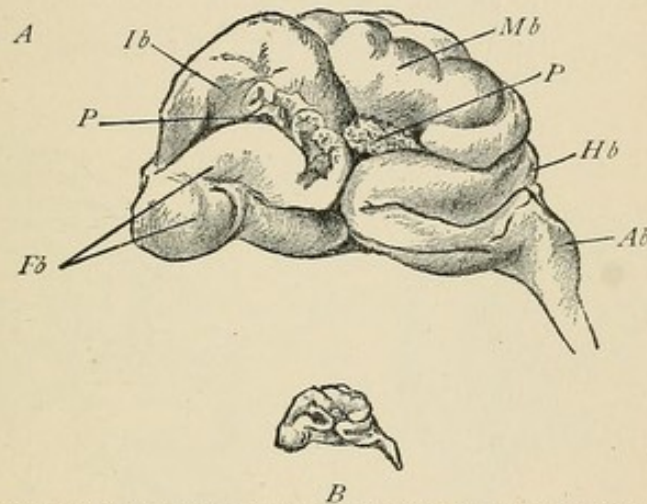


FIG. 132.—Brain of human fetus of about eight weeks: *A*, enlarged; *B*, actual size; *Fb*, fore-brain; *Ib*, inter-brain; *Mb*, mid-brain; *Hb*, hind-brain; *Ab*, after-brain; *P*, folds of pia mater.

greater development than in mammals and constitute the *corpora bigemina* or *optic lobes*. In the human embryo, each of these elevations is divided into two by an oblique groove, and thus are formed the *corpora quadrigemina*, which are peculiar to man and other mammals.

The part of the dorsal wall of the vesicle that underlies the *corpora quadrigemina* is the *lamina quadrigemina*.

The thickening which the walls of the vesicle undergo to produce the several parts of the mid-brain encroaches so much upon its cavity that an exceedingly small canal, the *aqueduct of Sylvius*, remains. It is scarcely necessary to point out that this canal is a part of the ventricular system of the brain, establishing a communication between the fourth ventricle and the third ventricle or cavity of the inter-brain.

### The Metamorphosis of the Inter-brain Vesicle.—

The inter-brain vesicle results from the division of the primary fore-brain vesicle, comprising what is left of the latter after the outgrowth from it of the diverticulum that becomes the secondary fore-brain. The thickening of the walls of the inter-brain vesicle produces the structures which surround the third ventricle in the mature condition, and which constitute collectively the **thalamencephalon** or **inter-brain**, the cavity of the vesicle persisting as the adult **third ventricle**. These structures are the **optic thalami**, which are formed from the lateral walls; the **velum interpositum** and the **pineal body**, which develop from the roof; and the **lamina cinerea**, the

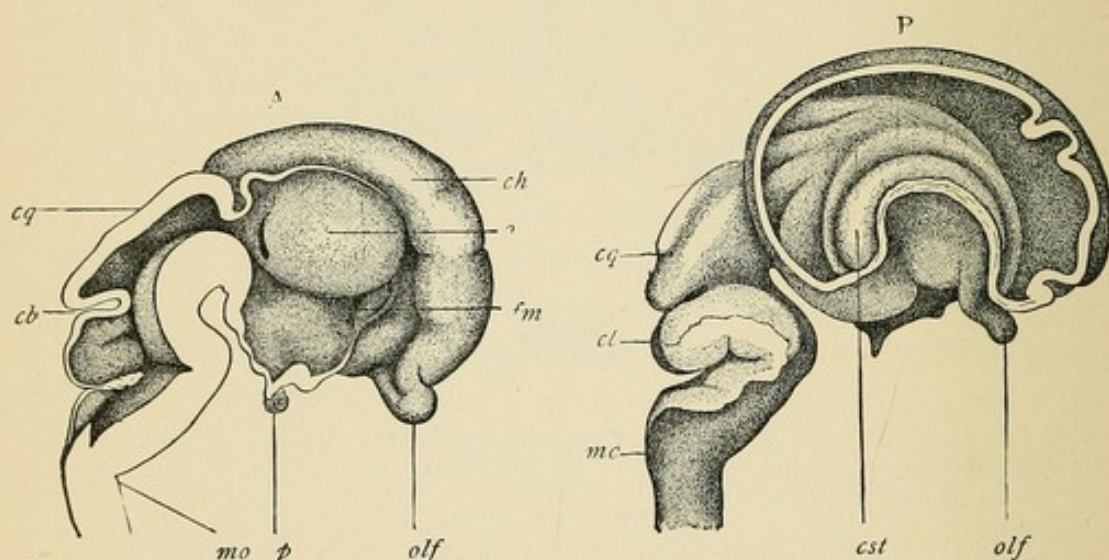


FIG. 133.—A, mesial section through brain of a human fetus of two-and-a-half months (His): *ch*, cerebral hemisphere; *o*, optic thalamus; *fm*, foramen of Monro; *olf*, olfactory lobe; *p*, pituitary body; *mo*, medulla oblongata; *cq*, corpora quadrigemina; *cb*, cerebellum. B, brain of human fetus of three months (His): *olf*, olfactory lobe; *cst*, corpus striatum; *cq*, corpora quadrigemina; *cb*, cerebellum; *mo*, medulla oblongata.

**tuber cinereum**, the **infundibulum**, the **posterior lobe** of the **pituitary body** and the **corpora albicantia**, which are differentiated from the floor of the vesicle.

The **lateral walls** of the vesicle undergo the most marked thickening. The cell-multiplication here is so rapid that each lateral wall is converted into a large ovoid mass of cells with intermingled bands of fibers, the **optic thalamus**.

The **roof** of the inter-brain vesicle, in notable contrast with the lateral walls, remains extremely thin throughout

the greater part of its extent (Fig. 128). From the back part of the roof, at a point immediately in front of the lamina quadrigemina of the mid-brain, a diverticulum grows out and becomes metamorphosed into the **pineal body**. With this exception, the roof of the vesicle remains a single layer of epithelium, just as in the case of the roof of the after-brain. This epithelial layer adheres closely to the pia mater, which covers it in common with the other parts of the brain. As the fore-brain expands, it covers the inter-brain, the under surface of the cerebral hemispheres of the former being closely applied to the roof of the latter. As a consequence, the pia mater on the under surface of the fore-brain is brought into contact with and adheres to the pia covering the roof of the inter-brain. Thus the thin epithelial roof of the inter-brain becomes closely united with the two layers of the pia mater to form the **velum interpositum** or **tela choroidea anterior** or **superior** of adult anatomy. Obviously, the edges of the velum interpositum rest upon the optic thalami, and its piamatral layers are continued into the cavities of the lateral ventricles (Fig. 134). The space occu-

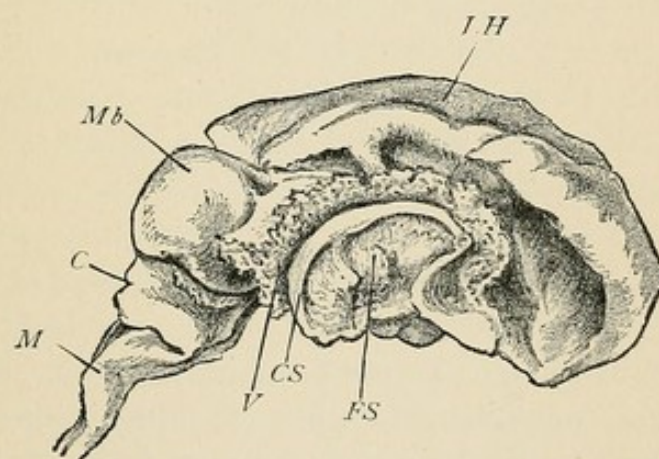


FIG. 134—Brain of fetus of three months, enlarged. The outer wall of the right hemisphere has been removed; *LH*, left hemisphere; *CS*, part of corpus striatum; *FS*, site of fossa of Sylvius; *V*, vascular fold of pia mater which has been invaginated through the mesial wall of the hemisphere; *Mb*, mid-brain; *C*, cerebellum; *M*, medulla oblongata.

ried by the velum is designated the **transverse fissure** of the brain, and it is often stated that the pia mater is pushed in from behind, between the optic thalami and the cerebral hemi-

spheres. As will be seen from the above description, however, its development really begins in front.

The **pineal gland** or **conarium** develops from the back part of the roof of the inter-brain at its point of junction with the mid-brain (Fig. 128). This body is found in all vertebrate animals except the amphioxus, but its form varies greatly in different groups. In all cases it begins as a small pouch-like evagination from the roof of the inter-brain, the diverticulum being directed forward. In the human brain alone the structure is subsequently directed backward, so that it comes to occupy a position just over the corpora quadrigemina. This peculiarity of location is due probably to the greater development of the human corpus callosum, by which the conarium is crowded backward.

In **selachians** (sharks and dog-fish), the enlarged vesicular end of the diverticulum, which is lined with ciliated columnar cells, lies outside the cranial capsule and is connected with the inter-brain by the long hollow stalk which perforates the roof of the cranium. In many **reptiles**, the conarium is more highly specialized. In the chameleon, for example, the peripheral extremity has the form of a small closed vesicle which lies outside the roof of the cranium and which is covered by a transparent patch of skin. The stalk in this case is partly a solid cord and partly a hollow canal, which latter opens into the cavity of the inter-brain. The solid portion lies within a foramen in the parietal bone, the **parietal foramen**. A further modification of the conarium is presented in lizards, blind-worms, and some other reptiles. In these the vesicle undergoes a marked specialization, its peripheral wall being so modified as to become transparent and to resemble the crystalline lens of the eye, while the opposite deeper wall comes to consist of several layers of cells—some of which become pigmented—and acquires a striking resemblance to the retina. The stalk of the body, which perforates the roof of the skull and is attached to the roof of the inter-brain, bears a certain likeness to the optic nerve, being solid and composed of fibers and elongated cells. The presence of the transparent epidermal plate which covers the vesicle

serves to complete the similarity of this particular type of pineal body to the eye of vertebrate animals. It is for this reason that it is often designated the **pineal** or **parietal eye** and that it has been looked upon as a third or **unpaired organ of vision**.

In **man** and other mammals and in birds the pineal diverticulum does not reach the degree of development that is attained in certain of the Reptilia. The evagination from the roof of the inter-brain begins in the sixth week in the human embryo. The peripheral end of the process enlarges somewhat and small masses of cells project from it into the surrounding mesodermic tissue. These cellular outgrowths, giving off secondary projections, become converted into small closed follicles lined with columnar ciliated cells. The follicles in the case of mammals very soon become solid or nearly so by the accumulation of cells in their interior. Solid concretions of calcareous matter, the so-called **brain-sand** (*acervulus cerebri*) are found in the follicles in the adult. By these alterations the pineal body of birds and mammals acquires a structure resembling that of a glandular organ. Since it is only the end of the diverticulum that becomes thus altered, the remaining part constitutes the relatively slender stalk of the pineal body, the stalk being solid at maturity except at its point of attachment to the inter-brain, where a portion of the cavity persists as the **pineal recess** of the third ventricle.

The **pineal body of man** and the **higher vertebrates** is therefore a rudimentary structure and is the representative of an organ that is much more highly developed in some of the lower members of the same series. Its true significance is still a matter of conjecture. Although resembling the eye in its structure, and although regarded by some on that account as primitively an organ of vision, it is considered probable by others that in its most highly developed condition it is an organ of heat perception.

The **floor** of the inter-brain vesicle presents several interesting metamorphoses. The anterior part of the floor remains quite thin and becomes the **lamina cinerea** of the mature brain (Fig.

128). Immediately posterior to this region, the floor of the vesicle pouches out, this evagination developing into a slender tube, the **infundibulum**. Behind the point of origin of the infundibulum a second protuberance indicates the beginning of the **tuber cinereum**. By subsequent alterations, the tuber cinereum enlarging in circumference so as to include the point of origin of the infundibulum, the base of attachment of the infundibulum comes to be the center of the tuber cinereum, so that the cavity of the former is a continuation of the cavity of the latter. The end of the infundibulum becomes the **posterior lobe** of the **pituitary body** or **hypophysis** (Figs. 128 and 133). Posterior to the tuber cinereum a small evagination of the floor of the vesicle appears and becomes divided in the early part of the fourth month into two lateral halves by a median furrow. The two little bodies thus formed become, after further development, the **corpora albicantia**.

The **hypophysis** or **pituitary body** briefly referred to above requires more extended consideration because of its morphological importance. The **posterior lobe** of this body is the enlarged end of the infundibulum, which is an evagination of the floor of the inter-brain. The cells in the lower end of the infundibulum specialize into nerve-cells, and nerve-fibers also develop. In some lower vertebrates these elements are retained throughout life, but in man and the higher-type animals the distinctively nervous character of the tissues is soon lost, and the cavity of this part of the infundibulum suffers obliteration. The branched pigment-cells sometimes recognizable in the posterior lobe of the human pituitary body are the only remnant of the early nerve-cells.

The **anterior lobe of the hypophysis** is essentially different in origin as well as in structure from the posterior lobe. It is produced by an evagination from the posterior wall of the primitive pharynx, but from that region of the pharynx which is anterior to the pharyngeal membrane and which therefore belongs to the primitive mouth-cavity (Fig. 55, p. 119). The out-pocketing of the pharyngeal wall begins in the fourth

week, shortly after the rupture of the pharyngeal membrane. The little pouch is the **pocket of Rathke**. The pouch grows upward and backward toward the floor of the inter-brain and meets the end of the infundibulum. As the pharyngeal diverticulum lengthens, its stalk becomes a slender duct, which for some time retains its connection with the pharynx. As the membranous base of the skull becomes cartilaginous, the duct begins to atrophy, and finally entirely disappears. In selachians, however, it is retained permanently, establishing thus a connection between the hypophysis and the pharyngeal cavity. With the disappearance of the duct the enlarged extremity of the diverticulum becomes a closed vesicle lying now within the cavity of the brain-case, in contact with the end of the infundibulum. From the wall of the vesicle numerous little tubular projections grow out into the enveloping mesodermic tissue, and these, by detachment from the parent vesicle, become closed tubes or follicles. The entire structure becomes converted in this manner into a mass of closed follicles held together by connective tissue, after which event this mass acquires intimate union with the infundibular lobe.

Thus the pituitary body consists of two genetically distinct parts, the **anterior lobe** being derived from the ectoderm of the primitive pharyngeal or buccal cavity, and the **posterior lobe** from the ectoderm of the central nervous system. The posterior lobe, developing as it does as an evagination from the floor of the inter-brain, is to be regarded as a small out-lying lobe of the brain.

What remains of the **cavity of the inter-brain**, after its walls have thus developed into the several structures described, is the **third ventricle** of the adult brain, and the aperture of communication with the secondary fore-brain vesicles becomes the **foramen of Monro**. Since the lateral walls become the massive **optic thalami**, while the dorsal and ventral walls give rise to much thinner structures, the cavity of the vesicle is encroached upon to a greater extent on the sides than from above and below, and hence the form of the third ventricle in the mature condition is that of a narrow vertical fissure between the thalami.

**The Metamorphosis of the Fore-brain Vesicle.—**

The secondary fore-brain vesicle gives rise to the **prosencephalon**, which includes the cerebral hemispheres and the structures belonging directly to them. As above indicated, this vesicle grows from the anterior wall of the primary fore-brain vesicle as a diverticulum which is at first single, but which soon becomes divided into two lateral halves by the formation of a cleft in the median plane (Fig. 131, *fb*). This cleft, or **interpallial fissure** is the early representative of the **longitudinal fissure** of the adult cerebrum. The two vesicles remain attached at their bases or stalks with the parent vesicle and communicate by a common orifice with its cavity. The vesicles of the secondary fore-brain grow in an upward and backward direction as well as laterally, and their development is so much more rapid than that of the other vesicles that they soon spread over them and partially hide them from view. It is for this reason that the mass resulting from the fore-brain vesicles, except their basal ganglia, is known in comparative anatomy as the **pallium** or **mantle** (Fig. 128).

The relative rate of growth of the cerebral hemispheres is such that in the third month they completely overlie the inter-brain and by the sixth month they have extended so far back as to hide the corpora quadrigemina.

The **mesodermic tissue** surrounding the developing brain becomes differentiated into the **three brain-membranes**, which penetrate into the fissure and therefore invest the vesicles on their mesial surfaces as well as elsewhere. The invaginating layers of the dura mater constitute the primitive **falx cerebri**.

The metamorphosis of this pair of sacs into the cerebral hemispheres is brought about by three important processes: first, the **multiplication of the cells** which compose its walls to form the masses of nerve-cells and fibers of the hemispheres; second, the **formation of folds** in the wall whereby are produced the fissures which divide the hemispheres into lobes and convolutions; and third, the **development of adhesions within certain areas** between the mesial walls of the

two vesicles, by which the system of **commissures** of the hemispheres is produced.

The **walls** of the cerebral vesicles are at first very thin, consisting merely of several layers of spindle-shaped cells. By the rapid multiplication of these cells, the walls are thickened and the cavity of the vesicle is gradually encroached upon until the mature condition of the brain is attained, when the cavity is relatively very much smaller than in the fetus and constitutes the ventricle of the hemisphere or the **lateral ventricle**. The nerve-cells develop processes or polar prolongations, of which the most conspicuous, the **axis-cylinder processes**, lengthen out to form the axis cylinders of nerve-fibers. The fibers thus formed are directed away from the surface and make up the **white medullary matter** of the hemispheres, while the more superficially placed layers of cells constitute the **gray matter of the cortex** of the brain.

In addition to the cortical or superficial gray matter there are masses of gray matter within the hemisphere, the **basal ganglia**, which are likewise collections of nerve-cells. Within a limited area on the lateral wall of each cerebral vesicle, near the lower margin, the cells undergo excessive proliferation resulting in the production of a large ganglionic mass, the **corpus striatum**, and of two smaller aggregations of cells, the **claustrum** and the **nucleus amygdalæ**. These basal ganglia are in reality an infolded part of the cortex.

Inasmuch as the cortical matter develops more rapidly, as regards superficial extent, than does the medullary substance, the cortex becomes thrown into folds, forming thus the **convolutions** and **fissures** of the hemispheres.

Some of the **fissures** of the brain are produced by an infolding of the entire thickness of the vesicle-wall so that their presence is indicated by corresponding projections in the walls of the ventricles. Such fissures are distinguished as **total fissures**. Included in this category are the **fissure of Sylvius**, which is represented in the wall of the lateral ventricle by the corpus striatum; the **calcarine fissure**, the **dentate fissure**, and the **collateral fissure**, which are responsible respectively for the calcar avis, the hippocampus major, and

the collateral eminence of the lateral ventricle; and the **great transverse fissure** of the brain, the infolded wall in this case being very thin and consisting merely of the layer of epithelium which covers the choroid plexus.

The **fissure of Sylvius** is the earliest fissure formed and one of the most important. At an early period in the history of the secondary fore-brain, there is a region in the lower part of the lateral wall of the vesicle where expansion is less rapid than elsewhere, this area, as it were, remaining fixed. As the vesicle-wall immediately surrounding this

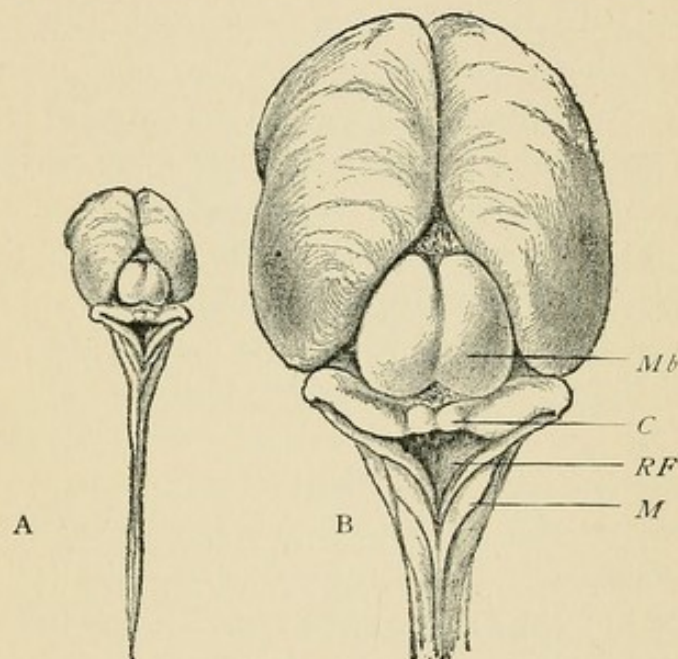


FIG. 135.—Posterior view of brain shown in Fig. 136: A, actual size; B, enlarged; *Mb*, mid-brain; *C*, cerebellum; *RF*, rhomboidal fossa (its dorsal wall having been removed); *M*, medulla oblongata.

spot continues to expand, a dimpling of the wall is produced, the depression being designated the **fossa of Sylvius** (Fig. 136, *S*). The part of the vesicle-wall behind the fossa advances forward and downward to form the future **temporal lobe**, and thus the fossa comes to be surrounded by a convolution having the form of an incomplete ring, open in front—the **ring lobe**. The floor of the fossa undergoes very considerable thickening to form the **basal ganglia**—that is, the corpus striatum, the amygdaloid nucleus, and the claustrum. These structures, most conspicuously the corpus striatum, encroach upon the cavity of the vesicle, the nucleus caudatus of the

corpus striatum bulging into the floor and outer wall of the adult lateral ventricle.

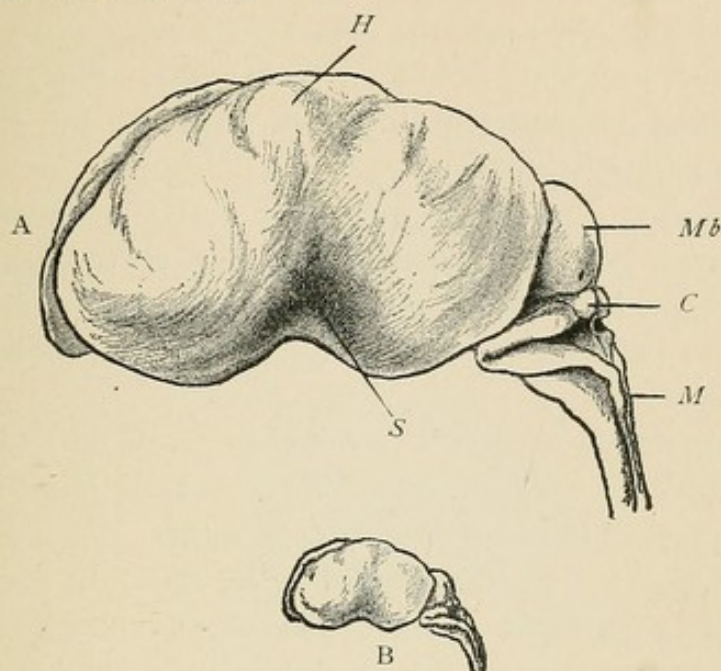


FIG. 136.—Brain of human fetus of approximately three months: A, enlarged; B, actual size; *H*, hemisphere; *Mb*, mid-brain; *C*, cerebellum; *M*, medulla oblongata; *S*, fossa of Sylvius.

The cortical matter of the floor of the fossa of Sylvius, being circumscribed by a groove or sulcus, constitutes the

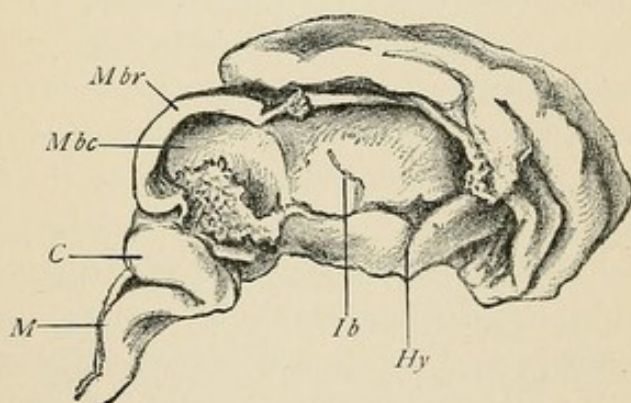


FIG. 137.—Brain of human fetus of three months, with right half of fore-brain, inter-brain, and mid-brain removed: *Ib*, cavity of inter-brain; *Hy*, site of hypophysis; *Mbr*, mid-brain roof; *Mbc*, mid-brain cavity; *C*, cerebellum; *M*, medulla oblongata.

central lobe or island of Reil, which is subsequently broken up, by secondary fissures, into from five to seven small convolutions.

By the extension of the fossa of Sylvius backward, and by the increased growth of the vesicle-wall above and below it, the fossa is converted into the **fissure of Sylvius** (Fig. 140, B), and the island of Reil is hidden from view. Subsequently the **ascending** and **anterior limbs** are added to the chief or **horizontal** part of the fissure.

The anterior part of the ring lobe corresponds with the future **frontal lobe**, the posterior part represents the **parietal lobe** while the lower part of the ring becomes the **temporal lobe**. A backward extension of the ring lobe produces the **occipital lobe**.

The **cavity of the vesicle** is modified in form and extent coincidentally with the formation of the corpus striatum and the alterations in the ring lobe. Just as the ring lobe partially encircles the fossa of Sylvius, so does the cavity of the ventricle partially encircle the corpus striatum. An anterior prolongation of the cavity extends into the completed frontal lobe as the **anterior cornu** of the ventricle, and an extension downward and forward into the apex of the temporal lobe constitutes the **descending cornu**, while the **posterior horn** is gradually protruded into the **occipital lobe** as the latter develops. From the earliest stage, therefore, until the completed condition is attained, the cavity of the ventricle conforms in a general way to the shape of the hemisphere. The apertures of communication between the vesicles of the cerebrum and the cavity of the inter-brain are the later Y-shaped **foramen commune anterius** or the **foramen of Monro**.

The **mesial surfaces of the hemispheres** are much modified in character by the development here of two total fissures, the **arcuate fissure** and the **choroid fissure**. These appear in the fifth week while the vesicles are still separate from each other down to their stalks of attachment to the inter-brain, prior to the development, therefore, of the corpus callosum and the fornix. The two fissures lie close together, parallel with each other and with the margin of the ring lobe, their course conforming to that of the cavity of the ventricle. Beginning near the anterior extremity of the brain, above the

level of the corpus striatum, they pass backward and then downward and afterward forward to terminate near the anterior extremity of the temporal lobe, thus incompletely encircling the striate body.

The **arcuate fissure** is the more peripherally placed of the two. Its anterior portion lies just above the region through-out which adhesions subsequently develop between the two hemispheres, or in other words, above the position of the future corpus callosum (Fig. 138, *a.f.*). This part of the arcu-

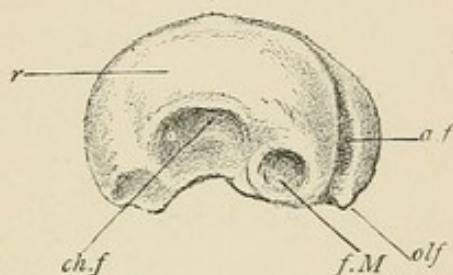


FIG. 138.—Mesial surface of left fore-brain vesicle of brain shown in Fig. 132 (*Fb*): *f.M.*, foramen of Monroe, or opening into inter-brain; *a.f.*, arcuate fissure; *ch.f.*, choroid fissure; *r.*, "randbogen," corresponding to future corpus callosum and fornix; *olf.*, olfactory lobe.

ate fissure is the **sulcus of the corpus callosum** of the mature brain. The posterior segment, that which belongs to the temporal lobe (not present at this stage), is the future **hippocampal** or **dentate fissure**. The hippocampal fissure is represented upon the mesial wall of the descending horn of the lateral ventricle by the prominence known as the **hippocampus major**.

The **choroid fissure** or **fissure of the choroid plexus**, forming an incomplete ring within, and parallel with, that described by the arcuate fissure, encircles the corpus striatum more closely (Figs. 138, 139). It begins at the foramen of Monroe, and its anterior part lies under the position of the body of the future fornix. It then sweeps around into the temporal lobe and terminates near the anterior part of the latter. The fissure of the choroid plexus, like other total fissures, is an infolding of the wall of the cerebral vesicle. It presents the peculiarity, however, that the infolded part of the wall is extremely thin, consisting of but a single layer of epithelial

cells. The pia mater, which everywhere closely invests the surface of the brain, is infolded with the vesicle-wall, the infolded part becoming very vascular and constituting the **choroid plexus** of the lateral ventricle. The choroid plexus, although within the limits of the ventricle, is excluded, strictly speaking, from its cavity by the layer of epithelium which still covers it and which has been simply pushed before it into that cavity. Since the epithelial layer is very thin and easily ruptured, the choroid fissure is apparently an opening into the cavity of the ventricle through which the pia enters; in the adult it is called the **great transverse fissure** of the brain.

The **calcarine fissure**, another of the total fissures, develops in the latter part of the third month as a branch of the arcuate fissure. It bulges into the mesial wall of the posterior horn of the ventricle, producing the elevation known as the **calcar avis** or **hippocampus minor**. Since the posterior horn of the ventricle is developed as an extension of the cavity into the backward prolongation of the ring lobe which forms the occipital lobe, the calcarine fissure necessarily is later in appearing than the fissures above described.

The **parieto-occipital fissure** is added in the fourth month as a branch of the calcarine, effecting the definite demarcation between the parietal and occipital lobes.

The **fissure of Rolando** develops in the latter part of the fifth month in two parts. The two furrows are at first entirely separated from each other by an intervening area of cortex. Subsequently this part of the cortex sinks beneath the surface, as it were, since it expands less rapidly than the adjacent regions, and in this way the upper and lower limbs of the fissure become continuous. The sunken cortical area is to be found even in the adult brain as a deep annectant gyrus embedded in the Rolandic fissure at the position of its superior genu. The development of the fissure of Rolando effects the division between the frontal and parietal lobes.

The **collateral fissure** appears in the sixth month as a longitudinal infolding of the mesial wall of the hemisphere

below and parallel with the hippocampal fissure. Being a total fissure, its presence affects the wall of the cavity of the vesicle, producing the *eminentia collateralis*. At about the same time the *calloso-marginal fissure* makes its appearance, and this is morphologically continuous, through the medium of the *post-limbic sulcus*, with the collateral fissure (Fig. 141). These three fissures constitute the peripheral boundary of a region of the mesial wall which is known in morphology as the *falciform* or *limbic lobe*.

The *longitudinal fissure* in the early stage of the growth of the cerebrum separates the two vesicles from each other except at the place where they are attached to the inter-brain; here the two sacs are united by that part of their common anterior wall which is immediately in front of the apertures of communication with the inter-brain and which is called the *lamina terminalis*.

The *development of adhesions between the mesial surfaces* of the hemisphere vesicles throughout certain definite areas marks the beginning of the *corpus callosum* and the *fornix*. The fusion of these areas begins in the third month in the region corresponding to the anterior pillars of the fornix, the septum lucidum and the genu of the corpus callosum; in the fifth and sixth months adhesion occurs in the position of the body of the fornix and of the body and splenium of the corpus callosum.

Although the central white medullary matter of the cerebral hemisphere is covered almost universally by the cortical gray matter, there is a limited area of the mesial surface from which the gray matter is absent, leaving the white matter exposed. The area of uncovered white matter has the form of a narrow band, which begins at the base of the hemisphere, in front of the opening into the inter-brain, extends upward along the anterior wall of the inter-brain, then passes backward along its roof and curves downward and outward behind, and then forward under it, to terminate at the front part of the temporal lobe. Thus this white band, which is known as the *fimbria*, and which represents the lower mesial edge of the hemisphere, almost encircles the inter-brain. The fimbria

runs between the arcuate fissure and the fissure of the choroid plexus (Fig. 139, *f*). It holds such a close relation to the lat-

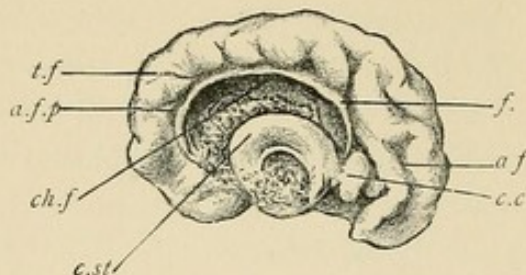


FIG. 139.—Mesial surface of left hemisphere, brain of fetus of three months (enlarged): *f.*, fornix; *c.c.*, beginning of corpus callosum; *c.st.*, part of corpus striatum arching around fossa of Sylvius; *a.f.*, anterior, and *a.f.p.*, posterior parts of arcuate fissure; *ch.f.*, choroid fissure, the concavity between which and the corpus striatum accommodates the inter-brain, which has been removed. The fissure is occupied by the pia mater.

ter fissure, being placed on its peripheral side, that it constitutes the edge of the apparent opening into the cavity of the vesicle through which the pia mater, bearing blood-vessels, is reflected into the interior, and which, as pointed out above, is the transverse fissure of the brain. The opening is only apparent, however, since the wall is still unbroken, although reduced to a single layer of epithelium. The pia mater, forming, with its blood-vessels, the choroid plexus of the lateral ventricle, pushes the layer of epithelium before it, and although the plexus is said to be within the cavity of the ventricle, it is still covered by the layer of epithelium, the **ependyma**, which lines that cavity.

The part of the fimbria that immediately overlies the roof of the inter-brain becomes intimately united, as noted above, with the corresponding part of the fimbria of the other hemisphere, these fused portions of the two fimbriæ forming a flat triangular sheet, the **body of the fornix**. The anterior and posterior portions of the fimbria, which diverge from the median plane, represent respectively the **anterior** and **posterior limbs** of the fornix.

Noting the relation of the anterior part of the fimbria to the aperture of communication between the inter-brain and the cerebral vesicles, it becomes apparent that the anterior pillar of the fornix forms the anterior and upper boundary of

the foramen of Monro. When, further, one considers the relation of the fimbria to the apparent opening into the ventricle, through which the pia mater is invaginated (the transverse fissure), it is explained why the edge of the fornix appears as a narrow white band, not only as viewed from within the ventricular cavity, but also in a mesial section of the brain (Fig. 140, C).

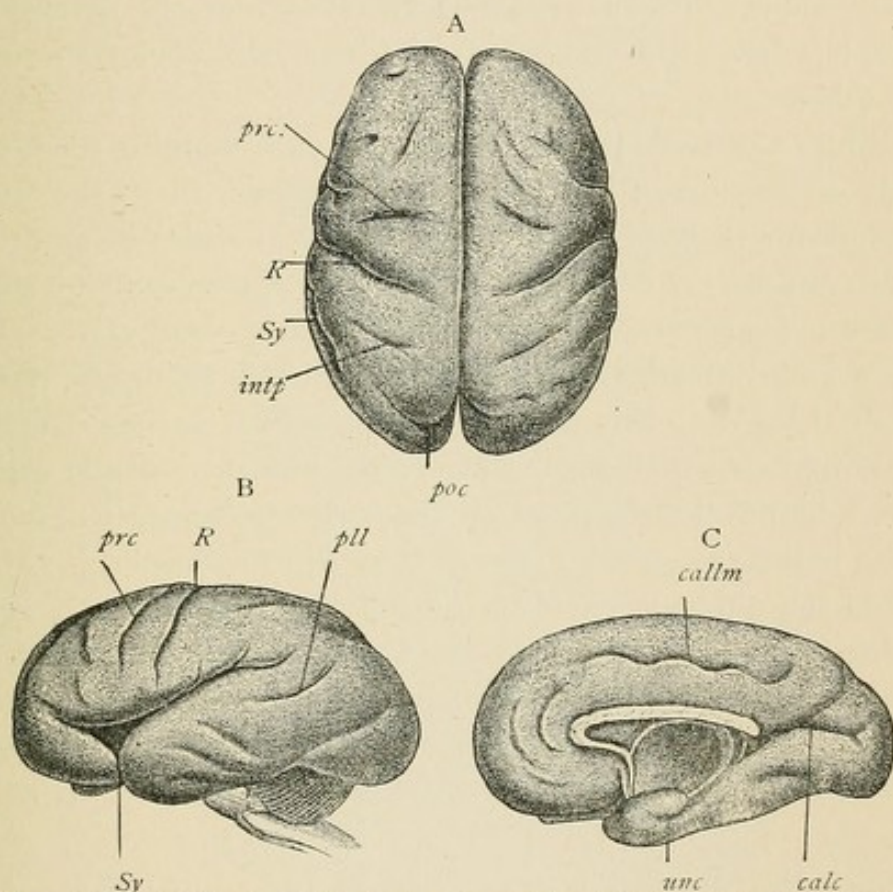


FIG. 140.—Fetal brain at the beginning of the eighth month (Mihalkovics): A, superior, B, lateral, C, mesial surface: *R*, fissure of Rolando; *prc*, precentral fissure; *Sy*, Sylvian fissure; *intp*, interparietal fissure; *poc*, parieto-occipital fissure; *pll*, parallel fissure; *callm*, callosomarginal fissure; *unc*, uncus; *calc*, calcarine fissure.

Another important region of fusion of the opposed mesial surfaces of the hemispheres is that corresponding to the future **corpus callosum**. Throughout this area the hemispheres closely unite with each other. The line of fusion begins at the bases of the vesicles, some little distance in front of the anterior parts of the fimbriæ (Fig. 139, *c.e.*), and after passing upward and forward, curves horizontally backward

in close relation with the fused portions of the fimbriæ, now the body of the fornix. The adhesion begins at the anterior part in the third month, and affects the region of the body and splenium of the future corpus callosum in the fifth and sixth months. Fibers penetrate from one hemisphere to the other throughout this zone of contact, intimately uniting the cerebral hemispheres. The corpus callosum is therefore a great commissure between the two halves of the cerebrum, and is necessarily composed of fibers having a transverse direction.

While the back part of the corpus callosum lies over the body of the fornix and is in close contact with it, the front part of the body of the corpus collusum, as also its genu or curve and its rostrum or ascending part are at some distance from the front parts of the fimbriæ. In other words, while the great longitudinal fissure extends at first to the bases of the cerebral vesicles, this fissure is made relatively less deep by the adhesions which occur between the mesial walls and which result in the development of the corpus callosum ; and the space below the anterior part of the corpus callosum, between it and the anterior parts of the fimbriæ (Fig. 140, C), is an *isolated part of the great longitudinal fissure*. This space is bounded on either side by that part of the wall of the corresponding cerebral vesicle or hemisphere which is limited above and in front by the corpus collusum, and behind by the anterior part of the fimbria or anterior limb of the fornix. The space is the so-called **fifth ventricle** of the adult brain. The circumscribed parts of the mesial walls of the hemispheres, which form the lateral walls of the space, together constitute the **septum lucidum**. The parts of the hemisphere walls that become the septum lucidum do not participate in the process of fusion mentioned above. Their surfaces are in contact, however, and do not develop the typical gray cortical matter, such as appears elsewhere upon the surface of the cerebrum. Cortical gray matter is produced here, but only in rudimentary form.

From what has been said, it will be seen that the **two layers of the septum lucidum** are circumscribed and opposed

parts of the mesial walls of the hemispheres; that the **fifth ventricle** is not a true ventricle but an isolated part of the longitudinal fissure having no connection whatever with the system of ventricular cavities; and that this so-called ventricle is not, like the true ventricles of the brain, lined with ependyma, but with atrophic gray cortical matter.

The **limbic lobe** has been referred to as that part of the mesial surface of the hemisphere which is circumscribed by the calloso-marginal fissure, the post-limbic sulcus, and the collateral fissure. It is limited centrally by the fissure of the corpus callosum and the hippocampal fissure, which are represented in the fetal brain by the single uninterrupted arcuate fissure. Hence the limbic lobe would include the gyrus fornicatus, the isthmus, and the gyrus uncinatus, which constitute morphologically a single ring-like convolution. Schwalbe, however, includes with this so-called limbic lobe all the surface of the mesial wall of the hemisphere included between the arcuate fissure and the fissure of the choroid plexus (Fig. 138), designating it the **falciform lobe** (Fig. 141).

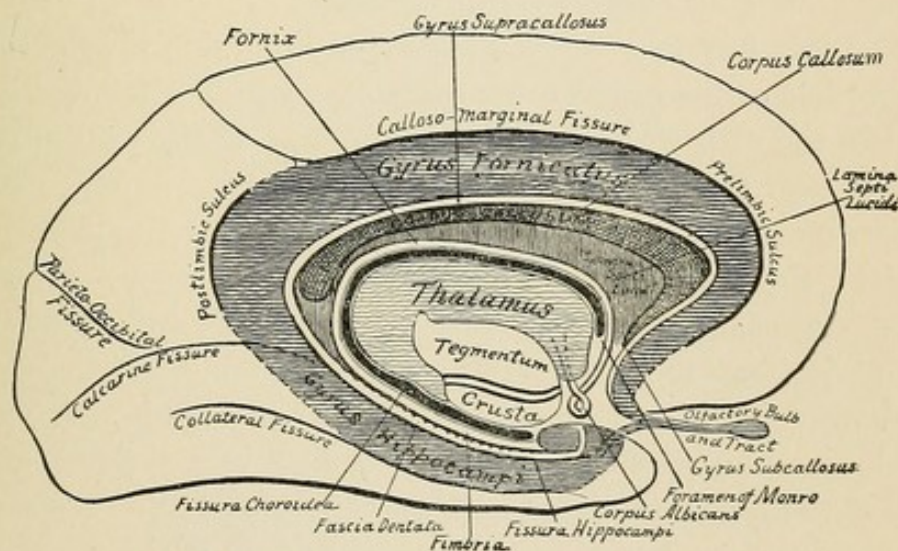


FIG. 141.—Diagram of the limbic lobe (after Quain).

The falciform lobe therefore consists of two ring-like convolutions, one within the other, the two being separated from each other by the arcuate fissure (the adult callosal and dentate fissures) and being limited centrally by the fissure of the choroid plexus (the great transverse fissure of the adult

brain). While the outer of these concentric convolutions—the limbic lobe of Broca—develops into the fornicate or callosal, the isthmian, and the uncinatæ gyri, the inner ring differentiates but slightly, its cortical matter remaining atrophic. The atrophic condition of the cortex here is associated with those adhesions between the mesial walls of the hemispheres that result in the formation of the corpus callosum and the septum lucidum. By these adhesions the continuity of the inner concentric convolution is broken, and it is therefore represented, after the development of the corpus callosum, by the atrophic gray matter of the septum lucidum, by the gyrus dentatus, and by the lateral longitudinal striæ on the free surface of the corpus callosum, the latter being an atrophic or rudimentary convolution. Since the transverse fissure of the brain is the centric boundary of the ring, the fornix is also a part of the falciform lobe. To sum up, the **falciform lobe** includes the gyrus fornicatus, the isthmus, the gyrus uncinatus, the lateral longitudinal striæ or tænia tectæ of the corpus callosum, the gyrus dentatus, the laminæ of the septum lucidum and the fornix.

The **olfactory lobe** or **rhinencephalon** is an outgrowth from the vesicle of the cerebral hemisphere. Its development begins in the fifth week by the pouching-out of the wall of the vesicle near the anterior part of its floor (Figs. 131 and 133). This diverticulum, which contains a cavity continuous with that of the vesicle, grows forward and soon becomes somewhat club-shaped. In the selachians (sharks and dog-fish) the projection attains a great relative size, the olfactory lobes in these animals being one of the most conspicuous parts of the brain. In all mammals except man it is well developed, and in the horse its cavity persists throughout life. In **man** the cavity soon becomes obliterated and the lobe itself in part aborts. The protruded portion, becoming more distinctly club-shaped, differentiates into the **olfactory bulb** and the **olfactory tract**, the position of the original cavity being indicated by a more or less central **mass of neuroglia** conspicuous in cross-sections of those structures. The proximal portion of the olfactory lobe is represented in the adult

human brain by the gray matter of the anterior perforated lamina (or space), and by the trigonum olfactorium and the area of Broca, as well as by the inner and outer roots of the olfactory tract (note olfactory lobe of dog's brain, Fig. 142).

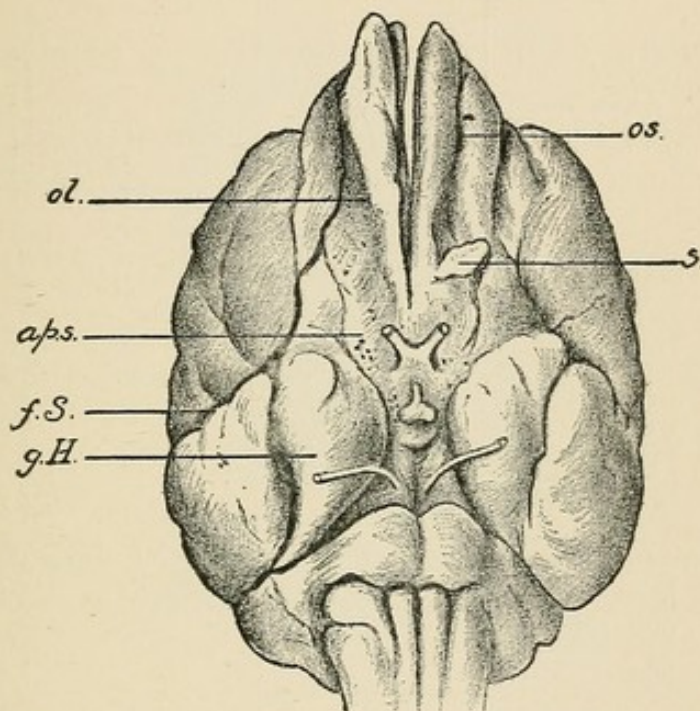


FIG. 142.—Base of dog's brain: *ol.*, olfactory lobe; *a.p.s.*, region corresponding to anterior perforated space, which is included in the olfactory lobe; *f.S.*, fissure of Sylvius; *g.H.*, hippocampal gyrus, developed to a greater degree than in human brain; *s.*, sectional surface of olfactory lobe; *os.*, olfactory sulcus.

Because of the relation of the place of evagination of the olfactory lobe to the fossa of Sylvius, it happens that a part of this lobe, the **anterior perforated lamina**, is situated at the commencement of the fissure of Sylvius and that it is in continuity with both extremities of the ring lobe; hence, the olfactory lobe is connected with both extremities of the falci-form lobe. To express it in the language of human anatomy, the **outer** or **lateral root** of the olfactory tract is connected with the **gyrus uncinatus**, while the **inner** or **mesial root** may be traced to the fore part of the **gyrus fornicatus**.

After what has been said, the reader need scarcely be reminded that the **olfactory bulb and tract**, often erroneously referred to as the olfactory nerve, are parts of a lobe of the

brain, a lobe which in man is rudimentary but which in all other mammals is well developed.

*Tabulated Résumé of the Derivatives of the Brain-vesicles.*

BRAIN-VESICLES.	FLOOR.	ROOF.	LATERAL WALLS.	CAVITY.
After-brain vesicle.	Medulla oblongata.	Tela choroidea inferior.	Inferior peduncles of cerebellum.	Fourth ventricle.
Hind-brain vesicle.	Pons Varolii.	Posterior medullary velum. Cerebellum. Anterior medullary velum.	Middle and superior peduncles of cerebellum.	
Mid-brain vesicle.	Peduncles of cerebrum. Posterior perforated space.	Corpora quadrigemina. Lamina quadrigemina.	Brachia. Internal geniculate bodies.	Aqueduct of Sylvius.
Inter-brain vesicle.	Corpora albicantia. Tuber cinereum, infundibulum, and part of hypophysis. Optic chiasm.	Pineal body. Posterior commissure. Epithelium of velum interpositum.	Optic thalami.	Third ventricle.
Secondary fore-brain vesicle.	Anterior perforated lamina. Corpus striatum. Island of Reil. Olfactory lobe.	Convolutions of cerebral hemispheres. Corpus callosum. Fornix. Septum lucidum.		Lateral ventricles.

### THE DEVELOPMENT OF THE PERIPHERAL NERVOUS SYSTEM.

The development of the peripheral nervous system is still involved in some degree of obscurity. In general terms it may be stated that the peripheral nervous apparatus is derived as an extension of the central cerebro-spinal axis.

In the case of the **spinal nerves**, each nerve-trunk is composed of both motor and sensory fibers, the former being in continuity with the spinal cord through the medium of the anterior or motor roots, and the latter through the posterior or sensory roots, each sensory root possessing a ganglion. The **cranial nerves** exhibit a less regular composition. While the trigeminal nerve, for example, arises by two roots, after the manner of a spinal nerve, some others correspond in relative position and in mode of development to the ventral or motor roots of the spinal nerves, and still others are equivalent to the sensory spinal roots.

The development of the sensory nerve-fibers is dependent upon and is preceded by that of the ganglia of the posterior roots of the spinal nerves, and of several ganglia of the head region which are related to the development of certain of the cranial nerves. Hence the consideration of the genesis of

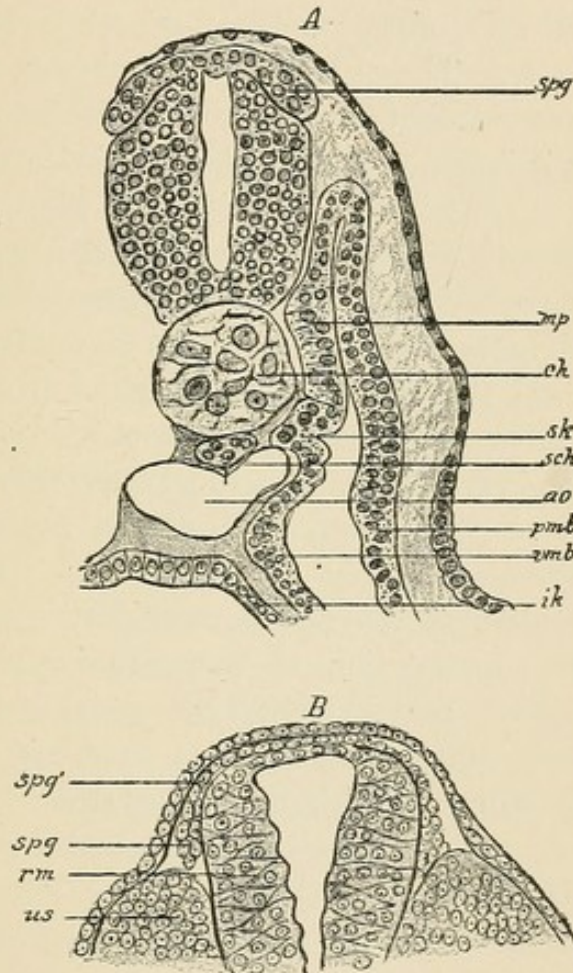


FIG. 143.—A, cross-section through an embryo of *Pristiurus* (after Rabl). The primitive segments are still connected with the remaining portion of the middle germ-layer. At the region of transition there is to be seen an outfolding (*sk*) from which the skeletogenous tissue is developed; *ch*, chorda; *spg*, spinal ganglion; *mp*, muscle-plate of the primitive segment; *sch*, subchordal rod; *ao*, aorta; *ik*, inner germ-layer; *pmb*, parietal, *vmb*, visceral middle layer. B, cross-section through a lizard embryo (after Sagemehl): *rm*, spinal cord; *spg*, lower thickened part of the neural ridge; *spg'*, its upper attenuated part, which is continuous with the roof of the neural tube; *us*, primitive segment.

the ganglia must precede the account of the growth of the sensory nerve-fibers.

The origin of the ganglia is connected with the early history of the evolution of the neural tube. Just after the

sides of the medullary plate (*vide* p. 255) have united with each other to form the neural tube, there appear two ridges of cells between the tube and the epidermis, one on each side of the raphe or line of union of the sides of the tube. These ridges are the **neural crests** (Fig. 143). They first appear in the region of the hind-brain and advance from this point both headward and tailward. The ganglia develop from these neural crests. The cells of the neural crest are usually described as growing out from the neural tube, though according to His it is probable that they originate singly from the ectoderm.

The mass of cells composing the neural crest grows outward and then ventrad along the wall of the neural tube, and very soon undergoes segmentation into a number of cell-masses which are the rudimentary ganglia. In the spinal region the number of segments corresponds to the number of future spinal nerves. In the head region there are four segments. These latter, the **cephalic ganglia**, will be referred to subsequently.

The **segmentation of the neural crest** corresponds in the main with the segmentation of the paraxial plate of the mesoderm, whereby the myotomes are produced, and each segment lies upon the inner side of a myotome. The connection of the segments with the neural tube becomes reduced in each case to a slender strand, the point of continuity of which with the tube is shifted farther away from the median line, as development progresses, to correspond with the dorsolateral position of the sensory nerve-roots in the mature condition.

The cells of the ganglia acquire axis-cylinder processes, each such process, upon further elongation, becoming the axis cylinder of a future nerve-fiber. The cells being bipolar, each one gives origin to two nerve-fibers, one passing to the spinal cord and one going to the periphery of the body as a sensory nerve-fiber. Thus the ganglia are made up of cells which are interpolated in the course of the sensory nerve-fibers, and these cells may be regarded as having migrated from the developing cerebrospinal axis, or, if the

view of His be accepted, from the region of the ectoderm from which the tube originates, their connection with the axis being maintained by the gradually lengthening out axis-cylinder process.

The **development of the motor nerve-fibers** differs from that of the sensory. These fibers, or at least, the axis cylinders of the fibers, are the elongated neurites of nerve-cells of the spinal cord and brain. The neuroblasts of the thickened neural tube, as they become fully differentiated nerve-cells, migrate from their central position into the mantel layer, or superficial stratum (Fig. 124). On the distal side of the nucleus of the cell, the protoplasm first becomes massed and then lengthens out to form an axis-cylinder process or neurite, which in all vertebrate animals grows out from the cerebro-spinal axis to form a motor nerve-fiber.

Although, in the case of the spinal nerves, the motor and sensory fibers are separated from each other at their origin from the cord, they soon intermingle to constitute a spinal **nerve-trunk**. In certain lower types, as cyclostomes and amphioxus, the motor and the sensory fibers permanently pursue separate routes to their peripheral distribution.

The **envelopes of the nerve-fiber** are acquired at a relatively late period. The appearance of the **neurilemma** precedes that of the **white substance of Schwann**. Both these investments are derived from the mesoderm. The cells of the latter apply themselves to the nerve and, penetrating between the fibers, become arranged as an enveloping layer upon each axis cylinder, ultimately forming a complete sheath, the **neurilemma**. The persistent nuclei of these cells, scantily surrounded with protoplasm, constitute the **nerve-corpuscles** of the neurilemma. The **medulla, or white substance of Schwann**, is formed at a considerably later period within the neurilemma. The deposit of the medullary sheath varies as to time for different groups of fibers—although the time is constant for each group—and proceeds always in a direction away from the cell from which the fiber originates, or, differently expressed, in the direction in which the fiber conveys impulses. Thus, in the spinal cord, groups of afferent

fibers may be distinguished from those that are efferent by observing the direction in which the medullary sheath develops—that is, whether the sheath appears first at the upper end of the fiber or at the lower end.

The **cranial nerve-fibers** in their development follow in the main the same general principles that govern the growth of the spinal nerves. That is to say, the motor fibers grow out as extensions of the axis-cylinder processes of nerve-cells of the cephalic part of the neural tube and the sensory fibers proceed from the cells of outlying ganglia, or in the case of at least one nerve, the olfactory, from infolded and highly specialized cells of the ectoderm.

The **cephalic ganglia**, four in number, have been referred to as resulting from the segmentation of the head-region of the neural crest. As previously stated, the neural crest begins to grow first in the region of the hind-brain and extends from this point both forward and backward, occupying a position upon the roof or dorsal wall of the hind-brain. The part of the neural crest belonging to the head-region then divides into the four masses or head-ganglia which are designated respectively the first or **trigeminal**, the second or **acusticofacial**, the third or **glossopharyngeal**, and the fourth or **vagal**, ganglia.

The **trigeminal ganglion**, which is very large, becomes divided into a smaller anterior portion, the **ophthalmic** or **ciliary ganglion**, and a larger posterior segment, the **trigeminal ganglion** proper. These two become widely separated during the progress of development, since they constitute respectively the later **ciliary** and **Gasserian ganglia**, the ciliary ganglion belonging to the ophthalmic division of the fifth nerve, while the trigeminal belongs to the superior maxillary division and the sensory part of the inferior maxillary division of the fifth. Their nerve-cells give rise to the sensory fibers of these trunks in the same manner that the cells of the spinal ganglia produce the sensory fibers of the spinal nerves. By some observers, the sphenopalatine (Meckel's) ganglion and the otic, and possibly the submaxillary ganglia, are to be regarded as offshoots from the Gasserian ganglion.

The **acusticofacial ganglion**, after its migration from its original position on the dorsum of the hind-brain, lies just in front of the otic vesicle. This ganglion subsequently divides into the facial and the acoustic ganglia. The **facial ganglion**, the geniculate ganglion or intumescencia gangliiformis of the facial nerve, situated in the facial canal of the temporal bone, although described as a ganglion upon a motor nerve, the facial, is, in reality, connected mainly with the pars intermedia, a bundle of sensory fibers issuing from the nucleus of origin of the glossopharyngeal nerve. It is equivalent therefore to a spinal ganglion.

The **acoustic portion** of the acusticofacial ganglion divides still further to become the ganglion on the vestibular part of the auditory nerve, and the ganglion spirale of the cochlear division of the auditory, which latter is situated in the spiral canal of the modiolus. It is considered probable that the **lateral accessory auditory nucleus**, which is connected with the cochlear fibers of the auditory nerve and lies on the outer side of the restiform body, is also a part of the acoustic ganglion. From the cells of the vestibular ganglion, which is situated in the internal meatus, centrifugal fibers develop to form the **vestibular nerve**, while other centripetally growing fibers become the ventral or mesial (vestibular) *root* of the **auditory nerve**. The **cochlear ganglion** in the same way gives rise to the cochlear branch of the nerve and to its dorsal or lateral root. Thus the auditory nerve and its ganglia correspond respectively to the sensory root of a spinal nerve and to a spinal ganglion.

The **third cephalic ganglion** becomes the ganglion of the glossopharyngeal nerve, undergoing segmentation to form the upper or jugular and the lower or petrous ganglia of this nerve, while the axis-cylinder processes of its cells lengthen out to become the sensory fibers.

The **fourth cephalic ganglion** similarly becomes the two ganglia of the pneumogastric nerve and gives rise to its sensory fibers.

While the motor fibers of the cranial nerves develop by the outgrowth of the axis-cylinder processes of the motor

nerve-cells of the brain, and thus correspond in manner of development with the spinal motor fibers, *there is a modification as to their point of emergence from the central axis.* Instead of issuing in line with the spinal motor roots, there are two sets of cranial motor roots, the **ventral** and the **lateral**. Both arise from the cells of the ventral zone of the neural tube and thus correspond in point of origin with the spinal motor fibers, but the cells from which proceed the fibers of the ventral roots are situated in the ventral part of this zone, whereas the parent cells of the lateral roots lie near its dorsal edge, close to the deep connections of the sensory fibers. It happens therefore that the lateral roots emerge in close proximity to the dorsal or sensory bundles, the two apparently constituting one nerve-trunk. The motor fibers of the fifth, seventh, ninth, and tenth nerves have this lateral position, and are so closely identified with the sensory fibers that the two sets form one trunk in each case.

The **ventral motor nerve-roots** emerge in line with the ventral or motor roots of the spinal nerves. The only cranial nerves which represent persistent ventral motor roots are the **abducens** and the **hypoglossal**.

*A still further modification in the cranial nerves is presented by their relation to the segmentation of the head.* As pointed out above, the segmentation of the spinal part of the neural crest is in correspondence with the segmentation of the trunk, and each spinal nerve therefore may be regarded as belonging to a particular segment of the trunk. In the case of the cranial nerves, however, there is no such regular correspondence, since in some instances, several nerves are referred to one head-segment, while in others, one nerve belongs to several segments. An example of the latter is furnished by the hypoglossal, which arises from the side of the medulla by a series of bundles of fibers which are referable to several segments.

As will be seen later, in the account of the development of the nose and of the eye, the olfactory and optic nerves exhibit certain peculiarities which set them apart from the other cranial nerves.

From what has been said, it will be apparent that the cranial nerves develop in a far less regular manner than the spinal nerves, and that consequently their trunks consist in some cases of only sensory fibers, in other cases of only motor fibers, and in still others, of both varieties. Typically, each cranial nerve would have a dorsal sensory root with a ganglion, and two motor roots, one lateral and the other ventral. But by the suppression of one or two of these typical roots there will be produced a nerve, for example, representing only the ventral root, as the sixth and twelfth nerves, or a trunk containing sensory and lateral motor fibers, as the vagus, or a nerve consisting solely of sensory fibers, as the auditory.

By way of recapitulation the cranial nerves may be briefly considered *seriatim* :

First Pair.—The olfactory nerve-filaments grow centripetally from the olfactory epithelium of the nasal mucous membrane.

Second Pair.—The optic nerve is not a true nerve (see Chapter XVI.).

Third Pair.—The oculomotor nerve represents a persistent lateral motor root of the first head-segment (the ophthalmic division of the fifth nerve being the sensory root of the same segment).

Fourth Pair.—The trochlear nerve represents a lateral motor root and belongs to the second head-segment.

Fifth Pair.—The trifacial or trigeminal nerve, containing sensory and motor fibers, represents a persistent lateral motor root and a dorsal sensory root. The ophthalmic portion of the sensory root belongs to the first head-segment, while all the remaining fibers, with the fourth nerve, are assigned to the second segment.

Sixth Pair.—The abducens develops as a ventral motor root and belongs to the third and possibly to the fourth segments.

Seventh and Eighth Pairs.—The acusticofacialis nerve, or the facial and auditory nerves, develop as a single nerve with several roots. The auditory nerve and the sensory fibers of

the facial—that is, the *pars intermedia*—correspond to a dorsal sensory root, the division of the acusticofacial ganglion into the several ganglia of the auditory nerve and the geniculate ganglion of the facial accounting for the division of the root into the auditory trunk and the *pars intermedia*. (The sensory fibers of the facial pass off through the chorda tympani to go to the tongue as special-sense fibers.) The motor fibers of the facial develop as a lateral motor root, originating from cells in the ventral zone. These two nerves, with the sixth, belong to the third and possibly to the fourth head-segments.

**Ninth Pair.**—The glossopharyngeal nerve, made up largely of sensory fibers, represents a dorsal sensory root and a lateral motor root, the fibers of which latter grow out from cells in the dorsal part of the ventral zone of *His*, the later nucleus ambiguus. It belongs to the fifth head-segment.

**Tenth Pair.**—The vagus develops in the same manner as the glossopharyngeal.

**Eleventh Pair.**—The spinal accessory represents in part motor spinal roots and in part probably the lateral motor and dorsal sensory roots of the cranial nerves.

**Twelfth Pair.**—The hypoglossal develops as the ventral motor roots of several segments, being identical in mode of origin with the anterior roots of the spinal nerves. This nerve and the vagus belong to the head-segments from the sixth to the tenth inclusive.

#### THE DEVELOPMENT OF THE SYMPATHETIC SYSTEM.

There are two views as to the origin of the sympathetic system. One theory, based upon the investigations of *Pater-son*, is that the gangliated cord of the sympathetic is differentiated from mesodermic cells, the cell-cord thus formed acquiring, secondarily, connections with the spinal nerves, and presenting still later the enlargements which constitute the ganglia.

The more generally accepted view, based upon the researches of *Balfour* and the later work of *Onodi* and *His*, is that the sympathetic ganglia develop as offshoots from the

**ventral extremities of the spinal ganglia.** Each little mass, which has budded off from a spinal ganglion, moves somewhat toward the ventral surface of the body, its bond of union with the parent spinal ganglion being drawn out to a slender cord, the representative of the future **ramus communicans**. Each primitive sympathetic ganglion sends out two small processes, one growing tailward from its lower extremity, and one in the opposite direction from its upper end, the approaching processes from each two adjacent ganglia meeting and uniting and thus secondarily establishing the connection between the different ganglia of one side of the body and forming the **gangliated cord of the sympathetic**. From these ganglia migrating cells probably pass out to develop into the **secondary ganglia** of certain viscera, as His has shown to be the mode of origin of the ganglia of the heart.

## CHAPTER XVI.

### THE DEVELOPMENT OF THE SENSE ORGANS.

IN the organs of the senses we have to do with peripheral nervous mechanisms of greater or less degrees of complexity, the essential elements of which are elaborately modified or specialized neuro-epithelial cells. These neuro-epithelial structures are specialized cells of the ectoderm, derived from it either directly, by the infolding of patches of ectodermic epithelium, as in the case of the olfactory cells, or indirectly, by growth outward from the central nervous system, as in the case of the retina. The organs of the sense of touch, the tactile corpuscles of the skin and mucous membranes, are distributed somewhat irregularly, while such highly specialized structures as the organs of the special senses of vision, hearing, smell, and taste are provided with special protective and accessory apparatuses.

### THE DEVELOPMENT OF THE EYE.

It will perhaps facilitate the comprehension of the general principles involved in the development of the eye if its function as the organ of vision is kept in mind, and if, therefore, the retina and the optic nerve are recognized as the essential parts of the organ, and the other structures as accessories. The **retina** and the **optic nerve** are an outgrowth from the brain, the rod- and cone-visual cells of the former being epithelial cells so specialized as to serve as percipient elements, while the optic nerve-fibers are the conducting medium. To allow of the penetration and refraction of the rays of light, the overlying epidermis differentiates into a transparent and refractive medium, the **crystalline lens**, and the necessary protection and means of nourishment

are provided by the other constituents of the eyeball. Further protection is furnished by two folds of modified skin and subcutaneous tissue, the **eyelids**, and lastly for the lubrication and still further protection of the exposed part of the eyeball, there is formed still another set of accessory organs, the **lacrimal apparatus**.

The first step in the development of the eye is the growth of a diverticulum from the side of the primary fore-brain vesicle (Fig. 144). These optic evaginations are quite large

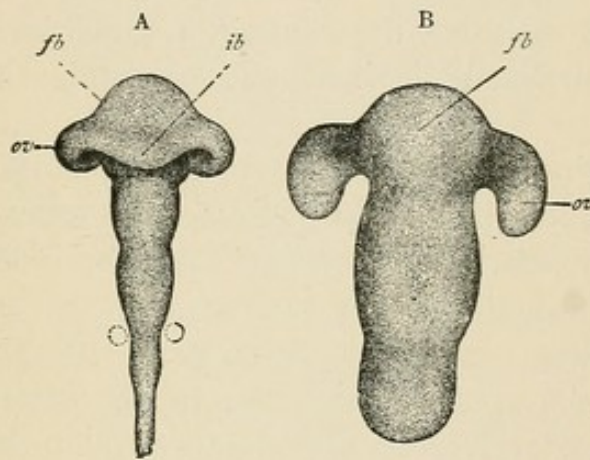


FIG. 144.—A, brain of two-day chick-embryo; B, brain of human embryo of three weeks (His). Shows the development of the optic vesicles and brain-vesicles; *fb*, fore-brain; *ib*, inter-brain; *ov*, optic vesicles.

as compared with the brain-vesicle. They begin to be evident even before the neural tube is completely closed. As the attached part of the diverticulum expands less rapidly than the distal portion, the evagination soon assumes the form of a sac or vesicle, the **optic vesicle**, connected by a hollow stalk with the primary fore-brain. When the secondary fore-brain vesicles grow out anteriorly from the primary vesicle, the region of the latter that becomes in consequence the inter-brain is the part to which the stalk of the optic vesicle is attached. Hence the optic vesicle is an appendage of the inter-brain or thalamencephalon and its point of attachment to the latter is at the lateral part of the base, in front of the region of the infundibulum (Fig. 131, A and C).

The optic vesicle expands laterally and dorsally until it lies immediately beneath the epidermis, forming a promi-

nence on the side of the head (Fig. 51). The ectoderm at the point of contact with the optic vesicle becomes thickened and depressed, the differentiation of this **lens-area** being the starting point of the **crystalline lens**. The depressed patch of ectoderm, sinking more deeply, is converted into a sac, the **lens-vesicle**, the connection of which with the surface-cells is soon lost. The distal wall of the optic vesicle, upon coming into contact with the lens-vesicle, undergoes invagination, this wall sinking in until the cavity of the vesicle is almost obliterated. Thus the vesicle is converted into the double-walled **optic cup**, the opening of which looks laterally toward the surface of the head, and is occupied by the lens-vesicle.

The invaginated wall of the vesicle—that is, the layer nearer the center of the cup—becomes the **retina**, except its pigment-layer, the latter resulting from the outer layer of the cup. The stalk of the cup becomes the **optic nerve**. The surrounding mesodermic tissue grows into the openings referred to above, and gives rise to the **vitreous humor**, while the mesodermic cells that closely envelop the optic cup produce the **uveal tract** and the **sclera** and **cornea**.

Having traced briefly the development of the organ, its several parts may now be considered in detail.

**The Retina and the Optic Nerve.**—These two structures, as stated above, are directly derived from the optic vesicle and its stalk.

To repeat, for the sake of continuity, some points already mentioned, the optic vesicle grows forth as a diverticulum from the side of the primary fore-brain vesicle, its appearance being foreshadowed by a lateral bulging of this vesicle even before the neural canal is completely closed. When the primary fore-brain vesicle divides into the secondary fore-brain vesicles and the vesicle of the inter-brain, the region of origin of the optic vesicle falls to the latter, the point of attachment being at the outer edge of the base of the vesicle in front of the infundibular evagination. The optic nerve is to be regarded therefore as springing from the inter-brain or thalamencephalon.

The outer extremity of the diverticulum expanding more rapidly than its base of attachment assumes the form of a vesicle with a narrow stalk (Fig. 145), the stalked condition

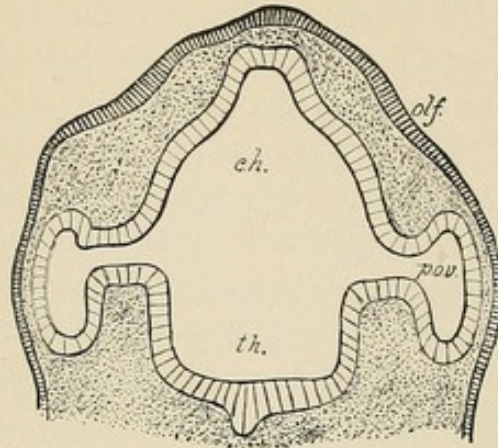


FIG. 145.—Part of a section through the head of an early human embryo, showing the connection of the primary optic vesicles with the fore-brain (His): *olf*, olfactory area of epiblast; *c.h.*, part of fore-brain which gives rise to cerebral hemispheres; *th.*, thalamencephalon; *p.o.v.*, primary optic vesicles.

being present in the fourth week. The vesicles grow in the outward direction and form a prominence on each side of the head. There being no brain-case at this time, they lie imme-

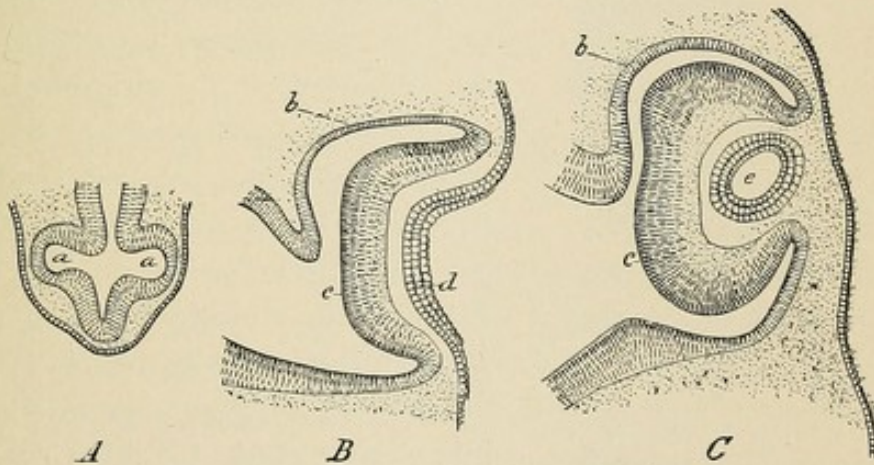


FIG. 146.—Three successive stages of development of the eye, showing formation of secondary optic cup and crystalline lens in human embryos of 4 mm. (A), 6 mm. (B), and 8 mm. (C), (Tourneux): *a, a*, primitive optic vesicles; *b*, external layer of secondary optic cup (future pigment-layer of retina); *c*, inner layer of cup (retina proper); *d*, lens-pit (thickened and depressed ectoderm); *e*, lens-vesicle.

diately under the epidermis, separated from it by only a thin layer of embryonal connective tissue. This lateral position of the optic vesicles is characteristic of the early stages of development. After the end of the first month the eyes

gradually move forward and downward toward their permanent position, which is approximately attained probably early in the third month.

Shortly after the fourth week the distal or lateral wall and the under surface of the optic vesicle become invaginated. The invagination begins when the vesicle comes into contact with the lens-vesicle (Fig. 146). When the infolding is complete, the vesicle has become the **secondary optic cup**, which latter consists therefore of two layers, an inner and an outer. The mouth of the cup, which faces away from the median plane of the head, is occupied by the lens-vesicle. Since the under surface of the vesicle participates in the invaginating process (Fig. 147) there is also in this wall of the cup an aperture, which is known as the **choroidal fissure**. The invagination likewise affects the under surface of the tubular stalk of the vesicle so that it is converted into an inverted double-layered trough. These invaginations bear an

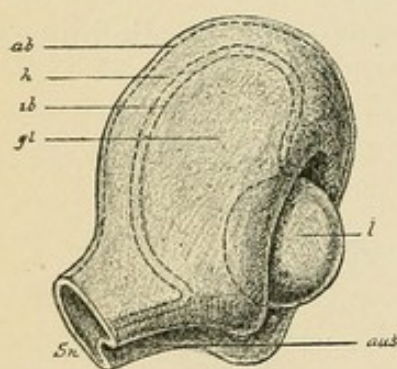


FIG. 147.—Plastic representation of the optic cup with lens and vitreous body (Hertwig): *ab*, outer wall of the cup; *ib*, its inner wall; *h*, cavity between the two walls, which later disappears entirely; *Sn*, fundament of the optic nerve (stalk of the optic vesicle with a furrow on its lower surface); *aus*, optic (choroid) fissure; *gl*, vitreous body; *l*, lens.

important relation not only to the further metamorphosis of the optic vesicle and its stalk into the retina and the optic nerve, but also to the development of the vitreous body and of the central artery of the retina. Thus, the vitreous body is produced by the mesodermic tissue that finds access to the cup through the choroidal fissure, and the arteria centralis retinae is developed in the vascular mesodermic tissue that invaginates the under surface of the stalk of the vesicle.

The choroidal fissure gradually contracts after the entrance of the

mesoderm, and in the last month of fetal life it entirely closes. The mouth of the optic cup embraces the lens, its rim being always on the distal side of, or superficial to, that structure. This opening represents the **pupil** of later stages.

The further metamorphosis of the optic cup includes alterations peculiar to each of the two layers and also to the different regions of the cup. The mouth of the cup contracts somewhat by increased growth of the wall, and thus there is a zone bordering this orifice which is anterior to the lens, holding the same relation to the latter body that the future iris holds. A second zone corresponds with the periphery of the lens, while a third region, the fundus of the cup, includes all the remaining part of its wall.

The **fundus** of the cup undergoes much greater specialization than the other regions. The **outer layer** of the cup remains thin, consisting of a single layer of cells which assume the cuboidal form and become infiltrated with pigment-granules. This forms the **pigment-layer** of the retina. The **inner lamina** of the cup thickens, by the multiplication of its cells, and soon consists of numerous spindle-shaped cells. The thickened fundus is marked off from the zone that surrounds the periphery of the lens by a slight groove which corresponds in position with the future **ora serrata**. These early spindle-cells give rise to two kinds of elements, the **stroma** of the retina, or **Müller's fibers**, and the various nerve-cells, including the highly specialized **rod- and cone-visual cells**.

The principal **sustentacular elements**, or Müller's fibers, like the spongioblasts of the neural tube, are radially arranged and extend throughout the entire thickness of the retina. Their inner expanded extremities, in close contact with each other, form the **inner limiting membrane**, while their outer ends, in the same way, constitute the **outer limiting membrane**, which latter is in contact with the pigment-layer. The stroma of the retina receives a small contribution from the **mesodermic tissue**, which grows into it through the choroidal fissure to furnish the vascular supply.

Of the **nerve-cells**, those near the pigment-layer undergo great alteration in form and become the **sensory epithelium**—that is, the rod- and cone-visual cells. At first these lie entirely internal to the external limiting membrane, which separates them from the pigment-layer. After a time, however, processes grow out—that is, away from the center of

the eyeball—and perforate the external limiting membrane to penetrate between the cells of the pigment-layer. These processes are the rods and cones, and collectively constitute the **layer of rods and cones** of the adult. The bodies of the

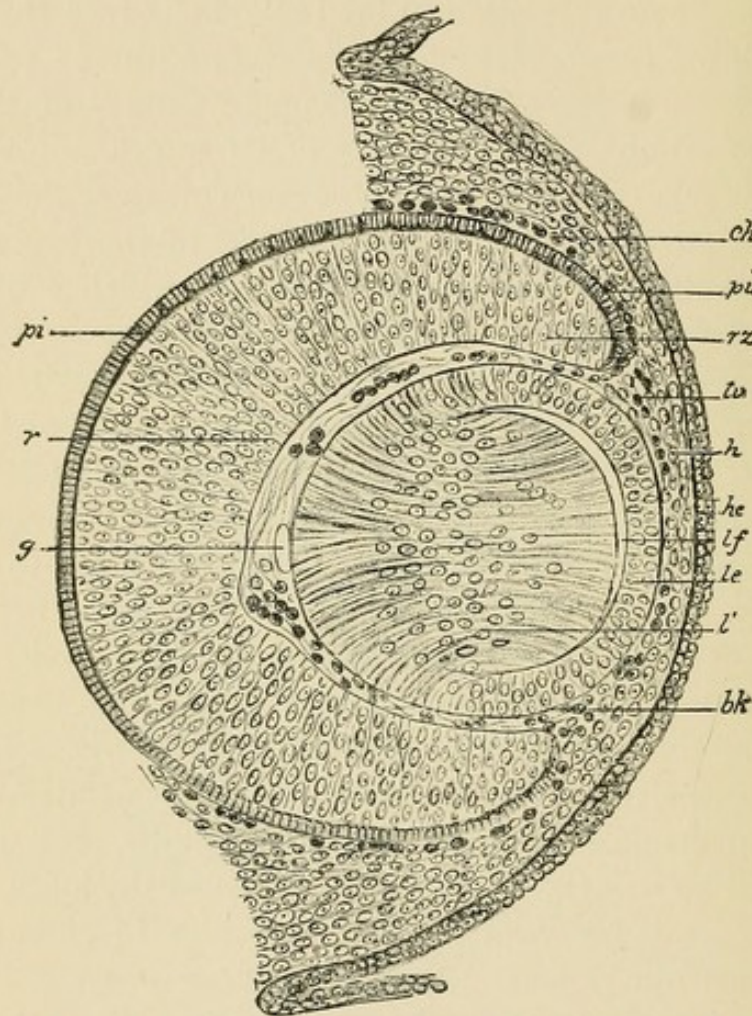


FIG. 148.—Section through the optic fundus of an embryo mouse (after Kessler): *pi*, pigmented epithelium of the eye (outer lamella of the optic cup, or secondary optic vesicle); *r*, retina (inner lamella of the optic cup); *rz*, marginal zone of the optic cup, which forms the pars ciliaris et iridis retinæ; *g*, vitreous body with blood-vessels; *tv*, tunica vasculosa lentis; *bk*, blood-corpuses; *ch*, choroidea; *lf*, lens-fibers; *le*, lens-epithelium; *l'*, zone of the lens-fiber nuclei; *h*, fundus of the cornea; *he*, external corneal epithelium.

rod- and cone-visual cells, situated on the inner side of the membrana limitans externa, are elongated into narrow elements, the position of the nuclei being indicated by slight enlargements. They constitute the **outer nuclear layer** of the mature retina. The outer nuclear layer and the layer of

rods and cones are to be regarded, therefore, as one layer of highly specialized neuro-epithelium, made up of the rod-visual cells and the cone-visual cells, the inner segments or bodies of the cells being only apparently isolated from the outer segments, the rods and cones respectively, by the fact that the latter project through minute apertures in the external limiting membrane. The axis-cylinder processes of these cells pass toward the center of the eyeball.

The **neuro-epithelium of the retina** is the last of its elements to develop. In man and in many mammals, it is present at birth. In the cat and the rabbit, the rod- and cone-visual cells develop after birth, and hence the new-born of these species are blind. The **macula lutea** is developed after birth.

The cells of the inner part of the retina differentiate into the remaining nervous elements, some becoming the bipolar and other cells of the inner nuclear layer—the ganglion retinae—while others form the large ganglion cells of the **ganglion-cell layer**. The axis-cylinder processes of the **ganglion cells** are directed inward to form the **nerve-fiber layer**, the fibers of this layer converging from all parts of the inner surface of the retina toward the optic disk or papilla. Here they perforate the retina, as well as the choroid and sclera, to pass, as optic nerve-fibers, to the brain.

This part of the optic cup, the **fundus**, produces then, in the manner described above, the functioning portion of the retina, or the **pars optica retinae**, the anterior termination of which is indicated by the **orra serrata**.

The **lenticular zone** of the **optic cup**, which is in relation with the periphery of the lens, undergoes comparatively slight specialization. Its outer lamella is pigmented, as in the fundus of the cup. Its inner layer remains very thin and consists of cells which at first are cuboidal, but which later become cylindrical. At the end of the second month, or the beginning of the third, the two layers of the lenticular zone become plicated, owing to excessive growth in superficial extent. The folds are nearly parallel and are arranged radially with reference to the lens, the margin of which they surround. These folds are the first indication of the **ciliary**

**processes.** The mesodermic tissue immediately external to the optic cup differentiates into the uveal tract, the part corresponding with the lenticular zone of the cup furnishing the ciliary body. The young growing connective tissue penetrates between the folds of the lenticular zone of the cup, acquiring intimate union with the pigment-layer, and thus provides the connective-tissue basis of the ciliary processes. This lenticular zone of the two layers of the optic cup, therefore, constitutes the lining, or internal covering, of the ciliary body, and must necessarily be regarded as the continuation of the retina. It is known as the *pars ciliaris retinæ* of the fully developed eye.

The **marginal zone of the optic cup**, or the region bordering its orifice, is also related in its further growth with the uveal tract. Although in the earlier stages of development the lens lies in the mouth of the cup, as time goes on the relation is so altered that the aperture and the zone which borders it occupy a position in front of the lens. In this marginal zone both lamellæ of the cup become pigmented and acquire union with the layer of mesodermic tissue which is differentiating into the iris, and they therefore contribute to the formation of that structure, constituting its **pigment-layer**. The pigment-layer of the posterior surface of the iris is, therefore, an extended but rudimentary part of the retina. It is called the *pars iridica retinæ*.

From what has been said, it will be apparent that the retina forms a complete tunic with an anterior perforation, the **pupil**, and that it consists of the functionally active part, or retina proper, the *pars optica retinæ*; of the *pars ciliaris retinæ*, marked off from the latter by the *ora serrata*; and of the *pars iridica retinæ*, which terminates at the margin of the pupil.

The evolution of the optic cup or secondary optic vesicle may be thus summarized :

- |   |  |
|---|--|
| I. Marginal or most anterior region of cup. | The thin atrophic <i>pars iridica retinæ</i> , or pigment-layer of the iris. |
| II. Lenticular zone of cup.                 | <i>Pars ciliaris retinæ</i> , covering inner surface of ciliary body.        |

## III. Fundus of cup.

A. Outer layer.

B. Inner layer.

Functionating part of retina, or pars optica retinæ, including :

A. Pigment-layer of retina.

B. 1. Neuro-epithelial layer, made up of layer of rods and cones (the processes of the rod- and cone-visual cells); membrana limitans externa; outer nuclear layer (the bodies of the rod- and cone-cells).

2. Cerebral layer (representing an interpolated ganglion with connecting fibers), consisting of :

Outer reticular layer;

Inner nuclear layer;

Inner reticular layer;

Ganglion-cell layer;

Nerve-fiber layer.

The **optic nerve** is the metamorphosed stalk of the optic vesicle. When the distal and under surfaces of the vesicle suffer invagination, the stalk participates in the process, its under surface being marked by a groove which is a prolongation of the choroidal fissure of the optic cup (Fig. 147). By this infolding, the cavity of the stalk is obliterated and the stalk is converted into a double-walled tube enclosing mesodermic tissue which follows the invaginating ventral wall. In this mesodermic tissue is developed the **arteria centralis retinæ**. In mammals the invagination affects only the distal part of the stalk, the segment included between the eyeball and the point corresponding in the adult to the place of entrance into the nerve of the central artery. It must be apparent that the outer layer of the tube thus formed is directly continuous with the outer layer of the optic cup, while the invaginated lamina is the prolongation of the inner wall of the cup or of the part that becomes the retina proper, since not only the distal wall of the optic vesicle is invaginated, but its under or ventral wall as well.

The primitive optic nerve at this stage consists of layers of spindle-shaped cells, with a central core of vascular connective tissue.

The manner in which the **nerve-fibers** are developed is

still a matter of controversy. According to His and Kölliker, the fibers grow out from the ganglion-cells of the optic thalami and the anterior corpora quadrigemina, while Müller believes that they are the prolonged axis-cylinder processes of the ganglion-cells of the retina. In either case the cells of the optic stalk would furnish only the sustentative tissue of the nerve. There is also a contribution of sustentative tissue or stroma from the mesoderm, as in the case of the central nervous system.

**The Crystalline Lens.**—The lens, exclusive of its capsule, is, like the retina, of **ectodermic origin**. The first step in its development is the formation of a thickened and depressed patch of the ectoderm on the lateral surface of the head, this area being situated at the place where the optic vesicle is nearest the surface (Fig. 146, *B, d*). The depression is the **lens-pit**. It soon becomes converted into a closed sac, the **lens-vesicle**, by the gradual approximation and union of its edges. The pit receding from the surface as its lips come together, the completed vesicle lies under the surface ectoderm, with which it is for a time connected by the slender stalk of the invagination. Upon the disappearance of the strand of cells constituting the stalk, the lens-vesicle is completely isolated from the outer germ-layer (Fig. 146, *C, e*).

The lens-vesicle in birds is a hollow epithelial sac several layers thick, but in mammals the central cavity contains a mass of cells, which latter disappear in the later stages of development.

Upon the invagination of the optic vesicle to form the secondary optic cup, the lens-vesicle is embraced by the lips of the cup and still later comes to lie within the cup, near its orifice (Fig. 148).

The further alterations in the vesicle are dependent primarily upon changes in its deep and superficial walls respectively, each of which consists of several layers of cylindrical cells. The cells of the superficial wall alter their form, becoming cuboidal, while the posterior or deeper cells lengthen so as to become fibers. Thus the deeper wall of

the vesicle thickens at the expense of the central cavity—the central mass of cells at the same time disappearing—while the superficial layer remains thin. The two strata are continuous with each other at the equator of the lens, one form gradually merging into the other at this region, which is a zone of transition (Fig. 148).

The lens at this stage is composed, therefore, of a thin superficial or anterior stratum of cuboidal epithelial cells and a much thicker posterior or deep layer of so-called fibers, the latter being simply the greatly elongated cells of the posterior wall of the vesicle. Between the two laminae is a small remnant of the cavity of the vesicle. The epithelial layer persists throughout life as the **epithelium of the lens**, while the fibrous layer is the basis of the **lens-fibers** of the mature condition. The cavity sometimes persists as a small space containing a few drops of fluid, the **liquor of Morgagni**.

The next important stage in the development of the lens is the formation of additional lens-fibers. These result from the proliferation of the cells of the epithelial or anterior layer. The lens-fibers are formed in successive layers, as may be made evident by the maceration of a lens. Each fiber extends from the anterior to the posterior surface of the lens. The ends of the fibers meet each other along regular lines, producing thus the characteristic three-rayed figures or stars of the lens, one of which belongs to each surface. Hence, while the lens-fibers first formed are the elongated cells of the posterior layer of the lens-vesicle, the fibers of later growth originate from the cells of the anterior wall. The epithelial character of the lens-fibers is evinced by the presence of a nucleus in each fiber of a young lens.

The **lens-capsule** results from the differentiation of the mesodermic tissue which surrounds the lens. It is from this enveloping vascular lamina, the **tunica vasculosa lentis**, that the growing lens derives its nutrition. The capsule is well marked in the second month. Its blood-vessels are derived from those of the vitreous body. At the end of the seventh month this well-developed, highly vascular membrane begins to undergo retrograde alterations, the final result of which is

its transformation into the thin, non-vascular, transparent capsule of the mature lens.<sup>1</sup> The most active growth of the lens itself occurs prior to the degeneration of the tunica vasculosa lentis, so that even before the end of fetal life the lens has nearly attained its full size. Thus the weight of the lens of the new-born child is 123 milligrammes, while that of the adult lens is but 190 milligrammes (Huschke).

Hence the **crystalline lens** has a **double origin**, the lens-substance or lens proper being derived from the **ectoderm**, while the capsule originates from the **mesoderm**.

**The Vitreous Body.**—The **vitreous body**, representing a comparatively slightly differentiated form of **connective tissue**, is derived from the **middle germ-layer**. The mesodermic tissue, already in the stage of embryonal connective tissue, gains access to the optic cup through the choroidal fissure (Fig. 147), its ingrowth in fact accompanying the invagination of the under surface of the optic vesicle. Since the inferior surface of the stalk of the vesicle—the future optic nerve—participates in the invagination, the mass of mesodermic tissue which gives rise to the vitreous is continuous with that which invaginates the primitive optic nerve to produce the central artery of the retina. As a consequence, the blood-vessels which soon develop so plentifully in the vitreous body are extensions from the central artery of the retina, the latter itself being continued forward as the **hyaloid artery**. The terminal branches of the hyaloid artery pass on through the vitreous body to terminate in the vascular capsule of the growing lens, constituting the blood-supply of that structure.

The **intercellular substance** of the young tissue undergoes but little differentiation, while the cells become gradually reduced to a few stellate elements which ultimately entirely disappear. The peripheral part of the tissue develops into

<sup>1</sup> It sometimes happens that parts of the fetal lens-capsule persist. The most common example of such persistence is the so-called *membrana pupillaris* sometimes present at birth, producing *congenital atresia of the pupil*. This results from the persistence of that part of the fetal capsule which is situated on the anterior surface of the lens, behind the pupil.

the **hyaloid membrane**, which anteriorly acquires union with the capsule of the lens.

The **blood-vessels** of the vitreous disappear during the last two or three months of fetal life. The **hyaloid artery** persists, although in reduced form, for a longer time than the smaller vessels. Upon its final degeneration it is replaced by a canal, the **hyaloid canal**, or **canal of Stilling**, which is present in adult life.

**The Middle or Vascular and the Outer or Fibrous Tunics of the Eye.**—The outer fibrous coat of the eye, including the **sclera** and the **cornea**, and the **middle tunic** or **uveal tract**, comprising the **choroid**, the **ciliary body**, and the **iris**, are structures of **mesodermic origin**, being directly produced by the mesodermic tissue surrounding the optic cup. The richly-cellular mesoderm applies itself to the exterior of the cup and differentiates into the two layers in question, the changes involving on the one hand the metamorphosis of the mesodermic cells chiefly into muscular and vascular elements, and on the other hand the evolution of a tissue essentially fibrous in structure. These two tunics are distinguishable in the sixth week.

The **cornea** is formed from the thin layer of mesoderm that penetrates between the lens-vesicle and the surface ectoderm. The lens-vesicle lies very near the surface, and the thin stratum of mesoderm that is interposed between the two is the anterior layer of the lens-capsule (Fig. 148). This anterior layer thickens by the immigration of other cells and subsequently splits into two laminae, a superficial one which produces the cornea (Fig. 148, *h*), and a deeper, which is now the proper anterior wall of the lens-capsule. Thus a space filled with fluid appears between the primitive cornea and the lens, which corresponds with the future anterior and posterior chambers of the eye, the division of the space into these two chambers being effected subsequently by the development of the iris. The further development of the cornea consists simply in the differentiation of the mesodermic cells and the intercellular substance into the several characteristic elements of the adult structure.

The **uveal tract** closely corresponds in extent with the two layers of the optic cup. The **choroid** is differentiated from that portion of this primitive uveal tract which envelops the pars optica of the retina. In this region the enveloping layer of mesodermic cells develops into the several elements of the choroid, the most conspicuous of which are an inner layer of capillary vessels, the **choriocapillaris**, and an outer layer of larger vessels, the **stroma-layer** of the choroid. The development of the choroid bears a certain relation to the choroidal fissure of the optic cup. This fissure has been referred to as a gap in the under surface of the cup corresponding with the line of invagination through which the mesodermic tissue, of which the developing choroid is a part, grows into the cup to produce the vitreous. Although normally this fissure in the retina entirely disappears, its site becomes pigmented later than other regions of the pigment-layer of the retina, and hence there is, for a time, a clear streak in this part of the retina which has the appearance of a fissure in that membrane. As the pigment-layer of the retina was formerly assigned to the choroid, this streak appeared to be a breach of continuity of the choroid; hence the term *choroidal fissure*. In some cases, however, the choroidal fissure fails to close, and as the development of the choroid is largely dependent upon or is governed by that of the retina there remains a corresponding gap in the choroid. This defect enables the sclera to be seen from the interior in a line extending forward from the optic nerve entrance. It is known as **coloboma of the choroid**.

The **ciliary body** is developed immediately in advance of the choroid and from the same layer of mesodermic tissue. The deeper parts of the tissue in this region correspond with the plications of the ciliary part of the retina, sending processes into and between the radial folds of this part of the two layers of the optic cup, with which latter the highly vascular mesodermic tissue acquires firm union. This results in the formation of the **ciliary processes**. Some of the cells of the more peripheral part of this zone are converted into unstriated muscular tissue, thus producing the **ciliary muscle**.

All the characteristic or important elements of the ciliary body are, therefore, derived from the mesoderm, while the thin layer of tissue on its inner surface, representing an undeveloped part of the optic cup, the *pars ciliaris*, is of ectodermic origin.

The *iris*, the most anterior zone of the uveal tunic, is produced from the same mesodermic tract that gives rise to the

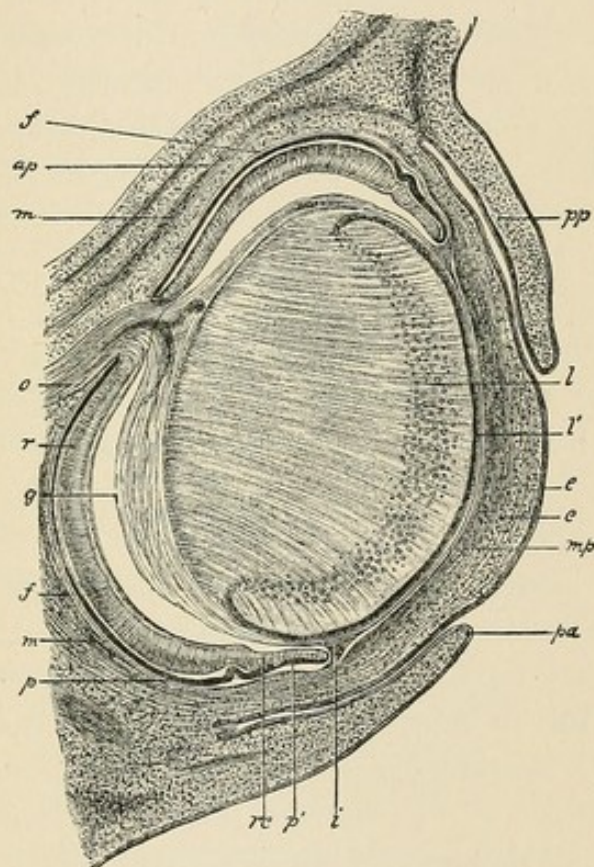


FIG. 149.—Sagittal section through the eye of an embryo rabbit of eighteen days  $\times 30$  (Kölliker): *o*, optic nerve; *p*, hexagonal pigment-layer; *r*, retina; *rc*, ciliary part of the retina; *p'*, forepart of the optic cup (rudiment of the iris-pigment); *g*, vitreous, shrunk away from the retina, except where the vessels from the *arteria centralis retinae* enter it; *i*, iris; *mp*, *membrana pupillaris*; *c*, cornea with epithelium *e*; *pp*, *pa*, palpebrae; *l*, lens; *l'*, lens-epithelium; *f*, sclerotic; *m*, recti muscles.

choroid and to the ciliary body. As stated above, soon after the lens-vesicle becomes constricted off from the surface ectoderm, it is enveloped by a mass of mesodermic cells which constitute its primitive capsule, and the layer of these cells lying between the lens-vesicle and the surface ectoderm splits into an anterior layer, which becomes the cornea, and a pos-

terior stratum which is the anterior wall of the lens-capsule. This produces a space between the lens and the cornea. The lens now recedes farther from the surface, and the margins of the optic cup advance, so that the lens now lies within the cup, the marginal zone of the cup being in front of the lens, between it and the cornea, while its equator is in close relation with the ciliary regions of the cup and of the uveal tract. Thus the space between the lens and the cornea is divided into an anterior compartment, the **anterior chamber**, and a posterior space, the **posterior chamber**, the orifice of the cup being a means of communication between the two and representing the **pupil** of a later stage. The marginal zone of the cup furnishes the guiding line for the development of the iris. The mesodermic tissue in relation with the outer surface of the marginal zone of the cup differentiates into the vascular, muscular, and connective-tissue elements of the iris proper, while its posterior pigment-layer is constituted by the slightly specialized layers of the most anterior part of the optic cup, the part that is known as the *pars iridica retinae*.

Since the **anterior** and **posterior chambers** of the eye are spaces hollowed out of the mesoderm, they represent a lymph-space and are, as such, lined with endothelial cells.

The cleft in the inferior wall of the optic cup referred to above as the choroidal fissure necessarily affects the marginal zone of the cup as well as the region posterior to it. If this part of the fissure persists, as it sometimes does, it may be accompanied by a corresponding deficiency in the tissues of the iris proper. Such a congenital defect, appearing as a radial cleft in the lower half of the iris, is known as **coloboma of the iris**.

**The Eyelids and the Lacrimal Apparatus.**—The **eyelids** are developed from folds of the primitive epidermis that form over the superficial part of the developing eyeball (Fig. 149, *pp* and *pa*). After the separation of the lens-vesicle from the surface ectoderm, the latter pouches out into two little **transverse folds** for the upper and lower lids respectively. Each fold includes a certain quantity of

mesodermic tissue, from which are produced the connective-tissue elements of the lids, as the tarsal plates, etc. After the folds attain to a certain degree of development their edges approach each other and become adherent, thus enclosing a space between the primitive lids and the front of the eyeball. The **infolded ectodermic layers** lining this space acquire the characteristic features of mucous membrane and constitute the **epithelium of the conjunctiva**, the part of this membrane that covers the cornea adhering closely to that structure as its anterior epithelial layer. The **union of the edges** of the lids begins in the third month and lasts until near the close of fetal life. A short time before birth the permanent **palpebral fissure** begins to form by the breaking down of the adhesions.

A part of the mesodermic tissue of the lids undergoes conversion into fibrous connective tissue, thus producing the **tarsal plates** of the upper and lower lids, with the **palpebral fasciæ** and **tarsal ligaments** by which the plates are attached to the margins of the orbit.

During the period when the edges of the lids are adherent, the **Meibomian glands** and the **eye-lashes** are formed. The glands develop from solid cords of epithelial cells that grow from the deepest or Malpighian layer of the primitive epidermis into the tarsal plates. The cords become hollow tubes by degeneration of their central cells.

In addition to the two principal folds that produce the lids, a **third, vertical fold** appears at the inner, nasal side of the conjunctival space, beneath the lids. This fold remains quite small in man and forms the **plica semilunaris**, but in most other vertebrates it attains much greater size as the **third eyelid** or **nictitating membrane**. A small part of this third fold develops sebaceous glands and a few hair-follicles and becomes the **lacrimal caruncle**.

The **lacrimal gland** is developed in the same manner as the Meibomian glands, by the growth of solid epithelial cords from the conjunctiva. The cords grow into the underlying mesoderm at the outer part of the line of reflection of the conjunctiva from the inner surface of the upper lid to the

front of the eyeball. The cords acquire lateral branches and then become hollowed out to form the **secreting tubules** and **efferent ducts** of the gland, the **connective-tissue stroma** of which is contributed by the surrounding mesodermic tissue. The orifices of the adult efferent ducts in the upper outer part of the conjunctival sac correspond with the points from which the primitive cell-cords first grow forth.

The **efferent lacrimal apparatus**, consisting of the nasal or lacrimal duct and the canaliculi, is related genetically to the growth of the nose and the upper jaw. Soon after the appearance of the nasofrontal process, a lateral projection, the **lateral nasal process**, grows from its side near the base and advances downward so as to form the outer boundary of the nasal pit and consequently of the future nostril (Fig. 56, A, B). This lateral nasal process is separated from the maxillary process of the first visceral arch by an oblique furrow, the **naso-optic groove**, which extends from the inner angle of the orbit to the outer side of the nostril, or, before the separation of the nasal pit from the primitive mouth, to the upper boundary of the latter orifice. The naso-optic groove indicates the situation of the lacrimal duct. By some authorities—Coste and Kölliker—it is believed that the duct results from the union of the edges of the groove. Later investigations seem to indicate, however, that the duct is formed by the hollowing out of a solid cord of epithelial cells that appears at the bottom of the furrow. In either case the epithelial lining of the duct is an ectodermic involution. When the nostrils are separated from the oral aperture by the union of the nasofrontal, the lateral nasal, and the maxillary processes (p. 121), the lower end of the furrow is obliterated, and the partially formed duct is made to terminate in the nasal cavity.

The **canaliculi**, representing the bifurcated upper extremity of the duct, result, according to one view, from the division of the upper end of the epithelial cord into two limbs, one for each lid, and their subsequent hollowing-out; according to another, from the continuation of the cell-cord into the upper lid and the later addition of a limb for the

canaliculus of the lower lid. The lacrimal sac is merely an expanded part of the duct.

#### THE DEVELOPMENT OF THE ORGAN OF HEARING.

As in the case of the other sense-organs, the auditory apparatus consists of highly specialized neuro-epithelium, connected by nerve-fibers and interpolated ganglia with the central nervous system, and of protective and auxiliary structures. The neuro-epithelial structures, including the organ of Corti and the cells of the cristæ and maculæ acousticæ, result from the specialization of certain of the epithelial cells which line the membranous labyrinth. The perilymphatic space, which is a lymph-space, together with its bony walls, the osseous labyrinth, serve for the protec-

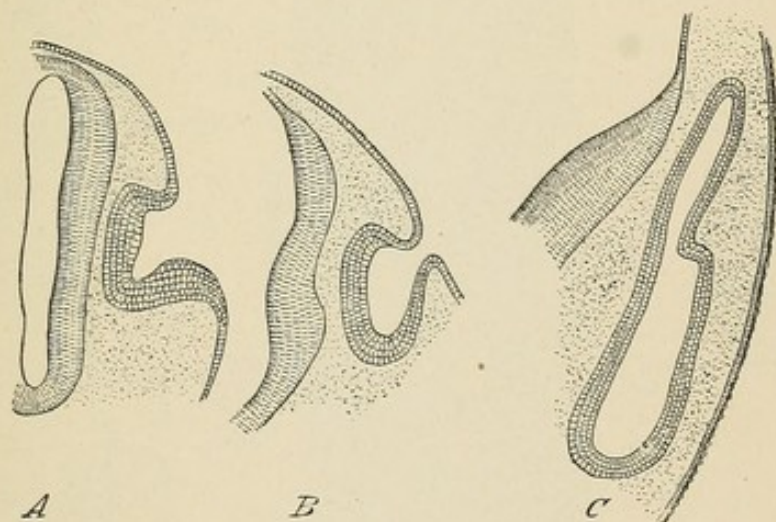


FIG. 150.—Three transverse sections showing development of otic vesicle of human embryo (Tourneux): *A*, from embryo of 3 mm., showing auditory pit; *B*, from embryo of 4 mm., showing the transformation of the pit into the otic vesicle; *C*, from embryo of 6 mm., showing otic vesicle detached from surface ectoderm, and presenting a posterior diverticulum, the recessus vestibuli.

tion of the delicate neural elements, while the middle ear and the external ear act as media for the conduction of sonorous vibrations.

The internal ear being the essential part of the organ of hearing and being also the part first formed may properly receive first consideration.

**The Internal Ear.**—The membranous labyrinth of the

internal ear is the oldest part of the organ of hearing. Its origin is from a thickened circular patch of ectoderm on the dorsolateral surface of the head-region of the embryo near the dorsal termination of the first outer visceral furrow. The thickened area sinks below the surface, forming thus the **auditory pit**, which is present in the third week (Fig. 150, A). The pit becomes deeper, its edges approach each other and finally meet and unite to form the **otic vesicle** or **otocyst**. This little epithelial sac gradually recedes from the surface ectoderm. At this stage of development there is no cranial capsule other than the indifferent mesodermic tissue which surrounds the brain-vesicles; hence, the otic vesicle, em-

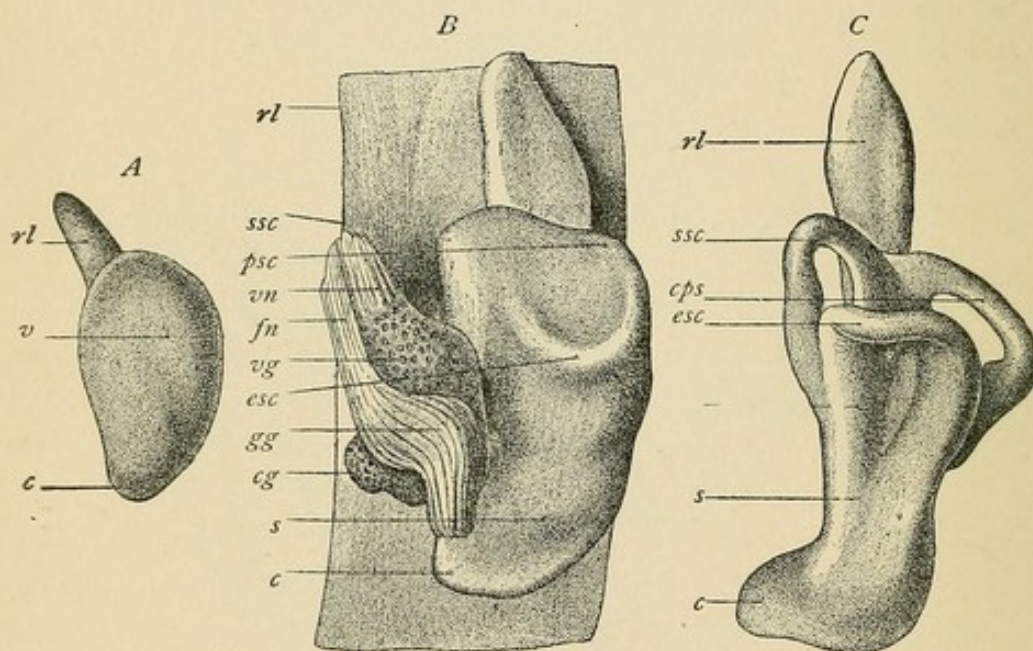


FIG. 151.—Development of the membranous labyrinth of the human ear (W. His, Jr.): A, left labyrinth of embryo of about four weeks, outer side; *vc*, vestibular and cochlear portions; *rl*, recessus labyrinthi. B, left labyrinth with parts of facial and auditory nerves of embryo of about four and a half weeks; *rl*, recessus labyrinthi; *ssc*, *psc*, *esc*, superior, posterior, and external semicircular canals; *s*, sacculus; *c*, cochlea; *vn*, *fn*, vestibular and facial nerves; *vg*, *cg*, *gg*, vestibular, cochlear, and geniculate ganglia. C, left labyrinth of embryo of about five weeks, from without and below; labelling as in preceding figure.

bedded in this tissue, lies in close proximity to the after-brain, and comes into relation with the acousticofacial ganglion (p. 297). The vesicle, at first spherical, soon becomes pear-shaped owing to the protrusion of its dorsal wall. This dorsal projection, the **recessus vestibuli** or **labyrinthi** (Fig.

150, *C*), lengthens out into a slender tube, the **ductus endolymphaticus** (Fig. 152), the slightly dilated end of which, the **saccus endolymphaticus**, is found in the adult occupying the aqueductus vestibuli of the temporal bone.

The opposite, anterior or ventral extremity of the otic vesicle also bulges out into a small evagination, which gradually elongates until it is a tapering tube, slightly curved inward toward the median plane. This lengthens still more and becomes spirally coiled, forming the **cochlear duct** or **scala media** of the future cochlea (Fig. 152). The vesicle itself becomes constricted in such manner by an inward projection of its wall as to indicate its division into an upper larger and a lower smaller sac, the terms upper and lower referring respectively to the head-end and the tail-end of the embryonic body. Before the constriction occurs, the wall of that part of the vesicle which is to become the future upper or **utricle division** presents two pouched-out areas (Fig. 151, *B*). One of these gives rise to the **external semicircular canal**, while from the other are formed the **superior** and **posterior canals**. The pouch that produces the external

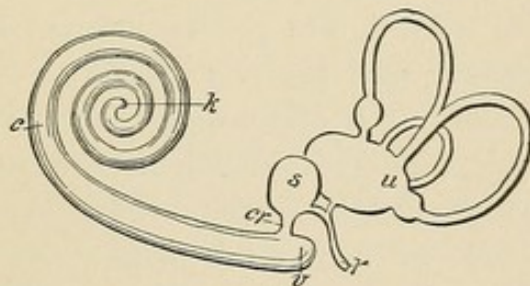


FIG. 152.—Diagram to illustrate the ultimate condition of the membranous labyrinth (after Waldeyer): *u*, utricle; *s*, sacculus; *cr*, canalis reuniens; *r*, ductus endolymphaticus; *c*, cochlea; *k*, blind sac of the cupola; *v*, vestibular blind sac of the ductus cochlearis.

canal is semicircular in form and flat, lying in the horizontal plane, its upper and lower walls being in contact with each other. The opposed walls fuse, except at the periphery of the pocket, and hence all that remains of its cavity is a small marginal tube or channel, corresponding with its border and opening at each end into the cavity of the vesicle. Throughout the region of fusion of the walls, the latter be-

come thin and finally disappear, being replaced by connective tissue. Thus a semicircular epithelial tube is formed, which is the **horizontal** or **external semicircular canal**. One end of the tube being dilated, the **ampulla** of the canal is produced.

The **superior** and **posterior semicircular canals** are formed in a somewhat similar manner by the other evaginated pouch or pocket, which is irregularly globular. To produce this result, the walls of the pocket contract adhesions throughout two regions, which correspond with the respective spaces enclosed by each of the two future canals in question. The fusion of the walls takes place in such manner as to leave two narrow channels or tubes, one of which almost encircles the inner or mesial aspect of the pocket, while the other bears the same relation to its posterior wall, the inner limb of the latter semicircle coinciding with the posterior limb of the former. The result of this arrangement is that two vertical semicircular canals are formed with their planes at right angles to each other, the two communicating with the otic vesicle by three openings, one of which is common to both canals. The other two apertures, being dilated, are the **ampullated individual orifices** of the **posterior** and **superior canals**.

The constriction in the otic vesicle referred to above increases until this sac is divided into two parts, a larger, which includes the region from which the semicircular canals have developed and which is now the **utricle**, and a smaller vesicle, the **sacculle**, comprising the part from which the cochlear duct was evaginated (Fig. 152). The line of division coincides with the middle of the orifice of the ductus endolymphaticus, the proximal end of which participates in the division. Thus the ductus endolymphaticus becomes a Y-shaped tube, and affords the only bond of connection between the sacculle and the utricle (Fig. 152).

The beginning of the cochlear duct, failing to keep pace in growth with the other parts, appears as a smaller tube relatively, and is known as the **canalis reuniens** (Fig. 152, *cr*).

The structures so far considered—the **utricle**, the **sacculæ**, the **semicircular canals**, and the **cochlear duct**—being the product of the ectodermic otic vesicle, represent simply the adult **epithelial linings** of those cavities. The **fibrous layer** of the membranous labyrinth, in common with the walls of the bony labyrinth, is a product of the enveloping mesodermic tissue. While the cells of the otic vesicle thus for the most part constitute the walls of the several sacs and canals of the primitive internal ear, some of the cells specialize into **neuro-epithelium**. The most marked specialization of this sort occurs in the cochlear duct, where most of the cells on that wall of the duct which may be called its floor—the part corresponding to the future *membrana basilaris*—undergo such profound modification in form as to produce the most highly specialized neuro-epithelial cells anywhere to be found, the elements that constitute the **organ of Corti**.

In the utricle and the sacculæ, as well as in the *ampullæ* of the semicircular canals, there is a similar but less marked specialization of epithelial cells to produce in the former case the **maculæ acusticæ**, and in the latter, the **cristæ acusticæ** of the *ampullæ*. While, therefore, the cells of the otic vesicle which are to serve as the lining mucous membrane of the membranous labyrinth become flattened polyhedral cells arranged as a single layer, those cells which are to functionate as the peripheral part of the acoustic mechanism become the specially modified columnar cells, many of them with cilium-like appendages, of the *maculæ*, the *cristæ*, and of the organ of Corti.

From the first the otic vesicle lies in close relation with the acusticofacial ganglion (Fig. 151, *B*). As pointed out in a preceding chapter (p. 297), this ganglion subsequently divides into two parts, corresponding with the two divisions of the auditory nerve. This division of the ganglion and of the nerve is correlated with the separation of the otic vesicle into a cochlear part, the **cochlear duct**, and the two vestibular vesicles, the **sacculæ** and the **utricle**. While the cochlear duct is still a short, slightly curved tube, the cochlear part of the ganglion lies in close proximity to the tube, in the concavity

on its inner side. As the duct lengthens and becomes more coiled, the ganglion likewise lengthens into a band which follows the spiral course of the duct, lying parallel with the latter and on the side toward the axis about which it is coiled. After the formation of the bony parts of the cochlea, this ganglion occupies the spiral canal of the modiolus and is known as the **ganglion spirale**. It belongs to the cochlear division of the auditory nerve, which is distributed to the cochlea.

The remaining part of the acoustic ganglion becomes rather widely separated from the spiral ganglion, coming to occupy a position in the internal auditory meatus, and the part of the auditory nerve with which it is connected acquires relation with the macular regions of the utricle and saccule as well as with the cristæ of the ampullæ of the semicircular canals. These nerve-fibers constitute the vestibular division of the auditory nerve, while the ganglion is the **vestibular ganglion** or **intumescencia ganglioformis** of Scarpa.

The development of the bony labyrinth of the internal ear, as well as of the connective-tissue parts of the membranous labyrinth, is effected solely by the differentiation of the mesodermic tissue which surrounds the epithelial structures above considered. As previously stated, at the time when the otic vesicle is first formed there is no indication of a cranial capsule, the brain-vesicles being surrounded and separated from the ectoderm by indifferent mesodermic cells. During the progress of the alterations in the otic vesicle, this tissue undergoes condensation and alteration to form the membranous primordial cranium, and shortly thereafter the petrous portion of the temporal bone is outlined in cartilage by the further specialization of a portion of this primitive connective tissue. The formation of cartilage does not affect all of the tissue which is afterward represented by the petrosa, the region that borders the semicircular canals, the cochlear duct, the saccule, and the utricle remaining soft embryonal connective tissue. There is thus a **cartilaginous ear-capsule** produced which is more than large enough to contain the primitive epithelial labyrinth, and the walls of

which are separated from the latter by embryonal connective tissue.

The **bony semicircular canals** are almost exact reproductions, on a larger scale, of the epithelial canals, and they are formed by the ossification of the cartilaginous petrosa. Even before this ossification occurs the soft connective tissue between the cartilage and the epithelial semicircular canals differentiates into **three layers**. The **inner layer**, becoming more condensed, is converted into fibrous tissue, and, adhering to the epithelial walls of the canals, furnishes the connective-tissue component of the completed membranous canals. Its blood-vessels serve for the nutrition of the canals. The **outer layer** also undergoes condensation and forms a fibrovascular membrane, the **perichondrium**, which later becomes the **internal periosteum** of the bony canals. The **middle layer**, on the contrary, becomes softer—by the liquefaction of the intercellular substance and the degeneration of the cells—so that gradually increasing, fluid-filled cavities make their appearance, and these latter becoming larger and many of them coalescing, a space is formed around the membranous canals which is filled with fluid, the **perilymph**. This **perilymphatic space** is bridged across at intervals by connective-tissue processes that serve for the conveyance of blood-vessels to the membranous canals.

The **vestibule** of the internal ear is formed in practically the same manner as the bony semicircular canals, the epithelial saccule and utricle acquiring their connective-tissue constituents in the same way. There is the difference, however, that the bony vestibule does not conform to the shape of the vestibular parts of the membranous labyrinth, since it is a single undivided cavity enclosing the two little vesicles, the saccule and the utricle.

The **bony cochlea**, while developed upon the same general plan as the other parts of the bony labyrinth, presents certain conspicuous modifications. The epithelial cochlear duct, as stated above, in its early stage is a short, tapering, and slightly curved tube. While it is still in this condition, chondrification of the petrous bone occurs, whereby the

duct acquires its **cartilaginous capsule** (Fig. 153, *kk*). This capsule is open at the proximal end of the duct and through this opening the cochlear branches of the auditory nerve gain access to the capsule, being connected with the cochlear division of the auditory ganglion, which, owing to its previously having assumed a position beside the duct, comes to be enclosed by the capsule as the latter is formed (Fig. 153, *nc*, *gsp*). It is only after the chondrification that the cochlear duct lengthens out and becomes spirally

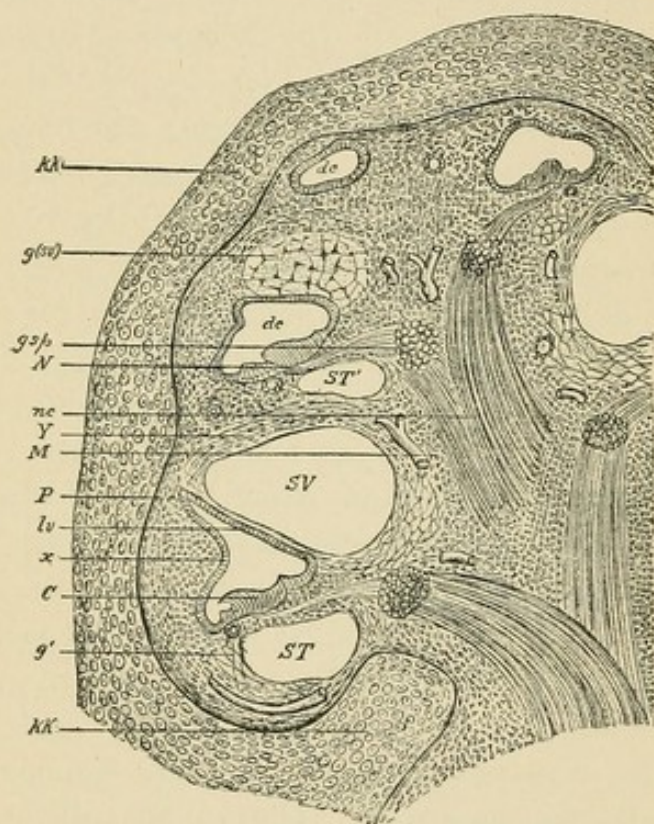


FIG. 153.—Part of a section through the cochlea of an embryo cat, 9 cm. (3.6 in.) long (after Boettcher): *kk*, cartilaginous capsule, in which the cochlear duct describes ascending spiral turns; *dc*, ductus cochlearis; *c*, organ of Corti; *lv*, lamina vestibularis; *x*, outer wall of the membranous ductus cochlearis with ligamentum spirale; *SV*, scala vestibuli; *ST*, *ST'*, scala tympani; *g*, gelatinous tissue, which still fills the scala vestibuli (*sv'*) in its last turns; *g'*, remnant of the gelatinous tissue, which is not yet liquefied; *M*, firm connective tissue surrounding the cochlear nerve (*nc*); *gsp*, ganglion spirale; *N*, nerve which runs to Corti's organ in the future lamina spiralis ossea; *Y*, compact connective-tissue layer, which becomes ossified and shares in bounding the bony cochlear duct; *P*, perichondrium.

coiled. The coiling is in such manner that the cochlear nerve is surrounded by the duct—that is, it lies in the axis

about which the duct is spirally wound. Within the cartilaginous capsule, filling all the space not occupied by the spirally coiled duct and the cochlear nerve with its lengthened-out ganglion, is the embryonic connective tissue of which formerly the entire cartilaginous petrosa consisted. The cochlea consists now of a spirally coiled epithelial tube lying within an elongated cavity in the cartilaginous petrosa, a cavity, the walls of which are, therefore, cartilaginous. The peripheral wall of the coiled tube is in contact with the inner surface of the wall of the cartilaginous capsule (Fig. 153, *x*), a fact which has an important bearing upon the further stages of growth.

The embryonal connective tissue within the capsule now undergoes important modifications, which vary greatly in different regions. That portion of this tissue which immediately envelopes the cochlear nerve becomes first dense connective tissue, which is afterward directly converted into bone, constituting the **modiolus**, or axis, of the cochlea. The processes of condensation and subsequent ossification extend outward from the modiolus in a spiral line, which corresponds with the intervals between the successive turns of the cochlear duct, until they meet the wall of the original capsule, thus producing the **bony cochlea**. That is, by the development of this spiral plate and its connection internally with the modiolus and externally with the wall of the capsule, a tube at first partly membranous and partly cartilaginous, and at a later stage osseous, is produced, which encloses the much smaller cochlear duct, and like it is wound spirally around the modiolus. To repeat, the original *simple cavity* of the cartilaginous capsule is subdivided by the growth of the modiolus and of the spiral shelf in such manner as to become a *spirally coiled tube*.

The **cochlear nerve**, enclosed within the coil of the cochlear duct, sends branches (Fig. 153, *N*) in a continuous spiral line to the duct, and the soft tissue surrounding and supporting these branches condenses to form a **connective-tissue plate** which extends outward from the modiolus to the cochlear duct and which, therefore, has a spiral course

about the modiolus, its entire inner edge being attached to that central axis, while its outer border is, throughout its entire extent, in continuity with the inner wall of the duct. At a later stage this spiral plate undergoes direct ossification to form the two lamellæ of the **bony lamina spiralis**. Thus it is that the ganglion spirale and the successive terminal branches of the cochlear nerve come to be enclosed within the spiral lamina. Recalling the condition of the cochlea before the growth of the spiral lamina, it will be seen that the latter, in connection with the epithelial cochlear duct, divides the tube into two parts (Fig. 153, *SV*, *ST*). It will be evident, too, that the epithelial cochlear duct now holds a relation to the larger tube of the future bony cochlea which is similar in principle to the relation of the membranous semicircular canals to the bony canals, but with the difference that the outer wall of the epithelial duct is in close contact with the outer wall of the future bony canal at *x*, and that the inner walls of the two are connected by a spiral plate, the lamina spiralis.

The cochlear duct, then, is surrounded by undifferentiated mesodermic tissue, except on the side farthest from the modiolus, where its wall is in contact with and finally adheres to the wall of the cartilaginous capsule. The lamina spiralis divides this tissue into two parts which respectively occupy the positions of the future **scala vestibuli** and **scala tympani**. This soft embryonal tissue, as in the case of the corresponding tissue of the semicircular canals, develops differently in different regions. The **innermost stratum**, which is in relation with the epithelial cochlear duct, becomes fibrous connective tissue and constitutes the **fibrous layer** of the adult cochlear duct; that is, on the side of the duct toward the scala tympani, it becomes the connective-tissue layer of the **membrana basilaris**, while on the side toward the scala vestibuli it forms the fibrous stratum of the **membrane of Reissner** (Fig. 153). The peripheral zone of indifferent tissue, that in contact with the now cartilaginous wall of the future bony cochlea, as well as that which lies against the lamina spiralis, also undergoes condensation and forms a fibrous,

or fibrovascular, membrane, the **internal perichondrium** or future **periosteum**. The tissue intervening between these two layers retrogrades, the cells degenerating and the intercellular substance liquefying, until finally the spaces known as the **scala vestibuli** and the **scala tympani** are hollowed out. These channels are lymph-spaces and the fluid they contain is the **perilymph**. This **perilymphatic space** is in communication with that of the vestibule. Therefore, while the cochlear duct or scala media encloses an **epithelium-lined space**, as do the saccule, the utricle, and the membranous semicircular canals, and in common with those structures contains the so-called **endolymph**, the scala vestibuli and the scala tympani are in the same category with the perilymphatic spaces of the other parts of the internal ear.

**The Middle and the External Ear.**—The middle ear, consisting of the tympanic cavity and the Eustachian tube, is developed from the back part or dorsal end of the **first inner visceral furrow**. The **external ear**, comprising the external auditory meatus and the auricle, comes from the dorsal extremity of the first outer furrow and the tissue about its margins, the **tympanic membrane** representing in part the closing membrane which separates the inner furrow from the outer.

The first inner visceral furrow, in common with the other inner furrows, is an evagination of the lateral wall of the primitive pharyngeal cavity, or head-end of the gut-tract. The ventral end of this groove suffers obliteration, but the dorsal segment, designated the **tubotympanic sulcus**, becomes converted into a tube by the growing together of its edges. The tube is composed therefore of entodermic epithelial cells. It elongates in the dorsal and outward direction, and its dorsal extremity becomes enlarged to produce the cavity of the **tympanum**, the remaining part of the canal becoming the **epithelial lining of the Eustachian tube**. The canal being formed before the development of the cranium, and approximately its posterior half being surrounded by the mesodermic embryonal connective tissue that afterward becomes the petrosa of the temporal bone, the

tympanic cavity and a part of the Eustachian tube come to be enclosed within that bone, while the connective tissue encasing the anterior part of the tube differentiates into the curved plate of cartilage that forms the cartilaginous part of the **Eustachian tube**.

Since the posterior end of the primitive epithelial tube insinuates itself between the otic vesicle and the surface, the tympanum comes to occupy its normal position on the outer side of the internal ear. The tympanum, being derived from the back part of the first visceral cleft, is in close relation with the first and second visceral arches, and the **ossicles** of the middle ear are derived from the dorsal extremities of the cartilaginous bars of these arches in the manner described in Chapter XVIII. Necessarily the primitive ossicles are exterior to the primitive epithelial tympanic sac, as is also the chorda tympani nerve, which passes along its outer side. After the ossification of the temporal bone, these structures are embedded within the abundant soft connective tissue which is between the epithelial sac, now the **mucous membrane**, and the bony walls of the tympanum. This mass of soft tissue undergoes very considerable diminution, owing to which the mucous membrane comes into contact with the bony walls, and as a result the ossicles and the chorda tympani are enclosed in folds of the mucous membrane and seem to lie within the tympanic cavity. They are excluded, however, from the true cavity of the tympanum, since they are exterior to the epithelial or mucous-membrane layer.

The **external auditory meatus** is simply the persistent posterior part of the first outer visceral furrow or hyomandibular cleft (see pp. 101, 105), this cleft closing completely everywhere but in this region. The **closing plate** of the first cleft becomes the **tympanic membrane**. Hence the **outer layer** of this membrane is of ectodermic origin, while the **inner layer** is entodermic, being continuous with the epithelial tympanic lining, and the **middle fibrous layer** is derived from the mesoderm. The relation of the malleus to the membrane and of the latter to the bony tympanic plate

which forms part of the wall of the meatus is dealt with in the chapter on the development of the skeleton.

The **auricle** is derived from the tissue around the margin of the unclosed back part of the first outer cleft (Fig. 155, C). Six little elevations make their appearance here, the projections being mesodermic tissue covered with ectoderm. The mesodermic component of the elevations differentiates into the cartilaginous and other connective-tissue parts of the auricle. The nodules marked 2 and 3 in Fig. 154 becoming a continu-

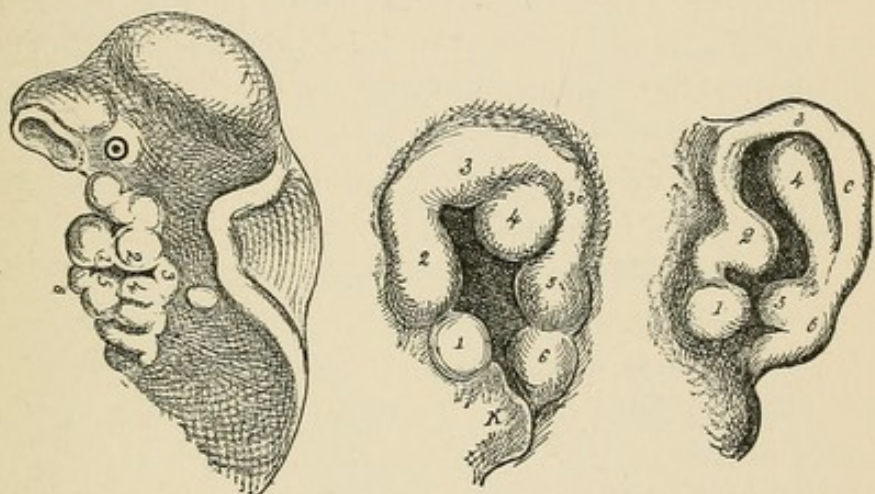


FIG. 154.—Showing the gradual development of the parts of the external ear from prominences upon the mandibular and hyoidian visceral arches (His), variously magnified: 1, 2, prominences on mandibular arch; 3, prominence between the two arches, prolonged posteriorly in second figure to 3c; 4, 5, and 6, prominences on hyoidian or second visceral arch; K, lower jaw. Prominence 1 forms the tragus; 2, 3, 3c, the helix; 4, the antihelix; 5, the antitragus; 6, the lobule.

ous ridge, produce the **helix**, while nodule 4 becomes the **anti-helix**. The **tragus** and **antitragus** develop respectively from the projections 1 and 5. At the end of the second month, these parts are so far advanced as to be easily distinguishable, and the connective-tissue basis of the ridges and projections and the continuous plate-like mass to which they all are attached begin to undergo chondrification. From the third month onward, this primitive auricle, by continued growth and greater separation from the side of the head, assumes more and more the characters of the fully formed member. The **lobule**, however, which results from the growth of the little elevation marked 6, lags behind the other parts in development and is rather indistinct until the

fifth month, after which time it increases in size and gradually acquires its normal proportions.

### THE DEVELOPMENT OF THE NOSE.

The nose is primarily a special sense-organ, although a part of its cavity serves, in air-breathing vertebrates, as an adjunct to the respiratory system. The evolution of the mature organ of smell may be epitomized by the statement that the **olfactory epithelium**, the essential part of this sense-organ, is a patch of depressed or infolded ectoderm, the cells of which are highly specialized and are brought into relation with the central nervous system by means of the outgrowth from the latter of a part of its mass, the olfactory lobe.

Very early in intra-uterine life—before the end of the third week—the **olfactory plates** appear as localized thickenings of the ectoderm situated just in front of or above the oral fossa. These **nasal areas** are the forerunners of the future **olfactory epithelium**. It is worthy of note that the olfactory plates are in very close relation with the primary fore-brain vesicle, being, in reality, on the outer surface of the ectodermic covering of its ventral wall.

Owing to the rapid outgrowth of the surrounding tissue, the olfactory plates become relatively depressed, constituting now the **nasal pits**, which are distinguishable at about the twenty-eighth day. The pits are separated from each other by a broad mass of tissue, the **nasal** or **nasofrontal process** (Fig. 155), which is, as it were, a localized thickening of the mesodermic tissue on the ventral wall of the primary fore-brain vesicle; and this process makes its appearance in the third week. During the fifth week the nasofrontal process thickens greatly along its lateral margins, the thick edges being known as the **globular processes** (Fig. 155, A, B). At the same time the **lateral nasal processes** bud out from the nasofrontal process, one on each side, above the nasal pits, and, growing downward, form the external boundaries of the pits, each of which depressions is bounded on its inner side by the corresponding globular process. The nasal pits, therefore, have well-marked

walls on every side except below, where they are directly continuous with the oral fossa.

In the latter end of the sixth week the nasofrontal process, which, it will be remembered, constitutes the upper

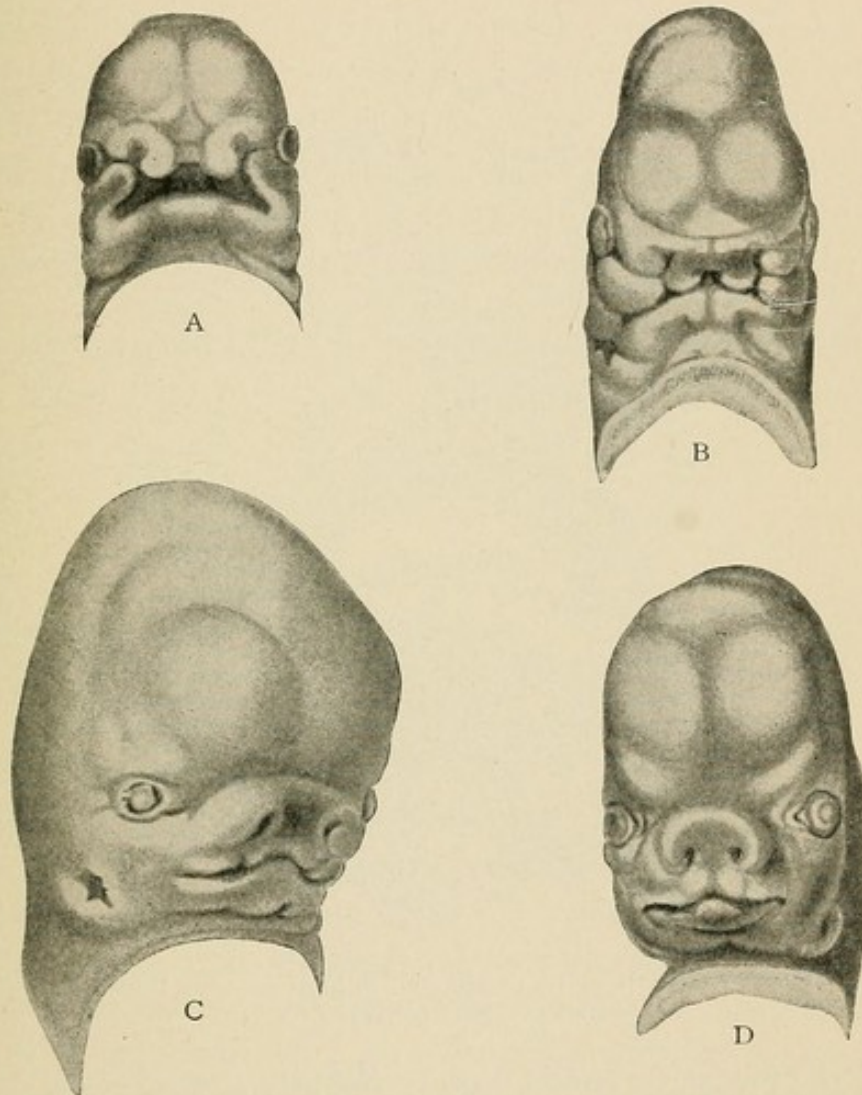


FIG. 155.—Development of the face of the human embryo (His): A, embryo of about twenty-nine days. The nasofrontal plate differentiating into processus globulares, toward which the maxillary processes of first visceral arch are extending. B, embryo of about thirty-four days: the globular, lateral frontal, and maxillary processes are in apposition; the primitive opening is now better defined. C, embryo of about the eighth week: immediate boundaries of mouth are more definite and the nasal orifices are partly formed, external ear appearing. D, embryo at end of second month.

limit of the oral fossa, is joined on each side by the united maxillary, and lateral nasal, processes. This effects a division between the oral fossa and the nasal pits, and forms,

though as yet crudely, the **external nose**, and the upper lip as well. The definite formation of the external nose may be said to be indicated about the *eighth week*. The orifices of the nasal pits are now the **anterior nares**, while the pits themselves have become short canals, opening by their deep orifices, the **posterior nares**, into the primitive mouth-cavity above the palatal shelves. The nares are separated from each other by the still broad nasofrontal process. That portion of the nasofrontal process that separates the nares gradually becomes thinner and produces the septum of the nose, while its external or superficial part gives rise to the bridge and tip of the organ.

The growth of the **palate-shelves** (Fig. 156) toward the median line, resulting in their union with each other and

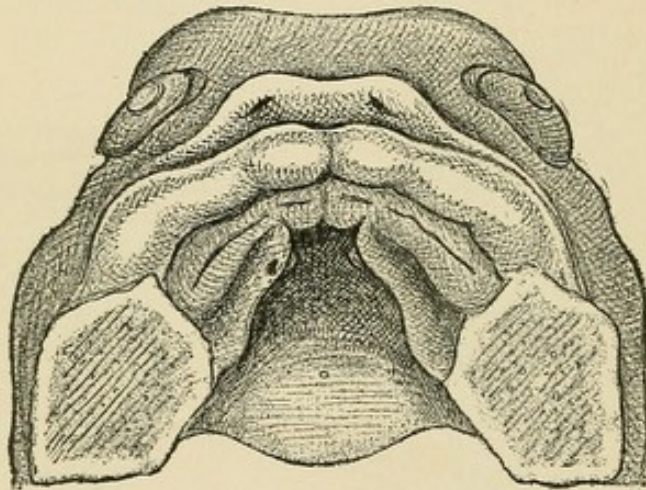


FIG. 156.—Roof of the oral cavity of a human embryo with the fundamentals of the palatal processes (after His),  $\times 10$ .

with the recently-formed septum, definitely divides the nasal chambers from the cavity of the mouth, the posterior nares now opening into the pharynx. This separation is completed toward the end of the third month.

The complexity of the adult **nasal cavities** is produced by the formation of ridges and pouches on the lateral walls of the original nasal pits. Three inwardly projecting horizontal folds of the ectodermic lining of the cavity, the **superior, middle, and inferior turbinal folds**, appear upon the outer wall of each nasal fossa (Fig. 157). Each fold contains a stratum

of mesodermic tissue which develops into cartilage and subsequently into bone, forming respectively the **three turbinated bones**. The cartilaginous character of these folds becomes apparent at the end of the second, or the early part of the third, month. An evagination on the lateral wall of each

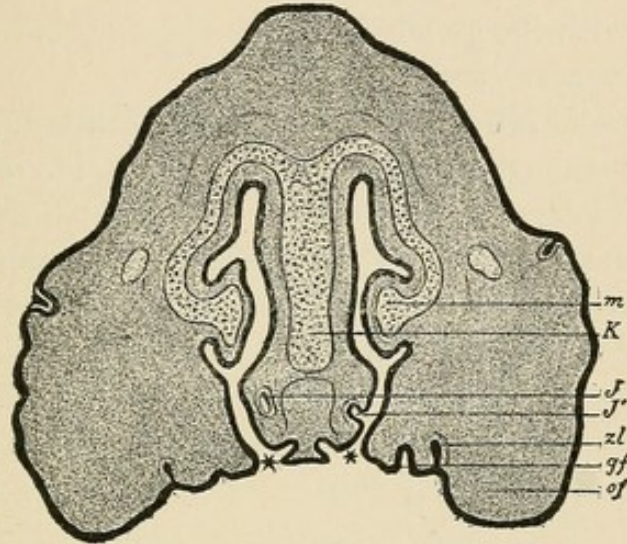


FIG. 157.—Cross-section through the head of an embryo pig 3 cm. (1.2 in.) long, crown-rump measurement. The nasal cavities are seen to be in communication with the oral cavity at the places designated by a \*: *K*, cartilage of the nasal septum; *m*, turbinal cartilage; *J*, organ of Jacobson; *J'*, the place where it opens into the nasal cavity; *zf*, palatal process; *of*, maxillary process; *zl*, dental ridge (Hertwig).

nasal fossa, between the middle and the inferior turbinal processes, becomes the **antrum of Highmore**; this is formed in the sixth month. Other evaginations produce the **ethmoidal**, the **frontal**, and the **sphenoidal sinuses**, the last two of which are not completed, however, until after birth. Very early in the development of the nose a small invagination appears on the mesial wall of the nasal pit. In the fourth month of gestation this invagination has become a canal in the septum (Fig. 157, *J*), running from before backward and ending in a blind extremity. It is the so-called **organ of Jacobson**, which, in man, is merely a rudimentary structure, but which, in most other mammals, is more highly developed, being surrounded by a cartilaginous capsule and receiving a special nerve-supply from the olfactory nerve.

The **olfactory plates** become separated from the fore-brain vesicle and consequently from the later brain and its out-

growth, the olfactory bulb, by the development of an intervening bony plate, the cribriform lamina of the ethmoid bone. The ectodermic cells of the olfactory plates differentiate into the highly specialized **neuro-epithelial** elements of the olfactory mucous membrane and their associated **supporting cells**. The neurites of the neuro-epithelial cells, assuming relationship with the glomeruli of the olfactory bulb, constitute the **olfactory nerve-fibers**.

The external nose, as previously stated, first acquires definite form about the eighth week by the union of the distal ends of the lateral nasal processes with the nasofrontal process, the former producing the **alæ** and the latter the **bridge** and the **tip** of the nose. In the third month the organ is unduly flat and broad, but from this time on it gradually assumes the familiar characteristic form. From the third month to the fifth each external naris is closed by a gelatinous plug of epithelial cells.

## CHAPTER XVII.

### THE DEVELOPMENT OF THE MUSCULAR SYSTEM.

#### THE STRIATED OR VOLUNTARY MUSCLES.

THE voluntary muscular system, genetically considered, is divisible into (1) the muscles of the trunk and (2) those of the extremities. The muscles of the trunk include two distinct sets: (a) the muscles of the trunk proper, or the **skeletal muscles**, and (b) the muscles of the visceral arches or the **branchial muscles**.

To arrive at a proper comprehension of the evolution of the muscular system it is necessary to revert to an important fundamental embryological process, the **segmentation of the body of the embryo**, or, as it is sometimes expressed, the segmentation of the **cœlom**, or body-cavity. As pointed out in Chapter IV., this process of segmentation occurs in all vertebrate animals and in some invertebrates.

**The Muscles of the Trunk Proper.**—At a very early stage of development the tracts of mesodermic tissue situated one on each side of the median longitudinal axis of the future embryonic body, the paraxial mesodermic tracts, undergo division or segmentation, in lines transverse to the long axis, into a series of pairs of irregularly cubical masses of mesodermic cells. These masses are the **mesoblastic somites** or **primitive segments**, often inappropriately called the protovertebræ. The somite **first** formed corresponds with the future occipital region, the **second** one lies immediately in front of the first, while **two** others, situated still more anteriorly, that is, near the cephalic end of the embryonic area, and **seven** more, behind the first, are added almost simultaneously. The formation of the primitive segments

then proceeds tailward until a considerable number have been added. Those in front of the one first formed are denominated the **head-segments**, while the others are known as the **trunk-segments**. Each somite is at first triangular in cross-section, the base of the triangle looking toward the chorda dorsalis. Subsequently they assume a more cuboidal shape. In the lower vertebrates—amphibians and fishes—the somite is hollow, its cavity being in these cases a constricted-off portion of the body-cavity (hence the term “seg-

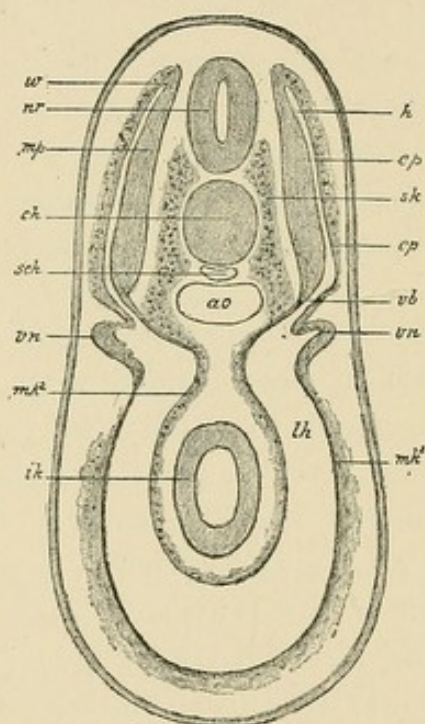


FIG. 158.—Cross-section through the region of the pronephros of a selachian embryo in which the muscle-segments (myotomes) (*mp*) are in process of being constricted off. Diagram (after Wijhe): *nr*, neural tube; *ch*, chorda; *ao*, aorta; *sch*, subnotochordal rod; *mp*, muscle-plate of the primitive segment; *w*, zone of growth where the muscle-plate bends around into the cutis-plate (*cp*); *vb*, tract connecting the primitive segment with the body-cavity, out of which are developed, among other things, the mesonephric tubules; *sk*, skeletogenous tissue which arises by a proliferation from the median wall of the connecting tract *vb*; *vn*, pronephros; *mk*<sup>1</sup>, *mk*<sup>2</sup>, parietal and visceral middle layer, from whose walls mesenchyme is developed; *lh*, body-cavity; *ik*, entoblast.

mentation of the cœlom” to express this process). In the higher vertebrates, however, the cavity is obliterated by the encroachment of the cells of the walls of the somite.

The cells of the somites soon undergo differentiation and rearrangement. It is usually stated that, preparatory to the

segmentation of the paraxial mesodermic tract, this tract has become separated from the remaining lateral plate of the mesoderm. The separation is not complete, however, and therefore, after the appearance of the primitive segments, each segment is connected with the more laterally placed lateral plate—by the separation of which latter into two lamellæ the cœlom is formed—by a smaller mass of tissue, the **nephrotome**, also called the **middle plate**, or **intermediate cell-mass** (Fig. 158, *vb*). As development progresses the distinction between the primitive segment proper and the nephrotome becomes more sharply expressed, and the former is designated the **myotome**. The primitive segment on its mesial surface, near the point of union with the nephrotome, sends forth cells which form a mass called the **sclerotome** (Fig. 158, *sk*). The sclerotomes spread out and blend with each other, forming a continuous mass of tissue which envelops the chorda and the neural canal, and which, being concerned in the production of the permanent vertebræ, has no further interest in this connection.

What remains of the primitive segment after the formation of the nephrotome and of the sclerotome is the myotome proper or the **muscle-plate**. Although, as previously stated, the primitive segments of the higher vertebrates contain no cavity, the myotome and the nephrotome each enclose a space, that belonging to the former being known as the **myocœl**. The myotomes or muscle-plates are so called because they give rise to the voluntary musculature of the trunk. But not all of the cells of the muscle-plate undergo transformation into muscular tissue. While the cells on the mesial or chordal side of the myocœl are going through certain alterations preparatory to their metamorphosis, the cells nearer the body-wall become rearranged to form a characteristic layer which is known as the **cutis-plate** from the fact that it contributes to the formation of the corium of the skin (Fig. 158, *cp*). The cutis-plate and the remaining part of the muscle-plate are continuous around the myocœl, the transition from one to the other being more or less gradual. To summarize, the primitive segment is differentiated

into the **nephrotome**, the **sclerotome**, the **myotome** or **muscle-plate**, and the **cutis-plate**.

**The Metamorphosis of the Muscle-plate.**—By the term *muscle-plate* is meant here the thickened layer of cells on the chordal or mesial side of the myotome proper, which layer constitutes what remains of the myotome after the differentiation of the cutis-plate. These cells having proliferated and increased in size, and having encroached thereby upon the cavity of the myotome, next undergo alteration in shape, becoming cylindrical, with their long axes parallel with that of the body of the embryo. The length of each cylindrical cell equals the thickness of the primitive segment, at least in the Amphibia and probably also in the chick. The next step in the transformation is the acquisition of the **transverse striation** characteristic of vertebrate voluntary muscle. Soon after this the protoplasm of the cell undergoes longitudinal division into minute **fibrillæ**—which latter do not necessarily correspond, however, with the primitive fibrillæ of mature muscle—and the cell-nucleus likewise divides. The metamorphosis of the now fibrillated protoplasm into muscular tissue is first completed at the periphery of the fiber, so that a young muscle-fiber contains a central core of undifferentiated material, including the daughter-nuclei resulting from the division of the original nucleus. Soon after the appearance of striation and the fibrillation of the fiber, the fibers begin to separate from each other, and developing connective tissue with young blood-vessels penetrates between them, the fibers now showing aggregation into bundles. For some time longer the fibers are naked, since the sarcolemma is not acquired until considerably later. The differentiation into muscular tissue gradually extends from the periphery of the fiber to its core, the process being complete in the human embryo at about the end of the fifth month for the muscles of the upper extremities and in the seventh month for those of the lower. The embryonic muscle-fibers are smaller than the mature elements and increase in size until the third month.

It is considered highly probable by most embryologists

that muscle-fibers undergo **multiplication** during embryonic life. There are several theories as to the method of this multiplication. The most generally accepted view is that put forth by Weismann, the essential feature of which is that the fibers multiply by longitudinal division or fission. Reference was made above to the repeated division of the nucleus of the cell as one of the initiatory steps in the formation of the muscle-fiber. According to the fission theory, there is one class of fibers in which the nuclei are arranged in a single row, and the fibers of this class do not undergo fission; while there is another class, the fibers of which have their nuclei arranged in several rows. Fibers of the latter type divide longitudinally into as many daughter-fibers as there are rows of nuclei.

Although many of the details of the development of the muscular system are still involved in obscurity, it is a generally accepted fact that **each fiber** is derived from a **single cell**, the protoplasm of which develops the function of contractility to the subordination of the remaining vital properties of protoplasm. With this specialization of function there is necessarily a concomitant alteration of structure.

The muscular mass resulting from the transformation of each myotome grows in the ventral direction between the ectoderm and the parietal leaf of the mesoderm, or in other words into the somatopleure, to produce the muscular structures of the **ventrolateral body-wall**. It grows also and to a greater extent in the dorsal direction, covering, and acquiring points of attachment to, the vertebral column, which has meanwhile been forming. In addition to the ventral and dorsal extension of the muscle-plates, each one grows both forward and backward—cephalad and caudad—in such manner that overlapping and intermingling result.

What has been said above concerning the evolution of the **trunk-musculature** from the primitive segments refers to those muscles that are developed from the **segments of the trunk**. As to the evolution of the **head-segments** comparatively little is definitely known. It is generally accepted that in elasmobranchs—a group including sharks and rays—

there are **nine** primitive segments in the region of the future head. The number present in mammalian embryos has not been clearly worked out. In the lower vertebrates each segment contains a cavity lined with flattened cells, the mesothelium, the metamorphosis of which into muscular tissue may be inferred to be essentially as already outlined above. The **first head-segment**, which lies in contact with and partially envelops the optic vesicle, gives rise to the superior rectus, the inferior rectus, and the inferior oblique muscles of the eyeball; the **second segment** produces the superior oblique, and the **third**, the external rectus. The **fourth, fifth, and sixth segments** abort and hence produce no adult structures; while the **seventh, the eighth, and the ninth segments** become metamorphosed into the muscles that connect the skull with the shoulder-girdle.

From recent studies<sup>1</sup> it would appear that individual muscles undergo peculiar and significant migrations during their development, and that the origin of the nerve-supply of a muscle indicates the location of the particular myotome or myotomes from which it originated, since the segmental nerves are connected with their respective myotomes and supply the muscles derived from such myotomes. For example, the serratus magnus, being innervated by branches of the cervical nerves, develops from myotomes in the neck region, and subsequently moves down to become attached to the scapula and the ribs.

**The Branchial Muscles.**—This term embraces the muscles of mastication and the various muscles connected with the hyoid bone, with the jaws, and with the ossicles of the middle ear. They result from the metamorphosis of the **mesothelium of the visceral arches** and acquire connections with structures that have arisen from the so-called mesenchymal cells of these arches or, in other words, from the embryonal connective tissue which makes up the chief part of their bulk. For an account of the growth of the visceral arches the reader is referred to Chapter VII. From this

<sup>1</sup> See "Development of the Ventral Abdominal Walls in Man," Franklin P. Mall, *Johns Hopkins Papers*, vol. iii., 1898.

account and from that found in Chapter IV., it will be seen that the formation of the visceral arches and clefts is in reality the segmentation of the ventral mesoderm of the head-region of the embryo, or to express it in another way, it is the segmentation of the ventral cœlom of that region. It is interesting to note that whereas in the trunk the segmentation of the mesoderm is restricted to the dorsal part of the body, in the head-region the ventral mesoderm also participates in the process. Hence the visceral arches, as might be expected, consist of so many masses of mesodermic tissue, each arch containing a small cavity lined with mesothelium, which cavity is a constricted-off part of the body-cavity or cœlom. It is these mesothelial cells that produce, by their differentiation, the muscles under consideration. While so much concerning the origin of this group of muscles is practically assured by observations upon the embryos of the lower vertebrates, the details are still obscure. His assumes the origin of the **palatoglossus**, the **styloglossus**, and the **levator palati** from the second or hyoid arch; of the **stylopharyngeus**, perhaps the **palatopharyngeus**, the **hyoglossus** and the **superior constrictor of the pharynx** from the third arch; and of the **middle and inferior pharyngeal constrictors** from the fourth arch. Further, it is held by Rabl that the muscles of the face, including those of the scalp and the platysma—the **muscles of expression**—originate from the mesothelium of the hyoid arch in the form of a thin superficial sheet, which, gradually spreading out from the place of origin, breaks up into the individual muscles.

**The Muscles of the Extremities.**—Of the development of these there is little to be said. Enough is known of the development of the limb-muscles to establish two important facts: that these muscles develop as buddings from the muscle-plates of the trunk, and that the muscles of each extremity arise not from one but from several myotomes, the exact number being uncertain. The observations have been chiefly upon selachians (sharks, etc.), and in these embryos each myotome gives off two buds, each of which

divides into two others, while the main part of the myotome continues its growth into the somatopleure.

#### THE INVOLUNTARY OR UNSTRIATED MUSCULAR TISSUE.

This variety of muscular tissue, like that considered above, is of mesodermic origin. But while the voluntary muscles arise from the flattened or mesothelial cells of the primitive segments, **involuntary muscle** results from the transformation of the embryonal connective-tissue elements, the **mesenchymal cells**, of the mesoderm. It is for this reason that some authors speak of the voluntary muscles as the **mesothelial muscles** and designate the involuntary muscular tissue as **mesenchymal muscle**.

While it is a generally accepted fact that each of the fiber-cells which make up unstriated muscle is a metamorphosed mesenchymal or connective-tissue cell, the details of the process have not been accurately worked out. One may assume that necessarily the young connective-tissue cell elongates and that its protoplasm must undergo such differentiation as will fit it for the exercise of its future function, contractility.

#### THE CARDIAC MUSCLE.

The account of the development of the heart-muscle will be found in Chapter X.

## CHAPTER XVIII.

### THE DEVELOPMENT OF THE SKELETON AND OF THE LIMBS.

ALTHOUGH the skeleton is the framework of the body in the anatomical or mechanical sense, it is not so embryologically, since its development is not begun, at least not to any important extent, until nearly all the principal organs are well differentiated, and its growth is largely subsidiary to that of the structures which, in the mature state, it supports and protects. Morphologists speak of the **exoskeleton** and the **endoskeleton**, the former having reference to the hard structures found superficial to the soft parts, for whose protection they serve, such as the carapace of the lobster, and the hard scales of certain fishes; while the latter term signifies the cartilaginous or bony structures found within the bodies of most vertebrate animals. Even in the highest vertebrates, certain bones, such as those of the vault of the cranium, are usually considered by morphologists as being the representatives of part of the exoskeleton of lower types.

The **skeleton**, using the word in its ordinary sense, consists of the **axial skeleton** and the **appendicular skeleton**, or skeleton of the limbs. The former, including the head and the trunk, is common to all vertebrates; the latter is not found in the lowest members of this class and hence is to be regarded as a later acquisition in the evolution of the skeleton.

In studying the development of the skeleton, as in considering that of other systems and organs, clearer conceptions of the growth of the individual may be obtained by comparing it with the evolution of the type. For example, the simplest form of skeletal apparatus is that of the **amphioxus**. In this animal the only representative of the skeleton is the

**notochord**, a cylindrical rod composed of cellular or gelatinous tissue in which neither chondrification nor ossification ever takes place. Such an animal furnishes an example of the **notochordal stage** of the skeleton. The surrounding of the chorda with a sheath of embryonal connective tissue, by which it is strengthened and thereby better fitted to serve as the body-axis, furnishes the **membranous type** of skeleton, a stage a little farther advanced than the preceding. The next higher type of skeleton is the **cartilaginous form**. In this case the embryonal connective tissue has undergone transformation into cartilage, at which point development is arrested, the stage of ossification never being attained. The cartilaginous type of skeleton is illustrated by that of the selachian (sharks and dog-fish).

The third and highest type of skeleton is the **osseous**. This results from the replacement of the cartilaginous tissue by bone. The process of ossification does not, however, affect every part of the cartilaginous skeleton, there being some portions of the latter which remain permanently unossified. As there are, throughout the vertebrate series of animals, various gradations in the degree of differentiation of the skeleton, so in the course of development does the osseous system of every higher vertebrate pass through these stages from the simplest condition, that of the notochordal skeleton, to the highest form of the almost completely ossified skeletal apparatus.

#### THE AXIAL SKELETON.

The axial skeleton, as stated above, includes the bones of the trunk and those of the head. Logically the development of the former will first claim attention.

##### The Development of the Trunk.

**The Stage of the Chorda.**—The formation of the chorda dorsalis or notochord is the earliest indication of the axis of the embryonic body and it will be recalled that it is also one of the earliest embryological processes. The mode of development of the chorda from the entodermal epithelium has been described at p. 65. The chorda serves the pur-

pose, as it were, of an axis about which the permanent vertebral column and a part of the skull are, at a much later date, built up. The anterior or headward termination of the chorda corresponds to the position of the later **hypophysis**, or **pituitary body**, and thus the chorda is coextensive, not only with the vertebral column, but also with a portion of the cranium. The cells of the chorda enlarge and become distended with fluid, the protoplasm of each cell being reduced to a thin layer. The peripheral cells, however, constituting a distinct layer, the **chordal epithelium**, remain small, and it is by their proliferation that the chorda increases in size. In the amphioxus the chorda is the only "skeleton" that is ever acquired, and in this animal it is a *permanent structure*. In all other vertebrates it becomes surrounded by embryonal connective tissue, mesenchyme, which latter undergoes chondrification, and in the higher types ossification also. While in some of the lower vertebrates, as in certain classes of fishes, the chorda persists as a structure of more or less importance, in the higher members of the series, birds and mammals, it retrogrades as the processes of chondrification and ossification go on, until finally it is represented only by the **pulpy centers** of the **intervertebral disks**.

**The Membranous Stage.**—The notochordal stage of the development of the vertebral column is succeeded by the membranous stage. The transformation is effected by the appearance of an ensheathing mass composed of **embryonal connective-tissue cells** which surround not only the chorda but also the neural canal or fundament of the nervous system (Fig. 158, *sk*). The source of this embryonal connective tissue or mesenchyme bears an important relation to the primitive segments. As the development of the primitive segments was described in the last chapter, and also in Chapter IV., it will suffice to remind the reader that each primitive segment undergoes differentiation into the **myotome** or **muscle-plate**, the **cutis-plate**, the **nephrotome**, and the **sclerotome** (Fig. 158), the sclerotome occupying the mesial surface of the segment and lying in close proximity to the chorda.

While the **myotome** originates from the flattened or meso-

thelial cells of the primitive segment, the **sclerotome** is made up of cells of the type characteristic of young-growing connective tissue—that is, of the mesenchymal part of the primitive segments as distinguished from their mesothelium. Owing to the rapid multiplication of its cells, each sclerotome spreads out headward and caudalward, and dorsad and ventrad, surrounding both the chorda and the neural canal, until both these structures become enclosed in a common, continuous sheath of embryonal connective tissue. That part of this tissue which surrounds the chorda is often designated the **skeletogenous sheath** of the chorda and also the **membranous primordial vertebral column**. The cells of the sclerotomes not only surround the chorda and the neural canal, but they also spread out laterally into the intervals between the muscle-segments to constitute the **ligamenta intermuscularia** or the bands or strips of connective tissue which separate adjacent muscle-

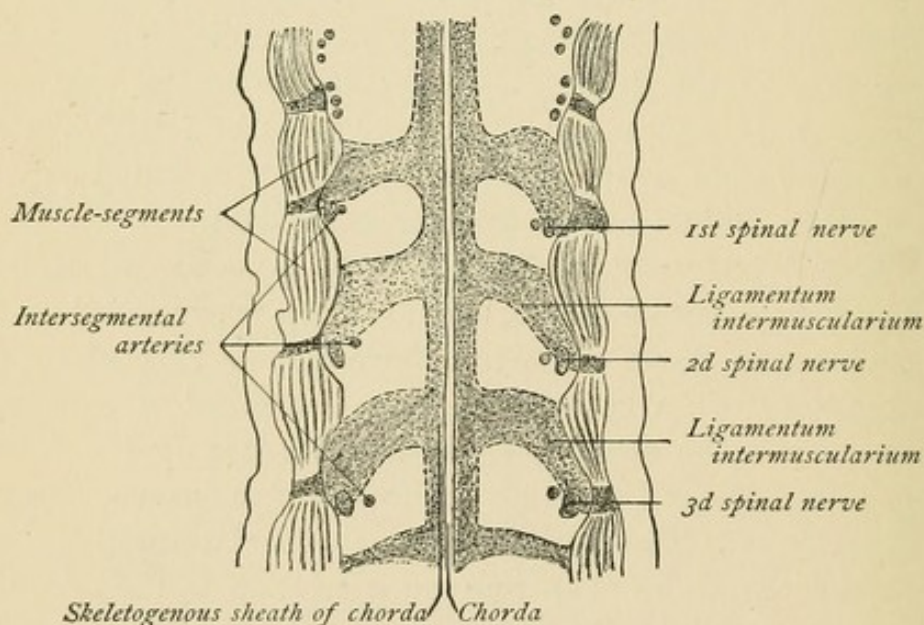


FIG. 159.—Frontal projection from a series of sections through a cow embryo of 8.8 mm. (0.35 in.). (From Bonnet, after Froriep.)

segments from each other (Fig. 159). It is worthy of note that while this skeletogenous sheath of the chorda originates from segmented structures, the somites or primitive segments, and is to that extent related to the segmentation of the body, *it now presents no trace of segmentation.*

**The Cartilaginous Stage.**—This stage of the development of the spine is brought about by the metamorphosis of parts of the membranous vertebral column into the **cartilaginous vertebræ**. Other and alternating parts of the same structure furnish the **intervertebral disks** and the **ligaments** that bind together the individual elements of the spine. The histological changes necessary to effect the transformation of the embryonal connective tissue into cartilage are, briefly, the moving apart of the cells and the modification of both the cells and the intercellular substance, the latter acquiring the characteristic qualities of the matrix of cartilage.

As a preliminary step to the formation of the cartilaginous vertebræ, the ensheathing membranous tissue exhibits, at regular intervals, **areas of condensation** of its connective-tissue elements. It is in these condensed areas that the process of cartilage-formation begins, and each such area, which has the form of a somewhat obliquely placed bow or half-arch, corresponds approximately but not accurately to a future vertebra. This half-arch of condensed mesenchymal tissue is called the **primitive vertebral bow** by Froriep, whose

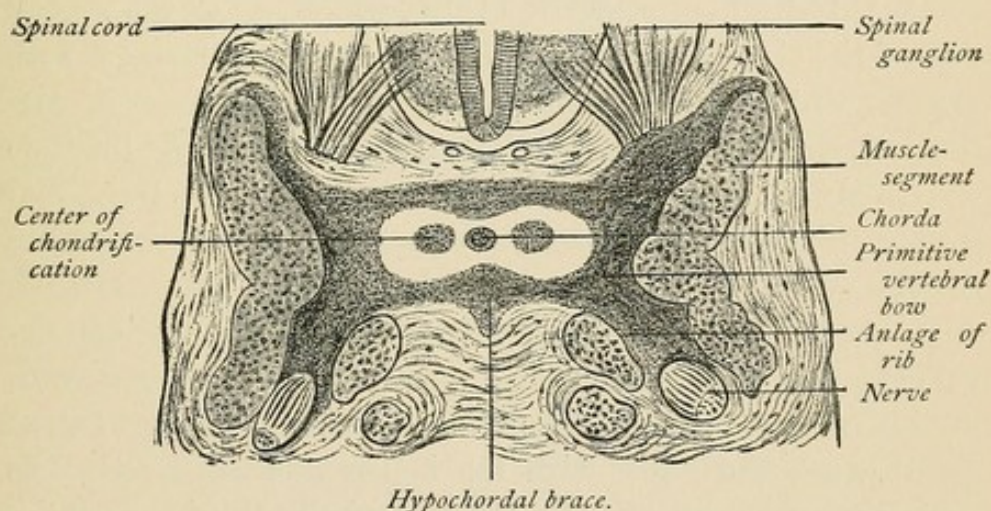


FIG. 160.—Cross-section through the anlage of the third cervical vertebra of a cow embryo of 12 mm. ( $\frac{1}{2}$  in.) (Bonnet).

investigations established many of the facts known concerning the development of the skeleton (Fig. 160). The median part of the bow is on the ventral side of the chorda and is known as the **hypochordal brace**. The extremities of the bow

abut against the corresponding muscle-segments, each extremity becoming bifurcated. The **dorsal limb** of the bifurcation spreads over the dorsal or superficial surface of the primitive spinal cord, forming the membranous forerunner of the **neural arch** of the vertebra; while the **ventral limb** advances ventrad, foreshadowing the **hemal arch** or **costal process** of the vertebra, or, as regards the thoracic region of the body, the future **rib**.<sup>1</sup> The **lateral parts** of the bow become the **processes** of the vertebra, but the **median part** of each bow, the **hypochordal brace**, remains unchondrified in mammals and becomes a part of the **intervertebral ligament**, except in the case of the first cervical vertebra, or atlas, the anterior or ventral arch of which it furnishes. The membranous anlage of the cartilaginous **body** of the vertebra is found in a special condensation of the ensheathing tissue of the chorda just caudad of the hypochordal brace.

For each **vertebral body** there are two centers of chondrification, one on each side of the chorda within the mass of tissue referred to above (Fig. 160). The formation of cartilage begins in the second month. The two centers are soon connected with each other by a third, which lies on the ventral side of the chorda, the three forming now a **cartilaginous half-cylinder** which is later completed by the development of cartilage on the dorsal side of the chorda (Fig. 161). At the time when the chorda is completely encased in cartilage the spinal cord is still ensheathed by merely membranous tissue. Before the end of the second month the **neural arches** of the vertebrae are indicated by small isolated masses of cartilage which develop in the connective tissue surrounding the spinal cord, the lateral parts of the membranous vertebral bows. In the eighth week these fuse with the bodies and appear then as projections from them. By the end of the third month the processes, or neural arches, have grown sufficiently to meet

<sup>1</sup> Morphologically, each vertebra is possessed of a *neural arch*, for the protection of the spinal cord; and a *hemal arch* for the protection of the organs of circulation, respiration, and digestion, the ribs of man and the higher vertebrates being the persistent hemal arches in the region of the thorax.

with their fellows on the dorsal side of the spinal cord, and in the fourth month the corresponding arches of the two sides become united, thus completing the **cartilaginous sheath of the cord**.

The masses of connective tissue occupying the intervals between the vertebral bodies are known as the **intervertebral**

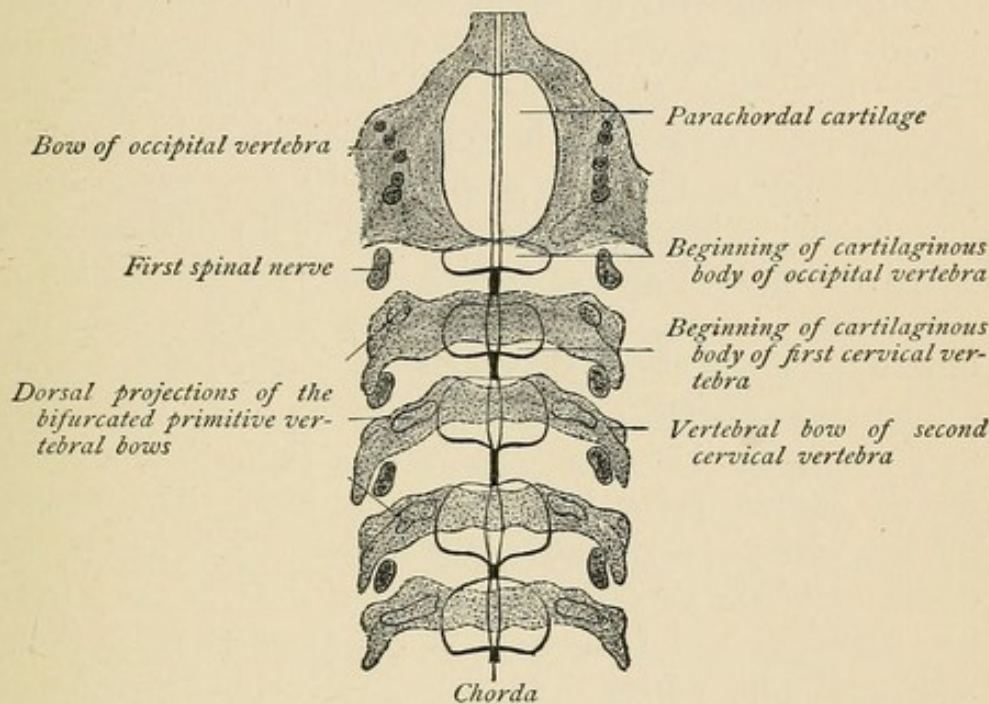


FIG. 161.—Frontal projection from a series of sections through a cow embryo of 17 mm. (0.67 in.), dorsal view (from Bonnet, after Froriep): Connective tissue stippled; cartilage white.

**ligaments.** Subsequently they become the **intervertebral disks**. The tissue between the cartilaginous arches becomes differentiated into the **ligamenta subflava**.

While the unsegmented skeletogenous sheath of the chorda is gradually differentiating into the separate elements of the cartilaginous vertebral column, the **chorda** itself begins to retrograde. Within the bodies of the vertebræ its development is completely arrested, while those portions of it contained within the intervertebral disks continue to grow. The chorda at this stage consequently shows alternating enlargements and constrictions. In certain fishes it persists as a structure of more or less importance. In vertebrates above cartilaginous fishes, all traces of the parts of the chorda

within the vertebral bodies are lost as soon as ossification occurs, while in the intervertebral disks parts of it persist as the **soft pulpy cores** of the latter.

The **cartilaginous trunk** is completed by the chondrification of the ligamenta intermuscularia to form the cartilaginous thorax.

**The Osseous Stage.**—The process of ossification begins in certain parts of the trunk at the end of the second month, before the work of chondrification is entirely completed. As the histological details of bone-formation are to be found in the text-books of histology, it will not be necessary to enter into the subject here. The places in any individual cartilage where ossification begins are called the centers of ossification. The process is one of substitution, the cartilage becoming broken down and absorbed as the formation of bone goes on.

The **ossification of each vertebra** is begun at three centers, one in the body and one in each arch. The centers for the **arches** appear in the seventh week. The centers for the **bodies** appear a little later and are found first in the dorsal vertebræ, appearing successively later in the vertebræ farther up and farther down. The ossified arches unite with each other during the first year of life, but their union with the body of the vertebra takes place between the third and eighth years. At a much later period **five accessory centers** of ossification are added to each vertebra. Two of these belong to the body and give rise to two annular plates of bone, the **epiphyses**, one for the upper or cephalic surface and one for the opposite or caudal surface. The remaining three centers belong respectively to the **spinous process** and the two **transverse processes**. The epiphyses do not acquire osseous union with the vertebra proper until about the twenty-fifth year.

The so-called **transverse process** of a cervical vertebra, enclosing a foramen, and consisting of an anterior and a posterior part, includes more than the transverse process proper, since its anterior or ventral portion is the rudiment of a **cervical rib**. During the time of the fusion of this rudimentary rib with the transverse process, the vertebral artery, which passes

between them, is surrounded by the two processes, and thus the adult cervical transverse processes differ from those of the other vertebræ in the possession of a foramen.<sup>1</sup>

The **atlas** and the **axis**, being strikingly modified cervical vertebræ, require special mention. The atlas contains less and the axis more than an ordinary vertebra, since that which corresponds to the **body** of the **atlas** never unites with it but fuses with the **body** of the **axis** to constitute its **odontoid process**.

The **atlas** presents two centers of ossification for its neural arches—the so-called posterior arch—just as other vertebræ do. Unlike other vertebræ, these centers do not unite with the body but become joined to each other on the ventral side of the position of the chorda by a piece of cartilage which results from the chondrification of the hypochordal brace, referred to on page 352. This forms the cartilaginous ventral or **anterior arch** of the atlas, which, in the first year of life, develops a center of ossification. The arch acquires bony union with the lateral parts between the fifth and sixth years.

The **axis** or **epistropheus** develops from the usual centers of ossification and from an additional one for its odontoid process. Bony union of the odontoid process with the proper body of the axis occurs in the seventh year. The odontoid process, in common with every other vertebral body, is traversed in the cartilaginous stage by the notochord.

The **transverse processes** of the **lumbar vertebræ**, like those in the cervical region, include not only the transverse process proper but also the rudiment of a rib.

The **sacral vertebræ** each present the usual ossific centers. Inasmuch as they become articulated firmly with the pelvic bones and undergo fusion to form a single adult bone, the **sacrum**, their form is much modified during the course of development. The **transverse processes** of each side coalesce to form the **lateral mass** of the sacrum. Each transverse process

<sup>1</sup> The point is made by some authorities, as Minot, that the bone does not grow around the artery, but that the artery grows through the ossifying tissue.

consists, as in the cervical and the lumbar vertebræ, of the transverse process proper and a rudimentary rib, the center of ossification for the latter being quite distinct during early stages of development. The **intervertebral disks** of the sacral vertebræ begin to ossify in the eighteenth year, the process being completed in the twenty-fifth year.

The **coccygeal vertebræ** are quite rudimentary. Each one is ossified from a single piece of cartilage, and usually from but a single center of ossification. Occasionally the first piece of the coccyx develops from two ossific centers, the process beginning at birth. **Ossification** begins in the second vertebra between the fifth and the tenth years; in the third, shortly before puberty; in the fourth, soon after puberty. The lower three pieces fuse into one before middle life, and this unites with the first, and the latter with the sacrum, at variable periods thereafter.

#### **The Development of the Ribs and Sternum.—**

Reference has been made in the preceding pages to the **ligamenta intermuscularia** as strips or bands of embryonal connective tissue lying between adjacent muscle segments, which have originated, in common with the sheath of the chorda, from the cells of the sclerotomes. The **ligamenta intermuscularia** become invaded by the costal processes of the primitive vertebral bows, the **costal process**, which is the ventral division of the tip of the bow, growing ventrad and penetrating the substance of the ligament to constitute a **curved rod of connective tissue**, the forerunner of the future rib. Thus there are formed connective-tissue representatives of the ribs, each of which is embedded in the looser connective tissue of the corresponding intermuscular ligament. It is by the development of cartilage within these curved rods of condensed mesenchyme, the **membranous ribs**, that the **cartilaginous ribs** are produced. The process of chondrification commences in the second month, but does not involve the proximal ends of the ribs, the tissue here becoming ligamentous and serving to bind together the ribs and the vertebræ. Ribs are formed throughout the entire extent of the vertebral column, except in the coccygeal region, but while in

the lower vertebrates the entire series goes on to mature development, in mammals, including man, their growth is arrested in the cervical, lumbar, and sacral regions. In the case of man and mammals only the thoracic ribs persist and become adult structures.

As the distal (ventral) extremities of the ribs advance toward the ventral median line, the tips of the first five, six, or seven each exhibit an enlargement. These broadened ends soon coalesce, thus forming on either side of the median line a continuous strip of cartilage, the **anlages of the sternum**. The other ribs remain free at their ends. The **sternum** is therefore produced from two lateral halves, a circumstance that explains some of its anomalies, as for example, **cleft sternum**, which is a condition due to arrested development or deficiency of union.

The **ossification of the ribs** begins in the second month of fetal life and from a single center for each. The process does not involve the entire rib, a portion near the distal extremity remaining cartilaginous and becoming the adult **costal cartilage**. **Accessory centers** of ossification for the head and tubercle appear between the eighth and fourteenth years of life.

The **ossification of the sternum** proceeds from numerous centers. There is one for the manubrium and from six to twelve for the gladiolus. The ensiform acquires a center of ossification in the early years of life, but for the most part remains cartilaginous.

Although, as stated above, the ribs of adult human anatomy are limited to the thoracic region, their rudimentary representatives are found throughout the other regions of the vertebral column. In the cervical, lumbar, and sacral regions each rudimentary rib becomes blended with the transverse process of the corresponding vertebra to form the **transverse process** of human anatomy. It is from the persistence of the seventh rudimentary cervical rib and its failure to fuse with the corresponding transverse process that the anomaly of a **free cervical rib** results; while the presence of a **thirteenth or lumbar rib**, as occasionally met with, is due

to the unusual development of the first lumbar rudimentary rib.

### The Development of the Head Skeleton.

Just as the skeleton of the trunk consists of a dorsally situated bony case for the protection of the spinal cord and a series of ventral or hemal arches for the protection of the organs of circulation and respiration; so does the head skeleton comprise a bony case for the accommodation of the brain with smaller accessory osseous compartments for the organs of special sense, as the orbits and the nasal chambers; and also a ventrally situated apparatus which constitutes both a receptacle for the oral and the pharyngeal parts of the digestive system and a mechanism for the mastication of

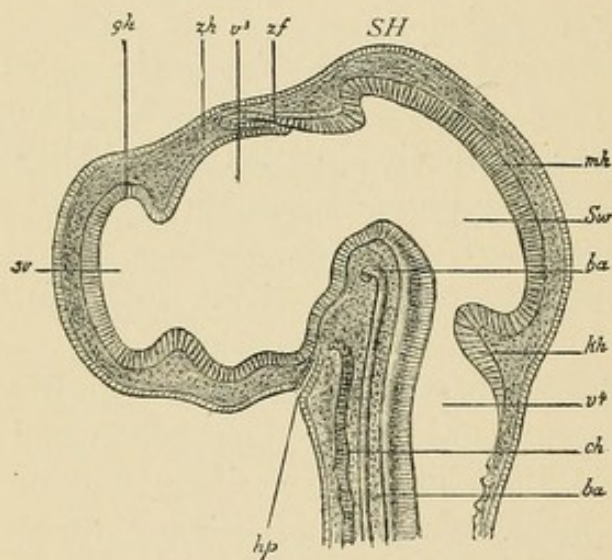


FIG. 162.—Median sagittal section through the head of a chick incubated four and a half days (after Mihalkovics): *SH*, parietal (mid-brain) elevation; *sv*, lateral ventricle of the brain; *v<sup>3</sup>*, third ventricle; *v<sup>4</sup>*, fourth ventricle; *sw*, aqueductus Sylvii; *gk*, cerebral vesicle; *zh*, between-brain (thalamencephalon); *mh*, mid-brain; *kh*, cerebellum; *zf*, pineal process; *hp*, hypophyseal (or Rathke's) pocket; *ch*, chorda; *ba*, basilar artery.

food. The former part, the **cranial capsule**, or **brain-case**, is developed to a great extent from the connective tissue surrounding the head-end of the chorda, its origin thus being similar to that of the spinal column. On the other hand, the **ventral parts**, as the jaws and the hyoid bone and related structures, constituting the so-called **visceral skeleton**, develop from the mesodermic tissue of the **visceral arches**. As in the

case of the trunk skeleton, the cranium is first outlined in membranous tissue resulting from the differentiation of the embryonal connective tissue which ensheaths the head-end of the chorda, and also of the connective tissue of the visceral arches, this differentiation producing the **membranous primordial cranium**. The metamorphosis of the membranous cranium into cartilage brings about the **cartilaginous stage** of the cranium, while the replacement of the cartilage by bone is the final step in the process.

Bones that develop from centers of ossification in previously formed masses of cartilage are styled **primordial bones**, while those that are produced independently of cartilage, either in the skin covering the membranous cranium, or in the mucous membrane lining indentations in its walls, are known as **covering or dermal bones**. The development of bone is therefore said to be either **endochondral** or **membranous**. For the most part, the bones of the base of the skull are of endochondral formation, while those of the vault are developed in membrane. The membranous or dermal bones are similar in point of origin to the exoskeleton—placoid and ganoid scales—of certain fishes.

**The Membranous Cranium.**—The membranous brain-case is differentiated from the young connective tissue which ensheaths the anterior or head-end of the chorda. As previously stated, the anterior end of the chorda is at a point ventrad to the mid-brain vesicle, in the angle formed by the latter with the fore-brain, at a position corresponding with that of the pituitary body (Fig. 162). The skeletogenous sheath of the chorda, in this situation as elsewhere, results from the multiplication of the cells of the sclerotomes, since this region of the body undergoes segmentation in common with the trunk. The **number of head-segments** is uncertain. According to recent investigations upon shark embryos, there are at least nine primitive segments formed in the head-region.

The skeletogenous sheath of the chorda spreads out dorsad to cover the brain-vesicles. From the terminal point of the chorda, beneath the inter-brain, the sheath advances ante-

riorly to invest the fore-brain, which latter at this stage is bent over ventrad. From the part investing the fore-brain, a protuberant mass, the **nasofrontal process**, extends toward the primitive mouth-cavity, constituting the anterior or upper boundary of the latter. Meanwhile the **mesenchymatic tissue of the visceral arches**—that is, that part of the mesodermic tissue of these structures which does not form muscular tissue—is undergoing similar transformation into membranous tissue. The first visceral arch divides into an anterior or upper part, the **maxillary process**, and a posterior or lower mass, the **mandibular arch**, these being the membranous jaw arches. The four jaw arches, with the nasofrontal process, form the boundaries of the primitive mouth-cavity, the mandibular arches of the two sides having united in the median line to form its lower border, and the maxillary arches having fused with the lateral nasal and the nasofrontal processes to constitute its upper boundary.

The **membranous primordial cranium**, then, consists of a complete connective-tissue investment for the brain-vesicles, of the membranous jaw arches, and of the hyoid and the branchial arches, and presents in its walls the indications of the cavities for special-sense organs in the shape of the surface invaginations which constitute respectively the otic vesicle, the lens-vesicle, and the nasal pits.

**The Cartilaginous Cranium.**—By the further differentiation of the membranous cranium the cartilaginous stage is attained. The development of cartilage begins in the second month. While the membranous cranium furnishes a complete capsule for the brain, the cartilaginous brain-case is deficient, since the process of chondrification does not affect the regions of the future parietal and frontal bones. This is true at least of man and the higher vertebrates. In those cases where the skeleton remains permanently cartilaginous, as in selachians (sharks, dog-fish, etc.), the entire brain-case participates in the chondrifying process. As the skull extends very much farther forward than the end of the chorda—which latter terminates at the position of the future sella turcica—the regions of the primitive skull are designated

respectively *chordal* and *prechordal* (Kölliker), or *vertebral* and *evertbral* (Gegenbauer), according as they fall behind or in front of the end of the chorda.

The formation of cartilage begins in the region corresponding to the base of the future skull. On each side of the end of the chorda a mass or bar of cartilage is formed, extending forward and backward, this pair of parallel bars being designated the **parachordal cartilages** (Fig. 163, 1). Farther forward,

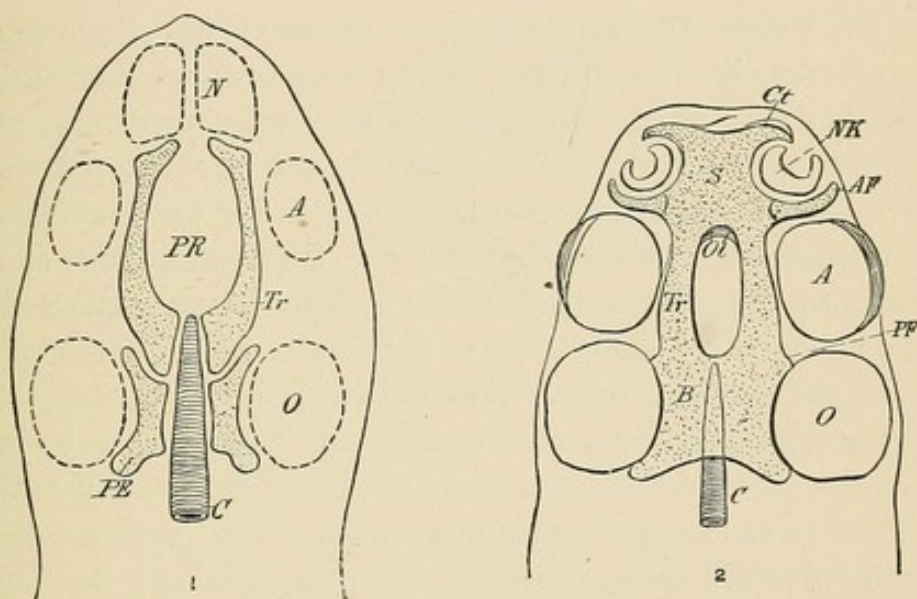


FIG. 163.—First fundement of the cartilaginous primordial cranium (from Wiedersheim): 1. *First Stage*: C, chorda; PE, parachordal cartilage; Tr, Rathke's trabeculae cranii; PR, passage for the hypophysis; N, A, O, nasal pit, optic vesicle, otocyst. 2. *Second Stage*: C, chorda; B, basilar plate; Tr, trabeculae cranii, which have become united in front to constitute the nasal septum (S) and the ethmoid plate; Cl, AF, processes of the ethmoid plate enclosing the nasal organ; Ol, foramina olfactoria for the passage of the olfactory nerves; PF, postorbital process; NK, nasal pit; A, O, optic and labyrinthine vesicles.

in the prechordal region, another pair of cartilaginous masses is produced, known as the **trabeculae cranii**. The latter are not straight bars, but have somewhat the form of a pair of calipers. In a short time the cranial trabeculae unite with each other, but not throughout their entire extent, an aperture being left at the position of the pituitary body. It is through this aperture that the oropharyngeal diverticulum, which forms the anterior lobe of the pituitary body, projects to come into relation with the diverticulum from the inter-brain, which produces the posterior lobe. At a later period ossifi-

cation occurs here, as elsewhere in the base of the skull, thus completely isolating the pituitary body from the wall of the pharynx. The parachordal cartilages also fuse with each other and with the cranial trabeculæ, the four pieces now forming one mass. The process of chondrification extends to other parts of the membranous cranium so as to produce a cartilaginous brain-case, just as, in the case of the vertebral column, the dorsal extension of cartilage-formation gives rise to a case or canal for the spinal cord. As before stated, however, the chondrifying process does not affect the entire membranous cranium in the higher vertebrates, chondrification occurring around the position of the foramen magnum and in the lateral walls of the cranial capsule, while parts of the vault remain membranous. The anterior extremities of the united cranial trabeculæ become so modified in form as to constitute the **plate of the ethmoid** and the **nasal capsule** for the lodgement of the olfactory epithelium. In each lateral region the **cartilaginous ear capsule** is differentiated.

Meanwhile the **cartilaginous visceral skeleton** is developing from the membranous structures of the visceral arches. As in the case of the brain-capsule, the chondrifying process does not involve all parts of the membranous visceral skeleton, parts of the latter being replaced later by dermal or covering bones—that is, bones that develop in membrane without having been previously mapped out in cartilage.

In the **first visceral arch**, the formation of cartilage occurs only in the mandibular portion, the maxillary process continuing membranous. The cartilage of the mandibular arch appears in the form of a curved bar running ventrodorsally. This bar divides into a smaller proximal or dorsal piece, the palatoquadratum of comparative anatomy, and a longer distal or ventral segment, **Meckel's cartilage**. The palato-quadratum subsequently divides into two parts, the cartilaginous anlagen respectively of the palato-pterygoid plate and the **incus**. Meckel's cartilage likewise undergoes division, there being separated from the chief mass a small proximal segment called the articulare, which is the forerunner of the future **malleus**. Thus the cartilaginous bar of the mandibular arch

has to do with the formation of certain of the ossicles of the middle ear as well as, to a limited extent, with the development of the mandible.

In the **second visceral** or **anterior hyoid arch**, chondrification also occurs, but not throughout its entire extent. A bar of cartilage, the **hyoid bar** or **Reichert's cartilage**, is produced in this arch and undergoes division into three segments, of which the proximal or dorsal is the forerunner of the future **stapes** of the middle ear, while the other two pieces represent respectively the **styloid process** and the **lesser horn** of the **hyoid bone**. The tissue intervening between the position of the styloid process and the lesser hyoid cornu does not chondrify in man but remains membranous and becomes the **stylohyoid ligament** (see Fig. 169).

In the **third visceral arch**, or the **posterior hyoid arch**, a rod of cartilage develops which represents the **greater cornu** of the future **hyoid bone**. Ventral to this, there is formed a median unpaired piece of cartilage, the **copula**, belonging to the arches of the two sides, which later develops into the **body** of the **os hyoides**.

To summarize, the **head skeleton** in the cartilaginous stage of development presents an imperfect cartilaginous brain-case, capsules for the organs of smell, sight, and hearing, and a cartilaginous visceral skeleton, the several parts of which map out the lower jaw, the hyoid bone, the styloid process, and the ossicles of the middle ear.

**The Osseous Stage.**—The bony condition of the head skeleton is brought about in part by the development of bone from centers of ossification in the cartilages described above, and in part by the growth of covering or dermal bones in the integument covering those areas which are deficient in cartilage; in other words, by both endochondral and membranous ossification. It may be stated in general terms that the bones of the base and of the sides of the skull, including the auditory ossicles, the ethmoid, and the inferior turbinated bone, are produced by ossification in cartilage and are hence called *primordial bones*; and that the bones of the vault of the cranium, and for the most part of the face, result from the membranous method of

ossification, and are therefore styled *dermal* or *covering bones*. Some of the individual bones, however, are partly of car-

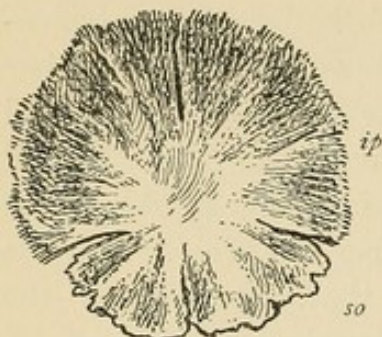


FIG. 164.—Tabular part of occipital bone of about fifth fetal month, inner surface: *ip*, interparietal, which is ossified in membrane; *so*, supra-occipital, ossified in cartilage.

tilaginous and partly of membranous origin, the several portions remaining permanently distinct in certain lower vertebrates, but in man uniting so intimately with each other as to present no trace of their previously separate condition.

The **occipital bone** consists of two genetically distinct parts, the superior or **interparietal** portion, which is a dermal bone, and the **occipital bone proper**,

which is of cartilaginous origin. The **ossification** of the latter occurs from four centers, one on each side of the foramen magnum for the condylar portions, one in front of the foramen for the basilar process, and one posterior to that aperture for all the tabular portion of the bone not belonging to the interparietal segment. Ossification begins in these centers early in the third fetal month and proceeds at such rate that at the time of birth the bone consists of four bony parts which are separated from each other merely by thin layers of cartilage. Since in some animals these parts remain separate throughout life, they are designated by morphologists, respectively, the **ex-occipitals**, the **basi-occipital**, and the **supra-occipital** (Fig. 165). The supra-occipital is augmented by the union with it of the interparietal portion, a covering or dermal bone that ossifies from two centers, and that begins to fuse with the supra-occipital near the end of the third month of fetal life. Consisting at birth of four distinct parts, separated by cartilage, the occipital becomes a single bone by the end of the third or fourth year by the bony union of the separate segments.<sup>1</sup>

The **temporal bone** is made up of three genetically distinct

<sup>1</sup> In some cases the union of the interparietal with the supra-occipital is incomplete, the adult bone then presenting two transverse fissures which pass, one from each lateral angle, toward the median line.

parts, the squamosal or squamozygomatic, the petrosal or petromastoid or periotic, and the tympanic. At the time of birth these three elements of the bone are still separate from each other, the tympanic being an incomplete ring, and the petro-

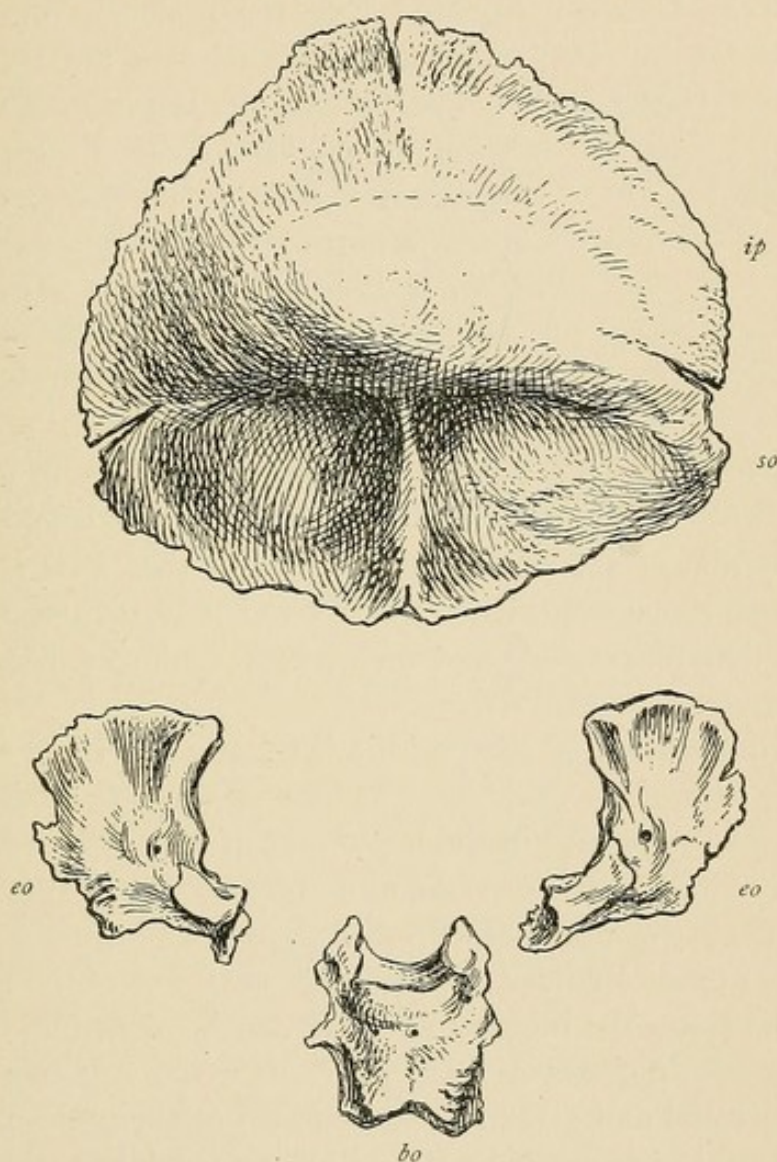


FIG. 165.—Occipital bone at birth, external surface: *ip*, interparietal; *so*, supraoccipital; *eo*, exoccipitals; *bo*, basi-occipital.

mastoid being still without a mastoid process. The petromastoid is the only part of the temporal bone that is outlined in cartilage, the squamozygomatic and the tympanic being represented in the cartilaginous stage of the cranium by membranous tissue.

The **squamozygomatic** (Fig. 166) is ossified in previously

formed membrane from a single center of ossification, which appears in the lower part of this segment at about the seventh week. The process of bone-formation extends in all direc-

tions from this center, but especially upward into the squamosa and outward and forward into the zygoma.

The **periotic** or **petromastoid** results from the ossification of the cartilaginous ear-capsule, which latter constitutes a part of the cartilaginous portion of the early cranium. It should be remembered that the essential part of the organ of hearing, the internal ear, is differentiated from a small pouch of epithelium, the otic vesicle, which is produced by an infolding or

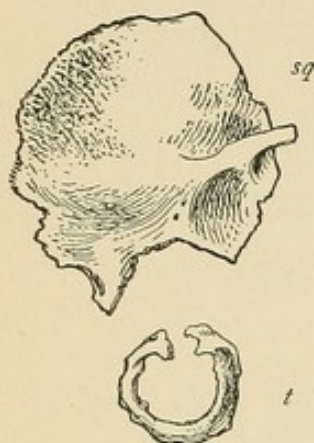

FIG. 166.—Squamozygomatic (*sq*) and tympanic (*t*), of temporal bone at birth.

invagination of the surface ectoderm, and that it is the cartilaginous tissue enclosing the otic vesicle and its outgrowths, the semicircular canals and the cochlea, that constitutes the cartilaginous ear-capsule.

The ossification of the periotic is usually described as proceeding from three centers. The first of these, the **opisthotic**, makes its appearance in the latter part of the fifth month on the outer wall of the capsule, at a point corresponding to the position of the promontory, whence the formation of bone spreads in such manner as to produce that part of the petrosa which is below the internal auditory canal. A second center, the **pro-otic**, appears a little later over the superior semicircular canal and gives rise to that part of the petrosa above the internal auditory meatus, and also to the inner and upper part of the mastoidea. The third nucleus, the **epiotic**, arises in the neighborhood of the posterior semicircular canal. Ossification proceeds rapidly, the three parts speedily uniting to form one bone, the periotic or petromastoid. The petrous portion of the periotic is the more important and the more constant. The mastoid is of variable size in different animals, and in the human species, at birth, it is flat and devoid of the mastoid process which is so conspicuous in the mature

condition of the skull. The mastoid process develops during the first two years of life, but its air-cells do not appear until near the age of puberty.

The **pars tympanicus**, or the **tympanic** (Fig. 166), which constitutes the bony part of the wall of the external auditory meatus, is ossified in membrane from a single center of ossification. This center appears in the third fetal month in the lower part of the membranous wall of the external canal, from which point the process of bone-formation extends upward on either side so as to form an incomplete bony ring, open above. This tympanic ring is situated external to both the ear capsule and the ossicles of the middle ear and gives attachment to the periphery of the tympanic membrane. The further growth of the tympanic ring being in the outward direction, it becomes a curved plate or imperfect cylinder of bone which constitutes the bony wall of the external auditory canal. At birth, the pars tympanicus still has the form of the incomplete ring, its further development taking place during the first few years of life. The extremities of the ring unite with the squamozygomatic before birth. The tympanic unites also with the petrosa except in a region adjacent to the proximal end of Meckel's cartilage, where an aperture is left which is the petrotympanic or **Glaserian fissure**. Since upon the part of Meckel's cartilage which is thus enclosed by the union of the two bones is formed the long process of the malleus, the presence of this process in the Glaserian fissure is accounted for.

The **styloid process** of the temporal bone belongs to the visceral-arch skeleton. It ossifies in two parts in small masses of cartilage that belong to the anterior hyoid arch. One, the **tympanohyal**, gives rise to the base of the process (Fig. 170); it begins to ossify before birth and soon unites with the temporal. The other segment, the **stylohyal**, undergoes ossification later and joins with the tympanohyal only after adult age is reached. Sometimes it remains separate throughout life.

The **sphenoid bone** is for the most part ossified in cartilage. The body of the bone is represented in the fetus by two

separate parts, the posterior body or **basisphenoid** (Fig. 167, *bs*), which includes all that part of the body of the mature bone which is posterior to the olivary eminence and to which belong the **greater wings**; and an anterior body or **presphenoid** (*ps*), situated in front of the olivary eminence, to which belong the **lesser wings**. The ossification of the **basisphenoid** proceeds from two centers placed side by

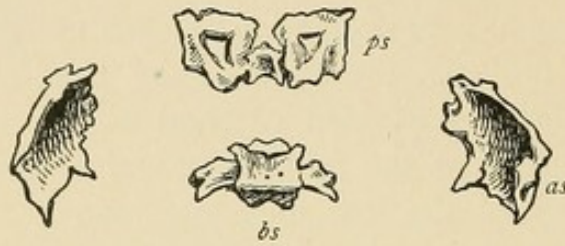


FIG. 167.—Sphenoid bone, fifth or sixth fetal month; seen from above: *ps*, presphenoid or anterior body, with lesser wings; *as*, greater wings; *bs*, basisphenoid or posterior body.

side, which appear in the eighth week. Two months later two secondary centers appear for the lateral parts of the body. The **presphenoid** likewise develops from two centers, which are apparent in the ninth week. The union of the presphenoid with the basisphenoid occurs in the seventh or eighth month. Each **greater wing** develops from a single center of ossification, which is present in the eighth week. The process of ossification spreads from this center to produce not only the greater wing but also the external pterygoid plate. The greater wings remain separate from the body until some time during the first year after birth. Each **lesser wing** ossifies from a center that appears about the ninth week. The lesser wings unite with the presphenoid in the sixth fetal month.

The **internal pterygoid plate** differs from the other parts of the sphenoid in that it does not ossify in cartilage but in membrane. It is therefore a *covering bone*. Its center or centers of ossification appear in the fourth month in the connective tissue in the lateral walls of the oropharyngeal cavity. In many animals this plate acquires no connection with the external pterygoid plate but remains throughout

life a distinct bone, the pterygoid. In man it fuses with the external plate in the fifth month.

The presphenoid with its attached lesser wings, and the basisphenoid, to which are united the greater wings and the pterygoid plates, remain permanently separate bones in some animals. In man, as noted above, the two parts of the body of the bone unite shortly before birth, although the greater wings remain separate until some months after that event.

The **ethmoid bone** and the **inferior turbinate** are formed in cartilage, resulting from the ossification of the posterior portion of the cartilaginous nasal capsule (Fig. 168, *m*). The

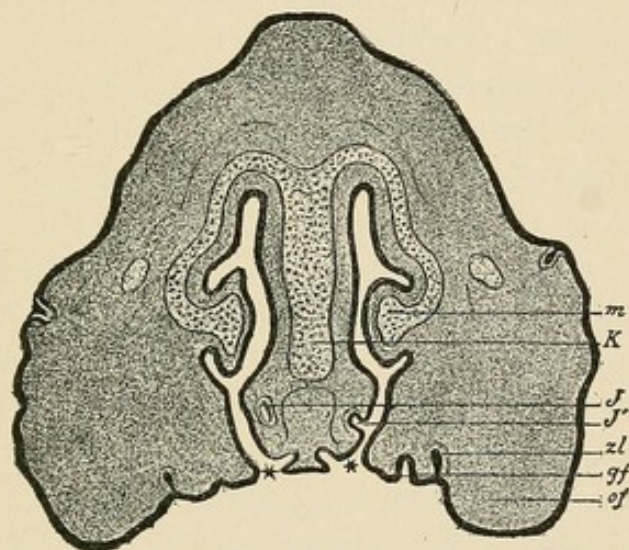


FIG. 168.—Cross-section through the head of an embryo pig 3 cm. (1.2 in.) long, crown-rump measurement. The nasal cavities are seen to be in communication with the oral cavity at the places designated by a \*: *K*, cartilage of the nasal septum; *m*, turbinal cartilage; *J*, organ of Jacobson; *J'*, the place where it opens into the nasal cavity; *pf*, palatal process; *of*, maxillary process; *zl*, dental ridge (Hertwig).

latter represents the anterior extension of the cartilaginous trabeculae cranii so modified as to constitute a receptacle for the olfactory epithelium. The anterior part of this capsule remains cartilaginous throughout life as the **septal** and **lateral cartilages** of the nose. By the ossification of the posterior part of the nasal capsule the ethmoid and the inferior turbinate bones are produced. Ossification, beginning in the fifth month, involves the lower and the middle turbinals and a part of the lateral masses. The ossification of the superior turbinal, of the vertical plate, of the crista galli, and of the

remaining parts of the lateral masses is effected after birth. The bony union of the lateral masses with the median plate is completed between the fifth and seventh years.

The **frontal bone** is a covering or dermal bone, being ossified in membrane from two centers of ossification, one for each lateral half. These centers are situated above the orbital arches and are first apparent in the seventh week. At birth, the two halves of the bone are still separate, their union not occurring until during the first year of life. Sometimes the union fails to take place, the condition of the persistent frontal or **metopic suture** being known as **metopism**. Metopism is considerably more common in European skulls than in those of lower type.

The **parietal bone** is also ossified in membrane. It develops from two nuclei which soon coalesce. Their position corresponds to that of the future parietal eminence.

The **bones of the face** are for the most part dermal bones. Of these, the upper and the lower maxillæ and the palate bones belong to the visceral-arch skeleton. The others develop in the membranous wall of the cranial capsule.

The **nasal and lacrimal bones** ossify each from a single center, which appears in the eighth week.

The **malar** is ossified in membrane from three nuclei, the process beginning in the eighth week.

The **palate bone** is formed in mucous membrane from a single center which is situated at the junction of the vertical and the horizontal plates.

The **vomer** develops from two centers of ossification which appear at the back part of the cartilaginous nasal septum. Each center gives rise to a lamina of bone, the two laminae gradually uniting with each other from behind forward, and embracing between them anteriorly the septal cartilage.

The **vomer** and the **palate bone** are examples of the formation of bone in mucous membrane. The centers of ossification first appear in the eighth week in each case.

The **skeleton of the visceral arches** includes the upper and lower maxillæ, the hyoid bone with a part of the styloid process, the ear ossicles, and the palate bones. The palate

bones have been referred to above. These bones of the visceral-arch skeleton are partly primordial and partly membranous.

The **superior maxilla** comprises two parts, the superior maxilla proper and the intermaxillary bone. While these intimately unite in man, in some animals, as the dog, they are permanently distinct, the intermaxillary bone constituting the important and conspicuous **premaxilla** of the dog. The superior maxilla ossifies in membrane—within the membranous maxillary process of the first visceral arch—from an uncertain number of centers. It seems probable that there are three nuclei of origin, one for the palate process, one for the malar part of the bone, and one for the portion internal to the infra-orbital foramen and a part of the nasal wall. The formation of the **antrum** begins in the fourth month by the development of a recess or fossa on the inner or nasal wall of the bone.

The palate process is formed by the growth, on the inner aspect of the bone, of a shelf-like projection which advances toward the median line until it meets and unites with its fellow of the opposite side (Fig. 156). The horizontal plate of the palate bone develops similarly and very shortly after, and thus is produced the **hard palate**, which separates the nasal chambers from the mouth. The two halves of the hard palate unite first in front, their union being completed by the twelfth week. If union is incomplete, the anomaly of *cleft-palate* results. The **intermaxillary segment** begins its development in the seventh or eighth week upon that part of the nasofrontal process which lies between the nasal apertures. In the fifth month the intermaxillaries fuse with the maxillæ, the line of union being indicated by a suture which is apparent upon the oral surface of the palate processes. The intermaxillaries contain the germs of the four incisor teeth. As previously mentioned, deficiency of union between the maxilla and the intermaxillary results in the deformity of *hare-lip*. Obviously, the hiatus in hare-lip will be found to be not median, but lateral, corresponding to the position of the line of normal union.

The lower jaw or mandible is intimately associated in its development with that of the malleus and incus of the middle ear. Inasmuch as these three bones are differentiated from the cartilaginous and membranous visceral skeleton of the first visceral arch it is desirable to consider their development together.

As described above, the membranous jaw-arches form the lateral and lower boundaries of the mouth-cavity, the first visceral arch dividing into the maxillary process and the mandibular arch. There appears in the mandibular arch a bar of cartilage which abuts by its proximal extremity upon the outer wall of the auditory labyrinth. This cartilaginous

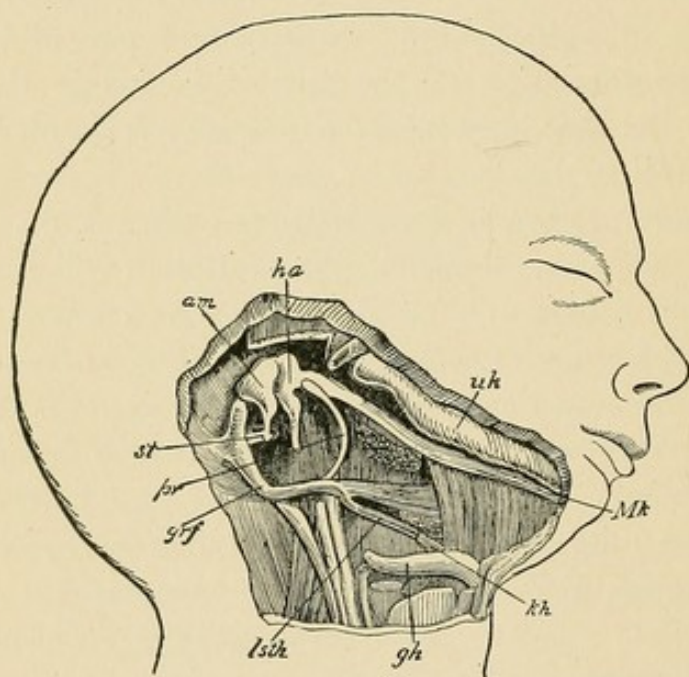


FIG. 169.—Head and neck of a human embryo eighteen weeks old with the visceral skeleton exposed (after Kölliker), magnified. The lower jaw somewhat depressed in order to show Meckel's cartilage, which extends to the malleus. The tympanic membrane is removed and the annulus tympanicus is visible: *ha*, malleus, which passes uninterruptedly into Meckel's cartilage, *Mk*; *uk*, bony lower jaw (dentale), with its condyloid process articulating with the temporal bone; *am*, incus; *st*, stapes; *pr*, annulus tympanicus; *grf*, processus styloideus; *lsth*, ligamentum stylohyoideum; *kh*, lesser cornu of the hyoid bone; *gh*, its greater cornu.

rod segments into a distal portion, **Meckel's cartilage** (Fig. 169, *Mk*), and a smaller proximal piece, which is called, in comparative anatomy, the palatoquadratum. From the palatoquadratum a process, the palatopterygoid process,

grows toward the roof of the mouth-cavity and becomes a separate segment. The piece of cartilage remaining, which represents the proximal end of the original bar, undergoes ossification, becoming the **incus** (Fig. 169, *am*). The posterior or proximal extremity of Meckel's cartilage, becoming a partly separated cartilage, the **articulare**, ossifies to produce the **malleus** (Fig. 169, *ha*). Though the form of the malleus is recognizable, it is still in direct continuity with Meckel's cartilage. In the opposite direction it is articulated with the incus. As the tympanic ring develops, and the interval below, between this ring and the petrosa, is gradually narrowed to the **petrotympanic** or **Glaserian fissure**, the malleus comes to lie within the tympanic cavity, being continuous, through the fissure, with Meckel's cartilage. Upon the separation of the malleus from the cartilage of Meckel, the **long process** of the malleus represents the former bond of union and therefore occupies, in the mature state, the Glaserian fissure. The joint between the malleus and the incus represents the primitive vertebrate jaw articulation. In the shark, for example, the mandibular joint is between the two pieces into which the cartilaginous bar of the first visceral arch divides—that is, between the palatoquadratum and the representative of Meckel's cartilage, the mandibulare. In mammals, however, the malleus, as we have seen, loses its connection with the mandible, the joint between the latter and the skull, the temporomaxillary articulation, being secondarily acquired in a manner to be pointed out hereafter. While the malleus develops for the most part by ossification in cartilage, its long process develops in membrane as a small covering or dermal bone, the **angulare**.

The membranous lower jaw with its enclosed bar of cartilage becomes osseous, not by the ossification of the cartilage, but by the development of a casing of bone within the surrounding membrane. In other words, the lower jaw develops chiefly by the intramembranous method of bone-formation. Several centers of ossification appear, and from these the process of bone production extends rapidly, forming, by the fourth month, a covering or dermal bone, the

**dentale** (Fig. 169, *uk*), which is situated mainly on the outer side of Meckel's cartilage. A smaller plate appears on the inner side. Thus the cartilage comes to be surrounded by an irregular cylinder of bone. The cartilage of Meckel plays a comparatively unimportant part in the ossification of the lower jaw-bone and begins to degenerate in the sixth fetal month. Its distal extremity, however, undergoes ossification, thus aiding in the formation of a small part of the mandible near the symphysis; while a posterior segment, with the fibrous tissue encasing it, which extends from the temporal bone to the inferior dental foramen, persists as the **internal lateral ligament of the lower jaw**. With these exceptions, Meckel's cartilage entirely disappears. The angle of the mandible and a small part of the ramus are also ossified in cartilage, which latter is developed independently of Meckel's cartilage. From the posterior part of the dentale the condyloid process develops and becomes articulated with the glenoid fossa of the temporal bone, thus establishing the **temporomaxillary articulation**. This joint, as previously stated, is a secondary one and replaces in mammals the primitive articulation between the mandibulare and the palatoquadratum of the lower vertebrates.

At birth, the two lateral halves of the inferior maxilla are united at the symphysis by fibrous tissue; bony union occurs during the first or second year after birth.

To summarize, the inferior maxilla develops as a part of the visceral-arch skeleton and is chiefly a covering bone, since, with the exception of the angle, a portion of the ramus, and a small part near the symphysis, which are of cartilaginous origin, it is formed by the membranous method of ossification. The two other products of the mandibular arch, the malleus and the incus, are ossified from cartilage, with the exception of the processus gracilis of the malleus, which is of membranous origin.

The **development of the hyoid bone**, of the **styloid process** of the temporal bone, and of the **stapes** was referred to in considering the cartilaginous visceral-arch skeleton, but for the sake of clearness and completeness it may not be amiss to

repeat, in this connection, some points previously mentioned.

The membranous anterior hyoid or second visceral arch, at a certain stage of development, presents, in its interior, the dorsoventral cartilaginous bar known as **Reichert's cartilage**. This is parallel with Meckel's cartilage, and, like it, is in contact by its dorsal or cranial end with the outer wall of the auditory labyrinth. A shorter bar of cartilage appears in the third visceral arch, which latter is known also as the **posterior hyoid arch**. Together, these two cartilaginous elements furnish the **stapes** of the middle ear and the **hyoidean apparatus**, the latter consisting of the hyoid bone, the stylohyoid ligaments, and the styloid processes. In man the

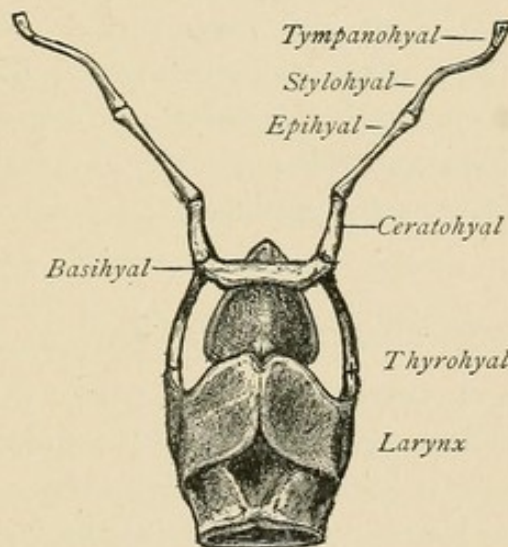


FIG. 170.—Hyoidean apparatus and larynx of dog.

**hyoidean apparatus** is somewhat rudimentary, but in the dog and many other mammals it is present in its typical form (Fig. 170). In such animals the stylohyoid ligament of human anatomy is represented by a bone, the epihyal, the hyoid bone being, therefore, connected with the skull by a series of small bones articulated with each other. All the elements of the hyoidean apparatus, save the body and the greater cornua of the hyoid bone, are produced by Reichert's cartilage; the hyoid body, known in comparative anatomy as the basihyal, and the greater cornua, or the thyrohyals, ossify

from the cartilage of the third arch, the cartilage for the body being a median unpaired segment known as the copula.

**Reichert's cartilage** undergoes division into five segments. The segment at the cranial end, upon ossification, becomes the stapes.<sup>1</sup> This ossicle, by the closing of the walls of the tympanic cavity, is isolated from the other segments. The second piece, the **tympanohyal**, ossifies to form the base of the styloid process and ankyloses firmly with the temporal bone at the point of junction of the periotic portion of that bone with its tympanic plate. The third portion, the **stylohyal**, forms the lower part of the styloid process. It undergoes ossification later than the tympanohyal and does not acquire osseous union with it until the time of adult age. It sometimes remains separate throughout life. The fourth segment, the **epihyal**, does not even become cartilaginous in man, but remains fibrous, constituting the stylohyoid ligament. In most mammals it ossifies, to form a distinct bone, the epihyal. The ventral extremity of the cartilage of Reichert, the **ceratohyal**, produces the lesser cornu of the hyoid bone.

#### THE DEVELOPMENT OF THE APPENDICULAR SKELETON.

The **upper** and **lower limbs** articulate with the trunk through the medium respectively of the **pectoral** and **pelvic** girdles, the former being constituted by the scapula and the clavicle, and the latter by the ossa innominata. As in the case of the axial skeleton, the bones of the limbs in their development pass successively through a membranous and a cartilaginous stage.

The general development of the upper and lower extremities is described in a later section. As stated in that account, each limb-bud is to be regarded as an outgrowth from several primitive segments, the tissue composing the little bud-like process subsequently differentiating into the muscular, cartilaginous, and connective-tissue elements of the member. The origin of each limb from more than one primitive segment has been established chiefly by embryological investi-

<sup>1</sup> See foot-note, page 105.

gations upon the lower vertebrates, and is borne out by the fact that each extremity receives its nerve-supply from a series of spinal nerves instead of from the nerve-trunk of any one segment.

**The Development of the Pectoral and the Pelvic Girdles.**—The **pectoral** or **shoulder girdle** consists in its earliest stage of a pair of curved bars of cartilage, each of which is made up of a dorsal limb occupying approximately the position of the future spine of the scapula and approaching but not touching the spinal column, and a ventral segment lying near the ventral surface of the trunk. At the angle of union of the dorsal and ventral parts is a shallow depression, an articular surface, which represents the point of articulation with the future humerus.

The **scapula** is developed, except its coracoid process, from the dorsal part of the primitive shoulder-girdle. This soon acquires a form resembling that of the adult scapula with the infraspinous portion of the bone very much shortened. Ossification begins at the neck of the scapula about the eighth week, and in the third month extends into the spine. The ventral part of the cartilaginous shoulder-girdle extends almost to the median line of the chest-wall. It divides into two diverging bars, the lower one of which undergoes ossification in birds and in some other vertebrates to form the conspicuous **coracoid bone**. In mammals, however, it aborts and gives rise to a smaller element, the **coracoid process** of the scapula. At birth the human scapula is but partially ossified, the coracoid process, the acromion, the edges of the spine, the base, the inferior angle and margins of the glenoid cavity being cartilaginous. The coracoid process ossifies from a single center and acquires osseous union with the body of the bone at about the age of puberty. The acromion ossifies from two or three nuclei and joins the spine between the twenty-second and twenty-fifth years. Still other centers of ossification appear from time to time. Thus there is an accessory center for the base of the coracoid and the adjacent part of the glenoid cavity,

and one at the inferior angle of the bone, from which latter ossification extends along the vertebral border.

The **clavicle** does not develop from the primitive shoulder-girdle, but is formed in membrane, for the most part, as a dermal bone. Its ossification begins in the sixth or seventh week, before that of any other bone in the body. Subsequently, **cartilaginous epiphyses** are added, one at each end. It is by means of the epiphyses that the bone grows in length.

The **cartilaginous pelvic girdle** consists of a pair of cartilages, which are united with each other by their ventral extremities, and each of which, by its dorsal end, is articulated with the sacral region of the cartilaginous spinal column. At about the middle of each cartilage, on its outer surface, is a depression representing the future **acetabular fossa**. Anterior to the depression is a large aperture, the **thyroid foramen**, the upper and lower boundaries of which are respectively the **pubic** and **ischiatric** rods or bars, which make up the ventral portion of the cartilage, while posterior to the fossa is the **iliac segment**, which has a somewhat irregular plate-like form. Ossification begins in the third month, proceeding from three centers, one for each of the three divisions of the innominate bone. At the time of birth a large proportion of the original cartilage is still present, the os pubis, the ischium, and the ilium being separated from each other up to the age of puberty by strips of cartilage. The ischium and the pubes unite first, and later acquire osseous union with the ilium. In addition to the three primary centers of ossification, other and secondary nuclei appear at a later date in the crest of the ilium, the tuberosity of the ischium, and in the various spines and tubercles.

The skeleton of the **free portions of each extremity**, consisting at first of a continuous mass or rod of partially metamorphosed mesenchymal tissue, undergoes division into segments which represent the skeleton of the arm or of the thigh, of the forearm or of the leg, and of the hand or of the foot. This segmentation corresponds with that of the entire mass

of the limb, both as to extent and order of appearance (see page 380). Nuclei of chondrification now appear, one in the center of each skeleton-piece, from which cartilage formation extends toward either end. The several cartilaginous elements thus produced present approximately the respective forms of the future bones. The larger cartilages are present in the upper extremity in a six weeks' embryo, but not until somewhat later in the lower limb. All the bones of the extremities are of endochondral origin.

The **long bones** develop in a fairly uniform manner. The shaft or diaphysis ossifies from a single center, while the two epiphyses each present several centers. The centers for the diaphyses appear at about the eighth week, ossification proceeding at such rate that at birth only the ends of the long bones are cartilaginous. The centers for the epiphyses appear at various times after birth. Osseous union between the diaphysis and the epiphyses does not occur until the growth in length of the bone is completed. As the details concerning the time of appearance and the number of these centers are to be found in the text-books of anatomy, they are omitted here.

Each **bone of the carpus** and of the **tarsus** ossifies from a single center, except the os calcis, which has two ossific nuclei. The bones of the carpus are entirely cartilaginous at birth, their ossification beginning in the first year with the appearance of a center in the scaphoid. The pisiform bone is the last of the series to ossify, its ossification beginning in the twelfth year.

The **bones of the tarsus** begin to ossify earlier than those of the carpus. The os calcis and the astragalus present osseous nuclei in the sixth or seventh fetal month, and the cuboid shortly before birth. With these exceptions the tarsal bones undergo ossification between the first and the fourth years.

The **metacarpal** and the **metatarsal bones** and the **phalanges** present each a center of ossification for the shaft and one epiphyseal center. In the case of the phalanges and of the metacarpal bone of the thumb and of the great toe, the epiphyseal center is at the proximal extremity, while in the

remaining metatarsal and metacarpal bones it is at the distal end.<sup>1</sup> The ossification of the shaft begins in the eighth or ninth week of fetal life; of the epiphyses, not until several years after birth. The development of the ungual or distal phalanges—of the hand, at least—is peculiar in that the ossification begins at the distal extremity, instead of in the middle of the shaft.

### THE DEVELOPMENT OF THE LIMBS.

The limbs of vertebrates develop from little bud-like processes (Fig. 51) that spring from **two lateral longitudinal ridges**, situated one on each side of the body. These ridges are not exactly parallel with the median plane of the body, but converge somewhat toward that plane as they approach the caudal end of the embryo. It results from this circumstance that the posterior limbs are placed closer together than the anterior. In man, the **limb-buds** appear soon after the third week. Each bud contains a basis of primitive connective tissue contributed by several somites, as well as muscular structure, which is the offshoot from the muscle-plates of a less number of primitive segments.

The assumption of the origin of each limb-bud from more than one primitive segment is borne out by the nerve-supply of the fully-formed limb, each extremity being innervated by a number of spinal nerves (compare page 344). The connective tissue of the limb-bud produces the bony structures of the limb, while the outgrowths from the muscle-plates contribute their musculature.

In the fifth week each limb-bud becomes divided, by a **transverse groove**, into two segments (Fig. 48, 12, 13), of which the distal part becomes the hand or foot, while the proximal portion very soon afterward divides into the forearm and arm or leg and thigh. Even as early as the thirty-second day, the **digitation** of the limb-buds—in the case of the upper extremities—is indicated by four longitudinal parallel lines or grooves on the distal extremity

<sup>1</sup> Quain's Anatomy, 10th edition.

of each (Fig. 48, 14). By the conversion of these grooves into clefts, the **fingers** appear, in the sixth week, as separate outgrowths. The development of the upper extremities precedes that of the lower by twelve or fourteen days, so that, when the fingers are present as distinct projections, the **toes** are just being marked off in the manner noted above for the fingers. The toes begin to separate, by the deepening of the intervening clefts, from the fiftieth to the fifty-third day. By the end of the eighth week, the fingers are perfectly formed, with the exception of the nails. The **nails** have their beginning in the seventh or eighth week, in little claw-like masses of epidermal cells, which are attached to the tips of the digits instead of to the dorsal surfaces. Subsequent transformations result in bringing the nail into its normal position on the dorsal surface of the distal phalanx. The nails are well formed by the fifth month, at which time the covering of modified epidermal cells begins to disappear. The extremity of the nail, however, does not break through so as to project beyond the finger-tip until the seventh month. A more complete account of the development of the nails will be found in connection with the origin of the skin (page 247).

**The Position of the Limbs.**—The paddle-like limb-buds at first project laterally almost at right angles with the axis of the trunk. At this time the future dorsal surface of each limb looks toward the back of the fetal body (dorsad), the future flexor surface toward its anterior aspect (ventrad), while the first digits—the future thumb and great toe—and consequently the radius and tibia, occupy the side of the member that is directed headward or cephalad, the future little finger and fifth toe with the ulna and fibula looking caudad. As the limbs enlarge and differentiate into their respective segments, they apply themselves to the ventral surface of the body, this change in position being facilitated by the occurrence of the future elbow- and knee-flexions, which cause the flexor surfaces of the forearm and leg, respectively, to approach the corresponding surfaces of the upper arm and thigh. At about the same time, the distal segments, the hand and foot, become bent in the opposite

direction, producing the condition of the limbs that is permanent in the Amphibia—that is, the condition in which the dorsal surface of the proximal segment of the limb faces in the same direction as the dorsal surface of the trunk, while the middle segment is flexed and the distal is extended. To establish the permanent condition of the human limbs, there occur an outward rotation of the arms and an inward rotation of the lower extremities, on their long axes. The thumb and radius, therefore, instead of looking cephalad, are now directed dorsad—with the forearm in the supine position and the arm outstretched—or laterad, away from the median plane of the body, if the arm hangs by the side in the anatomical position. By the inward rotation of the lower limb, the great toe and the tibia come to lie toward the median plane of the body, causing the extensor surface to look ventrad, the flexor surface, dorsad.

## TABULATED CHRONOLOGY OF DEVELOPMENT.

<p>Maturation of ovum in Graafian follicle. Rupture of follicle. Entrance of ovum into oviduct. Fertilization.</p>	STAGE OF THE OVUM.	
	FIRST WEEK.	SECOND WEEK.
General Characters.	Segmentation of fertilized ovum to form morula while passing along oviduct to uterus. Cleavage-cavity present, marking stage of blastula. Great increase in size. Cells of inner cell-mass rearranged to form entoderm and ectoderm. Outer cells become thin—cells of Rauber. Embryonal area. Primitive streak. Mesoderm. (Amnion completed at 4th or 5th day. Peters.) Trophoblast and early syncytium (3d day).	Ovum in uterus, embedded in mucosa. Amnion. Chorion and its villi (Fig. 39). Vascularization of chorion and its villi. Yolk-sac partly formed.
Vascular System.		Heart indicated as two tubes in splanchnic mesoderm. Vascular system represented by vascular area of yolk-sac.
Digestive System.		Oral pit (12th or 14th day). Gut-tract partly separated from yolk-sac.
Respiratory System.		
Genito-urinary System.		
Skin.		
Nervous System.		Medullary plate (14th day).
Special Sense Organs.		Nasal areas.
Muscular System.		
Skeleton and Limbs.		

TABULATED CHRONOLOGY OF DEVELOPMENT (*Continued*).

	STAGE OF THE EMBRYO.	
	THIRD WEEK.	FOURTH WEEK.
<b>General Characters.</b>	Body of embryo indicated. Dorsal outline concave. Vitelline duct (21st day). Segmentation of paraxial mesoderm begins. Visceral arches and clefts begin to appear. Nasofrontal process. Allantoic stalk (Fig. 46). Distinction between chorion leve and chorion frondosum begins.	Marked flexion of body (21st to 23d day); gradual uncoiling after 23d day. Visceral arches and yolk-sac attain greatest development (28th day). Somites well formed. Well-marked tail (25th day). Lining cells of coelom begin to flatten. Increased growth of allantois. Cephalic flexures.
<b>Vascular System.</b>	Heart with single cavity present, soon dividing into atrium and ventricle. Vitelline circulation begun. Visceral-arch vessels begin to appear.	Division of atrium begins. Completed condition of vitelline circulation. Allantoic vessels developing.
<b>Digestive System.</b>	Gut-tract a straight tube connected with yolk-sac by a wide aperture. Liver-evagination present. Oral pit a five-sided fossa. Anal plate.	Alimentary canal presents pharynx, esophagus, stomach, and intestine. Pancreas begun. Liver-diverticulum divides. Bile-ducts acquire lumina. Pharyngeal membrane breaks down.
<b>Respiratory System.</b>	Pulmonary anlage as a longitudinal protrusion of ventral wall of esophagus, afterward becoming a stalked sac.	Pulmonary anlage bifurcates, the two pouches being connected by a pedicle, the primitive trachea, with the pharynx.
<b>Genito-urinary System.</b>	Wolfian bodies recognizable.	
<b>Skin.</b>	Segmentation of paraxial mesoderm.	Somites or primitive segments. Cutis-plate.
<b>Nervous System.</b>	Neural canal: its cells show differentiation into spongioblasts and germ-cells. Fourth ventricle indicated. Fore-brain, mid-brain, and hind-brain vesicles, soon dividing into five vesicles.	Walls of cerebral vesicles thicken. Ventral roots of spinal nerves. Anterior lobe of hypophysis begins.
<b>Special Sense Organs.</b>	Auditory pit followed by otic vesicle. Olfactory plates. Optic vesicles begin. Lens-vesicles.	Otic vesicle with recessus labyrinthi. Nasal pits distinct. Optic vesicle stalked and transformed into optic cup.
<b>Muscular System.</b>	Segmentation of paraxial mesoderm.	Somites or primitive segments. Myotomes.
<b>Skeleton and Limbs.</b>	Segmentation of paraxial mesoderm. Notochord.	Somites or primitive segments. Skeletogenous sheath of chorda. Limb-buds apparent (about 21st day).

TABULATED CHRONOLOGY OF DEVELOPMENT (*Continued*).

STAGE OF THE FETUS.	
FIFTH WEEK.	SIXTH WEEK.
Body shows dorsal concavity in neck-region. Globular and lateral nasal processes. Lacrimal groove. Third and fourth gill-clefts disappear in sinus præcervicalis. Umbilical cord longer and more spiral. Umbilical vesicle begins to shrink. Length of fetus 1 cm. ( $\frac{3}{8}$ inch).	Nasofrontal, lateral nasal, and maxillary processes unite. Umbilical vesicle shrunk. Amnion larger.
Primitive aorta divides into aorta and pulmonary artery. The only corpuscular elements of the blood during the first month are the primitive nucleated red blood-cells.	Vitelline circulation atrophic and replaced by allantoic circulation.
Intestine shows flexures, notably the U-loop, inaugurating the distinction between large and small bowel. Anal pit.	First indication of teeth in the form of the dental shelf. Submaxillary gland indicated by epithelial outgrowth. Duodenum well formed; cæcum; rectum (end of week).
Right and left bronchi divide into three and two tubes respectively (5th to 7th week).	Larynx indicated as dilatation of proximal end of trachea. Arytenoid cartilages indicated (though not cartilaginous). Thyroid and thymus bodies begun.
Genital ridges appear on wall of body-cavity and soon become the indifferent genital glands. Ducts of Müller appear.	Genital tubercle, genital folds, and genital ridge (external genitals).
Epidermis present as two layers of cells.	Cells of cutis-plate proliferate and gradually spread out beneath epidermis.
Olfactory lobe begins. Arcuate and choroidal fissures on mesial surfaces of fore-brain vesicles. Cells of central canal of cord ciliated. Ridge-like thickening of roof of mid-brain.	Membranes of brain and cord indicated. Pineal body begins. Dorsal roots of spinal nerves. Some tracts of spinal cord indicated, and its lumen alters (Fig. 123).
Semicircular canals indicated. Eyes begin to move forward from side of head.	Semicircular canals. Concha of external ear. Outer fibrous and middle vascular tunics of eye. Eyelids.
Mandibles unite (35th day). Meckel's cartilage. Limb-buds segment. Digitation indicated (32d day) for hand.	Lower jaw begins to ossify. Clavicle begins to ossify. Ribs begin to chondrify. Bodies of vertebrae are cartilaginous. Fingers as separate outgrowths.

TABULATED CHRONOLOGY OF DEVELOPMENT (*Continued*).

	STAGE OF THE FETUS.	
	SEVENTH WEEK.	EIGHTH WEEK.
<b>General Characters.</b>	Fetal body and limbs well defined (Fig. 53). Head less flexed. No longer any trace of syncytium on decidua vera.	Head more elevated (Fig. 54). Free tail begins to disappear. Subcutaneous lymph-vessels present. Cells lining the coelom are true endothelium.
<b>Vascular System.</b>	Interventricular septum of heart completed, the heart now having four chambers. Other corpuscular elements added to blood during second month.	
<b>Digestive System.</b>	Transverse colon and descending colon indicated.	Parotid gland begins. True endothelium lines the body-cavity. Gall-bladder present (2d month). Anlage of spleen recognizable (2d month).
<b>Respiratory System.</b>	Median and lateral lobes of thyroid unite.	Larynx begins to chondrify. Formation of follicles of thymus.
<b>Genito-urinary System.</b>	Maximum development of Wolffian body.	Müllerian ducts unite with each other. Genital groove. Bladder present as spindle-shaped dilatation of allantois. Suprarenal bodies recognizable.
<b>Skin.</b>	Nails indicated by claw-like masses of epithelium on dorsal surfaces of digits.	Corium indicated as a layer of spindle-cells beneath epidermis. Development of mammary glands begun.
<b>Nervous System.</b>	Fore-brain vesicles increase in size disproportionately. Cerebellum indicated.	Sympathetic nerves discernible.
<b>Special Sense Organs.</b>		External nose definitely formed (Fig. 155). Lens-capsule. Palpebral conjunctiva separates from cornea.
<b>Muscular System.</b>	Muscles begin to be recognizable, though not having as yet the characters of muscular tissue.	
<b>Skeleton and Limbs.</b>	Ossific centers for vertebral arches and for vertebral bodies; ossific centers for frontal bone and for squamosa. Membranous primordial cranium begins to chondrify. Claw-like anlagen of nails.	Ribs begin to chondrify. Centers of ossification of basisphenoid, of greater wings, of nasal and lacrimal bones, of malar, vomer, palate, neck of scapula, diaphyses of long bones and of metacarpal bones. Fingers perfectly formed. Toes begin to separate (53d day).

TABULATED CHRONOLOGY OF DEVELOPMENT (*Continued*).

STAGE OF THE FETUS.	
NINTH WEEK.	THIRD MONTH.
Weight, 15 to 20 grams; length, 25 to 30 mm. (1 to 1½ inches). Hard palate completed. Free tail has disappeared. Differentiation of lymph-nodes begins (O. Schultze). Cloaca divided.	Weight (end of month), 4 ounces; length, 2½ inches. At first chorion leve and chorion frondosum present; later, formation of placenta (see second frontispiece).
Pericardium indicated.	Placental system of vessels. Blood-vessels penetrate spleen.
Anal canal formed by division of cloaca. (Anus opens at end of 2d month, according to Tournoux.)	Mouth-cavity divided from nose (end of month). Soft palate completed (11th week). Papillæ of tongue. Evagination for tonsil. Intestine begins to recede within abdomen (10th week). Rotation of stomach. Vermiform appendix as a slender tube. Omental bursa. Gastric glands and glands and villi of intestine fairly well formed (10th week). Liver very large. Peritoneum has its adult histological characters.
	Epiglottis.
External genitals begin to show distinctions of sex. Ovary and testis distinguishable from each other. Kidney has its characteristic features. Urogenital sinus acquires its own aperture by division of cloaca.	Union of testis with canals of Wolffian body complete. Testes in false pelvis. Ovaries descend. Prostate begun (12th week).
	Corium proper present as distinct layer. Nails not quite perfectly formed. Beginning of development of hair as solid ingrowths of epithelium.
Corpus striatum indicated. Corpora quadrigemina represented by two elevations on mid-brain roof.	Cerebrum covers inter-brain. Fornix and corpus callosum begun. Fissure of Sylvius. Calcarine fissure. Crura cerebri. Restiform bodies. Pons.
External ear indicated (Fig. 154). Ciliary processes indicated.	Eyes nearly in normal position. Eyelids begin to adhere to each other.
Centers of ossification of presphenoid, of lesser wings of sphenoid, and of shafts of metatarsal bones.	Beginning ossification of occipital bone, of tympanic, of spine of scapula, of ossa innominata. Cartilaginous arches of vertebræ close. Limbs have definite shape; nails almost perfectly formed.

TABULATED CHRONOLOGY OF DEVELOPMENT (*Continued*).

	STAGE OF THE FETUS.	
	FOURTH MONTH.	FIFTH MONTH.
<b>General Characters.</b>	Weight, $7\frac{3}{4}$ ounces; length, 5 inches. Head constitutes about one-quarter of entire body.	Weight, 1 lb.; length, 8 in. Active fetal movements begin. Two layers of decidua coalesce, obliterating the space between vera and reflexa. Lymphatic glands begin to appear.
<b>Vascular System.</b>		Heart very large.
<b>Digestive System.</b>	Enamel and dentine of milk-teeth. Germs of permanent teeth (17th wk); (for 1st molar, 16th wk). Muscularis (longitudinal and circular) of stomach and esophagus. Intestine entirely within abdomen. Acid cells of peptic glands. Malpighian bodies of spleen. Anal membrane disappears.	Salivary glands acquire lumina. Villi of large intestine begin to disappear. Liver very large. Meconium shows traces of bile (sometimes early in fourth month).
<b>Respiratory System.</b>	Cells of tracheal and bronchial mucous membrane ciliated.	
<b>Genito-urinary System.</b>	Sexual distinctions of external organs well marked. Closure of genital furrow. Scrotum. Prepuce. Prostate well formed.	Distinction between uterus and vagina. Hymen begins.
<b>Skin.</b>	Papillæ of corium. Subcutaneous fat first appears. Lanugo or embryonal down on scalp and some other parts.	Panniculus adiposus. Lanugo more abundant. Sebaceous and sweat-glands begin.
<b>Nervous System.</b>	Parieto-occipital fissure. Corpora albicantia. Transverse fibers of pons. Middle peduncles and chief fissures of cerebellum. Spinal cord ends at end of coccyx. Deposit of myelin on fibers of posterior roots, extending to Burdach and Goll.	Fissure of Rolando. Body of fornix and corp. callosum. Longitudinal fibers in crura cerebri. Superior peduncles. Anterior pyramids of medulla. Chief transverse fissures of lateral lobes of cerebellum. Deposit of myelin completed for tract of Goll and later of Burdach, and for short commissural fibers (Tourneux).
<b>Special Sense Organs.</b>	Eyelids and nostrils closed. Cartilage of Eustachian tube.	Organ of Corti indicated.
<b>Muscular System.</b>		Differentiation of muscular tissue of arms.
<b>Skeleton and Limbs.</b>	Osseous center for internal pterygoid plate. Antrum of Highmore begins. Ossification of malleus and incus. Tympanic ring.	Ossification of stapes and petrosa. Opisthotic and prootic appear. Ossification begins in middle and inferior turbinals and lateral masses of ethmoid. Internal pterygoid plate fuses with external. Intermaxillaries fuse with maxilla. Legs longer than arms.

TABULATED CHRONOLOGY OF DEVELOPMENT (*Continued*).

STAGE OF THE FETUS.	
SIXTH MONTH.	SEVENTH MONTH.
Weight, 2 pounds; length, 12 inches. Vernix caseosa begins to appear. Amnion reaches maximum size; amniotic fluid of maximum quantity.	Weight, 3 pounds; length, 14 inches. Surface less wrinkled owing to increase of fat.
Peyer's patches. Trypsin in pancreatic secretion (fifth or sixth month).	Meconium in large intestine. Ascending colon partly formed. Cæcum below right kidney.
Air-vesicles of lungs begin to appear.	
Walls of uterus thicken.	Testes at internal rings or in inguinal canals.
Vernix caseosa begins to appear. Eyebrows and eyelashes begin.	Epithelial buds for sebaceous glands acquire lumina. Branching of cords of milk-glands. Eponychium of nails lost; nails said to break through. Lanugo over entire body.
Collateral and calloso-marginal fissures. Body of fornix and corpus callosum complete. Hemispheres of cerebrum cover mid-brain.	Cerebral convolutions more apparent. Corpora quadrigemina. Myelination of fibers of direct cerebellar tracts. (Crossed pyramidal tracts not until after birth.)
Lobule of ear more characteristic.	Lens-capsule begins to acquire transparency. Eyelids permanently open. Pupillary membrane atrophies.
	Differentiation of muscular tissue of lower extremities.
Lesser wings unite with presphenoid. Meckel's cartilage begins to retrograde. Ossific nuclei of os calcis and astragalus.	Basisphenoid and presphenoid unite (7th or 8th month).

TABULATED CHRONOLOGY OF DEVELOPMENT (*Concluded*).

	STAGE OF THE FETUS.	
	EIGHTH MONTH.	NINTH MONTH.
<b>General Characters.</b>	Weight, 4 to 5 pounds; length, 16 inches. Body more plump.	Weight, 6 to 7 pounds; length, 20 inches. Umbilicus almost exactly in middle of body.
<b>Vascular System.</b>		
<b>Digestive System.</b>	Ascending colon longer. Cæcum below crest of ilium.	Meconium dark greenish.
<b>Respiratory System.</b>		
<b>Genito-urinary System.</b>	Testes in inguinal canals.	Testes in scrotum. Labia majora in contact.
<b>Skin.</b>	Vernix caseosa covers entire body. Skin brighter color. Lanugo begins to disappear. Nails project beyond fingertips. Increase of subcutaneous fat.	Lanugo almost entirely absent. Galactopherous ducts of milk-glands acquire lumina.
<b>Nervous System.</b>		Spinal cord ends at last lumbar vertebra.
<b>Special Sense Organs.</b>		Ossification of bony lamina spiralis and of modiolus. Neuro-epithelial layer of retina completed; macula still absent. Choroidal fissure closes.
<b>Muscular System.</b>		
<b>Skeleton and Limbs.</b>		Ossification in lower epiphysis of femur, sometimes also in upper epiphyses of tibia and humerus. Tympanohyal begins to ossify. Ossific nuclei for body and great horn of hyoid bone.

# INDEX.

- ABDOMINAL cavity, development of, 198  
 Accessory thyroid, 209  
 Acetabular fossa, 378  
 Achoria, 84  
 Achromatin, 25  
 Acid cells, formation of, 189  
 Acoustic ganglion, 297  
 Acusticofacial ganglion, 297  
 Adamantoblasts, 127  
 Adenoid tissue, development of, 117  
 Adipose tissue, formation of, 115  
 After-birth, 94  
 After-brain, 263  
 Age of fetus, estimation of, 111  
 Air-chamber of hen's egg, 27  
 Air-sacs, development of, 207  
 Alæ of nose, development of, 338  
 Allantoic arteries, 81, 148  
     circulation, 81  
     formation of, 148  
     stalk, 76  
     veins, 81, 148  
 Allantois, 80, 173, 232  
     function of, 81  
     respiratory function of, 183  
 Alar lamina, 266  
 Alecithal ova, 24  
 Alimentary canal, development of, 168  
     differentiation into separate regions, 180  
     histological alterations in, 188  
     tract, alteration in position of parts, 185  
     increase in length of, 184  
 Alveoli, pulmonary, development of, 207  
 Ameloblasts, 127  
 Amnion, 73, 74  
     false, 73  
     of man, 76  
 Amnion-fold, 72, 73, 75  
 Amniota, 75  
 Amniotic cavity, 76, 77  
     fluid, 76, 77  
     function of, 77  
     suture, 75  
 Amphibians, blastula of, 46  
 Amphioxus, blastula of, 45  
     skeletal apparatus of, 347  
 Ampullæ of semicircular canals, development of, 324  
 Ampullæ, seminal, 223  
 Anal canal, 233  
     membrane, 178  
     plate, 178  
 Anamnia, 75  
 Animal pole, 25  
 Animalculists, 18  
 Anlage, 159  
 Annular sinus, 163  
 Anomalous arrangements of aortic arch, 152  
 Anterior chamber of eye, 318  
     nares, development of, 134, 336  
     pyramidal tracts of medulla, development of, 266  
 Antitragus, formation of, 333  
 Antrum of Highmore, development of, 337  
 Anus, development of, 178  
     imperforate, 180  
 Aorta, caudal, 150  
     development of, 144  
     primitive, 137, 150  
 Aortic arch, anomalous arrangements of, 152  
     arches, 149  
 Appendages of skin, 247  
 Appendicular skeleton, 347  
     development of, 376  
 Aqueduct of Sylvius, development of, 271  
 Arch, hyoid, 104  
     mandibular, 104  
     maxillary, 104  
     of aorta, development of, 152  
 Archenteron, 47, 49  
 Arches, aortic, 149  
     branchial, 103  
     mandibular, 123  
     visceral, 101  
 Archiblast, 58  
 Arcuate fissure, 282, 283  
 Area, embryonal, 50  
     glandular, 251  
     opaca, 51  
     pellucida, 51  
     vasculosa, 51, 79, 136  
 Areas, nasal, 133, 334  
 Areola, development of, 252  
 Areolar tissue, development of, 114  
 Arrectores pilorum, 246  
 Arteria centralis retinæ, development of, 311

- Arterial system, fetal, 149  
 Arteries, allantoic, 81, 148  
     umbilical, 93, 149  
     vitelline, 137  
 Artery, carotid, common, develop-  
     ment of, 151  
     external, development of, 151  
     internal, development of, 151  
     innominate, development of, 152  
     middle sacral, development of, 150  
     pulmonary, development of, 152  
     subclavian, left, development of,  
         152  
     right, development of, 151  
     superior vesical, 166  
 Arytenoid cartilages, development of,  
     207  
 Ascending colon, formation of, 186  
     mesocolon, formation of, 186  
     root of fifth nerve, 206  
     root of vagus, 266  
 Aster, 41  
 Atlas, formation of, 355  
 Atresia of pupil, 314  
 Atrioventricular canal, 141  
     valves, 142  
 Atrophic tubules of Wolffian body,  
     216  
 Attraction-sphere, 41  
 Auditory apparatus, development of,  
     321  
     meatus, external, formation of, 332  
     nerve, formation of, 297  
     nucleus, lateral accessory, 297  
     pit, 322  
 Auricle, development of, 333  
 Auricles, division into right and left,  
     142  
 Auricular appendages, 144  
     canal, 141  
 Auriculoventricular apertures, 145  
     valves, 146  
 Axial fiber of spermatozoon, 20  
     skeleton, 347  
         development of, 348  
 Axis, development of, 354  
 Axis-cylinder process, 260  
  
 BARTHOLIN, glands of, 237  
 Basal ganglia, 279, 280  
     lamina, 266  
 Basi-occipital bone, 364  
 Basisphenoid, 368  
 Belly-stalk, 76  
 Bifid uterus, 230  
 Bile-capillaries, formation of, 192  
 Bile-ducts, formation of, 192  
 Bladder, development of, 232  
 Blastopore, 47  
 Blastula, stage of, 45  
 Blood, development of, 115, 135  
 Blood-corpuscles, red, primitive, 136  
 Blood-islands, of Pander, 135  
 Blood-lacunæ, 87  
 "Blue baby," 142  
 Bodies, polar, 31  
 Body of vertebra, formation of, 352  
 Body-cavity, 55, 58, 197  
 Body-wall, development of muscles  
     of, 343  
     formation of, 71  
 Bony cochlea, development of, 327  
     labyrinth, development of, 326  
     semicircular canals, 327  
 Bowman, capsule of, 216, 217  
 Brain, development of, 262  
 Brain-case, 358  
 Brain-membranes, development of,  
     278  
 Brain-vesicles, 262  
     derivatives of, 292  
 Branchial arches, 103  
     development of, 344  
 Bridge of nose, development of, 338  
 Brunner, glands of, 189  
 Bulbus arteriosus, 142  
     vestibuli, 237  
 Burdach, tract of, myelination of, 388  
 Bursa, omental, 187, 200  
     pharyngeal, 124  
 Bursal sacs, development of, 115  
  
 CADUCOUS membranes, 85  
 Cæcum, development of, 185, 186  
 Calcar avis, 284  
 Calcarine fissure, 279, 284  
 Callosomarginal fissure, 285  
 Calyces of kidney, formation of, 218  
 Canal, anal, 233  
     atrioventricular, 141  
     auricular, 141  
     hyaloid, 315  
     medullary, 62  
     neural, 62, 255, 257  
     neurenteric, 66, 257  
     of anus, 180  
     of His, 133, 208  
     of Nuck, 232  
     of Stilling, 315  
 Canaliculi, lacrimal, development of,  
     320  
 Canalis reuniens, 324  
 Capsule of Bowman, 216, 217  
 Cardinal veins, 148, 154  
 Carotid artery, common, development  
     of, 151  
     external, development of, 151  
     internal, development of, 151  
 Carpus, development of bones of, 379  
 Cartilage, formation of, 115  
     Meckel's, 104, 372  
     Reichert's, 104  
 Cartilage-cells, 115  
 Cartilaginous capsule of cochlea, 328  
     cranium, 360  
     ear-capsule, 326  
     ribs, 356  
     sheath of spinal cord, 353  
     stage of skeleton, 348  
     of trunk skeleton, 351

- Caudal aorta, 150  
 Cavity, amniotic, 76  
   pleuroperitoneal, 58  
   segmentation, 45  
 Cell-mass, inner, 45  
   intermediate, 69  
   outer, 45  
 Cells, sexual, 29  
   mesenchymal, 58  
 Cementum of tooth, 125  
   development of, 129  
 Central canal of cord, formation of, 262  
   lobe, formation of, 281  
 Centrolecithal ova, 25  
 Centrosome, 41  
 Cephalic flexure, 101, 264  
   ganglia, development of, 296  
 Ceratohyal, 376  
 Cerebellum, development of, 268  
 Cerebral fissures, development of, 278  
   vesicles, 262, 263  
 Ceruminous glands, 250  
 Cervical fistula, 105  
   flexure, 101  
   rib, 354, 357  
 Chalazæ, 27  
 Chambers of eye, 318  
 Chorda dorsalis, 65  
   formation of, 348  
   stage of, 348  
 Chordæ tendineæ, 146  
 Chordal epithelium, 349  
   plate, 66  
   region of primitive skull, 361  
 Choriata, 84  
 Choriocapillaris, 316  
 Chorion, 82  
   frondosum, 84  
   leve, 83  
   primitive, 82  
   true, 82  
 Choroid, coloboma of, 316  
   development of, 316  
   fissure, 282, 283  
   plexus, 284  
   plexuses of fourth ventricle, 267  
 Choroidal fissure, 306, 316  
 Chromatin substance, 25  
 Cicatricula, 26  
 Ciliary body, development of, 316  
   ganglion, 296  
   muscle, development of, 316  
   processes, development of, 309, 316  
 Circulation, allantoic, 81, 148  
   placental, 135  
   portal, 161  
   vitelline, formation of, 135  
 Claustum, 279  
 Clavicle, development of, 378  
 Cleavage, kinds of, 43  
   of ovum, 41  
   partial discoidal, 44  
   peripheral, 44  
   total equal, 43  
 Cleavage, total unequal, 43  
 Cleavage-cavity, 45  
 Cleavage-nucleus, 39  
 Cleavage-planes, 42  
 Cleft palate, formation of, 125  
   sternum, 357  
   cause of, 74  
   uvula, formation of, 125  
 Clefts, visceral, 101  
 Climacteric, 35  
 Clitoris, development of, 235, 236  
 Cloaca, 173, 179, 233  
 Cloacal depression, 180, 233  
 Closing membrane, 102, 106, 177  
 Coccygeal curve, 101  
   vertebræ, ossification of, 356  
 Cochlea, bony, development of, 327  
 Cochlear duct, formation of, 323  
   ganglion, 297  
   nerve, 329  
 Cœlenteron, 47, 49  
 Cœlom, 55, 58, 197  
 Collateral fissure, 279, 284  
 Coloboma of choroid, 316  
   of iris, 318  
 Colon, ascending, formation of, 186  
   descending, formation of, 184, 186  
   transverse, formation of, 186  
 Columnæ carneæ, 140  
 Commissures of brain, development of, 279  
   of cord, white, 260  
 Conarium, 274  
   modifications of, 274  
 Cone-visual cells, 307  
 Congenital atresia of pupil, 314  
   diaphragmatic hernia, 161  
   fecal fistula, 190  
   hernia, 226  
   umbilical hernia, 188  
 Coni vasculosi, formation of, 223  
 Connective tissues, development of, 113  
 Constructive stage of menstrual cycle, 35  
 Copula of hyoid bone, 363  
 Coracoid bone, 377  
   process of scapula, 377  
 Cord, spinal, development of, 257  
   umbilical, 92  
 Cords of cells, 135  
 Corium, development of, 245  
 Cornea, development of, 315  
 Corona radiata, 23, 29  
 Coronary ligament, 193  
   of liver, 202  
   sinus of heart, 156  
   valve, 144  
 Corpora albicantia, 272  
   bigemina, 271  
   cavernosa, formation of, 238  
   quadrigemina, 271  
 Corpus callosum, formation of, 285, 287  
   hemorrhagicum, 33

- Corpus luteum of, pregnancy, 33, 34  
     false, 34  
     of menstruation, 34  
     true, 34  
     spongiosum, formation of, 239  
     striatum, 279  
 Corpuscle of Hassal, 210, 211  
 Corti, organ of, 325  
 Costal process of vertebra, formation of, 352, 356  
 Cotyledons of placenta, 89  
 Covering bones, 359  
 Cowper, glands of, 239  
 Cranial capsule, 358  
     nerve-fibers, development of, 296  
 Cranium, cartilaginous, 360  
     membranous, 359  
     osseous, 363  
 Cristæ acusticæ, 325  
 Crossed pyramidal tract, myelination of, 389  
 Crura cerebri, development of, 270  
 Crusta petrosa, 129  
 Cryptorchism, 226  
 Crystalline lens, development of, 312  
 Cutis-plate, 69, 245, 341  
 Cuvier, duct of, 148, 154, 160  
 Cystic duct, development of, 192
- DAUGHTER-CELLS, 22  
 Daughter-wreaths, 41  
 Decidua menstrualis, 36, 85  
     of pregnancy, 86  
     reflexa, 86  
     serotina, 86, 91  
     vera, 86  
 Decidua, 85  
 Dendrites, 260  
 Dental groove, 126  
     papilla, 127, 128  
     processes, 129  
     ridge, 125  
     shelf, 125  
 Dentale, 374  
 Dentate fissure, 279, 283  
 Dentinal fibers, 129  
     tubules, 129  
 Dentine, 125  
 Dermal bones, 359  
     navel, 74  
 Descending colon, formation of, 186  
 Descent of testicles, 225  
 Destructive stage of menstrual cycle, 36  
 Deutoplasm of hen's egg, 26  
     of ovum, 24  
 Development during eighth month, 111  
     during eighth week, 108  
     during fifth month, 110  
     during fifth week, 107  
     during ninth month, 111  
     during second month, 107  
     during seventh month, 110  
     during sixth month, 110  
     Development during third month, 109  
     during third week, 106  
     length of time necessary for, 18  
     tabulated chronology of, 383  
     theories of, 17  
 Diaphragm, development of, 161  
 Diaphragmatic hernia, congenital, 161  
     ligament, 225  
 Digestive system, development of, 168, 385-390  
 Digitation of limb-buds, 380  
 Diphyodont, 125  
 Direct cerebellar tract, myelination of, 385  
 Discoidal cleavage, partial, 44  
 Discus proligerus, 29, 228  
 Disk, germinative, 26  
 Dorsal curve, 101  
     mesentery, 173  
 Double monster, origin of, 51  
     uterus, 230  
 Duct of Cuvier, 148, 154, 160  
     mesonephric, 214  
     of Gartner, 231  
     of Müller, 220, 224, 230, 242  
     of Rathke, 225  
     pronephric, 212  
     segmental, 213  
     thyroglossal, 133, 208  
     thyroid, 208  
     vitelline, 72, 78, 169  
     Wolffian, 214  
 Ductus Arantii, 164  
     communis choledochus, formation of, 192  
     endolymphaticus, 323  
     venosus, 93, 164  
 Duodenum, formation of, 199
- EAR, external, development of, 331, 333  
     internal, development of, 321  
     middle, development of, 331  
 Ear-capsule, cartilaginous, 326  
 Ectoderm, 47, 48  
     derivatives of, 59  
 Egg, ultimate origin of, 29  
 Egg-columns, 29, 227  
 Egg-envelopes, 23  
 Egg-plasm, 24  
 Egg-tubes, primary, 29  
 Eighth month, development during, 111, 390  
     pair cranial nerves, development of, 299  
     week, development during, 108, 386  
 Ejaculatory duct, formation of, 224  
 Elastic tissue, formation of, 114  
 Eleventh pair of cranial nerves, 300  
 Embedding of ovum, 86  
 Embryo, differentiation of, 61  
     of eight-and-a-half weeks, 110  
     of fifteenth day, 98  
     of six weeks, 107

- Embryo of thirteenth day, 97  
   of three weeks, 101  
   of twenty-eight days, 105  
   segmentation of body of, 69  
   stage of, 19, 96  
 Embryology, defined, 17  
 Embryonal area, 50  
   down, 250  
 Embryonic crescent, 51  
 Eminentia collateralis, 285  
 Enamel of milk teeth, formation of,  
   128  
   of teeth, 125  
 Enamel-cells, 127  
 Enamel-germ, primitive, 126  
 Enamel-germs of permanent teeth,  
   129  
 Enamel-prisms, 127  
 Enamel-sac, 126  
 Endocardium, 140  
 Endochondral bones, 359  
 Endolymph, 331  
 Endoskeleton, 347  
 Endothelium, formation of, 58, 115  
 Enterocœl, 55  
 Entoderm, 47, 48  
   derivatives of, 59  
 Epencephalon, 268  
 Ependyma, 286  
 Ependymal layer, 260  
 Epiblast, 47  
 Epidermis, development of, 245, 246  
 Epididymis, formation of, 223  
   head of, 223  
 Epigenesis, doctrine of, 18  
 Epihyal, 376  
 Epitotic center of ossification, 366  
 Epithelium, germinal, 27, 29, 221  
 Epitrichium, 246  
 Eponychium, 248  
 Epophoron, 231  
 Ethmoid bone, ossification of, 369  
   cribriform plate of, 362  
 Ethmoidal sinus, development of, 337  
 Eustachian tube, development of, 331,  
   332  
   formation of, 177  
   valve, 144  
 Vertebral region of primitive skull,  
   361  
 Exoccipitals, 364  
 Exoskeleton, 347  
 Exstrophy of bladder, cause of, 74  
 External auditory meatus, formation  
   of, 332  
   ear, development of, 331, 333  
   fertilization, 38  
   genitals, female, 236, 243  
   male, 237, 244  
   organs of generation, 234  
 Eye, development of, 122, 302  
 Eyelashes, development of, 319  
 Eyelid, third, 319  
 Eyelids, development of, 318  
   primitive, 122  
 FACE, development of, 106, 118  
 Facial ganglion, 297  
 Falciform ligament of liver, forma-  
   tion of, 193  
   lobe, 285, 289  
 Fallopian tubes, development of, 230  
 False amnion, 73  
 Falx cerebri, 278  
 Fecal fistula, congenital, 190  
 Female external genitals, 236, 243  
   internal genital organs, 226  
   pronucleus, 32  
   sexual system, 243  
 Fertilization, 38  
   artificial, 40  
   external, 38  
   internal, 38  
 Fetal arterial system, 149  
   membranes at birth, 94  
   vascular system, final stage of, 165  
   venous system, 153  
 Fetus, length of, at term, 111  
   stage of, 20, 107  
   weight of, at term, 111  
 Fiber-tracts of cord, development of,  
   261  
   myelination of, 388, 389  
 Fibrillæ of muscle, formation of, 342  
 Fibrous tunic of eye, development of,  
   315  
 Fifth brain-vesicle, metamorphosis  
   of, 264  
   month, development during, 110,  
   388  
   pair cranial nerves, development  
   of, 299  
   ventricle, 288  
   week, development during, 385  
 Fimbria, 285  
 Fingers, development of, 381  
 First pair cranial nerves, develop-  
   ment of, 299  
   week, development during, 393  
 Fissure, arcuate, 282, 283  
   calcarine, 279, 284  
   calloso-marginal, 285  
   choroid, 282, 283  
   choroidal, 306  
   collateral, 279, 284  
   dentate, 279, 283  
   great transverse, 280, 284  
   hippocampal, 283  
   of choroid plexus, 283  
   of Rolando, 284  
   of Sylvius, 279, 280  
   parieto-occipital, 284  
 Fissures, cerebral, development of,  
   278, 279  
   median of cord, 261  
 Fistula, congenital fecal, 190  
   umbilical urinary, 233  
 Flexure, cephalic, 101, 264  
   nuchal, 264  
   pontal, 264  
 Floor-plate, 257, 258

- Fold, pleuropericardial, 160  
 Folds, medullary, 64  
 Follicle, Graafian, 27  
   of tooth, 129  
 Foramen cæcum, 133, 208  
   commune anterius, 282  
   of Monro, 277, 282  
   of Winslow, 203  
   ovale, 143  
 Fore-brain, 262, 278  
   secondary, 263  
   vesicle, 65  
     metamorphosis of, 278  
 Foregut, 73  
 Formative yolk, 24  
 Fornix, formation of, 285, 286  
 Fossa of Sylvius, 280  
   oral, 175  
 Fourth month, development during,  
   109, 388  
   pair cranial nerves, development  
     of, 299  
   ventricle, 267  
     development of, 265, 270  
     week, development during, 384  
 Fretum Halleri, 142  
 Frontal bone, ossification of, 370  
   lobe, 282  
   sinuses, development of, 337  
 Funiculus solitarius, 266
- GALL-BLADDER, development of, 192  
 Ganglia, cephalic, 296  
   spinal, 293  
 Gangliated cord of the sympathetic,  
   301  
 Ganglion, acoustic, 297  
   acusticofacial, 297  
   cephalic, fourth, 297  
   third, 297  
   ciliary, 296  
   cochlear, 297  
   facial, 297  
   Gasserian, 396  
   ophthalmic, 296  
   spirale, 326  
   trigeminal, 297  
   vestibular, 326  
 Ganglion-cell layer, development of,  
   309  
 Gartner, duct of, 231  
 Gasserian ganglion, 296  
 Gastral mesoderm, 55  
 Gastrohepatic omentum, 192, 202  
   formation of, 188  
 Gastrosplenic omentum, 195  
 Gastrula, 47  
   mammalian, 48  
   stage, 47  
 Generative organs, external, develop-  
   ment of, 234  
   internal, development of, 220  
 Genital cord, 220  
   eminence, 235  
   in male, 238
- Genital folds, 235  
   in female, 236  
   in male, 239  
   gland, indifferent, 242  
   groove, 235  
   ridge, 220, 233  
     in female, 237  
   ridges, 29  
 Genito-urinary system, development  
   of, 212, 383-390  
 Germ-cells, 221  
 Germ-disk, 25  
 Germ-layers, 47  
   derivatives of, 58  
 Germinal epithelium, 27, 29, 221  
   spot, 23, 25  
   vesicle, 23, 25  
 Germinative disk, 26  
 Giraldès, organ of, 224  
 Glands of alimentary tract, forma-  
   tion of, 189  
   of Bartholin, 237  
   of Brunner, development of, 189  
   of Cowper, development of, 239  
   of intestine, development of, 189  
   of Lieberkühn, development of,  
     189  
   of Moll, 250  
   of stomach, development of, 189  
 Glandular area, 251  
   hypospadias, 239  
 Glans clitoridis, formation of, 235  
   penis, formation of, 235, 238  
 Glaserian fissure, 367, 373  
 Globular processes, 107, 120, 334  
 Glomerulus of kidney, 213, 216, 217  
 Goll, tract of, myelination of, 388  
 Graafian follicle, 27  
   development of, 228  
   formation of new, 229  
 Gray matter of brain, formation of,  
   279  
   of medulla, development of, 206  
 Great omentum, formation of, 187,  
   201  
 Groove, dental, 126  
   lacrimal, 108, 120  
   medullary, 63  
   naso-optic, 320  
   primitive, 52  
   pulmonary, 205  
   transverse crescentic, 372  
 Gubernaculum testis, 225  
 Gum, development of, 124  
 Gut, postanal, 179  
 Gut-tract, 72, 73, 169, 171  
 Gyrus fornicatus, 291  
   uncinatus, 291
- HAIR, development of, 248  
 Hair-bulb, 248  
   development of, 249  
 Hair-follicle, 248  
   development of, 249, 250  
 Hair-germs, 249

- Hard palate, development of, 371  
 Hare-lip, 122, 371  
 Hassal, corpuscles of, 210, 211  
 Head, muscles of, development of, 343  
     of epididymis, 223  
     of spermatozoon, 20  
 Head-fold, 72  
     of amnion, 72, 75  
 Head-gut, 171  
 Head-kidney, 212  
 Head-process of primitive streak, 54, 62  
 Head-segments, 340  
 Head-skeleton, development of, 358  
 Heart, development of, 138  
     metamorphosis of single into double, 142  
     valves, development of, 144  
 Helix, formation of, 333  
 Hemal arch, formation of, 352  
 Hen's egg, description of, 25  
 Hensen's node, 54  
 Hepatic cylinders, 192  
     vein, development of, 164  
 Hermaphroditism, 239, 244  
 Hernia, congenital, 226  
     umbilical, 188  
 Highmore, antrum of, development of, 336  
 Hilum folliculi, 29  
 Hind-brain, 262, 268  
     secondary, 263  
     vesicle, 65, 268  
 Hindgut, 73, 171  
 Hippocampal fissure, 283  
 Hippocampus major, 283  
     minor, 284  
 His, canal of, 133, 208  
 Holoblastic ova, 43  
 Homogeneous twins, origin of, 51  
 Homologies of the sexual system, 240  
 Hyaloid artery, formation of, 314  
     canal, 315  
     membrane, formation of, 315  
 Hydatid of Morgagni, 224  
     sessile, 224  
     stalked, 224  
     unstaked, 224  
 Hydramnios, 77  
 Hymen, formation of, 237  
 Hyoglossus, origin of, 345  
 Hyoid arch, anterior, 363  
     posterior, 363  
     arches, 104  
     bar, 363  
     bone, development of, 363, 375  
 Hyoidean apparatus, 375  
 Hyomandibular cleft, 104  
 Hypoblast, 47  
 Hypochordal brace, 351  
 Hypophysis, 276  
     formation of, 123  
 Hypospadias, 239  
     glandular, 239  
 ILIAC segment of pelvic girdle, 378  
     vein, left common, development of, 156  
 Imperforate anus, 180  
 Impressions, maternal, 109  
 Incus, development of, 362, 373  
 Indifferent genital gland, 242  
     sexual gland, 221  
 Inferior medullary velum, 268  
     peduncles of brain, 266  
 Infundibula of lungs, development of, 207  
 Infundibulum of brain, 272, 276  
 Inguinal ligament, 225  
     in female, 231  
 Inner cell-mass, 45  
 Innominate artery, development of, 152  
 Inter-brain, 263, 272  
     vesicle, metamorphosis of, 272  
 Intermaxillary bones, formation of, 124, 371  
 Intermedial cell-mass, 69, 341  
 Internal ear, development of, 321  
     fertilization, 38  
     lateral ligament of lower jaw, 374  
     limiting membrane of spinal cord, 259  
 Interpallial fissure, 278  
 Intervertebral disks, 351, 353  
     ligament, development of, 352, 353  
 Intervillous spaces, 87, 92  
 Intestinal canal, formation of, 71  
     glands, development of, 189  
     mesentery, 198  
     mucosa, formation of, 172  
     villi, formation of, 189  
     portals, 73, 169  
 Intestine, small, development of, 185, 188  
 Intestino-body cavity, 47  
 Intumescencia ganglioformis, 326  
 Involuntary muscle, development of, 346  
 Iris, coloboma of, 318  
     development of, 317  
 Ischiatic rod, 378  
 Island of Reil, 281  
 JACOBSON'S organ, development of, 337  
 Jaw, upper, development of, 122  
 Jaw-arch, 104  
 Jelly of Wharton, 93  
 Joint-cavities, development of, 117  
 Jugular vein, primitive, 148, 154  
     transverse, 156  
 KIDNEY, development of, 212  
 LABIA majora, 237  
     minora, formation of, 237  
 Labyrinth, bony, development of, 326  
     membranous, development of, 321  
 Lacrimal bones, ossification of, 370

- Lacrimal canaliculi, 320  
   caruncle, 319  
   duct, development of, 320  
   gland, development of, 319  
   groove, 108, 120  
   sac, development of, 321  
 Lamina cinerea, 272, 275  
   quadrigenina, 271  
   spiral, bony, development of, 330  
   terminalis, 285  
 Langhans' layer, 87  
 Lanugo, 110, 250  
 Larynx, development of, 207  
 Latebra, 27  
 Lateral cartilage of nose, 369  
   folds of amnion, 72  
   frontal processes, 107, 120, 122  
   in formation of nose, 134  
   ligaments of liver, 193  
   nasal process, 320, 334  
   plate of mesoderm, 57  
   plate of somite, 55  
   ventricle, development of, 279  
 Length of fetus at term, 111  
 Lens, crystalline, development of, 312  
 Lens-area, 304  
 Lens-capsule, development of, 313  
 Lens-pit, 312  
 Lens-vesicle, 99, 122, 304, 312  
 Lenticular zone of optic cup, 309  
 Lesser omentum, 202  
   formation of, 188  
 Levator palati, origin of, 345  
 Lids, union of edges of, 319  
 Lieberkühn, glands of, 189  
 Ligament of ovary, 232  
 Ligaments of liver, formation of, 192  
 Ligamenta intermuscularia, 350  
   subflava, 353  
 Ligulae, 267  
 Limb-buds, 108, 380  
 Limbic lobe, 285, 289  
 Limb-muscles, development of, 345  
 Limbs, bones of, development, 379  
   development of, 380, 383-390  
   position of, 381  
 Limiting membrane, inner, formation of, 307  
   outer, formation of, 307  
 Lip, upper, development of, 124  
 Liquor amnii, 76, 77  
   function of, 77  
   folliculi, 29, 228  
   of Morgagni, 313  
 Liver, development of, 190  
   first rudiment of, 181  
   ligaments of, formation of, 192  
 Liver-ridge, 159, 191  
 Lobes of liver, 191  
 Lobule of ear, development of, 333  
 Longitudinal fiber-tracts of medulla, 266  
   fissure of brain, 278  
 Lower jaw, ossification of, 372  
 Lumbar rib, 357  
   vertebrae, ossification of, 355  
 Lungs, development of, 205  
 Lymph, formation of, 115  
 Lymph-clefts, development of, 117  
 Lymph-sacs, development of, 116  
 Lymph-spaces, development of, 116  
 Lymphatic system, development of, 116  
   vessels, development of, 117  
 Lymphoid follicles of tonsil, 178  
   tissue, development of, 117  
 MACULA lutea, formation of, 309  
 Maculae acusticae, development of, 325  
 Malar bone, ossification of, 370  
 Male external genitals, 237, 244  
   internal genital organs, 222  
   pronucleus, 39  
   sexual system, 222, 242  
 Malleus, development of, 362, 373  
 Malpighian corpuscle, development of, 195, 217  
   primitive, 216  
 Mammalia deciduata, 89  
   indeciduata, 89  
 Mammals, blastula of, 45  
 Mammary gland, development of, 251  
 Mandible, ossification of, 372  
 Mandibular arch, 104, 123, 360  
 Mantle layer, 260  
 Marginal sinus, 92  
   zone of optic cup, 310  
 Marshall, vestigial fold of, 156  
 Maternal impressions, 109  
 Maturation of ovum, 30  
   theories of, 32  
 Maxilla, superior, ossification of, 371  
 Maxillary arch, 104  
   process, 123, 360  
 Meatus, external auditory, 332  
   urinarius, male, 239  
 Meckel's cartilage, 104, 362, 372  
   diverticulum, formation of, 190  
   ganglion, 298  
 Meconium, 111  
 Median fissures of cord, 261  
   lobe of cerebellum, 268  
 Medulla oblongata, development of, 265  
 Medullary canal, 62  
   cords, 229  
   folds, 64, 255  
   furrow, 63  
   groove, 63  
   plate, 62, 255  
   tube, 255  
   velum, anterior, 269  
   inferior, 268, 270  
 Meibomian glands, development of, 319  
 Membrana adamantina, 127  
   basilaris of cochlea, formation of, 330  
   eboris, 129

- Membrana granulosa**, 29  
     formation of, 228  
     præformativa, 129  
**Membrane**, anal, 176  
     closing, 102, 106, 177  
     nuclear, 25  
     of Nasmyth, 128  
     of Reissner, 330  
     pharyngeal, 106, 119, 171, 175  
     vitelline, 23, 24  
     tympanic, 177, 332  
**Membranes**, caducous, 85  
     deciduous, 85  
**Membranous bones**, 359  
     cranium, 359  
     labyrinth, development of, 321  
     ribs, 356  
     stage of skeleton, 348  
     of trunk, 349  
**Menopause**, 35  
**Menstrual cycle**, 35  
**Menstruation**, 35  
     relation of, to ovulation and con-  
     ception, 37  
**Meroblastic ova**, 44  
**Mesencephalon**, 270  
**Mesenchymal cells**, 58  
     muscle, 346  
**Mesenchyme**, 58  
**Mesenteries**, 173  
**Mesentery**, intestinal, 198  
     ventral, 187  
     development of, 202  
**Mesoblast**, 54  
**Mesoblastic somites**, 57, 67  
**Mesocardium anterius**, 139, 158  
     posterius, 139, 158  
**Mesocolon**, ascending, production of,  
     186  
     formation of, 186  
**Mesoderm**, 54  
     derivatives of, 60  
     gastral, 55  
     paraxial, 57  
     peristomal, 55  
     somatic, 58  
     splanchnic, 58  
     structures developed from, 113 *et*  
     *seq.*  
**Mesogastrium**, 187, 198  
**Mesonephric duct**, 214  
**Mesonephros**, 213, 241  
**Mesorchium**, 225  
**Mesothelium**, 58, 115  
**Mesovarium**, 225  
**Metacarpal bones**, development of,  
     379  
**Metamorphosis of single into double**  
     heart, 142  
**Metanephros**, 217, 241  
**Metatarsal bones**, development of,  
     379  
**Metencephalon**, 264  
**Metopic suture**, 370  
**Metopism**, 370  
**Micropyle**, 23, 39  
**Mid-brain**, 262, 270  
     prominence of, 264  
     vesicle, 65, 270  
**Mid-gut**, 171  
**Middle ear**, development of, 177, 331  
     piece of spermatozoon, 20  
     plate, 69, 212, 341  
     sacral artery, development of, 150  
     tunic of eye, development of, 315  
**Modiolus of cochlea**, development of,  
     329  
**Moll**, glands of, 250  
**Monorchism**, 226  
**Monro**, foramen of, 277, 282  
**Mons veneris**, formation of, 237  
**Morgagni**, hydatid of, 224  
     liquor of, 313  
**Morula**, 41  
**Mother-cells**, 22  
**Motor nerve-fibers**, development of,  
     295  
**Mouth**, development of, 122, 175  
**Mucous tissue**, formation of, 114  
**Mulberry-mass**, 41  
**Müller**, duct of, 220, 224, 230, 242  
**Müller's fibers**, 307  
**Muscle**, involuntary, development of,  
     346  
     voluntary, development of, 339  
**Muscle-plate**, 69, 341  
     metamorphosis of, 342  
**Muscles**, branchial, development of,  
     344  
     of extremities, development of, 345  
     of trunk, development of, 339  
**Muscular coat of intestines**, forma-  
     tion of, 188  
     system, development of, 339, 383-390  
**Musculi papillares**, 147  
     pectinati, 140  
**Myocœl**, 341  
**Myotome**, 69, 341  
  
**NAIL-BED**, 248  
**Nail-plate**, 247  
**Nails**, development of, 247  
     of toes, 248  
**Nail-welt**, 248  
**Nares**, anterior, formation of, 134  
     development of, 336  
**Nasal areas**, 133, 334  
     bones, ossification of, 370  
     capsule, 362  
     cavities, development of, 336  
     pits, 107, 120, 133, 334  
     process, 120, 334  
     lateral, 320, 334  
**Nasmyth**, membrane of, 128  
**Nasofrontal process**, 104, 107, 120, 122,  
     334, 360  
     in development of nose, 133  
**Naso-optic furrow**, 120, 122  
     in formation of nose, 134  
     groove, 320

- Nephrotome, 69, 214, 241, 341  
 Nerve-cells, formation of, 258  
   of cord, formation of, 260  
 Nerve-corpuscles of neurilemma, 295  
 Nerve-fiber, envelopes of, formation of, 295  
   layer, development of, 309  
 Nerve-fibers, cranial, development of, 296  
   motor, development of, 295  
   sensory, development of, 293  
 Nerve-trunk, spinal, development of, 295  
 Nervous system, development of, 254, 383-390  
   peripheral, development of, 292  
   sympathetic, development of, 300  
 Neural arch of vertebra, formation of, 352  
   canal, 62, 255, 257  
   crest, segmentation of, 294  
   crests, 294  
   tube, 255  
 Neurenteric canal, 66, 257  
 Neurilemma, formation of, 295  
 Neurite, 254, 260  
 Neuroblasts, 258, 260  
 Neuro-epithelium of retina, development of, 309  
 Neuroglia, 258, 259  
   layer, 260  
 Neurons, 254  
 Nictitating membrane, 319  
 Ninth month, development during, 111, 390  
   pair cranial nerves, development of, 300  
   week, development during, 387  
 Nipple, development of, 252  
 Node, Hensen's, 54  
 Nose, development of, 133, 334  
 Notochord, 65  
 Notochordal stage of skeleton, 348  
 Nuchal flexure, 264  
 Nuck, canal of, 232  
 Nuclear juice, 25  
   layer, of retina, outer, 308  
   membrane, 25  
   spindle, 41  
 Nucleus amygdalæ, 279  
   cleavage-, 39  
   of ovum, 25  
   segmentation-, 39  
 Nutritive yolk, 24  
 Nymphæ, formation of, 237  
  
 OBEX, 267  
 Occipital bone, ossification of, 364  
   lobe, 282  
 Odontoblasts, 129  
 Odontoid process, development of, 355  
 Olfactory bulb, 290  
   epithelium, 334  
   lobe, 290  
   Olfactory nerve-fibers, 338  
     plates, 120, 133, 334  
     tract, 290  
 Omental bursa, 187, 200  
 Omentum, gastrohepatic, 192, 202  
   formation of, 188  
   gastrosplenic, 195  
   great, formation of, 187, 201  
   lesser, 202  
     formation of, 188  
     phrenicosplenic, 195  
 Omphalomesenteric veins, 136  
 Ontogeny, 17  
 Oogenesis, 27  
 Ophthalmic ganglion, 296  
 Opisthotic center of ossification, 366  
 Optic cup, 304  
   secondary, 306  
   lobes, formation of, 271  
   nerve, development of, 311  
   thalami, 272  
   vesicle, 263, 303  
 Ora serrata, 307  
 Oral cavity, development of, 175  
   fossa, 175  
   pit, 97, 106, 119, 123, 175  
   plate, 118, 122, 175  
 Organ of Corti, 325  
   of Giraldu, 224  
   of Jacobson, development of, 337  
   of Rosenmüller, 231  
 Osseous cranium, 363  
   stage of trunk skeleton, 354  
   tissue, formation of, 115  
 Ossicles of ear, development of, 332  
 Ossification of ribs, 357  
   of skull, 363  
   of sternum, 357  
   of vertebrae, 354  
 Otic vesicle, 98, 322  
 Otocyst, 322  
 Outer cell-mass, 45  
 Ova, alecithal, 24  
   centrolecithal, 25  
   classification of, 24  
   formation of, 27  
   holoblastic, 43  
   meroblastic, 44  
   primitive, 29, 222, 227  
   telolecithal, 24  
 Ovaries, change of position of, 231  
 Ovary, development of, 226  
 Oviducts, development of, 230  
 Ovists, 18  
 Ovulation, 32  
   relation of, to menstruation, 34  
 Ovum, 22, 228  
   embedding of, 85, 86  
   maturation of, 30  
   ripening of, 30  
   segmentation of, 41  
   stage of, 19, 96  
  
 PALATE bone, ossification of, 370  
   formation of, 124


- Palate process, development of, 371  
 Palate-shelves, 336  
 Palatoglossus, origin of, 345  
 Palatopharyngeus, origin of, 345  
 Palpebral fasciæ, 319  
   fissure, 319  
 Pancreas, development of, 194  
   first rudiment of, 182  
 Pancreatic duct, development of, 194  
 Pander, blood-islands of, 135  
 Pander's nucleus, 26  
 Panniculus adiposus, 246  
 Papillæ of tongue, formation of, 133  
 Parablast, 58  
 Parachordal cartilages, 361  
 Paradidymis, 224  
 Paraxial mesoderm, 57  
 Parietal bones, ossification of, 370  
   elevation, 264  
   eye, 275  
   foramen, 274  
   layer of pleura, 161  
   lobe, 282  
   zone, 68  
 Parieto-occipital fissure, 284  
 Paroöphoron, 231  
 Parovarium, 231  
 Pars ciliaris retinae, 310  
   intermedialis, 237  
   iridica retinae, 310  
   optica retinae, 309  
 Parthenogenetic eggs, 32  
 Patulous foramen ovale, 143  
 Pectoral girdle, development of, 377  
 Pelvic girdle, 378  
 Pelvis of kidney, formation of, 218  
 Penis, development of, 235  
 Perforated lamina, anterior, 291  
   space, posterior, 270, 271  
 Pericardial cavity, 159  
 Pericardium, development of, 158  
 Perilymph, 327, 331  
 Perilymphatic space, 327  
 Perineal body, 180  
 Perineum, formation of, 180  
 Perionyx, 248  
 Periotic bone, 366  
 Peripheral cleavage, 44  
   nervous system, 292  
 Peristomal mesoderm, 55  
 Peritoneal cavity, 198  
 Peritoneum, development of, 195  
   visceral layer of, 172  
 Perivitelline space, 23  
 Permanent kidney, 217  
   teeth, development of, 129  
     eruption of, 131  
 Petromastoid bone, 366  
 Petroitympanic fissure, 373  
 Pflüger's egg-tubes, 227  
 Phalanges, development of, 379  
 Pharyngeal bursa, 124  
   constrictors, origin of, 345  
   membrane, 106, 119, 171, 175  
   in formation of mouth, 123  
 Pharyngeal pouches, 102, 171, 176  
 Pharynx, 176  
 Phrenicosplenic omentum, 195  
 Phylogeny, 17  
 Pial processes, 259  
 Pigment-layer of retina, 307  
 Pillars of Uskow, 161  
 Pineal body, 272  
   or gland, 273, 274  
   eye, 275  
 Pit, auditory, 322  
   oral, 97, 106  
 Pits, nasal, 334  
 Pituitary body, 276  
   formation of, 123  
 Placenta, 88  
   at term, 91  
   discoidea, 89  
   prævia, 92  
   zonaria, 89  
 Placental sinuses, 90  
   spaces, 92  
   system of blood-vessels, 149  
 Planes of cleavage, 42  
 Plantar horn, 247  
 Plate, chordal, 66  
   medullary, 62  
   vertebral, 57  
 Pleura, parietal layer of, 161  
   visceral layer of, 161  
 Pleuræ, development of, 158, 159  
 Pleural sacs, formation of, 158, 159  
 Pleuropericardial fold, 160  
 Pleuroperitoneal cavity, 58, 197  
 Plica semilunaris, 319  
 Pocket of Rathke, 277  
 Polar bodies, 31  
   striation, 41  
 Polarity of egg, 25  
 Pole-corpuscles, 30  
 Polyphyodont, 125  
 Polyspermia, 39  
 Pontal flexure, 264  
 Pous, formation of, 268  
 Portal circulation, 154, 161  
   vein, development of, 164  
   venous system, 154, 161  
 Postanal gut, 179  
 Posterior chamber of eye, 318  
   nares, development of, 336  
 Post-limbic sulcus, 285  
 Preformation theory, 18  
 Prehepaticus, 159, 191  
 Prehyoid gland, 209  
 Premaxilla, 371  
 Prepuce, formation of, 238  
 Presphenoid, 368  
 Primary egg-tubes, 29  
 Primitive aorta, 137, 150  
   chorion, 82  
   enamel-germ, 126  
   eyelids, 122  
   groove, 52  
   heart-valves, 144


- Primitive jugular veins, 148, 154  
   Malpighian corpuscle, 216  
   nails, 247  
   ova, 29, 222, 227  
   red blood-corpuscles, 136  
   segment plate, 57  
   segments, 57, 67  
   sexual cells, 221  
   streak, 51  
   vertebral bow, 351  
 Primordial bones, 359  
 Proamnion, 56  
 Process, lateral frontal, 107, 120, 122  
   nasal, 120, 334  
   nasofrontal, 104, 107, 120, 122, 334  
   in formation of nose, 133  
 Processes, dental, 129  
   globular, 107, 120, 334  
   nasal, 334  
   maxillary, 123  
   of vertebra, development of, 352  
 Processus vaginalis, 226  
 Prochorion, 45, 82  
 Proctodeum, 179  
 Pronephric duct, 212  
 Pronephros, 212, 241  
 Pronucleus, female, 32  
   male, 39  
 Pro-otic center of ossification, 366  
 Prosencephalon, 278  
 Prostate gland, formation of, 234  
 Prostatic urethra, formation of, 234  
 Protoplasmic processes, 260  
 Protovertebra, 55  
 Pterygoid plate, internal, develop-  
   ment of, 368  
 Pubic rod, 378  
 Pulmonary alveoli, development of,  
   207  
   artery, development of, 144, 152  
   diverticulum, 205  
   groove, 205  
 Pulp of spleen, development of, 195  
   of teeth, 125  
 Pupil, 306  
   congenital atresia of, 314  
   development of, 318  
 Pyramidal tracts, anterior develop-  
   ment of, 266  
   crossed, of cord, myelination of,  
   389  
  
 RAMUS communicans, 301  
 Rathke's pocket, 124, 277  
 Rauber's layer, 45, 49  
 Receptive prominence, 39  
 Recessus labyrinthi, 322  
   vestibuli, 322  
 Rectum, 180  
 Recurrent laryngeal nerves, 152  
 Red blood-corpuscle, primitive, 136  
 Reichert's cartilage, 104, 363, 375  
 Reil, island of, 281  
 Reissner, membrane of, 330  
 Renal vein, left, 157  
  
 Reproduction, theories of, 17  
 Respiratory system, development of,  
   204, 383-390  
 Restiform bodies, development of, 266  
 Rete mucosum, 247  
   testis, formation of, 223  
 Retina, development of, 304  
 Rhinencephalon, 290  
 Rhomboidal fossa, 267  
 Rib, cervical, 354, 357  
   lumbar, 357  
   thirteenth, 357  
 Ribs, development of, 356  
 Ridge, genital, 220  
   terminal, 50  
 Ring lobe, formation of, 280  
 Ripening of ovum, 30  
 Rod-and-cone-layer, formation of, 308  
 Rod-visual cells, 307  
 Rolando, fissure of, 284  
 Roof-plate, 257, 258  
 Rotation of stomach, 186, 200  
 Round ligament of liver, 167  
   formation of, 193  
   of uterus, 225, 232  
  
 SACCULE, development of, 324  
 Saccus endolymphaticus, 323  
 Sacral vertebrae, ossification of, 355  
 Sacrum, formation of, 355  
 Salivary glands, development of, 131  
 Sauropsida, blastula of, 46  
 Scala media of cochlea, development  
   of, 323  
   tympani, development of, 330, 331  
   vestibuli, development of, 330, 331  
 Scapula, development of, 377  
 Schwann, white substance of, 295  
   deposit of, upon fibres of tract of  
   cord, 388, 389  
 Sclerotome, 69, 341, 350  
 Scrotum, development of, 239  
 Sebaceous glands, development of, 251  
 Second month, development during,  
   107  
   pair cranial nerves, development of,  
   299  
   week, development during, 383  
 Secondary hair, 250  
   optic cup, 306  
 Segmental duct, 213  
 Segmentation of body of embryo, 69  
   of ovum, 41  
 Segmentation-cavity, 45  
 Segmentation-nucleus, 39  
 Semicircular canals, bony, 327  
   development of, 323, 324  
 Semilunar valves, development of, 147  
 Seminal ampullae, 223  
   vesicle, formation of, 224  
 Seminiferous tubules, formation of,  
   223  
 Sense organs, development of, 302,  
   383-390  
 Sensory epithelium of retina, 307


- Sensory nerve-fibers, development of, 293
- Septa placentæ, 92
- Septal cartilage of nose, 369
- Septum lucidum, formation of, 288  
transversum, 148, 159
- Serosa, 73
- Serous membranes, development of, 115
- Sertoli's, columns, 21, 223
- Sessile hydatid, 224
- Seventh month, development during, 110, 389  
pair cranial nerves, development of, 299  
week, development of, during, 386
- Sexual cells, 29  
primitive, 221  
cords, 29, 222  
female, 227  
gland, indifferent, 221  
segment of Wolffian body, 219  
system, female, 226, 243  
homologies of, 240  
indifferent type, 220  
male, 222, 242
- Shell of hen's egg, 27
- Shell-membrane, 27
- Shoulder girdle, development of, 377
- Sinus, annular, 163  
pocularis, 224, 234  
præcervicalis, 105  
reuniens, 144  
terminalis, 136  
urogenital, 173, 233  
venosus, 144, 153
- Sixth month, development during, 110, 389  
pair cranial nerves, development of, 299  
week, development during, 108, 385
- Skeletogenous sheath of chorda dorsalis, 350  
tissues, 69
- Skeleton, appendicular, 348  
development of, 376, 383-390  
axial, 348  
development of, 347  
of head, development of, 358  
of trunk, cartilaginous stage of, 351  
chordal stage of, 348  
development of, 348  
membranous stage of, 349  
visceral, 358
- Skin, appendages of, 247  
development of, 245, 383-390
- Small intestine, development of, 188
- Smegma embryonum, 247
- Somatic mesoderm, 58
- Somatopleure, 58, 169
- Somites, 55, 67  
mesoblastic, 57, 67
- Space, perivitelline, 23
- Spaces, intervillous, 87, 92
- Spermatic cord, 226  
veins, 157
- Spermatids, 22
- Spermatoblasts, 22
- Spermatogenesis, 21
- Spermatogenic cells, 21
- Spermatozoon, 20  
power of locomotion of, 21  
vitality of, 21
- Sphenoid bone, ossification of, 367
- Sphenoidal sinus, development of, 337
- Sphenopalatine ganglion, 296
- Spinal cord, development of, 257
- Spinous process of vertebra, development of, 354
- Splanchnic mesoderm, 58
- Splanchnopleure, 58, 169
- Spleen, development of, 194
- Spongioblasts, 258, 259
- Spot, germinal, 25
- Squamozygomatic bone, 365
- Stage of embryo, 19, 96  
of fetus, 20, 107  
of ovum, 19, 96  
of quiescence of menstrual cycle, 36  
of repair of menstrual cycle, 36
- Stalked hydatid, 224
- Stapes, development of, 363
- Stem-zone, 67
- Sternum, cleft, 357  
development of, 357
- Stigma, 29
- Stilling, canal of, 315
- Stomach, development of, 186  
first rudiment of, 181  
glands of, development of, 189  
rotation of, 186, 200
- Stomodæum, 119, 175
- Stratum Malpighii, 247
- Streak, primitive, 51
- Striated muscles, development of, 339
- Stroma-layer of choroid, development of, 316
- Styloglossus, origin of, 345
- Stylohyal, 376  
cartilage, 367
- Stylohyoid ligament, 363
- Styloid process of hyoid, 363  
temporal, development of, 367
- Stylopharyngeus, origin of, 345
- Subclavian artery, left, development of, 152  
right, development of, 151
- Submaxillary ganglia, 296
- Submucosa of intestines, formation of, 188
- Sulcus interventricularis, 143  
of corpus callosum, 283
- Superior maxilla, ossification of, 371
- Suprahyoid gland, 209
- Supra-occipital bone, 364
- Suprapericardial bodies, 209
- Suprarenal bodies, development of, 218, 242

- Suspensory ligament of liver, formation of, 193  
 Sustentacular cells of seminiferous tubule, 21  
 Suture, amniotic, 75  
 Sweat-glands, development of, 250  
 Sylvius, aqueduct of, 271  
   fissure of, 279, 280  
   fossa of, 280  
 Sympathetic nervous system, 300  
 Syncytium, 83, 87  
 Synovial sacs, development of, 115  
  
 TAIL of spermatozoon, 20  
 Tail-fold, 72  
 Tarsal ligaments, 319  
   plates, 319  
 Tarsus, development of bones of, 379  
 Teeth, development of, 125  
   permanent, development of, 129  
     eruption of, 131  
   temporary, development of, 125  
     eruption of, 130  
 Tela choroidea, 273  
 Telolecithal ova, 24  
 Temporal bone, ossification of, 364  
   lobe, formation of, 280  
 Temporary teeth, development of, 125  
   eruption of, 130  
 Temporomaxillary articulation, 374  
 Tendon, development of, 114  
 Tendon-sheaths, development of, 117  
 Tenth pair cranial nerves, development of, 300  
 Terminal ridge, 50  
 Testicle, development of, 222  
   descent of, 225  
 Thalamencephalon, 272  
 Thebesius, valve of, 144  
 Theca folliculi, 27  
 Thecal sacs, development of, 115  
 Theory of evolution, 17  
   of unfolding, 17  
 Third eyelid, 319  
   month, development during, 109, 387  
   pair cranial nerves, development of, 299  
   ventricle, formation of, 272  
   week, development during, 384  
 Thirteenth rib, 357  
 Thoracic prolongations of abdominal cavity, 159  
 Throat-pockets, 102, 171, 176  
 Thymus body, 177, 210  
 Thyroglossal duct, 133, 208  
 Thyroid body, accessory, 209  
   development of, 177, 207  
   duct, 208  
   foramen, 378  
 Tissue fungus, 87  
 Toes, development of, 381  
 Tongue, development of, 131, 177  
 Tonsil, development of, 177  
 Tonsillar pit, 178  
  
 Trabeculae cranii, 361  
 Trachea, development of, 207  
 Tragus, formation of, 333  
 Transverse colon, formation of, 186  
   crescentic groove, 72  
   fissure of brain, 273  
   processes of vertebrae, 354  
 Trigeminal ganglion, 296  
 Trophoblast, 83  
 True chorion, 82  
 Truncus arteriosus, 102, 137, 140, 149  
 Trunk, skeleton of, development of, 348  
   osseous stage of, 354  
 Trunk-muscles, development of, 339  
 Trunk-segments, 340  
 Tuber cinereum, 272, 276  
 Tuberculum impar, 132, 177  
 Tubotympanic sulcus, 331  
 Tunica albuginea of ovary, 227  
   fibrosa, 28  
   propria, 28  
   vaginalis testis, 226  
   vasculosa, 27  
     lentis, 313  
 Turbinal folds, 336  
 Turbinate bone, inferior, ossification of, 369  
 Turbinated bones, development of, 337  
 Twelfth pair cranial nerves, development of, 300  
 Twins, origin of, 51  
 Tympanic cavity, formation of, 177  
   membrane, 177  
   development of, 332  
   portion of temporal bone, development of, 367  
 Tympanohyal, 376  
   cartilage, 367  
 Tympanum, development of, 331  
  
 UMBILICAL aperture, 78, 169  
   arteries, 93, 149  
   cord, 92  
   hernia, congenital, 189  
   urinary fistula, 233  
   vein, 93, 149, 153  
   vesicle, 72, 78, 169  
     function of, 80  
     human, 80  
   vessels, 93  
 Uncinate gyrus, 291  
 Unstriated muscle, development of, 346  
 Urachus, 82, 233  
 Ureter, 218  
   development of, 212  
 Urethra, female, 234  
   male, formation of, 239  
   prostatic, formation of, 234  
 Urinary fistula, umbilical, 233  
 Uriniferous tubules, formation of, 217  
 Urogenital aperture, 233  
   sinus, 173, 179, 233  
 Uskow, pillars of, 161

- Uterus bicornis, 230  
   development of, 230  
   double, 230  
   masculinus, 224, 234  
 Utricle, development of, 324  
 Uveal tract, development of, 316  
 Uvula, formation of, 125
- VAGINA, development of, 230  
   median septum in, 230  
 Valve, coronary, 144  
   Eustachian, 144  
   of Thebesius, 144  
   of Vieussens, 269  
 Valves, atrioventricular, 142  
   auriculoventricular, 146  
   of heart, development of, 144  
   semilunar, development of, 147  
 Vas deferens, formation of, 223  
 Vasa efferentia, 223  
   recta, formation of, 223  
 Vascular area, 79  
   system, development of, 135, 383-390  
     fetal, final stage of, 165  
     tunic of eye, development of, 315  
 Vegetative pole, 25  
 Vein, cardinal, 148  
   hepatic, 164  
   iliac, left common, development of, 156  
   portal, development of, 164  
   renal, left, 157  
   umbilical, 93  
 Veins, allantoic, 81, 148  
   cardinal, 154  
   omphalomesenteric, 136  
   primitive jugular, 154  
   spermatic, 157  
   umbilical, 149, 153  
   vitelline, 136, 153  
 Velum interpositum, 272, 273  
 Vena azygos major, 157  
   minor, 158  
   cava inferior, 155, 157  
   superior, 154  
 Venæ hepaticæ advehentes, 163  
   revehentes, 163  
 Venous segment of heart, 141  
   system of fetus, 153  
   portal, 154  
 Ventral mesentery, 173, 187  
   development of, 202  
 Ventricles, separation of, 143  
 Vermiform appendix, development of, 186  
   process of cerebellum, 268  
 Vernix caseosa, 78, 110, 247  
 Vertebrae, ossification of, 354  
 Vertebral bow, primitive, 351  
   column, development of, 348-356  
   membranous primordial, 350  
   plate, 57
- Vertebral region of primitive skull, 361  
 Vesicle, germinal, 23, 25  
   otic, 98, 322  
   umbilical, 72, 78, 169  
 Vesicles, cerebral, 262, 263  
   lens, 99  
 Vestibular ganglion, 326  
   nerve, 297  
 Vestibule of ear, development of, 327  
   of vagina, 237  
   of vulva, 234  
 Vestigial fold of Marshall, 156  
 Vieussens, valve of, 269  
 Villi of chorion, 83  
   of intestine, formation of, 189  
 Visceral arch, first, function of, 104, 119  
   arches, 101  
     metamorphosis of, 104  
     morphological significance of, 102  
   clefts, 101  
   layer of peritoneum, 172  
   of pleura, 161  
   skeleton, 358  
 Visceral-arch vessels, 102, 137, 149  
 Vitelline arteries, 137  
   circulation, formation of, 135  
   duct, 72, 78, 169  
   membrane, 23, 24  
   veins, 136, 153  
 Vitellus, 23, 24  
 Vitreous body, development of, 314  
 Vocal cords, development of, 207  
 Voluntary muscles, development of, 339  
 Vomer, ossification of, 370
- WEIGHT of fetus at term, 111  
   at different stages, 386-390  
 Wharton, jelly of, 93  
 White commissures of cord, 260  
   fibrous tissue, formation of, 114  
   matter of brain, formation of, 279  
   of cord, development of, 261  
   of hen's egg, 27  
   substance of Schwann, development of, 295, 383, 389  
 Winslow, foramen of, 203  
 Witches' milk, 253  
 Wolffian body, 213  
   duct, 215  
   in female, 230  
 Wolff's doctrine of epigenesis, 18  
 Wreath, 41
- YOLK of ovum, 23  
 Yolk-sac, 72, 78, 169
- ZONA pellucida, 23, 29  
   radiata, 29  
 Zone, parietal, 68  
   stem-, 68







---

---

**SAUNDERS' BOOKS**

---

on

**Practice, Pharmacy,  
Materia Medica, Thera-  
peutics, Pharmacology,  
and the Allied Sciences**

---

**W. B. SAUNDERS & COMPANY**

**925 WALNUT STREET**

**PHILADELPHIA**

**NEW YORK**

**LONDON**

**Fuller Building, 5th Ave. and 23d St.**

**9, Henrietta Street, Covent Garden**

---

**SAUNDERS' SUCCESSFUL PUBLISHING**

**A**S is well-known, the lists of most publishers contain a number of books that have never paid, and for which the publisher will never get back the money invested. Messrs. W. B. Saunders & Company would call attention to the fact that they have no such works on their list. In all the years of their business experience they have never published a book at a loss. This they confidently consider a most remarkable record, and submit the fact to the attention of the profession as an example of what might justly be called "Successful Publishing."

**A Complete Catalogue of our Publications will be Sent upon Request**

---

---

# Barton and Wells' Medical Thesaurus

A NEW WORK—JUST ISSUED

---

**A Thesaurus of Medical Words and Phrases.** By WILFRED M. BARTON, A. M., Assistant to Professor of Materia Medica and Therapeutics, and Lecturer on Pharmacy, Georgetown University, Washington, D. C.; and WALTER A. WELLS, M. D., Demonstrator of Laryngology and Rhinology, Georgetown University, Washington, D. C. Handsome octavo of about 650 pages. Cloth, \$0.00 net; Sheep or Half Morocco, \$0.00 net.

## THE ONLY MEDICAL THESAURUS EVER PUBLISHED

This work is the only Medical Thesaurus ever published. It aims to perform for medical literature the same services which Roget's work has done for literature in general; that is, instead of, as an ordinary dictionary does, supplying the meaning to given words, it reverses the process, and when the meaning or idea is in the mind, it endeavors to supply the fitting term or phrase to express that idea. To obviate constant reference to a lexicon to discover the meaning of terms, brief definitions are given before each word. As a dictionary is of service to those who need assistance in interpreting the expressed thought of others, the Thesaurus is intended to assist those who have to write or to speak to give proper expression to their own thoughts. In order to enhance the practical application of the book cross references from one caption to another have been introduced, and terms inserted under more than one caption when the nature of the term permitted. In the matter of synonyms of technical words the authors have performed for medical science a service never before attempted. Writers and speakers desiring to avoid unpleasant repetition of words will find this feature of the work of invaluable service. Indeed, this Thesaurus of medical terms and phrases will be found of inestimable value to all persons who are called upon to state or explain any subject in the technical language of medicine. To this class belong not only teachers in medical colleges and authors of medical books, but also every member of the profession who at some time may be required to deliver an address, state his experience before a medical society, contribute to the medical press, or give testimony before a court as an expert witness.

# **Pusey and Caldwell on X-Rays in Therapeutics and Diagnosis**

---

**The Practical Application of the Röntgen Rays in Therapeutics and Diagnosis.** By WILLIAM ALLEN PUSEY, A. M., M. D., Professor of Dermatology in the University of Illinois; and EUGENE W. CALDWELL, B. S., Director of the Edward N. Gibbs X-Ray Memorial Laboratory of the University and Bellevue Hospital Medical College, New York. Handsome octavo volume of 591 pages, with 176 illustrations, nearly all clinical. Cloth, \$4.50 net; Sheep or Half Morocco, \$5.50 net. *Sold by Subscription.*

## **A NEW WORK — JUST ISSUED**

It has been the aim of the authors of this work to elucidate fully the practical aspects of the subject. All the authentic literature which has developed since Röntgen's wonderful discovery has been carefully digested, this being supplemented by the extensive experience of the authors. The value of the X-rays in diagnosis has been discussed in a thoroughly practical manner, and their limitations in this field indicated. Particular attention has been devoted to the use of the X-rays in therapeutics. Nearly all the illustrations in this section represent actual clinical subjects, and show the condition before the use of the X-rays, at various stages of their application, and, finally, the therapeutic results obtained. Full details are also given as to the use and management of the apparatus necessary for X-ray work. All the methods with which the best results have been achieved have been carefully described in a comprehensive way. There are chapters on X-Ray Tubes, Induction Coils and Controlling Apparatus, Static Machines, Fluoroscopy, Radiography, Photographic Materials used in Radiography, etc. This section is also fully illustrated with instructive photographs and drawings of the apparatus, including four colored plates of X-ray tubes. The work will be found of invaluable assistance, not only to the practitioner, but also to the dermatologist, as presenting the very latest advances in the subject.

GET  
THE BEST

# American Illustrated Dictionary

THE NEW  
STANDARD

Third Revised Edition—Just Issued

---

**The American Illustrated Medical Dictionary.** A new and complete dictionary of the terms used in Medicine, Surgery, Dentistry, Pharmacy, Chemistry, and kindred branches; with over 100 new and elaborate tables and many handsome illustrations. By W. A. NEWMAN DORLAND, M. D., Editor of "The American Pocket Medical Dictionary." Large octavo, nearly 800 pages, bound in full flexible leather. Price, \$4.50 net; with thumb index, \$5.00 net.

**Gives a Maximum Amount of Matter in a Minimum Space, and at the Lowest Possible Cost**

**THIRD EDITION IN THREE YEARS—12,500 COPIES**

The immediate success of this work is due to the special features that distinguish it from other books of its kind. It gives a maximum of matter in a minimum space and at the lowest possible cost. Though it is practically unabridged, yet by the use of thin bible paper and flexible morocco binding it is only 1  $\frac{5}{8}$  inches thick. The result is a truly luxurious specimen of book-making. In this new edition the book has been thoroughly revised, and upward of one hundred important new terms that have appeared in recent medical literature have been added, thus bringing the book absolutely up to date. The book contains hundreds of terms not to be found in any other dictionary, over 100 original tables, and many handsome illustrations, including 24 colored plates.

---

## PERSONAL OPINIONS

---

**Howard A. Kelly, M. D.,**

*Professor of Gynecology, Johns Hopkins University, Baltimore.*

"Dr. Dorland's dictionary is admirable. It is so well gotten up and of such convenient size. No errors have been found in my use of it."

**Roswell Park, M. D.,**

*Professor of Principles and Practice of Surgery and of Clinical Surgery, University of Buffalo.*

"I must acknowledge my astonishment at seeing how much he has condensed within relatively small space. I find nothing to criticize, very much to commend, and was interested in finding some of the new words which are not in other recent dictionaries."

# Stevens' Materia Medica and Therapeutics

---

**A Text-Book of Modern Materia Medica and Therapeutics.** By A. A. STEVENS, A. M., M. D., Lecturer on Physical Diagnosis in the University of Pennsylvania. Handsome octavo of about 650 pages. Cloth, \$3.50 net.

## THIRD EDITION, ENTIRELY REWRITTEN AND GREATLY ENLARGED

Since the appearance of the last edition of this book such rapid advances have been made in Materia Medica, Therapeutics, and the allied sciences that the author felt it imperative to rewrite the work entirely. All the newer remedies that have won approval by recognized authorities have been incorporated, and their therapeutic properties fully discussed, thus bringing the book absolutely down to date. The work includes the following sections: Physiologic Action of Drugs; Drugs; Remedial Measures other than Drugs; Applied Therapeutics; Incompatibility in Prescriptions; Table of Doses; Index of Drugs; and Index of Diseases; the treatment being elucidated by more than two hundred formulæ.

---

## OPINIONS OF THE MEDICAL PRESS

---

### New York Medical Journal

"The work which Dr. Stevens has written is far superior to most of its class; in fact, it is very good. . . . The book is reliable and accurate."

### University Medical Magazine

"The author has faithfully presented modern therapeutics in a comprehensive work . . . and it will be found a reliable guide and sufficiently comprehensive for the physician in practice."

### Bristol Medico-Chirurgical Journal, Bristol

"This addition to the numerous works on Therapeutics is distinctly a good one. . . . It is to be recommended as being systematic, clear, concise, very fairly up to date, and carefully indexed."

# Saunders' Pocket Medical Formulary

Sixth Edition, Revised

---

**Saunders' Pocket Medical Formulary.** By WILLIAM M. POWELL, M. D., author of "Essentials of Diseases of Children"; Member of Philadelphia Pathological Society. Containing 1844 formulas from the best-known authorities. With an Appendix containing Posological Table, Formulas and Doses for Hypodermic Medication, Poisons and their Antidotes, Diameters of the Female Pelvis and Fetal Head, Obstetrical Table, Diet-lists, Materials and Drugs used in Antiseptic Surgery, Treatment of Asphyxia from Drowning, Surgical Remembrancer, Tables of Incompatibles, Eruptive Fevers, etc., etc. In flexible morocco, with side index, wallet, and flap. \$2.00 net.

## CONTAINING 200 NEW FORMULAS

In compiling this handy volume the author has introduced as many of the more important recently discovered drugs as possible. Besides the many hundreds of famous formulas collected from the works of the most eminent physicians and surgeons of the world, it contains many valuable, and hitherto unpublished, prescriptions from the private practice of distinguished practitioners of to-day. In this new edition the work has been thoroughly and carefully revised and corrected, and some two hundred new and valuable formulas added. The Dose-table has been brought up to date, and the entire work made to comply in every way with the latest knowledge on the subjects it contains.

---

## OPINIONS OF THE MEDICAL PRESS

---

### **Medical Record, New York**

"This little book, that can be conveniently carried in the pocket, contains an immense amount of material. It is very useful, and, as the name of the author of each prescription is given, is unusually reliable."

### **Johns Hopkins Hospital Bulletin**

"Arranged in such a way as to make consultation of it as easy as possible. It is remarkable how much information the author has succeeded in getting into so small a book."

### **Boston Medical and Surgical Journal**

"The book is attractively bound in flexible leather, and the fact that it has reached its sixth edition bears ample testimony to its popularity."

# Anders' Practice of Medicine

Sixth Revised Edition—Just Issued

---

**A Text-Book of the Practice of Medicine.** By JAMES M. ANDERS, M. D., PH. D., LL. D., Professor of the Practice of Medicine and of Clinical Medicine, Medico-Chirurgical College, Philadelphia. Handsome octavo, 1297 pages, fully illustrated. Cloth, \$5.50 net; Sheep or Half Morocco, \$6.50 net.

## SIXTH EDITION IN SIX YEARS—21,000 COPIES

The success of this work as a text-book and as a practical guide for physicians has been truly phenomenal, six large editions having been called for in as many years. The rapid exhaustion of each edition has made it possible to keep the book absolutely abreast of the times, so that Anders' Practice has become justly celebrated as the most up-to-date work on practice. In this edition extensive changes have been made in connection with the large group of Infectious Diseases. The etiology and mode of transmission of Malaria and of Yellow Fever have been almost entirely rewritten. Certain affections of growing importance, as Diphtheritic Dysentery and Parasitic Hemoptysis, have been recast and more fully discussed. The new articles include Fatty Infiltration of the Heart, Streptococcus Pneumonia, and Acute Diffuse Interstitial Nephritis.

---

## PERSONAL OPINIONS

---

**James C. Wilson, M. D.,**

*Professor of the Practice of Medicine and of Clinical Medicine, Jefferson Medical College Philadelphia.*

"It is an excellent book—concise, comprehensive, thorough, and up-to-date. It is a credit to you; but, more than that, it is a credit to the profession of Philadelphia—to us."

**A. C. Cowperthwait, M. D.,**

*President Illinois Homeopathic Medical Association.*

"I consider Dr. Anders' book not only the best late work on Medical Practice, but by far the best that has ever been published. It is concise, systematic, thorough, and fully up-to-date in everything. I consider it a great credit to both the author and the publishers."

**George Roe Lockwood, M. D.,**

*Attending Physician to the Bellevue Hospital, New York.*

"I have read several of the important chapters carefully, and am very much pleased with the work. It is thoroughly up-to-date, well expressed, and shows evidence of clinical experience."

## AMERICAN EDITION

**NOTHNAGEL'S PRACTICE**

UNDER THE EDITORIAL SUPERVISION OF

**ALFRED STENGEL, M.D.**

Professor of Clinical Medicine in the University of Pennsylvania; Visiting  
Physician to the Pennsylvania Hospital.

It is universally acknowledged that the Germans lead the world in Internal Medicine; and of all the German works on this subject, Nothnagel's "Specielle Pathologie und Therapie" is conceded by scholars to be without question the best Practice of Medicine in existence. So necessary is this book in the study of Internal Medicine that it comes largely to this country in the original German. In view of these facts, Messrs. W. B. Saunders & Company have arranged with the publishers of the German edition to issue at once an authorized American edition of this great Practice of Medicine.

**BEST IN  
EXISTENCE**

For the present a set of ten volumes, selected with especial thought of the needs of the practising physician, will be published. These volumes will contain the real essence of the entire work, and the purchaser will therefore obtain, at less than half the cost, the cream of the original. Later the special and more strictly scientific volumes will be offered from time to time.

**FOR THE  
PRACTITIONER**

The work will be translated by men possessing thorough knowledge of both English and German, and each volume will be edited by a prominent specialist. It will thus be brought thoroughly up to date, and the American edition will be more than a mere translation; for, in addition to the matter contained in the original, it will represent the very latest views of the leading American and English specialists in the various departments of Internal Medicine. Moreover, as each volume will be revised to the date of its publication by the eminent editor, the objection that has heretofore existed to treatises published in a number of volumes will be obviated, since the subscriber will receive the completed work while the earlier volumes are still fresh. The American publication of the entire work is under the editorial supervision of Dr. ALFRED STENGEL, who has selected the subjects for the American Edition, and has chosen the editors of the different volumes.

**PROMINENT  
SPECIALISTS****VOLUMES SOLD  
SEPARATELY**

The usual method of publishers when issuing a publication of this kind has been to require physicians to take the entire work. This seems to us in many cases to be undesirable. Therefore, in purchasing this Practice physicians will be given the opportunity of subscribing for it in entirety; but any single volume or any number of volumes, each complete in itself, may be obtained by those who do not desire the complete series. This latter method offers to the purchaser many advantages which will be appreciated by those who do not care to subscribe for the entire work at one time.

**SEE NEXT TWO PAGES FOR LIST**

AMERICAN EDITION

**NOTHNAGEL'S PRACTICE**

VOLUMES NOW READY

**Typhoid and Typhus Fevers**

By DR. H. CURSCHMANN, Professor of Medicine in Leipsic. The entire volume edited, with additions, by WILLIAM OSLER, M. D., F. R. C. P., Professor of the Principles and Practice of Medicine, Johns Hopkins University, Baltimore. Octavo, 646 pages, illustrated. Cloth, \$5.00 net; Half Morocco, \$6.00 net.

"Under the editorial supervision of Dr. Osler, the original German work, excellent though it is, has been much improved, greatly enlarged, and enhanced in value, especially to American readers. . . . The monograph on typhoid fever is the best exponent of the knowledge that we have in regard to this disease that is to be had in any language."—*Journal of the American Medical Association*.

**Smallpox (including Vaccination), Varicella, Cholera Asiatica, Cholera Nostras, Erysipelas, Erysipeloid, Pertussis, and Hay Fever**

By DR. H. IMMERMAN, of Basle; DR. TH. VON JÜRGENSEN, of Tübingen; DR. C. LIEBERMEISTER, of Tübingen; DR. H. LENHARTZ, of Hamburg; and DR. G. STICKER, of Giessen. The entire volume edited, with additions, by SIR J. W. MOORE, M. D., F. R. C. P. I., Professor of Practice, Royal College of Surgeons, Ireland. Octavo, 682 pages, illustrated. Cloth, \$5.00 net; Half Morocco, \$6.00 net.

"Dr. Immermann's vindication of vaccination in the prophylaxis of smallpox will be read with peculiar interest at the present time, since it is probably the most complete and unassailable indictment of the propaganda of antivaccination fanatics which has ever been published."—*The London Lancet*.

**Diphtheria, Measles, Scarlet Fever, and Rötheln**

By WILLIAM P. NORTHRUP, M. D., of New York, and DR. TH. VON JÜRGENSEN, of Tübingen. The entire volume edited, with additions, by WILLIAM P. NORTHRUP, M. D., Professor of Pediatrics, University and Bellevue Hospital Medical College, New York. Octavo, 672 pages, illustrated, including 24 full-page plates, 3 in colors. Cloth, \$5.00 net; Half Morocco, \$6.00 net.

"The author is to be congratulated on the exhaustive and practical manner in which he presents the subject. . . . The articles on measles, scarlet fever, and German measles are exhaustive treatises, with numerous additions by the American editor."—*Journal of the American Medical Association*.

**Diseases of the Bronchi, Diseases of the Pleura, and Inflammations of the Lungs**

By DR. F. A. HOFFMANN, of Leipsic; DR. O. ROSENBACH, of Berlin; and DR. F. AUFRECHT, of Magdeburg. The entire volume edited, with additions, by JOHN H. MUSSER, M. D., Professor of Clinical Medicine, University of Pennsylvania. Octavo, 1029 pages, illustrated, including 7 full-page colored lithographic plates. Cloth, \$5.00 net; Half Morocco, \$6.00 net.

"These monographs in the original hold an enviable place in German medical literature, each one being exhaustive, complete, authoritative, and written by men specially fitted for the work. But the American edition is not only a reproduction in English, it is all of this and more; for the American editor has added much of value not included in the original, and he has brought every part thoroughly up to date."—*Journal of the American Medical Association*.

AMERICAN EDITION

# NOTHNAGEL'S PRACTICE

VOLUMES NOW READY AND IN PRESS

## Diseases of the Pancreas, Suprarenals, and Liver

By DR. L. OSER, of Vienna; DR. E. NEUSSER, of Vienna, and DRS. H. QUINCKE and G. HOPPE-SEYLER, of Kiel. The entire volume edited, with additions, by REGINALD H. FITZ, A. M., M. D., Hersey Professor of the Theory and Practice of Physic, Harvard University; and FREDERICK A. PACKARD, M. D., Late Physician to the Pennsylvania and to the Children's Hospitals. Octavo of 918 pages, illustrated. Cloth, \$5.00 net; Half Morocco, \$6.00 net.

It has been the aim of the authors and editor of this work to describe the present condition of our knowledge on the subjects, to point out where it is deficient, and to stimulate to new work. The work will be found practical in every particular.

## Diseases of the Stomach

By DR. F. RIEGEL, of Giessen. Edited, with additions, by CHARLES G. STOCKTON, M. D., Professor of Medicine, University of Buffalo. Handsome octavo of 835 pages, with 29 text-cuts and 6 full-page plates. Cloth, \$5.00 net; Half Morocco, \$6.00 net.

This work is a complete exposition of the diseases of the stomach. Full consideration is given to the hydrochloric acid question, the latest views being incorporated by the editor. Particular attention has been given to disturbances of motility and secretion.

## Diseases of the Intestines and Peritoneum

By DR. HERMANN NOTHNAGEL, of Vienna. The entire volume edited, with additions, by HUMPHREY D. ROLLESTON, M. D., F. R. C. P., Physician to and Lecturer on Pathology at St. George's Hospital, London. Handsome octavo of 800 pages, finely illustrated.

## Influenza, Dengue, Malarial Diseases

By DR. O. LEICHTENSTERN, of Cologne, and DR. J. MANNABERG, of Vienna. The entire volume edited, with additions, by RONALD ROSS, F. R. C. S., ENG., D. P. H., F. R. S., Major, Indian Medical Service, retired; Walter Myers Lecturer, Liverpool School of Tropical Medicine, Liverpool. Handsome octavo of 700 pages, with 7 full-page lithographic plates in colors.

## Anemia, Leukemia, Pseudoleukemia, Hemoglobinemia, and Chlorosis

By DR. P. EHRLICH, of Frankfort-on-the-Main; DR. A. LAZARUS, of Charlottenburg; DR. FELIX PINKUS, of Berlin; and DR. K. VON NOORDEN, of Frankfort-on-the-Main. The entire volume edited, with additions, by ALFRED STENGEL, M. D., Professor of Clinical Medicine, University of Pennsylvania. Handsome octavo of 750 pages, with 5 full-page lithographs in colors.

## Tuberculosis and Acute General Miliary Tuberculosis

By DR. G. CORNET, of Berlin. Edited, with additions, by WALTER B. JAMES, M. D., Professor of the Practice of Medicine, Columbia University, New York. Handsome octavo of 700 pages.

**EACH VOLUME IS COMPLETE IN ITSELF AND IS SOLD SEPARATELY**

# Eichhorst's Practice of Medicine

**A Text-Book of the Practice of Medicine.** By DR. HERMANN EICHHORST, Professor of Special Pathology and Therapeutics and Director of the Medical Clinic, University of Zurich. Translated and edited by AUGUSTUS A. ESHNER, M.D., Professor of Clinical Medicine, Philadelphia Polyclinic. Two octavo volumes of 600 pages each, with over 150 illustrations. Price per set: Cloth, \$6.00 net; Sheep or Half Morocco, \$7.50 net.

## BY ONE OF THE GREATEST OF GERMAN CLINICIANS

This book is a new one, but on its publication it sprang into immediate popularity, and is now one of the leading text-books in Germany. It is practically a condensed edition of the author's great work on Special Pathology and Therapeutics, and it forms not only an ideal text-book for students, but a practical guide of unusual value to practising physicians.

### Bulletin of Johns Hopkins Hospital

"This book is an excellent one of its kind. Its completeness, yet brevity, the clinical methods, the excellent paragraphs on treatment and watering-places, will make it very desirable."

---

# Bridge on Tuberculosis

**Tuberculosis:** Recast from Lectures Delivered at Rush Medical College. By NORMAN BRIDGE, A.M., M.D., Emeritus Professor of Medicine in Rush Medical College, in affiliation with the University of Chicago. 12mo of 302 pages, illustrated. Cloth, \$1.50 net.

## JUST ISSUED

In this excellent work the practical side of the care and management of those sick with the various non-surgical forms of tuberculosis has been concisely stated. Full consideration has been given to prophylaxis, an all-important phase of the subject that has heretofore been much neglected. There are also chapters upon the Bacillus of Tuberculosis; on the Pathology, Etiology, Symptoms, Physical Signs, Diagnosis, and Prognosis of the disease, each treated in the judicious and thorough manner to be expected in a work by such a well-known authority as Dr. Bridge. Treatment is accorded unusual space.

# Sollmann's Pharmacology

Including Therapeutics, Materia Medica, Pharmacy,  
Prescription-writing, Toxicology, etc.

---

**A Text-Book of Pharmacology.** By TORALD SOLLMANN, M. D., Assistant Professor of Pharmacology and Materia Medica, Medical Department of Western Reserve University, Cleveland, Ohio. Handsome octavo volume of 894 pages, fully illustrated. Cloth, \$3.75 net.

## A NEW WORK—RECENTLY ISSUED

This work aims to furnish a scientific discussion and definite conception of the action of drugs, as well as their derivation, composition, strength, and dose. The author bases the study of therapeutics on a systematic knowledge of the nature and properties of drugs, and thus brings out forcibly the intimate relation between pharmacology and practical medicine.

**J. F. Fotheringham, M. D.**

*Prof. of Therapeutics and Theory and Practice of Prescribing, Trinity Med. College, Toronto.*

"The work certainly occupies ground not covered in so concise, useful, and scientific a manner by any other text I have read on the subjects embraced."

---

# Butler's Materia Medica Therapeutics, and Pharmacology

---

**A Text-Book of Materia Medica, Therapeutics, and Pharmacology.** By GEORGE F. BUTLER, PH. G., M. D., Professor of Materia Medica and of Clinical Medicine, College of Physicians and Surgeons, Chicago, Octavo, 896 pages, illustrated. Cloth, \$4.00 net; Sheep or Half Morocco, \$5.00 net.

## FOURTH EDITION, REVISED AND ENLARGED

In this new edition the chapters on Organo-therapy, Serum-therapy, and cognate subjects have been enlarged and carefully revised. An important addition is the chapter devoted to the newer theories of electrolytic dissociation and its relation to the topic of pharmacotherapy.

**Medical Record, New York**

"Nothing has been omitted by the author which, in his judgment, would add to the completeness of the text, and the student or general reader is given the benefit of latest advices bearing upon the value of drugs and remedies considered."

# Gould and Pyle's Curiosities of Medicine

---

**Anomalies and Curiosities of Medicine.** By GEORGE M. GOULD, M. D., and WALTER L. PYLE, M. D. An encyclopedic collection of rare and extraordinary cases and of the most striking instances of abnormality in all branches of Medicine and Surgery, derived from an exhaustive research of medical literature from its origin to the present day, abstracted, classified, annotated, and indexed. Handsome octavo volume of 968 pages, 295 engravings, and 12 full-page plates.

**Popular Edition : Cloth, \$3.00 net ; Sheep or Half Morocco, \$4.00 net.**

As a complete and authoritative Book of Reference this work will be of value not only to members of the medical profession, but to all persons interested in general scientific, sociologic, and medicolegal topics ; in fact, the absence of any complete work upon the subject makes this volume one of the most important literary innovations of the day.

**The Lancet, London**

"The book is a monument of untiring energy, keen discrimination, and erudition. . . . We heartily recommend it to the profession."

---

# Saunders' Year-Book

---

**The American Year-Book of Medicine and Surgery.** A Yearly Digest of Scientific Progress and Authoritative Opinion in all branches of Medicine and Surgery, drawn from journals, monographs, and textbooks of the leading American and foreign authors and investigators. Arranged with critical editorial comments by eminent American specialists, under the editorial charge of GEORGE M. GOULD, M. D. In two volumes—Vol. I., including *General Medicine* ; Vol. II., *General Surgery*. Per volume : Cloth, \$3.00 net ; Half Morocco, \$3.75 net. *Sold by Subscription.*

**EQUIVALENT TO A POSTGRADUATE COURSE**

**The Lancet, London**

"It is much more than a mere compilation of abstracts, for, as each section is entrusted to experienced and able contributors, the reader has the advantage of certain critical commentaries and expositions . . . proceeding from writers fully qualified to perform these tasks."

# Thornton's Dose-Book

**Dose-Book and Manual of Prescription-Writing.** By E. Q. THORNTON, M. D., Assistant Professor of Materia Medica, Jefferson Medical College, Phila. Post-octavo, 362 pages, illustrated. Flexible Leather, \$2.00 net.

## Second Edition, Revised and Enlarged

In the new edition of this work, intended for the student and practitioner, additions have been made to the chapters on "Prescription-Writing" and "Incompatibilities," and references have been introduced in the text to the newer curative sera, organic extracts, synthetic compounds, and vegetable drugs. To the Appendix, chapters upon Synonyms and Poisons and their antidotes have been added, thus increasing its value as a book of reference.

**C. H. Miller, M. D.,**

*Professor of Pharmacology, Northwestern University Medical School, Chicago.*

"I will be able to make considerable use of that part of its contents relating to the correct terminology as used in prescription-writing, and it will afford me much pleasure to recommend the book to my classes, who often fail to find this information in their other text-books."

---

# American Text-Book of Applied Therapeutics

**American Text-Book of Applied Therapeutics.** Edited by JAMES C. WILSON, M. D., Professor of Practice of Medicine and of Clinical Medicine, Jefferson Medical College, Philadelphia. Handsome imperial octavo volume of 1326 pages. Illustrated. Cloth, \$7.00 net; Sheep or Half Morocco, \$8.00 net.

## For Student and Practitioner

Written for both the student and practitioner, the aim of this work is to facilitate the application of knowledge to the prevention, cure, and alleviation of disease. The endeavor throughout has been to conform to the title of the book—"Applied Therapeutics"—to indicate the course of treatment to be pursued at the bedside, rather than to name a list of drugs that have been used at one time or another. The work will be found accurate and trustworthy.

**Buffalo Medical Journal**

"It is one of the most complete books of reference that has been presented to the profession on medicine in a long period of time; and never before have we had one that undertook to cover the field in this manner."

**The American Pocket Medical Dictionary. Fourth Edition, Revised**

THE AMERICAN POCKET MEDICAL DICTIONARY. Edited by W. A. NEWMAN DORLAND, M. D., Assistant Obstetrician to the Hospital of the University of Pennsylvania. Containing the pronunciation and definition of the principal words used in medicine and kindred sciences, with 64 extensive tables. Flexible leather, with gold edges, \$1.00 net; with thumb index, \$1.25 net.

"I can recommend it to our students without reserve."—J. H. Holland, M. D., *Dean of the Jefferson Medical College, Philadelphia.*

**Vierordt's Medical Diagnosis. Fourth Edition, Revised**

MEDICAL DIAGNOSIS. By DR. OSWALD VIERORDT, Professor of Medicine, University of Heidelberg. Translated from the fifth enlarged German edition by FRANCIS H. STUART, A. M., M. D. Octavo, 603 pages, 104 wood cuts. Cloth, \$4.00 net; Sheep or Half Morocco, \$5.00 net.

"Has been recognized as a practical work of the highest value. It may be considered indispensable both to students and practitioners."—F. Minot, M. D., *late Professor of Theory and Practice in Harvard University.*

**Cohen and Eshner's Diagnosis. Second Revised Edition**

ESSENTIALS OF DIAGNOSIS. By S. SOLIS-COHEN, M. D., Senior Assistant Professor in Clinical Medicine, Jefferson Medical College, Phila.; and A. A. ESHNER, M. D., Professor of Clinical Medicine, Philadelphia Polyclinic. Post-octavo, 382 pages; 55 illustrations. Cloth, \$1.00 net. *In Saunders' Question-Compend Series.*

"Concise in the treatment of subject, terse in expression of fact."—*American Journal of the Medical Sciences.*

**Morris' Materia Medica and Therapeutics. Fifth Revised Edition**

ESSENTIALS OF MATERIA MEDICA, THERAPEUTICS, AND PRESCRIPTION-WRITING. By HENRY MORRIS, M. D., late Demonstrator of Therapeutics, Jefferson Medical College, Phila. Post-octavo, 250 pages. Cloth, \$1.00 net. *In Saunders' Question-Compend Series.*

"Cannot fail to impress the mind and instinct in a lasting manner."—*Buffalo Medical Journal.*

**Sayre's Practice of Pharmacy. Second Edition, Revised**

ESSENTIALS OF THE PRACTICE OF PHARMACY. By LUCIUS E. SAYRE, M. D., Professor of Pharmacy, University of Kansas. Post-octavo, 200 pages. Cloth, \$1.00 net. *In Saunders' Question-Compend Series.*

"The topics are treated in a simple, practical manner, and the work forms a very useful student's manual."—*Boston Medical and Surgical Journal.*

**Brockway's Medical Physics. Second Edition, Revised**

ESSENTIALS OF MEDICAL PHYSICS. By FRED. J. BROCKWAY, M. D., late Assistant Demonstrator of Anatomy, College of Physicians and Surgeons, N. Y. Post-octavo, 330 pages; 155 fine illustrations. Cloth, \$1.00 net. *In Saunders' Question-Compend Series.*

"It contains all that one need know on the subject, is well written, and is copiously illustrated."—*Medical Record, New York.*

**Stoney's Materia Medica for Nurses**

MATERIA MEDICA FOR NURSES. By EMILY A. M. STONEY, Superintendent of the Training School for Nurses at the Carney Hospital, South Boston, Mass. Handsome octavo volume of 306 pages. Cloth, \$1.50 net.

"It contains about everything that a nurse ought to know in regard to drugs."—*Journal of the American Medical Association.*

**Grafstrom's Mechano-therapy**

A TEXT-BOOK OF MECHANO-THERAPY (Massage and Medical Gymnastics). By AXEL V. GRAFSTROM, B. Sc., M. D., late House Physician, City Hospital, Blackwell's Island, N. Y. 12mo, 139 pages, illustrated. \$1.00 net.

"Certainly fulfills its mission in rendering comprehensible the subjects of massage and medical gymnastics."—*New York Medical Journal.*

## Jakob and Eshner's Internal Medicine and Diagnosis

ATLAS AND EPITOME OF INTERNAL MEDICINE AND CLINICAL DIAGNOSIS. By DR. CHR. JAKOB, of Erlangen. Edited, with additions, by A. A. ESHNER, M. D., Professor of Clinical Medicine, Philadelphia Polyclinic. With 182 colored figures on 68 plates, 64 text-illustrations, 259 pages of text. Cloth, \$3.00 net. *In Saunders' Hand-Atlas Series.*

"Can be recommended unhesitatingly to the practicing physician no less than to the student."—*Bulletin of Johns Hopkins Hospital.*

## Lockwood's Practice of Medicine.

Second Edition,  
Revised and Enlarged

A MANUAL OF THE PRACTICE OF MEDICINE. By GEO. ROE LOCKWOOD, M. D., Attending Physician to the Bellevue Hospital, New York City. Octavo, 847 pages, with 79 illustrations in the text and 22 full-page plates. Cloth, \$4.00 net.

"A work of positive merit, and one which we gladly welcome."—*New York Medical Journal.*

## Salinger and Kalteyer's Modern Medicine

MODERN MEDICINE. By JULIUS L. SALINGER, M. D., late Demonstrator of Clinical Medicine, Jefferson Medical College; and F. J. KALTEYER, M. D., Demonstrator of Clinical Medicine, Jefferson Medical College. Handsome octavo, 801 pages, illustrated. Cloth, \$4.00 net.

"I have carefully examined the book, and find it to be thoroughly trustworthy in all respects and a valuable text-book for the medical student."—*Sam'l O. L. Potter, Formerly Professor of Principles and Practice of Medicine, Cooper Medical College, San Francisco.*

## Keating's Life Insurance

HOW TO EXAMINE FOR LIFE INSURANCE. By the late JOHN M. KEATING, M. D., Ex-President of the Association of Life Insurance Medical Directors. Royal octavo, 211 pages. With numerous illustrations. Cloth, \$2.00 net.

"This is by far the most useful book which has yet appeared on insurance examination."—*Medical News.*

## Corwin's Physical Diagnosis. Third Edition, Revised

ESSENTIALS OF PHYSICAL DIAGNOSIS OF THE THORAX. By A. M. CORWIN, A. M., M. D., Instructor of Physical Diagnosis in Rush Medical College, Chicago. 220 pages, illustrated. Cloth, flexible covers, \$1.25 net.

"A most excellent little work. It arranges orderly and in sequence the various objective phenomena to logical solution of a careful diagnosis."—*Journal of Nervous and Mental Diseases.*

## American Text-Book of Theory and Practice


AMERICAN TEXT-BOOK OF THE THEORY AND PRACTICE OF MEDICINE. Edited by the late WILLIAM PEPPER, M. D., LL. D., Professor of the Theory and Practice of Medicine and of Clinical Medicine, University of Penna. Two handsome imperial octavos of about 1000 pages each. Illustrated. Per volume: Cloth, \$5.00 net; Sheep or Half Morocco, \$6.00 net.


"I am quite sure it will command itself both to practitioners and students of medicine, and become one of our most popular text-books."—*Alfred Loomis, M. D., LL. D., Professor of Pathology and Practice of Medicine, University of the City of New York.*


## Stevens' Practice of Medicine. Sixth Edition, Revised—Just Issued


A MANUAL OF THE PRACTICE OF MEDICINE. By A. A. STEVENS, A. M., M. D., Lecturer on Physical Diagnosis, University of Pennsylvania. Specially intended for students preparing for graduation and hospital examinations. Post-octavo, 519 pages; illustrated. Flexible leather, \$2.00 net.

"An excellent condensation of the essentials of medical practice for the student, and may be found also an excellent reminder for the busy physician."—*Buffalo Medical Journal.*









QM601

Heisler

Text-book of Embryology

H36

cop. 2.

1901

✓

