

Principles and practice of filling teeth.

Contributors

Johnson, Charles Nelson, 1860-1938.
Augustus Long Health Sciences Library

Publication/Creation

Philadelphia : S. S. White Dental Manufacturing Co., 1900.

Persistent URL

<https://wellcomecollection.org/works/n84jymr9>

License and attribution

This material has been provided by This material has been provided by the Augustus C. Long Health Sciences Library at Columbia University and Columbia University Libraries/Information Services, through the Medical Heritage Library. The original may be consulted at the the Augustus C. Long Health Sciences Library at Columbia University and Columbia University. where the originals may be consulted.

This work has been identified as being free of known restrictions under copyright law, including all related and neighbouring rights and is being made available under the Creative Commons, Public Domain Mark.

You can copy, modify, distribute and perform the work, even for commercial purposes, without asking permission.

**wellcome
collection**

Wellcome Collection
183 Euston Road
London NW1 2BE UK
T +44 (0)20 7611 8722
E library@wellcomecollection.org
<https://wellcomecollection.org>

COLUMBIA LIBRARIES OFFSITE
HEALTH SCIENCES STANDARD



HX64071189

RK541 J62

Principles and pract

RECAP

RK541

J62


Columbia University
in the City of New York
School of Dental and Oral Surgery




LIBRARY OF
DR. CARL F. W. BÖDECKER
1846-1912
The gift of
Dr. Henry and Dr. Charles Bödecker
1929







Digitized by the Internet Archive
in 2010 with funding from
Open Knowledge Commons



C. W. Bodeker

Principles and Practice

OF

Filling Teeth.

BY

C. N. JOHNSON, M.A., L.D.S., D.D.S.,

PROFESSOR OF OPERATIVE DENTISTRY IN THE CHICAGO COLLEGE
OF DENTAL SURGERY.

WITH ILLUSTRATIONS.

PHILADELPHIA :

THE S. S. WHITE DENTAL MANUFACTURING COMPANY.

LONDON :

CLAUDIUS ASH & SONS (Limited).

1900.

R1541

562

Copyright, 1900, by C. N. JOHNSON.
Entered at Stationers' Hall, London.

CONTENTS.

	PAGE
INTRODUCTORY.....	5
CHAPTER I.....	9
DEPOSITS ON THE TEETH. Kinds of Deposits.—Salivary Calculus.—Serumal Calculus.—Stains on the Teeth. REMOVAL OF DEPOSITS. Removal of Salivary Calculus.—Instruments for this purpose.—Technique of the Operation.—Removal of Stains from the Teeth.—Instructions to Patients as to the Care of the Teeth.	
CHAPTER II.....	31
DENTAL CARIES.	
CHAPTER III.....	44
EXAMINATION OF THE TEETH FOR CARIES. Appliances for Examining the Teeth.	
CHAPTER IV.....	47
EXCLUSION OF MOISTURE DURING OPERATIONS. Kinds of Rubber Dam.—Size of Dam.—Punching the Holes in Rubber Dam.—Rubber-Dam Clamps.—Kinds of Clamps.—Clamps for Molars and Bicuspid.—Cervical Clamps for Buccal, Labial, or Lingual Cavities.—Ligatures —Manner of Applying the Dam in the Different Locations in the Mouth.—Applying the Dam for Operations on Buccal, Labial, or Lingual Cavities.—Application of Dam in Difficult Cases.—Use of Napkins and Cotton Rolls for Maintaining Dryness During Operations.—Napkins.—Rolls.	
CHAPTER V.....	79
CLASSIFICATION AND PREPARATION OF CAVITIES. CAVITY PREPARATION. Simple Proximal Cavities in Incisors and Cuspids.—Separating Teeth.—Detail of Cavity Formation.—General Considerations.—Proximal Cavities in Anterior Teeth Involving the Incisal Angle.—Detail of Cavity Formation.—General Considerations.—Proximal Cavities in Bicuspid and Molars.—Simple Proximal Cavities not Involving other Surfaces.—Proximo-Occlusal Cavities in Bicuspid and Molars.—The Interproximal Space.—Separating the Teeth.—Details of Cavity Formation.—General Considerations.—Buccal, Labial, or Lingual Cavities.—Occlusal Cavities in Bicuspid and Molars.—The Treatment of Softened Dentine in Deep-Seated Cavities.—Hypersensitive Dentine.	
CHAPTER VI.....	150
FILLING-MATERIALS. Gold and its Combinations.—Gold and Platinum.—Gold and Tin.—Gold and Iridium.—Amalgam.—Tin.—Cements.—Gutta-Percha.—Inlays.	
CHAPTER VII.....	164
GOLD. Cohesive and Non-Cohesive Gold.—Annealing Gold.—Different Forms of Gold.—Crystal Golds.	
CHAPTER VIII.....	174
MALLETS AND MALLETING. The Hand Mallet.—The Automatic Mallet.—The Rapid Mallets.—Hand Pressure.—Protection to the Periodontal Membrane in Malleting.	

	PAGE
CHAPTER IX.....	185
THE INTRODUCTION, CONDENSATION, AND FINISHING OF GOLD FILLINGS IN THE DIFFERENT CLASSES OF CAVITIES. Simple Proximal Gold Fillings in Incisors.—Pluggers.—Finishing Proximal Fillings in Incisors.—Proximal Fillings in Anterior Teeth Involving the Incisal Angle.—Fillings in Proximo-Occlusal Cavities in Bicuspids and Molars.—The Matrix.—Disto-Occlusal Fillings in Left Lower Bicuspids and Molars.—Pluggers.—Finishing Fillings.—Disto-Occlusal Fillings in Right Lower Bicuspids and Molars.—Disto-Occlusal Fillings in Upper Bicuspids and Molars.—Mesio-Occlusal Fillings in Bicuspids and Molars.—Occlusal Fillings in Bicuspids and Molars.—Buccal, Labial, or Lingual Fillings.	
CHAPTER X.....	221
MANIPULATION OF PLATINUM AND GOLD IN FILLING TEETH.	
CHAPTER XI.....	223
MANIPULATION OF TIN AND GOLD.	
CHAPTER XII.....	227
MANIPULATION OF AMALGAM. Method of Packing Amalgam.	
CHAPTER XIII.....	231
MANIPULATION OF CEMENTS.	
CHAPTER XIV.....	234
MANIPULATION OF GUTTA-PERCHA.	
CHAPTER XV.....	235
MAKING INLAY FILLINGS. Porcelain Inlays.—Gold Inlays.	
CHAPTER XVI.....	241
PULP-CAPPING. Materials for Capping Pulps.—Method of Capping Pulps.	
CHAPTER XVII.....	247
DESTRUCTION OF THE PULP. Destroying the Pulp with Arsenic.—Removing the Pulp with Cocaine.—Removal of the Pulp	
CHAPTER XVIII.....	254
FILLING PULP-CANALS.	
CHAPTER XIX.....	258
THE TREATMENT OF PULPLESS TEETH. Treatment of Pulpless Teeth where the Canals have long been Exposed to the Fluids of the Mouth, but where there is no Fistulous Opening.—Treatment of Pulpless Teeth having a Fistulous Opening on Gum.—Opening into Filled Teeth in which Pulps have Died, but Lain Dormant.—Management of Pulpless Teeth in Anterior Part of Mouth to Prevent Discoloration.—Bleaching Teeth.	
CHAPTER XX.....	269
THE MANAGEMENT OF CHILDREN'S TEETH. Management of the Deciduous Teeth.—Treatment of Exposed Pulps in Deciduous Teeth.—Treatment of Abscessed Deciduous Teeth.—The Management of Permanent Teeth in Childhood.	

INTRODUCTORY.

THE problem of preventing or controlling caries of the teeth is one which enters very materially into the health, longevity, and happiness of the human race. Apparently we are not yet able to prevent decay, and it thus becomes imperative that we study the best means of checking and controlling it. When caries occurs on any surface of a tooth the dentist should study carefully the conditions which brought it about, and should aim in his operations so to change those conditions that caries will not be likely to recur.

Too many practitioners are in the habit of following their work day after day in a thoughtless, slipshod manner, without due consideration of the principles which should underlie all operative procedures, and without a proper study of the relations of cause and effect. When failures occur, as they do in the hands of all practitioners,—some more, some less,—the most profitable lesson is not always learned thereby. No dentist should allow himself to pass over any failure, whether his own or another's, without carefully studying the particular reasons for that failure and the problems which must be solved to avoid a repetition in the future. With the clearness of vision which should eventually result from this kind of study the practitioner will be better equipped to serve his patrons, and his failures will grow perceptibly fewer. If all dentists would bring to their work a due regard for this form of observation, it would add materially to the permanence of dental service.


In the consideration of the present subject the principal aim will be to direct attention to some of the causes of failure in filling teeth, and to offer suggestions relative to possible improvement in methods of procedure. In doing this no originality of treatment is claimed. The thought of the profession in recent years has been too active along these lines for any one individual to claim much in the way of originality. But some of the recent advances in practice would seem to need systematizing, and most of them require emphasizing. This is the present aim.

The plan is to treat the various topics as nearly as practicable in the order of their performance in the mouth; to give in detail the consecutive steps of the operation, and to say something of the technique of the subject. This latter is considered to be of very great importance, but it is a matter quite difficult of intelligent treatment. The proper selection and use of instruments has much to do with the effectiveness of our work and the comfort of our patients, but the personal equation of each individual operator enters so prominently into the question that it is difficult to lay down rules for all to follow. Then, again, there is such a variation in patients with regard to their toleration of different instruments that it is not always judicious to use the same instruments in the same way on all patients. We must study carefully this susceptibility of our patients, and in all cases where it will not interfere with the perfection of our work we should respect their preference. Some individuals will submit to the use of hand instruments, such as excavators and chisels, with better grace than they will to the engine, while very many prefer the smooth, light touch of a rapidly-revolving bur to the grating, rasping sensation of an excavator. In the routine practice of operating there are some stages of the work where the engine is clearly indicated, and some where hand instruments must be used, but the predominance

of the use of either may in certain instances be determined by the patient. Not that we should in any sense allow patients to dictate to us how we shall operate, but that we may often profitably study their varying susceptibilities to the impressions made upon them by different instruments, and govern our manipulation somewhat thereby.

Much in the way of prejudice may be overcome by the invariable use of keen, sharp instruments and a dextrous, careful method of manipulation. This applies as well to the engine as to hand instruments. The dentist should cultivate the utmost delicacy of touch, so as to impress upon his patient at all times the fact that he is giving the least possible discomfort commensurate with effective work.

The system of technique here suggested is not presented as being applicable to all operators or all patients. It is not even claimed that it is the best system, but merely that it is an attempt to formulate a definite and consecutive method of procedure in the performance of many of our operations, which in the past seem, for the most part, to have been performed without method and without system.



Principles and Practice of Filling Teeth.

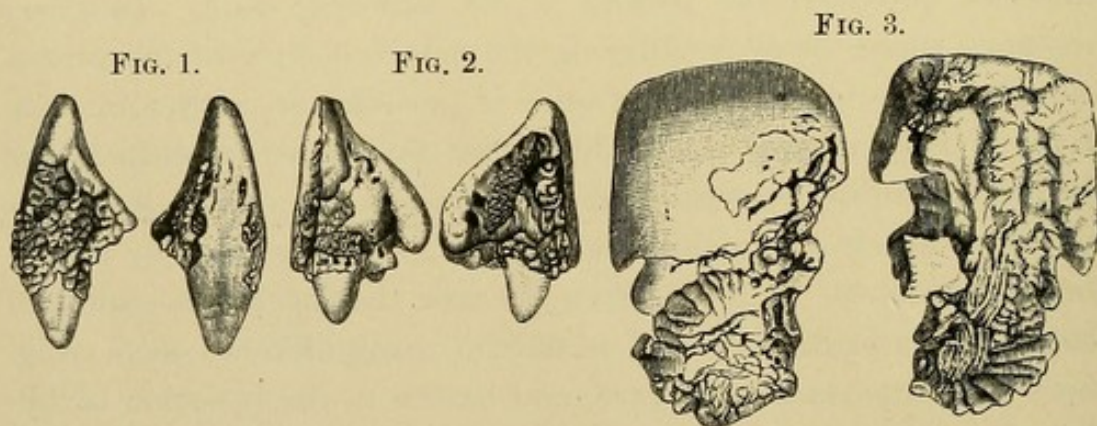
CHAPTER I.

DEPOSITS ON THE TEETH.

THE first duty of the dentist when a patient applies to him for attention to the natural teeth is the thorough removal of all deposits, provided the patient is not suffering pain. In every instance where there is suffering the manifest duty of the professional man is to relieve it at once if possible, no matter in what form it may present itself; but after this is accomplished, and before any filling operations are undertaken, the mouth should be put in as nearly a hygienic condition as may be secured by the utmost cleanliness. It is too often the case that operators—some of them with a brilliant record as skillful manipulators—seem to ignore this important procedure, and hasten to the insertion of fillings in teeth covered with calculus. It matters not how beautiful or how perfect an operation may be under these conditions, the work should never be considered as ideal dental service. No successful architect ever builds a house without first looking well to the foundation, and no surgeon of repute will proceed to operate upon a wound without at least making the surrounding parts as healthy as may be in advance. Dentists are not living up to the highest possibilities of their art when they fail to consider the importance of maintaining the tissues around the teeth in a state of health, and this cannot be done short of a careful removal of all extraneous material which may be found adherent to the teeth. It is not within the province of the present work to go minutely into the pathology of this subject, and yet it would seem desirable

to briefly indicate some of the deleterious effects produced by deposits when allowed to remain.

The encroachment of calculus along the neck and root of a tooth, if left unchecked, results in an absorption of the gum, the peridental membrane, and even the alveolar process, so that finally the support of the tooth is destroyed, and it is allowed to topple over and fall out. It is estimated by many observant practitioners that more teeth are lost as the result of diseased conditions in the tissues surrounding them than from decay of the teeth themselves; and, if this be true, it is very important that dentists should pay especial attention to the agencies calculated to bring about such conditions. It is undeniably a fact that calculus in a mouth subject to its continual formation will, if allowed to accumulate, sooner or later work the destruction of the teeth.



Figs. 1, 2, and 3 illustrate some extreme cases of calculus formation about the teeth. Figs. 1 and 2 show the mesial and distal aspects of two lower incisors with calculus attached, actual size. Fig. 3 is a mass of calculus detached from the buccal surface of an upper molar. The patient applied to her dentist for examination relative to some "growth" which she said was forming in her mouth, and the result was the removal of this piece of calculus; here reproduced in two views, actual size. It must be apparent that in the specimens shown the teeth need not necessarily have been lost if early attention had been given to these deposits. There was not the slightest indication of caries upon any of them, and it is safe to conclude that had the patients sought

and obtained proper dental service in the initial stages of the affection the teeth might have been preserved for many years of usefulness. It is true that in these particular cases the patient had failed to apply to the dentist in time to accomplish anything, through an ignorance of the significance of the deposits, and yet there would seem to be many instances where the neglect is not entirely traceable to the patient. It should be the office of the dentist not only to perform operations on the teeth, but to so educate those who come under his charge that the general public shall be made familiar with conditions so readily understood as these, and so manifestly self-evident when attention is once called to them.

KINDS OF DEPOSITS.

Deposits are usually classified under three kinds, *salivary calculus*, *serumal calculus*, and *green stain*, though from an operative point of view the latter would seem to be widely distinguishable from the other two. It is not a deposit of appreciable bulk, and it is entirely different in character, both as regards its deleterious effects and the methods to be employed in its removal. Nor would it seem to be altogether appropriate to limit the term to "green" stain. There are other stains on the teeth besides those of a green color, and they should not be ignored in considering the subject.

Salivary Calculus.

This, as its name implies, is chiefly a deposit from the saliva. The solid constituents of this secretion, which are normally held in solution during its progress from the gland to the mouth, become so affected by the change of environment on entering the oral cavity as to be precipitated in the form of calculus on the teeth. This being true, we should naturally expect to find the most extensive deposits upon the surfaces of the teeth lying nearest to the openings of the salivary ducts, a fact borne out by clinical observations. The usual points of initial deposit of salivary calculus are upon the lingual surfaces of the lower incisors, opposite the openings of the ducts from the sublingual and submaxillary glands,

and upon the buccal surfaces of the upper molars, which are copiously bathed in the parotid saliva. This must not imply that these are the only surfaces subject to the deposition of salivary calculus. There is no surface of any tooth exposed to the fluids of the mouth which may not accumulate this deposit, provided there is an absence of friction on that surface.

The full function of mastication would seem to be one of the most effectual natural processes in limiting the deposition of salivary calculus, it being plainly evident to an observant operator the moment he looks into a mouth where mastication is confined to one side. It will invariably be found that the teeth on the unused side will present an altogether neglected appearance, and if there is a predisposition to the formation of calculus they will be almost completely covered with it, even over the occlusal surfaces. A striking object-lesson may be given patients as to the necessity of keeping the teeth in active and uniform service by calling attention to the difference in appearance of the teeth on the two sides, and impressing them with the fact that wherever, for any reason, thorough mastication is impracticable the deficiency should be supplied by substituting artificial friction with the tooth-brush. The demand for friction relates as well to the gums as to the teeth, it being very exceptional to find a healthy condition of the gums in any locality not subjected to full functional use.

This question of giving the teeth and gums adequate employment should be carefully studied by operators, and its necessity forced upon the attention of patients. It is the keynote of health in the mouth, as elsewhere in the human body, and it should be the prime function of the dentist to keep the oral tissues healthy. It is infinitely a higher aim to prevent disease than to cure it, and if dentists take this matter seriously at heart they can accomplish much in this direction. A critical study should be made of the conditions present in every mouth coming under the operator's attention, and a careful note made of the various landmarks of neglect. The results of this neglect must invariably be pointed out to the patient, and an impression made in such a manner that it cannot be ignored. If the dentist thereby fails to enlist the

co-operation of his patient, it is only common justice to at once absolve himself from responsibility for the ultimate saving of the teeth. This will usually bring the patient to a proper realization of the true relation existing between operator and patient, and will at least establish an intelligent understanding between them.

In character salivary calculus may vary from a soft granular mass, easily removed and disintegrated with an instrument, to a hard, dense, and almost flint-like consistence. This difference in density relates chiefly to the rapidity with which it is formed and the length of time it is allowed to remain in the mouth. When it is rapidly deposited and of recent formation it is comparatively soft, but seems to grow progressively harder if left undisturbed. The color also varies materially in different specimens, from a yellowish gray to a black, the former usually being associated with rapid and recent formations, while the latter is ordinarily confined to cases of long standing. In some mouths the yellowish gray remains almost indefinitely, so that the question of color is not entirely one of age; and yet in specimens of extensive accumulation, such as those illustrated, it will usually be found that the portion nearest the tooth, and which accordingly has been longest in place, is much darker than that more recently formed upon the surface.

The present reference to color relates to a staining of the calculus itself, and not to a surface deposit of black such as is commonly found in the mouths of smokers. The latter is a characteristic jet black discoloration, unmistakably from tobacco smoke, while the former is less intensely black, with sometimes a greenish tinge,—especially where it has been long in contact with the gum,—and its source is not so apparent.

Serumal Calculus.

This deposit is distinguishable from salivary calculus in several particulars, but chiefly in its initial point of location on the tooth. Salivary calculus finds its lodgment on that portion of the tooth which is bathed in saliva, and therefore becomes adherent to the crown or neck of the tooth, the part not covered by the gum.

It may advance and force the gum and adjacent tissues back so as to follow the root to the apex, as in Fig. 1; and yet it begins not under the gum, but crownwise of it. Serumal calculus, on the contrary, attaches itself to the root of the tooth, or to that portion of the neck which is covered by the gum. The source of this deposit is therefore different from salivary calculus, and, as its name implies, it is supposed to be from the serum of the blood. In fact, it has sometimes on this account been termed *sanguinary calculus*, though it would appear that there are certain formations of this deposit which cannot well be considered as coming directly from the blood. In chronic alveolar abscess we often find upon the apex of a root which has been for some time constantly bathed

FIG. 4.

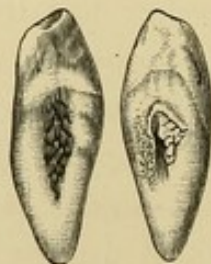
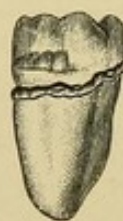

FIG. 5.



in pus the characteristic serumal deposit. But it at least may safely be stated that serumal calculus is a deposit from the fluids which surround the root of the tooth, while salivary calculus is deposited from the fluids in contact with the crown.

Another point of distinction between the two is found in the relative bulk of the deposit. Salivary calculus, as we have seen, may assume extensive proportions, while serumal calculus, on account of its environment, is restricted in growth, and is usually found in the form of small nodules, narrow bands, or thin scales (Figs. 4 and 5). These are ordinarily attached quite firmly to the surface of the root, and require considerable force to dislodge them. It is probable that the irritation produced by serumal calculus under the gums is accountable for many of the diseases to be found in the surrounding tissues, and which frequently lead to loss of the teeth, it being impossible to conceive of gums remaining healthy with any considerable deposit of serumal calculus under them.

The color of serumal calculus is usually darker than that of salivary calculus, and quite commonly has a greenish tinge running through it. It is also dense in structure, and is probably formed more slowly than salivary calculus. It may be found in some instances deposited in a thin scale along the side of the root where the peridental membrane has been lost, or it may occur as small nodules, particularly at the apex of a root, as the result of chronic alveolar abscess. In other cases, where the attachment of the peridental membrane to the root seems perfect from the apex to near the alveolar border, but where the free margin of the gum is congested and puffed, a narrow band of calculus may be found encircling the neck of the tooth in its entire circumference just under the gum. This is sometimes so near the margin of the gum that it may readily be seen by forcing the gum back with a pledget of cotton. In any pocket formed between the gum and the root as the result of the loss of that portion of the peridental membrane, we may ordinarily expect to find more or less of a deposit of serumal calculus, and we need not hope to see the gum-tissue overlying this become healthy so long as the deposit is allowed to remain.

Stains on the Teeth.

These may present themselves in varying degrees of extent and intensity, and in varying shades of color. The one claiming most attention from the profession in the past is *green stain*, which seems to occur with the greatest frequency on upper incisors in young patients. It may also be found in certain instances coating the entire buccal and labial surfaces of all of the teeth in adults, though this is comparatively rare. It would appear strange that so much prominence had been given green stain to the almost complete ignoring of the other varieties. In point of frequency the brownish stains are more prevalent, and they are found occurring at all ages and upon any of the surfaces of the teeth not subjected to considerable friction.

All of the stains seem to form with the greatest intensity near the gum-margin, and gradually shade away toward the occlusal surface, though in some instances they constitute a more or less

well-defined concentric band near the gingival line, following the curvature of the gum, and including the lingual as well as the labial surfaces. There is a wide variation in the degree of tenacity with which these stains adhere to the surfaces of the teeth; in some instances the slightest friction being all that is necessary to remove them completely, while in others they seem almost part and parcel of the enamel itself. The green stains are usually more adherent than the brown, and in cases of great intensity of stain the surface of the enamel seems disintegrated and roughened after its removal. The indications in every instance are for the perfect polishing away of all such stains upon the teeth, the fact of their unsightliness being an all-sufficient reason for such a procedure outside of the somewhat undetermined point as to their possible deleterious effect upon the enamel.

The origin of these stains seems not yet definitely settled. Various writers have advanced different theories upon the subject, probably the most noteworthy of which is that of Professor W. D. Miller in the *Dental Cosmos*, April, 1894. His conclusions seem to lead to the inference that the different stains are caused by different agencies, and that no one theory will account for all cases. In the light of the diversity of opinion expressed by writers upon this subject, it would appear unprofitable to consider it in detail at this time.

Another variety of discoloration upon the teeth may be mentioned as being distinct from the green and brown stains, and of a character entirely peculiar to itself. This is the black deposit caused by tobacco smoke. It may be found adherent to the teeth of smokers much the same as the other stains, except that it is more prevalent on the lingual surfaces, and it has more appreciable bulk. It may be scraped away with instruments, leaving the enamel apparently unaffected under it; but it does not accumulate like salivary calculus, so as to impinge upon the gum or cause irritation to the surrounding parts. In instances of the long-continued use of tobacco the structure of the teeth themselves may become so stained as to permanently remain so, particularly where the enamel is gone and the dentine exposed to the smoke.

REMOVAL OF DEPOSITS.

Removal of Salivary Calculus.

There are two principal plans of manipulative procedure for the removal of salivary calculus, the push-cut method and the draw-cut method, each having different forms of instruments adapted to its use. By the push-cut method the blade of the scaler is brought to bear upon the calculus at the point nearest the occlusal surface of the tooth, and the mass dislodged by forcing the scaler between the calculus and the enamel in the direction of the root. By the draw-cut method the scaler is placed rootwise of the deposit, and force applied by pulling toward the occlusal surface. Each method has its advocates in the profession, and each is applicable to certain conditions, the best practice probably being to use them interchangeably, as circumstances suggest. The limitations of the draw-cut method relate to the fact that to force an instrument of sufficient size for the removal of salivary calculus far enough rootwise to seize the deposit frequently involves considerable impingement on the gum, with consequent laceration; while by the skillful use of the push-cut instrument the deposit may often be forced away without touching the gum at all. On the other hand, the push-cut method invites a certain danger which is never present with the draw-cut. The application of force directly toward the gum carries with it the constant possibility of the instrument slipping and wounding the gum, while a slip of the draw-cut instrument is comparatively harmless. The element of apprehension on the part of the patient when the push-cut is being used is sometimes a menace which invites accidents from the patient flinching on the application of force, thus causing the instrument to glide into the gum. To avoid accidents of this nature, and to carry assurance to the mind of the patient, it is always necessary before applying any force with the scaler to so guard the hand of the operator against undue movement that the instrument, in case it does slip, will not be carried into the gum. This can be done by bracing the unused fingers—the ones not grasping the scaler—firmly against the occlusal surfaces of the teeth before applying

the scaler to the deposit. By this means a perfect control may be maintained over the instrument, and a sense of security imparted to the patient which usually results in a reasonable degree of confidence during the operation. This matter of creating confidence on the part of the patient is an important element in conducting a successful practice in all lines of procedure, and the operator should study the manipulation of instruments to this end. The cardinal principles in operating should be precision of methods, firmness of control, and delicacy of execution. Patients are more susceptible to impressions made upon them through manipulative procedure than the average operator would seem to conceive of. They are quick to recognize superior skill in an operator by reason of his mastery of instruments and the apparent intelligence with which he approaches his work, and there are few operations in dentistry calling for a more diversified order of skill than the successful removal of calculus from the teeth.

The cases are so varied in their nature, both as regards the extent and location of the deposit and also the character of the teeth and their position in the arch, that it may almost be said that each case constitutes a law unto itself, and must be approached in accordance with its individual requirements. And yet it would seem desirable to formulate so far as possible definite rules of procedure in this as in all other operations on the teeth, though the fact must constantly be borne in mind that in any formulation of this nature the element of personal equation must necessarily enter conspicuously into it and largely influence its details. No two men need be expected to approach this work in precisely the same way, though each should at least study out some systematic order of procedure for his own guidance, so as to accomplish the result in an orderly sequence, rather than by haphazard and slipshod methods. Lack of system in the performance of our work has been one of our chief limitations as operators, and it is accountable for a grievous waste of time both to practitioner and patient.

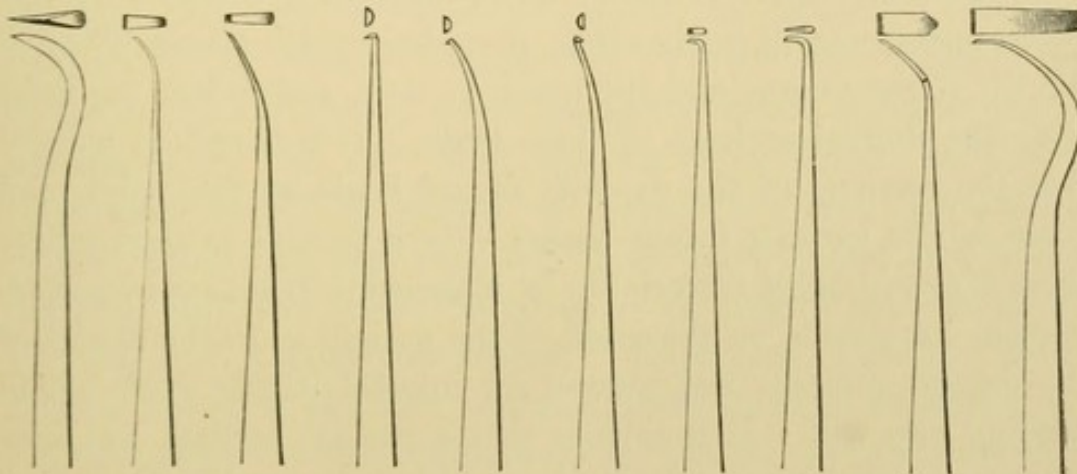
The methods here suggested are not applicable to all cases, nor will they probably appeal to all operators; but it is confidently hoped that they may at least prove helpful to those who in the

past have not thought it necessary to employ any particular method in these operations.

Instruments for the Removal of Calculus.

The instruments here illustrated are largely adaptations from or modifications of the forms long since introduced to the profession by various operators. Fig. 6 is a somewhat sickle-shaped contra-angle instrument, having three sides for cutting. It may therefore be used interchangeably as a push-cut or draw-cut instrument, though the sharpest or most acute edge being along the extremity of the instrument gives it greater efficiency as a push-

FIG. 6. FIG. 7. FIG. 8. FIG. 9. FIG. 10. FIG. 11. FIG. 12. FIG. 13. FIG. 14. FIG. 15.



cut than as a draw-cut. Its uses will be indicated hereafter. Fig. 7 is an ordinary direct push-cut scaler, with the curvature somewhat nearer the cutting-edge than usual; while Fig. 8 is a long, slender, delicate instrument for reaching places inaccessible to Fig. 7. Figs. 9, 10, and 11, designed by Dr. A. G. Johnson, are hooked instruments of varying forms for draw-cut work along the roots of teeth in pockets under the gum. The distinguishing feature between these and the instruments generally suggested for this purpose relates to the reverse side of the scaler. Ordinarily the back of the scaler—the side coming in contact with the gum in passing between it and the root—is left with sharp angles and corners, which inflict unnecessary discomfort on the patient by lacerating the gum. In the ones here shown these angles are

rounded off, so as to leave a smooth back to the instrument, which may be insinuated under the gum and along the root without serious disturbance to the patient. Fig. 12 is merely a short-bladed hoe excavator, while Fig. 13 is a delicate hatchet excavator, the uses for which will be considered later. Fig. 14 is a curved wide push-cut scaler for passing over the surfaces of teeth where the bulk of the deposit has already been removed, and scraping off any small particles that may have been left. Fig. 15 is a long-reach push-cut scaler for approaching localities in special cases inaccessible to the ordinary instruments.

Technique of the Operation.

In the examination for calculus on the teeth probably nine out of ten operators will instinctively place the mouth-mirror between the tip of the tongue and the lower incisors, and reflect the light upon the lingual surfaces of these teeth. It is therefore natural that the removal of the deposits should begin at this point, and there is also another minor reason why it is well to start where there is considerable material to be removed. It makes an instantaneous impression on the mind of the patient as to the extent of the deposit present, and arouses an interest in the work which nothing else will. It is seldom that a patient realizes just how much calculus there is upon the teeth, due to its gradual formation and the fact that the tongue becomes accustomed to its presence. But if, on the first introduction of the scaler, several large pieces are flaked off and allowed to fall into the floor of the mouth, the patient is startled into a realization of what has been going on, and is impressed with the importance of proper attention to the matter in the future. The same impression never seems possible later on in the operation if the large masses are left till the last.

For the removal of salivary calculus from the lingual surfaces of the lower incisors in ordinary cases the scaler illustrated in Fig. 6 is admirably adapted. (It need not here be urged that all scalers should be keenly sharp in whatever location they are used.) With the mouth-mirror in the left hand, and held in such a position that the tongue is kept well away from the lower incisors and

the light thrown upon the deposit, the first movement of the operating hand should be to firmly brace the end of the third finger against the occlusal surfaces of the adjacent teeth in such a manner that the patient must at once realize that the operator has complete control of the instrument against slipping. This accomplished, rapid work is possible. A push-cut should be used along the disto-lingual surface of the right lower lateral, and the deposit dislodged. Immediately this is done the point of the instrument should be turned rootwise of the deposit on the mesio-lingual surface of the same tooth, and a draw-cut given to flake it off along that surface. Thus with two movements, one downward and the other upward, the large bulk of calculus from that tooth has been dislodged in the most expeditious manner. The same plan should be followed successively with the other teeth in line as far as the left cuspid, when the sickle-shaped scaler should be exchanged for Fig. 14. With this the entire lingual surfaces of these teeth should be scraped to remove any small particles of deposit which may have been left by the other scaler, and, following this, attention should be given to the lingual surfaces of the left lower bicuspids and molars. Beginning with the mesio-lingual aspect of the first bicuspid, these surfaces should be followed in regular order to the distal surface of the left lower third molar, the instruments usually best adapted for this work being either the hoe or hatchet forms, Figs. 12 and 13. The lingual surfaces of all of the lower teeth to the left of the right cuspid have now been covered. To reach the lingual surfaces of the right cuspid and the teeth posterior to it the operator should step slightly forward and face his patient, so as to look along these teeth. Then, with the hatchet instrument held in the palm and the thumb braced against the teeth, the deposit may be lifted from the necks very expeditiously.

After the lingual surfaces are attended to the buccal and labial surfaces may ordinarily be reached with the hatchet instrument, using the pen grasp for the right side of the mouth as far forward as the cuspid, and then changing to the palm grasp for all the teeth to the left of that. These surfaces should be followed suc-

cessively from one third molar to the other. As the deposit is being lifted from the labial aspect of the lower incisors, care should be taken that the pieces of calculus do not fly into the operator's eyes. The force is necessarily exerted directly toward the operator, and the particles sometimes snap off with considerable momentum, so that accidents of this nature are not uncommon.

When large masses of calculus are found on any of these surfaces, it may be removed with the push-cut instruments, Figs. 7 or 14. In cases of great recession of the gum and extensive deposits along the exposed portion of the roots, particularly if the teeth lean in toward the tongue, so that they stand obliquely in the arch and are very long, the lingual surfaces can only be reached to good advantage with an instrument like Fig. 15. In using this on the lower incisors or right cuspid, bicuspid, or molars it will be found better to pass to the left side of the patient and throw the light down into this secluded locality with the mouth-mirror in the left hand. The right hand, grasping the scaler, may pass around the patient's head to the right angle of the mouth, so that the end of the third finger rests on the occlusal surfaces of the teeth in the region of the right lower cuspid or first bicuspid. Braced in this way, effective push-cutting may be done without impingement on the gum.

When the deposits have been thoroughly removed from the buccal, labial, and lingual surfaces there remain only the proximal surfaces to claim attention. For this work where there has been a recession of the gums, and the deposit is accordingly of a salivary formation, the push-cut method of removal is by far the more effective. The chair should be raised so as to bring the patient's lower teeth well opposite the operator, and a direct push-cut exerted from labial or buccal to lingual across the proximal surfaces. For this work the scaler Fig. 7 is mostly serviceable, though in some cases Fig. 8, having a longer reach and a more delicate form, is applicable. There are certain instances where this method of push-cutting from labial to lingual on the lower incisors is indicated at the very outset of the operation, before any

attempt is made to use the scaler Fig. 6. This is where there has been much recession of the gums and the interproximal spaces are wide and filled with calculus, and the lingual aspect of the deposit presents a solid phalanx of incrustation, with only the merest line to show the demarkation between the different teeth. If a case of this kind is approached from the labial aspect and the push-cut scaler Fig. 7 is forced between the teeth along the proximal surfaces toward the lingual, the large masses of calculus may be tumbled off into the mouth with astonishing ease and rapidity.

The operator should study the various means of attacking these deposits, to the end that he may approach the work in the different phases of the deposit and be able to meet each case in the most expeditious manner.

In removing salivary calculus from the upper teeth the operator may start at the buccal surface of either third molar. The work may be done with push-cut scalers if the deposit is bulky, or with the hatchet and hoe forms if it consists only of a narrow ring near the gum. For the proximal surfaces of these teeth the hatchet form seems best adapted, there being less facility for employing the ordinary push-cut instruments than with the lower teeth. It is seldom that salivary calculus is found on the lingual surfaces of the upper teeth, but whenever it does occur it can best be removed with the hoe form, Fig. 12.

Removal of Serumal Calculus.

This operation is one really requiring the utmost delicacy of touch and the highest degree of digital perception. All of the work is done under cover of the gum, where the operator cannot see, and consequently the sense of feeling is the only guide. This sense must be highly developed if the operator expects to attain anything like success in this work. He must be able to distinguish accurately by the impressions conveyed to him through contact of the instrument with the root of the tooth whether he is touching calculus or cementum; and he must do this not by reason of the bulk of the deposit, but from the nature of its density. There is a decided difference in the character of the two substances, and

the practiced operator can make a sharp distinction between them. The necessity for this lies in the fact that in many instances the formation is limited to the thinnest possible scale along the side of the root, sometimes resting in a concavity, so that there is no appreciable elevation of the deposit over the surface of the root. In such cases the instrument must be gently raked over the surface, and the line of demarkation detected between the deposit and the cementum. This may be done by carefully noting the difference in the effect upon the blade of the instrument when encountering the two materials, cementum and calculus. In passing over cementum a sharp instrument will readily peel up the tissue and scrape it off, much as one may scrape a bit of bone. It has a dead, comparatively soft consistence, so that the scaler "bites" into it readily. With serumal calculus the case is different. The scaler encounters a hard, flint-like substance, which gives a decided resistance to the instrument, and which cannot be scraped to lessen its bulk. It must be dislodged *en masse* or not at all. By cautiously feeling along the root the expert operator is thus enabled to detect the slightest flake of calculus and to remove it.

The instruments best adapted for this delicate kind of work are the hooked forms, Figs. 9, 10, and 11. They may be insinuated up under the gum into a pocket alongside the root, and thus scrape it free from deposits with a draw-cut. The straight form, Fig. 9, will be found serviceable for most of the work, though occasional cases on posterior teeth call for the curved forms, 10 and 11. Fig. 10 may be used on the distal surfaces of molar and bicuspid roots, while Fig. 11 will best reach the mesial surfaces of such teeth. The greatest patience and perseverance are necessary for the thorough removal of this thin scale-like deposit, but no operator does his full duty to his patient when he allows it to remain.

There is another variety of deposit coming under the head of serumal which is distinct from the scale-like form, and is frequently met in cases where there is no appreciable pocket. This is a narrow ring encircling the root just under the free margin of the gum, dark in color, dense in structure, and well defined in

outline. The only indication of its presence is a slightly puffed and congested condition of the gum lying over it, and in some instances even this is not very apparent until the deposit assumes appreciable size. It cannot be seen by the operator without pressing the gum back from the neck of the tooth, but it may be felt with a fine explorer. It is often present on the proximal surfaces without forming on the others, and it seems to work its greatest injury between the teeth. If allowed to go unchecked it results in a detachment of the gum from the root in the interproximal space, and a general impairment and puffing of the gum-festoons.

The removal of this band of calculus is usually best accomplished on the lower jaw by delicate push-cut scalers, and the work is greatly facilitated if the operator will pack the interproximal spaces in advance with small pellets of cotton to force back the gum, so as to expose the deposit. The cotton requires to be in only a few minutes, and on its removal the scaler must be conveniently at hand in order to accomplish the work before the gum creeps back over the deposit. A ready method of procedure is to force cotton into two or three spaces and keep that number in advance of the operation, so that by the time each space is reached the gum will be well out of the way. In this manner the calculus can ordinarily be seen distinctly, and removed more expeditiously than if it were all done solely by the sense of touch. For the upper teeth the delicate hatchet excavator will usually be indicated in place of the push-cut instruments, and in some localities, particularly along the lingual surfaces, the hoe form will be most effective.

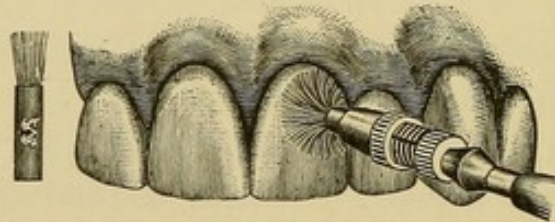
The surfaces of all roots where serumal calculus has found attachment should be very carefully scraped and left smooth, so that the gum may resume its normal position and tonicity. If small particles of the deposit are overlooked and allowed to remain they not only irritate the gum, but they invite the redeposition of fresh calculus so that the relief is only temporary. The gum need not be expected to become healthy where any appreciable particles of the deposit are left, and in a week or two

after the operation for removal it is frequently possible to locate the precise points at which flakes of calculus have been overlooked, on account of the appearance of the gums at these places. If a purplish or congested condition of the gum persists at certain points, it may be taken as an almost infallible indication that a bit of serumal calculus is lying under it. These facts are eloquent object-lessons as to the necessity for constant vigilance in keeping the teeth free from deposits.

Removal of Stains from the Teeth.

After salivary calculus has been removed with instruments, it will usually be found that the surfaces formerly covered by the deposit are left somewhat roughened and in need of polishing to

FIG. 16.



prevent a ready attachment of fresh calculus, while the surfaces extending from the point of deposit are ordinarily more or less stained and unsightly. To complete the operation as it should be, and also to remove stains from the teeth where there has been no salivary calculus, it is necessary to so polish the surfaces of the teeth by friction that the enamel will assume a white and glistening appearance.

This is best accomplished by rotary appliances in the engine in the form of brushes, rubber cones, or moose-hide points carrying pulverized pumice. Probably the most effective method in ordinary cases is to use the small polishing brushes made for the purpose, Fig. 16, though there are occasionally places where the cones or points may reach to better advantage. The brushes should invariably be of the stiffer variety, on account of the tendency to soften from the moisture after a few revolutions on the tooth. If the brush becomes soft it is useless.

The manner of using the brush is to place its end against the surface to be polished, and as the engine revolves to cause gentle pressure. The degree of pressure will determine the area of enamel to be covered by the brush from the spreading of the bristles, Fig. 16, and in this way the brush may be made to conform accurately to the curvature of the gum, and thus polish the enamel close to the gingival line without lacerating the gum or irritating it. All of the exposed surfaces of the teeth should be included in the polishing till the last vestige of stain is removed, except in those cases where the tooth-tissue itself is discolored from tobacco or other causes. This, of course, cannot be polished off, though even a tooth in this condition should be made as smooth on the surface as possible by friction of the brush.

In moistening the pumice for the removal of stains it is well to use some other liquid than water. Miller found that the peroxide of hydrogen had a solvent effect on green stain, and it is an admirable cleansing agent in a general way. While the main reliance in the removal of these stains should be the mechanical friction of the pumice, yet there would seem to be no objection to employing adjuncts in the form of liquids having an antiseptic or disinfectant, as well as a solvent, action such as this. In cases of highly congested gums, where the slightest contact of the brush causes profuse bleeding, it may be well to use with the pumice some one of the astringent mouth-washes on the market whose formulæ are published and known to the operator. It is also a relief to the patient after a sitting for the removal of calculus, where there has necessarily been considerable wounding of the gums, to add some of this wash to the water used for rinsing the mouth. In every case where pumice has been employed the teeth and gums should be thoroughly syringed with tepid solutions to remove as perfectly as possible all traces of the pumice, which is insoluble in the mouth, and which should not be left lodging in any quantity around the gum-margins.

Two items bearing on the hygiene of this operation must be mentioned; not because they are not patent to every conscientious and observant operator, but because there seems to be much laxity

in these minor details on the part of some in the profession. No polishing brush should ever be used under any possible circumstance in more than one mouth. They are made in such quantities by the manufacturers, and are so inexpensive, that there is no manner of excuse for so gross a violation of personal and professional refinement. Outside of the question of conveying infection, the idea must be sufficiently revolting to make more than a mere mention of it unnecessary. The moment a set of teeth is polished the brush used should at once be discarded, and a fresh one placed in the mandrel, which itself should be cleaned each time it is used. The other item relates to mixing the pumice. The same mix should not be made to do service for more than one individual. A convenient quantity should be prepared in a small glass or porcelain dish for each patient, and the dish thoroughly cleaned after using. These simple precautions are not only demanded on the basis of professional integrity, but they are really remunerative in the way of inviting patronage of the most desirable kind. Patients are more observant of these matters than is generally supposed, and they are usually appreciative of every effort which insures to them cleanliness and protection.

Instructions to Patients as to the Care of the Teeth.

The dentist has done much less than his whole duty if he contents himself with the mere performance of the operation of cleaning the teeth, and fails to so instruct his patient that they may thereafter be kept clean. Comparatively few individuals really know how best to care for the teeth, and it should be the office of the dentist to so educate those coming under his charge that the result will be a more general enlightenment on this important subject. An opportune moment for making an appreciable impression is just at the conclusion of a sitting for the removal of calculus and stain, when the patient's mind will most likely be in a receptive mood on the subject.

The technique of brushing the teeth should be explained so that the patient may learn how to reach all of the surfaces with the brush, and to impart the requisite friction to the gums and

teeth without doing injury. The ill-advised cross-brushing of teeth with gritty powders has undoubtedly done much harm in wearing the enamel and in forcing the gum away from the necks of the teeth, so as to admit of a groove being cut by the brush just rootwise of the enamel. Cross-brushing is not entirely unavoidable in a thorough cleansing of the teeth, nor is it at all injurious if used with judgment, but the patient should be taught the danger of an indiscriminate sawing against the necks of the teeth with a stiff brush loaded with a gritty powder or paste. The general plan of brushing the teeth should be to produce a sort of rotary movement with the brush, so as to bring the bristles against the lower gums and teeth on the upward motion and against the upper ones on the downward motion. This cannot be done with anything like precision on all of the teeth, but it should be the general aim with the idea ever in mind that the gums require friction as well as the teeth, and that they must be brushed against the necks of the teeth instead of away from them. In cases where the patient complains that the gums are too sensitive to admit of proper brushing of the teeth, they should be subjected to a thorough system of massage with the fingers three or four times a day till they become sufficiently hard to comfortably tolerate any ordinary brushing.

As to the frequency with which teeth must be brushed by the patient to keep them well cleaned, no definite rule can be given on account of the variation in the different mouths. In one individual the teeth may be kept in admirable condition with one-half the care that would be necessary for another, and even in the same individual there is considerable variation at different periods in the tendency to the accumulation of deposits. Patients must therefore be requested to study the matter on their own behalf till they learn with some degree of accuracy just how much care is necessary to keep the teeth bright and clean.

The use of floss for passing between the teeth and removing any particles which may be found lodging where the brush will not reach is an admirable practice, provided the patient will use it judiciously and without working injury to the gum. The great

danger, as used by most individuals, lies in the fact that in passing it between the teeth it is inclined to snap as it passes the contact points and come down forcibly upon the festoon of gum. This may in time injure the gum and force it back in the interproximal space, leaving the space imperfectly filled with tissue. Whenever floss is used it should be most carefully guarded as it is passing the contact points and prevented from impinging on the gum, and unless the patient can gain control of it in this way it had better not be used.

One feature in the care of the teeth by the patient must not be overlooked. This relates to the use of toothpicks, which, if properly employed and of suitable form, may be used to advantage for the dislodgment of certain kinds of food-material from between the teeth, but which if used as they too commonly are may result in great injury to the gums. The large blunt wooden toothpicks so extensively provided for the patrons of public eating-houses are especially calculated to work irreparable injury if persisted in. Outside of the rough nature of the wood and the sharp corners and blunt ends, all of which tend to irritate the gums, the very bulk of the pick is such as to finally force all of the gum out of the interproximal space and furnish a receptacle between the teeth for the constant collection of food. Dentists should invariably discourage the use of such destructive agents as these. Whenever a toothpick is indicated at all, it should be of the very thinnest, smoothest, and most flexible nature. Probably the best toothpick is the quill, which can be scraped with a knife to any degree of fineness and pliability. The constant habit of picking the teeth, as a habit, should be discouraged, and the custom limited to the mere removal of particles of food which may find lodgment between the teeth.

CHAPTER II.

DENTAL CARIES.

It is scarcely within the province of this work to enter minutely into the etiology of dental caries, and yet a few observations bearing on the subject from an operative point of view would seem to be eminently in order. Dental caries has been accounted one of the most prevalent of all human diseases, and one of the most persistent through life, in view of which it would appear on the face of it a very discouraging task to attempt to combat this affection. In fact, there are many men in the profession who apparently give themselves over very easily to this idea, and consign the natural teeth to the grasp of the forceps with a resignation which borders closely on an assumption of the inevitable. This ready yielding on their part has its influence on the patient, and an unfortunate impression is thus allowed to go out to the effect that in many cases it is quite impossible to save the teeth, and therefore waste energy to make the attempt. This teaching is wrong in the highest degree, and the profession has much to answer for if it fails to inform itself in the most intimate manner on the true relation of this disease to the human economy, and on the best means of securing its control.

A close study of the manifestations of dental caries will reveal the fact that while it may be considered a very persistent disease, it is seldom the case that it is continuously so either in relation to its initial appearance or the degree of its severity. Some of the most discouraging cases that come under the attention of the practitioner will be found, if carefully studied, to experience periods of immunity from attack, during which the process of decay seems for the time suspended. In fact, it is the exception, rather than the rule, for teeth to go progressively to destruction from caries one after the other till every tooth is lost without intervals of practical cessation of activity on the part of the micro-organisms which bring about decay, even where no attempt is made to combat

the disease. Cases are frequently noted where a number of teeth in a mouth have been lost through caries while the remaining teeth present themselves years afterward practically free from caries, the disease seemingly becoming limited with the loss of the teeth that are missing. It might be thought in such cases that there was something in the structure of the remaining teeth which accounted for their escape were it not for the fact that these same teeth may at a subsequent period, without any appreciable provocation, take on an active attack of caries and require the closest attention to save them.

In a broad view of the whole question of the susceptibility to or immunity from caries, it seems to resolve itself down to the fact that in some mouths the conditions are such that the micro-organism of caries cannot work effectively upon the teeth, while in others they are favorable to its most active influence, and that in the same mouth there are periods when the conditions favor the work of the micro-organism and others when they interfere with its action. Just what these conditions are the profession at present do not seem to be able to determine, but the recent investigations of Dr. J. Leon Williams would appear to promise an encouraging step toward the solution of the problem. Professor W. D. Miller had demonstrated some years ago that caries was brought about by the action of an acid produced as the result of micro-organic growth in the mouth, and Dr. G. V. Black called attention to the fact that this acid must be formed and allowed to act immediately at the point where the decay was to begin. (In fact, Robertson, in 1828, indicated that the carious process was the result of some influence acting directly on the enamel at certain points where the cavities were to occur, his idea being that this influence was due to "decomposition.") It was therefore seen that the old and somewhat prevalent idea that the reaction of the saliva had something to do with the progress of caries must be abandoned, so far, at least, as any direct action on the tooth-tissue was concerned. It remained to be determined how any requisite number of micro-organisms could remain stationary on certain unsheltered surfaces of the teeth where decay was seen to occur for a sufficient time to form their

acid and dissolve the enamel without being washed away by the fluids of the mouth.

It is found in the cultivation of micro-organisms that there are certain forms which in the progress of their development form a substance allied in physical appearance to gelatin, and are therefore called gelatin-forming micro-organisms. It is to this class that the micro-organisms of caries belong, and, in pursuance of their function, they produce on the surface of the tooth a gelatinous film, under cover of which they are enabled to work their destructive processes undisturbed. This film is sufficiently adherent to the tooth to withstand the ordinary rinsing of fluids in the mouth, and thus we see decay taking place in positions where the micro-organism itself would be washed away if left unprotected. But the film may be broken up and detached by any appreciable amount of friction, such, for instance, as the friction of food in mastication, where that process is exercised to its fullest functional activity. Accordingly, we may look for the greatest ravages of decay in surfaces of the teeth not subject to the friction of food, as the proximal surfaces, or in sheltered localities formed by developmental defects, as in the fissures or pits where the micro-organisms may work unmolested.

The legitimate office of the tooth-brush, the dental floss, or the toothpick may be more intelligently comprehended when the character and significance of this gelatinous film is understood. If that film can be kept from the teeth it would seem that we have small need for worry over the problem of controlling dental caries, and in this connection our advice to patients as to the proper time to brush the teeth should be governed largely by a recognition of the facility with which this film may form under favorable conditions. If we find a mouth where decay is progressing rapidly, showing active work on the part of the micro-organisms, we should advise frequent attention to the teeth, so as to interfere as largely as possible with the formation of these films. Brushing the teeth three times a day under these conditions will not be too much, but the time of all others when it would seem necessary to go over every surface carefully with brush, pick, or floss is just before re-

tiring, when the fluids of the mouth are to remain quiet for the greatest length of time in the twenty-four hours, and the micro-organisms are given the best opportunity for work.

Dr. Williams's notable achievement in clearing up this subject of the *modus operandi* of dental decay relates to the fact that he succeeded in grinding sections of the teeth sufficiently thin for microscopical examination, and at the same time retaining in place this gelatinous film with its nest of micro-organisms thereby glued to the enamel, and showing plainly the action of the acid upon the tooth-tissue. This was the missing link which changed conjecture into certainty, and developed one of the most significant factors in the institution of dental caries. It would from this demonstration seem necessary for this film to form in order to have caries begin as we usually find it, and therefore any influence which tends to prevent its formation would to that extent act as a prophylactic.

As has been intimated, cleanliness of the teeth may be considered an important adjunct in checking the inroads of the micro-organisms, but unless it is faithfully pursued, and the cleansing of sufficient frequency, it will not be found wholly effective in preventing caries in mouths where the tendency to its development is favorable. It is a question of hours instead of days when these micro-organisms can form gelatin and produce acid, and a mouth may be cleansed as perfectly as possible once in twenty-four hours and yet give the micro-organisms ample time to act in the intervals, provided the conditions are suitable to their progress.

This question of condition is the keynote of immunity or susceptibility, and, with our present knowledge, it would seem that the influence of the fluids of the mouth on the formation or dissolution of this micro-organic film has more to do with the advance or retardation of dental caries than any other single factor. If in a certain mouth the conditions are such that the micro-organisms are unable to form their film, and thereby afford themselves protection in the progress of their work, we may be hopeful that the ravages of decay in that mouth will not be serious; but if, on the contrary, the conditions seem to favor the formation of these films, we must consider such a case susceptible.

It was formerly the prevalent idea in the profession that the structure of the teeth had much to do with the liability to decay; that teeth which were found to be extensively attacked must be considered of poor structure, while those practically free from caries were accordingly accounted as being of good structure. The investigations of Dr. Black into the physical character of the teeth proved that this position was untenable; that there was really much less variation in the structure of the teeth than had been supposed, and that what little difference did exist seemed to have almost no relation to the liability to decay. It simply resolved itself down to a question of environment. If teeth decayed rapidly in a mouth it was because the conditions in that mouth were favorable to the agencies which bring about decay, and not because the teeth were necessarily of poor structure; and it is confidently believed that along this line of investigation lies the only hope of the profession toward the solution of the problem of preventing dental caries. If by any means we are eventually able to bring about such a condition in the mouth that the micro-organism of decay cannot therein find a suitable habitat for the full performance of its acid-producing function, or rather if we can so medicate the mouth that it will be found impossible for the micro-organism to form its gelatinous film in contact with the tooth, we can to that extent control decay. Either one of two things seems necessary: that we create a condition inimicable to the formation of the film, or that we provide a solvent which is capable of dissipating it as fast as it forms. In order to do this we must first learn more of the nature of this film and the conditions suitable to its growth, and it is in this relation that future study should be directed.

That conditions exist in the mouth which influence this matter for good or ill is clearly evident from a clinical study of cases. We find that there is in the same individual a great variation at different periods in the tendency to caries, and since we have learned that the tooth-tissue is not so fluctuating in its character, and does not grow hard and soft so readily as was formerly supposed, we must look to changes in the conditions surrounding the teeth to account for the varying manifestations of the disease.

A close study of cases in practice will reveal some rather marked instances of periodical susceptibility and immunity, and the history of these cases will often prove not only of the greatest value, but also a source of the utmost satisfaction and encouragement. The recital at this point of a single case from practice may serve to indicate the common run of such clinical histories where the disease is followed up vigorously by the dentist. This case seemed a desperate one, a case in which, under ordinary circumstances, many of the teeth would probably have been lost if any half-hearted methods of treatment had been employed. And yet the final outcome was such as may be confidently expected in nine cases out of ten where the dentist is in earnest with his work and has an intelligent conception of the possibilities of an approaching immunity.

The patient was a girl of eight or nine when brought to the dentist by her parents, and the first permanent molars were already affected. From this time forward during the next six or seven years the activity of the carious process in that mouth was appalling. Teeth would decay on their journey through the gums in eruption; recurrences of caries around fillings would take place with discouraging frequency, and new cavities would spring up seemingly almost in a night. The dentist did the best he could, which he freely acknowledges was not very good, owing to the hypersensitiveness of the dentine wherever decay occurred. But an honest effort was made to fight back the intruder, and to encourage the patient to persevere in the face of the most disheartening conditions. Gold was out of the question, and resort was accordingly had to amalgam, the cements, and gutta-percha. Even then the cavities were often not well prepared, through fear that radical methods of treatment would prove too great a tax on the patient and tip the balance in the wrong direction, so that she would give up the work in despair and let the teeth go. At times during those trying years it seemed almost a hopeless case, and yet the sacrifice of losing a set of teeth which in appearance were really beautiful was too great to be thought of. The patient was instructed to report for examination every three months. Some-

times she would appear before the allotted time with the stereotyped remark, "Doctor, I am afraid there are other cavities coming." And they usually were coming. It grew to be something of a dread to have this patient's name announced, and yet she was never met with anything but the most encouraging demeanor, and the idea was constantly schooled into her that those teeth must be saved at any cost.

This kind of warfare was kept up till she was sixteen or seventeen, when a period of a year elapsed without her reporting at the office, and the natural inference was that she had finally yielded to what seemed the inevitable and was allowing the teeth to go by default. But one day she came again with a request to have her teeth examined, saying that she had experienced no trouble with them in the interval, but thought they must by this time need attention. The first glance at the teeth revealed a condition entirely different from anything that had ever been noted in that mouth before, and the dentist realized instantly that the battle had at last been won. The surfaces of the teeth were clean and bright, and the gums hard and normal. When questioned as to whether she had given the teeth particular attention since her last visit to the office, the patient said that she was not conscious of having done more than the ordinary.

Since then, now more than five years, there has been almost no necessity for dental service in that mouth, except to replace with gold the worn-out cement and gutta-percha fillings one by one as they failed. To-day the young lady has her full complement of natural teeth, without even the necessity of having had any of them crowned. The posterior teeth are most inartistically patched and plastered with amalgam, but from an anterior view this young lady would be credited by the average observer with having an exceptionally good and an exceptionally beautiful set of teeth.

Such a result as this—and the case here recorded is by no means an isolated one—should prove of the greatest possible encouragement to both operator and patient, and should stimulate the practitioner to take vigorously in hand even the most unpromising case and fight back the disease, no matter how active its ravages appear

to be. Immunity does not always develop so suddenly or so completely as in this instance; in fact, there are some patients who never seem to become immune, but in the vast majority of individuals we may confidently look for a very appreciable change in the liability to decay as age advances from childhood to middle life, provided we take stringent measures to control the difficulty. It would seem from clinical observation that the period of immunity is hastened by an active campaign against the development of caries, whereby the occurrence of large cavities is avoided and the teeth are kept comfortable for the maintenance of a full functional activity. Neglected cavities in teeth invite decay in adjacent teeth, and wherever the function of mastication is interfered with through sensitiveness the teeth in that locality are deprived of the adequate friction to keep them free from adhesive materials of a character calculated to bring about decay. The highest degree of health in the mouth, as elsewhere, is to be obtained only by the requisite exercise of all the functions, and this cannot ensue where the teeth are sensitive from decay or where they are not adequately used in mastication. A close study should be made to determine whether or not the patient masticates fully, and if it is found that this function is not properly performed the patient should be vigorously schooled into an observance of its necessity.

It is of the very greatest importance, if immunity is to be established early in life, that the most strenuous efforts be made to check the disease in its incipiency, and to keep a watchful eye over the general condition of the mouth to see that the functions are normally active. Nor must it be assumed that even where an apparent immunity has been once established the case will invariably remain permanently immune. Relapses seem as likely to occur here as in other diseases, though they are usually manifested in a different manner, and they do not necessarily follow the initial attack for some years. In the case just recorded the probability is that, even after this long period of practical immunity, if the young lady gets married and is called upon to pass through all the concomitant vicissitudes of motherhood, those treacherous

little micro-organic dogs of war will be turned loose upon her teeth once more, and there will be another contest for supremacy. Decay will commence again in a manner to discourage any practitioner who has not a well-defined idea as to the usual manifestations of periodical susceptibility and immunity, but to one who is accustomed to watching these cases there can be only one mind as to the final outcome, provided the proper course is pursued. If the case is met in a vigorous manner, and the teeth kept comfortable by checking the decay in its earliest stages, the attack will soon pass by and the teeth be saved. In some of these relapses, when the circumstances are such that the patient is unable to apply to the dentist with sufficient frequency, a pulp is occasionally lost and a tooth sometimes breaks down to the degree of requiring a crown, but this is usually the extent of the disaster, and the mouth is still maintained in full functional usefulness.

As has been intimated, it is the rarest thing to find a case where the carious process is uniformly and progressively active through life if anything like a reasonable attempt is made to check it. There are, of course, many cases where the teeth are lost one after another till all are gone, even at an early age of the patient, but these are usually cases where no adequate attempt has been made to check the disease, and where the carious process has had the most favorable opportunity to advance.

In the light of what we now know, it may be laid down as a conservative statement to say that with proper attention the teeth of most individuals may be saved through life, so far as decay is concerned, and it is confidently believed that an intelligent conception on the part of the profession of the phenomena presented by immunity and susceptibility will add materially to the possibility of such a consummation. If the operator's attention is constantly directed to the conditions surrounding the teeth, rather than falling back on the old fallacy that the tendency to decay is influenced by changes in the structure of the teeth, and thus entirely out of his reach, it will place him in a more enlightened relation to the matter, and he will be better equipped to meet the emergency and overcome it. That there is a difference in the density of teeth need

not be argued, and that there is a wide variation in the behavior of teeth under the action of cutting instruments no man of long clinical experience will attempt to deny. Some teeth may be cut and chiseled away very readily, while others appear to cut like flint, and will dull the sharpest and hardest instrument; but a close observation of these cases would seem to indicate that the difference in resisting power to instruments is confined largely to the enamel, and that this difference is due more to the variation in the arrangement of the enamel-rods than to variations in density. In some teeth the rods stand straight, regular, and parallel; in others they are wavy and exceedingly irregular in their course. It is the difference between straight-grained maple and bird's-eye maple. The axe will readily split straight-grained maple, while bird's-eye maple is stoutly resistant. It is practically the same with the different kinds of enamel. But that there is really little variation in the liability to decay of the different classes of tooth-tissue Dr. Black's investigations proved most conclusively. The hardest tooth that was ever developed, if placed in a mouth where the micro-organisms are permitted to form their gelatinous masses and produce their characteristic acid, will promptly be attacked by caries, while a tooth seemingly friable in structure will remain free from caries in a mouth where the conditions are unfavorable to such action. It thus seems to be wholly a question of environment, though it is not here intended to intimate that the denser tooth will break down as rapidly under the carious process when it has once started as will the one of less resisting structure.

That well-formed enamel is capable of being attacked is amply demonstrated by the location of many of the cavities we find in the mouth. The proximal surfaces of the teeth are probably attacked as often as any other, and at this point we do not ordinarily look for defects in the tooth-structure. There are no pits or fissures, and the enamel is laid on as perfectly as at other surfaces where decay seldom occurs. The reason we find cavities on the proximal surfaces is because of the environment, the position being sheltered and free from the friction which interferes with the micro-organisms on exposed surfaces. Then, again, we learn

many an instructive lesson in the examination of developmental defects in tooth-tissue. We ordinarily look for cavities at points where the enamel has failed in a continuity of structure, leaving pits or fissures, and in a mouth subject to caries we usually find initial decay at these points. But, on the other hand, we frequently see cases where, on account of immunity, the teeth go for a lifetime containing deep fissures entirely through the enamel without decay occurring in any of them. These are phenomena which should command the closest attention of the profession, to the end that we become familiar with all of the manifestations of dental decay and have an intelligent conception of its true nature.

If it be finally proved beyond doubt, as would at present seem to be the case, that the question of condition is the chief factor in this disease, then it devolves upon us to know what this condition is, and to treat cases scientifically to control condition. As has already been intimated, we at present know very little about this subject of condition. We cannot tell what particular elements there are in the fluids of a certain mouth tending to favor the formation of these micro-organic films, which seem to be the main instrumentality of the destructive process, nor do we know what constitutes a condition unfavorable to them. We are not even clear in our clinical observations as to surface indications which may lead us to judge whether a mouth is susceptible or immune, except as we see cavities or do not see them. And yet, even with our present knowledge, it should not be necessary, if we are truly observant, for us to see actual caries in order to know that a mouth is susceptible. There are unmistakable evidences present in some mouths which indicate the activity of the carious process to one who has closely studied the matter, and yet to attempt to describe these indications so that they will be intelligible to others seems not to be easy of accomplishment. They relate more to an intuitive perception of general conditions on the part of the observer, rather than to any definite landmarks in the mouth that may be described.

It is with this limitation clearly in mind that a few hints are herein offered for observation, with the suggestion that each practi-

tioner take up the study of this matter in his own experience till he secures an intelligent basis for judgment.

A mouth that is acutely susceptible will ordinarily present an unkempt appearance; not necessarily resulting in the presence of salivary calculus, but apparently indicating that the teeth are not well cared for. Accumulations of a soft nature may be scraped from the surfaces, as if the patient had just arisen from a meal of pasty materials and had not even rinsed the mouth. The fluids around the teeth seem to contain much thick mucus, which renders the semi-solid substances adhesive to the surfaces of the enamel, though the saliva on entering the mouth at the orifices of the ducts may appear of normal fluidity. If such a patient is handed a glass of water and asked to rinse the mouth thoroughly, it will be found that after the attempt is made the teeth are left with these glutinous accretions still clinging to them. Nothing but a very vigorous rubbing will leave the teeth reasonably smooth, and even after the most thorough cleansing it is only a matter of a few hours when they are found coated again. The first impression on looking into such a mouth is that the patient ignores dental hygiene altogether, and yet some of these cases are at least as well cared for as the average. It simply seems an almost impossible task to keep the teeth free from accumulations. If a thin, flexible scaler be passed along the sheltered surfaces of the teeth it will almost invariably peel up a film of gelatinous material, and even the occlusal surfaces of such teeth are never found as highly polished as ordinarily. The teeth seem to invite the adhesion of materials as if the enamel were roughened, and in connection with this the gums are usually found more or less hypertrophied, so that the festoons creep up over the teeth more prominently than normal and bleed on the slightest touch. This is frequently noted in such cases, even where there are no calcareous deposits to account for it. A mouth in this condition should be watched very closely with the expectancy of caries if the condition persists for any time.

The change from this to a state of immunity is usually marked by a general clearing up of the fluids of the mouth, with decreased viscosity and tenacity. The mouth can be rinsed tolerably clean

without the use of the brush, and there is an appearance of cleanliness, as if better care were taken of the teeth even in cases where no change has been made in the patient's habits in this regard. There is little tendency for the accumulation of foreign material about the teeth, and the impression on the observer is that there seems to be some kind of solvent present in the mouth which keeps the fluids clear and prevents the formation of the glutinous masses seen during the susceptible period. Coincident with this the gums shrink to their normal form and become firm and pink, and do not readily bleed on pressure.

When the operator observes these changes going on in a mouth that has been causing him unlimited anxiety, he may feel much the same sense of elation which comes over a physician when he finds a patient who has been suffering from a high and stubborn fever suddenly bursting out into a generous perspiration. The tension is relieved, and for the time at least the dogs of war are chained, so that both operator and patient may have a chance to breathe.

The practical lesson of this whole study of susceptibility and immunity resolves itself down to the fact that an operator is never justified in allowing even the worst case of dental caries to go by default. He should institute the most vigorous proceedings against the enemy, with the idea ever in mind that sooner or later the kindly offices of a beneficent nature will intercede and help him win the battle. It is his duty in the darkest hours of these trying cases to explain to the patient as clearly as he may the theory of immunity, and offer such encouragement as an understanding of this phenomenon will suggest. By so doing he will often carry the patient through a disheartening experience, which otherwise would prove sufficient to cause a total neglect and loss of the teeth.

CHAPTER III.

EXAMINATION OF THE TEETH FOR CARIES.

WHEN a patient selects a dentist and places the teeth in his charge, it is the dentist's duty to make a careful examination of the teeth at intervals sufficiently frequent to enable him to keep perfect control of them and prevent the possibility of caries even approaching the pulp, much less causing the loss of a tooth. There should be a definite understanding with each new patron with regard to the mutual responsibility existing between operator and patient, the former assuming the obligation of saving the teeth and keeping them in a condition of functional utility, barring accidents or unforeseen complications, provided the latter will faithfully report for examination at stated times to be suggested by the dentist. A clear understanding of this nature will not only stimulate the practitioner to his best endeavor, but will place the patient in such a relation to the matter as to lead to increased respect and appreciation of dental service. It will also establish a professional and personal sentiment between the two which will tend finally to a series of friendships in the conduct of a practice calculated to prove one of the most pleasant features of professional life.

As to the frequency with which patients shall be instructed to apply for examination, the dentist must judge on the basis of a study of each case in its relation to the evident tendency or otherwise to decay in that mouth. In some particular cases where the carious process seems acutely active, the teeth should be seen as often as every second month, while in others they may safely go six months. But in no case where decay has once shown itself should the patient fail to apply at least twice a year for examination, and in the mean time should report immediately on the appearance of any suspicious sensitiveness in the teeth. With patients who are inclined to neglect or forget these examinations the dentist should have an understanding whereby he shall notify them at regular intervals to appear for inspection. Appreciative

patients take very kindly to the idea of these regular notices when they understand the motive.

All operative procedures upon the teeth should be pursued in a systematic and orderly sequence, even one apparently so simple as the examination for caries. When it is considered that each tooth has five surfaces, any one of which may be decayed, it will be seen that to properly examine an entire set of teeth involves more than a casual glance into the mouth, such as is often made to pass muster for an examination. An operator owes it to his patient not to overlook the slightest defect, particularly in a mouth where caries is prevalent, and to this end every surface should be brought under critical inspection. To accomplish this at the expenditure of the least time the operator should have some definite starting point in the mouth, and proceed from this in regular order till the entire set of teeth has been covered. A convenient place to begin is the left lower third molar, and from this to the next tooth in line till the right lower third molar is reached, when the mirror may be turned to the right upper third molar, and all the upper teeth examined, ending with the left upper third molar. In this way no tooth need be missed, and the least possible time is consumed in the examination.

Appliances for Examining the Teeth.

These should consist of a *mouth-mirror*, an *exploring instrument*, and some *unwaxed floss silk*. The mouth-mirror is an appliance which has the widest possible range of usefulness in operative dentistry. It begins with the examination of the teeth, and ends only with a final inspection of the completed operation. The dentist should early acquire the closest familiarity with this appliance, so that it becomes second nature with him to constantly hold it in his left hand while operating. By its use he is able to discover defects in the teeth which his unaided eye would never reveal, and when he has attained a thorough mastery of it he can perform many operations through the agency of the image presented in the glass without the necessity of stooping over to look directly into the mouth. In any operation on the molars or bi-

cuspid, even where direct vision is possible, the work is greatly facilitated by reflecting the light fully upon the operation with the mirror.

For examining the teeth this reflected light is very valuable, in the evidence it often gives of caries on the proximal surfaces where the probe fails to find any defect. Sometimes decay occurs so near the contact point that the exploring instrument cannot enter it, but by throwing the light upon the teeth the enamel will usually show a different color from normal tooth-tissue. This relates to a dead white appearance which is distinctive in character, and readily recognized by an experienced operator. When this appearance is noted, and there seems no possibility of gaining entrance to the cavity with the finest probe, the question of whether there is decay or not may often puzzle the beginner. It is here that the floss silk is especially useful. If drawn between the proximal surfaces of the teeth where caries is present it will usually drag and fray against the rough margins of the cavity, instead of passing the contact points with a snap, as is the case where the teeth are normal. In some instances the floss will be severed completely, and when such is the case there can be no longer any doubt about the presence of a cavity.

The exploring instrument is especially useful for investigating the fissures and pits of the occlusal surfaces, and for probing around the teeth generally wherever the light from the glass cannot penetrate. It should be very fine and sharp at the point, but with sufficient bulk at the shank to make it reasonably rigid.

As to the best kind of mirror for ordinary use in the mouth, it may be stated incidentally that a plane mirror is preferable to a magnifying mirror. The latter so distorts the image as to be very misleading, while a plane mirror always gives the true image. In critical examinations, where the image requires enlargement, a good magnifying glass is very useful, but never a magnifying mirror.

CHAPTER IV.

EXCLUSION OF MOISTURE DURING OPERATIONS.

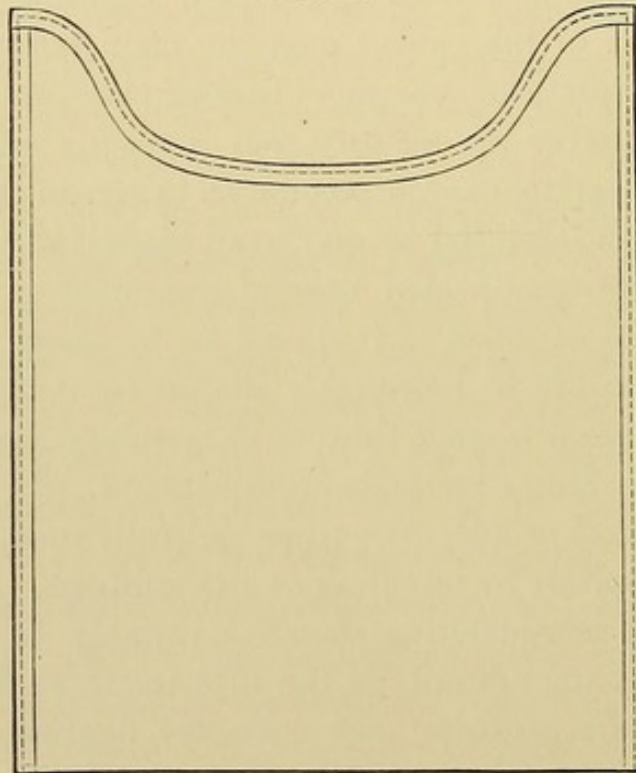
ONE of the chief hindrances to the execution of perfect work in the mouth is the saliva, and the problem accordingly presents itself of keeping the teeth free from moisture during operations. Various methods have been employed for this purpose, but in the majority of cases the only effective means is by the use of the rubber dam introduced years ago by Dr. Barnum. Previous to the introduction of the rubber dam the main reliance was upon napkins, and, while many operators became very proficient in their use, there was never the security that is readily afforded by the dam. Every operator should become an expert in the application of the dam, to the end that he may avail himself of its advantages in all difficult or complicated cases of treatment or filling. The dam is not used as much as it should be by many operators, on account of a failure to thoroughly master its ready application, and in many cases it is made to work unnecessary hardships on the patient through faulty methods of adjustment. It is sufficiently unpleasant to most people, even when skillfully used, without adding to the discomfort by bungling or awkwardness.

The greatest consideration should invariably be exercised on the patient's behalf; not only in the adjustment of the dam itself, but in the use of accessories, such as clamps, ligatures, dam-holder, weights, etc. Adequate protection to the patient's clothing from the overflow of the saliva, particularly when operating upon the lower teeth, should be provided in the way of saliva ejectors, napkins, or a rubber bib. The latter is especially serviceable, and should always be at hand for immediate use in an emergency, even where it is not deemed necessary to apply it at the outset of the operation. The saliva ejector in many instances seems to discommodate the operator, and also to prove with some patients more of an annoyance than a relief, though with others it is a very acceptable adjunct. The peculiar preferences of patients must be studied in this as in other matters.

Where the ejector cannot be used the chief reliance should be the rubber bib, because of the inadequate protection afforded by napkins from the tendency of the saliva to soak through and reach the clothing. It need not be intimated that the bib must be kept scrupulously clean at all times, and thoroughly dried after washing before being used on another patient.

A very agreeable accessory to the use of the dam is a form of napkin, Fig. 17, suggested by Dr. J. W. Wassall, to be placed

FIG. 17.



between the dam and the chin. The size of this napkin is about nine inches square, and the greatest depth of the curvature about three inches from the upper margin. Most patients are appreciative of this attempt to keep the dam away from the face, and it is especially useful in cases where the contact of the dam has a tendency to induce nausea. The curvature in the pattern fits approximately the outline of the mouth, and the two ends may be tucked up under the dam-holder, and thus be held in position and protect the cheek. In every case where this napkin is not used a smaller napkin should be folded and placed between the holder

and the face on either side, to render the patient comfortable and prevent the imprint of the holder being made in the cheek. A close observance of these minor details, as they affect the comfort of the patient, will do much toward removing the prevalent dread of dental operations, and no operator can afford to neglect them, even from the point of view of his own personal advantage.

With individuals who are inclined to be nauseated by the rubber dam, the difficulty may often be overcome by diverting attention from the dam in the following manner: Before applying the rubber have everything in readiness to proceed at once with the operation, and the moment the dam is in place go vigorously at work upon the tooth with something of a hammer-and-tongs method; not necessarily inflicting undue pain, but using sufficient force with the instrument to divert the patient's attention from the dam to the tooth. Continue this rapidity of action for some minutes, ignoring all attempts at protest, and directing every energy upon the operation with a quick succession of movements and a more or less noisy rattling of instruments. This, if pursued for a time, will usually result in the nausea passing away and the patient quieting down, but the operation must be carried along to completion without any interruptions. If the patient be left for a moment, even after the nausea seems to have passed, the sensation will return instantly when the mind is allowed to dwell upon it. This is why the operator must seemingly ignore the symptoms of nausea on the first application of the dam, and proceed with the work irrespective of it. If he quietly waits for the symptoms to pass away they will never pass, but grow progressively worse till the dam must be removed. This is only one of many cases in dental practice where a bold, rapid, and vigorous policy is the sole line of procedure capable of successfully meeting the emergency.

Kinds of Rubber Dam.

The weight of the dam is largely a matter of individual preference, some operators preferring a light dam, and others a heavy one. The advantages of the light, or thin, dam consist in its more ready passage between the teeth, and its consequent greater ease of

application; but this is offset by the fact that it will not ordinarily remain in place without ligating, and it is too readily caught up by revolving appliances, such as disks or burs. The slightest contact of a rotary instrument with a piece of thin dam will cause it to be wound up in the dam so as to tear the dam or puncture it. On the other hand, very heavy dam, while ordinarily more difficult to apply, will to a greater degree admit of the revolving instrument playing over its surface without being wound up or injured. It will also remain more securely placed on the teeth, and seldom requires ligatures to hold it. But with some teeth the contact of the proximating surfaces is such that it becomes something of a problem to force thick dam between them, and in general practice it would seem best to employ a medium weight of dam.

As to the relative advantages of the twilled dam and the smooth dam, the operator has his choice between a dam which remains well in place when once adjusted, but which annoyingly catches on every instrument or appliance coming in contact with it, and one which may not be quite so tenacious to the tooth, but which admits of reasonable usage without annoyance. The twilled dam seems to have an especial propensity for being caught up by every movement of an instrument against it, and, while there are some operators who use it successfully and with evident satisfaction, it will prove too troublesome for general recommendation.

Size of Dam.

The size varies according to the particular case in hand, and the location in the mouth. For the molars it should be about seven inches square, and ranging from this down to six inches for the incisors. Some operators prefer the dam cut in the form of a triangle by dividing a square piece in two from one corner to another, the long base of the triangle being placed uppermost and the ends grasped by the dam-holder, while the apex hangs down over the chin. This is an economical way of cutting the dam, and answers a good purpose in the anterior part of the mouth, but for posterior teeth the square form is preferable.

Punching the Holes.

The various forms of rubber-dam punches may be used for making the holes, but in case a punch is not available a very simple and very effective method is as follows: Take a round instrument handle about four millimeters in diameter, slightly oval-faced on its end, and perfectly smooth. Over this stretch the dam, with some tension at the point where the hole is desired, and with a sharp knife nick the dam against the side of the handle a short distance from the end. This will invariably cut out a perfectly round piece of rubber and leave a hole as true and clean in outline as is possible with the sharpest punch. The size of the hole may be gauged accurately by the distance from the end of the instrument at which the cut is made. If it is near the end, the hole will be small; if farther away, it will be correspondingly large. In this way it is possible to vary the size of the hole from the smallest perceptible puncture to a hole the size of a lead pencil, and still have a clean-cut outline.

The sizes required for the different teeth will vary from about three millimeters in diameter down to one millimeter, and a little practice will enable the operator to cut the holes precisely as desired. The width of rubber between the holes must vary according to the width of the interproximal spaces and the condition of the gum-septum occupying them. If the teeth are long-crowned, with the contact point near the occlusal surface and the interproximal space large and imperfectly filled with gum-tissue, the width of dam between the holes must be great; while if the teeth are short, with small interproximal spaces and the gum coming up to the contact point, there is little room for the dam between the teeth, and it must be correspondingly narrow. But it should never be made so narrow that it fails to adequately cover the gum-septum and shut out moisture. If too narrow, it will, when stretched between the teeth, pass down to one side of the gum-septum and pinch it against the proximal surface of the tooth, leaving part of the gum exposed to view, instead of having it wholly covered. The width of dam between the holes should

vary from two to four millimeters in medium-weight rubber,—the lighter the rubber, the greater the width necessary. This has no relation to cases of unusual spaces between teeth where the proximal surfaces are not in contact, and where the width of dam must be governed by the extent of separation.

Rubber-Dam Clamps.

The use of clamps for the purpose of holding rubber dam in place upon the teeth has been much misunderstood and greatly abused. Clamps, if properly selected and carefully adjusted, are capable of a wide range of usefulness, but if employed without a knowledge of their limitations and in direct violation of the necessary care and skill, as they frequently seem to be, they are calculated to work irreparable injury to the teeth and surrounding parts, and involve the patient in much needless suffering.

The principal faults in the manipulation of clamps consist in a failure to select the suitable form of clamp for the case in hand, and a lack of care in its proper adjustment. A clamp that does not approximately fit the tooth cannot be expected to effectively remain in position without undue impingement at certain points, which results in injury and discomfort. An operator should have a sufficient number of forms to meet the varying cases presented in the mouth, and to this end should make a careful study of the different teeth with especial relation to the shapes of the crowns and necks, so as to be able to make his selection of clamps with intelligence. In the adjustment of a clamp harm may be done in two ways: the clamp may be too small for the tooth and pinch it so severely at the neck as to injure the tooth, especially in a long operation where the slight movement of the clamp resulting from the pressure of the rubber dam against the bow may cause the sharp beaks to grind against the enamel so as to indent it; or the clamp may work so far rootwise on the tooth as to cause impingement on the gum and set up serious inflammation. Even if this injury is not always permanent, it is sufficiently distressing to the patient to account for future distrust and apprehension whenever the clamp is employed.

The rubber dam itself is sufficiently objectionable to the average individual without adding to the dread by painful methods of application, and, while it is not always possible to maintain the dam in place without some slight discomfort, there is no excuse for inflicting the serious injury in its use that is too often done by careless operators. The clamp may be used in the large majority of cases without perceptible pain or other ill effects, if properly selected and skillfully applied. The two classes of teeth most difficult to manage in this regard are those of the extreme bell-crowned variety, where the crowns are exceedingly long with broad occlusal surfaces, and the short conical teeth appearing very little above the gum. In the former case the contact points on the proximal surfaces are near the occlusal surface, and the interproximal spaces are large and long. The tooth at the gingival line is much narrower in circumference than at the occlusal surface, and the buccal and lingual surfaces accordingly present an incline toward the gum. The ordinary clamp applied to a molar or bicuspid of this type has a tendency to slide along this incline and gradually impinge seriously upon the gum. Every movement of the rubber dam against the bow of the clamp tends to force it still farther along the incline, till it becomes excruciating to the sensitive gum-tissue. To obviate this difficulty clamps have been devised with stays on the bows to rest on the occlusal surface of the tooth, with the idea of preventing the clamp from slipping too far rootwise, but in many cases these stays do not prevent the clamp from tipping forward and gouging the anterior point of the beak in the gum, and in other cases the stays are in the way of the operation. The better method where these extreme bell-crowned teeth are encountered is to dispense with the clamp altogether and secure the dam by some other means.

The other form of tooth, in which the crown is short and the tooth much larger in circumference at the free margin of the gum than at the occlusal surface, presents difficulties of a vastly different character. In this case the incline is from the gum toward the occlusal surface, and the chief problem presented is to maintain a clamp in position at all. The inevitable tendency is to dis-

lodge the clamp by the slightest movement, and unless the clamp is made secure in the beginning of the operation an intricate piece of work may be jeopardized, and even ruined, by dislodgment of the clamp when the operation is only partially completed. In this instance there is little danger of injuring the tooth or the gum with the clamp. It may cause temporary discomfort, but seldom permanent injury. The gum covers the enamel to such an extent that the enamel is thick at the point where the clamp rests, and as for the gum, it will usually be found lapping over the surface of the tooth to a considerable distance from the point where it is attached to the root. This flap of overlying gum may safely be forced back by the clamp at several points sufficiently to admit a grip of the beaks without permanent injury, provided it is not pinched by the beaks or severely lacerated. If necessary, a local anesthetic may be used on the gum before applying the clamp, and after the operation an anodyne antiseptic should be applied and the gum gently kneaded against the buccal and lingual surfaces with the finger.

For extremely difficult cases of this character, such as are sometimes encountered in stunted third molars, a specially devised clamp is indicated, to be referred to subsequently.

With the exception of these two classes of teeth, and the peculiar difficulties experienced in the management of labial, lingual, or buccal cavities, the ordinary use of clamps, if properly adjusted, ought not to be a serious dread to the patient.

KINDS OF CLAMPS.

Clamps for Molars and Bicuspid.

In the application of the rubber dam to molars and bicuspid, the chief problem in the past has related to the difficulty of carrying the rubber back over the teeth and holding it there while the clamp was being adjusted. To carry the dam to place with the fingers, particularly over teeth far back in the mouth, was exceedingly awkward, and in some cases almost impossible without distressing the patient. To overcome this, operators were in the

habit of passing the beaks of the clamp through the hole in the dam and carrying the clamp and rubber to place at once, afterward lifting the rubber over the beaks and passing it between them and the gum. The drawback to this, with beaks of the ordinary form, was the fact that the rubber stretched across the opening between the beaks and obscured the tooth so that it was difficult to see where the clamp was being placed. A new form of clamp was devised to obviate this, known as the Ivory clamp, in which the beaks are carried out buccally and lingually and then turned down into a flange, over which the rubber may be hung, leaving the space between the beaks open for perfect vision. With this form of clamp the application of the rubber dam is a very simple matter, as will be detailed later.

Another advantage of this clamp is the projecting forward of an extension from each beak to hold the rubber out of the way during an operation. In this connection it may be stated that one of the chief offices of the clamp, aside from its service in maintaining the rubber on the tooth, is to keep it away from the region of the cavity, so that it shall not constantly be in the operator's light and be caught up with instruments and displaced. The bows of the clamp accomplish this distally, and the projections on the beaks of the Ivory clamp do it buccally and lingually. Figs. 18 and 19 illustrate the Ivory clamp with the flanges referred to and the manner of hanging the rubber over them. Fig. 20 is a special form of beak which will be found very serviceable for those difficult cases previously referred to,—the short conical teeth whose buccal and lingual surfaces incline sharply toward each other as they pass from the gum-margin to the occlusal surface, so as to lead to the displacement of an ordinary clamp. As will be seen, the extremities of the beaks are deflected in such a way as to dip under the free margin of the gum and grasp the tooth well root-wise. This clamp would be an exceedingly cruel device to use in ordinary operating, but for these especially trying cases it will securely maintain the rubber in place when no other form of clamp is effective, and if used with discriminating care it need not be productive of any serious injury or discomfort to the patient.

The operator should have a large assortment of special forms of clamps to meet all the special cases, but for ordinary use a few of the standard forms of molar and bicuspid clamps will do the major part of the work in the routine of office practice.

FIG. 18.

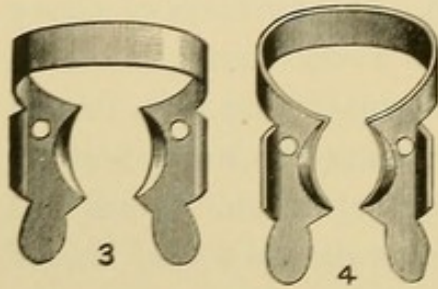


FIG. 19.

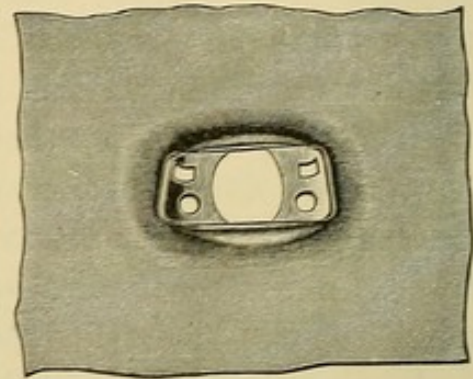
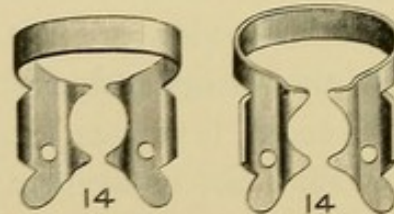


FIG. 20.



Cervical Clamps for Buccal, Labial, or Lingual Cavities.

With the large range of service demanded of a cervical clamp and the intricate positions it is sometimes called upon to reach, it could scarcely be expected that any one form of clamp would advantageously cover all cases. Much improvement has been made in recent years in the development of the cervical clamp, and some of the more modern forms would seem to be as nearly universal as ingenuity can make them; but for the average practitioner it will be found best to have several varieties to meet all of the emergencies that may present. Some operators seem to have a special aptitude for one particular kind of clamp, and are apparently able to accomplish more with it than with any other; but for most men it will be necessary to have at least three or four forms to secure the best results.

The forms here illustrated are not intended to include all of the

serviceable clamps in the market, but with these in his case the operator will be reasonably well equipped to meet most cases applying to him for treatment. Fig. 21 is the Keefe clamp, a feature of which is the triple bearing on the tooth afforded by the three jaws or beaks. This tends to hold the clamp securely in place and prevent rocking when screwed down snug with the set-screw. To provide for different lengths and forms of teeth and the various positions of cavities two of the beaks are made adjustable, by which means the clamp has a wide longitudinal range on the tooth, so as to be carried well rootwise in cases of extensive caries. In using this clamp it should first be carefully adjusted to the tooth

FIG. 21.

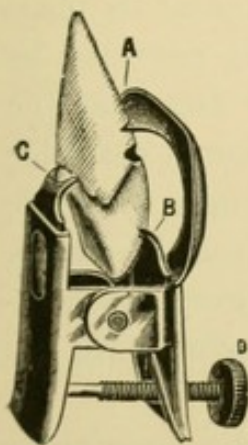


FIG. 22.

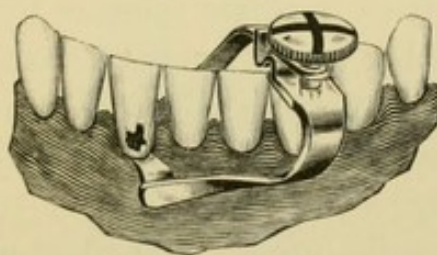
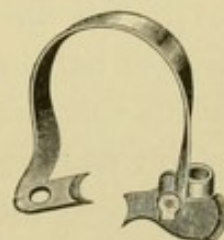


FIG. 23.



before the rubber is in place, so that the operator may clearly see all of the bearings and set the movable beaks in the correct position. It may then be taken from the tooth, the rubber adjusted, and the clamp returned to place, after which the set-screw may be turned down tight to hold the clamp firm.

Fig. 22 represents the Dunn clamp No. 2, which is intended to be as widely universal as possible. The bows are strong and rigid, so as to gain security of retention when the set-screw is tightened. In cases of extensive decay rootwise the beak may be carried beyond the cavity by placing a thick pad of bibulous paper between the opposite beak and the gum, against which the clamp may be tightened without injury to the tissues. This pad will enable the operator to give the clamp a wide range of position, and

should be employed in most cases where the clamp is used. The clamp should be loosely placed upon the tooth with the pad under the lingual beak, and then the labial beak gently forced to position and the clamp tightened with the set-screw. In case the arch of the teeth in the cuspid region interferes with the bow, the clamp may be reversed and used with the bows looking in the opposite direction.

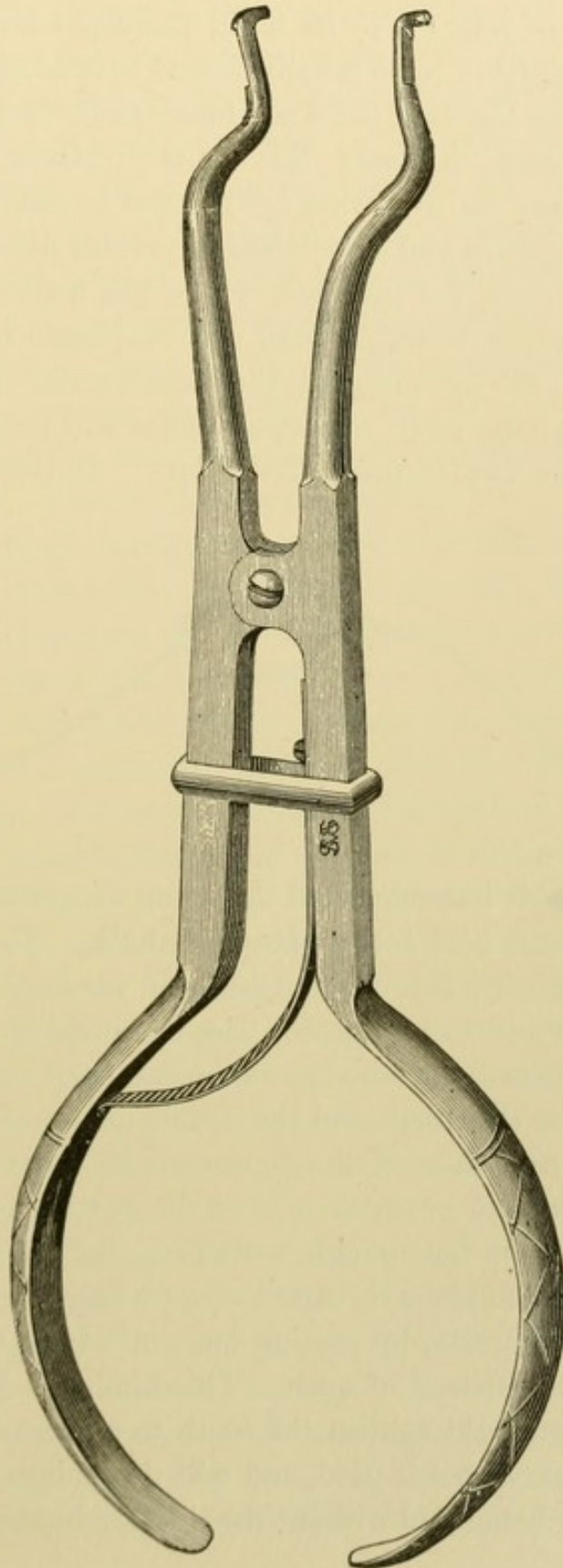
Fig. 23 is the Libby clamp, made in a right and left. The distinctive feature of this clamp is the hinged beak or pivoted shoe on the lingual extremity, which enables the clamp to readily seek a bearing and remain fixed in any position where it is placed. This clamp should be carried to position with the Brewer clamp forceps, Fig. 24; and when once properly adjusted it maintains its place very satisfactorily, on account of the broad bearing provided by the hinged apparatus on its lingual aspect. The fact that the extremity of this usually rests against the gum renders it desirable to protect the gum from too great pressure by slipping a short section of half-inch rubber tubing over it before applying the clamp. With this rubber pad properly adjusted there is never any complaint from the patient, and it does not seem to interfere with the security of the clamp.

A careful study of the proper method of using the three kinds of clamps here illustrated will enable the operator to successfully meet the most difficult cases which apply to him for treatment, and will render the average cases very easy of control. In some instances the clamp will need to be steadied by the fingers of the operator to make certain that there shall be no movement, but the usual length of time necessary to complete an operation of this kind ought not to be sufficiently long to make this especially irksome.

Ligatures.

In operating on proximal cavities in the anterior teeth where clamps are not indicated, or in cases of bell-crowned molars and bicuspids where the clamp would prove too cruel, ligatures may be used for the retention of the dam to good effect. The most

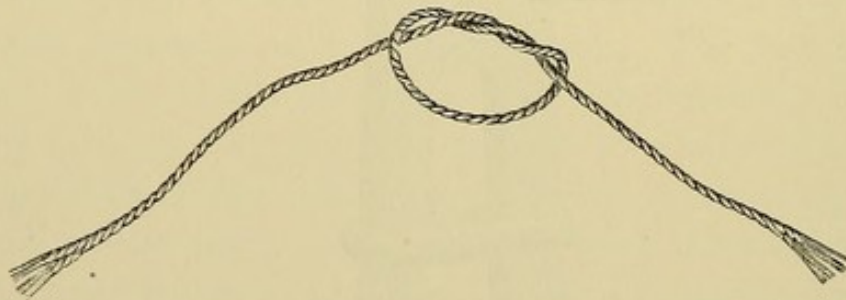
FIG. 24.



serviceable kind of ligature is waxed floss silk, on account of its great strength in relation to its bulk, thereby admitting a sufficiently strong ligature to be readily forced between the teeth.

In cases where the dam has a tendency to be dragged over the ligature and become displaced, leaving the ligature on the tooth, the difficulty may be overcome by the use of small glass beads strung on the ligature and distributed at various points around the tooth. On a molar, for instance, where the tendency would be greatest for the dam to slip, a bead may be placed respectively at the disto-buccal, the disto-lingual, the mesio-buccal, and the mesio-lingual angles of the tooth, and these beads will present sufficient bulk to resist the displacement of the dam. In lieu of beads Dr.

FIG. 25.



E. K. Wedelstaedt has suggested the tying of a small roll of cotton in the ligature, and thus creating bulk. The manner of adjusting the ligature is to force it between the teeth on the distal surface of the tooth to be ligated, pass it around the lingual surface, and out buccally or labially, as the case may be, between the mesial surface of this tooth and the distal surface of the one next in line. The two ends of the ligature now extend out so the operator may readily grasp them, but the portion embracing the tooth is usually not far enough rootwise. Before attempting to force the ligature to place the first loop of a surgeon's knot should be formed, like Fig. 25, by passing one end of the ligature twice around the other, instead of once. This kind of a knot will hold firm when drawn tight against the tooth to a greater degree than where the ordinary knot is used, and will thus admit of the second loop of the knot being tied without the ligature loosening. Before

drawing the first loop tight the ligature should be forced as far rootwise on the lingual surface as is desired with an instrument, and while being held there the strands of the ligature may be carried well into the interproximal spaces by gentle force on the free ends exerted in an oblique direction buccally (or labially) and slightly rootwise. When the ligature on the mesial and distal sides of the tooth has glided under the free margin of the gum and carried the dam with it the first loop of the knot may be drawn tight, which will securely fix the ligature and dam in place till the second loop of the knot is tied. This second loop need not be double-twisted, as the first. When the ligature is thus tied the free ends may be cut near the knot, preferably with a small curved pair of scissors like manicure scissors.

This forcing of the ligature to place is to some patients painful, while others do not seem to mind it in the least, the difference being due to the natural sensitiveness of certain patients more than others, and also to the fact that in some conditions of the gums there is an undue tenderness to pressure even when the individual is not otherwise nervous. The fact that the ligature in any instance may give pain should influence the operator to dispense with it whenever possible, and in actual work in the mouth this may be done to a very large degree. If the dam is of the proper weight and is skillfully adjusted it is the exception, rather than the rule, for a ligature to be required. The chief problem of retaining the dam in place without a ligature consists in so applying the dam that the edges of the holes are curled up under the free margin of the gum and look rootwise instead of crownwise. If this can be accomplished, the rubber will ordinarily remain in place and prevent leakage without a ligature. To do this the dam should be stretched rootwise by placing the ends of the fingers over the dam on the buccal (or labial) and lingual sides of the hole, and forcing it against the gum and toward the root. If, on being released, the dam does not curl up to position as desired, it may often be tucked to place with a smooth blunt-edged instrument like an amalgam spatula by stretching the dam rootwise and sweeping the instrument obliquely along under the edge of the dam as

it is being released. Where this is not effective the dam may readily be curled under by ligating the tooth, a procedure which will invariably result in turning the edges of the dam so that they extend rootwise. If it is a case where there is objection to the ligature, or where the ligature does not seem necessary for retaining the dam, it may be immediately removed after the rubber has been carried to place.

Occasionally it is necessary to ligate only one or two teeth in a given series embraced by the dam. The tooth to be operated on will usually require ligating to secure the maintenance of the rubber in its proper place and prevent leakage, unless a clamp is being used. If the cavity is a proximal one it is often necessary to ligate the tooth next in line, so that the strip of dam in the interproximal space will be held well out of the way and any possible oozing of moisture under the margin of the dam avoided. The last tooth embraced by the dam and farthest from operation may also require ligating to prevent the rubber from being dragged away by the action of the lips or the tongue, though it will frequently be found that ligating can be dispensed with in such a case by merely drawing between the proximal surface of this tooth and the rubber as it hangs up over the tooth not embraced by it a single strand of the ligature and cutting it off, allowing a piece of the strand about five or six millimeters in length to hang as a wedge between the dam and the tooth last embraced. In case there is too much space between the teeth to render the strand effective, a piece of rubber may be substituted for it by using an ordinary elastic band of suitable size, stretching this to place, and cutting it the proper length.

In cases where there is appreciable recession of the gums, leaving the interproximal spaces somewhat open and admitting a certain amount of movement to the dam between the teeth, the tendency is often great for the dam to leak unless it is held against the gum and kept from movement. To ligate all of the teeth is usually more or less distressing to the patient, besides consuming time. A much less painful and a more rapid method is to pack a bit of cotton in each interproximal space between the contact

points of the teeth and the rubber, forcing the cotton well up toward the contact points so that it will remain wedged to place. This will usually be quite effective in holding the rubber to position against the gum, and, if done with care, need not give the patient the slightest discomfort. The operator should never forget to remove these little cotton plugs before attempting to take off the dam, otherwise he is likely to give a rather uncomfortable pull to the dam without removing it.

In every instance where there is the slightest doubt about the dam passing readily between the teeth, a ligature or strip of rubber should first be carried between all of the teeth to be embraced by the dam, to make certain that the spaces are clear and free from rough or sharp edges calculated to cut the dam. Sometimes bits of calculus are found on the proximal surfaces, and these should invariably be removed before the dam is applied. In other cases incipient caries may have begun near the contact point on teeth other than the one being operated on, and the sharp margin of the cavity may cut the ligature or rubber. To obviate this a thin broad instrument like the gum-depressor, Fig. 26, should be forced between the teeth with a see-sawing motion, so as to smooth the rough or jagged edges of enamel in advance of the application of the dam. This instrument may be readily passed between the contact points of the teeth, especially if the edge has been ground quite thin, and after its free passage the dam may be applied with safety.

When the teeth are thus prepared for the reception of the dam, a general survey of the situation should be made to determine the required location of the holes. For the lower molar teeth the last hole back should be about three inches from the upper edge of the dam, and about two and one-half or three inches from the edge on the side of the operation, though this may vary some-

FIG. 26.



what according to the shape of the jaws and lips of the patient. For lower bicuspid the holes may be somewhat nearer either edge, but in no instance should they be near enough to prevent the dam from properly covering the upper lip and angles of the mouth. For the upper molars or bicuspid the last hole back need not be more than two inches from either side. Following this point forward, the holes should be cut so as to correspond with the curve of the arch, and in every instance a sufficient number of teeth should be included in the dam to properly expose the operation to view and keep the dam well out of the operator's way. It is too frequently the case that operators hamper themselves in their work by including only one or two teeth in the dam, thereby allowing the dam to curl up about the cavity and hide it from view, besides risking the danger of continually catching the dam in burs or other revolving instruments. There may be occasional instances where, on account of the difficulty of applying the dam, it is justifiable to limit as far as possible the number of teeth to be embraced by it, but under ordinary conditions in operating upon the molars or bicuspid the dam should be made to include the teeth as far forward as the lateral or even the central incisor. Aside from the idea of having the dam well out of the way, there is an anatomical reason for ending at one of the incisors. To end at the cuspid would often afford the operator ample opportunity for work, but the form of this tooth is usually such as to render it unsuited to be the last tooth embraced by the dam. It is often so cone-shaped that the dam readily draws away from it, while the mesial surfaces of the incisors ordinarily present such an incline as to prove an excellent medium over which to hang the last hole of the dam.

Manner of Applying the Dam in Different Locations in the Mouth.

To apply the dam to the lower bicuspid and molars the operator should first select a suitable clamp to fit the last tooth back to be included in the dam, and, after hanging the dam over the flanges of the clamp and adjusting the clamp forceps, he should grasp the upper edge of the dam with the thumb and fingers of the left hand in such a way as to stretch the dam up against the bow of

the clamp and hold the edges well out of the way of perfect vision during the application. Then, standing to the right and slightly in front of the patient, with the chin raised sufficiently to look directly into the mouth, the clamp with dam attached should be carried to place upon the tooth. The clamp should be adjusted with the utmost delicacy and gentleness, so as to inflict the least possible discomfort. In some instances the first grip of the clamp on the tooth will cause a slight flinching on the part of the patient, but if it is a clamp of the proper form for the case in hand and is carefully applied all appreciable discomfort passes away in a moment. Immediately following the placement of the clamp the forceps should be laid aside and a pair of pliers or a thin-bladed spatula should be employed to lift the rubber free from the flanges of the clamp, so as to let it snap around the tooth. The dam thus fixed, the edges may be fastened back out of the way, with the dam-holder around the patient's head, when both hands will be free for the further adjustment of the dam over the remaining teeth. With the number of holes in the dam already fixed in his mind, the operator should count back toward the tooth embraced by the clamp to be assured that he is placing each hole over the proper tooth, otherwise he may make the mistake of leaving a hole in the dam between the tooth embraced by the clamp and the one in front of it. Then, starting at the tooth next to the one already exposed by the clamp, he should consecutively pass the rubber over each tooth till all are included. This should be done by forcing the edge of the dam bordering the hole past the contact points, and thus carrying the strip of rubber between the holes into the interproximal space. If at any point the rubber seems to stick and refuses to pass between the teeth short of sufficient stretching to risk the danger of tearing the dam, the rubber should be merely hung over this particular tooth while the operator passes to the others and slips the dam over them. Then the ligature may be used to force the dam past the difficult spaces, and a careful examination made to see that there are no points at which a leak may occur. In doing this the distal surface of the tooth embraced by the clamp must not be overlooked. If the dam hangs

over this tooth so as to invite leakage, the ligature should be used to carry the dam well between this tooth and the one back of it.

After the proper adjustment of the dam the comfort of the patient must be looked to, as previously indicated, by the use of napkins, cheek pads, rubber bibs, etc. If the lower edges of the dam exhibit an inclination to curl up in the operator's way, they may be fastened down by weights.

In applying the dam to the upper bicuspids and molars the plan of procedure is much the same as for the lower teeth, except that some of the motions must be reversed, and the position of the patient and operator slightly changed. The grasp of the clamp forceps is also different. When adjusting the clamp to the lower teeth the forceps is placed with the claws looking downward, and the handles are grasped in the palm of the hand with the back of the hand upward and the thumb pressing against the outside of the handle nearest the operator close to the hinge, while the fingers reach over and clasp the handle farthest from the operator. (Fig. 27.)

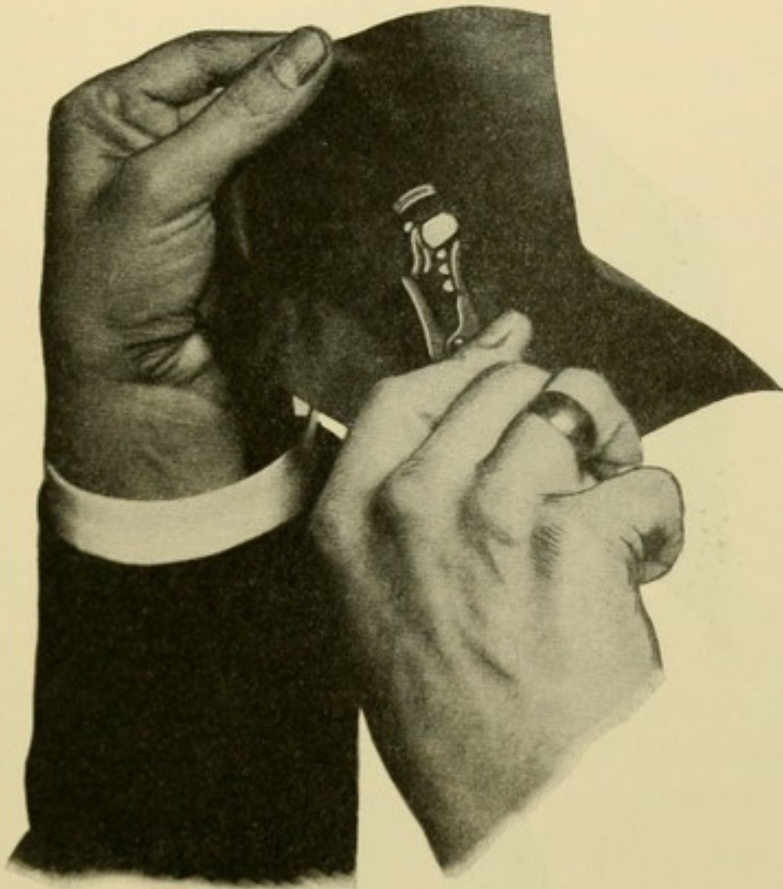
For the upper teeth the claws of the forceps look upward and the back of the operator's hand downward. The handles of the forceps pass diagonally across the palm between the second and third fingers and out between the thumb and index finger, so that the handles near the end are grasped by the thumb and index finger, and farther down toward the hinge by the second and third fingers. The ends of the index and second fingers clasp around and over the top of the handle farthest from the operator, while the thumb clasps around and over the top of the handle nearest him, and the ends of all three are turned so as to look somewhat in the direction of the claws. Thus the only finger not touching the forceps is the little finger, and the principal grasping force is exerted by the index finger and the thumb, while the lifting force in carrying the clamp to place is exerted by the third finger as the handle lies across it. (Fig. 28.)

In adjusting the dam to the upper teeth the patient's head should be tipped back so as to expose these teeth as perfectly as possible, and for the right side of the mouth the operator should

stand to the right and in front of the patient with the patient's head slightly turned to the right, so as to present the occlusal surfaces of the teeth directly toward the operator, the chin being raised to a convenient height for this purpose.

On the left side of the mouth the teeth can often be better approached by slightly lowering the chair and stepping a trifle to the

FIG. 27.

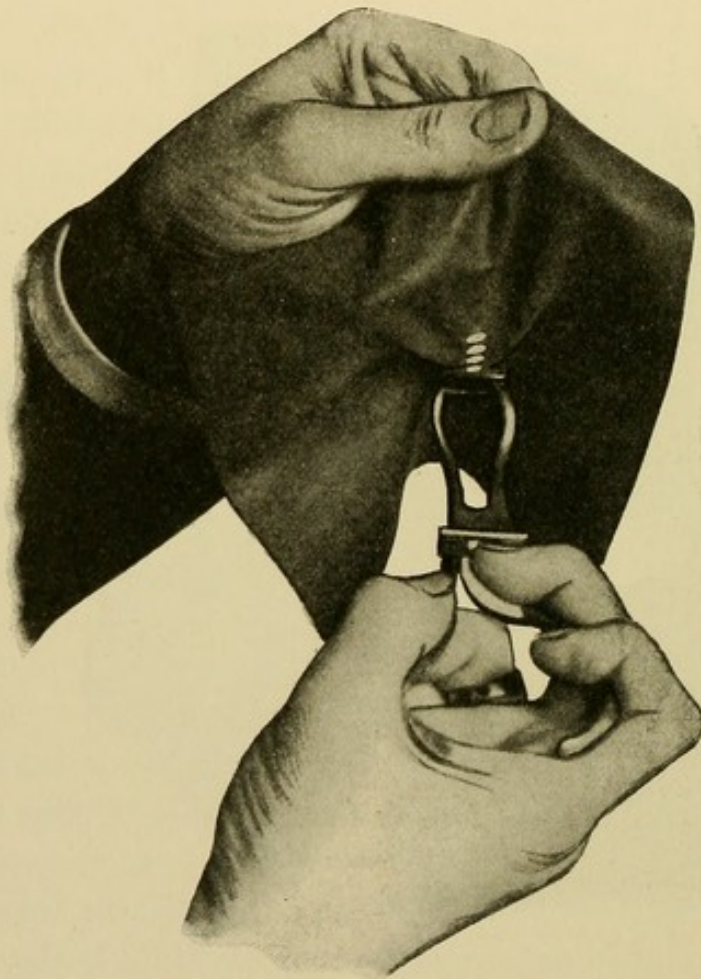

back of the patient, so as to pass the left hand and arm over and around the patient's head to hold the upper edge of the rubber away while the right hand is manipulating the forceps. The operator should study carefully the various peculiarities of form and position presented by the different mouths and teeth of individuals, so as thereby to avail himself of every advantage which his ingenuity may suggest. There is always a best and handiest way of doing these things, but no one way is always the best nor

the handiest, and to gain the most satisfactory results in every case the operator must be prepared to vary his methods, so far at least as the minor details of execution are concerned.

For the upper incisors and cuspids the holes should be punched in the dam from an inch and a half to two inches from the upper edge, depending on the case. The former distance will be ample

FIG. 28.



in most instances, but for a gentleman patient with a large moustache the holes should be at least two inches from the edge, to afford sufficient area of dam to perfectly cover the moustache and hold it out of the way. In no case should the dam be allowed to pass over the nostrils and obstruct the patient's breathing. For the lower anterior teeth the holes should be from three inches to three inches and a half from the upper margin, so that the mouth

may be thrown well open and still admit of the dam extending over the upper lip.

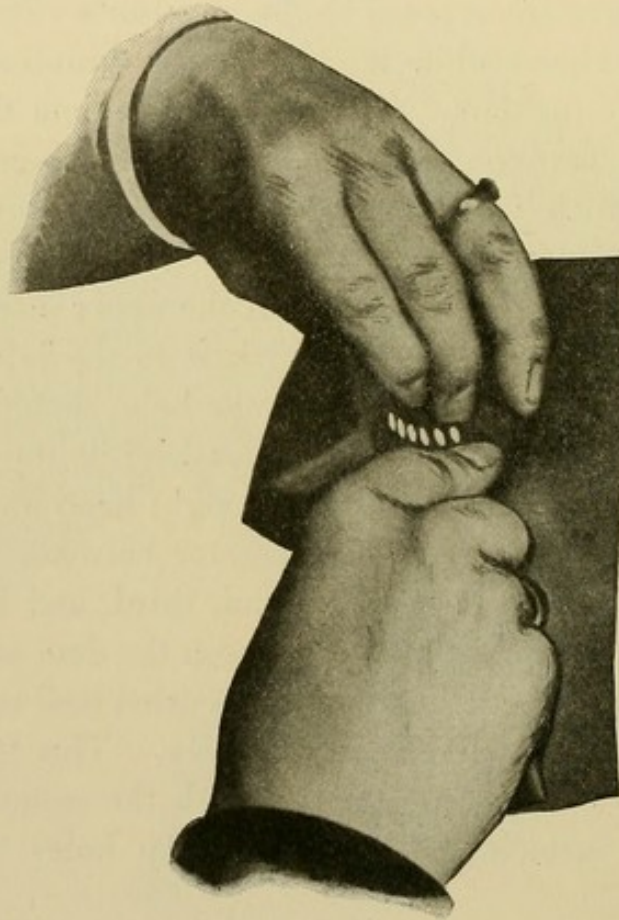
To adjust the rubber to the upper anterior teeth the upper edge of the dam should be grasped by the left hand in such a manner that the back of the hand looks away from the patient's face, while the palm is turned toward the face and the ends of the fingers look downward with the elbow raised over the patient's head. The dam should pass between the thumb and index finger and out again between the third and little fingers, so that the index, second, and third fingers are exposed to the operator's view as he looks at the back of his hand while the ends of the thumb and little finger are covered by the dam. The grasp of the dam therefore comes in two places, between the thumb and index finger and between the third and little fingers, thus keeping the dam on a tension and leaving the second finger free to stretch the holes. The end of the second finger should be placed at the upper margin of the hole which is to embrace the tooth farthest to the left, and opposite this, on the lower margin of the same hole, should be placed the end of the index finger of the right hand, while the rubber extends from this down into the palm of the right hand and is grasped by gathering the edge nearest the operator between the thumb and palm on the one side and the second, third, and little fingers on the other, the thumb extending between the dam and the patient's chin, while the ends of the fingers are curled well up into the palm to readily bring the rubber on a tension. This leaves the index finger free to work in conjunction with the second finger of the left hand in stretching and forcing the holes over the teeth. (Fig. 29.)

Beginning with the tooth farthest to the left, the dam should be carried consecutively over each tooth toward the right till all are included. The strips of dam between the holes should be forced well into the interproximal spaces by a see-sawing or stretching motion exerted by the second finger of the left hand and the index finger of the right, so that if possible the edges of the dam around the holes are turned under the free margin of the gums and look rootwise. The outer edges of the

dam may now be fastened back with the holder, after which ligatures may be applied wherever necessary, and the comfort of the patient looked after as previously indicated.

For the anterior teeth of the lower jaw the grasp of the rubber in the left hand is practically the same as for the upper teeth, but the grasp with the right hand is entirely different. Instead of gathering the edge of the dam nearest the operator in the palm,

FIG. 29.

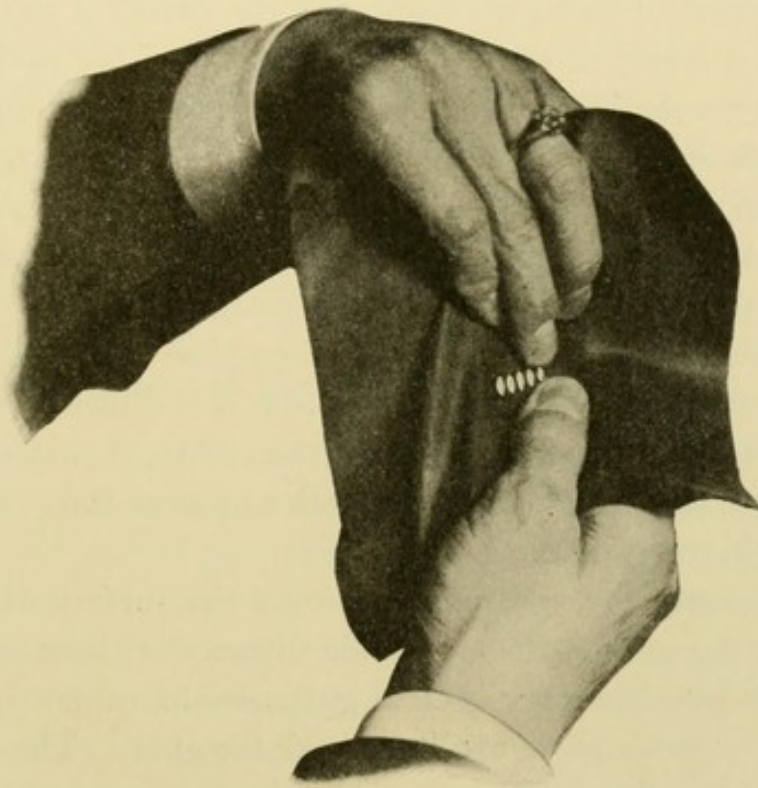


the grasp is made from the lower margin of the dam with the thumb uppermost. The grip is exerted by curling all four fingers up into the palm and gathering the lower edge of the rubber between the ends of the fingers and the palm. This leaves the thumb free to stretch the holes over the teeth in conjunction with the second finger of the left hand (Fig. 30). But the method of forcing the dam to place is different from that of the upper teeth.

When stretching the holes over the upper teeth the end of the second finger of the left hand is carried along the labial surface of the tooth, while with the lower teeth it is carried into the mouth and along the lingual surface, the thumb forcing the dam over the labial surfaces.

To gain an intelligent conception of the methods of procedure here outlined, both as regards the handling of the clamp forceps

FIG. 30.



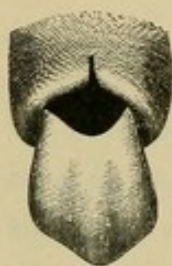
and the various grasps of the rubber dam, the beginner would better follow out the descriptions with the forceps and dam in his hands. It is too often the case that descriptions which read well prove impracticable when applied to the mouth, while methods which appear cumbrous in print are very-effective in their practical application. It is with this idea in mind that, in conjunction with the writing of these descriptions, an actual adjustment of the dam has been made in each instance.

Applying the Dam for Operations on Buccal, Labial, or Lingual Cavities.

The peculiar difficulties to be encountered in controlling these cases relate to the rootwise extension of the decay, and the consequent involvement of the gum-tissue in the cavity. In some instances the gum fills more than one-half the cavity, and the problem then is to displace the gum so as to expose the gingival margin of the cavity and admit of carrying the clamp and rubber rootwise of it. This may be done in one of several ways. Where a large mass of hypertrophied gum-tissue fills the cavity it should be cut away with a lancet or curved scissors, and then the cavity packed with gutta-percha in the form of a soft temporary stopping, with considerable excess extending over the gingival margin of the cavity so as to force the gum well away from this region. This should be allowed to remain two or three days, when the gum will be found well healed and the cavity-margin exposed. In many cases the temporary stopping will accomplish the object without previous cutting of the gum, and in case it is difficult to maintain in place, on account of the form of the cavity, it may be secured by passing a ligature around the tooth and over the gutta-percha, thus tying it to position.

In some cases the decay extends over the surface of the tooth and under the gum for considerable distance without appreciable penetration into the tooth, so that gutta-percha cannot in any way be employed to force back the gum. The only alter-

FIG. 31.



native is to press away the gum with the clamp at the time of operating, or, if this cannot be done, to make a vertical incision in the gum over the cavity, reaching from the gum-margin rootwise past the decay. The flaps of gum may then be forced out of the way, and after the operation they will readily heal, provided care is taken not to produce too much laceration. (Fig. 31.)

With the gingival margin of the cavity thus exposed one of the chief difficulties in the application of the dam is removed, but a

minor one instantly presents itself in the fact that the cavity extends so much farther rootwise than the gum on the opposite side of the tooth that the jaws of the clamp do not impinge on the tooth at points directly opposed to each other. This results in insecurity of the clamp unless specially provided for. With the Keefe clamp this difficulty is overcome by the adjustable jaws and the triple bearing, in the Libby by the pivoted shoe for the lingual surface, and in the Dunn by the use of the gum pad, so that the points of bearing may be arranged directly opposite one another. It is of the utmost importance to test the various clamps on the tooth before the application of the dam, so that a suitable selection may be made for the case in hand.

In making holes in the dam for these cavities they should be punched farther apart than for other cavities, so as to admit of considerable stretching of the strips between the holes without drawing them too thin or too narrow.

Application of the Dam in Difficult Cases.

It is seldom that the dam cannot be readily applied to any of the anterior teeth and securely retained in place, but with the molars, particularly the second and third molars, the problem sometimes becomes more or less complicated. The chief difficulties relate to peculiar forms of teeth, unfavorable positions of teeth, bad contacts on the proximal surfaces, and a general tendency to resistance on the part of the patient.

The forms of teeth most unsuited for the retention of the clamp are those of a cone-shape, with buccal and lingual surfaces so sloped that the clamp is invariably displaced unless made of a peculiar pattern. Teeth of this character are much larger in circumference at the gum-margin than at the occlusal surface, and there is consequently no opportunity for the grip of an ordinary clamp. But if a close study be made of these teeth it will usually be found that a short distance under the free margin of the gum there is a slight depression as the enamel approaches its thin edge near the cementum. The gum is never adherent to the tooth at

this point, and with a clamp so formed that the jaws are turned down into a reasonably sharp projection at either extremity, so as readily to slip under the free margin of the gum, an adequate grip may be obtained, provided the patient will submit to a slight temporary discomfort. Such a clamp has already been referred to in Fig. 20, and if this clamp is used with discriminating judgment it will be found very effective without the infliction of any serious pain. It should be applied with the Brewer forceps, the bows of the clamp necessarily being very rigid and the jaws not readily spread with the ordinary forceps.


Unfavorable positions of the tooth relate particularly to upper third molars which are turned outward so that their occlusal surfaces look somewhat toward the cheek. In these cases it is often found that on opening the mouth the anterior border of the ramus of the lower jaw is carried forward, so as to impinge against the bow of the clamp. This difficulty may be overcome by using a clamp with a small bow and applying it in the following way: After carrying the clamp into the mouth, and before any attempt is made to place it over the tooth, the angle of the lips on the side of the operation should be stretched well out and back with the fingers of the left hand, so as to expose the buccal surfaces of the upper molars to view; and then the patient should be instructed to close the mouth as far as possible. This will immediately throw the ramus back out of the way and further loosen the tension of the cheek and lips, so a better view is had and an adequate space left to slip the clamp to place. It will be found that in operating on these teeth there is little necessity for keeping the jaws very far apart, particularly if the operator is expert in the use of the mouth-mirror. All of the work on these teeth after the application of the dam should be performed through the reflection of the mirror, with the operator standing erect. By this method these cases are readily met and the difficulty overcome.

In some instances on the lower jaw the ridge of bone extending forward from the ramus is so prominent opposite the buccal surface of the third molar as to interfere with the application of an ordinary clamp, and in such a case the Southwick clamp,

Fig. 32, is indicated. This clamp is made in four sizes, and should be in every operating case. It is often applicable to the upper teeth as well as the lower.

Bad contacts between teeth, interfering most seriously with the adjustment of the dam, are found in cases where slight decay has commenced near the contact point, leaving sharp edges of enamel calculated to cut the dam, and also where there has been extensive wear of the teeth on the proximal surfaces from the individual movement of the teeth one against the other, resulting in broad contacts with the teeth tightly lodged together. Reference has already been made to the management of the former whereby a thin broad-bladed instrument is forced between the teeth and the sharp edges of enamel broken down, but in many of the latter cases it is impracticable to force such an instrument between the teeth. This condition of worn facets on the proximal surfaces is often associated with teeth the occlusal surfaces of which have also been worn so that the teeth present a broad, flat, table-like surface on their occlusal aspect, joining at a sharp right angle the worn facet on the proximal surface. With teeth of this character presenting no V-shaped depression or slope from the occlusal surface to the contact point, as in normal cases, the problem of entering the rubber between the teeth is frequently difficult. In every such case the ligature should be passed between the contacts in advance of the rubber, to carry away any small particles of foreign material that may be lodged between the teeth. When the operator is certain that all the spaces are free the dam should be carried over the last tooth back with the clamp, and then the strip of rubber between that tooth and the one in front of it should be brought on a stretch over the contact points and held there with the fingers of the left hand, one finger forcing it down hard upon the buccal festoon of gum and the other upon the lingual festoon. While the dam is thus hung up over the junction of the two teeth, the right hand may be employed to slightly force the teeth apart by passing the end of a thin-bladed spatula in the interproximal space

FIG. 32.



from the buccal or labial aspect, and prying on the teeth with a rotary movement of the spatula. This will usually force the teeth apart sufficiently to allow the strip of rubber to glide between them, and the process may be continued from one contact point to another till all of the teeth are embraced by the dam.

In every case of difficult contact the passage of the rubber may be facilitated by smearing the strips between the holes with vaseline or other suitable lubricant. This will allow it to glide more readily past the tight places, but care should be exercised not to allow any of it to come upon the surface of the dam to be grasped by the fingers. If by any inadvertence it gets on this surface it will instantly destroy all possibility of securing an adequate grasp, and it is therefore well to dispense with it entirely except with teeth presenting particularly difficult contacts.

Occasionally the operator will encounter trouble in applying the dam in cases where the teeth themselves are not at fault, on account of muscular resistance on the part of the patient's lips and tongue. Where this tendency is discovered in any manipulation about the mouth it is sometimes advisable to hand the patient a mirror and let him watch the movements of the tongue and lips, and see to what extent they are discommoding the operator. With some patients this is a sufficient appeal to their intelligence to result in overcoming the impulse, but with others there seems to be an uncontrollable tendency to resist the dam. In such cases, where it is impossible to bring about a relaxation of the muscles and an acquiescence on the part of the patient, the operator would better limit the application of the dam to as few teeth as will permit of reasonable access to the work. This difficulty is ordinarily confined more particularly to the lower molars, and it is usually advisable in such cases to let the application of the dam terminate at the first bicuspid. To keep the dam out of the operator's way and to hold it more secure against displacement from the action of the tongue and cheek, it is often a most excellent plan to slip a clamp over the first bicuspid with the bow looking toward the front of the mouth. A strong clamp should be used for the molar, and, after the rubber has been carried to place as best it may till

the first bicuspid is reached, the bicuspid clamp should be taken up in the forceps with the jaws looking away from the forceps, and the clamp forced to position on the tooth. The dam is thus secured at either extremity of its application, and the operator's hands are free to use ligatures and carry the dam past the contact points and further perfect its adjustment. This method will often save the operator much annoyance in these stubborn cases.

There are also certain cavities which, in mouths where for any reason the application of the dam is difficult, may be adequately protected by adjusting the dam to a single tooth. Small cavities in the occlusal surfaces of molars may often be filled in this way if the case presents peculiar obstacles to the extension of the dam over other teeth. But the disadvantages of operating on a tooth under such conditions render it advisable to limit this practice to the fewest possible number of cases.

The Use of Napkins and Cotton Rolls for Maintaining Dryness during Operations.

In many minor operations, where the time necessary for their performance is quite limited, the rubber dam may well be dispensed with, and the teeth kept dry by the use of napkins or cotton rolls made for this purpose. The upper teeth are more easily managed in this manner than the lower ones, but even on the lower jaw the skillful use of the napkin may in many mouths serve a useful purpose. In employing napkins or rolls for the exclusion of moisture consideration should be had for the points at which the saliva enters the mouth, and an effort should be made to control it as far as possible at the location of its entrance. On the lower jaw the salivary ducts open into the floor of the mouth under the free end of the tongue, or just in front of the attachment of the tongue to the floor; while on the upper jaw the ducts open from the cheek opposite the buccal surfaces of the molar teeth.

Napkins.

Napkins for this purpose are conveniently made from a piece of clean bleached linen, cut to the desired size and form for the

case in hand, and after being used once should be thrown away. To exclude moisture from the lower teeth a piece should be cut sufficiently long to reach from the lingual surfaces of the molars on one side around under the tip of the tongue to the lingual surfaces of the molars on the other. It should be wide enough so that when folded into a pad it will be sufficiently thick to fit with some pressure between the tongue and the lower jaw, but not so thick that the tongue is discommoded to the extent of rebelling against it and forcing it out of position. It will thus be seen that the size must vary in different mouths.

To adjust this napkin it should be grasped with the pliers near one end, and the patient instructed to raise the tongue toward the roof of the mouth. This end of the napkin should then be carried down between the side of the tongue and the lower jaw beneath the lingual surfaces of the molar teeth on one side, and then the napkin passed under the tip of the tongue immediately over the salivary ducts and around to the other side of the mouth in the same way. The patient should then be instructed to allow the tongue to rest lightly on the napkin, but cautioned not to run it under the napkin and lift it. This protects the lingual aspect of the teeth, but the buccal surfaces require attention to guard against the saliva which flows down the cheek from Steno's duct. If the duct is located quite far up on the cheek it may be guarded by packing a short napkin between the cheek and the upper teeth, but if the opening is low the saliva is likely to trickle down along the cheek and reach the lower teeth. The only alternative is to place a plump napkin along the buccal surfaces of the lower molars and bicuspid, and hold it against the cheek and gum with the fingers. The saliva will of course flow down from the upper duct, but it will be absorbed by the thick napkin and not reach the lower teeth. If the napkin gets too much saturated, so as to endanger leaking against the teeth, it may be adroitly removed and replaced by a dry one.

In some instances the adjustment of the napkin over the openings of the ducts will effectually stop all saliva from entering the mouth, and under these conditions the napkin becomes adherent

to the dried mucous membrane, and must be removed with the greatest caution through fear of injuring the membrane.

In excluding moisture from the upper teeth with the napkin, it is necessary only to pack against the opening of Steno's duct by placing the napkin between the cheek and the upper jaw above and against the buccal surfaces of the molars and bicuspid. To prevent the patient from closing the mouth and moistening the cavity with the tongue, a mouth-mirror should invariably be held as a guard under the upper teeth in such a way as to protect the operation.

Rolls.

To provide a more convenient means than the use of the napkin, cotton rolls were devised and placed on the market. They are furnished by the manufacturers in various sizes, and in lengths sufficient to enable the operator to cut them to suit any individual case. They are effective for very short operations,—particularly upon the upper teeth,—but they have not the same range of service that has a napkin properly applied. It is seldom that they can be maintained in place if passed from the lingual surfaces of the molars on one side of the lower jaw to the molars on the other side, and their use is therefore practically limited to one side of the mouth. They are not so effective in guarding the orifices of the ducts as are napkins, and must depend chiefly upon their absorptive properties for gathering up the saliva as it flows against them. But they should be found in every operating case, on account of their great convenience in the limited number of cases to which they are suited.

CHAPTER V.

CLASSIFICATION AND PREPARATION OF CAVITIES.

THE following brief classification of cavities is adapted from the report of the Committee on Syllabus presented to the Institute of Dental Pedagogics, and adopted by that body.

Cavities, as to character, are divided into two general classes: *pit and fissure cavities,* and *smooth surface cavities.*

Pit and fissure cavities are those occurring as the result of structural imperfections in the enamel due to faulty development, whereby two or more islands of calcification in approaching each other have failed to grow together or coalesce, leaving a break in the continuity of the enamel-covering. This defect results in the admission of the micro-organisms of decay, and forms a harbored shelter in which they may work their destructive processes unmolested.

These cavities are found in the occlusal surfaces of bicuspid and molars, in the lingual surfaces of upper incisors, and in the occlusal two-thirds of the buccal and lingual surfaces of molars. It will thus be seen that they occur in surfaces which are ordinarily kept clean by the friction of food in mastication or by the tongue or cheeks, and are therefore directly traceable to faults in the enamel-structure.

Smooth surface cavities are those occurring in surfaces where the enamel is perfectly formed, but where the location is such that it is not ordinarily kept clean by friction. They are thus distinctive in character from pit and fissure cavities, both as regards the conditions which bring them about and the methods to be employed in their preparation. These distinctions will receive more detailed consideration later.

Cavities under this head occur in the proximal surfaces, and in the gingival third of labial, buccal, or lingual surfaces.

Cavities, as to extent and location, are divided into *simple cavities* and *complex cavities.*

Simple cavities are those involving only one surface of a tooth, as an "occlusal" cavity, a "buccal" cavity, a "labial" cavity, etc.

Complex cavities are those involving two or more surfaces, as a "mesio-occlusal" cavity, a "disto-labial" cavity, a "mesio-disto-occlusal" cavity, etc.

Cavities are named according to the surfaces of the teeth in which they occur, and cavity-walls are named according to the surface or anatomical landmark toward which they approach.

Examples: In a mesio-occlusal cavity in an upper bicuspid the buccal wall is that wall which, if extended far enough, would involve the buccal surface of the tooth; the gingival is that wall which, if extended far enough, would involve the gingival line. In an occlusal cavity in a lower molar the bottom or floor of the cavity is called the pulpal wall, and in case of death of the pulp, so as to involve the pulp-chamber, the floor then becomes the sub-pulpal wall.

An axial surface of a tooth is any surface parallel with the long axis of the tooth, and an axial wall is that wall which approaches the pulp in a cavity in an axial surface.

CAVITY PREPARATION.

Proximal Cavities in Incisors and Cuspids.

Simple cavities not involving the incisal angle.—When decay occurs in the proximal surfaces of any of the anterior teeth, we are confronted with problems peculiar to the locality. The first consideration, as in every other class of cavities, is of course the preservation of the teeth, but in these exposed positions we must not ignore esthetic and artistic effects if we would do the highest class of service. Were it possible for us to save these teeth by filling without advertising the fact to the world, it would be our manifest duty to do so; but unfortunately this cannot always be done. It may also be stated that in the attempt to hide our work by confining our fillings to narrow areas we often jeopardize the teeth and lessen the confidence of the public in the permanence of dental operations through recurrence of decay and consequent undermining of the tooth-structure.

Observant operators have noticed that there are certain points around ordinary proximal fillings where decay is most likely to recur. This relates in anterior teeth to the gingivo-labial, gingivo-lingual, and the incisal angles. The reason for this is found in the fact that these regions are not kept clean by the friction of food in mastication, or by the lips or tongue in their various movements. If the anatomical relation of the proximal surfaces of these teeth

is studied, it will be seen that a considerable area in the vicinity of the contact point is not self-cleansing. This is what admits of caries in this region in the first instance. If in the preparation of a cavity we limit the area to a small round outline, we have left unprotected, at the points indicated, more or less of the surface of enamel. With the same conditions present and the same influences at work which originally induced decay, there is little to prevent a recurrence. The remedy lies in so extending the outlines of the cavity that the margins are carried to a point where they will be kept clean. This process has been termed "extension for prevention" by Dr. G. V. Black, and its observance must be insisted upon where the most permanent work is required.

Another point of frequent failure around these fillings is along the lingual margin. This is due to the fact that the lingual wall is often left exceedingly thin, and the enamel is crushed under the stress of mastication. The force of the lower incisors comes directly against this surface, and any unprotected enamel is likely to be broken down. In every instance where possible the margin should be so extended as to leave the enamel well supported by dentine, and wherever this cannot be done the enamel should be freely beveled and the gold built over it in such a manner as to protect it. Enamel protected in this way with care and skill will remain intact in ordinary positions, and yet this does not alter the general rule that enamel is safest when supported by dentine.

Fig. 33 shows the proximal surface of an incisor with a small round filling, *a*, points of recurrence of decay, *b b b*, and the outline to which the cavity should be carried for greatest safety, *c*.

This question of extension is a matter calling for the most careful consideration. It is confidently believed to be a solution of the problem connected with a very frequent form of failure in this class of cases, and yet it must not be employed indiscriminately. There are many cases where it would be manifestly impossible and injudicious to cut the cavity to the extent indicated. Patients apply to us for these fillings occasionally in such a nervous condition that any extra cutting beyond the present necessities of the case must be avoided. We should never jeopardize the nervous system

of our patient in order to carry out some heroic theory. Then, again, there are persons in whose mouths the tendency to caries is so slight that extension for prevention would appear to be an unnecessarily extreme measure. In some of these cases where there is limited decay, small fillings may prove serviceable for years. The age of the patient also has an important bearing on the question. Whenever we find the proximal surfaces breaking down rapidly under decay early in life, we may infer that the process of caries is to be active in that mouth, and we must employ the most strenuous means to control it. Extension for prevention is here indicated to its fullest legitimate extent. But in a patient well toward maturity with an occasional cavity developing, we may often safely stop short of the most extreme cutting. Then esthetic reasons play an important part in the anterior teeth. If we can

FIG. 33.

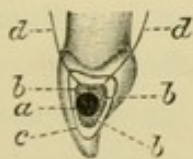


FIG. 34.




FIG. 35.



hide our fillings from view we should do so, and many of our patients are willing to take the chances of a recurrence of decay rather than have large fillings made in the first instance. A distinct understanding should be had with patients upon these points, so that they may enter intelligently into the merits of the different methods. We should be sufficiently honest with them to proceed on the theory that wherever these small hidden fillings are inserted the work must be considered more or less temporary, and must be kept under constant surveillance by the dentist.

In brief, the operator's attitude toward the practice of extension should be to aim always at the most ideal and permanent form for his cavities, and in every instance where he deviates from this it must be only on account of some well-defined reason for doing so.

There is one feature connected with the appearance of fillings in the anterior teeth which must not be overlooked. As has been said, it is sometimes well to keep fillings from view if possible,

but whenever it becomes necessary for a filling to show at all it should be extended labially, so as to show distinctly. The reason for this is that where gold is placed between teeth in such a way that it is in the shadow, the appearance a few feet distant from the patient is that of a black mass simulating decay, while if the filling is carried out sufficiently to allow the rays of light to reflect upon it the bright yellow tinge of gold is immediately perceptible. There should therefore be very little compromise between a filling kept entirely out of sight, and a good, bold showing of the gold from the labial aspect. Figs. 34 and 35 illustrate this point.

Separating teeth.—The first requirement in operating on these cavities is to have sufficient space between the teeth for perfect access. This must be obtained in some instances by wedging previous to the operation, in others space may be gained while operating by the use of a separator. In cases where the teeth have fallen together to any appreciable extent as the result of deep proximal decay, or where the teeth overlap in a slight irregularity, the separator will ordinarily not gain sufficient space for a proper contour of the filling. Neither can we gain access to do perfect work on small, hidden cavities (in those cases where it may be deemed advisable to fill in that manner) short of extensive separation. Where the labial or lingual wall is well cut away, the access is simplified.

The methods employed for gradual separation previous to operating may be varied according to the requirements of the case. Rubber has been used for this purpose quite extensively in the past, but it is only in the rarest cases where rubber is properly indicated. The difficulty with this material lies in the fact that it cannot easily be maintained in position. The sloping surfaces of the teeth tend to make it slide away from the contact points and insinuate itself into the interproximal space to the serious injury of the gum-tissue. Rubber should never be used even in the extremest cases without previously protecting the gum by packing cotton, gutta-percha, or cement against the gingival wall of the cavity, allowing it to extend across the interproximal space to prevent the movement of the rubber rootwise.

The materials best adapted for separating are cotton, gutta-percha, and waxed linen tape. Cotton should be packed firmly between the teeth while dry, and if there is difficulty in maintaining it in position it can be secured by passing a ligature between the teeth in the interproximal space before placing the cotton, and then bringing the ends down over it toward the incisal surfaces of the teeth and tying tightly around the cotton. This holds it securely in place and proves a very effective means of separating teeth. Fig. 36 illustrates the method of tying the cotton in place.

Gutta-percha may be employed by first adjusting the separator, forcing the teeth slightly apart, and packing the gutta-percha into the cavity and firmly between the teeth. The separator is then removed and the gutta-percha allowed to remain for several days. This will usually result in good space without soreness.

Waxed linen tape of a suitable width for the case in hand may profitably be employed in those cases where there has been little or no breaking down of the proximal surfaces, and where it would be difficult to retain cotton or gutta-percha. By either of these methods the pressure is so gradual that space is gained without the distressing irritation which usually accompanies the use of rubber.

In favorable instances, or in emergency cases, space may be gained at the time of the operation by the use of the separator. Wherever the separator is indicated it should be used in the following way: Care must be exercised in its adjustment not to allow it to impinge on the gum or unnecessarily wound the soft tissues. It should not be tightened to the limit at once, but merely "snuggled up" till the patient feels it. Then, as the operation progresses, it can be gradually tightened at intervals without appreciable discomfort. By the time the cavity is prepared, sufficient space will usually have been gained to admit of the insertion and proper contouring of the filling, and then a slightly additional space obtained during this part of the operation will afford opportunity for polishing. When the filling is finished, the greatest caution should be observed in removing the separator. If it is loosened suddenly after being tightened to the extent usually neces-

sary, it will result in most excruciating pain to the patient, the discomfort from this source ordinarily being greater than from the process of separating. It should be loosened very gently and slowly till the contact between the filling and the tooth next in line is sufficient to hold the teeth from further movement.

In manipulating the separator the greatest delicacy of touch should at all times be exercised. It is a dangerous and cruel appliance in the hands of the thoughtless or careless. The operator should invariably employ one hand to steady the bows while the other tightens the screws, to prevent tilting or shifting the separator. Any rocking or twisting of the appliance will result in unnecessary pain, and undue injury to the soft parts. Another serious limitation to the separator lies in the danger to enamel-margins

FIG. 36.

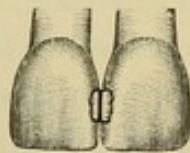
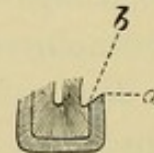


FIG. 37.

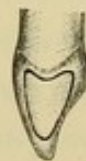

FIG. 38.



when the jaws impinge close to the cavity. The enamel may thereby be checked in such a way as to jeopardize the usefulness of the filling without the operator's observation of the fact at the time. Cases for the separator should be selected with care and judgment, and due consideration for the patient must invariably accompany its use. With these precautions, it is really a humane appliance and is capable of a large range of usefulness. It is not only indicated for gaining space between teeth, but may frequently be used, where space has already been obtained, for the purpose of holding the teeth firm during the operation. This avoids in large measure any soreness from malleting, and also prevents the teeth from gradually dropping together while the filling is being inserted.

Wooden wedges may also be used occasionally for this purpose, but the difficulty with wooden wedges lies in the fact that they are usually injurious to the gum-tissue in the interproximal space, and their entire wedging force must be exerted immediately instead of gradually. Whenever a wooden wedge is used to hold the teeth

firm during an operation it should be made as narrow as possible, and the rubber dam should be stretched well labially before the wedge is inserted, to overcome the tendency which the dam otherwise would have of dragging the wedge out of place. Dr. George E. Hunt suggests as an expedient to prevent the rubber from snapping the wedge out of place to take a thin shaving made in whittling the wedge, and with the pliers slip it into the interproximal space with its side against the rubber, using this as a guard for the wedge.

Detail of Cavity Formation.

After frail enamel-walls have been broken down and the margins extended to the desired outline, all decay should be removed and the cavity given such form that the filling will be retained securely in place.

The gingival wall.—This wall should be extended rootwise sufficiently to carry the margin of the filling well under the gum in accordance with Fig. 33. The line *d* represents the gum as it comes down between the teeth in the interproximal space, and the outline of the filling *c* shows the gingival portion well under the gum. The reason for this extension is the well-known fact that wherever we have the gingival portion of a perfectly inserted filling covered by healthy gum-tissue, we will never have recurrence of decay at that point. In cases where the enamel has begun to take on a whitened appearance at the gum-margin extending gingivo-labially and gingivo-lingually from the cavity, thus indicating an approaching disintegration, or where the activity of the carious process seems to be very great in that mouth, the gingival outline of the cavity should be carried well out gingivo-labially and gingivo-lingually as illustrated in Fig. 37. This gives the gingival outline a curve with its convexity toward the cavity.

The gingival margin of proximal fillings has often been alluded to as the "vulnerable point," even when fillings were well inserted, but this is hardly in strict accordance with facts. In reality decay seldom recurs along the gingival margin proper. It usually begins at the gingivo-labial (or buccal) and gingivo-lingual angles. From here it may extend and involve the entire gingival margin, but the

initial point of failure is usually at the angles. This is because there is a lodgment-place in these positions for deleterious matter to form undisturbed by friction from the tongue or lips, and unprotected by gum-tissue. In this small sheltered harbor the micro-organisms of caries create their films and attack the enamel. No tooth may be considered safe from recurrence of decay around proximal fillings unless the gingival wall has been carried sufficiently rootwise to bring that portion of the filling under the gum, and the gingivo-labial and gingivo-lingual angles have been extended to a point where these margins of the filling are kept clean by friction.

This form of extension results in the gingival wall being either flat labio-lingually or convex toward the cavity, and this is believed to be desirable for other reasons than those of prevention. A filling is more easily built upon a flat base than upon a curved base, and is more secure from dislodgment when completed. The prevailing custom of forming the gingival wall on a curve labio-lingually so as to be concave toward the cavity is accountable for the fact that many operators find their fillings rocking when partly inserted, and it has also led to the necessity of drilling pits more or less deep (and more or less disastrous) in the gingival portion of the cavity.

To subserve the best ends in anchorage the gingival wall should also be made flat mesio-distally, with a slight incline rootwise as the gingival wall approaches the axial wall. In some instances this incline may take the form of a shallow groove in the dentine extending from the gingivo-labial to the gingivo-lingual angles of the cavity, and carried somewhat into the lingual wall at this point to facilitate the starting of the filling. It should not be carried to any extent into the labial wall, on account of the difficulty of adapting gold into an inaccessible undercut such as this would be.

The lingual wall.—As has already been intimated, this wall should be freely cut away if frail. The temptation to leave it for the purpose of having something to build the gold against in the insertion of the filling has proved the stumbling-block of many an operator. If sufficiently supported by dentine it need not be ex-

tended farther than is necessary for prevention, but in some instances it must be cut away nearly on a line with the axial wall.

Especially is this true in those cases where for esthetic reasons it is considered desirable to leave the labial wall standing and insert the filling mostly from the lingual aspect. The difficulty of doing a perfect and permanent operation in this way renders these cases rare, and limits them sharply to cavities having a strong, thick labial wall.

When the lingual wall is cut away freely, the only attempt at retention along this wall should be as it approaches the gingivo-axial angle and the incisal angle. Here a right angle may be made with the axial wall, or in the gingival extremity of the lingual wall the groove previously mentioned in the gingival wall may be diverted at right angles into the gingival third of the lingual wall. This not only aids in retention, but provides a cul-de-sac into which may readily be secured the first pieces of gold. Deep grooving should generally be avoided in these cavities on account of the uncertainty of gaining perfect adaptation and density of the gold in the bottom of grooves, and also because of the consequent weak walls to the cavity; but in the gingivo-lingual region these objections are not strictly operative. Direct access may be gained with a plugger, and the bulk of tooth-tissue covering the pulp at this point admits of judicious grooving without creating weak walls. But in no instance, even where it is deemed advisable to leave the lingual wall standing, should the groove be extended throughout the length of the wall. The most that should be done in the middle third of the wall is to make more or less of an angle between that and the axial wall.

The labial wall.—The same general rules apply to the formation of this wall that have just been outlined for the lingual wall, except that grooving is contraindicated in any portion of its length. In cases where possible an angle may be formed with the axial wall to increase the security of anchorage, and especially should this be done in the gingival and incisal thirds.

The incisal angle.—This should be formed at right angles with the axial wall. It should never be deeply grooved, nor should a

pit be drilled at this point, as is frequently done. To assist in retention of the filling it may be slightly inclined toward the incisal edge of the tooth as it approaches the axial wall.

The axial wall.—The form of the other walls practically determines the shape of this wall. It should be as nearly as possible at right angles with the others, leaving in all cases as much dentine covering the pulp as is consistent with strength of the filling and a thorough removal of all decay.

The enamel-margins.—The final step in the preparation of the cavity is the treatment of the margins. The enamel should be so beveled that the peripheral ends of the rods are cut off and the dentinal ends covered with gold when the filling is inserted. This calls to mind the necessity for introducing two terms to properly designate enamel-margins. In reality there are two margins to enamel, and in cavities such as we are considering a clear distinction between the two is important. There is the enamel-margin at the periphery of the tooth, and the enamel-margin next to the dentine. For want of better terms these may be designated the *peripheral enamel-margin*, and the *dentinal enamel-margin* (Fig. 38, *a* and *b*).

If in all cases the enamel could be left well supported for considerable depth by dentine the distinction in terms would not seem so important, but this is not always possible; and where such is the case the treatment of these two margins is dissimilar. The peripheral margin should be given a distinct bevel, while the dentinal margin should be slightly rounded.

The necessity for beveling enamel relates to the peculiarity of its structure. It is composed of rods standing with their ends on the dentine and radiating out toward the periphery of the tooth in a more or less regular manner. The enamel when supported by dentine, and with no break in the continuity of its structure, will sustain great stress without fracture, but when undermined by decay it is easily broken down. This break is usually in line with the enamel-rods, which indicates that the cement-substance holding the rods together is not very strong. If, then, the peripheral ends of the rods are left standing around a filling while the dentine is

gone, and possibly the dentinal ends of the rods dissolved out by caries or burred away in the preparation of the cavity, it is readily seen that the short peripheral rods must sooner or later drop out, even if they escape crushing in the insertion of the gold. This admits of a leak around the filling. To make perfect margins the enamel should be so beveled that there are no short rods at the periphery. But this bevel must not be too acute, nor must the peripheral margin be rounded. Either of these conditions would result in the filling-material assuming too attenuated a form at the edges, which would admit an element of weakness to the filling. The exact degree of bevel cannot well be given in figures, owing to the variation necessary in the different locations along cavity-margins on account of the varying direction of the enamel-rods. The degree of bevel must largely be governed by the direction of the rods in each particular locality, and the only way to determine this short of a microscopical examination, which, of course, is impracticable in the mouth, is by the sense of touch. The operator's fingers may be so schooled that in trimming the enamel with a sharp chisel he can readily determine the arrangement of the rods by the ease with which the enamel is cleaved in certain directions. Remembering that the enamel cleaves most readily in line with the direction of the rods, he is able to intelligently judge the condition of the margin by the manner in which the blade affects it, and so long as the peripheral portion of the enamel breaks down readily, or is easily pulverized, the trimming must continue. This delicate "feeling" along the margins of cavities with a sharp instrument is very necessary to the establishment of a perfect outline, and is the only true criterion as to the degree of bevel indicated in each given case.

In every instance where the dentinal enamel-margin is at all prominent it should be slightly rounded, as already indicated, to facilitate the perfect adaptation of the gold against it. (Fig. 39, *a*, peripheral enamel-margin beveled, *b* dentinal enamel-margin rounded, *c* filling-material protecting margin.)

The marginal outlines of these cavities should represent symmetrical and graceful curves that will not offend the eye of the

artist. In the formation of the walls of the cavity, angles have been recommended at various points for the firm retention of the filling, but angles are never permissible along the margins for esthetic reasons. As the gingival margin joins the labial or lingual margin it should not be at a sharp angle, but on a curve. This curve may in some instances be rather short, but it must invariably be a symmetrical and definite curve. The outlines along the labial and lingual walls should be true and clearly cut to present the most artistic appearance. The dentist should aim not only to do serviceable operations, but to do beautiful ones as well.

Technique.—The first step in the operation is to break down unsupported enamel-margins. This may best be done with suitably formed chisels, made sharp. In some instances the thin overhanging labial wall may be cleaved away to advantage with a short, strong hatchet excavator. The blade must not be long enough to penetrate into the cavity sufficiently to expose the pulp or impinge on sensitive dentine as the enamel is broken in. Care should be exercised especially in the early stages of the operation not to shock the patient. A false movement at this time will do much to unnerve the average individual. If it is found necessary to give pain in an operation, it is best if possible to defer that particular part of the work till the patient has been some minutes in the chair. It will ordinarily then be better tolerated.

After weak walls are broken down the cavity should be extended to its proper outlines. This can usually be done rapidly and effectively with sharp burs, either round or oval as the case demands. In the use of burs for this purpose—or in fact for any purpose—due regard must be exercised for maintaining the bur precisely at the angle and in the position required. No operator should venture to use an instrument like the dental engine without previously having acquired an absolute control of the hand-piece, and having studied carefully its dangers and limitations as well as its legitimate uses. The failure of operators to properly manipulate the engine is accountable for much of the prejudice against it. The principal dangers to be guarded against in extending these proximal cavities in incisors relate to the displacement of the bur by

catching the blades against the margins of enamel and carrying the bur either into the cavity or out across the surface of enamel. To prevent this the hand-piece should be firmly grasped and the bur applied to the margin without too much force, and at such an angle that it may be maintained in position.

If the cavity is one which looks toward the operator, the bur may be held at right angles with the long axis of the tooth, and in that position it is not likely to slip. In cavities looking away from the operator where the position of the bur is more nearly parallel with the long axis of the tooth, the shank of the bur should have a bearing on the surface of the enamel in such a way that the bur will be braced against the displacement while the blades are playing along the margins.

FIG. 39.

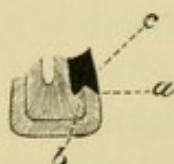
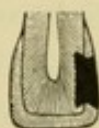


FIG. 40.



After the cavity has been extended to the desired outlines the decalcified dentine should be removed. This is ordinarily best done with thin, sharp excavators, though in some instances the same bur which extended the outlines may be used for a few revolutions to remove the diseased tissue. In those cases where the decay has penetrated to any extent, this work should be done with spoon excavators to avoid needless pulp-exposure. An instrument with a sharp angle, as in the hatchets and hoes, is more likely to penetrate too far and puncture the pulp than one with a rounded form such as the spoons.

When the carious tissue is removed the walls should be shaped for anchorage. For the gingival wall an inverted cone bur of suitable size should be placed with its end against this wall, and the shank as nearly as may be parallel with the long axis of the tooth. It is then carried labially and lingually along the gingival wall till the proper form is secured. The end of the bur leaves the gingival wall flat, and produces nearly a right angle between the gingival and axial walls. This angle, while not strictly speaking a right

angle (unless the bur is held perfectly parallel with the tooth), is sufficiently so for practical purposes, and the form left by the bur presents a surface parallel with the end of the plugger point, thus facilitating the adaptation of the gold against this wall. In cases where necessary the gingival wall may be slightly grooved with the bur, but in every instance it must be used with care and judgment to avoid too deep cutting and pulp-exposure.

As the bur reaches the gingivo-linguo-axial angle of the cavity it may be withdrawn crownwise along the gingival third of the lingual wall, making a slight groove at this point as before advocated. This groove formed by the side of the bur will be rounded. If deemed advisable it may be squared out with an excavator to an angle with the axial wall.

The labial wall is formed by placing the inverted cone bur with its end against the axial wall and its shank at right angles with the long axis of the tooth. By carrying the bur laterally along the labial wall from the gingival wall to the incisal angle the side of the bur will give form to the labial wall, and an angle will be created between that and the axial wall.

The incisal angle of the cavity may be formed, in cases where there is suitable access, by carrying the inverted cone bur down into this angle, cutting sidewise, with its end facing the axial wall. The form of the bur gives the required angle between the incisal and axial walls. Where the bur cannot be placed in the proper position to accomplish this purpose, the incisal angle may be formed with small, delicate excavators, and in the entire formation of the cavity indications may point to the use of excavators instead of burs. It is believed that with sharp burs carried in a hand-piece under perfect control more effective cutting can be made in a given time than with hand instruments, and yet the operator must not lose sight of the advantages of excavators under certain conditions, nor enslave himself to the prejudiced following of any one method under all circumstances. He should study the mechanical and the nervous requirements of the case, and readily adapt himself to the most serviceable plan of procedure.

The enamel-margins may be beveled with a fine-bladed round

bur used in the manner advocated for cavity extension, or they may be planed off with delicate sharp chisels, as the case indicates.

General Considerations.

It may be noted that some of the suggestions here advanced relative to cavity formation appear somewhat radical when compared with the methods generally in vogue in the profession. The advocacy of angles between the walls of these cavities may impress many as being illogical and impracticable in view of the orthodox teaching on the subject. Curved outlines to cavity-walls have usually been suggested whenever there has been any suggestion at all. This has been done with a view of making a cavity into which the filling-material might easily be adapted, and one of the first objections likely to be urged against the formation of angles is the supposed difficulty of adapting gold into such angles. This question of the non-adaptability of gold to angles has been much overdrawn. It is simply a matter of proper manipulation, with pluggers of a suitable form to carry the gold into the angle. It need not here be stated that a plugger with a round shank and a flat serrated face is not the form for this purpose.

Gold can easily and accurately be adapted into a sharp right angle, as has repeatedly been proved by experiment. The advantages of making angles in cavities relate to the ease with which fillings may be started in such cavities, and the unquestioned security of anchorage without undermining and weakening the walls. Fillings built upon flat bases have a greater stability against displacement under stress than those built upon curved bases, and the gold is less likely to rock during its insertion.

It will be found that in the practical application in the mouth of the methods here advocated it is seldom that a perfectly sharp angle is ever made in one of these cavities, especially in any position where it is at all difficult to fill. The principle involved is merely the formation of flat walls instead of curved walls, and the operator who makes the trial of building fillings against flat walls after being accustomed to curved walls will not long remain in doubt as to which is the preferable method. There is a sense of security to

the work as it progresses which is never experienced when the walls have been formed in curves.

Fig. 40 shows a longitudinal section of a tooth mesio-distally, with cavity formed and filled. It will be seen that the filling is mortised or dovetailed into place, with no deep grooves or undercuts to weaken the walls.

Proximal Cavities in Anterior Teeth Involving the Incisal Angle.

When caries has progressed so far that the proximo-incisal angle is either broken down or so undermined that it is unsafe to leave it, the problem of anchorage becomes correspondingly complicated. With this angle gone and the consequent necessity for its reproduction in gold, an additional area of filling is exposed to stress tending to its dislodgment. The usual plan of anchoring these fillings has been to groove the gingival wall deeply, with additional grooves along the labial and lingual walls wherever possible, and then drill for anchorage in the incisal region between the lingual and labial plates of enamel as they approach each other near the incisal edge. (Fig. 41.)

While many fillings anchored in this manner have stood the test for years, and while there are some instances in which this is the only practical method of anchorage, it is confidently believed that for the majority of cases there is a better and safer means at hand. The limitations of this method relate to the fact that any tipping stress upon such a filling has a tendency to lift it away from its incisal anchorage, and either loosen it entirely, or so dislodge it as to cause a leak along the incisal half of its outline. (Fig. 42.)

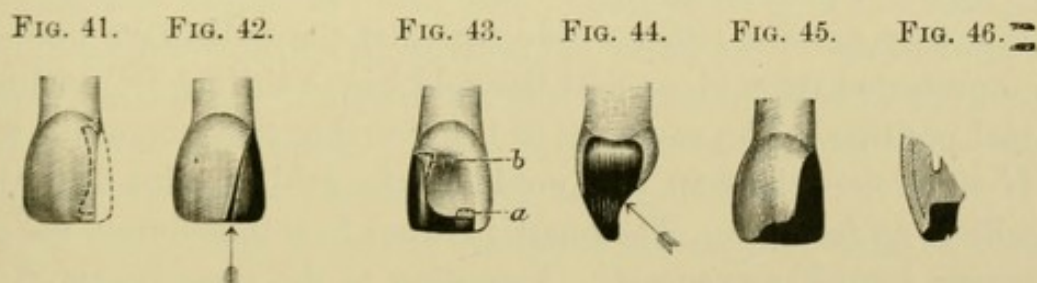
To more securely anchor these fillings at their incisal extremities, it is recommended to create a step at right angles with the main body of the filling by cutting a groove along the incisal edge, or rather by cutting away the incisal portion of the lingual plate of enamel to a sufficient depth and length to gain strength of filling-material. The labial plate of enamel is ordinarily left standing for appearance, so that while more gold is used in this kind of a filling, the excess is presented to the lingual aspect of the tooth, Fig. 43, and there is no greater exposure of gold to the labial aspect

than in the ordinary contour filling. The advantage of this form of anchorage must appeal to every mechanical mind. A filling properly placed in such a cavity cannot be dislodged short of fracture of the filling or stretching of the gold from repeated impacts of the lower tooth at the point where the main body of the filling joins the step. Stress brought to bear on such a filling in the process of biting has a tendency to force the filling into the cavity instead of lifting it away, as in the usual methods of anchorage.

Detail of Cavity Formation.

The same general plan of formation is followed in the gingival third of the cavity that was advocated for simple proximal cavities, except that the anchorages may be made deeper, and if possible broader, for the contour filling.

The labial wall.—This wall should be formed as nearly as possible at definite right angles with the axial wall. The creation of an angle at this point is a matter of importance in all cases where the



extent of the labial wall will permit it. The direction of stress against these fillings by the lower incisors is often obliquely upward and toward the labial (Fig. 44), and the broader we can make the area of resistance to this stress the more securely will we retain the filling. The open aspect of these cavities renders the adaptation of gold into such an angle very convenient. The labial wall of the step should have the same form and same angle between it and the seat of the step or pulpal wall. This portion of the labial wall should be left as thick as possible to prevent the gold from showing through and to represent considerable strength. In those

teeth where the incisal edge is so thin that there is no opportunity for leaving an adequate labial plate it may be necessary to shorten the labial wall somewhat and build the gold over it so as to expose it to view from the labial aspect. (Fig. 45.) In such a procedure artistic appearance is sacrificed for safety.

In every instance where this wall is left standing, it should be beveled as illustrated in Fig. 46, and the gold built over the bevel with the greatest care. Protected in this way, it is often possible to retain this wall with safety, and thus disguise our operation to that extent.

In considering the strength of this wall an objection may be urged by some against the formation of an angle to the cavity at the junction of the labial with the other walls, on the mechanical ground that whenever a fracture occurs it is more likely to locate itself at an angle than at any other place. In view of the fact that the present system of cavity preparation involves the formation of angles at different points in the depths of cavities, it may be well to consider this matter at this time.

If we stop to study the causes of fractured walls, we shall see that they are due either to the fact that the walls have been left unprotected by gold, or that the gold has so shifted from its original position in the cavity as to bring undue stress upon the wall. If we protect the wall with gold and the gold remains firm, there will be no fracture. The question arises how to maintain the gold secure against movement. According to the most approved and logical mechanical principles, this is best solved by building it against flat walls joined by angles, rather than against circular walls joined by curves. Other things being equal, gold will shift under stress just in proportion as the base upon which it rests is rounded. It is simply the difference between attempting to roll a cube and a sphere.

But aside from this, those who have been led to fear fractured walls on account of making angles in cavities need not hesitate on this score, because in the mouth it will be found practically impossible to form an angle so sharp or so acute that it will determine the location of a fracture,—even if a fracture should occur. The

attempt to make angles insures more fully the general plan of flat surfaces, and is recommended mainly for that purpose. It is firmly believed that the ideal cavity should have flat walls joined by definite angles, forming a mortise for the filling-material, but it is exceedingly difficult to attain the ideal in the mouth.

As has already been stated, these angles should be confined to the interior of the cavity, and when the exposed outlines are formed they should be given symmetrical curves for esthetic reasons. In accord with this the margin of the labial wall of the cavities under consideration should execute a short curve from the proximal to the incisal rather than have an abrupt angle at that point. (Fig. 47.)

The lingual wall.—This wall should be cut freely away in the incisal region to admit of sufficient bulk of gold to represent considerable strength to the filling as the proximal joins the incisal portion. This is essentially the weak point of these fillings, any breaking or stretching of the gold resulting in a lifting away of the proximal portion of the filling.

This wall should be given some retentive form to maintain the filling against possible force from the labial aspect in the form of accidental blows. This can usually be accomplished in the gingival third of the wall and at the extremity of the step if no other opportunity presents itself. (Fig. 43, *a, b.*)

The step.—The length of the step mesio-distally must be determined by the requirements of the case. It should be extended far enough to firmly anchor the filling, and in those cases where the incisal edge of the enamel has been worn down so as to expose the dentine the step should be carried across the tooth to include all exposed dentine. It should be made sufficiently deep pulpally to admit of strength to the gold, but not far enough to endanger the pulp. Its width labio-lingually must be governed somewhat by the thickness of the tooth, and in those cases where necessary the lingual plate may be cut away freely to add to the width of the step.

The base of the step, or pulpal wall, should be made perfectly flat. This is one of the most important considerations in the kind

of cavity formation under discussion. If the pulpal wall is rounded in the least degree, it materially lessens the stability of the mesial portion of the filling. The limited area presented for the reception of the gold at this point imposes upon us the necessity for maintaining the greatest possible security to a given bulk of material, and this can only be done by building the gold against a perfectly flat surface. This wall should also be extended slightly into the dentine pulpally as it approaches the termination of the step. (Fig. 43, *a*.) This is to add to the security of the filling against the tipping stress. As the step terminates, it should end in an abrupt wall parallel with the long axis of the tooth and at a right angle with the pulpal wall.

FIG. 47.



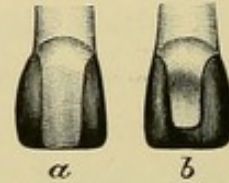
FIG. 48.



FIG. 49.

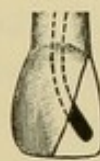

FIG. 50.



Technique.—The same general plan of technique may be followed as was advocated for simple proximal cavities up to the formation of the step. To form the step an inverted cone bur should be placed with its side against the incisal third of the axial wall, as illustrated in Fig. 48, and carried laterally into the tissue to the extent required for the length of the step,—the cutting being done with the side of the bur. This leaves the desired flat base to the step. The projecting lingual plate of enamel left by the bur can readily be broken down with chisels.

The labial and lingual enamel-margins can best be beveled with small sand-paper disks in the engine, provided the operator studies carefully their proper use. The disk must be held at such an angle as to give a distinct bevel. Any rocking or tipping of the disk will result in a rounding of the peripheral enamel-margin, the disadvantage of which has already been mentioned. The enamel at the termination of the step can be beveled with a round bur.

General Considerations.

Two items of detail must be carefully observed to make this method of cavity preparation of the highest esthetic value. The labial wall must be left as thick as possible to avoid the reflection of the gold through the enamel, and the gold must be adapted accurately to this wall throughout. If there is any failure of perfect adaptation, the filling will eventually leak at this point, giving rise to an unsightly discoloration under the enamel. The most delicate and precise placing of the gold and the highest degree of density possible are necessary for perfect results. When these are attained, it is confidently believed that this method will prove very serviceable in a certain class of cases which have in the past been troublesome to many operators.

The contraindications to this method relate to cases where the lingual wall has been extensively disintegrated by caries, thus destroying the possibility of making a step anchorage. Usually such cases involve the pulp, and wherever the pulp is removed, anchorage may be obtained if necessary by cementing a strong iridio-platinum post into the pulp-chamber and allowing it to extend toward the incisal portion of the cavity in such a manner that the gold can be built around it and the filling retained in position. (Fig. 49.) No one method is universally applicable to these cases any more than to other cavities, and the operator who would attain the best results must carefully study each case that presents and be prepared to apply the particular method indicated in that especial case. The most that can be taught are principles and plans, and he who cannot apply his individual ingenuity to meet the requirements of special cases ought never to have been a dentist.

The question may arise with some as to the advisability of inserting these large contour fillings instead of crowning the teeth; in fact, we see occasional doubts thrown upon contour operations since crown-work has become so common. It must always remain a matter of the nicest discrimination just when to abandon filling and substitute crowning, but it may be laid down as a safe axiom that a tooth presenting sufficient material to maintain a filling for a

reasonable period should be filled. Sometimes these extensive operations will last many years, and when the final crash comes and the filling is lost, the tooth presents the same opportunities for crowning that it did before it was filled. Crown-work has not yet been sufficiently long in use to determine definitely its permanence, and until we have had a more prolonged experience it may be safe to assume that in filling a doubtful tooth we extend the serviceability of that tooth just the number of years the filling lasts. In other words, the crown is likely to remain in service as many years after the filling has failed as it would have done had it been employed in the first instance. It is therefore sometimes advisable to fill these incisors, even when both mesial and distal incisal angles are gone, and to produce a filling such as is illustrated in Fig. 50, *a*, labial aspect, *b*, lingual aspect.

The objections often urged against these extensive fillings on the ground of their excessive weariness and nervous tax to the patient are rapidly being discounted by modern methods of operating, and the dental chair of to-day need not be the rack of torture that it sometimes in the past has been accounted. Filling-operations by virtue of improved technique and systematic plans of procedure have been shortened nearly one-half over former days.

Proximal Cavities in Bicuspids and Molars.

The principles involved in the treatment of caries occurring in the proximal surfaces of bicuspids are so similar to those occurring in like surfaces of molars that they will be considered as one class of cavities. Minor differences in the detail of the work will, it is true, be called for, but these are readily suggested by the differences in the forms of the teeth. The position and function of bicuspids and molars are nearly identical, and they are subject to practically the same influences leading to decay primarily and to a recurrence of decay around fillings. The same forces are at work to dislodge fillings, and the same general plan of anchorage must be pursued in the one as in the other. For these reasons they are treated in common.

Simple Proximal Cavities not Involving Other Surfaces.

The instances are very rare where it may be deemed advisable to fill this kind of a cavity. Usually when decay begins on the proximal surface of a bicuspid or molar, the proper preparation of the cavity involves its extension through to the occlusal surface. Almost the only exceptions relate to those cases where the cavity faces an open space caused by the loss of a tooth, or to those occasional instances where there has been extensive recession of the gums in the interproximal space and consequent decay in the gingival region. This latter usually occurs in advanced age, when such extensive cutting as would be necessary to involve the occlusal surface would not be justifiable, and where the open interproximal space admits of access from the buccal aspect. The farther rootwise the decay occurs the stronger the argument for filling without extending occlusally, on account of the better facility for approach and the greater thickness of the occlusal wall.

But in ordinary caries occurring near the contact point, and with the teeth standing in line one against the other, the rule should be to open the cavity to the occlusal surface. The reasons for this lie in the fact that in such cases access cannot be gained to do perfect work short of very extensive separation, and then when the teeth have been so separated and filled, and have fallen back to their original position, an element of danger to the filling remains on account of the margin of the filling being too near the contact point. The reason that decay begins in this locality in the first instance is because a certain area of the tooth-substance is left exposed to the action of micro-organisms, undisturbed by friction of the tongue, cheeks, the tooth-brush, or of food in the process of mastication. If the line between enamel and filling be left near the contact point, the same influences which induced the original decay may be expected to act on the enamel at the margin of the filling to bring about a recurrence. If the cavity is extended occlusally far enough to make a clean margin, the occlusal wall is thereby rendered too weak to withstand mastication. All operations performed upon these surfaces without extension must therefore be considered in the light of temporary work.

Sometimes such fillings do good service through the care with which they are inserted, coupled with the probable fact that just at this time the patient acquires a partial or complete immunity from caries. Many indifferent operations have received credit for being perfect owing to this very fact of immunity, and, as has already been intimated, the whole question of periodical immunity and susceptibility of our patients in regard to the attack or progress of dental caries should receive more careful consideration than it does. But what concerns us now in treating the present subject is that clinical experience proves most of these small fillings to be temporary, and resort should be had to their occasional insertion with this fact clearly in mind.

The plan of anchorage for such fillings is very simple. There is little stress to dislodge the filling, and all that seems necessary in the formation of the cavity is to make parallel walls surrounding it at right angles with the axial wall, and to bevel the enamel-margins.

Proximo-Occlusal Cavities in Bicuspids and Molars.

Wherever decay has so invaded the proximal surface as to involve the occlusal surface, or wherever it is deemed necessary to open the cavity to the occlusal surface in those cases presenting with this wall still remaining, a new class of conditions confronts the operator. In view of the fact, as already intimated, that most proximal cavities in these teeth must be made to include the occlusal surface, it becomes necessary to study somewhat carefully the conditions governing the treatment of such cases.

The principal objects to be attained in the insertion of this kind of a filling are, first, to check the existing decay; second, to prevent, so far as possible, a recurrence of decay in the future; third, to securely anchor the filling against displacement from the stress of mastication; and, fourth, to so restore the original form of the tooth that it will be maintained in its proper relation with the other teeth and with the gum-tissue filling the interproximal space.

The first of these requirements may be met by simply removing the decay and inserting a filling with perfect margins; and this would seem to be the limit of attainment with many operators.

A failure to recognize other necessities in the case is accountable for much of the disappointment following these operations, through the temporary nature of such a line of work.

The same general rules of extension for prevention apply to these cavities that were given for proximal cavities in the anterior teeth, except that in bicuspids and molars esthetic considerations do not so materially affect the case, and the rules may therefore be less frequently waived on this account. The usual points of recurrence of decay around these fillings are at the gingivo-buccal and gingivo-lingual angles of the cavity, though in cavities left very narrow bucco-lingually the entire buccal and lingual margins may become involved.

Another form of failure, where cavities are narrow in the region of the marginal ridge, relates to a fracture of the enamel at the proximo-occlusal angles. Enamel left in this form is easily broken down by the stress of mastication, causing a break between the filling and the margin. Fig. 51 illustrates a bicuspid with a narrow filling *a*, points of recurrence of decay *b b*, and of fractured enamel *c c*. The line *d* indicates extension to avoid these forms of failure.

The plan of anchorage for these fillings calls for careful consideration along the lines of the most approved mechanical principles, and with a due regard for the location of the filling and the probable stress to which it will be subjected in the process of mastication. The force of mastication varies greatly in different individuals, and the intelligent operator will take cognizance of this and govern his operations thereby.

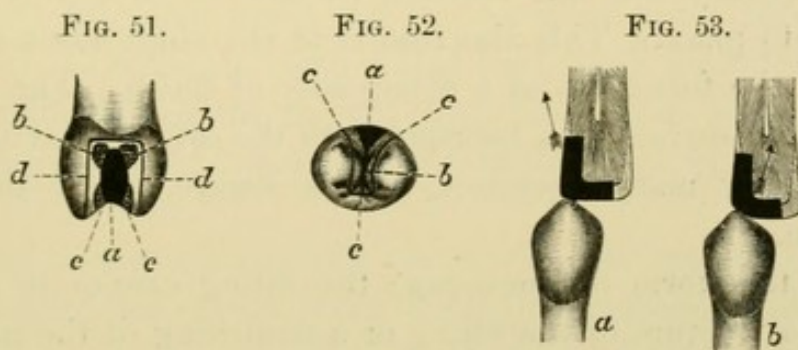
In estimating the probable durability of a filling and the extent of anchorage required to maintain it in place, a careful study should be made of the landmarks of mastication in the mouth under treatment. The expression "landmarks of mastication" is coined for the purpose of directing attention to this form of study. Mastication leaves its marks plainly and indelibly upon the teeth and upon fillings placed in them, and these markings offer a good index for the observant operator to estimate the probable average force exerted in ordinary mastication in a given mouth. The use

of the gnathodynamometer for the purpose of recording the stress of mastication, while very valuable for scientific study and for throwing much light on the possible force of mastication, is not considered to be the most reliable index to the force actually employed in the comminution of food. The greatest possible force that can be exerted in closing the jaws is often far removed from the actual force used in mastication in the same mouth, and is not invariably relative to it. For this reason, if we accept it as our sole guide for the extent of anchorage required for our fillings, we shall in some instances subject our patients to unnecessarily broad and painful cutting to accomplish an object which might have been attained by less heroic means. On the other hand, we may sometimes fall short of adequate anchorage in those cases where the gnathodynamometer gives a low record, but where the actual wear and tear on fillings in mastication is somewhat severe.

It is true we should aim in all cases to anchor our fillings in such security that the greatest possible stress of which the jaws are capable will not dislodge them, but the conditions under which we are compelled to operate will not invariably permit it. The requisite bulk of tooth-tissue is not always left for us by the carious process, and the sensibilities of our patient must also be considered. The same statement is true here which was used in connection with cutting cavities in anterior teeth, that we must not jeopardize the nervous system of our patient to follow out some heroic theory. The fact of ignoring the patient in these matters by a blind pursuit of an ideal in the mind of the operator is accountable for much of the aversion experienced against the dental chair, and we must have a care not to discourage people against permitting dental service to be done for them by too great a degree of severity during the operation. This does not imply that we must be slipshod in our methods, or that we must at all times avoid giving pain. It is occasionally necessary to give pain, but the operator should carefully study his patient and limit the discomfort to a reasonable degree of tolerance. (This matter will be considered more in detail in a subsequent chapter on the treatment of sensitive dentine.)

The landmarks of mastication relate to worn surfaces of enamel at points of occlusal contact which are evidently formed by mechanical wear instead of by erosion, to deep indentations in fillings made by repeated and vigorous thrusts of the opposing cusp, and occasionally to fractured and jagged enamel showing evidence of rough usage. If the operator will give a careful study to the condition of his patients' teeth and watch for these markings he will soon be able to tell quite accurately the probable degree of service which a given set of teeth are called upon to do at table, and it will often guide him in his methods of anchoring fillings.

The different plans of anchorage for these proximo-occlusal fillings in bicuspid and molars deserve careful consideration. The



method almost universally employed in the past has been to cut a groove along the buccal and lingual walls of the cavity, and in some instances to groove the gingival wall. The limitations of this method relate to the insecurity of such anchorage against heavy stress, and to the danger of weakening the walls, particularly in those cases where the buccal and lingual outlines of the cavity are sufficiently extended for safety against recurrence of decay. Unless the grooves are very broad and deep—a condition disastrous to cavity-walls—any tipping stress on such a filling will tend to lift it slightly away from the axial wall, leaving a leak along the filling at that point. Then, again, the occlusal aspect of this form of filling is ordinarily unsatisfactory. In bicuspid especially the filling encounters a fissure running mesio-distally between the cusps, and leaving at the junction of the filling and fissure a shoulder on the filling impossible of perfect finish, and an element

of weakness in the probable recurrence of decay along the fissure. As has already been stated, a fissure is invariably a defect in the tooth whereby two islands of calcification have failed to coalesce in its development, leaving a break in the continuity of the enamel at that point and a crevice for the ingress of deleterious matter. It should therefore be the constant rule that whenever a cavity on the occlusal surface of a tooth encounters a fissure, the fissure should be drilled out to its extreme end and included in the cavity.

What would appear to be a much preferable method of anchorage to that just considered, and one offering greater security to the filling, is to create a step on the occlusal surface of the tooth at right angles with the proximal portion of the cavity, and extending sufficiently into the occlusal surface to effectively lock the filling into place. This also results in the obliteration of the fissure and the formation of a filling easy of finish. Fig. 52 shows the occlusal surface of a bicuspid with the original cavity *a*,—the form left by many operators,—*b* the fissure, and *c* the line of extension.

With this form of anchorage the filling cannot be displaced short of a fracture of the filling or a stretching of the material at the point where the proximal portion joins the occlusal, through repeated impacts of the opposing cusp in mastication. To prevent this the cavity should be made deep enough at this point to allow of sufficient bulk of filling-material for strength, and the material should be thoroughly packed and well condensed to give it the greatest degree of resisting power.

Another point in connection with the dislodgment of these fillings relates to the form of the occlusal surface of the filling and also the form of the cusps on the opposing teeth. While the general rule holds good that in the formation of fillings they should be made as nearly as possible to reproduce the original form of the tooth, yet in these proximo-occlusal fillings a slight modification of the original form is often advisable. In the natural form we find the marginal ridge of enamel standing more prominent than the enamel between the cusps, thereby receiving greater impact in the process of mastication. If in the insertion of the filling we

reproduce the marginal ridge, we subject the filling to too great leverage at a point where it has a tendency to tip away from its anchorages. This may be avoided by making the filling as high as possible midway between the cusps, and sloping it toward the contact point in such a way as to avoid making a marginal ridge and to present a gradual incline from the highest point between the cusps to the point of contact on the proximal surface. In doing this the occlusal surface of the filling is so presented to the cusp of the opposing tooth that the tendency on closure of the jaws is to force the filling laterally into the cavity against the axial wall instead of lifting it away, as would result if the marginal ridge were reproduced. Fig. 53 *a* shows the section of a bicuspid mesio-distally with filling in place and the marginal ridge reproduced. The cusp of the opposing tooth would tend to tip the filling in the direction indicated by the arrow. Fig. 53 *b* shows sloping filling with the direction of force diverted against the interior of the cavity.

This plan does not materially impair the efficiency of the tooth for mastication, but even if it did lessen the masticating area somewhat it would still be justifiable on the ground that a tooth with its masticating area reduced one-half, but containing a filling safely anchored and enamel so sloped as to avoid fracture, is more valuable than one presenting a full masticating area subject to the danger of filling displacement and fractured enamel-walls. This does not imply that the filling should be made narrower mesio-distally at the contact point than the tooth originally was. For reasons which will appear later the full width of the tooth must be maintained wherever possible. This may result in some instances in the point of contact with the proximating tooth being carried slightly rootwise of the original contact, but if care is exercised this may safely be done without impairing the efficiency of the contact or interfering with the gum-tissue in the interproximal space.

The treatment of the cusps of opposing teeth coming against these fillings is a matter of much importance, particularly with bicuspids. When the sharp buccal cusp of a lower bicuspid

impinges so far into a cavity on the opposing upper bicuspid as to necessitate making the filling too thin for strength, or where it passes so far between the cusps of the upper tooth as to form a wedge capable of splitting the tooth, the tip of the cusp on the lower bicuspid should be ground down so as to shorten it and present a broad surface to the upper tooth instead of a wedge shape. This will result in the formation of a thicker and stronger filling in the decayed tooth, and such a change in the direction of force exerted by the lower tooth as to minimize the danger of splitting its opponent. With a wedge-shaped cusp there is much lateral force exerted buccally and lingually against the cusps of the upper tooth, but with a broad, flattened cusp the direction of force is more nearly parallel with the long axis of the tooth and the tendency to split is lessened. This grinding, if done judiciously, will not interfere with the usefulness nor impair the integrity of the lower bicuspid. The enamel is very thick at that point, and there is little liability to decay, so that this method should be employed quite frequently for the greater permanence of our fillings and the greater safety of the teeth, especially in those cases where the cusps of the lower teeth are very prominent and sharp.

One of the most important considerations in the management of these proximo-occlusal cavities relates to the form of the filling on the proximal surface. It should be so built out to a contour that the tooth will be maintained in its proper position in the arch, and that the gum-tissue in the interproximal space shall be protected and preserved in a healthy condition. When the teeth stand in their normal relation in the jaws they are supported on their proximal surfaces by contact with the tooth next in line, and the interproximal space between these points of contact and the border of the alveolar process is filled with gum-tissue. This gum-tissue has an arched form bucco-lingually, with the crest of the arch near the contact point; and this form facilitates the cleansing of the space by a deflection of the food buccally and lingually in mastication. So long as the contact points are small and the space of normal form and filled with gum-tissue, foreign material will not

find a lodgment in the space. In the comminution of fibrous food, such as meat, the fibers may occasionally be forced between the contact points, but they are not retained there on account of the narrowness of contact. The next passage of food on closure of the jaws in being squeezed out buccally and lingually along the incline of gum will catch them and carry them with it, leaving the space clean.

When decay takes place on the proximal surface and the contact point breaks down, the teeth, lacking proximal support, have a tendency to drop together, forcing the gum from between them and narrowing the space. In cases of extensive caries the teeth may so change their position as to practically obliterate the space

FIG. 54.

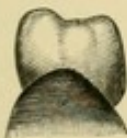


FIG. 55.

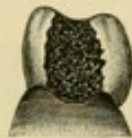

FIG. 56.

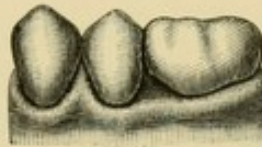
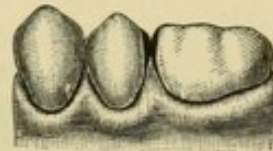


FIG. 57.



and crush out all of the gum-tissue, leaving the buccal and lingual festoons of the gum more prominent than that portion midway between the teeth. This results in an inverted arch to the gum, and produces a pocket between the teeth which is especially favorable to the reception and retention of food *débris*. Fig. 54 illustrates the proximal surface of a sound lower molar with the gum covering it in a normal arched form; Fig. 55, a similar case, with proximal decay and an inverted arch to the gum, forming a pocket. When caries occurs in this way the necessary procedure to restore the gum to health is to wedge the teeth apart to their original position, and then to so contour the filling that they will be maintained there.

If the filling is inserted without this precaution the result is a broad, flat proximal surface to the filling, which will catch fibers of food and retain them to decompose. This wedging of food between teeth is an element of great discomfort to the patient, and a prolific source of failure in these proximal fillings. It not only results in recurrence of decay, but sadly impairs the health of

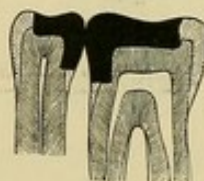the gum and pericemental membrane. No operation should be considered satisfactory which does not include in its performance a due regard for the form of the interproximal space and the health of the gum-tissue within it.

The attempt to prevent food from wedging between teeth by making broad contacts built tightly against the proximating tooth usually fails in its object through the fact that contact cannot in this way be made so perfect that at times the individual movement of the teeth one against the other will not result in the passage of fibrous food between them. When it once makes its way between the filling and the proximating tooth, it is firmly held there by the broad contact. The only safe form to give these fillings is to make a narrow rounded contact, sufficiently dense to

FIG. 58.



FIG. 59.



maintain the teeth in position and to preserve its form against the wear occasioned by the individual movement of the teeth. This wear is sometimes quite severe, as is shown by the facets worn in the enamel on the proximal surfaces of many sound teeth. This recalls the fact that these worn facets are often a prolific source of discomfort to the patient, even where there is no decay; and in those cases where a filling is being built in a cavity proximating a tooth with an extensive facet, the margins of the facet should be slightly rounded off to produce an oval form to the surface. The attention of the operator should not be limited to the single tooth being filled, but he should study carefully the adjacent parts, to the end that the teeth and gums in the entire region be placed in the best possible condition.

Fig. 56 shows the buccal surfaces of two lower bicuspid and the first molar. There is no decay between the bicuspid, and the contact is normal and gum healthy. Between the second bicuspid and first molar decay has taken place on both proximal surfaces,

allowing the teeth to fall together and obliterate the space. The congested buccal festoon of gum is shown opposite the original position of the space. Fig. 57 illustrates the same two teeth when wedged apart and contour fillings made to reproduce the interproximal space. The gum-tissue is seen reoccupying the space in a normal condition. Fig. 58 represents the occlusal aspect of the case, with outline of fillings and point of contact. Fig. 59 shows a section mesio-distally at the contact point.

In view of the importance of making contact points of the proper form and size on all proximal fillings, it would seem necessary to study somewhat carefully the precise form and the exact area of contacts found in normally shaped sound teeth. To make an ocular examination of the teeth in the mouth is somewhat misleading. With the teeth standing in line in the arch and the gums filling the interproximal spaces, the appearance would tend to convey the impression that a much larger area of enamel was in contact than is actually the case. The presence of foreign material or even of moisture clinging to the proximal surfaces obscures the vision so that a true estimate can never be made by this kind of examination. Neither will an operator be likely to gain a clear conception of the area of contact by an examination of the teeth singly out of the mouth unless in cases of worn facets, which should not be considered as typical or normal contacts. The variation in the breadth of the proximal surfaces of the different teeth would seem to imply that there must be a like variation in the area of contact, but this is by no means the case.

The fact is that the area of enamel in actual contact even between the broadest molars is normally almost infinitesimal, and the surest means of determining this beyond any possibility of doubt is to take two such teeth that have been extracted, and, placing them together in the same relation to each other which they sustained in the mouth, hold them up to the light with the buccal surfaces presented to the operator. It will be seen at what a minute point the light is obscured by contact,—a point so very small as scarcely to admit of measurement. Now turn the teeth so that the occlusal surfaces are presented to the operator

and a similar result is apparent, or if possible intensified. This is an object lesson in the area of contact between teeth at once so apparent and so vivid that the experiment should not be ignored by any dentist who is called upon to fill cavities in these surfaces.

This must not imply that all proximal surfaces have the same form, or that the contact points are located in the same place on all teeth. A close study of the anatomical features of the proximal surfaces of the different teeth will reveal a great variation in form, and this variation should be respected in the building of fillings. For instance, a lower second bicuspid usually presents a proximal surface somewhat rounded bucco-lingually at the contact point, and sloping away from this point buccally and lingually with a relatively equal degree of curvature. This brings the contact point nearly midway between the buccal and lingual surfaces, and calls for a generally rounded form to the filling. On the contrary, the upper first molar presents on its mesial aspect a greatly flattened surface with the contact point located much nearer the buccal than the lingual surface, and sloping away abruptly toward the buccal and gradually toward the lingual. Speaking in a general way, it will be found that in making the contact point on fillings the distinction should be made between the upper bicuspids and molars and the lower ones, that on the former it should be located much nearer the buccal than the lingual surface, while on the latter it should be more nearly midway between the two. The location of the contact point occluso-gingivally is quite uniform in both jaws, the common rule being to find it near the occlusal surface sloping abruptly with a sharp curve toward this surface and falling away gradually toward the gingival.

There is often a marked difference between the prominence of the contact point on the mesial and on the distal surfaces which applies to both the upper and lower teeth, the distal surfaces usually presenting a bolder and more rounded prominence than the mesial, and therefore curving sharply to the gingival. This results in such a form to the interproximal spaces that they incline with their apices directed somewhat backward, and their mesial boundary a trifle larger than their distal.

To gain the most intelligent idea of the actual form of the interproximal spaces and the variations in the proximal surfaces of the teeth, a close study should be made of a well-formed jaw from a skeleton with the teeth in their normal position in the arch. An examination of such a jaw from the buccal, the lingual, and the occlusal aspects will place the operator in a more enlightened relation to the subject than can be attained in any other way.

In judging the area of contact between teeth in the mouth or between fillings, the most convenient test is the ligature. If a ligature be passed between the proximal surfaces of teeth having normal contact points it will bind quite tightly near the occlusal surfaces as if meeting a sudden obstruction, but this obstruction is narrow and the ligature readily springs past it under pressure, and moves back and forth with the greatest freedom in the interproximal space. In lifting the ligature out of the space it should pass nearly to the occlusal surface before being engaged by the contact points, and should then come out from between the teeth with a sudden snap. If the ligature drags in passing the contact points, or if it is frayed against the surfaces, the contact is not normal whether it be on a filling or on a tooth.

Separating the Teeth.

In those cases where the decay has not progressed very far and where there has been little breaking down of the contact point and consequently no dropping together of the teeth, sufficient space may often be obtained by the separator, the proper use of which has already been indicated. But where any considerable movement of the teeth is necessary it is more safely and comfortably accomplished by gradual wedging. The same system may be employed as was advocated for anterior teeth, with the exception that a more extended use may be made of gutta-percha. This substance, if properly employed, is really the ideal material for separating bicuspids and molars, and its more general use would do much to remove the prejudice existing against having teeth wedged.

It may be used in the following manner: The occlusal wall

should be broken down in those cases where it is still standing, and the cavity cleared of *débris* and softened dentine with a few sweeps of a broad spoon excavator. It should then be flooded with an essential oil and the excess wiped out, leaving the cavity-walls soaked in the oil. Gutta-percha should then be packed into the cavity and snugly against the proximating tooth, so that pressure may be exerted between this tooth and the axial wall of the cavity. The gutta-percha should be built up sufficiently for the cusp of the opposing tooth to impinge upon it in closing the jaws, and the repeated impact thus resulting will tend to spread the gutta-percha and force the teeth apart. By this method teeth may be separated with very little soreness, it being the rarest exception for a patient ever to complain of this sort of wedge. The process is somewhat slow, but it may be hastened in emergency cases by first applying the separator and lifting the teeth as far apart as practicable before packing the gutta-percha. Ordinarily without the use of the separator the gutta-percha may be left in a week, and if at the end of that time there is not sufficient space, fresh gutta-percha may be added and the case dismissed for another week.

To economize time in the management of these cases, it is well for the operator, on examining a mouth where several fillings are needed, to select these proximal cases at the first sitting and pack gutta-percha in each of them. He may then proceed with the other necessary work in the mouth, and by the time that is completed some of the teeth thus wedged will be found ready to operate upon. The more stubborn cases may be left till the last, and, if necessary, the gutta-percha may be renewed in these as the other operations are under progress.

Where the cavity slopes so rapidly from the axial wall to the gingival margin as to result in a sliding of the gutta-percha into the interproximal space instead of exerting lateral pressure, the gingival wall should be somewhat flattened previous to inserting the wedge. The gutta-percha will then rest on a broad base and will spread under pressure, exerting force in the required direction.

When gutta-percha is used in this way, or when it is employed for sealing medicaments in proximal cavities or for any temporary purpose, it should be so built out buccally and lingually as to impinge on the buccal and lingual festoons of gum to force them back on a level with the gum midway between the teeth. There are two reasons for doing this. It keeps the festoons out of the way during the operation, thus preventing their laceration by files or finishing strips and affording better access to the work, and it also leaves the gum in the best possible condition for re-occupying the interproximal space after the operation. If the festoons are left higher than the gum between the teeth, it results in an inverted arch or pocket into which food may pack, thus retarding the healthy growth of the gum. If the festoons are pressed back so that they are not lacerated and a favorable form is left to the gum after operating, it will be found that the gum will quickly creep back into the space and occupy it in a healthy condition.

Details of Cavity Formation.

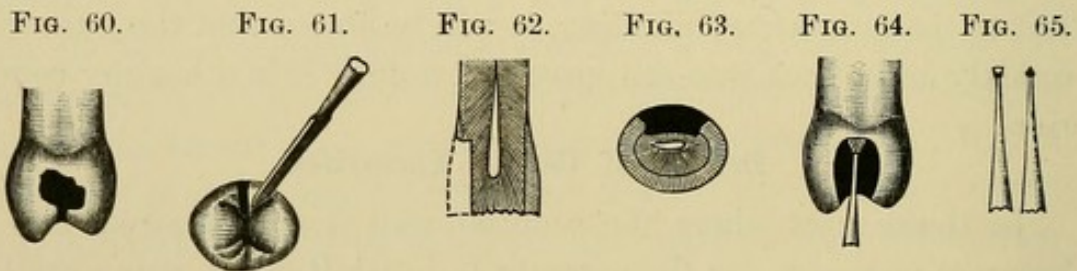
In those cases where the occlusal wall is still standing and it becomes necessary for the operator to break it down, it is a matter of some importance to know how to do it to the best advantage. The arch of enamel overhanging the cavity at this point is often strongly resistant, and if the attempt is made to crush it in with a chisel, as is frequently done by operators, the result is ordinarily a somewhat severe shock to the patient. This shock, coming in the early stages of the operation, has a tendency to unnerve the patient and create an apprehension which often lasts through the entire sitting. As has already been intimated, all unnecessary violence must be avoided, particularly when the patient first takes the chair.

To open these cavities comfortably, a slot should be drilled through the arch as illustrated in Fig. 60, which practically removes the keystone of the arch and destroys its main support. If a small sharp drill be used, with the engine revolving rapidly, this slot may be made without appreciable discomfort, and the enamel may then be broken down with a chisel, as shown in Fig. 61.

The chisel should be held at the angle indicated and pressed firmly against the enamel to prevent gliding. If the proper angle be maintained, it will require only the slightest tap of the mallet to break the enamel away. Chisels for cleaving enamel should be made keenly sharp, so that they "bite" into the surface immediately at the point where they are held, instead of sliding along the surface with a grating, rasping sensation so distressing to most patients.

After the cavity has been thoroughly opened, the walls may be formed as follows:

The gingival wall.—The margin of this wall should be extended far enough rootwise to carry it well under the gum in accordance with the outline in Fig. 51. The degree of extension will



differ in different cases. In those teeth where there has been little decay and where the gum fills the interproximal spaces normally to the contact points, it will not require much extension to bring the margin safely under the gum, but in mouths where the gums have receded in the spaces and where the tendency to proximal decay is great, it will call for more extensive cutting to insure a permanent operation.

The form of the wall bucco-lingually should be flat, and it should be made wide enough in this direction to furnish a broad base for the filling to rest upon and to bring the gingivo-buccal and gingivo-lingual angles to a point of safety against recurrence of decay. The wall should also be flat mesio-distally, and it should join the axial wall at right angles. In some instances, where great security of the filling is required, or where it may seem difficult to start the filling, the wall may be made to dip slightly rootwise as it approaches the axial wall, but a groove should not be drilled along

the gingival wall, as is often advocated. To groove this wall results in the formation of a ridge of tissue along the margin of the cavity, against which it is difficult to adapt gold without injuring the enamel.

As the gingival wall joins the buccal or lingual wall it should form a distinct angle in the axial region, but should execute a short curve at the enamel-margin. The angle thus formed in the gingivo-linguo-axial corner of the cavity forms an excellent means for securing the first pieces of gold in position, and the general form of the gingival wall when shaped as just outlined affords a base upon which the filling may be built without danger of the gold rocking under the plugger-point. A rounded gingival wall, or in other words a curved base, is responsible for much of the difficulty experienced by some operators in starting these fillings.

The width of the wall mesio-distally must be governed by the extent of tooth-tissue available. The cavity should have as wide a base as possible without endangering the pulp. In this connection the location of the pulp-chamber in the various teeth should be carefully studied by the operator, so that he may judge intelligently how far he can extend his cavities with safety. Fig. 62 illustrates a section of a bicuspid mesio-distally with the form of the gingival wall.

The buccal and lingual walls.—As already intimated, the form usually given these walls by operators is to groove them with the idea of anchoring the filling,—the limitations of which method have already been pointed out. There are some cases, it is true, where these walls must be made to sustain the filling; such, for instance, as lower first bicuspids with an exceedingly long buccal cusp and a diminutive lingual cusp joined by a perfect fusion of enamel. In these cases we have no opportunity for creating a step on the occlusal surface, and really little necessity for doing so, owing to the conical shape of the teeth and the consequent limited tipping stress on the filling. The occlusal surface of a proximal filling in one of these teeth presents a sloping surface to the cusp of the upper tooth, and there is practically no leverage to dislodge it. A slight buccal and lingual retention in the form of

shallow grooves in connection with a broad, flat seat or gingival wall is all that is required to retain the filling.

But for ordinary cases grooving along these walls should be avoided; though a possible retentive shape should not be ignored in their formation. This may be secured by making an angle between these walls and the axial wall in such a way that the cavity is slightly wider bucco-lingually at the axial wall than it is at the dentinal enamel-margin. (Fig. 63.) This may be done without materially weakening the walls, and the mortise or dovetail form thus provided is an element of security to the filling. This mortised effect should be carried from the gingival wall throughout the length of the buccal and lingual walls till they approach the enamel on the occlusal surface, where they should merge into the form shown in Fig. 52, *c*. This kind of wall presents a surface against which gold may readily be adapted, and the filling-material once locked between these two perpendicular walls is securely held in place. The building of fillings in cavities thus formed is a very simple matter.

The step.—This should be cut at right angles with the proximal portion of the cavity, and should present a flat base for the filling-material to rest upon. Its width bucco-lingually and its depth pulpally should be governed by the form of the tooth. If it is a short, thick tooth, the step should be made correspondingly wide, with a diminished depth, while if the tooth be long and thin the step may be narrowed and deepened. The object in any case is to secure a sufficient bulk of filling-material in the step to afford strength,—which is particularly true at the point where the step joins the proximal portion of the cavity. The step should be made as wide and deep here as is practicable without undermining the cusps or weakening the tooth between the cusps so as to render it liable to split. Particular study, especially in bicuspid, should be given to this question of splitting in its relation to the depth of the step pulpally. A safe rule to follow is to drill as deeply between the cusps as the fissure extends pulpally, and make the base of the step at this point. This cannot result in any greater tendency to fracture than existed before, because of the fact that

wherever there is a fissure there is no binding strength represented throughout its extent.

The buccal and lingual walls of the step should be made perpendicular, with an angle between them and the pulpal wall. The end of the step most remote from the proximal portion of the cavity should also have a perpendicular form, and the step at this point may often be widened bucco-lingually in those teeth having a notable depression on the occlusal surface at the termination of the fissure. This results in a dovetail form which aids in the retention of the filling.

The axial wall.—The shape of this wall will be governed materially by the depth of the decay. Where there is little penetration of the carious process it should be made perpendicular and at right angles with the gingival wall. In cases of deep decay with a concave axial wall it may be well to create a new axial wall with cement, which will afford protection to the pulp and give a better form to the filling. The cement should not be built out so far as to result in leaving the metal filling too thin for strength. Veneer fillings of this character cannot be depended on for extended service. The axial wall should never be left sloping from the step to a narrow gingival wall, on account of the tendency of the filling to shift under stress when built against an inclined surface such as this would present.

The enamel-margins.—The buccal and lingual margins should be beveled to a greater extent than in any other part of the outline of the cavity. The gingival margin need be beveled but very little on account of the lack of lateral violence against such a surface, and also because of the difficulty of producing a perfect bevel in this region and building the gold over it. On the occlusal surface the slope of the enamel down to the cavity-margin and the proper shaping of the walls result in a margin which requires very little beveling by the operator. Care must of course be exercised that in forming the margins no overhanging enamel be left. If the slightest ledge of unsupported enamel is allowed to remain, it will quickly be fractured by the stress of mastication.

Technique.—In opening the cavity all friable or overhanging

enamel should be broken down by chisels, and in this connection some study should be made of the proper angle at which a chisel must be held in order to cleave enamel to the best advantage. Enamel will bear appreciable pressure without fracture if the force is exerted upon it in certain directions, but a slight deviation of the force may be made to result in a ready parting of the enamel-prisms. Advantage should be taken of this characteristic of enamel so that overhanging walls may be broken down with the least possible force. Little can be definitely taught as to the precise angle at which the chisel should be held for the best results in varying cases, but the observant operator will readily learn to detect the vulnerable points in overhanging enamel and know best how to attack it.

The character of the force exerted on the chisel also becomes important. Wherever an angle of enamel is to be broken down or where there is any appreciable bulk of tissue to be cleaved away, it is best and most comfortably accomplished by a sharp, decisive blow of the mallet on the chisel. But where it is merely a question of cavity extension or a trimming of ragged or frail walls, hand pressure on the chisel is preferable. When used in this way care should be exercised not to allow the chisel to slip into the cavity and impinge on sensitive tissue. The hand should be guarded and kept under perfect control by bracing the ends of the fingers—the ones not used in holding the chisel—firmly against the teeth. This work may in certain positions be best accomplished by grasping the chisel in the palm of the hand and allowing the end of the thumb to rest against the teeth as a brace.

The next step is to give form to the cavity-walls. An inverted cone bur of sufficient size to cover the gingival wall mesio-distally should be placed with its end on this wall, as illustrated in Fig. 64, and carried buccally and lingually along the wall till the proper extension is reached. This will give a flat form to the gingival wall and create an angle between it and the axial wall. Care should be exercised that the blades of the bur do not penetrate too close to the pulp. The buccal and lingual walls may often be extended with the same bur by carrying it up and down along these

walls,—cutting with the side of the bur. In lower teeth, or in distal cavities difficult of access in upper teeth, an inverted cone bur in the right-angle hand-piece will be most effective. After the walls have been extended with the large bur it will be found that the angles between the buccal and axial or lingual and axial walls, and particularly in the gingivo-bucco-axial and gingivo-linguo-axial corners, are not sufficiently well defined. A smaller inverted cone bur used in the same way may be carried into these angles to deepen them, and if a still sharper angle be required it can be made with hatchet or hoe excavators.

As the small inverted cone bur is being used along the gingival wall it should be carried laterally somewhat into the buccal and lingual walls at this point and then withdrawn a short distance crownwise along the gingival third of these walls. This will result in an angle or pocket into which the first pieces of gold may readily be secured. Such a form as this is especially serviceable for beginners, who may otherwise find difficulty in starting these fillings. If there be much softened dentine along the axial wall it may be removed with spoon excavators.

In forming the step, the fissure on the occlusal surface may be opened up with a small drill, a suitable form for this purpose being readily made from a worn-out inverted cone bur by grinding it on two sides to a sharp edge, as illustrated in Fig. 65. This form of drill, small in size and ground sharp, may be made to walk directly through between the two plates of enamel bordering a fissure by revolving the engine rapidly and swaying the hand-piece back and forth, so that the sharp corners of the drill effectively bite into the enamel. When a narrow trench is thus made it may be widened with a chisel, after which the floor of the step may be formed with an inverted cone bur stood with its end on the step. This results in the desired flat base to the step, while the sides of the bur give form to the walls.

The gingival enamel-margin may be given the slight degree of bevel necessary with suitably formed chisels or long-shanked excavators. Sometimes in cases of good access a round bur may be passed along this margin to advantage. For beveling the buccal

and lingual enamel a thin, sharp chisel may be used to plane down the peripheral margin, but what is far preferable in those cases where it can be used is a sand-paper disk in the engine. This, if held at a definite angle, will give the required bevel, and will leave a margin clearly cut, symmetrical, and smooth. Care must of course be exercised not to round the margin with the disk by swaying the hand-piece as the disk is revolving.

General Considerations.

While the form of cavity here recommended is believed to be the best adapted for the majority of cases applying to the dentist, it is acknowledged that there are many instances where it cannot well be followed out in all of its details. The extent of the decay is sometimes so great as to determine the shape of the cavity-walls, and where there has been much undermining of the tissue the operator is left to make the most of the opportunities presented; but the principles involved in cavity formation should never be lost to view, and every cavity should be made to conform to them as accurately as the case will permit.

A distinction is sometimes made in these cavities between those intended for gold and those for amalgam. So far as the general form of the cavity is concerned, there should be no distinction, except that for amalgam more extensive anchorage is usually required than for gold. Gold if properly condensed is so stable and uniform in its behavior that it may be depended on to remain placed in a cavity where amalgam with its freaks and fancies will too often prove insecure. With most of the amalgams in use it requires a much greater bulk of the material to stand a given stress than it does of gold, and the anchorages must therefore be broader and deeper, and the bevel of enamel along the margins not quite so great. With these exceptions the plan of cavity formation should be the same.

One feature relative to the security of these fillings in bicuspid and molars should not be overlooked in estimating the extent of anchorage required. It is too often the case that operators insert these fillings without an adequate study of the kind of service they

are destined to perform. Even if they stop to consider the force of mastication in its relation to the extent of anchorage, it is usually only with the idea of a given number of pounds pressure which may be exerted on the filling, and the probability of a certain area of anchorage withstanding such a pressure. They do not consider in its full significance the feature of aggregate service. It is the constant dripping of water which wears away the stone, and in anchoring these fillings we must provide against a series of masticating impacts so numerous in extent as to stagger one who has not studied the matter. Persons vary greatly in the number of occlusions they make during a meal, as they do in the degree of force used in masticating, but a somewhat close observation would lead to the belief that for the proper mastication of an average dinner the individual will make at least one thousand distinct occlusions, and in many instances it will greatly exceed this. Let us stop to consider what this means for our filling. Suppose one-half of these impacts fall on one side and that one-half of these come against the filling. This is really a low estimate, because many persons will manage a bolus of food on each side of the mouth at the same time, and this bolus will extend over several teeth. At a moderate computation each meal will result in nearly three hundred impacts of food against the filling, varying in force and character according to the habit of the individual and the nature of the food. When it is remembered that this process is kept up three times a day for three hundred and sixty-five days in the year, it will soon become manifest that our fillings must be anchored against some pretty severe usage, and, with such a reckoning as this constantly before him, the conscientious operator will proceed to his work with the greatest care and thoroughness to the end that it may be made as permanent as possible.

A close study of the process of mastication in the operator's own mouth in its relation to this subject is strongly recommended. The nature and extent of the force used, together with the manner of its application in the comminution of different food materials, are fit subjects for careful observation; and an intelligent comprehension of the forces at work in the performance of mastication

will place the operator in a better position to render the most perfect service.

Buccal, Labial, or Lingual Cavities.

All cavities occurring in either of the three surfaces—buccal, labial, or lingual—call for similar treatment so far as the principles of cavity formation are concerned, except the small rounded cavities having their origin in the pits on the buccal surfaces of lower molars and the lingual surfaces of the upper anterior teeth. These pitted cavities are quite distinct in character and environment from the ordinary buccal and lingual decay occurring near the gum-margin, and their preparation is so self-evident as not to call for any extended or detailed description. The fact that they are usually the result of structural imperfections in the tooth at the point of decay, and that they occur in surfaces which are ordinarily readily cleansed by friction, renders it necessary only to remove the carious and imperfect tissue, secure good margins, and give a mortised form to the cavity. No extension for prevention is required in these cases.

But where decay occurs near the gum-margin and extends in a crescent form, following the outline of the gum along the surface of the tooth, the problem of its control becomes more complicated. These are sometimes accounted the most difficult of all cavities to deal with, and yet if properly managed they will respond to treatment with most gratifying results.

The cavity outline.—The proper marginal outline of the cavity becomes a matter of vital importance in its relation to the probable permanence of the operation. The reason that many of these fillings fail so early after their insertion may be traced to the fact that in the preparation of the cavity the margins are not extended to include all of the affected enamel. If we study the manner of progress of this form of decay, it will enlighten us greatly as to the necessities of the case in treatment. Occasionally we may find these cavities well defined in outline with a notable penetration of decay at a given point, and when such is the case with a surrounding surface of perfect enamel our method of procedure is clear. We need very little extension of the margins.

But in the vast majority of cavities occurring in these surfaces it will be found that the area of decay is ill defined, and that the enamel is more or less disintegrated along the surface leading from the cavity and following the margin of the gum. This affected enamel must invariably be included in the cavity outline and replaced by filling-material if we are to be assured of permanent results. The fact that disintegration has commenced is conclusive evidence that the active agent of caries has found this particular point of the surface a suitable field upon which to work its destructive processes, and the assumption is clear that unless the conditions are radically changed the process will continue. The surest method of changing the conditions is to remove the area of tissue upon which the micro-organisms of caries are known to act, and replace it with filling-material upon which they cannot act. This one fact that enamel is vulnerable to the attack of micro-organisms, while filling-material is not, should give us a clearer conception of the required line of treatment in all those positions which are subject to the influence of the destructive agent. The broader we make our metal surface at the expense of the enamel-surface, the more certain we are to avoid a recurrence of decay, and yet this does not imply that we must ruthlessly or ill-advisedly carve away sound enamel for the purpose of making a broad metallic area. It simply implies that we shall not stop short of reaching perfectly sound enamel in the extension of these cavities, and that particularly in positions suitable for the lodgment of micro-organisms we shall be especially thorough.

The surface of the enamel surrounding one of these cavities must be critically examined for defects. Sometimes a crescentic line of discoloration extends from the cavity in such a manner as to confuse the operator with regard to the true condition of the enamel under it. It may be simply a discoloration on the surface, with sound enamel below it, or the enamel may be softened to considerable depth and the discoloration tend to hide the defect. The only way to determine the true condition of the enamel is to thoroughly polish away the discoloration with pumice carried on a brush in the engine. If the brush succeeds in removing all the

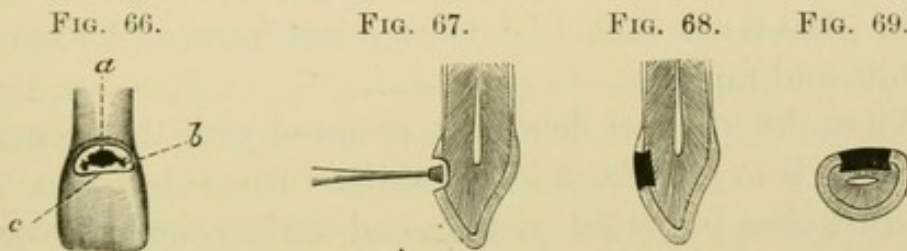
discoloration, leaving a white and glistening surface to the enamel, we may know that the destructive agent of caries has not yet affected it; but if the enamel shows disintegration on its surface after the brush has been used, we must cut out this disintegrated tissue, even if it has not already penetrated the entire depth of the enamel.

The proper extension of the cavity rootwise involves the carrying of this margin well under the gum. There are two reasons for this,—first, the one already given in connection with proximal cavities, that wherever the filling is carried under the free margin of the gum there will be no recurrence of decay at that point, and second, that the gum is more likely to remain healthy when overlapping a smooth gold filling than when overlapping tooth-tissue, particularly if there has been any recession of the gum. This latter statement may appear illogical at first thought, but a somewhat close clinical observation would seem to confirm it beyond any doubt, and a careful study of the conditions will suggest a tenable reason therefor. In all cases where there has been any extended decay it will be found that the margin of the gum has been interfered with in one of two ways. Either the decay has crept up under the gum, leaving the free margin lying in the cavity in an unhealthy condition, or else the gum has progressively receded and is lying against the cementum instead of enamel. In the latter case the gingival outline of the cavity is usually ill defined, with little penetration of the carious process. Under either of these conditions the gum will be found abnormal. If in the preparation of the cavity we press back the gum gently but to considerable extent and make the gingival margin of the filling sufficiently rootwise, we shall find that the gum will rapidly cover it in a healthy condition. Not only this, but in many cases the gum will creep so far crownwise as to cover the neck of the tooth and filling far in excess of its position before the operation. It apparently takes more kindly to a smooth gold surface than it does to cementum which may be denuded, or to enamel which may be slightly roughened. Some extreme cases of this kind of gum-reproduction have been noted, particularly in cuspids, where the

gum has been known to cover the gingival portion of a filling to the extent of over two millimeters. Such results as these are sufficiently gratifying to reward the operator for the necessary expenditure of energy, and the patient for the discomfort accompanying the work.

In Fig. 66 will be seen a central incisor, with the cavity *a* penetrating through the enamel, *b* defective enamel extending from cavity, and *c* the proper outline of filling.

The cavity-walls.—The plan of anchorage for these fillings is exceedingly simple. There is no need for the deep undercutting sometimes resorted to by operators, all that is necessary being to give a mortised form to the cavity by making the axial wall flat



and the surrounding walls at right angles to it. At two points in the cavity it is well to make a slight dovetail to more securely lock the filling into place, viz, at the mesial and distal extremities. To this end the axial wall should be made slightly wider mesio-distally than the orifice of the cavity at the dentinal enamel-margin. This is especially true where amalgam is to be used on the buccal or lingual surfaces of molars. Amalgam requires broader and deeper anchorages to hold it in place than does gold, and this fact should be noted particularly in those cases on molars where the cavity passes so far mesially and distally as to curve somewhat toward the proximal surfaces. These are the cases where amalgam is so often seen to curl away from the cavity at the extremities, admitting a leak around the filling. If amalgam is to be held securely in position in buccal or lingual cavities, it must be placed in broad, dovetailed anchorages.

Technique.—In many of these cavities it will be found that while the enamel is completely disintegrated and dissolved away,

the dentine maintains practically its original form, being simply softened or decalcified for considerable depth without breaking down. This softened mass of dentine is best removed with a hatchet excavator, the blade of which is thin, delicate, and exceedingly sharp. The keen edge of the blade is placed on end at one extremity of the cavity and forced to the full depth of the decay. Then by a dextrous turn the whole carious mass is rolled out of the cavity in one piece, thus removing at a single sweep what is ordinarily the most sensitive portion of the tissue. This, if done skillfully, is usually not a very painful proceeding, but there must be no half measures about it. Any picking or manipulation of the carious mass bit by bit is simply excruciating as well as ineffective. The operator should be at the same time gentle and thorough. His touch should be delicate and forceful, his movements definite and rapid.

When the softened dentine is removed with the excavator the next step is to give form to the walls. This is best done with an inverted cone bur stood with its end against the axial wall, Fig. 67, and carried mesially and distally across the cavity till the desired form is obtained. This kind of bur gives the proper shape to the walls and leaves a mortised effect, as shown in Fig. 68. As the bur approaches the mesial and distal walls of the cavity it should be carried somewhat into these walls to give a dovetailed form, as illustrated in the cross-section of an incisor, Fig. 69. In posterior teeth inaccessible to the straight hand-piece the desired result may be attained by using an inverted cone bur in the right-angle hand-piece.

When the walls are formed the enamel-margins may be beveled with a sharp chisel, or, what is preferable when properly used, a round bur in the engine. This must be kept under perfect control and made to follow the margin without slipping out of place. To maintain a bur in its proper position in following the margins of a cavity it is often advisable to let the shank rest on a support or fulcrum formed by some adjacent surface of the enamel. In this way the bur may be accurately guided along the margin so as to cut at any desired angle. A more perfect symmetry may be given

to a margin with a revolving instrument like a bur than is possible with a chisel. This is particularly true of the curves in the cavity outline.

General Considerations.

As has been stated, these cavities are often the most dreaded of any by the majority of operators. That they present elements of difficulty peculiar to themselves is undoubtedly true, but if treated on correct principles they are in many respects the most satisfactory of all filling-operations. The problem of anchorage is exceedingly simple on account of the lack of any stress tending to dislodge the filling. The marginal outlines of the cavity, if properly formed, are comparatively safe from recurrence of decay, through the fact that the gum completely protects the gingival margin and the other margins are kept clean by friction of the cheeks, lips, or tongue. The open aspect of these cavities admits of an accurate placing of the gold and a close scrutiny of the margins to detect and correct any imperfections.

The chief difficulties of management relate to forcing the gum out of the way sufficiently to admit of free working, to keeping the cavity dry, and to the supposed fact that these cavities are usually more sensitive than others. As to the latter complication, it is counterbalanced both for the patient and operator by the rapidity with which such a cavity can be prepared, and the discomfort in the aggregate is therefore not much greater than with other cavities of similar extent. The problem of managing the gum and keeping the cavity dry is simply a question of skill and "knack" which may be acquired by almost any operator who will give a close study to the special requirements of the case. With this skill once developed these cavities are readily brought under control.

Occlusal Cavities in Bicuspids and Molars.

These cavities are usually the result of structural imperfections in the tooth by which the developing islands of calcification, beginning at the tips of the cusps, have failed to properly unite on approaching each other, leaving a leak for the ingress of foreign matter. The chief considerations in the management of these

cases relate to the breaking down of overhanging enamel, the removal of decay, the obliteration of any remaining structural imperfections in the way of fissures extending from the cavity, and the proper retentive form for the filling.

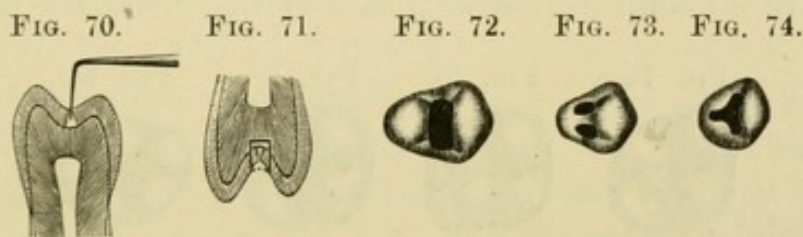
An important distinction between caries occurring upon these surfaces and that of other surfaces already considered is due to the fact that upon occlusal surfaces decay seldom occurs except as the result of defects in the enamel, while on the others it is often found beginning upon perfectly formed enamel. The reason for this is that the friction of mastication very largely prevents the possibility of decay upon the occlusal surfaces, except as the agent of caries is harbored in some crevice or fissure where the cleansing process of mastication cannot reach. On this account extension for prevention is seldom indicated in occlusal surfaces unless the drilling out of all fissures running from the cavity may be so interpreted.

This problem of the treatment of fissures is one indissolubly linked with the management of these occlusal cavities. Many operators do not seem to consider it necessary to drill out fissures unless actual decay has begun in them. They overlook two things,—the difficulty of making a good margin to the filling at the intersection of a fissure, and the real nature of the imperfection that a fissure represents. If an operator has any doubt as to the necessity for drilling out all fissures extending from a cavity under preparation, let him make a microscopical examination of sections of teeth cut crosswise of a fissure, and he will no longer hesitate. In many of these cases where the orifice of the fissure is so narrow as scarcely to admit the finest exploring instrument, the microscope will show a decided imperfection reaching entirely through the enamel, as indicated in Fig. 70. This kind of a break in the enamel-surface is a serious menace to the tooth, and no operator is doing his duty by the patient when he leaves such a defect in connection with his work. It is the minutiae which count in dental practice, and microscopic conditions must not be ignored.

It would be a revelation to many operators to turn the microscope upon cases similar to the ones they are treating every day, and see the numberless imperfections which the unaided eye can-

not detect. One of these fissures, apparently so slight as to be of little moment, and which the blunt exploring instruments in common use in offices will scarcely penetrate, may be found large enough on microscopical examination to admit a whole army of micro-organisms sufficient, if the conditions be favorable, to undermine the tissue in a few months. If we are to successfully combat this disease of dental caries we must be observant and infinitely painstaking.

Another reason for drilling out these fissures and filling them is because the surface of the tooth is thereby rendered more perfect in form. In almost every case where a fissure exists there will be found a somewhat notable depression in the enamel leading down to it, and this V-shaped sulcus furnishes a receptacle for the lodg-



ment of certain kinds of food material, to the annoyance and discomfort of the patient. Berry seeds and other like substances are especially prone to lodge in these depressions, and comfortable mastication is thus interfered with. It should be the office of the dentist to correct, if possible, any faults of form in the teeth he is operating on, and this may readily be done in the case of fissures by drilling them out and building up the filling as illustrated in Fig. 71. This change in the form of the occlusal surface does not in any way detract from the efficiency of mastication, because the biting force of the cusps of the opposing tooth will be fully as effective—if not more effective—when exerted against a moderate concavity such as the surface of the filling would present, as it will when brought to bear upon a V-shaped depression.

The marginal outlines.—The outlines of the different cavities in the occlusal surfaces will vary greatly according to the kind of tooth and the particular conditions present in each case. The number of cusps and the direction of the fissures seem to be the

most prominent factors in determining cavity outline, while the extent of decay is of course always to be reckoned with. What may be considered typical cavity outlines are here illustrated in the different teeth. Fig. 72 shows the occlusal surface of an upper bicuspid with filling in place. This is almost universally the form for these teeth where the slightest decay has begun upon the surface, even if only one pit at the termination of the central groove has been affected. The reason for this is that the groove is nearly always fissured throughout its length, and even when not fissured it is sufficiently sulcate to prevent the proper finish of a filling against its intersection. In lower bicuspids—particularly in the first—the transverse ridge of enamel leading from the buccal cusp to the lingual is often so prominent and so perfect in structure as to leave no central groove, thus dividing definitely the mesial

FIG. 75.

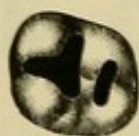

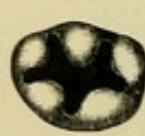FIG. 76.



FIG. 77.



FIG. 78.



and distal pits. In these cases the pits may be filled separately, as illustrated in Fig. 73. In the lower second bicuspid the outline may sometimes simulate that of the upper bicuspids, while in occasional cases we find three cusps on this surface, necessitating the outline given in Fig. 74. In the upper molars there are usually two cavities corresponding to the central and distal pits, as shown in Fig. 75, or the disto-lingual groove may be fissured throughout its length, resulting in an outline such as that in Fig. 76. In cases of extensive decay, where the oblique ridge of enamel between the central and distal pits is so seriously undermined as to jeopardize its stability, it should be cut away and a cavity formed like the one in Fig. 77.

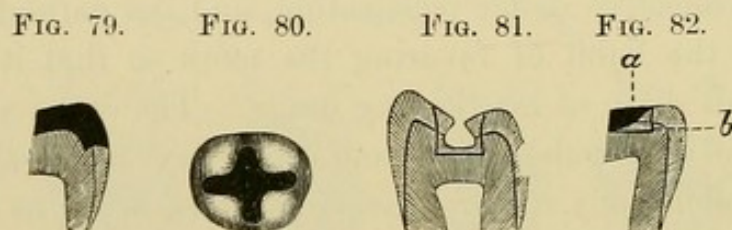
It is sometimes a point of nice distinction to determine whether this ridge shall be left standing or be broken down, the decision being based principally upon two factors,—the extent of dentine supporting it and the depth of the distal groove. If it is not well supported by dentine it will prove an element of weakness between

the two fillings, and if the groove is sufficiently deep to present a notable depression at this point it will leave an undesirable form to the surface. The operator must decide on the basis of long-continued usage in the future rather than from past usage or a temporary service. One condition in this connection is calculated to mislead an unobservant operator, and this holds true as well of other walls on the occlusal surfaces as of the one under consideration. The fact that a certain wall has stood without fracture up to the time of the operation is often accepted as an indication that it may safely be left around a filling. The argument is used that if it has not broken when surrounding a cavity it certainly will not break when reinforced by a filling, but an important factor in the case is overlooked. When a tooth begins to decay it is often more or less sensitive under mastication, and the patient involuntarily forms the habit of favoring the tooth so that it does not receive its full share of masticating usage. The decay progresses till the enamel is so undermined as to leave very weak walls, which may stand indefinitely under these conditions, so far as the stress of mastication is concerned. But when the cavity is filled and the tooth rendered comfortable, the patient gradually begins to use it again, and the consequence is often fractured walls when the operator had judged them to be safe. The highest class of service to our patients demands the closest insight into all of the factors making for or against the success of our operations.

The cavity outlines on lower molars differ from those on upper molars, and there is also a variation between the lower first molar and lower second molar. The lower first molar has five cusps intersected by grooves which are frequently fissured, thus resulting in a cavity outline such as is illustrated in Fig. 78. Occasionally the buccal groove and the disto-buccal groove are fissured throughout their length, which would result in the filling being carried over on the buccal surface to the full extent of the fissure. When this is done the buccal extremity of the cavity should present the form in Fig. 79. The lower second molar, having four cusps, calls for a cavity outline similar to that in Fig. 80. The third molars, upper and lower, are so variable in form as to pre-

clude the possibility of suggesting anything like a uniform cavity outline in either of them, each case calling for special consideration as it presents itself.

The cavity-walls.—The walls surrounding these cavities should be perpendicular, or in line with the long axis of the tooth. The pulpal wall or seat should be horizontal or flat, and should join the other walls at right angles. (Fig. 81.) This is particularly true of the mesial, distal, buccal, and lingual extremities of the cavity. On account of the difficulty of making a perpendicular wall at the termination of a fissure, the cavity extremities are sometimes left as illustrated in Fig. 82, *a*. This is an incorrect form, no matter how well the filling may be anchored in other parts of the cavity. In every case it should be formed as in Fig. 82, *b*. The reason for



this is that the extremities of the fillings formed like that at *a* are likely to be lifted out of place in the mastication of adhesive materials such as candies, etc.

The depth of the cavity pulpally is governed in the carious portion by the extent of decay, and in the fissured portions by the depth of the fissure. It will be found that anything short of a full extension to the depth of the fissure will result in so shallow a cavity as to render the filling-material weak. Numerous failures of portions of these fillings along fissures have been noted in consequence of insufficient bulk of material. There can be no argument against deepening the cavity to the full extent of the fissure from the fact, as already stated, that wherever a fissure exists there is no binding strength to the tooth throughout its extent. The certainty of determining definitely just when the bottom of a fissure is reached is sometimes rendered difficult on account of the fine particles of tooth-tissue from the drill filling the deepest portion of the fissure and hiding it from view. This may readily be

overcome by flooding the cavity with one of the essential oils, which will cause the fissure to immediately show up dark and presents its entire outline.

The width of the cavity bucco-lingually or mesio-distally in the decayed portion must be great enough to insure strong, well-supported walls, while in the fissured portion it must be governed somewhat by the extent of the sulcus leading down to the fissure. The minimum width in any case should be not less than one and one-half millimeters. The mistake of leaving too narrow a cavity relates to the difficulty of readily securing adaptation and density of gold in a constricted crevice, besides the important factor of providing for a sufficient bulk of filling-material to represent considerable strength on all surfaces which are subjected to continued usage.

Technique.—All overhanging walls may be broken down with sharp chisels, and the fissures opened with drills as already described. The cavity may be cut to form with an inverted cone bur placed with its end looking toward the pulp and carried laterally to the extent required. In cases difficult of approach with the straight hand-piece,—particularly on the lower teeth and the upper teeth of the left side,—the bur may be used in the right-angle hand-piece. Where the decay is extensive the softened dentine should be removed with spoon excavators to avoid unnecessary pulp-exposure. The enamel-margins may be beveled with a round bur. These cavities are cut to form very expeditiously, provided the operator uses sharp burs and goes straight to his work with a definite idea in his mind as to the required outline and form of the cavity before he begins cutting.

General Considerations.

Of all filling-operations in the mouth these should prove the most permanent and satisfactory if properly performed. There is little likelihood of a recurrence of decay around such fillings unless the operator has left imperfections in his work which would invite failure under any circumstances. The wear and tear upon occlusal fillings is sometimes great, but it is confidently believed that with

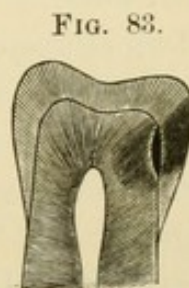the plan of anchorage here outlined ample provision is made for sustaining the filling against severe usage. The flat base to the cavity secures immunity from movement, and the perpendicular walls leave no overhanging enamel to be broken down. The obliteration of fissures results in improved form to the surface and precludes the possibility of micro-organisms finding a habitat in this region. Operations here as elsewhere must be carefully planned and executed throughout, but the results on occlusal surfaces are never so much in doubt as they would seem to be in other localities.

The Treatment of Softened Dentine in Deep-Seated Cavities.

In the preparation of cavities the operator often encounters a problem in the presence of a large mass of decalcified or partially decalcified dentine in the bottom of a cavity lying over the pulp. The treatment of this softened dentine is a subject that has long engaged the attention of operators and writers on dental topics, and the concensus of opinion seems in the past to have been favorable to the retention of a considerable portion of the decalcified tissue for the purpose, as stated, of affording protection to the pulp. It has been argued that the pulp will accept more kindly this sort of protection than it will the presence of any foreign material in the nature of filling or pulp-capping. Some writers have even advanced the theory that the softened dentine would take on a hardening process and become recalcified when left in the cavity under these conditions, and protected from further external irritation by a filling.

Without stopping to go into the histological process of tooth-building and the pathological process of tooth-disintegration, it is safe to assume that tooth-tissue is not amenable to any such a law as would account for the recalcification of dentine once decalcified, and the sooner this idea is dismissed from the minds of our operators the better it will be for their patients. From the closest clinical observation of thoughtful men, and from recent investigations into the penetrating effects of caries of the teeth, it would seem to be a serious menace to leave any considerable quantity of decalci-

fied dentine under a filling. Miller has shown that the tubuli of dentine are packed with micro-organisms far in advance of the actual breaking down of the tissue, and, more recently, Dr. J. Leon Williams has presented to us a revelation in the far-reaching effects of caries. On page 289 of the *Dental Cosmos* for April, 1897, he presents a photograph of which Fig. 83 is a fair representation, showing how a tooth may be affected by the acid of caries to a depth beyond the enamel, and reaching very nearly to the pulp without any serious surface indication. The tooth was one in which "there was not a trace of a cavity to be seen on the external surface." Presumably an exploring instrument might have been passed over the enamel without detecting any imperfection, and yet the acid formed by the mass of micro-organisms lodged upon the surface had so affected the tooth-tissue as to dissolve out the cement-substance between the rods of enamel, leaving minute canals down which the acid traveled to form a perceptible cavity at the junction of the enamel and dentine and also to extend its softening influence some distance into the dentine in the direction of the pulp.



Here is an object lesson to set even the most careless operator to thinking. If the acid of decay may affect tissue to the depth indicated without any perceptible external evidence, what must be the condition of the dentine covering the pulp when the process of decay has gone on so far as to cause a complete disintegration of the enamel and an extensive cavity into the dentine? We can no longer trifle with a disease which projects its baneful influence so far in advance of any ocular manifestation.

Let us study briefly the nature of this decalcified tissue which we are taught to leave under our fillings. It has in large part been disorganized; it is packed with micro-organisms and infiltrated with poisons. If we seal it under a filling we have confined within the tooth just so much of a menace to the life and comfort of the pulp. It will not do to say that the micro-organisms thus inclosed are rendered harmless on account of cutting off their out-

side sustenance and allowing them to die. A mass of dead micro-organisms is by no means inert. In fact, scientists are telling us that from the dead bodies of micro-organisms come the most virulent poisons. Neither will it do to assume that by the application of an antiseptic to the cavity we overcome the difficulty. We may destroy more or less perfectly the micro-organisms in the dentine, but we are not at all certain of thereby destroying the poisons. In experimental work micro-organisms are killed with chemical agents, and then from the mass thus destroyed the poisons are extracted. It would seem to be a fruitful field of research for some scientist to determine the kind of agent required to destroy the micro-organism and at the same time neutralize its poison.

But what concerns us most in the consideration of the present subject is that by following the generally accepted teaching of the day in the management of decalcified dentine we are simply confining in intimate proximity to the pulp a mass of material which is peculiarly calculated to poison the pulp to death. And this is precisely what occurs in many of those vague cases where the pulp has "unaccountably" died under a filling without an exposure. The greatest surprise is that more pulps have not died from this treatment, and it is accounted for only on the ground that pulps are sometimes exceedingly tenacious of life, and protect themselves against the inroads of the poisonous process by throwing out a deposit of secondary dentine. Even in those cases where the pulp finally triumphs over the evil influence, the operation of filling is quite frequently succeeded by an extended period of sensitiveness which is the direct result of the irritating influence of the infiltrated dentine. In almost every instance where softened dentine is left in the cavity as a source of pulp protection, or to prevent shock from thermal changes, it defeats the very object for which it was left. This mass of tissue is exceedingly irritable. It is more sensitive to impressions of all kinds, whether thermal, chemical, or mechanical, than is normal dentine. It would therefore seem theoretically that the less we left of this infected tissue under a filling the more comfortable would the tooth remain after the operation, and this very fact is amply borne out by clinical observa-

tion. In a somewhat close study of this question it has been noted that in those cases where a radical removal of all softened dentine has been effected there is seldom any complaint of subsequent sensitiveness.

This does not imply that we must carelessly expose pulps by wantonly slashing away at every cavity that presents. No operator should expose a pulp if it can be safely avoided. In working around a pulp under these conditions, as has already been intimated, a spoon-shaped excavator should be used to avoid needless exposure. The excavator should be very thin and sharp, so as to peel up the leathery dentine with the utmost delicacy and the expenditure of very little force.

The rules to govern the operator in the management of decalcified dentine may be summarized as follows: Remove thoroughly all decalcified tissue in every instance where its removal will not result in exposure of the pulp. In those cases where it extends to the pulp remove all that can safely be done short of actual exposure, and, if large masses of decomposing tissue surround any portion of the pulp, remove even if it causes exposure. The pulp will be safer under a capping of foreign material than when subjected to the influence of this infected and poisonous mass. Stained dentine is not necessarily infected dentine. If hard and flint-like it may be allowed to remain, even if slightly discolored.

While the exact results of the application of medicaments to decalcified dentine may be as yet somewhat undetermined, it would seem, with our present knowledge on the subject, to be a wise precaution to flood all cavities containing any such tissue with an antiseptic previous to filling. We must also protect the pulp from impingement in those cases where the partition between the cavity and the pulp is so thin as to be compressible under the force of impact by the plugger in condensing a metal filling, or where there seems to be danger from thermal impressions. For this purpose a non-irritating cement is indicated as an intermediate between the filling and the pulpal wall, but this cement must not be built up in such bulk as to render the metal filling too thin for strength.

Hypersensitive Dentine.

This is a subject which has been more or less prominently before the profession ever since teeth began to be filled, and yet it would sometimes seem to be little nearer a solution of the problem than when it was first discussed. This is partly because there are so many varying aspects of the question, and because no sovereign or universal remedy can ever be suggested by which uniform results may be obtained; but possibly, more than all else, because the very thing most essential to success in meeting the trouble is something that cannot well be taught. It relates to a quick perception on the part of the operator as to the real difficulty with each case which presents, and to the most active ingenuity in meeting the particular issue involved. In many instances it would seem to be the dentist who needed treatment instead of the dentine. In others the patient requires operating on in advance of the tooth.

To present this subject in anything approaching a systematic order, it will be necessary to classify somewhat the conditions which may confront the operator. These conditions relate to the varying temperaments of patients, and to the differences in character of sensitive teeth. Patients require the closest study in order to know how best to approach them to dispel the common dread of the dental chair, and no operator is suited to the practice of dentistry who ignores this important feature of his work. It has been too long a crying disgrace to dentistry to permit the impression to prevail among all classes that dental operations are necessarily so very painful. Some of the old-time heroic operators (blessed be their memory) are, in this one particular, blamable that they too often entirely ignored the sensibilities of their patients, and treated them as if they were mere blocks of wood. We of to-day are reaping the results of some of this early sowing in the almost universal dread with which patients approach the dental chair, owing largely to the traditional story of its tortures. In the modern dental practice, properly conducted, there is little to justify this dread, and the dentists of to-day should do all in their power to overcome the impressions formed by past years of mismanagement.

In studying the characteristics of our patients in this regard it

might be possible to make many minute classifications as to conduct and temperament, but for present purposes a more general consideration must suffice.

First as a class may be noted those of a highly-wrought, nervous temperament, who are by nature sensitive to impressions of all kinds, whether physical or mental. This, when augmented by environment or occupation, creates a condition which calls for the keenest perception on the part of the dentist, both as to management of the patient and manipulation of the teeth. They are usually professional men or women,—artists, musicians, sculptors, or literary people,—and, fortunately for us, they are generally individuals of a high order of intelligence. They are quick in their perceptions and are appreciative of skillful service. No dentist of mediocre attainments need hope for an extended practice among this class, and yet, if managed by a master hand, they prove a most desirable clientele. The essentials in meeting these patients relate to a thorough mastery of the minutest details of the work in hand, and a quiet but rapid execution of all manipulative procedures. There must be no false movements, and no lapses of the closest application. To accomplish the greatest good all work must be done on the high-pressure principle. A patient like this will bear to be hurt for one short moment provided something definite be accomplished in that moment, but will not tolerate unskillful puttering. Every line of procedure must be carefully studied by the operator in advance, so that he knows precisely what he is going to do before he attempts to do it. Any awkward fumbling in the manipulation is instantly recognized by the patient, and confidence is to that extent destroyed. The utmost delicacy of touch should be cultivated, and this complemented by firmness of force wherever force is indicated. Short sittings must be assigned, and the greatest possible measure of accomplishment attained during the time the chair is occupied. In brief, this type of individual demands of a dentist the exercise of his keenest wits, and to operate to the best advantage he must operate on a tension keyed to the highest pitch. It is therefore well that all our patrons are not of this variety, and yet, as has been intimated, they prove a savor-

ing lump to the rank and file and are in many ways a desirable class. They stimulate an operator to his best achievements, and reward him with an intelligent appreciation of all that he accomplishes for them.

Another class of patients consist of large, robust, healthy individuals who are by nature cowardly when it comes to the infliction of physical discomfort. They may be brave enough about other affairs of life, but it would sometimes seem that the larger they are in physical proportions the smaller they are in courage to take the dental chair. There is no moral suasion that can be used on these people to make good patients of them. The only line of procedure is to avoid as far as possible giving pain by the use of obtundents, or by employing plastic fillings and temporizing to keep the teeth comfortable, with the hope that eventually we may in some degree overcome their dread sufficiently to accomplish more permanent results. If we undertake anything like thorough work at the outset, we simply drive them away from the dental office to allow the teeth to decay past all recovery. Then when toothache assails them they seek out some dentist who gives gas, and that is the end of that chapter.

Another class relates to those effeminate, irresponsible individuals who have no stamina of any kind, physical or mental, and who require a strong guiding hand to control them in any emergency of life. They are usually forced to go to the dentist either by pain or by the admonition of friends, and their successful management calls for a rare combination of gentleness and firmness. They must of course be assured that the dentist will not hurt them more than is absolutely necessary, but they should also be given to understand that they must nerve themselves against any pain that is necessary. A dentist should never be harsh with any patient, but with this particular class it is sometimes salutary to be stern and to permit of no trifling. If much sternness is demanded during an operation, it should invariably be tempered before the patient vacates the chair with the kindest possible tone of voice, to the end that the patient leaves the office with the conviction that the dentist is kind of heart and is severe only for the patient's good.

A series of dental operations for an individual of this type often proves of the utmost disciplinary benefit, provided the operator is an acute reader of character and knows just when to be firm and when to be gentle.

He should be quick to detect the difference between simulated pain and real pain, from the fact that these patients are much given to protesting even when there is no occasion for it. A simple pressure of an excavator on the enamel of a sound tooth is as likely to cause them to flinch as if a mass of sensitive dentine were being removed, and no self-respecting operator will long allow himself to be made the victim of this kind of folly. He should have the issue out with them immediately on the detection of such imposition, and give them to understand that he is neither to be deceived nor trifled with. But the moment it becomes necessary to give real pain he should be the very essence of gentleness and forbearance, and do all in his power to help the patient over the painful points. In this way he will not only prevent imposition in the future, but will establish confidence in the mind of the patient that he is solicitous only for his patron's welfare. Absolute honesty of conviction and conduct, together with tact in its fulfillment, is the keynote of success with these, as in fact with all other patients.

The management of children in the dental office is another consideration worthy of the closest study. A child never should be given pain if possible on the occasion of its first visit to the dentist. In fact, the infliction of pain should be as largely avoided as may be till a feeling of harmony and confidence has been established between the little patient and the operator. A child should be received in the operating-room with a cheery smile, as if the affairs of the world were very bright on that particular occasion, and that a visit to the dental office was not such a terribly serious thing after all. Unfortunately, children usually come to the dentist with more or less apprehension, owing to the traditional talk about the horrors of the dental chair. It is the prime function of the dentist to dispel this idea, and he who has kindness, tact, and good judgment can work wonders in this direction on that

momentous first visit. But he must have a love of children inherent in his heart or he cannot hope to succeed. He who does not love children would better direct them to some one who does, because of a certainty they will prove a constant source of annoyance to him, and he will accomplish little else with them than to increase their dread and distaste of dental operations.

A child should never be deceived by a dentist under any pretext whatever, and yet it is not well to make prominent the fact that it is going to be necessary to inflict pain. The dentist should lead gradually up to any painful operation by a series of dextrous and careful manipulations about the teeth, and a running talk with the patient upon the contingencies of the case from a child's point of view. The thing of first importance is to establish confident and cordial relations with the patient, and when this is once attained the operator can accomplish really wonderful results, even upon the youngest child. Tact, kindness, the alleviation of pain when the patient is suffering, lack of deception, and short sittings, all harmonize into the successful management of children's teeth.

If the control of the different classes of patients herein briefly outlined is studied, the problem of the sensitive dentine is many degrees more than half solved; in fact, it would sometimes seem as if this bugbear were greatly exaggerated by the profession. A careful observation of the causes which lead the average patient of to-day to dread the dental chair in a properly conducted practice will reveal the fact that it is as much the concomitant annoyances of the rubber dam, the separator, the mallet, the use of disks or finishing strips, the grating of excavators, or the vibration of rotary instruments, as it is the infliction of any real pain in the cutting of sensitive dentine. And yet there are many unmistakable cases of actual hypersensitiveness that must be recognized and dealt with.

The treatment of these cases relates to proper instrumentation and proper medication,—the former fully as important as the latter. The dextrous use of instruments will reduce the number of cases requiring medication to a very narrow limit, and it is strongly urged that a most careful study be made of the manner of ap-

proaching hypersensitive dentine so as to remove it with the least possible discomfort.

Cavities may be divided more or less perfectly into classes, each class presenting its own peculiarities of sensitiveness, and suggesting the method of treatment best suited for it. A large class consists of those cases where there is a mass of softened dentine nearly filling the cavity, with much overhanging enamel. If an instrument is thrust into this leathery mass at almost any point it is sensitive. If there is any manipulation of it along the surface it gives pain. The first thing to do is to break down all overhanging enamel, so that the dentine lies as fully exposed as may be before any attempt is made to remove it. Then, with a thin-bladed excavator, whetted keenly sharp, the whole mass should be removed as completely as possible with one sweep. This can ordinarily be done with little pain if the blade of the excavator be sunk at one side of the leathery mass to its depth, and the mass rolled out. The tissue immediately under this softened layer is usually not so sensitive as the surface, and the remaining cutting to give form to the cavity is seldom appreciably painful. But, in case there is sensitiveness, it can be controlled by dehydrating the tissue with alcohol, followed by warm air. If the rapid dehydration causes pain it should be preceded by ninety-five per cent. carbolic acid, after which the cavity can be dried with little discomfort.

In the application of any medicament to a cavity the fact should be made prominent to the patient that the drug is being used for the purpose of relieving the pain. This of itself reassures the patient, and is often of more benefit in a psychological way than is the specific action of the drug.

Another class of cavity calling for treatment peculiar to the case in hand consists of those shallow oval cavities, particularly on the labial or buccal surfaces, where there is little softened dentine, but merely a corroded and reasonably hard surface to the cavity. Most of the cutting must be done in comparatively firm tissue, for the purpose of giving retentive form to the cavity and to secure perfect margins. These cavities are much dreaded by dentists on account of their traditional sensitiveness, but by a careful observa-

tion it will be found that with very many of them the sensitiveness exists only on the surface. The first touch is the worst. If, when the rubber dam is applied and the cavity dried, the operator will take a sharp inverted cone bur, as already advised for forming these cavities, and, with the engine revolving rapidly, place the end of the bur in the deepest portion of the cavity, and just at that moment speak to the patient in a reassuring tone of voice, and while speaking at once penetrate this outer sensitive crust with the bur, the worst of that cavity preparation is over. The bur may then be carried laterally, its end to the full depth of the cavity and cutting with its sides, causing little pain. The active cutting in the deep portion of the cavity is less painful than would be the slightest manipulation on the surface. The surface should therefore be left alone as largely as possible till the sides of the bur have undermined it in advance. In the successful management of these cases there must be no hesitation and no half measures. The operator must know definitely what he is going to do, and then do it with the greatest dispatch and precision. It requires a masterly, vigorous hand, wielded with the utmost delicacy.

Sometimes the surface sensitiveness of these cavities may be greatly reduced by medication and desiccation. For this purpose carbolic acid, followed by alcohol evaporated with warm air, seems to give the best results with the least accompanying discomfort. The application of drugs which cause more pain on contact with the dentine than would the preparation of the cavity itself should be discontinued, unless for those exceptional individuals who seem to prefer any kind of pain rather than pain given by an instrument.

With very many cavities it will be found that the sensitiveness is confined to one or two small areas, which if dextrously undermined or cut through quickly will solve the problem in short order. When an operator discovers in a cavity one of these sensitive points he should avoid manipulating it, unless with a definite attempt at its complete removal.

The last class of cavities for consideration relates to those occasional cases where the teeth are in an unmistakably hypersensitive condition, where the slightest pressure upon a cavity results in

pain, and where anything like thorough manipulation is out of the question. There is one of two courses to pursue: either to numb the sensibilities of the tooth by cataphoresis, with all of its concomitant paraphernalia, its consumption of time, its accidents, and its as yet undetermined ultimate results, or to employ as a temporary expedient till the sensitiveness subsides some filling-material such as cement, which may be used without the thorough preparation of the cavity required for the metals.

Sometimes one course is indicated and sometimes the other, but in the large percentage of cases it will be found better to make use of temporary fillings to tide the teeth over the sensitiveness, rather than to follow the general employment of cataphoresis. This latter process, unless simplified far beyond its present complications, is indicated only in exceptional and desperate cases, where hope for relief in no other way is possible.

In the use of cement for the sealing of cavities temporarily, as just advised, the common error is made of allowing it to remain too long, till it is so disintegrated as to defeat the object for which it was used. If a cement filling be placed in a very sensitive cavity so as to perfectly seal it from external irritants, and allowed to remain from three to four months, it will be found on removal that the cavity can be prepared properly with little pain. As much of the decay as possible should be removed from the cavity before the cement is inserted, and when the cement is to be drilled out the rubber dam should be applied and the cavity kept free from moisture till prepared as desired. In those cases where it seems impossible to remove the decay in the first instance it is often advantageous to seal a pledget of cotton saturated with the oil of cloves in the cavity for three or four days, when the decay can ordinarily be rolled out of the cavity with sharp excavators.

The whole question of the management of sensitive dentine, except in the rare instances just indicated, resolves itself to the following summary: Manipulative skill on the part of the operator, tact in knowing how to control the different temperaments among our patients, and the invariable use of the keenest, sharpest instruments.

CHAPTER VI.

FILLING-MATERIALS.

A PROPER consideration of the filling-materials in use at the present time leads us at once to the conviction that we have no ideal material with which to fill teeth. We have materials which answer the purpose reasonably well under certain conditions, but no material which answers well under all conditions. It is therefore important that in the consideration of this question we study somewhat carefully the characteristics of the different materials and the indications for or against their use under the varying conditions found in the mouth. This must be done with the fact constantly in mind that no rigid or invariable rule may be laid down for the operator to follow in every case in the selection of his material. He must exercise his best judgment on the basis not only of expediency, but of the history of the various materials under long-continued service.

Gold and Its Combinations.

Of all the materials yet introduced for filling teeth, gold must be acknowledged the peer. When properly understood and properly manipulated, under conditions favorable to its use, it is one of the most permanent materials we possess. It is imperious in its requirements, as are all things worthy, and he who would get the most from its use must adequately acquaint himself with its characteristics. These once understood, and the necessary skill developed to master the details of its manipulation, the operator is equipped with a material which is more reliable than any other, and more definite in results.

Its chief advantages consist in the fact that it may be made sufficiently hard to withstand the wear of mastication; that it is not acted on chemically by the fluids of the mouth so as to change color or disintegrate; that it remains stationary in form when properly condensed, and that it is uniform in its behavior when subjected to uniform methods of manipulation. This latter quality is really of

much greater importance than a superficial consideration would suggest. It enables the operator to attain with it definite results, year after year. It will do to-day precisely what it did the day before, or what it did a year ago. This is not true of most other filling-materials, or at least, if it is true, the requirements for maintaining uniformity in the others are vastly more intricate and not so readily comprehended as with gold.

When it is stated that uniform results may always be obtained with gold, reference is made solely to its physical behavior. It is not intended to imply that teeth are uniformly saved by its use, even when it is manipulated to the best advantage. There are extraneous factors entering into the salvation or loss of filled teeth entirely apart from the intrinsic merits of the material with which they are filled, and gold cannot be exempted from these conditions. But it has a greater range of qualities entitling it to respect as a saver of teeth than any other one material, and its thorough understanding should be the aim of every practitioner.

Its disadvantages may be said to consist chiefly in the fact that it is somewhat exacting in its demands upon the operator; that it cannot be manipulated successfully under moisture; that its color renders it conspicuous for anterior teeth, particularly in individuals of certain types, and that it is a conductor of thermal changes. Another objection which must be considered in some patients is the length of time necessary for its insertion, with its corresponding tax on the individual, and its relative cost; though the fact should be strongly noted that a thorough mastery of the material by the operator will reduce much of this within the limits of tolerance.

Nor must the claim of its exacting nature be held in too high esteem as a disadvantage. This very requisite on the part of gold has done more than any other one thing in developing the skill of the dental profession to its present standard of excellence. Had it not been for gold, or, in other words, had all our filling-materials been of a plastic nature, dentistry never would have developed the brilliant manipulators who have graced its ranks. Gold is the stimulative astringent of the dental profession, keeping our operators keyed up to the highest point of proficiency by reason of its

imperious demands upon their ability. A good gold-worker is enabled to perform all other kinds of dental service as the result of his skill acquired in the manipulation of gold, and this sort of training has been the saving grace of dentistry.

Too many sins which belonged properly elsewhere have been laid at the door of gold. Men have attempted its use without a sufficiently developed skill, or without a proper understanding of its necessities. They have ignored its physical properties and its peculiar demands. Other men have essayed with it the impossible, and then attributed their failures to the material, thus laying gold unjustly at fault.

The fact that gold cannot be successfully used under moisture is neither an unmixed evil nor altogether a disadvantage, when viewed in the light of the greatest perfection of results in our work. No filling, of whatever material, can be inserted under moisture as perfectly as if the cavity were dry, and this necessity of gold simply increases our care and leads to greater certainty of results. It has also made us more expert in maintaining dryness of teeth to be operated on.

The objection of color is a real one in many instances, and the vulgar display of gold in the mouths of the American people is greatly to be deplored. But this may largely be overcome, and the artistic sense of observers less seriously offended than it is without an abandonment of gold in the anterior teeth. A close study of the question will reveal the fact that gold is much more objectionable in some mouths than in others. In certain individuals a well-finished gold filling, beautifully polished without being burnished so as to glisten, is not at all conspicuous, even in an incisor, and not an offense to the esthetic taste of the most exacting. In other individuals a gold filling in the anterior part of the mouth is at best an eyesore.

The difference in the effect of gold upon the appearance of individuals relates principally to the temperament and complexion of the patient, as well as to an esthetic sense on the part of the operator, which may enable him to give his fillings artistic forms. The latter consideration should be carefully studied by every operator,

to the end that gold fillings in the future should not be allowed to offend so glaringly as in the past, particularly in those instances where offense is not necessary. As to complexion, it will be found that decided blondes will tolerate gold in their anterior teeth with less objection than will brunettes. In fact, the color of gold harmonizes so well with the former that if the filling is well inserted there is nothing to offend the eye at a distance of several feet. On the other hand, a gold filling in the mouth of a brunette becomes at once conspicuous and objectionable. It is completely out of harmony with the features, and should never be tolerated except under circumstances of the most urgent necessity. This necessity seldom exists, in view of the fact that we have a material at hand which makes a filling scarcely discernible in these cases at a distance of ordinary conversation. This relates to a combination of gold and platinum which, under its proper head, will be considered in detail. The various gradations from brunette to blonde may be met with gold and platinum by using the different numbers as they come to us from the manufacturer, so that fillings may be made which will not be conspicuous, and every operator should acquaint himself with this material.

The question of thermal influence under gold fillings has claimed much attention from the profession, and there has been a large degree of misconception concerning it. Gold has been credited with more mischief in this particular than its merits warrant; for, while the material itself is a good conductor, it can be used in the mouth with little discomfort and little danger, provided proper precautions are taken. Gold is well tolerated even in large cavities, if the pulp is not nearly exposed, or if there is not hypersensitiveness of the dentine. In the former case the pulp should be protected by an intermediate layer of cement before the gold is inserted, and in the latter case the hypersensitiveness should be controlled by medication previous to filling. Probably one of the best agents for this purpose is ninety-five per cent. carbolic acid.

One important factor connected with this question of thermal trouble relates to a condition apart from the filling itself. In the

past, the profession has been very generally advised to leave in the bottom of cavities of any extent a portion of decalcified dentine as a protection to the pulp, the fallacy of which has already been pointed out. Gold has frequently been severely censured when the chief factor at fault in the case has been the presence in the cavity of a hypersensitive mass of decalcified tissue which should have been removed in the preparation of the cavity.

If these precautions are taken, the trouble from thermal changes under a gold filling will be found for the most part temporary, and not of such serious import as has usually been attributed to it.

The indications for or against the use of gold in filling teeth relate to conditions most of which must be apparent to every observant operator. It should be used in all cases, if possible, where the greatest utility and the greatest permanence are expected of the operation. It should not be used where the conditions are such that it is manifestly impossible to accomplish perfect work with it. The control of the patient, whether young or old, is a necessary concomitant to the successful use of gold. It should not be attempted with a patient upon whom the physical or nervous tax would be too great, nor should it be employed in a tooth the periodontal membrane of which is so greatly impaired as to revolt seriously against the impact of the mallet. In short, the best judgment and the closest discrimination should be exercised to the end that this king of all filling-materials be not crucified by the enthusiastic unwisdom of its chief advocates.

Combinations of Gold with Other Materials.

Gold and Platinum.—This material makes a harder filling and one capable of greater wear than gold alone. It is also—as has been indicated—possible to produce with it fillings of varying degrees of shade which may be made to harmonize agreeably with the different types of patients which come under our hands. These degrees of shade are regulated by the percentage of gold and platinum in the given product. One preparation contains more gold than platinum, another about equal parts, while a third has a

preponderance of platinum, and the color is thereby affected so as to range from a decidedly yellowish to a decidedly grayish tinge. This variation of the material may be used to striking advantage in harmonizing the filling with the features of the patient. The soft gray platinum shade falls in beautifully with the general effect in the mouth of a decided brunette, while the varying gradations from that to a light blonde may be followed with artistic results by a careful selection of the corresponding shades of material.

The combination of gold and platinum should be employed to a greater extent by the profession than it is to-day, for, while its manipulation is somewhat more exacting than that of gold, its intelligent use will lead to artistic results not attainable with gold alone, and its superior density adds greater permanence to the surfaces of all fillings which are in any way subject to attrition. Its manipulation will be considered later.

Gold and Tin.—This combination of materials possesses qualities which should commend it to the favorable attention of the profession. If its limitations are understood and the cases carefully selected for its use, it will prove a source of great satisfaction both to patient and practitioner; and it is therefore worthy of sufficient merit to induce every operator to study its characteristics and master the details of its manipulation. The claim has been made that it possesses no virtues which may not be found in non-cohesive gold, but in two important particulars this would seem to be an error. The tin foil imparts to the mass a quality which non-cohesive gold does not possess, viz, a lead-like consistence which makes the product tougher and more readily adapted to walls of cavities. A plugger-point will not penetrate gold and tin so easily as it will a similar mass of non-cohesive gold; and another important item is the fact that the filling will build up more rapidly under the plugger than will gold with equal manipulation. A filling of gold and tin may therefore be inserted in less time than a similarly condensed filling of gold. But probably the most important difference between this combination and non-cohesive gold lies in the fact that in most instances, after a filling of gold and tin has

been inserted for a time, the material undergoes a change which renders it much harder than it originally was, or than non-cohesive gold can possibly be made. It becomes crystalline in character, so that the filling is an integral mass, with little distinction between the gold and the tin. When it is first inserted, it is easily picked apart; but after several years' service in the mouth it becomes almost vitreous in nature, so that an excavator when drawn across it will respond with a metallic vibration. It has lost its dead softness and taken on a crystalline character which greatly increases its resisting properties and adds to its serviceability.

Its limitations consist in the fact that it will discolor in the mouth, so that it cannot be used in any position where it may be seen, and also that it can never be built into contours or used in cavities of sufficiently large area to bring any considerable attrition of mastication upon it. The indications for its use relate principally to occlusal cavities in molars and bicuspid for children, and along the gingival third of deep occluso-proximal cavities in molars and bicuspid where the main body of the filling is to be of gold. It is especially useful in this latter case on account of materially shortening the operation and avoiding any possibility of discomfort from thermal changes, owing to the reduced conductive properties of the tin in the combination. The rapidity with which it may be inserted renders it a very desirable material in the mouths of children, where the avoidance of the rubber dam is an important consideration.

Gold and tin cannot be expected to do the same length of service as gold in any position where it is subjected to the constant attrition of mastication, and yet many of these occlusal fillings which have been under observation for ten or twelve years give every prospect of long-continued usefulness,—their length of service in most cases being out of all proportion to the limited time necessary for their insertion.

Gold and Iridium.—This combination has gained little attention from the profession, nor has it much to recommend it as a filling-material. By its use a harder surface may be given a filling than is possible with gold, but on being finished it presents a

brassy appearance not pleasing to the eye, and it is therefore applicable only to posterior teeth. Even in these cases there is seldom an instance where gold and platinum will not do equal service and present a more artistic effect.

Amalgam.

This material has been at once the refuge and despair of the dental profession. It has probably saved teeth that never would have been saved without it, but, even in the hands of its most enthusiastic advocates, it has so often proved a disappointment that observant men can no longer remain blind to its limitations. The investigations of Fletcher, Flagg, Bogue, Black, Wedelstaedt, and others have thrown much light on its characteristics; but even with the most that has been learned of it, and the best that has been said of it, the fact remains that much of the amalgam now offered the profession is ill adapted to the permanent saving of teeth. Nor are we likely soon to have in general use amalgams which may be uniformly depended upon,—not because a reasonably reliable grade of amalgam is impossible of manufacture, but because the conditions necessary to produce it are so exacting and the process so intricate that few men will be found sufficiently painstaking to invariably furnish it.

The chief faults with amalgam, as presented to us in the past, have exhibited themselves in a tendency to compress under the impact of mastication, so as to be drawn away from the cavity-walls, but more particularly in a tendency to so change form, even after crystallization has taken place and where no undue pressure is exerted, as to produce a serious leak between the filling and the wall of the cavity. This is frequently exhibited in a decided crack along the cavity-margins, easily visible to the naked eye, and capable of allowing the ingress of deleterious agents calculated to bring about recurrence of decay around the filling. These cracks do not need to be large enough to be seen in order to invite mischief, and very many teeth have been lost in the past as the result of this one characteristic of amalgam. The color of amalgam is also against it, but particularly the fact that much of

the amalgam used by the profession has so changed color after its insertion in the mouth as to render it most unsightly. Neither has the blackening process always been confined to the material itself,—the teeth, in many instances, being so badly stained by it as to remain discolored for life.

These various faults of amalgam have claimed the attention of the profession for years, but no one would seem to have overcome them in any encouraging degree till the investigations of Dr. Black. After the most painstaking study of the physical character of the various alloys, he was finally enabled to produce one which would neither shrink nor expand, and which would sustain sufficient stress to make it reasonably serviceable in the mouth. But the conditions surrounding the manufacture and manipulation of such an alloy are so intricate and so exacting, and the ingredients so sensitive to the slightest variation in temperature or in treatment, that to produce a uniform product from one time to another would seem to be well-nigh beyond the possibility of human attainment. Manufacturers find that an ingot melted from a given formula may give a certain result, while another ingot from the same formula, and apparently treated in the same way, will show a variation in the result. The closest attention to the minutiae is, therefore, necessary all along the line, from the refining of the original metals down to the filing and annealing of the finished product. Even then no one batch of alloy should ever be sent out short of a final test of the amalgam made from it by the most delicate machinery; and, in passing, it may be stated that when these tests are made they frequently prove a source of discouragement to the conscientious manufacturer. Discrepancies arise at every hand where, apparently, the greatest care had been taken with the preparation, and the more this amalgam question is studied, the more it would seem to be hedged about by limitations so great as to be disheartening in view of the immense amount of the material being used at the present day. It would probably be better for the profession and the public if much of the energy which is now being expended on amalgam were diverted to other materials which are capable of more definite and uniform results.

And yet amalgam under existing conditions cannot well be excluded from our present list of filling-materials. It has been too useful for certain purposes, even with its limitations, to be entirely discarded. Its chief utility relates to the building up of teeth so badly broken down or so remotely situated in the mouth as to render the use of gold too exacting, and also to the saving of teeth whose peridental membranes are so impaired as to preclude the use of the mallet. Employed with discriminating care, amalgam may, under these conditions, serve a useful purpose; but it can never hope to attain to the same degree of excellence as a saver of teeth that has long since been established by gold.

Tin.

The statement has often been made that this material does not claim from the profession the attention which its virtues merit, and this is probably true, though it would seem that the combination of gold and tin possesses all of the advantages of tin alone, together with the added virtue of being better able to resist wear on account of its greater hardness.

Tin may be used in one of two forms,—that of foil, or in the form of shavings cut from block tin. The former is perfectly non-cohesive, while the latter, if freshly cut, is said to possess cohesive properties, though tin cannot be built into contours with any assurance of permanence on account of its softness. The indications for the use of tin are practically the same as those suggested for gold and tin,—it being especially useful in any position where it is surrounded by four walls and is not subjected to wear. It is readily adapted to the cavity, will retain its form perfectly, except under pressure, and it is a poor conductor. This suggests that tin may serviceably be employed in simple cavities on all posterior teeth, such as buccal or lingual cavities of limited area, or in proximal cavities which do not involve the occlusal surface.

Cements.

There are three main varieties of cement,—the oxychloride of zinc, the oxyphosphate of zinc, and the oxyphosphate of copper. The *oxychloride of zinc* is indicated in pulpless teeth, for filling the

pulp-chamber after the canals have been previously filled with gutta-percha, and also to form a lining to the cavity under the filling proper. It is seldom indicated in teeth with living pulps, particularly if there is a near approach to the pulp or if there is much hypersensitiveness, on account of its strong irritating properties. Neither can it be relied on for reasonable service in any position where it is subjected to the fluids of the mouth, from the fact that it is so readily dissolved,—this being especially true of proximal cavities at the gingival margin.

The *oxyphosphate of zinc* is an excellent agent as an intermediate under metal fillings in cases where there is a near approach to the pulp,—it being less of an irritant than the oxychloride,—and also for a temporary filling-material in the management of teeth which for any reason may not be in a condition for a permanent operation. Its chief limitation consists in a tendency to dissolve under the fluids of the mouth, though it is not so subject to this fault as is the oxychloride, and there is a considerable variation in its behavior in different mouths. In some instances it seems to wear well for years, particularly if the material used is of superior quality and it receives proper manipulation, but at best it may be accounted only a temporary expedient, and should not be relied on for permanent service,

The *oxyphosphate of copper*, introduced by Dr. Ames, of Chicago, is also somewhat soluble in the mouth, particularly in vulnerable positions; and the fact that it is intensely black in color limits its use to positions not exposed to view. It is especially indicated in remote cavities on the necks of teeth occasioned by a recession of the gum, where the cavity is so ill defined as to make the use of gutta-percha or amalgam difficult. It may be made to adhere to the surface of a cavity very tenaciously, so that little undercutting is necessary, and it will prove an excellent expedient in that particular class of cases for which no other kind of filling seems suited.

Gutta-Percha.

This is a material which deserves more attention from the profession than it has received. In the particular field for which it is

best suited it has no equal, and its uses are varied and unique in the saving of teeth. Its chief limitation lies in the fact that it is not sufficiently hard to withstand attrition, but placed in positions secure from wear it gives most excellent results. It is not dissolved by the fluids of the mouth, and it is one of the best of non-conductors. As a temporary sealing agent in the treatment of teeth it is, without question, the best material we possess. It is especially indicated for the filling of pulp-canals, being non-irritant, impervious to moisture, and readily molded to fit any inequality in the canal. It is also very valuable as a temporary filling-material in connection with oxyphosphate of zinc for proximal cavities, the gutta-percha being used in the gingival third of the cavity and the filling completed with cement. Gutta-percha will not dissolve out under these conditions, as will any of the cements; nor will the latter wear away so rapidly under attrition as will gutta-percha, so that by combining the two materials in this manner in the same cavity the operator gains the advantage of more adequate protection to the gingival margin and a better wearing service on the occlusal portion of the filling.

Inlays.

The discussion of filling-materials at the present time would hardly be complete without a consideration of inlays. The desirability of controlling caries in the anterior part of the mouth, without the necessity for an objectionable display of gold, would seem to be apparent, as also would the possibility of saving badly decayed teeth in any location where the insertion of gold foil is contraindicated on account of too great tax on the patient, or too much infliction on an impaired periodontal membrane by the mallet. Crown-work, as the result of the considerations just indicated, has often been resorted to by operators in cases of extended decay at a period earlier than would make crowning justifiable if some more feasible means could be employed to tide the tooth over a number of years. It is in cases of this kind that inlay work finds its most legitimate field. This would seem to be an intimation that inlays are to be considered more or less temporary in their nature, and from our past experience with them, and our present resources in

their manufacture and methods of setting, this fact must seem undeniable.

It will scarcely do to point to a few isolated cases where inlays have done an excellent and, to all intents, a permanent service, and thereby claim that inlays are in the main trustworthy for extended use. There are principles involved in the process of their manufacture, and in the means employed to secure them in the cavity, which cannot by any sort of skill on the part of the operator, or any sort of reasoning on the part of their advocates, be overcome so as not to interfere with perfection of results. A metal matrix for receiving the material of the inlay, whether it be of gold, or glass, or porcelain, cannot by present methods be so adapted to the walls of the cavity as to prevent the penetration of moisture; neither can it be fashioned to remain firm in the cavity without something to hold it. To overcome these mechanical discrepancies, some material must be used to seal the interstice between the inlay and the cavity, and to retain the inlay in position by reason of its adhesive properties. Up to the present time no suitable material has been discovered which is not open to the objection of being more or less soluble in the fluids of the mouth. It is true that with an expert and careful operator, and a material manufactured and used in the light of the most recent investigations, these imperfections may in some degree be overcome, but with our present knowledge they cannot hope to be entirely obliterated.

If the too enthusiastic advocates of inlays would recognize this fact, and would more carefully discriminate in their selection of cases, the future of inlay work would be more secure than it seems to be at present. There is a useful purpose for it to perform in the profession, but from existing indications it would appear that it is doomed, as many another worthy object, to be made the victim of its overzealous friends.

The cases most suited to the reception of inlays are in cavities on exposed surfaces of the anterior teeth, and in large cavities in bicuspid and molars where filling operations would prove too exhausting. The former should be of porcelain, for esthetic reasons, while the latter should be of gold. Gold inlays are more easily

made than porcelain, and in localities subject to the stress of mastication are much less liable to fracture. They should therefore invariably be used in any position not exposed to view, and it is in this particular class of inlay work that the most satisfactory and permanent results are to be obtained.

It should be a cardinal principle with every operator who uses inlays to so inform his patients on the subject that they shall return at stated intervals for examination of the work, with the expectancy of an occasional resetting, as the result of disintegration of the cement, except in the case of gold inlays where the cavity-margins have been freely beveled and the gold carried over them so as to protect the cement and prevent its solution. To do less than this with our present light on the subject is to be seriously derelict in duty.

A certain class of patients will cheerfully submit to the periodical replacement of porcelain inlays in preference to having an exhibition of gold in the mouth, and yet it may be well just at this point to look somewhat carefully into the probable results of doing too much of this temporary class of work. While some individuals possessed of a high sense of the esthetic and with unlimited patience will follow up this work with the faithfulness its nature demands, the great majority will after a time become wearied and fall by the wayside. This is not conducive to confidence in the profession as to their ability to save teeth, and the general impression on the people will be unfortunate. The enviable reputation which dentistry possesses to-day as a calling capable of rendering unique and lasting service to the human race was not obtained by the performance of ephemeral operations. It is the result of hard, painstaking effort on the part of our illustrious predecessors, whose supreme effort was aimed in the direction of producing such work as would prove of the greatest possible permanence and utility to their patients. It is safe to conclude that it could never have been accomplished by the general use of inlay work.

CHAPTER VII.

GOLD.

Cohesive and Non-Cohesive Gold.

ALL gold for filling teeth should be as pure as it can be made. The distinction between cohesive and non-cohesive gold does not so much relate to its purity as to the condition of its surface. If two layers of gold foil which is perfectly pure and perfectly clean upon its surface be brought into intimate contact at ordinary temperatures, they will cohere. In other words, they will weld cold. Two pieces of gold in this condition cannot be rubbed together without sticking. This is an inherent quality of gold when pure and clean, and it is gold in this state which is termed cohesive gold.

If pure gold foil be exposed to the atmosphere for any length of time, or is brought in contact with certain gases, it gathers upon its surface an imperceptible film, which, while not affecting the purity of the substance itself, interferes with its cohesion. Two layers of foil in this condition may be rubbed together without adhering. This is called non-cohesive gold.

In accordance with this, it might naturally be assumed that, given a piece of pure and clean gold foil, it could be made cohesive or non-cohesive at will, and this is in strict agreement with fact. A pellet of cohesive gold may be made non-cohesive by exposing it to the influence of ammonia gas, and this pellet, thus rendered non-cohesive, may in turn be made cohesive by driving off the gas with heat. It is on this hypothesis that we anneal our gold for filling teeth. But there are some gases which, if allowed to come in contact with the surface of gold foil, apparently cannot be driven off by heat, and thus render the gold permanently non-cohesive. Exposure to the atmosphere under certain conditions for an extended period seems to have the same effect, so that operators who wish their gold to work uniformly fresh and cohesive should keep it protected from the atmosphere.

The difference in behavior of cohesive and non-cohesive gold under the plugger is readily suggested by the characteristics of the two materials. From the fact that with non-cohesive gold one pellet may be forced across another without adhering to it we are able conveniently to carry such gold into corners of cavities difficult of access and secure ready adaptation to walls, but the absence of cohesion between the layers of foil limits us in any attempt to build it into contours. With cohesive gold we have the advantage of giving any desired form to the filling and obtaining increased strength to the mass, with the limitation of greater difficulty in securing adaptation to points not easy of access. This does not imply that adequate adaptation cannot be gained with cohesive gold. Cohesive gold may be adapted to the wall of a cavity with as great a degree of perfection as can non-cohesive, but the method of manipulation is more exacting and less rapid.

From the fact that a pellet of cohesive gold will immediately stick to gold which has already been placed in the cavity, care must be exercised in adding each fresh pellet to locate it in precisely the position where it is intended to condense it. If it is allowed to come in contact with any part of the surface remote from the point indicated, it cannot be forced across the surface to the proper position on account of its cohesion. With non-cohesive gold there is more latitude in this particular, but, properly placed and thoroughly condensed, cohesive gold may be made to seal a cavity perfectly.

Annealing Gold.

Much of the difficulty experienced by operators in the insertion of gold is due to faulty methods of annealing; and, even among operators who are sufficiently skilled to obtain good results by the ordinary methods, there is much to be gained by adopting some of the more recent advances in this important particular. The great majority of operators are in the habit of annealing their gold by passing it through the flame of a spirit lamp or a Bunsen burner,—a method which has serious objections. In either instance we are never certain of always having a pure flame, and if we do not have a pure flame we jeopardize the working quality of the gold. An

alcohol flame is seldom uniform in its character, from the fact that it is so appreciably affected by atmospheric changes. An undue humidity in the operating room will result in a vitiated flame, which shows itself in a yellowish tinge. The presence of moisture in the air always affects this flame, owing to the great affinity which alcohol has for water.

The gas flame from a Bunsen burner is more reliable than the alcohol flame, but it is not without its limitations. The operator is always dependent on the gas company to furnish him a pure quality of gas, and he must watch the burner to keep it in perfect working order if he expects a uniform flame. Even at the best, it is doubtful if gold coming in contact with any flame is not more or less contaminated thereby.

Then the manner of annealing followed by many operators is calculated to give unequal results, even with a pure flame. If a pellet of gold be picked up by the pliers and carried through the flame and then to the filling, as is so frequently done, nearly one-half of the pellet is imperfectly annealed. The portion of gold grasped by the pliers is not annealed at all, and for some distance from the plier-points the gold is kept sufficiently cooled by the points to prevent perfect annealing. This accounts for much of the pitting on the surfaces of some gold fillings. A certain portion of every pellet is left non-cohesive, and when wear is brought upon the filling these little particles which were grasped by the plier-points flake off, leaving an imperfect surface. The operator does not notice this defect while building up the filling because of the fact that the end of the pellet most remote from the pliers is well annealed, and this, coming in contact with the gold in the cavity, adheres perfectly, and the whole pellet seems to mallet down to place in good condition. It is only when subsequent attrition on the filling discloses the flaked surface that the operator realizes there is something wrong with the density of his gold; and even then he is quite likely to attribute it to some inherent defect in the gold rather than to faulty methods on his part. This plan of annealing also occasionally leads to another detrimental effect. The operator, in observing the pellet in the flame, notes that it is

dark in color for more than half its length from the plier-points, and attempts to get a uniform heating by holding it longer in the flame. This results in the overheating of the pellet at the end most remote from the pliers, and the fusing together of the layers of foil at that point so as to present a harsh, unyielding mass, with which it is impossible to do uniform work. If an operator must employ the flame for annealing he would better use the smallest pliers obtainable, and grasp the minute corner of one end of the pellet and pass it carefully through the flame, or near the flame, till the other end reddens. Then, dropping the pellet in the gold drawer, he should pick it up again at the annealed end and gently heat the other one. In this way both ends are annealed; but even then there is a lack of uniformity in such a method, and it also requires unnecessary time and undue manipulation of the pellet before it reaches the cavity. A pellet should be handled as little as need be from the time it leaves the gold-beater till it is placed in position in the tooth.

Another method employed by some operators to obviate the difficulties just indicated is to roll their foil into a rope of suitable size, and then anneal the entire rope, cutting it into pellets subsequently. An objection to this is found in the fact that with a rope of annealed gold the impact of the scissors in cutting the pellets compresses the rope so that there is a line of condensed gold across each end of each pellet before it is placed in the cavity. This may appear a trivial consideration, and yet it is attention to the minutiae which goes to make up the most perfect result in the insertion of gold. A pellet condensed at either end in this way is not so obedient to the plugger, nor can it be so accurately manipulated in the performance of delicate work as can a uniform pellet.

The plan of some operators whereby the plugger-point is used to pick the gold from the drawer and carry it to the flame and then to the cavity, is objectionable in several particulars. Unless the point is heated sufficiently to ruin its quality as a plugger, the gold is never perfectly annealed in the region of the point. If it is annealed at all adequately, the point is made so hot as to be painful to the patient on application to the tooth, and the products of

repeated oxidation at the end of the point are continually being incorporated into the structure of the filling, which, at best, cannot result to its benefit. There is also a lack of uniformity in the degree of annealing throughout the pellet, the ends being invariably heated higher than the part touched by the plugger-point. The same condition exists, though in a modified degree, when a smaller instrument is used for picking up the gold in lieu of a plugger, as practiced by some operators. Another minor objection relates to the fact that when a pellet is annealed in this way it has a tendency to slightly change its form under the flame, so as to drop from the plugger or annealing instrument and fall into the flame.

In view of these considerations, it would seem desirable for the profession to adopt a different method of annealing gold to obtain the best results. The problem to be solved is simply to heat the gold sufficiently to effectively drive off all gases from its surface without the possibility of concurrent contamination, and with absolute uniformity of annealing throughout the mass. Various methods have been devised for this purpose, the one most employed in the past being to place the gold on a mica or metal tray over the spirit lamp, and allow the heat thus generated to gradually accomplish the purpose; but the most perfect method yet suggested is through the medium of the electric gold annealer devised by Dr. L. E. Custer, of Dayton, Ohio. With this appliance complete uniformity of result is obtained in the most convenient and ready manner, and with no liability of contamination. Even to operators who have been accomplishing apparently satisfactory results by other means, this appliance will soon reveal a working quality to the gold which seems impossible of attainment in any other way, and it is confidently believed that its general adoption by the profession would disarm much of the criticism which is occasionally waged against the manufacturers of gold on the plea of lack of uniformity in preparation. The only procedure necessary is to place the pellets in convenient arrangement on the annealer and turn on the current, which may be left running to the end of the operation. No matter how long the current is on, there

is no overheating of the gold. It simply anneals perfectly, without ever fusing any of the layers of the pellets together.

A most satisfactory manner of treating gold from the time it reaches our hands till it is carried to the tooth is to first subject it to the influence of ammonia gas by placing in a small porcelain receptacle a pledget of cotton saturated with aqua ammonia, and setting this in the same drawer with the gold, leaving the box or bottle containing the pellets open, so that the gas may readily act upon them. The pellets are thus rendered uniformly soft, velvety, and manageable. They are absolutely non-cohesive. They may be shaken or rubbed together *ad libitum* without one pellet, even in the slightest degree, adhering to another. When the filling is to be made they should be transferred to the annealer and the current turned on, the result of which will furnish a series of pellets each in its behavior precisely like its fellow. Gold treated in this way has a beautifully soft working quality, devoid of harshness, but capable of perfect cohesion and density under the impact of the plugger.

With gold prepared according to these details, and with the characteristics of its manipulation perfectly understood, it is nearly or quite as easy of introduction into a cavity as any of the other filling-materials, the chief distinction being the greater length of time necessary to insert it. It must be built up piece by piece, while most of the other materials may be added in masses of greater bulk.

For those practitioners who are not convenient to the electric current it is suggested to employ gas for this purpose, by arranging a series of small jets on the same principle as the modern gas cooking burners, whereby the heat may be distributed as uniformly as possible upon a given area, and placing over this a framework supporting a piece of mica or other suitable material to prevent contact of the gold with the flame. On this the gold may be satisfactorily annealed, though not so rapidly nor so perfectly, so far as the regulation of heat is concerned, as by the electric appliance. In case gas is not available the same arrangement may be made with a spirit lamp, but this is slower in its results, and the heat is

less readily distributed with uniformity throughout the surface of the annealer.

It would seem that either of these methods was greatly to be preferred to the one so common in vogue of passing the gold through the flame, and a careful consideration of this entire subject of the proper preparation of our gold for filling teeth is hereby strongly commended to the profession. Gold has almost invariably been credited with the advantage of having claimed a more serious study in its management and a greater care in its manipulation than any other filling-material we possess, and yet in this one particular it would sometimes appear as if it had been strangely misunderstood in its characteristics or ignored in its chief requirements.

Different Forms of Gold.

The form in which gold is used in filling teeth is largely one of individual preference, whether in ropes, pellets, cylinders, or strips. Possibly the best results are obtained by a convenient arrangement of the different forms in the same cavity, such, for instance, as starting the filling with a rope of non-cohesive gold of suitable size and building the main body of the filling with pellets or cylinders annealed, followed by strips of heavy gold upon the surface. Some operators are in the habit of twisting their foil into ropes, and cutting these into pellets for general use. Others, whose methods of operating are highly individualized, cut the foil into strips and roll these into cylinders of varying sizes for the special case in hand. One advantage of this method is that the layers of foil constituting the cylinder are arranged in a regular series, one upon the other, and are therefore capable of a more even placement in the filling than when the pellets are cut from a twisted rope. This even arrangement of the layers of foil in building a filling is an item of some importance in its relation to the strength of the filling and its uniform density, but the element of time in the preparation of these cylinders must also be acknowledged as a consideration with the busy practitioner. The prepared pellets or cylinders of graded sizes and lengths, as they come to us from the manufacturers, would seem to furnish a most convenient form for

the bulk of our work, and these, supplemented on the surface in cases calling for special density with strips cut from Nos. 30, 60, or 120 rolled gold, are capable of producing a uniformly good result. For the rapid-acting mallet, in cases where it may not seem desirable to use the heavier foils, strips can be prepared by folding the lighter foils and cutting them into suitable widths. For instance, a sheet of No. 4 foil may be folded three times, which makes four layers of foil. This fold is then cut into strips of from two to three millimeters in width, making a very convenient preparation for the rapid mallet, tacking one end on the filling and folding it back and forth across the surface as it is being condensed.

For those operators who do not use the rapid mallet and who find the heavier golds inconvenient or difficult of manipulation for surface work, the following method of preparing the gold is strongly advised. The folds just mentioned do not contain a sufficient number of layers of foil to build up with any rapidity under the slower mallets such as the hand mallet or the automatic, but the order of arrangement of the layers is good and should be preserved. To do this take a whole sheet of No. 4 foil and fold it once, having the margins even and the one layer pressed flat on the other. Then fold again in precisely the same way, pressing flat and even, and continue the folding till the width of the resulting ribbon is about five or six millimeters, or a trifle less than a quarter of an inch. This flat ribbon may then be cut into strips from two to six millimeters wide, according to the requirements of the case in hand. Gold prepared in this way will be found very effective in securing a uniformly dense and perfect wearing surface to fillings. The little pads after annealing should be laid upon the filling with their sides flat against the surface and in precisely the position where it is intended to condense them, and each pad should be thoroughly condensed before another is added. If the final one-third of the filling be built up in this way there will be less complaint of faulty surfaces, both as regards wearing quality and appearance.

The form of the different kinds of gold will receive more detailed mention incidentally with the consideration of their introduction into the various classes of cavities.

Crystal Golds.

Crystal gold is prepared by precipitating the gold into crystals instead of by beating it into foil. Its working qualities are somewhat different from foil, and its characteristics must be well understood in order to obtain good results. Some operators seem to have a peculiar aptitude for manipulating this kind of gold, and are able to use it more satisfactorily than foil, but for the great majority of practitioners it can never be relied upon to do the same service as foil in the varying conditions presented in different classes of cavities. Its main virtue lies in its tendency to remain placed in the bottom of a cavity when once forced there. It does not so readily curl away from a wall, or rock under subsequent pressure, as does foil, and it is therefore indicated for starting the filling in those cases where the best retentive form to the cavity at this point has not seemed possible of attainment. It is also more rapidly condensed in a cavity, the filling apparently growing in bulk at a greater rate of speed under the plugger than where foil is used; but this very rapidity of growth may prove an element of insecurity in the constant danger of bridging over spaces and leaving a filling imperfect in density. This may readily occur with a careless operator, while the surface of the filling appears satisfactory. The fact that large masses of crystal gold may be inserted into a cavity and matted down to place with apparent ease is calculated to mislead many operators. These large masses behave much like wet snow under pressure,—they condense on the surface but are inclined to remain porous in the depth of the mass. In order to accomplish good results with crystal gold, and do justice to the material, the very greatest care must be used in its manipulation. It will not tolerate the range of usage that will foil, and unless an operator is prepared to give a careful study to its peculiar requirements he would better not employ it. The chief distinction in this connection between foil and crystal gold is that foil demands care, and so expresses itself at every turn, while the other demands equal or greater care, but seems constantly to give the impression that it does not.

As to the form of crystal gold best adapted for serviceable work,

those preparations in which the deposit has been carried on long enough at one time to produce crystals or spiculæ of considerable length would seem to offer the greatest promise of usefulness, both as to strength of the finished product and convenience of manipulation. A mat of gold formed of small crystals is granular in structure. It is easily disintegrated in handling, and crumbles so as to waste extensively; while a filling made from it cannot be expected to present the same strength in a given mass that would one made from gold of a more fibrous nature. Another important consideration in this connection is that a fibrous gold may be expected to result in better margins to the filling than one of a granular structure. One serious limitation to some of the crystal golds offered in the past has been the insecurity of the material when built over beveled enamel-margins, on account of the tendency to disintegrate and crumble away. The more perfectly the fibrous arrangement is maintained, the greater strength may be expected of the material. Recent improvements along this line in the manufacture of crystal golds would seem to promise an increased usefulness for them in practice, but, as already intimated, no operator should employ them without a perfect understanding of their peculiarities.

The main points to be considered in manipulating crystal gold relate to accuracy in placing each pellet as it is carried to the cavity, to a careful selection of the cases suitable for its use, and to the proper form of plugger-points. Each piece of gold should be carried precisely to the spot where it is intended to condense it, and it should not be disturbed by too much manipulation before it is condensed. It is quite impossible, with crystal gold of good cohesive texture, to move a pellet of it across the surface of the gold already in the cavity for the purpose of securing a more convenient position. Any attempt to insinuate it out of the location first taken will result in tearing the uncondensed pellet so that it is disintegrated and wasted.

The places where crystal gold is indicated are in starting fillings in difficult cases, and in large, open cavities easy of access, where the gold may be conveniently laid on in regular arrangement and condensed under the eye of the operator. It should not be em-

ployed for filling undercuts or remote positions in cavities, on account of the tendency to bridge.

The pluggers best adapted to its use are the oval-faced forms, with shallow serrations. For starting the filling a large point should be used, with vigorous hand-pressure, to carry the mass in front of the plugger instead of puncturing it; but as the filling is being built up too large points must not be used, for fear of failure in density. A convenient method of condensing the main portion of the filling and securing an even surface is to use a rapid mallet with the Royce plugger-points. These points, being oval on their serrated ends, may be swept back and forth across the surface of the filling with little danger of tearing the uncondensed gold away and wasting it, as is sometimes the result with flat-faced pluggers. The Royce pluggers should be held a short distance from the condensed surface, so that the jump of the mallet catches the gold in front of the plugger and mats it to place.

CHAPTER VIII.

MALLETS AND MALLETING.

THE selection of a mallet for the insertion of gold is a matter which must be left largely to the individual preference of the operator, and yet there are distinguishing characteristics related to the different forms of mallet which call for consideration. Laying aside the factor of personal equation, we must not ignore some of the fundamental qualities inherent in the nature of the appliance which influence its practical utility.

The Hand Mallet.

This mallet was the first to be used for condensing gold, and it would seem to-day to be capable of a wider range of service than any other single form of mallet. No other mallet yet suggested has so many advantages with so few disadvantages. Its chief limi-

tation relates to the necessity of employing an assistant to manipulate it, owing to the fact that the operator has too many uses for his left hand to make it convenient for him to employ it for this purpose. It is true that some practitioners prefer to do their own malleting, and by constant practice become very expert, but in the daily routine of gold filling there are too many demands on an operator's vitality without adding to them in this particular. No operator can do his own malleting without placing himself in a more strained position than would be necessary if some one else malleted, and there are times when it seems almost imperative to utilize both hands for other purposes. While it may be possible to strike a more intelligent blow and regulate the force more accurately to the requirements of the case, yet the method calls for too great a tax on the operator to make it desirable practice.

The Assistant.—The problem of training an assistant to be a good malleter is a necessary concomitant to success in the use of the hand mallet. Usually a young lady assistant is best suited to this purpose,—one who has no intention of studying dentistry as a profession. The reason for this is that to be an expert malleter the assistant should have no interest in the operation except to use the mallet. A student of dentistry naturally becomes interested in the progress of the filling, and is inclined to divert the attention occasionally to the tooth instead of concentrating it solely upon the end of the plugger handle. This diversion results in imperfect work, and any imperfection on the part of the assistant renders the hand mallet almost the worst that can be used. The quickest perception is necessary to anticipate every move of the operator, and a young lady usually possesses this intuitive perception to a greater degree than the average young man. A nod of the operator's head or the slightest intimation—so slight, in fact, that the patient need never be cognizant of it—is all that should be necessary to indicate to a capable assistant the character of blow required, whether as to force or rapidity of stroke. The assistant should be trained to develop the wrist to the highest degree of suppleness, so that in striking the blow there shall be an entire absence of arm-weight exerted upon the mallet. She should also

learn to use either hand with equal facility, but in the event of one hand being developed to a higher degree of perfection than the other, preference should be given to the left hand, on account of the fact that during most operations the assistant must stand on the left side of the patient, facing the operation, thus giving the left hand the widest range of usefulness.

One of the most important considerations in the use of the hand mallet relates to the angle at which the mallet meets the plugger. The striking face of the mallet should be at direct right angles with the long axis of the plugger, or, in other words, the mallet should strike the plugger squarely on the end at every blow. Any deviation from this results in a gliding of the mallet across the end of the plugger, which interferes with its condensing power and proves very distressing to the patient. To invariably strike a square blow necessitates the constant attention of the assistant, added to a quick anticipation of any change in the angle made by the operator, so as to meet it with a corresponding change in the direction of the mallet blow. There should be developed between the operator and malleter the closest concert of action, and the one should understand the methods of the other so perfectly that no verbal instruction is necessary during an operation. This harmony of procedure is very reassuring to a patient and leads to confidence in both operator and assistant.

The Kind of Mallet.—Various forms of hand mallets have been devised with the idea of finding something which was alike agreeable to the patient and effective in condensing power. The steel mallet has probably been more universally used than any other, and while to some patients objectionable on account of the hard metallic ring to the blow, it still possesses characteristics which make it a very desirable form of mallet. By its use an intelligent operator can detect instantly when his gold is dense under the plugger-point. There is something which telegraphs to the hand holding the plugger a sense of solidity to the filling the moment this solidity is reached, and distinguishes perfectly between a surface partially condensed and one completely condensed. This nicety of distinction is scarcely to be attained by any other form

of mallet, such as those made of lead or lead covered with leather. These have a dead soft blow more acceptable to most patients, but requiring in the aggregate a large number of blows for a given density, or at least a larger number before the operator can be assured of density. One very great advantage of the softer mallets is that a much heavier mallet can be tolerated by the patient than if made of steel, and the condensing power is thereby materially increased without discomfort. The operator should make a careful study of these two forms of mallets with the view of employing the particular kind which seems the most effective in his hands with the least accompanying pain to the patient.

The wooden mallet used by some operators is ill adapted to the purpose of condensing gold. Unless it is so large as to be unwieldy, it has not sufficient weight to be effective, and in order to gain anything approaching adequate density it requires so many blows that the process becomes exceedingly irksome to the patient. It is not only inefficient, but is objectionable in point of comfort.

The Automatic Mallet.

This mallet was devised to avoid the necessity of employing an assistant, and in the hands of some operators it seems to be an efficient appliance. But it may well be doubted whether it is ever capable of the same degree of delicacy that is easily attained with the hand mallet, or whether for most patients it can be compared to the hand mallet when comfort is considered. Given an expert assistant in a test of the two forms of mallets, and probably nine out of ten patients will select the hand mallet. There is a feature of the automatic mallet which doubtless may be held in some degree accountable for this aversion on the part of patients. In order to obtain the blow it is necessary to exert pressure on the filling with the plugger-point, and this pressure carried to a certain limit, causing a sudden recoil and blow, creates in the mind of the patient a series of anticipations which in the aggregate become exhausting. In other words, the patient is continually being warned by the pressure that a blow is to be struck, and this repeated leading up to the blow by pressure keeps the patient con-

stantly on a tension. The precise character of the discomfort is not always capable of analysis by patients, and they are often unable to explain why they dislike the automatic mallet, but if this matter be carefully watched by the operator he will soon ascertain that there is invariably an intuitive finching on the part of the patient whenever the pressure of the plugger is prolonged beyond the ordinary. It seems to be this interval of suspense which is trying to the patient more than the actual blow. All of this is avoided by the hand mallet. There is no advance pressure to herald the coming blow, and the character of the stroke is short, sharp, decisive, and instantly over with.

This recalls one feature of an automatic which would seem to have an important bearing on its utility. The stroke should be as short as possible consistent with volume of blow. Most automatic mallets have so long a stroke that their manipulation is a slow and awkward process, besides adding materially to the element of discomfort. An automatic, to do the best service capable of such an instrument, should work with a short, snappy blow, definite in quality and with a rapid rebound, so as never to miss a stroke. To attain this the appliance must be kept in the most perfect condition by repeated cleansing and oiling.

The Rapid Mallets.

Each of the various forms of rapid mallets has its adherents among operators, but probably the ones most in use to-day are the mechanical or pneumatic mallets operated by the engine or by a motor. The electric mallet seems largely to have been displaced in recent years by others more readily kept under control and less complicated. It would seem that the ideal rapid mallet was one which, besides giving a definite blow at any desired speed, may be run by the motor. To operate a mallet with the foot engine becomes wearisome in a long sitting.

The only places suited for a rapid mallet are in cavities ready of access, where it is merely a matter of laying on the gold, and also for finishing the surfaces of fillings after the inaccessible parts of the cavity have been filled. It is hazardous to attempt to build

gold around corners or to reach difficult positions with the rapid mallet. Such an effort usually results in bridging the gold over spaces, and fails in perfect protection of cavity-walls in the inaccessible regions.

It is often an agreeable change for the patient to have the rapid mallet substituted for the hand or automatic mallet as the filling nears completion. Any diversion in the character of the blow seems to afford relief from the monotony of a long sitting, and to be more acceptable to most patients than the continued use of any one kind of blow throughout the entire filling. For this purpose the rapid mallet becomes very useful, and it also materially shortens the operation. Gold may be condensed on an accessible surface almost as rapidly as the pellets can be carried to the tooth and placed by the assistant. This mallet also leaves a surface even and dense, if its manipulation be well understood.

The proper method of using a rapid mallet is to sweep the plugger point across the surface of the filling from center to margin, as if the gold were being wiped into the cavity. The process is entirely different from that of the hand or automatic mallet, and this fact should be recognized by those who attempt to use it.

As before intimated, oval-faced pluggers with shallow serrations are indicated for the rapid mallet, whereby the gold may be wiped down on the filling instead of being caught by the side of the plugger and torn off laterally, as would be likely to result with a flat-faced plugger having a sharp angle between the serrated end and the shank. Another advantage of oval-faced pluggers relates to the safety of enamel-margins. The rapid mallet carrying a plugger with sharp angles is exceedingly prone to chop up or pulverize the margins unless the greatest care is exercised, but the oval-faced pluggers will permit greater freedom of action without injury. This watchful care of the enamel-margins is one of the necessary precautions in the use of any rapid mallet, and no operator should attempt to use such an appliance without due appreciation of its dangers in this respect.

Hand Pressure.

If an operator were rigidly confined to any one process for the insertion of gold, it is probable that he would do better service for his patient in the varying conditions presented in the mouth by the use of hand pressure than by any other one method, and yet the places where hand pressure is properly indicated are comparatively limited. The great bulk of our work is better accomplished by mallet force, but in those occasional locations demanding hand pressure there seems to be nothing else which will at all adequately take its place. In distal cavities in molars and bicuspid teeth there is often a certain region which cannot be reached by a direct blow of the mallet, and unless the operator recognizes this fact and resorts to hand pressure in building up the filling at these points he will fail of perfect protection to the cavity-walls. These inaccessible locations are usually represented by the wall of the cavity which stands nearest to the operator, or, in other words, whose face is presented away from the operator so that it cannot be seen except with a mirror.

For instance, in a disto-occlusal cavity on a right lower molar the buccal wall of the cavity can seldom be seen by the unaided eye, and the relation of the operator to this wall is such that direct mallet force against it is impossible. In a case like this the only certain means of securing adaptation of the gold to the wall is by the use of right-angle pluggers wielded by hand pressure. When these cavities are on the distal surfaces of teeth far back in the mouth, or where the muscles of the lips are tense and unyielding, it is often necessary to build the entire gingival third—or even half—of the filling by hand pressure.

The right-angle mallets devised as a substitute in the various cases indicated are useful in the hands of some operators under certain conditions, but it would seem impossible to get so accurate a placing of the gold by their use as by hand pressure. The gold can be "pulled" against inaccessible places or insinuated under overhanging walls where such conditions are encountered with greater precision by hand pressure than by any mallet force. The pluggers used for the purpose should have a very stiff shank with

a large handle, capable of being conveniently grasped in the palm, by which means most of the pulling force is best exerted. In order to be assured of perfect adaptation and an adequate degree of density with hand pressure, it is necessary to exert considerable force, and the plugger should be strong and the wall sufficiently thick to safely sustain this force. This recalls a certain mistaken idea which appears to be prevalent among operators as to the indications for and against hand pressure. The impression would seem to prevail that hand pressure is indicated when building along frail walls or over friable enamel. The exact contrary is the fact. No operator can with hand pressure secure the same degree of density or adaptation along weak walls that can safely be obtained by delicate blows of the mallet. This is particularly true of the hand mallet wielded by a trained assistant.

One place where hand pressure is useful relates to the starting of all fillings. This can be readily accomplished on the wedging principle with non-cohesive gold, and the first pieces of cohesive gold may also be carried to place and fastened into the substance of the non-cohesive to the best advantage with hand pressure. For this purpose a certain manner of manipulating the plugger should be observed, in order to obtain the most perfect results. It is seldom that a straight pushing or pulling force will prove as effective as will the same degree of force exerted with a wrist movement whereby the point of the plugger is held on the gold and the end of the handle is swayed back and forth so as to describe the short arc of a circle. If a right-angle plugger is being used, the swaying should occur at the angle. This insinuating spreading force accomplishes two objects: it carries the gold into every inequality in the wall of the cavity, securing perfect adaptation, and the swaying motion also presses the uncondensed portion of the pellet which has curled up around the shank away from the plugger, allowing the instrument to be withdrawn without carrying the pellet with it.

This same method of manipulation is very effective when for any reason not apparent to the operator a pellet of gold fails to adhere to the surface of the filling under mallet force. A rebel-

lious pellet may be fastened to the filling by hand pressure exerted as just indicated, and made to remain more securely than by mallet force. The rocking motion of the plugger insinuates the substance of the loose pellet into the structure of the condensed gold and pins it to place to better advantage than if the mere property of surface cohesion were the sole dependence. For this purpose a plugger point with clean-cut, sharp serrations is indicated, and after several pieces have been added to the filling in this way it should be followed by the mallet over the surface to insure uniformity of density.

It may be here stated that a more satisfactory wearing surface can be given to any filling with mallet force than is possible with hand pressure, though hand pressure fillings properly inserted usually succeed in saving the teeth. They do so by reason of good adaptation to the cavity-walls, thus preventing leakage, even in many cases where the wearing surface of the filling becomes pitted and unsatisfactory. No filling which is subjected to the attrition of mastication should be considered safe, so far as the condition of its surface is concerned, unless the mallet has been employed in finishing the filling to impart a resisting property to the gold.

Protection to the Peridental Membrane in Malleting.

The problem of securing sufficient density to a gold filling so that it may safely withstand the usage to which it is subjected in the mouth without causing too much punishment to the peridental membrane during the operation, is one which confronts the practitioner on approaching any cavity of considerable size. The peridental membrane is more or less elastic, and when a blow is struck on the tooth with a mallet the tooth is forced slightly into the alveolus, causing a compression of the membrane. Instantly following this impact the membrane reasserts itself, forcing the tooth out again to its original position. Another blow drives it against the membrane once more, and the membrane again reacts. This repeated forcing in and out of the tooth soon results in such impairment of the membrane that if the process is kept up sufficiently

long without protection the operator is finally pounding the tooth on a jellied membrane.

This stage of injury is reached much sooner in those cases where the teeth have recently been wedged apart and are correspondingly loose, and this one factor becomes an important consideration in the choice of methods for gaining space as between previous wedging and the use of a separator. Wherever sufficient space can be safely gained with a separator it will ordinarily result in less aggregate discomfort to the patient than will the process of previous wedging followed by an operation while the tooth is still loose. One important office of the separator is to hold the tooth firm against movement under the impact of the mallet, and it may often be profitably employed during an operation for this purpose alone in cases where space has previously been gained by wedging. In those instances where it has been necessary to wedge extensively thus causing so great a movement of the teeth that they are left loose and sore, the operation of filling should invariably be deferred till the soreness subsides. The teeth may be held apart during this interval with gutta-percha.

The whole problem of protecting the membrane against injury from mallet force relates to giving the tooth such support that it is held firm and immovable under the blow. This may be accomplished in various ways, each case suggesting the method most suited to itself. Sometimes a wooden wedge may be used for this purpose, or a separator as already indicated, but for an extended operation the surest means is to hold an instrument in the left hand braced firmly against the tooth or filling throughout the operation. This kind of support is especially indicated as the filling nears completion on account of the tendency to soreness at that time, and also because the surface of the filling requires the most thorough malleting to be assured of adequate density. If a tooth be protected in this way the membrane will ordinarily not rebel against mallet force sufficient to condense gold into a serviceable filling, except in those cases where the membrane is impaired or is hypersensitive. When a tooth is loose from absorption of the alveolar process or from inflammation of the soft parts sur-

rounding it, a gold filling of any size should not be attempted in it till the tooth is made firm by treatment. If it cannot be made firm the operator would better select some other filling-material.

In some instances the peridental membrane is so weakened through lack of use that it is painfully responsive to mallet force. This is ordinarily brought about by the fact that when caries occurs the tooth becomes sensitive to mastication, and the patient involuntarily avoids its use to the end that the membrane, lacking its normal functional exercise, deteriorates in its resistive qualities so as to quickly rebel against the mallet. The remedy for this condition lies in subjecting the tooth to masticatory usage in advance of the operation, by placing in the cavity a gutta-percha plug to control the sensitiveness and instructing the patient to bring the tooth into active service. In this way the membrane may be so toughened in a week or ten days as to receive the impact of the mallet comfortably.

Another consideration connected with the toleration of the membrane to mallet force relates to the direction in which the pressure is brought to bear upon the tooth. If the condensation of the gold takes place in line with the length of the root, it will be found that there is less soreness than where an equal force is exerted against the tooth laterally. With this idea in mind, all fillings requiring extended malleting should be so built, if possible, that the pellets of gold are laid at right angles to the long axis of the tooth and the plugger held parallel with this axis. When a blow is struck in this direction the force is distributed throughout the entire surface of the membrane instead of being exerted against only one side of the root, as would result if a blow were struck at right angles to any of the axial surfaces. There are, of course, instances where lateral force must be employed, but these are usually in fillings of limited area where the aggregate mallet force is not sufficient to leave any serious impress upon the membrane.

CHAPTER IX.

THE INTRODUCTION, CONDENSATION, AND FINISHING OF GOLD FILLINGS IN THE DIFFERENT CLASSES OF CAVITIES.

WHILE each cavity is to a certain degree a law unto itself so far as the manner of building the filling is concerned, yet there are fundamental principles of procedure which if intelligently recognized will render the work more systematic and satisfactory. The methods herein suggested are not always applicable because of the constant occurrence of cavities unique in location and form, but for the so-called typical cavities of the different classes it is believed that if intelligently followed they will at least prove effective in the accomplishment of satisfactory work.

The arrangement in the cavity of the layers of foil constituting a pellet becomes a matter of some importance in its relation to the symmetrical growth of the filling under the plugger, and also to its resultant strength. It is with this idea in mind that the present plans of procedure have been suggested, as well as on the basis of expediency in the manner of building the filling.

To start any filling a rope of non-cohesive gold, varying in size as indicated by the requirements of the case, will be found effective. A convenient form may be made as follows: Divide a sheet of No. 4 foil twice, making one-third of a sheet; then roll into a rope about the size of a large knitting needle, and cut the rope in three parts. This makes a rope approximately an inch in length, and of a size that can be readily carried into most cavities of any extent. In small cavities the rope may be cut short enough for convenience.

When starting a filling the rope should be grasped by the pliers about one-fourth of an inch from the end, and this end carried into the angle of the cavity where it is intended to commence the filling. The rope will fold upon itself as it is pressed into the angle, so that it will remain there while the pliers release it and grasp it farther back and fold it once more into the cavity. This process is kept up till the entire rope is carried into position, where it may be con-

densed in the manner to be described when considering the details of filling building in the different cavities. Into the structure of this non-cohesive cushion may be wedged the first pellets of cohesive gold till the two forms of gold are so interlocked that they will not separate, when the filling may be completed with cohesive gold.

Simple Proximal Fillings in Incisors.

These fillings, when built from the labial aspect, are ordinarily best started in the gingivo-linguo-axial angle of the cavity by carrying a rope of non-cohesive gold into this angle as already indicated. The rope should be folded upon itself from the starting point along the gingival wall toward the labial wall, till it is securely locked between the gingival third of the labial and lingual walls. If the gingival wall has been made flat there will be little difficulty in securing the rope in place. The first rope used should be of sufficient size to cover the entire gingival wall from lingual to labial, and extend well over the gingival enamel-margin. The office of this rope is to secure ready adaptation to the angles of the cavity, and also to form a non-cohesive cushion against which cohesive gold may be condensed without danger of injury to the gingival enamel-margin. In condensing gold over margins it should always be a cardinal principle to keep a sufficient mat of gold between the plugger point and the margin to avoid the possibility of injuring the enamel with the serrations of the plugger.

When the non-cohesive rope has been carried to place with the pliers it should be more securely locked in position by bringing a plugger to bear on it at two or three points with hand pressure, wielded in the rocking motion already described. The first direction of the plugger should be toward the gingivo-linguo-axial angle, and the gold should be wedged into this angle with considerable force. If the rocking motion of the plugger is used the gold can be so locked into place as not to be readily moved by subsequent manipulation, but if there seems any doubt about its security a retaining instrument may be placed on the condensed gold the moment the plugger is withdrawn, and held there while the locking process is carried on by the plugger at other points.

The next direction of the plugger should be toward the gingivo-labio-axial angle, and these two points may be all that is necessary to condense at this time. The object is simply to lock the rope into the angles of the cavity rather than to attempt the condensation of the entire mass. In fact, too much condensation must be avoided until some cohesive gold has been called into service. After the plugger is withdrawn from the gingivo-labial angle a cohesive cylinder sufficiently large to cover the entire gingivo-lingual region should be laid with its side upon the non-cohesive gold, and one end looking along the lingual wall and the other along the gingival wall. This should then be forced into the substance of the non-cohesive gold in the direction of the gingivo-linguo-axial angle, so as to incorporate the two forms of gold into one mass. After pinning this pellet of cohesive gold into the non-cohesive at several points with hand pressure, another cylinder of cohesive gold may be forced into the gingivo-labio-axial angle in the same manner. These two pellets will usually reach across the entire gingival wall, but if they do not a third one may be used to connect the two. When there is a complete covering of cohesive gold over the non-cohesive the mallet may be used for the first time, and the entire mass malleted to place. The result is that the gingival wall is perfectly protected by a cushion of non-cohesive gold covered by a layer of cohesive gold, and the whole locked between the labial and lingual walls of the cavity with a slight excess of gold overlying the gingival enamel-margin to insure sufficient material for a perfect finish.

In building the filling from this point the pellets of cohesive gold should be laid with their sides looking toward the gingival wall and their ends looking labially and lingually, and each pellet should be wide enough to reach from the axial wall to the extreme proximal surface of the filling. With this arrangement of the pellets the condensation is in the direction of the long axis of the tooth, and the filling is kept sufficiently prominent on its proximal surface while it is being built down to avoid the necessity of subsequently adding any gold laterally to this surface to round out the filling. Gold tacked on the proximal surface of one of these

fillings by laying the pellet on its side and directing the mallet force at right angles with the long axis of the tooth is not so securely maintained in place as it is where the arrangement of the gold is such that each pellet reaches from the proximal surface to the axial wall and is built toward the gingival wall. The operator cannot always avoid the necessity of arranging his gold so that the condensation is in the direction of the axial wall, but this necessity is usually confined to small fillings where the means of approach will not permit of any other arrangement, and where the element of strength is not so material.

One important consideration in building these fillings relates to the protection of the lingual margin. This seems to be the most difficult feature in their insertion, and it is where operators fail more often than at any other point. This failure is usually due to inadequate covering of the margin as the gold is being built along the lingual wall toward the incisal angle. A slight excess of gold should invariably be carried over this margin, and in order to be assured of this the operator should keep the gold in the lingual region built somewhat in advance of the filling at the labial margin. That is, the gold should extend farther incisally along the lingual than along the labial wall, so that the operator may clearly see the lingual margin and thus be certain of lapping the gold over it. If the labial part of the filling be built in the least advance of the other, it obstructs the view of the lingual margin and prevents access with the plugger.

As the filling is being built down toward the incisal angle, the operator must have a care not to approach too near the angle before wedging some gold into the angle and between it and the filling already in place. If the cavity is deep pulpally, so as to leave an appreciable pocket between the condensed gold and the incisal angle of the cavity, it is advisable to use a short rope of non-cohesive gold to wedge into this pocket to be assured of perfect adaptation. Into this non-cohesive gold a small pellet of cohesive gold may be forced with hand pressure, and the filling completed with the mallet.

When a filling is thus inserted it will be found that there is a

slight excess of gold overlapping the margins of the cavity, and the final step in condensing such a filling should be to mallet down this gold with a foot plugger. If access cannot be gained with a plugger a very thin burnisher may be used to force the gold to place, burnishing from the center of the filling toward and over the margins. Then the filling is ready for polishing.

In cavities where the lingual wall is missing and the labial wall perfect, so that the filling must be built from the lingual aspect, the same general principles of filling building may be followed, except that the gold should be started in the gingivo-labial region instead of the gingivo-lingual, and the filling kept more prominent along the labial wall as it approaches the incisal angle. The same care must be exercised in lapping an excess of gold over the labial margin while the filling is being built that was advised for the lingual margin while building from the labial aspect. It is well-nigh impossible to tack gold on the labial region of the filling after it has been built down to the incisal angle, and the operator should therefore provide perfect protection to this wall while he has the opportunity.

In those cases with the lingual wall missing but the labial aspect so open that the filling must be built mostly from this direction, the gold should be started in the regular way, and as the lingual margin is being covered a portion of each pellet should be allowed to extend some distance over the margin and hang beyond the lingual surface of the tooth. This end of the pellet cannot be condensed from the labial aspect, but the portion reaching into the cavity can be made fast to the filling and the filling built as full as convenient from this aspect. When the labio-proximal portion of the filling is built to form it will be found that from the lingual aspect a large mass of uncondensed gold extends lingually beyond the margin, each pellet of which is securely fastened into the substance of the condensed portion of the filling. This uncondensed mass will ordinarily not contain sufficient gold to properly round out the filling when malleted to place without the addition of more gold, and it is the addition of this gold from the lingual aspect which often proves troublesome to operators. To avoid

difficulty of this nature it is suggested to take an annealed pellet and force it with hand pressure up into the structure of the uncondensed gold before malleting the latter to place. If this be done the freshly annealed pellet will leave a surface to which, if necessary, more gold may be attached with greater certainty than where the uncondensed gold has been malleted without this precaution.

The object of leaving this excess of uncondensed gold is to enable the operator to interweave the freshly annealed pellets into its substance, and thus prevent flaking of the lingual portion of the filling, which is likely to occur where an attempt is made to condense the gold as the filling is being built down, and then add more gold to the condensed surface from the lingual aspect. Wherever possible the practice should be avoided of leaving for any length of time a condensed surface of gold exposed to the atmosphere with the expectation of subsequently adding more gold to it. The property of cohesion seems to be more or less impaired by exposure, and in order to secure the best working quality to cohesive gold it will be found desirable to add pellet after pellet to the freshly condensed surfaces from beginning to completion of the operation.

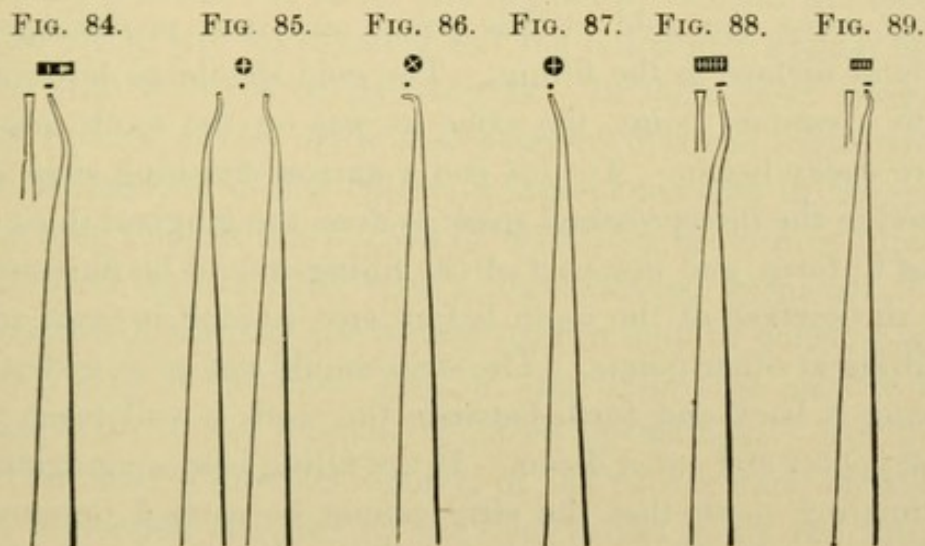
Pluggers.

The choice of pluggers becomes largely a matter of personal selection with most operators, but for these proximal fillings in anterior teeth the forms here illustrated would seem to answer a convenient purpose. Fig. 84 is suggested for starting the filling and locking the gold into the gingival third of the cavity. Its length from the serrated end to the angle is sufficient to reach perfectly to the gingival region of any cavity on an incisor, and the degree of curve is such that direct hand pressure or mallet force may be exerted against the gingival wall. In cavities of large area with ready access much of the filling may be built with it to the point where the incisal angle requires protection, but for small cavities other forms are mostly indicated.

As the incisal angle is reached a plugger of smaller size, and with a greater curve, is required, such as the pair, right and left,

illustrated in Fig. 85. Occasionally even these forms will not properly reach the angle on account of the position of the proximating tooth, and where such is the case a small, short right-angle plugger is indicated, Fig. 86. These right-angle pluggers are invariably to be used with hand pressure, and in cases difficult of access the gold may often be "tucked up" into an angle in this way when mallet force is entirely impracticable.

For building fillings from the lingual aspect in all cavities of sufficient size Fig. 84 is especially adapted, on account of its adequate reach. In cavities too limited for its use, whether of



labial or lingual aspect, the form illustrated in Fig. 87 may be substituted to advantage in conjunction with the curved pair Fig. 85.

One important factor in securing the most stable anchorage of these fillings relates to perfect density of the gold along the angles which join the walls of the cavity. As has previously been stated, accurate adaptation of gold may be obtained to any angle provided the proper form of plugger point is used, and for this purpose such a form as that in Fig. 88 is excellent in those positions where it will approach. Another form suggested for places where Fig. 88 will not reach, and especially for curving under the labial wall and carrying the gold into the angle between the labial and axial walls, is shown in Fig. 89. In cavities where these forms are not available for the angles the curved pluggers with round points may be

made to do good service, and secure perfect adaptation by exercising care and malleting step by step along the angle so that the plugger point covers the entire mass of gold with the mallet impact. For the surface of these fillings, according to their area, pluggers ranging from Fig. 88 up to a small-sized foot plugger may be used to give an even, dense surface.

Finishing Proximal Fillings in Incisors.

When the filling is built to proper form the gold will ordinarily be found to knuckle tightly against the contact point of the proximating tooth, and in finishing the filling the operator must avoid cutting away the gold at this point, and thus producing a flat proximal surface to the filling. The gold should be left rounded out to a contact point, the same as was on the tooth originally before decay began. To this end a narrow finishing strip should be used in the interproximal space to dress the gingival third of the filling to form, and this part of the filling should be finished even with the surface of the tooth before any attempt is made to trim the filling at other points. The strip should not be so wide that in drawing it back and forth between the teeth it will reach to the contact point and cut it down. If the filling is so snug against the proximating tooth that the strip cannot be carried between the teeth, it may be introduced endwise into the interproximal space from the labial aspect.

When the gingival margin is properly trimmed to form, the gingivo-lingual portion of the filling may often be dressed down by carrying the cutting surface of the strip—which is still in the interproximal space—as nearly as possible along the lingual surface of the tooth, and the back or smooth side of the strip across the labial surface of the proximating tooth. This brings pressure of the cutting side of the strip to bear immediately on the gingivo-lingual part of the filling, and it does not cut at any other point.

After the narrow strip has been used it will often be found convenient to slip on a separator where one has not previously been employed, and force the teeth slightly apart to admit of a finishing strip being carried between the teeth. Where this cannot be done

a very thin, broad burnisher, battered out to a uniform thickness and having a sharp edge, after the nature of the Dunn hand matrix, should be forced between the filling and the proximating tooth, and the end of the handle swung back and forth, describing the arc of a circle, while the blade is held between the teeth till there is more or less freedom of movement of the burnisher. This will ordinarily smooth the gold so that a strip may be passed between the teeth.

The strip used for finishing this portion of the filling should be broad, and in manipulating it the cutting surface should be drawn quite sharply across the labial and lingual surfaces of the tooth, so that the filling will be rounded and the labial and lingual aspects dressed even with the cavity-margins. In those cases where the lingual surface of the tooth is so concave that the strips will not follow the outline of the cavity, a sand-paper disk in the engine may be used to dress this portion of the filling to form by directing the disk into the concavity with a round-headed burnisher.

After the filling is of the proper form it may be polished with a finishing strip of the finest grit, or thin linen tape may be used, carrying with it fine pumice, followed by whiting. All of this should be done before the removal of the rubber dam, on account of the protection afforded by the dam to the gums and lips, and also because the saliva interferes with the work.

Whenever strips or disks are used in finishing gold fillings they should invariably be smeared with vaseline, oil, or some similar lubricant to avoid as much as may be the generation of heat in the filling. The lubricant also renders the disk pliable, and it can therefore be directed into depressions with a round-headed instrument—such as a ball burnisher—to much better advantage than where such an attempt is made with a dry disk. This practice will also prove of considerable financial advantage to the dentist if he will preserve his worn-out disks and strips and send them to the refiner. The amount of gold retained on the sanded surface, if lubricated this way, will in the aggregate yield a surprising profit in the course of a year, and no operator should ignore this kind of economy.

Another aid in the maintenance of a normal temperature in a filling under the friction of a strip or disk may be made available by those who have compressed air at their command. If a jet of air be allowed to play upon the filling during the process of polishing, it will be found to equalize the temperature and render the work more tolerable to the patient.

Proximal Fillings in Anterior Teeth involving the Incisal Angle.

The method of building these fillings is practically the same as that for simple proximal fillings down to the point where the incisal anchorage is made, except that in the contour fillings the open aspect of the cavity renders it possible to more uniformly lay the gold on parallel with the gingival wall and at right angles to the stress of mastication. In these large fillings the proximal surface should be kept sufficiently prominent as the filling is being built from the gingival to the incisal region, to make it unnecessary to add more gold laterally to the proximal surface to complete its contour.

In those cases where the incisal anchorage has been made between the two plates of enamel in the incisal third of the axial wall, the greatest care must be exercised in securing perfect adaptation and density of the gold in this anchorage. Small pieces of gold must be used, and each piece compactly malleted to place with small pluggers. The slightest lack of density or the slightest bridging of the gold at this point must eventually result in a springing away of the incisal portion of the filling which sooner or later leads to its loss.

Where the incisal anchorage is made by cutting a step or groove across the end of the tooth at right angles to the proximal cavity, as suggested in considering cavity preparation, the method of building the filling is to carry the gold down the proximal portion of the cavity level with the base of the step in the ordinary way, and then lay a pellet with its side presented to the floor of the step and its ends looking mesially and distally, reaching from the center of the gold already condensed over into the step. The pellet should be fastened securely to the condensed gold, and then malleted to

place in the step. Another pellet should be laid slightly farther along the step, but with one end still lapping the gold already in place. In this way the proximal portion of the filling is securely locked into the step, and the greatest possible strength is given the gold at the point where the proximal joins the incisal portion of the filling by such an arrangement of the pellets. This process of building the gold should be carried on till the end of the step is reached. The entire incisal portion of the filling must be built up with the greatest care, and the arrangement of the pellets, so far as possible, should be in the order already suggested,—the sides at right angles to the force of occlusion, and the ends looking mesially and distally across the step.

The gold should be perfectly annealed and small pellets employed, to the end that the greatest degree of density and resisting power is imparted to the gold. For this portion of the filling it is sometimes desirable to use the heavier golds in strips, such as the No. 60 rolled gold; or in cases where extreme density is desired platinum and gold may be employed. If the rolled gold is used it should not be added till the surface is nearly reached, on account of the greater difficulty of securing perfect adaptation to the labial plate of enamel.

This is one of the most important considerations in building these fillings. Unless the gold is adapted to the labial plate with the greatest accuracy there will eventually occur a leak at this point, which will result in such discoloration as to make the tooth unsightly. The angle between the labial plate and the step should also receive close attention in adapting the gold, so that the filling may be securely seated in place.

For building this portion of the filling pluggers 88 and 89 are admirably adapted, though larger sizes may be used in cases where the area of the cavity will permit it. In teeth long and thin, where the step must be correspondingly deep and narrow and where it has been made to terminate in a depression, for the more secure anchorage of the filling a plugger as small as Fig. 87 may be required to reach the deepest part of the step and bring this portion of the filling level with the rest; but when this is accomplished

Figs. 88 and 89 will ordinarily be found none too large to complete the operation. As the surface of the filling is reached the gold should be malleted somewhat beyond the stage where it seems dense, on the theory that repeated blows harden gold and make it more resistant, even after compactness has been reached. In going over the surface for the last time with the mallet a smooth-faced plugger may be used, and the blows so arranged that the final ones are invariably struck along the margins.

For finishing the incisal aspect of these fillings a sand-paper disk, held to position with a ball burnisher, will quickly dress the filling to form, after which it may be polished with a fine cuttle-fish disk.

Fillings in Proximo-Occlusal Cavities in Bicuspids and Molars.

The Matrix.—A necessary concomitant to the proper consideration of the insertion of contour fillings in bicuspids and molars relates to the question of the matrix. A perfect understanding of its advantages and limitations should be acquired by every operator, in view of the fact that if properly employed under suitable conditions it is capable of materially lessening the fatigue and difficulty of these operations, while if used ill-advisedly or unskillfully it leads to the gravest defects in the work and proves simply a delusion and a snare.

The chief office of the matrix is to supply the missing wall of a cavity, thus converting a proximal cavity of three walls into one of surrounding walls. This becomes a matter of very great importance in distal cavities far back in the mouth, on account of the angle at which a plugger must approach such cavities. Unless there is a supporting matrix-wall against which to build the gold, the filling must either be made unnecessarily full while it is being built or else it must fail of adequate density on the proximal surface. With a matrix properly adjusted, the correct contour can readily be given the filling while the gold is being condensed, so that little trimming is necessary in finishing, and the surface may be made as hard as desired. It will very materially lessen the labor and nervous strain of an operation, and will therefore well repay the study necessary for its successful use.

The main objections urged against the matrix may be summarized as follows: The difficulty of obtaining adaptation of the gold into the angle formed by the junction of the matrix with the margin of the cavity thus resulting in imperfect margins to the filling, and the obstruction which the matrix is supposed to form to a good view of the cavity. Each of these objections is well founded under certain conditions, and each is equally inoperative under certain other conditions. If a thick, stiff matrix is used and tightly wedged against the cavity outline, it will be found difficult to properly carry the gold over the enamel-margin and secure a perfect sealing of the cavity, but if a matrix is made of a thin, springy material, capable of being forced away from the cavity-margin at will, so that the gold may be carried between the matrix and the margin, there is really no obstacle in the way of doing perfect work. In fact, the proper use of the matrix will facilitate the making of good, dense margins to our fillings with less difficulty in these distal cavities than where the attempt is made to build the filling in an open cavity. The matrix is a support to the gold during condensation, and it has a sustaining influence to hold the filling to form under the impact of the plugger. If a mallet blow is used on the gold in the direction in which it is often necessary in these cavities far back in the mouth, the tendency is to force the gold away from the cavity-margins, unless there is some sustaining wall against which to build. This matrix-wall keeps the gold up to its place and gives the opportunity for free malleting without rolling the gold away from the axial wall and margins.

This does not imply that the greatest care is not always necessary in the use of the matrix. As has been intimated, no matrix should be used which is not capable of being forced by the plugger sufficiently away from the cavity to admit a mat of gold between it and the margin. Given a matrix which on adjustment fits approximately to the margins of the cavity, the aim should be, in placing the first pieces of gold over the gingival wall, to so force back the matrix with the plugger that it will stand away from the buccal and lingual margins at least half a millimeter, and this space should be maintained throughout the building of the filling.

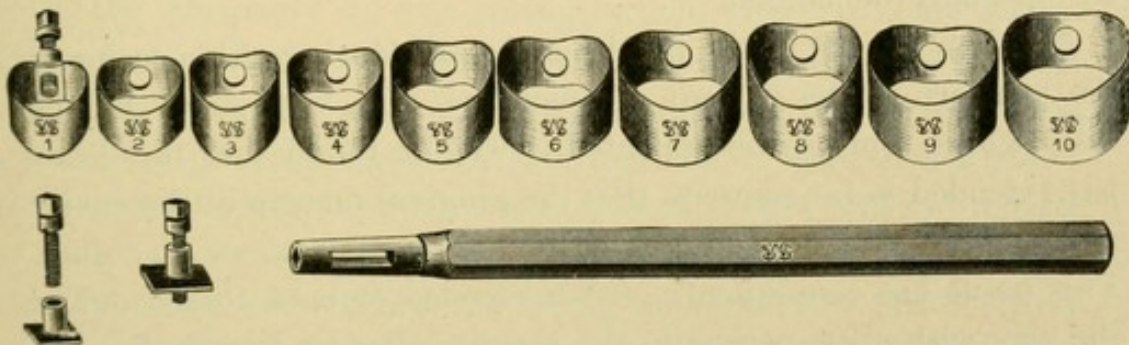
If this is done the margins may be readily covered and the gold made dense and perfectly adapted.

The objection as to the obstruction of light and vision from the cavity holds good if a broad matrix be used on a mesial cavity, but there is no obstruction whatever on a distal cavity. In view of the fact that there is seldom any necessity for a broad matrix on a mesial cavity, the question becomes one of judgment in the selection of suitable cases for the matrix rather than one bearing on a fundamental objection to the appliance itself. The most that is ever required in the way of a matrix on a mesial cavity is a narrow strip of metal placed across the gingival third of the cavity to give form to the filling in the interproximal space and provide a guiding wall against which the filling may be so built that it will require very little subsequent trimming in finishing it. This does not materially obstruct the view of the cavity, and it furnishes all that is necessary in the way of a matrix for these cavities.

Another objection which is sometimes urged against the matrix may be mentioned merely to controvert it,—viz, the difficulty of securing adaptation of gold to the surface of the matrix. The claim is made that in building gold against a matrix it is seldom that a filling is perfect on the proximal surface owing to spaces being left here and there as the gold is laid against the matrix. If this be true, it is due to either one of two things,—an oversight on the part of the operator or improperly formed pluggers. That gold can be perfectly adapted to a surface like the matrix has been too often demonstrated to require further emphasis. It is surely as easy to adapt gold to a matrix as to the wall of a cavity, and it is safe to conclude that in many of the cases where the surface of the filling next to the matrix has been found defective the surfaces next to the walls of the cavity would present similar imperfections, if the same facilities for examination were available. The chief distinction between building gold against the flat surface of a matrix and the flat surface of a cavity is that the former is somewhat more disastrous to plugger points than the latter, the serrations being more rapidly battered down when coming in contact with steel than with dentine or enamel.

The Kind of Matrix.—No one form of matrix may be deemed available for all cases, and in some instances it will be found desirable to improvise a matrix specially for the case in hand. The band matrices made of thin steel, such as the Brophy matrix (Fig. 90), serve an excellent purpose for ordinary work, though they are not universally applicable. The material of which these matrices are made is almost ideal for the purpose. The steel is sufficiently rigid to sustain the gold against thorough malleting, and yet its springy nature admits of it being forced away from the cavity-margins by pressure of the plugger. There are some objections to these matrices which occasionally assert themselves, chief of which may be mentioned the fact that in bell-crowned teeth the matrix

FIG. 90.



embraces the tooth tightly near the occlusal surface and stands some distance away from the neck along the gingival half of the cavity. This objection may readily be overcome by packing some gutta-percha into the interproximal space between the matrix and the proximating tooth, so as to force the matrix up to the gingival margin of the cavity. Wooden wedges have sometimes been advocated for this purpose, but the danger with these is that the wedge is likely to force the matrix too close to the margin, and the wood is so unyielding that the plugger cannot press the matrix back to allow the gold between it and the margin. With gutta-percha the matrix may be carried as close to the cavity as desired, and the material will be found sufficiently yielding to admit of manipulation by the plugger so as to secure perfect protection to the cavity-margins.

Another difficulty sometimes encountered with the band matrix

is the problem of maintaining it in position on teeth that are more cone-shaped than bell-crowned,—where the axial surfaces slope from the gingival line to the occlusal surface in such a way as to present an inclined plane along which the matrix slides to its displacement. Occasionally this may be prevented by packing hot gutta-percha between the matrix and the buccal and lingual surfaces of the teeth and letting it cool before there is any manipulation of the matrix. If the gutta-percha is quite hot, it will be more or less adhesive both to the matrix and the enamel, and it will often prove effective. In cases where this will not answer cement may be substituted, though this requires so much time for its application and crystallization that it is indicated only in those cases where nothing else will suffice and where such a matrix seems to be especially demanded.

Another feature of the band matrix calls for attention so far as the comfort of the patient is concerned. In very many of the cases where a matrix is indicated it will be found that the decay has extended so far rootwise that the gingival margin of the cavity is some distance beyond the original free margin of the gum. This tissue has consequently either receded or been forced out of the way with gutta-percha in the manner already described in the consideration of cavity preparation. Under these conditions the gum in the adjoining interproximal spaces extends much farther crownwise than that in the affected space, and if the matrix is carried sufficiently rootwise to cover the gingival margin of the cavity,—which it must be in order to prove effective,—that portion of the band in the adjoining interproximal space impinges forcibly on the gum-tissue, to the serious discomfort of the patient. The only remedy for this is to cut away the edge of the band which passes into the adjoining space in such a manner that a considerable concavity is presented to the gum instead of a convexity, and this should be done with all band matrices, even though it involves the necessity of having a separate set for each side of the mouth.

When it becomes desirable to make a matrix for the special case in hand, a suitable material for the purpose is found in copper or German silver rolled thin. This may be wrapped around the

tooth and fashioned with a burnisher to any desired form, and the two ends tacked together with solder.

The narrow matrix for the interproximal space in the management of mesial cavities may be conveniently made from an old watch-spring. This should be broken into lengths varying from a third to half an inch for the different sized teeth, and then ground convex on one edge so as to dip down into the space with the convexity looking rootwise. The varying degrees of curve to the spring may be utilized in the selection of suitable forms for the different teeth. For instance, a lower second bicuspid which is nearly round at the neck would call for a matrix made from near the center of the spring, where the curvature is greatest, while for a molar with a broad proximal surface the matrix should be made from the periphery of the spring, where there is little curve. These matrices may be slipped between the teeth and held in place ordinarily by their own form, the convexity of the curve resting against the proximating tooth just rootwise of the contact point. If the space between the teeth is so great that they will not remain of their own accord, they may be fastened with gutta-percha, as already described. When the filling is completed, this form of matrix should be removed by forcing it either buccally or lingually, it being ordinarily impossible to remove it occlusally.

Manner of Using a Matrix.—The greatest care should be exercised in securing a proper adjustment of the matrix to the end that it shall be maintained in position during the condensation of the gold, and that it shall have such a form that when the filling is built against it the proximal surface of the filling will present a contour that requires little trimming. The matrix should dip in close to the tooth at the gingival region of the cavity, and stand out tight against the contact point of the proximating tooth near the occlusal surface. If it does not take this position when applied to the tooth, it should be forced to take it by packing gutta-percha in the interproximal space, as previously suggested, and by burnishing the free end of the matrix against the proximating tooth. One of the prime advantages of the matrix is that by its use a filling may be so malleted as it approaches the contact point of the

proximating tooth that the contact point on the filling is given the greatest possible density without building any excess of material. The matrix should be so thin that when the filling is condensed and the matrix removed there is practically no space left and the gold falls against the proximating tooth. By the use of the matrix a tooth may be filled and the proper contour maintained with less separating than where no matrix is used.

Before placing any gold in the cavity it is well to go along the matrix-wall with a plugger and test it, to see if it may be pressed away from the cavity-margins at will. If there is any point where it seems too rigid, so that there is likelihood of an oversight in adapting the gold, this portion of the matrix should be forced away from the margin in advance of the operation, to make certain of a ready overlapping of the gold.

When the matrix is satisfactorily adjusted, the filling may be started by introducing a rope of non-cohesive gold along the gingival wall and wedging it into the angle between the gingival and axial walls, and also locking it into the gingivo-buccal and gingivolingual angles. When the first part of the filling is thus securely fastened in position, the gold should be carefully condensed over the gingival border of the cavity by forcing the matrix slightly away from the margin with the plugger and slipping the gold in between the margin and the matrix. This may readily be done with a plugger formed like that in Fig. 84, placing the serrated end on the gold and tipping the shank against the matrix to force it back. When this is successfully accomplished along the entire gingival margin, and the non-cohesive gold is covered by a layer of cohesive pellets, the mallet may be used to secure thorough condensation over the whole area of gold, and especially at the junction of the gold with the matrix. The plugger should be carried step by step along the matrix-wall until the filling is hard and dense. If this precaution is taken throughout the operation, and if the gold is not laid on in too large masses, there will be no doubt about the uniformity of density on the proximal surface of the filling.

To secure the best results in building against a matrix, the

pellets should be laid with their sides to the matrix and their ends looking buccally and lingually, while the filling should be kept nearly horizontal.

As has already been intimated, from the time the first pieces of gold have been forced between the matrix and enamel the appliance should be kept sufficiently away from the cavity during the operation to admit of carrying the gold well over the peripheral enamel-margin. (Fig. 91.) With these precautions there is no need for poor work with the matrix, but unless an operator is prepared to give close attention to the points indicated he would better dispense with the appliance altogether. It is an appliance which if abused or misunderstood is exceedingly treacherous, and will result in very faulty work, but if used with judgment and care it is capable of materially lessening the strain of these complicated operations, and will prove a source of great satisfaction to the operator.

FIG. 91.



The plan of building these ocluso-proximal fillings will be considered in greater detail under the heads of the different cavities.

Disto-Occlusal Fillings in Left Lower Bicuspids and Molars.

With the matrix in place a rope of non-cohesive gold of suitable size should be grasped with the pliers and one end carried into the gingivo-lingual angle, and the rope folded on itself at convenient intervals along the gingival wall toward the buccal wall. If the rope is not of sufficient length to reach entirely to the buccal wall when thus folded, another rope should be started in the gingivo-buccal angle in the same way and the two ropes joined. With a mass of non-cohesive gold thus laid along the gingival wall, the condensation should begin by taking a square-faced plugger with a serrated area as broad as the width of the gingival wall mesio-distally, and bringing it down on the gold with hand pressure toward the gingivo-lingual angle. A plugger of this size will carry the gold ahead of it instead of puncturing it, as would be the case with one of too limited area; and if operated in the swaying motion already described it will insure perfect adaptation of the gold without the rope following the plugger out of the cavity.

When the plugger has been brought to bear on the non-cohesive

gold at several points along the gingival wall, so as to compress the gold partially into position, a cylinder of cohesive gold wide enough in diameter to reach from the axial wall to the gingival enamel-margin should be laid in the gingivo-lingual angle with its side upon the gold already in place and one end looking along the gingival wall, while the other is slightly tipped up against the lingual wall and looks along this wall. This should be forcibly driven into the structure of the non-cohesive gold in the direction of the gingivo-linguo-axial angle by hand pressure with a smaller plugger exerted in the swaying motion, and when securely pinned into place, by bringing the plugger to bear on it at several points in this manner, another cylinder may be laid a little farther along the gingival wall toward the buccal wall, but still lapping the cohesive cylinder already in place. This process should be continued with hand pressure till the cohesive gold reaches across the gingival wall to the buccal wall, and especial care should be taken to force the last cylinder so placed securely into the gingivo-buccal angle. When the filling is thus locked in position the mallet may be used to condense the entire mass, starting the plugger at either the gingivo-linguo-axial angle or the gingivo-bucco-axial angle, as the case indicates, and carrying it step by step across the cavity, directing it first along the gingivo-axial angle. The object is to secure the greatest degree of adaptation and density in this angle, to the end that the filling may be so seated in position that there is no possibility of subsequent movement from manipulation. A convenient form of plugger for this purpose is found in Fig. 84.

After density is gained along the gingivo-axial angle a broader faced plugger may be used to condense the remaining gold, provided the area of the gingival wall is great enough to call for it. Usually in bicuspids the width of the gingival wall mesio-distally is so limited that the form Fig. 84 is as large as can well be used.

When the gold is thus malleted down upon the gingival wall the plugger should be directed into the angle formed by the junction of the matrix with the margin of the cavity, and the gold should be carried against the matrix and over the entire gingival margin. This will force the matrix slightly away from the margin as pre-

viously advised, and insure perfect adaptation of gold over the enamel.

The operation now presents with the gingival portion of the filling in place, a cushion of non-cohesive gold lying against the gingival wall with a layer of thoroughly condensed cohesive gold covering it, and the whole mass securely seated on the gingival wall and locked between the buccal and lingual walls. A filling thus started in a cavity of proper form cannot by any means be made to rock or loosen with subsequent manipulation. It is firmly seated on a flat base and supported laterally by perpendicular walls, so that there is no possibility of tipping, provided the gold has been well adapted and made dense. The virtue of creating angles to join the walls of these cavities, as advocated in considering their preparation, is now especially apparent to the operator as he starts the filling. There is a sense of security to his work obtainable in no other way.

The building of the filling from this stage to the point where the proximal portion of the cavity joins the occlusal anchorage step is simply a process of laying the cohesive cylinders on the gold already in place with their ends looking buccally and lingually, and malleting firmly to place. These cylinders should be wide enough to reach from the axial wall to the matrix, and the filling should be kept as high along the matrix as along the axial wall. When a cylinder is placed near the buccal or lingual wall the end should be turned slightly up against this wall, so that when condensed it will leave the filling a trifle higher along these walls than at other points. This is to insure the possibility of directing the plugger against these walls, and also to avoid the danger of leaving a pocket between the condensed gold as it approaches the occlusal surface and any possible overhang which may exist in the cavity at this point. This overhang relates to two conditions, either where it has not been possible to make the cavity as wide bucco-lingually at the marginal ridge as at the gingival margin, or where decay has so eaten up under the cusps that an arch is formed to the cavity under which the gold must be adapted. It is not always possible or at all advisable to cut up through this arch so as to create a

perpendicular wall to the cavity for facility in building the gold. Neither of these forms of cavities may be considered ideal, but in the mouth we must meet the issue of reality as well as ideality. In cavities thus formed the gold must be kept higher along the buccal and lingual walls than at any other point, and if a pocket should be encountered on approaching the occlusal aspect of the cavity some non-cohesive gold should be wedged into it.

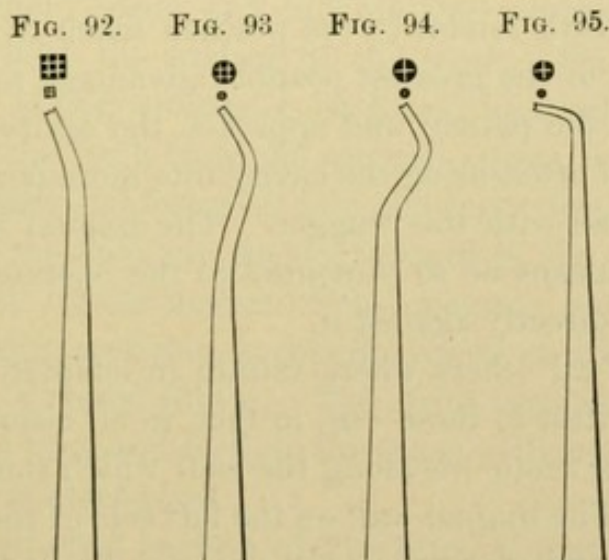
A modification of this method of building the gold may be advantageously followed in those cases where the cavity is broader bucco-lingually at the occlusal surface than at the gingival margin. In such cavities the buccal and lingual walls diverge as they approach the occlusal surface, thus presenting an open aspect to the cavity which renders the buccal and lingual walls easily accessible at all points. With a cavity so formed the gold may be kept as high in the central portion of the filling as at the buccal and lingual walls, or it may even be a trifle higher in the center so as to dip down slightly toward these walls. Into the angle thus formed between the walls and the filling cylinders may be so wedged as to most effectively lock the gold between the buccal and lingual walls, and lend a security and solidity to the filling unattainable in any other way.

When the filling is level with the anchorage step on the occlusal surface a cylinder should be laid with ends looking mesially and distally, one half over the gold already in place and the other extending into the step. After this is condensed another cylinder should be laid in the same way a little farther along the step, but still lapping the condensed gold, and this process continued till the base of the step is covered. By this arrangement of the cylinders the proximal portion of the filling is most securely locked into the step. The malleting should be especially thorough along the angle formed by the base of the step with the surrounding walls, and from this point to the completion of the filling each cylinder should be carefully laid on its side precisely at the point where it is intended to condense it; and this cylinder should be made perfectly compact before another is added. This conduces to an even and uniformly dense surface to the filling.

As has previously been intimated, there is one point in building these fillings which requires especial attention with relation to its density. While the gold is being built against the matrix-wall, and the matrix is thus forced against the contact-point of the proximating tooth, the greatest care should be exercised in malleting the gold firmly against the matrix in this region to insure a hard, dense contact-point on the filling. The ability to accomplish this with ease forms a not unimportant argument in favor of the matrix for these distal fillings.

Pluggers.

The form of plugger found most serviceable for carrying the non-cohesive gold to place in starting the filling is found in Fig. 92. This plugger is large enough to carry the non-cohesive gold in



front of it instead of puncturing it. The serrations are comparatively coarse and deep, thus leaving an indented surface on the gold to facilitate the interlacing of the cohesive with the non-cohesive. The shank is heavy and rigid, permitting of great force without springing; and the curve is such that the gingival wall of most cavities can readily be reached with it.

For forcing the first pieces of cohesive gold to place in the angles Fig. 84 is admirably adapted, and in cavities which are narrow mesio-distally most of the filling may be built up with it. It is also especially useful along the matrix-wall. In cavities of broader

area the form illustrated in Fig. 93 may be utilized, except for the angles or against the matrix. These rounded forms are not indicated along straight perpendicular walls, but for building the main body of the filling they are sometimes very useful.

In cavities far back in the mouth the curve in Fig. 93 will not always be found great enough, and in this event Fig. 94 may be utilized. This will reach where Fig. 93 will not. But even with this plugger there are many places in these distal cavities which cannot be reached with mallet force at all, and then resort must be had to right-angle pluggers and hand pressure. A convenient size for this is shown in Fig. 95. This plugger may be used along the buccal and lingual walls of these cavities, and, in fact, in any position not accessible to mallet force.

One great aid to the building of these disto-occlusal fillings on the left lower teeth relates to the position taken by the operator. It is frequently of the greatest possible advantage to go around to the left side of the patient and approach the cavity from this aspect. This will often bring the cavity into more perfect view and give better access with the plugger. The lingual wall will ordinarily by this means be so presented to the operator that he can mallet his gold directly against it.

The point of all others where failure in adaptation to walls is most often manifest in these—as, in fact, in all disto-occlusal cavities on the lower teeth—is along the wall which stands nearest to the operator. The lingual wall on the left side of the mouth often suffers in this particular unless the operator avails himself of the advantage of condensing from the left side of the patient at such intervals in the work as may seem desirable. This practice will also be found effective in those cases on the molars where the occlusal portion of the cavity involves the fissures so as to extend across the tooth bucco-lingually and pass between the mesial and distal cusps. The wall of the cavity which stands nearest the mesio-lingual cusp cannot be reached by mallet force from the right side of the patient, but by passing to the left the operator may get convenient access to it. In working from the left side the mirror should be used in the left hand, to hold back the angle of

the mouth and reflect light into the cavity, while the plugger is being used in the right. The pluggers indicated for this work must be suggested by the demands of the particular case, but ordinarily such forms as Figs. 84 and 94 will be found effective. The latter is especially useful in building the bulk of many of these large fillings, on account of the reach occasioned by the curve in the shank and the angle at which it is thus possible to present the serrated end to the gold.

Finishing the Filling.

When the matrix is removed a thin burnisher should be used to go along the margins and press down the slight excess of gold over the enamel, after which a narrow finishing strip may be passed into the interproximal space and the gingival portion of the filling dressed even with the surface of the tooth. On account of the close contact, it will ordinarily be found impossible to force this strip between the teeth from the occlusal aspect, in event of which it may be passed end-foremost into the space from the buccal aspect. When the ends are drawn forward in the mouth they are readily grasped by the fingers of the operator, and are more conveniently manipulated than is possible where an attempt is made to use a strip on a mesial filling. The strips used should be narrow enough to play back and forth in the space without danger of dressing down the contact-point.

When the gingival portion of the filling is perfectly finished, a sand-paper disk may be used in the engine to play along the buccal and lingual margins as they approach the occlusal surface and dress the filling even with the surface of the tooth, but the disk should not be allowed to pass between the teeth, through danger of cutting down the contact-point and creating a flat surface. The disk may also be used to advantage to smooth that portion of the occlusal surface of the filling which slopes from the contact-point up toward the cusps, by tipping the disk slightly and forcing it into position with a ball burnisher.

To polish the proximal surface of the filling immediately at the contact-point a broad, fine finishing strip should be used,

merely with the object of smoothing the gold, without cutting it away. If the filling is so tight against the proximating tooth that even a thin strip cannot be passed between the teeth, a separator may be employed to gain the slight space necessary, or, if this is not practicable, the broad, thin burnisher previously mentioned in connection with the finishing of proximal fillings in incisors may be forced between the teeth and manipulated with a rotating motion till the gold is burnished smooth and the way cleared for the introduction of the polishing strip. This broad burnisher will be found very serviceable in all these contour fillings where contact is close, and it should be in the hands of every operator.

When the proximal surface of the filling is thus dressed to form and polished, the rubber dam should at once be removed and the occlusal surface ground to form with corundum stones kept moist. The patient should be instructed to close the jaws frequently to test the necessary fullness to which the filling may be left without interfering with the occlusion, and in the event of a sharp cusp from the opposing tooth striking so far into the filling as to necessitate grinding it too thin, it is always advisable to shorten the cusp of the opposing tooth somewhat rather than make the filling weak and render the filled tooth subject to the danger of being split in mastication. When the filling is ground to the proper form with the stone it may be finished with a moose-hide or rubber point carrying moistened pumice till all the scratches left by the stone are removed, after which a high polish may be given it with whiting.

Disto-Occlusal Fillings in the Right Lower Bicuspids and Molars.

The same general plan of building these fillings may be followed as has been suggested for the left side of the mouth, except in one important particular. The buccal wall of these cavities on the right side of the mouth is almost invariably inaccessible to mallet force, and it would therefore seem necessary to build the filling along this wall by hand pressure with a plugger formed like Fig. 95. This should be grasped in the palm of the hand and the gold vigorously pulled against the buccal wall, and particularly into the

angle formed by the junction of the buccal with the axial wall. Occasionally it will be found necessary in teeth far back in the mouth to build the entire gingival third of the filling with hand pressure, but ordinarily mallet force may be employed on all parts of the filling from the gingival wall up, except along the buccal wall.

Another point where right-angle hand pressure is indicated in these fillings is in the angle formed by the base of the anchorage step and the mesial wall of the step. This is a wall which looks away from the operator, and the base of the step cannot be seen at this point except with the mirror. It is therefore impossible to reach it with direct mallet force, and the strong right-angle plugger should be employed to lock the gold into this angle and build it up to the point where the mallet blow is effective. Unless this precaution be taken, there is quite likely to be a bridging of the gold over the angle and a subsequent leak in the filling.

Disto-Occlusal Fillings in Upper Bicuspids and Molars.

The plan of building these fillings is practically the same as for lower teeth, except that mallet force may be more uniformly used here than on the lower jaw. Except in rare cases, the only place where the mallet may not be used after the filling is started is along the buccal wall of cavities on the left side of the mouth. Here it is often necessary to work by the aid of the mirror and adapt the gold with a large right-angle plugger grasped in the palm.

For the bulk of the work, when the filling has reached the point where mallet force may be used, such forms as Figs. 84, 93, and 94 will be found effective.

Mesio-Occlusal Fillings in Bicuspids and Molars.

The same arrangement of gold may be followed in building these fillings as for disto-occlusal surfaces, except that in mesial fillings mallet force is almost universally applicable. The better access to this kind of a cavity would seem to render these fillings more easily inserted than distal ones, but there is one counter difficulty which becomes important unless it is fully appreciated and the

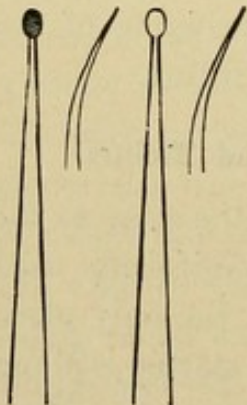
proper means taken to avoid it. This relates to the finishing of the filling along the gingival third of the proximal surface. As has already been stated, it is exceedingly difficult to manipulate a strip so as to cut against the mesial surfaces of these fillings. The ends of the strip cannot ordinarily be carried far enough back in the mouth to work effectively in the cutting of any great surplus of gold. The most that can be done is to smooth the filling after it is of the proper form.

It is therefore of the greatest importance that the filling when condensed shall present as nearly as possible the form it should assume when finished, and to this end a matrix should be used along the gingival third of the cavity to give the filling the most

desirable form while it is being built. A little time and care in the proper adjustment of the matrix will be amply repaid in the facility with which such a filling may be finished. In those cases where it is found that an appreciable surplus of gold has been built over the gingival margin so that its removal with the strip would be found a tedious and ineffective process, or in the instance of a tooth with a concavity on the proximal surface of the neck, as in an upper bicuspid where the strip will not reach, the gold may be dressed

to form with files or with keen-bladed trimmers. A suitable form of file for this purpose is found in the Rhein proximal trimmers (Fig. 96), which will reach between the teeth into the concavity and readily reduce the surplus. The effectiveness of these files may be greatly increased if, following a suggestion of the late Dr. George H. Cushing, the blades are sharpened and cut with the same care that is bestowed on the blades of a bur. Prepared in this way they take hold of the gold with a definite grip and peel it off rapidly, leaving a smooth surface.

FIG. 96.



Occlusal Fillings in Bicuspids and Molars.

The plan of building these fillings varies somewhat according to the extent and form of the cavity. A narrow deep cavity calls for

an arrangement of the pellets of gold different from that of a broad and comparatively shallow cavity. In the narrow cavity the entire area of the pulpal wall or seat may be covered by the first piece of gold inserted so that it is wedged between the surrounding walls, and the filling may grow from this in regular layers at right angles with the long axis of the tooth till the cavity is full. In a broad cavity this is not practicable. The filling must be started in one extremity of the cavity and carried across the pulpal wall pellet by pellet, till a sufficient number have been placed to reach from one perpendicular wall to another.

The idea in fastening these fillings in position against possible dislodgment is to securely lock the gold between the surrounding walls of the cavity and into the angle formed by the junction of these walls with the pulpal wall or seat. If these angles are formed on correct mechanical principles and the pulpal wall is made flat, as suggested in considering cavity preparation, the gold may be inserted with the greatest facility and the filling anchored beyond the possibility of displacement under stress of mastication. The wear on these fillings is often very severe, and the gold, in order to do the most permanent service, must not only be perfectly adapted to the walls, but must be made dense and hard. As has already been stated, the hardness of gold can be largely increased by continued malleting, even after compactness has been reached, and in the insertion of these fillings the operator should take advantage of this fact in order to secure as perfect a wearing surface to his fillings as possible. As the last pieces of gold are added the malleting should be carried somewhat beyond the point of compactness, until the operator can detect a hard, metallic ring to the surface of the filling. This does not imply prolonged or injudicious hammering on the gold to the injury of the peridental membrane or the enamel-margins. Care should be exercised not to go beyond the necessities of the case, but the idea should ever be present that these fillings, of all others, require the greatest density and the highest degree of resisting power.

If an operator will consider carefully the amount of aggregate service which such a filling is likely to be called upon to perform in

the course of its allotted life, he will be more seriously impressed with the necessity for the greatest care and thoroughness in its condensation. The repeated impact in the process of mastication aggregates enormously in a single year, and a filling inserted in the mouth of an individual of early or middle life with an expectancy of twenty, thirty, or even forty years' service must needs be of the highest order of excellence to meet the requirements. As has already been intimated, the proper mastication of an ordinary meal involves at least one thousand occlusions. Supposing that the force of one-half or even one-fourth of these falls on a certain tooth, the number of impacts on that tooth in the course of a twelvemonth is seen to be very great. Multiply this by the number of years such a tooth is likely to be called on for service, and the sum becomes well-nigh appalling. The force of these impacts varies in different mouths, and there is also a considerable range in the degree required for the comminution of the different kinds of food material in the same mouth; but the lowest force necessary for ordinary mastication is at least great enough to become an important factor in determining the degree of density required of a filling against which it is brought to bear.

In an extended study of the greatest possible force that could be exerted by closure of the human jaws, Dr. G. V. Black found that upon the molars it ranged from twenty-five pounds to three hundred pounds, and that the force in common use in mastication was greatly in excess of preconceived ideas on the subject.

Suppose, then, a filling on the occlusal surface of a lower molar with the cusp of an upper molar occluding directly against it, and this filling at each meal receiving the impact of the upper cusp crushing food-material between it and the filling at the rate estimated, it will readily become apparent that to do permanent service the material of which the filling is made must be capable of withstanding considerable wear.

The reason that many fillings of poor structure have been known to save teeth for years is accounted for in the fact that they have been so situated with relation to the opposing tooth that the particular filling in question has not received the full force of masti-

catory usage, but such a possible contingency as this should not deter an operator from making his fillings uniformly of the highest degree of excellence. If we could have the record of all the fillings which have failed as the result of imperfect condensation, and place it beside the number of such fillings that have succeeded, the evidence would be overwhelmingly in favor of dense fillings.

Insertion of Gold in Occlusal Cavities in Lower Molars.— Usually these cavities are so large in area that the gold must be started in one extremity of the cavity and carried across the pulpal wall toward the other extremity piece by piece, instead of wedging from one wall to the other at the beginning. Fillings of this character should ordinarily be started in that portion of the cavity most remote from the operator, and built progressively toward the wall nearest him. A rope of non-cohesive gold should first be carried into the angle formed by the junction of the distal wall of the cavity with the pulpal wall or seat, and into this non-cohesive gold should be forced a cylinder of cohesive gold and the whole mass driven to place with hand pressure, followed by the mallet. The cohesive cylinders should now be added one after the other, with their sides against the mass of gold already in place, and each cylinder condensed by mallet force over its entire surface. The ends of the cylinders should look toward the pulpal wall and the occlusal surface of the filling, except that as the filling is being built forward the portion near the pulpal wall should be slightly in advance and extend farther toward the mesial than that at the occlusal surface. This presents an inclined surface of gold to the operator against which the plugger point may have a direct bearing, and the cylinders should be laid with their sides upon this incline. Each cylinder should be long enough if possible to reach from the pulpal wall to the extreme elevation of the occlusal surface of the filling.

As the point is reached where the cavity widens out buccally and lingually between the mesial and distal cusps, care should be exercised to wedge the gold securely into the angles formed by the junction of the pulpal wall with the lingual and buccal extremities of the cavity. These portions of the filling are sometimes lifted

out of place by the use of adhesive materials such as sticky candy, etc., unless the precaution is taken to so deepen the cavity at these points as to afford ample retention, and then condense the gold firmly into place.

There are two points from this to the completion of the filling which demand especial attention,—the wall which looks toward the mesio-lingual cusp on left lower molars and the mesio-buccal cusp on right lower molars, and also the mesial extremity of cavities on either side of the mouth. Unless the operator be very cautious, these places will be bridged over and the filling fail of perfect adaptation and density. As has already been intimated, the difficulty of approaching these walls by mallet force on the left side of the mouth may be largely overcome by operating from the left side of the patient, but on the right side there is no alternative except to use curved pluggers and pull the gold into position.

When the walls are protected and the filling built flush with the masticating surface, the entire area of exposed gold should be thoroughly malleted to perfect density. This may be done with pluggers of shallow serrations or no serrations at all, and the final blows of the mallet should be struck along the margins of the filling.

Insertion of Gold in Occlusal Cavities in Upper Molars.—These cavities are usually of such an area that the first piece of gold inserted may be made to cover the entire pulpal wall so as to wedge between the surrounding walls. A non-cohesive rope of sufficient size to fill about one-third of the cavity should be used to start the filling, and into this the cohesive cylinders may be interlaced till the two forms of gold are locked together. When the filling is nearly completed the cylinders should be carefully laid in regular layers, with their sides upon the filling already in place and condensed with pluggers having shallow serrations, to the end that the surface of the filling may be made uniformly dense and even.

In those long, narrow fissure cavities, such for instance as those which follow the disto-lingual groove, the filling should be started in one extremity of the cavity and built progressively across to the other extremity, but the same principle of wedging the gold be-

tween the two lateral walls of the cavity should be followed throughout. The fact should never be lost to view that in the insertion of all gold fillings, no matter where located, the prime requisite for success is adaptation of the gold to the walls. This is more important, if possible, even on these occlusal surfaces, than a high degree of density, and yet the thorough and careful operator will not stop short of securing perfect adaptation and high density.

Insertion of Gold in Occlusal Cavities in Bicuspids.—The most difficult fillings to insert successfully on any of the occlusal surfaces are those in the small round pit cavities sometimes found on lower bicuspids. They appear to be the simplest possible form of cavity to fill, and yet they really demand a higher order of skill than cavities of much larger area. Unless the cavity has well-defined angles and a flat pulpal wall the gold has a tendency to roll under pressure, and there seems to be an especial difficulty, particularly with beginners, in securing good adaptation to the walls of these round holes. Then in some instances the occlusal portion of the filling is inclined to loosen as the final malleting is being done and come away from the gold in the depth of the cavity, leaving a little peg of gold to which it seems almost impossible to attach any fresh gold.

The proper method of inserting these fillings is to use a mass of non-cohesive gold of sufficient size to fill at least one-half of the cavity, and force a round plugger slightly less in area than the cavity into the center of the mass and wedge it in every direction with hand pressure wielded in the swaying motion before referred to. This leaves a depression in the middle of the filling, with some non-cohesive gold standing up against the surrounding walls of the cavity. A small cylinder of cohesive gold should now be wedged into the depression in the non-cohesive gold with hand pressure, and the whole mass forced in all directions,—toward the pulpal wall and against the surrounding walls. The pressure should be very vigorous, but the manipulation must not be kept up too long through fear of overworking the surface and rendering it difficult to attach more gold to it. Most of the filling should thus be built up by hand pressure on the wedging principle, and the mallet used

only on the immediate surface. If this plan be followed the operator will secure good adaptation to the walls through the medium of the non-cohesive gold, and the two kinds of gold will be so wedged or interlaced together that the surface of the filling will not flake off.

In cavities long and narrow, such as are ordinarily found on upper bicuspid and on lower second bicuspid, the method of inserting the gold is the same as for similarly formed cavities on molars. The gold should be started in the distal region of the cavity and built across to the mesial. The point in these fillings requiring especial care in adaptation is in the angle formed by the junction of the mesial with the pulpal wall. Unless the operator watch this angle carefully, he will be likely to bridge the gold over it and leave an imperfection in the filling.

Finishing Gold Fillings on the Occlusal Surfaces of Bicuspids and Molars.—As soon as the filling is thoroughly condensed it is ordinarily well to remove the rubber dam before finishing. The operator should make it a rule not to encumber his patient longer than possible with this necessary but disagreeable adjunct to the operation, especially in view of the fact that these fillings can usually better be finished without it. The most effective means of dressing the filling to form is by the use of corundum stones in the engine, and these should invariably be kept moist to facilitate the cutting of the stone and to prevent heat. The form of stone best adapted for most cases is the wheel, and they should range in sizes from a very large, thick wheel to a small, narrow form to meet the varying cases presented. Care should be taken to test the occlusion by repeated closure of the teeth, to be assured that the filling is not left so high that an opposing cusp impinges too hard upon it.

When the filling is ground to the desired form it will be found that the stone has left its surface covered with scratches, which must be removed in order to give it a finished appearance. This may ordinarily best be done with moistened pumice carried on a moose-hide, leather, or rubber wheel, and when the filling is perfectly smooth some whiting may be substituted for the pumice and a bright polish given the surface.

In certain cases these occlusal fillings may be finished to advantage with sand-paper disks by tipping the disk at an angle and compressing it into place with a ball burnisher. In fillings of narrow area situated in depressions between cusps it is often difficult to reach them with stones without cutting the surrounding enamel. In these cases small finishing burs may be used with short, sharp blades to dress the filling to form, when it may be polished with pumice and whiting on wood points carried in the engine. In other cases these fillings may be advantageously reached by winding a short finishing strip on a small slot mandrel in the engine.

Buccal, Labial, or Lingual Fillings.

The same principles of inserting the gold apply to these cavities that have just been advocated for occlusal fillings,—viz, in all cavities of sufficiently limited area the first piece of gold inserted may be made to cover the entire pulpal wall and wedge between the surrounding walls, and the filling built up in regular layers parallel with the pulpal wall, while in cavities too extensive for such an arrangement the gold must be started in an extremity of the cavity and built across the pulpal wall piece by piece toward the other extremity. In either case the chief requisites relate to perfect adaptation to cavity-walls and a reasonable degree of density to the gold. As the surface of the filling is approached the aim should be to lay the cylinders on in a regular order, so as to obtain as nearly as may be an even surface which will not demand much cutting to finish it.

There is one point in the insertion of these fillings which calls for especial attention,—the gingival enamel-margin. Great care should be exercised as the filling is being inserted to adequately protect the margin without building a large mass of gold over it. The slightest deficiency of gold at this point jeopardizes the operation and mars an otherwise perfect filling, while a great excess of gold leads to a peculiarly irksome procedure in its removal. The operator therefore should study carefully the outline of the cavity as he is inserting the gold, and should aim to reproduce the original form of the tooth with just sufficient excess of gold to make cer-

tain of a perfect finish. A little extra care at this stage of the operation will save much time and annoyance subsequently.

Finishing the Filling.—Usually the most effective means of dressing these fillings to form is to employ a sand-paper disk in the engine, and for the proper approach of the disk it is ordinarily necessary to remove the clamp. But in every instance where possible the rubber dam should be left in position till the filling is finished, for the purpose of keeping blood and saliva away from the disk, and also to afford protection to the gum and avoid its laceration. The dam may be held back so as to expose the filling with the fingers of the left hand, or by a hand instrument with its point pressed against the surface of the tooth rootwise of the gingival margin of the filling. The disk should be smeared with vaseline or some suitable lubricant to prevent heating the filling, and also to allow it to play freely against the rubber dam without cutting or catching in it and rolling it up.

When the filling is dressed to the proper form a beautiful polish may be given it with a cuttlefish disk or with a small rubber cup on a mandrel carrying pumice, followed by whiting. Care should be exercised in finishing these fillings to avoid as largely as possible any undue laceration of the gums. Some slight irritation of the free margin of the gum is often unavoidable, and need not be considered serious, but when the gum is badly cut or torn it is not always reproduced in as perfect a condition as it originally was, and the healing is sometimes a slow and discouraging process. With ordinary precaution the gum may be so protected from injury as to entirely recover from the operation in a day or two, and lap over the gingival portion of the filling in a healthy pink condition.

CHAPTER X.

MANIPULATION OF PLATINUM AND GOLD IN FILLING
TEETH.

THIS material comes to us in two forms from the manufacturer, —in the rolled form the same as the heavier golds, and in the form of folds made from thinner foils. It is a matter of individual preference which form is used, though for ordinary work the folds will be found a trifle more obedient to the plugger and more easily managed than the heavier forms. The folds are about an inch in width, and may be cut into strips of a convenient size for the case in hand. There are three shades, 1, 2, and 3, the former having a predominance of gold and showing a decidedly yellow color on finishing, shade 2 containing a larger percentage of platinum and showing more of a platinum color than shade 1, while shade 3 gives a decidedly gray color almost like pure platinum. The shades may be varied in the mouth to suit the case.

The chief points of distinction between the management of gold foil and the management of platinum and gold relate to the annealing and the method of condensing. Platinum and gold requires greater care in annealing to the end that it be not in the least overheated, particularly if the folds are used and the annealing is done in a flame. To pass a strip through the flame in the ordinary way will almost invariably result in the ends curling up and the gold shade disappearing entirely, leaving a pure platinum shade. These ends when thus overheated are harsh, unworkable, and wholly unreliable. In every instance where by any inadvertence platinum and gold is so heated as to change color in this way, it should at once be discarded and no attempt made to use it. To gain the best results in the manipulation of platinum and gold it should be annealed over mica on the electric annealer, first placing a piece of mica on the annealer and allowing a slow steady heat to thus reach the material. If placed directly on the annealer it will sometimes be found that it will turn to a platinum color.

In building the filling with this material the operator must work a little slower and more deliberately than with gold. It cannot safely be added in as large masses as gold, nor is it so easily adapted to walls or margins. The condensation must be very painstaking and precise, small plugger points being used with the serrations shallow but sharply cut, and each piece malleted perfectly dense before another is added.

In view of the more exacting nature of the work it is seldom advisable to utilize platinum and gold for the entire filling, the most satisfactory results being obtained by employing gold for starting the filling, and building it to a point along the walls where it approaches the exposed surfaces, and then completing the operation with platinum and gold. This will materially shorten the work and produce the most perfect filling, on account of the more ready adaptation of gold to the inaccessible parts of the cavity. As the first pieces of platinum and gold are added to the gold already in place the smallest plugger points should be used, and the utmost care taken to force the platinum and gold into the structure of the gold so that the two are incorporated as one mass. If this precaution is taken the platinum and gold will never separate from the gold. As the extreme surface of the filling is approached the folds should be laid flat upon the filling in precisely the place where they are to be condensed, and the malleting should be very thorough, with the impact brought to bear step by step over every part of the surface area down to the minutest points. To omit even the smallest area from this mallet impact means that the portion thus overlooked is likely to flake when the filling is subjected to wear, and if the operator desires a satisfactory filling free from blemishes he cannot give too close attention to the surface condensation.

Platinum and gold, if thoroughly and uniformly condensed, will take on a beautiful finish which is not only satisfactory in its wearing qualities, but is highly artistic in appearance. In fact, it may truly be said that to produce a perfect platinum and gold filling is to attain the highest degree of excellence in the art of filling teeth.

CHAPTER XI.

MANIPULATION OF TIN AND GOLD.

A CONVENIENT method of preparing this material is to take a sheet of No. 4 pure tin foil and lay upon it a sheet of No. 4 gold foil, cutting these in three equal parts, making strips about an inch in width. These strips may then be twisted into ropes and cut into suitable lengths for the particular use intended. In twisting the ropes it is well to so arrange the layers of foil that the tin will be on the outside of the rope, thus resulting in a tougher product and one easily adapted to cavity-walls.

For building the gingival third of deep occluso-proximal fillings in bicuspid and molars, as already suggested, the ropes of tin and gold may be used much in the same manner that was advocated for gold alone, except that the plugger points should be more coarsely serrated, and nothing but hand pressure used in forcing the tin and gold to place. The ropes should be vigorously wedged to position into the angles and between the cavity-walls, the swaying motion of the plugger being especially indicated, and the very greatest amount of force used consistent with safety to walls and margins. One cardinal point in the manipulation of this material should never be lost to view,—the danger of overmanipulation. The plugger should be brought down upon it at a given point with slow, strong, wedging force, and as large a mass of the material carried to place as possible with this one thrust. The next position taken by the plugger point should be deliberate and carefully directed, and another area of the mass condensed in the same manner. If manipulated in this way the material will go to place readily and remain there, while the integrity of the resultant mass will not be impaired, but if the material is in the least degree overworked by the plugger it chops up and disintegrates so as to ruin it. Many operators have failed to get satisfactory results with this material on account of overmanipulation.

After the requisite amount of tin and gold has been forced to

position with hand pressure, the surface will present coarse indentations resulting from the deep serrations of the plugger, and into this surface should be incorporated cohesive gold cylinders, using the same plugger with hand pressure till the gold reaches from the buccal to the lingual wall. As soon as the gold is securely locked across between these two walls and interwoven into the tin and gold, the coarse plugger should be laid aside and a plugger with shallower serrations substituted for it. Up to this point the process has been one of wedging with hand pressure and an interlacing of the layers of tin and gold together, and also of the gold cylinders into the tin and gold. There is no cohesion between the tin and gold, nor between this and the cohesive gold, so that they must be interwoven in the manner indicated. But from this point the mallet should be used and the layer of cohesive gold should be very vigorously malleted down onto the tin and gold till the entire mass is made compact and dense. From this the filling is completed with gold in the ordinary way.

The finishing and polishing of the tin and gold at the gingival margin is in no wise different from that advocated for gold.

In filling occlusal cavities in bicuspids and molars for children with this material, a rope should be selected if possible large enough to fill the entire cavity and leave a sufficient surplus for a perfect finish. If the cavity is found to be too extensive for one rope to fill, care should be taken that the first rope used shall not be so large as to carry the filling too near the occlusal surface. In other words, the final rope should be allowed to extend sufficiently into the cavity to be firmly locked between the surrounding walls and be retained by reason of this locking rather than from any union between it and the mass already in place. Tin and gold, as has been said, is not cohesive, and while the layers may be interwoven to a certain degree, yet the union thus formed cannot be considered sufficiently secure to hold the final piece in place against any appreciable wear. If the operator finds in condensing the first rope that it is likely to carry the filling too close to the occlusal surface, he should tear off a piece and lay it aside so as to leave an appreciable depth to the cavity before adding the last rope. This use

of two or more ropes instead of making a single rope of sufficient size to fill any of these occlusal cavities is advocated because of the unwieldy nature of a rope which is much greater than an inch in length.

In view of the fact that it is seldom advisable to use this material in cavities having a very broad area presented to the occlusal surface, on account of the tendency to rapid wear under such conditions, the usual method of inserting the filling is to wedge between surrounding walls, the limit of the cavity ordinarily being such as to permit of this plan. The rope should be grasped by the pliers about five or six millimeters from the end, and this end carried into the cavity so as to fold upon itself against the pulpal wall. The rope should then be grasped a little farther back and folded again into the cavity, this process being kept up till sufficient of the rope has been gathered into the cavity to constitute an appreciable mass when condensed and permit of being wedged between the surrounding walls of the cavity. If the cavity is so deep that it will require more than one rope to fill it, the first rope may be nearly all carried to place with the pliers before the plugger is used to condense it, but if only one rope is required the condensation should begin after the first half has been forced into place and while the other half is still hanging free from the cavity.

The manner of condensing is by hand pressure, using a stiff-shanked, coarsely-serrated plugger. This should be forced toward the pulpal wall in the middle of the mass of material, and then vigorously swayed in every direction to carry the material snug and tight against the surrounding walls, using as much force in these movements as can safely be done short of injury to tooth-tissue or the peridental membrane. The same precaution against overmanipulation is necessary here as with the gingival portion of proximal fillings. When a few vigorous and effective wedging movements have been made against the mass, some more of the rope should be gathered into position and the wedging continued. As the surface is approached the free end of the rope should be folded over so as to look toward the pulpal wall, and it should be forcibly driven into the mass of filling-material and interwoven

with it, leaving the looped side of the rope presented to the occlusal surface. Care should be taken to have the material somewhat more than flush with the orifice of the cavity, but this surplus should not be manipulated to any extent with the plugger point. For the surface condensation a large ball burnisher should be used, and the filling vigorously burnished into the cavity and against the margins till the surface is as hard as this material will permit.

To dress the filling to form and give it an even surface a fine corundum stone may be used in the engine, or in cases of a very small filling in a deep depression between cusps where a stone will not reach a finishing bur may be substituted. In places where the sand-paper disk may be made to reach the filling by forcing it to place with a ball burnisher, this will be found the ideal method of finishing these fillings.

The use of tin and gold in these small occlusal cavities in children's teeth is strongly advocated in preference to amalgam. Contrary to the prevailing impression in regard to the matter, it can be inserted more expeditiously than amalgam, and if properly manipulated it is more certain in its results. It is less treacherous than amalgam. If it fails it does so in a manner at once recognized, while amalgam may appear perfect to the naked eye and yet be leaking so badly as to cause the enamel to be undermined by decay for a considerable area around the deeper portions of the filling. Tin and gold does not shrink or change form as does much of the amalgam in use, and it is accordingly a better protection to the cavity-walls. If an operator becomes expert in its manipulation he will find a large range of usefulness for it in his practice, and it will not prove a disappointment. In using tin foil for filling teeth the same general plan of manipulation is indicated as that just outlined for tin and gold.

CHAPTER XII.

MANIPULATION OF AMALGAM.

It may be considered scarcely practicable to lay down any invariable rule in regard to the percentage of mercury which must be mixed with an alloy to gain the best results in an amalgam. The vast number of alloys on the market and the variable requirements in the different makes render the question of percentage a difficult one. The most that can be done is to suggest in a general way the manner of mixing the alloy with the mercury, and indicate as accurately as may be the proper consistence or plasticity of the mass to secure the best results. While it is a mooted question as to whether or not it may be injurious to an amalgam to so mix it that an excess of mercury is added and subsequently wrung out before inserting the filling, it will be found that practically under present conditions the most uniform product may be obtained in that way. If manufacturers would put up their alloy in small capsules with an accompanying capsule of mercury accurately weighed out in the per cent. that has been demonstrated by experiment to be the best for that particular alloy, it might be practicable to so mix amalgam in office work that there need never be any free mercury present; but the fact that this experiment has been tried by at least one manufacturer and failed to receive the support of the profession would seem to indicate that the profession was not willing to yield this much homage to the material. Neither can it be expected that practitioners generally will ever be persuaded to take the trouble to weigh out the exact proportions for each filling in the daily routine of practice, even where it is possible to ascertain the proper proportion for the alloy they are using. It would be the ideal method if this could be done, but it may well seem fruitless to advocate any method of practice which the profession manifestly will not follow.

In our teaching we must aim to accomplish the greatest good to the greatest number, and with the varying alloys on the market the surest way to do this is to give the technical procedure neces-

sary to the best preparation of the alloy for filling. With most of the alloys at present in use by the profession the amalgamation of the mass does not seem to take place so readily as those in common use a dozen years ago, and the mass therefore requires more extended mixing in order to secure a perfect incorporation of the mercury with the fillings. To do this it is advisable to use a pestle and mortar at least in the early part of the mixing. This mortar should be of appreciable size, and the inner surface of the bowl should be roughened. The small smooth glass mortars sometimes offered for sale for mixing amalgam are not at all suited to the purpose, there being insufficient area for trituration and no resistance to the gliding of the mass along the inner surfaces in front of the pestle. A roughened surface results in the ingredients being caught between the pestle and the mortar so that they receive the proper amount of grinding.

Sufficient mercury for the case in hand should be placed in the mortar, and filings added little by little as the grinding proceeds, until the mass reaches a consistence which would seem to indicate that if more filings were added it would interfere with the plasticity of the product and render it granular. At this point it is well to transfer the mass to the palm of the hand and knead it quite vigorously with the ball of the finger of the other hand. This kneading will usually result in increasing the plasticity of the mass, and if it is found that too much mercury is apparent some more filings should be added and the kneading continued. The mass should be mixed just to the point where there seems to be a complete incorporation of the filings with the mercury and where pressure of the mass, such as wringing vigorously in chamois or strong linen with the fingers, will result in a minute quantity of mercury being expressed from it. In view of a possible disarrangement of the formula of the alloy by carrying away more of one metal than another in the expressed mercury, it is always well to have the mass of such consistence that it is possible to wring out only a very small amount. When the mass is taken from the linen it should break apart easily with little apparent plasticity to it, and if the amalgam is of the quick-setting variety it should be kept

under constant movement till the last piece is condensed in the cavity. That is, when part of it has been placed in the cavity preparatory to condensing it the portion remaining on the operating table should be kneaded by the assistant till it is required, and if the operator has no assistant he should manage in some way with the fingers of his left hand to keep the mass in motion. If he finds this impracticable he would better select a slower-setting alloy.

Method of Packing Amalgam.

The pluggers used for this purpose should be flat-faced instead of rounded, and should be as large in area as can conveniently be employed in the given cavity. The idea should always be to carry the mass in front of the plugger directly against the cavity-wall, instead of having it squeeze out alongside the instrument. Amalgam should not be treated as if it were intrinsically a plastic material and could be patted to position with little force. Amalgam to gain the best results must be condensed by heroic pressure. If too small an instrument is used, a sufficient pressure for proper condensation will result in the plugger piercing the mass and driving the material to either side of it. The aim should be to keep the mass gathered before the instrument so that it is carried only in the direction toward which the force is exerted, and to accomplish this a broad flat-faced plugger is necessary, unless the area of the cavity is so small that the amalgam is forced against the surrounding walls. If a filling is to be made which is not more or less porous, the ingredients of the amalgam must receive vigorous compression. Realizing this, some operators recommend mallet force to condense amalgam, but it would seem to be immaterial which way the force is applied, whether by mallet or hand pressure, so long as the compression is sufficiently forceful.

Recognizing the character of amalgam, it will readily be appreciated that to secure the best results in its insertion it is necessary to have a cavity with surrounding walls instead of one with an open aspect and one wall missing, as in a proximo-occlusal cavity in a molar. All cavities, therefore, involving the proximo-occlusal surfaces should be reinforced by a matrix to gain the best results in

condensation. In cases of very extensive restoration where the tooth-tissue has been badly broken down, a matrix of thin German silver should be made for the case by wrapping a strip of the material around the tooth and tacking the ends together with solder. When this is slipped over the tooth it can be burnished to the proper form, and after the insertion of the filling the matrix may be allowed to remain on the tooth till the following day as a support to the amalgam during the process of crystallization. At the next visit of the patient the matrix may be cut and removed and the filling polished.

The manner of inserting amalgam is to take a small piece in the pliers and carry it to place in the cavity, condensing it thoroughly before another piece is added. As the filling is thus being built up piece by piece, if the compression results in bringing surplus mercury to the surface the soft mass thus resulting should be scraped from the filling and the next piece of amalgam added to the harder portion beneath it. An amalgam filling cannot have a satisfactory surface with an excess of mercury present. Even if it did not interfere with the integrity of the mass, there would still remain a physical reason why a softened surface is contraindicated. No operator can be certain that he has secured uniform adaptation to cavity-walls in the attempt to condense a soft mass of amalgam. This material under those conditions acts relatively like a mass of jelly, so that if the operator forces it against one margin it is immediately drawn away from another. The only possible way to be assured of adaptation to all of the outlines of a cavity in the effort to insert soft amalgam would be to have a plugger point as broad as the area of the cavity, and bring force over the entire surface of the filling at the same time. This, of course, is seldom feasible, and it will accordingly be apparent that to get good results with amalgam and produce a filling which does not leak at some point it must be used without an excess of mercury.

When the filling is built to the requisite fullness it should at once be trimmed to form before it is allowed to become hard. The occlusal surface may be smoothed by taking a pellet of tightly rolled cotton in the pliers and gently wiping it across the surface,

always in the direction of the margins. Any surplus on the proximal surface in the interproximal space must be carefully removed at this sitting with thin amalgam trimmers. If small particles of the material are allowed to extend over the cavity-margins at this point till crystallization has taken place it will be found very difficult to remove them, and if they are not removed and the filling made smooth and even with the surface of the enamel the gum in the interproximal space will invariably present an abnormal condition on account of the irritation. It is necessary to look as carefully to the finish of an amalgam filling at this point as to a gold filling, and the trimming to form should invariably be done while the amalgam is still semi-plastic. Close attention should also be given to the occlusion, so that an opposing cusp may not injure the filling by too great impact before it is hard.

When the filling is thus properly formed the case may be dismissed till another sitting, at which time it should be polished with the same care and in the same manner as a gold filling. Amalgam will take a most beautiful finish, and if inserted with painstaking care along the lines indicated, and polished at a subsequent sitting, the results in amalgam work will prove more beneficial and more uniformly satisfactory than we ordinarily see in the mouths of our patients.

CHAPTER XIII.

MANIPULATION OF CEMENTS.

IN the preparation of cement for filling teeth the plan of mixing is somewhat important. A quantity of powder sufficient for the case in hand should be placed upon the mixing slab, and a short distance from this the requisite amount of liquid. The means used to dip the liquid from the bottle should be such as not to contaminate the remaining contents of the bottle. The liquid of cement to give the most serviceable working quality should be of a consistence bordering closely on crystallization. In fact, a liquid

which presents no tendency to crystallization and which remains permanently fluid under all circumstances cannot be considered the safest kind of liquid for ordinary use in the mouth. This tendency in most of the reliable fluids renders it necessary to handle them with great care, to avoid as largely as possible the formation of crystals. Crystals are readily formed if small quantities of the liquid are left exposed to the air, and thus we find about the mouths of the bottles more or less of a crystallized mass, on account of leaving a surplus of the material clinging to the cork and smeared over the rim of the bottle. Small particles from this crystallized mass dropping into the bottle from time to time tend to start other centers of crystallization in the fluid, and the entire contents of the bottle may thus be contaminated. In view of this it is always desirable to keep the mouth of the bottle as free from the liquid as possible, and consequently the practice of pouring the liquid from the bottle to the slab is contraindicated. The liquid should be carefully dipped out and dropped on the slab by some instrument which is not in any way acted on by the liquid. The ordinary steel spatulas are more or less affected by the acid in the liquid, and should not be used either for dipping out the liquid or mixing the cement. Dr. W. V-B. Ames suggests for this purpose a spatula made of German silver, which is sufficiently rigid for a thorough trituration of the cement and which is not affected by the liquid. It need not be intimated that the spatula should never be placed in the liquid to dip an additional amount from the bottle after it has been used to commence the mixing. If more liquid is required, it should be dipped with a glass rod or some non-corrosive instrument.

In mixing the cement the powder should be added to the liquid little by little, the mass meanwhile being thoroughly stirred and rubbed with the spatula. Most operators fail to mix their cement with sufficient vigor to obtain a perfect incorporation of the powder with the liquid. The best results are gained by a very vigorous rubbing over a considerable area of the slab,—the powder being added till the mass is almost as stiff as freshly prepared putty. If it is to be used for the temporary sealing of medicaments in a

cavity or for any purpose where pressure cannot be used in its insertion, it may be left more plastic so as to flow with little resistance, but if to be used for fillings it should be made reasonably stiff and then forced into place with considerable pressure.

A convenient means of carrying the mass from the spatula to the cavity is to first gather the cement into a ball on the end of the spatula, and then, having some cotton rolled into a tight, compact pellet, grasp this firmly with the pliers and use it as a means of scraping the cement from the spatula to the cavity. The cotton must be rolled tight to prevent the cement from clinging to it. Some varieties of cements are more adhesive to cotton than others, but with most of them if they are mixed sufficiently stiff to yield the best results in fillings the tight cotton roll may be used very advantageously. When the cement has been pressed to place in the cavity with the cotton and the excess wiped away, still further compression may be made with a broad, smooth, flat-faced plugger just as the mass begins to crystallize, but after crystallization has once definitely set in the filling should not be disturbed by manipulation till it has become hard. The filling should be dressed to the proper form while it is still soft by the use of thin instruments of a form indicated by the requirements of the case, the trimming always being done toward the margins.

In using cement for children's teeth in those incipient cavities in the occlusal surfaces of bicuspid and molars, a most effective means of forcing the cement to place and keeping it dry for a few minutes after its insertion is to carry the material to the cavity in the ordinary way and press it into position with the cotton pellet, leaving an excess heaped up over the vicinity of the cavity. On this excess the ball of the operator's finger should be placed, covering the entire occlusal surface of the tooth and forcibly compressing the cement into position till the surplus is squeezed out over the marginal ridges of the occlusal surface. The finger should be most vigorously forced against the tooth and held there with considerable compression till the cement has begun to crystallize, after which the surface may be smoothed with an instrument.

CHAPTER XIV.

MANIPULATION OF GUTTA-PERCHA.

THE great desideratum in the use of gutta-percha is to so regulate the heat in softening it that the mass will be made sufficiently pliable to be readily inserted in the cavity without in the slightest degree overheating the material. If gutta-percha is brought into contact with the flame it is almost instantly charred and ruined, and should never be introduced into a cavity. The most effective means of heating it is on a warm porcelain slab placed some distance from the flame so that the heat is gradual and steady, but if the operator cannot take the time for this he may get satisfactory results by heating it over a flame, provided he exercises sufficient caution. The pieces of gutta-percha may be grasped in the pliers and held so far above the flame that the heat is not intense enough to injure the mass, and when sufficiently warmed they may be carried directly to the cavity and compressed to place. If the ordinary pink gutta-percha base-plate is used—and this makes a more permanent filling than any of the white preparations—there is another reason why the heating should be carefully watched. This material requires greater heat to render it soft than most other forms, and it is therefore inclined to cause pain when applied to a tooth with a living pulp, and the slightest degree of over-heating adds seriously to the discomfort. The idea with any gutta-percha is to warm with a low degree of heat continued for some time, the reason being that the conductive properties of the material are poor and it requires time to make the mass uniformly soft. A rapid heating at high temperature simply sears the surface without softening the entire piece.

For temporary work such as sealing medicaments in teeth the softer forms of gutta-percha known as the temporary stoppings are preferable to the base-plate. They are softened with much less heat, are readily molded to cavity-walls, making perfect sealing agents, and are more easily removed. In using them care must

be exercised not to overheat, because of the disagreeable stickiness which too much heat imparts to them. If gently heated they may be made soft at a temperature which will permit of the mass being kneaded between the thumb and finger like putty.

In finishing a gutta-percha filling the surplus may be trimmed away with a heated instrument, dressing always toward the margin. If there seems a tendency for the gutta-percha to curl away from cavity-margins the instrument should be made just warm enough to slightly soften the mass, and then the broad side of it should be placed forcibly against the surface of the filling and held there with considerable compression till it becomes cool. The gutta-percha will then remain stationary.

CHAPTER XV.

MAKING INLAY FILLINGS.

THE two kinds of inlays most in use are the porcelain inlays for exposed positions in the anterior teeth, and gold inlays in bicuspids and molars where the stress of mastication is an important consideration. An inlay is made by first fitting a thin metal matrix to the cavity, and then flowing into this the inlay material to the required contour and cementing it into position in the tooth.

Porcelain Inlays.

The demand for porcelain inlays sprang from the indiscriminate and inartistic display of gold in the anterior part of the mouth, whereby the esthetic sense of the people has been too frequently offended. If the profession had more carefully studied the possibilities of platinum and gold for harmonizing shades on exposed surfaces, there never would have developed the reflection upon dental art that has been justly urged against it, but it still remains true that there are certain cavities in which a well-made porcelain inlay is more artistic in appearance than it is possible to attain with any metal filling. It is also true that inlay work is less exhausting

to the patient than extensive filling-building, and these two considerations should induce every operator to so perfect himself in inlay work that he is enabled to give his patients the benefit of the highest class of skill in those cases where inlays are indicated.

The chief indications for inlays in the anterior teeth relate to cavities with an open aspect presented to the labial. These may occur occasionally in the labio-proximal region, giving a broad labial exposure with a strong lingual wall still standing, but the most frequent demand for inlays is in those cavities occurring in the labial surface near the gum. The preparation of the cavity for an inlay involves the thorough opening up of the cavity so that no overhanging walls are left. The orifice must manifestly be broader than the interior, else the inlay if accurately fitted will not pass to place, but on the other hand the cavity must not be

FIG. 97. left too shallow or too much saucer-shaped on account of the difficulty of maintaining an inlay in position in a cavity so formed. The marginal outline should be made symmetrical and artistic, but the enamel for a porcelain inlay should not be so extensively beveled as to necessitate a thin edge to the porcelain. If possible the surrounding walls of the cavity should flare out very gently as they approach the enamel-surface, thus readily admitting the inlay to place, and protecting the enamel without creating an attenuated and friable edge to the inlay. (Fig. 97.)



When the cavity is prepared a piece of platinum foil, about No. 60, and somewhat larger in area than the orifice of the cavity, should be thoroughly annealed and placed over the cavity. A tightly rolled pellet of cotton grasped in strong-pointed pliers should be used as the first medium of compression to partially carry the platinum matrix to place. When the platinum has been forced sufficiently into the cavity to curl up and fold over itself along the margins, it should be withdrawn from the cavity and the folds carefully straightened out with pliers. This should be done frequently during the process of fitting the matrix, to avoid as largely as possible the overlapping of the platinum around the margins. When the cotton pellet is no longer effective with the

pliers, a round-headed burnisher may be used to still further drive the cotton into the matrix. The advantage of cotton is that the matrix is thereby seldom torn in the early part of the fitting. When the cotton has done its utmost limit of work, a burnisher may be used to bring about a closer adaptation to the cavity by holding the matrix with a retaining instrument against one side of the cavity while the burnishing proceeds against the opposite side. Care should be exercised not to tear the platinum during the burnishing, but usually if a tear does occur it is in the deeper parts of the cavity, and can be remedied by burnishing a fresh piece of platinum over the break before the matrix is removed for the last time.

In using the burnisher the operator will find a decided tendency for the platinum to be drawn away from one part of the cavity while it is being forced against another. To overcome this and also to secure the closest possible accuracy of adaptation to the entire cavity the final fitting should be done by placing a mass of unvulcanized rubber into the matrix—more than sufficient to fill the cavity—and with a broad-ended instrument forcing the rubber down into the matrix and driving it vigorously with a rocking motion of the instrument into the remotest parts of the cavity. A very accurate fitting of the platinum can thus be obtained if the rubber is properly manipulated. When the rubber is removed, the matrix should be carefully lifted from the cavity and the surplus platinum overlying the enamel-surface trimmed away. In lifting the matrix from the cavity there is always more or less danger of warping it slightly or in some manner getting it out of form, and to avoid this it should be placed back in the cavity after the trimming and packed full of temporary stopping before it is removed for the last time. When the gutta-percha becomes hard the matrix may then be removed without change of form, and the stopping can be picked out without disturbing the matrix by first heating it very gently. During the entire process of fitting the platinum to the cavity it should be frequently annealed to keep it soft and workable.

The matrix is now ready for the reception of the porcelain, and

if the details have been carefully carried out the result is a matrix which fits the cavity so as to leave the smallest possible interstice for the cementing material to occupy.

The question of the most suitable body for use in porcelain inlays has been quite extensively discussed by the profession, and there seems to be much diversity of opinion as to whether a low-fusing or a high-fusing body is indicated. While every practitioner is justly entitled to his own individual opinion in the matter, it may safely be stated on general principles that if an operator wishes invariably to give his patients the best class of service he can do so only by the use of the higher-fusing bodies. The low-fusing bodies (those used in a matrix of gold) are too nearly akin to glass—or at least are too readily rendered glass-like in character by the slightest overheating—to make them reliable for such delicate work as inlays. The problem of shades is a most important one in inlays, and shading is never so certain with the low-fusing bodies as with the higher.

The counter-consideration may be urged that the high-fusing bodies are more exacting in regard to the length of time and the degree of heat required for fusing, and also that the operator is limited to the one metal, platinum, for the matrix, whereas with a sufficiently low-fusing body pure gold may be used to greater advantage on account of being more readily adapted to the cavity. These considerations should have very little weight with a conscientious operator who aims only to give his patient the benefit of the highest perfection in his art. If a porcelain inlay is indicated at all the very best possible inlay is none too good, and unless an operator is willing to give to this work the same painstaking care that he does to other intricate and delicate operations he would better dispense with it entirely. It is here predicted that much of the hasty-pudding porcelain inlay work now being done by the profession will result in bringing discredit on the reputation of dentistry, and it will not be the first instance where the public and the profession have suffered from the universal clamoring after an easy way of doing things.

Before an operator attempts porcelain inlay work he should

make himself familiar with the management of high-fusing bodies both in relation to the method of baking and the control of shades, and this can only be attained by actual experimentation with the material itself. It is without the province of this book to go more minutely into the subject of porcelain, except to say that for inlays a finer-grained product and an altogether more perfect porcelain is required than for any other kind of work in the mouth.

When the inlay is baked the platinum matrix should be peeled away, leaving the porcelain ready for setting. If the form of the cavity is such that the retention of the inlay is in doubt, the former may be undercut with a bur or excavator and the cavity side of the inlay grooved with a thin disk. In setting the inlay the cavity should be dry and the cement carefully mixed to such a consistence that it will require some force to squeeze it out from under the inlay, but it should not be so stiff that the inlay cannot be driven perfectly in place. In forcing the inlay a wooden point may be used, and considerable pressure should be maintained on the inlay for several minutes till the cement begins to crystallize, after which the surplus may be trimmed away and the margins wiped clean with cotton.

Gold Inlays.

There is really a wide range of usefulness for this kind of inlay in those cases—already indicated—where the extent of the decay has been so great that a gold filling is contraindicated on account of the nervous tax on the patient. The entire operation is much less exhausting than filling, and while the results can never be considered so permanent as with a well-inserted foil filling, yet if the cases are selected with discriminating judgment and the operation performed with painstaking care the practice is justifiable in many instances.

The preparation of the cavity must be along the same lines as for porcelain inlays, except that the question of anchorage is more important, and in proximo-occlusal cavities the occlusal step method should be followed wherever available. A gold inlay locked into a step at right angles with the proximal portion of the cavity is peculiarly calculated to remain secure against dislodg-

ment. Another distinction in the preparation of cavities for gold inlays relates to the treatment of enamel-margins. With gold inlay work the margins should be very freely beveled and the edges of the inlay carried well over them. This is one of the most serviceable features of gold inlays, that all thin or frail enamel walls may be dressed down and the inlay so built over them as to perfectly protect them. In contradistinction to porcelain inlays, the edges of gold inlays are very strong and capable of protecting weak enamel. This overlapping of the cavity-margin by the inlay would also seem to largely do away with the tendency for the cement to dissolve out to any appreciable distance under the inlay.

The matrix for gold inlays may be made from pure gold, which is more readily adapted to the cavity than platinum. A convenient thickness for this purpose is found in one of the heavier forms of rolled gold used for finishing fillings, such as the No. 60. The same general plan of fitting the matrix is followed as with platinum, except that in a proximo-occlusal cavity the gutta-percha when packed into the matrix previous to its final removal should be built out into perfect contact with the proximating tooth and trimmed to the exact form required of the inlay. The same care in inlay work should be exercised with relation to contour and contact that has already been advocated for an ordinary filling, and this shaping of the gutta-percha is preparatory to this end. When the gutta-percha and matrix have been removed from the cavity an investment should be made in soldering plaster so as to include the cavity side of the matrix, and pass around over the gutta-percha to assume the position of the proximating tooth. The removal of the gutta-percha after the plaster has become hard will leave a form to the plaster which indicates the required contour of the inlay. In case the matrix has been torn at any point a pellet of gold foil should be pressed gently over the ruptured place, and the solder on soaking into this will effectively repair the breach. A high-grade solder—about 20 carat—should be used to fill the matrix. The piece should be gently heated up to prevent the formation of steam under the matrix and its consequent displacement. In flowing the solder into the matrix it should be

built out to the form left in the plaster by the gutta-percha, which will result in a good contour, and the possibility of making a perfect contact point when the inlay is dressed to the proper form and polished.

In fitting the inlay to place before cementing it, attention should be given to the occlusion of the opposing tooth, and the inlay so ground that it will not require further attention in this respect when cemented. In driving the inlay to position into the cement a plugger and mallet may be used, and the inlay held firm till crystallization has commenced in the cement. After this has taken place if there is any unevenness along the junction of the inlay and enamel it may be ground smooth and even, and then polished with a sand-paper disk. A well-fitted gold inlay so inserted may often be mistaken for a beautiful gold filling, and this may be said to involve the highest excellence in gold inlays.

CHAPTER XVI.

PULP-CAPPING.

WHEN decay has penetrated a tooth sufficiently to reach the pulp, the problem arises as to whether an attempt shall be made to save the pulp by capping or whether it shall be destroyed and the canal filled. The question is one which calls for discriminating judgment on the part of the operator and a careful study of the peculiar manifestations presented in the individual case. No set rule can be formulated as a guide under all conditions, but the most prominent indications for or against pulp-capping may be pointed out in the way of suggestion to the observant operator.

The chief considerations relate to the age of the patient, the extent of exposure, the location in the mouth of the affected tooth, and the duration and degree of the pain caused by the exposure. In young patients the prospect of saving a pulp alive is greater than in aged patients, and the necessity is also more urgent. A pulp

is never through with its active functional duty till the tooth is completely calcified to the very apex of the root, and this does not take place till after the eruption of the crown through the gum. In fact, teeth may erupt and take on the carious process to the extent of pulp-exposure before the apex of the root is formed, and if there is death of the pulp at this stage the apex is left unformed. It becomes important, then, in all cases of pulp-exposure in young patients to attempt to save the pulp till the process of calcification is complete, and while teeth may vary in different mouths in regard to the age of complete calcification, it may be said in a general way to be about six years after they begin to erupt. The fact that pulps may more successfully be saved during youth is another argument in favor of making the attempt, the reason for this being that the apical openings in the roots are larger, which gives greater play for the engorgement of the vessels of the pulp without injury. As age advances the apical openings become smaller, and a very slight irritation of the pulp may cause its death.

The extent of the exposure is also an important factor. If the pulp is only slightly exposed and has not been injured in any way, or if it has been accidentally uncovered by an excavator, the chances of saving it are greater than where the exposure is large and the pulp thereby subjected to all the dangers of infection. One of the chief elements of success in pulp-capping relates to the avoidance of pressure on the pulp, and in large exposures this is more difficult.

The question of location in the mouth refers to teeth that are exposed to view in contradistinction to teeth so situated that they are never seen in ordinary conversation,—the difference being that with the former a greater effort should be made to save the pulp than with the latter. The reason for this is that on death of the pulp there is usually a tendency for the tooth to become more or less discolored and lose its normal translucency—sometimes to the extent of being unsightly and conspicuous. The fact that by proper management from the time the pulp is destroyed to the final filling of the cavity any serious discoloration may ordinarily be avoided does not alter the general proposition that the most

conservative practice involves the saving of pulps in such teeth if possible. An operator is never able to predict with certainty that a pulpless tooth will permanently retain its color even under the best treatment, and it may therefore be considered a legitimate procedure to make the attempt at pulp-preservation in many of these cases even where the chances are against it. There is a wide variation in the tenacity of life exhibited in different pulps, and if there is a reasonable promise that the pulp may be saved in one of the anterior teeth it should be given the benefit of the doubt and treated accordingly. But the operator should invariably protect his reputation by a straightforward statement of the facts in the case to the patient, and a plain disavowal in advance of any responsibility in the event of the pulp dying under the capping. If patients are at all intelligent they will appreciate an operator's efforts on their behalf, and will not hold him blameworthy if the issue turns out amiss. With patients who are not reasonably disposed the operator would better take no chances, but proceed to destroy all pulps where there is doubt of their preservation. Patients of this type are not entitled to the same consideration in this particular that are those with a due regard for the necessary limitations of human nature on the part of the dentist, and who are charitably inclined in the face of seemingly unfavorable results.

A most important consideration bearing on the decision as between capping and destruction of the pulp relates to the length of time the pulp has been inflamed, and the degree of the inflammatory process. The most apparent index to this is the concurrent pain. If a tooth has ached violently from an exposed, or nearly exposed, pulp, and particularly if this high degree of inflammation has continued for many hours, the conclusions are that the pulp has been so profoundly affected that it cannot recover, and the attempt to save it will be fruitless. But if the pulp has been brought under treatment in the early stages of the inflammatory process, and especially if it yields promptly to palliative treatment, the promise is greater that it may be saved.

The question of the general health of the patient must not be

overlooked in relation to its bearing on the probable success or failure of pulp-capping, nor must we lose sight of the influence of locality. In some regions—particularly in malarial districts—the attempt to save exposed pulps is said to invariably result in failure. Repeated experiences of this nature have often led men who were ordinarily careful and conservative to make the statement that wherever a pulp becomes actually exposed the only legitimate line of treatment is to proceed to its destruction, but in view of the well-established fact that pulps have lived to do good service for many years after being capped, this must be considered extreme teaching. The pulp is too useful under certain conditions—which have already been indicated—to justify an operator in following so radical a procedure.

Pulp-capping, like many other lines of practice, must be studied with care and entered into with discriminating judgment. The operator must not expect success in every case, even among those which seem most favorable, but the fact that he has failures should not deter him from an honest effort to do the utmost limit for his patient in those cases where the preservation of the pulp seems desirable.

Materials for Capping Pulps.

Various materials have been suggested for capping pulps, each advocate claiming for his especial material peculiar virtues not found in the others. The fact that one operator will use a certain material with a greater degree of success than another, while the second will employ a different material to greater advantage than the first, is only another illustration of the ever-present factor of personal equation. We cannot eliminate this factor from consideration in any line of practice, and in the capping of pulps that method and that material which proves most successful in the hands of a given operator should be the method and material for him to adhere to.

And yet it may be well to consider in brief some of the various materials most commonly advocated for this purpose. The chief requisite of an ideal material would seem to be the ability to protect the pulp against external irritation. It should therefore be a

poor conductor of thermal changes, and should in itself be a non-irritant, and plastic in nature, so that when applied to the pulp adaptation without pressure may be attained, the mass subsequently crystallizing into a rigid covering to the pulp to protect it against external impact.

Gutta-percha has sometimes been advocated as a pulp-capping. It has the advantage of being a perfect non-conductor, and it is also non-irritating in character, but the very nature of the material is such that it cannot well be accurately adapted to an exposed pulp without the danger of causing pressure. Neither can it be depended on to remain of uniform bulk after insertion, and the slight expansion which often takes place in gutta-percha may act as a mechanical irritant to the pulp. It is therefore seldom indicated for this purpose,—the factor of pressure being a very serious one to consider in connection with pulp-capping.

To avoid undue pressure some operators employ a thin concave metal disk, placing the disk over the pulp with its concavity toward the pulp and the rim of the disk resting on the dentine around the point of exposure, and then flowing cement over this. A limitation to this plan would seem to be the space left between the disk and the pulp. Nature's proverbial abhorrence of a vacuum cannot be excluded from consideration in this operation, and the aim should invariably be—adaptation without pressure.

The oxychloride of zinc has also been advocated as a pulp-capping, but its strong irritating properties would seem to limit its use to those pulps which will tolerate a high degree of irritation without dying under it. Some pulps are apparently able to live under severe irritation and are thereby stimulated to throw out a deposit of secondary dentine to protect themselves, but most pulps if subjected directly to the irritating influence of oxychloride of zinc will probably die as the result. The fact that the operator cannot predict with any degree of assurance just which pulps will stand irritation and which will not, renders the use of oxychloride a rather hazardous practice.

The oxyphosphate of zinc has probably claimed more advocates than any other one material, it being less irritating than the oxy-

chloride and very convenient to use. It can be flowed over an exposed pulp so as to gain adaptation without pressure, and it becomes sufficiently hard to adequately protect the pulp from external force. But even the oxyphosphate is somewhat irritating,—so much so to some pulps that it is doubtful practice to place the material in direct contact with an exposure. To overcome this irritating action a most excellent plan is to first make a paste by mixing the powder of the cement with some oil of cloves and place a thin layer of this over the point of exposure before inserting the oxyphosphate. This paste will effectually protect the pulp from the irritating influence of the cement, and it is also anodyne in its action and a good antiseptic. This combination of materials if skillfully employed will probably save any pulp that can be saved, and it will prove of great comfort to the patient from the fact that it may be employed without causing the slightest pain. Instead of the oil of cloves paste some operators use a solution of gutta-percha dissolved in chloroform to form a film over the pulp before applying the oxyphosphate of zinc, but most pulps do not take so kindly to this as to the paste.

Method of Capping Pulps.

The first requisite of success is to remove all deleterious matter in the immediate neighborhood of the pulp by excavating the decalcified and infected dentine as completely as may be short of wounding the pulp. The less of this infiltrated mass that is left in the cavity the less the danger of pulp-infection, as already pointed out in a previous chapter. The fluids of the mouth should be carefully excluded from the cavity during the cleaning and subsequent capping, and nothing allowed to enter except what the operator places there himself. The cavity should first be flooded with a non-irritating antiseptic, preferably the oil of cloves, and after wiping out the surplus with absorbent cotton the layers of decalcified dentine may be peeled off with a sharp spoon excavator. When the cleaning is complete the cavity should again be flooded with the antiseptic and allowed to remain three or four minutes while the capping material is being prepared. When the paste

is ready the surplus antiseptic should be removed from the cavity with absorbent cotton and the paste carried to position over the pulp. This may be done most expeditiously with a small pellet of tightly rolled cotton in the pliers. As soon as the paste is gently patted to place and the surplus removed, the oxyphosphate of zinc may be carried to position over it and allowed to become hard. If it is a case where there seems much doubt about the final saving of the pulp, it is well not to subject the tooth at this time to the mal-letting of a gold filling. The entire cavity may be filled with the oxyphosphate of zinc and the case dismissed for six months. If at the end of that time the pulp is found alive and has given no trouble a portion of the cement filling may be removed and replaced by gold, leaving sufficient of the oxyphosphate over the pulp to protect it.

CHAPTER XVII.

DESTRUCTION OF THE PULP.

IN case it is deemed inexpedient to attempt to save a pulp, the necessity devolves upon the operator of destroying it and filling the canal. The most common method of killing a pulp is to make an application of arsenic to it. This may be used in the form of an arsenical paste prepared especially for the purpose by manufacturers, to be sealed in the cavity for a longer or shorter length of time as the circumstances indicate. Another method of pulp-destruction relates to forcing a solution of cocaine into the pulp either by cataphoresis, by injection, or by pressure, and removing the pulp at the same sitting.

The choice of methods must be governed by the necessities of the case in hand, and also by the relative success which each operator may experience with the different methods. Some operators claim a vastly greater success with pressure anesthesia than with arsenic, while others do not find it in the least satisfactory. In a general way it may be suggested that wherever the operator is not

pressed for time in the removal of the pulp, he will obtain more uniformly satisfactory results from arsenic than from cocaine, while in an emergency case where the immediate removal of the pulp is imperative, he will do well to employ cocaine.

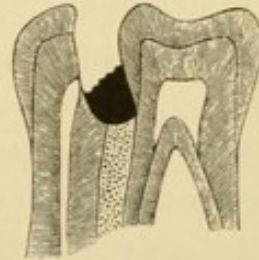
Destroying the Pulp with Arsenic.

The prime requisite in the application of arsenic to a pulp is to bring it in immediate contact with the pulp without exerting the slightest undue pressure upon it, and then sealing it so securely in the cavity that it cannot by any means ooze out and come in contact with the gums. Arsenic is exceedingly destructive to the tissues, and if it reaches the gums or other soft parts it will destroy them over a greater or less area, dependent upon the amount of arsenic and the length of time it is allowed to come in contact with them, often implicating the alveolar process in the destruction. This necessitates the most careful sealing of the agent in the cavity, and to accomplish this without causing pressure upon the pulp is often a delicate procedure. Much of the pain in pulp-destruction that has been laid at the door of arsenic is probably due to pressure in its application.

The two materials most effective in sealing arsenic may be said to be gutta-percha and cement, the former to be used in those cases where it can be applied to the surrounding walls of the cavity without causing pressure toward the pulp, and the latter in all cases where the application of gutta-percha is difficult. Cement may be gently flowed over the arsenic and made to adhere perfectly to cavity walls without pressure on the pulp, and it is therefore preferable in most cases, its chief drawback being the greater difficulty of removal. In proximal cavities where the cavity-wall slopes from the point of exposure toward the gingival margin in such a way as to present an incline down which the arsenic may easily be forced in applying the cement, the danger to the gum in the interproximal space is very great. An operator may readily force some of the arsenic into the space ahead of the cement without being aware of it till serious injury results. To avoid any possible danger of this nature, it is advisable in every instance

where arsenic is to be applied to a proximal cavity to first build a layer of gutta-percha over the gingival wall of the cavity leading from near the point of exposure down to the gingival margin of the cavity, and across the interproximal space against the proximating tooth, Fig. 98. If this bridge of gutta-percha be thus constructed with care before the arsenic is applied, the operator need have no fear

FIG. 98.



of trouble. In these cases it is well to use cement over the arsenic, allowing it to extend against the proximating tooth. It can be applied under the circumstances with less danger of pressure than gutta-percha, and it is not so compressible under mastication, and therefore less liable to be forced into the cavity so as to impinge on the pulp.

The amount of arsenical paste required to destroy a pulp is very small. Most operators use altogether more than is necessary, and thereby increase to that extent the danger of injury to the surrounding parts. A minute quantity, one-half or even one-fourth the size of the head of an ordinary pin, if brought in immediate contact with the pulp will be found ample for its destruction. A very convenient method of applying it is to first place the required amount on a porcelain slab, and then with the cavity ready for its reception a small pellet of cotton moistened in the oil of cloves may be used to pick up the paste and carry it to the pulp. Let the paste be laid immediately over the exposure, and then release the pellet of cotton so that it remains in the cavity with the paste. Cement may then be flowed over this without danger of pressure. If this is dexterously accomplished there is seldom any appreciable pain following the application.

The length of time necessary for the arsenic to remain may be judiciously varied in different cases. In young patients where the apical foramina are large, and in all cases where for any reason there may be doubt about the security of the sealing agent, the arsenic should be removed at the end of twenty-four hours, but it is seldom advisable to attempt the removal of the pulp at this time. While the arsenic may have effectually accomplished its purpose

so far as the ultimate destruction of the pulp is concerned, it will ordinarily be found that sensation persists for some days after the application. In fact, it is usually best to wait a week or ten days before removing the pulp, to give ample time for the pulp to sever its connection at the apical foramen. Until disintegration takes place at this point there is always more or less sensation on its removal, and never the same certainty of a thorough removal to the apex. If the attempt is made to extract the pulp while it is still adherent at the apex, there is always danger of tearing the pulp into shreds and leaving a portion of it in the canal. Decomposition and infection seldom follow immediately on the destruction of the pulp where it is carefully sealed from the fluids of the mouth, so that it may safely be left a sufficient time to insure its painless removal. In every instance where the arsenic is removed at the end of twenty-four hours, a non-irritating antiseptic should be placed over the pulp and the cavity sealed with gutta-percha till the pulp is ready for removal. Under no circumstances should the fluids of the mouth be allowed to enter the cavity after the application of the arsenic.

In the teeth of adults where for any reason the patient cannot conveniently return in twenty-four hours, and where the sealing may be made secure, it is permissible to leave the arsenic in for one week, at the end of which time the pulp may be removed painlessly. In leaving arsenic in for this length of time the greatest care must be exercised in sealing it, and only the minutest quantity of arsenic used.

There is always the remote danger in the use of arsenic that the tooth may be lost through a peculiar accident whereby the peridental membrane is destroyed without any leaking of the arsenic from the cavity to the gum. This is probably due to the presence in such cases of a tributary canal leading from the pulp-canal proper through the side of the root. In any event such cases have been reported where the arsenic was left in the tooth only twenty-four hours, but fortunately they are very rare,—so much so that when compared with the very general use of arsenic for pulp-destruction, they may be considered only in the light of the remotest contingency.

Removing the Pulp with Cocaine.

The occasional accidents in the use of arsenic, together with the length of time necessary for its action, have led many operators to seek other means for removing the pulp. Probably the best method is to force a solution of cocaine into the pulp to destroy its sensibility, and then extract it. This may be done by taking some of the crystals of cocaine and making a solution by adding a drop or two of alcohol or chloroform, and gathering this up on a small pellet of cotton and placing directly over the pulp. Pressure is then applied to this in such a way as to force the solution into the pulp by taking a mass of unvulcanized rubber sufficient to fill the entire cavity, and with a broad-ended instrument driving this toward the pulp. The pressure should be gentle at first and gradually increased as the pulp will tolerate it till a very vigorous pumping is possible, sufficient to force the solution well into the pulp. If the exposure is slight, it may be necessary to make a preliminary application in this way before the operator can secure a broad enough exposure to carry the solution well into the pulp-tissue.

This method of pulp-destruction seems in some instances to work almost like magic, the pulp evidently yielding at once to the influence of the cocaine to such a degree as to permit of its removal without the slightest disturbance to the patient. But in many other cases the results are wholly unsatisfactory. It is notorious that cocaine does not act uniformly in all cases, and this particular use of cocaine seems to be no exception. With some patients the attempt to force cocaine into a pulp in this manner is accompanied with most excruciating pain, no matter how gently the operator may work, nor how patient he may be in waiting for the preliminary effect of the cocaine. In other cases the most strenuous effort of the operator fails entirely in producing anesthesia of the pulp, the solution seemingly having no effect whatever. Another minor limitation of the method relates to the free flow of blood following the removal of the pulp under these conditions. It is sometimes difficult to stop the flow so as to get the canal in perfect condition for the reception of the root-filling. It

will also be found that in many cases following this kind of treatment a disagreeable soreness develops in the tooth, lasting several days, though seldom resulting in anything more serious than a temporary discomfort. This occurs oftener under this method than where the pulp has been destroyed with arsenic and removed in the ordinary way.

Removal of the Pulp.

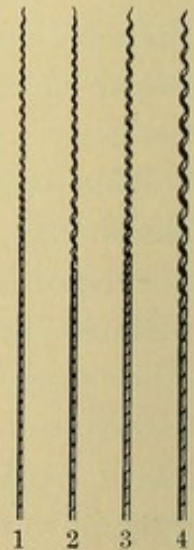
The operation of removing the pulp, whether it has been destroyed with arsenic or by pressure anesthesia, is sometimes a difficult one, particularly in small and tortuous canals. In the larger canals which contain an appreciable mass of pulp-tissue the problem is much simplified by the ready admission of a Donaldson barbed broach or an Ivory spiral broach (Figs. 99 and 100). The

FIG. 99.



latter in a canal of sufficient size to admit it will grasp the pulp and engage it more securely than will a barbed broach,—the barbs sometimes exhibiting a tendency to tear through the pulp-tissue and fall short of extracting it,—but the barbed broach will enter a smaller canal than the spiral broach on account of its lesser bulk. In this connection it may be stated that it is hazardous to introduce into any canal so constricted that the broach impinges on the canal walls while being turned, either a barbed or a spiral broach.

FIG. 100.



The attempt to remove pulp-tissue from constricted canals with a barbed broach is accountable for many a broken broach, and when a piece of barbed broach is thus wedged into a small canal it is exceedingly difficult to remove it.

Before attempting the extraction of a pulp, the approaches to it should be opened up to give the best possible access. The roof of the pulp-chamber should be well cut away so that the chamber is exposed to view and the orifices of the canals accessible. If in a

molar the large bulbous portion of the pulp in the chamber may be scooped out with a spoon excavator, leaving the openings of the canals exposed. The chamber should now be flooded with alcohol and thoroughly washed free of débris, after which warm air may be used to evaporate the moisture. This drying out must not be carried sufficiently far to endanger the integrity of the tooth-substance, the tendency being to render teeth brittle and easily fractured when subjected to extended desiccation. And yet it would be very desirable if the operator could extract the moisture from the pulp-tissue before attempting its removal from the canals. The drying has a two-fold beneficial effect upon the pulp,—it lessens its bulk so as to shrink it away from the walls of the canal, and it toughens it so that it may be more readily grasped and held by the broach. In many of these cases where the pulp is sensitive to the touch of the broach on opening up the chamber, the sensitiveness will be found materially reduced by desiccation. A pulp under these conditions, though sensitive to manipulation by the broach, is seldom sensitive to thermal changes and may therefore be dried without pain. To extract the moisture from the pulp without injuring the crown of the tooth it is sometimes advisable to carry the heat directly to the pulp without affecting the tooth-tissue. This may be done in many instances by following the application of the alcohol with a heated instrument held directly against the pulp stump in each root, thus drying at least this end of the pulp and converting it into a leathery consistence which will facilitate its removal.

When the pulp is as dry as practicable, the broach may be carried along its side as far into the canal as it will go and then carefully twisted so as to engage the pulp-tissue. If a barbed broach is being used, the barbed side should be placed against the wall of the canal and the smooth side in contact with the pulp-tissue while it is carried into the canal, and then so turned that the barbs grasp the pulp before its withdrawal. For removing pulps the broaches, whether barbed or spiral, should be used without handles, on account of the greater facility with which they may be made to enter the canal at the desired angle, particularly

in posterior teeth. By grasping them between the thumb and index finger the operator can direct them into canals far back in the mouth, and reach many cases advantageously where a broach with a handle could never be made to enter without curving it so as to prevent a subsequent twisting for the removal of the pulp.

In canals too small for insertion of the barbed broach—such, for instance, as the buccal roots of upper molars and the mesial roots of lower molars—the safest plan is to ream them out with a smooth broach made from piano-wire and filed so as to leave sharp angles on the sides. These piano-wire broaches are exceedingly tough when newly made, and almost any canal may be advantageously followed by them to a point where the constriction is so great that no broach will pass.

After the pulp-tissue is removed from the canals they should be flooded with alcohol to wash out any remaining fragments, and when thus cleaned the canals may be bathed in the oil of cloves to prevent any possible infection, and then flooded with alcohol once more previous to the final drying for the reception of the root-filling. If the pulps have been successfully removed and the canals rendered clean and aseptic, the roots may be filled at the same sitting.

CHAPTER XVIII.

FILLING PULP-CANALS.

THE selection of a suitable filling-material for pulp-canals is a question that has engaged the minds of the profession ever since pulpless teeth have been considered worthy of saving. Without going into the history of the various materials that have from time to time been advocated, it is sufficient to say that the most universal practice to-day is to use gutta-percha. This material has peculiar qualities entitling it to favor for this purpose, and while it cannot be considered ideal in all respects it probably fulfills the requirements to a greater degree than any other one material. It is

a non-conductor and a non-irritant. It can be molded to fit the inequalities of any canal, and be made to follow a constricted and tortuous canal, particularly if used in the form of a solution. This solution is ordinarily made by dissolving gutta-percha in chloroform to a cream-like consistence, and then pumping this into the canals, after which a cone of solid gutta-percha is forced into the canal to displace all of the solution possible and leave as much as may be of the canal filled by solid gutta-percha.

One limitation of the chloro-percha solution consists in the fact that the chloroform is so readily evaporated that it is difficult to keep the solution of a proper consistence for daily use. To provide a solution for this purpose which will remain stationary, it is suggested that when the gutta-percha is dissolved in chloroform and the latter begins to evaporate the loss of fluidity be made good by the addition of eucalyptol. This may be carried on till all the chloroform is gone and the solution consists entirely of gutta-percha and eucalyptol.

This solution is to be used not with the idea of forming a root-filling of itself, but merely as a moistening agent for the canals preparatory to the introduction of the solid gutta-percha, which latter will follow up a canal to better advantage under these conditions than if inserted in a dry canal.

The *modus operandi* of filling canals with gutta-percha is to first flood them with the solution by dipping a small pellet of cotton in it, and carrying this to the pulp-chamber and squeezing it out against the side of the chamber. This will cause the solution to flow into the canals. Then, with a smooth broach, pump the solution well into the canals, and thereby displace the air from the canals by carrying the solution to the apex. In constricted canals this pumping with the broach should be quite vigorous, but in larger canals there is not the same necessity for extended manipulation with the broach, on account of the ready flowing of the solution to the apex and the subsequent insertion of the gutta-percha cone. In fact, too much manipulation with the broach in large canals is to be avoided, on account of the possible danger from irritation beyond the apex. The aim should be in these cases

to carry the solution and the cone just to the apex and no farther. This is often a delicate matter, but by a close study of these cases the operator may be reasonably certain as to the moment the apex is reached. There is no rule which may be taught as an infallible guide to indicate just when the apex is reached. It has sometimes been suggested that the evidence of an approach to the apical foramen was furnished in a flinching of the patient, but this is by no means reliable. In some instances where the foramina are very small at the apex, and where there is no sensitive tissue beyond the root, we may secure a most thorough filling of the canal without the slightest sensation to the patient. To keep on pumping at a case of this kind looking for a response from the patient would be mistaken zeal, and might cause subsequent irritation. On the other hand, there are cases where the slightest pressure exerted on the contents of a canal, even where the pressure is so far removed as the entrance to the canal at the pulp-chamber, will cause a ready response. This may be due to the pressure of air in the extremity of the canal, and a response of this kind would be no indication whatever that the filling-material had reached the apex.

The whole question is one of intuitive perception on the part of the operator, and of such a training of the faculties and fingers that the sensation conveyed to the practitioner is the keynote, and not the sensation conveyed to the patient.

When the canals are filled with the solution a solid gutta-percha cone should be grasped by the pliers and carried into each canal, thereby displacing a part of the solution. If the canal is so large that the ordinary cones supplied by the manufacturers are not large enough to fill it, a second one may be forced in beside the first, or a cone may be made by the operator for the case in hand. Considerable pressure should be exerted on the cone to make it fit up tight to the canal at the apex. Ordinarily the large end of the cone will be found standing up in the chamber after it has been forced as far as possible into the canal, and if a heated instrument is applied to this in the attempt to compress it toward the canal, the tendency is for the cone to adhere to the instrument and be

withdrawn from the canal. Instead of heating the instrument, the end of the cone should be heated by directing a blast of hot air upon it, and then a broad-ended instrument may be used to compress it to place. In some instances, particularly in three-rooted teeth where the chamber is large, it may be well, before attempting to compress the large ends of the cones, to warm a pellet of gutta-percha and force this to place against the floor of the chamber or subpulpal wall, and then gather the ends of the cones over into the pellet and incorporate the whole in one mass. In doing this the end of the plugger may advantageously be wiped off with a cloth saturated with one of the essential oils, which will to a large degree prevent the adhesion of the gutta-percha to the instrument.

The case now presents with the cones in place and the floor of the chamber covered with gutta-percha, but the canals must not be considered perfectly filled. There is yet too much of the solution remaining, and this must be as largely displaced as possible by the solid gutta-percha. To do this a root-canal plugger should be warmed and wiped with the oiled cloth, and gently forced into the canals in such a way as to drive the gutta-percha more snugly into them. As the gutta-percha is compressed into the canals the solution will ooze out around the margins, and may from time to time be absorbed with a pellet of cotton. This forcing process should be continued till there is assurance that the canals are solidly filled with gutta-percha and all the surplus solution removed. Over the gutta-percha thus inserted a layer of cement, preferably the oxychloride of zinc, should be used upon which to build the permanent filling. Gutta-percha does not present a sufficiently firm or stable base to justify an operator in building a metal filling upon it.

In case there is no pericemental soreness the operation may be completed with a permanent filling—whether of amalgam or gold—at the same sitting, but if there is irritation present the cavity should be temporarily sealed and the case dismissed for a few days till the soreness subsides.

CHAPTER XIX.

THE TREATMENT OF PULPLESS TEETH.

WHEN a pulp dies in a tooth without the aid of the operator, the management of the case is different from that of a recently destroyed pulp where the tooth has been under the operator's supervision from the destruction of the pulp to the final filling of the root. The question of infection enters materially into the case so soon as the natural processes of dissolution are allowed to run their course without interference.

Cases of this character may be divided into three classes,—those where the pulps die as the result of the approach of caries, and which come to the operator with the cavity and canals exposed to the fluids of the mouth; those where the pulps die under a filling, and those in perfectly sound teeth where the pulp has been lost as the result of some injury.

Each of these classes may present in one of the following conditions: There may be no apparent disturbance beyond the apex of the root, with no soreness or inflammation of the peridental membrane and no pus, or there may be decided soreness with an elongation of the tooth from a swelling of the membrane, or there may be an absence of soreness with a pus pocket beyond the apex, but no external opening, and lastly, there may be an abscess with a fistula passing through the alveolar process and opening on the gum.

Treatment of Pulpless Teeth where the Canals have been Long Exposed to the Fluids of the Mouth, but where there is No Fistulous Opening.

These cases must always be treated with the possibility in mind that there may be a blind and passive abscess in the apical space which is quite likely to develop into a fiery furnace by a little mismanagement. The actual decay in the cavity should first be thoroughly removed and the pulp-chamber well opened up. This

must be done without the slightest manipulation of the contents of the canals, or the least pressure that is calculated to force anything through the apical foramen. This preliminary cleansing of the cavity may be done without the application of the rubber dam, and the débris may be rinsed out from time to time with a syringe. Make the cavity and chamber as mechanically clean as possible. Then apply the rubber dam and absorb the moisture from the cavity with cotton. Flood the cavity and chamber with alcohol, which has a great affinity for moisture, and absorb the alcohol with cotton. This will often extract some of the discolored and putrescent contents of the canals. Wash out well with alcohol in this manner till the alcohol fails to be discolored by contact with the cavity and chamber. Then dry the chamber and as much of the canals as possible with warm air, but do not carry the desiccation so far as to weaken the tooth-structure. Now flood the canals and chamber with a non-irritating antiseptic, a good one being the oil of cloves. The canals must not at this sitting be entered by a broach, and no attempt made to clean them by instrumentation except in a slight degree in those cases where the canal is very large and filled with débris and putrescent matter. A canal like this when flooded with the medicament may sometimes be approached very gently with a smooth broach, and the débris carefully coaxed out and floated away from the larger portion of the canal without disturbing the contents near the apex. The reason that great care is necessary in the preliminary treatment of these cases is because if the slightest bit of this putrescent matter be forced through the apical foramen it is almost certain to set up a serious inflammatory process which may run to abscess. After the chamber and canals have been flooded with the antiseptic, some cotton saturated with it may be loosely placed in the chamber and the cavity sealed with gutta-percha. For this purpose the temporary stopping may be used to good advantage, on account of its being easier of manipulation than the base-plate gutta-percha.

If it has been possible to secure a reasonably perfect cleansing of the tooth and there seems to be little putrescence left in the

canals, the case may be dismissed for one week, with instruction to report at once in case of trouble. It should be the aim of the operator from this time forward to allow nothing in the tooth except what he places there, and if trouble ensues it is better for the patient to seek the operator and let him change the dressing rather than to pick out the gutta-percha and again admit the fluids of the mouth.

In case the dentine seems badly infiltrated with putrescence and the first treatment has apparently failed to control it to the operator's satisfaction, he would better not let the case go a week. Under these conditions the tooth should be seen in twenty-four or forty-eight hours and the treatment repeated. After this second dressing the case may be dismissed for a week. If the tooth remains sealed up for this time without discomfort, the operator may safely proceed to clean out the canals. They should first be flooded with alcohol and manipulated gently with a smooth broach to float any particles of débris that may have been packed into them. Even at this second sitting the operator should guard against undue irritation of the apical tissues by the broach. He should aim to make his cleansing as thorough as possible without forcing anything through the apex.

This mechanical cleansing of the canals is a very important part of the successful treatment of pulpless teeth. When it is remembered that the cases at present under consideration are those in which the contents of the canals have long been subjected to the influences of infection and the dentine itself is more or less infiltrated with poisonous material, it must be apparent that the most thorough cleansing with instruments should supplement any or all kinds of medication. Many operators rely too largely upon the efficacy of drugs as a short cut to excuse them from the necessity of painstaking care in removing mechanically every particle of the putrid contents of canals. Medication is necessary, but it can never be fully effective without the aid of instrumentation.

To be successful in the mechanical cleansing of canals it is important to first gain the best possible access. The orifices of canals leading from the pulp-chamber are often constricted and unap-

proachable,—so much so in some instances as to make it difficult to find the openings. If the chamber is well uncovered these openings may readily be found by following a simple procedure. Flood the chamber with alcohol and evaporate it with warm air, when the openings will ordinarily be plainly visible as soon as the floor of the chamber is dry. These orifices should at once be widely reamed out with a large Gates-Glidden drill,—a drill too large to be admitted into the canal proper,—so as to form a funnel leading to the canal. This reaming out will perfectly expose the approach to the canal and permit the operator to ascertain the nature of the canal and its general direction. This should be carefully determined with a smooth broach, and in cases of constricted canals the proper cleansing and medication of the canal involves its enlargement by the operator.

This question of the enlargement of canals is one of the most intricate connected with the treatment of pulpless teeth. The attempt to enlarge canals with drills in the hands of careless or incompetent operators has been prolific of disaster. It is manifestly impossible to follow a curved canal with a drill, and the inevitable result has been that operators have drilled through the side of the root. The frequency of this accident has led many conservative men to make the statement that a drill should never be used for enlarging canals, and yet in the hands of a careful operator this instrument is one of the most useful we have in the management of these cases. It is seldom that such canals as those in the buccal roots of the upper molars, the mesial root of the lower molars, or the bifurcated root of an upper first bicuspid can be properly cleaned without a slight enlargement. Then again there are many of the larger canals in which there is an unevenness along the walls or a flattening of the canal which requires a reaming out to be properly treated and filled. In very many instances this may be safely and quickly accomplished with a drill,—at least in the first third or half of the canal,—provided the operator can secure the proper approach to it, and will first study the direction of the canal with a broach. Unless he can so hold the drill that the approach is at the proper

angle, he would better not attempt to drill at all. Any undue bending of the drill while it is revolving in a canal, or any binding or clogging, is quite likely to result in the drill being broken and lodged in the canal. The greatest care should be taken to avoid this, and consequently it is never permissible to exert much force on the drill nor to attempt to drill around a corner. In many instances in the molars and bicuspid's the drill should be used in the right-angle hand-piece to admit of the proper approach. It should be passed back and forth in the canal with the slightest pressure, so that the cutting is done without clogging, and most of the lateral reaming should be done on the withdrawal movement of the drill instead of on the forward movement.

If the drill is thus used with care and never forced too near the apex it is capable of great usefulness in the preparation of roots for filling, but there are some cases where the canals are so curved and the approach so difficult that it is injudicious to attempt to place a drill in them at all. In such cases the canals may be enlarged by the method suggested by Dr. J. R. Callahan, whereby a solution of sulphuric acid is used to soften the walls of the canals so that they may be readily scraped out and enlarged with a Donaldson cleanser. The manner of using the sulphuric acid is as follows: A forty per cent. solution of commercial sulphuric acid should be prepared and kept in a glass-stoppered bottle. A drop or two of this may be carried to the canals by winding some fibers of cotton on a wooden point, and dipping this in the solution and pressing the soaked cotton against the side of the chamber till the solution flows down into the canals. This should then be pumped to place with a piano-wire broach,—using a new broach each time. When the smooth broach will readily pass back and forth in the canal, a Donaldson cleanser may be used to further pare away the sides of the canal and enlarge it. As soon as this is accomplished to the satisfaction of the operator the chamber and canals should be freely flooded with a saturated solution of sodium bicarbonate to neutralize the further effect of the acid, and this should be continued till all effervescence ceases. The canals should then be dried out by flooding them with alcohol and evaporating it either

with warm air or a heated root-canal drier. The latter is ordinarily preferable on account of the danger to the crown of the tooth by the use of air. The fact should always be noted that it is unsafe to overheat or unduly dry the tooth-tissue on the crown, and a better drying of the canal can be attained without jeopardy to the crown by the use of a canal drier than with a diffused blast of warm air. As soon as the canal is dry it should immediately be flooded with the oil of cloves, which will under these conditions penetrate not only to the apex of the root, but be absorbed more or less by the open ends of the dentinal tubuli leading from the canal.

If the case has progressed favorably up to this point and there are no untoward symptoms, the canals may be filled at this sitting. Preparatory to this the oil of cloves should be wiped out and some more alcohol used for dryness. The moment the canals are dried the eucalyptol solution should be at hand for use, so that the dentine is not kept desiccated for any length of time.

In those cases where the canals have long been exposed to the fluids of the mouth there is always the possibility of an abscess occurring in the apical space and discharging through the tooth, thus giving no external evidence of its existence. In such cases the operator will ordinarily be able to detect the presence of pus either in his preliminary work on the canals, or at least on the cotton after it has been sealed in the tooth. As soon as pus is demonstrated the management of the case is slightly changed. The canals should at once be thoroughly cleansed, and all the pus removed that is possible by coaxing it from the apex toward the chamber with a broach, and then absorbed with cotton or with bibulous paper cones prepared for this purpose. When no more pus can be extracted the canals should be flooded with an antiseptic and some cotton placed in the chamber, and the cavity sealed. If there has been much pus, and particularly if it has been of an offensive character, the case should be seen in twenty-four hours and the treatment repeated. At the second sitting the condition of the case will indicate the line of treatment. If there has been perceptible improvement there need be very little manipulation

with the broach, but merely a change of dressing. If the pus seems as bad as ever the broach should be freely used, and in some instances it will be found beneficial to work with the broach till all pus is removed and a tinge of blood follows it into the canal. As soon as the blood shows it is well to pack the canal with cotton saturated with the antiseptic, and seal the cavity. Under these conditions the case may be dismissed for a week with instructions to report in the event of trouble. If at the end of this period there is still pus, it is well to inject peroxide of hydrogen into the abscess and let it effervesce through the tooth. Peroxide of hydrogen is not indicated at the outset before the canals have been disinfected, through fear of irritation following the effervescence. This danger is not so great after the first treatment. When effervescence has ceased the canal may again be packed with an antiseptic, and the case dismissed for two weeks. After the first thorough disinfection of the canal the tooth should not be treated frequently, unless the operator is forced to do so by pain. Many of these cases are kept in a state of irritation by too much operative interference, and it will often be found a very effective practice to give nature a chance.

When the character of the discharge changes from a thick yellowish pus to a thin serous fluid,—which is very frequently the case,—the canal should be packed tight to the apex with cotton saturated in an antiseptic, and the case left long enough to give it an opportunity to dry up. Except in stubborn cases this will usually occur in two weeks, and when the tooth has remained for that length of time free from trouble, while tightly sealed, it may be considered safe to fill it, provided the canal can be perfectly dried to the apex.

Treatment of Pulpless Teeth having a Fistulous Opening on the Gum.

Whether the fistula proceeds from a tooth with a filling in it or with an open cavity, the first treatment involves the thorough opening up of the chamber and canals, and the most painstaking cleansing to the very apex if possible. With a fistula leading from

the abscess there is little danger of setting up inflammation by the use of broaches or drills in the canals, and the more thoroughly this initial cleansing is done the more readily may the abscess be brought under control. After the canals are cleansed, the one from which the abscess comes—a fact which may usually be determined by passing a probe into the fistula and tracing its direction—should be packed with cotton saturated with a non-irritating antiseptic such as the oil of cloves, and pressure brought to bear upon it so as to force the agent through the fistula till it appears on the gum. This may ordinarily be best accomplished by placing a mass of unvulcanized rubber into the cavity and exerting pressure upon it with a broad-ended instrument with a pumping motion toward the orifice of the canal. This will cause compression on the contents of the canal and force the medicament through the fistula. As soon as it appears on the gum the rubber may be removed and the cotton changed for a freshly saturated piece, and the cavity sealed for one week. Usually the fistula will be found healed at the end of this time if the first treatment has been thorough, but in case the fistula still persists the treatment may be repeated. When a case exhibits this tendency to a chronic condition it is well at the second treatment to substitute carbolic acid, ninety-five per cent., for the essential oil. It is a rare case indeed which will not heal in response to a thorough injection of this agent through the fistula. The same rule in regard to waiting to give nature a chance after the first or second treatment should be followed here as with the previous cases under consideration. Many a chronic case will heal in two weeks when it will not heal in one.

In case a second or third injection of the carbolic acid fails to close the fistula it may be taken for granted that there is some caries of the process surrounding the apex of the root, or such a roughening of the end of the root as to prevent the tissues from healing over it. Under these conditions the root-canal should be filled and the external fistula packed with cotton to enlarge it. The cotton should be changed every twenty-four hours for a larger piece till the fistula is sufficiently expanded to permit of perfect access to the end of the root. When this is attained a sharp bur in

the engine should be used to ream out the carious bone and smooth the rough end of the root,—if necessary, cutting off a piece of the root. The opening thus made should be syringed out with an antiseptic solution and freely plastered with a paste made by mixing boracic acid with oil of cloves, after which some antiseptic gauze should be packed into it to keep it from healing at the orifice before granulations have perfectly filled in the interior. The dressing should be changed every twenty-four hours, and as the opening heals from within the gauze may be made less and less till it is not required at all. This will cure the most stubborn case,—and it may be said, in passing, that it is only the very stubborn cases that call for it, the vast majority of abscesses usually healing without recourse to such surgical interference. It should be the aim of the operator to cure all cases, if possible, by treatment through the pulp-canal in the ordinary way, but where this operation seems imperatively necessary it must not be considered a very serious or formidable one. A little delicacy on the part of the practitioner will usually enable him to perform it without appreciable pain to the patient.

Opening into Filled Teeth in which the Pulps have Died, but have Lain Dormant.

It will occasionally be found that pulps die under fillings without giving any particular trouble to the patient, and the tooth remains passive for an indefinite time with no indication of abscess. In opening into these teeth for the purpose of treating and filling the canals the very greatest care is necessary to avoid trouble. There seems to be a disposition in such cases for the most active inflammation to ensue the moment an opening is made through the filling. This is all the more embarrassing to the operator in view of the fact that the trouble dates from the time of his interference with the case, and it is sometimes difficult to explain to the patient that it is not due to his carelessness. These cases should therefore be approached with the utmost caution, and everything should be in readiness for immediate medication the moment the drill penetrates through the filling. On account of its dehydrating proper-

ties, alcohol would seem to be the best agent for the first flooding of the cavity. This should be conveniently at hand, and at once admitted to the opening when the drill passes into the chamber. After letting it remain a moment, the surplus may be absorbed with cotton followed by warm air till the cavity is dry. The opening through the filling may be then enlarged as indicated, and the cavity again flooded with alcohol. A very gentle stirring of the alcohol in the chamber is permissible with the object of washing out any débris or putrescent matter that may be present, but no attempt should be made to use instruments in the canals through fear of forcing infectious matter beyond the apex. After the chamber is well washed with alcohol it should be dried again, and a pellet of cotton saturated with oil of cloves placed loosely in the chamber and the opening sealed with gutta-percha. The subsequent management of the case is the same as that already outlined for the treatment of pulpless teeth having no fistulous openings.

The Management of Pulpless Teeth in the Anterior Part of the Mouth to Prevent Discoloration.

The tendency of all pulpless teeth to take on discoloration renders it necessary for the operator to exercise especial caution with teeth exposed to view, to avoid as largely as may be the resultant disfigurement of his patient. If a pulp must be lost in an incisor, it is preferable, if possible, to destroy it by means of pressure anesthesia rather than to apply arsenic, on account of the fact that many cases are on record where the application of arsenic has resulted in a sudden clouding of the tooth from the active inflammation induced. If it is deemed necessary to use arsenic, only a very small quantity should be used, and it should not be allowed to remain longer than twenty-four hours. At the end of this time the arsenic should be removed, and the cavity washed out with alcohol and dried, after which some light-colored antiseptic may be sealed in the cavity for one week,—using cement as the sealing agent. It should be a cardinal principle in the treatment of these cases never to allow the fluids of the mouth to gain en-

trance to the cavity after the case comes under the care of the operator, and in the sealing of medicaments it is safer to use cement than gutta-percha. The latter may not be so permeable to moisture under long-continued exposure as the former, but the ready adaptation and adhesion of cement to cavity walls renders it the most certain sealing agent. Along this same line no treatment should ever be made without the application of the rubber dam.

As soon as the pulp is removed and the canal dried the root should be filled, and, if possible, a permanent filling inserted in the crown at the same sitting. If these precautions are taken it will seldom be found that a tooth becomes sufficiently discolored to be noticeable.

Bleaching Teeth.

It is scarcely within the province of the present work to go minutely into the subject of treating discolored teeth, but a simple suggestion may be made as to a certain method of bleaching which will be found effective in a large percentage of cases applying to the operator. When a tooth presents which has become discolored as the result of loss of the pulp, the first consideration is to put the canal in a healthy condition and fill it. Then the tooth may be bleached in the following way: The root-filling should be removed sufficiently to allow the bleaching agent to act on the tooth well under the line of the free margin of the gum,—many of these cases showing the most marked discoloration near the gum. The cavity should then be dried out, and a pellet of cotton saturated with a fresh solution of the twenty-five per cent. pyrozone should be sealed in the cavity with cement for twenty-four or forty-eight hours, at the end of which time a very perceptible bleaching will ordinarily have occurred. In some stubborn cases it may be necessary to repeat the treatment,—always being careful to apply the rubber dam at each sitting, and invariably sealing with cement. If this method is carefully followed the results are usually very gratifying and the bleaching quite permanent.

CHAPTER XX.

THE MANAGEMENT OF CHILDREN'S TEETH.

THIS subject presents itself in two phases for our consideration from an operative point of view,—the care of the deciduous teeth, and the care of those of the permanent set which may be said to appear in childhood. The problems which confront the operator in the one case are not precisely the same as those in the other, and the intelligent practitioner will study the two situations from a somewhat different basis. The object in the management of the deciduous set is merely to do palliative work, with the idea of keeping the patient comfortable for a period of a few years, rather than to undertake thorough, permanent, and artistic operations. The avoidance of pain at this stage is very important, and this of itself often involves the performance of temporary work. While the operator is not by any means free from this restriction in his management of the permanent teeth, particularly those which appear early, yet his aim as he approaches these should be in the direction of attaining the greatest possible permanence to his operations, with the idea ever in mind that the highest exercise of his art involves the saving of these organs for a lifetime.

Management of the Deciduous Teeth.

The impression among many of the laity that these teeth may well be neglected, so far as operative procedures are concerned, on the basis that they are eventually lost through natural processes, should be corrected by the profession at every opportunity. Beyond the patent fact of much possible suffering on the part of the patient and much injury to the health through neglected and abscessed teeth, there is a question of habit which would seem to have an important bearing on the future welfare of the patient. These little folk are very impressionable at such a tender age, and readily acquire habits which may conduce to either their permanent bene-

fit or injury. If a deciduous tooth decays and is allowed to go without attention, it sooner or later becomes sensitive to the impact of food in mastication, and the little patient often, without being able to explain the real source of the discomfort, intuitively avoids chewing upon the side of the mouth affected. This leads to imperfect mastication, and where there are several sensitive teeth in the mouth it may lead to an almost entire cessation of mastication; so that a process of bolting the food is inaugurated which may, and undoubtedly often does, cling to the patient as a habit through life.

If a close observer will carefully note the workings of mastication in the mouths of the individuals he meets, he may of course get a reputation for rudeness, but he will also be impressed with the variations in the methods practiced and the degree of effectiveness exemplified in the different mouths. These variations occur in individuals who have teeth of relatively equal efficiency, so that they must be traced largely to matters of habit; and it is natural to conclude that these habits were formed in childhood. When it is considered that effective mastication is a weighty factor in the health and longevity of the individual, it may be seen how important it becomes that we keep the teeth of children in a condition comfortable under the trituration of food and conducive to habits of thorough mastication.

A child should be brought to the dentist at regular intervals for examination from the time of the third, or at latest the fourth, year of age. The first operation usually necessary is fortunately that of cleaning the teeth, and this may be accomplished as a sort of a frolic on the part of the little patient and without any pain. If the teeth are cleaned several times before any filling becomes necessary the dread of the dental chair is largely overcome, and filling operations are undertaken with a better prospect of success.

The materials to be used for filling the deciduous teeth are ordinarily limited to gutta-percha, cement, and amalgam. For the anterior teeth cement must be considered the chief reliance, on account of the nature of the decay which usually attacks these teeth. The cavities are for the most part shallow and not well defined in outline, nor is it possible in many instances to establish a

perfect outline or trim to a well-formed margin. After the removal, more or less thoroughly, of the decay, the filling must be plastered against the decayed surface and remain by its own adhesive properties. Cement is the only material which can be relied upon to do this, the fact that it is necessary to renew it occasionally being its chief limitation. It is ordinarily not a very difficult problem to save the deciduous incisors and keep them comfortable till the eruption of the permanent ones, on account of the early age at which they are shed; but the care of the deciduous molars becomes a more serious matter. They are usually retained four or five years longer than the incisors, and those years are sometimes very trying both to patient and operator. Occlusal cavities in these teeth are ordinarily easily managed with either cement or amalgam, the choice being governed by the degree of thoroughness with which the cavity may be excavated without pain. If a good preparation can be made, and the pulp is not too nearly involved, amalgam should be used on account of its greater permanence, but in some instances the teeth are so sensitive that the most that can be accomplished is to break down the thin overhanging enamel-walls, remove the softer portions of the carious dentine, and force cement into the cavity. When cement is used under these conditions it should be placed in position with considerable pressure. It should also be used in such excess that the entire occlusal surface of the tooth is covered even beyond the borders of the cavity, so far as this may be done without interfering with the occlusion. To accomplish this conveniently, and also to protect the filling from moisture for a few minutes without stuffing the mouth full of napkins or absorbent rolls, the index finger of the operator may be brought down upon the cement as it lies on the tooth and the whole occlusal surface subjected to pressure, so that the cement will be forcibly carried into every groove or inequality on this surface and the excess be squeezed out over the marginal ridges of enamel. If the finger be held upon the cement a few minutes the result is a filling which not only includes the cavity itself, but also protects the grooves and other vulnerable points radiating from it.

The problem of chief concern in the care of these teeth relates to

the management of occluso-proximal cavities. There are two factors which tend to make these cavities especially difficult to control,—the almost universal sensitiveness which we find present, thus preventing an adequate preparation of the cavity to retain the filling, and a gradual separating of the teeth from the natural expansion of the jaw, so as to lead to constant complaint on the part of the patient of food wedging between the filling and the proximating tooth and lodging in the interproximal space. This discomfort is often manifest as the teeth drift apart, even when no decay has occurred, but it is particularly annoying between filled teeth where it has not been possible to contour sufficiently to maintain perfect contact with the proximating tooth. The insecurity of anchorage usually imposes upon the operator the alternative of making fillings with limited contour, and this soon leads to a pocket between the teeth, which proves a constant source of discomfort.

Ordinarily where the proximal surface of a molar is decayed the proximating surface of the one next to it also becomes involved, and this complicates matters so far as making separate fillings is concerned. In desperate cases, where both teeth are decayed, it may be advisable to bridge across the interproximal space and join the fillings together. This will at once do away with the difficulty of food wedging between the teeth, and will often prove a relief to the patient where separate fillings have been a failure. But there are only two materials which are suitable for this purpose. If cement is employed it is only a matter of a few weeks when the whole mass is found loose between the teeth; so that the operator is limited to gutta-percha and amalgam. If the former is used it will ordinarily not draw away from either cavity, and it is excellent as a temporary expedient, but it is so easily worn out that it is at best only a makeshift. Amalgam is probably the most serviceable material for these cavities. It is not worn away by attrition, and will remain more securely fixed than cement, though in some instances the case will present in a few months with the filling loosened from one of the cavities while the other remains firm. The reason for this lies in the individual movement of the teeth, the one with the lesser retention giving way.

A great aid in securing firmness of these fillings when joined together, no matter which material is used, is to first place a metal bar across the interproximal space, with one end resting on the gingival wall of one cavity and the other on the gingival wall of the other, and building the fillings around and over it. This locks the teeth together more securely, and affords perfect protection to the gum. These bars may conveniently be made from German silver wire rolled flat, and cut to a suitable length for the case in hand.

Treatment of Exposed Pulp in Deciduous Teeth.

When a pulp becomes exposed in a deciduous tooth, it is seldom advisable to make an application for its destruction. If the patient applies with pain this can ordinarily be quickly relieved by syringing the cavity well with tepid water to remove loose débris, and carefully clearing away with a spoon excavator any hard material which may be causing pressure on the pulp. This is to be followed by an application of oil of cloves on a pledget of cotton about the size of the head of a pin, covered with dry cotton to fill the cavity. When the pain is relieved, it is better to treat the tooth in a palliative way than to subject the pulp to the action of drugs sufficiently powerful to work its destruction. Arsenic should never, under any circumstances, be used in a deciduous tooth. The risk is too great of doing serious injury to the surrounding parts, and the necessities of the case seldom call for any such radical treatment.

An exposed pulp may be treated by flowing over it a paste made by mixing oil of cloves with the oxide of zinc or the powder which comes with cement fillings. This paste is anodyne and antiseptic, and a pulp will usually remain comfortable under it. It should be protected by a filling of gutta-percha or cement. If a pulp has begun to suppurate, this paste sealed in with soft gutta-percha is an excellent means of keeping the tooth comfortable while the pulp is dying. It may be left in under these conditions for a week or two, as the case indicates, and on its removal the canals can ordinarily be cleaned and filled with safety. It will usually be found that when a pulp has once become exposed in a deciduous tooth it

is only a matter of time when it will die. These pulps do not seem to be very tenacious of life, and it does not require an application of arsenic to kill them. They will often die even under this antiseptic paste, but when protected in this way they seldom give the slightest discomfort while dying, and the tooth will often remain free from pain till it is shed. In other cases it may become somewhat sore following the death of the pulp, and even end in a small abscess opening on the gum; but there is never the intense suffering and excessive swelling which sometimes accompanies teeth that are neglected and left open to the fluids of the mouth.

Treatment of Abscessed Deciduous Teeth.

The canals should be as carefully cleaned as possible by mechanical means, and then packed with cotton saturated with oil of cloves. Some unvulcanized rubber sufficient in size to fill the cavity should then be forced down upon the cotton, and compression made on the rubber till the oil of cloves comes out the fistulous opening on the gum. When this is accomplished, if the preliminary cleansing has been thorough and the contents of the canals have not been too offensive, the tooth may be filled at the same sitting. If the dentine seems saturated with foul matter, the canals should be packed with cotton and oil of cloves and sealed with gutta-percha for a week. If the fistula still remains open at the end of that time, it should again be injected with oil of cloves and the tooth filled in the following way: The pulp-chamber and canals should be flooded with a solution of gutta-percha in eucalyptol, and some temporary stopping slightly warmed should be forced down into each canal till the eucalyptol solution shows at the opening of the fistula. The temporary stopping should be left in the canals as a root-filling, and the cavity proper may then be filled with whatever material is indicated.

Following this treatment, these cases will almost invariably heal and give no further trouble. Indeed, the management of abscessed deciduous teeth is usually a matter of not much difficulty, provided the patient is at all tractable and there is enough of the tooth left to work upon.

The Management of Permanent Teeth in Childhood.

This is one of the most important problems in the entire practice of dentistry. Decay of the teeth has been called essentially a disease of youth, and it is undoubtedly true that during childhood it seems to make its fiercest attacks. The teeth to suffer most from its ravages are accordingly among those which erupt earliest, and of these may be mentioned particularly the first permanent molars. These teeth should be the object of especial care on the part of the dentist. Beyond the fact that they are called upon to do longer service in the mouth than any of the other teeth, they have an important function in the dental arch which is not often carefully enough considered by practitioners. This relates to the time of their eruption and to the position they occupy in the arch. To them it is given to be the standard-bearers of the jaws during that period which intervenes between the loss of the deciduous molars and the growth to full length of the bicuspid and second permanent molars. Without the first permanent molars in their proper position at this time the jaws are allowed to drop too close together, so that the upper incisors overlap the lower incisors more than is normal, and the bicuspid and second molars are never allowed to assume their true length and position. This matter of maintaining the jaws in their proper relation one to the other is very important, as it relates to the symmetry of the face and to the most perfect mastication, and every effort should therefore be made to preserve the first permanent molars in their normal length. These teeth should be watched from the time of their eruption, and on the slightest approach of caries they should be carefully filled. In case the patient fails to apply to the dentist till decay has so involved the teeth that they are badly broken down and not capable of maintaining the jaws in their correct position, every effort should be made to so build them up with fillings that this function be not lost, and, failing in this, they should be crowned even at this early age rather than yield them up to the forceps.

The choice of materials to be used for filling these teeth in the early history of their eruption must be governed largely by the ability and disposition of the patient to withstand dental operations.

If decay occurs on the occlusal surface during the period of the tooth's eruption through the gum, as is sometimes the case, the most serviceable material to check the disease at this time is usually cement. It may be employed with less thorough preparation of the cavity than is demanded for metal fillings, and it will prove effective as a temporary expedient to tide the tooth over this critical period till it is fully erupted and in a condition to receive a more permanent operation.

This material may be used in the very earliest stages of decay, even when the flap of gum has not entirely receded from the occlusal surface; and in some mouths where the tendency to decay seems to be very great it is well to use it as a preventive by forcing it into the grooves and sulci of the occlusal surface before actual decay has begun.

This will often so protect the surface during the eruptive period that decay will be avoided. When the occlusal surfaces of the teeth of the two jaws so approach each other that they are subjected to the friction of mastication the tendency to decay is thereby materially lessened, and it is consequently a matter of much moment to prevent decay till this takes place. The cement may conveniently be forced to position by the finger of the operator, as was advocated in the treatment of deciduous teeth, and considerable pressure may be brought to bear upon the filling-material, so that every indentation on the occlusal surface is perfectly filled. This, while it may not be considered a very elegant method of operating, is assuredly a most effective one, and in this instance utility is paramount to elegance.

In cases where occlusal cavities have been filled in this way with cement the teeth should be examined every three or four months, and metal fillings inserted as soon as the cement wears away and the conditions in the mouth make it possible to do more permanent work. These conditions relate to expediency of operation and to the increasing fortitude on the part of the patient to withstand the tedium and pain necessary, rather than to any pronounced change of structure in the teeth. That a change does take place progressively from youth to age is without question, but it is

neither so radical nor so rapid that it need be accounted an important factor in the selection of a filling-material. Dr. Black has shown conclusively that all enamel and all dentine is harder at any age than any of our filling-materials, and this should be sufficient to settle the question so far as it has a bearing on the choice of material. If tooth-tissue is found which is softer than the materials we use it is due to pathological conditions aside from dental caries, and need not be considered in this connection.

As to the choice between gold and amalgam, this should be governed by two considerations,—the one of expense and the one of an adequate endurance on the part of the patient to submit to gold operations without undue nervous strain. It should be the aim of all operators who take pride in their work, and who wish to do the most permanent service, when they have the care of the teeth from childhood, to keep amalgam out of the mouth entirely, but this does not seem in all cases to be possible. We must not jeopardize the nervous system of our young patients in the blind effort to live up to some high ideal, no matter how beautiful it may appear to us. Neither will it do to affirm that gold should never be used under a certain age, say the age of twelve, as we have so often heard. It is not a question of age at all. It is a question of temperament, a question of physical and mental stamina on the part of the patient. Some children at a given age have a much greater capacity for enduring operations upon the teeth than have other children at the same age, and every operator should make a careful study of this matter among his patients.

A very useful material for filling these occlusal cavities where the area of the cavity is not too great is a combination of gold foil and tin foil rolled together. This can be used when the gold operation would be too exhausting, and if properly manipulated it will prove a very satisfactory and often a very permanent operation. With an operator who is familiar with its manipulation it may be inserted so rapidly that it is seldom necessary to apply the rubber dam, and this of itself is often an important item in the management of children's teeth. It is especially indicated in occlusal cavities of upper molars and bicuspid, the lower molars

ordinarily calling for fillings too great in area to make this material serviceable. It cannot be depended upon to wear well in cavities with a broad masticating surface.


There is one point upon first permanent molars which calls for the most careful attention in the early period of their eruption,—viz, the mesial surface. This surface is in contact with the second deciduous molar for several years before the loss of the deciduous teeth, and if the tendency to decay is great in that mouth, or if the deciduous molar is affected on its distal surface, the first permanent molar is almost certain to suffer. It is well in many of these cases, as soon as the permanent tooth is fully erupted, to grind away the distal surface of the deciduous tooth so that there is only a narrow contact between the two. In this way the mesial surface of the permanent molar is more readily kept clean.

In case decay occurs on this surface, it may ordinarily best be controlled during the presence of the deciduous teeth with gutta-percha. If a sufficient depth of cavity cannot be gained to secure the gutta-percha in place, it is best to flow cement over the surface as a temporary expedient, though cement on these proximal surfaces must not be depended upon for any length of service. The patient should be instructed to report immediately on the loss of the deciduous molar, and whether the permanent tooth has been filled with cement or gutta-percha it should at that time be replaced with gold. This can be done to better advantage before the eruption of the second bicuspid, when the mesial surface of the permanent molar is freely presented to the operator, than at any time subsequently. At this sitting every vestige of affected enamel should be included in the cavity, and the metallic surface be made sufficiently broad to render the operation as permanent as possible.

In cases where the proximal surface is so decayed that the occlusal surface becomes involved before the operator's attention is called to it, the best temporary filling is ordinarily to be found in a combination of gutta-percha and cement, laying gutta-percha over the gingival third of the cavity and completing the filling with cement. The latter will probably require occasional renewal, but

the gutta-percha will ordinarily last till the patient is in a condition to have gold inserted.

The care of permanent incisors in the mouths of children is a matter calling for careful consideration. If decay occurs very early, it is usually best to resort to cement or gutta-percha, instead of attempting permanent work at the outset. The choice between gutta-percha and cement must be governed by the nature of the decay. If there is sufficient penetration to securely hold the gutta-percha in place, it may be depended on for more permanent work than cement, but in shallow cavities, too sensitive for much cutting, the cement may be maintained in place more readily than gutta-percha. Neither of these materials need be considered in the light of anything but temporary expedients, and the patient should be carefully studied and judiciously schooled toward an attitude of sufficient fortitude to submit to gold operations as early as may seem practicable. The date at which gold may be substituted for the other materials must depend on the sensitiveness of the teeth and the ability of the patient to submit to thorough work without too much nervous tax. It is folly to attempt to insert gold while the patient is so illy under control that perfect work is impossible, as it is also wrong to defer longer than necessary the insertion of a reliable material like gold and leave the teeth to the mercy of materials long since proved to lack permanence.



INDEX.

	PAGE		PAGE
A			
Abscessed teeth, treatment of.....	258	Cavities, classification of.....	79
Amalgam	157	Cavity preparation.....	81
Amalgam, manipulation of.....	227	Cements	159
Amalgam, method of packing.....	229	Cements, manipulation of.....	231
Annealing gold.....	165	Cervical clamps for buccal, labial, or lingual cavities.....	56
Appliances for examining the teeth..	45	Children's teeth, the management of..	269
Application of the dam in difficult cases.....	73	Clamps, kinds of.....	54
Applying the dam for operations on buccal, labial, or lingual cavities .	72	Classification and preparation of cav- ities	79
Arsenic, destroying the pulp with...	248	Cocaine, removal of the pulp with....	251
Automatic mallet, the.....	177	Cohesive and non-cohesive gold.....	164
		Crystal golds.....	172
B		D	
Bicuspids and molars, cavities in, 102, 104, 131		Deciduous teeth, management of the..	269
Bicuspids and molars, clamps for....	54	Deciduous teeth, treatment of ab- scessed	274
Bicuspids and molars, fillings in, 196, 212		Deciduous teeth, treatment of ex- posed pulps in.....	273
Bleaching teeth.....	268	Dental caries	31
Buccal, labial, or lingual cavities.....	126	Dentine, hypersensitive.....	142
Buccal, labial, or lingual cavities, ap- plying the dam for operations on...	72	Deposits on the teeth.....	9
Buccal, labial, or lingual cavities, clamps for	56	Deposits on the teeth, kinds of.....	11
Buccal, labial, or lingual fillings.....	219	Destroying the pulp with arsenic....	248
Buccal, labial, or lingual fillings, fin- ishing.....	220	Destruction of the pulp.....	247
		Detail of cavity formation in proxi- mal cavities in anterior teeth in- volving the incisal angle.....	97
C		Detail of cavity formation in proxi- mo-occlusal cavities in bicuspid and molars.....	117
Calculus, salivary.....	11	Detail of cavity formation in simple proximal cavities in incisors and cuspid	87
Calculus, serumal.....	13	Different forms of gold.....	170
Capping pulps, materials for.....	244	Disto-occlusal fillings in bicuspid and molars	203
Capping pulps, method of.....	246		
Care of the teeth, instructions to pa- tients as to.....	28		
Caries, examination of the teeth for..	44		

	PAGE		PAGE
E			
Examination of the teeth for caries...	44	Instruments for the removal of sali-	
Examining the teeth, appliances for..	45	vary calculus.....	19
Exclusion of moisture during opera-		Interproximal space, the	110
tions.....	47	K	
F			
Filled teeth, opening into where the		Kinds of clamps.....	54
pulps have died but lain dormant..	266	Kinds of deposits.....	11
Filling-materials.....	150	Kinds of rubber dam.....	49
Filling pulp-canals.....	254	L	
Finishing buccal, labial, or lingual		Ligatures.....	58
fillings	220	M	
Finishing gold fillings on the occlu-		Making inlay fillings.....	235
sal surfaces of bicuspid and molars.	218	Mallets and malleting	174
Finishing proximo-occlusal fillings in		Management of children's teeth, the..	269
bicuspid and molars.....	209	Management of permanent teeth in	
G			
Gold.....	164	childhood, the.....	275
Gold, annealing.....	165	Management of pulpless teeth in the	
Gold and its combinations.....	150	anterior part of the mouth to pre-	
Gold and iridium.....	156	vent discoloration, the	267
Gold and platinum.....	154	Manipulation of amalgam.....	227
Gold and tin.....	155	Manipulation of cements.....	231
Gold, cohesive and non-cohesive.....	164	Manipulation of platinum and gold	
Gold fillings, the introduction, con-		in filling teeth.....	221
densation, and finishing of.....	185	Manipulation of tin and gold.....	223
Gold inlays.....	239	Manner of applying the dam in the	
Gutta-percha.....	160	different locations in the mouth....	64
Gutta-percha, manipulation of.....	234	Manner of using the matrix.....	201
H			
Hand mallet, the.....	174	Materials for capping pulps.....	244
Hand pressure.....	180	Matrix, the.....	196
Hypersensitive dentine.....	142	Matrix, manner of using the.....	201
I			
Inlay fillings, making.....	235	Method of capping pulps.....	246
Inlays	161	Method of packing amalgam.....	229
Inlays, gold.....	239	Moisture, exclusion of, during opera-	
Inlays, porcelain.....	235	tions.....	47
Instructions to patients as to the care		N	
of the teeth	28	Napkins.....	77
O			
		Occlusal cavities in bicuspid and	
		molars	131
		Occlusal fillings in bicuspid and	
		molars.....	212

	PAGE
Occlusal fillings in bicuspids and molars, finishing	218
Opening into filled teeth in which the pulps have died, but have lain dormant	266

P

Peridental membrane, protection to, in malleting	182
Platinum and gold, manipulation of.....	221
Pluggers	190, 207
Porcelain inlays.....	235
Proximal cavities in anterior teeth involving the incisal angle.....	96
Proximal cavities in incisors and cuspids, simple.....	81
Proximal cavities in bicuspids and molars.....	102
Proximal fillings in anterior teeth involving the incisal angle.....	194
Proximal gold fillings in incisors, simple.	186
Proximo-occlusal cavities in bicuspids and molars.....	104
Proximo-occlusal fillings in bicuspids and molars.....	196
Proximo-occlusal fillings in bicuspids and molars, finishing.....	209
Pulp-canals, filling	254
Pulp-capping	241
Pulp, destruction of the.....	247
Pulp, removal of the.	252
Pulpless teeth, treatment of.....	258

R

Rapid mallets	178
Removal of calculus, instruments for.	19
Removal of salivary calculus.....	17
Removal of serumal calculus.....	23
Removal of stains from the teeth.....	26
Removal of the pulp.....	252
Removing the pulp with cocaine.....	251
Rolls, cotton.....	79
Rubber-dam clamps.....	52
Rubber dam, kinds of.....	49
Rubber dam, method of applying in different locations in the mouth....	64


	PAGE
Rubber dam, punching the holes in..	51


S


Salivary calculus.....	11
Salivary calculus, removal of.....	17
Sensitive dentine, treatment of.....	138
Separating teeth.....	84, 115
Serumal calculus.....	13
Serumal calculus, removal of	23
Simple proximal cavities in bicuspids and molars.....	102
Simple proximal cavities in incisors and cuspids.....	81
Simple proximal gold fillings in incisors.....	186
Size of rubber dam.....	50
Stains on the teeth.....	15
Stains on the teeth, removal of.....	26

T

Technique of removing salivary calculus	20
The automatic mallet.....	177
The hand mallet.....	174
The interproximal space.....	110
The introduction, condensation, and finishing of gold fillings in the different classes of cavities.....	185
The treatment of pulpless teeth.....	258
The use of napkins and cotton rolls for maintaining dryness during operations.....	77
Tin	159
Tin and gold, manipulation of.....	223
Treatment of abscessed deciduous teeth.....	274
Treatment of abscessed teeth.....	258
Treatment of exposed pulps in deciduous teeth.....	273
Treatment of pulpless teeth having a fistulous opening on the gum.....	264
Treatment of pulpless teeth where the canals have been long exposed to the fluids of the mouth, but where there is no fistulous opening.....	258
Treatment of sensitive dentine in deep-seated cavities.....	138











RK541

J62


Johnson

Principles and practice of filling
teeth.

COLUMBIA UNIVERSITY LIBRARIES (hsl, stx)

RK 541 J62 C.1

Principles and practice of filling teeth



2002399555

