

Infections of the hand : a guide to the surgical treatment of acute and chronic suppurative processes in the fingers, hand and forearm / by Allen B. Kanavel ... illustrated with 133 engravings.

Contributors

Kanavel, Allen B. 1874-1938.
Augustus Long Health Sciences Library

Publication/Creation

Philadelphia ; New York : Lea & Febiger, 1912.

Persistent URL

<https://wellcomecollection.org/works/j57dg2hk>

License and attribution

This material has been provided by This material has been provided by the Augustus C. Long Health Sciences Library at Columbia University and Columbia University Libraries/Information Services, through the Medical Heritage Library. The original may be consulted at the the Augustus C. Long Health Sciences Library at Columbia University and Columbia University. where the originals may be consulted.

This work has been identified as being free of known restrictions under copyright law, including all related and neighbouring rights and is being made available under the Creative Commons, Public Domain Mark.

You can copy, modify, distribute and perform the work, even for commercial purposes, without asking permission.



Wellcome Collection
183 Euston Road
London NW1 2BE UK
T +44 (0)20 7611 8722
E library@wellcomecollection.org
<https://wellcomecollection.org>

COLUMBIA LIBRARIES OFFSITE
HEALTH SCIENCES STANDARD



HX64052494


RD551 K13 1912 Infections of the ha


RECAP





COLUMBIA UNIVERSITY
THE
LIBRARIES
THE CITY OF NEW YORK
HEALTH
SCIENCES
LIBRARY






1-1-1

1-1-1

1-1-1



Digitized by the Internet Archive
in 2010 with funding from
Open Knowledge Commons

INFECTIONS OF THE HAND


A GUIDE TO THE SURGICAL TREATMENT OF
ACUTE AND CHRONIC SUPPURATIVE
PROCESSES IN THE FINGERS,
HAND, AND FOREARM

BY

ALLEN B. KANAVEL, M.D.

ASSISTANT PROFESSOR OF SURGERY, NORTHWESTERN UNIVERSITY MEDICAL SCHOOL;
ATTENDING SURGEON, WESLEY AND POST-GRADUATE HOSPITALS, CHICAGO

Illustrated with 133 Engravings



LEA & FEBIGER

PHILADELPHIA AND NEW YORK

Entered according to Act of Congress, in the year 1912, by
LEA & FEBIGER
in the Office of the Librarian of Congress. All rights reserved

~~Webster~~

RD551

K13

1912

C.1

P R E F A C E

IN the presentation of a contribution such as this, an author is at a loss to know just how much of the experimental and anatomical investigations upon which his surgical deductions are based should be included. Upon one hand is the fear that, if too much is introduced, the practical surgical deductions will be lost to the busy and hurried practitioner who first sees these cases; upon the other, if dogmatic statements are made as to diagnosis and therapy, although based on sound reasoning and true for the great majority of cases, the careful surgeon will lack the basal facts upon which he can diagnosticate and treat the atypical and hence more dreaded cases. The author has, therefore, attempted so to arrange the results of his experimental work that, although all of the facts are given upon which deductions can be made in the latter cases, the chapters are so grouped that the busy practitioner can find the part dealing with his particular case quickly.

Given a case in which the practitioner is in doubt, he should read the chapters upon "Diagnosis and Treatment in General." This will indicate the group into which his case falls, and will also direct him to the proper sections of the book where cases of that nature are treated more in detail.

The author takes this opportunity to make acknowledgment of the many courtesies, in the way of permission to study cases, which have been received from

members of the profession at large, including Dr. Van Hook, Dr. Martin, and his co-workers in the Surgical Department of the Northwestern University Medical School, Drs. Besley and Richter. He feels a particular obligation to the Anatomical Department, its various instructors and students, who have been of great assistance on many occasions.

To his surgical assistants, Dr. Cushway, Dr. Eustace, Dr. Wolfer, and many others not so intimately associated with his work, he wishes to express his appreciation of their help in the care and study of the individual cases.

Surgery, Gynecology, and Obstetrics has kindly given permission to use certain plates from the author's articles published in that journal.

A. B. K.

CHICAGO, 1912.

CONTENTS

CHAPTER I

INTRODUCTION—GENERAL DISCUSSION—TYPES OF INFECTIONS

History	17
Scope and Classification of Types of Infection	20

PART I

SIMPLE LOCALIZED INFECTIONS AND ALLIED MINOR CLINICAL ENTITIES

CHAPTER II

INFECTIONS OF THE DISTAL PHALANGES

Felons	25
Treatment	29
Paronychia	31
Treatment	33
Subepithelial Abscesses	37

CHAPTER III

CARBUNCULAR INFECTIONS

Anatomical Considerations and Pathogenesis	38
Treatment	41
Differential Diagnosis	45
Oidiomycosis	45
Chronic Staphylococcus Processes	48

CHAPTER IV

MISCELLANEOUS ABSCESES

Collar-button Abscess (Shirt-stud Abscess) (Frog Felon)	52
Treatment	54
Localized Abscesses in the Thenar and Hypothenar Spaces	55

PART II

GRAVE INFECTIONS—TENOSYNOVITIS, FASCIAL SPACE
ABSCESSSES, LYMPHANGITIS, AND ALLIED
CONDITIONS

CHAPTER V

DIAGNOSIS IN GENERAL

Lymphangitis	58
Tenosynovitis	59
Fascial Space Infection	63
Diagnosis of Extensions from Various Sites	68

CHAPTER VI

GENERAL PRINCIPLES OF TREATMENT

Rest	70
Systemic Use of Drugs	70
Passive Hyperemia	71
Hot, Moist Dressings	72
Prophylactic Incisions	74
Drainage and Treatment of Wound	75
Stimulation of Excretion	77

SECTION I

THE ANATOMY OF THE HAND AND FOREARM, WITH ESPECIAL
CONSIDERATION OF ITS RELATION TO INFECTIONS OF
THE SYNOVIAL SHEATHS AND FASCIAL SPACES

CHAPTER VII

METHODS OF STUDY IN GENERAL—A STUDY OF SERIAL
CROSS-SECTIONS OF THE HAND, WITH PARTICULAR
RELATION TO THE FASCIAL SPACES

Methods of Study in General	80
A Study of Serial Cross-sections, with Particular Relation to the Fascial Spaces	83
Middle Palmar Space	90
Thenar Space	91
Hypothenar Space	95
Discussion of the Relation of the Middle Palmar and Thenar Spaces	96
Recapitulation	99

CHAPTER VIII

THE TENDON SHEATHS—A DISCUSSION OF THEIR
ANATOMICAL DISTRIBUTION AND RELATIONS,
WITH SURGICAL DEDUCTIONS

Sheaths upon the Flexor Surface	101
The Sheaths of the Tendons of the Index, Middle, and Ring Fingers	102
The Radial Bursa and the Sheath of the Flexor Longus Pollicis . .	104
The Ulnar Bursa and the Sheath of the Tendon of the Little Finger	105
The Intercommunication of the Sheaths	109
Sheaths upon the Dorsum	112

CHAPTER IX

THE RELATION BETWEEN THE SYNOVIAL SHEATHS AND
THE FASCIAL SPACES—A STUDY BY EXPERIMENTAL
INJECTION OF THE OUTLINES, BOUNDARIES, AND
DIVERTICULA OF THE FASCIAL SPACES, AND
THE RELATION OF THESE TO THE
SYNOVIAL SHEATHS

The Relation of the Tendon Sheath Rupture to the Fascial Spaces . .	117
Injection via the Tendon Sheath of the Middle Finger	117
Injection via the Tendon Sheath of the Ring Finger	118
Injection via the Tendon Sheath of the Little Finger	120
Injection via the Tendon Sheath of the Index Finger	124
Injection via the Tendon Sheath of the Flexor Longus Pollicis . .	125
General Deductions as to the Relation of Tendon Sheaths to Fascial Spaces	126
The Normal Boundaries of the Fascial Spaces and the Position of Secondary Abscesses in Case of Extension from the Spaces . .	127
The Middle Palmar Space	127
Injection via the Tendon Sheath of the Ring Finger	127
Injection through the Palmar Fascia	128
Injection along the Lumbrical Muscle of the Ring Finger . .	133
Thenar Space	133
Injection via the Tendon Sheath of the Index Finger	134
Injection of the Thenar Space under Forcible Pressure . . .	135
Injection Through Palmar Fascia in Attempt to Reach the Thenar Space	139
Dorsal Subcutaneous Space	140
Injection between the First and Second Metacarpals	140
Injection between the Second and Third Metacarpals	141
Dorsal Subaponeurotic Space	142
Injection under Tendons of Dorsum	142
Hypothenar Space	143
Résumé of Preceding Experiments as to Boundaries, Diverticula, and Extensions from the Fascial Spaces	143

CHAPTER X

ANATOMY OF THE FOREARM IN RELATION TO INFECTIONS

Anatomy in General	149
Serial Cross-sections of the Forearm	150
Experimental Injections of the Fascial Spaces of the Forearm	154
Injection of the Radial Bursa	155
Injection of the Ulnar Bursa	156
Injection from the Middle Palmar Space	157
Résumé of Findings by Dissection and Experimental Injection	159

SECTION II

THE SURGICAL CONSIDERATIONS OF TENDON SHEATH
INFECTIONS AND FASCIAL SPACE ABSCESES OF
THE HAND AND FOREARM

CHAPTER XI

PATHOGENESIS—SOURCE OF INVOLVEMENT OF THE
TENDON SHEATHS AND FASCIAL SPACES

Etiology in General	163
Source of Involvement of the Various Sheaths	164
Extension from One Sheath to Another	165
Source of Involvement of the Important Fascial Spaces in the Hand	168
Involvement from the Tendon Sheaths	168
Direct Implantation of the Infection in the Spaces	169
Involvement by Lymphatic Extension	173
Recapitulation as to Source of Involvement of the Fascial Spaces	176
Extension from One Fascial Space to Another	177

CHAPTER XII

THE SPREAD OF INFECTION FROM ANY GIVEN PRIMARY
FOCUS

The Probable Extensions from Primary Foci on the Fingers	185
The Spread of Infection Involving the Index Finger	185
The Spread of Infection Involving the Thumb	191
The Spread of Infection Involving the Middle Finger	191
The Spread of Infection Involving the Ring Finger	192
Infection Spreading from the Little Finger	193
Infections beginning in the Palm and Dorsum	194

CHAPTER XIII

THE PATHOLOGY OF TENDON SHEATH AND FASCIAL SPACE
ABSCESSSES

The Tendon Sheath Proper	196
The Fascial Space Abscesses	198

CHAPTER XIV

THE SYMPTOMS, SIGNS, AND DIAGNOSIS OF TENOSYNOVITIS
AND FASCIAL SPACE ABSCESSSES

The Symptoms, Signs, and Diagnosis of Acute Tenosynovitis in General	201
Symptoms, Signs, and Diagnosis of Extensions from Infections Beginning in the Little Finger	204
Extension to Ulnar Bursa	204
Extension to Radial Bursa	207
Extension to Forearm	207
Extension to Lumbrical and Palmar Spaces	208
Symptoms, Signs, and Diagnosis of Extensions from Infections beginning in the Index, Middle, and Ring Fingers	209
Symptoms, Signs, and Diagnosis of Extensions from Infections beginning in the Radial Bursa	213
The Symptoms, Signs, and Diagnosis of Fascial Space Abscesses	215
The Middle Palmar and Thenar Spaces	216
The Hypothenar Space	223
The Dorsal Abscesses	223
Forearm Abscesses	224
Differential Diagnosis	225

CHAPTER XV

THE TREATMENT OF ACUTE SUPPURATIVE TENOSYNOVITIS
—GENERAL CONSIDERATIONS—A REVIEW OF THE
LITERATURE

Excerpts from the Literature	228
--	-----

CHAPTER XVI

THE TREATMENT OF ACUTE SUPPURATIVE TENOSYNOVITIS
(CONTINUED)—DISCUSSION OF TECHNIQUE

Treatment While the Diagnosis May be in Doubt	248
Technique of Treatment after Diagnosis is Made	249
Treatment of Tenosynovitis of the Index, Middle, and Ring Fingers	251
When the Involvement of Adjacent Areas has Begun	253
The Index Finger	253
The Middle Finger	255
The Ring Finger	255

Technique of Treatment of Tenosynovitis of the Little Finger and Ulnar Bursa	255
Treatment of Extensions from the Little Finger and the Ulnar Bursa	262
Treatment of Inflammation of the Tendon Sheath of the Long Flexor of the Thumb	265
Treatment of Inflammation of the Synovial Sheaths upon the Dorsum	276
After-treatment	276

CHAPTER XVII

THE TREATMENT OF FASCIAL SPACE ABSCESES

Technique of Treatment of Abscesses in the Middle Palmar Space	282
The Treatment of Combined Involvement of the Middle Palmar and Thenar Spaces	285
The Treatment of Combined Involvement of the Middle Palmar and Subaponeurotic Spaces	289
Technique of Treatment of Abscesses in the Thenar Space	293
Technique of Treatment of Abscesses of the Subaponeurotic Space	295
After-treatment in Fascial Space Abscesses	296

CHAPTER XVIII

PROGNOSIS AND RÉSUMÉ OF ACUTE SUPPURATIVE TENOSYNOVITIS AND FASCIAL SPACE ABSCESES

Prognosis	297
Résumé	298

SECTION III

LYMPHATIC INFECTIONS

CHAPTER XIX

THE RELATION OF LYMPHANGITIS TO OTHER TYPES OF INFECTION—DISCUSSION OF THE ANATOMY

The Relation of Lymphangitis to Other Types of Infection	301
Anatomy	302
The Lymphatic Vessels of the Hand and Forearm	304
Superficial Lymphatics	304
Deep Lymphatics	312

CHAPTER XX

LYMPHANGITIS—ETIOLOGY, PATHOGENESIS, AND
PATHOLOGY

Predisposing and Active Factors in the Production of Lymphangitis	314
Influence of Type of Germ	316
Influence of the Anatomy on the Course	318
Sporotrichosis	322
Relation of Lymphatic Abscesses Studied by Experimental Injections	323
Report of Injections of Forearm Near the Radial and Ulnar Vessels	323
Experiments by Injection along Ulnar Artery	325
Pathology of Lymphangitis	325

CHAPTER XXI

SYMPTOMS AND SIGNS OF LYMPHANGITIS

Symptoms and Signs in General	328
Types	329
Type I. Simple Acute Lymphangitis	329
Type II. Acute Lymphangitis with Minor Local Complications	329
Type III. Acute Lymphangitis with Serious Local Complica- tions	329
Type IV. Acute Lymphangitis with Systemic Involvement	329
Acute Lymphangitis with Serious Local Complications	330
Phlegmonous Lymphangitis	332
Frequency of Localization in Lymphatic Infections	333
Acute Lymphangitis with Systemic Involvement	333
Deep Lymphangitis	334
Systemic Involvement	337
Postmortem Statistics	344
Thrombophlebitis	345

CHAPTER XXII

PROGNOSIS IN LYMPHATIC INFECTIONS

CHAPTER XXIII

THE TREATMENT OF LYMPHATIC INFECTIONS—GENERAL
DISCUSSION

Discussion of Various Procedures	351
Local	351
Hot, Moist Dressings	351
Rest	353
The Bier Treatment	353
Incisions	354
Systemic Treatment	356
Antagonistic Drugs	356
Serum and Vaccine Treatment	357
Supportive Measures	358

CHAPTER XXIV

THE TREATMENT OF THE COMPLICATIONS OF
LYMPHANGITIS

Tenosynovitis	359
Subcutaneous Abscesses	361
Periglandular Abscesses	362
Subclavicular and Shoulder Abscesses	362
Systemic Complications	363
Chronic Infections—Repeated Infections	363

SECTION IV

ALLIED INFECTIONS

CHAPTER XXV

ERYSIPELAS, ERYSIPELOID, GAS BACILLUS INFECTION,
ANTHRAX

Erysipelas	333
Erysipeloid	373
Gas Bacillus Infection	375
Anthrax	379

SECTION V

COMPLICATIONS AND SEQUELÆ OF INFECTIONS OF THE HAND

CHAPTER XXVI

FOREARM INVOLVEMENT FROM INFECTIONS OF THE
HAND—PATHOLOGY AND DIAGNOSIS

Subcutaneous Abscesses	383
Deep Abscesses	384
Forearm Involvement—Abscess Formation without Other Complica- tion	385
Location of the Abscesses	385
Symptoms, Signs, and Diagnosis	389
Deep Forearm Involvement Associated with Wrist-joint Invasion	391
Examination of the Radial Bursa in Cadavers	392
Pathology Found in Serious Wrist-joint Involvement	393
Forearm Involvement with Secondary Hemorrhage	400

CHAPTER XXVII


TREATMENT OF INVOLVEMENT OF THE FOREARM
SECONDARY TO HAND INFECTIONS

Treatment of Uncomplicated Cases	405
Treatment in Cases Where the Wrist-joint is Involved	410
Treatment in Cases of Secondary Hemorrhage	413

CHAPTER XXVIII

SEQUELÆ OF INFECTIONS OF THE HAND—CHRONIC PRO-
CESSES, OSTEOMYELITIS, ARTHRITIS, CONTRACTURES,
AND ATROPHY—RÉSUMÉ, CHRONIC INFECTIONS

Involvement of the Finger Proper	415
Pathology	415
Treatment	421
Involvement of the Hand Proper and the Metacarpals and Carpals	426
Pathology	426
Treatment	433
Atrophy and Contracture	436
Résumé—Chronic Infections	437



INFECTIONS OF THE HAND

CHAPTER I

INTRODUCTION

SCOPE AND CLASSIFICATION OF TYPES OF INFECTIONS

THE accompanying contribution to our knowledge of infections of the hand is the result of several years' study, comprising experimental and anatomical investigations carried on in conjunction with careful clinical observation of an extensive number of cases. In the following pages the diagnostic factors and incisions which this work has suggested will be described. By their use it has been possible even in neglected cases to insure a restoration to complete function in 95 per cent. of the abscesses of the fascial spaces; while in tendon-sheath infections the morbidity has been reduced by fully one-half, and a greater reduction is possible if the profession as a whole will learn to make an early diagnosis in this most lamentable complication.

HISTORY

Professor Albert¹ says that while the word panaritium was not used by Celsus, it is found in the Arabian and other ancient writings, and appears to be a corruption of the Greek *παρονγιά* (*παρά ὄνυξ*). Paracelsus, Dorneus, and others have used the words

¹ Chir., 1885. ii.

pandalitium, passa, panaris, and panarium, and it cannot be said whether these refer to different types or are corruptions of the same word. Concerning the elemental meaning of panaritium, Forestus¹ states: "Panaritium s. Paronychia tumor edicitur, calidus, ulcerosus, summe dolorosus, accidens in summitate digitorum in latere unguis et; quandoque tam vehementer afficiens, ut vigilias et inquietudinem excitet."

Our anatomical knowledge of the lymphatic vessels dates back to the time of Aristotle, but it is to Herophilus (300 B.C.) and Herasistratus (280 B.C.) to whom, according to Galenic writings, we ought to attribute the discovery of the chyliferous vessels. These observations fell into obscurity, and it was not until 1532, when Nicolas Massa discovered renal lymphatics, that the knowledge of the subject began to grow. Following Eustachius, Aselli, and others, Vessling and Rudbeck in the seventeenth century described lymphatics in the liver, pancreas, lungs, and pelvis. Mascagni, Lippi, and Lauth followed with admirable work, while Sappey, in 1876, published his large atlas after twenty years of work, when the subject can be said to have been put upon a scientific basis.

It was shortly before this time, however, that the study of lymphatic abscesses was begun. Bauchet's² treatise, in 1859, upon infections of the hand lacked this knowledge to make it a masterpiece. From this time until the culmination of Sappey's work an acrimonious discussion was maintained over the subject of lymphatic *versus* synovial sheath extension of infection. Gosselin, following dissections, adduced proof that extension nearly always progressed along synovial sheaths. Dolbeau meanwhile presented a masterly

¹ Chir., lib. v, Observat. 16.

² Du Panaris, Paris, 1859.

discussion, supported by clinical evidence, in support of the possibility of lymphatic extension with the formation of deep abscesses. Chevalet,¹ a pupil of Dolbeau, chose for his doctorate thesis, in 1875, to make a further contribution to the literature in support of his master's assumptions, bringing to his aid the brilliant investigations of Sappey and others. Later, Polaillon and Le Dentu supported the theories of Gosselin, although the latter was led to admit that the theories of Dolbeau might have some justification in a few cases. Since that time the subject has received little attention, but we have gradually come to assume that each party was too radical in its claims and that infection can spread by either channel, an assumption that every clinician has had occasion to verify.

In later years a carefully observed series of cases has been reported from the Griefswald Clinic by Max Tornier,² who brought prominently before the profession Helferich's method of opening widely the sheaths, which was later substantiated and discussed with carefully observed cases by Forssell.³

I wish to make acknowledgment of abstracts which I have taken freely from these authors. Forssell particularly has written a most masterly article upon tenosynovitis. I am forced, however, to take issue with him as to certain methods of treatment. Concerning these and the various modern ideas as to the treatment of tenosynovitis, full reference will be found in the chapter dealing with that subject.

In spite of the fact that from earliest times the importance of the subject has been recognized, neither

¹ Thèse pour le doctorat en Médecine, Paris, 1875.

² Beiträg zur Kenntnis schwerer Phlegmonen, Inaugural Dissertation, Griefswald, 1891.

³ Klinische Beiträge zur Kenntnis der akut septischen Eiterungen der Sehnenscheiden der Hohlhand besonders mit Rücksicht auf die Therapie, Nordisches Medizinisches Archiv, 1903, Abt. i, Heft 3.

in text-books nor in special articles can the student find clear descriptions of the various types of acute infections, with the methods of their diagnosis and treatment. This I shall here attempt to give.

SCOPE AND CLASSIFICATION OF TYPES

It is manifest that if we are to have a clear idea of the various phases of infections of the hand, it will be necessary to divide the subject into various types, depending upon the nature of the infection and the results it produces. It should be understood that we are dealing with acute infective processes, and not those associated with syphilis, tuberculosis, and other chronic infections, although the general principles laid down by the anatomical and experimental researches will be found to be applicable there also.

I have divided the subject in general as follows:

1. Simple localized infections and allied minor clinical entities.
2. Grave infections.
 - (a) Discussion of diagnosis and treatment in general.
 - (b) Tenosynovitis and fascial space abscesses.
 - (c) Acute lymphangitis and allied infections.
 - (d) Complications and sequelæ of acute infections.

It is true that in certain cases we shall find all three of the graver types present—*i. e.*, a lymphangitis, a tenosynovitis, and a fascial space abscess—yet in a majority of cases only one type will be found. If they are combined, the symptoms and signs of each are present, and each will demand a separate and distinct form of treatment, for in opening a synovial sheath infection we do not by any means drain the fascial spaces, nor *vice versa*. Again, unless we have

a clear picture in our minds of fascial space infection, and in a given case do not determine whether or not it is present in an acute tenosynovitis—and the diagnosis is by no means easy—we might so make our incision in the synovial sheath that the fascial spaces would become infected unnecessarily; and in a patient who depends upon his hands for his livelihood, such an error becomes criminal carelessness.

Again, while a lymphangitis may become a tenosynovitis or fascial space infection, in a great majority of cases it remains a clinical and pathological entity, and the mistake frequently made of assuming this relationship and treating it accordingly has been responsible for the gravest errors and most serious consequences, both as to morbidity and mortality, that I have met in my experience.

In a great majority of cases the differentiation of these types can be made, but I know of no single rule by which it can be done. The requisite knowledge comes only with a clear understanding of the basic principles of inflammation produced by the various bacteria, coupled with a knowledge of the anatomical relations peculiar to the hand and a study of the course any given infection will normally pursue. It has, therefore, seemed necessary to give in some detail the anatomical and experimental investigations upon which my deductions are based, rather than to state dogmatically the rules upon which a diagnosis should be made and the various incisions which I have found to lead to the most rapid recovery. If one will take the time to fix in mind the fundamental facts which are here discussed, he will have no difficulty in applying them to any given case. The technical procedures incident to the operations are easily learned and applied. In almost all cases the difficulty has been an

improper diagnosis, both as to the nature of the infection and the position of the pus.

Therefore, I wish to emphasize that while for the sake of clearness a brief résumé of the contents has been introduced into certain chapters, the careful surgeon will find it necessary to read the context for the coördination of the various data.

It will be found that lymphatic infections follow a distinct anatomical and clinical course, having at all times the possibility of producing certain definite complications which may be prognosticated and anticipated. We shall see that the tendon sheath infections pursue definite lines of invasion, and the position of the pockets of pus when rupture occurs can be prognosticated, so that incisions can be made early at these sites and further extensions prevented.

Concerning the fascial spaces it will be shown that:

(a) There are certain well-defined, uniform spaces upon the fingers, palm, and dorsum of the hand in which pus can accumulate.

(b) There are definite anatomical channels by which infection arising in a given spot will extend to certain of these spaces, while certain other spaces will remain uninvolved; hence the diagnosis of the position of the pus is simplified and the proper site for the incision determined.

(c) There are definite anatomical channels by which pus can spread from the uniform spaces mentioned, and when this occurs, the position of the pus can be prognosticated.


(d) The boundaries of the fascial spaces having been determined, it is easily seen that in the case of some of these the incisions for evacuation must be made at definite spots; otherwise important structures may be injured, or by ill-advised incisions adjacent spaces may be opened at the same time and a spread of the infec-

tion favored to parts of the hand that would not have become involved without this unfortunate surgical procedure.

(*e*) It can be understood readily why, in certain cases, the infection has persisted for weeks and months after apparently opening the pus pocket, since diverticula and intermediary chambers have not been taken into consideration.

The inter-relation of these various facts will be emphasized by case reports, each of which has been introduced to illustrate or clarify some important clinical fact. The number could have been multiplied many times, but I have tried not to duplicate these illustrations.

We will return now to the slighter infections, such as felons, carbuncles, paronychia, etc., which bear little or no relation to these more serious types just considered. It must be remembered that they are clinical entities, each having a pathology peculiar to itself. Owing to their frequency they are of especial interest to the practitioner. While the diagnosis is easily made, the course is often unnecessarily prolonged, owing to a lack of appreciation of the pathological anatomy and the proper means of treatment. These types will be discussed in the immediately succeeding chapters, so that they may not be left to confuse the student later while studying the graver and more important forms.



PART I

SIMPLE LOCALIZED INFECTIONS AND ALLIED MINOR CLINICAL ENTITIES

CHAPTER II

INFECTIONS OF THE DISTAL PHALANGES

FELONS, PARONYCHIA, SUBEPITHELIAL ABSCESES

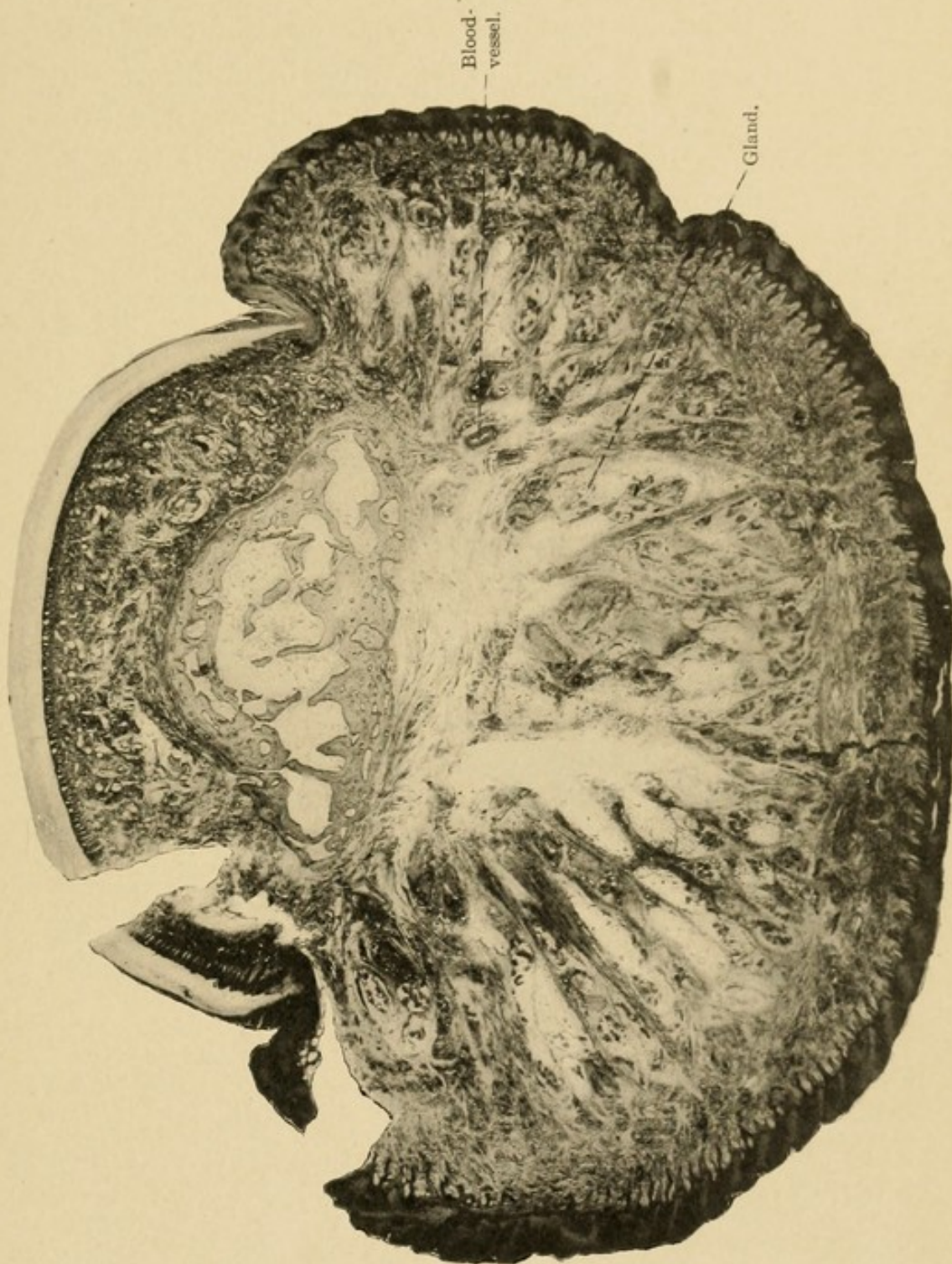
FELONS

FELONS are among the most common infections of the distal phalanx. The source may be a small pin prick or unnoticed injury, and occasionally no history of injury may be elicited. The patient first notices a sticking pain in the distal phalanx, which rapidly becomes throbbing in character and most severe. He cannot rest or sleep. The distal portion of the finger becomes red and swollen. Early it is tender to the touch and this tenderness is most marked over the site of the infection. In the later stages, after pus formation and tissue destruction, the sensitiveness disappears. The phalanx is at first tense from the edema; more tense, in fact, than is ordinarily observed with edema, owing to the peculiar anatomical structure, which will be discussed later. Soon the tenseness is replaced by an induration and later by a fluctuating boggy mass.

The reason for the peculiar pathological condition which is present here in localized infection and

nowhere else in the body is worthy of consideration. The ordinary conception of the pathogenesis is that which has been attributed to Roux, whether justly or not I cannot say. By this the lymphatic vessels are supposed to run perpendicularly from the skin to the periosteum; infection takes place under the periosteum, which is lifted off, and necrosis of the bone ensues. Against this assumption we have the very firm attachment of the periosteum to the bone, Sharpey's fibers going down into the osseous tissue in such a way that it is practically impossible for the periosteum to be separated and differentiated as it is elsewhere. Moreover, there are certain anatomical peculiarities which seem to point to another explanation of this frequent change, so essentially different from that noted elsewhere in the body. The connective-tissue framework is such as to produce a closed sac comprising the distal part of the phalanx, thus differing from the remainder of the finger, while the glands lying in the columns of fat present a portal for the entrance of pathogenic bacteria. This will be seen by examining the accompanying cross and longitudinal sections of the phalanx. Some of the glands may be seen lying near the periosteum. Of especial interest is the presence of the bloodvessels which may be seen in the cross-section, one lying upon either side in the closed space and running parallel with the phalanx (Figs. 1 and 2). Should pus or edema, the result of infection, develop to an undue degree in this closed space, it would have no means of free egress as in the other connective-tissue space. Hence it would have a tendency to shut off the blood supply and cause necrosis of the bone. It will be seen by examining the longitudinal section that the portion of the bone involved is the diaphysis, since the epiphysis receives its blood supply before the vessel enters the closed space. Anatomically, then,

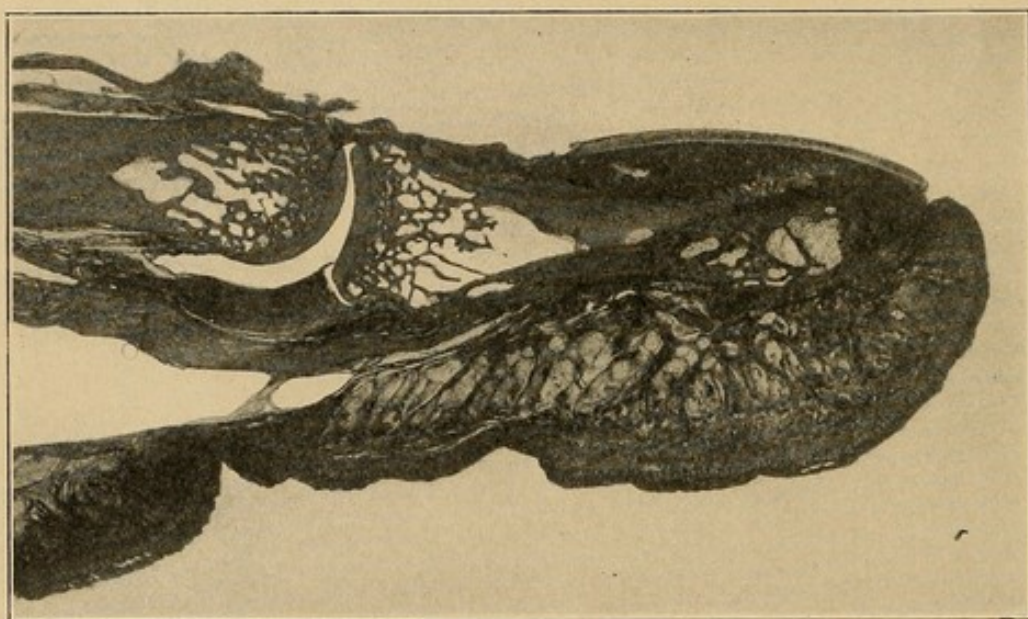
FIG. 1



Transverse section of distal phalanx, showing the closed pocket with columns of fat radiating from the bone. The glands are well shown and demonstrate how easy it would be for pathogenic organisms to invade this space through these glands.

we expect the epiphysis to escape necrosis in these cases, and clinical observation corroborates this view, since the diaphysis is the part of the bone which is lost. This finds its most perfect example in children and those whose epiphyses and diaphyses have not progressed to perfect bony union. It has been my experience frequently to open these old felons in children and have the diaphysis fall out of the sac, where

FIG. 2



Longitudinal section of the distal phalanx and articulation. Note the closed pocket of the pulp of the finger and the columns of fat, with glands shown as dark dots spread throughout. Note that the epiphysis is well separated from this pocket.

it has been floating, a free body, in a sea of pus. In adults, where osseous union has taken place, an examination will show the necrotic diaphysis standing out free from the surrounding tissue, with the epiphysis and joint, in the early stages at least, practically untouched by the destructive process.

This explanation of the pathological sequence would seem to be more reasonable than that of Roux, and also explains the rapid recession of the process after

an early opening, and the slow recovery when delay has permitted the disease to destroy the connective tissue which must ultimately be expelled as a slough.

When the incision has been delayed or the process permitted to go on to spontaneous expulsion of the necrotic matter, we find a bluish, insensitive pus bag with a sinus opening which frequently appears at one side near the nail. As a rule, the granulation tissue is not excessive, the sinus appearing more as a simple canal uniting the pus pocket with the exterior. Fragments of seminecrotic connective tissue often appear partially plugging the opening.

TREATMENT.—The treatment of felons consists in immediate incision into the infected area.

Certain errors are seen at times. The first is an incision made into a phalanx in which there is a beginning lymphangitis and not a localization in the distal phalanx. Such infections cause pain and tenderness throughout the whole finger, although most marked in the distal phalanx. Again, the edema is more general, not having the excessive tenseness in the pulp of the finger characteristic of a beginning felon. Incision here is not only unnecessary, but positively harmful, as will be brought out in discussing the subject of lymphangitis as a whole.

The second error consists in waiting until fluctuation has begun. If this is done, unnecessary pain is endured by the patient. Moreover, such destruction of the connective tissue, and even of the bone, has occurred as to cause not alone prolonged convalescence, but even permanent deformity. The incision should be made as soon as the edema restricted to the distal phalanx has proceeded to a degree causing a hardness, but not necessarily the board-like feeling characteristic of pus in other subcutaneous areas. In general, one may say that when there is present a painful, tender

distal phalanx, with excessive edema limited to the phalanx, incision should be made.

Generally, the patient comes for treatment after the whole area is involved, but at times the finger will be seen early enough to decide, because of the localized tenderness, that the pus has not extended throughout the whole of the closed space, in which case the incision should be made over the localized tender area. In those cases in which there is no localization, but the whole phalanx seems involved, the incision should be made somewhat to the side, and not in the median line, as is unfortunately frequently done. The median incision leaves a scar over the site of the tactile portion of the finger, so that the more delicate functions of that part may be impaired. By examining the cross-sections here shown it will be seen that this pocket can be opened by a lateral incision just as satisfactorily as by a median one, and, in fact, somewhat better, since the radiating columns of fat and connective tissue will be cut transversely, thus leading to more satisfactory drainage. If the incision is made early, one is often surprised at the rapidity of the recovery.

In those cases in which incision has been delayed until necrosis has ensued, certain phenomena may be observed. The connective tissue of the pulp may be so destroyed that pus will continue to discharge until the slough of seminecrotic tissue is expelled. If the opening is small, recovery may be hastened by removing the detritus with tissue forceps. Its removal, however, must await the natural pathological processes incident to all separation of necrotic from living tissue.

Again, when the bone is involved the question often arises as to what disposition to make of it. This will vary with the amount of involvement. If there is complete separation of the tissues from the diaphysis, so that it stands out like a telegraph pole in a sea of

pus, it should be removed at once by the bone-cutting forceps, remembering that the epiphysis is not involved. In the case of a child the diaphysis is often separated at the time of incision or can be easily cut off with the scissors because of the lack of bony union between the epiphysis and diaphysis. If the bone is exposed upon only part of its circumference it will frequently heal without further trouble and should be treated conservatively. In those cases in which the diaphysis is removed no disability of the joint need be feared unless it has become involved, a complication occurring only in a few instances. The phalanx will be somewhat short and the finger nail may be deformed, but movement will not be seriously impaired.

The after-treatment is the same as that used after any incision in acutely infected areas, consisting essentially in procedures designed to relieve pain and favor walling-off of the process by round-celled infiltration. Locally nothing is superior to the ordinary dressing saturated with hot boric acid solution until the acuteness of the inflammation subsides. The hand is elevated to lessen the throbbing pain. These measures are supplemented by opiates if necessary. After the acute inflammation subsides the finger is dressed by gauze thoroughly saturated with vaseline, which permits the free escape of pus and allows the removal of the dressings without pain to the patient.

PARONYCHIA

Among the infections of the distal phalanx is none apparently so simple as the paronychia, or "run-arounds," and yet they frequently baffle treatment for some weeks, since the pathology may not be understood. They begin ordinarily at one side of the nail as a simple infection, frequently from a "hangnail."

This infection may be of two types: first, an acute infection, giving rise to a small wheat-grain-sized abscess in the subepithelial tissue at the side of the nail, which, if opened, makes an immediate recovery; if neglected, it spreads along the side of the nail and back to the base, becoming secondarily a typical "run-around." More often, however, this chronic type develops from a chronic infection along the edge of a "hangnail." For a number of days a drop of pus or more will exude from the inflamed area about the nail edge. It will then be noticed that on the same side at the base there is a certain amount of swelling and redness, with little or no pain. As the days pass the swelling and redness gradually extend about the base of the nail until the opposite side is reached. At the end of two or three weeks drops of pus will be expressed from under various parts of the overlying epithelium (eponychium). A week or two later the entire nail may be lifted off the matrix and cast off, or at least detached along its entire base. Meanwhile, a chronic discharge of pus continues from the original nail sulcus from under the eponychium, since the swelling and edema do not favor satisfactory drainage. This continues for some time, during which the matrix begins to proliferate freely and an almost fungus-like elevation of granulation tissue appears growing from underneath the overhanging cuticle. This picture of the neglected case is not at all uncommon, owing to the habit of the patients to consider this infection as unimportant and consequently to treat it by poultices and salves. In this they are often abetted by the ill-informed physician. At times, it is true, spontaneous recovery may take place, but most often the nail is lost after a more or less prolonged course.

Let us consider the pathology of these chronic inflammations when they spread to the base of the


nail. It will be found almost always that the pus is under the overhanging edge of the nail. Upon extension the pus follows around the nail sulcus, still under the nail. The soft and delicate nail root, under the eponychium, is raised entirely off of the nail bed, although the distal exposed portion of the nail is still firmly attached to the matrix.

TREATMENT.—With a clear understanding of the above pathology, it is manifest that the only proper procedure is to allow escape of this imprisoned pus. This is done by making a longitudinal incision along the outer edge of the nail, going back to the base as far as the sulcus, with special care, let me repeat, to cut to the outer side of the nail so as not to cut the nail bed or the overhanging cuticle, since if this is done it may result in a permanently split nail when it grows out anew. The eponychium is now pushed back with a sponge and the point of a sharp scissors inserted under the detached edge of the nail and this is cut off, together with as much of the root of the nail as has become separated from the matrix by the pus. It is wise, generally, to be on the side of radicalism, since otherwise secondary operations may become necessary. After removing this portion of the nail the elevated flap of overhanging cuticle is packed up and out of the field by a small strip of gauze saturated with vaseline to favor drainage for a few days. A hot, moist dressing is applied to the entire finger for a couple of days, after which time a vaseline gauze dressing or dry dressing is applied as the case may demand.

Concerning those cases in which more than half of the base has become involved in the swelling and redness, a word further is required. Here a second incision should be made upon the other side of the nail, using the same precaution as in the first incision, not to cut the nail bed or the overhanging cuticle

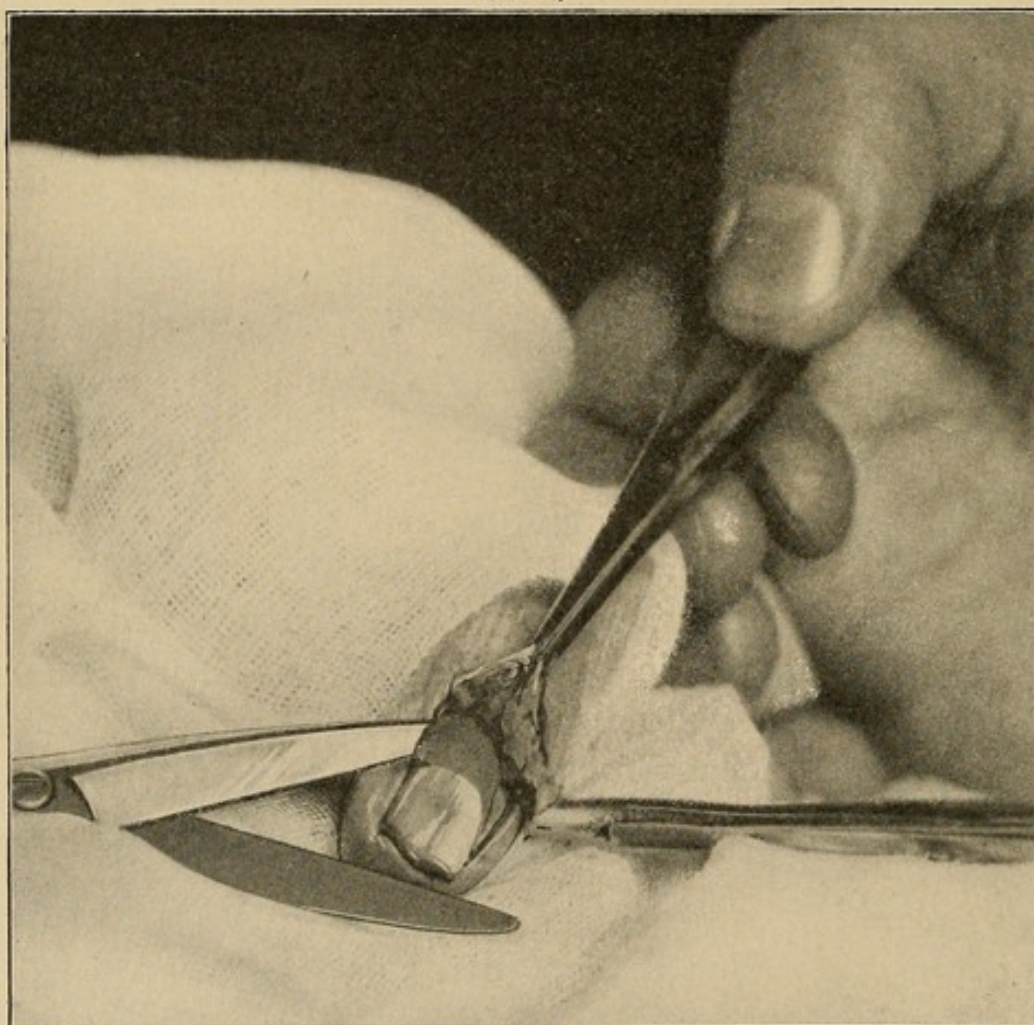
(Fig. 3). The eponychium which is now entirely separated from the epithelium on its two sides is pressed

FIG. 3



Lines of incision used in paronychia.

FIG. 4



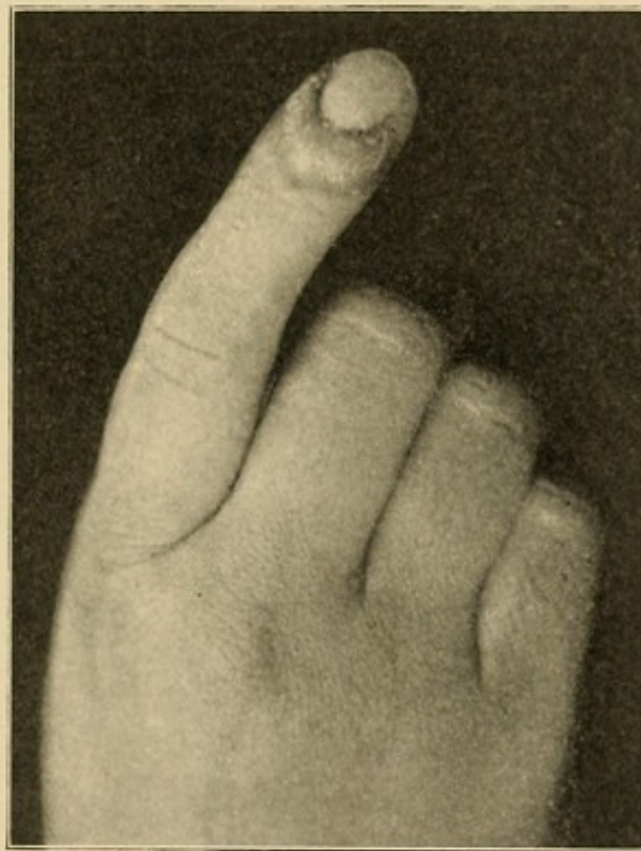
Photograph of steps of operation in paronychia. Flap has been raised and the point of the scissors inserted under the base of the nail.

back and elevated as before, exposing the entire sulcus. The loosened portion of the nail in these cases will

often comprise the entire nail root. This is completely removed, leaving the distal portion of the nail still attached to the matrix. Gauze is packed in as before to raise the flap and secure drainage (Fig. 4).

It is not necessary to remove the distal portion if it is not already detached. It does not interfere at all with recovery, and is still of some service after the

FIG. 5

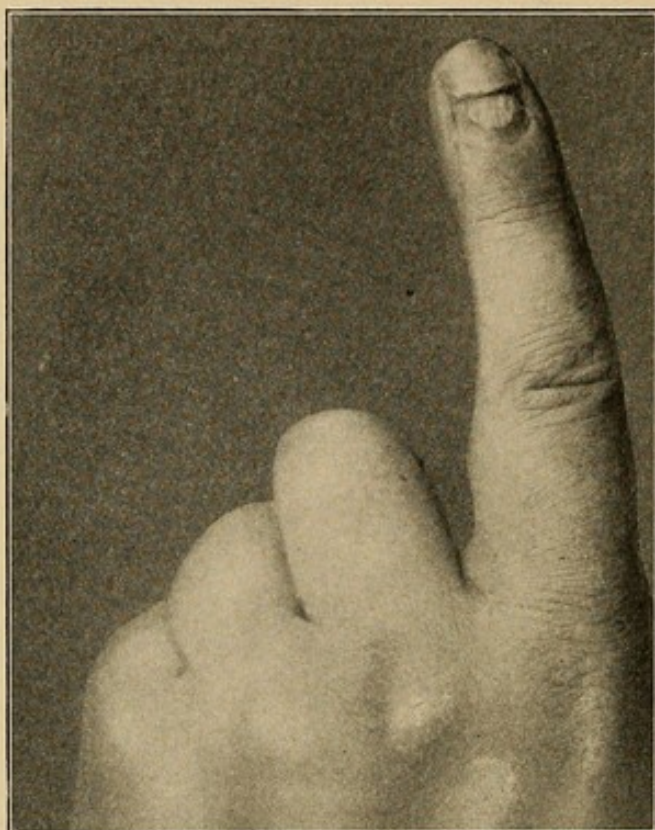


Untreated felon.

acute inflammation at the base subsides. The new nail rapidly forms, and in growing out pushes the old nail in front of it (Figs. 5, 6, and 7).

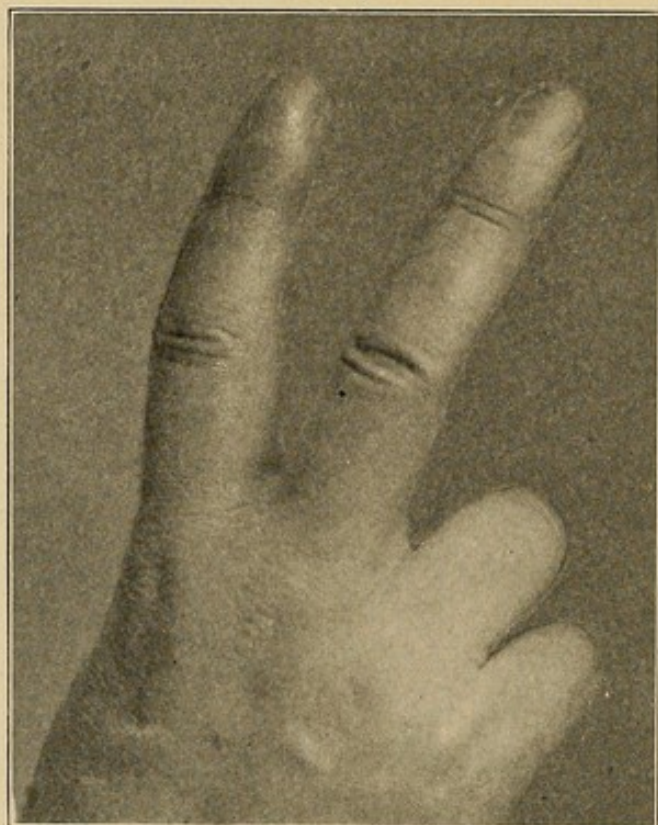
In those cases in which the condition has been neglected or in which the liberating incisions have not been made at the sides, a considerable cauliflower-like growth of granulations may appear, as has already been mentioned. This is, of course, due to the irritation

FIG. 6



All inflammation has subsided and new nail is growing out, forcing the old remnant off.

FIG. 7



Complete recovery at the end of seven weeks.

incident to inadequate drainage. Hence we should see that the drainage is free. This will be followed by the formation of nail and the rapid disappearance of the granulations. I have never yet cauterized these. In one intractable case rapid relief was secured by placing a rubber band about the base of the finger, producing a Bier's hyperemia for some days.

SUBEPITHELIAL ABSCESSSES

It is not at all uncommon for subepithelial infections to take place either as local processes or associated with more extensive infections. The epithelium may be raised over a considerable area, both upon the flexor and the extensor surfaces. As a local process this kind of infection is frequently seen about the distal phalanx, the contents being generally a seropurulent fluid of low grade of virulency.

The treatment consists in removing the elevated epithelial covering and applying some dry dressing or hot boric dressing as the virulency of the case demands. It is essential that every part of the detached epithelium be removed; otherwise, the moist, warm pocket will favor the further development of the infection.

CHAPTER III

CARBUNCULAR INFECTIONS

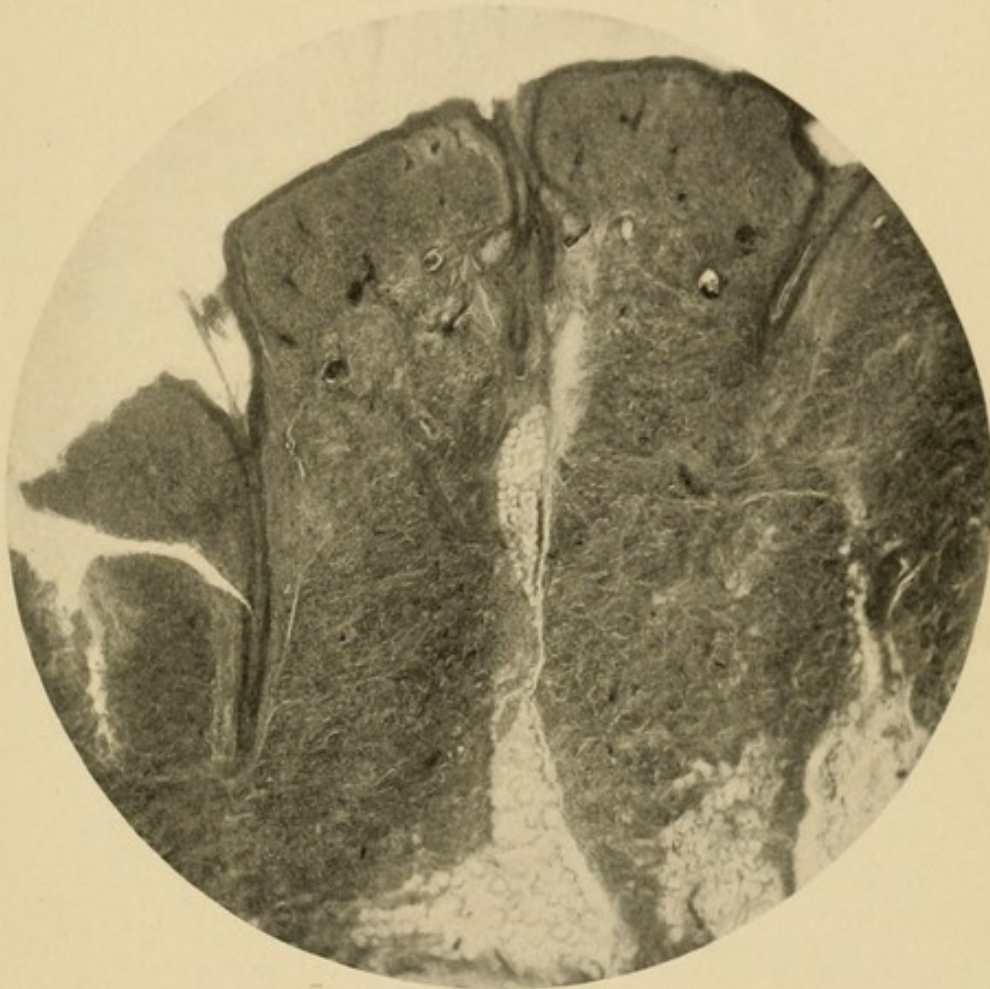
THE carbuncles which develop on the hand are typical of that condition elsewhere. Carbuncles, although seen frequently, are often not understood by the practitioner, who does not take the proper steps necessary to their immediate cure.

They may develop in any portion of the dorsum containing hair follicles, their most common site, therefore, being the dorsum of the proximal phalanges (Figs. 11 and 12) and the back of the hand upon the ulnar side. The various types of staphylococci are most often the exciting organisms. The peculiar pathology characteristic of this condition is due to the nature of the skin and subcutaneous tissue with its sweat glands, hair follicles, and columns of fat extending up into the derma.

ANATOMICAL CONSIDERATIONS AND PATHOGENESIS.—In an attempt to determine the source of these infections and the cause of their persistence, I made serial sections of a portion of the skin and identified the various structures in the succeeding sections, without, however, being able to say definitely that the source could be attributed to either the sweat glands or hair follicles alone. Repeatedly on examination a hair follicle with its sebaceous gland could be found in the subjacent columnæ adiposæ; on the other hand, it almost as frequently occurred that the convoluted sweat gland would also be found (Figs. 8 and 9). One could only conclude, therefore, that it was possible for the carbuncle to begin from either, although it

seemed more reasonable to attribute its source to the hair and its sebaceous gland. Garré, Budinger, and others have demonstrated upon themselves that it is very easy to produce such infections by rubbing into the skin virulent streptococcus cultures.

FIG. 8

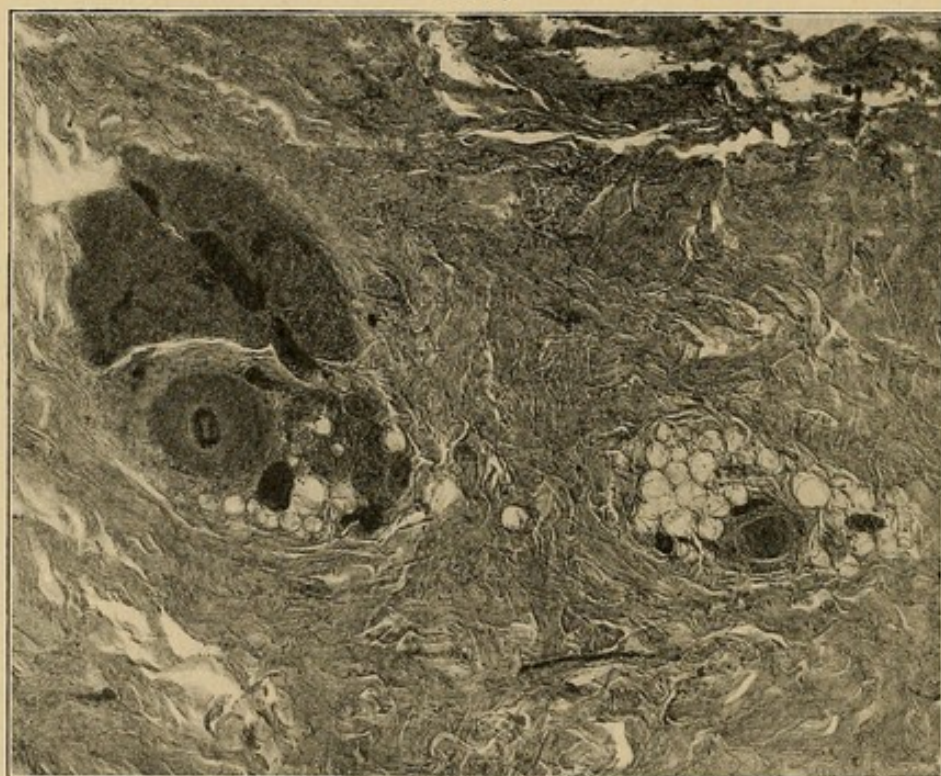


Sagittal section of the skin showing columna adiposa. At the upper part note the hair follicle with its sebaceous glands connecting this column of fat with the skin. In the lower portion of the column of fat a sweat gland is seen.

In the accompanying microscopic illustration of a cross-section of the skin, the various columnæ adiposæ may be seen with the hair follicles, sebaceous glands, and sweat glands in various locations (Fig. 10). From a study of this, the course an infection will pursue can be seen readily. Beginning in one of the columnæ,

the accumulation finds readier escape downward into the subjacent fat. From there it spreads laterally and gradually fills the loose mesh under the skin and ascends into the various columnæ, from whence the infection extends to the surface from these many sources, straining through a sieve, as it were. As the process persists the central part of the surface becomes necrotic, and

FIG. 9



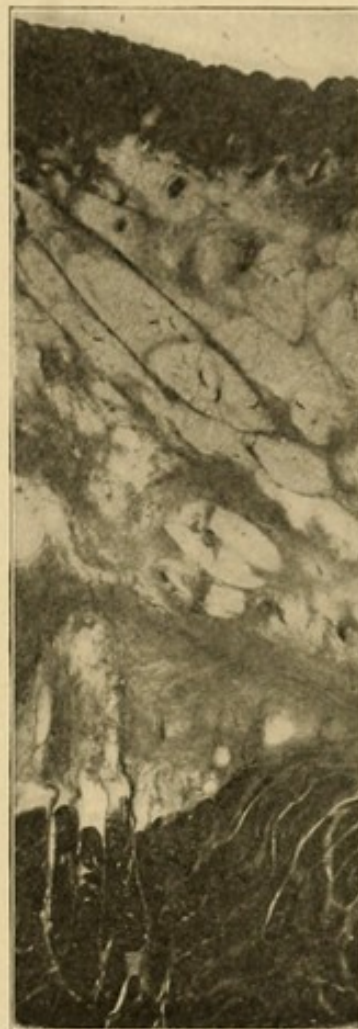Section parallel to the skin. Note that here we have two columnæ adiposæ cut transversely. In one a hair is seen and in the other a hair and a sweat gland. It is readily seen how pus would follow along these to the surface.

through this is extruded pus and seminecrotic connective tissue. Even this does not give free drainage, and the process still tends to extend around the periphery. Meanwhile, more and more of the overhanging skin becomes destroyed, until such a time as enough surface is destroyed to give free exit to the pus and the surrounding inflammatory infiltration walls off the infection, which it does with difficulty, owing to the

many interstices in the loose mesh of subcutaneous tissue through which the pus can extend. An examination of a schematic cross-section of such an inflamed area shows these various facts. Clinically they are observed on the surface as follows: First, the central necrotic area: about this the area of tissue shows punctate pus exudations, and beyond this a bluish circumference through which the pus has not penetrated, although it is under the skin, and finally, surrounding it all, an area of induration denoting inflammatory reaction.

TREATMENT.—These cases are best treated by a crucial incision, the ends of which extend beyond the edge of infiltration, followed by incisions under the skin, so that this may be raised off of the underlying tissue (Figs. 11 and 12). The base of the flaps should correspond with the ends of the crucial incisions. Hot, moist gauze is now packed under the flaps to insure drainage. The patients are always anesthetized, nitrous oxide being preferable. The reasons for carrying the incisions in the skin beyond the edge of inflammatory exudation, as indicated by the induration, are difficult to understand. The principle is directly opposed to the ordinary

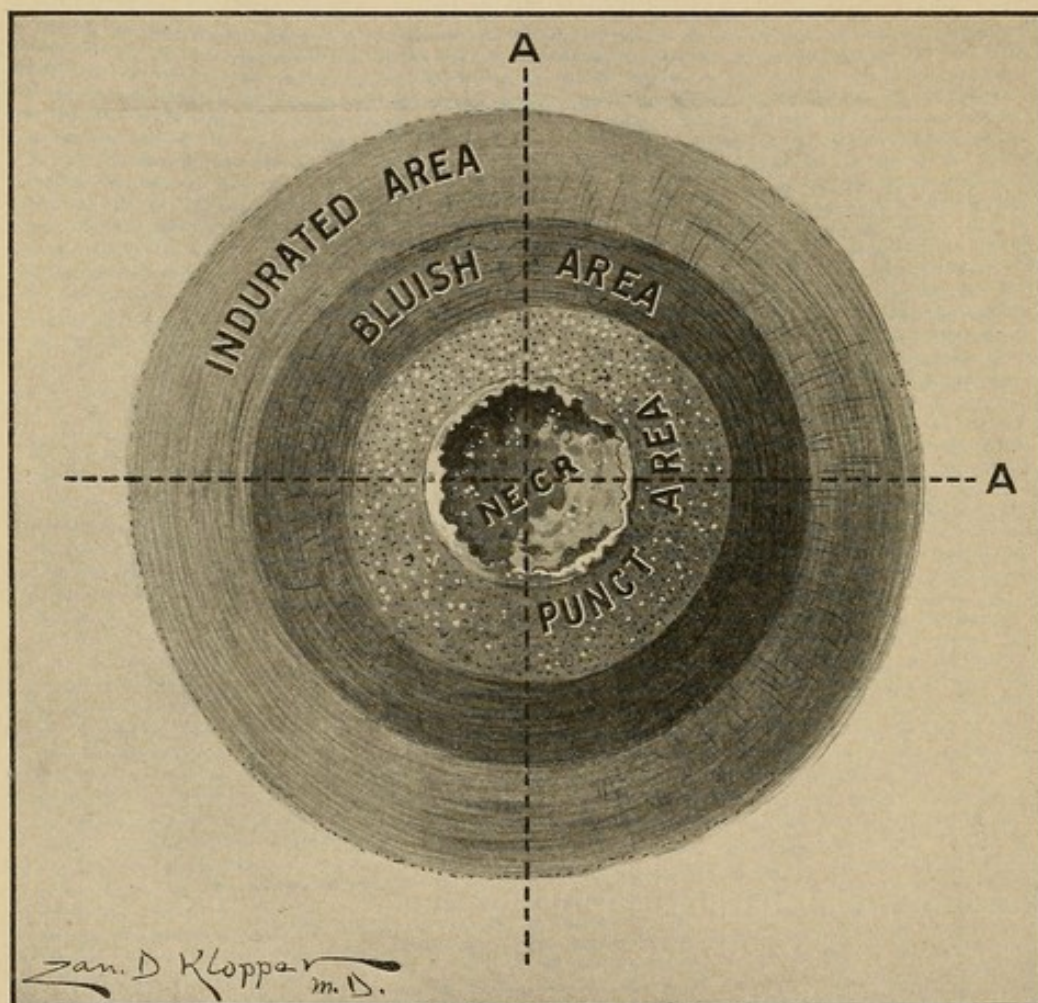
FIG. 10



A section of the skin, subcutaneous tissue, and muscle, showing the area in which the pus of a carbuncle develops and how it spreads beneath the skin and comes to the surface through the various dark lines in the skin which represent the hair follicles. Note several dark dots in the fat underneath the skin. These are cross-sections of hairs which have penetrated beneath the skin and lie in the fat.

conception of this area as a protecting wall, which in other conditions we would use every possible precaution to preserve. Of the advisability of the length, however, I have no doubt, since I have had occasion to use this method in probably 30 cases, and whenever the tech-

FIG. 11

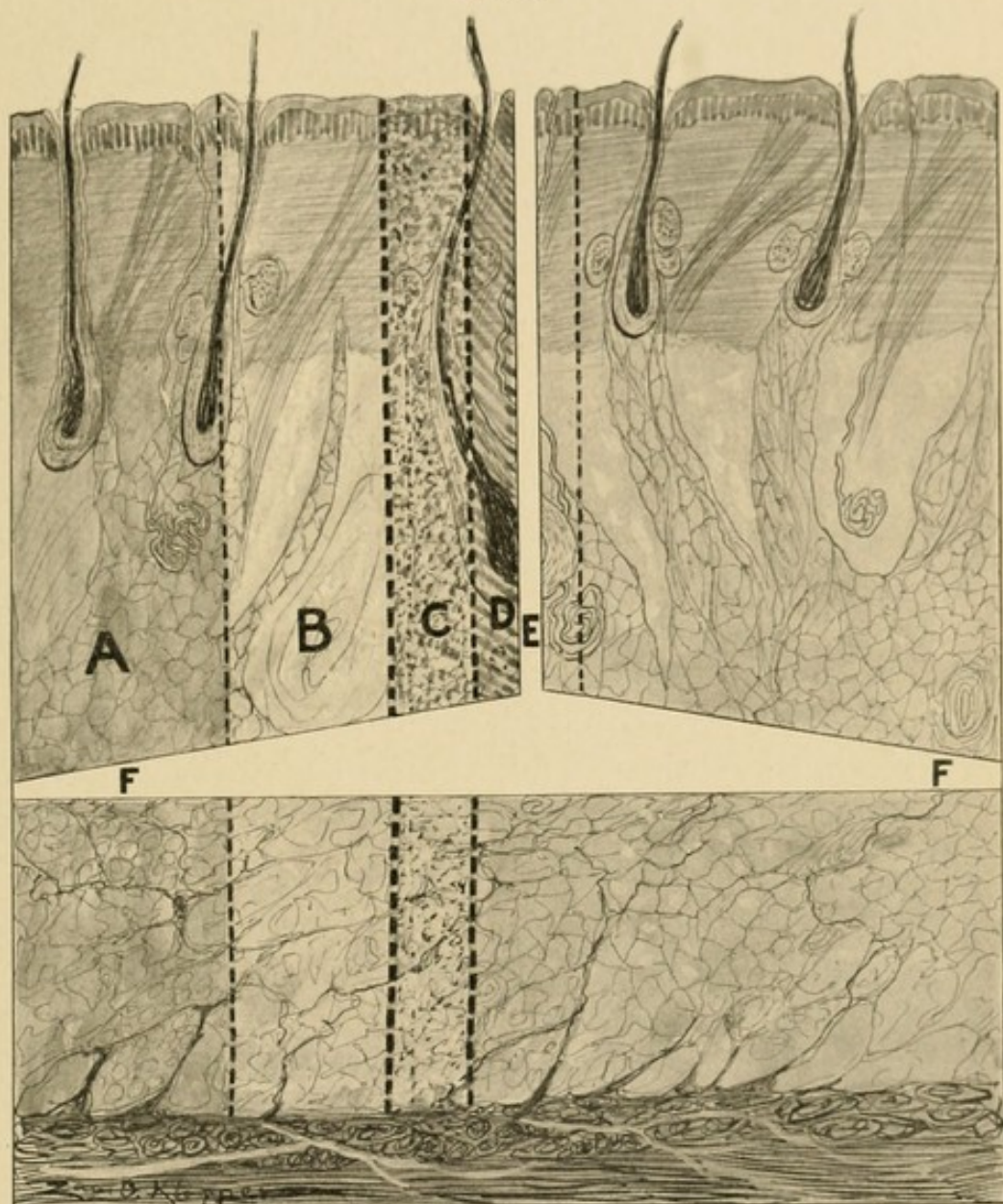


Schematic drawing showing the areas of the carbuncle with the length of incisions upon the skin.

nique described has been faithfully carried out the result has always been satisfactory. If, however, through a conservatism I fell short, the extension always took place along that area, while the sides where I had made the long incisions would go on to satisfactory recovery.

This same holds true for carbuncles of the neck and other areas.

FIG. 12



Schematic drawing showing areas of infection in the carbuncle and the method by which, through a transverse incision parallel to the skin, the flaps are raised up. Note that this incision *F* goes to the limit of the area of induration *A*; *B*, area of round-celled infiltration and some pus; *C*, area of pus, most of the fat being destroyed; *D*, area of necrosis.

The cuts parallel to the skin designed to free the skin from the deep fascia should be made about midway between these two layers going back through the area of induration also (Fig. 12). Any arterial bleeding

is stopped, but the venous oozing is controlled by packing, and this packing should be sufficient to raise the flaps well up. The packing is removed at the end of twenty-four hours, and the flaps allowed to fall back. If there is not much venous oozing, the gauze is thoroughly saturated with vaseline, which allows drainage and permits removal without pain to the patient.

If there is any free slough it is removed at the time of operation. It is not necessary to curette or cut away any tissue whatever. The removal of any of the skin, no matter how much damaged and fragmentary, should be condemned, since one is always surprised at the rejuvenation of apparently hopelessly injured skin. I have often found the flaps to fall into place and leave a granulating area no larger than a dime, where it had seemed the entire area must be lost. For that reason also one should condemn most severely the procedure advocated by some of excising the entire area. On the other hand, the crucial incision alone, without raising the flaps, is futile in almost all cases and certainly prolongs convalescence.

CASE I.—In this connection the history of a patient sent me for treatment is interesting. When the patient was first seen he had been suffering for three weeks with a carbuncle on the dorsum of the left hand. It had begun as a small pimple on the ulnar side, and incisions had been made on six different occasions at different points. The infection had spread to involve the entire dorsum, and had extended to the flexor surface around the thumb and the wrist at the ulnar side. The sloughing connective tissue was being extruded from the incisions and small necrotic ostea which had appeared over its surface. In other places it had the characteristic appearance of a carbuncle.

The patient was anesthetized and a crucial incision made, not, however, carrying the incision the full

length of the infected area, for fear of impairing the nutrition of the flaps. The entire area, however, was undermined and gauze saturated with hot boric acid solution carried to the edge. An immediate cessation of the process took place except at the wrist, where a subsequent incision had to be made, owing to the inadequacy of the early incision. When the flaps finally healed, it was found that no grafting was necessary. So much of the skin had retained its vitality that the denuded areas were soon covered by epithelium.

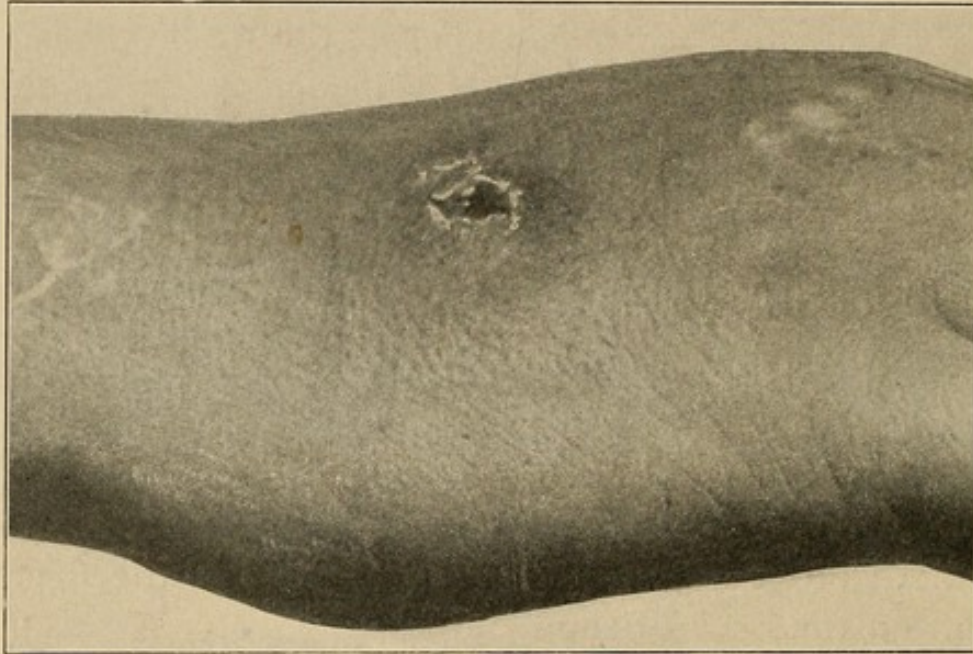
At times I have been compelled to cover a small denudation by a Thiersch graft from the patient's body. This should be done as soon as a good granulating base has been assured. This, in my experience, is more often necessary on the dorsum of the finger than on the back of the hand.

The illustrations show, in both cases, beginning carbuncles (Figs. 13 and 14). The one on the finger had been treated a week before it came under my observation, and, after incision, was dressed only twice and was entirely well in a week. The one on the dorsum of the hand had been treated for six days after a simple incision. After opening it properly and applying the Bier suction cup, which I have used at times with success, entire healing followed in a week. This picture of an apparently simple case is presented, since it is in such that the diagnosis is not made. They are considered simple abscesses. The more severe cases with the punctate areas of pus are recognized by all if they are acute.

DIFFERENTIAL DIAGNOSIS.—*Oidiomycosis*.—There is a more chronic type of infection of this area which may be mistaken for oidiomycosis (blastomycosis), and, conversely, an oidiomycosis may be construed to be a subacute carbuncle. The appearance of these

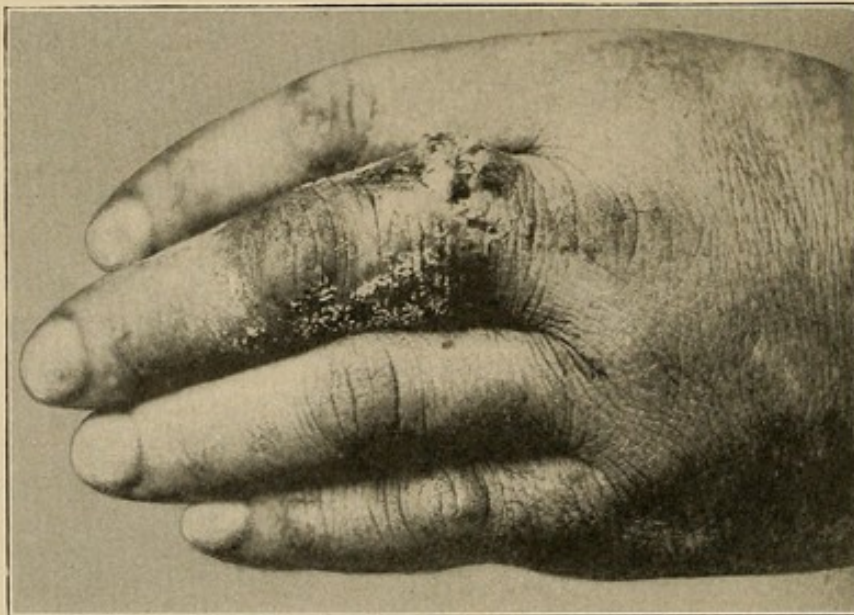
oidiomycotic areas is very characteristic, presenting a rather clean granulating surface, while the edge which

FIG. 13



Beginning carbuncle on the ulnar side of the dorsum of the hand.

FIG. 14



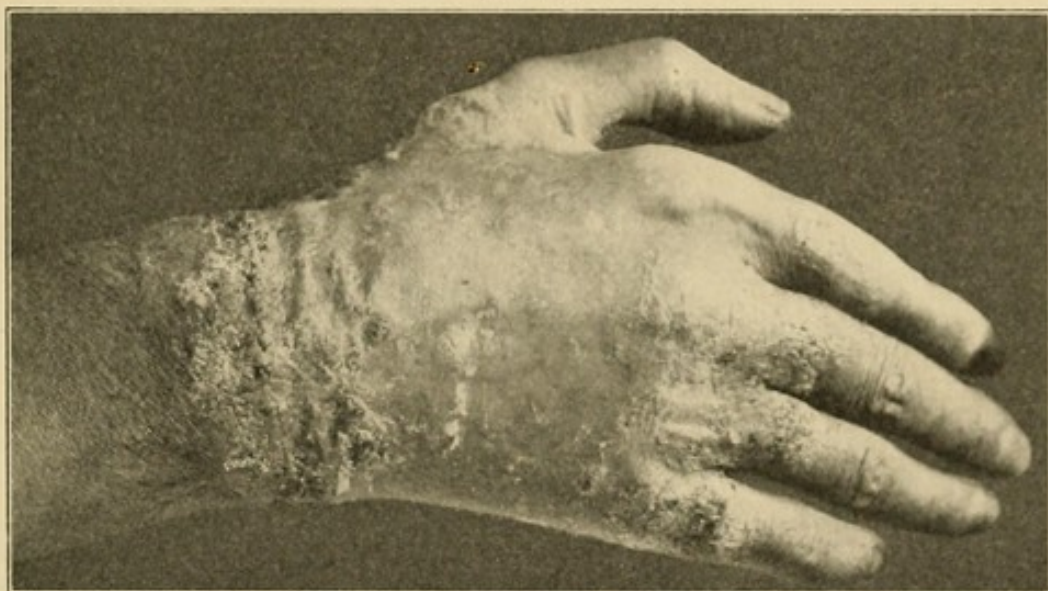Carbuncle on the dorsum of the proximal phalanx.

is undermined appears as if moth-eaten, with pus droplets exuding through. In some parts the process will

apparently have healed and be covered by a thin, shining sheet of epithelium. Over the granulating area the skin is not completely destroyed, since areas of epithelium remain which rapidly produce epidermization when the process is halted.

The diagnosis can be made readily by securing pus from the abscess and examining the unstained smear diluted with 4 per cent. KOH, or with normal salt solution. This finding may be corroborated by microscopic examination of the skin which will show the proliferating rete with miliary abscesses.

FIG. 15



Oidiomycosis. (Photograph loaned by Dr. Ormsby.) Typical and practically identical with that seen in the case described in the accompanying description.

One such case came under my care in which the condition had been held to be a chronic infection and had been treated with salves and applications until the entire dorsum was covered by the ulcerated area. The edges were curetted thoroughly and potassium iodide given in large doses (400 grains per day). The lesion finally healed after some weeks, during which it was necessary to remove the extending edge in

various parts several times. Unfortunately, I have not a photograph of the lesion, but it was practically identical with that shown by the photograph of the same condition in another patient kindly loaned me by Dr. Ormsby (Fig. 15).

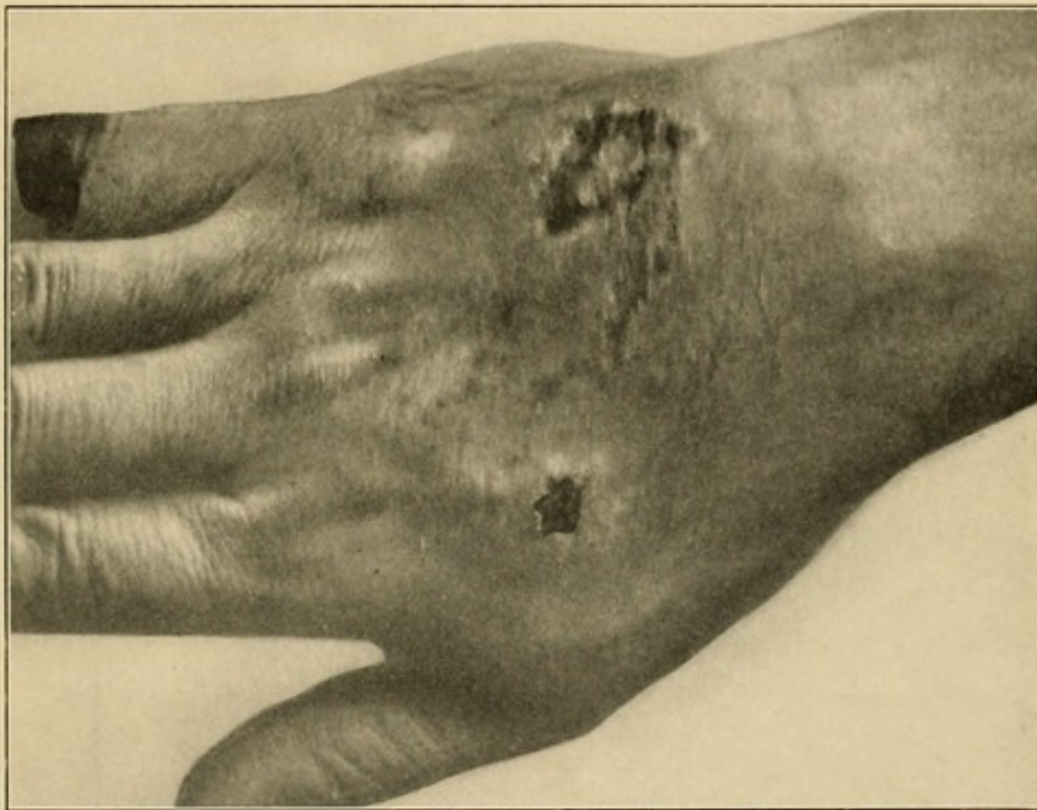
CASE II.—Mr. G. C., of Gallion, Ohio, was referred to me with the history that seven months before he noticed a small pimple on the dorsum of the right hand. The patient opened the pimple with the scissors, following which the sore began to spread by peripheral extension. A couple of weeks later a similar lesion began on the neck, as a result of the patient scratching a pimple there. These two lesions continued to spread until about three weeks before I saw the patient, when two small pustules appeared upon the right arm, and since that several small lesions had appeared on the trunk, all possibly implanted through self-contamination by scratching. The lesion on the hand was of approximately the size shown in the illustration. That upon the neck was about one and one-half inches in diameter. The characteristic appearance already described was present. The areas were excised, following which all the lesions disappeared except that upon the hand. This also finally disappeared under curettage and large doses of potassium iodide.

The condition is essentially different from the picture presented by the foul sloughing syphilitic ulcer or the blue undermined tuberculous process.

Chronic Staphylococcus Processes.—We may have a chronic staphylococcus process upon the dorsum, as has already been said, which may be wrongfully diagnosed as oidiomycosis. Such a case came under my observation with an ulceration upon the dorsum which had involved during its course a greater part of the area, some parts, however, showing pinkish,

glistening new epidermis, while others showed active process appearing as an ulcerating granulating surface, or rather as a depressed verrucous process, while the edges of these areas showed the advancing border of infection. Repeated examinations, both by culture and microscopic tissue study, demonstrated a pure culture of staphylococcus. It is my belief that the process had become chronic in its nature, owing to the peculiar

FIG. 16



Chronic staphylococcus infection of the dorsum simulating oidiomycosis.
(See case report, Pyle.)

anatomy I have described as being found here, coupled with lowered resistance to the specific organism and the irritation of the various treatments to which it had been subjected. It healed rapidly under bland, slightly antiseptic applications. It is my opinion that a passive hyperemia produced by local suction cups would also have hastened recovery in this case. An autogenous

vaccine might also have helped. The case history, written by the patient, who was a physician, is appended. The photograph (Fig. 16) shows the condition inadequately.

CASE III.—Family history negative; aged forty-four years; good health. On September 12, 1910, I noticed skin on middle knuckle of right hand flecked up as if by a pin. On the morning of the 15th I noticed some reddening of the knuckle extending up into the back of the hand, with a slight burning pain. On the morning of the 16th my hand was badly swollen. Pain very severe when hand hung down, and burning was intense.

I treated it vigorously with wet dressings of bichloride, carbolic acid, and boracic acid alternately. The swelling subsided in a few days. The pain was not so severe, but the burning sensation continued. The place where the infection started broke down, forming something like a small ulcer. The infection then seemed to extend up the back of my hand. Every hair follicle seemed to be a centre of infection, breaking down and forming a small opening from which exuded pus. I treated it with iodine, carbolic acid, ointments of every description, dry and wet dressings. With all the treatment the infection continued to spread over the back of the hand, with more or less pain all the time, but increasing at intervals, the burning being almost continuous.

On December 25, 1910, becoming disgusted with my own treatment, and upon advice of my neighboring doctors, I left for Chicago. There my hand was examined by a number of prominent physicians. Each man had a diagnosis of his own. Dr. W. L. Baum's diagnosis was staphylococcus infection. His diagnosis was proved by both culture and the microscope. This was corroborated by Dr. Kanavel.

Was under treatment of these physicians, which consisted of a bland, slightly antiseptic ointment, two weeks before I noticed much change; but within three weeks from the time they started treatment my hand was thoroughly healed, leaving a red scar, which yet remains. The scar resembles that of a severe burn extending over the entire back of the hand.

CHAPTER IV

MISCELLANEOUS ABSCESES

COLLAR-BUTTON ABSCESS (SHIRT-STUD ABSCESS) (FROG FELON)

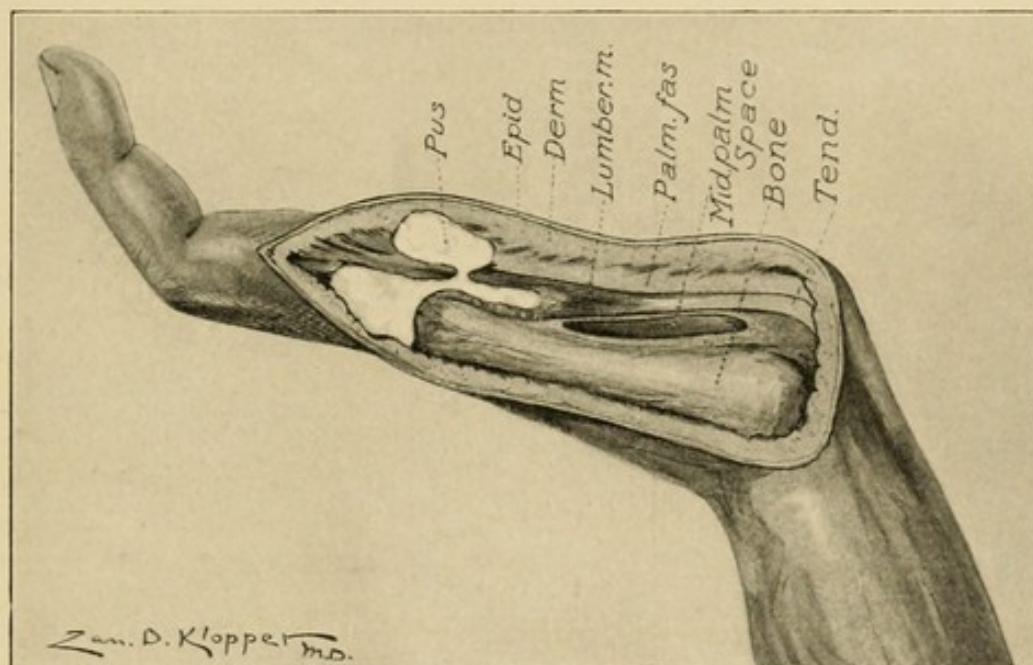
AMONG the local infections of the hand none is more typical than the collar-button abscess, or, as the French describe it, *en bouton de chemise*. This is an abscess located at the distal edge of the palm under the dermal and epidermal tissues. Its peculiar character is due to the fact that at this site, in workingmen, the epithelium becomes markedly hypertrophied, making a dense sheet under which the pus spreads. An infection present under the derma passes through this to the epidermal tissue, where a second abscess forms, thus producing a dumb-bell-shaped accumulation of pus. The pus may locate primarily in the epidermic space and erode through the dermal tissue rather than through the dense epidermis to the surface, producing the same condition. It is possible that this latter course is more common than the former.

These abscesses doubtless owe their origin to the lessened resistance due to trauma more than those developing elsewhere; for here the thickened area of superficial cornified epithelium is frequently opened by cracking, infection ensues in the deeper area by lymphatic extension, or, if the cracks are deep, by direct inoculation. Here it finds excellent food for development, since the repeated trauma has lowered the normal resistance found in healthy tissue.

In this connection attention should be drawn to the fact that at the lower or distal end of the palmar

aponeurosis the sheet may become very thin in spots, particularly between the processes which blend with the tendon sheaths and the superficial transverse ligament, and hence above the canal for the lumbrical muscles. Here, by noting one's hand, slight elevations of tissue may be seen, cushions of fatty tissue. When pus accumulates at this point it spreads very easily into the web of the finger, and in those anomalous cases where the fascia is lacking to any extent these shirt-

FIG. 17



Schematic drawing, showing distal palmar abscess and its extension into the dorsal tissue between the fingers.

button abscesses would enter the fat space and spread down into the cellular tissue of the web pointing on the dorsum between the bases of the fingers. Then the dumb-bell abscess would have from its second chamber a connection with a still larger one on the dorsum, a sort of chain of lakes of pus (Fig 17).

In relation to this, two very interesting cases can be cited, showing how infection apparently in nearly the same site may occupy different spaces.

CASE IV.—From Northwestern University Medical School Dispensary. History: C. B., carpenter by trade, has been using a chisel several days in succession almost constantly. He hits the handle of the chisel with the palm of the hand to force it along. Two days ago the patient began to note tenderness at the distal portion of the palm between the base of index and middle fingers, about 2 cm. from web. Upon examination this was found to be tender to pressure, and had considerable local hardness. Slight edema of dorsum. Temperature, 99°; pulse, 85.

Treatment.—Incision was made over the area and a small amount of pus evacuated. This was under the deeper layers of skin lying upon the transverse fascia in the pad of fat found in this region.

CASE V.—E. A. Applied to dispensary of Northwestern University Medical School November 5, 1904. The patient noticed pain and tenderness at base of ring and middle fingers, about 1.5 cm. from web. Swelling and redness had been increasing for four days. Temperature, 99°; pulse, 86. Local swelling and redness at site noted, involving web also, but most marked above. Tenderness noted as severe.

Diagnosis.—Abscess, subdermal, above aponeurosis. Operation: ethyl chloride spray, and incision made over site of greatest tenderness, down through deep layers of palmar skin. Moderate amount of pus escaped, and upon inserting probe the larger part of the pus was found to be in the cellular tissues of the dorsal web area, $\frac{1}{2}$ inch back from web. Through-and-through drainage inserted.

November 9, nearly well. Patient did not return.

Here we see two abscesses, to all appearances in the same place, yet in reality very different, being so near the distal edge of the transverse ligament that while

one was confined to the subdermal tissue, the second had invaded the adjacent cellular tissue of the web and spread, by continuity of spaces, into the loose tissue of the dorsum where most of the pus was localized.

TREATMENT.—The treatment, therefore, consists in being certain that the second pocket is opened if it be present, and not being content when after incising free discharge of pus is noted. Always examine carefully by inspection or a probe for the second pocket. If the pus has extended to the space in the web, it may be drained by a through-and-through incision from the palmar to the dorsal surface through the web. I have at times cut the web completely without noting any subsequent impairment of function.

LOCALIZED ABSCESSSES IN THE THENAR AND HYPOTHENAR SPACES

In the thenar region several minor and indefinite spaces lie beneath not only the skin, but also the fascia which covers the muscles. The areas are small, however, and are generally opened through the adjacent skin before any serious damage occurs. It is in these areas more often than the thenar space proper that direct infection from puncture takes place, since the latter lies rather deeply, and to invade it the puncture should enter between the muscular body and the adduction crease, rather than upon the prominent part of the thenar eminence. It is well to bear this in mind in making a diagnosis as to whether the thenar space is involved or not, since a minor infection in the superficial tissues of the thenar area either upon the palmar or dorsal surface may be associated with great edema upon the dorsum, and thus confuse the surgeon and lead to a diagnosis of pus in the thenar space when it is uninvolved. This error occurred in one of my cases,

and is of particular interest, since it demonstrates that treatment based upon this improper diagnosis may not produce serious results, for here it will be noted that no disastrous sequelæ followed the opening of the uninfected space in conjunction with an abscess of the subcutaneous tissue.

CASE VI.—E. K. Injured December 12, 1904, at stockyards, by running foreign body into thenar eminence at about middle of palmar surface. All signs of localized infection followed, and on December 16 patient applied to dispensary for treatment. Diagnosis of infection of the thenar space made and through-and-through drainage of thenar area instituted, under gas anesthesia. It was seen that the dorsal subcutaneous tissue only contained pus; tube was withdrawn and dorsal opening enlarged. Patient made rapid recovery, and was discharged in ten days, apparently fully recovered.

The hypothenar area is a closed space, as will be shown later, infection practically always arising from direct implantation and localizing at that site. It does not spread out of the space. Therefore, there is nothing peculiar in its pathology and the treatment of its abscesses consists in simple incision.

PART II

GRAVE INFECTIONS: TENOSYNOVITIS, FASCIAL SPACE ABSCESES, LYM- PHANGITIS, AND ALLIED CONDITIONS

CHAPTER V

DIAGNOSIS IN GENERAL

It is the purpose of this chapter to give in general the diagnostic factors of the three severe types of infection, viz., lymphangitis, tenosynovitis, and fascial space infection. It is not intended in any sense as a complete discussion of any, but is introduced with the idea that by reading this the beginner may be able in any given case to make his diagnosis in general, and thus be directed to the more extensive subsequent discussions for corroboration. Therefore, in various parts indication is made where these can be found. It is desirable to emphasize this, since the greatest difficulty to be met in these cases is the diagnosis. Unfortunately, a snap diagnosis is too often made and incisions hastily carried out which jeopardize the life of the patient and the use of a hand, when a little more care in the diagnosis would have led to an immediate cure. It should be emphasized, further, that if careful study is made it is possible in nearly every case to diagnosticate not alone the nature of the infection, but also the location of the pus if it be present.

There are certain facts which should be remembered:

1. The location of the greatest swelling does not indicate the position of the pus. The excessive swelling comes in those areas where there is the largest amount of loose cellular tissue, *i. e.*, upon the dorsum, while in nine cases out of ten the pus is on the flexor surface.

2. The site of the greatest tenderness is of marked importance in the location of the pus.

3. The three types of infection, *viz.*, lymphangitis, tenosynovitis, and fascial space infection, in the majority of cases are distinct processes, one type alone being present in a given case. At times the types may be combined.

4. The treatment of the three types is essentially different, and the gravest of errors will be made if they are not differentiated, since their treatment is diametrically opposed (see pp. 251 and 351).

Let us now take up these three types in order.

LYMPHANGITIS

Lymphangitis may be either superficial or deep. Deep lymphangitis may end in tenosynovitis or abscess formation in the deep tissues. Most often, however, this does not take place. There is rapid increase of swelling of the whole hand and forearm, with the greatest redness, swelling, and tenderness upon the dorsum. Some red lines of lymphatic infection may be seen running up the arm, to the axilla or elbow. There is an absence of pain on extension of the fingers and thumb. The fingers can be moved voluntarily without pain, and there is an absence of tenderness over the tendon sheaths and the middle palmar and thenar spaces. There is the absence of bulging of the palm, although the concavity may be lost. The patient often presents great prostration (see pp. 328 and 333).

The superficial type lacks the great swelling of the

entire hand and forearm. We receive a history of a slight abrasion or injury on the hand; within a short time the patient complains of all the symptoms of systemic absorption—headache, thirst, sleeplessness, restlessness, and fever. On examination we see locally an area of suffused redness, with a swelling of the finger which is involved. The color seldom becomes of that violaceous tint seen in abscess formation or the pallor which succeeds it. In the most acute types there may be little or no edema, but most often one finds a considerable edema most marked upon the back of the hand. The swelling varies with the site of the invasion. A general rule may be enunciated. *The lymphatics pursue the shortest course to the back of the hand.* In other words, if the infection enters at the distal part of the palm the course will lie between the bases of the fingers. The lymphatics upon the dorsum will show up as bright red streaks running up the arm. Ordinarily one or two only will be seen upon the back of the forearm, although there are fifteen to twenty here. The lymphatics from the little finger and ring finger pass to the glands in the epitrochlear region, and except in the fulminating type these will be found enlarged. From here the infection is carried to the axillary region and thence to the circulation. The lymphatics from the thumb and index finger will be found coursing upon the back and outer side of the forearm and wending their way to the axillary glands without the intervention of the epitrochlear glands (see p. 304).

TENOSYNOVITIS

This type of infection is much more difficult to diagnose, and the surgeon is often in doubt as to whether he is dealing with a lymphangitis or tenosynovitis.

The three cardinal symptoms and signs are:

1. Exquisite tenderness over the course of the sheath, limited to the sheath.
2. Flexion of the finger.
3. Exquisite pain on extending the finger, most marked at the proximal end.

These symptoms are seen to be only a difference in degree from those found in any infection of the hand, but when they are sought for in an intelligent manner there is not much difficulty in differentiating the conditions.

The size of the primary wound is of no importance. The tendon sheath may become infected secondarily to a simple pin prick or an extensive wound. One finds only the cardinal symptoms I have mentioned, and in addition he may notice that the abutting sides of the adjacent fingers are swollen, as well as the back of the hand. The whole of the involved finger is uniformly swollen. The whole hand is slightly tender and the fingers are slightly flexed. The involuntary expression of pain which is noticed when the tendon sheath is touched by the examining finger leaves no doubt in the mind of the examiner as to the location of the infection. The greatest amount of tenderness is generally complained of at the proximal end of the finger sheath in the palm at the metacarpophalangeal articulation. A difference is readily seen between the rigidity in the infected finger and the simple flexion in the adjacent digits. So great is this difference that one is able to diagnose an extension into the palmar sheath, for instance, from the little finger sheath, since the character of the flexion changes to the more rigid noted in tendon sheath infection. The spontaneous pain, which was at first severe, grows less as the edema develops, and may delude the surgeon into believing that the process is subsiding. The arm seems "to fall asleep," as the

patient expresses it. Paresthesias with creeping and itching sensations may be present, and, especially after rupture of the sheath, the tenderness may subside to a considerable degree, leading the surgeon to an early erroneous conclusion.

An infection of the sheath of the tendon in the little finger may be localized to the finger. Extensions to other areas are possible, however. The following are the most common: (1) The ulnar bursa; (2) the radial bursa; (3) the forearm; (4) fascial spaces in the hand: (*a*) middle palmar space, (*b*) lumbrical space; (5) osseous involvement, middle phalanx; (6) joints, proximal interphalangeal, wrist; (7) rupture to the surface.

Extension to the ulnar bursa is often difficult to diagnosticate. It is marked by the development of edema in the hand, especially upon the dorsum. A general fulness in the palm is seen, but the palmar concavity is still to be found. On the flexor surface the greatest swelling is found just proximal to the annular ligament. This is not necessarily due to the rupture of the sheath here, but to the looseness of the tissues, which permits of distention. This swelling is accentuated by the non-distensible annular ligament distal to it. The swelling in the palm occurs at the same time, but is not so conspicuous, owing to the palmar fascia. This also diffuses the swelling so that it is not accurately limited by the outline of the ulnar bursa. Moreover, the surrounding edema tends to confuse the picture (see pp. 201 and 204).

The most conspicuous and valuable sign is the extension of the exquisite tenderness to the area involved. It should be remembered that this is absent after a few days. The wrist becomes fixed, the thumb shows tenderness to pressure, and particularly on passive movements is the sensitiveness noted. It is seen readily

of how much importance this latter symptom is in diagnosing an extension to the ulnar bursa from the little finger. We note that while at first the symptoms are limited to the little finger and slight changes in the ring finger, because of its juxtaposition, all at once the thumb begins to show the characteristic signs while the index and middle fingers remain unchanged except for the increase of pain on passive extension explained above. This sensitiveness of the thumb may be due either to the juxtaposition of the sacs, or to a real extension into its sheath. At first there may be a diffuse redness of the palm and dorsum, but it rapidly gives place to a whitish or even cyanotic hue. Above the wrist, however, the tissue generally takes on a marked red color, which later becomes violaceous. The temperature and pulse may not be of any diagnostic importance. Ordinarily after the infection has lasted a few days and the walling-off process has begun, the temperature is that of the local accumulations of pus and varies with the freedom of drainage. The first few days, however, the systemic absorption bears no relation to the abscess formation and cannot be relied upon for diagnostic purposes.

From the bursa various extensions may take place into the fascial spaces of the hand and forearm. The symptoms and signs of this extension will be taken up under the head of "Fascial Space Infection" (*vide infra*; see also p. 204).

Involvement of the index, middle, and ring fingers presents the same signs as the little finger. The only difference is that here the paths of extension are different. Besides the extension to the surface at the proximal end, involvement of the middle phalanx and the proximal interphalangeal joint, the finger may show extension to the lumbrical space on either side, and from here the involvement of the adjacent tendon (see p. 209).

Extension to the radial bursa is diagnosticated as following an ulnar bursitis by the increased swelling and tenderness in the thenar eminence and along the sheath. The tumefaction of the thenar area is not that of abscess in the thenar space (see p. 217).

Diagnosis of extension from a tenosynovitis of the thumb into the radial bursa, and then into the ulnar bursa is more difficult. We must depend upon the extension of the tenderness to the area over the radial bursa and the tenderness above the anterior annular ligament. When the extension has proceeded over into the ulnar bursa the diagnosis is easier, since all of the fingers become painful to passive extension, most markedly the little finger, with tenderness over the area of the ulnar bursa. The tenderness over the sheath is not always so marked in secondary involvement, however, due possibly to the previously developed edema (see p. 213).

The pus from the radial bursa may rupture into the tissues of the forearm, and then the pus lies under the flexor profundus tendons just as in rupture of the ulnar bursa (see p. 155).

FASCIAL SPACE INFECTION

Pus may be found in various spaces in the hand and forearm, as I have already pointed out. This may occur as a primary infection or secondary to lymphatic or tendon sheath infection, especially the latter. I have demonstrated by injection and serial sections the spaces in which such accumulation can take place. These well-defined spaces are five in number:

1. Middle palmar space.
2. Thenar space.
3. Hypothenar space.
4. Dorsal subcutaneous space.
5. Dorsal subaponeurotic space.

The thenar and middle palmar spaces are by far the most important in the hand.

The forearm has certain spaces which are likely to become infected. Briefly, it can be stated that pus which has extended from the hand to the forearm always lies under the flexor profundus, upon the pronator quadratus and intermuscular septum. It passes upward, following the ulnar artery, going as high as the elbow (see p. 159).

Now, how shall we diagnosticate an involvement of these various spaces? First, upon the possibility of extension from other foci. The middle palmar space would receive infection by extension from the middle finger, ring finger, little finger, also from the ulnar bursa and localized infections in the lumbrical canals between the heads of the metacarpals. Again, it may be involved by direct implantation or through osteomyelitis of the middle and ring metacarpals. It is possible for a thenar space abscess to rupture into the middle palmar space (pp. 168 and 216).

The thenar space might receive the infection from the index finger or thumb, or by direct implantation, or by osteomyelitis of the index or thumb metacarpals, and finally, it would be possible for the space to become involved secondarily to the middle palmar space (see pp. 168 and 216).

The forearm may be involved by extension along the connective-tissue spaces back of the tendons or by rupture from either the ulnar or radial bursa (see pp. 154 and 383). The source of the involvement of the other spaces can be readily surmised (see pp. 168 and 215).

When the middle palmar space is involved we notice that whereas earlier there had been a fulness in the palm without loss of the concavity; now the concavity begins to be lost, and as the process becomes marked,

a slight bulging of the palm is noticeable in spite of the palmar fascia. The correlation of this with tenderness is of especial value. Early, before the swelling becomes marked, the tenderness is exquisite and limited by the outlines of the middle palmar space; but as the swelling increases, the tenderness and especially the spontaneous pain grow less. There is generally more or less extension along the lumbrical canals, so that the swelling of the area between the heads of the metacarpals adds to the general picture. The area may be red, but generally it is pallid. With this there is found the flexion of the fingers due to the juxtaposition of the tendons to this area. They are held rigidly flexed, decreasing in rigidity from the little finger to the index finger. The latter may have considerable voluntary motion. If the pus has extended along the lumbrical canals to the base of the fingers, there may be swelling and induration in the loose tissue of the web, and an accumulation of pus may be found to have extended to the dorsum between the heads of the proximal phalanges. The relation of the swelling in the palm to that in the thenar area is of great importance. In involvement of the middle palmar space there is an associated swelling of the thenar space of almost the same degree as that of the middle palmar space, but this is due to edema (see pp. 216 and 225). When the thenar space becomes involved the swelling is out of all proportion to that of the palm if it be involved. There is the induration of infection rather than the softness of edema. The thenar space will look as if a balloon had been inserted into the area and blown up to its full capacity. I know of no clinical picture in surgery that is more characteristic than this of thenar space infection, and having once seen it one cannot forget it. Besides the ballooning out of the thenar area, the metacarpal of the thumb is pushed away from the hand;

the flexion of the distal phalanx becomes more marked though lacking the rigidity found in involvement of the tendon sheath of the flexor longus pollicis. This infection of the thenar space may be primary and isolated or secondary to a middle palmar infection (see pp. 168 and 216).

The edema upon the back of the hand is always present and the swelling much greater, of course, than in the palm, even though that be the site of the pus. It is extremely uncommon to find any pus upon the dorsum unless there has been a lymphatic infection or the pus has extended, as already described, between the metacarpals of the index finger and thumb from the thenar space, or between the heads of the proximal phalanges. We should bear in mind that edema gives rise to a soft pitting, while if pus be present induration can always be felt. If this fact is borne in mind many embarrassing mistakes will be avoided. I think that in three-fourths of the hands I see in which treatment has been instituted a number of unnecessary and improper incisions are found upon the dorsum (Fig. 74).

The infection may spread from either space to the forearm, or this may be involved from a tenosynovitis of the ulnar or radial bursa. As has been pointed out, the pus in these cases passes between the pronator quadratus and the flexor profundus to the area between the latter and the interosseous membrane, and at about the middle of the area it passes more superficially and to the ulnar side along the ulnar artery and nerve. This extension is characterized by a brawny induration that should not be confused with the softness of an edema. No fluctuation should be expected, since the accumulation lies too deeply. If the primary source is the ulnar or radial bursa, this extension is marked by the loss of the relative swelling immediately above the annular ligament, due to the distended upper end

of the sheath. This swelling is not any less, but that of the arm is greater. The tenderness may become less, so it cannot be depended upon as a symptom. The redness is generally greater, and spontaneous pain, while at first marked, rapidly subsides. At this time some pus may accumulate subcutaneously above the wrist and lead to the supposition that there is no pus under the tendons. Thus valuable time is lost (see pp. 208 and 383).

Involvement of the hypothenar space can often be prognosticated from the site of the primary injury, while the relative lack of swelling in the palm and fingers, with absence of involvement of the tendons, combined with the ordinary symptoms of abscess, leads us to an easy diagnosis. Fortunately, the hypothenar area is so separated from the remainder of the hand that it is not frequently involved secondarily to palmar infection (see pp. 146 and 176).

An infection localized under the subaponeurotic fascia to the exclusion of the subcutaneous tissue may be difficult of differential diagnosis. However, we are aided materially if we remember the character of the primary injury, the methods of extension to this space already mentioned, and the local evidences of infection upon the dorsum, with the pitting edema of the subcutaneous tissue, yet lacking the brawny induration and localized tenderness of a subcutaneous abscess (see pp. 146 and 176).

We may be in doubt as to whether we are dealing with a tenosynovitis of the ulnar or radial bursa or a rheumatism of the wrist. I have seen several such cases, and in one case it was difficult to determine whether the patient was suffering from a gonorrheal rheumatism of the proximal interphalangeal joint of a finger or a gonorrheal tenosynovitis with secondary involvement of the joint. The latter assumption was

later found to be the condition present. In those cases presenting an apparently spontaneous development of an inflammation at the wrist, the diagnosis may be most difficult in spite of the ease with which a theoretical differential diagnosis is made. Here again, however, the localized tenderness over the sheath and pain on extension of the finger are of the greatest importance. Moreover, these cases are always virulent and extend rapidly, so that if it be a tenosynovitis the hand grows rapidly worse. In a rheumatism there is as much pain on the dorsal as on the volar surface, the swelling involves the wrist more than the hand, fingers, or forearm, and other joints may be involved. The presence of a gonorrhea does not aid us materially, since either condition may follow.

DIAGNOSIS OF EXTENSIONS FROM VARIOUS SITES

The diagnosis of the extensions from various sites is of the greatest importance from a therapeutic standpoint. I have worked out these possibilities by both experimental and clinical observations. The present chapter is too brief to allow a full discussion. I shall, however, append a tabulation, with references attached, denoting where a complete discussion of each subject can be found.

If the infection originates in the thumb, for possible extensions see p. 191.

If the infection originates in the index finger, for possible extensions see p. 185.

If the infection originates in the middle finger, for possible extensions see p. 191.

If the infection originates in the ring finger, for possible extensions see p. 192.

If the infection originates in the little finger, for possible extensions see p. 193.

If the palmar space is involved, for possible extensions see pp. 143 and 177.

If the thenar space is involved, for possible extensions see pp. 144 and 183.

If the forearm is involved, for possible extensions see pp. 159 and 384.

If the ulnar bursa is involved, for possible extensions see pp. 120 and 204.

If the radial bursa is involved, for possible extensions see pp. 125 and 213.

CHAPTER VI

GENERAL PRINCIPLES OF TREATMENT

It is not the intention here to discuss in detail the treatment of the various types of infections. Specific directions for dealing with individual cases will be discussed in the chapters devoted to the different types. It is proper, however, to deal with the general principles underlying the various procedures which might be scattered in the succeeding chapters.

The early treatment in any case has for its purpose the walling off of the infection, or its removal by phagocytic action.

REST.—Rest is one of the essential factors, at least in a negative sense. The extremity affected should always be so fixed that movement, either of the whole or muscular action of a part, is impossible, since it is well known that the lymphatic streams are aided materially in their return flow by muscular action. It will undoubtedly relieve the patient somewhat of the throbbing pain to have the hand elevated after the von Volkmann method, but beyond this I cannot feel that the procedure is of great therapeutic value.

Positive factors designed to increase phagocytic action are still subject to discussion, in spite of the extensive contributions in support of this or that procedure. They may be classified as systemic and local. The local again are divided into the results of active hyperemia and of passive hyperemia.

DRUGS.—The systemic use of drugs, such as nucleic acid, etc., to increase leukocytosis, has never been followed by such marked and positive results as to

prove beyond question the advisability of their use, and all, so far as known, may ultimately be discarded, as was turpentine, which preceded them. They have never given any results in my hands. We are not now discussing the applicability of drugs and sera in systemic infections. They will be taken up under that heading later (see pp. 356 and 357).

PASSIVE HYPEREMIA.—Among the local procedures those producing passive hyperemia (Bier) have received the greatest attention in later years. While much of an enthusiastic nature has been written in favor of this method, it is probable that the American surgeons have not secured the results claimed for it by its German supporters. It is not the province of such a contribution as this to review the subject, with a discussion of the various theories as to the changes in the blood; the lessened resistance as claimed by some, and the raised opsonic index as maintained by others. My personal opinion has become quite settled as to its value in acute infections. I have found its chief value in three conditions:

1. In those conditions in which I wish to prevent the rapid absorption of toxins into the circulating blood, as, for instance, in an acute lymphangitis (see pp. 353 and 354), or immediately after incising virulent abscesses of the hand and arm where a marked constriction will reverse the lymph stream and tend to wash the toxins out into the wound, preventing absorption (see pp. 227 and 279).

2. In those cases in which the process has become semichronic with a low grade of infection (see pp. 228 and 435).

3. In the case of localized abscesses which do not drain freely. Here the suction cup is of especial value (see p. 435).

Beyond these conditions I must say I look upon it as

a possible adjuvant in the treatment, but never as the primary factor. It follows, therefore, that early in the course of an infection, if we suspect the process to be particularly virulent, a bandage may be applied to the arm after the method described on pp. 227 and 353. Any other method is painful and may even be harmful. In the ordinary cases I have contented myself with other means, namely, hot, moist dressings, the use of which I believe rests upon a more rational basis. Klapp has emphasized the value of suction cups used over a localized infection. He has devised various types to fit various areas. Their value in certain conditions cannot be gainsaid, particularly in those cases which would be classified in the second and third groups above.

HOT MOIST DRESSINGS.—These are in common used by all, and have proved beneficial in many cases. The most common form in which they are applied is that of the saturated hot boric acid solution, although many other medicaments are employed, such as potassium permanganate, alcohol, bichloride, etc. The solution of hot boric acid, in my opinion, depends for its efficiency largely upon the moist heat, although scientific evidence is not wanting that its chemical action may be of some value. In this connection Dr. E. H. Ochsner reports that Professor Kakenberg, at the University of Wisconsin, conducted a series of examinations demonstrating the presence of a small amount of boric acid—0.01 to 0.03 per cent.—in urine voided after hot applications of a saturated solution of boric acid in water, 3 parts, and 95 per cent. alcohol, 1 part. This is not the occasion to discuss the question as to the bactericidal effect of boric acid, especially in small percentages. Other investigators have maintained that a large percentage is found in the skin and subcutaneous tissue. The dressings may be applied as follows: The saturated solution is boiled and then set aside, and, as

it is desired, it is heated to as great a heat as can be borne by the bare forearm of the attendant. Greater heat, as demanded by some, is not needful. The patient should not be left to decide "if he can stand it," since the infected hand is often very insensitive to superficial pain, and the inadvertent application of the excessive heat may lead to blisters which will be annoying and prolong convalescence. After the desired temperature is secured a sterile towel is unfolded and the dressings dropped into this, which is now immersed at its middle in the water. The dressings are wrung dry by turning the two dry ends in opposite directions, thus securing the dressings properly saturated and wrung out, but still sterile. The dressing is now applied widely, covering the entire infected area, going proximally some inches. Fear rather that your dressing may be too small than too voluminous. The whole is covered by some impervious material, such as paper saturated with paraffin or sheet gutta-percha. This should be covered by a layer of cotton followed by a bandage. Provision should be made at the time of dressing for subsequent applications of the solution by making a hole or two through the outside covering down to the dressing. Through these openings the boric acid solution should be poured every two hours, and the hand dressed as frequently as necessary.

Too often we see the hot boric acid continued for several days. It is not only useless but harmful to continue this treatment after the process is once under control, since it tends to favor congestion and round-cell exudation, which if long continued produces a soggy, infiltrated hand, in which absorption is slow, and as a consequence the ravages of the disease are slowly repaired and fibrinous ankylosis of joints, adhesions of the tendons, shrinking of muscles, and fibrosis in all the various structures are favored.

As soon as the process has subsided it may be treated in various ways, according to the condition. In the presence of congestion, a dressing saturated with a weak solution of alcohol will aid in the dehydration. If there is a foul discharge, a 1 to 2000 potassium permanganate dressing is advisable. If there are many raw surfaces requiring dressing, the gauze may be saturated with vaseline, which permits of painless dressing and does not retard drainage. Against alcohol may be urged with justice its inflammability, so that it should always be used with care. One case came to my notice in which the patient was severely burned through its use.

PROPHYLACTIC INCISION.—One constantly meets cases in which the patient has been subjected to incision at some swollen or tender area, under the assumption that if there is not pus there the "drainage will do good anyway." Such incisions are always ill-advised, since they nearly always do more harm than good. A general rule should be laid down not to incise unless the surgeon has an accurate appreciation of the condition and an absolute diagnosis made. In general, one may say that incision in lymphatic infections should be made as a last resort or because of secondary complications (see pp. 354 and 361). Tenosynovitis should be treated by drainage as soon as the diagnosis is made (see pp. 250 and 251). Abscesses of the fascial spaces are never so urgent as to demand operation before one is sure of the diagnosis. These rules are urged most emphatically, since I see in consultation fully as many cases in which the incision made has been ill-advised or unnecessary as I do those in which further surgical work is indicated.

When incision has been decided upon certain rules are imperative in the severe case. The operation should be done in a bloodless field. I preferably use a Martin

bandage, which is applied from the elbow to the shoulder. After the operation is concluded the bandage is loosened slightly, just enough to allow circulation, but still tight enough to prevent rapid absorption. In fact, I attempt to produce a Bier's hyperemia. This is done with the hope of preventing the rapid absorption of toxins. In a patient who is severely ill such rapid absorption may take place as to overwhelm the system before it has an opportunity to develop antitoxins, while if the bandage is removed through the course of twenty-four hours the system may have an opportunity to develop antitoxins and ward off a systemic infection that might ultimately lead to death. Again, the patient should always be anesthetized. Nitrous oxide is the anesthetic of choice, owing to its non-toxic action. This gives time for carefully placed and adequate incisions. The surgeon should always convince himself before allowing the patient to awaken that he has done the work thoroughly so that the operation will not have to be repeated upon subsequent days. This cannot be done under local anesthesia. Moreover, the hypodermic injection of tissue about an infected area cannot be done without danger of causing a spread either locally or systematically.

DRAINAGE.—Drainage of wounds by means of gauze, tubes, etc., is not of the importance attributed to it by some. The essential factor is to make the incision at the right place and of adequate size. If this is done, drainage strips will be not only unnecessary after the first forty-eight hours, but often positively detrimental to recovery. After incision it is my custom to use either plain gauze, gauze saturated with vaseline, or gutta-percha strips. The former is used only when there is venous oozing and we desire to stop it by favoring coagulation. We must never expect it

to do more than this, and keep the edges of the wound separated, for the plain gauze mesh is soon filled with pus and coagulated serum, which acts as an effectual bar to drainage. Where there is no bleeding, gauze strips thoroughly saturated with vaseline or gutta-percha strips are used. These secure adequate drainage, and can be removed without pain. They are left in for twenty-four to forty-eight hours; if left in longer they prolong the suppuration. It has happened to every surgeon that he sees cases in which the wound has been kept open for weeks by ill-advised drainage material. Rubber tubes are never used, since they favor tissue necrosis and are not any more satisfactory for drainage than gutta-percha strips.

It has been suggested by some that in order to prevent rapid absorption and danger of generalized infection, it would be advisable to open abscesses by the cautery, and again others have suggested painting the cut edges with some solution of iodine. The advisability of this procedure is open to discussion, since it surely should not be used unless the abscess is thoroughly walled off, in which case it is possible to conceive of this procedure being pathologically sound. In a majority of cases, however, bacteria and toxins in the wall are thus sealed up and serum drainage by the method I have suggested is prevented (see pp. 228 and 276). Thus the patient is in greater danger of systemic infection or prolonged local disturbance. It is my personal belief that any procedure which impairs the vitality of tissue cell life, thus reducing its resistance and reparative powers, will be discarded in the end.


The common habit of pressing and squeezing wounds with the purpose of forcing out the contained pus cannot be too severely condemned. It is both unnecessary and harmful. If adequate incision is made,

the pus free in the abscess will drain out, and if it is in the layers of fascia adjacent to the wound, pressure is just as likely to force it farther into the tissue as into the abscess cavity. If the opening is small and drainage inadequate because of the thickness of the pus the wound should be opened more widely, or the pus removed by the Klapp suction cup. If the opening is plugged by seminecrotic connective tissue, it may be removed by the forceps, never with a sharp curette. To repeat, the pressure and squeezing tend to disseminate the infection throughout the surrounding tissue and even produce systemic infection or dislodge septic thrombi.

After almost all incisions in virulent cases there is severe local reaction, causing more swelling in the first twenty-four to thirty-six hours. At the end of that time, if the process has been properly drained, the swelling should begin to subside.

STIMULATION OF EXCRETION.—The excretions should be stimulated, particularly by the introduction of large amounts of water into the system. This may be done subcutaneously by rectum or by mouth, according to the conditions to be met. In the severe toxemias I also use alcohol and peptonized foods for the reasons enumerated later (see p. 356).

MASSAGE.—The early use of massage and passive motion is one of the essentials in the production of functioning hands. Its use is particularly urged in tendon-sheath infection (see p. 278).



SECTION I

THE ANATOMY OF THE HAND AND FOREARM, WITH ESPECIAL CONSIDERATION OF ITS RELATION TO INFECTIONS OF THE SYNOVIAL SHEATHS AND FASCIAL SPACES

CHAPTER VII

METHODS OF STUDY IN GENERAL: STUDY OF SERIAL CROSS-SECTIONS OF THE HAND, WITH PARTICULAR RELATION TO THE FASCIAL SPACES

UPON beginning the study of infections of the hand it was realized immediately that our general knowledge of the anatomy was entirely inadequate when we came to apply it to specific conditions. The first problem, therefore, with which we had to deal was a thorough study of the anatomy carried out entirely in relation to this question. As the work progressed, its immense value from a diagnostic and therapeutic standpoint began to be realized. The reasons for many failures in treatment were seen. The diagnosis was placed upon a firm basis. We are firmly convinced that anyone who wishes to master the proper steps in diagnosis and treatment must follow step by step the unfolding of the anatomical picture as we shall try to present it in the subsequent pages. It will be discussed in the following manner:

*Anatomy of the Hand and Forearm, with Surgical
Deductions*

A. Anatomy of the hand.

- I. Methods of study.
- II. Study of serial cross-sections, with particular relation to fascial spaces.
- III. Study of the tendon sheaths in general.
- IV. Study of the fascial spaces and tendon sheaths by means of experimental injections.
- V. Study of x-ray pictures of injected hands.
- VI. Study of the embryology.

B. Anatomy of forearm.

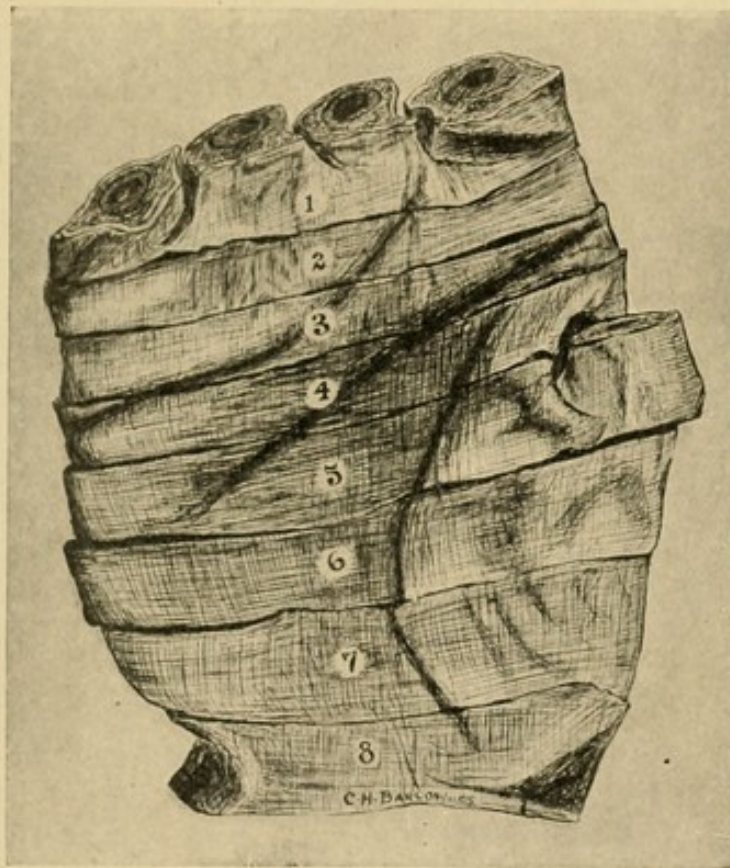
- I. Anatomy in general.
- II. Study of serial cross-sections.
- III. Study by means of injection of the connective-tissue spaces.

METHODS OF STUDY

I. With the object of securing a tentative picture of the spaces and their relation to the tendon sheaths in particular and other structures in general, a freshly amputated cadaver hand was hardened in formalin and cross-sections made, beginning at the middle joints of the fingers, and cutting sections about one centimeter in width, going as high as the elbow. The fascial layers were then teased out and their relations to the muscles, bones, tendons, nerves, and blood-vessels determined. The prolongations of the various spaces were followed up, each space and each tendon sheath being followed from one section to another; thus, their limitations were determined and the relation of the various adjacent structures noted. The specimen chosen was one with but little fat (Fig. 18).

The same process was carried out in a fresh cadaver hand in which the vessels were injected and the sections cut while the hand was frozen. Sections were made of a third hand at right angles to the metacarpal bone of the thumb, since it was found that the findings in the thenar area were somewhat confusing. This hand also was frozen, and, like the first and second, without much fat. By these sections a fairly definite idea of the spaces was secured.

FIG. 18



Drawing made from specimen showing sites of the various sections taken through the hand.

2. To corroborate the findings above, as well as to determine their exact limitations, injections were made into the various fascial spaces, by various channels, and with varying degrees of force. This determined not alone the positions and relations of the pockets, but also by what channels pus could reach them and

where it would extend if it broke through the walls of the closed fascial spaces. By this we also determined the course pus would pursue when it ruptured from the tendon sheaths, and thus fixed the relation of the tendon sheath infections to fascial space infections. The findings were very uniform and satisfactory, with the exception of three or four which did not reach the spaces intended. The material used was such as that ordinarily found in the dissecting room; hence, while the part was always well preserved, in some cases the material was more friable than in others, and, therefore, rupture from the space was more likely to occur. However, this does not interfere with the deductions, since the changes present were, in a measure, comparable to those found in inflammatory processes. Moreover, no matter whether the tissue was fresh or preserved, the findings were the same, so we may feel sure that the results are to be depended upon.

The fascial spaces of 56 hands and forearms were injected from various sites by plaster of Paris, which had been rubbed up with glycerin and diluted with water. It was injected by means of a hand pump through a cannula, which was inserted at various points, as will be noted later. As the hands were dissected, the location and paths of extension of the masses were noted. In those cases injected with moderate force a pressure of 4 to 8 pounds was used, and where forcible injection is noted, 25 to 35 pounds.

3. Several hands were injected as above, except that the injection mass was impregnated with red lead. X-ray pictures were taken. This showed the relation of the theoretical pus accumulations to the bones and bloodvessels, the latter having been injected with the same mass. Again, in other hands, injections of various spaces were made, concomitant with injections of the synovial sheaths, to show their relation and the

proper site for operations designed to open the former without injury to the latter.

4. After this work had been done a study of the embryology was made, with a view of determining whether or not there was any relation between the anatomical peculiarities of the spaces and the embryological development.

5. The clinical cases which came under observation were observed very carefully to see if the real pathology corresponded with the anatomical demonstration. Bacteriological studies of all cases were made, that we might investigate the relation between the variety of germs present and the tendency to spread.

A STUDY OF SERIAL CROSS-SECTIONS, WITH PARTICULAR
RELATION TO THE FASCIAL SPACES

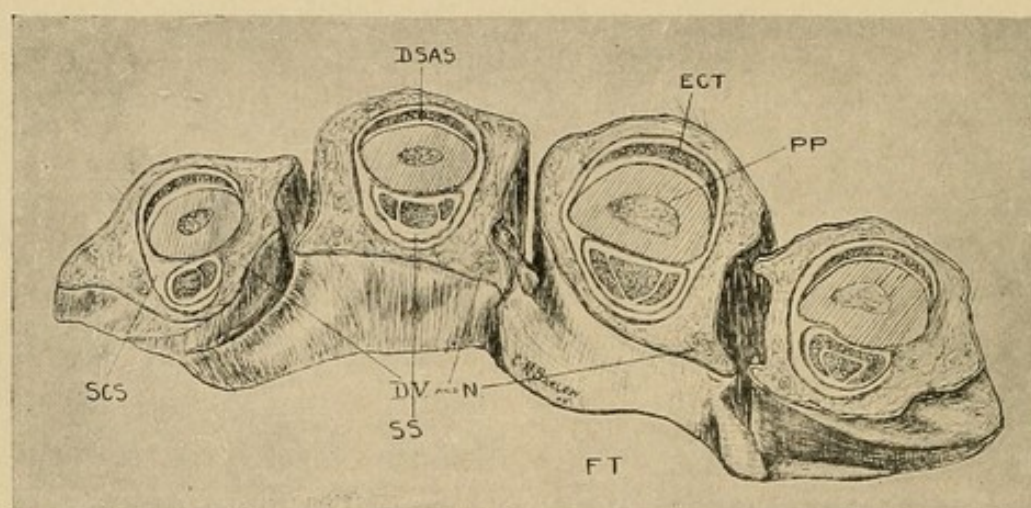
That we may follow the study of the serial cross-sections with more understanding, the following facts should be noted: It is known that five spaces may be found in the hand; the information about them, however, has been very indefinite. The result of our study shows that upon the palmar surface we have three distinct chambers, not communicating in any way with each other, and to these are given the names thenar, hypothenar, and middle palmar spaces respectively. Certain channels will be found which lead directly into them. Certain structures along which pus can pass will be noted lying in juxtaposition. Again, minor anatomical chambers will be noted; these, however, need little or no consideration from a surgical standpoint, since they are unimportant, not likely to become infected separately, and if they do, they will rupture into one of the larger pockets.

Upon the dorsum two areas will be found, in each of which pus can accumulate to the exclusion of the other.

To these are given the names dorsal subcutaneous space and dorsal subaponeurotic space. We shall find that while the pus may lie at various levels in the subcutaneous tissue, from an anatomical standpoint, yet for surgical purposes any subdivision of this space is unnecessary and confusing.

Section I. Beginning with a cross-section which lies just distal to the web of the fingers, we note the following facts: The index finger is slightly different

FIG. 19



Cross-section No. I.—See Fig. 23 for common lettering: *SCS*, subcutaneous space; *PP*, proximal phalanx; *DV* and *N*, digital vessels and nerves.

from the middle and ring fingers in that the space which is most superficial, and which we will call "the subcutaneous space," does not extend around the entire finger, as do the others, but at the radial side the perifascial space tissue is so dense as to obliterate it. It will be noted that this space is deep, and that between it and the skin is to be found considerable tissue which is rather dense and does not lend itself readily to the spread of pus, which in this area is more likely to come to the surface or infect the space above mentioned, where it will have little difficulty in spreading proximally or distally (Fig. 19).

The little finger corresponds with the index finger in that the space is obliterated upon its ulnar side. Between the tendon and the bone in each of the four fingers there is a second space, and to this we will give the name of "dorsal subaponeurotic space of the finger," for upon each side of the tendon a dense sheet of tissue is given off, which unites firmly with the periosteum at each side. Upon the flexor surface are found the flexor tendons in their synovial sheaths, which sheaths are so closely united to the periosteum that no definite free spaces can be found.

The importance of the close attachment of the tendon sheath to the bone will be brought out when discussing tendon-sheath infection in relation to the frequency of osteomyelitis secondary to this trouble.

In my experience the "subcutaneous space" mentioned above is frequently the seat of an abscess, and care should be taken not to mistake it for a tendon-sheath infection.

The spaces above mentioned all pass through this serial section into the next, the second cross-cut being made through the epiphysis of the proximal phalanx.

Section II. In this section the salient points may be pointed out briefly, so that we can retain a composite picture with that which has just been described (Fig. 20).

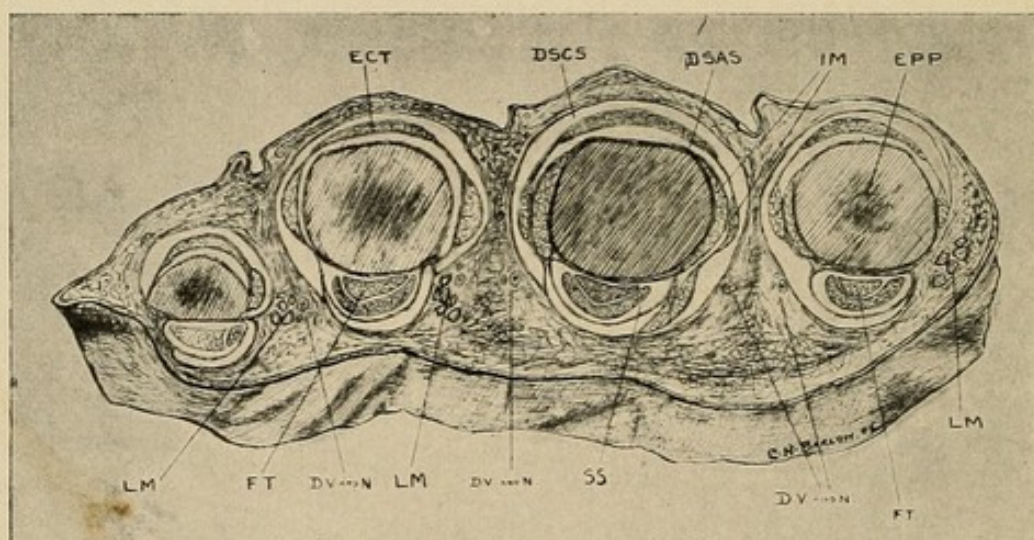
The subcutaneous space is continuous with that in Section I; at the volar side, however, we note a beginning division into two—a palmar and dorsal.

The subaponeurotic space is also continuous, and the interossei muscles (*IM*) begin to appear—one part attached to the periosteum and one part to the dorsal aponeurotic sheet. More important still, we see the beginning of the lumbrical muscles (*LM*), and note particularly the relation of this muscle to the subcutaneous space, especially in the third finger.

The flexor tendons are still covered by their synovial sheaths.

Ask yourself where pus would land if it followed down along the lumbrical muscle from the palm. As we follow these spaces into the next section, we will see that the subcutaneous spaces upon the abutting sides of the fingers merge into each other; that is to say, the subcutaneous spaces of the ulnar side of the index finger and the radial side of the middle finger join at the web, being in close relation to the lumbrical

FIG. 20



Cross-section No. II.—Through epiphysis of proximal phalanx. See Fig. 23 for common lettering: *EPP*, epiphysis proximal phalanx; *DV* and *N*, digital vessels and nerves.

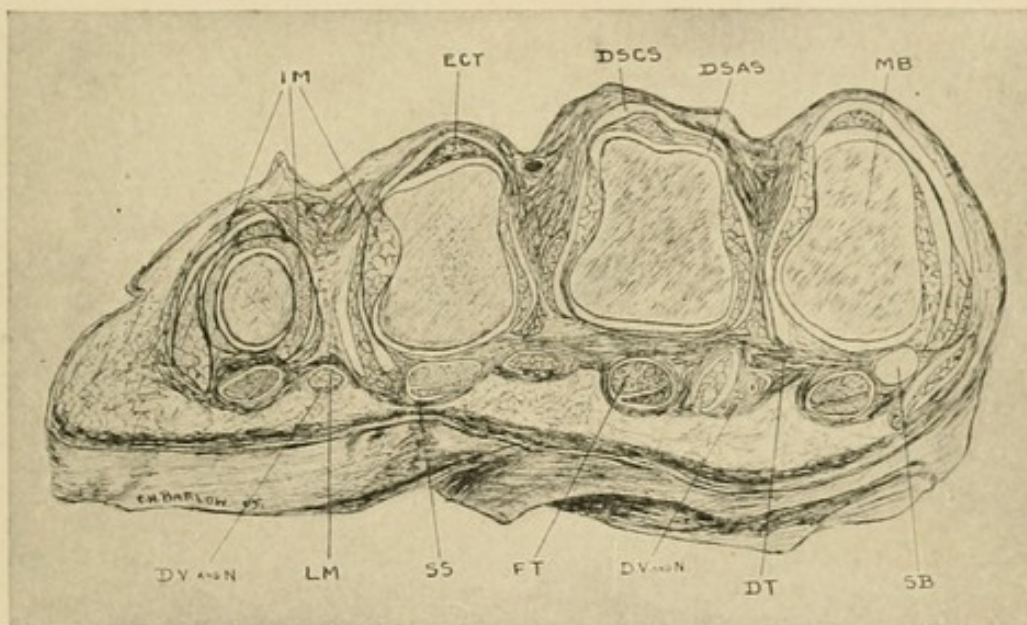
muscles; slightly proximal to this, as will be seen in the next serial section, the space is obliterated between the fingers, and only a small part remains upon the dorsum of each finger. It is in connection with the space about the lumbrical muscle in the palm, however, so that pus may spread from the palm downward into this space and thus point on the dorsum. (For schematic drawing showing this, see p. 427.) The dorsal subaponeurotic space is obliterated in this section, *i. e.*, at the joint.

Section III. The distal surface of the third serial section is seen upon a cut 0.5 cm. proximal to the joint (Fig. 21). Note here:

The absence of the subaponeurotic space, except for small diverticula lying between the two parts of the interossei muscle.

The absence of the subcutaneous space between the fingers. It is continued, however, in the dorsal subcutaneous space (*DSCS*) and the space about the lumbrical muscle (*LM*).

FIG. 21



Cross-section No. III.—Proximal to metacarpophalangeal joint. See Fig. 23 for common lettering: *SB*, sesamoid bone; *DT*, dense fibrous tissue; *DV* and *N*, digital vessels and nerves.

That the lumbrical muscle lies in a sheath of its own, as it were. This communicates with the subcutaneous space of the fingers, and should be followed carefully into the palm.

The dense layer of tissue that crosses the whole section lying around and over the tendon sheaths and under the lumbrical muscle.

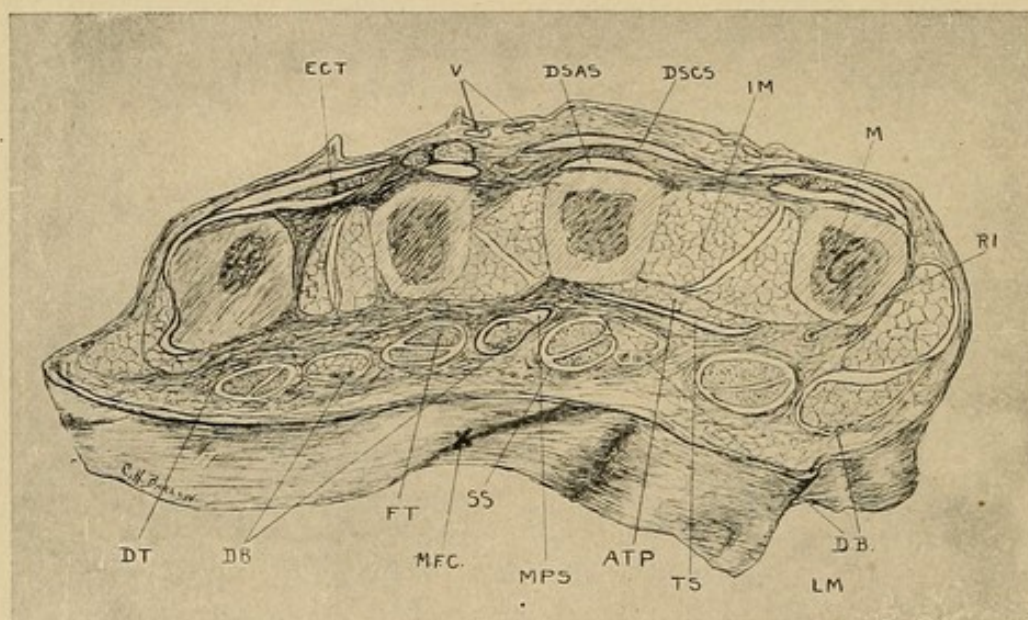
That the flexor tendons are surrounded by their sheaths.

The spaces are all obliterated in passing either through this section or the previous one, except the synovial space about the flexor tendons, that about the lumbrical muscles, and the slight channel on the dorsum, above noted, passing between the subcutaneous tissue of the finger and the hand.

The surgical application of this will be brought out later.

Section IV. The fourth cross-section lies two centimeters above the joint (Fig. 22).

FIG. 22



Cross-section No. IV.—Two cm. proximal to joint. See Fig. 23 for common lettering: *MFC*, middle flexion crease; *DV* and *N*, digital vessels and nerves; *RI*, radial interosseus.

The dorsal subaponeurotic spaces, which were obliterated at the joint, are beginning again between each tendon and the corresponding bone.

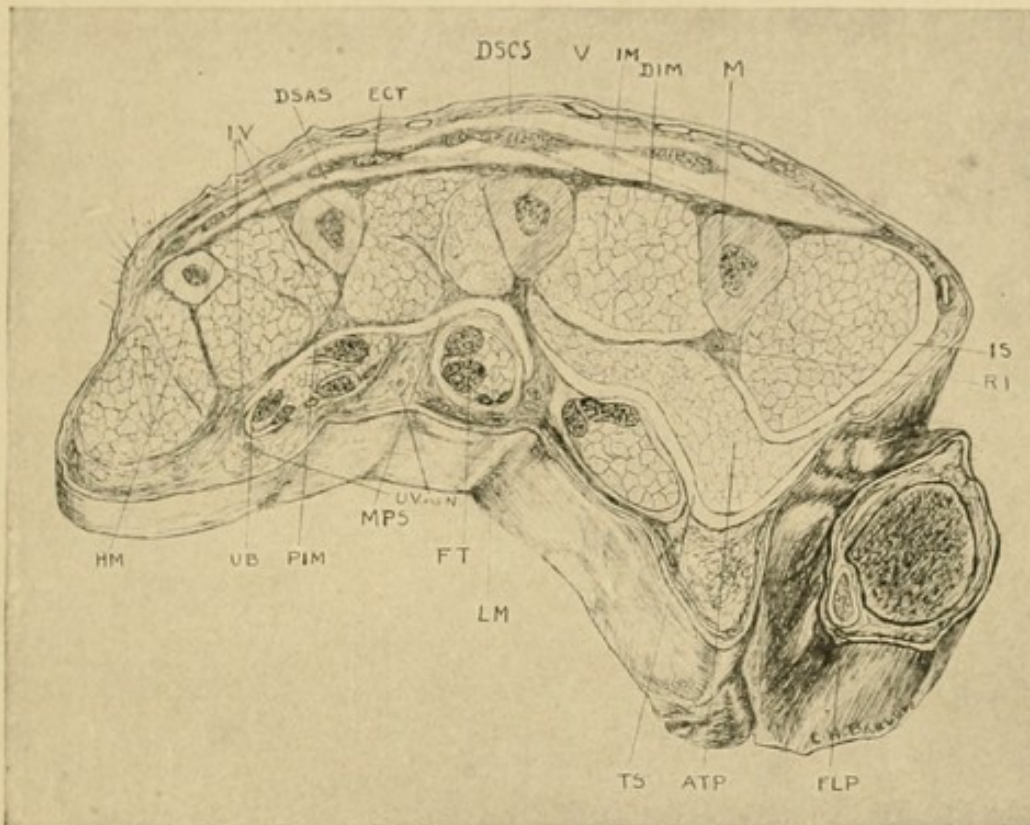
The dorsal subcutaneous spaces approximate each other.

The palmar tissue is still dense, with no free passages except those about the lumbrical muscles and those along the sheaths of the tendons which are still present,

but begin to be obliterated as they pass through this serial section.

As yet no space has appeared into which pus would extend if it were to pass proximally along these syno-

FIG. 23



Cross-section No. V.— $3\frac{1}{2}$ cm. proximal to joint. Lettering common to all plates: SS, synovial sheath; DSCS, dorsal subcutaneous space; DSAS, dorsal subaponeurotic space; ECT, extensor communis tendon; FT, flexor tendon; LM, lumbrical muscle; IM, interossei muscles; M, metacarpal bone; BV, bloodvessels; N, nerves; TS, thenar space; MPS, middle palmar space; ATP, adductor transversus pollicis; DIM, dorsal interosseous membrane; PIM, palmar interosseous membrane; UB, ulnar bursa; IS, space between adductor transversus and first dorsal interosseous; DIM, dorsal interosseous membrane; FLP, flexor longus pollicis in its synovial sheath; HM, hypothenar muscles with intermuscular spaces; IV, interosseous vessels and nerve.

vial sheaths. We note, however, that a small space has appeared just above the small piece of abductor transversus muscle, which will become the thenar space (TS).

Now let us imagine ourselves following through this serial section into the next. The free, open spaces of the hand appear suddenly, the synovial sheaths of the tendons become obliterated after entering them, the lumbrical muscles join the tendons, and the adductor transversus, which is the keynote to the thenar space, begins to assume its characteristic relations.

Section V. If we cut across about three centimeters above the joint, we find the following, which is well represented in the cut (Fig. 23).

THE MIDDLE PALMAR SPACE

There is a large, free space with few fibrous septa extending from the middle metacarpal bone to the radial side of the metacarpal bone of the little finger. It is bounded dorsally by a thin fibrous sheet which overlies the anterior interosseous membrane and the interossei muscles; upon its palmar side is a second thin sheet separating it from the tendons and the lumbrical muscles of the little and ring fingers. The space is limited upon its ulnar side by dense, fibrous tissue; and upon its radial side by a dense, fibrous sheet which lies over the adductor transversus. This space is probably the most important in the hand, and to it is given the name of "Middle Palmar Space."

If we were to note the layers of tissue through the middle of the hand, going from the palm to the dorsum, they would be as follows:

1. Epidermis.
2. Derma.
3. Firmly meshed subdermal connective tissue.
4. Palmar aponeurosis.
5. Loose mesh of connective tissue, in which lie (a) vessels; (b) tendons with lumbrical muscles, or endings of the synovial sheaths.

6. Anterior middle palmar sheet.
7. *Middle Palmar Space.*
8. Posterior middle palmar sheet.
9. Vessels.
10. Palmar interosseous membrane, extending from bone to bone.
11. Interossei muscles.
12. Posterior interosseous membrane.
13. Dorsal subaponeurotic space filled with thin meshed connective tissue and vessels.
14. Dorsal aponeurosis and tendons.
15. Dorsal subcutaneous space, with loose connective tissue.
16. Derma.
17. Epidermis.

THE THENAR SPACE

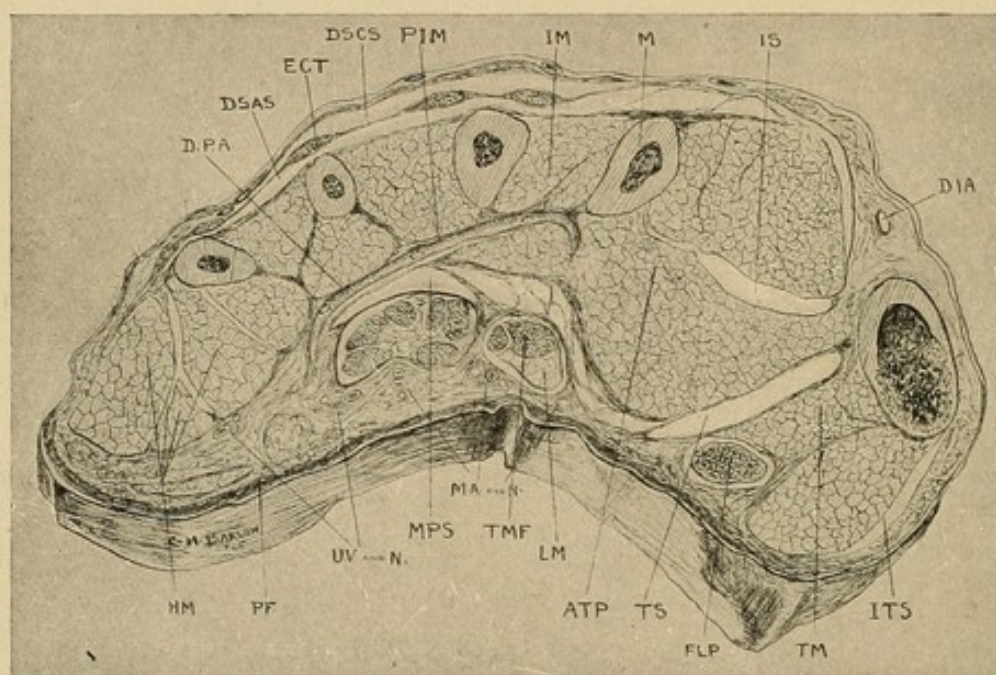
Upon the radial side we note the large mass of the adductor transversus, and upon its palmar side is shown a large space extending from the metacarpal bone of the middle finger over the muscle to the radial side of the hand, stopping, however, at the middle of the radial side, at about the level of the palmar surface of the bones; or, in other words, being L-shaped in cross-section. It will be seen later that this limitation is of importance, since it prevents injection masses from passing freely to the dorsum of the hand, or *vice versa*. This space is known as the "Thenar Space." Upon its palmar side there is a strong layer of tissue, blending into the dense tissue of the palm, and between this dense palmar tissue and the space lie the tendon and lumbrical muscle of the index finger. Over the adductor muscle is a thin layer of tissue or perimuscular sheath.

The middle palmar and thenar spaces are the two most important spaces in the hand, and it is well to

note their relations to each other and to adjacent structures. They will be taken up later, and a composite picture made from the fragmentary description noted here and in the following serial sections.

Upon the dorsum the dorsal subcutaneous and sub-aponeurotic spaces are well shown.

FIG. 24



Cross-section No. VI.—Through distal part of thenar area. See Fig. 23 for common lettering: *ITS*, indefinite thenar spaces; *TMF*, tendon of middle finger; *TM*, thenar muscles; *PF*, palmar fascia; *RA*, radial artery; *DPA*, deep palmar arch—digital branches beginning; *DIA*, dorsalis indicis artery.

The synovial sheaths have entirely disappeared except for a small prolongation along the little finger tendon (*UB*) and that about the flexor longus pollicis (*FLP*). The tendon sheaths of the three tendons were obliterated while passing through this section. The ulnar bursa (*UB*), however, is seen to lie in juxtaposition to the middle palmar space as do the tendon sheaths of the middle and ring finger distal to this section. The tendon sheath of the index finger is in close connection with the thenar space (*TS*).

Section VI (Fig. 24). This serial section is taken through the distal part of the thenar eminence, and thus shows the metacarpal bone of the thumb in cross-section. Here we note the great relative size of the thenar space (*TS*), and yet it is all upon the radial side of the middle metacarpal. The lumbrical muscle and index tendon are separated from it by a much thinner septum than in the previous section. The tendon of the flexor longus pollicis appears here surrounded by its synovial sheath.

The middle palmar space is much smaller and still lies under the group of tendons of the middle, ring, and little fingers. Upon the ulnar side of this group we see the ulnar synovial bursa in juxtaposition to the space, yet the septum between them must be strong, since the injection masses in this bursa, noted later, have a greater tendency to rupture into the forearm than into this space.

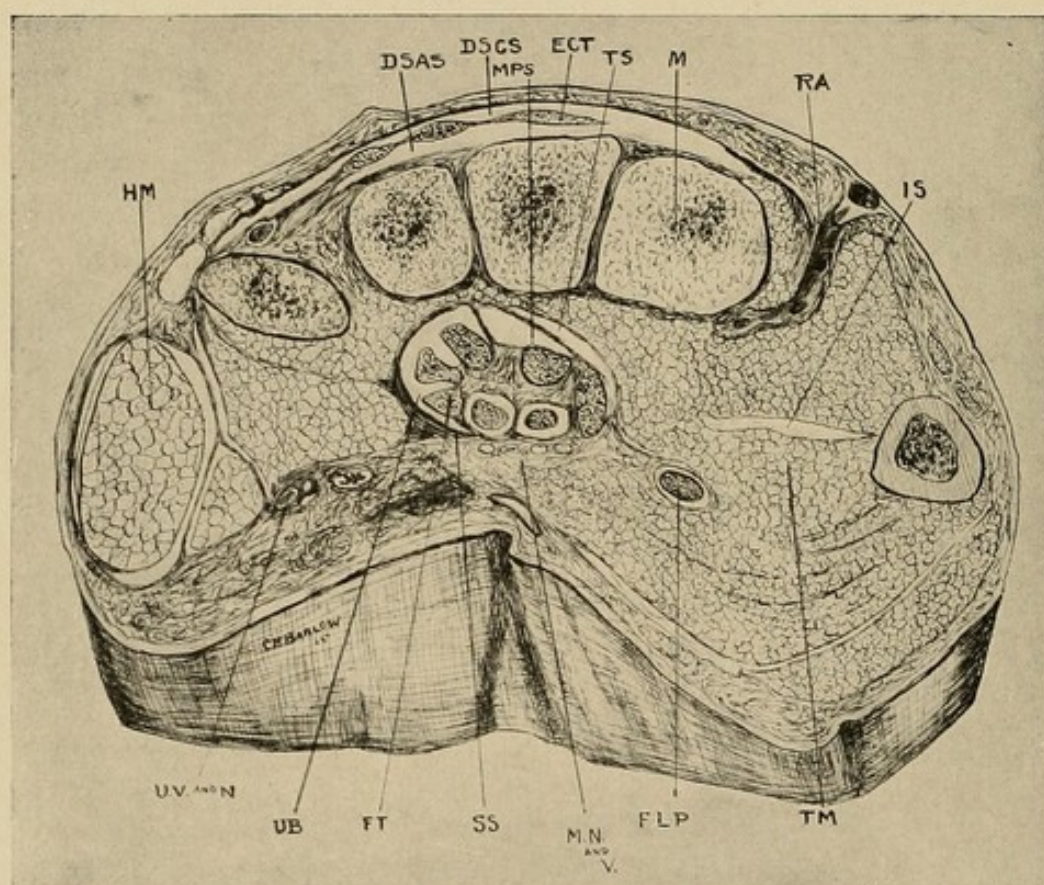
Upon the dorsum we still find our subaponeurotic and subcutaneous spaces, while over the thenar area the subcutaneous tissue is also lax, and either of the two former spaces can be made to communicate with it.

The deep palmar arch (*DPA*) appears in this section, and its relation to the middle palmar space and the synovial sheath should be noted. We see that there is not much danger of injuring it if care is taken in operating.

In the cases examined the flexor longus pollicis with its tendon sheath is separated from the thenar space by a considerable amount of tissue, and while rupture from it into the space is possible (particularly in those cases accompanied by inflammatory destruction), yet it would be more likely to rupture at the upper end of the synovial sac into the cellular tissue of the forearm. Experimental evidence to support this will be brought forward later (see pp. 125 and 126).

Section VII (Fig. 25). In the seventh section, taken through the base of the palm, the middle palmar space and the thenar space are seen to have shrunk into insignificance. They lie close together under the group of tendons, the middle palmar space being more superficial. They are still separated by a thin sheet, however, in those specimens examined.

FIG. 25



Cross-section No. VII.—See Fig. 23 for common lettering: *RV* and *N*, radial vessels and nerve; *MN* and *V*, median nerve and vessels; *UV* and *N*, ulnar vessels and nerve.

One or two indefinite spaces are present about the thenar region. They are of little importance, however, except to note that they are present between the groups of muscles, and localized infection can occur in them under exceptional circumstances.

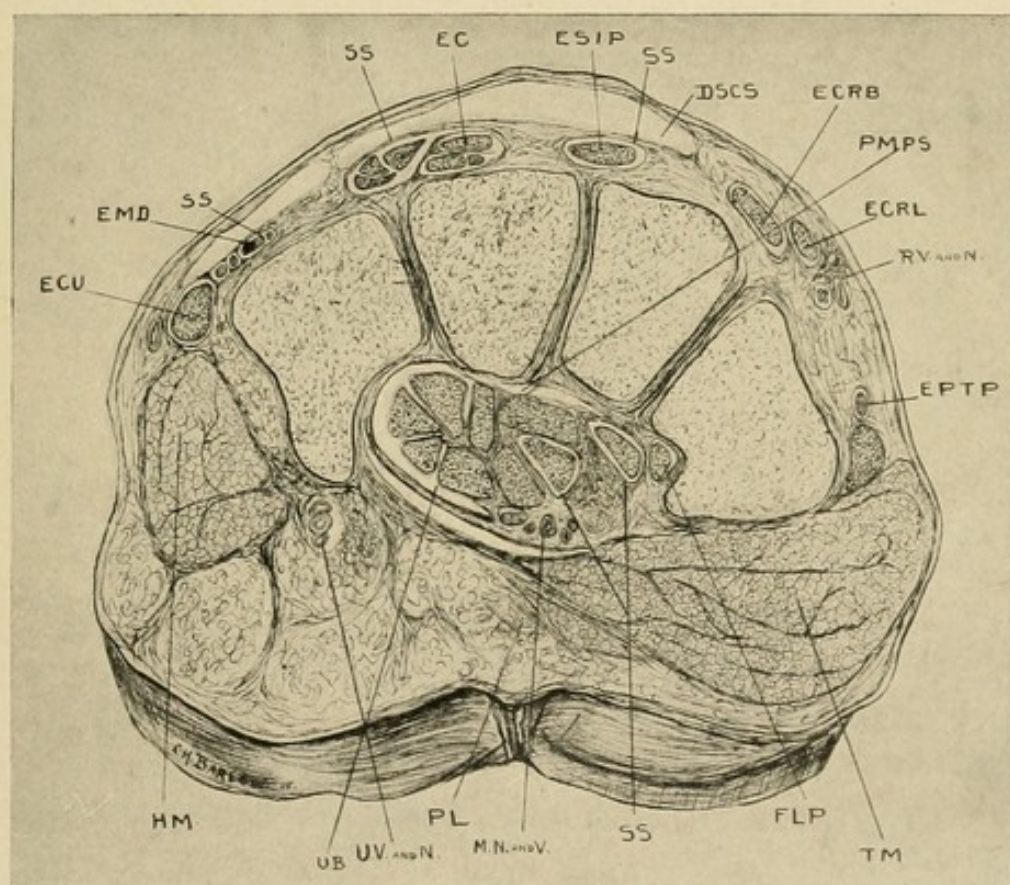
The dorsal spaces remain the same, except that the subaponeurotic is more constricted.

The tendon sheaths are seen in four places—the ulnar bursa (*UB*), the sheath about the flexor longus pollicis (*FLP*), and the two intermediate sheaths about the superficial tendons in juxtaposition to the ulnar bursa. These will be discussed later (see pp. 107 and 109).

THE HYPOTHENAR SPACE

Nothing as yet has been said of the hypthenar area, since it was desirable to avoid confusion. However,

FIG. 26



Cross-section No. VIII.—See Fig. 23 for common lettering: *RV* and *N*, radial vessels and nerves; *MN* and *V*, median nerve and vessels; *UV* and *N*, ulnar vessels and nerves; *PMPS*, prolongation of middle palmar space.

a glance at this section, and at those which have preceded, shows very clearly that while it is possible for

pus to accumulate in the intermuscular septa of this space, yet it would be absolutely localized here, and would spread to the surface. It would not enter either the middle palmar space or the ulnar synovial bursa. Such infections would be of little surgical interest, owing to their localized nature.

Section VIII (Fig. 26). In the eighth section, taken at the wrist, the middle palmar and thenar spaces can still be found, but they are so small as to be of little practical importance, since any inflammation in them would probably be followed by closure. Their behavior under forcible injection will be noted later.

While it might be possible by forcible dissection to produce a dorsal subaponeurotic space, yet it should not be described as being present.

The dorsal subcutaneous space can be demonstrated, but it is more difficult to do so here than in the previous sections, since more of the fibers tend to intermingle from layer to layer.

The synovial sheaths about the dorsal tendons also appear in this section.

DISCUSSION OF THE RELATIONS OF THE MIDDLE PALMAR AND THENAR SPACES

The inter-relation of the middle palmar and thenar spaces is of very great interest to the surgeon, and to understand it the roof and floor of the two spaces must be discussed together. They are separated from each other at the middle metacarpal bone by firm septa, so that neither one communicates with the other, nor does either overlap to the other side of this bone. The tendons of the third and fourth fingers, with their lumbrical muscles, lie just above the middle palmar space, separated from it by only a thin, indefinite membrane, while upon the palmar side of this group

are a few indefinite spaces; but pus must pass around the tendons to their dorsal surface and rupture into the middle palmar space, since in every other direction firm tissue is found. Such a course might be followed in an infection passing upward along the lumbrical muscles. If it follows along the synovial sheath of the ring finger, and finally ruptures from the proximal blind end, it will pass ultimately into this space. The same holds true for the tendon sheath of the little finger in those cases in which it is separated from the ulnar bursa. To the ulnar side of the tendon of the little finger is seen the small synovial space representing the continuation of the synovial sheath of the little finger into the synovial sheath of the tendons above, known as the ulnar bursa.

It will be seen that the lumbrical muscle and tendon of the index finger occupy the same relative position to the thenar space that the third and fourth do to the middle palmar space, with this exception, that in those hands which have been examined the sheet of tissue separating it from the thenar space is somewhat firmer; still, it is not so dense as that upon the other three sides, and here also, then, it must communicate with the space below it.

The lumbrical muscle and tendon of the middle finger in Section VI occupy an intermediary place between the two spaces, but in the previous section they will be seen to lie over the middle palmar space, at which site the enveloping fascia is much thinner, so that we would have reason to believe, from an anatomical standpoint, that pus spreading along this tendon would communicate more easily with the middle palmar space, and experimental injections of the synovial sheath substantiate this reasoning.

We have now discussed all of the relations of these spaces except the floor, or dorsal surface, and the

proximal prolongation. The latter we will speak of in the chapter dealing with anatomy of the forearm. Concerning the floor, however, it is well to mention several things. Owing to the closed nature of these pockets, it is customary for clinicians to draw attention to the frequency of rupture from them, through between the bones, to the dorsal surface.

In the middle palmar space the floor is composed of a very thin fascial layer, through which pus could rupture easily, were it not for the support given it by the interossei muscles and the interosseous membrane, upon which it lies. Should inflammatory destruction of this sheet arise, however, or rupture ensue, the interossei muscles would still offer a slight resistance, for there is no distinct channel leading to the dorsum, although the intermuscular septa do tend in that direction. Having come through these, however, the pus would then meet the septum passing from one bone to the other upon the dorsal surface of the interossei muscles. If the pus meets and overcomes the various obstructions, which it might do in chronic and exceptional cases, it would then lie beneath the tendons upon the dorsal surface, or in the dorsal subaponeurotic space.

Now let us go back to the thenar space and its floor, or dorsal wall. This is slightly more complex, in that the muscular masses making up the floor confuse us. For the most part it is made up of the adductor transversus and the adductor obliquus, and in those cases where there is little tension upon the contents it would be limited dorsally by them and the thin sheet of fascia over the muscles. Upon the other hand, if the tension were increased, it would be very easy for the contents of the cavity to pass between these muscles and come to lie upon the dorsal surface of the adductor transversus. That is to say, it would come

against the first dorsal interosseous upon the dorsum of the thenar region about on a level with the metacarpophalangeal joint of the thumb, and thus, if there were any inflammatory action present, spread to the cutaneous tissue at the web; or, if the dorsal interosseous muscle were unimportant, in the dorsal subcutaneous tissue of the thenar region. Experimental evidence will be adduced later to prove this can occur.

RECAPITULATION

We note that we have six important fascial spaces with their tributaries in which pus can accumulate.

1. The dorsal subcutaneous, which is an extensive area of loose tissue, without definite boundaries, allowing pus to spread over the entire dorsum of the hand.

2. The dorsal subaponeurotic, limited upon its subcutaneous side by the dense tendinous aponeurosis of the extensor tendons, upon the deep side by the metacarpal bones, having the shape of a truncated cone, with the smaller end at the wrist and the broader at the knuckle. Laterally the aponeurotic sheet shades off into the subcutaneous tissue.

3. The hypothenar area, a distinctly localized space.

4. The thenar space, occupying, approximately, the area of the thenar eminence. Superficially its internal boundary is indicated by the adduction crease of the thumb. It lies entirely upon the radial side of the middle metacarpal. It should be remembered that this space lies deep in the palm, just above the adductor transversus.

5. The middle palmar space, with its three diverticula below along the lumbrical muscles, limited by the middle metacarpal bone upon the radial side, overlapped by the ulnar bursa upon the ulnar side, and

separated from the thenar space by a partition which is very firm everywhere except at the proximal end, where it is rather thin. A small isthmus can be found leading from the proximal end of the space under the tendons and ulnar bursa at the wrist into the forearm.

6. The web space, an area of loose connective tissue between the bases of the fingers, with prolongations distally into the subcutaneous tissue at the sides of the fingers, and proximally into the subcutaneous tissue of the dorsum on the dorsal surface and into the connective-tissue spaces around the lumbrical muscle on the palmar surface. The corroboration of our statement as to the outlines of these spaces will be brought out in the chapter upon experimental injections (Chapter IX).

CHAPTER VIII

THE TENDON SHEATHS: A DISCUSSION OF THEIR ANATOMICAL DISTRIBUTION AND RELATIONS, WITH SURGICAL DEDUCTIONS

FROM a consideration of the cross-sections we have described in the previous chapters it is possible to give a composite picture of the various tendon sheaths from an anatomical and surgical standpoint. In the following description the well-known anatomical points which have no bearing on the subject in hand will not be dealt with. It is my intention to emphasize those facts which will aid us in understanding the course an infection will pursue, and will point to the proper course of treatment. Therefore, before reading this one should have a clear conception of the anatomy of the six fascial spaces described in the previous chapter.

The particular relation of the sheaths to the six fascial spaces will be emphasized in the chapter dealing with experimental injections (Chapter IX). These will also serve to corroborate the anatomical statements made here.

SHEATHS UPON THE FLEXOR SURFACE

From a surgical standpoint, the sheaths upon the flexor surface are the most important. The anatomy of these may be discussed under four heads: (1) The tendon sheaths for the index, middle, and ring fingers; (2) the tendon sheath for the thumb with its prolongation in the hand (radial bursa); (3) the tendon sheath of the little finger and its prolongation in the palm (ulnar bursa); (4) the communications between these various sheaths.

THE SHEATHS OF THE INDEX, MIDDLE, AND RING FINGERS

These begin just distal to the distal interphalangeal joint and extend into the palm, approximately a thumb's breadth proximal to the web; or the point of extension can be designated by drawing a line between the end of the proximal palmar crease at the base of the index finger and the end of the distal palmar crease at the base of the little finger. This line represents the approximate extension of these sheaths into the palm. It will be seen by noting Fig. 22 that at the distal portion of the palm there is a sheet of dense tissue enclosing the tendon sheaths and lumbrical muscles. The sheaths extend one-fourth inch proximal to this into the loose palmar tissue. This fact is of considerable importance from a surgical standpoint (see pp. 117 and 168).

While passing through the dense tissue mentioned above, these sheaths have on either side the space called the lumbrical canal, through which pass the lumbrical muscles and digital branches of the arteries and nerves (Fig. 21). This is also of surgical importance (see pp. 177 and 208).

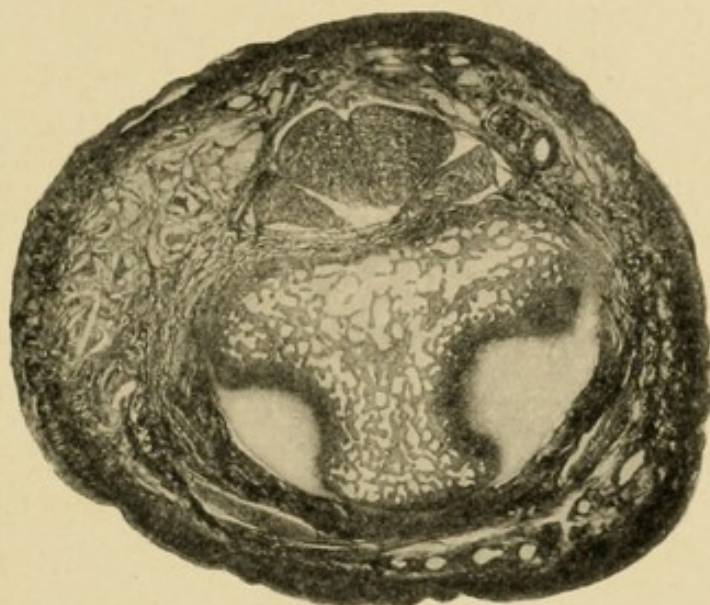
As we pass distally, we find considerable tissue between the metacarpophalangeal joint and the sheath proper, while more distally, as we come to the base of the proximal phalanx, we note that the sheath approaches the bone and is in close relation with the loose connective tissue going entirely around the bone. The surgical importance of this will be brought out later.

At the proximal interphalangeal joint (Fig. 119) we find considerable tissue between the sheath and the joint, while over the base of the middle phalanx, *i. e.*, at the epiphyseal line (Fig. 27), there is little or no

tissue between the sheath and the bone. From this point distally the relation to the bone is not so intimate. At the distal end the relation of the structures can be seen by studying Fig. 2. (For surgical application, see p. 164 and Chapter XXVIII.)

These sheaths bear almost the same relation to the respective fingers. They do differ slightly in their relation to the palm of the hand as I pointed out in Chapter VII. The proximal end of the sheath for the

FIG. 27



Cross-section through the epiphysis of the middle phalanx. Notice the loose mesh and the small amount of connective tissue between the tendon and the bone.

index finger is in relation to the thenar space, while that of the middle finger is most often in relation to the middle palmar space, although at times it will allow of rupture into the thenar space, possibly through rupture into the lumbrical space between the index and middle finger and thence into the thenar space. However, this lumbrical space itself most often leads into the middle palmar space. The tendon sheaths of the ring finger and of the little finger are in relation to the middle palmar space.

THE RADIAL BURSA AND THE TENDON SHEATH OF THE FLEXOR
LONGUS POLLICIS

This is of great importance from a surgical standpoint, owing to the fact that in youth and adult life the sheath nearly always communicates with the enlarged sac of the tendon sheath at the wrist (19 in 20 cases, Poirier). The entire sheath has been given the name of radial bursa, although technically speaking it should be applied to only the proximal part at the wrist.

The sheath begins distally at the base of the distal phalanx and extends proximally a thumb's breadth proximal to the anterior annular ligament. It lies first in close proximity to the proximal phalanx, but at the distal end of the metacarpal bone becomes separated from the bone by the muscles of the thumb lying between the outer head of the flexor brevis pollicis and the adductor obliquus pollicis (Figs. 24 and 25). At times (1 to 20, Poirier) there is a separation of the sheath into two parts at about the middle of the metacarpal bone. This is frequently only a thin diaphragm. The sheath is generally well separated by connective tissue from the metacarpophalangeal joint and an infection may spread from the joint to the sheath, or *vice versa*, but either is uncommon. It lies superficial to the proximal end of the thenar space, in juxtaposition to the flexor tendons in the carpal canal (Fig. 24) and passes upward to terminate about an inch above the annular ligament by a rounded cul-de-sac extending under the deep surface of the tendon, corresponding to the radio-carpal joint and the lower end of the radius, lying on the pronator quadratus.

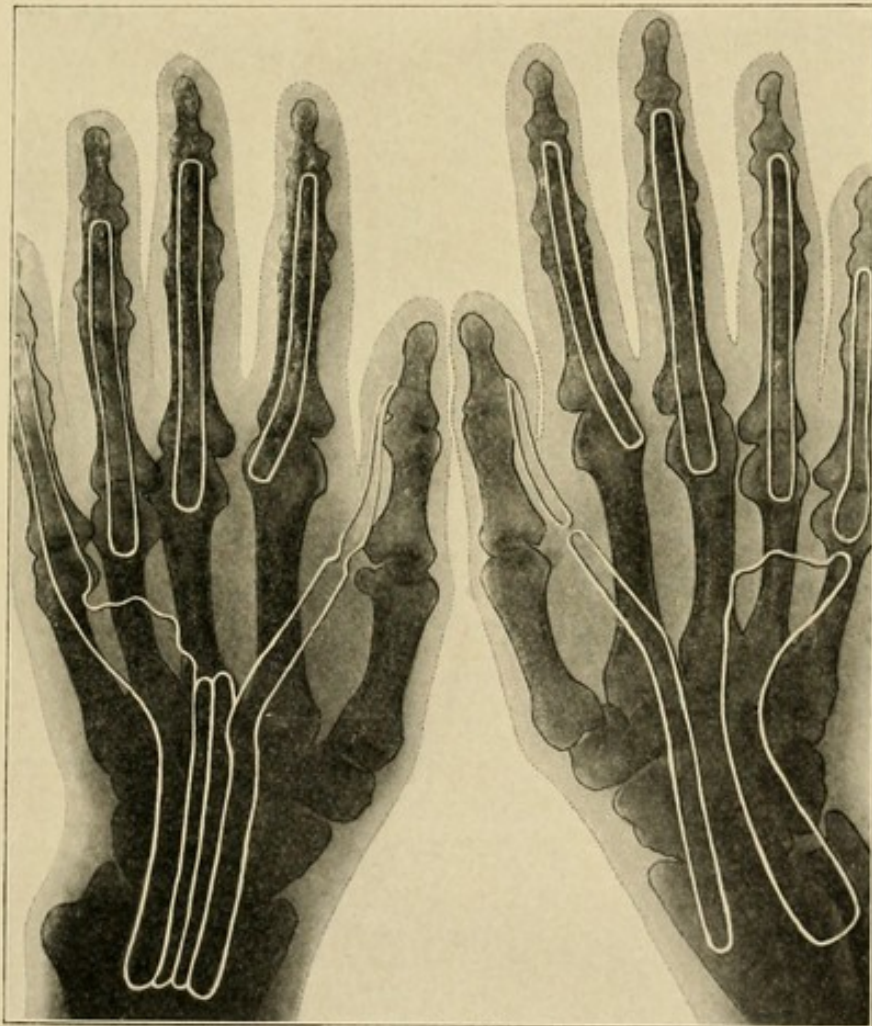
The communication between this and the ulnar bursa will be discussed later. The motor nerve to the thenar

muscle lies within a finger's breadth distal to the annular ligament and superficial to the sheath (see p. 109).

THE ULNAR BURSA AND THE SHEATH OF THE TENDON OF THE
LITTLE FINGER

The tendon sheath of the flexor tendon of the little finger communicates freely with the ulnar bursa in

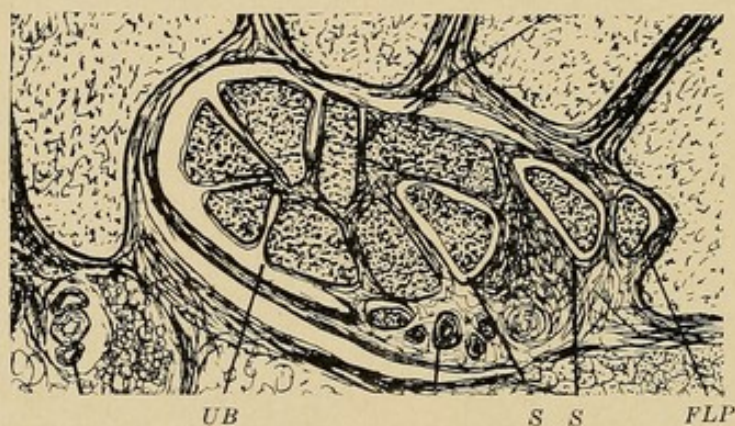
FIG. 28



X-ray picture upon which are shown two types seen in the flexor tendon sheaths. Note that in the hand upon the left side there is a continuation between the little finger and the thumb and the ulnar bursa and radial bursa respectively. Note also the connecting sheaths between. In the hand upon the right side the sheaths are separated, not alone from their respective fingers, but from each other.

about one-half of the cases according to Poirier, but statistics vary somewhat on this point. When the separation is present it is of any grade, from a simple narrowing to a complete occlusion some millimeters in length. In these cases the sheath corresponds in length to those of the other fingers. Also the relations to the joints and spaces are the same except that there is no lumbrical canal upon the ulnar side of the proximal end. The sheath extends into the middle palmar space, and the lumbrical canal upon its radial side

FIG. 29



Showing the relation of the tendons and synovial sheaths at the wrist. Note in this drawing the four pockets in the ulnar bursa instead of three as commonly described; also the tendon sheath of the flexor longus pollicis and the accessory synovial sheaths (SS). See text for description of the difference between the relations of the tendons shown in Figs. 25 and 29.

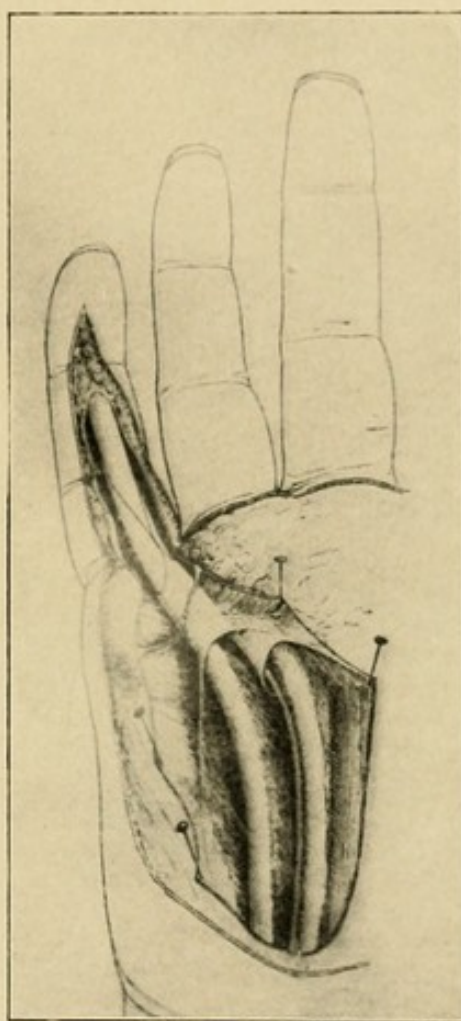
communicates with the same area. In this relation it should be remembered that these muscles do not lead into the thenar and middle palmar spaces directly, but lie just superficial to them, in a loft, as it were, from which pus easily extends into the spaces.

The ulnar bursa proper (Fig. 28) begins at the proximal end of the finger sheath, spreads out rapidly, and becomes a good-sized sac overlapping the metacarpal of the ring finger and the head of the middle metacarpal, passes under the anterior annular ligament and extends a thumb's breadth above this, lying in

relation to the lower end of the ulna and the ulnar side of the carpus and the radio-ulnar articulation, lying upon the pronator quadratus. It does not surround the tendons as a whole, but lies to the ulnar side of the group of superficial and deep flexors and only envelops them as if they were pushed in along the outside. It follows, then, that the ulnar side of the sac is free while the radial side envelops the tendons, forming three spaces or arches, as it were, the most superficial between the aponeurosis and the superficial tendons, the middle between the superficial and deep tendons, and the third between the deep tendons and the carpal canal (Figs. 25, 29, and 30). These all open upon the ulnar side into a common space. This arrangement, first drawn attention to by Leguey, I believe, is in general true, but the arrangement varies at different levels and in different individuals, as can be seen by examining Fig.

29, where there are four pockets, and none of them very deep. Moreover, the tendons upon the radial side frequently have sheaths separate from the ulnar bursa, as will be mentioned under our fourth caption,

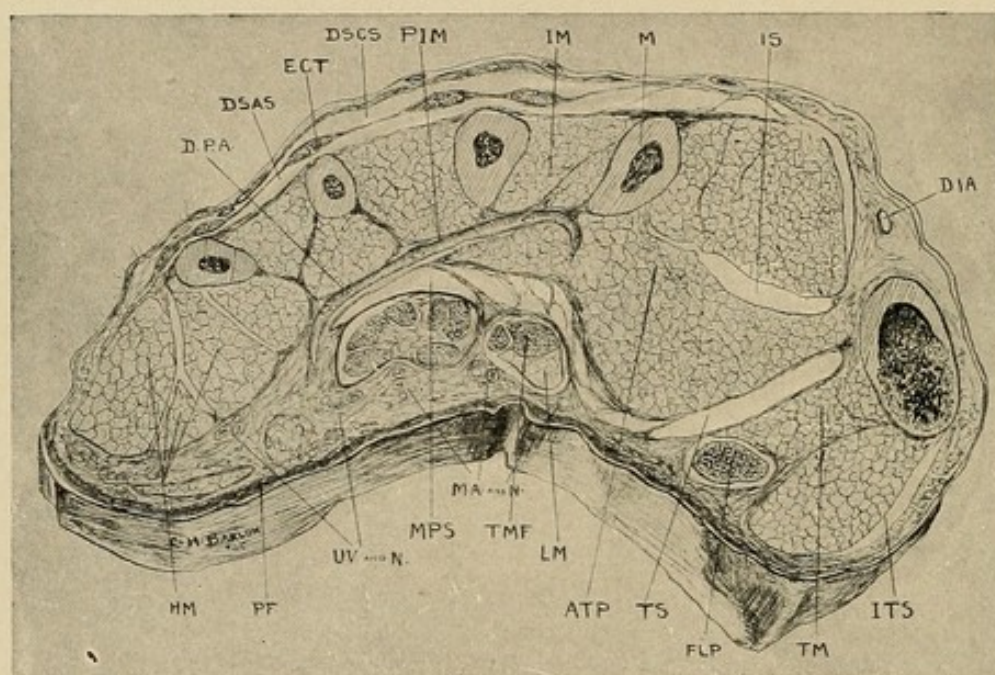
FIG. 30



Photograph after Poirier, in which the ulnar bursa has been opened, showing its extension into the little finger and its closure about the tendon of the ring finger.

"The Intercommunication of the Sheaths." Attention should also be drawn to the fact that the superficial palmar arch with some of the unimportant branches of the ulnar nerve lies superficial to the sheath. More important, however, is the fact that the sheath overlies the middle palmar space, making part of its roof, as it were (Fig. 31).

FIG. 31



Cross-section No. VI.—Through distal part of thenar area. See Fig. 23 for common lettering: *ITS*, indefinite thenar spaces; *TMF*, tendon of middle finger; *TM*, thenar muscles; *PF*, palmar fascia; *RA*, radial artery; *DPA*, deep palmar arch—digital branches beginning; *DIA*, dorsalis indicis artery.

Above the anterior annular ligament it is well to note that the tendons of the palmaris longus and the flexor carpi radialis lie above the radial bursa, and that by drawing the tendon of the flexor carpi radialis to the radial side one can come down directly upon the flexor longus pollicis and its sheath. Attention should likewise be drawn to the fact that the median nerve lies between the two bursæ and somewhat deeply.

THE INTERCOMMUNICATION OF THE SHEATHS

Poirier¹ discusses the communication between the bursæ as follows:

"The synovial sheaths of the palm have no communication with each other, and the authors cite in proof of this the case of Gosselin, who had observed it only once. However, the result of my observation has been that this communication between the two important sheaths is very frequent in the adult. It is found in about half of the cases. The connection is made by a median synovial sheath which I will describe.

"Accessory synovial sacs: The writers call attention to the occasional existence of synovial sheaths in addition to the two large synovial sheaths, which they call accessory sheaths, and are found at times along the flexor tendons of the index finger. They lie between the ulnar and radial bursæ, being found especially along the deep tendon. My researches show that these synovial sheaths are two in number. They ought not to be called accessory, since one of these is almost always present. I have named them the intermediary anterior and posterior palmar synovial sheaths.

"The intermediary posterior palmar sheath: This should be described as a normal sheath, since one finds it about eight times out of ten. It lies between the carpal canal and the flexor profundus of the index finger, and commences above the wrist at the edge of the radius. It spreads out at the level of the upper border of the semilunar bone and goes down more or less on the tendon of the flexor profundus, varying from 3 to 8 cm. To see it, it is necessary to cut transversely across the mass of muscles and tendons in

¹ P. Poirier et A. Charpy, *Traité d'Anatomie Humaine*, Tome ii, S. 189.

the lower third of the forearm and turn the distal end down toward the fingers. It is by the intervention of this sheath that the ulnar and radial bursæ communicate ordinarily.

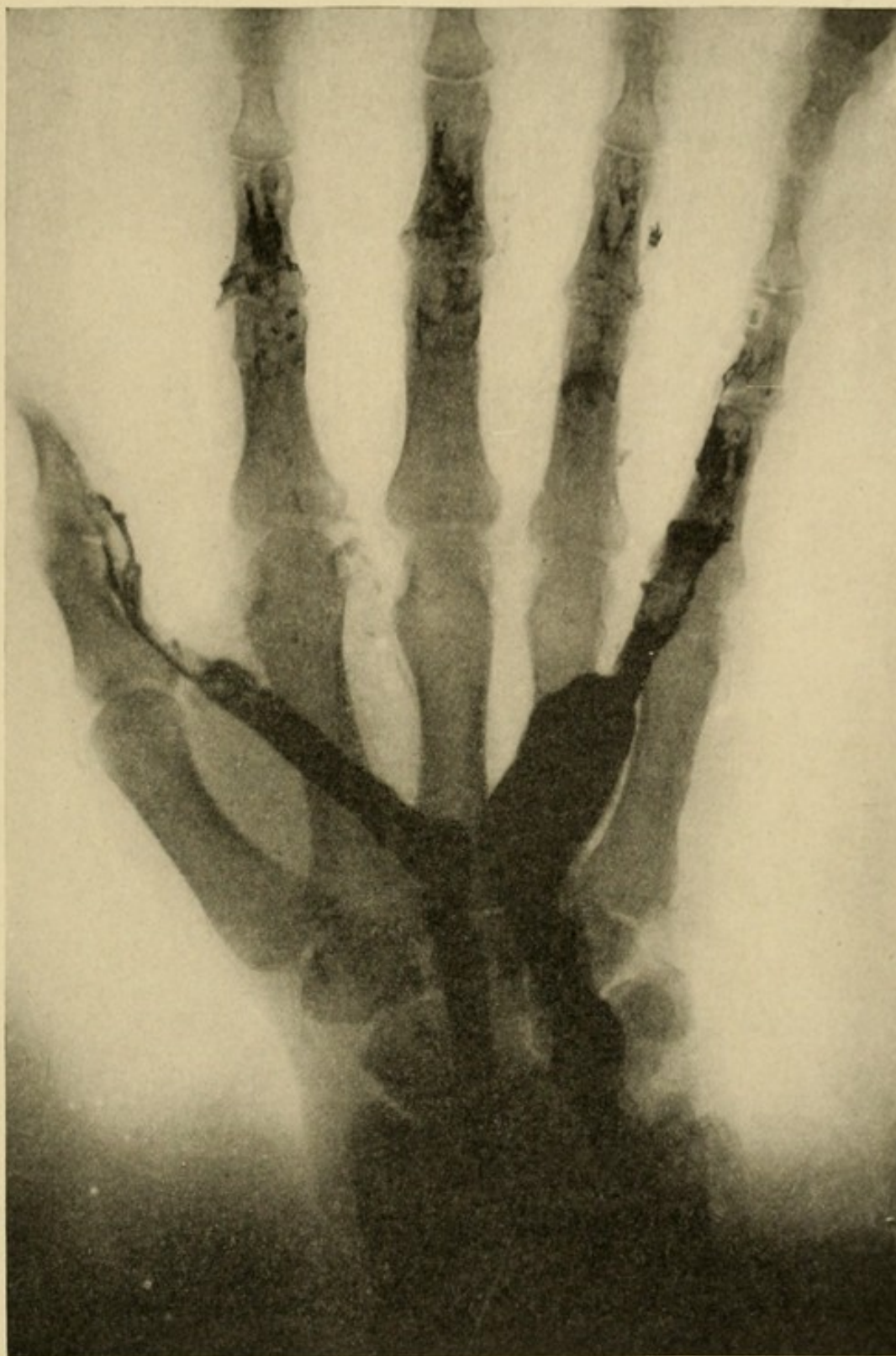"The anterior intermediary palmar sheath: This is found in hardly half of the cases. Much smaller than the preceding, it is found placed between the superficial and deep tendons of the index finger.

"Both of these appear later than the others, and it is very rare to find them as completely organized. In general, their walls lack the moist glassiness characteristic of complete development."

It is said¹ also that the synovial sheaths of the ring, middle, and index fingers communicate exceptionally with the ulnar bursa, following their respective tendons, occurring in the order of frequency as the fingers are named above. Again, attention should be drawn to the fact that the intermediary sheaths may differ from that type mentioned by Poirier. I have dissected one case in which the profundus tendons of the index and middle fingers had separate sheaths. Communicating with the ulnar bursa (Fig. 25) at this level the anterior intermediary sheath was absent, but 2 cm. higher up the sheath of the middle finger profundus had disappeared, while the anterior and posterior intermediary sheaths were present (Fig. 29). The communication here, then, would have taken place as follows: Ulnar bursa, sheath about the middle finger profundus, sheath about the index finger profundus, or posterior intermediary sheath, and, in this case apparently, anterior intermediary sheath, to the radial bursa. It can be seen that in a fulminating type of infection, such as a streptococcus involvement, the process would spread to the radial bursa, but in the more chronic

¹ Tilleau, *Traité d'Anatomie Topographique*.

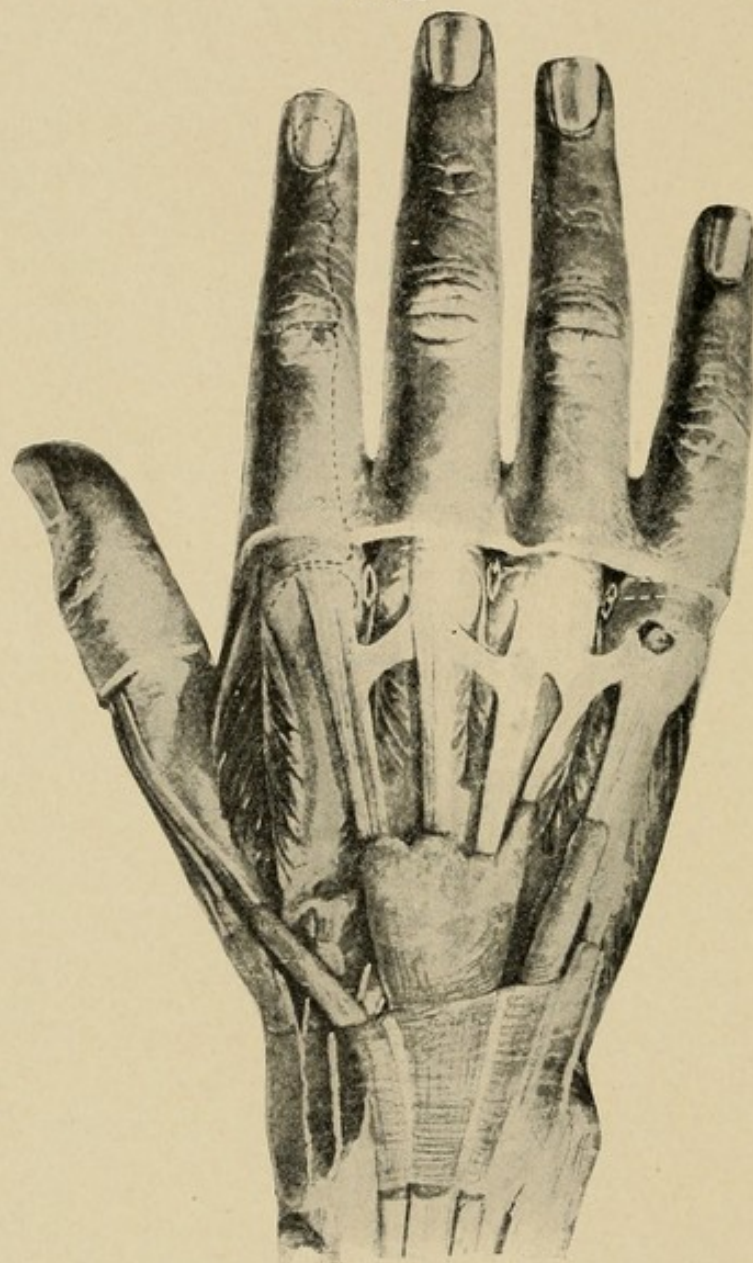
FIG. 32



An x-ray picture of a cadaver hand in which the tendon sheaths have been injected with red lead. The outline of the ulnar bursa and radial bursa with tendon prolongations is clearly shown. Note the distance of the radial bursa from the metacarpal bone of the thumb and the relation of the ulnar bursa to the metacarpal bone of the middle finger.

types this devious course offers many chances for adhesive occlusion of the channel (Fig. 32). This will be discussed later (see p. 207).

FIG. 33



Photograph from Bardeleben, showing tendons upon the back of the hand passing under the posterior annular ligament.

THE SHEATHS UPON THE DORSUM

The synovial sheaths of the hand upon the dorsum are six in number. These begin just above the posterior

annular ligament and pass under and through it (Figs. 26 and 33). They are found as follows:

1. Lying upon the outer side of the styloid process of the radius, for the extensor ossis metacarpi pollicis and the extensor brevis pollicis. They may have separate sheaths and are 5 to 6 cm. in length.

2. Behind the styloid process, for the tendons of the extensor carpi radialis longior and brevior. These are 5 to 6 cm. in length and communicate with the sheath of the extensor longus pollicis through an oval opening by way of the longior (Poirier).

3. Overlapping the above tendons, and communicating with them as described, we have the sheath of the extensor longus pollicis. This is 6 to 7 cm. in length.

4. To the ulnar side of this we find the large sheath enclosing the tendons of the extensor communis digitorum and the extensor indicis. It is 5 to 6 cm. in length and terminates below in three prolongations. The radial one encloses the communis tendon to the index finger and the extensor indicis; the middle, the communis tendon to the middle finger; the one on the ulnar side covers the tendons to the third and fourth fingers.

5. One opposite the interval between the radius and ulna, for the extensor minimi digiti. This is longer than the others, being 6 to 7 cm. in length. Covering the upper one-third of the length of the third interosseous space, it may bifurcate below, following the two branches of the tendon.

6. Upon the back of the ulna, the synovial sheath of the tendon of the extensor carpi ulnaris. This is 4 to 5 cm. in length.

CHAPTER IX

THE RELATION BETWEEN THE SYNOVIAL SHEATHS AND THE FASCIAL SPACES

A STUDY BY EXPERIMENTAL INJECTION OF THE OUTLINES, BOUNDARIES, AND DIVERTICULA OF THE FASCIAL SPACES AND THE RELATION OF THESE TO THE SYNOVIAL SHEATHS

IN my desire to corroborate the findings by dissection in relation to the fascial spaces and tendon sheaths which have been detailed in the two preceding chapters, a large number of hands were injected after the manner described in Chapter VII. The results obtained were most satisfactory, since they were so uniform that they absolutely fixed the boundaries and relations of the spaces and sheaths. Moreover, these experiments gave results which, when applied clinically, were of inestimable value in determining the course the infections tended to pursue. Again, they determined not only the proper sites for opening any particular focus, but also indicated where secondary abscesses would be located, and thus favored early diagnosis and treatment of such processes. Furthermore, they demonstrated the relation between tendon sheath abscesses and fascial space abscesses. These studies have been of greater aid than any other in placing the treatment of infections of the hand upon a scientific basis.

A brief outline of the various procedures will be of value in preserving a general picture. This will be followed by a discussion of the individual experiments.

Our first group of experiments had for its object the determination of the relation of rupture of the synovial sheaths to the secondary abscesses in the fascial spaces.

In other words, if an infection began in a particular tendon and ruptured from it, where would the secondary abscess lie? This was determined by an extensive series of experiments upon each sheath. Clinical evidence has accumulated in my hands sufficient to verify every one of the experimental deductions we have here made.

The second problem dealt with determining the boundaries and diverticula of each of the definite spaces I have described. To do this injections of these spaces were made from every possible source of infection—the tendon sheaths, direct implantation, and extension from neighboring spaces. The results were uniform, as will be seen by a study of the experiments.

Again, certain of these injections were made with great force to determine where pus would extend when it ruptured from these individual spaces.

Therefore, by these experiments we have determined the sites of extensions from the synovial sheaths and for each fascial space: (a) The source of involvement; (b) the normal limitations of that space; (c) the areas to which pus will extend from the space. Here again clinical evidence will be later adduced to show that all of these deductions are pathologically correct.

For the sake of clearness is appended a tabulation of these experiments:

I. The relation of rupture of the tendon sheaths to the fascial spaces.

From the tendon sheath of the middle finger, Experiments 1 and 2.

From the tendon sheath of the ring finger, Experiments 3, 4, 18, 19, and 20.

From the tendon sheath of the little finger, Experiments 5, 6, 7, and 47.

From the tendon sheath of the index finger, Experiments 8, 9, 27, and 35.

From the tendon sheath of the thumb, Experiments 10 to 17.

II. The boundaries and diverticula of the spaces.

(a) Middle palmar space.

Injection via ring finger sheath, Experiments 3, 4, 18 to 20.

Injection via middle finger sheath, Experiments 1 and 2.

Injection via little finger sheath, Experiments 5, 6, 7, and 47.

Injection via palmar fascia, Experiments 21 to 25.

Injection via lumbrical muscle space, Experiments 26*A* and 26*B*.

Of these, great force was used in 19, 20, and 3. From these and others deductions were made as to the location of pus extensions from the middle palmar space.

(b) Thenar space.

Injection via index finger sheath, Experiments 27 to 35, 8 and 9.

Injection via palmar fascia, Experiments 36, 37, and 38.

Of these, great force was used in the experiments from 27 to 35 inclusive, and from the results deductions were made as to the location of pus extensions from the thenar space:

(c) Dorsal subcutaneous space.

Injection between first and second metacarpals, Experiments 39 and 40.

Injection between second and third metacarpals, Experiments 41 and 42.

(d) Dorsal subaponeurotic space.

Experiments 43, 44 and 45.

(e) Hypothenar space.

General results of experiments quoted.

(f) Forearm space.

Injection via flexor longus pollicis sheath, Experiments 46, 10 to 17.

Injection via ulnar bursa and little finger, Experiments 47 and 50.

Injection via middle palmar space, Experiment 49.

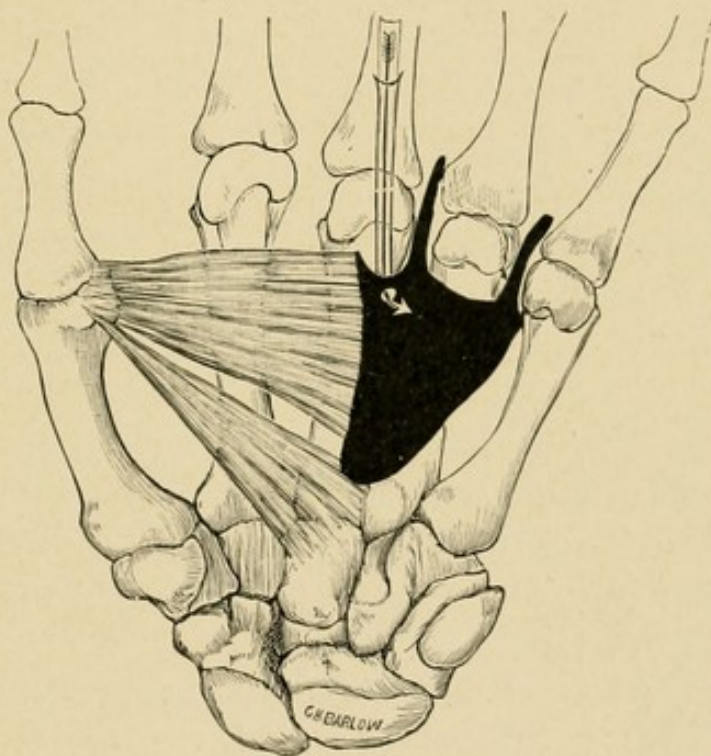
Injection along radial and ulnar vessels, grouped under composite experiment 51.

THE RELATION OF TENDON SHEATH RUPTURE TO THE
FASCIAL SPACES

INJECTION VIA THE TENDON SHEATH OF THE MIDDLE FINGER

In inserting the cannula no effort was made to reach any particular spot, but it was allowed to rupture

FIG. 34



Schematic drawing made from a dissection of a hand injected from the tendon sheath of the middle finger. The mass filled the middle palmar space and extended along the two lumbricals.

through the weakest spot in its course. It will be noted that in each instance the mass entered and filled the middle palmar space.

Experiment 1.—Left hand. Cannula inserted into tendon sheath of middle finger at the middle of the proximal phalanx, moderate force used in injection. The mass occupied the middle palmar space only, going up to about one-half inch below annular ligament. Downward it had returned along the lumbrical muscles of the little and ring fingers nearly to the web of the fingers. It did not return to any extent along the lumbrical muscles of the middle finger. In every way this was a perfect representation of what is probably a typical collection in the middle palmar space. (See experimental injection drawing, Fig. 34.)

Experiment 2.—Left hand. Same as No. 1 in every particular. No mass to radial side of middle finger.

Experiment 2A.—Right hand. Same as No. 1 in every particular.

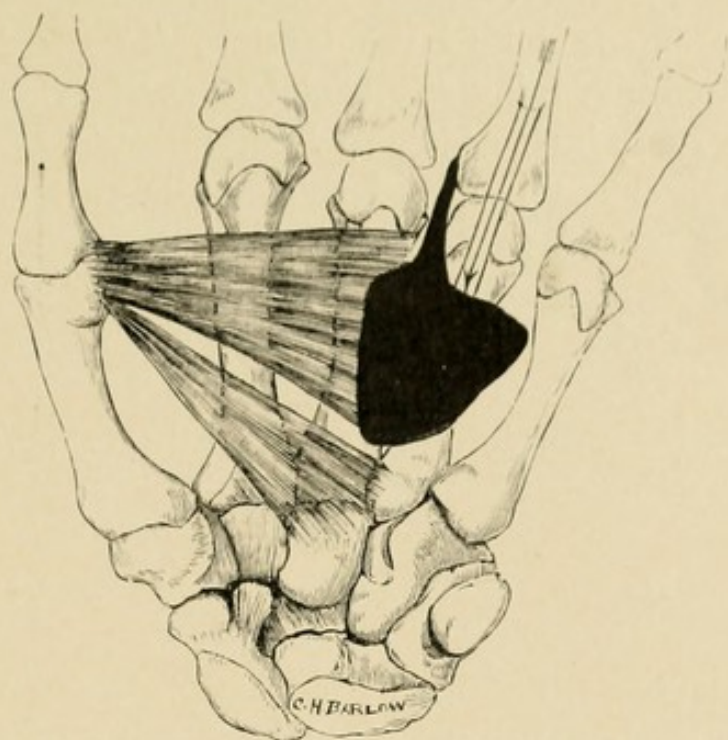
INJECTION VIA THE TENDON SHEATH OF THE RING FINGER

The tendon sheath was opened at the base of the finger and the cannula inserted in the sheath and pushed through the proximal blind end into whatever space was at that site, thus trying to demonstrate where an infection would spread to if it extended from the tendon sheath. In one case, which is not included in the report, the tendon sheath did not end blindly, but extended up into the group of tendons at the wrist. In every case where the sheath ended normally the mass filled the middle palmar space.

Experiment 3.—Right hand. Moderate force used. In this case the mass occupied the middle palmar space as it has been described. No diverticula were noted except that the mass extended along the lumbrical muscles of the ring finger for about one-half inch. (See experimental injection drawing, Fig. 35.)

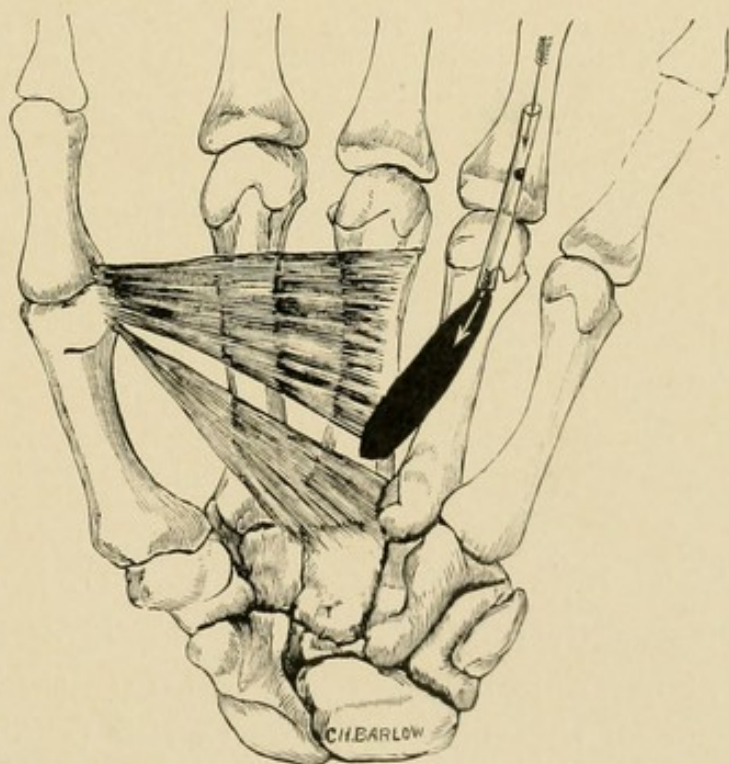
Experiment 4.—Right hand. Moderate force used. In this case the cannula broke from the blind end

FIG. 35



Schematic drawing made from a dissection of a hand injected along the tendon sheath of the ring finger. The mass filled the middle palmar space, with extension along the lumbrical muscle.

FIG. 36



Schematic drawing made from a dissection of a hand in which the mass was injected from the tendon sheath of the middle finger and filled the loft over the middle palmar space, but did not rupture into it.

evidently superficial to the tendon, for there was a small mass only, lying superficial to the tendon, about a quarter of an inch wide and three-quarters of an inch long. It had not involved the middle palmar space, but it was seen that the thinnest wall was in relation to that space, and in case of infection the pus would have extended into it in all probability. (See experimental injection drawing, Fig. 36.) This is further supported by Experiments 18, 19, and 20 (*q. v.*).

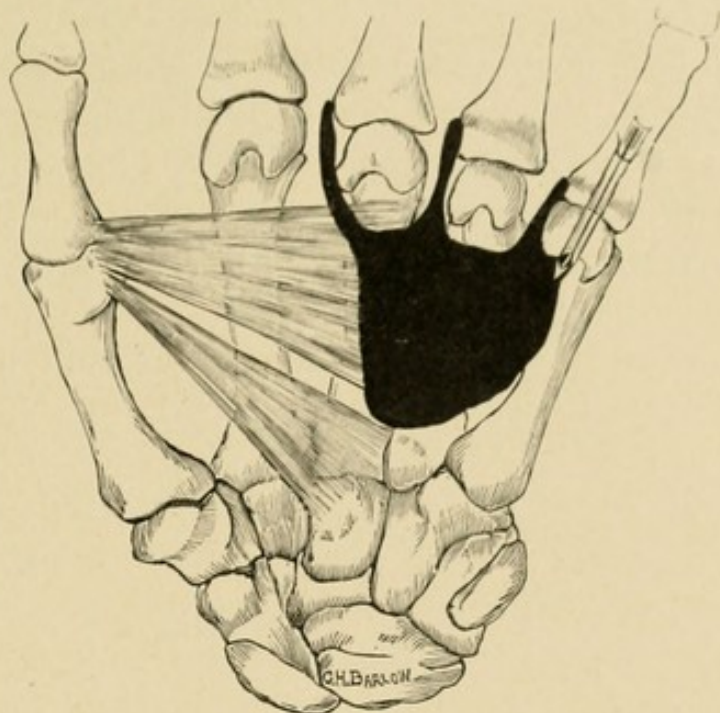
INJECTION VIA THE TENDON SHEATH OF THE LITTLE FINGER

The injections 5 and 6 demonstrate where the pus will lie in those cases in which the rupture takes place in the hand, namely, the middle palmar space. It may also rupture in the forearm. In fact, that is its most frequent site. The location of the pus in the latter case will be seen by studying Experiment 47.

Experiment 5.—During an attempt to inject the ulnar sheath in the right hand it was found to be obliterated at the phalangometacarpal articulation. The cannula broke out into a space which was injected with moderate force, and upon dissection the middle palmar space, as already described, was found filled with the mass. It had not gone up into the wrist, over into the thenar or hypothenar areas, but had returned along the lumbrical muscles of the little, ring, and middle fingers. (See experimental injection drawing, Fig. 37.)

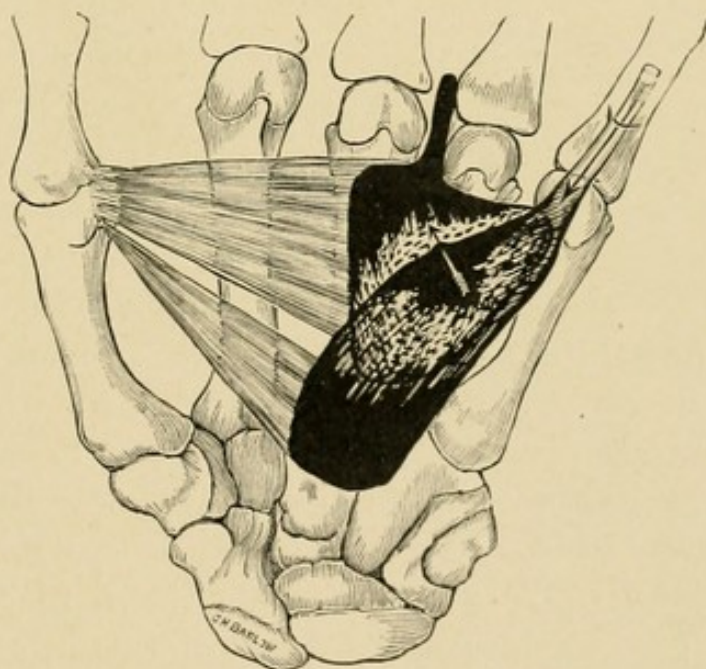
Experiment 6.—In another attempt to inject the ulnar bursa with moderate force, the injection was arrested at the annular ligament owing to the rigidity of the tissue of the subject. Due to this fact and the friability of the tissues incident to age, the ulnar bursa ruptured at about the middle of the palm, and the mass

FIG. 37



Schematic drawing made from a dissection of a hand injected from the tendon sheath of the little finger with which the ulnar bursa did not connect. The mass ruptured into the middle palmar space, filling it, with prolongations along three lumbrical muscles.

FIG. 38



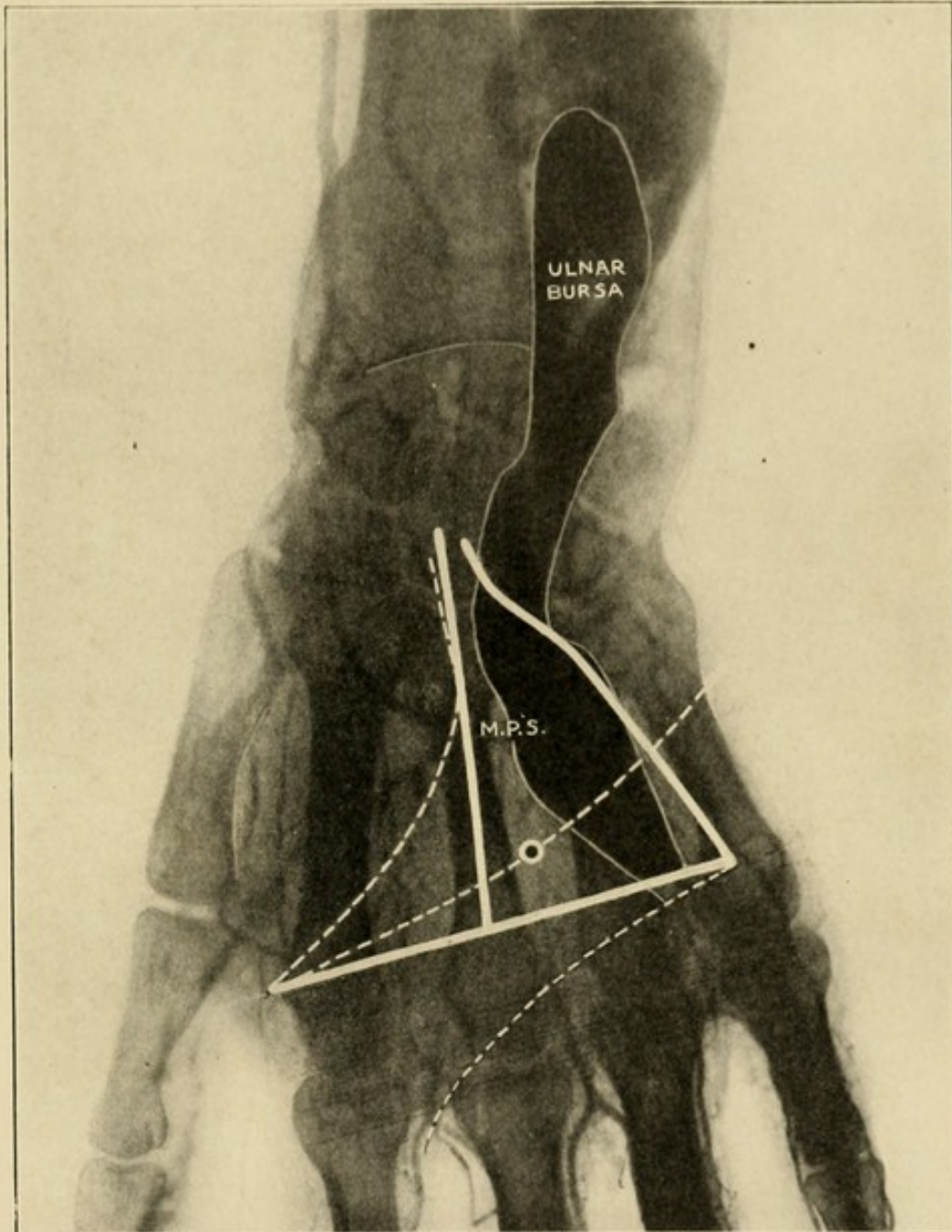
Schematic drawing made from a dissection of a hand in which the mass was injected along the tendon sheath of the little finger; closure at the upper end of the annular ligament of the ulnar bursa allowed rupture from the ulnar bursa, the mass filling the middle palmar space, with extension along one lumbrical muscle.

was found to occupy the middle palmar space only, in addition to the ulnar bursa sheath of the tendons. The mass returned along the ring finger lumbrical only. The surgical importance of this experiment is readily seen. (See experimental injection drawing Fig. 38).

Experiment 7.—Here we have the result produced in those cases in which the rupture is in the forearm and not in the hand. The x-ray photograph here presented, which is made from the hand injected in Experiment 7, presents a clear picture of the bones in their relation to the injected bloodvessels and ulnar bursa (Fig. 39). Upon this plate have been placed lines which represent the boundaries of the thenar and middle palmar spaces. The numerous parallel lines at the distal end of the palm represent the dense tissue here overlying the articulation, in which there are no spaces except those made by the lumbrical muscles with the vessels, and the synovial sheaths. (See cross-section, Fig. 22.) Three curved lines show the position of the flexion creases of the palm of the hand, and in relation to these, note that the proximal end of the distal flexion crease corresponds with the beginning of the dense tissue noted. Again, note that the distal end of the middle flexion crease also begins at the dense tissue, and hence a line drawn between these two points limits the palmar spaces distally. Pay particular attention to the point at which this middle flexion crease crosses the space between the metacarpal bones of the middle and ring fingers, at the distal end of the middle palmar space, avoiding the thenar space upon the radial side, the ulnar bursa upon the ulnar side, the dense tissue distally, and the deep palmar arch which is seen crossing the upper part of the middle palmar space proximally. Note that although the injection mass has broken from the

ulnar sheath in the forearm, yet the spaces in the hand are uninvolved.

FIG. 39



X-ray Plate. Boundaries of the thenar and middle palmar spaces marked and proper site for opening the latter indicated. Ulnar bursa and blood-vessels injected. Photograph made for me by Dr. Cubbins' Surgical X-ray Laboratory.

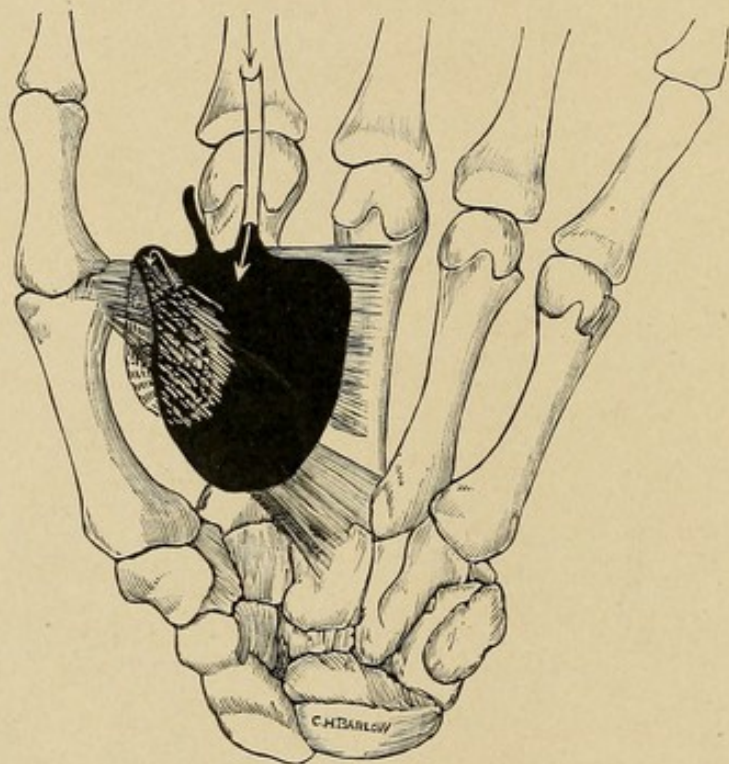
Experiments 54 to 58.—In these as with many other experiments, the records of which are not here reported,

the mass ruptured at the proximal end of the sheath under the flexor profundus tendons in the forearm. This is the most common site of extension. (See Experiment 50 for a complete description of these cases.)

INJECTION VIA THE TENDON SHEATH OF THE INDEX FINGER

Here the findings are positive. In addition to the experiment here detailed, many others were performed

FIG. 40



Schematic drawing made from a dissection of a hand injected along the tendon sheath of the index finger. Mass filled thenar space and extended around to the dorsum underneath adductor transversus and also along lumbrical muscle.

which gave the definite information that when pus ruptures from this sheath it enters the thenar space.

Experiment 8.—Injection was made through the tendon sheath of the index finger. The mass occupied the thenar space; did not go into the forearm or middle

palmar space. Passed around the lower or distal edge of the adductor transversus, filled a space the size of a walnut between that muscle and the first dorsal interosseous, and abutted on the dorsal subcutaneous tissue at web. Followed index lumbrical only. (See experimental injection drawing, Fig. 40.)

Experiment 9.—Same findings as in Experiment 8.

Experiments 24 to 30 and 29 to 35 corroborate these findings.

INJECTION VIA THE TENDON SHEATH OF THE FLEXOR LONGUS POLLICIS

Here one would expect the mass to enter the thenar space in the hand, and we were therefore surprised to find that this was not generally the case. To determine this point definitely, eight experiments were made. In each case great pressure was used in the injection. The cannula was inserted into the tendon sheath in the thumb and so bound that the mass could not escape around the needle. These experiments showed that in a majority of cases the rupture took place in the forearm under the flexor profundus digitorum. It did at times, however, rupture distal to the annular ligament and fill the thenar and even the middle palmar spaces.

Experiment 10.—A cannula was inserted into the sheath of the flexor longus pollicis at the thumb. The injection mass was found to have filled completely the bursa, including the part proximal to the annular ligament. The mass had ruptured from the proximal end and passed up into the forearm. No extravasation had taken place into the hand, either by direct rupture or retrograde extension. The attachment of the flexor longus pollicis at its origin had been torn in part from the bone. The mass extended up along this muscle

on the radial side of the forearm, having on its ulnar boundary and roof the flexor profundus digitorum and the flexor sublimis digitorum. The major portion of the mass was found under the flexor profundus digitorum, going over even to the flexor carpi ulnaris. It filled an area extending from the wrist-joint to within three inches of the elbow-joint.

Experiment 11.—The findings here were practically the same except that a small part of the mass passed downward under the annular ligament and the ulnar bursa to fill partially the middle palmar space. This, however, would probably not occur in an inflammatory case owing to the small channel present.

Experiment 12.—In this case the mass ruptured from the upper third of the synovial sheath, just distal to the annular ligament. It extended downward to the thenar space and partially filled it. A small part had also entered the upper end of the palmar space, owing to the indefinite septum separating these spaces at the upper end. The large mass, however, was in the thenar space, but it demonstrated that extension into the middle palmar space would be possible in neglected cases.

Experiments 13, 14, 15, and 16.—These were practically duplicates of the above results.

Experiment 17.—In this case there was apparently a free anatomical communication between the ulnar and radial bursa, for the mass filled the ulnar bursa. There was also an extension into the forearm from a rupture of the proximal end at the radial bursa.

GENERAL DEDUCTIONS AS TO RELATION OF TENDON SHEATHS TO FASCIAL SPACES

The injections through the synovial sheaths of the tendons of the ring and middle fingers passed into the

middle palmar space, while that space was reached also from the little finger in those cases where the synovial sheath was distinct from the ulnar bursa; and, indeed, the contents of the ulnar bursa itself, when it ruptured into the palm, entered the same space. Injection masses from the index synovial sheath passed into the thenar space. In those cases where the synovial sheath of either of these fingers communicated with the ulnar bursa, the mass passed into that, and followed the course of any bursal injection. The extreme rarity of communication between the index synovial sheath and the ulnar bursa robs that point of any surgical interest such an anomaly would have.

A mass from the radial bursa or the synovial sheath of the flexor longus pollicis, if it ruptures into the hand, will lie in the indefinite spaces mentioned as lying directly over the muscles of the metacarpal bone of the thumb. It is possible for it to erode into the thenar space, but it is more likely to rupture into the fascial spaces of the forearm and lie under the flexor profundus digitorum. The ulnar bursa may rupture into the middle palmar space and it will almost surely rupture into the forearm under the flexor profundus digitorum.

THE NORMAL BOUNDARIES OF THE FASCIAL SPACES AND
THE POSITION OF SECONDARY ABSCESES IN CASE OF
EXTENSION FROM THE SPACES

THE MIDDLE PALMAR SPACE

INJECTION VIA THE TENDON SHEATH OF THE RING FINGER.—*Experiment 18.*—Left hand, along tendon sheath of ring finger; the mass was injected with considerable force. The middle palmar space as described was filled. Thenar and hypothenar area free, mass followed along little and ring finger lumbricals for three-fourths inch, none along other fingers, none through between bones to back, mass extended under

tendons strictly, up into forearm, where a large mass was found lying under the deep muscles upon the pronator quadratus and the interosseous septum up to the pronator radii teres. The mass came to the surface late upon the radial side, about two inches above wrist, but the mass was most marked upon the ulnar side from above downward, between the flexor carpi ulnaris and the deep tendons and muscles. The importance of the position of this mass from a clinical standpoint can be seen.

Experiment 19.—Same findings as in Experiment 18.

Experiment 20.—Wrist bound tightly above annular ligament; cannula inserted along ring finger synovial sheath, and mass injected with great force, the idea being to see where the mass would rupture in case that means of exit was closed. None of the mass went to the forearm or dorsum, but did rupture into the thenar space at the upper or proximal end of the intervening septum and filled the thenar space, passed along all lumbrical muscles into canals for a considerable distance, but not out into the web between the fingers. (See experimental injection drawing, Fig. 41.)

Experiments 3 and 4 corroborate these findings.

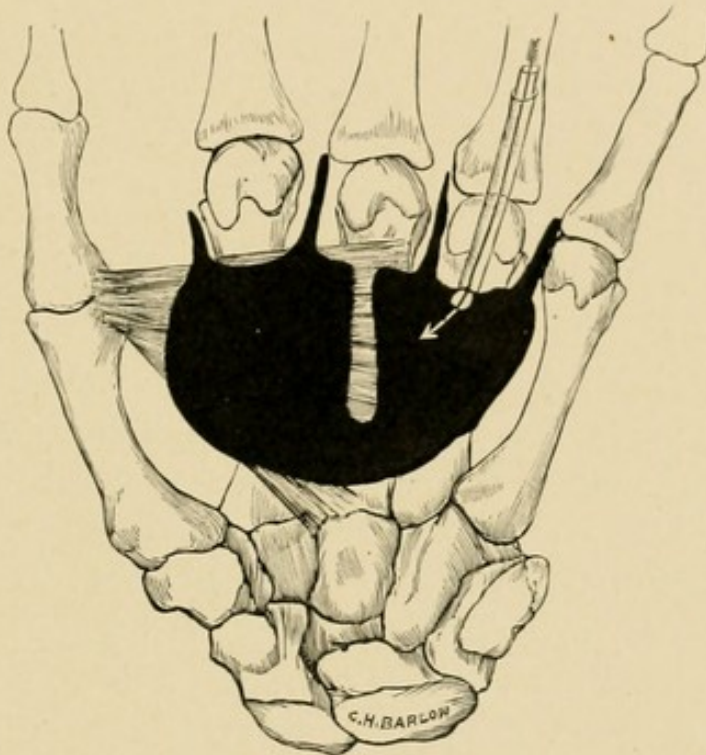
Experiments 1, 2, and 3, in which the space was injected from the middle finger, and Experiments 5 and 6, in which the space was injected from the little finger, present the same findings as in Experiments 18, 19, and 20.

INJECTION THROUGH THE PALMAR FASCIA.—Injection of the space by inserting a needle through the palm directly into the space gives the results uncomplicated by any other process.

Experiment 21.—Left hand. Cannula inserted through the palmar fascia where middle flexion crease crosses metacarpal space between ring and middle fingers. Moderate force used.

NOTE.—Care must be taken that the cannula goes dorsal to the tendons, *i. e.*, really into space, otherwise the mass will be confined to the imperfect spaces around the tendons, particularly superficial to them. Even if this should occur, if great force is used, it will rupture into the great space; not so readily, however, as would pus, since the erosive action of the latter is not present in simple injections.

FIG. 41



Schematic drawing made from a dissection of a hand in which the injection was made along the tendon sheath of the ring finger under great force. The mass filled middle palmar and thenar spaces, with extension along all lumbrical muscles.

Upon dissection the mass was found to be limited to what we have found in the middle palmar space. It was limited upon the radial side by the attachment of fascia to the middle metacarpal bone. This was the long leg of the right-angle triangle. The ulnar side represented the hypotenuse of the triangle lying to the radial side of the hypothenar space. The apex of

the triangle, or the highest point to which the mass spread, was about one inch distal to the distal flexion crease of the wrist, or about a finger's breadth proximal to a line drawn transversely across the palm from the web of the extended thumb.

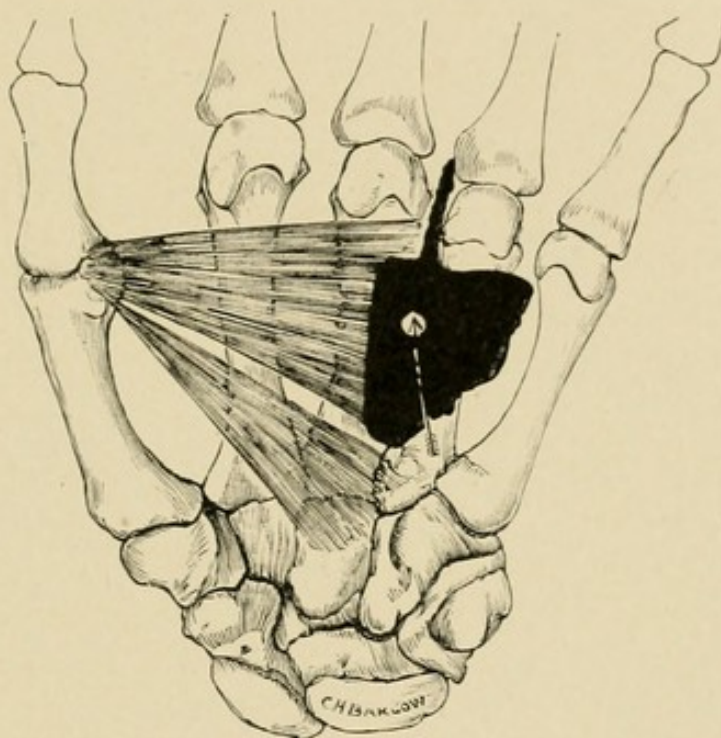
At the lower part of the palm, *i. e.*, toward the web of the fingers, the greater part of the mass was limited by a line drawn between the radial end of the middle flexion crease and the ulnar end of the distal flexion crease of the palm, or, roughly speaking, about a thumb's breadth above the web of the fingers; this is the short leg of our right-angle triangle. A prolongation of the mass had taken place, however, along the lumbrical muscle between the middle and ring fingers, going almost to the web of the fingers. There was no appreciable mass along the other lumbrical muscles, although some of the stain from the methylene blue used in the injection mass had stained the space around the muscle leading to the little finger. No other prolongations were present. It did not break into the interossei muscles or superficially about the tendons. Superficial palmar vessels crossed upper part of mass. (See experimental injection drawing, Fig. 42.)

Experiment 22.—Left hand. Injection at the same point and in the same manner as No. 21. The mass here occupied exactly the same area of distribution as in Experiment 21, except the mass as a whole was not so large, being a little larger than an almond. The most prominent part of the mass was in the middle of the palm, over the middle metacarpal space. There were slight prolongations distally along the lumbrical muscle between ring and middle metacarpals as above.

Experiment 23.—Injection made same as in Experiment 21. Both x-ray picture and dissection made of this right hand. Mass extended somewhat higher in the hand than in Experiment 21, going to a point about

a finger's breadth below, *i. e.*, distal to the distal flexion crease of the wrist lying dorsal to the tendon group; laterally its boundaries were the same, while at the distal portion of the palm a prolongation of the mass occurred along the lumbrical muscles going to the little, ring, and middle fingers. This is of considerable importance, since it is remembered that the relation of the lumbrical muscle of the middle finger to the

FIG. 42



Schematic drawing made from a dissection of a hand in which the injection was made through the palmar fascia into the middle palmar space. The mass filled middle palmar space, with extension along one lumbrical muscle.

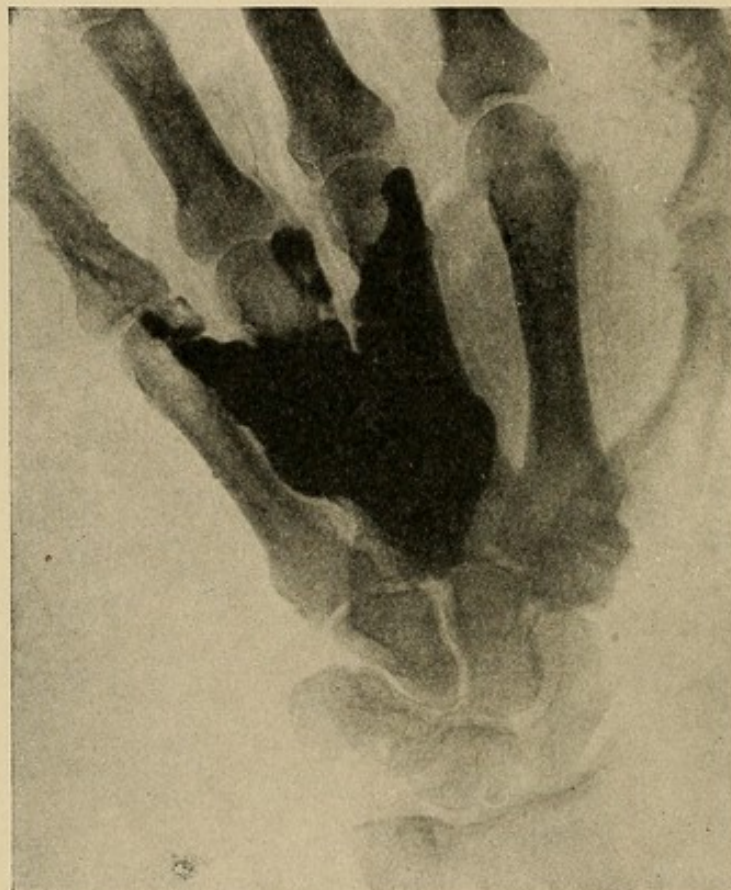middle palmar space was discussed in the division devoted to cross-sections, and this experiment bears out the assumption hazarded there that this muscle space was really a diverticulum of the middle palmar space and not of the thenar space. (See cross-sections, Figs. 23 and 24.)

Experiment 24.—Injection left hand, same as in Experiment 21. Mass occupied same space as in

Experiment 21, except that mass spread down along lumbrical muscle of little and ring fingers for a distance of one-third inch.

INJECTION THROUGH PALMAR FASCIA INTO MIDDLE PALMAR SPACE.—*Experiment 25* (see x-ray photograph, Fig. 43).—This hand was also dissected. It represents

FIG. 43

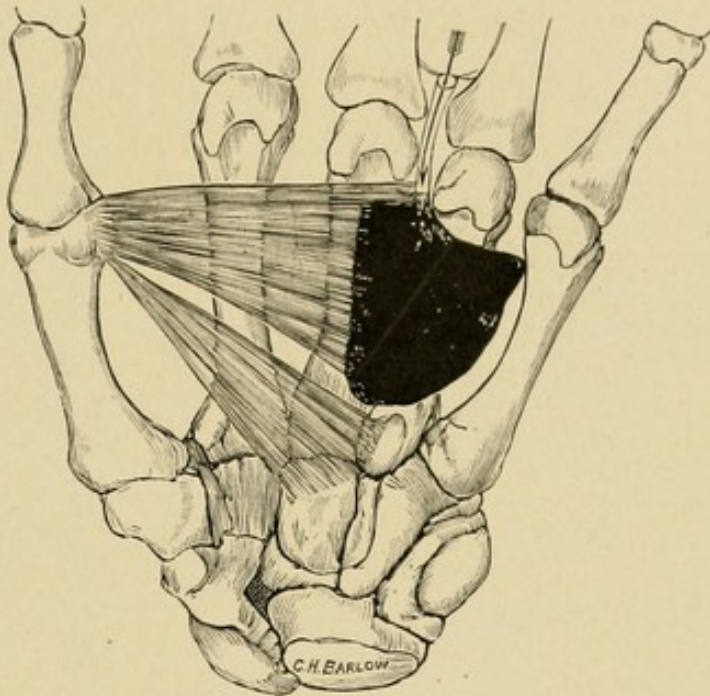


X-ray plate made from a hand in which the middle palmar space was injected with a mixture of red lead and plaster of Paris. Photograph represents location of pus in typical middle palmar space infection.

how the mass extends down along the lumbrical muscles, and shows also what site should be opened to evacuate the contents of the space. Note that the hypothenar and thenar regions are uninvolved, the mass not extending to the radial side of the middle metacarpal. It is seen that the ulnar bursa would lie over the ulnar side of the mass.

INJECTION ALONG LUMBRICAL MUSCLE OF RING FINGER.—*Experiment 26A.*—Cannula inserted along lumbrical muscle, left hand. Some difficulty was experienced in the insertion, but when successful the mass occupied the middle palmar space. There was no return along the lumbrical muscles. Moderate force used in injection. (See experimental injection drawing, Fig. 44.)

FIG. 44



Schematic drawing made from a dissection of a hand in which the injection was made along the lumbrical muscle space between middle and ring fingers. Middle palmar space filled.

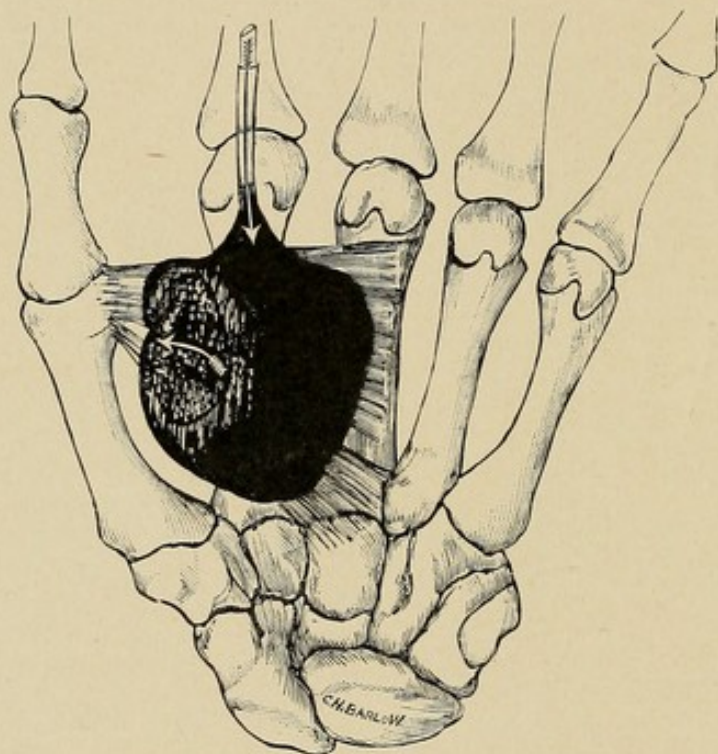
Experiment 26B.—Right hand. Same technique, injection mass lies along lumbrical muscle. Middle palmar space only partly filled.

THE THENAR SPACE

NOTE.—The first injections of this space were very unsatisfactory, owing to two errors in technique, which were corrected later. In the first place, the injections

were not made deep enough; and secondly, they were too far to the radial side over the thumb. It is true that the results obtained by these injections were instructive in that they served to show indefinite limited spaces at these sites, but they did not reach the large space under consideration.

FIG. 45



Schematic drawing made from a dissection of a hand in which the injection was made along the tendon sheath of the index finger. Mass filled thenar space and extended to dorsum between adductor transversus and adductor obliquus.

INJECTION VIA THE TENDON SHEATH OF THE INDEX FINGER.—*Experiment 27.*—Right hand. Cannula inserted into tendon sheath about middle of proximal phalanx and ruptured from sheath at its proximal end. Moderate force used in injection. The mass when dissected out showed the limitations of the thenar space as described. The mass passed up dorsal to the tendon, to a thumb's breadth below the annular ligament. It did not go to the ulnar side of the middle metacarpal.

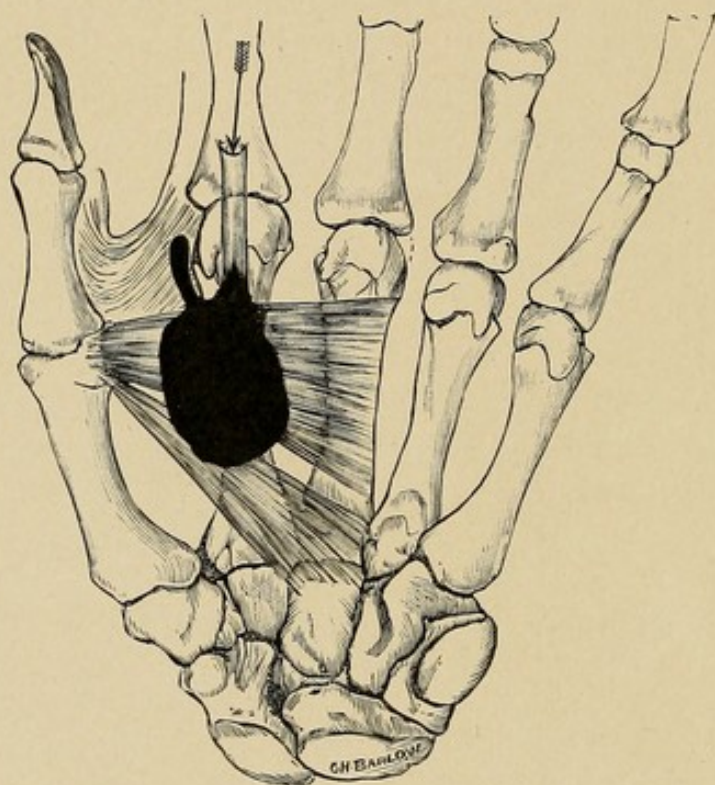
The mass laid directly upon the adductor transversus. It did not go along the lumbrical muscle to the side of the index finger. It did not spread around under the web of the thumb to the dorsum of the hand, but was limited at the distal border of the adductor transversus. It did spread to the back, however, at the upper or proximal edge of the adductor transversus, going between the adductor transversus and the adductor obliquus, thus lying between the adductor transversus and the first dorsal interosseous, at the distal edge of which it came to lie in the subcutaneous tissue of the dorsum. (See experimental injection drawing, Fig. 45.)

Experiment 28.—Injection same as Experiment 27. Here the mass did not fill the space completely, but did return along the lumbrical muscle to the radial side of the index finger; condition well marked. For clinical purposes, Experiments 27 and 28 should be studied together. The probability is that the cannula did not rupture entirely into the space, but did get out of the synovial sheath into the indefinite spaces in the loose connective tissue about the tendon in the loft, as it were, of the thenar space. (See experimental injection drawing, Fig. 46.)

INJECTION OF THE THENAR SPACE UNDER FORCIBLE PRESSURE.—The index synovial sheath was opened and cannula forced out of the proximal end into the palm; forcible pressure with force pump was maintained for from three to five minutes. Owing to the fact that the routes of extension from the thenar space were somewhat difficult to determine accurately, nine injections of the space were made, with the following results. In none of the cases did the mass go up into the forearm. In 3 cases only did it go into the middle palmar space. In 8 cases the mass passed dorsal to the adductor transversus; of these, in 6 the mass went

to the dorsum between the adductor transversus and the adductor obliquus, and in 4 passed below or distal to the adductor transversus to lie between the transversus and first dorsal interosseous. In no case did the mass pass to the dorsum between the second and third metacarpals.

FIG. 46

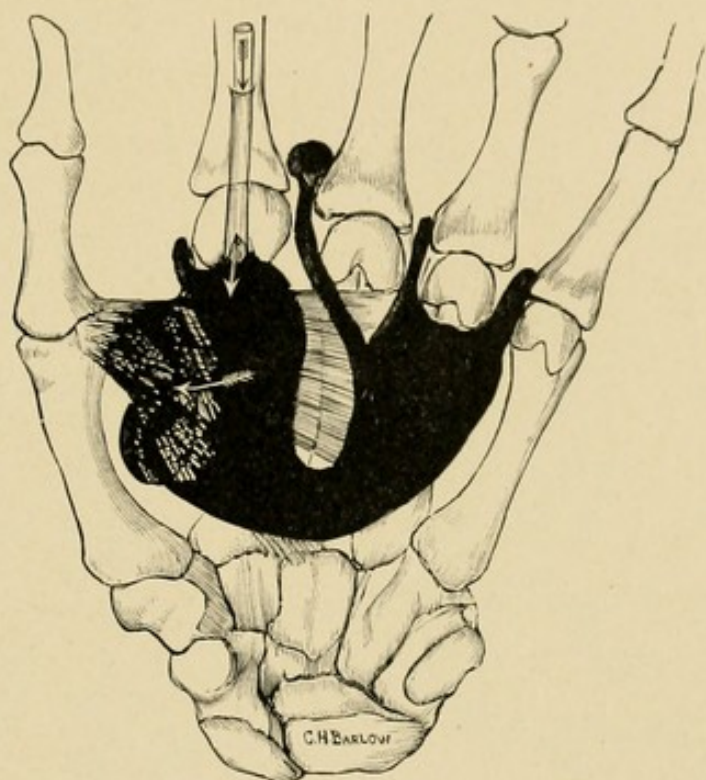


Schematic drawing made from a dissection of a hand in which the injection was made along the tendon sheath of the index finger. Mass filled the thenar space and extended along the lumbrical muscle.

Experiment 29.—Left hand. Tissues well preserved; mass here occupied thenar space, and spread between adductor transversus and adductor obliquus to fill space size of a walnut between them and first dorsal interosseous; also ruptured through tissues between thenar space and middle palmar space at the proximal end of the septum, passed over to fill the middle palmar space, and accompanied the four lumbricals into their respective canals. Did not go under tendons to forearm.

Experiments 30, 31, and 32 were the same as Experiment 29, except that the mass in 32 did not invade the middle palmar space. All went above the adductor transversus to dorsum, however. The mass in 31 passed along middle finger lumbrical and came to lie in the tissue of the web immediately beneath the web. (See experimental injection drawing, Fig. 47.)

FIG. 47

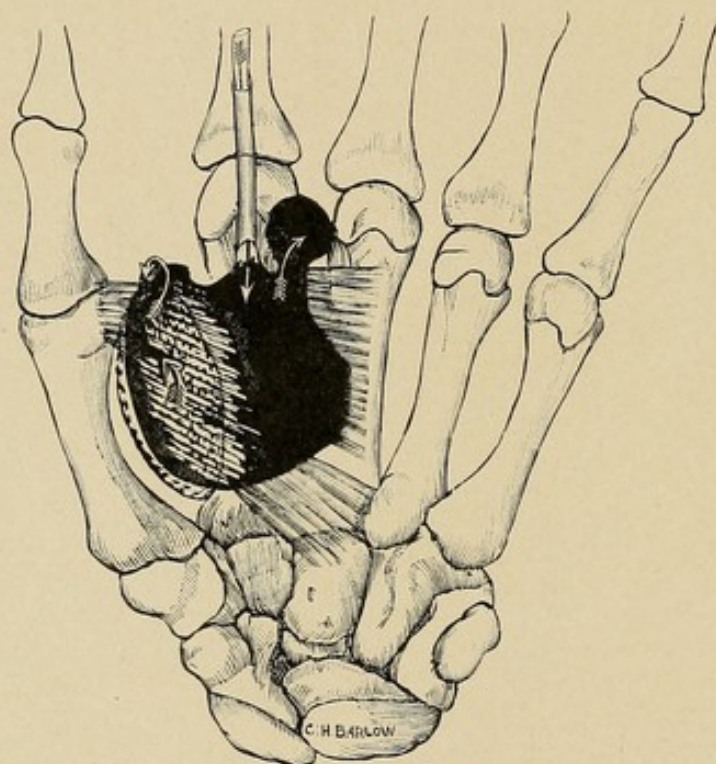


Schematic drawing made from a dissection of a hand in which the injection was made along the tendon sheath of the index finger. Mass filled the thenar space and extended over to the middle palmar space, along all the lumbrical muscles, and went to the dorsum, first between the adductor transversus and obliquus, and secondly between the index and middle fingers. (See Fig. 125 for explanation of this latter extension.)

Experiment 33.—This mass extension was extremely interesting. It filled the thenar space and then passed to the space between the adductor transversus and the first dorsal interosseous, going both above and below the adductor, *i. e.*, both proximal and distal, abutting on dorsal subcutaneous tissue at web at distal edge of

first dorsal interosseous, extended along index lumbrical canal, and did not go into middle palmar space or forearm. The most interesting extension, however, was that which occurred through the palmar aponeurosis at the distal edge of the bases of the index and middle fingers into the soft pad of fatty tissue which lies here in the palm, thus giving corroboration to those clinical cases

FIG. 48



Schematic drawing made from a dissection of a hand in which the injection was made along the tendon sheath of the index finger. The mass filled the thenar space, extended to the dorsum below the adductor transversus and to the palm through a defect of the palmar fascia.

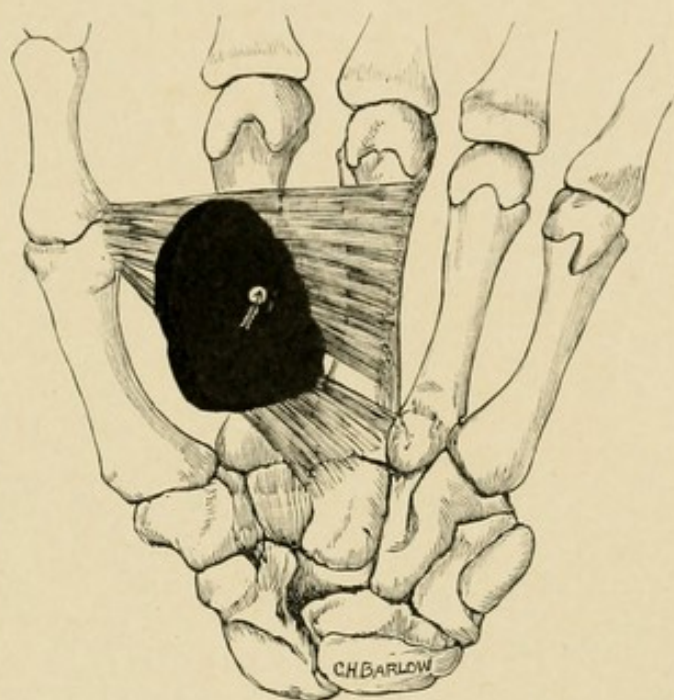
which are on record in which pus has pointed here, supposedly through an imperfect palmar fascia. This was the only experimental injection in which a mass appeared in the palm. (See experimental injection drawing, Fig. 48.)

Experiment 34.—Result same as 33 except no subdermal palmar extension.

Experiment 35.—Mass filled thenar space; no extensions except along index lumbrical canal.

INJECTION THROUGH PALMAR FASCIA IN ATTEMPT TO REACH THENAR SPACE.—To do this properly the cannula should be inserted about the middle line of the palm one centimeter to the thenar side of the adduction flexion crease of the thumb.

FIG. 49



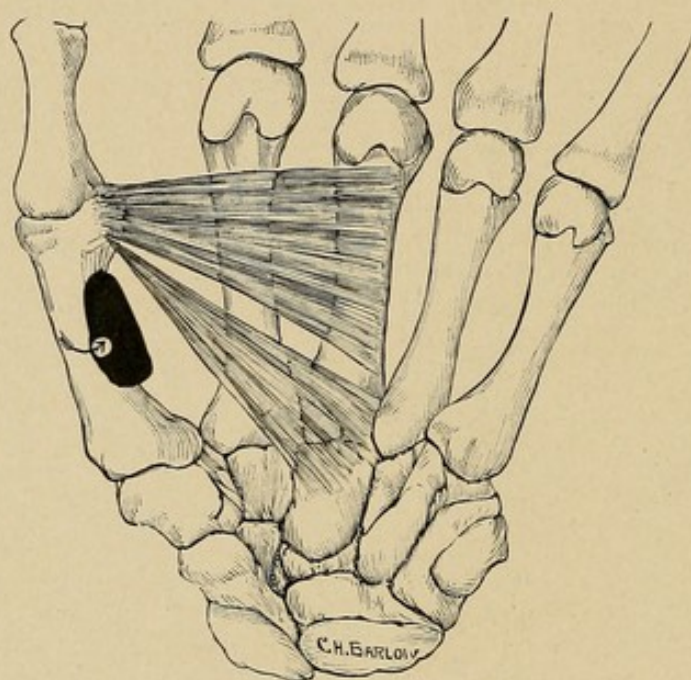
Schematic drawing made from a dissection of a hand in which the injection was made through the palmar fascia into the thenar space.

Experiment 36.—Left hand. Cannula inserted into middle thenar space, moderate force used in injection. Mass was found to have filled the space completely, but had not followed along the index lumbrical muscle to the finger, nor had it gone to the dorsum under the subcutaneous tissue. The space filled corresponded to the area comprised between the adduction crease of the thumb and the metacarpal bone of the thumb in adduction. (See experimental injection drawing, Fig. 49.)

Experiment 37.—Attempt to inject thenar space. Right hand. Cannula was inserted too far to radial side over muscular group. Small mass was found in indefinite space adjacent to flexor brevis pollicis. (See experimental injection drawing, Fig. 50.)

Experiment 38.—Same as Experiment 37.

FIG. 50



Schematic drawing made from a dissection of a hand in which an attempt was made to inject the thenar space but in which the cannula reached only one of the indefinite spaces near the metacarpal bone.

THE DORSAL SUBCUTANEOUS SPACE

INJECTION OF SUBCUTANEOUS TISSUE OF THE DORSUM BETWEEN THE FIRST AND SECOND METACARPALS.

—NOTE.—These injections were made to determine the relation of these spaces to the thenar space and the remainder of the subcutaneous tissue on the dorsum.

Experiment 39.—Injection right hand. Moderate force; insertion into subcutaneous tissue on dorsum, thenar region. Mass was found to be subcutaneous,

and while there was evidently a tendency to limitation at the index metacarpal, yet it is doubtful if it was due to the attachment of fascia to the bone, being more likely to be the natural tendency to limitation found in the meshes of any loose tissue. Moreover, in spite of the partial limitation at this point, it had spread into the subcutaneous tissue above the tendons going from the wrist proximally to the metacarpophalangeal articulation distally and over to the level of the fourth metacarpal bone. It did not go through to the palm by any channel.

Experiment 40.—Injection of left hand same as above. Mass upon dissection found to occupy dorsal thenar subcutaneous tissue over to the index metacarpal, beyond which it did not extend. It did not pass to the palmar surface nor into the thenar space.

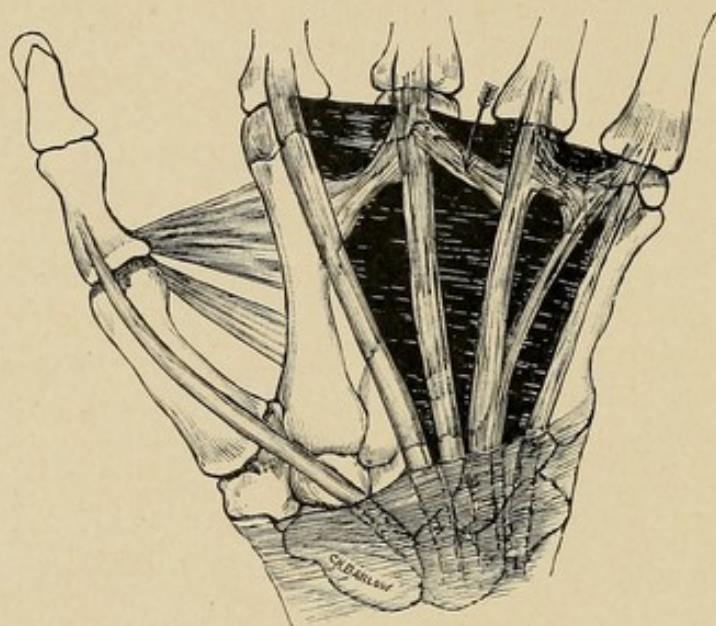
INJECTION OF THE SUBCUTANEOUS TISSUE OF THE DORSUM BETWEEN SECOND AND THIRD METACARPAL BONES.—*Experiment 41.*—Right hand. Cannula inserted into subcutaneous tissue of dorsum of hand and the mass injected with considerable force. The tip of the needle was superficial to the tendons but deeper than the superficial layers immediately beneath the skin. Upon dissection, mass found to occupy a considerable space extending from the wrist above to the metacarpophalangeal articulation below and from the metacarpal bone of the index finger to the metacarpal bone of the little finger; proximally and distally, at the wrist and fingers respectively, the tissue seemed to be bound more firmly to the underlying tissue than laterally.

Experiment 42.—Left hand. Technique and results same as Experiment 41. A study of these two show several layers of fascia between the skin and tendons, with no single space more distinct than another.

THE DORSAL SUBAPONEUROTIC SPACE

INJECTION UNDER TENDONS OF DORSUM. — The importance of this series is seen when we remember that it is in this space that pus would lie if it ruptured through between the metacarpals from the palmar surface. The results obtained were uniform.

FIG. 51



Schematic drawing made from a dissection of a hand in which the injection was made underneath the aponeurosis of the dorsum, the subaponeurotic space being filled.

Experiment 43.—Left hand. Cannula tip inserted under tendons between middle and ring fingers at lower third of dorsum. Considerable force was used in the injection. The mass was confined to the space under the tendons, *i. e.*, was covered by the tendons and the aponeurosis between them. It passed up to the wrist, down to within one-half inch of the fingers, and laterally to index metacarpal and little finger metacarpal; thus having the shape of a truncated cone flattened

on one side. The mass appeared to be ready to break out upon the ulnar side, but none had done so. (See experimental injection drawing, Fig. 51.)

Experiment 44.—Left hand. Technique and results same as Experiment 43.

Experiment 45.—Right hand. Cannula inserted between tendons of ring and little fingers, at the middle of the dorsum of the hand; entire subaponeurotic space filled; no tendency to rupture between tendons, but evidence of beginning extension at two sides over index metacarpal and little finger.

HYPOTHENAR SPACE

Many experiments were made to determine the limitations of this space. The injections spread from the site of injection only after considerable manipulation, and then the mass was limited to the hypthenar area, near the point of insertion. The details of the other injections are omitted, since they only corroborate the findings already noted.

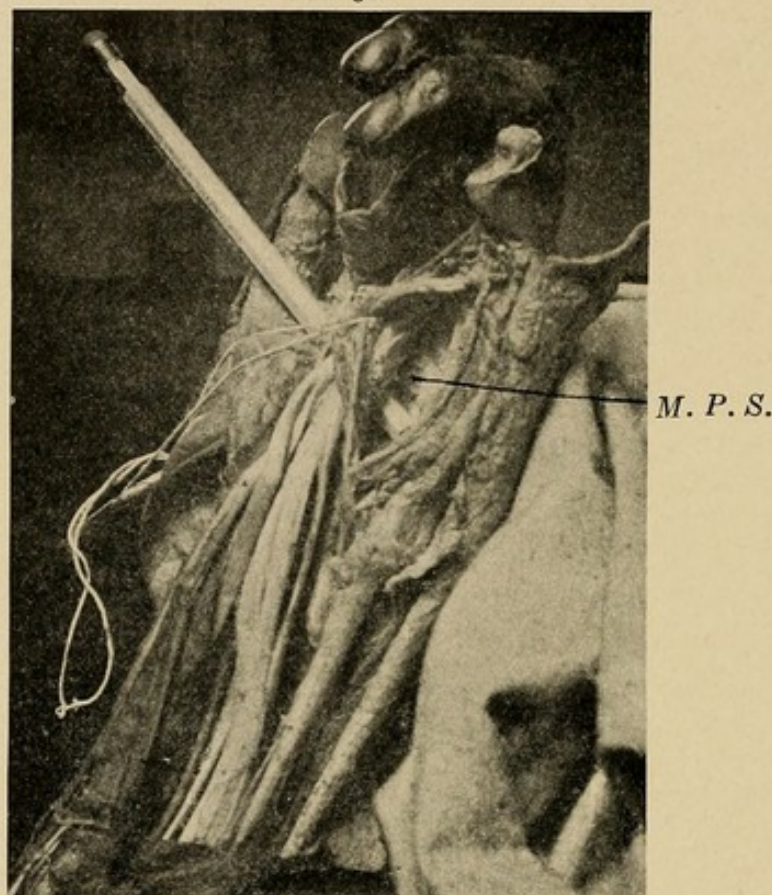
RÉSUMÉ OF PRECEDING EXPERIMENTS AS TO BOUNDARIES, DIVERTICULA, AND EXTENSIONS FROM THE FASCIAL SPACES¹

That we may have a clear understanding of the results obtained by experimental injection, let us

¹ A study of the comparative embryology throws some light upon the natural divisions of the hand, but unfortunately this has as yet only been worked out in relation to the palmar fascia and the tendon groups. Dr. McMurrich (Am. Jour. of Anat., No. 2, p. 202) described the relation of these in amblystoma. The muscular masses which here arise in the palmar fascia, and which correspond to the superficial tendons in the mammalia, divide longitudinally into three groups, the lateral parts destined for the second and fifth digits, separating from the median parts destined for the third and fourth digits. Here we see that thus early we have a suggestion of the ultimate relation of the parts, in that the tendons arising from the palmar fascia leave room below them

summarize them. The mass in the *middle palmar space*, in practically every case, filled the space we have outlined (Fig. 52). In no case did it extend into the

FIG. 52



Photograph of middle palmar space, tendons being raised. The end of the pencil lies in its deepest part.

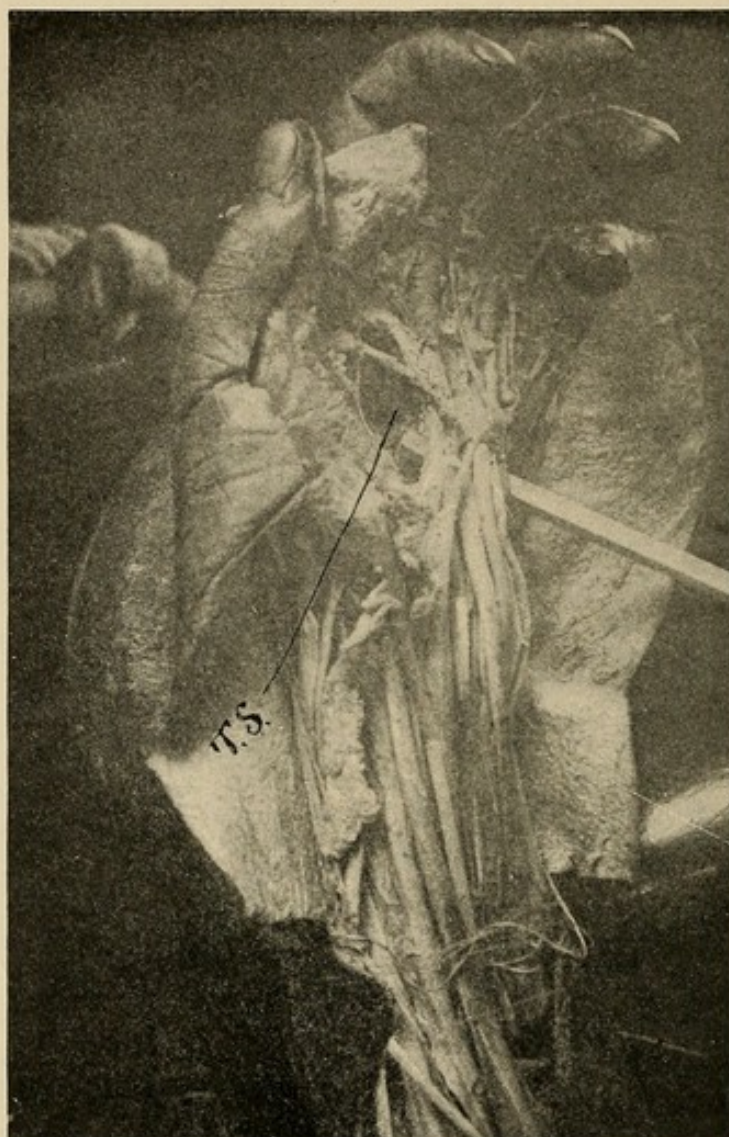
for fascial spaces between them and the bones. And again, the early grouping of the tendons corresponds to the spaces, *i. e.*, the radial lateral parts going to the index finger, and being entirely separated from the two ulnar parts corresponding to the middle, ring, and little fingers. The most ulnar part is not so distinctly separated from the median part as is the radial, that, in a way, being partly fused with the median, but still, both upon dissection and injection, we have noted a partial tendency to separation of the middle and ring finger area from the little finger area. How much the development of the muscular mass of the hypothenar area may have to do with this is, of course, undecided, since we as yet know little as to its embryological development, but it would seem reasonable to assume that it has little relation, owing to its extreme ulnar position; so that, reasoning *a posteriori*, we would say that in case of the mammalian embryo there had been a persistence of the separation between the index mass and the others, while there had been either an incomplete fusion between the median and ulnar mass, or else they had partially fused as development proceeded.

hypothenar area or to the radial side of the middle metacarpal bone, except in the case noted where a band was tied about the wrist in which the mass then ruptured into the thenar space. In every case there was some extension along the lumbrical muscles, almost always going down between the bases of the middle and ring fingers, and sometimes between the little and ring fingers, and, more uncommonly, the middle and index fingers. Unless great force was used, this was the limit of the extension. When great force was used, the masses in the lumbrical canals passed out into the loose tissue of the web; also the mass filling the space proper passed upward under the tendons into the forearm, where it spread beneath the deep muscles nearly up to the elbow before it came to the surface at the lower part of the forearm on the ulnar side. (For the location of the mass in the forearm, see Chapters X and XXVI.) In no case did the mass go through between the bones to the back.

The *thenar space* was found to be a large space, but lying very deep (Figs. 53 and 54). It was not continuous with the subcutaneous tissue of the dorsum, and the mass was limited at the free palmar edge of the radial side of the palm. The mass did pass, however, when force was used, into the perimuscular sheath on the dorsum, passing proximally and less frequently distally to the adductor transversus, lying between this muscle and the first dorsal interosseous. It also spread down along the lumbrical muscle of the index finger, making a diverticulum from one-quarter to one-half inch long. In no case did it spread up into the forearm, even though anatomical dissection demonstrated that this would be possible, although improbable, and if it did it would be in the same site as that described for masses coming from the middle palmar space. In no case did the mass lie to the ulnar side of the middle metacarpal bone,

unless great force was used in the injection; then it passed through the upper part of the septum and filled the middle palmar space in one-third of the cases.

FIG. 53



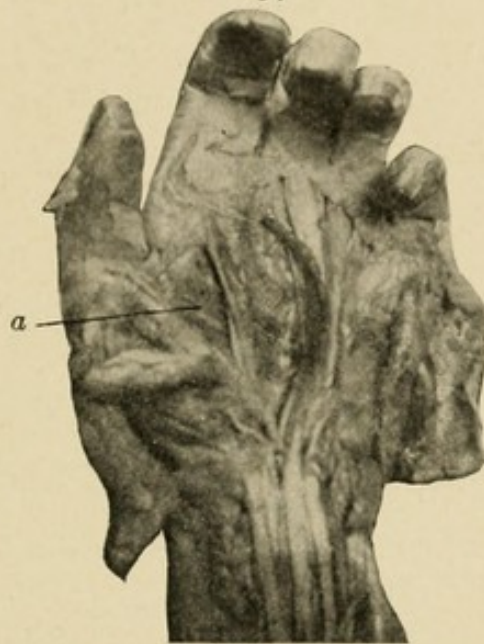Photograph showing thenar space. The end of the pencil appears in its deepest part.

Injections into the *hypothenar area* showed the spaces to be localized and perimuscular for the most part, not communicating with any large space, and hence of no particular surgical importance.

Injections of the *subaponeurotic space* demonstrated that the mass would not rupture through the aponeu-

rosis unless anatomical exceptions were present. It would spread up to the wrist, down to the metacarpophalangeal joint, and laterally to the edge of the index or little finger tendon on the radial and ulnar sides respectively. If greater force were used, it tended to spread under the subcutaneous tissues, particularly on the ulnar side and at the knuckles.

FIG. 54



Photograph showing thenar space with the tendons drawn away so as to expose it widely.

Injectations of the *dorsal subcutaneous space* showed no particular pockets, but did show a tendency to localization at any site injected because of the obliquity of fibrous bands crossing from space to space. If the injections were given with great force, the mass spread equally in every direction, except there seemed to be some particular factor at work limiting in a certain measure the spread of the mass over the index metacarpal from the dorsum of the hand to the thenar dorsal region, and *vice versa*.

Deep injections of the palm went into the spaces lying underneath, and since these spaces do not

overlap, except at the wrist, only one space is affected by a given punctured wound. It must be remembered, however, that the lymphatic channels from the centre of the palm pass deeply into the tissue and come to lie immediately adjacent to the adductor transversus, so that a lymphatic abscess from a punctured wound might lie in the thenar area, although the puncture might appear to be at the radial side of the middle palmar space. When the masses spread up into the forearm they appeared under the flexor profundus digitorum. This subject is considered as a whole in the next chapter, devoted to a study of the various spaces in the forearm.

CHAPTER X

ANATOMY OF THE FOREARM IN RELATION TO INFECTIONS

EARLY in my clinical work it was found that there was little knowledge as to the sites of predilection for pus in the forearm when it extended from the hand. Experience showed that incisions made at the sites suggested by Forssell and others were followed by a tedious convalescence owing to the necessity of maintaining satisfactory drainage through the muscular bodies. A study of the forearm after the same methods already pursued in the hand was begun, namely, by dissection of serial sections and injection of masses from various sites. As a result of this, I changed entirely the sites of my incisions, and had the great satisfaction of seeing cases, which under the old methods of incision required weeks of constant attention and multiple incisions, heal in a week to ten days, with two or at most three incisions made at one sitting. Parona, as quoted by Mauclair, has suggested the advisability of one of these incisions—that upon the ulnar side above the wrist.

The anatomical and experimental data upon which these incisions were based are detailed in brief in this chapter.

ANATOMY IN GENERAL

In general one should remember that the synovial sheaths, *i. e.*, the ulnar and radial bursæ, pass under the annular ligament and extend into the forearm for a distance varying from one to two inches. The greater

part of the sac of each lies upon the dorsal surface of the tendons, *i. e.*, between the tendons of the flexor profundus digitorum and the pronator quadratus (Fig. 81). Again, one should note that the bloodvessels and nerves are surrounded by fascial spaces and when pus once reaches them it can spread easily along these as channels.

Before beginning this study one should be familiar with the general anatomy of the forearm; particularly the relations of the flexor carpi ulnaris, of the flexor profundus digitorum as a group, of the flexor sublimis digitorum as a group, of the course of the median and ulnar nerves, and of the ulnar and radial artery, especially the former, the relation of the pronator quadratus and the ulna and radius with the interosseous membrane in one group to the flexor profundus digitorum. With these general facts in mind, let us now take up the study of the cross-sections.

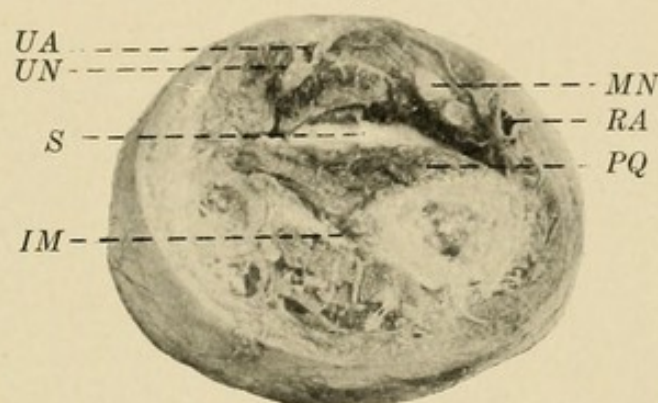
SERIAL CROSS-SECTIONS OF THE FOREARM

The cadaver arms were hardened in Kaiserling No. 1. After being sectioned the pieces were preserved in Kaiserling No. 2. Sections were made at the following distances from the radial styloid: 3 cm., 7 cm., 9 cm., and 12 cm. The proximal surfaces of these sections were teased out with a needle and forceps. The large spaces found were packed with cotton or held open with small props and photographs taken to show their relation to the other structures of the forearm. One particularly large free space was found in the lower part of the forearm in direct contiguity with the tendon sheaths and in continuity with the middle palmar space in the hand. It is upon this that we will centre our attention.

Section 1 (Fig. 55).—Three centimeters above radial styloid. The space is rather small here, opening out

from the narrow strait that connects it with the middle palmar space in the hand. It extends well across the forearm, but is slightly larger upon the radial side. The vessels and nerves are separated from the space by well-defined layers of muscular and connective tissue. Upon the superficial surface it has the tendons of the flexor profundus digitorum, covered by their synovial sheath, and the flexor longus pollicis, covered by its synovial sheath. On the radial and ulnar sides there is nothing but the attachment of the muscular fascial sheath to the bones, and the subcutaneous tissue. On its deep surface is seen the pronator quadratus.

FIG. 55

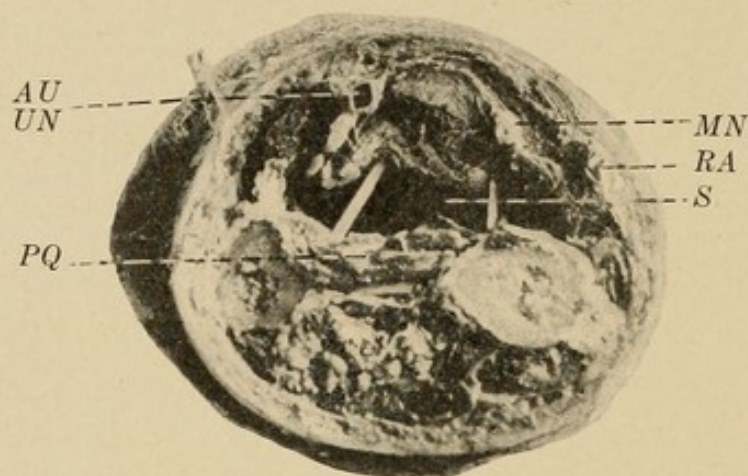


Section 3 cm. above radial styloid: *UA*, ulnar artery; *UN*, ulnar nerve; *MN*, median nerve; *RA*, radial artery; *S*, space; *IM*, interosseous membrane; *PQ*, pronator quadratus.

It is seen that if pus ruptured from the synovial sheaths or passed upward from the middle palmar space, it would enter this free area. It is manifest that a large accumulation could take place here. Its most superficial sites would be upon the sides.

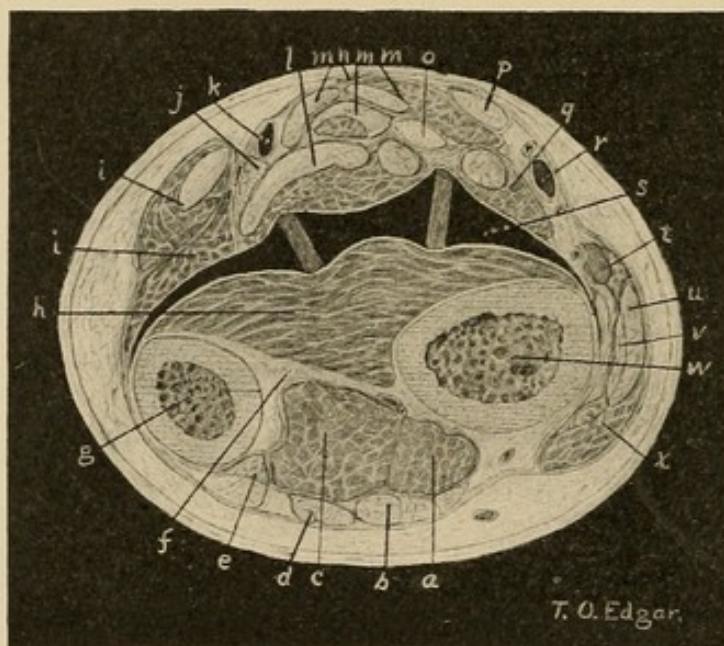
Section 2 (Figs. 56 and 57).—Five centimeters above radial styloid. The relation of the structures has not changed materially. The body of the pronator quadratus is somewhat smaller. The space here goes well to the ulnar side.

FIG. 56



Section 5 cm. above radial styloid. UA, ulnar artery; UN, ulnar nerve; MN, median nerve; RA, radial artery; S, space; PQ, pronator quadratus.

FIG. 57

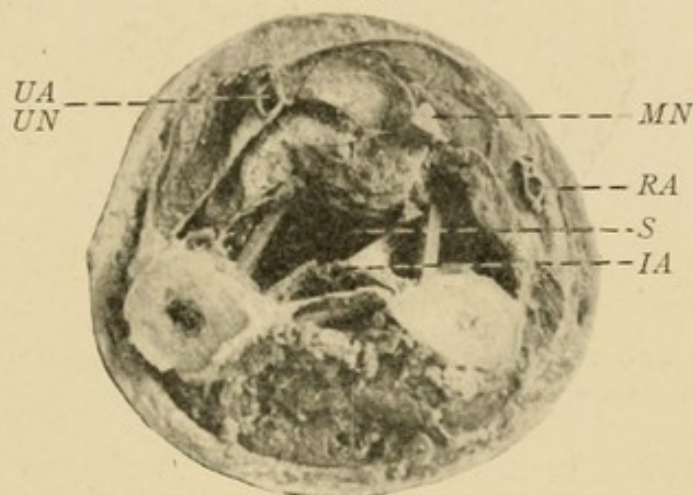


Drawing from teased cross-section, Fig. 56: *a*, extensor secundi internodii pollicis; *b*, extensor communis digitorum; *c*, extensor indicis; *d*, extensor minimi digiti; *e*, extensor carpi ulnaris; *f*, interosseous membrane; *g*, ulna; *h*, pronator quadratus; *i*, *i*, flexor carpi ulnaris; *j*, ulnar nerve; *k*, ulnar artery; *l*, flexor profundus digitorum; *m*, *m*, flexor sublimis digitorum; *n*, palmaris longus; *o*, median nerve; *p*, flexor carpi radialis; *q*, flexor longus pollicis; *r*, radial artery; *s*, space propped open by pegs of wood; *t*, supinator longus; *u*, extensor carpi radialis longior; *v*, extensor carpi radialis brevior; *w*, radius; *x*, extensor primi internodii pollicis.

By comparing this with the other sections it will be seen how little tissue lies at the sides, and it is at this site that drainage is instituted. The blocks of wood holding open the space are about a centimeter and a half in length.

Section 3 (Fig. 58).—Seven centimeters above radial styloid. In this section the pronator quadratus has almost entirely disappeared. The space is bounded below by the interosseous membrane with the artery

FIG. 58



Section 7 cm. above radial styloid. Pronator quadratus has almost disappeared. Notice that the vessels and nerves with the exception of the interosseous (*IA*) are well separated from the space.

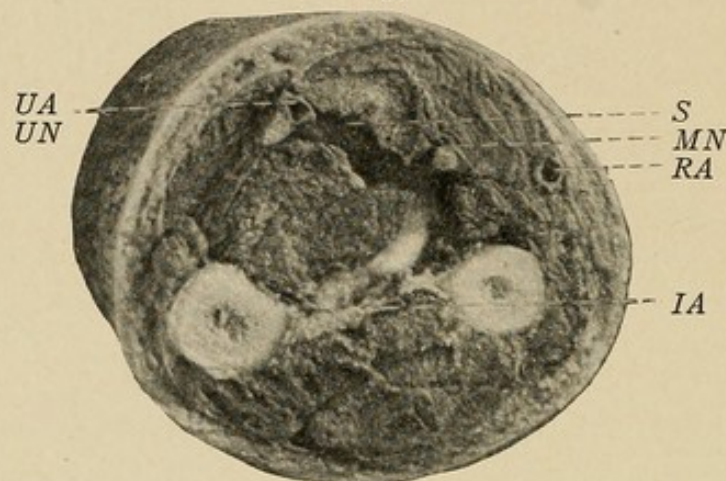
exposed. The radial and ulnar arteries and the median and ulnar nerves are still well separated from the space. Attention will be drawn to this fact later in discussing treatment.

Section 4 (Fig. 59).—Nine centimeters above radial styloid. In this section the space is leaving the interosseous membrane and passing toward the flexor surface on the radial side of the deep flexors. It extends to the median nerve and over to the ulnar artery and nerve along the ulnar side.

This relation of the space to the bloodvessels and nerves explains why the injection masses go up the

forearm and then pass in a retrograde manner toward the hand along these structures. It also explains those cases in which the injection mass passes up along the median above the elbow. It helps to explain the trophic sequelæ and cases of ulcerative hemorrhage that have been reported. In the upper part of the fore-

FIG. 59



Section 9 cm. above radial styloid. Note the relation of the space to the median nerve and the ulnar artery: *IA*, interosseous artery.

arm the space follows the nerves and bloodvessels and becomes indefinite. It is seen that the ulnar nerve and artery along which the secondary mass extends lie immediately under the junction of the flexor carpi ulnaris with the flexor profundus digitorum. This indicates then a second site for incision (Figs. 111 and 112).

EXPERIMENTAL INJECTIONS OF THE FASCIAL SPACES OF THE FOREARM

To verify the findings here, experimental injections were made with plaster of Paris from various sites that might be the origin of spreading abscesses. These will show the intimate relation which exists between the fascial spaces of the hand and the forearm and those about the bloodvessels.

It should be remembered that we are only selecting illustrative experiments which bear upon the subject

in hand, and that they do not by any means represent a complete report of the results obtained from injections at these various sites.

INJECTION OF THE RADIAL BURSA

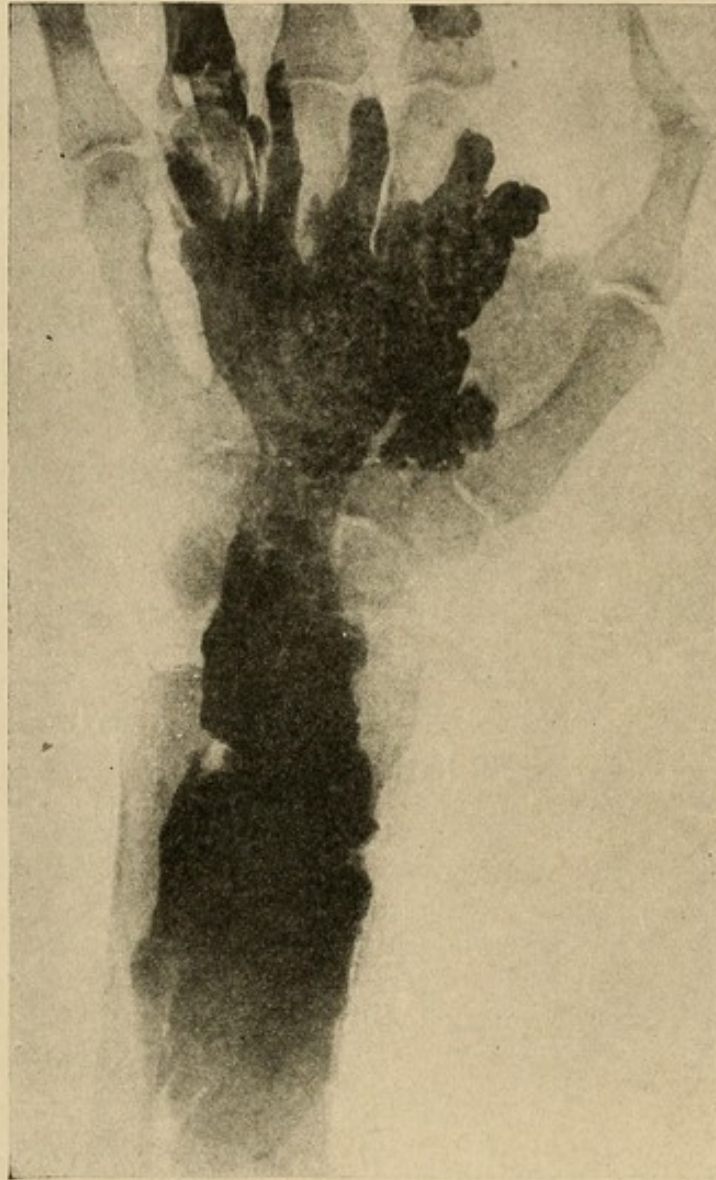Out of the eight injections made into the radial bursa under high pressure to produce rupture and extravasation of the mass, six showed extension from a rupture at the proximal end into the forearm (see p. 125). The following may be taken as an example of the condition found upon dissection of the arm.

Experiment 46.—Injection under great pressure of synovial sheath of flexor longus pollicis by plaster of Paris.

Upon dissection, the mass was found to have filled the synovial sheath completely and ruptured from the proximal end into the tissue of the forearm. No extension has taken place into the hand either by rupture of the sheath in continuity or by retrograde movement from the forearm under the annular ligament, although the mass had extended down to the annular ligament and lay under the superior border. The attachment of the flexor longus pollicis to the bone was partially destroyed, owing possibly to the friability of the muscle in this particular cadaver, but the mass showed a tendency to follow this muscle and a predilection for the radial side of the forearm. A portion of the mass lay between the flexor longus pollicis and the flexor sublimis digitorum. The larger part, however, extended underneath the flexor profundus digitorum to fill a space bounded on the ulnar side by the flexor carpi ulnaris, on the radial side by the flexor longus pollicis, dorsally by the bones with the interosseous membrane and pronator quadratus. This extended up to within three inches of the elbow-joint and distally to the wrist-joint. A great amount of

material was present. The area filled was practically that described in the cross-sections, except that the mass did not extend between the flexor carpi ulnaris and the flexor profundus.

FIG. 60



X-ray Plate.—Injection via tendon sheaths of both thenar and middle palmar spaces with considerable force. Note extension into forearm from middle palmar space. Showing where pus would lie in neglected cases, as in Cases 25 and 45.

INJECTION OF THE ULNAR BURSA

Injection of the ulnar bursa resulted frequently in rupture at the proximal end. The mass showed a

greater predilection for the ulnar side, and had a tendency to return along the course of the ulnar artery. This extension along the vessel explains the presence of the ulceration of the vessel and profuse hemorrhage which occurs at times.

Experiment 47.—Injection of the ulnar bursa, rupture from proximal end, filling deep space in the forearm (Fig. 39).

The ulnar bursa was injected with great force. Rupture occurred at the proximal end; the mass was found to fill space described above, being dorsal to the flexor profundus tendons and muscles. It showed a primary predilection for the ulnar side, but returned along both the ulnar and radial vessels. There was also an extension along the median nerve, this tongue of plaster following the nerve to two inches proximal to the elbow-joint.

INJECTIONS FROM THE MID-PALMAR SPACE

What is the result when the mass extends from the mid-palmar space of the hand?

Experiment 48.—(Fig. 60.) In this case the result is shown by an x-ray picture. Both the thenar and middle palmar spaces were injected with force from the index and ring fingers respectively. The thenar mass remained in its usual compartment, while the middle palmar mass passed up under the group of flexor tendons into the forearm. Note the prolongations along the lumbrical muscles, and the thinness of the mass under the site of the annular ligament.

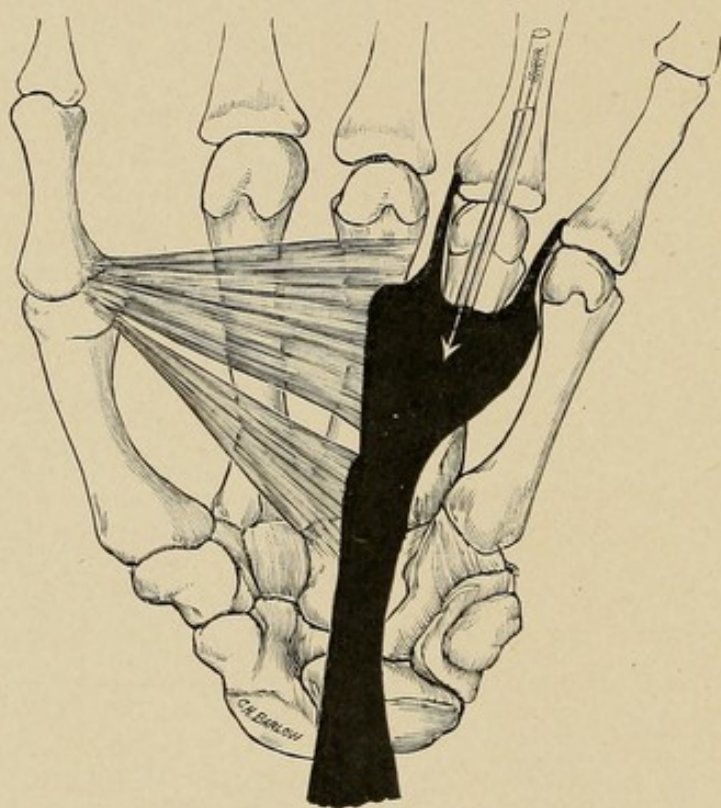
This graphically represents what has been suggested in the preceding pages, that extension to the forearm may occur from middle palmar space infections, but is not likely to from the thenar space.

This tendency for pus to extend along the vessels

and nerves helps to explain the frequency of trophic changes which so often occur as a sequence of infections of the hand.

Experiment 49.—Injection with great force through synovial sheath of the ring finger, filling mid-palmar space and extending under anterior annular ligament into forearm. (See experimental injection drawing, Fig. 61.)

FIG. 61



Schematic drawing made from a dissection of a hand in which the injection was made along the tendon sheath of the ring finger. The mass filled the middle palmar space and extended along two of the lumbrical muscles and under the annular ligament into the forearm.

The mass was injected with considerable force. The middle palmar space as described was filled. Thenar and hypothenar areas free, mass along little and ring finger lumbricals for three-fourths inch, none along other fingers, none through between bones to back, mass extended under tendons strictly, up into forearm,

where a large mass was found lying under the deep muscles upon the pronator quadratus and interosseous septum. It extended into the intermuscular fascial spaces up to the pronator radii teres, it came to the surface late upon the radial side at about two inches above wrist, but the mass was most marked upon the ulnar side from above downward between the flexor carpi ulnaris and the deep tendons and muscles, so that this upper mass was most easily reached by separating the flexor carpi ulnaris along its volar edge from the adjacent muscular body. This also exposed the ulnar artery and nerve which were surrounded by the mass.

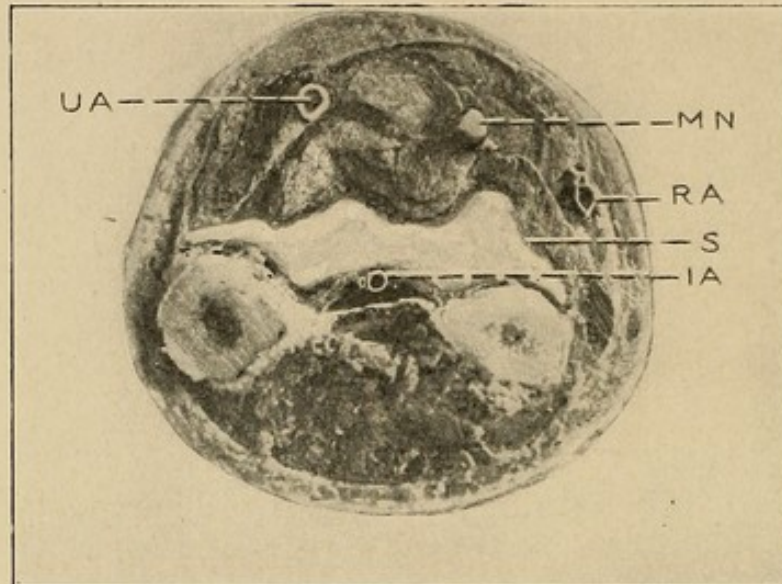
This is further exemplified by an x-ray picture taken of an arm injected as shown by the legend (Fig. 61), the mass being impregnated with red lead.

RÉSUMÉ OF FINDINGS BY DISSECTION AND EXPERIMENTAL INJECTIONS

By these experiments we have demonstrated that in neglected cases, no matter whether the pus extends up from the ulnar bursa, radial bursa, or the mid-palmar space, the same area of the forearm is involved, thus indicating the position pus would occupy in neglected cases, or in those cases in which early rupture of the synovial sheaths (ulnar and radial bursa) occurs. This space lies under the flexor profundus digitorum tendons and muscle (Fig. 62). About three inches up on the forearm the pus begins to invade the intermuscular septa, passing first to the area about the median nerve, and later to the area about the ulnar artery and nerve. Here it lies between the flexor carpi ulnaris and the flexor profundus (Fig. 63). This is about four inches up on the forearm. From here it may pass toward the elbow along the vessels and nerves, particularly

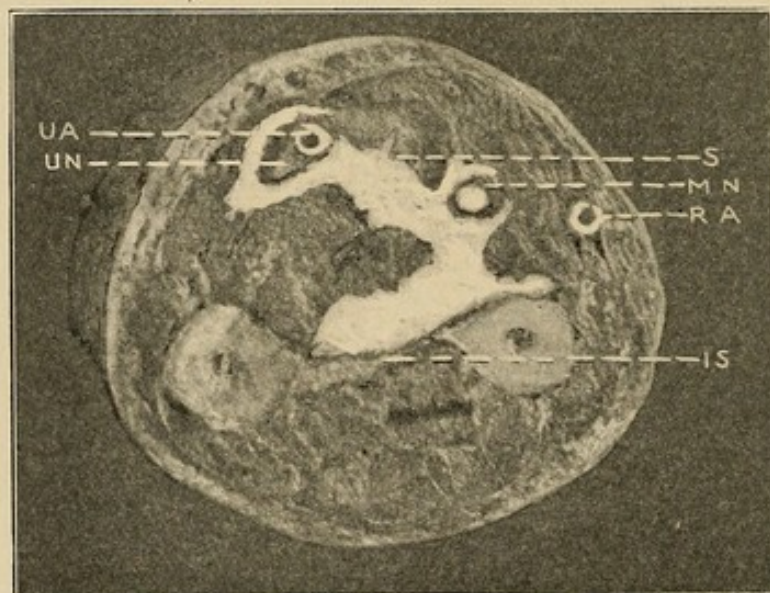
the median nerve, or, more commonly, it may extend distally along the ulnar artery under the flexor carpi ulnaris, and appear subcutaneously about three inches

FIG. 62



Photograph of cross-section, 7 cm. below the radial styloid, showing area filled with pus.

FIG. 63




Photograph of forearm just below the middle, showing position of pus in its relation to the ulnar artery and nerve and the median nerve.

up on the ulnar side. It may extend downward along the radial artery, but this is certainly an uncommon termination. The larger part of the space is about

two inches above the wrist. Its most superficial parts are on either side, just volar to the ulna and radius. The floor of the space is made up by the pronator quadratus at the wrist and the interosseous septum above. The space may hold a half pint or more of fluid.

The only other distinctly separated space is that comprising the subcutaneous tissue.

(For the surgical application of these facts see Chapters XXVI and XXVII.)



SECTION II

THE SURGICAL CONSIDERATION OF TENDON- SHEATH INFECTIONS AND FASCIAL SPACE ABSCESES OF THE HAND AND FOREARM

CHAPTER XI

PATHOGENESIS—SOURCE OF INVOLVEMENT OF THE TENDON SHEATHS AND FASCIAL SPACES

CONCERNING the surgical application of the anatomical and experimental data we have discussed in the previous chapters, it should be borne in mind that our remarks are strictly confined to a discussion of these facts in relation to the subject of tendon sheath and fascial abscesses in the hand. Lymphatic infection will be considered only in so far as it has a distinct bearing upon these conditions, a full discussion being reserved for a subsequent chapter.

ETIOLOGY IN GENERAL

In all of the cases coming under observation, the accumulations of pus have been submitted to bacteriological examination, and the results differed in nowise from the findings elsewhere; nearly all the slow growing abscesses showing the staphylococcus in pure culture, while those originating in the tendon sheaths, if of a fulminating nature, showed the streptococcus unless

there was a secondary infection. The severity of the course was often in inverse relation to the extent of the primary wounds. Again, the general health and resistance of the patient were often below normal. The latter factor has been particularly conspicuous. On the other hand, cases of localized infection (from deep lacerated wounds) have followed in very robust individuals, where doubtless the infection has been carried directly to the space infected. Again, it has been noted that local trauma, without apparent abrasion of the skin, has acted by lessening the local resistance, hence favoring infection. We soon learned also that the older the patient the greater would be the danger of a serious course and complications. The gonococcus may be found in some cases, almost always of hematogenous origin.

SOURCE OF INVOLVEMENT OF THE VARIOUS SHEATHS

Attention has been drawn above to the theories advanced by the earlier authors as to the source of infection of the sheaths. It is probable that they may be involved either by lymphatic extension or direct continuity. The latter, of course, needs no discussion. That wounds involving the sheath may be an atrium and that abscesses lying in continuity may cause necrosis and involvement will be admitted by all. It is rather uncommon for a felon to give rise to tenosynovitis. The same may be said of suppurative arthritis of the distal interphalangeal joint, and the metacarpophalangeal joint. This is explained by the anatomical relations, which also probably explain the frequent involvement from the proximal interphalangeal joint (see pp. 102 and 103). I have seen extension to a sheath from abscesses in a lumbrical canal. Here, however, the involvement is likely to

be localized to the proximal end of the finger sheaths. Indeed, this holds true for all of these cases which develop as a result of abscesses in continuity. One explanation of this can be found in the fact that the contiguous inflammation has probably given rise to plastic adhesions in the sheath before the actual involvement has taken place, and, again, these local accumulations have generally been produced by the staphylococcus or some like germ of moderate virulence. This is also true of involvement of the ulnar or radial sheaths secondary to abscesses in the palm, as was exemplified by the case of Henderson (see Case XVI).

The question of lymphatic involvement is one that is not so easily demonstrable, but any surgeon can recall numerous histories of patients who developed an infection of a sheath within twenty-four to thirty-six hours after a simple needle prick of a finger upon the volar surface. This is most commonly met with in the distal or middle phalanx (see Case XI), and is almost always streptococcic in origin. Why it does not occur in dorsal wounds is understood when we remember that the course of the lymphatic vessels is from the palmar to the dorsal surface. It is this type of infection which presages the most disastrous results, since localization to any part of the sheath is uncommon, and unless early incision is instituted, necrosis of the sheath takes place with serious local and constitutional sequelæ. The possibility of gonococcic tenosynovitis of hematogenous origin must always be borne in mind in cases with an obscure origin. Two such cases have come under my observation.

EXTENSION FROM ONE SHEATH TO ANOTHER

The extension from one sheath to another follows strictly on anatomical lines. Apparent exception to

this is found in simultaneous involvement of the thumb and ulnar bursa without involvement of the radial bursa, the thumb being primary, as was found in four of Forssell's cases. He did not note any cases of little finger infection and radial bursitis without associated ulnar bursitis. Before this exception is admitted further observations must be made. In two of my cases I was led to the same conclusion on first opening the sheath of the flexor longus pollicis, but further search revealed pus at both ends of the sheath.

The anatomical relations of the finger sheaths of the little finger and thumb to the ulnar and radial bursæ respectively, as well as the intercommunication of these latter, have already been discussed (see pp. 105 and 109). When we are dealing with an infection of little virulence, such as one due to the staphylococcus, we frequently find a plastic exudate or adhesions closing the narrowed opening between these parts and the infection located in any section; as for instance, the finger sheath, ulnar bursa, radial bursa, or the intermediary sheaths at the wrist. Indeed, I have at times seen an infection of an ulnar bursa limited to that part of the sheath between the base of the finger and the annular ligament, the part of the sheath in the forearm being uninvolved, protected by adhesions at the annular ligament. My experience here agrees with the earlier observations of Schwartz and Gosselin, and differs from that of Forssell, who says that "out of 34 cases of ulnar bursitis, an extension of the infection to the tendon sheath of the little finger was found in 30 cases on their entrance into the hospital, and if we assume with Poirier that the ulnar bursa is completely separated in 33 per cent. of the cases, it is very improbable that a secondary boundary should in a single one of the aforementioned cases have developed through an adhesive inflammation. . . . I have

never, in operating upon a suppurative bursitis, found within the bursa proper a fibrinous or plastic synovitis in such a mass as to notably affect the operation."

In general, however, it may be said that in the virulent types of infection beginning in the little finger sheath, we will almost always have an involvement of the ulnar bursa and in a majority of cases the radial bursa and sheath of the flexor longus pollicis will be involved from this (see p. 109). The converse is also true.

Besides spreading by direct continuity these infections may, of course, involve one or more sheaths secondarily by a rupture from a previously infected sheath.

I report the case of Mr. P., who had an infection of the middle finger tendon sheath which extended by way of the lumbrical canal over to the tendon sheath of the ring finger, since it demonstrates the possibility of such infection spreading to contiguous tendon sheaths, a point that has not been brought out in previous contributions.

CASE VII.—Mr. P., referred by Dr. A. T. Horn.

History: Patient received slight lacerated wound on the flexor surface of the middle finger. Inside of two days the finger was markedly swollen and tender, and when seen in consultation on the third day tenderness was marked throughout the course of the tendon sheath, the finger was flexed and on extension presented the greatest amount of pain at the proximal end of the sheath.

A diagnosis of tenosynovitis was made and the tendon incised throughout its length. The lumbrical spaces on either side were involved and were drained. The infection apparently subsided, but on the seventh day it was noted that the ring finger was markedly flexed, tender throughout the course of the sheath, and

that on extension pain was present at its proximal end. The diagnosis of infection of this sheath due to contiguity of the lumbrical space was made, and the tendon sheath was incised and drained by an incision upon its flexor surface. From this time on there was an uninterrupted recovery as to the infection, but the ultimate result showed the patient with moderate flexion of the ring finger at its proximal interphalangeal joint, no motion at its distal joint, and complete motion at the metacarpal phalangeal joint. The middle finger was held semiflexed with complete flexion at the metacarpal phalangeal joint; other joints of the finger could not be moved.

The extension from the sheaths by rupture has been discussed in the chapter on experimental injections (Chapter IX), and will be considered in the subsequent section upon the course of involvement of the fascial spaces.

SOURCE OF INVOLVEMENT OF THE IMPORTANT FASCIAL SPACES IN THE HAND. GENERAL DISCUSSION

INVOLVEMENT FROM THE TENDON SHEATHS.—This source is certainly one of the most common, and the experimental and anatomical discussions in Chapters VII, VIII, and IX had for one of their purposes the determination of these facts. Accepting the results of these investigations as probabilities only, I have been able to verify nearly every statement by clinical observation. In the less virulent cases inflammatory barriers may be thrown out that will close the normal anatomical canals. If the process continues any time, however, or the process is acute, the result follows absolutely along anatomical lines.

The *middle palmar space* becomes involved secondarily to a tendon sheath infection of the middle, ring,

and little finger. At times the middle finger may rupture into the lumbrical space between the index and middle finger, and by secondary rupture may involve the thenar spaces. But even in cases of such a lumbrical rupture, it generally involves the middle palmar space.

The *thenar space* is involved as a result of rupture from the tendon sheath of the index finger and exceptionally from the middle finger. It also occurs at times that a rupture of the flexor longus pollicis sheath may involve this space, but here the pus is more likely to come to the surface at the web.

The *lumbrical spaces* are most commonly the site of the primary focus after rupture from the proximal end of the various sheaths. The middle and ring fingers may rupture on either or both sides. The index finger most commonly ruptures to the ulnar side, but may rupture upon the radial side, while the little finger sheath ruptures only upon its radial side.

Infection of the dorsal tendon sheaths is so uncommon that prognostic data here would not be of any value.

DIRECT IMPLANTATION OF THE INFECTION IN THE SPACES.—The *middle palmar space* is more often infected by implantation, both through direct puncture and extensive crushing injuries and lacerated wounds.

CASE VIII.—Crushing injury of hand; fracture of ring finger metacarpal, with infection involving the middle palmar space.

Mr. B. P., aged twenty-five years, Chicago Charity Hospital.

Patient's Statement: Patient states that he was thrown in front of a moving car and the wheel ran on his hand, but evidently did not cross it. Condition found upon entrance to hospital following day: Lacerated wounds across dorsum of right hand, midway,

two and one-half inches long, rather deep, into subcutaneous tissue; lacerated wound of palmar surface two inches long and irregular, so that there was a flap raised up consisting of tissue superficial to palmar aponeurosis; wounds infected; fracture of metacarpal of middle finger; tendons intact; fingers extended; not particularly tender to flexion and extension, although thumb was more tender than others. (This was later found to be due to a fracture of the proximal phalanx.) Whole hand swollen, no particular areas. Flaps opened to allow drainage. Hot boric dressings applied.

Patient's temperature and pulse demonstrated a continuation of the severe infection, and two weeks after entrance, owing to the site of the injury and the greater rigidity of the middle, ring, and little fingers, a diagnosis of pus in the middle palmar space was made. Proximal phalanx extended, two distal phalanges flexed 45 degrees from the same line. Incision into middle palmar space disclosed abscess there in communication with the fractured metacarpal. Through-and-through drainage from palm to dorsum instituted. Rapid fall of temperature and pulse followed. Drainage was free. Edema and swelling continued for some time, beginning to decrease, however, at the end of the first week.

January 29 (second day). Temperature 101.5° to $102\frac{1}{6}^{\circ}$; pulse, 70 to 104.

January 30. Temperature, 101° to 103.25° ; pulse, 80 to 108.

February 1. Temperature, 101.5° to 101.25° ; pulse, 100 to 108.

February 3. Temperature, 99° to $99\frac{1}{8}^{\circ}$; pulse, 92 to 104.

February 4. Temperature, $98\frac{1}{6}^{\circ}$ to 99.5° ; pulse, 80 to 92.

February 6. Temperature, 99.5° to 102.5° ; pulse, 88 to 92.

Here the infection evidently extended.

February 9. Temperature, 100.5° to $101\frac{1}{6}^{\circ}$; pulse, 84 to 90.

February 11. Temperature, 99.25° to $104\frac{1}{8}^{\circ}$; pulse, 84 to 92.

February 13. Temperature, 100° to 103.25° ; pulse, 96 to 124.

February 15. Temperature, 100.25° to $101\frac{1}{6}^{\circ}$; pulse, 76 to 90.

Operation: Middle palmar space drained.

February 17. Temperature, 99.25° to 100.5° ; pulse, 96 to 100.

Temperature curve begins to fall and septic symptoms decrease. Sleeps well and begins to eat.

February 19. Temperature, 99.5° to 101.25° ; pulse, 92 to 96.

February 22. Temperature, $99\frac{1}{6}^{\circ}$ to 101° ; pulse, 94 to 96.

Drain removed.

Gradual fall until March 3, when the temperature fell to normal and remained there.

March 20. Temperature and pulse normal; hand still swollen and little movement in fingers; position of digits same as upon entrance; can move all slightly without pain, index most of all; thumb slightly tender to passive movements (fractured). Other fingers: little pain produced by manipulation.

April 20. Hand improved much; much greater range of movement of fingers; evident that nearly full functions will be restored.

In deciding, however, whether or not the middle palmar space has been invaded by injury, it is well to bear in mind that the space lies dorsal to the tendons and superficial vessels; hence these can be uncovered by a lacerated wound, and the space not necessarily become

involved, although it is probably true that unless scrupulous care be taken to give perfect drainage superficially, the space will later become involved, since the fascial sheet separating the tendons from the space is very thin, as has already been pointed out. This same fact is to be remembered in case of a punctured wound, since while the loose cellular tissue surrounding the tendons, superficial vessels, and the lumbrical muscles would harbor pus for a short time, which, if properly drained, need not extend to the space, yet if intervention is withheld for any length of time it must extend either down along the lumbrical muscles, through the fibrous canal at the distal part of the palm already noted, and thence into the cellular tissue dorsal to the web, or break into the palmar space, and in nearly every case the latter result will be found to have occurred long before the former.

Owing to the juxtaposition of the metacarpal bones, particularly of the middle and ring fingers, any crushing injury of the hand, with consequent compound fracture of these bones, will frequently lead to infection through this dorsal wound, as I myself have seen (Case VIII). The metacarpal bone of the little finger, being somewhat distant from the space, is not so likely to open the space, while the metacarpal bone of the index finger (and in exceptional conditions the middle finger) will open the thenar space. Compound fracture of the thumb metacarpal would more likely lead to dorsal subcutaneous accumulations of pus, or even synovial infection of the sheath of the flexor longus pollicis, than thenar space infection. It is well to bear these predisposing etiological factors in mind when we come to discuss the diagnosis of the position of the pus.

Since few lymphatics lead into the *hypothelar space*, and it is isolated from adjacent areas by densely

circumscribed tissue, infection here is due most often to direct implantation. For instance, a palmar infection will rupture into the ulnar bursa or extend, in preference, under the annular ligament, and then rupture into the cellular spaces of the forearm, before it will overcome the resistant tissue intervening between it and the hypothenar space (see Cross-sections, Figs. 24 and 25). The space can be infected, however, from the dorsum, through a compound fracture of the fifth metacarpal, but even there the pus would be more likely to accumulate upon the dorsum, owing to the intimate relation of the hypothenar muscles to the bone, than in the space, unless the injury of the muscles is extensive.

Direct infection of the *subaponeurotic space* can occur by punctured or incised wounds, or by crushing injuries compounded particularly upon the dorsum. The incised wounds, lying transverse to the tendons, would be less likely to lead to subaponeurotic accumulations of pus, owing to the retraction of the aponeurosis by the extensor muscles, thus opening the gap widely so that free drainage would ensue into the subcutaneous tissue, or externally. Longitudinal cuts, on the contrary, would tend to close, and thus prevent free drainage.

The *subcutaneous tissue* is infected in the same manner. It also can be invaded in the pileous infections occurring upon the dorsum, which at times become carbuncular in their nature, thus extending from the skin proper into the subcutaneous tissue.

INVOLVEMENT BY LYMPHATIC EXTENSION.—Besides the direct infection of these spaces, they may become involved by an extension from adjacent injuries, either through the lymphatics, or by continuity of fascial spaces. There is abundant clinical proof that infection by the less virulent germs can spread by lymphatic

channels, and abscesses develop at distant spots. Upon the other hand, it is often impossible to say whether an extension has occurred by means of the lymphatic vessels, or by means of the spaces, and fortunately in these cases it is not necessary to decide the question, since the two courses are generally side by side. Thus, the deep lymphatics pass from the fingers along with the vessels in the same space in which the lumbrical muscle lies, and in a given case, for instance, an infection at the base of the ring finger which spreads into the middle palmar space, who can say whether it extends by means of the lymph vessel or along the lumbrical muscle, going to the radial side of that finger? Moreover, we do not need to know. What is of importance is to know where the pus lies after it has extended, and certainly a study of the course of the lymphatic channels is of importance in relation to this. It is not our purpose to discuss the subject of lymphatic infection as a whole, nor do more than draw attention to the monumental work of Sappey, Leaf, Malgaigne and others, by which we can, in some measure, prognosticate the position of a metastatic abscess when the point of primary infection is known. The subject as a whole will be discussed in a subsequent chapter. The superficial lymphatics upon the palmar surface pursue the shortest course to the dorsum. Thus, for instance, an infection starting upon the distal part of the palm would go between the web of the fingers to the subcutaneous tissue of the dorsum. Hence, should an abscess develop as a result of this, it would be found in the dorsal subcutaneous area. Should a lymphangitis be present, however, without localized abscess formation, the swelling in this region would be just as great, owing to the edema which develops in the loose tissue found here. This will be brought out later in discussing the diagnosis. Should the deep

lymphatics be involved, the infection will follow the deeper vessels, hence passing into the palm. Theoretically speaking, then, an infection spreading from the adjacent sides of the little and ring finger, and the ring and middle fingers, would lead to an accumulation of pus in the middle palmar space, while an infection of the adjacent sides of the middle and index fingers and index and thumb would infect the thenar space. Other infections upon these fingers more dorsal would follow the deep vessels under the aponeurosis upon the back of the hand, thus producing a subaponeurotic abscess. Unfortunately, sufficient clinical evidence has not accumulated to prove these assumptions, although some cases have been reported which tend to support them. Chevalet and Dolbeau, particularly, have presented cases showing this complication, especially those showing extension and development of abscesses under the dorsal aponeurosis. The proof of an extension to the palmar and thenar spaces is much harder to demonstrate, for the reasons that have already been pointed out. But with the accurate outlines of the spaces that we have shown in mind, it is to be hoped that the future will enable us to be more definite upon this point.

Dolbeau has drawn attention to the frequency of infection along the course of the radial in the forearm, due to extension from the thenar region, by means of the radial lymphatics. He also notes the presence of abscesses along the ulnar artery and in the deep tissues in the forearm, originating, he believes, by a lymphatic extension along the anterior interosseous. That these all occur is not only possible, but probable; but in this connection the reader will remember the experimental injections of the palmar space, and the ulnar and radial bursæ where the mass spreads, by continuity of tissue, under the tendons into this middle foyer, and then

involved, secondarily, both the radial and ulnar areas mentioned (Experiments 46 to 49), demonstrating that the same clinical signs and pathological condition can be produced by fascial space or synovial sheath extension as by the lymphatic course, except those cases in which the radial and ulnar foyers are the primary source, or are alone involved.

RECAPITULATION AS TO SOURCE OF INVOLVEMENT OF THE FASCIAL SPACES.—Given a distinct space, from what source, in a majority of cases, is it likely to become involved, leaving out of consideration direct implantation of infection?

The *middle palmar space* would receive infection from the middle finger, ring finger, and radial side of the little finger, with their synovial sheaths and the corresponding lumbrical muscle spaces. Osteomyelitis of the middle or ring metacarpals would also extend to this space.

The *thenar space* would become involved by infection from the index finger and the ulnar side of the thumb and their synovial sheaths, especially that of the index finger and the index lumbrical space. Osteomyelitis of the index and thumb metacarpals could also involve this space, although it would be possible for either of them to be the seat of disease and not involve the space.

The *hypothenar space* would become involved in an osteomyelitis of the fifth metacarpal.

The *subaponeurotic space* would become involved by an osteomyelitis of the middle and ring finger metacarpals particularly, and at times from the little and index metacarpals. Lymphatic abscesses along the deep dorsal vessels would also lie under this sheet of tissue.

The dorsal subcutaneous space communicates freely with the fingers and the thumb.

The lumbrical spaces would be involved by extension from a tendon sheath infection from either side and from an infection at the web between the fingers or a "collar-button" abscess.

EXTENSION FROM ONE FASCIAL SPACE TO ANOTHER.—In the preceding section we have answered the question as to the source of involvement of the various spaces. We now arrive at the next question which confronts the surgeon. With a given space already involved, to what other spaces could the infection extend, and by what course? The question now becomes one more of pathology than anatomy, and while the infection still retains its full relation to the anatomical peculiarities of a part, yet the destruction of tissue incident to long inflammation must be taken into consideration. The longer one studies the question the more prone he is to ask whether many of the complicating extensions are not due either to inadequate treatment, or an improper idea as to the position of the pus, and consequently the institution of incisions which tend to favor the extension of the infection as much as to give proper drainage.

Let us take the *palmar space*. Here the question of extension has been studied by injection. The pus would have a natural tendency to spread in two ways: First, along the lumbrical muscles of the little, ring, and middle fingers, and thus point, in time, in the connective tissue of the web upon the dorsum. This we know has occurred in long-standing cases, in spite of the pseudoclosure of the canal at the lower end and its narrowness, which would thus favor closure by inflammatory exudate (see x-ray plate, Fig. 41, and schematic drawing, Figs. 39 and 45). Secondly, the pus would tend to pass under the annular ligament behind the tendons, immediately over the wrist-joint, thence into the forearm, lying upon the radius, ulna,

interosseous membrane, and its attached muscles, and the pronator quadratus, covered by the flexor profundus digitorum, thus filling the entire space from the elbow to the wrist before it comes to the surface laterally two to three inches above the wrist-joint (Experiment 49). This extension would take place in at least two-thirds of the injections of the palmar space if force were used. But now enters the question of destruction of tissue at the wrist-joint, swelling of the tissues under the annular ligament, and the plastic exudate, which would tend to close this natural exit. That this occurs in a majority of the cases we have abundant clinical evidence. I have not had a single case in which pus extended from the middle palmar space to the forearm, but in corroboration of the experimental data we find the report of a postmortem done by Professor Dolbeau, and reported by Chevalet in his Paris thesis of 1875. The extension under the synovial sheath, without invading it, and the involvement of the forearm, with its diverticulum along the radial, all make a picture the duplicate of Experiment 49. It will be noted that the pus occupies the exact outlines of the middle palmar space, bathes the free portions of the tendons in juxtaposition to the palmar aponeurosis, and yet it is specifically stated that the abscess cavity laid dorsal to the tendons.

CASE IX.—“At the hand the lesion is limited to the middle palmar region; the two eminences, thenar and hypothenar, are intact. In the middle palmar region the aponeurosis is raised with some difficulty, the tissues, infiltrated with plastic matter, form a thick layer as if lardaceous, in the deep part of which are plunged the superficial palmar arch and the terminal ramifications of the median nerve.

“These organs being dissected and raised, one begins to uncover the tendons in their palmar portion, and in

order to be able to examine them in their whole length, the annular ligament of the carpus is incised.

"The sheath of the tendon of the long flexor of the thumb is intact in all its length, at the thumb, at the palm of the hand, under the annular ligament, and above this ligament the cul-de-sac by which it terminates. Let us recall that it is upon the thumb that the initial wound is found, the point of departure of all the trouble. But the sheath of the flexor longus pollicis is absolutely intact.

"In examining the ulnar sheath one finds the following: The portion of this sheath destined to cover the tendons of the superficial flexor is little altered, and these tendons, save that of the little finger, are relatively intact. The portion of the sheath destined to the tendons of the deep flexor is much more diseased, especially at the level of the tendon of the little finger. In examining the sheath of this tendon, one finds it intact in its digital portion. The tendon presents there its mother-of-pearl appearance, and is absolutely sound. But if one follows it to the palm of the hand, one sees it penetrate into a purulent foyer, which occupies the deep part of the hand. The tissue about bathed in pus is diseased. Likewise the tendons which it envelops for a stretch of about 4 cm. of the tendon of the little finger, of 2.5 cm. to 3 cm. of the other tendons, index, middle, and ring. Above this point the sheath and the tendons take again their character of integrity and keep it in the carpal canal, even to the terminal cul-de-sac of the sheath.

"In raising the tendons of the deep flexor, one begins to uncover a purulent foyer occupying the profound palmar region, situated exactly upon a median line (par rapport) in relation to the axis of the hand, and corresponding exactly to the deep palmar arch that one sees placed against its posterior wall. Its anterior

wall is formed by the sheath of the deep flexor tendons that it flooded over. It is prolonged the length of the sheath of the tendon of the little finger, had opened it and pus had penetrated and traversed it in such a manner as to come to show itself beneath the palmar aponeurosis; but, a thing to notice, it had not spread into this sheath, neither at the lower part, toward the little finger; more in the upper part in the carpal canal.

"The radiocarpal articulation is filled with pus; its cartilages are destroyed, the osseous surfaces which supported them are eroded. The triangular ligament partly destroyed allows the radiocarpal articulation to communicate freely with the inferior radiocubital articulation.

"The articulation of the first row of the carpal with the second is in the same condition; likewise the articulation of the bones of each row between them, especially of the first. What is the origin, what has been the mode of production of this suppurative arthritis of the wrist? It is a question not easy to decide, but that which can be affirmed is that the lesion so limited by the sheath has not been there for nothing, since this sheath is intact at the level of the articulation.

"In dissecting the forearm, one is struck, first of all, by the apparent integrity of its anterior region. The lesions are, in fact, very deep. Alone, the sheath of the radial vessels appears diseased from the first inspection. It is, in the inferior half of the forearm region, infiltrated with a plastic matter which gives to it the appearance of a whitened cord with granulated surface. The artery, plunged in the middle of this plastic matter, is detached from it only with difficulty, and by dissecting it with care. The sheath of the ulnar is intact; the median nerve presents nothing at all

particular; the muscles are intact also; at least those of the superficial layers, because in dissecting the deep flexor one finds beneath it, or rather in its thickness, in front of and inside of the ulnar bone, a purulent foyer of about the volume of a small egg. This foyer, situated at the middle part of the forearm, well limited below, at least upon the anterior region of the forearm, is without communication with the lesion of the palm of the hand, and, with that which we shall see presently, exists at the level of the pronator quadratus. In seeking what has been its point of departure, one finds it at the side of the ulnar bone. This latter has been the seat, in its inferior half, of the suppurative periostitis, and is almost totally denuded, even to the middle of its length. The foyer that we have just indicated is a tributary of the subperiosteal foyer which bathes the bone from the back and the inside. The origin of this periostitis appears to have been the rupture of the articulation full of pus, which was opened from the back.

"In raising, at the wrist, all the tendons, the flexors, one begins to uncover a second foyer situated between these tendons and the pronator quadratus. This muscle, altered but not destroyed, separates this foyer from the ulnar bone, so that there exists no relation between it and the osseous lesion. On the contrary, this foyer communicates by the proper canal, behind the sheaths of the tendon, with the palmar foyer."

We now ask ourselves, What are the probabilities for extension when these normal exits are closed? In what way will the inflammatory destruction of barriers show itself? The pus cannot break through the firm palmar aponeurosis. We first turn our attention to the adjacent thenar space. We remember that the lower, or distal portion of the intervening wall is very firm, but that at the proximal end the dividing tissue

is rather thin, and it is very easy to suppose that the infection may destroy this and thus invade the radial side. Experimentally, this can be seen to occur (Experiment 20, Fig. 41). This, however, would not occur until late, since most of the pus is at the distal part of the hand. But that it does occur frequently in neglected cases I have abundant clinical evidence. It is one of the most common of the extensions.

Again, the pus might extend along the lumbrical muscle of the middle finger, and rupture from here into the thenar area.

Upon the hypothenar side there is so much tissue intervening between the middle palmar space and the hypothenar that we would expect this to become involved only in exceptional cases.

Text-books all tell us that the pus in these cases finds exits between the metacarpal bones, and thus escapes to the dorsum. When one studies the dense layer of fascia spreading from bone to bone, upon both the volar and dorsal surfaces, being really an anterior and posterior interosseous membrane, with the interosseous muscles between, and a division between them being often difficult to find, we are led to wonder if this complication really occurs as early in the course of the disease as we are led to believe. Whether often the edema upon the dorsum may not have been mistaken for pus, and the spurious corroboration obtained by through-and-through drainage misinterpreted. By no means can it be denied that at times, later in the course, the pus does find this means of exit. When it does, it first comes to lie in the subaponeurotic, and then in the subcutaneous tissue. I personally have never seen such a case unless there was an osteomyelitis of the metacarpals or carpal bones, and I believe it to be uncommon.

Another cause of extension is sometimes seen in

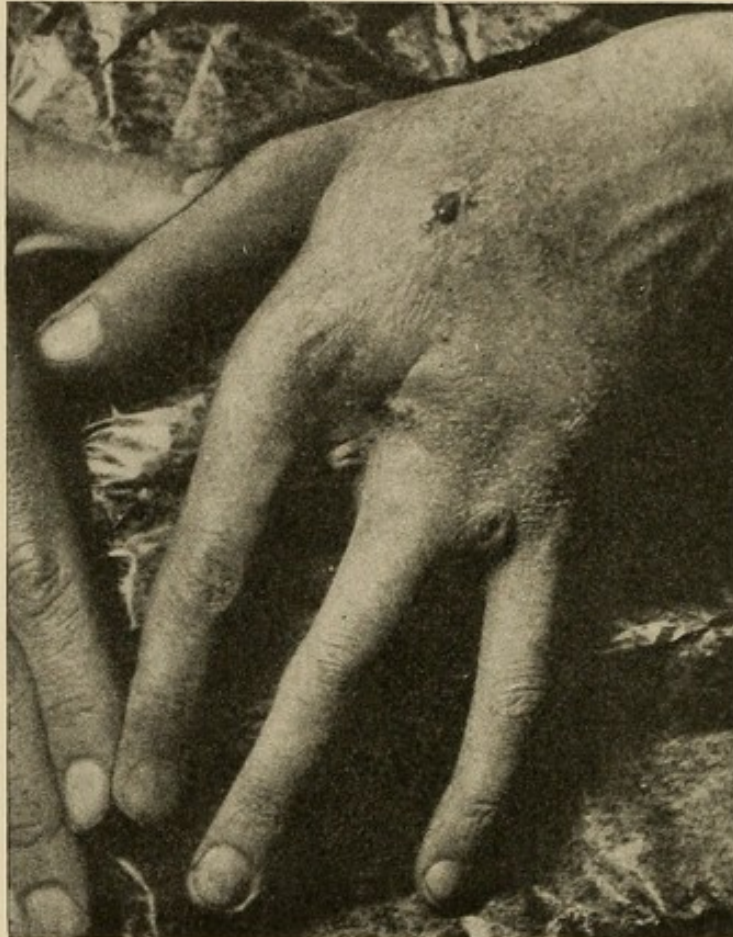which the ulnar bursal sheath is destroyed, and pus thus enters the sac, spreads along the tendons, and ruptures into the forearm in the same space we have already described as lying under the flexor profundus.

Suppose our *thenar space* to be primarily involved; the pus here does not so readily extend into the forearm (Experiments forcible, Nos. 29 to 33). Here probably the weakest place lies toward the dorsum, either above or below the adductor transversus, thus invading the tissue between the thumb and index metacarpal, and between the adductor transversus and first dorsal interosseous, where there is a large, cone-shaped cavity (see Experiments Nos. 29 to 32). It should be borne in mind, however, that this result is not obtained easily, since the pus will often remain for days confined to the thenar space (Case X). In long-continued or anomalous cases it can spread up along the lumbrical muscle of the index finger, infect the loose connective tissue about the palmar tendons, and thus infect the palmar space, or can rupture through at the upper end (Experiments 29 to 35). This complication should be rare, however, in properly treated cases.

In case the *subaponeurotic space* is infected by extension from the palmar space or otherwise, there might be considerable variation in the course the pus would pursue; if the sheet is dense, as it is in a majority of cases, the suppurative process would tend to extend under the aponeurosis and point laterally, upon either side, at the thinner tissue there, thus becoming subcutaneous, or at the distal margin between the metacarpophalangeal joints, as I myself have seen. However, at times there are thin places between the tendons, and then the purulent matter would become subcutaneous through this small opening. In all prob-

ability, however, before any of these things happen, operative interference will have opened the abscess (Fig. 64).

FIG. 64



Scars showing where subaponeurotic abscess has pointed. Note four openings at the edge of the aponeurotic sheet. Note prominence of tendons, *i. e.*, suppuration beneath.

CHAPTER XII

THE SPREAD OF INFECTION FROM ANY GIVEN PRIMARY FOCUS

THIS will be discussed under three heads—the possible spread from primary foci on the fingers, from foci on the palm, from foci on the dorsum.

THE PROBABLE EXTENSIONS FROM PRIMARY FOCI ON THE FINGERS

THE SPREAD OF INFECTION INVOLVING THE INDEX FINGER

The index finger having received a severe injury, causing a deep infection, we admit that the infection can spread by three methods: (*a*) Lymphatic; (*b*) fascial; (*c*) through the synovial sheath. The subject of lymphatic extension is discussed in Chapter XXI. The extension by the fascial spaces is easy to follow when we study the series of cross-sections (Figs. 19 to 26). Here we see there is loose connective tissue surrounding the phalanges in which it could spread with only moderate difficulty; upon the dorsum it might go up into the subcutaneous tissue in the back of the hand. Internally, it would come to lie in the cellular spaces at the web between the index and middle fingers, and could even spread along the lumbrical muscle of the middle finger into the palm, and thus invade the middle palmar space. This, however, would be more likely to occur in a deep inflammation involving the proximal phalanx of the middle finger, if at all; since, as a general rule, the pus would come to the surface before extending along the lumbrical canal.

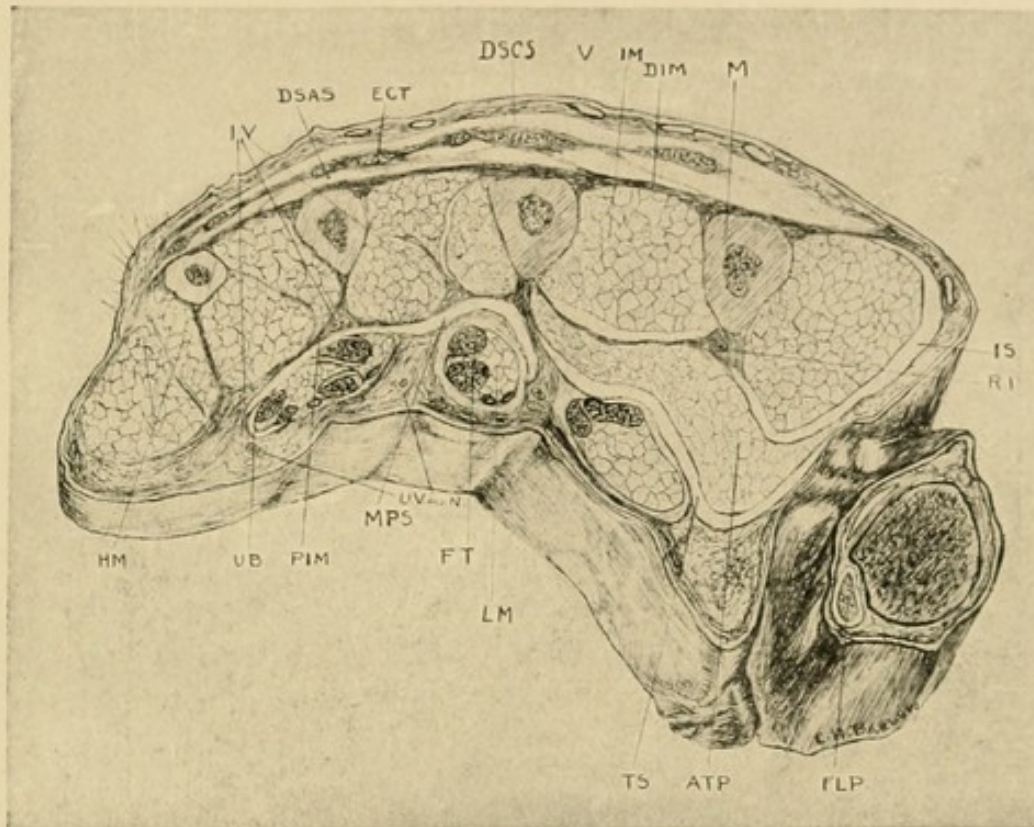
Upon the radial side of the index finger there would be still less likelihood of the pus entering the lumbrical canal in preference to coming to the surface, since this canal is not so well marked. Of course, it could not extend upon the volar side into the palm, because there is no connecting space (see cross-sections 20 and 22). Again, we note that if the pus were under the dorsal aponeurosis of the proximal phalanx, it would be limited to this area, since it is a closed space and does not communicate with the subaponeurotic foyer upon the dorsum of the hand. Thus, we see that while it is possible for the thenar space to become infected by fascial space extension, it is not probable. However, a metacarpophalangeal arthritis may develop with destruction of the bone and ligaments. This extension then becomes not only possible, but probable, since the metacarpal bone of the index finger lies in juxtaposition to the thenar space, separated, however, in part, by the adductor transversus. Pus would probably first enter the space between the adductor transversus and the first dorsal interosseous, then pass into the thenar space.

The question now arises, however, Should the pus lie either primarily or secondarily in the subcutaneous tissue upon the dorsum of the hand in the region of the index metacarpal, could it spread around the radial border of the index metacarpal into the thenar space? Again, should it lie in the subcutaneous tissue between the index and thumb metacarpals, could it pass under the web into that space? The study of the cross-sections (Figs. 65 and 66) as well as the experimental injections (Nos. 39 and 40) seem to show that this is not probable. Clinical evidence can be adduced to corroborate this. The pus would rather come to the surface upon the dorsum. The subaponeurotic accumulations, unless complicated by an osteomyelitis,

would also follow the same course (see Experiments, 43 to 45).

We now come to the third method of extension—by the index synovial sheath. Let us suppose that the

FIG. 65

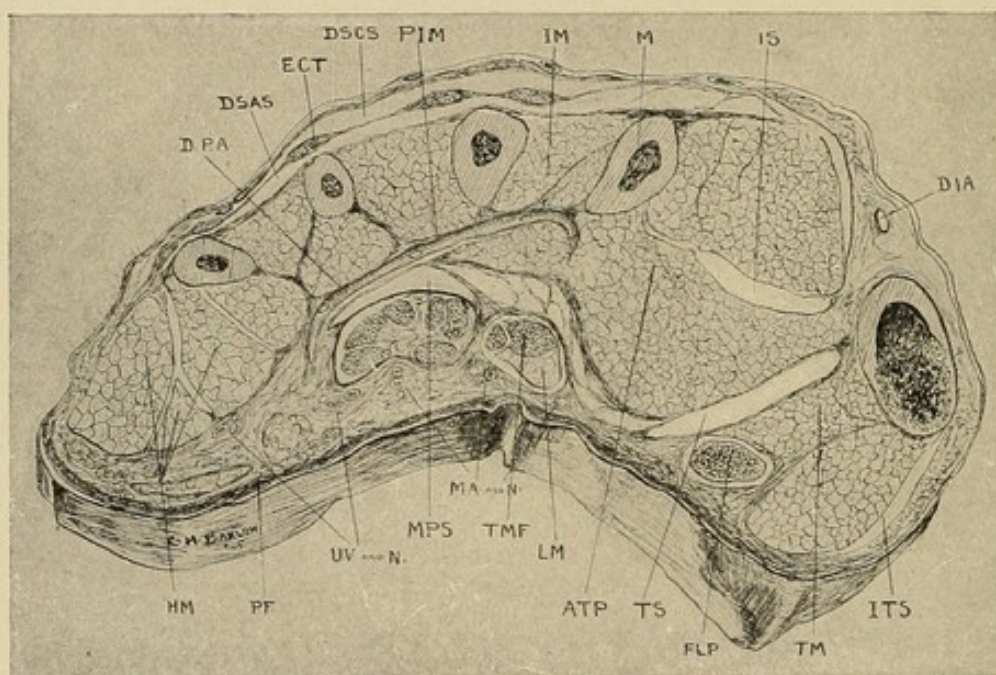


Cross-section No. V.— $3\frac{1}{2}$ cm. proximal to joint. Lettering common to all plates: *SS*, synovial sheath; *DSCS*, dorsal subcutaneous space; *DSAS*, dorsal subaponeurotic space; *ECT*, extensor communis tendon; *FT*, flexor tendon; *LM*, lumbrical muscle; *IM*, interossei muscles; *M*, metacarpal bone; *BV*, bloodvessels; *N*, nerves; *TS*, thenar space; *MPS*, middle palmar space; *ATP*, adductor transversus pollicis; *DIM*, dorsal interosseous membrane; *PIM*, palmar interosseous membrane; *UB*, ulnar bursa; *IS*, space between adductor transversus and first dorsal interosseous; *DIM*, dorsal interosseous membrane; *FLP*, flexor longus pollicis in its synovial sheath; *HM*, hypothenar muscles with intermuscular spaces; *IV*, interosseous vessels and nerve.

synovial sheath has become filled with pus and an extension taken place into the hand along this sheath. Here the anatomical, experimental, and clinical evidence is clear (cross-sections, Figs. 65 and 66;

Experiments 8, 9, 27, and 35; Case X). Having ruptured from the proximal end of the sheath, where it is very thin generally, the pus would lie in the loose connective tissue which surrounds this tendon and the lumbrical muscle. After a short time, as the infection persisted, or the accumulation of pus grew, it would follow the lines of least resistance, and run along the lumbrical muscle toward the radial side of the index

FIG. 66



Cross-section No. VI.—Through distal part of thenar area. See Fig. 63 for common lettering: *ITS*, indefinite thenar spaces; *TMF*, tendon of middle finger; *TM*, thenar muscles; *PF*, palmar fascia; *RA*, radial artery; *DPA*, deep palmar arch—digital branches beginning; *DIA*, dorsalis indicis artery.

finger (Experiment 8, Fig. 40), and, being limited here, would then rupture through the thin sheet of fascia, separating this tissue from the thenar space (cross-sections, Figs. 65 and 66), and thus become a thenar space infection. (For a complete discussion of tendon-sheath extensions, see Chapters IX and XII.)

The following case corroborates these deductions:

CASE X.—Seen in the service of Prof. F. A. Besley at the Post-Graduate Hospital.

Diagnosis: Infected wound of index finger, tenosynovitis of index tendon, infection thenar space, ultimate amputation of finger.

September 2, 1904. T. W. Ten days before coming to the hospital the patient cut his finger just above the knuckle-joint on a tin can; wound slightly to radial side of dorsum. This became infected, and the patient consulted a physician, who opened the wound and passed a drainage tube through and across dorsum, coming out between the index and middle fingers. Upon examination the finger was seen to be much swollen, as was the entire hand, particularly the dorsum. Several openings appeared about the proximal phalanx. A probe into one of these found rough bone and easily entered the knuckle-joint. The entire finger and hand were slightly tender, but marked and conspicuous tenderness was elicited over the site of the tendon sheath, and sharply limited by it, being most acute at proximal end, over the metacarpophalangeal articulation. Flexion of finger did not increase pain; extension of index finger caused marked pain through finger, but most sharply noted by patient at proximal end of sheath. Extension of other fingers caused little increase of pain; no particular pain on dorsum of finger where cuts were found. Temperature, 101° ; pulse, 92. Infection of foot present also, as well as small boil on opposite shoulder. Epitrochlear and axillary glands swollen out of proportion to those in left arm. (Patient's resistance is evidently far below par.) Systemic symptoms marked. Neutrophilia, 94 per cent.

Clinical Diagnosis: Infected wound of hand; probably staphylococcus; infected index tendon sheath; extension to glands of axilla and elbow and, in addition, infection of skin on shoulder and in foot. Etiology of latter unknown—possibly pyemic from hand; infected knuckle-joint.

Prognosis: Will probably lose finger.

Operation: Tendon sheath opened from end to end. Pus in moderate amount evacuated. Dorsal openings previously present enlarged. Hot boric dressings. Foot opened and drained. Temperature ran 99° to 101° every day.

September 9. Finger shows fluctuation on dorsum of hand just proximal to index finger and ulnarly. Incision and drainage. Finger not so painful; flexion about same. Not so tender; no special swelling in palm of hand.

September 12. Infection has extended to thenar eminence; tenderness localized to this area. Swelling marked; palm not involved.

Operation: Inserted forceps into cut on dorsum made September 9; forceps fell into direct communication with volar surface of thenar eminence; opened here; pushed forceps then from volar surface through to dorsum between first and second metacarpals; forceps passed through dorsal skin with little or no resistance; drainage inserted.

September 15. Subcutaneous abscess has developed in radial region of forearm above wrist and above elbow, and over brachial vessels; incised and drained. White blood cells, 18,000.

September 24. Temperature, 99° to 101°.

October 14. Temperature has been running 99° to 100° for last two weeks; index finger swollen to four times its normal size; blue, and evidently an osteomyelitis of the proximal phalanx, and a suppurative arthritis of metacarpophalangeal joint.

Operation: Index finger and head of metacarpal bone amputated; drainage.

October 20. Condition of hand much better.

Following this the patient improved rapidly; discharged.

November 3, 1904. Small area of granulation tissue over amputated area; moves thumb and three fingers three-fourths of normal; wrist-joint same; function of all will ultimately be restored.

THE SPREAD OF INFECTION INVOLVING THE THUMB

Infection of the thumb would at first glance seem to offer the most favorable course for pus to extend into the thenar space. But let us consider for a moment. Lymphatic extension does offer some chance, if the infection be deep and upon the ulnar side, as will be pointed out (Chapter XX, and Fig. 99). Upon the other parts, however, the tendency would be for the pus to be carried away from the space.

The synovial sheath of the flexor longus pollicis lies some distance from the space, and hence pus would tend to come to the surface if the sheath ruptured in its course. It can be seen, however, that if the sheath ruptured in its distal part, and the infection thus became an infection of the connective-tissue spaces, it could spread along the ulnar side of the thumb, and by considerable destruction of connective tissue come to lie upon the origin of the adductor transversus, and thus invade the space. In the majority of cases, however, the pus would rupture from the sheath into the forearm. (For a complete discussion of tendon-sheath extensions, see Chapters XII to XIV.)

Should the infection be upon the back of the thumb, the pus would extend more easily into the dorsal subcutaneous tissue of the thenar area, while, in all probability, upon its radial side it would point upon the surface.

THE SPREAD OF INFECTION INVOLVING THE MIDDLE FINGER

Here the finger, lying as it does in the dividing line between the thenar and middle palmar spaces, becomes an extremely interesting subject of study. The lym-

phatic extension has already been touched upon and will be discussed further in Chapters XX to XXIV.

Extension from the synovial sheath at its proximal end gives positive results experimentally (Experiments 1 and 2), since in every case the mass extended into the middle palmar space after rupturing through the indefinite connective tissue, separating it from the space, as already described under the index finger discussion. It is to be borne in mind, however, that the lumbrical muscle joining this tendon comes back to pass under the transverse ligament, between the index and middle fingers, and that while the tissue intervening between this muscle and the thenar space is firm, and experimental injections have failed to rupture through, yet, anatomically, it would seem to be possible in some cases. Clinical evidence shows that while it does occur this extension is rare. For a complete discussion of the extensions from the tendon sheaths, see Chapter XIV. Should the infection be a deep-seated accumulation of pus in the cellular tissue upon the dorsum it could spread subcutaneously upon the back of the hand; upon the radial side it would pass exceptionally along the lumbrical muscle into the middle palmar space, with the possibility of invading the thenar space, as above noted; upon the ulnar side, if it should spread along the lumbrical muscle, it would go into the middle palmar space (Experiments 26 *A*, and 26 *B*)

Subaponeurotic infection would be limited to the phalanx, while osteomyelitis, involving the metacarpal bone, would tend to invade the middle palmar space in front and the subaponeurotic on the back.

THE SPREAD OF INFECTION INVOLVING THE RING FINGER

Here there is little doubt about the relation between this finger and the middle palmar space. The exten-

sion by the dorsal subcutaneous tissue may be in any direction. The lymphatic extension will be discussed in Chapters XX and XXI. The connective-tissue spaces at either side of the finger and in the web of the infected hand allow the pus to spread through the fibrous canal surrounding the lumbrical muscles and lead into the palmar space (see Experiments 26 *A* and 26 *B*, and Fig. 37). In making this deduction it should be emphasized again that in a majority of cases pus would be evacuated on the surface before it would burrow through this canal. Hence it is only in neglected cases that this complication would ensue, unless extension had taken place by the lymphatic channels which pass through these same canals.

Suppuration extending from the synovial sheath would enter the middle palmar space (Experiments 2, 4, 18, 19, and 20; cross-sections, Figs. 65 and 66). Primarily, of course, it would lie in the loose connective tissue superficial to the space, spread down along the lumbrical muscles (Fig. 36), especially of the little, ring, and middle fingers, and then, destroying the thin roof of the space, would involve the entire middle palmar space. (For a complete discussion of tendon sheath extensions, see Chapter XIV.)

Arthritis of the metacarpophalangeal joint, with osteomyelitis of the diaphysis of the metacarpal, could also infect this space, as well as the subaponeurotic on the dorsum (Case VIII).

INFECTION SPREADING FROM THE LITTLE FINGER

Here the lymphatic channels and connective-tissue spaces upon the inner side of the finger could lead into the middle palmar space, although such extension is uncommon. On the outer and dorsal side they would tend to lead into the subcutaneous tissue externally.

The synovial sheath, if continuous with the ulnar bursa, would probably rupture earliest in the forearm (x-ray plate, Fig. 39). (For a discussion of this, see Chapters IX and XIV.) If it did rupture in the hand, or if the synovial sheath of the finger were shut off from the ulnar bursa, and the finger sheath ruptured, it would tend to involve the middle palmar space (Experiments 5 and 6). It might be mentioned here that Chevalet and Dolbeau maintain that a rupture of the sheath is not necessary to extension, but that this can take place from the sheath by lymphatic extension, and they adduce a postmortem examination in support of their contention. This, however, is an academic question, since the same space would be involved by the extension, and the clinical findings would be identical. (For a complete discussion of the tendon sheath extension, see Chapter XIV.)

In an osteomyelitis of the fifth metacarpal, the hypothenar space would be involved upon the volar surface and the subcutaneous tissue dorsally (cross-sections, Figs. 65 and 66).

INFECTIONS BEGINNING IN THE PALM AND DORSUM

When a primary focus appears upon the palm, if it is a punctured wound, the abscess may develop in any of the pockets I have described, if implanted there under the palmar fascia. If in the thenar or hypothenar area, they may develop local abscesses without entering the palmar or thenar spaces. If the infection develops at the distal part of the palm in the subcutaneous or lumbrical spaces, it will follow the course described on p. 208. In the central part of the palm it is not possible for large abscesses to develop between the skin and the palmar fascia, owing to their intimate association. Lymphatic infections in the central part

of the palm may involve the deeper part of the hand (Fig. 101). At the sides the infection pursues the shortest course to the back of the hand, where abscesses may develop subcutaneously. At the proximal end of the palm secondary lymphatic abscesses may develop subcutaneously above the anterior annular ligament (see Chapter XIV).

When the primary focus develops upon the dorsum, if it be a localized abscess it will be either in the subcutaneous or subaponeurotic spaces. If extension takes place by contiguity or lymphatic channels, the secondary abscesses lie upon the dorsum of the forearm or the glandular areas at the elbow and axilla.

CHAPTER XIII

PATHOLOGY OF TENDON SHEATH AND FASCIAL SPACE ABSCESSSES

THE discussion is here limited to changes in the tendons, tendon sheaths, and fascial spaces. The pathology of bone changes, arthritis, and secondary sequelæ in the hand and forearm will be taken up later.

A classification of the changes incident to tenosynovitis may be made as follows:

Primary. *A.* Changes while the infection is limited to the sac: (1) Contents of sac, serum, tendon. (2) Wall of sac. (3) Circulation, lymphatics with edema.

B. When rupture of the sac occurs: (1) Involvement of the fascial spaces, (*a*) hand, (*b*) forearm. (2) Involvement of the nerves. (3) Involvement of joints. (4) Involvement of bones.

Secondary. (1) Tendon adhesions. (2) Ankylosis of joints. (3) Persistent edema and hyperplasia of cellular tissue; scar contraction with subsequent atrophy. (4) Chronic osteomyelitis.

The changes occurring in the section under "Primary *B*," will be discussed under fascial space abscesses following, and the "Secondary" changes will be discussed in detail in later chapters, dealing with the complications and sequelæ of infections (see Chapter XXVIII).

THE TENDON SHEATH PROPER

Anyone who has had occasion to open the acutely inflamed tendon sheath has been surprised at the rapid

change which has taken place. The changes are comparable to a pressure necrosis, but whether due to the great toxicity of the streptococcus infection or the great edema about and the effusion into the sheath, shutting off the blood supply, may be a question.

The serum in the sac in the more acute cases is normally scanty in amount and only slightly tinted. The consistency varies from a slightly slimy fluid to a thick pus. While in the more acute varieties the amount may at times be very great, it soon ruptures, and on operation we may find little or much in the sac; in the more chronic type we frequently find a large amount of thick, creamy pus, even though rupture has ensued.

The wall of the sac is congested and edematous with the exception of the part under the anterior annular ligament where the pressure is great. Here necrosis, not alone of the sheath, but also of the tendons, is prone to occur. While we may find the synovial wall clear and unchanged, we generally find it cloudy with whitish-yellow spots of beginning necrosis, or we may find even early the entire wall seminecrotic. Even in these cases we are often surprised at the reparative possibilities after drainage is instituted.

The tendons themselves are swollen, but retain their glistening synovial covering for some time. At the wrist, however, the tendons show the result of compression by the non-distensible anterior annular ligament being pale and compressed; this is accentuated by the swelling which has occurred both above and below the ligament. If the case has been left untreated for too long a time, the tendons lose their glossy covering and, becoming necrotic, are extruded, looking like grayish strings of connective tissue.

While the entire hand partakes of the edema, it is in the finger involved that the most extensive and persistent changes occur. Especially in the neglected

cases do we see a most extensive exudation of inflammatory elements which persist for weeks after the acute process has subsided; this is followed by an atrophy of the entire finger, ankylosis of joints and impaired nerve function, which aids materially in preventing a proper use of the finger even if the tendon is not destroyed. The adhesions between the sheath and the tendon combined with these serious sequelæ make an almost hopeless prognosis as to function in the neglected cases.

If the ulnar bursa has been involved, the ultimate result is the characteristic claw-hand.

THE FASCIAL SPACE ABSCESES

In discussing the essential pathology it should be remembered that we are restricting ourselves strictly to that phase of the subject having a relation to the anatomical and experimental studies preceding. The pathology of acute abscess formation in connective tissue is too well known to merit discussion here. Moreover, to do more than mention the arthritis in the wrist, the osteomyelitis of the metacarpals, and the destruction of tissue and fistulous sequelæ would be out of place, since these will be discussed in the chapters dealing especially with these subjects. We should, however, draw attention to certain consequences of suppuration in the individual spaces.

Let us ask ourselves what would be the after-results of infection of the middle palmar space alone, the tendon sheath not being opened. We shall divide them into primary and secondary; and under the caption of primary, attention should be drawn to the fact that the scar tissue following such a process would involve particularly the tendons of the middle and ring fingers, with the lumbrical muscles of the middle, ring,

and little fingers. Consequently, it is in these fingers that we would expect to find the most persistent adhesions and contraction; and it is in consequence of the disturbed circulation in the bloodvessels going to these fingers that long persisting edema and nutritional changes occur, augmented somewhat, probably, by impaired nerve supply.

Secondary sequelæ are noted in the associated edema and changes in the index finger and the thumb, and while these are severe, they are not of such high grade as in others. These changes are most marked in the index finger, and are due to the juxtaposition of the tendons and the intimate relation of the circulation. Moreover, the ulnar bursa, with its contained tendons, is adjacent to the area of infection; consequently, there is the probability of a low grade of inflammation within. Again, the corollation of movement between the tendons determines approximately the same position for the index finger as the others. This constant position, associated with an effusion into the joints, leads to adhesions of the articular surfaces in all the fingers, the thumb least of all, since the tendon of the thumb is well separated from the site of infection. Should the process extend to the thenar area, the index finger would then be in the same condition as the other fingers. On the other hand, if the infection were primary in the thenar space, the most disastrous changes would ensue in that finger, while the other three fingers would suffer only the secondary changes, but fortunately not so severe as the secondary changes were in the thenar space when associated with palmar infection. This is owing not alone to the comparative size and complexity of the areas, but also to the fact that thenar abscesses are sooner recognized and drained more perfectly; consequently the process is not so disastrous.

Should the subaponeurotic space be involved primarily, or by an extension from the palmar space, secondary adhesions take place, and the whole sheet becomes more or less immobile as a consequence of the involvement of all the extensor communis tendons. Should proper treatment be resorted to even after a number of days, all of these changes will disappear and a perfectly functioning hand be assured.

CHAPTER XIV

THE SYMPTOMS, SIGNS, AND DIAGNOSIS OF TENOSYNOVITIS AND FASCIAL SPACE ABSCESES

THE SYMPTOMS, SIGNS, AND DIAGNOSIS OF ACUTE TENOSYNOVITIS

To diagnosticate the onset of involvement of the tendon sheaths is one of the most difficult problems in surgery; and yet withal one of the most important. I know of no place where calm judgment is more required, since the symptoms and signs are all of degree. It must be said, however, that more extensive experience has taught me that it is generally better to err by making an unnecessary incision than by failing to operate where it is needed.

The three cardinal symptoms and signs are:

1. Excessive tenderness over the course of the sheath, limited to the sheath. This symptom is by all odds the most important.
2. Flexion of the finger.
3. Excruciating pain on extending the finger, most marked at the proximal end.

These symptoms are seen to be only a difference in degree from those found in any infection of the hand, but when sought for in an intelligent manner there is not much difficulty in differentiating the conditions.

A patient applies to the physician with what is evidently a serious infection. If there has been a crushing injury, the probability of an infected tendon sheath is great; on the other hand, it frequently arises from simple cuts, as, for instance, a slight laceration

from a tin can or from the prick of a needle. The pain has increased in severity after a day or two. The systemic symptoms of infection may be present. The finger and the corresponding side of the hand at least are edematous. In addition to the tumefaction in the infected finger the adjacent digits are swollen. The back of the hand particularly is edematous. The whole hand is slightly tender to superficial palpation. The fingers are all slightly flexed. Now, how shall the differential diagnosis be made? Press deeply and firmly in all parts of the hand and fingers; the patient will volunteer the information that all points hurt; but if the tendon sheath is involved, pressure upon it throughout its course causes an immediate and involuntary expression of pain, and while before the patient has allowed his hand to remain passive in yours, he will now attempt to withdraw it voluntarily, and there is no doubt in your mind of the exquisite tenderness over this area. If this tenderness is outlined by the extent of the sheath, your diagnosis is nearly made. As a matter of fact, the greatest tenderness is generally complained of on deep pressure at the proximal end of the finger sheaths in the palm of the hand, just over the metacarpophalangeal articulation. I have seen a lacerated wound on the back of the finger, which was inflamed and naturally tender, show much less sensitiveness than the infected sheath on the opposite side of the finger where there was no injury. Now make passive extension of the finger, and the patient immediately complains of severe pain along the tendon sheath, very often again most marked at the site of the metacarpophalangeal articulation. This is a valuable symptom. The flexion of the fingers is of less importance and is probably due to several factors—the arthritis in the finger-joints, possibly irritation of the adjacent filaments of the median or

ulnar nerve, and again, possibly because it lessens the tension upon the tendon. The finger is generally held rigid in that position and a difference is readily seen between the simple flexion occurring in the adjacent swollen fingers and the rigid flexion of the infected finger. So marked is this that often one is able to diagnosticate an extension into the palmar sheath, for instance, from the little finger sheath, since the character of the flexion changes in that case at once in the fingers supplied by these tendons which pass through this common sheath. Mauclaire has described a claw-hand position, but I have not found it to be characteristic of acute inflammation, but to be rather the evidence of an old chronic untreated tenosynovitis.

There are two clinical types to be differentiated. First, that variety in which the infection is a local one, generally of staphylococcic origin, commonly following lacerated wounds. Here we have a local infection beginning slowly; plastic adhesions may be present, limiting the infection to a particular part. There is a little general reaction, but the local evidences of inflammation are marked. A second type is that in which the injury is generally a slight one, a pin prick or an insignificant cut. It is generally of streptococcic origin. The infection is carried to the sheath by lymphatics. The pain is severe, and within a few hours the finger is greatly swollen, red, and exquisitely tender. The evidences of toxemia are present early, but the red lines running up the arm, indicative of a lymphangitis, are absent, although they may have been present early (see Case XVIII). This type, not having a tendency to plastic adhesions, spreads rapidly throughout the entire communicating system of sheaths. This is distended with a fluid, at first only cloudy, but rapidly becoming purulent, and on examination we find thick pus with fragmented nuclei, due probably to the

virulent toxins, and here and there streptococci. This type is prone to produce early rupture and extension into the connective-tissue spaces.

The spontaneous pain, which was at first severe, grows less as the edema develops, and may delude the surgeon into believing that the process is subsiding. The arm seems to "fall asleep," as the patient expresses it. Paresthesias, with creeping and itching sensations, may be present, and especially after rupture of the sheath the tenderness may subside to a considerable degree, leading the surgeon to an early erroneous conclusion.

SYMPTOMS, SIGNS, AND DIAGNOSIS OF EXTENSIONS FROM INFECTIONS BEGINNING IN THE LITTLE FINGER

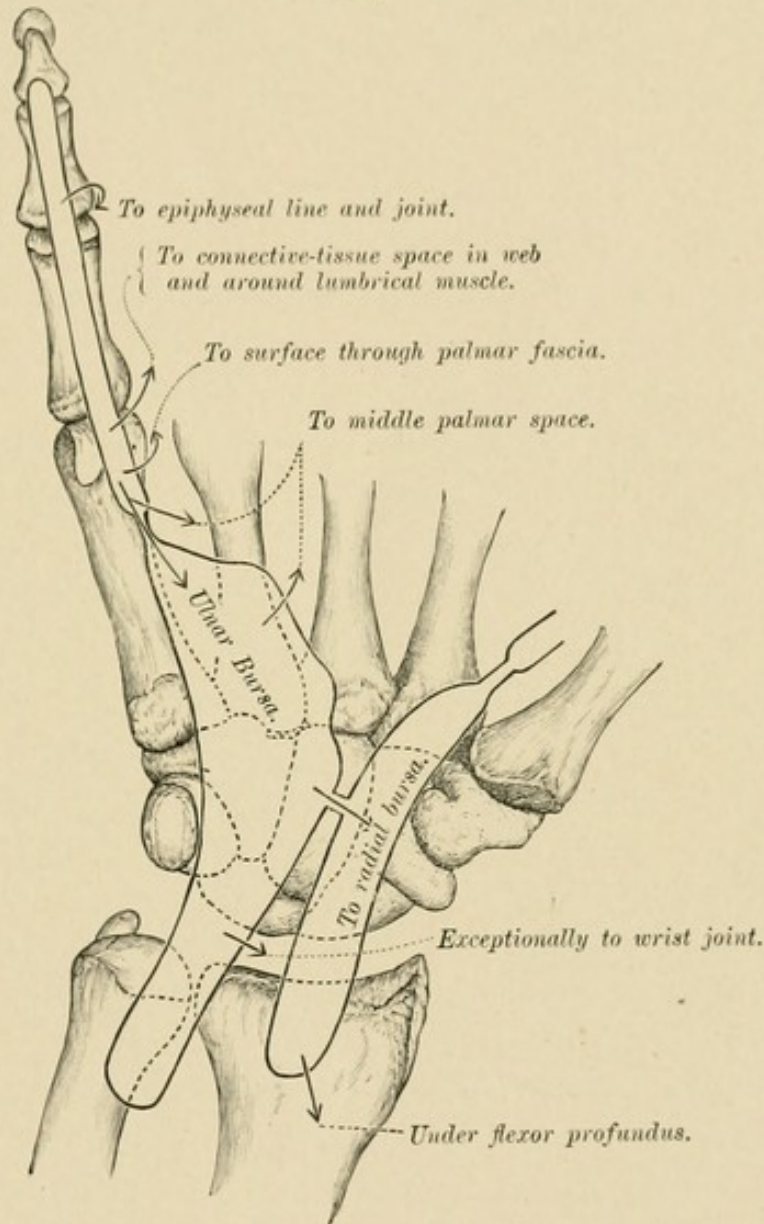
An infection of the sheath of the tendon in the little finger may be localized to the finger. Extensions to other areas are probable, however (Fig. 67). The following are the most common: (1) The ulnar bursa; (2) the radial bursa; (3) the forearm; (4) fascial spaces in the hand, (*a*) middle palmar space, (*b*) lumbrical space; (5) osseous involvement, middle phalanx; (6) joints, proximal interphalangeal, wrist; (7) rupture to the surface.

EXTENSION TO THE ULNAR BURSA.—In the fulminating type, where the opening between the ulnar bursa and the sheath in the little finger is present, the infection extends rapidly throughout the hand. It should be noted here that the frequency of extension from the one to the other is greater than the anatomical opening would explain; we are therefore led to conclude that the opening is present much more frequently than is stated, or there is some other method of extension, possibly by the lymphatics.

This extension is often difficult to diagnosticate.

It is marked by the development of edema in the hand, especially upon the dorsum. A general fulness in the palm is found, but the palmar concavity is still present.

FIG. 67



Schematic drawing showing the various probable extensions from an infection of the tendon sheath of the little finger.

On the flexor surface the greatest swelling is just proximal to the annular ligament. This is not necessarily due to the rupture of the sheath here, but to the looseness of the tissues which permits of distention.

This swelling is accentuated by contrast with the non-distensible annular ligament distal to it. The swelling in the palm occurs at the same time, but is not so conspicuous, owing to the palmar fascia. This also diffuses the swelling so that it is not accurately limited by the outline of the ulnar bursa. Moreover, the surrounding edema tends to confuse the picture. In relation to this Forssell states:

"One very seldom finds in acute infections of the bursæ so great a collection of pus within the latter as to cause a purely mechanical swelling of such extent that one can easily see it from the outside. The wall of the bursa, before an extensive formation of exudate, is necrotic and has usually permitted the accumulation to escape into the surrounding connective-tissue spaces."

As to fluctuation, Mauclaire says: "Fluctuation is almost the rule. One can easily notice it by placing the fingers above and below the annular ligament." While I agree that a sense of fluctuation can be noted by this maneuver, yet the edema and swelling is of such a character that I cannot attach the significance to it that is given by Mauclaire. One should never wait for this symptom before operating. In chronic tenosynovitis, such as tuberculous infection, the symptom is of undoubted value.

The most conspicuous and valuable sign is the extension of the exquisite tenderness to the area involved. It should be remembered that this is absent after a few days. The wrist becomes fixed, the thumb shows tenderness to pressure, and particularly on passive movement is the sensitiveness noted. It is seen readily of how much importance this latter symptom is in diagnosing an extension to the ulnar bursa from the little finger. We note that while at first the symptoms are limited to the little finger and slight changes in the

ring finger because of its juxtaposition, all at once the thumb begins to show the characteristic signs of contracture and tenderness, while the index and middle fingers remain unchanged except for the increase of pain on passive extension explained above. This sensitiveness of the thumb may be due to either the juxtaposition of the sacs or to a real extension into its sheath.

At first there may be a diffuse redness of the palm and dorsum, but it rapidly gives place to a whitish or even cyanotic hue. Above the wrist, however, the tissue generally takes on a marked red color, which later becomes violaceous. The temperature and pulse may not be of any diagnostic importance. Ordinarily, after the infection has lasted a few days and the walling-off process has begun, the temperature is that of the local accumulation of pus and varies with the freedom of drainage. In the first few days, however, the systemic absorption bears no relation to the abscess formation and cannot be relied upon for diagnostic purposes.

EXTENSION TO THE RADIAL BURSA.—This is diagnosed as following an ulnar bursitis by the increased swelling and tenderness in the thenar eminence and along the sheath with the associated symptoms described above. The tumefaction of the thenar area is not that of abscess in the thenar space. Forssell states that this extension occurred in 6 out of 29 cases coming under his observation—average age, fifty to fifty-eight years; 23 cases remained confined to the ulnar bursa—average age, thirty-six to thirty-nine years. In my own experience the percentage of extension is greater.

EXTENSION TO THE FOREARM.—By this we mean a rupture from the proximal end of the sheath and an extension along the connective-tissue spaces, or rather the intermuscular spaces. As I have already pointed

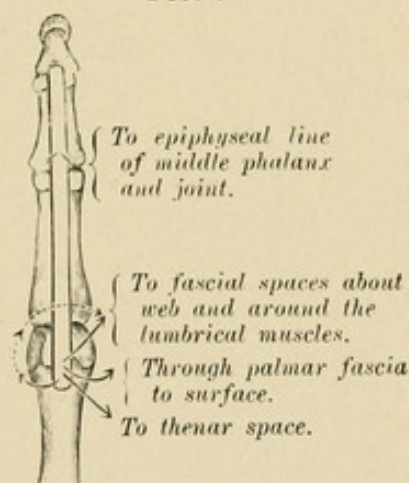
out, the pus passes between the pronator quadratus and the flexor profundus to the area between the latter and the interosseous membrane, and at about the middle of the area it passes more superficially and to the ulnar side along the ulnar artery and nerve. I have had opportunity to verify this area of extension many times in cases I have operated upon, and have also seen it in one fatal case I had an opportunity to dissect (Case XXII). This extension is characterized by a brawny induration that should not be confused with the softness of an edema. No fluctuation should be expected, since the accumulation lies too deeply. This extension is marked also by the loss of the relative swelling immediately above the annular ligament due to the distended upper end of the sheath. This swelling is not any less, but that of the arm is greater. The tenderness may become less, so it cannot be depended upon as a symptom. The redness is generally greater, and spontaneous pain, while at first marked, rapidly subsides (see Chapter XXVI).

At this time some pus may accumulate subcutaneously above the wrist, due to lymphangitis, and lead to the supposition that there is no pus under the tendons, so that valuable time is lost.

EXTENSION TO THE LUMBRICAL AND PALMAR SPACES.—One of the commonest sites of extension is into the lumbrical and palmar spaces. The involvement of the adjacent lumbrical space occurs so frequently as to keep one continually on his guard, since from this involvement of the tendon of the adjacent finger or palm occurs very easily. It is characterized by tenderness, swelling, and pain at the site. The tissue between the fingers on the dorsum of the corresponding web is generally swollen and red; the side of the finger adjacent to the infected finger is often red and tender.

It begins to swell slightly, and by extension the tendon sheath of that finger often becomes involved with the characteristic symptoms and signs. In involvement of the lumbrical space alone, the swelling of the area involved is marked. The middle palmar space is most commonly involved, either by extension along the lumbrical space or from rupture of the ulnar bursa which lies in juxtaposition. The thenar space is never primarily involved in the little finger infections. Involvement of the middle palmar space is characterized by a slight bulging of the palm replacing the normal concavity. The symptoms and signs of this complication, as well as those observed in osseous and joint involvement, will be discussed in the subsequent pages (see Chapter XXVIII). Also mention should be made of the frequency of rupture of the sheath through the palm to the surface at the proximal end of the finger sheath in neglected cases.

FIG. 68



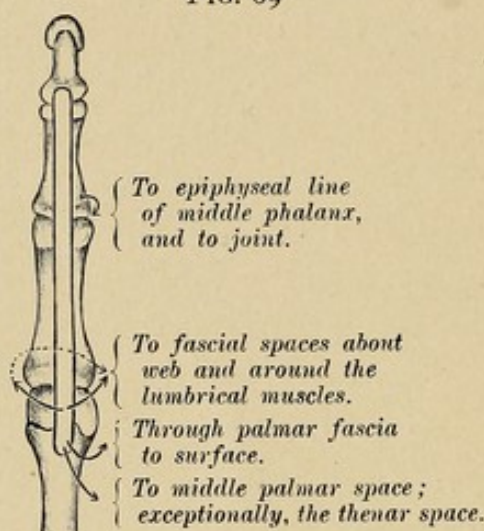
Schematic drawing showing probable extensions from an infection of the tendon sheath of the index finger.

SYMPTOMS, SIGNS, AND DIAGNOSIS OF EXTENSIONS FROM INFECTIONS BEGINNING IN THE INDEX, MIDDLE, AND RING FINGERS

Involvement of the index, middle, and ring fingers presents the same signs as the little finger. The only

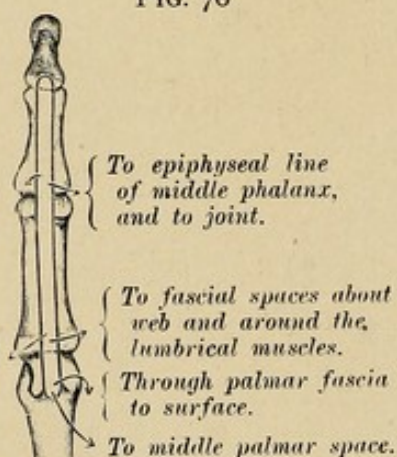
difference is that here the paths of extension are different. Besides the extension to the surface at the proximal end, involvement of the middle phalanx, and the proximal interphalangeal joint, the finger may show extension to the lumbrical space on either side, and

FIG. 69



Schematic drawing showing probable extensions from infection of the tendon sheath of the middle finger.

FIG. 70



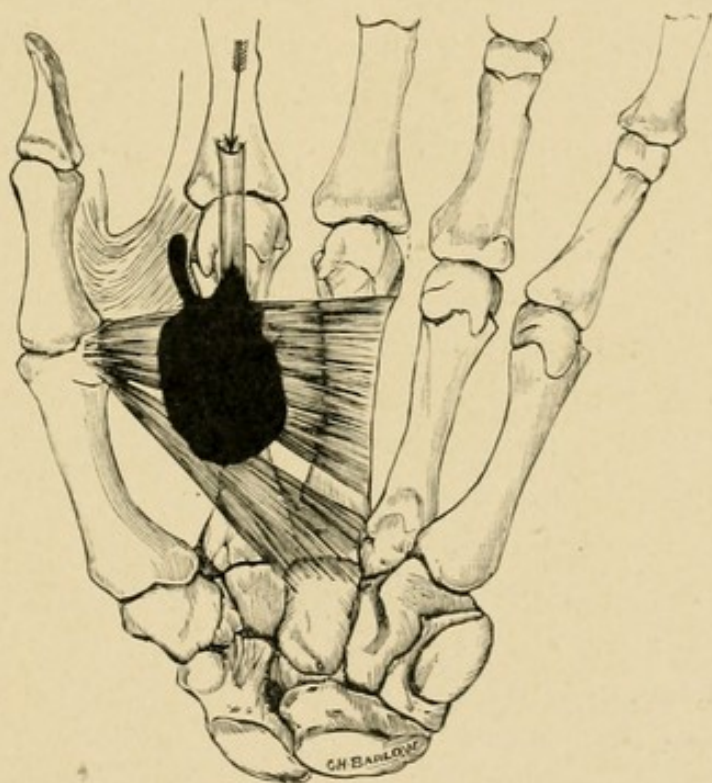
Schematic drawing showing probable extensions from the infection of the tendon sheath of the ring finger.

from here the adjacent tendon may be involved (see Case VII). The fingers differ somewhat in the method of their extension into the palm, as will be seen by noting the accompanying drawings (Figs. 68, 69, and 70). The middle and ring fingers drain into the

middle palmar space, and the index finger into the thenar space.

As illustrating the extension from the index finger into the thenar space, with no involvement of the middle palmar space, I record the case of Miss M., seen with Dr. Besley at the Post-Graduate Hospital. The probability of this extension was pointed out by myself experimentally some time previous to the opportunity to observe a clinical case proving the assumption. Fig. 71 shows such a condition.

FIG. 71



Schematic drawing made from a dissection of a hand in which the injection was made along the tendon sheath of the index finger. Mass filled thenar space and extended along the lumbrical muscle.

CASE XI.—Seen in consultation with Dr. F. A. Besley at the Post-Graduate Hospital, October, 1906.

History.—Patient stated that twenty-four hours before she had run a needle in the distal phalanx of the index finger of the right hand. Inside of seven or

eight hours the pain became severe and she arrived at the hospital complaining of excessive pain and tenderness.

Examination.—Patient's temperature, 102.5° ; pulse, 100. Index finger seemed to be slightly swollen. Tenderness was present over the entire finger and the lower portion of the hand on the radial side without localization at any point. The glands in the axilla were swollen, those in the elbow not involved. No lymphatic lines seen.

Treatment.—A diagnosis of lymphatic infection, possibly tenosynovitis, was made and hot boric dressings applied.

The next morning the temperature had fallen markedly and the patient insisted on leaving the hospital. She returned in two days with all the evidences of acute systemic infection—temperature, 102° ; headache and sleeplessness. Locally the finger presented about the same appearance as when seen two days before, except that there was a slight increase in swelling and the thenar space from the adduction crease in the thumb seemed to be ballooned out from the remainder of the hand. The concavity of the palm was still present.

Diagnosis of previous tenosynovitis in the index tendon sheath, with rupture at its proximal end and involvement of the thenar space, was made.

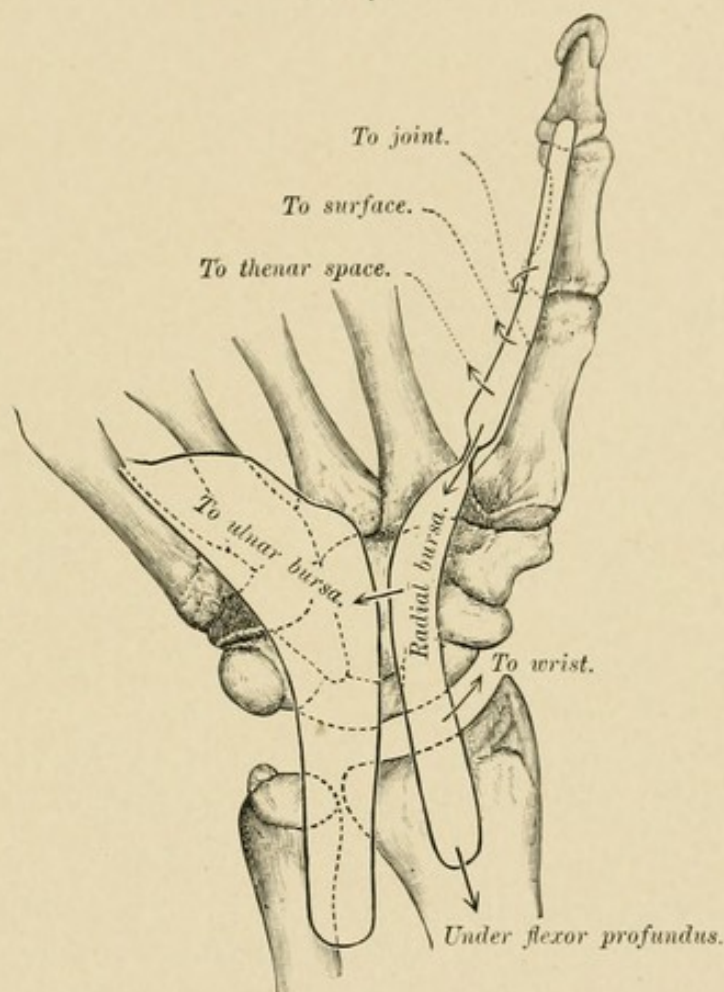
On operation pus was found to be present; there was a very large accumulation in the thenar space, which was drained by through-and-through drainage from the palm to the dorsum between the metacarpal bones of the index finger and the thumb. The tendon sheath of the index finger was opened throughout its extent.

Course.—Patient's temperature rapidly subsided and in two or three days was normal or 99° . Infection of the thenar space had entirely subsided at the end of

seven days, and the wounds healed promptly. The opening in the tendon sheath of the index finger, however, was present for four weeks, necessitating repeated dressings.

Result.—Recovery with all functions except flexion of the distal phalanges of the index finger.

FIG. 72



Schematic drawing showing probable extensions from infection of the tendon sheath of the thumb. (Flexor longus pollicis.)

SYMPTOMS, SIGNS, AND DIAGNOSIS OF EXTENSIONS FROM INFECTION BEGINNING IN THE RADIAL BURSA

The gravity of tenosynovitis of the flexor longus pollicis of the thumb has long been recognized. The symptoms and signs common to the other fingers are

found here. To diagnosticate the extension into the radial bursa and then to the ulnar bursa is more difficult (Fig. 72). Let us suppose the thumb has been the seat of the primary infection. This member is very painful, the index finger slightly sensitive, and the other three fingers hardly at all. After a time, if the infection spreads throughout the sheath, all the fingers become more painful to passive extension, and should the infection pass over into the ulnar sheath all the fingers become flexed and the pain severe upon extension of the tendons, most marked, however, in the little finger. In other words, it assumes the character of an ulnar sheath infection. The tenderness over the sheath is not always so marked in secondary involvement, however, due possibly to the previously developed edema. I recall one case where the only marked tenderness was at the base of the little finger. Here, however, owing to this tenderness, which was not present at the base of the other fingers, a diagnosis of involvement of the ulnar bursa was correctly made. Forssell's statistics show that 23 out of 27 cases of radial bursitis extended to the ulnar bursa—average age, forty-three years; the 4 that remained confined to the radial bursa averaged thirty-seven and one-half years of age. It cannot be emphasized too strongly that in the early state of secondary involvement of the ulnar bursa there is no marked swelling upon the palmar surface and that there is no special tumefaction over the ulnar bursa.

One fact may confuse the surgeon in that the tenderness over the radial bursa may be absent. Not only that, but upon operation no macroscopic pus may be found in the middle part of the sheath. By careful extension of the incision and pressure upon the two ends pus may be brought into the wound.

The extension of the infection into radial bursa is generally accompanied by a swelling above the anterior

annular ligament, just as in ulnar bursa infection. It may rupture from here into the tissues of the forearm, and then the pus lies under the flexor profundus tendons, as previously described in discussing rupture of the ulnar bursa (see page 149 and Chapter XXVI for complete discussion of forearm extensions).

The diagnosis of involvement of the wrist-joint will be discussed in Chapter XXVI.

THE SYMPTOMS, SIGNS, AND DIAGNOSIS OF FASCIAL SPACE ABSCESES

The well-defined spaces I have described as being present in the hand may be infected primarily or secondarily to a tendon sheath infection. In either case the symptoms and signs are the same except that the diagnosis of the location of the pus is simplified when we have had a certain finger sheath involved, as has already been pointed out. Let us discuss the question, however, as if we were dealing with one or more of the spaces without relation to tenosynovitis. The student will have no difficulty in combining or differentiating the two pictures if they are present in an individual case, and the differentiation must be made, since in draining a tendon sheath we do not drain a fascial space, nor *vice versa*. Each must be treated separately, even if in a given case the two infections are combined.

The symptoms and signs may be divided into local and general. The general evidences of this variety of infection do not differ at all from those seen elsewhere. The temperature often reaches 103° to 104° , and the restless tossing of the patient, the sleepless nights, the wandering eye, the sweaty brow, and the flushed cheek all demonstrate the absorption of the toxins, bound in closed spaces, with no means of exit.

Locally, one elicits particular pain limited to the

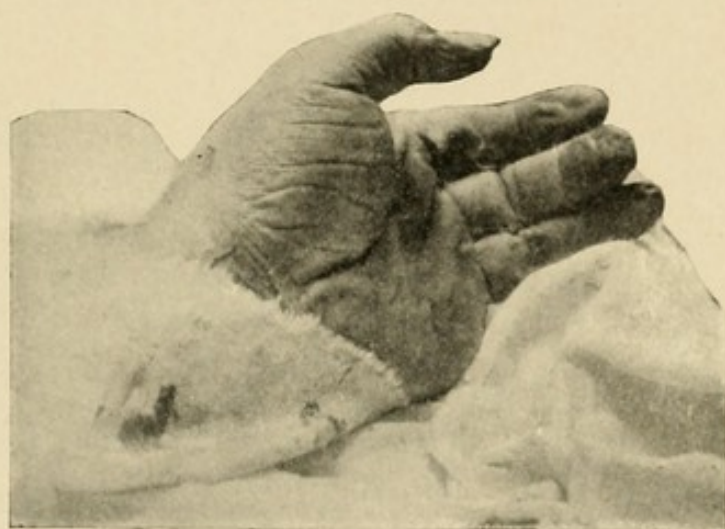area involved. This localization of the pain is not so definite, however, as that noted in the synovial sheath infection, particularly in those patients in whom the mental equilibrium is disturbed as a result of suffering and septic intoxication. After a number of days the tenderness and pain grow less severe owing to the edema with pressure on the nerves. Unfortunately, the brawny induration so helpful in diagnosing subcutaneous accumulations of pus cannot be definitely elicited upon the palmar surface, owing to the palmar fascia and its general rigidity. Upon the dorsal surface, however, the induration and localized tenderness will aid us materially in distinguishing between the doughy, pitting edema which is always present and an accumulation of pus, long before fluctuation gives its tardy evidence. The position of the fingers is worth noting. Incident to any inflammatory process about the palm of the hand, with its consequent edema, the fingers tend to become flexed; here, however, the flexion of the fingers is neither so marked nor so rigid as in synovial sheath infection.

THE MIDDLE PALMAR AND THENAR SPACES

If the middle palmar space be involved, we are often aided in making the diagnosis by the site of the primary injury. Since in the chapter upon pathogenesis (Chapter XI) the routes of extension from various fingers and parts of the hand were pointed out, it is not necessary to go into detail upon this subject again, although an example may be given. For instance, in Case VIII the palmar surface was evidently involved. The fistulous tract on the dorsum opened over the metacarpal bone of the hypothenar area dorsally; but with the facts in mind that the metacarpal bone of the middle finger was fractured and

infected, and also that pus in the subaponeurotic space would tend to point at the side, a diagnosis of pus in the middle palmar space rather than the hypothenar was made. Drainage of this space was instituted, and the immediate fall of the temperature, with rapid convalescence, substantiated the diagnosis. Tenderness most marked over this area, swelling of the whole hand, marked upon the ulnar side (or it is better to say without the excessive swelling of the thenar area which characterizes infection of that space), aid us in making

FIG. 73



Photograph showing the ballooning of the thenar space when filled with pus. Note that the concavity of the palm still remains.

the differential diagnosis. The obliteration of the concavity of the palm and the presence of a slight bulging is almost pathognomonic, since while edema may produce an obliteration of the concavity, I have never seen it produce a bulging or convexity—a condition which I have seen in all large abscesses of the middle palmar space. Attention is drawn to the relative swelling of the thenar and palmar areas, since in palmar infections the swelling of the two might be almost the same, owing to the rigidity of the palmar fascia over the one and its absence over the other, the swelling

of the thenar space being due to associated edema. On the contrary, however, infection of the thenar area is characterized by a much greater swelling in the thenar than the more resistant palmar tissue; and, moreover, the swelling of the thenar region is greater than that due to the collateral edema of mid-palmar infection (Fig. 73).

The position of the fingers does not aid much, although we expect the middle, ring, and little fingers to be held in their characteristic positions more markedly than the index when the middle palmar space is involved, while the converse is true in thenar space involvement. The slight rigidity of the thumb, in contradistinction to its involvement in thenar infection, also aids one in making the differential diagnosis between the two spaces. It is well to remember that the fingers can be moved from their position with much less pain than is elicited when the fingers are involved in a tenosynovitis.

The great difficulty in making the diagnosis, however, is not in those cases in which the question is only which space is involved; it is when we ask ourselves, Are they both involved? or when we wish to know whether a mid-palmar space infection has spread over into the thenar space, or *vice versa*. Fortunately, however, the thenar space infection does have, to a certain extent, that induration which has been spoken of as being absent in infections under the palmar fascia, and this aids us, slightly at least, to differentiate between collateral edema and pus in this space. Moreover, the history helps us some. Given a primary palmar space infection for several days, we note a rapid increase of the size of the thenar area; the edema upon the dorsum, which has not been so great as that upon the ulnar side of the hand, becomes greater; the palmar surface swelling becomes very marked, the

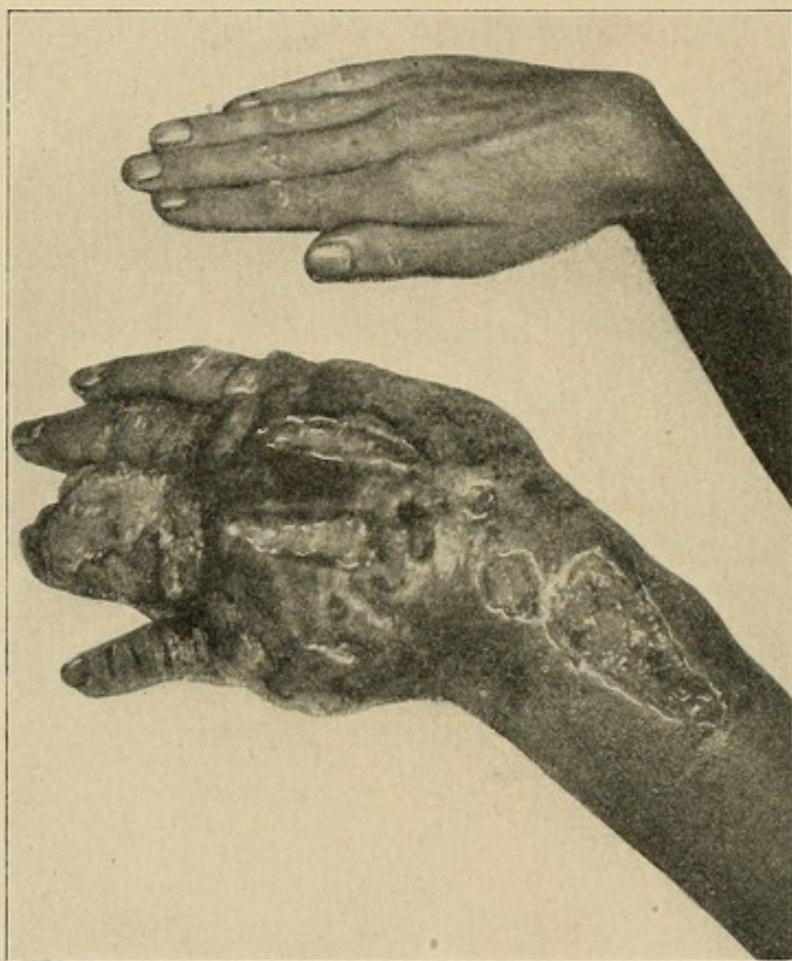tissues of the thenar area seeming to balloon out, as it were, from the adduction crease of the thumb; the thumb metacarpal is pushed away as far as possible from the hand, and the flexion of the distal phalanx becomes more marked, although lacking the rigidity of synovial infection of the flexor longus pollicis. In such a case we now fear an extension into that space.

The extension of an infection from the thenar to the palmar space is not so common, fortunately, since diagnosis is made earlier and the proper treatment instituted.

The immense size to which these infected hands may grow can hardly be believed unless they are seen. I recall particularly a patient who presented himself with such a hand which had been treated for four weeks without the surgeon having diagnosticated and opened a typical middle palmar abscess. It is that of Mr. S., the photograph of whose hands I here present. In the photograph the two hands are upon the same level, and the size of the infected hand is not exaggerated in the picture. It could be compared to nothing except the appearance of a large turtle. The patient had had ten or fifteen incisions upon the fingers and dorsum of the hand when I saw him. Only one incision—that of the middle palmar space, was necessary for drainage. A cupful of pus was evacuated, and the patient ultimately recovered complete function of his hand, as will be seen by examining the photographs. He had been advised by several surgeons to have his hand amputated. There might be some excuse for the failure to diagnosticate the position of pus, since the long-continued infection had so obtunded the nerves that he complained of no pain or tenderness. This is only one of the several cases that have been seen some weeks after the beginning of the infection in which the diagnosis as to the position of pus had not been made,

and in consequence of the apparently desperate condition of the hand the advice to amputate had been given, and yet upon proper drainage the patient secured serviceable hands (see Case Report, Henderson, Case XVI).

FIG. 74



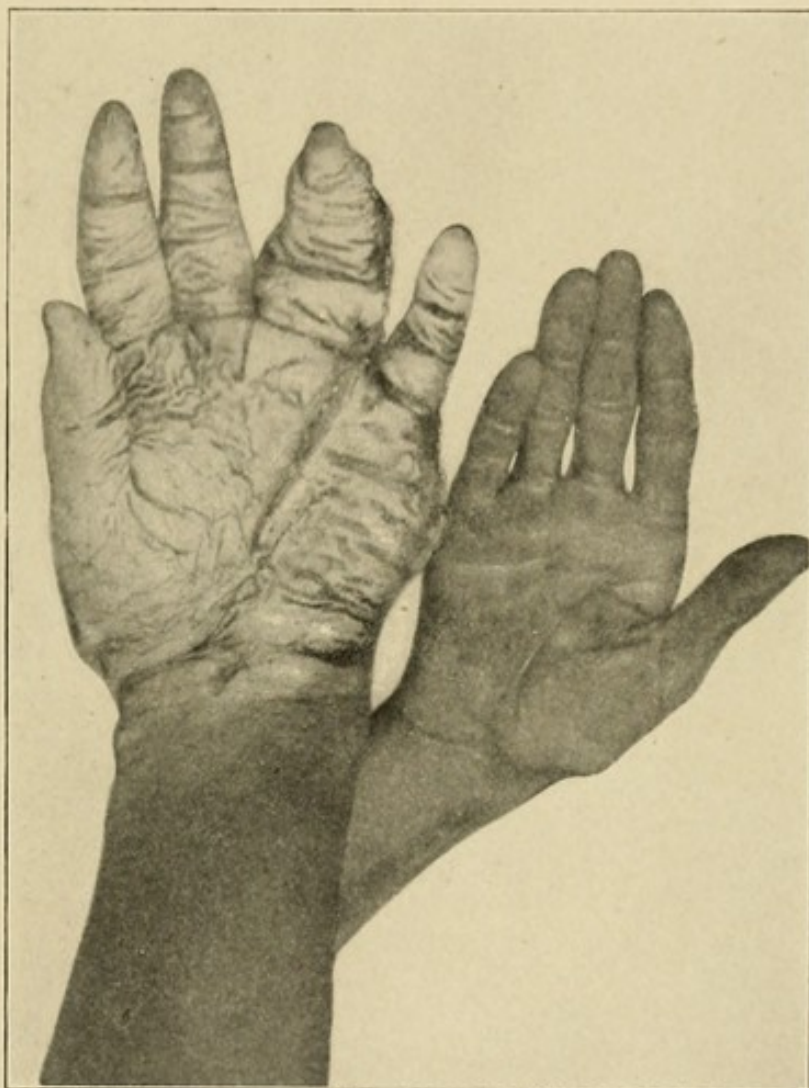Photograph of dorsum of infected hand. (See case report, Steiner.) Note multiple ill-advised incisions upon the dorsum.

CASE XII.—Geo. S., Streator, Illinois. *History in Brief.*—Four weeks ago patient cut his right hand on a piece of steel. He was in the hospital four days, and it apparently recovered. Following this, numerous small pockets of pus developed upon the fingers, which were opened by a surgeon. The hand began to swell enormously, and incisions were made upon the dorsum

of the hand without evacuating much pus. The patient began to suffer from systemic intoxication.

Examination on Entrance.—General condition, temperature, 101° ; pulse, 120; respirations, 26. Marked

FIG. 75

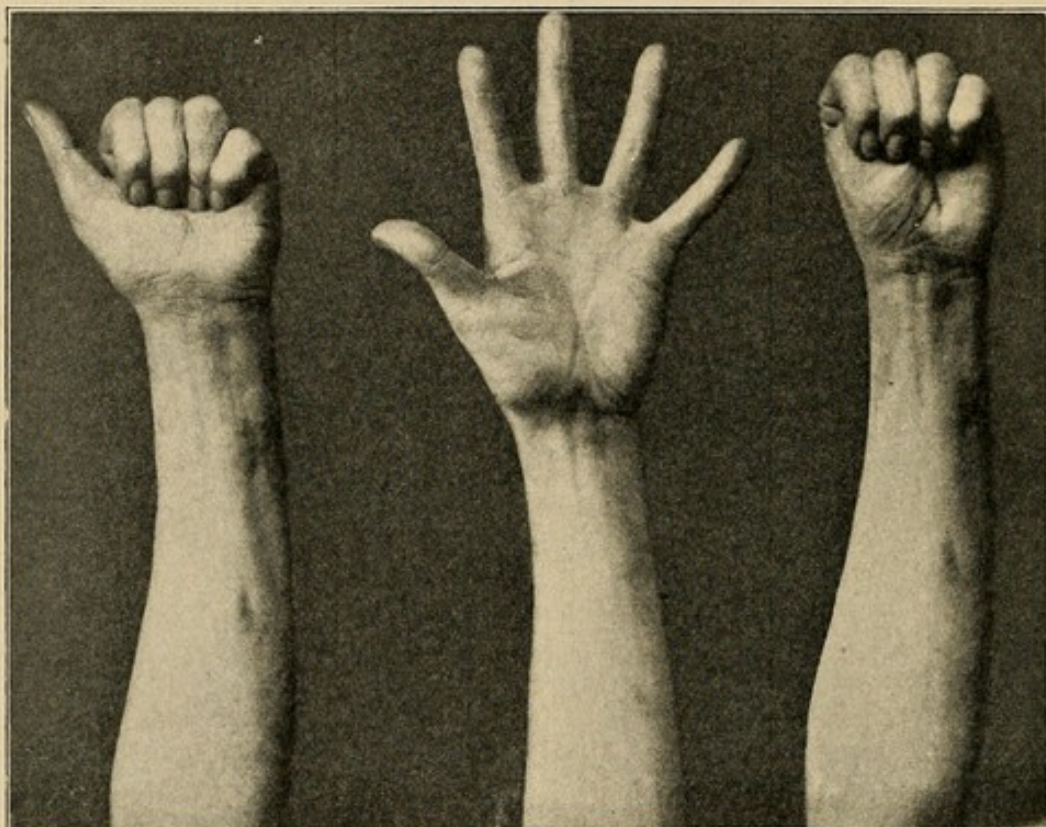


Photograph of palmar surface of the same patient. Note wound leading along lumbrical muscle through which the middle palmar space was drained. This was the largest hand I have ever seen. The pictures show the right and left hands respectively of the same patient. They are on the same level and the same distance from the camera.

headache and emaciation; general evidence of systemic intoxication. Locally, right hand swollen to two and one-half times normal size. The fingers are from one to one and one-half inches in diameter. The hand

is at least three inches thick, swollen both upon the flexor and extensor surfaces. Forearm slightly swollen. Numerous incisions upon fingers and dorsum, from which exude a moderate amount of pus. There is little or no tenderness about the hand.

FIG. 76



Result (case of Steiner, Figs. 74 and 75) six months after treatment. Note perfect function of all fingers and all joints.

Upon the bulging of the palm and the lack of evidences of tendon sheath involvement, a diagnosis of an abscess in the middle palmar space was made. Incision along ring finger lumbrical. A cupful of pus was evacuated.

After-history.—Following the operation the temperature rose to 103° , and fell the next day to 99.8° . It rose to 102° the second day, and then fell to 99.4° , from which time it gradually reached normal. The swelling slowly subsided under hot baths and active

and passive movements, so that the patient left the hospital at the end of five weeks with three-fourths function in the hand, and at the end of four months, when I had an opportunity to examine the patient, the function was perfect in every respect, as will be seen by examining the photographs (Figs. 74, 75, and 76).

THE HYPOTHENAR SPACE

Involvement of the hypothernar space can often be prognosticated from the site of the primary injury, while the relative lack of swelling in the palm and fingers, with absence of involvement of the tendons, combined with the ordinary symptoms of abscess, lead us to an easy diagnosis. Fortunately, the hypothernar area is so separated from the remainder of the hand that it is seldom involved, secondarily, to palmar infection.

DORSAL ABSCESES

An infection localized under the subaponeurotic fascia to the exclusion of the subcutaneous tissue may be difficult of differential diagnosis. However, we are aided materially if we remember the character of the primary injury, the methods of extension to this space already mentioned, and the local evidences of infection upon the dorsum, with the pitting edema of the subcutaneous tissue, yet lacking the brawny induration and localized tenderness of a subcutaneous abscess.

Reference has been made already to the edema upon the dorsum, due to the fact that there we find a large area of loose subcutaneous tissue in which serum can accumulate, and secondly, to the anatomical distribution of the superficial lymphatics, which, as we have pointed out, all seek the shortest course from the

palmar surface to the dorsum. Consequently, one often finds much greater swelling upon the latter than the former, even though the abscess be upon the palm. If, however, we bear in mind the soft pitting of edema, with its generalized moderate tenderness, as opposed to the induration with slight pitting and localized tenderness of the abscess in this tissue, the diagnosis is easy. One should never wait for fluctuation to make a diagnosis of abscess formation; it should be made from the induration.

FOREARM ABSCESES

It is well at this time to speak briefly of those cases which extend into the forearm. We remember that this is much more likely to occur in the palmar space infections than in the thenar infections (see experiments), although cases are reported in which it has extended from either (Chevalet). Personally I have not seen a single case in which an extension occurred from an uncomplicated middle palmar or thenar space abscess. It most commonly arises from a radial or ulnar bursitis. Here we would note the sudden increase of evidences of inflammation in the forearm; the temperature would rise, the tenderness over the forearm in front grow greater, and the swelling become more marked; but owing to the fact that the pus is deep under the muscles, induration would be absent until later, when the whole area became involved, and it would tend to come to the surface probably a few inches above the wrist, along the vessels (see Chapters X and XXVI for a full discussion of this subject).

Exception must be made of those cases already noted where the infection develops about the radial and ulnar arteries, probably of lymphatic origin. Here the abscess is not so deep, yet is considerably below the skin in the area of those vessels.

Osteomyelitis, arthritis, and other complications and sequelæ have no peculiar relation to fascial space infection, and hence will not be considered in the symptoms, diagnosis, and treatment. They will be reserved for a subsequent chapter.

DIFFERENTIAL DIAGNOSIS

One may mistake a lymphatic infection for a tenosynovitis. Here, however, the red lines of lymphatic involvement running up the arm without the localized tenderness over the tendon sheaths, the slight pain on moving the fingers, the generalized edema of hand and arm in contradistinction to the localized swelling found in the early stage of tenosynovitis aid us in the diagnosis. Again, we may be in doubt as to whether we are dealing with a tenosynovitis of the ulnar or radial bursa or a rheumatism of the wrist. I have seen several such cases. In one case it was difficult to determine whether the patient was suffering from a gonorrheal rheumatism of the proximal interphalangeal joint of a finger or a gonorrheal tenosynovitis with secondary involvement of that joint. The latter assumption was later found to be the condition present. In those cases where there is a lack of traumatic history and the apparently spontaneous development of an inflammation, especially at the wrist, the diagnosis may be most difficult in spite of the ease with which a theoretical differential diagnosis is made. Here again, however, the localized tenderness over the sheath and pain on extension of the finger are of the greatest importance; moreover, these cases are always virulent and extend rapidly, so that if it be a tenosynovitis the hand grows rapidly worse. In a rheumatism there is as much pain on the dorsal as on the volar surface; the swelling involves the wrist more than the hand,

fingers, or forearm; and other joints may be involved. The presence of a gonorrhea does not aid us materially, since either condition may follow. Subcutaneous infections are seldom difficult to differentiate. One case of gonorrheal tenosynovitis of the tendon sheaths of the dorsum of the wrist came under my notice in which the diagnosis of rheumatism had been made. Here the absence of any tenderness or swelling on the flexor surface combined with swelling and tenderness localized to the sheaths confirmed the diagnosis.

Forsell, in a personal communication, has drawn my attention to three cases which came under his observation in which there was a palmar infection represented by necrosis of a part of the palmar fascia. This condition, he states, was extremely difficult to diagnose from an ulnar bursitis. Personally, I have not met with such a case and can offer no suggestion as to its pathogenesis.

CHAPTER XV

THE TREATMENT OF ACUTE SUPPURATIVE TENOSYNOVITIS

GENERAL CONSIDERATIONS AND REVIEW OF THE LITERATURE

BEFORE discussing my own views as to the site and course of the incisions for the various fingers when the diagnosis of tenosynovitis has been made, let us study the suggestions of those who have previously made contributions to this subject.

Professor Bier (Berlin), with his assistants, has been an active advocate of the production of passive hyperemia in these cases of infection of the hand. His method consists in applying a constrictor to the arm so as to produce a moderate passive hyperemia without causing pain and without restricting the arterial flow of blood. The constrictor should be a broad band, and to prevent pain should extend from two to four inches up and down the arm. It should be so applied that the full amount of edema does not appear at once, but accumulates gradually for from three to four hours. The constrictor is left on from sixteen to twenty-four hours. After an interval of from two to four hours it is reapplied. Small incisions are made into the tendon sheaths or other sites of pus.

Klapp has added to this by suggesting the use of suction cups, these being applied so as to produce moderate hyperemia without pain. Cups from which the air can be exhausted are used over localized accumulations of pus. Long glasses with rubbers at the end,

which can be applied over the finger, as shown by the illustrations, have also been devised.

In involvement of the connective-tissue spaces, it is my personal opinion that these appliances may be of slight value. In other conditions the benefit to be derived, it would seem, is so slight as hardly to justify their use. Many German surgeons have maintained that Bier's methods are of value in tendon-sheath infections, but personally I have never been able to secure good results with them, except possibly in a few cases where there has been a sinus, leading down to a tendon sheath. The sinus seemed to close more rapidly under the suction cup of Klapp than by other means.

In order to prevent rapid absorption of toxins, it is my habit to leave on an Esmarch constrictor for from twelve to twenty-four hours after operation, except that a constrictor is loosened to produce only a slight hyperemia.

I cannot but feel that while slight benefit may occur in some cases, the so-called Bier treatment of infections of the hand cannot be looked upon as a marked aid.

EXCERPTS FROM THE LITERATURE

Klapp and other surgeons have discussed the Bier method of treatment in these cases at the German Surgical Congress.¹

Klapp has begun to make free incisions in the tendon sheaths at the lateral surface of the fingers and cut the ulnar bursa throughout its length with the exception of the anterior annular ligament, using alcohol dressings, and active movements the first day. His results have apparently been as satisfactory as those obtained

¹ Berliner klinische Wochenschrift, April 13, 1908, No. 25.

by Bier and Klapp previously where they made small incisions into the tendon sheaths and applied the Bier constrictor. By this method he had treated 19 cases.

1. Ten cases of pure tendon-sheath infection; 9 healed with necrosis.

2. Two cases of subcutaneous abscess under the tendon with necrosis of the skin: 1 healed and 1 recovered completely.

3. Six cases of tendon-sheath infection complicated with infected phalangeal fractures: 2 of these healed, and 4 became necrotic.

4. One case developed sepsis and died on the twelfth day.

Klapp therefore concludes that he has thus answered the question as to whether Bier's good results came from hyperemia or from the physiological treatment. He maintains that he has proved that it came from the latter. He now proposes to study whether good opening, physiological treatment, and Bier's hyperemia will not produce still better results.

Klapp's paper was discussed by Joseph, who suggested that there are two types of the infection which must be differentiated—(1) where it is localized to the sheath, not showing a tendency to spread; (2) a type which shows a tendency to spread beyond, due to the great virulence of the infection.

He maintained that we should use care not to go beyond the zone of protection which Nature has thrown out to wall off the infection, whether it be within the sheath or without. In these cases we should use the smallest possible incisions and Bier's hyperemia.

Kausch stated that he had treated a large number of tendon-sheath infections after Bier's method, and must say he was generally well satisfied with the result. He has not been so well satisfied with the very severe cases. In the beginning he used small incisions,

then medium-sized, and drained with passive hyperemia, but in his severe cases he has now gone back to large incisions, although not as large as formerly.

Karewski stated that he could not attribute his bad results to the Bier method, but rather to the fact that his material was ambulatory and could not be correctly handled. He had used the older method for twenty-five years. He now makes a moderate-sized incision, packs lightly, and keeps the arm at rest as long as there is fever. Of 57 cases, 4 had to have amputation of the fingers at once. Of the 53 cases remaining, 9 were treated by lateral incisions. Of the 53 cases, 42 showed good results, that is, 79.25 per cent.; bad results, 5 cases, or 9.5 per cent. This result is better than that given by Dr. Klapp.

Forssell, in his monograph previously referred to, has collected the opinions of various surgeons, and I shall quote and abstract extensively from him. He gives the results of his own experience as follows:¹

"Even if one makes smaller incisions into the sheath, at least according to the experience met with in the Seraphimer-Lazarett, one rarely succeeds in saving the sheath (Poulsen's experience was the opposite). I have often attempted to treat such an infection with incision at each end of the tendon sheath and with complete exposure of the surrounding folds of the synovialis (and subsequent washing of the sheath with water, normal salt solution, boracic acid solution, iodoform-glycerin, weak carbolic, or sublimate solutions), but only on three occasions was this treatment successful.

"The treatment which in my judgment should be used in most cases is a complete splitting of the sheath from one end to the other. Thus, one often succeeds

¹ Nordisches Med. Archiv, 1903, Abt. i, Heft 3.

in saving at least the inner tendon from complete necrosis.

“For the opening of the ulnar sheath on the forearm, if for this or that reason one prefers to begin the incision here, several starting points are at his command. If one can determine the ulnar pulse, the skin incision is made one centimeter to the radial side thereof, and after cutting through the fascia meets the collected muscular bundle of flexors of the fingers, at whose ulnar and posterior circumference the sheath extends farthest upward; by passive movement of the ulnar finger it is now a simple matter to know the lay of the land. If one does not feel the ulnar pulse, nor the os pisiforme, which lies close to the ulnar side of the ulnar artery, nor the unciform, on whose radial boundary the incision must fall, one can make the skin incision on the border of the middle and inner third of the wrist-joint and then dissect layer for layer down to the tendon sheath.

“If it is a case of inflammation of the ulnar sheath of the palm, and the tendon sheath of the little finger, it is often preferable to begin with the fissure of the latter. Only in exceptional cases it might be worth while to use a more conservative treatment, and that especially in such cases of fresh tenovaginitis, where this is secondary after an ulnar bursitis; in such cases one can occasionally make an attempt to conquer the inflammatory process by washing out the tendon sheath through incisions made in either end; there is little danger in this method, and if successful, it insures complete movability of the little finger.

“The skin incision must then be laid from the upper end of the opened little finger sheath, up toward the hook of the unciform (*i. e.*, must follow the radial boundary of the hypothenar), and then continued in the length of the forearm to a point three or four

centimeters or more above the wrist. After cutting through the skin and the subcutaneous fat, usually especially developed here, the palmar aponeurosis, the strong anterior annular ligament, and the forearm fascia are cleft, the superficial vessels cut through and ligated (the ligatures being left long because the vessels usually draw back deep into the tissue and with their infected ligatures give rise to collections of pus which might easily be overlooked), after which the sheath is opened. Even when the infection is confined to the tendon sheath, the incision should be continued in the skin and soft parts until it gives a good opening into the sheath, through which this can be easily and completely packed with gauze.

"In continuing the incision, it must not be allowed to deviate too far to the ulnar side, as the ulnar nerve and artery might thus be injured; the cut can and should be so laid that neither of them is exposed. The anterior annular ligament is best cut some distance from the hook of the unciform.

"If, however, it is a question of suppuration of the radial bursa, I believe that a complete cutting of the anterior wall of the bursa should not be attempted. If the incision is made in the early stages of the infection, one may have the satisfaction of seeing the tendon of the thumb saved and the infection restricted; the tendon cannot, however, be saved in all these cases, and sometimes, moreover, it is rendered useless by adhesions to neighboring regions. An incision of the whole length of the sheath is to be regarded as even more than useless when it is attempted in more advanced cases where there is no chance of saving the tendon since the suppuration is kept up by the necrotic tendon; moreover such an operation lames an important group of muscles and so makes the thumb practically useless.

"How then should one proceed in suppurations of this order? I believe there are three ways at our command.

"1. Incision in the radial bursa above and below the ligamentum carpi, sparing the nerve of the thenar group. The first mention of this method which I have found in the literature I found in an article by Nicaise (*Gazette médicale de Paris*, 1870, s. 615), who, however, opens only the tendon sheath of the thumb under the carpal ligament and not the radial bursa; the case ended in necrosis of the distal part of the tendon. Surely, then, if a decided improvement has not been shown within the first twenty-four hours, one should proceed more radically, in which case the choice is between the two following methods.

"2. Incision as in 1, and excision of the long flexor tendon of the thumb. Through removal of the tendon, which is usually the principal reason for persistent suppuration, one also gains a lessened pressure in the radial bursa and better drainage with less danger of a spreading of the inflammation. Primary excision of the tendon is to be considered: (1) When the tendon is already necrotic, or its continuity broken, or if it is so injured that its restitution seems hopeless; (2) if the synovialis is infiltrated with pus and necrotic; (3) in case of inflammation of the joint or fracture of the thumb, whereby the functions of either the interphalangeal joint or of the tendon are completely interrupted; (4) in people of age or poor general condition.

"3. A more or less complete cutting of the ligamentum carpi beginning at the upper edge is added to the above-mentioned incision. Complete fissure of the ligamentum carpi can be carried out without any direct injury to the motor medianus branch to the thenar muscles; nevertheless, this nerve branch in

case of an infection of the edges of the wound might possibly be exposed to the dangers of necrosis."

I am in receipt of a letter from Dr. Forssell, under date of September 10, 1908, in which he reiterates his belief in free incision. It is abbreviated as follows:

"With regard to your query, whether I have modified my opinion of the complete splitting of the tendon sheath from the end of the finger up into the forearm, I must answer that I still adhere to it with the exception mentioned on pages 37 and 63 of my paper, *i. e.*, I still make attempts sometimes with smaller incisions and irrigations through the tendon sheaths of the thumb and little finger when a tendon sheath has there given rise to an infection of the radial or ulnar bursa and split the tendon sheath of the finger only when the smaller incisions do not lead to the desired results.

"Prof. Bier's hyperemic treatment has been used by me for a few cases of infection, but without any appreciable benefit, this being also my experience with cases of tendon-sheath infection. The material at my disposal may, however, have been too slight for my forming an opinion of my own concerning the value of the Bier method for tendon-sheath infections. At the surgical department of the Karolinska Institute (The Royal Seraphim Hospital), where I worked out my paper, and where the principles I advocated gained general approbation, and caused a considerable improvement in the results obtained, there was later on a good deal of enthusiasm felt for the method invented by Bier; but I was told that some time ago the method was discontinued, since it had given several very unfavorable running cases, and in the main the former old method of treatment has been taken up again.

"Whatever method may be used, I feel sure that fatal cases will have to be deplored. As the prophylaxis, therefore, is invariably of the very greatest

importance, I have lately come to the conclusion that one way of trying to prevent infections of the fingers from attacking the tendon sheaths is by previously exposing the tendon and tamponing it around, to the extent of a couple of centimeters. This proceeding should be of special use in necrosis of the end phalanx of the thumb that so often occurs and which greatly endangers the tendon sheath of the thumb and thus also the bursa of the hand.

"The method has been proved by me as yet in but one single case, though with success. I then proceeded as follows: The tendon sheath of the thumb was split to the extent of a couple of centimeters, the tendon was cut near its attachment on the end phalanx, and was fixed by a suture in the vicinity to its surroundings, a tampon being placed around. After this the necrotic and phalanx with the tendon attachment was removed.

"Seeing the interest you have for the infections of the hand in general, I must call your attention to the small contribution I have given in pages 32 and 33 of my paper. So far as I am aware, the isolated necrosis of the fascia palmaris has not previously been mentioned in literature, which is singular, since both from a diagnostic and therapeutic point of view it is of great interest. I have recently had a similar case under treatment. An English sailor a fortnight previous to being admitted to the hospital had punctured his hand with a nail. Besides the mark of the injury, there was great soreness in the palm, accompanied by considerable swelling of both palm and back of the hand, with a very observable crooking of the fingers together with pain when moved, but no tenderness when the fingers themselves were subjected to palpation. The diagnosis was made of a probable abscess in or around one of the aforesaid fascia, which was found to be necrotic in the great part of its extent,

this without any appreciable accumulation of pus in the vicinity. It would be interesting to hear whether you have had any occasion of observing a case of this localizing of the infection."

W. Heineke, in his *Anatomie und Pathologie der Schleimbeutel und Sehnenscheiden*, Erlangen, 1868, p. 79, speaks of the acute inflammations of the tendon sheaths of the hand:

"The only cure in these malignant inflammations is to be found in an early and extensive incision; thus, one can sometimes prevent a necrosis of the tendon, but one must not expect too much in this direction. After cutting several openings, one can, by use of the drain, help the outflow of pus and the cleaning of the wound."

An article by Scheide¹ shows what a lack of even elemental knowledge there has been in the past in regard to the position of the pus in these cases. He warns against hot cataplasm treatment of these diseases, and recommends that introduced by Volkmann, the so-called vertical suspension of the arm together with continuous ice applications, and even painting with iodine.

"In very great swellings, and excessive overfilling of the veins, numerous stabs with a very sharp knife often do good service. When the period of progressive inflammation has passed and with it the danger of death, when the healing has begun, then the question will again be, What operations are necessary? Many a necrotic phalanx, many a finger whose tendon sheath has become purulent, will have to be removed; and now another question becomes of primary importance, the greatest possible functional activity of the remaining parts.

¹ Ueber Hand und Fingerverletzungen, Volkmann's Sammlung klinischer Vorträge, 1871, No. 29, Note 1.

"This latter is most frequently hindered through the necessary fixation of the hand for weeks and months, thus causing the fingers to lose a great part of their power of motion. The well-known changes to which joints are subject when kept stiff for a long while seem to take place especially quickly in these small joints under the influence of rest and the inflammation of the surrounding tissue. One distinctly feels then how in bending pseudoligaments snap or the capsule tears. With the necessary patience and endurance one can master these disturbances without a doubt. But a great deal of trouble to the physician and pain to the patient would be avoided if immediately after the first period of reaction simple passive exercises were given whenever the dressing was changed, and so prevent any severe stiffening of the joint."

Schüller¹ shows the same lack of anatomical knowledge. His remarks are typical in that they show a lack of tendency to make an early diagnosis. His drainage under the anterior annular ligament should also be condemned. The same may be said concerning the remarks of Tilleaux, which follow:

"If after a tendonal panaritium of the thumb a doughy swelling along the arterioradialis of the forearm is noticeable, pressure there and on either side of the ligamentum carpi volare is very painful, while the fingers are crooked, it is advisable to make a few incisions immediately, if possible, along the line of the flexor longus pollicis, into the tendon sheath as far as the muscle, in order to prevent further changes, especially the occurrence of pyemia or septicemia. The incisions are made to the best advantage on the forearm outward (radially) from the arterioradialis and

¹ Chirurgisch-Anatomische Studien über die Sehnenscheiden der Hand, Deutsche med. Wochenschrift, 1878.

along it. In some cases this is sufficient, as evidently the whole of the great tendon sheath is not always affected from the very beginning, but only its radial half. In other cases, further incisions in the great tendon sheath, in the ulnar side, are necessary. Here an incision is made to the best advantage close above the anterior annular ligament and at that, not exactly in the centre, but to avoid injuring the median, more toward the ulnar side and in the direction of the long axis of the forearm. That one should put drains in all incisions (best under the *ligamentum carpi volare*), wash out the pockets with an antiseptic fluid, and bandage the wound antiseptically, I will only mention in passing. Sometimes even these incisions are not sufficient; then one must add similar ones in the palm and in the forearm."

P. Tilleaux¹ speaks of the so-called subaponeurotic abscess:

"One must hasten to make two incisions, one in the palm of the hand, the other in the forearm, connecting them by a drainage tube which passes behind the anterior annular ligament of the wrist."

Concerning operation when a diagnosis of extension into the forearm is made, he continues as follows:²

"It is now well to delay no longer in opening the focus extensively without waiting for the fluctuation to become more superficial. In reaching the skin the pus must invade the lower layers of the forearm and also the radiocarpal articulation.

"In making this opening one must cut through the entire thickness of the antibrachial region and 'manage' the important organs there enclosed, especially the median nerve. Remember that this nerve is placed slightly without the axis of the forearm; consequently

¹ *Traité d'Anatomie topographique*, 1887, p. 572.

² *Traité de Chir. clinique*, 1897, tome i, p. 674.

the place to choose for the opening of deep abscesses of the wrist-joint is located just inside the median line.

"At this level make an incision about 4 to 5 cm. long, and successively, layer for layer, as if for a ligature of the artery, cut through all the soft parts of the forearm until you reach the focus.

"If in the hand there be a focus communicating with that of the wrist below the anterior annular ligament of the wrist, it would be necessary to drain it, and it might be even necessary to make another opening."

Farther on (pages 684 and 685) he not only continues to show a lack of knowledge of the anatomical and pathological condition present, but advises procedures which should be condemned.

"Subaponeurotic abscess. The abscess must be opened from the palmar face, always remembering that the superficial palmar arch lies in a transverse line, beginning at the root of the thumb. One should, at the same time, open the abscess from the dorsal side and establish thorough drainage.

"If necessary, pass another drain, joining the hand and wrist through the radiocarpal canal. Long carbolic baths should be given."

König¹ speaks for early and large incisions, strong antiseptics (5 per cent. carbolic acid), drainage, suitable position of the hand and finger inside the bandage, vertical suspension of the arm, excision of the arm, excision of the necrotic tendon, but only after a true loosening has taken place.

"But even when the tenovaginitis has persisted for a long time, if the abscesses have formed along the forearm with suppuration, much may be accomplished with antiseptic treatment. Here, too, it is a question, after one or two days of suspension, to stop the swell-

¹ *Speciale Chirurgie*, vol. iii, pp. 369, 370.

ing, of extensive opening of the abscesses and drainage, to introduce a number of small pieces of a drain into the abscess openings. Then all the abscesses are disinfected in the manner described above and an antiseptic bandage applied (iodoform). If one succeeds in this wise in mastering the progress of the disease, then usually permanent irrigation with salicylic acid will work admirably.

"Large, widespread incisions are to be recommended under such circumstances, and one should not hesitate to do as Helferich has already suggested, under special conditions to cut through the transverse ligament. Helferich recommended that after so extensive an incision the ligament and the wound should soon be closed with a secondary suture, if the phlegmon is receding."

The use of strong antiseptics, particularly 5 per cent. carbolic acid, as suggested by König, has been almost entirely abandoned. It is recognized now that these antiseptics certainly impair the physiological function of the cells and probably do as much harm as good.

E. Lexer¹ says:

"Good results may be obtained only by as early and as long an incision as possible."

B. Tillmans² says:

"In light cases one treats an acute non-suppurative carpal bursitis by a high vertical position on a splint, and ice. If improvement does not follow, if suppuration threatens, or if it has already started, one should open the synovial sac by extensive incisions above and below the anterior annular ligament, drain it and apply an aseptic bandage, preferably with a higher vertical position on the suspension splint, according to von Volkmann. Strict precautions should be taken against

¹ *Speciale Chirurgie*, 1902, s. 726.

² *Lehrbuch der specialen Chirurgie*, 1901.

an extension of the suppuration, for example, to the forearm."

P. L. Friedrich¹ expresses himself as follows:

"If the inflammatory process finally extends upward under the carpal ligament and in the manner just described reaches the subfascial muscular interstices of the arm, the only advice one can give is to go down with knife and dressing forceps into each suspected focus of infection, with careful consideration of the nerves and vessels, and to drain effectually with a not too thin drainage material which will not be pasted together by taut portions of the tissue. If it is not possible to guarantee the outflow of the pus in a short time to such an extent in the region of the transverse ligament, consideration of the danger to the carpal joints demands the cutting of the transverse ligament (Helferich, König)."

Friedrich's article demonstrates that even at the present time there is a tendency to blind dissection in these cases. The same may be said of the articles appearing in the later symptoms of surgery emanating from American authors.

P. Mauclaire,² in a similar French system of surgery (we find a very similar description by Lyot), gives the following description of treatment:

"As for the subaponeurotic abscess, if it is a question of deep lymphangitis, or of suppurative synovitis, the incision should be made where there is fluctuation, and the region drained, it being possible for the same drain to go from the palmar region to the anti-brachial region. In making this incision one should guard the bloodvessels, the nerves, and the tendons. One often finds a focus of suppuration in the forearm,

¹ Von Bergmann, v. Bruns, v. Mikulicz, *Handbuch der praktischen Chirurgie*, 1901, vol. iv, p. 420.

² Dentu et Delbert, *Traité de Chirurgie*, 1901, tome x, and tome iii, p. 850.

in the median line in front of the pronator quadratus, or sometimes between this muscle and the interosseous membrane.

"To open this focus, one should make an incision either on the centre of the anterior face of the wrist, along the inner edge of the palmaris longus, or longitudinally along the internal border of the wrist; by approximately following the anterior face of the ulna, one makes a path between the deep flexor and the pronator quadratus (Parona)."

F. Lejars¹ gives the following advice for the treatment of deep phlegmon of the hand:

"One must open the palm, the great palmar sheath, then above the wrist, incise the superior extension, the antibrachial cul-de-sac of the abscess; and last from one opening to the other pass a drain. An operation, indeed, a difficult operation in such a position, yet an operation of immediate urgency, if one wants to save this hand. This done, place the member in a continuous bath, leave it for hours in the liquid, which one renews from time to time to keep the temperature the same. This will be the best after-treatment of the operation which you have just made."

Lejars' procedure is one that can be carried too far, since the development of granulation tissue may be excessive, and in my opinion the treatment should be abandoned after twenty-four to forty-eight hours, when the process is found to have come to a standstill. After that the hot bath may be used at the time of dressing only.

In a treatise on the treatment of serious phlegmons, delivered in the Naturforscherversammlung in Halle,² 1891, Helferich, of Griefswald, explains his methods as follows: As example, he takes a phlegmon of the hand

¹ *Traité de chirurgie d'urgence*, Paris, 1901.

² *Berliner klinischen Wochenschrift*, 1892, No. 4.

and forearm, resulting from a penetrating injury to the little finger, and emphasizes that such a case, as well as a crushed fracture, should be opened as quickly as possible to prevent the spreading and further resorption of the poisonous matter and the inflammatory disturbances of tendons and connective tissue.

"After the usual preparations for the operation (bath, deep narcosis, cleaning of the operative field, application of Esmarch's bandage), he makes an extensive incision at the point of infection, that is, for example, on the little finger, which runs to the side of the flexor tendon longitudinally. An assistant carefully draws apart the edges of the wound, which are at first only slightly gaping, with two little hooks. If the suppurative channel is opened either beside or within the tendon sheath, the careful introduction of a sound serves to control the direction of the knife and scissors. And so, the preparations having been made, one continues the incision farther into the palm of the hand, sparing only the tendons, nerves, and large vessels, through the anterior annular ligament over the volar side of the forearm. Here, in case of a phlegmon extending from the little finger, one keeps to the ulnar side of the common flexors, continuing upward, the region having been prepared below. If it is a question of a phlegmon on the thumb side of the hand and the radial side of the forearm, one would proceed accordingly, but following the same principles. The object is complete exposure of the suppurative foci and the prevention of the infiltration of pus into the intermuscular layers of connective tissue. Often enough a focus somewhat encapsulated by the sticking together of the edges is found between the muscles, and even under the flexor profundus digitorum, so that the interosseous membrane is widely laid open. Upward the incision first comes to an end when a

thorough examination of the tissue and the palpation of the adjoining region leads one to expect healthy conditions.

"So far as necessary, other incisions are added to this large one, either on the other side of the palm or on the dorsal side."

He is decidedly against any other treatment of this process, and has never seen any good results from small punctures; small incisions and drainage cannot effect nearly as much. Disinfection of the wound is dispensed with, and he confines himself to a careful washing out with a 6 per cent. salt solution, emphasizing the local injurious, irritating effect of antiseptics and the very unfavorable effect of the same on the kidneys.

In the after-treatment he emphasizes passive movements, baths, active movements in water baths, massage, electricity, occasional compression, and nightly fixation in various positions.

Helferich then recommends an apparatus invented by Dr. Krukenberg for the development of passive movements.

C. L. Schleich¹ says, in speaking of the treatment of phlegmons of the palm of the hand:

"If we cut through the ligament we can prepare for the most serious functional disturbances; if, on the other hand, we do not follow up the channel of suppuration we leave a great mortal danger. To decide this matter we press firmly on the tendinous convolutions above the ligament of the forearm and pressing out the contents toward the periphery; we will suppose that no drop of pus flows from the tendon pocket below the ligament. We are then obliged to make a counter-opening above the ligament, which would have been absolutely necessary in the presence of pus above the

¹ *Neue Methoden der Wundheilung*, Berlin, 1899.

same. I depend on the appearance of this superligamentary flexor swelling to decide whether, through a counteropening, I shall pass a drain of gauze strip under the ligament, or whether I shall cut through the ligament to further lay bare the avenues of infection. In case of dry opacity and scarring, I usually let gauze drainage suffice; if, however, fluid pus is found between the tendons, I stand for unconditional severing of the ligament and further following up the avenues of infection."

K. Poulsen (quoted from Forssell) gives the following description of the opening of the ulnar tendon sheaths:

"If the sheath is swollen, or the skin edematous, it is not so easy to see what one is about or to say exactly what flexor tendon lies before him while he is making the incision; yet in these cases it is of no great importance if one should happen to get in between the deep flexor tendons of the second and third fingers; the sheath when it is stretched is always opened, if one only gets in between the tendons of the deep flexor muscles. The incision is then made in the following manner: The arm is rendered bloodless, and then one determines the position of the *M. flexor ulnaris* with the help of the *os pisiforme*, its point of insertion, and of the tendon of the *M. flexor carpi radialis* by drawing a line upward from the second metacarpal joint, to whose base it is attached. Half-way between these two tendons an incision is made to the *ligamentum carpi volare* proper; hooks are used to widen the wound, with the radial (side) one must be very careful on account of the median nerve. Next, he proceeds into the depth between the tendons, first the superficial ones, then the deep-lying ones; when the connective tissue which binds together the deep tendons has been passed, the sheath is opened, the pus streams out, with a Lister's forceps the opening of

the sac is dilated upward and downward; after this iodoform gauze is laid in, the bandage removed, and the bleeding stopped by compression.

"As a bandage I usually use a boric acid application, which is changed daily while the gauze remains undisturbed until it loosens of itself; as a support for the hand a volar splint is used. Some prefer to make an opening upon a bulb-headed probe previously introduced in the vola manus on the lower border of the ligamentum carpi volare proper, and to draw a drain in between the two openings. Yet I must say that I have no particular fondness for using drains in this place, as they easily compress the tendons in this comparatively narrow canal and thereby give rise to necrosis. If the incision has been made above the ligament, and along the tendon to the little finger, there will be an upper and lower opening of the bursa, which, without danger to the tendons, can be held open by gauze drainage, which offers sufficient outlet for the pus, at least so long as the pus confines itself to the sheath alone. If the suppuration lasts I prefer to split the ligamentum carpi volare proper and lay open the canals; it is not rare to succeed in this way in rescuing the tendons, which at this point have a fairly large vessel lying in mesotendon."

K. Poulsen has also discussed the therapeutics of tendovaginitis of the thumb and radial bursa. He opens the finger tendon sheath to the lower edge of the M. abductor pollicis and the radial bursa above the ligament, avoids drainage tubes, and in their place uses gauze drainage.

"In cases of persistent suppuration the ligament is cut and a peritendinous phlegmon is mastered by continuing the incision on the thumb along the lower border of the abductor, and laying in drains when it is seen that the tendon will be lost; the cutting through of the muscular system of the thenar, used by some,

should be resorted to only in desperate cases, because it destroys in large measure the function of the abductor."

It would seem from this that Poulsen, at least in coincident infections of the tendon sheath of the thumb and the radial bursa, opens the latter only above the ligament, and to expose that part of the bursa which lies within the thenar, only when the suppuration has spread beyond the bursa. In cases of persistent suppuration the ligament is cut; but he does not state whether, after this tardy fissure of the ligament, he has found the flexor tendon of the thumb and the thenar nerves capable of carrying on their work or not.

"Why it should ever be necessary to split the thenar muscles after cleaving the ligament I cannot see, as only a small upper point covers the radial bursa below the ligament. Nor is it clear why such a fissure of the muscles in question should destroy a great part of their functional activity; but the incision, continued through the ligament and all the soft parts, including the tendon sheath, cuts through the nerves, not only of the *M. abductor*, but also of the *M. opponens* and of the superficial part of the *M. flexor brevis*, and thus causes a very troublesome crippling of the thumb.

"Finally, to use this method of operation in 'desperate' cases will not save the tendon of the thumb; it is undoubtedly better to remove the tendon, which in such a case would undoubtedly be destroyed or rendered useless at this late date."

To open the upper end of the radial bursa, Max Schüller proceeds as follows: The incisions are best made outward (toward the radial side) on the forearm, beginning at the radial artery and extending along it.

Nicaise, on the other hand, places the incision between the *arterioradialis* and the tendon of the *M. flexor carpi radialis*, and between the latter and the tendon of the *M. palmaris longus*.

CHAPTER XVI

TREATMENT OF ACUTE SUPPURATIVE TENOSYNOVITIS—DISCUSSION OF TECHNIQUE

FOLLOWING the anatomical investigations detailed in the previous chapters and a careful study of all clinical cases coming under observation, certain procedures were instituted, which in my hands have given most satisfactory results. The technique used by myself in these serious cases is herewith described. This may be classified under three heads:

1. In the early hours while the diagnosis may be in doubt.
2. When the symptoms and signs of tenosynovitis are marked.
3. After-treatment.

TREATMENT WHILE THE DIAGNOSIS MAY BE IN DOUBT

Very commonly, when a finger is infected, it is some days before the tendon sheath becomes involved; again, it may be early, and when it is invaded the symptoms develop rapidly because, as was mentioned above, there is so little resistance that the infection spreads throughout the sheath in a short time. However, during the preliminary stage, much may be done to prevent a spread into the sheath. The best sort of application is undoubtedly some form of moist, hot dressing. Boric acid solution in saturated strength is most commonly used, but any of the other solutions in common use are probably just as efficient. Carbolic

acid dressing in any form should be avoided because of the danger of gangrene. Local painting with ichthyol, iodine, and such irritating solutions is absolutely useless. German surgeons speak highly of 95 per cent. alcohol dressings left on twenty-four hours. They probably are no more efficient than the hot boric solution, and are always a source of some anxiety, owing to the possible danger of their catching fire, as I have personal knowledge of in one case. Probably the next most essential procedure is to keep the part at rest; this, of course, is indicated in any infection, since the muscular action tends to disseminate the germs, thus extending the area to be walled off by the leukocytes carried in by the dilatation of the vessels incident to the hot dressings. Elevation of the part is recommended by many, but personally I could never see any advantage in it except to make the arm comfortable, and it is true the elevation of the hand is sometimes necessary for this. If the infection is severe, put the patient in bed. An ice bag in the axilla may help some. Keep the bowels open and the kidneys active. Preserve the nutrition of the patient. The methods of Bier and Klapp are discussed above.

TECHNIQUE OF TREATMENT AFTER DIAGNOSIS IS MADE

The diversity of opinions as to the proper methods of treatment held by various surgeons, as noted above, is sufficient proof of the severity of this condition and the difficulty of its treatment. It emphasizes the frequency of bad functional results, and should stimulate us to most careful study of our cases.

The diagnostic acumen of the operator cannot but be a vital factor in the treatment. It is probable that too many will err on the side of conservatism in the treatment of the first cases that are met. It will be

reasoned that since some damage already will have occurred to the tendons, if they are involved, a few hours' delay will not add seriously to the condition. This possibility will be preferred to that of opening and infecting an uninvolved sheath. However, these few hours are of great importance in the fulminating type, and operation should be most prompt.

I do not intend this as advocacy of operation regardless of accurate diagnosis, but as a stimulus to careful study to the end that the surgeon, being better qualified, may neither, by ill-advised conservatism, delay necessary operation, nor by thoughtless audacious incisions jeopardize the usefulness of a healthy hand.

My own opinions as to the best methods are based upon my anatomical researches and upon observation of the patients presenting themselves at the dispensary and hospital of the Post-Graduate Medical School and Hospital, at Wesley Hospital, and the Northwestern University Medical School. To Professors Besley and Richter, and others of my friends at these hospitals and at the Cook County Hospital, I wish to acknowledge my appreciation of the opportunity for the study of their cases in addition to my own. Concerning the technique of treatment, I cannot help but feel that the future has much in store for us that we cannot know at the present time. The subject is one not only of local condition, but of the resistance of the individual and his reaction to various toxins. In other words, the newer problems in serum pathology must first be worked out before we can attain the best results. I cannot but feel, however, that even the local conditions are not so well understood by the average surgeon as is possible, and that our bad results would be reduced at least by half if more study were given to careful diagnosis.

I have secured the best results by the following

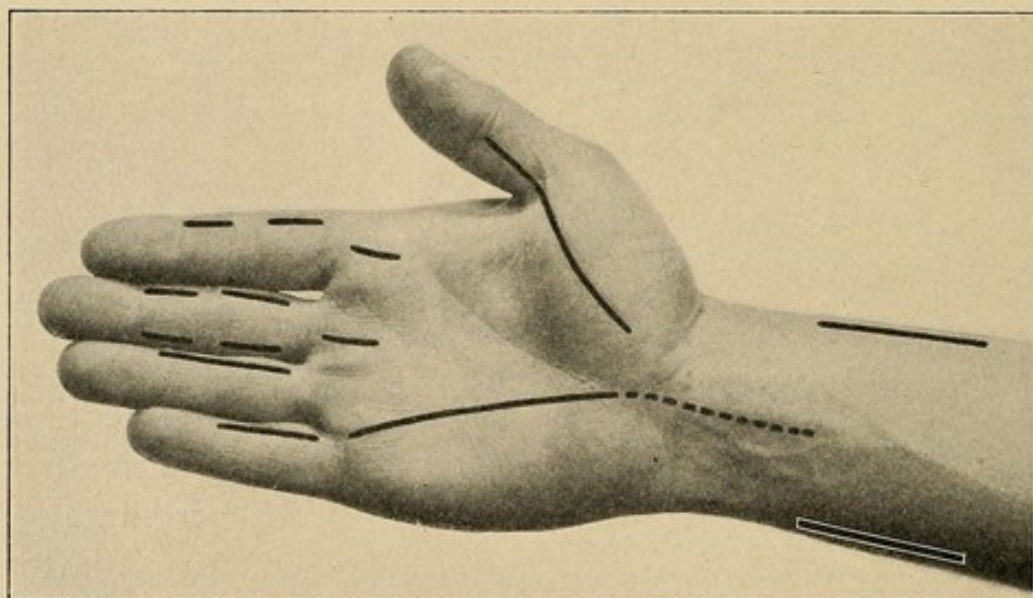
procedures. *Operation should always be done under general anesthesia and in a bloodless field.* Where the process is virulent and acute, I leave on the Esmarch bandage for twelve to eighteen hours after the operation. Care is taken, however, to loosen it so as to produce a passive hyperemia. In other words, a Bier's hyperemia is secured for this time. This is done not so much for the therapeutic effect as to prevent the rapid absorption of virulent toxins. I hope in this manner to give the patient time to react and develop anti-toxins to overcome the poison rather than allow him to be overwhelmed by a large amount of virulent toxin absorbed at one time.

TREATMENT OF TENOSYNOVITIS OF THE INDEX, MIDDLE, AND RING FINGERS

The procedure will vary according to the form of infection and the amount of destruction present. The first incision is made at the site of known infection, opening the sheath at the side and not in the median line, cutting the length of the shaft of the proximal or middle phalanx, leaving the part over the articulation uncut, unless there is doubt as to the freedom of drainage, so that the tendon does not prolapse. I wish to insist that *the first requisite is adequacy of the opening for drainage*, since a small incision soon becomes closed by prolapsing tissue. *Make the incision too free rather than too small.* In those cases where it has seemed advisable to incise the length of the sheath, and I do this in case of doubt, I have bound the finger out in an extended position to prevent prolapse of the tendons. After having opened the sheath at this one point, pressure upon its various parts will give one some idea of the extent of the invasion. If it is complete, as is generally the case, a similar incision

is made over the uncut proximal or middle phalanx. No incision is necessary, as a rule, over the distal phalanx, and in making this I feel that Klapp is in error, if his drawing represents his technique correctly. Over the proximal end of the sheath, at the base of the palm, the technique will vary according to the extent of the invasion. If early, the incision is made over the middle of the sheath at its end in the palm, carrying it from the flexion crease at the base of the proximal phalanx for about three-fourths of an inch into the

FIG. 77



Lines show area of possible incisions for infections of the various tendon sheaths. (See text for full description.)

palm. If, however, there is some question whether the lumbrical spaces at the sides have begun to become involved (*vide supra*), the incision is made upon the side most affected, opening the space and the tendon sheath at the same time. If both sides are involved, two incisions are made. The finger is now cleansed and examined. If the amount of pus is great, a second line of incisions is made upon the opposite side of the finger over the two proximal phalanges by inserting the knife blade through from the incision already made

on the one side (Fig. 77). If there is much involvement of the synovial surfaces, or if there is much edema of the finger, which would tend to close the incisions, I connect the two first incisions made, thus making *one incision the length of the finger rather than multiple incisions on both sides of the finger*.

I have tried cutting down to the sac in doubtful cases,¹ then inserting an aspirating needle and attempting to draw off some pus for diagnostic purposes, hoping by this procedure to avoid the possibility of infecting an uninvolved sheath through opening it with a scalpel. While theoretically the procedure would appear to be advisable, practically it is of little aid. The bulging of the sheath, proving the presence of fluid under tension, is generally easily seen, while a failure to secure pus is not sufficient evidence of its absence.

WHEN THE INVOLVEMENT OF ADJACENT AREAS HAS BEGUN.—The involvement of the articulation between the middle and proximal phalanges, which occurs in late cases, will be discussed in the chapter dealing with complications and sequelæ (Chapter XXVIII). The method of treatment will be outlined there. I shall only add to what I have already said that if early incision of the sheath is made this involvement is generally prevented, another reason for early incision. As has been pointed out, the paths of extension in the involvement of the lumbrical spaces vary in the individual fingers.

The Index Finger.—When the infection passes to the lumbrical space on the outer side, it may extend into the thenar space, and the incision which opens the lumbrical space can extend up into the thenar. Pressure upon the thenar area will force pus out along the

¹ White, Whitlow and its Treatment, Brit. Med. Jour., February 24, 1906.

line of incision. This is then extended along the radial side of the metacarpal bone, the incision lying dorsal to the web which extends from the thumb to the base of the index finger. The artery forceps is then carried across the palmar surface of metacarpal bone and the blades opened, thus draining the thenar space without an incision upon the palmar surface (Figs. 89 and 95). Care should be used not to force the point of the forceps beyond the middle metacarpal bone; otherwise the middle palmar space will be entered and an extension to this space favored.

When the extension has entered the lumbrical space between the index and middle finger, the incision should be made into the sheath at its ulnar side, thus opening both the sheath and the lumbrical canal through the same skin incision. If the lumbrical canal is badly involved, the pus may have extended distally into the loose mesh of tissue at the web or proximally. If distally, it may be necessary to add a second incision upon the dorsum between the bases of the index and middle fingers, and procure through-and-through drainage of the web, or at times I have split the web completely and have not as yet observed any serious impairment of function following (Fig. 95).

If the infection extends proximally, some care should be used in the incision, since it may extend either into the thenar or middle palmar spaces. After the lumbrical canal is opened, pressure over these areas will demonstrate which is involved, since pus will exude into the incision. This is then extended upon a grooved director along the line of invasion, cutting about one-fourth of an inch proximal to the line joining the ends of the flexion creases at the distal part of the palm; an artery forceps is thrust under the tendon into the space, which, by separating the blades, is effectually opened. We frequently find invasion of

the thenar area either directly from the sheath or secondarily by way of the lumbrical canals; when this occurs I supplement this palmar incision by one upon the dorsal surface between the metacarpal bones of the thumb and index finger, *i. e.*, drainage of the thenar space as described in Chapter XVII.

The Middle Finger.—When extension occurs into the lumbrical canal upon the radial side, or the web on either side, the technique of treatment is as has just been described. When the extension is along the lumbrical canal between the middle and ring fingers toward the palm, early the pus may be between the palmar fascia and the tendon in the "loft," as already described, but it very soon involves the middle palmar space. Here the incision is carried one-quarter inch into the palm, *i. e.*, proximal to the transverse line joining the ends of the flexion creases. If pus is expressed through this from the palm, an artery forceps is inserted under the tendons going to the ulnar side and the blades opened. No drainage is inserted, although in a few instances I have placed in the pocket small strips of gutta-percha or gauze thoroughly impregnated with vaseline. Ordinary gauze acts simply as a plug, and I never use it.

The Ring Finger.—Here the extension to the web or into the palmar space from either side is treated by the same technique as described above.

TREATMENT OF TENOSYNOVITIS OF THE LITTLE FINGER AND ULNAR BURSA

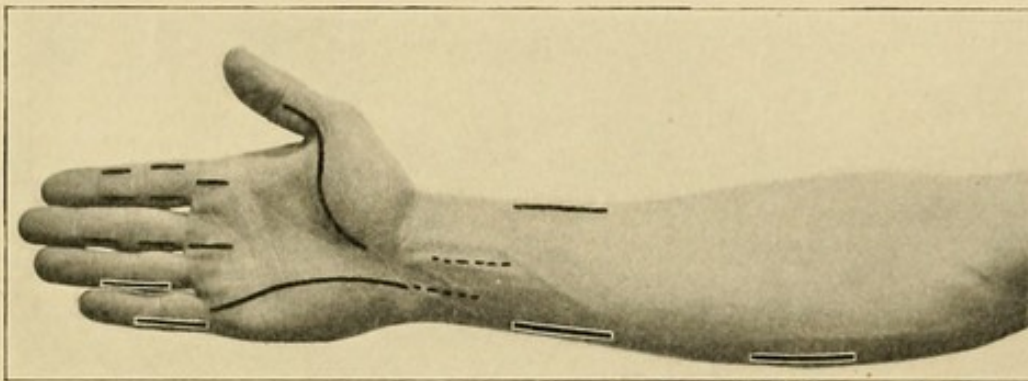
If the finger alone is involved, the treatment is the same as that noted above for the other fingers, except that almost always it will be found advisable to make a single incision on the side the length of the two proximal phalanges, since we wish to procure perfect

drainage, and thus avoid possible extensions. We remember that in about half of the cases there is a congenital separation of the proximal from the distal portion at approximately the metacarpophalangeal articulation, and in a certain proportion of these cases in which there is no separation the opening is so narrowed that there is a temporary dam produced by serous adhesions if the inflammation is not too fulminating in character, which unfortunately it generally is. In the former condition there is little likelihood of a spread to the ulnar sheath, so that we should be extremely careful not to open this sheath unless we are certain that it has become infected, since we are exposing the patient to grave danger. On the other hand, if the occlusion is of temporary inflammatory origin, we can readily see how important it is that an early diagnosis of the condition should be made and proper treatment of the distal portion instituted to prevent a spread to the ulnar sheath. As to just what the proper procedure should be in case we are fairly certain that there is an infection of the distal portion of the sheath and we are still in doubt as to whether it has extended to the proximal or palmar portion or not, there is room for discussion.

Forssell advises that we should begin at the point where we are least sure of infection, while Helferich suggests that we begin at the point of infection where we are sure and make our way along with care. Naturally, we would admit the former to be the proper method if certain unknown equations did not enter into the discussion. In the first place, what proportion of aseptic ulnar sheaths can be opened and not infect the sheath from the lymphatics which are constantly carrying germs from the point of infection through the subcutaneous tissue in which our so-called aseptic incision is made? Upon the answer to this question depends in

all probability the proper solution of the question, and it will take a large number of carefully observed cases to arrive at a decision. Increasing experience, however, has confirmed me in the opinion that it is wiser to incise at a known point of involvement. This pocket being opened, pressure is exerted over the sites of predilection in continuity. If they are involved, pus will be seen to enter the previously opened site. A grooved director is now inserted along the canal and the incision continued or the focus opened by the proper methods.

FIG. 78



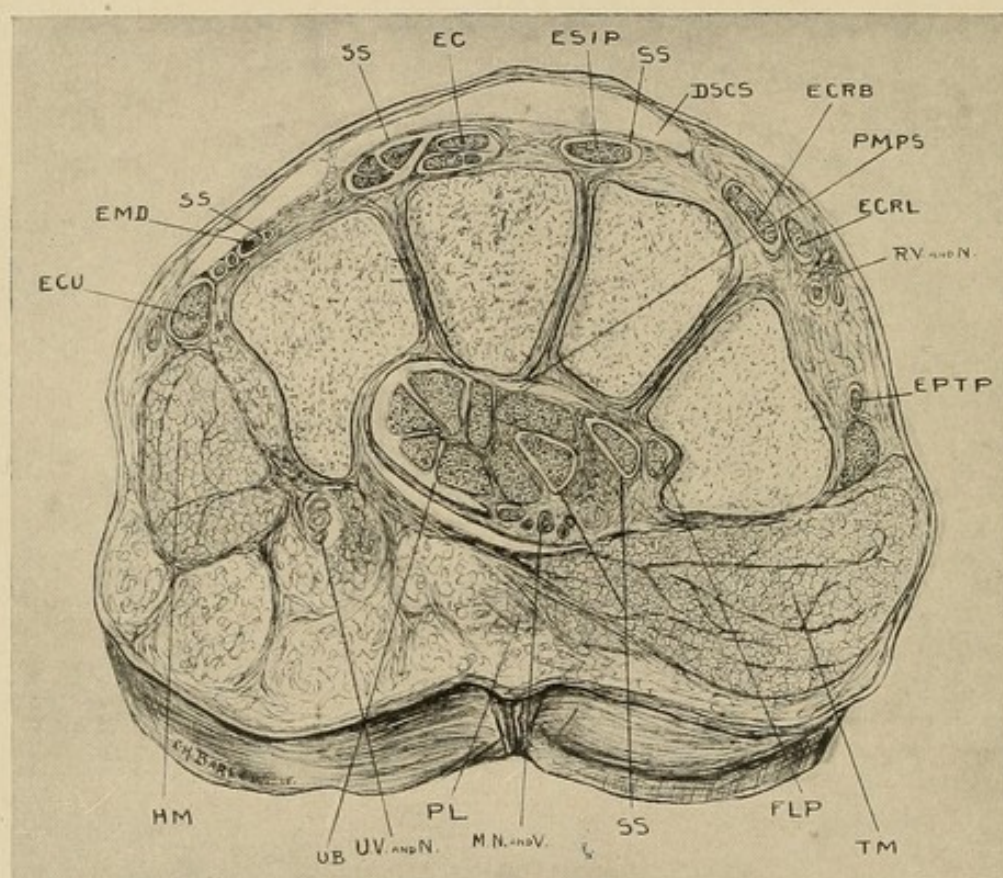
Lines represent the various incisions made for infections of the tendon sheaths and their possible extensions into the forearm. (See text for complete description.)

When the continuation of this sheath in the hand is involved, the palmar portion is opened by an incision extending from the base of the finger at the distal flexion crease of the palm and passing toward the base of the palm (Fig. 78). It is my custom to insert a grooved director in the sheath at this point and follow along this, cutting the tissues between the sheath and the surface, having the thought in mind to avoid the tendon and cut as far to the ulnar side of the sheath as possible, since there will be better drainage, particularly at the wrist, if this is done (Fig. 79). After the anterior annular ligament is reached, pressure above over the prolongation of the sheath in the forearm will

force pus downward into the sheath below the ligament if the infection has extended here, as it generally has.

If an involvement of the prolongation of the sheaths above the annular ligament or a forearm involvement is diagnosticated, I proceed as follows. At a point about one and one-half inches above the tip of the ulna

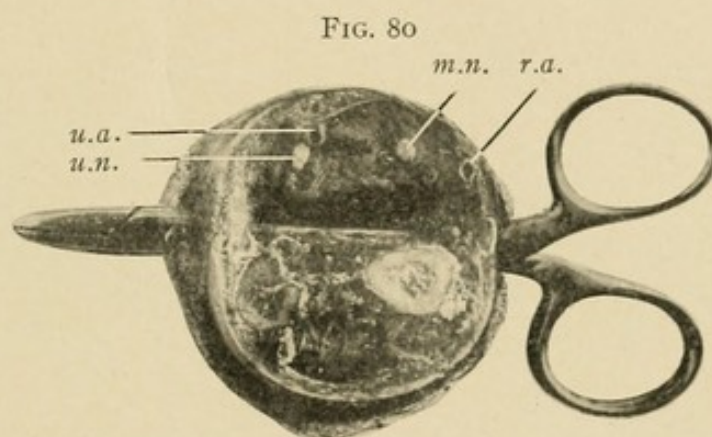
FIG. 79



Cross-section No. VIII.—See Fig. 23 for common lettering: *RV* and *N*, radial vessels and nerves; *MN* and *V*, median nerve and vessels; *UV* and *N*, ulnar vessels and nerves; *PMPS*, prolongation middle palmar space.

an incision is made directly down on this bone at its flexor surface, an artery forceps is now thrust across the flexor surface of this bone and the radius until it impinges on the skin at the radial side, where the knife cuts down upon it. The incisions in the skin are now enlarged to the length of an inch and one-half or more and the artery forceps opens the subtendinous

area to the same extent. *Make the incision too long rather than too short*, since a large incision with free drainage will heal more rapidly than a small incision with adequate drainage. Especial care should be used here to make the incision neither too far upon the flexor surface nor dorsally, since in the first instance, especially upon the radial side, the artery may be injured either by the primary incision or subsequent necrosis; and in the second instance, if the incision is too far dorsal it will not drain easily. If the primary incision is

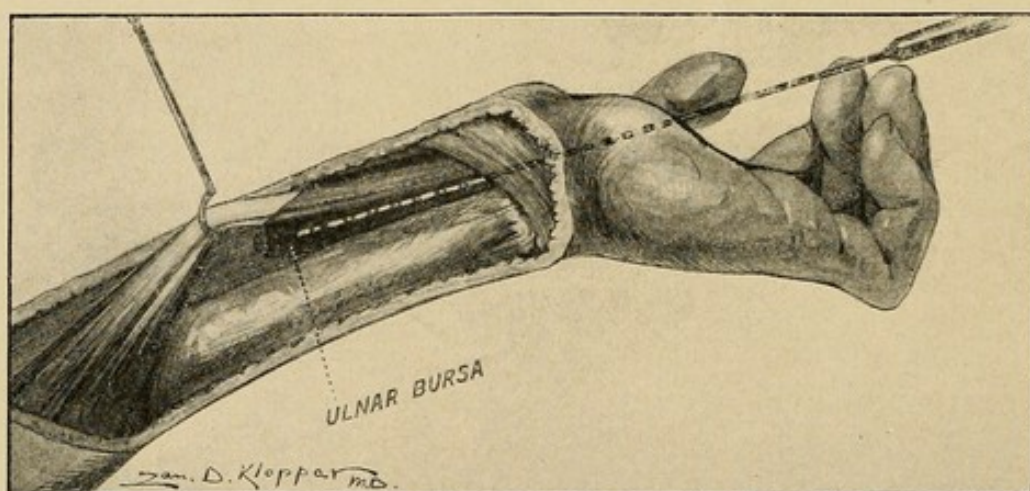


Cross-section 7 cm. above radial styloid. Artery forceps inserted transversely in juxtaposition to ulna and radius through the anterior interosseous space, showing that incision can be made here and not injure important vessels and nerves. Notice tissue between radial artery and the forceps: *r. a.*, radial artery; *u. a.*, ulnar artery; *u. n.*, ulnar nerve; *m. n.*, median nerve.

made low down and on the radial side the danger of injuring the radial is greater. With the proper precaution, no anxiety need be felt (Fig. 80). Having opened this area, the finger is now inserted under the flexor profundus tendons, and if there is any infection of the sheath it is bulging and can be opened easily. In case it is not found easily, flexion and extension of the fingers will locate the tendons involved and the palpating finger can be pushed up among them, or an artery forceps can be pushed under the annular ligament through the bursa which has been opened in the palm

in front (Fig. 81). Its point is felt plainly by the finger under the tendons, and the opening dilated freely. As a matter of fact, the infection will be found to have ruptured into this space in practically every case, except in the very earliest stages. *I wish to emphasize that it is upon this incision that I depend for drainage of the upper end of the bursa*, since it extends upward on the tendons on their posterior surface (Fig. 81). In other words, this site is used for entering and draining the sheath before rupture, as well as the site of

FIG. 81



Drawing showing extension of the ulnar bursa underneath dorsal surface of the flexor tendons, and probe inserted from a palmar incision, passing under the anterior annular ligament with end showing in the ulnar bursa above.

incision for draining the extension into the forearm. At times when the ulnar bursa alone is involved the incision upon the ulnar side has been found sufficient, and I shall be inclined to use that alone in the future in the uncomplicated cases. It will be remembered that attention has already been drawn to the fact that when extension takes place this area between the flexor profundus tendons and the interosseous septum and the pronator quadratus is always first involved. In the early stages of rupture, after having cut through

the skin and subcutaneous tissue, the operator will be inclined to desist, since no evidence of pus will be found. It is not until the area under the profundus is reached that one finds the pus. Again, a second fallacious reason for stopping the incision at this stage may be found. There may be a subcutaneous accumulation of pus on the flexor surface of the wrist, in all probability of lymphatic origin; this having been opened, the operator feels that he has drained a pocket in direct communication with the tendon sheath or may fear that his diagnosis of tendon sheath infection has been incorrect.

Because of necrosis of tendons or superficial involvement of the tendons above the wrist, it may be deemed advisable to make drainage upon the flexor surface. The anterior annular ligament may or may not be cut as is indicated in the given case. If we wish to open the tendon sheath above the ligament without cutting it, the line of incision lies about one-half inch to the radial side of the ulnar artery. Generally, however, the swelling is such that the pulsation of this vessel cannot be felt. It is then necessary to proceed by choosing a point at the junction of the middle and ulnar thirds of the flexor surface and incising carefully, layer by layer, until the group of flexor tendons is reached. These can be identified by moving the fingers. The dissection is now carried down along the ulnar border of these tendons in juxtaposition to them and immediately above the anterior annular ligament, since the sheath lies to the ulnar side and posterior to the tendons. If infected, it should be freely opened, since the swelling due to edema and inflammatory infiltration tends to close a small opening. If the infection is now seen to be at all severe, the anterior annular ligament is split as far to the ulnar side as possible. The hook of the unciform interferes some-

what with the incision. If it is determined at first when the palmar part is incised that the anterior annular ligament shall be cut, one proceeds differently. The incision is continued from below upward, carrying the incision about an inch up on the forearm. This latter is made as much to drain the subcutaneous area above the wrist, which commonly becomes infected, as to open the sheath. This method of drainage of the upper part of the sheath and the forearm was used exclusively in my early cases before I began to use the transverse drainage under the tendons, and, while fairly satisfactory, it in no way compares with the transverse drainage in ordinary cases. Its use should be restricted to exceptional cases.

Concerning drainage in these wounds, it has been my experience that when incision has been made in this manner no drainage material is necessary in a majority of cases. At times I insert small strips of gauze thoroughly saturated in vaseline. Rubber tubes I never use.

It seems especially unsurgical to draw rubber tubes or gauze under the anterior annular ligament. The drainage is not improved and pressure necrosis is favored. Moreover, where drainage at the wrist is unsatisfactory, I have had little cause to be displeased with the splitting of the anterior annular ligament. No case has been seen in which I felt that that procedure *per se* had resulted in loss of function, and I have frequently seen entire restoration of function after it had been cut.

TREATMENT OF EXTENSIONS FROM THE LITTLE FINGER AND THE ULNAR BURSA.—The treatment of the various extensions in the finger proper is the same as that outlined while discussing the index finger. When we come to the base we may have extension either into the ulnar bursa, the lumbrical space, or both.

In the more acute cases the former alone is more common, while in the more chronic type it is often both. Here the incision opening the tendon sheath can be made to drain the lumbrical space.

Extensions into the middle palmar space are opened by following along the lumbrical space as in the other fingers, if the ulnar bursa is uninvolved. If this latter is invaded, the same incision which opens the ulnar bursa may be utilized by inserting the forceps through the synovial wall of the bursa under the tendons into this space. If the pus has extended over to the thenar space it should be drained by making the incision upon the dorsum between the metacarpal bones of the thumb and index finger and opening it by the forceps, as was described above when discussing the extensions from the index finger.

The treatment of involvement of the wrist-joint will be discussed in detail in Chapters XXVII and XXVIII, dealing with chronic processes and complications.

Beginning invasion of the forearm has already been touched upon. Those cases presenting marked involvement of the forearm are best treated by incisions as follows (Figs. 111 and 114):

First, incision upon either side just above the wrist, allowing drainage of the subtendinous space under the profundus digitorum, as described above. These incisions should be increased to two or three inches in length if the accumulation of pus is large. This is especially true of the ulnar side, where even longer incisions can be made with advantage. If the pus has involved the intermuscular septa higher up, the incision should be made about half-way up the forearm upon the ulnar side, either just above the level of the ulnar bone or about an inch farther up on the flexor surface, the desire being in the first instance to go between the

flexor carpi ulnaris and the ulna. Here the muscle must be separated from the bone. In the second instance we attempt to go between the muscular body of the flexor carpi ulnaris and the inner border of the flexor sublimis digitorum. This latter incision gives better drainage, but there is some danger of injuring the ulnar artery either primarily or secondarily. The incision between the ulna and the flexor carpi ulnaris is safer and is sufficiently satisfactory to give good results in a majority of cases. This one incision may be extended for three to four inches and generally is all that is necessary in these cases. The incisions through the flexor surface upon the middle or radial side should be condemned. Particularly in those lying upon the middle, *i. e.*, going through the flexor sublimis digitorum, the inflammatory swelling of the muscular mass acts as an effective barrier to free drainage. I have yet to see the case in which the ulnar incision supplemented by the incisions above the wrist, as described, failed to give free and satisfactory drainage. (For a complete discussion of forearm involvement and treatment see Chapters XXVI and XXVII.)

At times it may be necessary to make some incisions through the skin for the liberation of subcutaneous accumulations of pus, probably lymphatic in origin. The most common site for this is immediately above the wrist on the flexor surface.

Secondary hemorrhage is nearly always from the ulnar bursa. It will generally be advisable to ligate this after verifying the fact that it is the vessel at fault, since repeated hemorrhages are likely to occur if tamponade is depended upon, and the patients are generally not in condition to withstand many hemorrhages. (For a complete discussion of this subject see Chapters XXVI and XXVII.)

When the radial bursa becomes involved secondarily

to the ulnar bursa, it should be treated as a primary radial bursa infection, which we will discuss below. Primary dressing and after-treatment are discussed later.

TREATMENT OF INFLAMMATION OF THE TENDON SHEATH OF THE LONG FLEXOR OF THE THUMB

Here it is my habit to dissect down to the tendon upon the flexor surface of the proximal phalanx; after entering the sheath, the incision is enlarged along the sac through the thenar eminence, separating the muscular mass (heads of the flexor brevis pollicis). It should be remembered that the tendon lies nearer the palm than one would be inclined to think, and that the mass of the thenar muscles lies to the radial side of the incision. This is only carried up to within a thumb's breadth of the lower border of the anterior annular ligament. I limit the incision at this point, since with the assistance of Prof. P. T. Burns and Dr. A. T. Horn, at the Anatomical Laboratory of the Northwestern University Medical School, I made a careful examination of 85 cadaver hands, with the result that it was shown that the motor nerve to the thenar muscles passes across the sheath between this point and the lower edge of the anterior annular ligament, and in my opinion loss of the flexor longus pollicis tendon is to be preferred to destroying this nerve and thus bringing about a loss of the muscles which it supplies. Drainage of the upper end of the radial bursa is best carried out by the methods described above when discussing drainage of the upper end of the ulnar bursa. Incisions are made laterally at the flexor surface of the ulna and radius and through-and-through drainage secured under the flexor profundus tendons. At times incision upon the radial side alone will be sufficient if the sheath has not already ruptured. If

it has not ruptured, two fingers are thrust into the radial incision under the tendons and a grooved director or forceps is pushed up from the palmar incision along the sheath. The end of the forceps is easily felt in the forearm under the tendons. The sheath is opened and gauze saturated with vaseline or gutta-percha strips inserted into the wound for drainage. (For a further study of the basis upon which this method is advised see Chapters XXVI and XXVII.)

At times an accumulation of pus will be found on the forearm subcutaneously just above the wrist upon the radial side. When this is opened the surgeon may be of the opinion that the sheath has ruptured and is thus draining anteriorly; hence, he will desist from drainage of the deeper tissue. Such an accumulation is of lymphatic origin and has no connection with the sheath, so that the lateral incisions described above should always be made in addition to this skin incision in front.

At times, owing to necrosis of tendons or extensive suppuration among them, it may be advisable to drain the sheath from the front, in which case an incision is made going a quarter of an inch to the radial side of the median line of the flexor surface of the forearm. The dissection is carried down to the radial side of the flexor sublimis tendons, avoiding the median nerve which lies in the floor and to the ulnar side. The tendon sheath has generally ruptured by this time, or can be identified by a grooved director or fine probe passed from the opened sheath below. It is entirely safe to cut the upper part of the anterior annular ligament (Fig. 78).

In almost every case, however, I feel that this anterior incision should be limited to opening the subcutaneous accumulation if there be any, and the tendon sheath should be opened by the lateral incisions

described above for entering the space between the flexor profundus tendons and the pronator quadratus. Good-sized incisions should be made, so that drainage may be free.

In many cases where the infection has been severe or the tendon impaired primary removal of the tendon should be favored. This is particularly liable to die and remain for many weeks, causing the infection to persist and jeopardize other structures, so that if the tendon is at all destroyed or the infection shows a slow recovery the tendon should be removed at once. I am also especially inclined to do this if the ulnar bursa has so far escaped involvement, since the preservation of this is particularly to be sought.

The treatment of secondary involvement of the thenar space and the ulnar bursa has already been discussed. Involvement of the carpal joints is discussed in Chapter XXIV. In relation to *secondary ulnar sheath infection*, it may be noted that there is frequently doubt as to the diagnosis in these cases. In such cases it is advisable to dissect down carefully upon the sheath in the lower third of the palm just to the radial side of the hypothenar space. After the palmar fascia is cut a pad of edematous fat will be seen to bulge into the wound as if there were great tension in the subaponeurotic palmar space. This fat having been dissected away, the tense bursa will be seen to bulge into the field. This is opened and the operation proceeds as described above while discussing the technique of treatment of the ulnar bursa. There is always a grave decision to make as to whether or not the sheath of the little finger tendon has become involved, and therefore should also be opened.

When the forearm becomes involved, the treatment is the same as when the involvement has originated

from the ulnar bursa, since the foci of extension are the same.

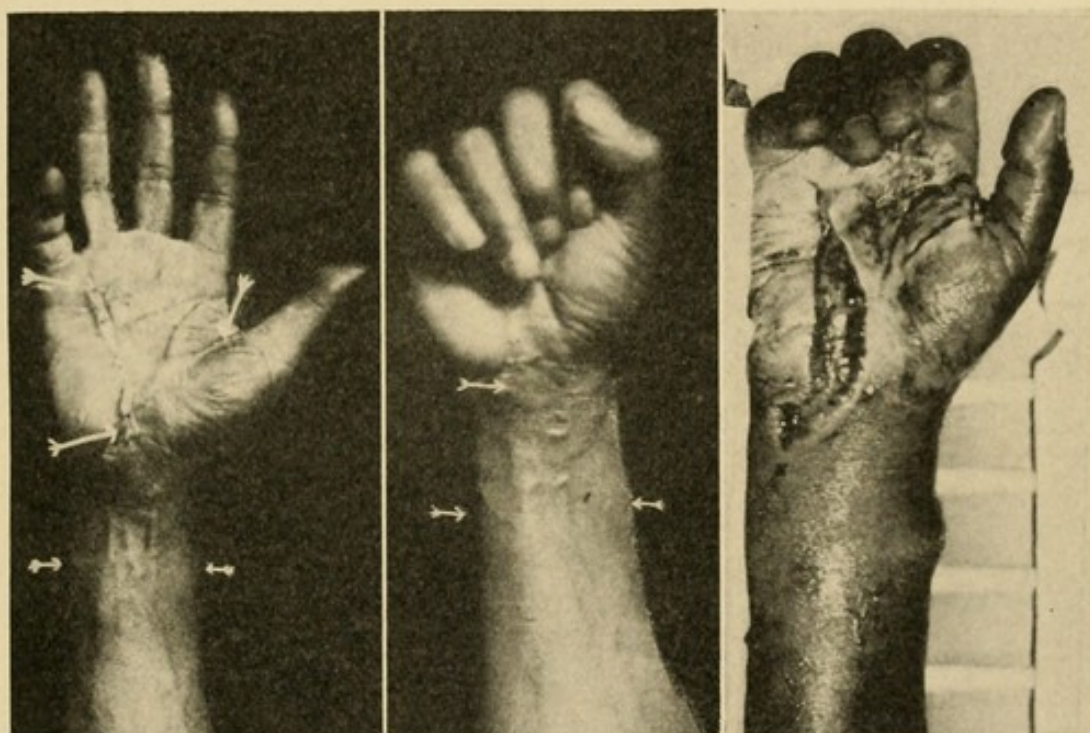
The case of Mr. W. is reported, since it is probably the most virulent case of tenosynovitis beginning in the thumb and extending over by way of the tendon sheath of the flexor longus pollicis to the ulnar bursa that I have had an opportunity to observe. The infection was virulent and the toxic symptoms so severe as to threaten the patient's life. The result was very satisfactory considering the fact that the case did not come under observation until after the sheath had been involved for at least thirty-six hours. In this case there was a complete restoration of function of the entire hand and fingers, with the possible exception of slight loss of flexion of the distal phalanx of the little finger. This result is a marked contrast to those cases of similar nature which I have seen several days after the sheath had become involved, when such destruction of the tendons and their coverings had taken place as to preclude the possibility of a favorable outcome no matter what the surgical procedure might be. The history of the case is practically identical with one seen two months previously, which has remained eight days without opening. The general health and resistance of the individuals were much the same. The outcome in the first case which had been treated conservatively was most disastrous, the patient barely escaping with his life and ending with a functionless hand. After observing these two cases, so close together and with such similar conditions, I cannot but feel that under these conditions conservatism is most inadvisable, and that the earliest possible opening of the sheath is indicated.

CASE XIII.—Mr. W., referred by Dr. Colleran, Post-Graduate Hospital, July, 1908 (Fig. 82).

Patient gave a history of having run a splinter of

wood into the distal phalanx of the thumb seven days previous to coming to the clinic. This had been removed with a penknife, and later, at the end of five days, another splinter had been removed. Three days before, he began to complain of pain over the course of the thumb and radial side of the hand. The whole hand now became tender and swollen.

FIG. 82



Photograph showing the incision in the case of Mr. W., splitting of the ulnar bursa and radial bursa and incisions above the wrist. Accompanying photographs show result two and one-half months after treatment. (See case report, Case XIII.)

On examination, temperature was 101° ; pulse, 96. The whole hand was found to be swollen on both the flexor and dorsal surfaces, as was also the forearm. Concavity of the palm was still present. Tenderness was most marked at the wrist-joint and slightly above on both the radial and ulnar sides. There was tenderness also along the course of the ulnar bursa in the palm of the hand and over the tendon sheath of the little finger.

There was only slight tenderness in the palm of the hand. Tenderness is also found over the course of the flexor longus pollicis. There is no tenderness over the index, middle, or ring fingers and none on the dorsum. On extension of the fingers, extension of the little finger and thumb caused marked pain, the ring finger slight pain, and the middle and index fingers very little pain.

Diagnosis of tenosynovitis of the flexor longus pollicis, the intermediary sheaths at the wrist, and the ulnar bursa was made.

Operation.—General anesthesia; Esmarch's bandage applied. Incision was made through the skin and subcutaneous tissue over the ulnar bursa in the lower third of the palm. After cutting through the palmar fascia the fat bulged into the wound. This was split and the bulging sheath was seen beneath. This was opened and pus found. The sheath was then opened throughout its length from the base of the middle finger up to and through the anterior annular ligament (Fig. 82). Pus was found throughout. An incision was then made in the forearm on either side at the level of the flexor surfaces of the ulna and radius, one inch above the anterior annular ligament; an artery forceps was passed underneath the tendons of the flexor profundus digitorum. A slight amount of pus was found here. An artery forceps now opened the sheath of the ulnar bursa at its upper end, passing into the space underneath the flexor tendons, and a finger enlarged the opening.

An incision was made over the proximal end of the proximal phalanx of the thumb into the sheath of the flexor longus pollicis. A small amount of slightly turbid fluid was present that was not clearly pus. The opening was extended, however, to the distal end, where considerable pus was evacuated. The incision was then extended upward along the sheath to within

a thumb's breadth of the lower border of the anterior annular ligament. Free pus was found here also. An artery forceps was then passed along the sheath up into the forearm underneath the flexor profundus tendons, communicating with the opening previously made.

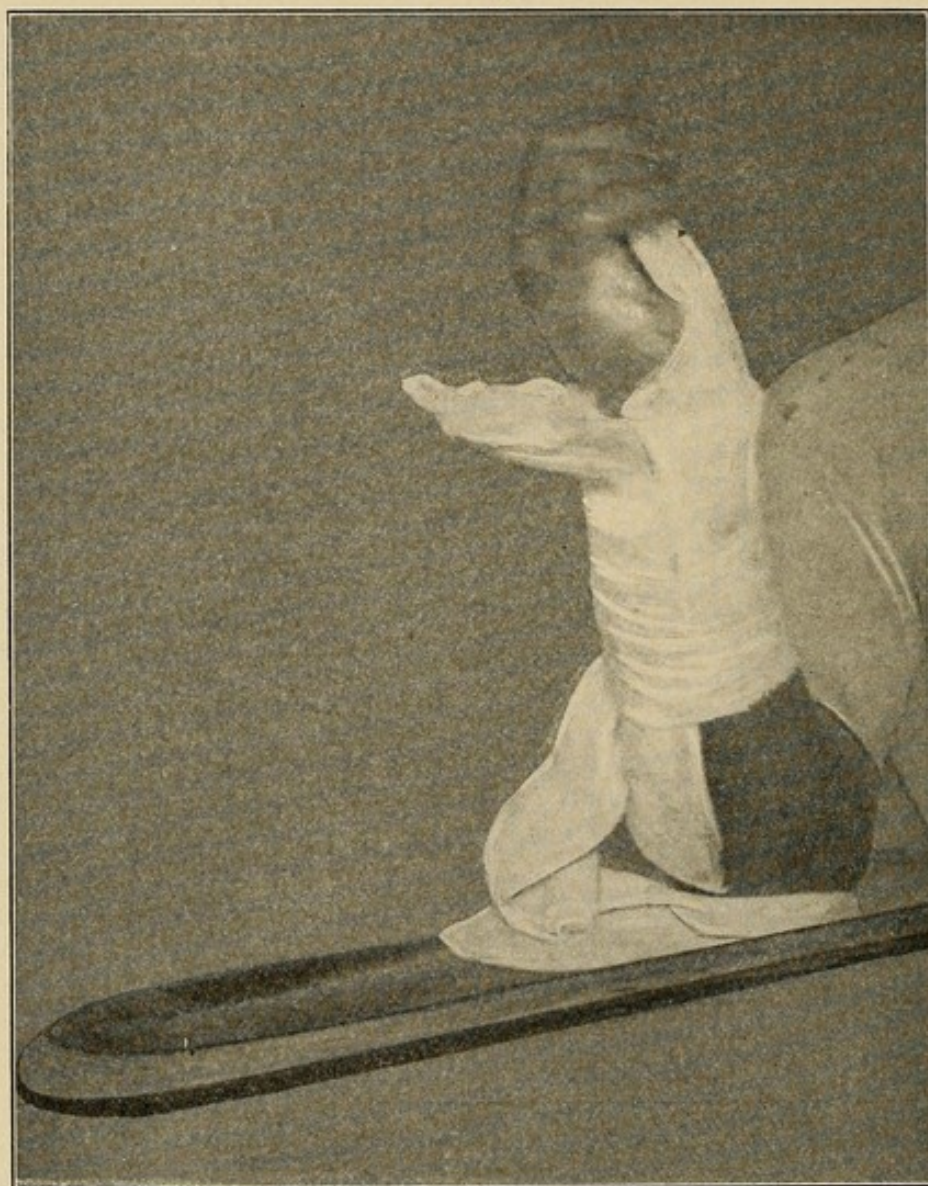After washing the sheath out thoroughly with normal salt solution, strips of gauze saturated with vaseline were laid between the cut edges of the skin and also drawn underneath the flexor profundus. Hot boric dressings were applied.

Subsequent Course.—Pain was immediately relieved, temperature fell to 99° , around which it remained, at no time going higher than 100° , and the patient made a gradual and satisfactory recovery. At the end of twenty-four hours the hot boric dressings were changed for dry dressings, the inner layer of which was saturated with vaseline. The strips of gauze between the edges of the wound were removed, the hand was dressed in dorsal extension on a right angled dorsal splint (Fig. 83).

Subsequent Treatment.—Each day the hand was dressed, each of the articulations was moved, including the finger-joints and wrist, and the hand dressed in dorsal extension. On the fifteenth day it was deemed advisable to open the tendon sheath of the little finger, which had not been opened at the time of operation. A small amount of pus was evacuated, and I believe it would have been advisable to have opened this sheath at the time of the primary operation. The incisions over the flexor longus pollicis were completely healed at the end of three and one-half weeks. Those above the wrist closed at the end of five days. That over the tendons of the ulnar bursa was completely closed at the end of four and one-half weeks. At that time the patient could move slightly all the fingers of the hand and flex voluntarily, with the exception of the

little finger, every joint, including the wrist. He was urged to use his hand repeatedly and to return for passive motions. In this respect he was somewhat

FIG. 83



Photograph showing the dorsal right-angled splint used after splitting the annular ligament in infection of the ulnar bursa. In the photograph the hand has been loosened from the dressing so as to show the right angled splint.

dilatory. At the beginning of the sixth week his hand was treated daily in the Klapp apparatus for breaking up adhesions, and at the end of the ninth week he began to work with his hand, and at the end of the

twelfth week he had practically complete function of all joints and fingers, with the exception of the little finger, where there was only 25 per cent. of function. This will improve, but will never be perfect (Fig. 82).

The following case of acute streptococcic infection of the flexor longus pollicis is reported in some detail, since it is one in which the patient narrowly escaped with her life, and shows the course in these cases; and because the sheath ruptured permitting involvement of the subprofundus space without involvement of the ulnar bursa.

The complete restoration of the tendon function in this case is most encouraging. I believe that with an early incision, carefully followed by conservative treatment, we can hope for much better results in the future than in the past.

CASE XIV.—Dr. S., seen in consultation with Dr. Besley, gave the following history. This is abbreviated from the history sheets of the hospital.

January 23. Pulse, 100; temperature, 101.8° ; respirations, 26. Hot dressings applied to right arm; under nitrous oxide anesthesia, Dr. M. L. Harris incised the flexor surface of the thumb. Condition good.

January 24. Pulse, 80; temperature, 98.6° ; respirations, 20. Slept fairly well. Condition seems very much improved.

January 26. Leukocytosis, 11,000.

January 27. Pulse, 64; temperature, 98° ; respirations, 20. Entire thumb swollen and pus oozes from incisions. Thumb again incised by Dr. Charles Davison; drainage inserted. Normal salt enemias given every four hours; hot boric acid solution to part; 5 P.M., pulse, 80; temperature, 101° ; respirations, 20.

January 29, 4 A.M. Pulse, 108; temperature, 102.8° ; respirations, 26; 8 A.M., pulse, 80; temperature, 103.4° ;

respirations, 22; leukocytosis, 21,000. Thumb irrigated with hot boric and peroxide; dry dressings applied; 9 P.M., temperature, 102.2°; palm of hand greatly swollen and angry red extending into wrist. Vomited small amount of fluid.

January 30, 9 A.M. Temperature, 101.6°; nauseated and vomited greenish fluid; face flushed; slept very little.

January 31, 9 A.M. Temperature, 101.4°; pulse, 96; respirations, 20. Swelling on hand increasing and extending; under gas-ether anesthesia Dr. F. A. Besley made an incision into the radial bursa, liberating yellowish pus. Rubber drain inserted, allowing free drainage between first and second metacarpals. Small incision made above wrist, but no pus found in arm, although there was considerable redness and swelling.

February 1. Pulse, 84; temperature, 102°; respirations, 20. Slept some since 10 P.M. Pain in hand. Hot dressings. Smears from pus show short chains of streptococci.

February 2. Temperature, 101.6°; leukocytosis, 24,000. Feels rather drowsy. Does not have much pain. Slept at intervals.

February 3. Pulse, 84; temperature, 100.2°; respirations, 20. Cultures on agar and in bouillon show only streptococci; leukocytosis, 32,000. Under gas anesthesia incisions enlarged and opened wide by forceps by Drs. Besley and Kanavel.

February 4, 1 A.M. Pulse, 80; temperature, 102°; 9 P.M., temperature, 101°. Slept much of forenoon.

February 5, 10 A.M. Temperature, 102°. Hand dressed. Swelling, hyperemia, and tenderness along flexor surface of arm, radial side. Pus oozes from wounds. Good night's rest; 4 P.M., pulse, 112; temperature, 103°; respirations, 24. Another incision made in forearm by Dr. Besley. The incision was made on

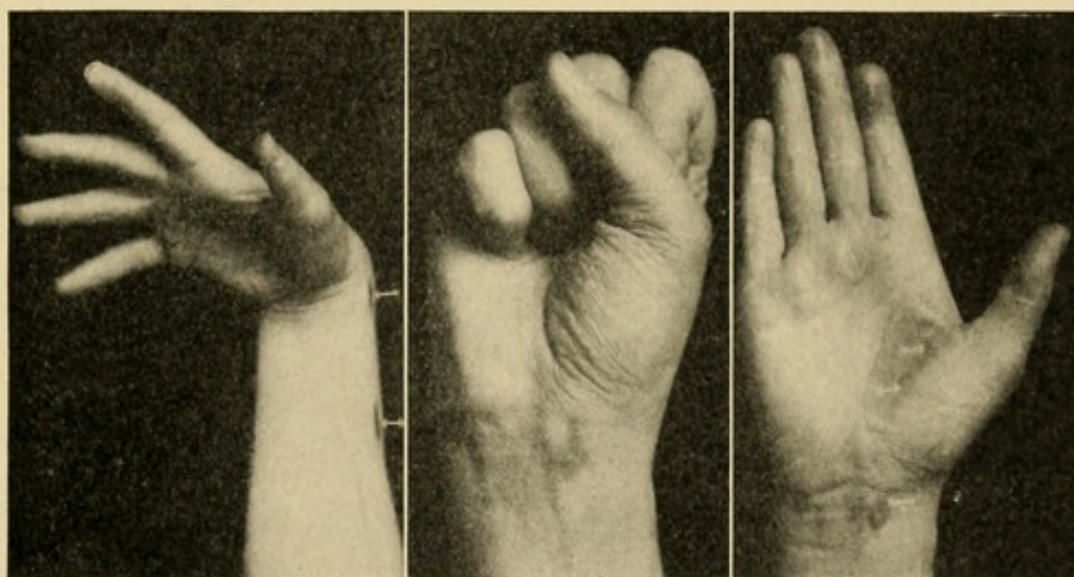
radial surface of arm, and liberated a large quantity of yellow pus. Gauze packing inserted. Gas anesthesia. 7.30 P.M., gauze packing removed. Patient rather restless.

February 6. Pulse, 92; temperature, 102° ; respirations, 20.

February 7. Pulse, 90; temperature, 99.4° ; respirations, 20. Patient very comfortable. Small superficial pocket of pus on anterior surface of wrist opened by Dr. Besley.

February 8. Pulse, 80; temperature, 98° ; respirations, 20.

FIG. 84



Photograph showing the function present in Case XIV; infection of the radial bursa, three months after treatment.

From this time on the temperature remained normal. Patient gradually improved, and was discharged February 24. The wound in the thenar space closed about two weeks later.

Subsequent History.—At the end of five months the case presents a complete restoration of function of the muscles of the thumb and the tendon of the flexor longus pollicis, and the tendons of the hand upon flexion (Fig. 84).

SYNOVIAL SHEATHS ON THE DORSUM

When the synovial sheaths upon the dorsum are infected, a simple splitting of the sheath throughout its length apparently gives the best results. I have had only four of these cases due to acute infection, and they all recovered with good function after a short time, with the exception of the case in which this involvement was associated with a palmar infection, in which a fatal issue followed (Case XXII).

AFTER-TREATMENT

DRAINAGE.—The use of drainage has been discussed by every surgeon, and the principles underlying it here are the same as elsewhere. Those who after much experience and thought have decided upon its use will probably use it here. My own results have led me to abandon it almost entirely. I never use a rubber tube, owing to my fear of pressure necrosis. Gauze, if left in many hours, begins to act as a plug. Unless there is bleeding, it is not used. If, however, one fears that the skin will close down at once and prevent the escape of pus, gauze saturated with vaseline is inserted. I have found this to give good drainage and not to act so much as a plug, yet giving tampon pressure in cases of oozing. Strips may be inserted from the sides above the wrist under the flexor profundus, and also above into the ulnar incision on the forearm. I have also used gutta-percha strips with satisfaction. In my earlier cases drainage tubes were inserted through from the palm to the dorsum, after the older methods of palmar drainage, but since introducing palmar drainage along the lumbrical spaces this procedure has been abandoned entirely.

After the incisions are made every part is thoroughly

washed out by salt solution from an irrigator or pitcher. Strong antiseptics are never used. In the virulent cases, every attempt is made not to manipulate the arm and hand any more than is necessary, so as to protect the patient against absorption of toxins as much as possible. The application of the Bier method of constriction of the arm to prevent the rapid absorption of bacteria and toxins during and immediately after incision has already been touched upon. During the after-treatment the same precautions are taken so long as the process is acute. The area is kept immobilized and slightly elevated. This latter is done to secure comfort as much as to aid in recovery. The von Volkmann treatment, *i. e.*, vertical elevation of the hand, has not seemed to me to be of great therapeutic value, although apparently it is a valuable procedure in that it prevents excessive edema in the later stages.

For the first few days after incision it would appear that hot, moist dressings are of value to relieve the pain and promote walling off of the infection. After this stage they should be abandoned in favor of dry dressings, since they seem to produce excessive granulation. In several cases I have been able to apply dry dressings at the end of twenty-four hours. The hot, moist dressings are generally made from a saturated solution of boric acid. However, it is probable that the moist heat is the essential factor. Strong antiseptic solutions, such as bichloride and carbolic acid, are never used. The inner layer of the dry gauze may be saturated with vaseline to prevent it adhering to the wound.

The hand is dressed from once to twice daily. If gauze has been inserted and has adhered to the wound, there is less shock produced by anesthetizing the patient with a small amount of nitrous oxide than is given by the pain incident to withdrawal without such an aid.

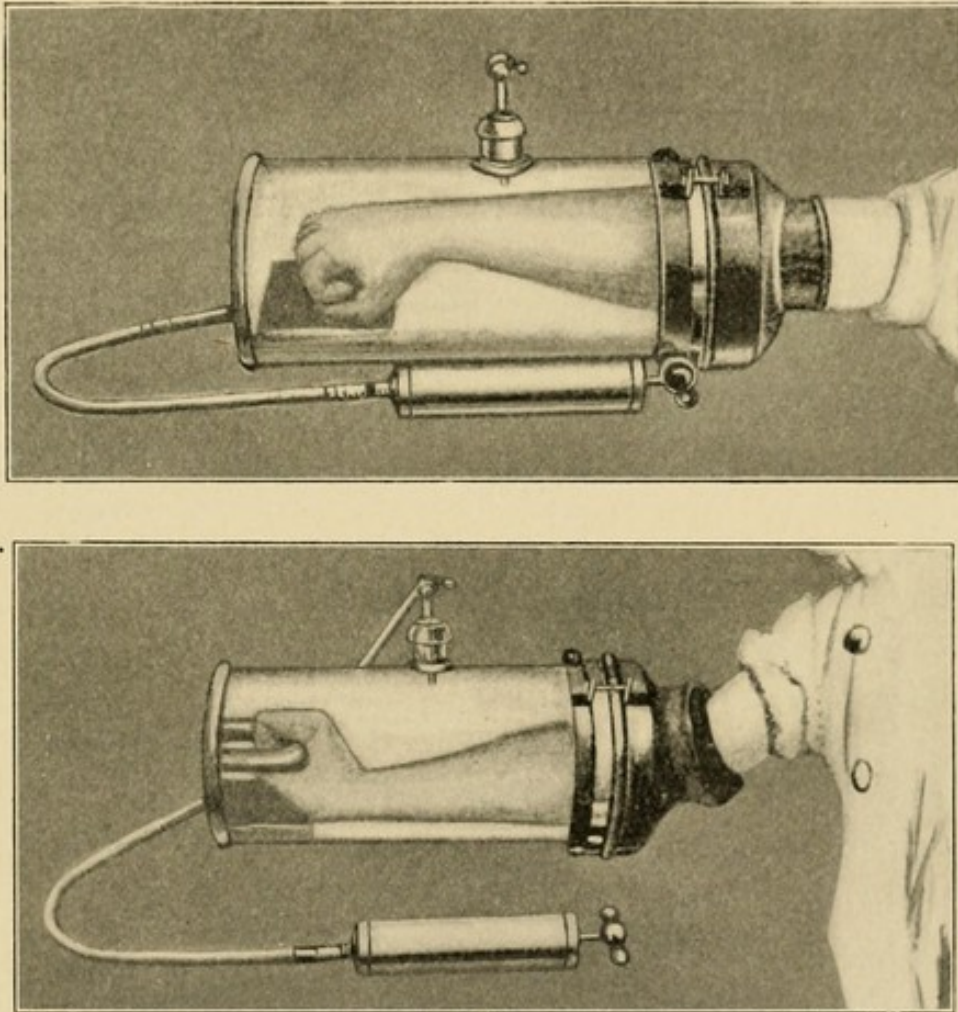
The hand is dressed with the fingers in extension upon a dorsal splint. This is done to prevent prolapse of the tendons. In the first few dressings the hand may be flexed and normal salt irrigation used to wash out about the tendons. In the fingers this procedure is of special importance, not only to avoid the prolapse of the tendons, but also to prevent all of the fingers tending to become flexed in one position.

The prolapse of the tendons at the wrist is prevented by dressing the hand with the wrist sharply bent backward. I ordinarily mould a plaster of Paris splint to fit the back of the forearm up to the wrist; here the plaster splint is bent back at a right angle. The hardened splint is applied to the forearm and held in place by a bandage. A second bandage now attempts to bring the hand back to the horizontal prolongation. At times I have used light elastic pressure. The tension and position are varied from day to day after danger of prolapse has ended, so as to prevent ankylosis of the tendons and joint in one position. The primary splint is applied immediately after the operation (Fig. 83).

The prevention of adhesions in the joints, preservation of the vitality of the muscles, and the use of the tendons is most important, and at times the results are discouraging. Unfortunately the surgeon sees these cases so often after primary incisions have been made and the case treated for several days. In those severe fulminating types this has permitted such destruction of the tendons and synovial coverings as to make any after-treatment of little avail. It seems to me advisable to begin passive and active movements within a few days after primary incisions; in other words, as soon as the danger of systemic infection is over. I do not believe that the local condition is made materially worse, and we do aid in the prevention of firm adhesions.

It is better to do this in baths of very hot water, which relieves the pain to some extent and helps to cleanse the discharging wound. The patient's hand and forearm being immersed in hot sterile water, the surgeon with glove-covered hands gently flexes and extends

FIG. 85



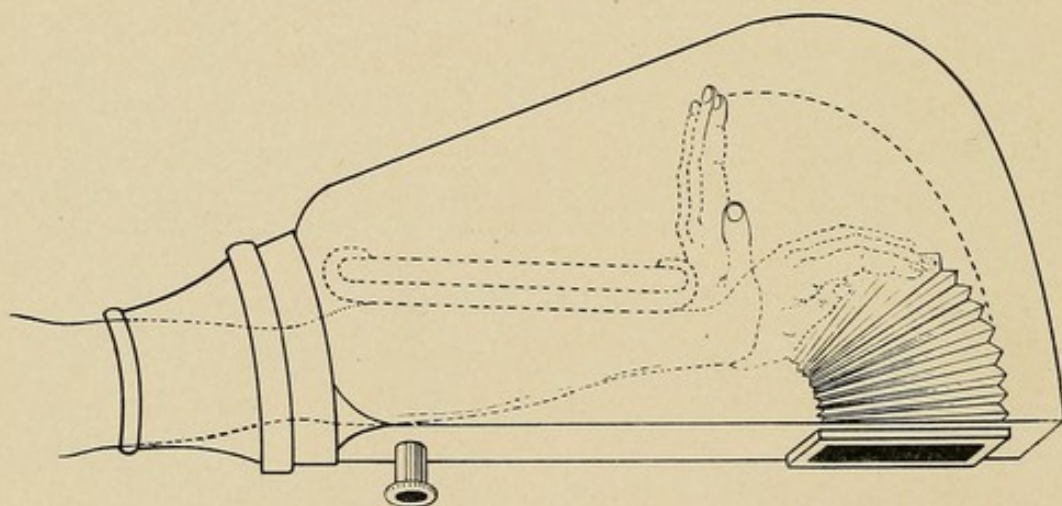
Showing the Bier apparatus for production of mobility in stiffened tendons and joints.

each finger, as well as the hand at the wrist, several times. Violent movements are not indulged in. The bath is not kept up any length of time, since we wish to prevent rather than to favor the development of granulation tissue at this stage. The patient is

encouraged to make active movements himself. If a dry, hot chamber is at hand, this may be used to advantage. I cannot emphasize too strongly the importance of this early, gentle, and intelligent manipulation. I do not refer to massage, but to the intelligent use of the various joints, muscles, and tendons.

Bier (Fig. 85) and others (Fig. 86) have used mechanical appliances to produce the same effect. The force may be exerted by exhausting the air in a chamber in which the hand has been placed, the hand or the individual fingers being applied to the fixed end, so

FIG. 86



Showing the Klapp apparatus for producing mobility in stiffened wrist-joint.

that when the air is exhausted the joints are flexed or extended. He attributes some of his good results to the therapeutic effect of exhausting the air and producing a hyperemia. The apparatus also has the advantage that the patient will be more persistent and regular in the application of the treatment than he will be if he depends on treatment by the surgeon alone. The results of treatment may be materially bettered by such an apparatus, as I have had opportunity to verify in my late cases. The surgeon must not expect that it will cure old contracted cases or those with great destruction of tissue.

CHAPTER XVII

THE TREATMENT OF FASCIAL SPACE ABSCESSSES

WE shall here consider the treatment of fascial space abscesses uncomplicated by tenosynovitis, or in case of complications presenting only those of minor importance, so that the fascial space abscess is still the predominant picture.

The treatment naturally divides itself into prophylactic and active. In the first instance all wounds should be given aseptic care, and any localized infection should be attended to, thorough drainage being instituted before the infection has a chance to spread. In those cases in which we are waiting to decide whether or not a localized abscess is present, immobilization and the local use of the well-known hot, moist dressing is probably more efficient than any other application. The usual general tonic and excretory procedures should be instituted.

Should the diagnosis of a localized accumulation of pus in any of the various tissues be made, our first question is, What is the best site for incision? for we need not discuss the proposition that such a condition as that demands early and efficient drainage. Should the subcutaneous tissue of the dorsum or the areas under the epidermis or derma of the palm be involved, or minor infections of the thenar and hypothenar areas be present, a wide opening by simple incision is generally sufficient. Should the middle palmar, thenar, lumbrical, or subaponeurotic spaces be involved, however, some special consideration is necessary.

THE MIDDLE PALMAR SPACE

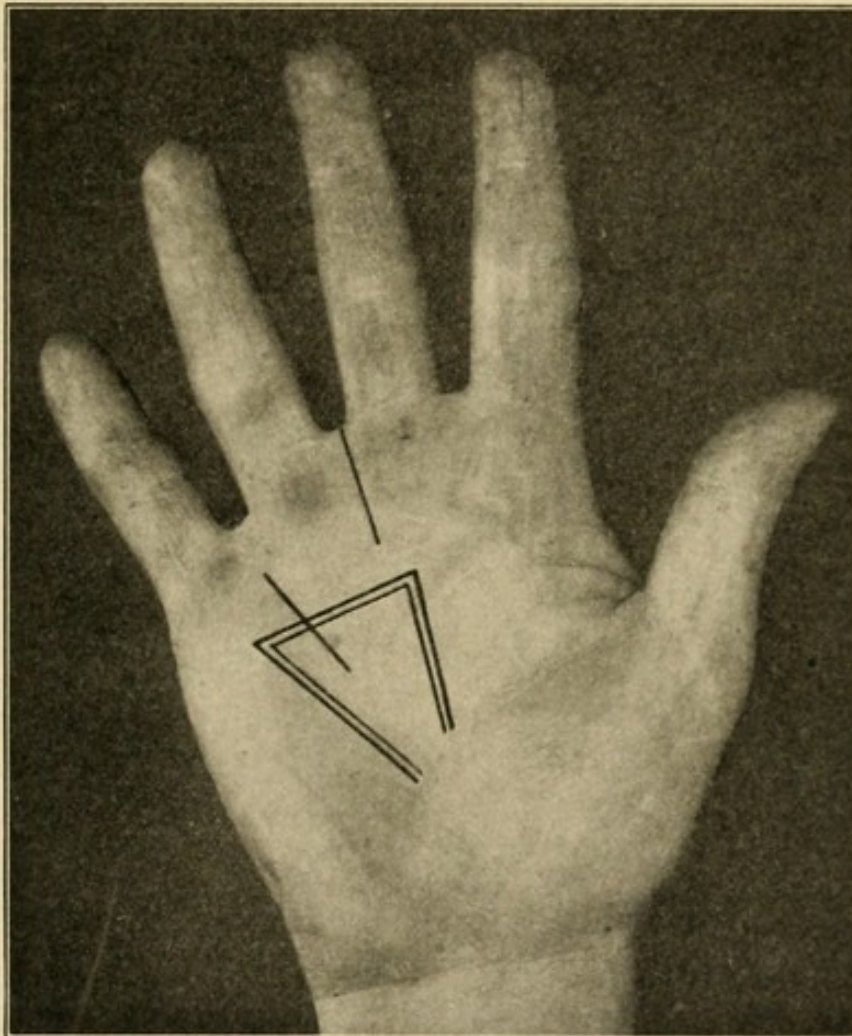
TECHNIQUE OF TREATMENT.—The opening of the middle palmar space is a grave responsibility; the diagnosis is difficult, and, on the other hand, the danger of delay is great. It is probably better to err upon the side of radicalism, however, than conservatism, owing to the liability of complications in the ulnar synovial sheath, the bones, and the joints.

Any method of opening the space exposes certain tissues to injury, and it is a question of choosing the least dangerous route. It cannot be opened upon the ulnar side, owing to the fear of infecting the ulnar bursal sheath; a flap of the palmar fascia should not be dissected up from below, as has been suggested, making a sort of trap-door, as it were, since the infection lies below the tendons, and to make such an opening and then drain anteriorly between the tendons would result in unnecessary adhesions.

The least injury and the most efficient drainage of the middle palmar space can be secured by an incision along one of the three lumbrical canals leading into this space, *i. e.*, the little finger, ring finger, or the middle finger canals (Fig. 87). That canal will be chosen which is already markedly infected, either because it has been the atrium of the infection or because it has been secondarily involved. If the surgeon has any choice in the matter, that between the ring and middle fingers gives the most satisfactory drainage. An incision is made into the canal and carried one-half inch above its end up into the palmar space, *i. e.*, one-half inch proximal to a line joining the proximal end of the distal flexion crease with the distal end of the middle flexion crease, or, grossly speaking, a thumb's breadth and a half up into the palm. This brings the incision between the tendons. An artery forceps is

thrust under the group of palmar tendons and the blades opened, satisfactory drainage ensuing. A small strip of gutta-percha or gauze saturated with vaseline will keep the opening from closing for a day, after which time it will not be needed. I think that I am indebted

FIG. 87



Showing incisions for opening the lumbrical space and for opening the lumbrical space in conjunction with the middle palmar space.

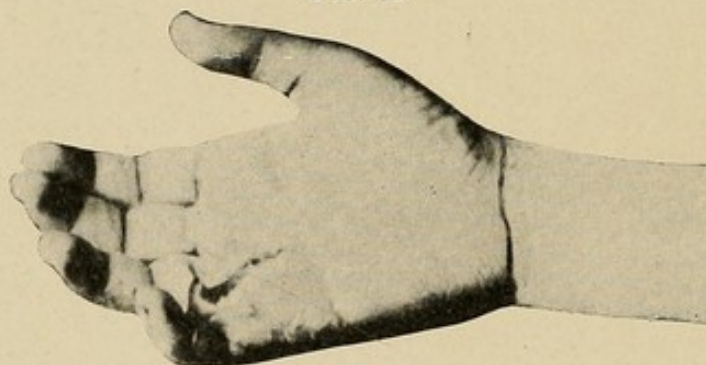
to Dr. F. A. Besley for the suggestion as to this method of incision. It is remarkable how rapidly cases will recover under this treatment.

Herewith is reported the first case in which I used this method. I have used it many times since with absolute satisfaction.

CASE XV.—Infection base of palm spreading along lumbrical canal into palm; incision along canal. Recovery with perfect function.

M. R., treated at the Post-Graduate Hospital, July, 1906. Service of Prof. F. A. Besley. Five days before entrance patient developed an infection from the crack of a callus at the base of the palm of the right hand between ring and little fingers. An abscess had formed in the fascial space at the base of these fingers and extended along the lumbrical canal. Upon investigation it was found to have involved the middle palmar space. This was diagnosticated by the tenderness localized

FIG. 88



Photograph of incision in a case of infection in the middle palmar space originating in web at end of lumbrical canal. Recovery with complete function in ten days. Patient—Relihan. (See Case XV.)

over the lumbrical canal, and the bulging of the palm associated with localized tenderness. The incision was made at the original site of the infection, passing from the palm through the fascial tissue to the dorsum between the proximal phalanges of the fingers. A grooved director was then inserted along the lumbrical canal, which was opened throughout its extent, the incision being carried up to the middle flexion crease of the palm; in other words, one-half inch above the lumbrical canal. Forceps were now inserted underneath the tendons, opening the palmar space widely; about one ounce of pus escaped, no drain was inserted, hot boric dressings applied.

Course.—At the end of ten days all discharge of pus had ceased and wound had healed. At the end of three weeks complete function was present in all the fingers and hand (Fig. 88).

THE TREATMENT OF COMBINED INVOLVEMENT OF THE MIDDLE PALMAR AND THENAR SPACES

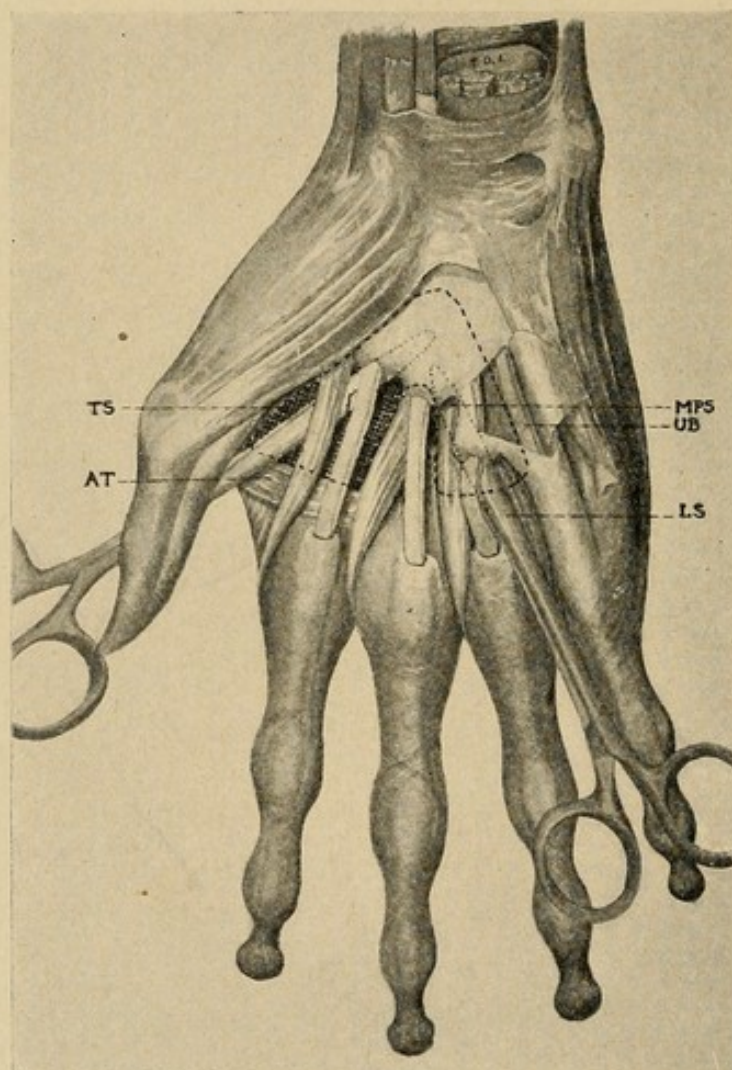
The treatment here can be best illustrated by quoting a typical case. Here the middle palmar and the thenar spaces having been simultaneously involved, the forceps is passed from the incision into the middle palmar space under the palmar tendons, as already described, and pushed through the thin septum separating the palmar and thenar spaces at the proximal end, the point thus passing through the thenar space superficial to the adductor transversus and coming out on the dorsum between the metacarpal bones of the thumb and index finger (Fig. 89). A drainage strip is then drawn through and left eighteen hours.

CASE XVI.—Primary infection, cracks from callus on palm, extension into palm of hand, drainage of middle palmar space, thenar space, ulnar bursa, and forearm. Recovery with perfect function.

H., Post-Graduate Hospital. Two weeks before coming to the hospital patient had developed an infection in the palm of the hand, evidently in the callus produced by tongs handling ice. Two or three inadequate incisions had been made when the patient entered the hospital, with a temperature of 102° and an enormous swelling of the entire hand and forearm, involving the palmar and dorsal surfaces. The palmar fascia bulged up instead of presenting its normal concavity, while the thenar area was ballooned out as if inflated to its complete capacity. There was redness and swelling upon the flexor surface of the forearm involving par-

ticularly the lower third. The swelling upon the back of the hand was ascribed to edema. The fingers were flexed at an angle of 45 degrees, while the metacarpal bone of the thumb set back from the hand and the distal phalanx of the thumb was sharply flexed. The

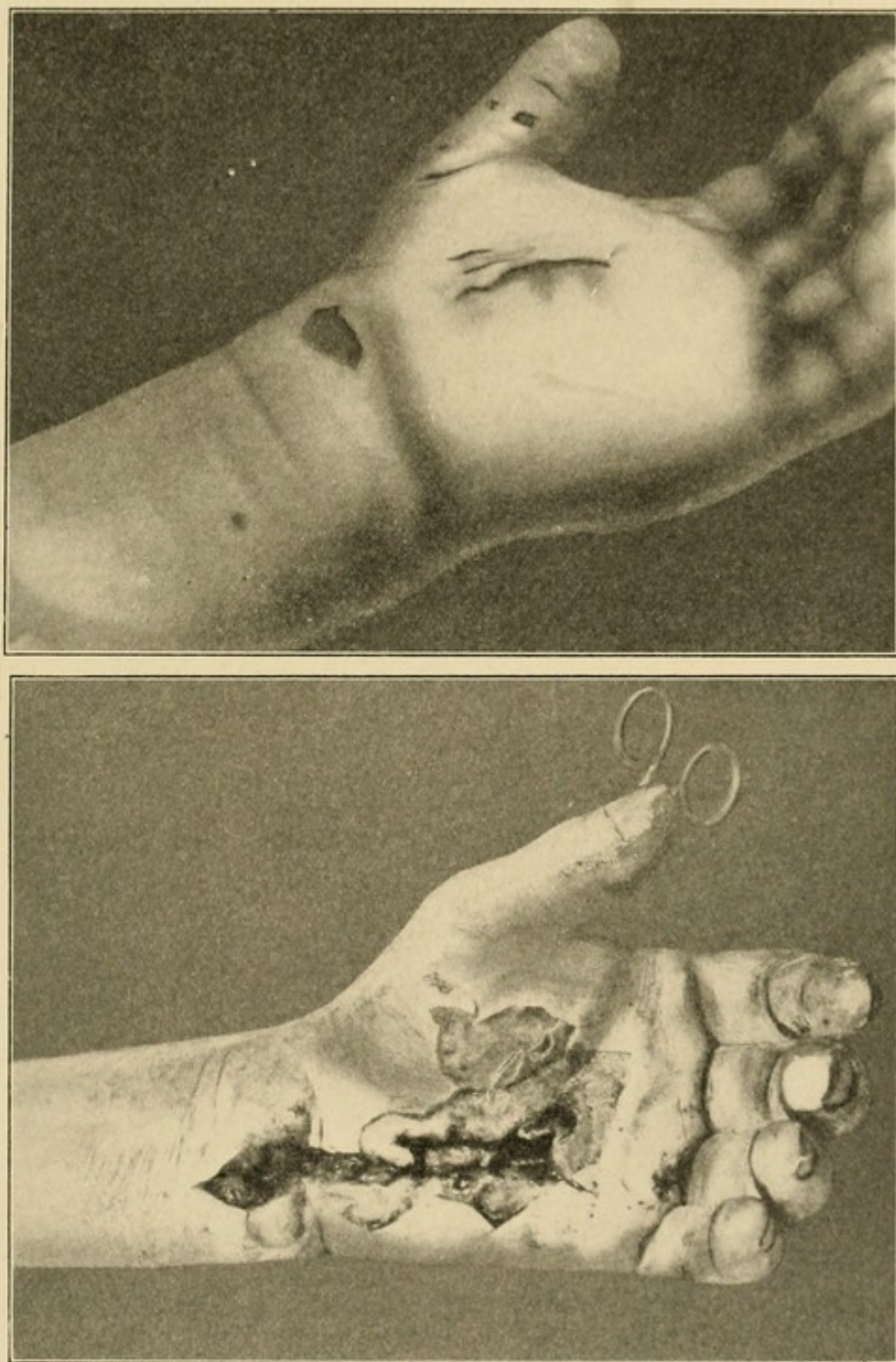
FIG. 89



Drawing showing the drainage under tendons.

diagnosis of pus in the middle palmar space, thenar space, the forearm under the profundus tendons, and the probable involvement of the common synovial sheath in the palm was made. Owing to the inadequate incision already made in the palm, this was chosen as

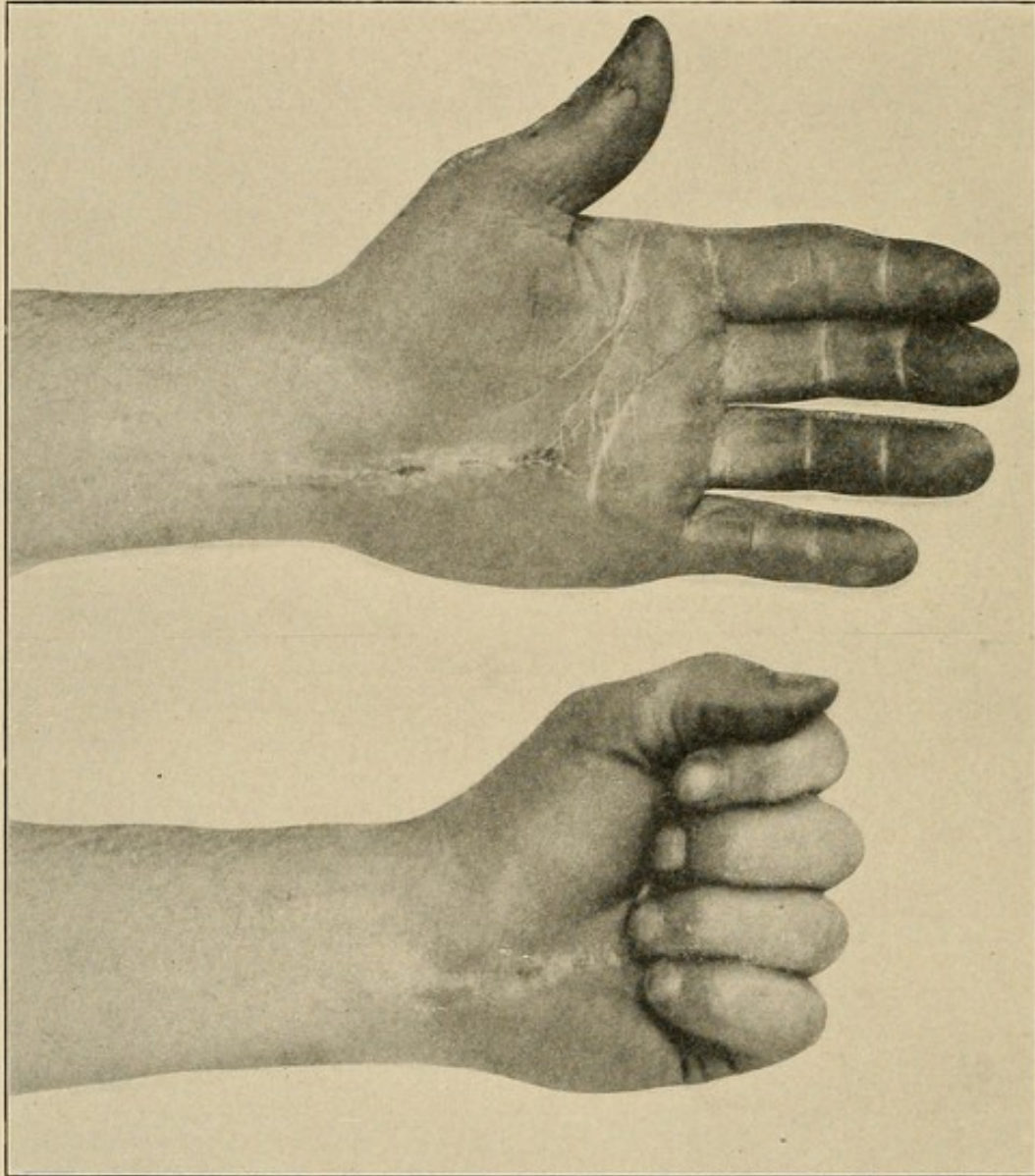
FIG. 90



Photograph of the hand of H. before and after incision. Note the artery forceps through from the dorsum into the thenar space. In this case the anterior annular ligament was cut. (Case XVI.)

the proper site for exploration. The incision having been carried through the palmar fascia, pus was found in the position designated with the involvement of the ulnar bursa from the base of the little finger to

FIG. 91



Showing result in the case of H. three months after treatment. Note perfect function. (Case XVI.)

the forearm. This was opened throughout its length, cutting through the anterior annular ligament. The major portion of the pus, however, lay outside the sheath. An artery forceps was inserted under the

tendons of the palm below the sheath and a large ostium made. An artery forceps was then thrust through the partition between the thenar and middle palmar spaces at the base of the hand lying on the volar side of the transversus pollicis, coming out between the metacarpal bones of the thumb and index finger. A drainage strip was then drawn through this space of the palm and left in eighteen hours. The incision, which was carried through the anterior annular ligament to the forearm, exposed a large abscess lying underneath the tendons of the flexor profundus digitorum upon the pronator quadratus and interosseous membrane. The incision was extended for three inches up on the forearm to open this space completely. Hot boric dressings were applied.

Course.—Immediate subsidence of temperature and septic symptoms. In ten days complete cessation of discharge, and in two weeks all wounds were healed. In three weeks the patient was using his hand with 75 per cent. of function, and in five weeks complete function was present, as demonstrated by accompanying photographs (Figs. 90 and 91).

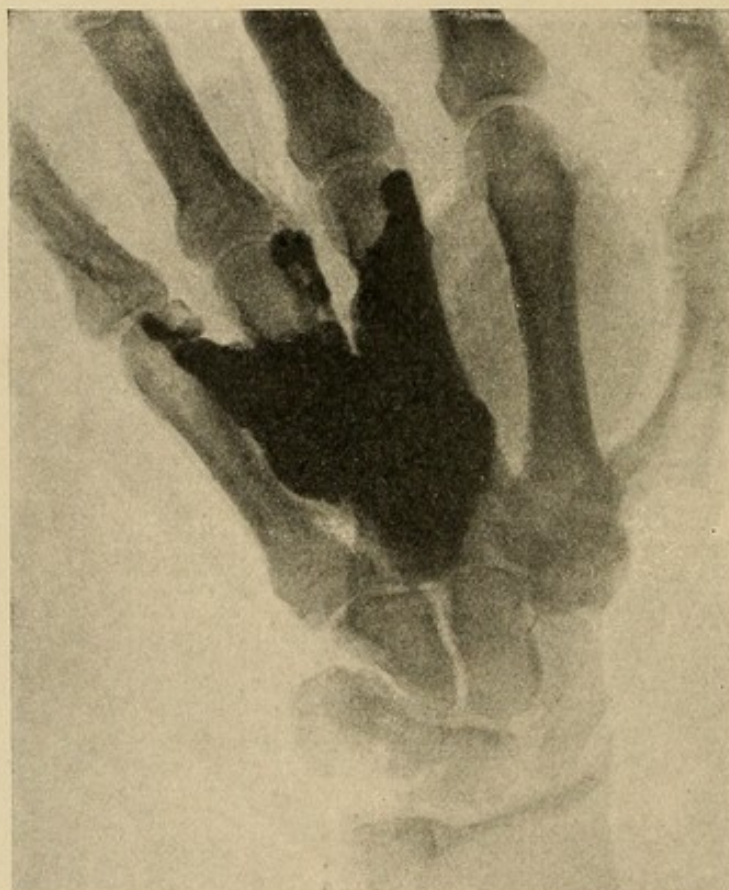This case was one of the worst that ever came to my notice. We were fortunate, however, in that no necrosis of the tendons had taken place. The rapid and complete recovery can be ascribed only to the thorough opening of every pocket of pus by incisions that did not endanger previously uninvolved areas. We should also note that the annular ligament was cut.

THE TREATMENT OF COMBINED INVOLVEMENT OF THE MIDDLE PALMAR AND SUBAPONEUROTIC SPACES

At times we will have crushing injuries of the hand in which the metacarpal bones are fractured. Here the *subaponeurotic space on the dorsum is involved in con-*

junction with the middle palmar space (Case VIII). In such cases the through-and-through drainage so much in vogue among the older surgeons is indicated. Let us study where such drainage can be safely instituted if it is indicated. Such a point should be chosen as would give the most satisfactory outlet to all the diver-

FIG. 92

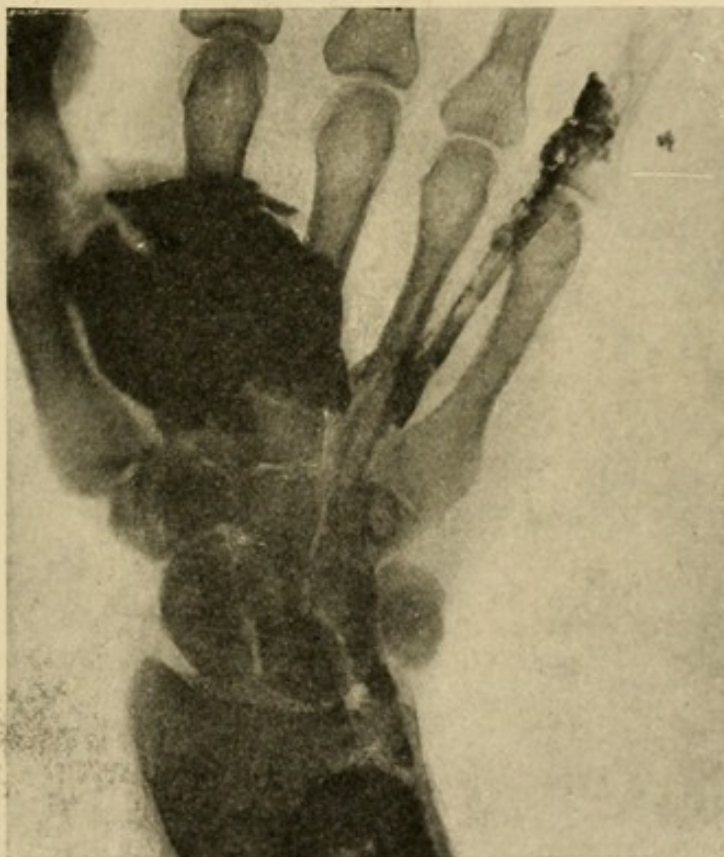


X-ray plate made from a hand in which the middle palmar space was injected with a mixture of red lead and plaster of Paris. Photograph represents location of pus and typical middle palmar space infection.

ticula, and at the same time injure the fewest structures. Here the value of our x-ray plates, with the cross-sections and injections, is invaluable. We see that the mass always lies over the interosseous space between the ring and middle fingers, and that an opening here will drain all the pockets (Fig. 92). Our incision, however, must lie proximal to the superficial trans-

verse ligament (see cross-section, Fig. 22; x-ray, Fig. 94). Secondly, it must lie to the radial side of the ulnar bursa (x-ray plate, Fig. 93), and must be to the ulnar side of the middle metacarpal, or it will enter the thenar space. This again throws the incision into the metacarpal space, between the middle and ring fingers. Thus we see that not only are the fewest structures injured at this site, but also the most perfect drainage is instituted.

FIG. 93

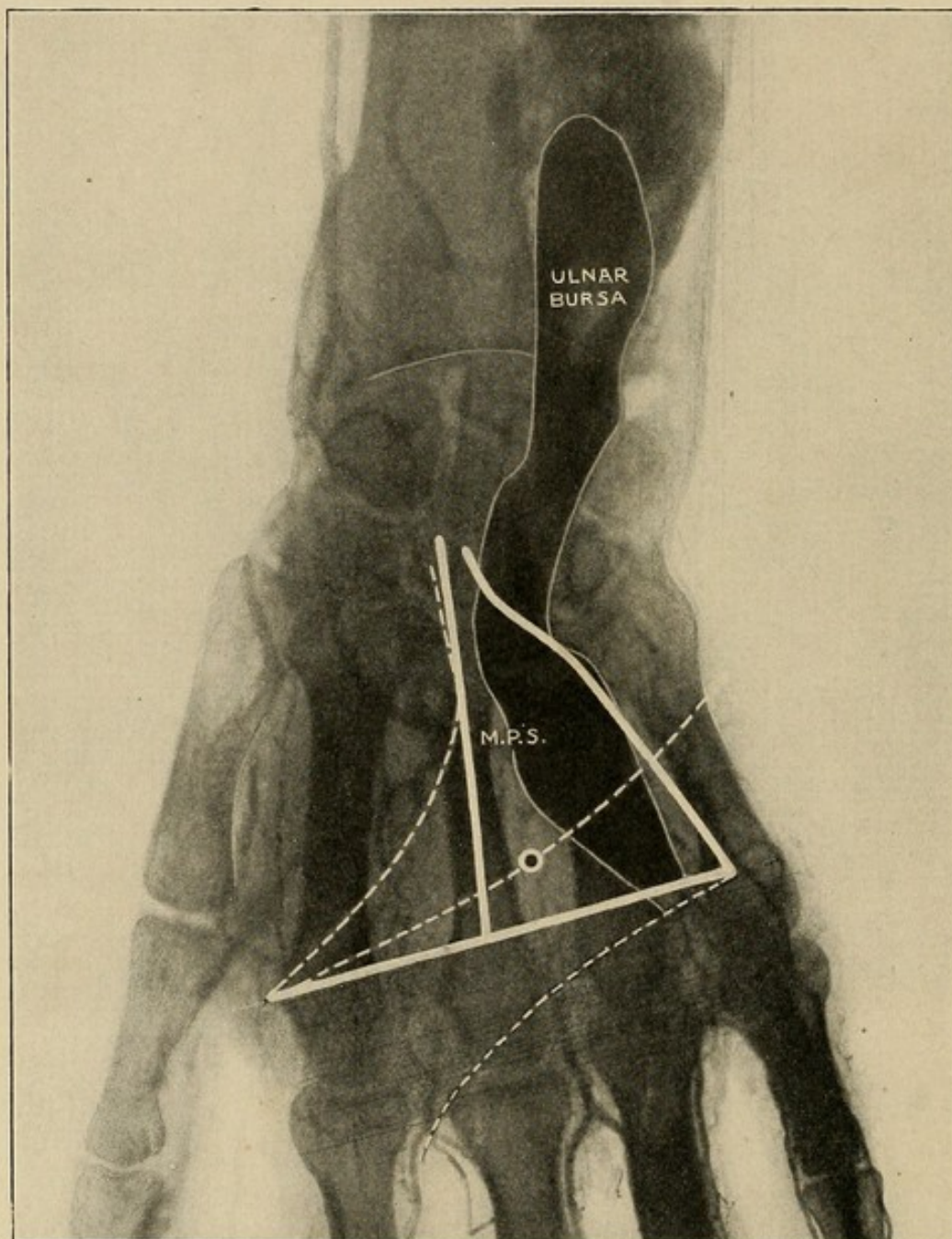


X-ray plates, representing the location of pus in the thenar space, with its relation to the ulnar bursa.

Now let us consider where an incision should lie in this space. An examination of the x-ray picture (Fig. 94) shows the deep palmar arch running across this area, at the upper end; the fine lines drawn transversely represent the dense transverse ligament while the curved lines represent the palmar creases. It is thus

seen that at the point where the middle palmar crease crosses the metacarpal space should be the indicated

FIG. 94



X-ray Plate.—Boundaries of the thenar and middle palmar spaces marked, and proper site for opening the latter indicated. Ulnar bursa and blood-vessels injected. Photograph made for me by Dr. Cubbins' Surgical X-ray Laboratory.

site for drainage. Making a cut here through the palmar aponeurosis, and then forcing a pointed artery forceps

through to the dorsum, being careful to rupture the dorsal aponeurosis freely, we draw through a large twisted gutta-percha strip. At this site there is little danger of a pressure necrosis of the ulnar bursa or the palmar arches.

TECHNIQUE OF TREATMENT OF ABSCESES IN THE THENAR SPACE

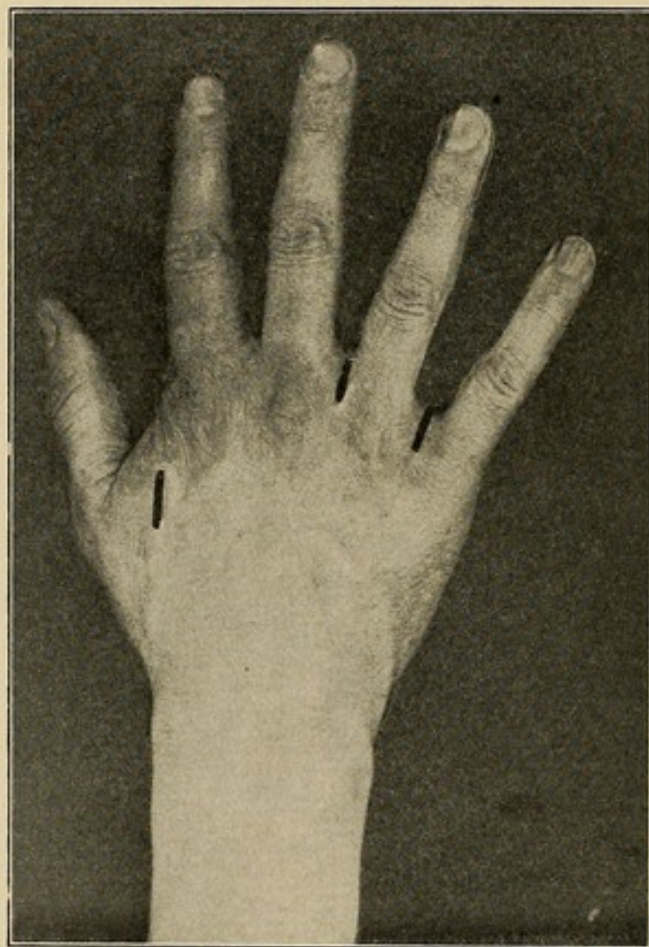
Should the thenar area be involved, the indications for radical operation are absolute, even upon less evidence than in the case of palmar infection, since here the dangers of delay are greater, and the consequences of opening the space, even though uninfected, are not serious (see Case VI, in which space was opened when uninfected, under mistaken diagnosis). Here the pus lies either anterior to the adductor transversus, or upon both its dorsal and palmar surface. Theoretically, the most available place to open would lie to the radial side of the index metacarpal, where a free incision would drain both in front and behind the adductor. We therefore make an incision through the dorsum, on the radial side of the index metacarpal and opposite its middle, and on a level with its flexor surface. An artery forceps is then thrust into the thenar space across the flexor surface of the index metacarpal. This gives perfect drainage and leaves no scar upon the flexor surface of the hand. Care should be taken not to pass the artery forceps beyond the middle metacarpal bone, for fear of spreading the infection to the middle palmar space (Fig. 95).

Illustrating these facts, the following case may be cited:

CASE XVII.—K., injured September 3, 1904. The sharp point of a meat tongs ran into the thenar area upon level of the extended thumb about 2 cm. from the

thenar adductor crease. Pain and swelling ensued the following day. On September 5 he consulted a physician, who found much redness and swelling upon the dorsal thenar area and made an incision there, but evidently failed to evacuate pus. Hot dressings were

FIG. 95



Showing incisions made upon the dorsum of the hand. That upon the thenar space is made to drain the thenar space and the palm. Those upon the distal part are made to drain extensions from the palmar space to the dorsum and the so-called collar-button abscesses when they extend to the dorsum.

applied, and two days later patient presented himself at the Northwestern University Surgical Dispensary for treatment. There was considerable swelling of the whole hand, but distinctly greater upon the radial side. Dorsal thenar area had slightly greater swelling present than palmar thenar area. Upon inspection it

was not difficult to see that the thenar area, as a whole, was much more swollen than the remainder of the hand. Adduction thenar crease was the dividing line. Thumb metacarpal fully abducted, proximal phalanx semiflexed, distal phalanx fully flexed, giving an almost spastic look to the hand. The finger phalanges were all semiflexed. The flexion of the index finger, however, was more rigid than that of the other three, and movement of it and the thumb caused more pain than of the three ulnar fingers. Both epitrochlear and axillary glands slightly enlarged and tender. Old incision upon dorsal thenar region, from which small amount of pus was exuding. Temperature, 101° ; pulse, 90. Tenderness marked over palmar thenar area.

Diagnosis.—Abscess, thenar space. Operation: Under nitrous oxide anesthesia incision made into thenar area at about the same site as the wound; much pus evacuated. Gutta-percha drainage established; hot, moist boric dressings applied. September 7, swelling almost subsided, still discharge of much pus. Temperature, 99° ; pulse, 84. Treatment continued. Cultures taken; typical staphylococcus aureus colonies, methylene blue and Grams stains; staphylococcus aureus. September 9, hand much better, drainage removed, hot dressings reapplied. September 11, hand in good condition; dry dressings applied. Following this, patient made a rapid recovery. Seen July, 1905. No contraction; function perfect.

TECHNIQUE OF TREATMENT OF ABSCESSSES IN SUBAPONEUROTIC SPACE

If the subaponeurotic space be involved, we should remember that the tendons proper in the lower part of the dorsum overlie the metacarpal bones, except the tendon going to the little finger; consequently our incision should lie over the interosseous space. More-

over, any deep transverse incision, if too long, would cut the tendon, while a simple longitudinal incision would tend to close. Therefore, in making our incision and drainage, these two factors should be taken into consideration and an adequate opening provided, which does not injure the tendon. Those cases complicated with middle palmar space infection have already been discussed (p. 289).

If the infection has spread up under the annular ligament into the forearm, the pus will lie beneath the tendons of the flexor profundus and upon the pronator quadratus. The best method of emptying this abscess would be to go laterally, just anterior to the radius and ulna about three inches from the wrist. A complete description of the method of treating these cases will be found in Chapter XXVI.

AFTER-TREATMENT IN FASCIAL SPACE ABSCESES

After any of these procedures the usual hot, moist dressings are applied until we feel that extension of the process has ceased, when they should be abandoned, since the continuation of the enlargement of the vessels incident to their use results in increasing edema and ultimately lessening resistance, owing to improper circulation; hence they become a menace to the part rather than a help. At this stage elevation of the part will be found to be of material aid. Immobilization should be kept up as long as there is any danger of muscular action disseminating the infection. As soon as this stage has passed, however, active and passive movements should be encouraged at once, with the idea of assisting in the absorption of the excessive edema, as well as assisting in the prevention of tendon and joint adhesions. I frequently begin these on the third day.

CHAPTER XVIII

PROGNOSIS AND RÉSUMÉ OF ACUTE SUPPURATIVE TENOSYNOVITIS AND FASCIAL SPACE ABSCESES

PROGNOSIS

THE life of the individual is frequently jeopardized in either of these types of infections. Undoubtedly if proper treatment is instituted the danger will be reduced to a minimum. The lymphatic infections which will be discussed in the subsequent chapters are the most frequent source of death. The fulminating type of tendon-sheath infections may cause death, but the more chronic type, as also the fascial space abscesses, should have few fatalities except in neglected cases. Especial caution should be exercised in giving a favorable prognosis in the aged, since the prognosis grows rapidly worse after forty. The presence of a nephritis is also of serious import.

It is very nearly impossible to state from a study of the literature what proportion of cases may hope for a satisfactory local outcome. The authors base their statistics upon different classifications. "Good result" is used by some to designate a recovery without loss of any part of the hand, with function at the wrist and in the uninvolved fingers, while others insist upon a complete restoration of the function in the finger as well. It is to be hoped that in the future the statistics may be more accurate. From my personal experience, however, I feel that the following statements may be made. A complete functioning hand can always be promised in acute infections of the hand, not involving the tendon sheaths, unless necrosis of tissue has taken

place or joint involvement has occurred. That is to say, abscesses of the middle palmar space, thenar space, and forearm, as well as simpler conditions, can be treated with a perfect functioning result. This has occurred in my experience even after four or five weeks of inadequate treatment. In tendon sheath infection, however, the results are not nearly so good. By proper and early treatment a perfect result can generally be assured as to function of the wrist-joint, hand and fingers not involved. Where the tendon sheath of a finger is involved, unless early treatment is instituted, flexion of the phalanges of that finger is likely to be lost, while flexion at the metacarpophalangeal articulation may generally be preserved. In early cases or under exceptional circumstances complete function may be secured. In the thumb, even though the function of the flexor longus pollicis is lost, the hand will not be seriously impaired, since the smaller muscles of the thumb will give it such function that the impairment will not be as serious by any means as in the fingers. Extension from tendon sheaths to the forearm should be looked upon with anxiety, and if serious complications or sequelæ are present, the patient must be warned that the course may be long and the ultimate restoration of function depend much upon continued and faithful application of after-treatment.

RÉSUMÉ

Success in the treatment of tendon-sheath infections of the hand depends upon early accurate diagnosis, upon incisions so made as to drain the proper sites without involving uninfected areas, and upon careful after-treatment.

Two types must be recognized, the fulminating and the subacute. The treatment will vary with the type. The most marked symptoms and signs are: Localized

excruciating tenderness over the course of the sheath, pain on extension, especially at the proximal end of the sheath, and the characteristic position of the finger.

Infection from the tendon sheath of the index finger will most often extend to the proximal interphalangeal joint, thenar space, lumbrical spaces, and the surface at the proximal end of the sheath.

From the middle finger it most often extends to the proximal interphalangeal joint, the lumbrical spaces, the surface at the proximal end, and the middle palmar space, although it may invade the thenar space.

From the ring finger the extensions are the same, except that it always involves the middle palmar space if extension takes place into the palm.

From the little finger, the most common sites of extension are to the proximal interphalangeal joint (not common), the lumbrical space, the middle palmar space, the surface at the proximal end of the sheath, and the ulnar bursa. From the ulnar bursa, it may extend to the middle palmar space, radial bursa, interosseous space below the flexor profundus, and the wrist-joint. From the sheath of the flexor longus pollicis to the thenar space, ulnar bursa, wrist-joint, and interosseous space above described.

Incisions should be too radical rather than too conservative. Incisions are best made in the fingers, either upon one or both sides of the tendon sheath over the length of the shaft of the middle and proximal phalanx, avoiding the joints, and into the proximal end of the sheaths or the lumbrical spaces to provide drainage there. Complete splitting along one side should be done in case of doubt as to the adequacy of drainage which should be the first requisite.

The ulnar bursa is best treated by splitting it throughout its length, cutting upon the ulnar side. The anterior annular ligament may be cut if necessary. This is commonly supplemented by incisions upon the

radial and ulnar sides of the forearm above the wrist-joint, and on a level with the flexor surface of the bones; through-and-through drainage is then carried out under the flexor profundus tendons. An ulnar incision may be sufficient. If the pus has invaded the forearm, an ulnar incision is made at the middle of the forearm between the flexor carpi ulnaris and the flexor sublimis, or between the flexor carpi ulnaris and the ulna.

Incision of the flexor longus pollicis sheath is made from a finger breadth below the anterior annular ligament to the end of the sheath. Opening may be made above the anterior annular ligament, the upper half of which may be cut. However, drainage may be better instituted above the wrist by the lateral incision mentioned under ulnar bursal infections.

In the after-treatment the Bier constrictor may be used for a few hours, hot, moist dressings for from two to four days, followed by dry dressings, the hand being held in overextension by splint, daily manipulation of joints and muscles after immediate danger of systemic infection has ended.

There may be accumulations of pus in any of the six fascial spaces I have described, to the exclusion of any or all the others, namely, the middle palmar, thenar, lumbrical, hypothenar, dorsal subaponeurotic, dorsal subcutaneous. These may be involved separately or in conjunction with the tendon sheaths. The middle palmar space with its diverticula along the three lumbrical muscles is best drained by an incision along a lumbrical canal carried up to the space. The thenar space is best drained by an incision on the dorsum to the radial side of the index metacarpal. Hypothenar abscesses are localized and can be drained by simple incision. All forearm extensions may be drained by lateral incisions above the wrist, the drainage being inserted under the tendons of the flexor profundus digitorum.

SECTION III

LYMPHATIC INFECTIONS

CHAPTER XIX

THE RELATION OF LYMPHANGITIS TO OTHER TYPES OF INFECTION—DIS- CUSSION OF THE ANATOMY

THE RELATION OF LYMPHANGITIS TO OTHER TYPES OF INFECTION

LYMPHANGITIS may be of two types, superficial and deep. Of these, the superficial is most common, owing to the fact that slight abrasions, superficial fissures, and small punctures, disregarded by the patient because they are considered of no importance, are generally the source. These lie in the superficial tissues and lead to a superficial or subcutaneous infection. The rarer type, deep lymphangitis, may undoubtedly occur. When it does, however, it develops as a complication of superficial lymphangitis or as a sequence of deep injury, and when such deep injury occurs the wound is generally considerable, so that the lymphangitis is of secondary importance to the local condition.

For the sake of study, lymphangitis must be sharply differentiated from tenosynovitis and fascial space infection. It is true that in a large number of cases a tenosynovitis or fascial space infection may develop from a lymphangitis, but it is also true that in a majority of cases neither complication ensues unless ill-advised surgery produces them. Under pathogenesis I shall

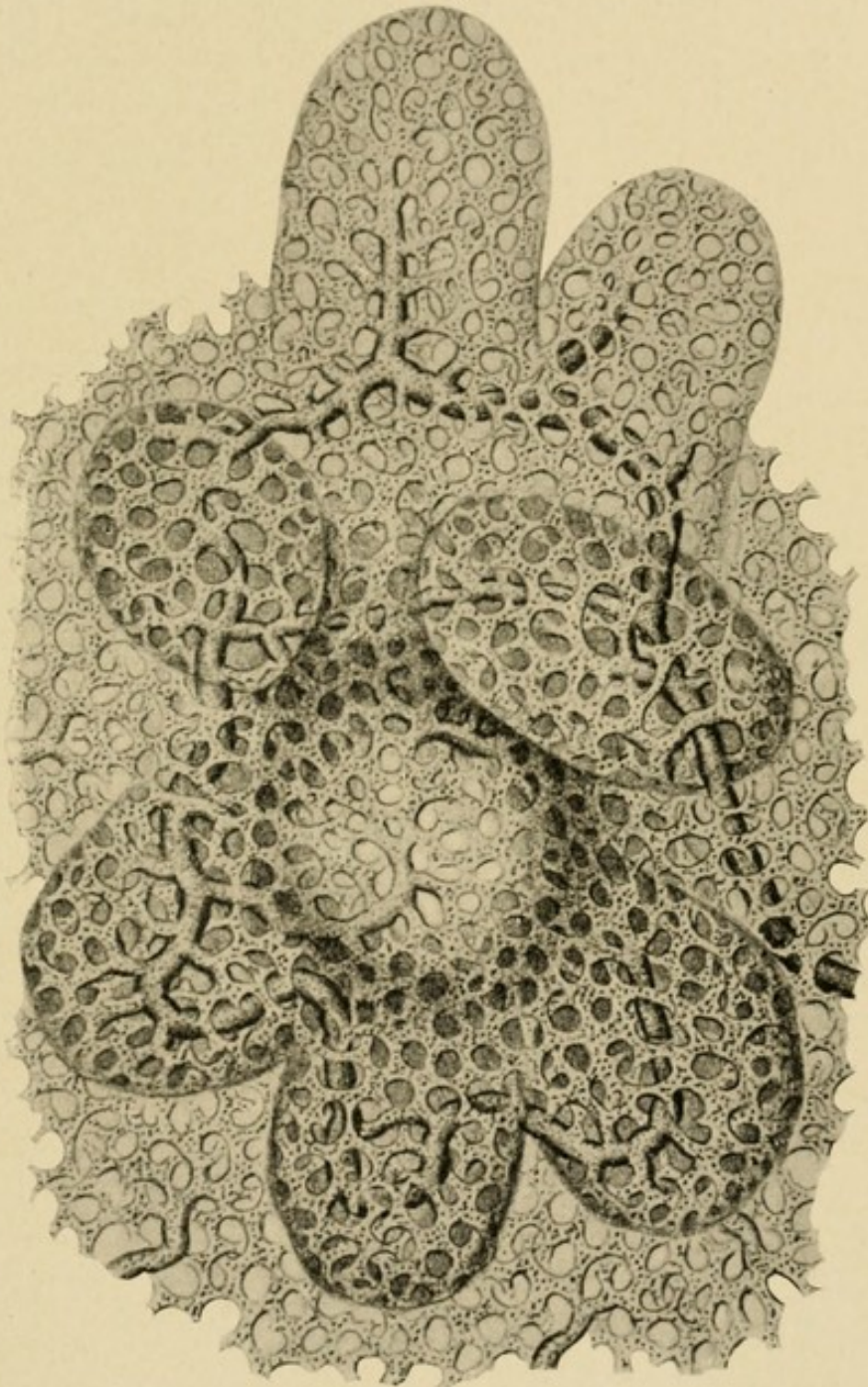
discuss these complications in full, and under symptomatology shall try to suggest the various points which may serve to differentiate them when they are separate conditions or may serve to diagnosticate their development when they arise in the course of a pure lymphatic infection. Owing to the intimate relation of lymphangitis to septicemia, it has seemed wise to associate the discussion of the former with that of the latter, and, for the sake of the clinical picture, to consider in relation to them the various severe infections jeopardizing life, such as gas bacillus infections and anthrax. A complete discussion of tenosynovitis and fascial space abscesses may be found in the preceding chapters.

ANATOMY

In order to understand the pathogeny of lymphatic abscesses, an accurate knowledge of the position and course of the lymphatic vessels is absolutely essential. The masterful work of Mascagni and the later work by Sappey have been fully reviewed and verified by Poirier, with the assistance of his pupil Cuneo, making use of Gerota's process of injection, and the following is largely quoted from their treatise upon that subject. We so often see the superficial lymphatics in the course of surgical practice that we are inclined to forget that there are deep lymphatics which follow the deeper vessels. Sappey believed that these two symptoms were absolutely independent. Poirier, however, maintains that communication is fairly common, especially in the articular regions. It is important to remember that the principal vessels and glands lie superficial to the large veins and seldom deep. The clinical significance of this is apparent to the surgeon. Another general point of importance is that the texture of the surrounding connective tissue influences their shape and

number. If the connective tissue is lax, their tendency is to run together and become sinuous and sacciform

FIG. 96



Drawing showing lymphatics grouped about a hair follicle on the dorsum. Character of lymphatic tissue commonly seen in loose connective-tissue spaces. (After Sappey.)

(Fig. 96). Consequently the infection is likely to localize in the looser connective-tissue areas. This

probability is accentuated by the fact that glands, either microscopic or macroscopic, show a predilection for these areas. The fact that sacciform dilatations and microscopic glands do occur explains the production of abscesses in the course of an apparently uninterrupted lymphatic. Moreover, the variability both in the number and the position of these glands renders absolute statements as to their position impossible. Not alone are microscopic glands present in the course of the vessels; Gulland has demonstrated them in the axilla, and Stiles has seen axillary glands appear during lactation and disappear on its cessation. However, this may be stated: In a given animal and a given region the quantity of glandular tissue is always practically identical. Thus if the glands are small they are numerous, and if large they are likely to be scarce. In any case, however, they are generally paravascular.

THE LYMPHATIC VESSELS OF THE HAND AND FOREARM

These may be divided into two groups—the superficial lymphatics, which arise from the integument and whose collecting trunks run in the subcutaneous cellular tissue, and the deep lymphatics, arising in the deeper tissues and in vessels following the deep blood-vessels.

SUPERFICIAL LYMPHATICS

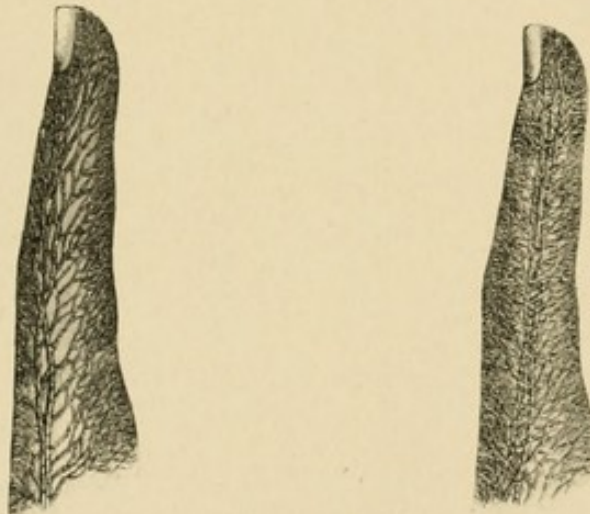
These, being easily demonstrated experimentally and seen so often clinically, are well known.

“The superficial lymphatics come from all parts of the cutaneous covering of the limb, but it is in the fingers (Fig. 97) and the palm of the hand that the network of origin is the richest. It is therefore at

these points, and more particularly on the palmar surface of the fingers, that punctures must be made for the injection of the lymphatics of the upper limb.

"The collecting trunks of the superficial network appear at the roots of the fingers and at the base of the palm of the hand (Fig. 98). They then run upward on the forearm and arm, receiving as they ascend the lymph from other parts of the cutaneous covering. They terminate in the glands of the axilla. We will study first their digital and palmar origin, and then their course and termination.

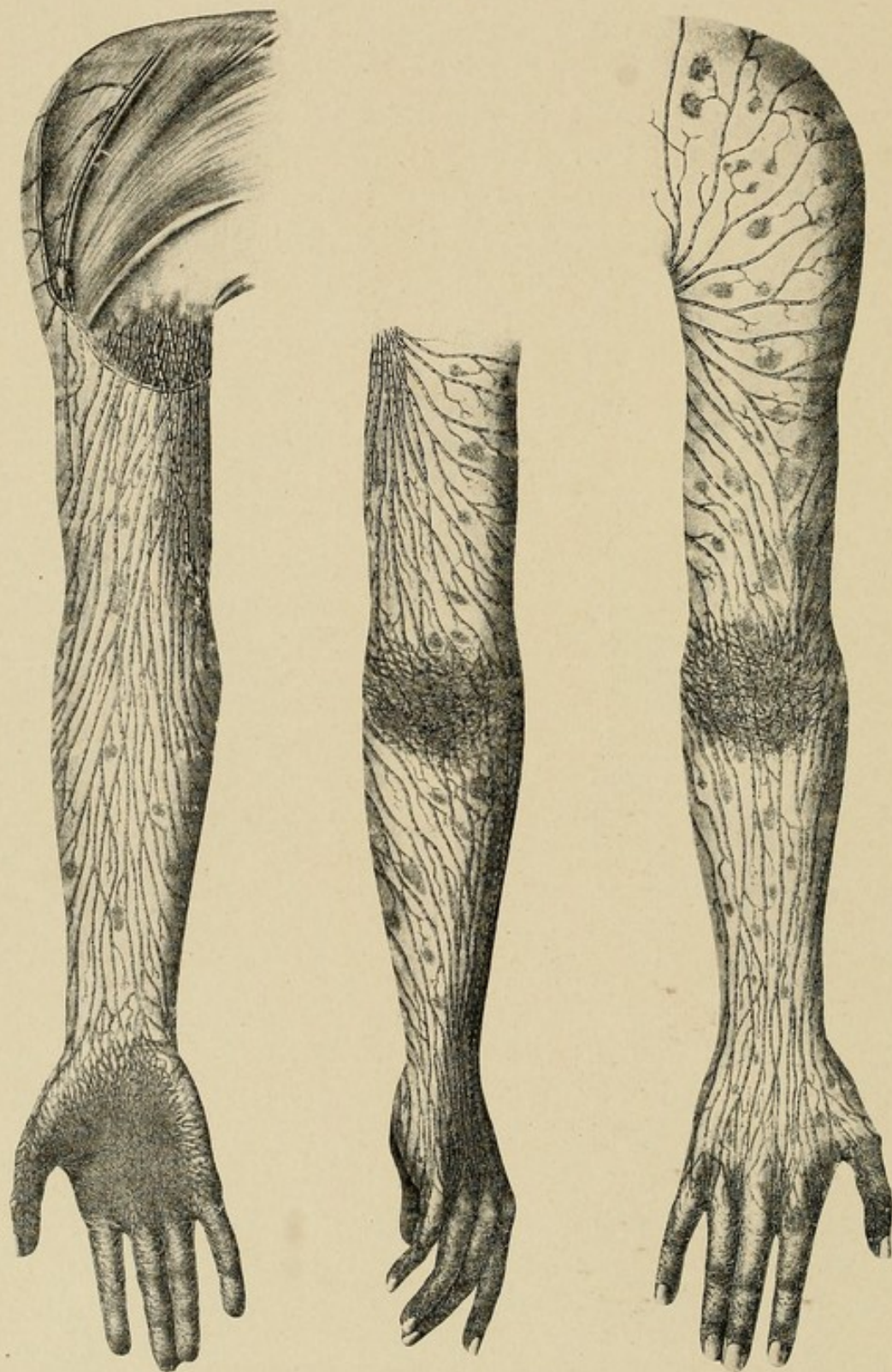
FIG. 97



Network of lymphatics on the side of the finger. The accompanying drawing represents the trunklets which carry the lymphatic stream to the base of the finger. (After Sappey.)

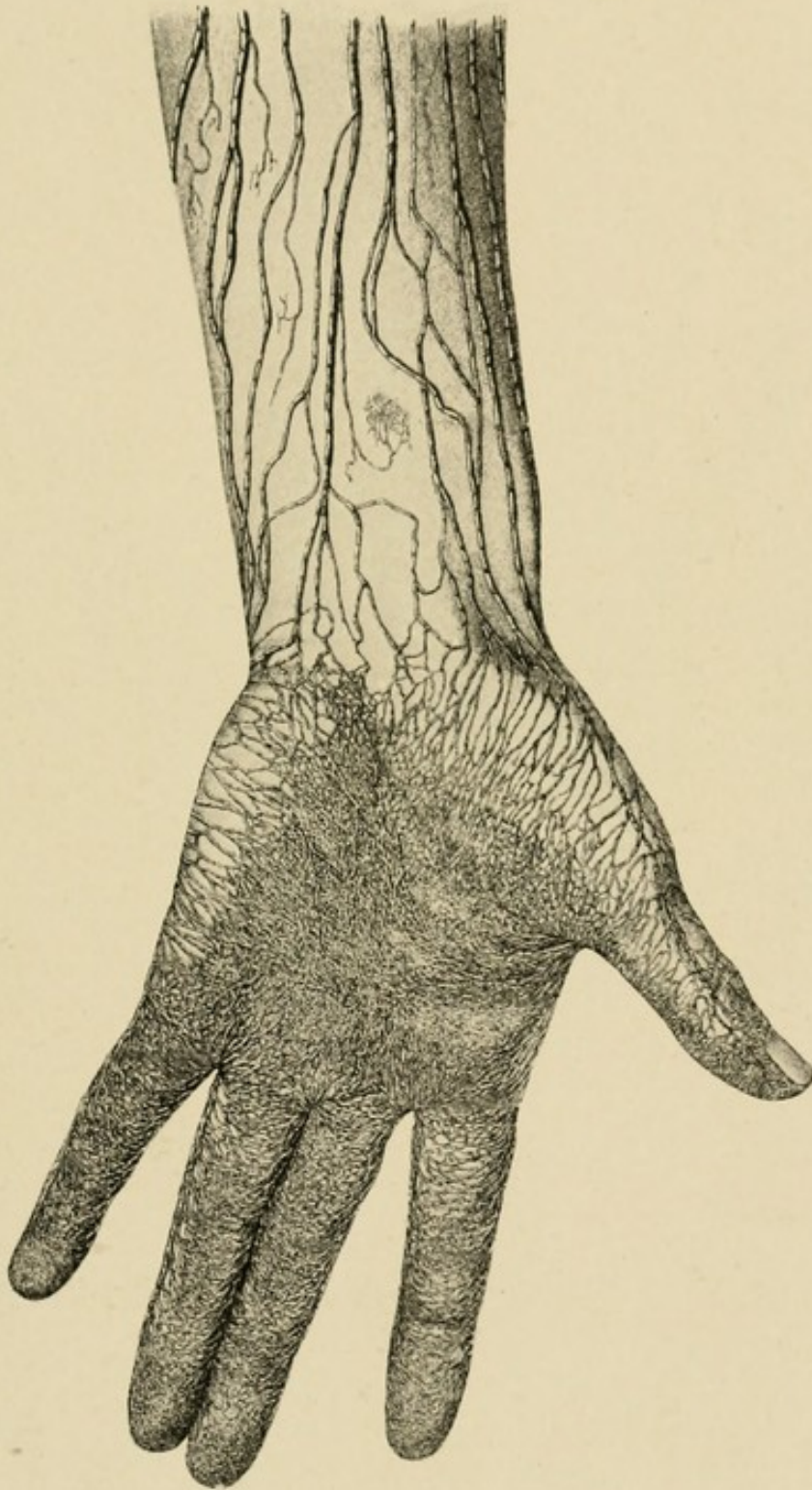
"Origins: (A) In the fingers, the network of origin presents its maximum of development on the palmar surface (Fig. 99). Here the meshes are so closely set that it is only by a careful examination with a lens that they can be distinguished. The dorsal network is much less rich than the preceding (Fig. 100). From these two networks arise a considerable number of collectors, which converge toward the sides of the fingers and unite to form two or three trunks on each of these surfaces (Fig. 97). These trunks at first follow

FIG. 98



Showing lymphatics of a hand and arm, the areas of origin and distribution.
(After Sappey.)

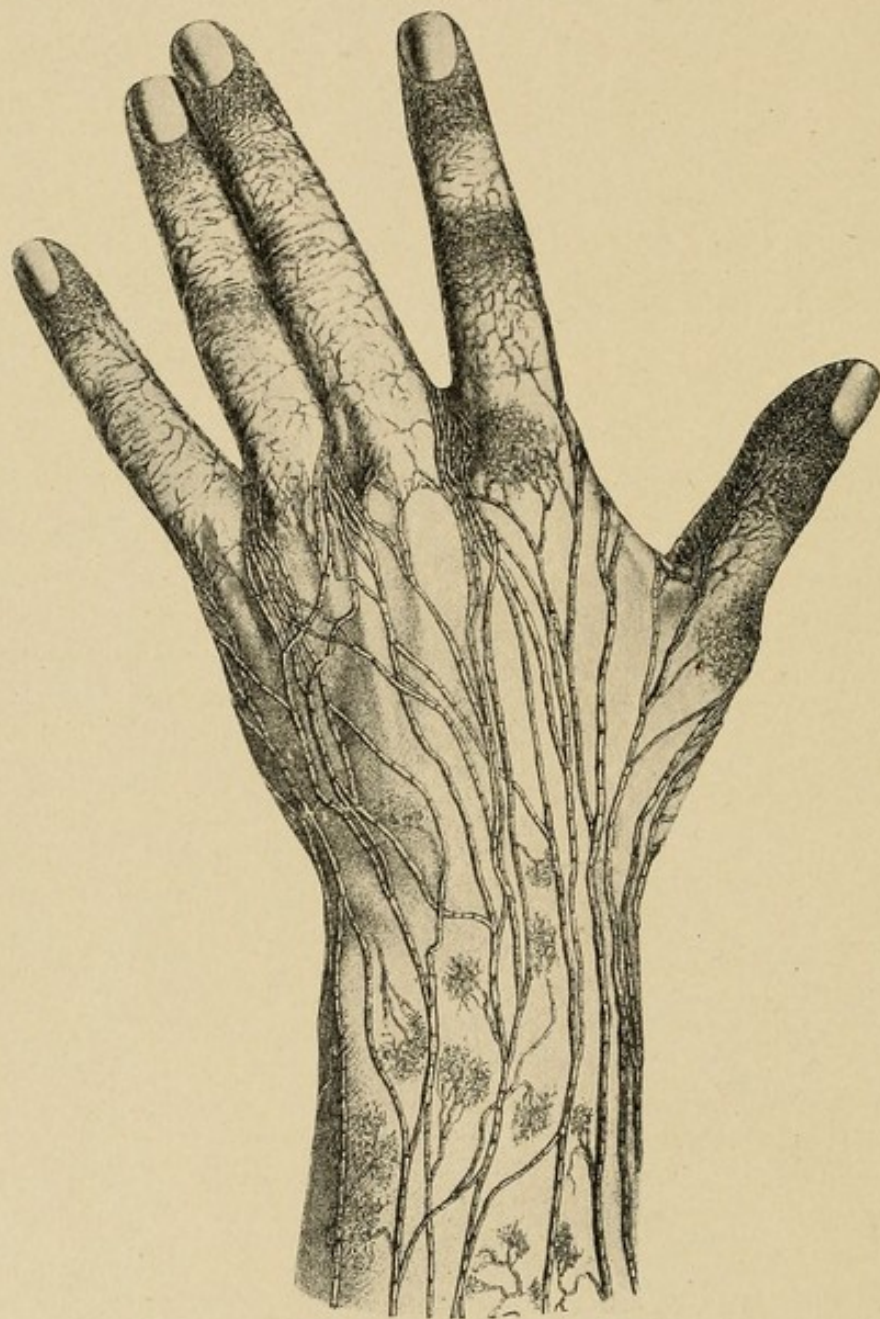FIG. 99



Showing extensive network of lymphatic channels on the palm and fingers, with their extensions to the dorsum and to the forearm through the collecting trunklets. (After Sappey.)

the corresponding collateral artery, but, having arrived at the base of the finger, they incline backward and

FIG. 100



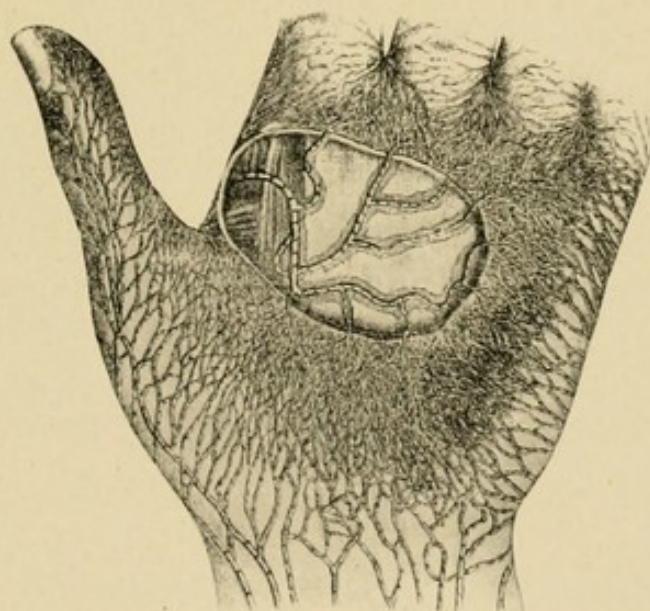
Showing lymphatics upon the dorsum. Note how few there are in comparison with those upon the palmar surface. (After Sappey.)

run toward the interdigital space. They then pass to the posterior surface of the hand, and are directed toward the wrist, where we shall trace them again

shortly. In their course on the dorsal surface of the hand they effect numerous anastomoses. They cross one another frequently, and it is no unusual thing to see a collecting trunk, which has arisen, for example, in the fourth interdigital space, uniting with trunks which run along the external part of the dorsal surface of the hand.

“(B) In the palm of the hand the network of origin is also extremely rich. From this network run numerous trunklets, which we may divide into external, internal, inferior, superior, and central (Fig. 101).

FIG. 101



Lymphatic vessels of the palm, showing their extensions from all the borders to the dorsum and the extension from the central portion into the deep lymphatic along the palmar arch. (After Sappey.)

“The external trunklets, four to six in number, run obliquely upward and outward, and, crossing the surface of the thenar eminence in a slanting direction, terminate in the lymphatics coming from the integuments of the thumb.

“The internal trunklets, more numerous than the preceding (eight or ten), run almost transversely inward, and, crossing the ulnar border of the hand,

reach the dorsal surface and empty themselves into the collecting trunks which arise from the integument of the little finger.

"The inferior trunklets, which vary from twelve to fifteen in number, are directed toward the interdigital spaces; they then reach the dorsal surface of the hand and terminate in the digital collecting trunks.

"The superior trunklets reach the anterior surface of the wrist, and unite to form three or four trunks, which ascend on the anterior surface of the forearm.

"The central trunklets run toward the deep portion. They traverse the subcutaneous fatty layer and the superficial palmar fascia, and they usually unite into a single trunk. The latter, which has been well described by Sappey, takes the following course: It is directed immediately outward, running underneath the fascia, in front of the flexor tendons. It thus comes to the adductor transversus pollicis, crosses the inferior border of this muscle, and then crosses the outer border of the first dorsal interosseous, on the posterior surface of which it ascends. It there joins collectors coming from the index finger, and in company with the latter reaches the dorsal surface of the wrist.

"Course: All these collecting trunks, which arise from the integuments of the fingers and hand, run in the subcutaneous cellular tissue toward the root of the limb. They are usually more superficial than the veins whose trunks they cover. They diminish in number as they are traced upward. In the forearm there are about thirty, but in the middle of the arm not more than fifteen to eighteen (Sappey).

"In the wrist they are divided into two groups, of which one runs on the dorsal, the other on the palmar surface of this part of the limb.

"In the forearm they tend to divide themselves into three groups—an external group, which ascends

along the radial border of the forearm; an internal group, which follows the ulnar border; a middle group, which is a satellite of the median vein and runs between the two preceding.

"A little below the bend of the elbow the two lateral groups come more and more to the anterior surface of the limb and unite with the median group; on the dorsal surface we find nothing but some rather small collecting trunks, which incline obliquely, some outward, others inward, and reach the anterior surface of the arm (Fig. 98). At the level of the olecranon these collecting trunks present remarkable sinuosities.

"In the arm the different collecting trunks, henceforth united into a single bundle, show a tendency to arrange themselves on the external surface of the arm, parallel to each other.

"Termination: The majority of these collectors run as far as the neighborhood of the base of the axilla. Here, they perforate the deep fascia and terminate in the humeral chain of axillary glands. The collectors from the outermost and innermost parts have quite a different termination; thus, two or three of the most internal end in the supra-epitrochlear gland. We have already seen that the efferents of this gland perforated the deep fascia in the middle part of the arm and end in the deep vessels. When this gland is absent, we may nevertheless see the internal collectors perforating the fascia at the same point to reach the deep absorbents. The most external trunk is also remarkable for the special course it pursues. It separates itself from the other collectors in the region of the humeral insertion of the deltoid, then ascends in the deltopectoral groove, where it may traverse one or several glands which we have indicated above. This trunk usually passes into a subclavian gland, placed at the spot where the cephalic joins the axillary vein. It may also be seen

to pass above the clavicle, and to empty itself into a supraclavicular gland. This arrangement, though somewhat infrequent (Grossmann says 38 out of 100 cases), has been figured by Mascagni. This delto-pectoral trunk is sometimes double and even triple."

DEEP LYMPHATICS

"The deep lymphatics follow the brachial artery and its chief branches. There are usually two lymphatic trunks for each artery. With Sappey, we will divide these deep lymphatics into radial, cubital, posterior interosseous, anterior interosseous, and brachial.

"The radial trunks arise from the subfascial portions of the palm of the hand. 'One accompanies the deep palmar arch, turns around the head of the first metacarpal bone, and runs on the outer side of the carpus, and reaches the forearm, where it is situated on the external side of the radial artery; the other, whose origin is not so deep, follows, according to the sketch left us by Mascagni, the course of the radiopalmar artery, and also joins the forearm, where it is placed on the inner side of the radial. Both then ascend as far as the bend of the elbow, where they anastomose. In their antibrachial course they traverse one or two small glands, the existence of which is not constant.' (Sappey.)

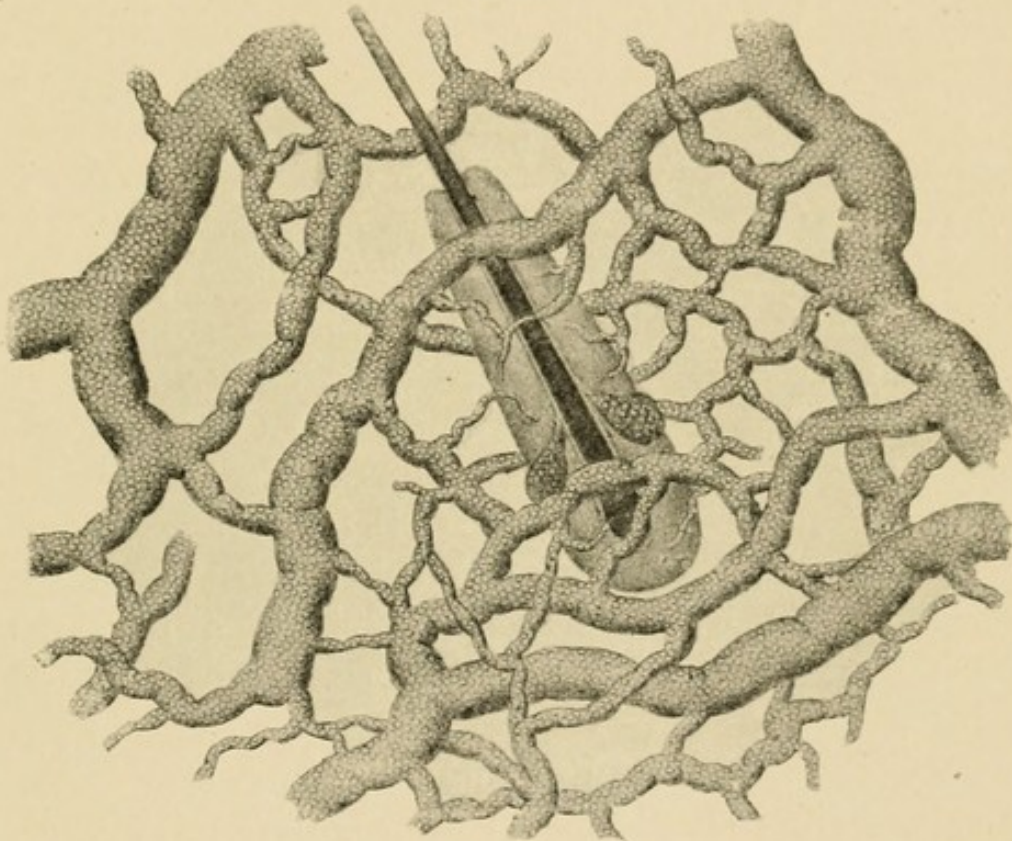
"The ulnar trunks are also two in number. They have a separate origin. One, in fact, appears by the side of the superficial palmar, while the other is a satellite of the deep palmar arch. They unite at the wrist, just above which they receive a large affluent which is a satellite of the dorsal branch of the ulnar. They then run parallel to the ulnar vessels as far as the bend of the elbow. During their course they sometimes present one or more small glands.

"The posterior interosseous trunks, which arise from

the deep muscles of the forearm, perforate the interosseous membrane and then unite at the bend of the elbow with the preceding vessels.

"The anterior interosseous trunks follow the vessels of this name, and, after presenting in their course one or two small glands, also end in the lymphatic meeting-place at the bend of the elbow.

FIG. 102



Showing lymphatics about a hair follicle. (After Sappey.)

"The humeral trunks comprise all the above-mentioned antibrachial collecting trunks. They vary from two to three in number. They run by the side of the humeral vessels, and terminate in the humeral group of the axillary glands. As we have already seen, they present in their course some small glands which appear to be nearly always present. In the middle part of the arm they collect the efferent vessels from the supra-epitrochlear gland. They also receive some small trunks from the muscles of the arm."

CHAPTER XX

LYMPHANGITIS—ETIOLOGY, PATHOGENESIS, AND PATHOLOGY

PREDISPOSING AND ACTIVE FACTORS IN THE PRODUCTION OF LYMPHANGITIS

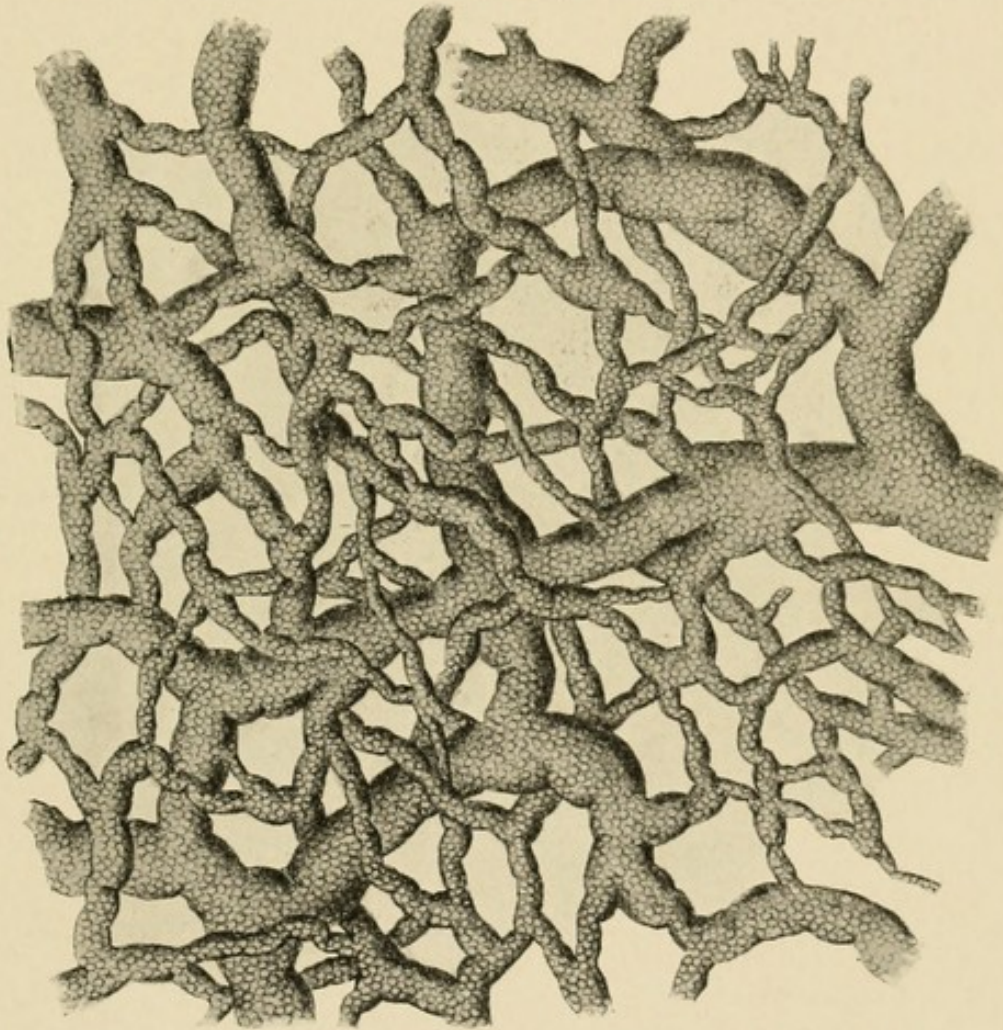
WHILE a lymphangitis may develop at any time of the year, it is most frequently observed in the fall and winter, an observation that is concurred in by all authors. This may find its cause in the unnatural conditions under which workmen live during the colder months, at which time they are closely housed, with the result that they breathe impure air, and because of this and the lack of outdoor exercise their power of resistance is reduced. It is possible that the colder air which contracts the superficial vessels may have some bearing on the development of the infections by lessening the natural protection against superficial injuries.

The source is most often some slight puncture, carrying bacteria beneath the surface, or the small cracks so often found in workmen's hands, especially in winter about the calloused areas, the so-called *durillon forcé* of the French authors. These are particularly noted at the distal part of the palm, where dirt incident to the occupation is rubbed into the fissures. The slight punctures often come from needles or pins, and are thus frequently found on the distal phalanx, generally being so slight as to have been forgotten when the patient applies for treatment. Again, we note its frequency after trauma of the nail. The patient gives a history of running a splinter under the nail, or of some

injury which has caused a separation of the nail from its bed, with a small subonychia hemorrhage, which has become infected.

Why it is that similar injuries may be followed in one case by severe lymphangitis and in another by no results is still an unanswered question. We are

FIG. 103



Showing lymphatics in the palm of the hand. (After Sappey.)

accustomed to say that the resistance of the patients varies, and this is undoubtedly true. On the other hand, every surgeon has seen many cases of severe lymphangitis in patients of apparently normal resistance. We cannot attribute the cause entirely to lessened resistance. It is possible that some bacteria contain

inherent cytolytic attributes which lessen the possibility of the walling-off process and favor extension. Many investigators have studied the question and added individual facts to our knowledge, which is inadequate, however, for a complete understanding of the subject. Canon showed that ligation of the small intestine favored bacterial growth in the blood stream, thus showing the importance of proper intestinal action. He also thought that he had demonstrated that an excessive acidity of the blood is more favorable to bacterial growth than any alkalinity. This, however, has not been verified.

THE INFLUENCE OF THE TYPE OF GERM

It is probable that almost any of the various pathogenic bacteria may give rise to lymphatic infection. In a great majority of the cases, however, the streptococcus will be found to be the etiological factor. The virulence of both streptococci and staphylococci varies within wide limits, and even the same organism may in successive cultures or various media change its virulence. Many attempts have been made to classify the bacteria according to their virulence, but without success. On the other hand, certain physiological processes of bacteria have been studied which may in time lend some aid, and meanwhile they serve to explain some of the phenomena noted in infections. Among the most marked characteristics of severe infections we have the cytolytic and hemolytic functions. The semijaundiced appearance of the severe cases due to the hemolysis is a well-known picture, and while most often seen with streptococcus infections, it may also appear in the staphylococcus forms to a marked degree, especially in the aureus infections and to a lesser degree in the albus. This staphylohemolysin

must, however, be present in considerable amounts before its effects become apparent in man, since his serum contains normally small amounts of antistaphylolysin, as was shown by Neisser, and, moreover, if the inoculation or infection begins slowly, the system will develop larger amounts.

This hemolysis is particularly marked in the streptococcus infections, where the pasty, semiyellow appearance in the fatal cases is almost constant. This observation was discussed by Marmorek in 1895, but attempts to classify the virulence of the types in relation to it have, however, failed, since many avirulent forms possess the same property as shown by Schottmüller. Fromme thought he could differentiate these by attempting a culture on a media of lecithin and bouillon, in that the lecithin would inhibit the growth of the more pathogenic forms, and that through this he could prognosticate the severity of any infection and thus take proper steps for its cure. Unfortunately, subsequent investigations of Sachs and others have dispelled these hopes, and we are no further in our knowledge than we were. Attempts have also been made to classify the virulence of the streptococci by reference to the length of the chains. Lingelsheim, in 1899, first employed the terms streptococcus "longus" and "brevis." The more virulent types in man are most likely to be found in the long chains. No absolute dependence, however, can be placed upon this finding. Many of the other types of bacteria may be found in the systemic infections; even the *Bacillus pyocyaneus* has been found in a number of cases, as instanced by Roberts, Finkelstein, and Brill and Libman.

A careful study of the effects of combined bacterial infections is to be desired. The effect of symbiosis is not fully known, although it has been hinted at by various authors. The effect of combined streptococcus

and staphylococcus involvement is of especial interest, since we so often see this combination. Fisher and Levy suggest that the streptococcus through its rapid spread prepares the soil for the staphylococcus. When this occurs the prognosis is more grave, since the combination seems to increase the virulence of the streptococci. I personally have observed that such cases have a convalescence prolonged much beyond the ordinary course seen in patients infected with either separately.

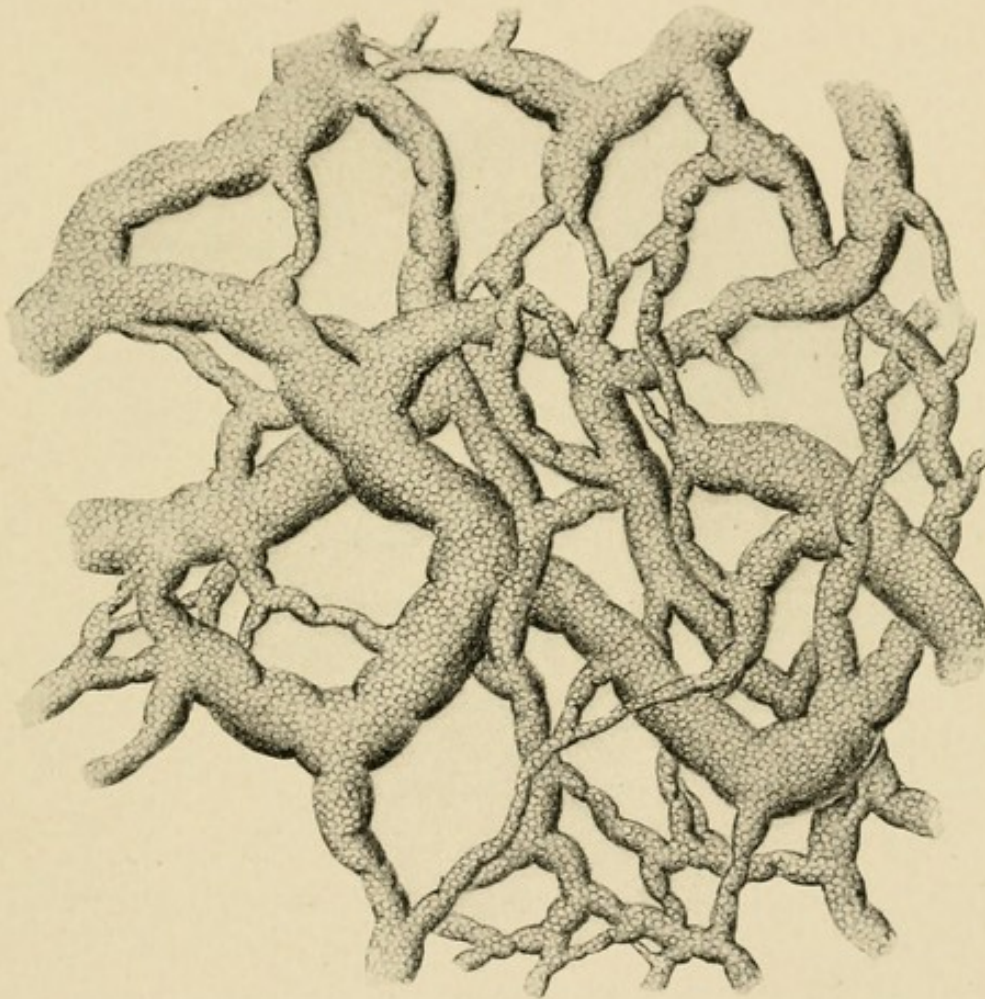
THE INFLUENCE OF THE ANATOMY ON THE COURSE

A general rule which the anatomy emphasizes is that from any given point the superficial lymphatics pursue the shortest course to the dorsum. An exception is made of the centre of the palm, from which, as has been shown, an infection would tend to go down to the superficial palmar arch. These are rare, however. The general rule of the dorsal extension explains the frequency of great edema on the back of the hand in all cases. As specific examples of the importance of this observation, those infections arising at the distal part of the palm should be noted. Here the lymphatics first go distally, then pass around the web and on to the dorsum, at which site the swelling and redness are seen, giving rise to the assumption on the part of the thoughtless that the infection is primarily there. This is then followed by unnecessary and harmful incisions. A little care would have shown that the starting point was a slight fissure in the callus on the flexor surface, and that the dorsal redness was lymphatic in nature, accompanied by an inflammatory edema which would be harmed rather than helped by an incision. The same is true of infections upon the ulnar and radial sides of the palm. Where there is localized redness on the dorsum of the hand we less often see the dorsal lines of

redness running up the arm. These are generally the accompaniment of an absence of local reaction.

Along the course of the lymph vessels, particularly on the dorsum of the hand, will be found areas of redness and edema about twice the width of the redness accompanying the vessels, appearing as if the

FIG. 104



Showing lymphatics in the skin and around the nail in a child, aged four years. (After Sappey.)

infection were localizing there or as if small abscesses were forming. These may then be incised under that assumption. It is doubtless true that in the semi-acute cases, or those going on to abscess formation, the localizing processes may start from these foci, but great care should be exercised before making this deduction,

since these are but the evidences of the lacunæ mentioned in the anatomical discussion, and generally subside at the same time the inflammation disappears from the vessel proper.

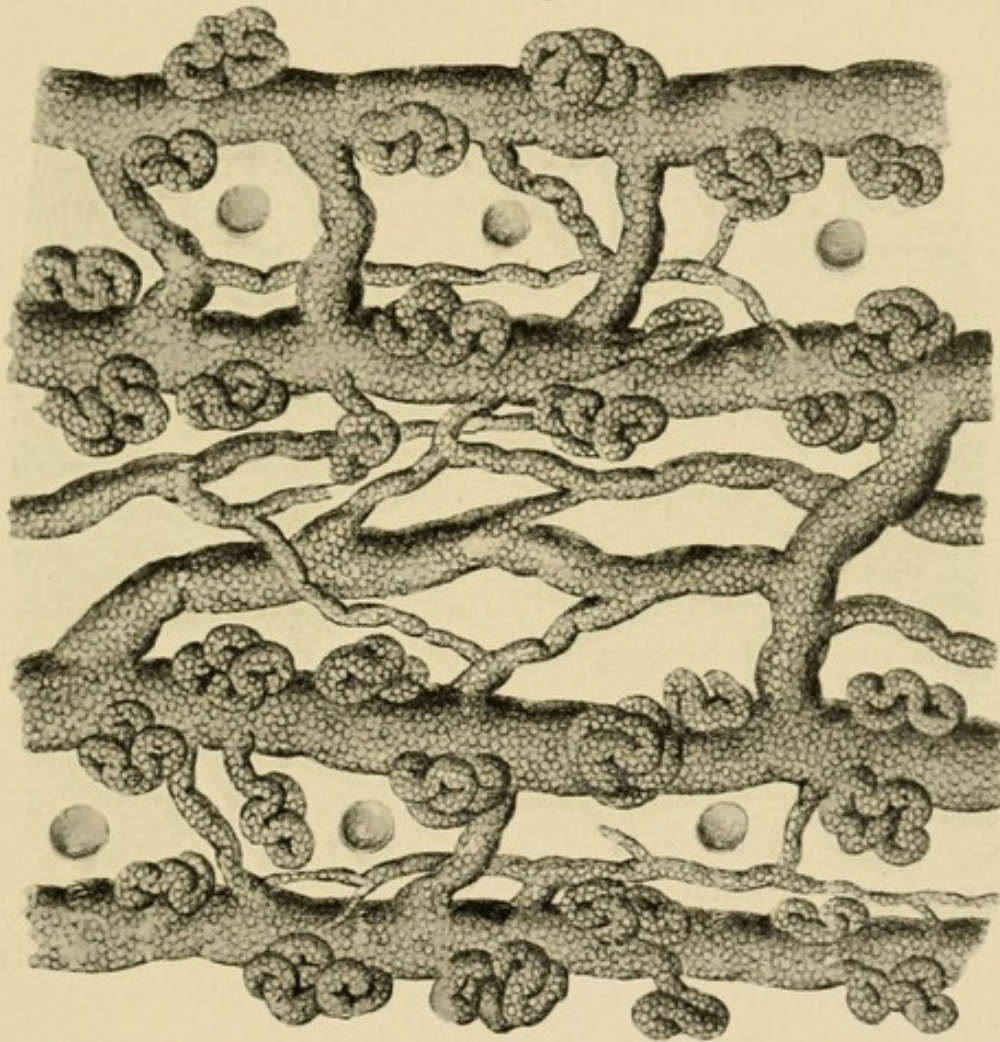
Attention should also be drawn to the normal course of the vessels, and it should be emphasized that lymphatic extension from the little and ring finger takes place through the epitrochlear glands, then to the axillary, while infections beginning in the thumb and forefinger go to the axillary glands without the interposition of the epitrochlear; hence systemic infection is more easily engendered, and, moreover, if the observer were searching for glandular enlargement he would not expect to find it at the elbow in these cases. Infections beginning in the middle finger are of especial interest in that either the axilla or the epitrochlear glands may be first involved, and in some cases neither of these areas may receive the lymphatic vessels, since they may pass up over the clavicle and into the subclavian glands and thus directly into the circulation. The clinical importance of this lies in the fact that these infections may reach the circulation very early and because of the rapidity of involvement lead to severe and even fatal systemic infection. I have had one case that lends support to this assumption. Therefore one would look with great anxiety upon severe infections arising from the middle and index fingers.

In some of the patients the lymphatic infection rapidly spreads from the lymphatic vessel and extends over the entire dorsum of the hand and forearm with the appearance of an erysipelas without the raised border. The swelling is considerable, the skin takes on a board-like hardness, and vesicles may appear on the surface. This may subside without further trouble, but very often the subcutaneous tissue soon becomes involved and diffuse abscess formation takes place.

These are ordinarily virulent cases and should be carefully watched and the abscesses opened.

There is an intimate relation between the lymphatics of the distal extremity and the tendon sheaths. Of this I have no anatomical proof, but such clinical evidence that there can be no doubt of the association.

FIG. 105



Lymphatics about one of the palmar flexion creases. (After Sappey.)

It has been my experience frequently to meet with cases in patients with pin pricks, especially of the distal phalanx, which lead to a typical lymphangitis with a red line running up the arm, and after a couple of days these would show the typical evidences of tendon-sheath infection of the finger involved. The distal

phalanx itself, the site of the primary injury, would show little or no serious consequences. This will be discussed more fully under symptomatology.

If the deep lymphatics are involved, the course naturally follows the course of the veins, as has been pointed out above. If localized abscesses develop, they appear along the line of these vessels. If it be the interosseous, the abscesses will naturally lie under the flexor profundus, thus occupying the site I have already pointed out as that in which the deep abscesses spreading from the tendon sheaths are always found. In these cases doubtless the tendon sheaths would be involved early, and then we would have a typical tendon-sheath infection.

If the lymphatic vessels along the radial and ulnar vessels are the source, the abscess will naturally lie along these vessels. It has not been my experience to meet with any such cases, and I am inclined to believe that their occurrence is uncommon. I have seen abscesses along the brachial vessels, however. In one case it developed as an extension from a deep infection of the forearm, and in another as the sequel of a typical superficial lymphangitis of the forearm. It seemed to me reasonable in this latter case to ascribe its development to suppuration in a lymphatic gland lying in juxtaposition to the vessel, since we know that, while these glands ordinarily lie at the elbow and axilla, they may occur at any part of the lymphatic stream. From the very nature of the cases we would expect deep lymphatic abscesses to be uncommon.

SPOROTRICHOSIS

Certain cases in which nodules develop along the lines of the lymphatics, giving rise to small abscess formation, may cause confusion in that it is possible

for us to have in traumatic injuries of the hand an infection by sporotrichosis. Practically all of these infections follow open wounds. It is first described by Schenck.

The disease seems fairly prevalent in rural districts. It is possible that some of the cases have been diagnosed as tuberculous lymphangitis. The organism consists of a branching septate, coarse mycelium from which ovoid bodies develop by budding, either from lateral or terminal filaments or from the sides of the threads. These ovoid bodies are spores.

The condition is characterized by the history of a traumatic injury, and is accompanied by the development of one or more sharply circumscribed painless or subcutaneous abscesses along the course of the lymphatic. Inflammatory manifestations are generally absent. The course is extremely chronic, lasting for a number of weeks.

The treatment consists in thoroughly opening the abscesses, cleansing them, and giving large doses of potassium iodide internally.

RELATIONS OF LYMPHATIC ABSCESES STUDIED BY EXPERIMENTAL INJECTIONS

In order to study the subject, attempts were made to inject masses from given sites along the vessels in cadaver hands. The results did not add much to our knowledge, but I will summarize them here.

REPORT OF INJECTIONS OF FOREARM NEAR THE RADIAL AND ULNAR VESSELS.—*Experiment 1.*—Canula passed through small incision superficial to the radial vessels just above the wrist. The mass was injected with considerable force, and on examination a superficial area three inches in length and one inch in diameter was found filled with the injected mass.

(NOTE.—It is extremely difficult in injecting the cannula to know just exactly the position it occupies.)

Experiment 2.—Injected posterior, *i. e.*, dorsal to the radial vessels. The mass spread upward, and in the section was found to lie on the radial side of the flexor longus pollicis, tearing the muscle to a great extent up to its origin. The mass had extended to the ulnar side of this vessel, a small part of it lying on the radial side between the bodies of the flexor profundus digitorum and flexor sublimis digitorum. The greater portion had passed underneath the flexor profundus digitorum and filled up the area between this muscle and the bones with the interosseous membrane. It had extended to the ulnar side, lying in juxtaposition to the flexor carpi ulnaris, and at its distal end came to lie near the surface, *i. e.*, near the ulnar vessels. It had extended distally between the tendons of the flexor profundus digitorum and the pronator quadratus. It did not pass into the hand. It had extended *en masse* approximately to about three inches below the elbow-joint, and a small prolongation or isthmus extended along the median nerve above the elbow-joint for three or four inches into the arm, still lying close to the median nerve and consequently near the brachial vessels and accompanying nerves. (NOTE.—Out of six injections more or less satisfactory, this extension occurred in two cases, suggesting why it is that in deep infections of the forearm, loss of function of the muscles is so uncommon, since both the blood supply and the nerve supply are impaired.)

Experiment 3.—Results practically the same as Experiment 2.

Experiment 4.—Results practically the same as Experiment 1.

Experiment 5.—Mass lay to the radial side of the arm above the flexor longus pollicis and to the radial side of the flexor profundus digitorum.

GENERAL CONCLUSIONS IN THIS SERIES OF EXPERIMENTS UPON THE RADIAL VESSELS.—We have demonstrated that if an abscess should develop along the course of the lymphatic vessels, lying in juxtaposition to the radial artery, it may be a superficial abscess which would point on the radial side of the arm. If it follows the vessels farther it may spread to the deep tissues of the arm. In other words, it may produce the same result as an extension along the interosseous vessels or a rupture from the ulnar or the radial synovial sheaths. It may extend to the ulnar side and lie immediately under the skin.

EXPERIMENTS BY INJECTION ALONG THE ULNAR ARTERY.—As in the injections along the radial artery, these experiments are more or less unsatisfactory owing to the fact that there was always considerable doubt as to the exact position the tip of the cannula occupied, although the intention was to inject as close to the ulnar artery as possible, *i. e.*, to simulate the origin of a large abscess coming from the lymphatics and lying in juxtaposition to this vessel.

In this series five injections were made at various sites, and demonstrated the tendency of such accumulations to come to the surface on the ulnar side early in the course. If the injection was persisted in, the area of the forearm involved was first that between the flexor carpi ulnaris and the flexor profundus digitorum; then between the superficial and deep flexors, and then the area between the deep flexor and the bone, *i. e.*, the typical deep abscess of the forearm.

THE PATHOLOGY OF LYMPHANGITIS

The pathology of these cases concerns itself particularly with the changes in the lymph vessels and glands, and need not be discussed in completeness, since the

general facts are well known. A picture of the condition found in a typical case will be as follows:

The local changes at the site of injury may be so insignificant as to escape notice. The local reaction, even in a case that threatens lethal issue, may be nothing more than a slight redness indicative of a hyperemia. There is no hardness suggestive of the outpouring of the protective leukocytes with the coagulation of the lymph and blood elements about a site of injury and infection, as is seen in the localized staphylococcus infection, although great pain may be present. This is particularly seen in the distal phalanx, where the differential diagnosis between this condition and a beginning felon must be made.

The lymphatic vessels show grossly by their redness the hyperemia surrounding them, and a microscopic examination shows the destruction of the endothelium, suggesting a virulent poison or great activity in overcoming the bacteria. Adami has emphasized the important part the endothelial cells play in inflammations, in that they may act as phagocytes and may undergo changes to giant cells or other forms more fitted to combat the process. A cross-section will show these changes, and in addition may show the vessels filled by a thrombus made up of cells and bacteria, and in those cases where the thrombus lies close to the wall the bacteria may be seen in that also. If the vessel is injured or cut, the bacteria spread beyond the wall, but in the ordinary simple case they will be found confined to the wall and the lumen. The bacteria do not seem to be in the leukocytes to any great extent, but they are so mixed together in the thrombus as to leave some doubt in my mind on this point. At some points I have found the thrombus entirely free from bacteria, in which case it may be reasoned that the toxin has produced the thrombus in advance of bac-

terial extension. In some instances, in spite of the changes in the lumen, the vessel wall showed little change. The endothelium was not changed. There were no endothelium giant cells. The connective tissue about showed the evidences of inflammation with moderate round-celled infiltration, although this did not extend far into the adjacent areas. The capillaries were engorged with blood for some distance, and the connective tissue fibers were separated by the serous exudate. If the inflammation is a chronic one, all of the changes incident to such infection are seen. If the vessel is cut, there is a rapid extension to the surrounding tissue, which macroscopically takes on the appearance of an erysipelas and pathologically shows the inflammatory changes associated with it. About the lacunæ the changes I have just described are most marked, a much wider area about them being involved.

The lymph glands show nothing different from the ordinary picture seen in varying inflammations of their structure. Systemically in severe cases marked changes in the blood and various organs are found which will be discussed when speaking of the fatal cases.

In the severe cases locally we may find that the subcutaneous tissue and even the skin may become gangrenous. Of course, the former is most common. Here the abscess will form, and when opened large sloughs of connective tissue may be removed from which the streptococcus may be secured in pure culture.

CHAPTER XXI

SYMPTOMS AND SIGNS OF LYMPHANGITIS

SYMPTOMS AND SIGNS IN GENERAL

A PATIENT with a lymphangitis ordinarily gives a history of a slight abrasion or pin prick, which had been considered of no importance. Frequently no history of injury can be secured. The patient has noticed a slight malaise or chilly sensations, possibly a severe chill may be noted. There may be no local pain in the hand or arm and no swelling. Generally, however, there is slight swelling accompanied by a dull pain, and at times the edema on the dorsum may become marked and the pain very severe. The symptoms and signs bring the patient to the physician, who finds in addition to the local condition a red line running up the forearm and arm corresponding to the anatomical distribution of the lymphatic vessels draining the area of primary infection. There may or may not be tenderness or swelling in the region of the epitrochlear or axillary glands. Generally, however, after the infection has lasted twenty-four hours some tenderness and swelling are found. The arm as a whole may show some slight swelling, although this is generally absent.

The degree of systemic involvement varies in the widest limits. In some cases, even early in the course, the patient will present the evidences of severe toxemia with a chill and high or low temperature, headache, anorexia, and prostration. In a majority of cases, however, these severe symptoms are delayed two or three days, even though there may be a severe onset with a chill, temperature, and headache.

TYPES

Four types may be seen.

TYPE I. SIMPLE ACUTE LYMPHANGITIS.—If the process subsides, the physician may be surprised at the rapid disappearance of all evidences of the infection, both systemic and local. All objective evidences may entirely disappear in from twenty-four to forty-eight hours. The red line of lymphatic inflammation may disappear over night with slight tenderness over the gland area persisting for a few hours longer.

TYPE II. ACUTE LYMPHANGITIS WITH MINOR LOCAL COMPLICATIONS.—In a second group the symptoms may subside more slowly and end in a delayed resolution or even abscess at the site of inoculation or in the gland area accompanied by mild systemic symptoms.

TYPE III. ACUTE LYMPHANGITIS WITH SERIOUS LOCAL COMPLICATIONS.—In a third group of cases complications arise ending in tenosynovitis or subcutaneous abscesses. These cases are accompanied by severe pain early in the course and symptoms more or less grave which arouse the anxiety of the physician, first, as to the possibility of death early from systemic infection, and later, on account of the toxemia associated with the local process, which heals slowly and threatens the life of the patient or raises the question as to the necessity for amputation.

TYPE IV. ACUTE LYMPHANGITIS WITH SYSTEMIC INVOLVEMENT.—In a fourth group the process may give rise at once to most alarming systemic symptoms and with or without local difficulty end fatally in a few days.

The first and second groups are easily classified and understood.

ACUTE LYMPHANGITIS WITH SERIOUS LOCAL
COMPLICATIONS

The third type may be a constant source of anxiety, and the surgeon is often in doubt as to the ability of the patient's resistance to cope with the infection, and he is constantly questioning the correctness of his diagnosis as to the position of pockets of pus and the adequacy of his treatment. It may clear up the picture somewhat to illustrate this by one or two examples.

CASE XVIII.—A patient, Mr. L. W., was seen by me on the second day of his infection. He had injured the forefinger of his left hand with a piece of fine, rusty wire which had penetrated the distal phalanx upon the volar surface. He was complaining of severe pain in the entire finger, but most marked in the distal phalanx. An examination showed that the entire finger partook of a pinkish hue, and was somewhat swollen throughout. The distal phalanx, while the most painful and tender, lacked the induration characteristic of localized infection. A red line ran up the back of the hand and forearm and could be traced to the axilla, where slightly tender glands could be palpated. He was profoundly ill, with a temperature of 104° to 106° .

The proper procedure was considered to be that of applying a hot boric solution dressing, rest both local and general, eliminatives, and sedatives. The question immediately arises as to the advisability of incising the distal phalanx. It seemed to me that lacking the induration, suggestive of localized pus, the incision would do little good, and might open new avenues for absorption. There could have been no question as to making incisions at other points. Upon the third day our conservatism was rewarded by seeing the pain disappear from the distal phalanx as well as the red

line of lymphatic involvement in the arm. The patient now located and limited the tenderness to an area over the tendon sheath of the index finger. There was not an increase of the swelling of the distal phalanx, although the finger as a whole had taken on the full appearance characteristic of distention of the sheath with pus. The tendon sheath was opened and the pus evacuated, following which the patient ultimately recovered with a preservation of the finger. It should be noted that no incision was made into the distal phalanx, although that was the site of the original pain and tenderness. Moreover, upon the second day it was certainly impossible to make the diagnosis of tenosynovitis.

CASE XIX.—Mr. Geo. W. applied to the dispensary of the Post-Graduate Hospital with a history of having had a small cut upon the ulnar side of the palm. Suddenly after three days he suffered from a chill and felt feverish. The hand began to swell, especially upon the dorsum. Upon examination the remains of a small cut could be seen upon the palm, but there was no evidence of inflammation about it. No localized tenderness or swelling. The dorsum of the hand, especially upon the ulnar side, was greatly swollen and reddish. The skin of the entire dorsum was red. There was no subcutaneous induration, and the skin itself, while red, did not have the brawny induration found in erysipelas. A red line of lymphatic involvement ran up on the dorsum of the forearm, and could be traced to the epitrochlear region and then along the inner side of the arm to the axilla. Tender glands could be palpated in both regions. Temperature, 103° ; pulse, 100.

The question arose whether or not an incision should be made over the tender swollen dorsum. It was reasoned that this was not indicated, since there was no evidence of a localized abscess here or of a

diffuse phlegmon, which at times accompanies erysipelatous infection in this region. Conservative treatment was therefore instituted with a rapid cessation of all symptoms in the hand and lymphatic vessels. However, the tenderness gradually increased in the epitrochlear region, and a redness which had not been present before now appeared. At the end of seven days a suppuration which had had its origin in the gland here was diagnosticated. Drainage was instituted, with complete recovery in a short time.

PHLEGMONOUS LYMPHANGITIS.—One of the most serious types is that in which the infection seems to involve the skin of the back of the hand and forearm like an erysipelas. The toxemia is great, the forearm greatly swollen, and the board-like skin shows small blebs or blisters upon its surface. The bacteria soon invade the subcutaneous tissue and lead to a destruction of areas of the subcutaneous tissue *en masse*, thus leaving the infected skin without proper blood supply. Consequently, large pockets filled with pus and semi-necrotic tissue underlie the skin of the dorsum, which itself soon becomes gangrenous in spots. Meanwhile, the patient is suffering from a severe toxemia or sepsis. The superficial veins may become thrombosed and threaten death by acting as the source of infection, even though the lymphatic absorption may have ceased. The greatest care should be exercised in differentiating this type from the swollen, reddened, edematous form seen in ordinary lymphangitis, in which there is no induration, either of the skin or subcutaneous tissue.

Examples of these types could be multiplied many times in my experience. The early signs and symptoms very commonly point to an entirely different area as the probable site of abscesses than the one in which it ultimately develops, and I wish to emphasize, therefore, that the diagnosis of the accumulation of pus

should be made only upon positive signs. After once localizing, the abscesses follow the definite lines laid down in the chapters upon tenosynovitis and fascial space infection.

THE FREQUENCY OF LOCALIZATION IN LYMPHATIC INFECTION.—The frequency with which localization takes place in lymphangitis is hard to state accurately. In my experience 10 to 15 per cent. of the cases would probably be nearly correct, and if anything it would be less rather than more than that. The sites of such involvement are ordinarily the tendon sheaths of the respective finger, the dorsum of the hand, the dorsum of the forearm, the axilla, and the epitrochlear region. Secondary to tendon-sheath infections and deep infections of the hand, it is common to find a subcutaneous accumulation of pus of lymphatic origin on the flexor surface of the wrist. From these observations it is very evident that a great majority of the cases of lymphangitis subside without secondary abscesses unless they are engendered by ill-advised incisions.

ACUTE LYMPHANGITIS WITH SYSTEMIC INVOLVEMENT

In our classification we have included in this group those severe infections which through systemic absorption or infection threaten or destroy the life of the individual. They may arise from any source or in any individual. They are more likely to occur in individuals over thirty-five years of age, and, if fatal, within a short time are more inclined to follow infections of the thumb, index, or middle finger. The little finger is the origin of many fatal cases, but here the lethal issue is often due to infection through involvement of the tendon sheaths with improper drainage. In other words, death is the outcome of two types of

infections: (1) An acute type without localization in the hand, and (2) a severe type with localization, subsequent toxemia from inadequate drainage, and the inability of the patient's system to wall off the infection, ending in death from exhaustion and sepsis. These types will be discussed when dealing with systemic infection, and we shall mention them only briefly here for the sake of completeness. The onset is generally brusque. The patient suffers a chill, followed by a high temperature, which later becomes lower as the toxemia increases. There is little local reaction along the line of the lymphatic or other glandular region. The prostration is profound, the headache severe. The face becomes pinched, the eyes roving, the pulse running, and the patient is restless and cannot sleep. The prostration becomes greater, the pulse more running, the temperature normal, subnormal, or high, the skin clammy and the nose cold; in other words, the typical picture of a virulent toxemia. Meanwhile the physician looks on helplessly, since there is no localization which he may attack.

DEEP LYMPHANGITIS.—The diagnosis of deep lymphangitis must often remain in doubt, since it is generally associated with a superficial inflammation, at times showing red lymphatic lines, but generally appearing as of the erysipelatous type. The whole arm and forearm are swollen as if the extremity were a sac and the whole filled with fluid. It will be noted that this is different from the appearance in superficial lymphangitis, in which the back of the forearm is swollen out of proportion to the front. There is tenderness early throughout, but most marked on the dorsum, where the superficial lymphatics are acutely inflamed. The patient is generally profoundly ill with all the evidences of toxemia. In no case that I have had has there been any localization of pus about

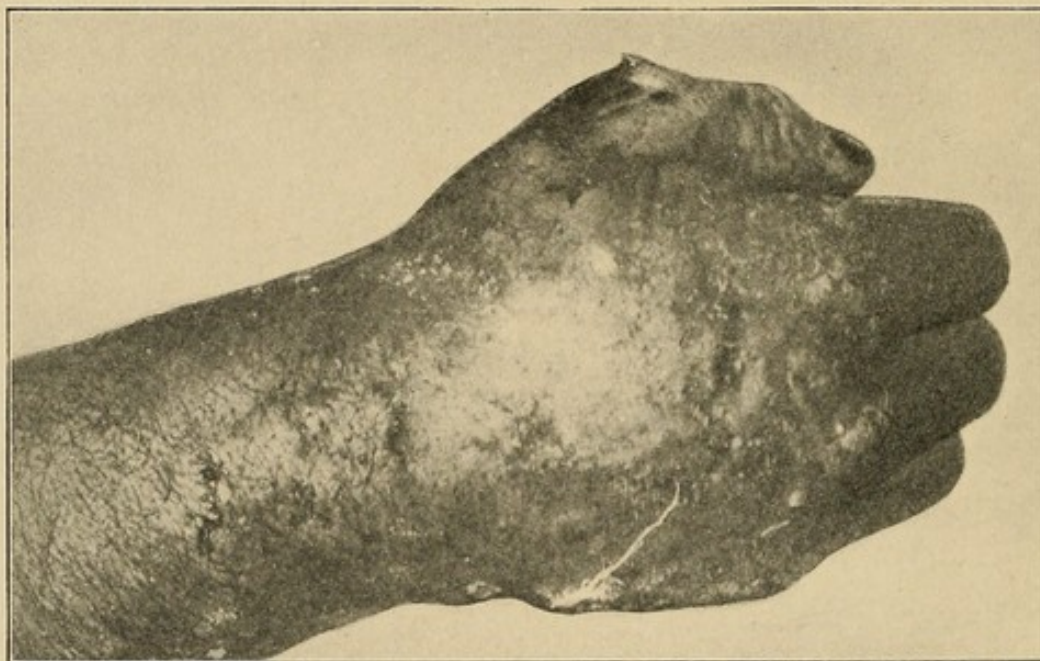
the deeper portion of the arm. In one patient an abscess localized itself along the radial artery about two inches above the wrist. This was subsequently drained, with recovery of the patient. I have not seen any cases with abscesses under the flexor profundus tendons which could not be explained on the assumption of an extension from a ruptured tendon sheath, although it is certain they are possible.

A fatal case of deep lymphangitis came under my notice a short time ago, in which the patient made a primary recovery, but died after four weeks from a pneumonia, probably directly dependent upon the primary infection. Indeed, these serious cases of infection frequently come to a fatal issue because of some intercurrent complication, and such should always be looked for and guarded against. A brief résumé of the case will emphasize the clinical picture.

CASE XX.—Mr. J. R. D. (Fig. 106), an employee of the customs house, bruised the thumb of his left hand in getting off a street car. As he expressed it, he thought that he had dislocated the thumb. There was some primary swelling. At the end of the third day there was a considerable increase of the swelling, so that the whole thenar area was involved, and the forearm also began to increase in size. He now consulted Dr. J. J. Cole, with whom I saw the patient in consultation. The swelling of the thenar area was so great as to suggest the ballooning out seen in the abscesses of the thenar space. The swelling was distinctly an edema, however, there being no hardness present. It was treated by hot boric dressings. Within a few hours the whole arm was swollen and edematous, as much upon its flexor as its dorsal surface, although the dorsum showed some redness which was not present on the flexor surface. Deep tenderness could be elicited on both surfaces, especially over the radial side. By

the end of the third day the swelling of the arm had subsided to a considerable extent, and the swelling of the flexor surface of the forearm was distinctly less. The dorsum, however, was still swollen, having the appearance and giving the same sense of hardness on palpation as noted in erysipelas. Incisions made upon the dorsum showed that the subcutaneous connective tissue was necrotic *en masse* and could be removed with the forceps. The whole dorsum of the forearm was undermined. Several incisions were made which drained satisfactorily. Owing to the large flaps of skin

FIG. 106



Photograph of the hand of a patient with a deep lymphangitis (phlegmonous erysipelas). (See Case report XX.)

left without blood supply, in which the vitality was impaired by the infection, some areas of this also sloughed. As the process subsided the thrombosed superficial veins could be seen on the surface of the deep fascia. The patient made a rapid primary recovery, so that he left the hospital at the end of eight days. The local process, however, had not entirely healed. Some slight toxemia was present, from which

the patient was slowly recovering, when he was suddenly overtaken by a pneumonia at the end of four weeks, and died after three days. A culture taken from a bleb which had formed upon the skin showed a staphylococcus infection. In the subcutaneous pus, however, a pure culture of streptococcus pyogenes was found, and I believe that to have been the source of the infection. Incidentally this finding of the staphylococcus under the epidermis when the real cause was a streptococcus emphasizes the error which is common of mistaking the local subepidermal infection for the primary cause when it may be really secondary. Unfortunately, no postmortem could be secured.

SYSTEMIC INVOLVEMENT.—As a sequence of lymphangitis proper or associated with other types of infection of the hand, systemic involvement may be seen. It occurs more frequently as the age increases. While deaths may occur at any age, by far the greatest number occur after forty-five years, and after fifty years a severe infection of the hand should be looked upon with anxiety. It occurs most often associated with a streptococcus infection. In one case, however, that died under my care, a staphylococcus was present in the pus of the primary abscess (Case XXI). Every case showing evidence of septicemia should be regarded as extremely grave. Early in the course it may be impossible to differentiate a septicemia from a toxemia, since they will present the same picture at the onset. The temperature is often 103° to 106° ; the pulse, 120 to 130. The dry tongue and skin; the restless, roving eyes; the constantly moving limbs; the thirst; scanty urine; headache; sleeplessness; flushed cheek; damp brow; and the quivering nostril, with the history of chilly feelings or a chill, present a picture known to all, and early may be present in either a toxemia or a septicemia. In a toxemia, however, all

these symptoms should subside within three days if due to a primary unopened lymphangitis or if it follows the opening of an abscess or a tenosynovitis. If, instead of subsiding, the symptoms grow more severe, it is probable a systemic infection is present if the local pockets of infection have been drained. The temperature generally continues high until death, but may become remittent, showing chills from time to time or symptoms and signs incident to complications, such as bronchitis, pneumonia, pleurisy, lung abscess, metastatic abscesses, and tenosynovitis, especially of the extensor tendon of the great toe, in my experience. The eye muscles may become paralyzed (Tornier). Almost all cases die when these severe symptoms develop. Death comes on with the patient in coma or delirium. Should the patient recover, the evidences of toxemia gradually subside and the local wound begins to show evidences of repair. The condition of the local wound as to repair is of considerable prognostic importance. When a wound does not heal as rapidly as it should after opening, exceptional care as to the systemic treatment should be used.

A fatal case following a simple middle palmar abscess which had been undiagnosed was referred to me and is worth reporting, since it illustrates the picture in the septic cases.

CASE XXI. — Mr. R. K., aged sixty-five years, admitted to the hospital January 23, 1909. Died, February 1, 1909.

The history as recorded is very meager. He stated that he hurt his hand rubbing meat and getting some brine in the scratches about a month previous to entrance, December 22, 1908. Following this his hand was swollen and painful. Several incisions had been made on the dorsum. On examination the right hand was found to be swollen, with the palm bulging. The

fingers were slightly restricted in motion. Little restriction of motion at the wrist and little swelling of the forearm. Systemically the patient showed the results of toxemia, being pale, weak, and emaciated, with the hunted look characteristic of these cases. The urine showed a specific gravity of 1020, was scanty in amount, but contained no albumin. There were, however, many hyaline and granular casts, both broad and narrow. A diagnosis of a middle palmar abscess was made, associated with a toxemia of a high grade, or a sepsis, and in addition a nephritis.

In view of these findings and the man's age, a poor prognosis was given. Operation: Under nitrous oxide anesthesia, a Bier constrictor was applied and about a half-pint of thick, creamy pus was evacuated from the middle palmar space. There was no pus in the thenar space or the tendon sheaths.

Following the operation the temperature varied from 99° to 101°; pulse, 84 to 100. During the second day it is noted on the history sheet: "Patient removed Bier constrictor during night, has involuntary urination. Hand and forearm violently inflamed, arm not involved. Am not sure whether mental symptoms are due to kidneys or hand."

That night the temperature rose to 102°, but varied from this to normal during the next day. The pulse averaged 100. During the fourth day the temperature varied from normal to 100°. The pulse was still not rapid, although the patient was delirious and there was evidently a metastatic infection in the tendon sheath of the extensor hallucis of right leg. Operation, January 29, 1909. Incision in palm enlarged and incision on lateral surface of forearm to secure drainage. Considerable pus evacuated. Incision over right fibula near ankle and into tendon sheath of extensor hallucis. Watery pus evacuated.

The pulse and temperature ran about the same as before. The highest pulse recorded is 120, and the highest temperature, 101.4°. The mental condition grew worse, and the patient died two days later.

Another fatal case, which I saw in consultation with Dr. A. B. Eustace, to whom I am indebted for the history and report of the findings at postmortem, at which I was permitted to be present through the courtesy of Dr. W. H. Hunter and Dr. Eustace, is a very valuable one, since the positions of pus shown at the postmortem fully corroborate the findings which I have noted clinically in the cases which recovered, as well as verify the results which I obtained experimentally by injections of the forearm. It emphasizes also the difficulty of differentiating these cases at times from rheumatism. Unfortunately, I have not the exact age, but the patient was in the neighborhood of fifty years, which again draws attention to the influence of age in these fatalities.

Here the primary focus was in the ulnar bursa. Owing to the difficulty of diagnosis, the diagnosis and, consequently, the proper treatment were held in abeyance several days.

CASE XXII.—Miss E. J., Cook County Hospital. Patient entered on June 1, 1908. Attending surgeon, Dr. E. Wyllys Andrews; house physicians, Drs. Eustace and Courtenay.

History of present trouble: Patient enters hospital complaining of pain and swelling in right wrist and hand. Upon questioning she says she awoke last Friday night with pain in this joint. There was a sense of heat and the joint was particularly painful on motion. Her sleep was disturbed, and by the next morning she says her wrist was notably swollen and red. Tenderness was pronounced over the end of the ulna posteriorly, and

also anteriorly over both bones of the forearm at their carpal articulation.

A history of any previous injury, fall, infection, or arthritis of any sort is denied. Accompanying this the patient denies other symptoms of any sort, but since Friday the joint has become swollen and progressively worse, the pain is agonizing, and there is an indefinite history of chills and fever.

Previous illnesses: For the past ten years she has suffered intermittently from articular rheumatism, and three weeks ago she was a patient in this institution for otitis media and discharged after a period of two weeks' treatment.

Physical examination: Negative except as follows: The right wrist and hand are greatly swollen and inflamed, the wrist on both surfaces, the hand on the posterior surface only. The swelling is localized to the wrist joint and extends up the forearm for about three inches. The fingers are in semiflexion, and the slightest movement causes extreme pain. There is also extreme tenderness around the wrist-joint, which is also very painful upon motion. Lymphatic involvement is lacking, and apparently there is no tendon-sheath involvement. No atrium of infection can be found, and shoulder and elbow-joints are not involved. The left arm is not involved, though some pain is elicited on motion of shoulder. Fingers give evidence of a rheumatic diathesis (G. T. Courtenay).

	Pulse.	Temperature.	Respirations.
June 2, 1908	94	102°	24
June 2, 1908	103	102°	24
June 2, 1908	104	101°	22

White blood count on entrance, 8200. Patient given large doses of sodium salicylate.

Operation, June 4, 1908. Incision down to ulnar bursa and one above the anterior annular ligament on ulnar side. A hemostat was forced through to the

radial side and pus evacuated. Gauze drainage and hot boric dressings. Bier's constrictor applied to arm (A. B. Eustace).

Operation, June 7, 1908. Two incisions on the flexor surface of the forearm just above the wrist-joint and another three inches above this. These were each one inch long and penetrated to the flexor tendons; openings connected with gauze drainage (G. T. Courtenay).

Operation, June 15, 1908. Incision along ulnar bursa enlarged and a large amount of pus evacuated. Knee-joint aspirated and pus obtained. Two per cent. solution of formalin in glycerin injected. Died June 16, 1908. Autopsy by Dr. A. B. Eustace and Dr. Allen B. Kanavel.

Hand and Arm: Extensor surface: On opening back of forearm a small focus of pus is found at junction of lower quarters of forearm. This communicates with incision in skin on side. There was no pus between extensor communis and deeper tissues, except at point indicated, and this pus extended down underneath this muscle.

No pus found subcutaneously on the dorsum of the hand except at the wrist-joint, and this could be traced into the tendon sheath of the extensor communis digitorum. The tendon sheaths of the extensor radialis longior and brevior also showed pus. The tendon of the extensor carpi ulnaris was free from pus.

Back of the sheath of the extensor communis digitorum is seen an opening extending down to the carpal bones. Articulation between the carpal bones and the radius found to contain a slight amount of pus. Articulation between proximal and distal row of bones also contains a slight amount of pus. No pus found under tendons on the back of the hand, communicating with joint.

Flexor surface: Incision found in median line, at junction of lower and middle thirds through skin

immediately above annular ligament, and on either side at and above articular surface.

Incision on ulnar side extended upward for a distance of two and one-half inches. Incision also in palm of hand on ulnar side lengthwise along inner edge of hypothenar eminence. The hand as a whole does not appear to be greatly swollen, and some concavity appears in the middle of the palm.

Upon opening the palm of the hand, ulnar bursa found to be filled with pus and tendon sheath of little finger also filled with pus. Rupture had occurred into the forearm at a point one and one-half inches above the articular surface of the wrist-joint. Middle palmar space opened and found to be filled with pus. Thenar space free from pus. Tendon sheath of flexor longus pollicis free from pus. Radial bursa, no pus found at any point. Above the wrist-joint, pus is found in sheath passing up underneath tendons from mid-palmar space.

Forearm: Pus is found underneath the flexor profundus digitorum. Pus extended up the forearm in juxtaposition to ulna up to the elbow lying immediately on the ulna.

Pus also found along ulnar artery for a distance of about one and one-half inches at middle of forearm, but did not extend up to the elbow. A small opening is discernible at lower end of ulna connecting joint with ulnar bursa. It could not be determined definitely whether this opening was made by dissection or was present before.

No opening was demonstrable between wrist-joint and radial bursa.

No necrosis of bones of wrist-joint; tendon sheath of ring finger intact; tendon sheath of middle finger intact; tendon sheath of index finger intact. Pus extended out in little finger to proximal interphalangeal joint. Periosteum of radius and ulna not destroyed.

No pus in elbow-joint. Axillary glands barely palpable.

Heart: No evidence of pericarditis or adhesions.

Pleural cavities: Left, no adhesions; right, few adhesions at apex.

Lungs: Left, crepitates, no consolidation, frothy red serum exudes, apparently normal; right, answers above description.

Liver: Gall-bladder distended and filled with fluid. Liver is mottled on cut sections, the interlobular markings faint, no evidence of miliary abscesses. Tissues very soft and friable and color is paler than normal.

Spleen: Enlarged in size, is soft and friable. Cuts like butter. Miliary abscesses found.

Kidneys: Soft and friable. Capsules strip with some difficulty and leave parts of the cortex. Cortex is almost obliterated, as also are the pyramids, but here and there a distinct outline of a pyramid may be found.

Right knee-joint: Filled with thick yellow pus, small ecchymotic areas in periosteum.

Cultures before and after death showed staphylococcus albus.

Microscopic examination of the various organs showed acute parenchymatous degeneration.

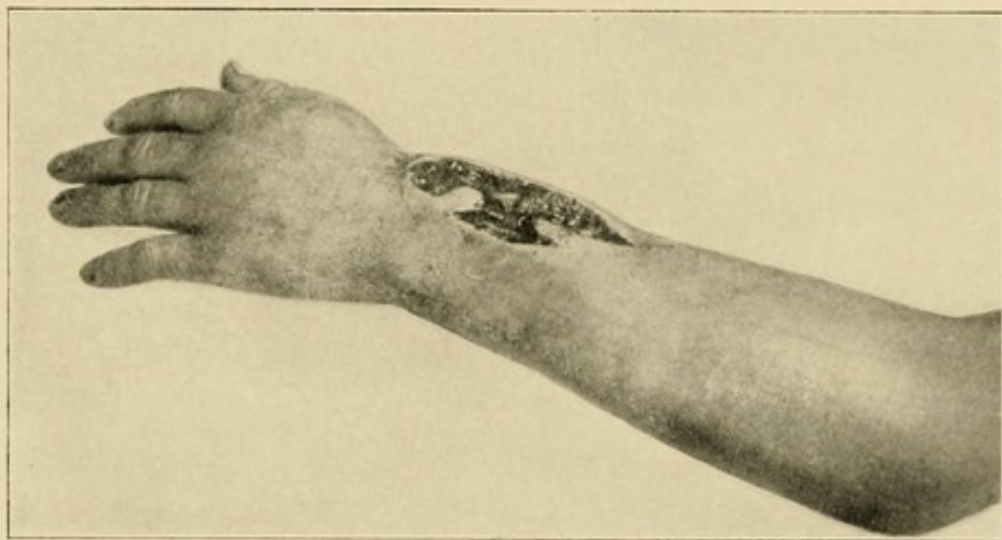
POSTMORTEM STATISTICS.—Tornier reports 10 fatal cases upon which postmortem had been made. The findings were as follows:

	Cases.
Acute hyperplasia of spleen	9
Parenchymatous nephritis	7
Bronchopneumonia	5
Lung abscesses	2
Empyema	2
Acute pericarditis	1
Hemorrhagic pleuritis	1
Subpericardial, subpleural, and cecal hemorrhages	4
Abscess of kidney	2
Abscess of liver	2
Thrombosis of veins	2
Icterus	3

The age of the fatal cases averaged forty-three and eight-tenths years.

THROMBOPHLEBITIS.—Either associated with lymphangitis or as a distinct process we may have thrombophlebitis. The symptoms and signs here would be the same as those occurring with thrombophlebitis of the leg, where it is more common. Generally beginning with a localized infection, the process extends into a vein. The severity of the symptoms depends upon the extent of the process, varying from those of a mild

FIG. 107



Photograph of a hand of a patient with thrombophlebitis. Wound is left open, as is seen in photograph. (Case XXIII.)

septicemia with localized evidences to most severe toxemia, metastatic abscesses, and death. This can best be illustrated by a case which came under my care at the Post-Graduate Hospital.

CASE XXIII.—Mr. L., aged twenty-five years. Post-Graduate Hospital, March 5, 1909 (Fig. 107).

Diagnosis.—Suppurative phlebitis of veins of dorsum of hand.

The patient applied to the hospital with a small infection upon the dorsum of the hand, apparently carbuncular in nature. The infection had been present

for four days, and was gradually increasing in size. The hand was considerably swollen, and there was an area of swelling and induration extending up the dorsum of the forearm for three inches. Temperature, 101° ; pulse, 94; urine negative.

Operation.—Gas anesthesia. A crucial incision was made over the area and an accumulation of thick pus and seminecrotic tissue evacuated. The indurated area extending up the dorsum of the forearm was found to be a large vein which was filled with a septic thrombus. This was opened for four inches up on the area, when a free regurgitation of venous blood was secured. The vessel was tied and the wound left open (Fig. 107). A Bier constrictor was applied.

Following the operation the local area granulated freely, and rapidly went on to complete repair. Over a period of four weeks, however, the patient developed three metastatic abscesses in various parts of the body, which were opened. Fortunately, none developed in the bones or viscera, at least, so far as was discovered. The temperature and pulse were never high, but still fluctuated with the development of the foci. The patient ultimately made a complete recovery.

CHAPTER XXII

PROGNOSIS IN LYMPHATIC INFECTIONS

THE prognosis as to life in lymphatic infections is dependent upon so many factors over which we have no control that it is extremely difficult to arrive at any satisfactory statement concerning it. In Helferich's clinic, in a series of nearly 200 severe infections of the hand, a fatal issue followed in 22 per cent. These statistics comprise all types of infection of the hand, and are limited to extensive abscesses, tenosynovitis, and severe lymphangitis. This percentage is certainly high for patients in the ordinary walks of life.

Of the factors concerned, of chief importance is the age of the individual. The average age of fatal cases is in the neighborhood of forty-five years. The general state of the patient's resistance is of importance. For instance, in Cook County Hospital, where the social derelicts are found, the mortality is much higher than in private hospitals. The presence of nephritis in the various forms or of any of the chronic system diseases has a marked influence upon the prognosis.

If the symptoms of toxemia do not subside within three days, if no local process has developed, or within two days after opening such foci, anxiety should be felt for the patient. Either there is a local extension, or the patient is not reacting. The part affected has some influence upon the prognosis. The presence of an infection beginning in the little finger or the thumb causes fear of tenosynovitis with a prolonged convalescence, while an involvement of the index or middle finger may lead to severe systemic symptoms early. The type of germ in a given patient is also of great importance from a prognostic standpoint, since it is

well known that the gravest infections arise from the streptococcus and certain of the gas bacilli. Again, a brusque onset with high temperature and chills speaks for a serious infection.

To my mind the prognosis is influenced somewhat by the character of treatment. If ill-advised and premature incisions are made, what might have been a moderate infection may be turned into a severe type. Many attempts have been made to secure data upon which prognosis may be made by an examination of the blood, and this is of some general value. One of the latest and most complete researches is that of Zangmeister.¹

The first conclusion which the author derived from a large series of blood counts was that the numeric fluctuations of the single leukocyte forms per cubic centimeter of blood show the real condition of the patient, but not the numerical ratio of the variety of forms to each other. To make a prognosis in streptococcus infections from the blood picture it is important to know that the conditions change completely after the first twenty-four hours after the infection, and that the findings during the first twenty-four hours do not apply later on.

In monkeys he found the following after the first twenty-four hours after infection:

1. In infections rapidly fatal, all forms of leukocytes decline quickly in number.
2. In infections fatal after a few days he found a tardy and small increase of the mononuclear neutrophilic cells and a decrease of the polynuclear neutrophilic and eosinophilic cells and lymphocytes in the first eighteen hours.
3. In infections not fatal he found an increase of the mononuclear neutrophilic cells during the first six

¹ Monatsschrift f. Geb. und Gynäk., Band xxxi, Heft 1.

hours after the infection; from then a decrease. The polynuclear and eosinophilic cells and lymphocytes increase in number after the first six hours.

Therefore good prognostic symptoms are:

(a) An immediate increase of the mononuclear neutrophilic cells for the first six or eight hours, with a following decline.

(b) An increase of the polynuclear cells after six hours, after a short decline.

(c) An increase of the eosinophilic cells inside the first twenty-four hours.

(d) An increase of the lymphocytes in the first twenty-four hours.

The prognosis is bad (1) if the mononuclear cells show no increase or a decrease in the first eight hours; (2) if there is a continuous decrease of the polynuclear cells and lymphocytes.

In a large series of the blood countings before and immediately after operations, the author found that these findings in monkeys are parallel to those in man.

After the first twenty-four hours conditions are changed, and the curve of the eosinophilic cells, of the lymphocytes, and of the mononuclear neutrophilic cells is of no importance. A continuous decrease of the polynuclear cells or their remaining stationary is a bad prognostic sign. In less severe infections they will rapidly or at least slowly increase.

His final conclusions are:

"We are allowed to make a good prognosis inside the first twenty-four hours after the infection if we find (a) an immediate increase of the mononuclear neutrophilic cells with a slow decrease after eight hours; (b) an increase of the polynuclear cells after eight hours after a small decrease.

"We have to deal with a fatal infection (a) if the mononuclear cells increase after the first twenty hours;

(b) if the mononuclear cells do not increase at all or decrease immediately after infection; (c) if the polynuclear cells decrease constantly.

He made one blood count before, one six to eight hours, and one twenty to twenty-four hours after the operation respectively after infection.

After twenty-four hours, the number of polynuclear cells only is of importance; if they are below normal and keep on decreasing the prognosis is bad, and *vice versa*.

By injecting a person with dead streptococci, Zangmeister was able to test the resisting power of the person against streptococcus infection—"Resisteur probe." If the resisting power is reduced, the mononuclear cells after the injection will show no increase or the increase comes late; the polynuclear cells will show no increase soon after the infection, or a decrease.

What may be said regarding the probability of local complications? It is impossible to arrive at any just estimation as to the probability of the development of tenosynovitis and fascial space abscesses. In my experience those patients showing a brusque onset with great pain are more likely to have such complications. The tenosynovitis is more likely to develop from infection implanted on the volar surface of the distal or middle phalanx. Local accumulations on the dorsum of the web between the fingers is apt to develop from the callus cracks at the distal portion of the palm. Dorsal subcutaneous thenar abscesses appear in infections of the thenar palmar surface. Subcutaneous abscesses above the anterior annular ligament often occur in connection with tenosynovitis. Ill-advised incision may determine the localization of infection in various spaces. In several patients whom I have seen in consultation, I feel sure that the tenosynovitis which developed was directly due to the primary incision.

CHAPTER XXIII

THE TREATMENT OF LYMPHATIC INFECTIONS—GENERAL DISCUSSION

THE treatment of lymphatic infections is based upon two principles—conservatism and conservation. In no type can more harm be done by ill-advised incisions than in this. The position of masterful inactivity is most difficult to maintain, and yet the surgeon is constantly aware that his tendency to incise is due to his desire “to do something” rather than an exact knowledge as to what to do. We therefore use local measures designed to wall off and overcome the infection, combined with procedures designed to support the system and increase its resisting powers. In the ordinary case, until some localization is present, we apply hot, moist dressings, insist upon local and systemic rest, combined with cathartics and sedatives, as the case may demand.

DISCUSSION OF VARIOUS PROCEDURES

LOCAL.—*Hot, Moist Dressings.*—Many forms of such applications are in use and have a vogue for a time. It is my personal opinion that such applications owe their value more to the moist heat than to the drug with which they are combined. It is my custom to use boric acid in saturated solution. I am aware that many studies have been made from which conclusions were drawn as to its antiseptic property when absorbed by the blood stream. It is probable that it would be unjust to say that such minute quantities as have been

demonstrated in the blood, and consequently in the urine, can have no effect, since no one knows the effect of combining small proportions of any chemical solution with blood serum in vivo, although in the test-tube such combinations may be shown to be without value. It would seem more reasonable to ascribe the beneficial value of such applications to the dilatation of the capillaries and the bringing of more blood to the part, favoring the walling off of the infection.

Peculiar value has been ascribed by various surgeons to bichloride solution, creolin, almost all of the various antiseptics, ichthyol, alcohol, etc. Unless they are used for a particular purpose, however, it would seem that hot boric solution will be as efficient as any.

Certain special purposes may be secured by special solutions. In those cases in which there is a foul odor, a 1 to 2000 or 1 to 4000 potassium permanganate solution will be found of value. We may secure some slight local antiseptic property in the use of alcohol dressings, using a 30 to 50 per cent. solution. This should not be kept up any length of time. It is certainly not necessary to warn the profession against the use of carbolic acid solution in any strength. The frequency with which carbolic acid gangrene is seen, however, leads me to urge upon physicians the necessity of informing patients of the danger of this remedy, which is so often the home application for all cuts and injuries.

The method of applying hot boric dressings has been discussed on p. 72. They are so applied as to cover the entire forearm and arm in the severe cases. It is a good rule to make the dressing much larger than the condition would seem to call for. These hot, moist dressings are to be used until the red line of lymphatic involvement has entirely disappeared and any acute edema has begun to subside, at which time a change should be made to a dry dressing of some kind.

Rest.—Both local and systemic rest should be insisted upon, especially in severe infections. The local rest is of especial value in a prophylactic sense, since every movement of the fingers or hand tends to favor lymphatic circulation and hence to favor dissemination of the infection. Von Volkmann and others have advised suspending the arm so that the hand is elevated. It does not seem that this would be of value except to relieve the pain of a congestion, and it has not seemed to me to influence the course favorably.

The Bier Treatment.—The place of the Bier treatment in infections of the hand has already been touched upon (p. 71). In these lymphatic infections I have used it only in the same sense that we would use a ligature to prevent the rapid absorption of any poison, as, for instance, in the slow absorption permitted in snake bites. It, therefore, would find a place in the early hours of a virulent lymphatic infection in which the system may be receiving large doses of virulent toxins without seeming to have the reactive power necessary to wall off the infection. Here the constrictor is applied for from twelve to eighteen hours, tight enough to secure a marked edema. This is done with the hope that the lack of reaction upon the part of the system is due in part to the fact that it is overwhelmed, and that if small doses are allowed to enter the system a marked antitoxin will be developed which will be able to withstand the toxin if its entrance into the system is spread over some time. Whether or not diapedesis of leukocytes in these infections is favored by passive congestion is a moot question.

The method of applying the bandage is as follows: A Martin bandage two inches wide is used. The bandage is begun at a point slightly above the elbow and carried to a point slightly below the axilla. Several turns are carried about the arm, so made as to preserve an

equable pressure throughout. The pressure should be sufficient to produce a moderate edema in an hour, and should not be sufficient to produce pain. The method used by some of wrapping a towel about the arm and securing constriction by a rubber tube or narrow rubber band is unwise, since it will cause considerable pain and is more likely to produce nerve injury. After the bandage has been in place twelve to eighteen hours it is removed and replaced in a couple of hours if the toxemia is still high. Ordinarily, one or two eighteen-hour periods is all I have found of advantage in these cases.

Incisions.—There may be some difference in opinion as to the advisability of these under certain conditions.

There are those who teach that an incision made at the point of great pain and tenderness when it is the site of the primary infection will be of value. They maintain that such an incision if it does not evacuate pus favors drainage about the site of the infection, and that the escaping serum carries off the bacteria. It is my own belief that this hope is seldom justified, and that the incision simply opens new lymphatics for infection and fails to reach the bacteria which have already entered the lymphatic stream and are multiplying some distance from the site of entrance. Therefore, the prophylactic incision fails of its purpose and may do much harm by producing complications.

Shall incisions be made along the line of lymphatics? In those cases in which there is one or possibly two red lines of lymphatic involvement running up the arm the advice to make a transverse incision through the skin and subcutaneous tissue, so as to prevent the channel from carrying more toxin, seems logical, and I have carried it out in a few cases. I am convinced, however, that the procedure is likely to do more harm than good, since it pours out into the wound the virulent bacteria

and toxins which at the end of a few hours begin to be absorbed in greater amount than before. The picture presented by this procedure is very characteristic. Within an hour after the cut is made the part proximal to the incision becomes pale, the red lymphatic disappears, and the surgeon feels that his procedure has been justified by the results. At the end of a few hours, however, it is seen that the portion distal to the incision has begun to assume a reddish tinge, and shortly a considerable area takes on the characteristic appearance of an erysipelas, with an aggravation of the symptoms.

In other instances the little lacunæ found in the course of the lymphatic vessels (see p. 319) show small areas the size of a bean in the course of the lymphatics, at which sites there is a local swelling and edema. These are most common on the dorsum of the hand. The thoughtless are inclined to incise these under the impression that localization will be found there and that drainage is indicated. If incision is made, however, only a small amount of serum will exude, and in the severe cases the procedure is generally followed by a chill and rise of fever within an hour or two, sometimes to an alarming degree, while the procedure is detrimental rather than beneficial to the ultimate course.

If incision is made in these cases for any cause, the possibility of spreading the infection must be borne in mind and one should seek at least to prevent rapid absorption. This is done by keeping the arm absolutely at rest and applying a Bier constrictor to the arm. This should be left on for from twelve to eighteen hours. These incisions will be called for in those cases in which localization in the tendon sheaths or in the subcutaneous tissues has taken place, as, for instance, on the back of the forearm or about the glands. (For a discussion of these, see p. 359.)

SYSTEMIC TREATMENT.—*Antagonistic Drugs.*—Various drugs have been vaunted from time to time as of exceptional value in septic conditions. They may be classified as those designed to destroy bacteria and those to neutralize the toxin. The value of any of them is questionable. Quinine has been used for many years, and if it were of marked value sufficient positive evidence should have accumulated by this time to leave no doubt, and this cannot be said to be true. The same may be said of urotropin and the various silver salts which have been vaunted so highly. Upon none of these can the surgeon depend with any distinct hope that they will be of value. The use of whisky is in a different class. Any value it may have depends upon the fact that its elements are less stable than normal cell protoplasm, and consequently there is some hope that the toxin may unite with these rather than cause destruction of the living cells. There may be some truth in this. The trouble is that to be of much value in this regard there should be a considerable amount in the blood, and the excretion of any considerable amount would be injurious to the kidneys.

In this connection it has been my habit to give these patients who are seriously ill fully peptonized food per rectum if they cannot take it by mouth, so as to introduce into the blood peptones, less stable than normal albumin of the living cells, with the hope that the toxins will unite with the less stable combinations and thus protect the system. This can do no harm, and may do good.

Related to this we have the use of normal salt solution introduced into the system per rectum, as well as large amounts of water and fluids by mouth. In serious cases the normal salt may be given subcutaneously. It is my belief that the introduction of

large amounts of fluid with the idea of diluting and eliminating the toxins is of great value.

Serum and Vaccine Treatment.—We have not as yet developed any serum or vaccine that can be said to be of definite value in these acute cases. The field is a most engaging one, and many attempts have been made to produce an antitoxin. The difficulties seem to be almost insuperable. If given very early it might have some effect, since some of the sera, such as that of Aronsen, have some bactericidal in addition to its antitoxic and opsonizing effect. Often the toxemia is well advanced, and such an immense amount of antitoxin would be necessary to neutralize the toxins that we cannot hope to inject it, and the opsonizing and bactericidal effects are insufficient. Moreover, it has been shown many times that the antitoxin prepared for one type of streptococcus will have no effect upon the toxins generated by a second type of streptococci.¹

Van de Velde showed that the leukocidin produced by one staphylococcus pyogenes aureus might be almost innocuous, while another might be most virulent. Denys, Van de Velde, Neisser, and Wechsberg have produced antileukocidin, but it must be for the specific organism.

Therefore, to secure the best results a serum must be made from the germ producing the disease, and this is manifestly impossible, since the time is too short. In attempts to obviate this difficulty some have made their antistreptococcus serum from a combination of several strains of streptococci, *i. e.*, the so-called polyvalent antistreptococcus sera, such as those of Tavel, Moser, Menzer and others, while the sera of Marmorek and others is monovalent, *i. e.*, made from one strain. Whether these sera act in a bactericidal or antitoxic

¹ Meakins, Phagocytic Immunity in Streptococcus Infection, Jour. of Exper. Med., xi, 815.

manner or by stimulating cellular activity is a subject for discussion, but at least the effect is inadequate. It is possible that in the more chronic types vaccines may be produced that will aid somewhat. In this connection a perusal of Case XXIV should be of interest. In this case almost all of these methods were tried without avail.

The injection and use of *elements designed to increase leukocytosis* is another favorite method of treatment. For this purpose several drugs have been used, as, for instance, protonuclein and nucleic acid, but without definite results. His has recently suggested the injection of sterile exudate, secured incident to aseptic injections of the pleural cavities of lower animals with aleuronat. As yet this has not secured a trial.

In spite of the lack of definite results by any of these methods, one cannot but hope that the future holds some promise of aid from these studies. The surgeon should always have in mind the possibility of value from the sera, watching his cases closely for a favorable opportunity; but as the case now stands it is my personal opinion that he is not in position to promise his patients any distinct curative action in the more acute cases.

Supportive Measures.—Supportive measures in the way of stimulants, fresh air, good food, attention to the bowels, and proper rest should not be neglected. The fresh air and sunlight, especially in the more chronic cases, is of distinct value. One patient suffering from such a chronic infection, which defied all manner of treatment, was transferred to an open air sun room where he lived and slept. The benefit of the change was evident to everyone (see Case XXIV).

CHAPTER XXIV

THE TREATMENT OF THE COMPLICATIONS OF LYMPHANGITIS

TENOSYNOVITIS

ATTENTION has been drawn to the frequency of tenosynovitis in lymphatic infections beginning in the distal phalanges on the volar surface. In the chapter dealing with the subject of tendon-sheath infections (Chapter XI), a complete discussion has been given which should enable the student to diagnosticate the presence of such a complication, and rules have been laid down for the treatment that has been most successful in my hands. There only remains, therefore, a discussion of such general principles as pertain to lymphangitis in particular.

If the patient complains of great pain over the tendon sheath when the primary puncture has been upon the volar surface of the finger, even though the pain has not extended to the entire finger, one should be especially on his guard, and the moment that the tenderness has extended from the site of the infection to involve the distribution of the subjacent tendon sheath, the incision should be made exposing the sheath. If one delays longer, destruction of the synovial covering will have occurred, in which case the prognosis for function is much more grave. It is my habit to make lateral incision on one or both sides of the middle and proximal phalanges, and thus secure drainage, being careful not to produce a secondary infection, and also using care to cut far enough toward the volar surface

to avoid the lateral vessels and nerve which run up the sides of each finger. If there is much destruction of the synovial covering parietal and tendinous, it will be advisable to lengthen the incision upon one side so as to connect the two phalangeal cuts, thus giving free drainage but preventing a prolapse of the tendon because of the lateral site of the incision. This is further prevented by placing a dorsal splint upon the finger and hand, which tends to keep the finger in extension and thus favor retention of the tendon in its proper place. If one is very prompt in the incision, so that no destruction has taken place, he is gratified and surprised at the rapid recovery he secures. Sometimes it is entirely well by the end of ten days or two weeks. If the process has lasted some time, it is frequently necessary to incise at the side of the finger over the lumbrical space to secure drainage of the loose tissue here and in the web. Care should be taken here not to cut the blood supply. If there is doubt as to the side involved, it may be best to cut down upon the median surface over the proximal end of the sheath in the palm and then secure drainage from either side through this incision by inserting an artery forceps into the loose tissue at the side and separating the blades so as to give free exit to the pus (see p. 252, and Figs. 87 and 89). If vaseline gauze drainage is inserted in the early cases, it can be removed the next day. If the thumb or little finger is the source of the infection, the radial or ulnar bursæ are opened after the method described in Chapter XVI. If there is no tenderness above the wrist it may not be necessary to make the lateral incision above the flexor surface of the ulna and radius. If there is any tenderness, however, or swelling, incisions should be made at once and drainage instituted (see p. 258). Before any incisions are made the Martin elastic bandage should be applied

to the arm, and following the operation it should be loosened only to the degree necessary to produce a marked Bier's hyperemia. This helps to wash the toxins out of the tissue adjacent to the wound, and also prevents the rapid absorption of toxins, a fact which I have already discussed. All the various locations of pus secondary to tendon-sheath infections and the proper procedures indicated in their treatment have been discussed in Chapter XVI.

SUBCUTANEOUS ABSCESES

Subcutaneous abscesses frequently appear upon the dorsum. As soon as a definite redness and hardness have appeared, indicating pus, free incisions should be made. Simple redness and edema is not sufficient to indicate incision, but when the hardness has been added free incisions under the same precautions as mentioned above should be made. The presence of extensive subcutaneous destruction of the connective tissue with the formation of a slough with streptococcic pus is one of the most serious complications. Incision should be made early, in several places upon the dorsum, so as to give perfect drainage. At the risk of useless repetition, let me say again that I am speaking of the indurated, brawny, dark red dorsum, characteristic of the spreading virulent phlegmon, not of the pinkish, edematous, pitting dorsum. Neither am I speaking of the simple staphylococcic abscess. The gravity of this severe type has long been recognized.¹

¹ Bauchet thus describes how they were considered and treated by Velpeau:

"An unconfined phlegmon is one of the most serious complications of a whitlow. It is heralded by a series of serious symptoms here as in all other parts, by a considerable swelling, and a characteristic dull, yellowish redness.

"The diffuse phlegmon is undoubtedly a serious matter when it appears on the back of the hand, but it is even more dangerous when it invades the forearm and arm.

"The first symptoms of this awful complication once recognized, one must not hesitate to have recourse to the most drastic therapeutic measures; anti-

PERIGLANDULAR ABSCESES

Periglandular abscesses occur especially on the epitrochlear and axillary regions. These are not so virulent as the type just described, and a more conservative course may be pursued. Since they start from glandular suppuration, some days will elapse before they become evident. The surgeon will often be in doubt for a day or two as to whether the infection may not be a simple glandular hyperplasia. The waiting period is not without advantage to the patient, since it offers an opportunity for the abscess to become walled off, and thus favors the prevention of extension when it is opened.

SUBCLAVICULAR AND SHOULDER ABSCESES

The occurrence of such an abscess will of course be rare, since they arise in the course of the lymphangitis extending along the lymphatics lying in the pectoro-deltoid groove, having its origin most commonly in the middle finger. It has been my fortune to meet with only one such case, and this began in the index finger. Dr. J. M. Neff, of Spokane, has seen and operated upon another one, in which the origin was in the middle finger, followed in three days by a subclavicular ab-

phlogistics, local and general baths, purgatives, opiates, and the arm placed in an elevated position. If at the end of twenty-four or thirty-six hours the symptoms do not mend, and if the disease seems stationary, one must insist upon the compresses, if the patient has been able to stand them, after generous applications of ointments of mercury. If the compresses increase the pain, one may profitably resort to the application of a large volatile vesicatory, covering all the diseased parts. This means, so extolled by M. Velpeau, has and always will render good service.

"However, if the general symptoms continue to grow worse, if the swelling increases, the moment to proceed with the bistoury has come, and three or four long deep incisions must be made. This is the only road to recovery left to the patient."

cess, which was opened, and this in turn was followed by, or accompanied, a synovitis of a knee-joint of a serious nature, but from which the patient ultimately recovered. This case then is most interesting, since it emphasizes the origin of these abscesses and also serves to emphasize what I have previously called attention to, and that is the seriousness and frequency of systemic involvement from lymphangitis originating in the middle finger.

SYSTEMIC COMPLICATIONS

These must be met as they arise and the treatment based upon the general surgical principles governing septicemia and pyemia. The metastatic abscesses should be opened, empyemas drained, pneumonia, etc., guarded against with every possible precaution.

The question of amputation of the arm in these severe cases will be a constant one, but no definite rules can be laid down. One will constantly feel in the early cases that amputation is too severe for the condition, and when systemic infection has begun it will be considered that amputation will be futile, so that the indications for amputation will be drawn between narrow lines. In exceptional cases some hope may be offered by this procedure, as, for instance, in a spreading phlegmon or in a malignant edema.

CHRONIC INFECTIONS; REPEATED INFECTIONS

It is an unfortunate fact that one infection with a streptococcus does not immunize the patient; at least, if it does, it is only for a short time. Not only are repeated infections possible, but one infection seems almost to favor a second at a later date. This is not true to the same degree with the staphylococcus, by

which a mild degree of immunization may be secured. This is demonstrated by the raising of the opsonic index as determined by the Wright method. The streptococcus particularly not only may not develop immunization, but also lacks to a marked degree the power in many cases to produce antitoxins in a degree sufficient to overcome itself, so that we often see cases of chronic long-continued infection which undoubtedly had their origin in a streptococcus infection. No better example of this type of infection could be cited than that of a case I saw with Dr. Oleson, of Lombard, Ill. It is true that another factor came into this case, namely, that the infection had possibly come from organisms which had passed through a lower animal, which we know may change the virulence in many ways. The case, however, is worth a careful perusal, since it was so carefully and conscientiously treated by Dr. Oleson by every known scientific method, and yet it resisted treatment for over two years, the patient apparently not having the slightest ability to develop antitoxins. He has now completely recovered.

Dr. Oleson has already reported the case, and I herewith abbreviate his report:

CASE XXIV.—“On June 15, 1906, over three years ago, the patient removed a wart from the index finger of his right hand, leaving an opening in the subcutaneous tissue which did not readily close. While this condition existed he received orders to care for some sick calves, afflicted with a disease which caused dyspnea, with considerable salivation. In giving them medicine it was necessary for him to introduce his right hand into their mouths, with the natural consequence that it became covered with their slobbery saliva. In a few days he sickened and called in Dr. William Dillon, of Urbana, who reports under date of August 18, 1906, substantially as follows:

“In regard to Mr. J.’s illness, I was called to his room about 9 P.M., June 27 (1906). I found him lying down, with perspiration in large drops over his face, pulse full and rapid, temperature about 103° F. Pain about axilla. Axillary glands indurated and enlarged. There was a small unhealed place in the centre of a spot on one of his right fingers, from which I could press out a little serum, but which had no soreness. I ordered fomentations during the night, with magnesia sulphate internally. The following morning there was less pain, but more fever, and I had him removed to a hospital, where the treatment was continued. The glands returned to their normal size so far as could be detected, but fever and sweating continued. About the third day in the hospital painful tympanites developed, also swelling along the general direction of the pectoralis tendon from a little *below the arm-pit to near the eleventh rib. This was the first appearance of localization.* I called in Dr. Newcomb, who aseptically incised the tissues down through the deep fascia. A little serum escaped. About July 22 the second incision was made and the entire cavity washed out with bichloride and dressed with dry dressings. Now the patient rapidly improved and the abscess walls united so that when irrigated the fluid would extend but a short distance in any direction. The pus by July 30 had almost ceased. Temperature normal, pulse normal, patient bright, no sweating.’”

Dr. Oleson here continues:

“I first saw the patient on August 10, 1906. On entering my office a limitation of motion in the right shoulder and a marked cervical scoliosis was evident. He was pale, anemic; pulse, 106; temperature, 98° F. At the anterior margin of the right axilla, along the border of the pectoralis major, appeared a long scar, presenting at its upper end a small orifice discharging

a thin blue-green serum. A second opening existed to the axillary side of the scar, about an inch below the first sinus. No swelling, some redness, tenderness slight, shoulder-joint motion limited, evidently from scar contraction. A flexible sterilized probe introduced into the sinus with strict asepsis passed under the clavicle for some distance toward the vertebræ, so that the general clinical picture simulated a cervical Pott's. But a few days' study satisfied me that there was no vertebral disease, nor could I find evidence of any shoulder-joint trouble.

"He passed into the hands of a neighboring sectarian practitioner, and after some weeks of unimprovement entered a homeopathic hospital in this city. Here the gradually enlarging ulcer, which appeared at the site of the sinus and slowly spread downward along the thoracic wall in the direction of the original incision, was curetted, and the patient received considerable x-ray treatment, with steady failure of his vital forces until the latter part of March, 1907, some nine months after the original infection, when, on the suggestion of the hospital authorities, he was taken from the institution to end his days among his friends. Here I saw him on March 28, 1907, since which time he has been continuously under my care. He presented then the typical picture of advanced chronic sepsis. He was thin, haggard, with a marked Hippocratic facies, scoliosis more evident, temperature running a classical hectic curve (morning remissions to 98° F., evening readings varying around 102° F.), then constantly between 120° and 130° , having the appearance of impending death. Locally the margins of the sinus had broken down to form along the thoracic wall a deep ragged ulcer as large as the palm of one's hand with sinuses radiating upward, forward, and downward, honeycombing the tissues in the pectoral region, while

over the third and fourth right costochondral junctions appeared bluish-red depressed areas, evidently marking points at which pus was about to appear. The former bluish-green discharge was now almost colorless, very profuse, and of a thin serous nature, soaking large gauze dressings daily. . . .

"On April 6, 1907, under chloroform anesthesia by Dr. Pickard, with Dr. W. F. Scott assisting me, I removed inflamed periosteum and perichondrium, with subjacent necrotic tissue at the points indicated by the discolored skin, curetting from all accessible places the various sinuses, scraping out large quantities of soft, pale, pulpy friable granulations, with free hemorrhage easily checked by pressure. The patient was put to bed in an exhausted condition, while my consultants cheerfully foretold an early lethal termination.

"On May 6, 1907, I performed a second similar operation, attacking new fresh necrotic areas over the second and fifth costochondral junctions. The result of these two operations was a considerable improvement in the pulse curve, which now rarely went over 110, while the temperature did not pass above 101°, with no local change except the healing of one sinus which had invaded the tissues from the lower margin of the ulcer.

"On July 6, 1907, I performed what was intended for a radical operation, by making a deep curved incision from the lower border of the ulcer, anteriorly to the sternum, separating the entire pectoral flap of muscles, reflecting them back over the shoulder and exposing this region for general curettage. . . .

"After thorough scraping of all other lesions the flap of muscle was sutured back into place. The patient did not react well, it being several days before he ceased vomiting, and the general immediate result of this intervention was the actual spread of the infection,

as it followed each suture and needle puncture into new regions, reaching around also into the intermuscular septa and subcutaneous tissue of the back, a region previously uninvaded. Various abscesses were opened during the next month.

"During all this time the wound had been dressed by daily irrigation through drainage tubes or along the sinus tracts. All sorts of fluids had been used—normal saline, plain sterilized water, iodine water, hydrogen peroxide, pure and in solutions of varying strengths, bichloride and phenol dilutions, with no appreciable improvement. On September 2, 1907, I made a radical change, permanently abandoning all forms of irrigations, and substituting plain dry sterile dressings, with immediate marked improvement in the general condition. The temperature fell to 99° and remained there, while the pulse varied between 90 and 100. There had been nervous digestive disturbances, so that any unwelcome suggestion, *e. g.*, the discussion of an anesthetic or the odor of ether, etc., would cause a prompt and thorough emesis. Yet he had gained 10 pounds in bodily weight in five months, but with the cessation of irrigation the digestive derangement ceased, he took and retained large amounts of food, with cod-liver oil, sevetol, etc., so that in the next five months he gained 26 pounds, with corresponding physical improvement. By the middle of January, 1908, he was strong, robust, healthy appearing, but with absolutely no improvement whatever in the local lesion, which remained stationary, discharging daily large quantities of seropus, necessitating copious aseptic dressings.

"At about this time Dr. Emil Beck announced the result of his work in the treatment of certain unhealed sinuses by the *bismuth paste* method. Injections were given January 22 and 28, 1908, with no especial result

except that the patient's weight fell off a little. In order to give the paste a little better chance, I decided to curette the granulations from the sinuses again, and then to make a third injection. This I did on February 10, 1908, and on the morning of February 11 I found my patient with a pulse of 140; temperature, 102°; rusty sputum and consolidation of the left lower lobe. . . . A typical crisis occurred on the seventh day, with uncomplicated convalescence. One peculiar phenomenon presented itself on the third morning of the seizure, when the patient suddenly expectorated a single mouthful of pure pus, of which the anatomical origin was never satisfactorily located.

"On February 26, 1908, he returned to his home, having lost 17 pounds, which he proceeded to regain. At this time, through the courtesy of Prof. Ormsby, I secured from the research laboratory of Parke, Davis & Co. a supply of *staphylococcus vaccine*, varying doses being injected on March 14, and for a month afterward, without effect. Thorough search was now made by Prof. Ormsby for evidences of blastomycosis, actinomycosis, and tuberculosis, with negative results. Prof. Hektoen now generously placed at my disposal his laboratory facilities, and his assistant, Dr. D. J. Davis, readily isolated from the pus a streptococcus which grew abundantly in almost pure cultures, but presented no identifying morphological characteristics. The patient's opsonic index to this organism was subnormal.

"On April 16, 1908, I injected the dead bodies of 500,000,000 *autogenous cocci* obliquely into the subcutaneous tissue of the right thigh. In two days an induration appeared at the site of injection. Twelve days from date of puncture fluctuation was evident at this point. On May 6, twenty days from the injection, the skin here grew purplish. Two days afterward, on

May 8, under aseptic precautions, I aspirated some of the contents of the swelling, which, on examination by Dr. Davis, proved to be sterile, chemical pus. On May 15, twenty-nine days after injection, the skin finally broke down and the contents escaped, leaving a superficial ulcerated area, which slowly cicatrized across from the margins, ultimately healing on July 3, 1908, seventy-eight days after the date of injection.

"This history is that of each inoculation made obliquely, leaving the vaccine in the subcutaneous tissue. As the weeks went on I lessened the dose to 250,000,000, 60,000,000, 10,000,000, and each one caused the breaking down of connective tissue, the formation of sterile chemical pus, the death of the overlying skin from starvation—an open ulcer—slow healing, so that we finally had an absolute clinical demonstration of the method of local spread of this coccus, namely, by the secretion of toxins, which by their chemical action on the connective tissue—not skin, not muscles, but subcutaneous tissue, fasciæ, septa, etc.—cause this to gradually die and melt away, destroying the bloodvessels which run in its meshes, and so bringing about the death of overlying skin or underlying bone, not by attacking these structures themselves, but by cutting off their nourishment.


"To prove this I then proceeded to inject the same doses of dead cocci deeply in the muscles themselves, beginning with 10,000,000 and steadily increasing the quantity until, on August 29, 1908, I gave him 300,000,000—and not once was there the least reaction, local or general, to a single intramuscular injection, while everyone of the oblique subcutaneous injections of the same cultures, with identical aseptic precautions, produced local necrosis.

"During this period, while we were endeavoring to do something to help the patient by means of specific

vaccine, his general condition failed slightly. He lost about 8 pounds in weight, and there was a slow spreading by undermining the skin around the affected area, so that at the end of this time, when this method was abandoned, the area involved reached its maximum, covering the right side of the body from the sternum into the middle of the right half of the back and extending from a point above the clavicle down beyond the costal margin—a stretch of 29 cm. in each diameter. I now decided to expose the affected region thoroughly, and on September 15, 1908, I curetted again all sinuses and completely excised all undermined skin. At last this was followed by actual healing, beginning in the back of the arm, but progressing slowly.

“For some time I had been anxious to give my patient the benefit of sunshine in direct application to the wound surfaces, but no practicable method presented itself to me on account of the large area to be covered and the very free discharge. Fortunately, on November 28, 1908, Dr. Allen B. Kanavel saw him and suggested a home-made wire cage. This crude appliance was applied on December 3, and proved to be the one missing link in the chain to drag the patient back to health. The wire cage was enveloped with sterile gauze, and so enfolded and protected, my patient has spent the last ten months basking in the sunlight, with slow but steady healing of the local lesions in all spots the sun's direct rays could reach. The range of pulse is in the sixties, the temperature normal and the general condition most excellent.”

The history of this patient serves to emphasize that in such cases the general hygienic rules are of more value than any special procedures. This would include outdoor life and nourishing food, combined with the least possible local treatment of the infected areas. The futility of vaccine treatment was also emphasized.



SECTION IV

ALLIED INFECTIONS

CHAPTER XXV

ERYSIPELAS, ERYSIPELOID, GAS BACILLUS INFECTION, ANTHRAX

ERYSIPELAS

ERYSIPELAS may appear in two types: first an uncomplicated cutaneous lymphangitis corresponding to the picture seen upon the face, and second, as a cutaneous lymphangitis, complicated with a subcutaneous lymphangitis. This latter type is more common in the hand. The former, the rarer type, is that of the typical erysipelas as seen upon the face with the brawny induration confined to the skin and outlined by a distinct border. The deep purple-red skin may have blebs upon it. The second type is the accompaniment of the severe subcutaneous lymphangitis, and has been discussed on pages 332 and 361.

The treatment of erysipelas proper is clearly that of a lymphangitis which also has been discussed (see pp. 351 and 356). No special applications such as carbolic acid, ichthyol, salicylic acid can be considered to be of especial value. In the superficial type the usual hot, moist dressings may be used; the treatment of the severer types referred to, which are often called gangrenous erysipelas or gangrenous cellulitis by surgeons, has been discussed on page 361.

ERYSIPELOID

This is a condition seen most commonly upon the fingers and which may be mistaken for true erysipelas. The earlier writers have described it under the title of chronic erysipelas, or erythema migrans. Rosenbach designated the condition erysipeloid, a name which has been accepted by the profession.

It commonly has its origin in some slight wound, and is most often seen in those handling fish and oysters or cheese and herring. Therefore, it is found among fishermen, butchers, cooks, etc. Gilchrist has described his findings in over 300 cases which originated in crab bites. He thought the condition was due to a ferment injected by the crab bite, and not to a special organism. Rosenbach described a cladothrix-like organism as the cause, and this finding was later confirmed by Ohlemann. It is an irregular round organism, developing into threads in old cultures. Pathologically one finds an invasion of the corium with polynuclear leukocytes and a massing of lymphoid cells about the bloodvessels.

Symptoms.—Following a slight injury, generally upon the fingers, the skin becomes swollen, painful, and of a deep bluish color. There is some local burning and itching, but no fever or any general reaction. The infection extends gradually with a sharp line of demarcation up the finger into the hand rarely as high as the middle, but it may involve the adjacent fingers. As it extends, the older area becomes pale. A lymphangitis of a very resistant type may develop. There are no papules, vesicles, or suppuration. The disease lasts from one to four weeks, varying with the treatment.

Treatment.—Lexer advises immobilization by a splint for from two to four days, accompanied by applica-

tions of vaseline. If movement begins too early, the trouble will reappear. Others recommend 25 per cent. salicylic acid ointment followed by a bland oil.

GAS BACILLUS INFECTION

Under this title many conditions are included which have in past years been described by many titles, such as gaseous phlegmon, emphysematous gangrene, malignant edema, etc. It is probable that there are at least two distinct types here included, if not more; namely, infection by the bacillus of malignant edema and that by the *Bacillus aërogenes capsulatus*. Other bacteria may produce gas, and thus come under this classification.

While we may thus separate them etiologically, clinically we must consider them as one, since we cannot be certain when making smears at the operation with which type we are dealing. We are wont to say that the more serious type is probably due to the bacillus of malignant edema, and the milder type to the *Bacillus aërogenes capsulatus*. We cannot be certain of this, however, and for the purpose of treatment must divide them into fulminating and subacute, and base our treatment upon this without regard to the organism present.

The condition is characterized pathologically by a rapidly spreading inflammation associated with the formation of gas, the presence of which is denoted by the crepitation found on palpation characteristic of emphysema elsewhere. In the milder cases, locally, one finds a moderate degree of serum between the muscular bodies and in the subcutaneous tissue associated with gas. Systemically, one finds the changes of a moderate toxemia. In the severe cases we find a diffuse, watery, semibloody edema of marked degree,

going on even to necrosis of tissue with gas bubbles throughout. There is an absence of phagocytosis. Gas bubbles may be found disseminated in the blood stream. An excessive amount of gas speaks for an infection by the *Bacillus aërogenes capsulatus* rather than one by the bacillus of malignant edema. The finding of a mixed infection with streptococci and staphylococci is not uncommon.

The infection may begin with the slightest wound, but more often it is found with severe injuries in which dirt has been ground into the tissues. It has been my fortune to see three cases in the arm, two of which began from very insignificant injuries, and the third followed a compound fracture of a finger.

The accompanying table, which may be found of aid in differentiating the various organisms obtained by smear or culture in these cases, was prepared for me by Dr. W. H. Buhlig. It is designed to differentiate not alone the virulent organisms, but also to separate these from the non-pathogenic organisms with which they may be confused.

In the milder cases the systemic evidences of toxemia are not marked. The local swelling is frequently very great, however, and one elicits the sense of crepitation under the palpating finger. The history is that of a wound received twenty-four to forty-eight hours before. The arm is reddened and the swelling is increasing rapidly. Upon incision, free fluid, non-bloody, is seen, and from between the blanched muscles the gas-laden serum can be evacuated. Following free opening the extension stops.

In the severer type the evidences of systemic intoxication are marked. The restless roving eye, the nervous movements of the body and hands, the parched tongue, cold perspiring brow, scanty high-colored urine, and running pulse are evident.

Organism.	Anthrax.	Malignant edema.	B. aërogenes capsulatus (B. Welchii).	Tetanus.	B. subtilis.
Chains.	Chains; often very long on culture media.	Usually in pairs. May be in chains.	Occasionally. Usually single from animal.	Usually single. Chains only in old cultures.	Yes. Often very long on media.
Ends.	Rounded when single, as from tissues; but square when in chains.	Rounded.	Rounded or square cut.	Rounded.	Slightly rounded.
Spores.	In some cultures. There are non-spore bearing species.	Yes. In middle of bacillus, rarely near end.	In some cultures. Some species make spores more readily than others.	Spores on one end give characteristic drumstick or pin appearance.	Abundant in cultures grown in aerobic condition.
Motile.	No.	Yes.	No.	Yes.	Yes.
Flagellæ.	No.	Lateral.	No.	Yes.	Yes.
Capsule.	Yes.	No.	Yes.	No.	No.
Shape.	Bacillus; rod; see size.	Bacillus. Spores in central part of bacillus bulge sides of organism.	Straight or slightly curved rods.	Slender rods, rounded ends. See "spore."	Thick, short rods.
Gram stain.	Positive.	Negative usually.	Positive.	Positive.	Positive.
Size.	1 to 1.25 μ by 2 or 3 to 20 μ .	0.8 to 1 μ by 2 to 10 μ .	Somewhat thicker than anthrax and varying in length.	0.5 to 0.8 μ by 2 to 4 μ .	0.8 to 1.2 μ by 1.5 to 3 μ .
Animal experiment.	Subcutaneous injection. Laboratory animals die in 48 to 72 hours of bacteraemia. From all organs bacilli may be recovered on direct smear.	Subcutaneous injection in laboratory animals gives extensive hemorrhagic edema of subcutaneous tissue.	Rabbit injected intravenously and killed after 10 minutes' interval and incubated 24 hours gives characteristic generalized gas formation in all tissues. Organisms easily recovered from this animal.	Pure culture or material from wound gives tetanus after 1 to 3 days. Mice and guinea-pigs most susceptible. Hemorrhagic at site of injection.	Non-pathogenic
Cultures.	Grows readily and rapidly on all ordinary culture media under aerobic conditions.	Strict anaërobe.	Strict anaërobe.	Strict anaërobe.	Grows readily on all media. Aëroë.

Locally the evidences of severe infection are marked. While the gaseous crepitation may not be any more marked, and, indeed, it is often less so, yet to it is added the livid or blackish color suggestive of impending gangrene; the epidermis may be raised in blebs filled with a dark bloody fluid, the skin is hard, and incision evacuates a reddish or brownish fluid, foul-smelling, and, as a rule, containing gas. The muscles may begin to show the evidence of oncoming gangrene, while the subcutaneous and intermuscular tissue may have already become necrotic. The process continues to spread rapidly in spite of the incisions. The arm becomes gangrenous and the patient rapidly succumbs to the toxemia, sometimes in from four to five days.

The prognosis depends upon the type and the promptness of treatment. As our experience grows it is probable that we will be enabled to apply the proper treatment earlier, and in certain cases demand amputation more promptly, and thus reduce the mortality, which now varies from 30 to 55 per cent. according to various authorities. Personally, of my three cases one recovered and two died. One of these two was seen too late for any hope of relief.

If we could but differentiate the types, clear indications for treatment could be placed. Unfortunately, this is not the case. The milder type of infection due to the *Bacillus aërogenes capsulatus* can often be cured by wide incisions draining every focus. This includes separating the muscular masses if necessary, washing out the areas with peroxide of hydrogen or oxygenated water, and inserting gauze drainage to prevent the collapse of the openings and thus giving the anaërobic bacteria an opportunity for further development. The cutaneous incisions should be extensive and left unsutured. If under this treatment there is any tendency to spread in the next twelve hours, amputation should

be advised. The same advice should be given in the more virulent type as shown by the local and systemic reaction. Here no time should be wasted in palliative measures, for the patient rapidly passes into the stage of systemic infection or toxemia, from which he will not recover even with amputation. One may say, therefore, that amputation should be performed in case of doubt. It should be done well proximal to the infection, so as to make incisions in healthy tissue, and the stump should be left open for secondary suture after we are certain that the process is under control.

My own experience in three cases bears out these statements. In the first case seen, amputation was performed at once and the patient recovered promptly. The gaseous infection had spread well into the arm. The amputation was performed at the upper third of the humerus. In the second case seen in consultation, wide incisions were made which were further increased upon the next day. The patient was not seen by me subsequent to the first day. I am informed, however, that the gaseous infections subsided, and a secondary infection began from which the patient succumbed at the end of three weeks. The third case seen by me was one in which the patient had suffered a slight abrasion of the middle finger of the left hand. I saw him at the end of the fifth day when the systemic condition showed the patient to be suffering from a marked toxemia. The whole arm has a bluish-black color, is swollen, and covered by blebs. The arm was amputated by an able surgeon at once, but the patient succumbed from his toxemia within a few hours.

ANTHRAX

Anthrax is not common in the United States, although sporadically it may appear in various sections. The frequency of lesions upon the hand and arm is

given by Koch in a series of 923 cases as 40 per cent. Keen has described a typical case in the *Annals of Surgery* of August, 1905. Personally, my experience is limited to one case seen during my internship at the Cook County Hospital. The description of the condition which I append is modified from that given in Frazier's excellent description of the disease. No attention, of course, is here given to the pulmonary and intestinal types. When the disease is implanted upon the hand or forearm of those having to deal with hides and other sources of infection, we note an elevated pustule, 5 mm. to several centimeters in diameter, with a depressed central scab. The corium and papillary body become infiltrated with a serocellular exudate and with bacilli. The perivascular and connective-tissue spaces become filled with leukocytes, and the pressure of this serous and cellular infiltrate, together with the toxins of the bacteria, cause the central coagulation necrosis, though suppuration does not occur unless there is a mixed infection. When the serocellular exudate extends upward to the superficial epithelium, it elevates the latter and produces the typical vesiculation. In the edematous variety the swelling is due to the diffuse serocellular infiltrate and to the effect of the bacteria blocking or inducing coagulation in the capillary vessels.

The lesion may be transferred to other parts of the arm or body, especially the face, by scratching the lesion and then the secondarily infected part. Wherever the lesion occurs we note that from a few hours to some days after the inoculation some itching and burning are felt, and upon inspection a small papule with a central bluish point is seen. A few hours later the papule becomes vesiculated, contains a brownish, sanguineous fluid, and may be scratched off by the patient. The surrounding tissues become red, indurated, and puffy, and later purplish and gangrenous

in appearance, although there may be no indication of suppuration. Pain now ceases, and beyond malaise, nausea, slight fever, and muscular or joint pains, there may be no other constitutional effect. A vesicular areola limited in extent is soon observed about the pustule, containing serohemorrhagic fluid; the pustule may undergo necrosis, the area of necrosis rarely exceeding 3 cm. in diameter. In about ten days, in favorable cases, a line of demarcation forms about the eschar, which "floats off," leaving a defect to heal by granulation. In more severe cases the edematous swelling about the pustule may be very extensive and erysipelatous in appearance, associated with a lymphangitis and lymphadenitis with hard and tender lymph nodes. The vesicles become bullæ, contain a bloody fluid, and the ultimate suppurative and gangrenous process may involve areas as large as the entire half of the face. In these severe cases the constitutional symptoms are marked, resembling those of cholera, with great prostration and depression, a weak, rapid pulse, often icterus, diarrhea, delirium, and coma.

In the parts where there is considerable loose areolar tissue, as the eyelids, neck, and forearm, great edema may be seen. Here, instead of the characteristic changes described above, the area may have a well-defined border without vesiculation, redness, or gangrene. There may be little or no pain, even in those cases ending fatally.

The diagnosis must be made from the furuncles and carbuncles. The careful surgeon will at once note that the lesion is essentially different from these, and will by smears and culture determine the presence of the anthrax bacillus.

The statistics as to the mortality vary greatly, being from 6 to 30 per cent. Koch collected 1413 published cases, with a mortality of 32 per cent.

Frazier summarizes the treatment as follows:

To judge from the experience of those who are most qualified to speak, the treatment of anthrax should consist essentially in the administration of Sclavo's serum, in the excision of the pustule, and in the application of certain bactericidal agents. The serum should be administered subcutaneously and the pustule should be excised only when the surrounding tissues are not very edematous, taking the precaution to cauterize the exposed surfaces with carbolic acid or the actual cautery. If the edema is marked, absolute rest of the part should be enjoined and local hot antiseptic fomentations, such as bichloride of mercury, applied. The serum has no deleterious effects, and in the hands of its originator and others, especially in Italy and England, the results substantiate the claims which have been made. It assists in the destruction of the bacilli, before they become so numerous that their destruction by the bodily defences increases the danger of fatal poisoning from the toxins set free by the disintegration of the bacilli. When the serum cannot be obtained, and when excision is impracticable, injections of carbolic acid (5 per cent.) should be tried, introducing the needle at several points along the margin of the pustule and infiltrating the base of the pustule and surrounding healthy tissue. These injections may be repeated frequently. The constitutional symptoms must be met by appropriate and supportive measures.

It has been my fortune to meet with only one case of anthrax. That occurred in a man, aged thirty-five years, who worked in the Chicago stockyards. He applied at the Cook County Hospital for treatment, and I regret to say that the records of the case cannot be secured at the present time. The lesion was upon the left forearm and presented the characteristic gangrenous centre. He was treated by local antiseptics and made a prompt recovery.

SECTION V

COMPLICATIONS AND SEQUELÆ OF INFECTIONS OF THE HAND

CHAPTER XXVI

FOREARM INVOLVEMENT FROM INFECTIONS OF THE HAND—PATHOLOGY AND DIAGNOSIS

FOREARM involvement occurs in two forms—that associated with lymphangitis and that following tendon-sheath infection of the flexor tendons and abscesses in the palm. These two forms have been touched upon in general in discussing these infections in the preceding chapters. The pathology and localization is essentially different, as it arises from the two sources. I refer, of course, to suppurative involvement, and have no reference to the edema which always occurs with any infection. At the risk of some repetition, I shall review the subject in general, so as to give a composite picture.

SUBCUTANEOUS ABSCESSSES

That form due to lymphatic involvement of superficial origin has been referred to on page 318. We may have a secondary involvement upon both the flexor and extensor surfaces. Upon the flexor surface we find a localization just above the annular ligament in many cases of deep infection of the hands, particularly those cases showing an ulnar bursitis. They are character-

ized by redness and slight induration over an area two or three inches in length at the lower end of the forearm. The diagnosis is not difficult, the only thing to be borne in mind being that the surgeon should understand its origin and should not desist from dealing with the extension under the tendons from a rupture of its synovial sheath, since there is no connection between these pockets, and draining the superficial pocket does not drain the deeper and more important focus.

Besides this well-differentiated localization, small foci may develop along the lines of any lymphatic, either on the flexor or dorsal surface. Care should be taken not to mistake these uncommon localizations for the acute non-suppurative inflammation of the lacunæ (see p. 319). Again, localizations may take place about the glands of the epitrochlear region, as has been described in Chapter XX.

The most important subcutaneous accumulation associated with lymphatic infection occurs upon the dorsum of the forearm. This condition, characterized by a brawny induration of the entire dorsum, with necrosis and sloughing of the subcutaneous tissue, is one of the gravest complications met with in hand infections. A full discussion may be found in Chapters XX and XXI.

DEEP ABSCESSSES

The deep involvement, no matter what the origin, almost always is found upon the flexor surface. This most commonly arises through extension by rupture of the proximal end of the ulnar or radial bursæ or by extension from a palmar abscess. This is by all odds the most important question we have to deal with when considering forearm involvement. It will be discussed under three heads:

1. Cases showing forearm abscesses without other complications.
2. Cases showing forearm involvement with carpal joint involvement.
3. Cases showing forearm involvement with secondary hemorrhage.

FOREARM INVOLVEMENT: ABSCESS FORMATION WITHOUT OTHER COMPLICATIONS

LOCATION OF THE ABSCESSSES.—It has been the habit of surgeons and writers dealing with this subject to speak of these abscesses in a general way only, and to suggest drainage through the volar surface between the tendons and muscles. In my earlier cases I was struck with the long convalescence, the repeated incisions, and the inadequate drainage owing to the rapid closure of the sinuses through the muscular bodies. Therefore a careful study of the anatomy of the forearm was undertaken both by dissection of serial sections and by experimental injections made through the various tendon sheaths and from other sites of predilection of pus in the hand. By this I determined the probable site of these secondary abscesses in the forearm. These experimental and anatomical deductions were verified by a study of all my cases showing this complication, as well as an extensive review of cases reported in the literature. The result was beyond expectation. The study enables the surgeon to prognosticate before operation the exact location of pus in the forearm. It suggested new sites for drainage which cured cases in from one to two weeks by two, or at most three, primary incisions, which by the older procedures would have required from three to five weeks, with the probability of many complications.

The anatomical and experimental work I have detailed in Chapter X. It remains for me, therefore, to

adduce the clinical proof of its correctness and suggest plans of treatment. It will be seen, by referring to Chapter X, that the final deduction made from the researches was that the important space in which pus would be found in those cases where the infection originated in the hand had the following boundaries: It lies under the flexor profundus digitorum tendons and muscle. About three inches up on the forearm the pus begins to invade the intermuscular septa, passing first to the area about the median nerve and later to the area about the ulnar artery and nerve. Here it lies between the flexor carpi ulnaris and the flexor profundus. This is about four inches up on the forearm. From here it may pass toward the elbow along the vessels and nerves, particularly the median nerve, or more commonly it may extend distally along the ulnar artery under the flexor carpi ulnaris and appear subcutaneously about three inches up on the ulnar side. It may extend downward along the radial artery, but this is certainly an uncommon termination. The largest part of the space is about two inches above the wrist. Its most superficial parts are on either side just volar to the ulna and radius. The floor of the space is made up by the pronator quadratus at the wrist and the interosseous septum above. The space may hold a half-pint or more of fluid. No other well-defined space is present except that comprising the subcutaneous tissue.

In corroboration of this statement, I shall report in brief cases that have come under my observation, and shall add a few from the reports of Tornier and Forssell to show that my deductions are unbiassed. That there may be no question as to the possibility of the infection having arisen sequentially from a carpal-joint involvement, those cases will be excluded and only uncomplicated forearm involvement discussed. Altogether I have now had 26 cases showing this extension. The

report of the postmortem in Case XXII may also be noted in corroboration.

CASE XXV.—The ulnar bursa was opened and incision extended to the middle of the forearm which exposed an abscess lying mainly under the flexor profundus digitorum.

CASE XXVI.—The flexor side of the forearm was swollen and painful to the upper third, incision was continued from the ulnar bursa on the forearm toward the centre. In juxtaposition to the nerves and blood-vessels a pocket of pus was evacuated, which extended between the flexor sublimis digitorum and the flexor profundus digitorum, and lying on the interosseous membrane of the upper half of the forearm.

CASE XXVII.—The hand and forearm were swollen, incision was extended from the ulnar bursa in the forearm and the flexor muscles were separated by the handle of the scalpel. The abscess extended along the interosseous ligament to within a hand's breadth of the elbow.

CASE XXVIII.—Incision was made opening the sheath of the flexor longus pollicis and up to the annular ligament; a second incision was made into the same sheath above the annular ligament, and this was extended along the lower half of the forearm over the radial sources of the flexor sublimis digitorum. Pus was found along the flexor longus pollicis and behind the flexor profundus digitorum in the lower third of the forearm.

CASE XXIX.—A large amount of pus was shown in the lower two-thirds of the forearm lying between the flexor sublimis digitorum and the flexor carpi ulnaris, below the flexor profundus, which was entirely evacuated by a single incision upon the ulnar side above the wrist-joint.

In the following case there was a neglected tendon

sheath infection on the dorsum. These cases are extremely uncommon, since they are generally only local abscesses without extension.

CASE XXX.—An infection extended upon the back of the forearm; after two superficial abscesses had been opened, it was noted some days later that there was a painful swelling on the dorsal ulnar side of the forearm; this was incised as far as the fascia without freeing any pus. A pocket was found, however, under the dorsal annular ligament extending into the otherwise healthy muscle above.

CASE XXXI (Forssell).—A large incision was made on the middle of the forearm down to the palm, cutting the anterior annular ligament and part of the palmar aponeurosis, a large abscess was found in the palm and under the annular ligament and in the forearm lying between the ulnar muscles and the flexor profundus digitorum. The tendon sheaths were entirely intact.

CASE XXXII (Forssell).—About a week after the primary injury there was an increase of pain in the arm, which became red, sensitive, and swollen. After four or five days pus was forced out by pressure on the forearm, a 7 cm. cut was made above the wrist through the skin, followed by a blunt dissection to the tendon sheaths, from which thin pus was evacuated, drain was inserted through this opening under the annular ligament out through the hand.

On the ulnar side of the forearm an incision was made, 15 cm. long, carried down between the flexor profundus digitorum and the flexor carpi ulnaris; pus was met with here and the tendons of the flexor profundus digitorum were surrounded with pus in the lower three-fourths of the forearm.

CASE XXXIII (Tornier).—Two weeks after injury it was noticed that the entire arm was swollen, especially the forearm. On the same day the ulnar bursa

was opened, a large amount of pus was found, much burrowing behind the muscles of the forearm, and wide incisions were made here.

CASE XXXIV (Forssell).—The lower third of the forearm was swollen and tender, but the patient had no spontaneous pain. The ulnar bursa was opened throughout its length and the incision continued over the lower third of the forearm. This exposed an abscess lying on the interosseous membrane under the muscles. Counterincisions were made. Culture showed streptococcus.

CASE XXXV (Tornier).—Incision was made into the radial bursa and on the forearm extending on the radial side, exposing an abscess lying between the pronator radii teres and the flexor carpi radialis, behind the deep flexors.

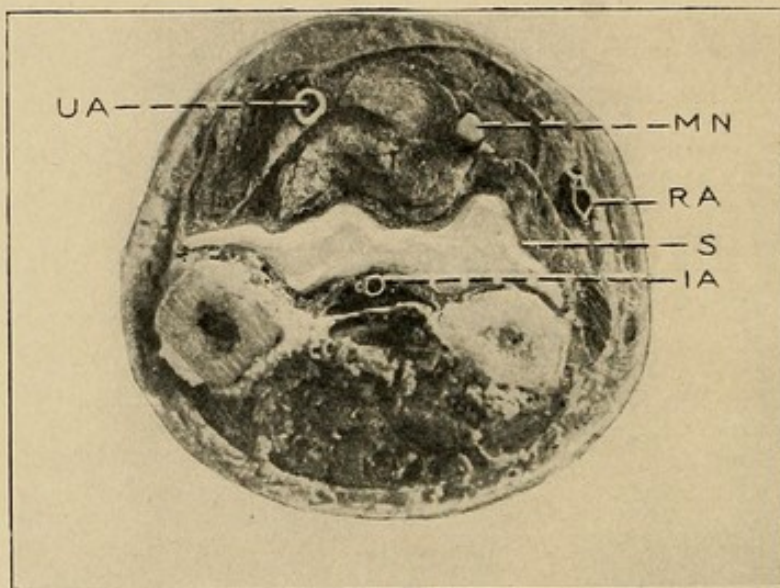
CASE XXXVI (Tornier).—Both bursæ opened, anterior annular ligament incised, large amount of thick yellowish-green pus was found in the lower part along the interosseous membrane.

From these studies it is certainly justified to outline the position of these secondary abscesses as we have. The position of the pus at a point one and one-half inches up on the forearm is shown in cross-section (Fig. 108), and also the position of the pus when it reaches the middle of the arm is shown in a second cross-section (Fig. 109).

SYMPTOMS, SIGNS, AND DIAGNOSIS.—The diagnosis of a forearm involvement is based on the knowledge of an associated tendon-sheath infection of the ulnar or radial bursæ or a middle palmar infection and the signs incident to the development of any deep abscess. Especially in an ulnar bursitis which has existed two or more days before drainage do we look for a beginning forearm involvement. In any case, we have the devel-

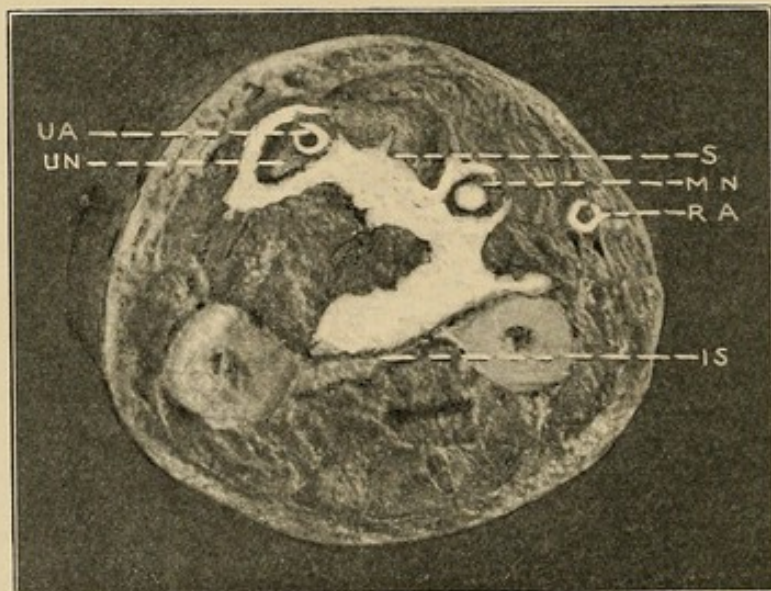
opment of increased swelling of the forearm. The swollen part has not the soft feeling incident to edema,

FIG. 108



Photograph of cross-section 7 cm. below the radial styloid, showing area filled with pus.

FIG. 109



Photograph of forearm just below the middle, showing position of pus in its relation to the ulnar artery and the median nerve.

but a full tense feeling as if the forearm were an over-distended bag. There may be but little increase in redness. The induration seen in subcutaneous ab-

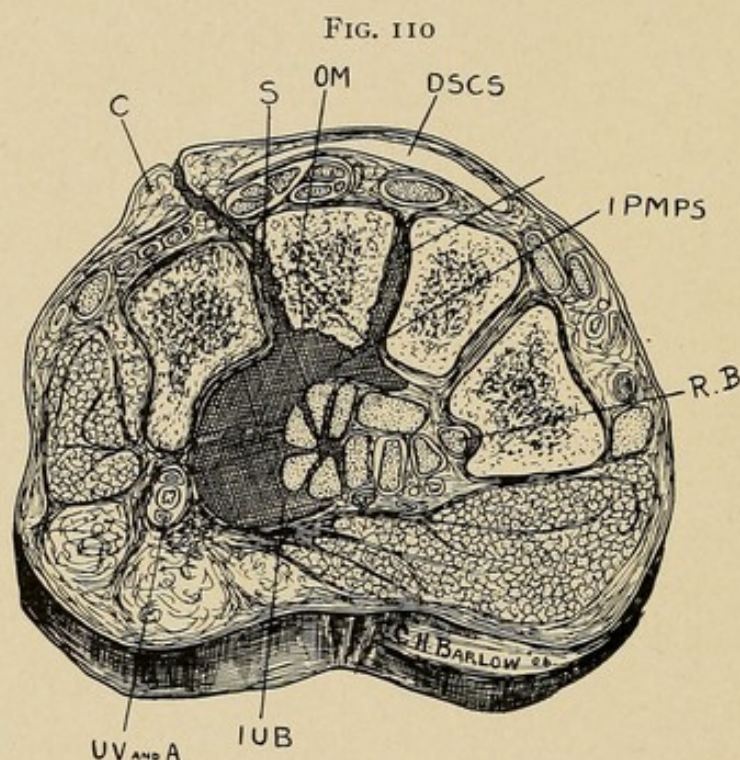
scesses will be absent. However, tenderness to deep pressure is increased. The wrist becomes more or less fixed and the careful observer has no difficulty in suggesting the diagnosis on the history of these findings. Of course, later, when the pus had infiltrated every part, even the novice can make the diagnosis. Early diagnosis is greatly to be desired, however. It should be urged that in case of doubt incision may be made after the manner already suggested, by lateral incisions, without in any way jeopardizing the patient's forearm. Whenever I open an ulnar or radial bursa, and there is any question in my mind as to forearm involvement, the forearm incisions are made. Indeed, these same incisions may be used to drain the upper end of the sheaths in the forearm. So that the incisions thus serve two purposes—they drain the bursæ, and if pus is already in the forearm or develops subsequently, they afford it an immediate outlet.

DEEP FOREARM INVOLVEMENT ASSOCIATED WITH WRIST-JOINT INVASION

If operated upon early the involvement of the wrist-joint will be uncommon. In certain cases, however, it will be met with either early in the course or later as a complication. The wrist-joint involvement is a most serious complication, and it should be watched for, particularly in aged patients with involvement of the radial bursa (tendon sheath of the flexor longus pollicis). By reference to the cases it will be seen that of the 8 cases here reported, 7 were fifty-four years of age or older. It is to be noted particularly, however, that every case was one of involvement of the radial bursa, either alone or in conjunction with other foci. In 5, the primary process was in the thumb. One cannot help but feel that this is more than a coincidence; as

yet, however, no definite anatomical reason can be adduced to explain it. In none of my injections of this synovial sheath has the mass ruptured or extended into the wrist-joint.

EXAMINATION OF THE RADIAL BURSA IN CADAVERS.—To determine whether or not there is at times a normal opening connecting the radial bursa and the wrist-joint, with the assistance of Prof. P. T. Burns



Drawing showing intimate relation of the ulnar bursa to the os magnum and its early involvement. Notice the association of the radial bursa and the trapezium: *S*, sinus; *OM*, os magnum; *IPMPS*, infected process leading from middle palmar space; *IUB*, infected ulnar bursa; *RB*, radial bursa.

and Dr. A. T. Horn, of the Anatomical Department of the Northwestern University Medical College, I have examined 30 cadavers, and in no one of them have we found any normal opening, although Prof. Burns states that he has at times noted such a communication. This is borne out by other observers, but it must be extremely rare. According to Schwartz, the parietal layer of the ulnar bursa is attached to the

ligaments and periosteum of the carpal bones, particularly the unciform and os magnum. Forssell states that in cases of carpal involvement he has noted that the os magnum suffers the greatest destruction (Fig. 110).

PATHOLOGY FOUND IN SERIOUS WRIST-JOINT INVOLVEMENT.—Since my own experience with this condition is rare, I have been compelled to turn to the literature for reports of postmortems. Of my personal cases, 4 in number, all recovered. One case (Sable) is found in the chapter dealing with Osteomyelitis. Owing to the seriousness of this complication, one may be pardoned for making rather complete reports.

In the first case the position of the sinus openings on either side above the annular ligament at the site of the two vessels emphasizes the tendency of these abscesses to follow the vessels (see Experiment 47, where the only place the mass became subcutaneous was on the ulnar side just above the annular ligament). The absence of tenderness and pain about the necrotic joint is also worthy of note. The involvement of the radio-ulnar joint, as here noted, is a frequent complication.

CASE XXXVII (Bauchet).—Deep phlegmon of the right thumb; deep phlegmon of the hand; phlegmon of the forearm; fistulous processes; abundant suppuration. Great scar over the sacrum; septic infection. Death. Postmortem.

This man, between fifty-five and sixty years old, gives a history of an inflammation of the thumb two months before entrance. On the forearm there are two openings; one is at the inside and the other at the outside of the anterior surface; both are about 4 cm. from the radiocarpal joint. These two openings are longitudinal, about 2 cm. long, with edges grayish and fungous. At the level of the first phalanx of the

thumb one sees the scar of a former purulent focus. No redness; dorsal aspect of the hand shows no tumefaction; no sinuses. Tenderness to pressure is not very acute; the wrist is neither swollen nor painful. By pressing on the palm of the hand or on the lower part of the forearm, one causes a notable quantity of whitish, poorly mixed, fluid pus, without a bad odor, to flow out through the openings already mentioned. The probe introduced through these openings slides a considerable distance along the lower layers of the forearm, but meets no denuded portions of the bone.

Aside from the two openings already mentioned, one notes still farther inward, at the level of the upper third of the anterior surface, a small opening from which pus escapes, but in smaller quantity than from the other two openings.

By pressing the ulna, the radius, and at the same time trying to make the patient move the wrist, one notes a grating between the ulna and the radius and between these bones and those of the wrist, which resembles nothing more than two nuts being rubbed together.

Diagnosis.—Deep whitlow of the thumb; extension of inflammation into the great common synovial sheath of the tendon of the little finger; rupture of the focus between the muscular layers of the forearm, but more especially of the deeper part; extension of the suppuration to the carpal joints; necrosis of the bones.

Postmortem.—The tendons are fixed in an invariable position, and to free them it is necessary to cut out the resisting fibrous adhesions. These changes are evident in the palm of the hand, under the annular ligament, and the lower part of the forearm, all along the synovial sac. These changes extend to the ends of the tendons of the thumb and little finger. They stop slightly above the metacarpophalangeal joints of the

index, middle, and ring fingers. Along these fingers the synovial sheaths and the tendons are absolutely intact. The large focus, black and purulent, has an exit in the two openings before mentioned. At the upper and outer part it is closed, and the muscles of the forearm on this side are healthy. On the ulnar side, on the contrary, the fibrosynovial sac is frayed, and the pus has spread to the level of the upper part of the forearm, between the deep and superficial muscular layers. This purulent focus, formed by a rupture of the synovial sheath, has its exit in the smaller opening, which has already come under discussion.

The joints, radiocarpal, radio-ulnar, and carpal, are open anteriorly and communicate extensively with the palmar purulent focus, through several openings. The bones are neither red nor spotted nor crumbling. They are rather of an ivory-gray color and, in spots, blackish; there is no false membrane or generative abscess in the joint; but the cartilage has been destroyed, almost entirely resorbed, and has disappeared; the bones bared of this cartilage resemble bones which have been soaked in water for some time.

The following case, reported in the inaugural dissertation of Max Tornier, from the Griefswald Clinic (Prof. Helferich), emphasizes again the frequency of sinus openings in carpal involvement at the sites we have mentioned.

CASE XXXVIII.—Phlegmon of the forearm, involvement of carpal and radiocarpal joints.

Man, aged fifty-eight years. On the ulnar side of the wrist there is a sinus opening 4 cm. long, through which a probe reaches down into the wrist-joint. Under narcosis and anemia, Langenbeck's incision, the tendon of the long radial muscle, infiltrated with pus, was resected for about 8 cm. Resection of the proximal line of the carpal bones, between which small masses of

pus were found. Drainage established. Very dilatory course; the distal row of carpal bones sloughed through necrosis. An erysipelas with numerous abscesses on the forearm made further incisions necessary. When dismissed the incisions were healed; the wrist hung loose.

The following case from the same report shows the beneficial results of early and radical operation in the case of wrist-joint involvement, and shows the inadequacy of superficial incisions on the forearm.

CASE XXXIX.—Severe phlegmon of the hand and forearm; caries of carpal and radiocarpal joints.

Patient, aged sixty-three years. Two weeks after infection, incision over abscess on flexor and extensor sides of forearm. Two weeks later, second incision through the intermuscular spaces to the ligamentum interosseum. Iodoform drainage. No fever evenings.

The probe in the wound of the dorsal incision strikes carious bones of the wrist; it is pushed on in the direction of the dorsoradial incision to the wrist-joint. The latter is opened, and shows destruction of the cartilage and the bone. The joint is filled with pus. Resection of the navicular, semilunar, trapezium, and trapezoid. Good healing under Langenbeck's extension bandage. Good granulation. Daily massage. Patient dismissed for a few days and did not return.

Case XL, besides demonstrating the pathology of severe cases of carpal involvement and the extension of infection to this and the forearm, from the tendon sheaths, emphasizes the error that often occurs in mistaking for pus the enormous edema which is found upon the dorsum in these cases of palmar infections.

CASE XL (Forssell).—Suppuration of the radial and ulnar bursæ with involvement of the radio-ulnar, radiocarpal, and carpal joints and forearm.

J. L., aged fifty-four years. Woman. Pain in the left hand from no known reason; three days later visited

hospital. Seven days later, left hand (except for thumb and second and third phalanges of the other fingers) and to a certain extent the whole arm are swollen; pain over the whole back of hand, more in the palm, especially in the fourth interosseous space. Finger half bent; extension very painful. Temperature, 100.5° . Incision of the dorsum on the same day; little pus. Incision along the tendon sheaths of the first and fifth fingers; communication established between this and incision above the ligament. Also incision over the flexor carpi ulnaris, with communication with the last mentioned incision. Pus in large quantities from all the incisions.

Four weeks after onset of infection the tendons removed as far as they appeared infected. All carpal bones removed with a curette except the trapezium and the upper part of the third metacarpal bone.

Discharged after three months with ankylosis of the joint of the hand.

CASE XLI (Forssell).—Tenosynovitis of radial and ulnar bursæ, with involvement of the carpus.

G. K., aged sixty years, January 7, 1898. After a small wound at the end of the thumb, symptoms of tenosynovitis in the thumb and little finger. Same day, incision in the tendon sheath of the thumb.

January 8. The ulnar bursa was completely cleft; incision into the upper part of the radial bursa.

Aside from an insignificant necrosis of the thumb and little finger tendons, all went well until January 16, when symptoms of an infection of the wrist arose. These increased, and (January 18) necessitated an incision into the wrist-joint, a considerable serofibrinous secretion being found. Joint washed out with 1 per cent. sublimate solution. Gradually distinct formation of pus took place, which led to a partial resection of the wrist (February 5).

In the following case the decreased sensitiveness in the area of the distribution of the median nerve serves to emphasize the tendency of infection to spread along that nerve, as demonstrated in Experiment 47 and shown in Fig. 109.

CASE XLII (Forssell).—Tenosynovitis of the thumb and little and ulnar bursæ. Phlegmon of the forearm and articulation between hand and forearm.

S. T., aged thirty-three years, female. April 4, 1898. Distinct symptoms of suppuration of the carpal tendon sheaths (tendon sheath of the little finger intact) and on the forearm. Only slight pain on passive movements of the finger; "the finger twinges;" the same is true of palpation of the palm and the flexor side of the forearm. Complete opening of the ulnar bursa; by mistake the sheath of the little finger was opened; no pus; incision into the thumb; pus within and without the sheath.

April 11. Incision into the lower part of the forearm down to the ulna (burrowing of pus). For three days there have been symptoms of infection of the wrist-joint; pus pours from a small hole in the capsule between the pisiform and cuneiform. Around the tendon of the flexor longus pollicis there is much pus, wherefore an incision of the same is made; it was especially necrotic in the region of the carpal ligament; here there is also necrosis of other tendons.

April 12. Much pus in the wrist and upper arm. Several carpal bones removed under anesthetic.

April 16. Temperature, 102° to 105°. Amputation of the arm. Examination of the amputated arm; elbow-joint intact; all pus cavities opened except the suppurated tendon sheaths of the fourth and third fingers. Necrosis of all tendons at the anterior annular ligament; the condition of the median nerve was by mistake not investigated.

April 17. Exitus 12 M.

Epicrisis.—Worthy of notice was the decreased sensitiveness and pain in the median region, due probably to the compression of the nerve. The inflammation of the wrist was possibly due to the infection of the joint between the pisiform and the cuneiform; in the capsule of this joint a certain defect was noted, whether primary or secondary, still pointing to a certain weakness in the boundary of the canal toward the carpal canal.

In the subjoined case the wrist did not become involved until fifteen days after the beginning of the infection. In this case, as in many of the others reported here, there may be some question as to whether or not the incisions were made early enough and at the proper sites. Throughout the literature it is evident that surgeons have paid too little attention to the fascial pockets in which pus lies, confining their attention almost entirely to the tendon sheaths.

CASE XLIII.—Compound dislocation of thumb. Infection of radial and ulnar bursæ, resection of necrotic carpal bones.

C. E., aged fifty-eight years. A large quantity of grayish-yellow, thinly fluid pus was freed by opening the radial bursa. An incision which had been made on the volar side of the thumb lengthened, and the tendon cut out.

May 20. Complete splitting of the ulnar bursa and the tendon sheath of the little finger; in the bursa and the tendon sheath a yellowish fluid pus. No burrowing toward the forearm could be discovered. The swelling on the hand went down. On May 24 it is especially noted that there is no swelling around the wrist-joint. The superficial tendons of the little finger had become necrotic just below the carpal ligament, and those of the fourth finger as well showed beginning of necrosis here.

May 29. Temperature, 37.3° to 37.4° . Slight pain in the hand near the wound in the carpal region. Several tendons showed signs of necrosis. On the anterior side of the wrist, exposed bone (radius, carpal bone?) can be felt.

June 7. Temperature, 37.4° to 38.2° . Partial resection of the wrist-joint. Removal of the carpal bones except the trapezium and pisiform; unciform necrotic.

By these cases I have attempted to portray the pathology, symptomatology, and course of these forearm cases, complicated by wrist-joint involvement. The diagnosis of its occurrence depends upon the crepitation noted in the joint, associated with an increase of tenderness and swelling about the joint. It will be remembered that the original infection is upon the flexor surface. The swelling and tenderness are here. When the joint becomes involved the dorsum also partakes of this. Under normal conditions a depression is noted on the back of the wrist-joint to the radial side of the extensor communis tendons at the lower end of the radius. This marks the site of the radiocarpal articulation. When this fills with fluid the depression is replaced by a fluctuating swelling, and in case of doubt a needle can be inserted here and the contents of the joint aspirated for diagnostic purposes. This site is particularly indicated in doubtful cases, since, the original infection being upon the palmar side, there is not great danger of infecting the joint if it is not already involved.

FOREARM INVOLVEMENT WITH SECONDARY HEMORRHAGE

One of the most serious complications met with in the later stages of forearm involvement is that of

hemorrhage. The onset of a sudden, profuse hemorrhage in a patient who is unable to care for himself in the temporary absence of attendants may lead to an immediate lethal issue. The condition is especially dreaded, since the surgeon looks upon the condition as most difficult to handle, since he fears to undertake the dissection which he believes to be necessary to find the point of hemorrhage and ligate. He therefore temporizes with a bandaging of the arm and tamponade, only to be subjected to greater anxiety on account of a subsequent hemorrhage. It would seem that this complication may be successfully dealt with if the surgeon will only have in mind the following facts.

1. The vessel nearly always at fault is the ulnar.
2. The surgeon should not temporize, but cut down upon and ligate at once the bleeding vessel.

The reason for the involvement of the ulnar vessel is seen by examining the cross-sections (Figs. 53 to 57, and 107), in which it is shown that the pus early involves this vessel. The line of extension is along this vessel, both up toward the elbow and downward to the ulnar side of the forearm. The radial is well separated from the space in a majority of cases.

My statements do not depend alone upon my anatomical and experimental studies. Clinical proof in support of it can be adduced from my experience, and also from numerous cases reported in the literature. I will let two cases suffice for that: one that came under my observation, and one from the service of Prof. Velpeau in which a postmortem was performed. This latter is added for the further reason that the postmortem serves to give further corroboration to my statements as to the position of pus in these cases, a fact which cannot be definitely proved except by postmortem. My own case I shall report briefly.

CASE XLIV.—Mr. H. Referred to Dr. Richter at the Post-Graduate Hospital, with whom I saw the patient in consultation.

Ten days previous to the onset of the first hemorrhage the patient had suffered from a tendon-sheath infection of the ulnar and radial bursæ, with extension into the forearm. The infection had not been opened promptly, and even after the primary incisions the drainage from the forearm had not been satisfactory. Dr. Richter had made free drainage, but by that time the vitality of the vessel had been impaired. A sudden profuse hemorrhage occurred, which jeopardized the patient's life before it was discovered by the nurse. A constrictor about the arm and tamponade completely controlled the hemorrhage, and it was felt that it would not recur. However, two days later a second profuse hemorrhage occurred, and the ulnar vessel was cut down upon as soon as the patient had recovered from the severe shock. The source was found to be the ulnar, as had been prognosticated. It was ligated with catgut, and the patient made an uneventful recovery. Function in the hand, however, was impaired.

The history of the following case, made the more interesting by the personal attention of the eminent Prof. Velpeau, serves further to emphasize the possibility of hemorrhage from ulceration of the ulnar vessel. The presence of the fistulous tracts near the annular ligament suggested the necrosis of the carpal bones which was present, and the deep position of the pus in the forearm is worthy of note. The whole clinical picture was one of extensive involvement of the wrist-joint, deep phlegmon of the arm, and the infection of synovial sheaths which at a later day would in all probability have been relieved by operative procedure.

CASE XLV (Bauchet).—Whitlow of the left thumb caused by a prick of a needle; multiple abscesses produced by the spread along the synovial sheath to the wrist and forearm. Hospital gangrene complicating the abscesses of the wrist and following the tissues along the ulnar artery, severe hemorrhage, tamponade, tourniquet; gangrene of hand and forearm; amputation; danger of hospital gangrene in stump. Recovery.

Patient, aged fifty years, in the service of M. Velpeau, Charity Hospital; sick for two and one-half months; entered April 25, 1851; was dismissed August 13.

About two and one-half months ago the patient pricked the thumb of his left hand with a needle. There resulted a phlegmon of this finger which extended rapidly over the whole hand; abscesses formed on the palmar aspect of the finger and hand, some of which opened simultaneously and some of which were opened by a bistoury; the swelling persisted, and even spread through the entire thickness of the wrist and forearm, along the synovial sheath.

On the palmar face of the wrist one notes several sinus openings from which passes a purulent fluid, viscid, clear, and thready; by pressing the palmar surface from below up, one causes this liquid to flow back. These openings seem to communicate freely with the synovial sheaths of the flexor tendons of the fingers at the level of the wrist.

The inflammation spreading from the hand to the forearm along these channels is very intense, and presents the characteristics of a diffuse phlegmon. During the next seven weeks the patient was treated in an expectant manner.

June 20. Appearance of hospital gangrene. The openings on the palmar aspect of the wrist are larger, puffed up, mushroom-like, and forming a large projection showing a spongy, fungous, grayish aspect.

June 28. Growth of the wound, which now covers the whole palmar face of the wrist. Sinking of the mushroom-like elevation of flesh. All the tissues between the skin and the bones of the wrist are in a state of putrilage, and the flexor tendons are floating in this decomposed matter. These tendons are stripped of their sheath, exfoliated, and have lost their silvery appearance.

June 29. During the preceding night considerable hemorrhage from the ulnar artery.

After several days hospital gangrene developed in the hand, and Prof. Velpeau amputated at the upper third of the forearm. The patient then made a rapid recovery.

Pathological anatomy of the amputated member. A careful dissection permits one to ascertain that the ulceration involves only the ulnar artery; the central end of this artery is stopped by a blood clot. The radial artery in the gangrenous portion is filled with fibrinous clots.

Upon examining the other tissues, one notes at the level of the focus of the palmar abscess purulent trails which ascend the length of the forearm in the tendinous grooves, and the length of the aponeurotic sheaths of the muscles of the anterior aspect of the forearm, to the level at which the forearm was amputated. One notes, moreover, an infiltration of purulent fluid between these grooves and these aponeurotic sheaths. The connective tissue of the forearm is all infiltrated like lard. All the tissues of the hand are completely sphacelated, dead, and black.

From all the evidence, therefore, one is justified in assuming that in the ordinary case the hemorrhage arises from the ulnar artery, and proceeding after the manner suggested below when dealing with this complication.

CHAPTER XXVII

TREATMENT OF INVOLVEMENT OF THE FOREARM SECONDARY TO HAND INFECTIONS

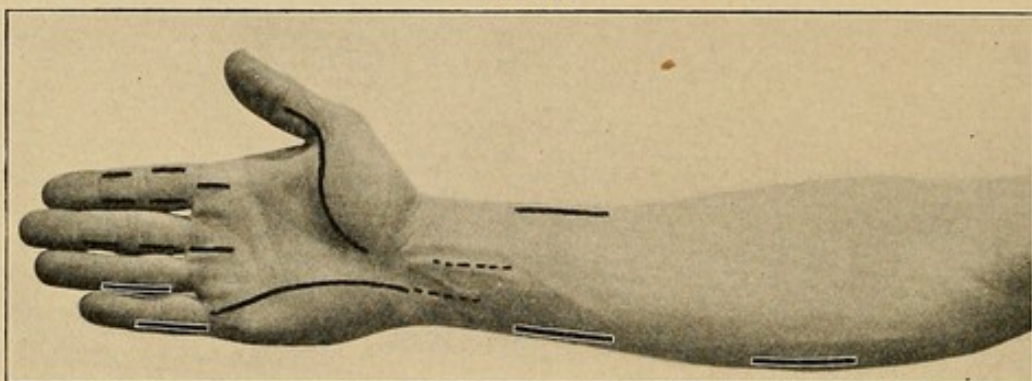
TREATMENT OF UNCOMPLICATED CASES

THE treatment of the subcutaneous abscesses secondary to lymphangitis has been discussed in Chapter XXIII.

In dealing with the deep forearm involvement, two methods may be used: (1) The older procedures by which the incision which opened the ulnar bursa may be continued upward into the forearm, cutting the anterior annular ligament (see p. 261 for full description of this method). This procedure, however, I personally have abandoned except in rare cases. (2) Following the anatomical studies described in previous chapters, I have used lateral incisions upon either side above the wrist (Fig. 111). In many cases only one has been used, that upon the ulnar side. By referring to the cross-sections and Figs. 106 and 107, the site of these incisions may be seen. I begin my incision about an inch above the styloid process of the ulna and carry it upward for about three inches, cutting down to the ulna on a level with its volar surface. The attachment of the deep fascia to the bone is separated and then the finger is inserted between the tendons and the pronator quadratus. A free opening is secured. If it is deemed wise to make a second incision upon the radial side, an artery forceps is passed across from the ulnar side (Fig. 112). The forceps should hug the radius

closely, and when the point impinges upon the skin of the radial side an incision is made through the skin for a distance of a couple of inches. The opening is

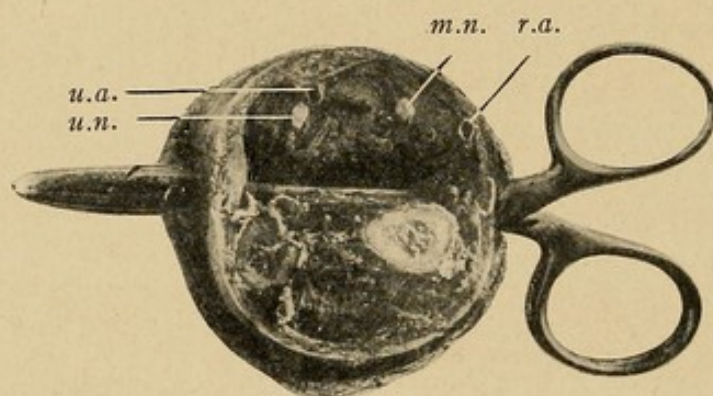
FIG. 111



Lines represent the various incisions made for drainage of the infected tendon sheaths and their possible extensions into the forearm. (See text for complete description.)

enlarged by separating the fascial attachment with the fingers. Any pockets between the tendons or muscles are widely opened by the palpating finger.

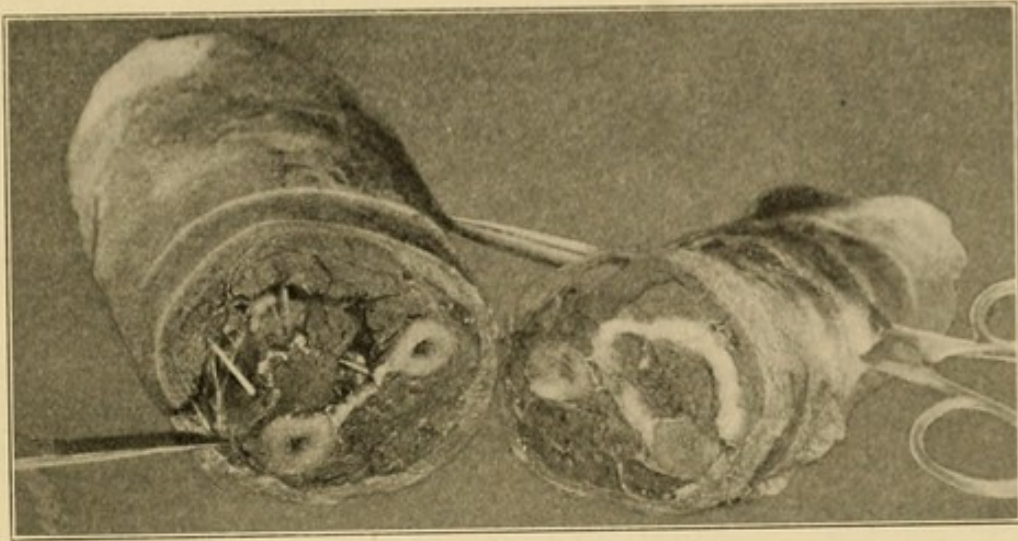
FIG. 112



Cross-section 7 cm. above radial styloid. Artery forceps inserted transversely in juxtaposition to ulna and radius through the anterior interosseous space, showing that incision can be made here and not injure important vessels and nerves. Notice tissue between radial artery and the forceps: *r. a.*, radial artery; *u. a.*, ulnar artery; *u. n.*, ulnar nerve; *m. n.*, median nerve.

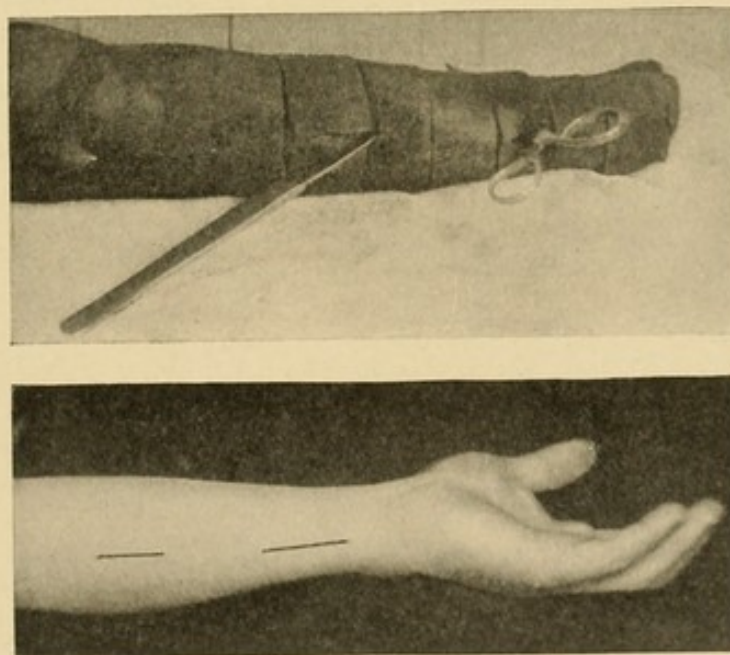
If the case has been opened late and the pus has infiltrated the forearm extensively, I commonly add an incision at a second site higher up, about the middle

FIG. 113



Cross-section of forearm at about its middle. The knife is seen to make an incision beyond the flexor carpi ulnaris and the flexor profundus, which incision should be made for pus in the middle of the forearm. (See Fig. 114.) Cotton packed in the opposing surface shows the position of pus.

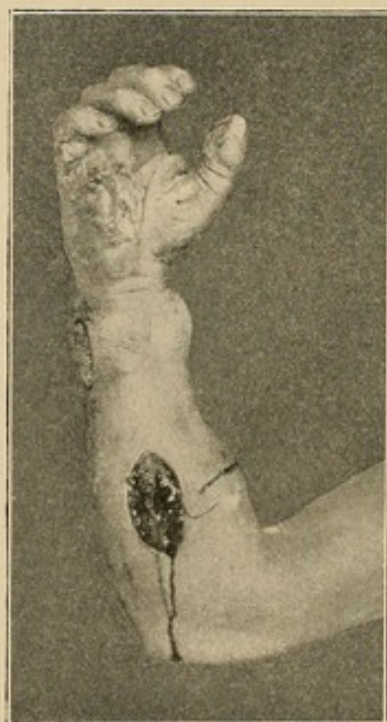FIG. 114



Photographs showing the proper incisions for draining abscesses in forearm. The photograph above is made of a cadaver arm in which serial sections were made and the proper sites for striking large cavities determined, the artery forceps being thrust through immediately above the wrist, and an ulnar incision being made at the middle of the forearm. The photograph below shows the sites of these two ulnar incisions.

of the forearm. Here one will see by examining the cross-section (Figs. 109 and 113) the pus tends to lie between the flexor carpi ulnaris and the flexor sublimis around the ulnar artery and nerve. Therefore an incision is made about one inch from the ulna on the flexor surface of the forearm, attempting to strike the area between these two muscular bodies (Figs. 113, 114,

FIG. 115

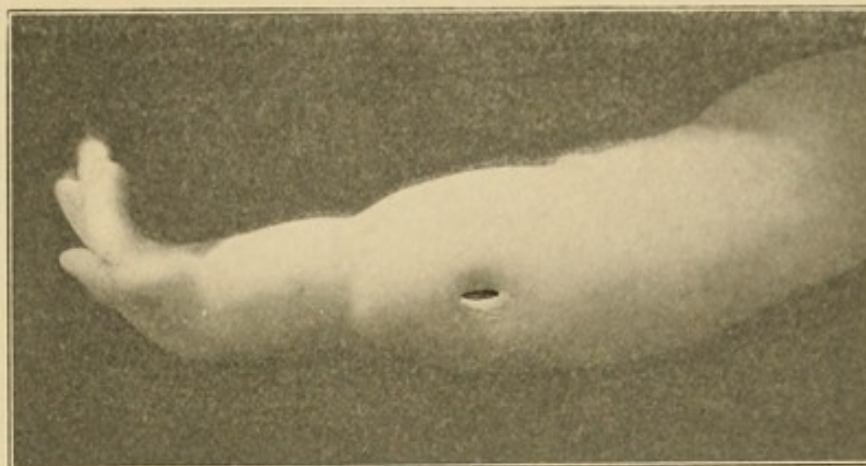


Photograph of a hand of a patient showing proper incisions for opening tendon-sheath infections of the thumb and little finger, with ulnar bursal extensions of pus in the forearm. This patient made a complete recovery with function and left the hospital at the end of one month. Function was complete at the end of three months.

and 115). The opening is separated widely by the forceps and fingers after the skin incision is made. Instead of this, one may cut down directly upon the flexor surface of the ulna and separate the fibrous attachment of the flexor carpi ulnaris from this bone, and in this manner separate the muscle from the flexor sublimis and profundus and thus drain the pockets.

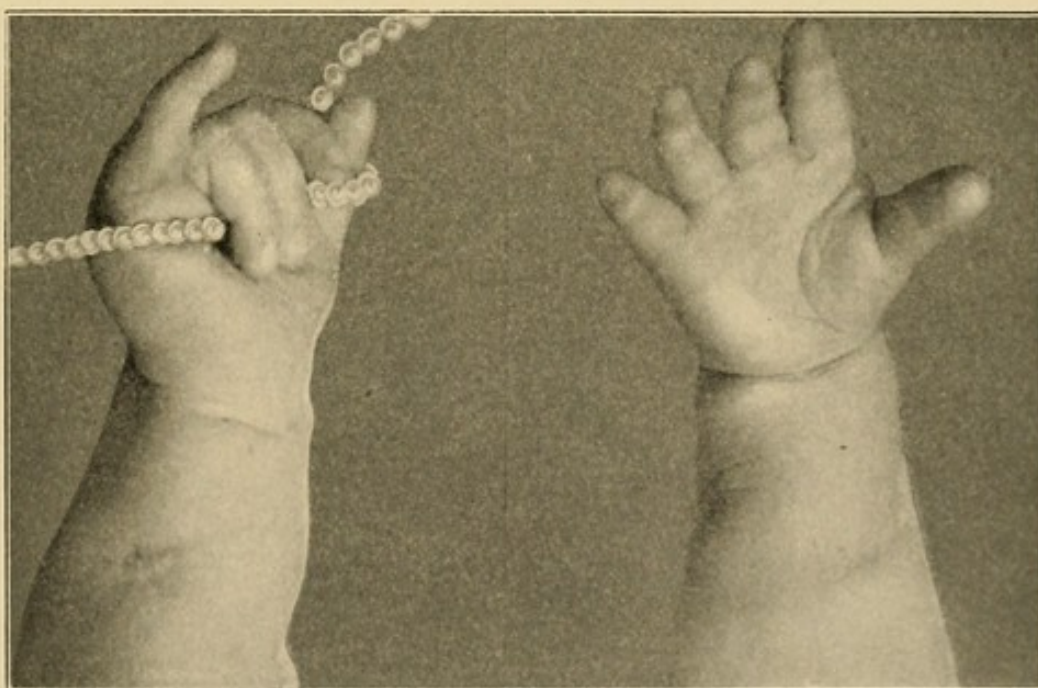
These are all the incisions that in my experience have been necessary to produce rapid cure in these cases. One

FIG. 116



Photograph of baby G.'s hand and forearm three days after incision was made for the drainage of an ulnar bursal infection with extension into the forearm. (See Case XLVI.)

FIG. 117



Result three months after (baby G.), showing extension and flexion of fingers. Perfect function restored except for two distal phalanges of the little finger.

should use care not to cut through any muscular body, since drainage will be unsatisfactory. The incisions

should be free and may be kept open from twenty-four to forty-eight hours by gutta-percha strips or vaseline saturated gauze. Even in very young individuals this treatment is most satisfactory. My youngest case of ulnar bursitis and forearm involvement was in a child (Case XLVI, Figs. 116 and 117, p. 409), whose photograph I here present.

CASE XLVI.—Wesley Hospital. The child was three months old when it was treated and six months old when the second photographs were taken. There was absolutely no impairment of function in any of the joints or muscles except the little finger, in which it lost the power of flexion, as will be seen by examining the photographs. Owing to the age of the patient and the severity of the infection, the life of the patient was despaired of by the family physician. The child left the hospital at the end of the eighth day after the incision described above had been made.

TREATMENT IN CASES WHERE THE WRIST-JOINT IS INVOLVED

Besides the incisions suggested above for drainage of the forearm, especial considerations must be borne in mind when dealing with involvements of the carpal, carpometacarpal, or carporadial articulations. Owing to the frequently associated involvement of the radial bursa, this will generally have been opened, and in serious cases the necrotic tendon will have been removed. The fact that when this occurs the patient is generally of advanced age will emphasize the necessity of radical treatment rather than temporizing measures which might be justifiable in younger individuals. This holds true not alone for the resection of the tendon, but also as regards removal of the carpal bones. In every one of the several cases reported

above, in which the joint became involved, a resection of some or all the carpal bones was indicated. Even in younger individuals, unless prompt and radical incisions are made, associated with careful after-treatment, unfortunate sequelæ are likely to result. That it does not always ensue I am convinced by two cases which came under my observation, in which the joint made a recovery without necrosis of the bones, but here prompt drainage had been instituted. However, I cannot speak with authority upon this point, since, fortunately, my own experience with this serious sequela has been limited. A study of the anatomy suggests the cause of the tenacity of this infection and the rapidity with which it involves the entire joint. We note that, as described by Gray,¹ while there are four separate synovial sheaths, yet in reality the joint proper has only two, and, moreover, these two are so intimately associated that the least erosive action on the part of an infection lying in one would cause an extension to the other. Moreover, the removal of any of the more important carpal bones in the radiocarpal articulation will permit of immediate extension in the synovial spaces about the distal bones, as, for instance,

¹ Although all the authors agree in describing the radiocarpal synovial sac as isolated from the carpal, there is great variation in the description of the carpal sacs. Cunningham and Quain follow Allen Thompson, and, in addition to the radiocarpal and cuneiform-pisiform, describe one sac between the semilunar and cuneiform above and the os magnum and unciform below, another between the scaphoid above the trapezium and trapezoid below, these being separated from the carpometacarpal sac below, with a single sac between the trapezium and thumb metacarpal. Gerrish follows Testut, giving the same description with the exception that he divides the carpometacarpal between the middle and ring metacarpals into two. Joessel, on the other hand, shows a communication between the carpal and the metacarpocarpal on the radial side, with a separate sac for the metacarpocarpal of the ring and little finger metacarpals. Gray shows a general communication between the carpal and metacarpocarpal. This difference of opinion simply demonstrates that the communications vary in different individuals. In a surgical consideration we should expect a more or less free communication, consequently in this discussion I have followed Gray's classification.

in Case XXX we read: "Resected proximal line of carpal bones, later distal row of carpal bones sloughed." Consequently, in those cases where the infection is confined to the radiocarpal articulation we should attempt to remove the carious bone by the curette and give perfect drainage to the joint, with the hope of preventing extension to the carpal synovial sac. The probable involvement of the radio-ulnar synovial sac should be borne in mind, since it seems to be a frequent complication. The intimate relation of the ulnar sheath, as already pointed out, results in early and extensive involvement of the os magnum (Fig. 108).

Where the carpal synovial sheath is involved, however, we may remove any of the carpal bones with the exception of the cuneiform, semilunar, or scaphoid without danger of causing a spread to the radiocarpal joint.

The infection of the synovial sheath between the pisiform and cuneiform may spread to the carpal articulation, as in Case XLII. In relation to which Forssell quotes from Henle to the effect that anatomically there is frequently a communication between the two sheaths.

In no case of involvement of the wrist-joint, in which the diagnosis was delayed three weeks, did the patient escape without the removal of some of the bones of the joint. In other words, there was considerable erosion of the bones before the diagnosis was made. We are urged, therefore, to watch with especial care aged patients with involvement of the radial bursa and to open the joint at the first evidence of infection. I am convinced, however, that this complication should be a rare one in those cases submitted to early and radical treatment for infections of tendon sheaths and soft parts. Early in the course of joint involvement free incision will give great possibility of a cure without the necessity for resection. But should the indication

arise for curettage or removal of the carpal bones, it should be done thoroughly and completely along the lines suggested above.

TREATMENT IN CASES OF SECONDARY HEMORRHAGE

As has already been hinted in dealing with this subject, those cases showing hemorrhage should not be temporized with. As soon as the patient has recovered from the primary shock and before the temporary tamponade and constriction have been removed, the surgeon should make an incision over the ulnar vessel. To do this an incision should be made about the middle of the forearm on the ulnar side, as described above. The flexor carpi ulnaris is then drawn to the ulnar side and the artery searched for (see Fig. 111). The site of the hemorrhage should be sought and the vessel double ligated proximally and distally. Tamponade and clotting cannot be depended upon. Further hemorrhages are almost sure to occur and leave the patient in such serious condition that he may not survive the combined hemorrhage and infection.

CHAPTER XXVIII

SEQUELÆ OF INFECTIONS OF THE HAND

CHRONIC PROCESSES, OSTEOMYELITIS, ARTHRITIS, CONTRACTURES, AND ATROPHY

IN cases showing a long-continued suppuration, we ask ourselves what structures are involved which prolong the trouble, or why we have inefficient drainage. Frequently both factors are at work. By far the most frequent causes are osteomyelitis, arthritis, and necrosis of tendons.

Areas which were primarily poorly drained cavities are soon complicated by one of these factors. Suppurative arthritis seldom exists without concomitant osteomyelitis. Such cases frequently give a history of primary tenosynovitis, followed by osteomyelitis, ending in arthritis.

Involvement of the wrist-joint has been discussed in the previous chapter.

The pathology of these cases naturally varies with the tendency of the tissues to react to the particular germ which is the exciting cause, the length of time the process has existed, and the structure involved. Grossly the most important findings are the sinuses, which are an almost constant accompaniment of chronic disease. Here we note several types, and while there is a distinct difference between them, any system of classification is inadequate. We might say the osseous and connective-tissue types, or the acute, subacute, and chronic. While the pathology presents some justification for either system, yet the reactive resist-

ance of the individual and the kind of germ enter into the subject as varying factors; consequently only generalized statements can be made.

The chronic osseous type presents three pictures, varying with the bones involved: (1) Those cases where the terminal phalanx is the seat of osseous destruction; (2) where the finger proper is involved; (3) where the metacarpals and carpal bones are involved.

INVOLVEMENT OF THE FINGER PROPER

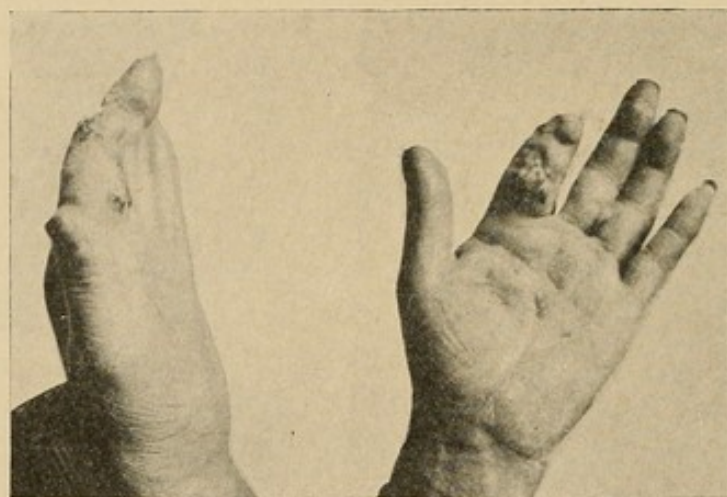Those cases (first group) showing chronic processes in the terminal phalanx have already been discussed in the chapter on Felons (Chapter II).

The second group of cases noted in the chronic osseous type is that which comprises suppurative processes of the proximal and middle phalanges. We all have had opportunity to observe that the proximal interphalangeal joint particularly may become involved early, either primarily or secondarily. In the case of the metacarpophalangeal-joint, however, there is more fibrous tissue intervening between the tendon sheath and the joint and the adjoining bone; therefore, the sheath erodes through at some less resistant point, as, for instance, at the proximal interphalangeal joint, in the course of the tendon over the proximal phalanx, or at its proximal end in the palm of the hand. Frequently I have seen a sinus lead from the proximal end of the sheath of a tendon through the palmar fascia, and the metacarpophalangeal joint still remain intact (Fig. 108). Again, the metacarpophalangeal joint is likely to escape in cases of palmar abscesses where the diaphysis of the metacarpal has become involved, or even when the process has been so severe as to extend under the annular ligament and invade the carpal articulation. It has been my experience in these cases

that the distal articulation frequently escapes even in long-continued synovial disease and extensive osteomyelitis.

In the ordinary case of chronic suppuration in the finger it is the proximal interphalangeal joint that is at fault, and the pathological condition noted in Fig. 119 is fairly typical. The constant irritating discharge coming from the necrosing bone, passing through the connective tissue rich in lymphatics,

FIG. 118

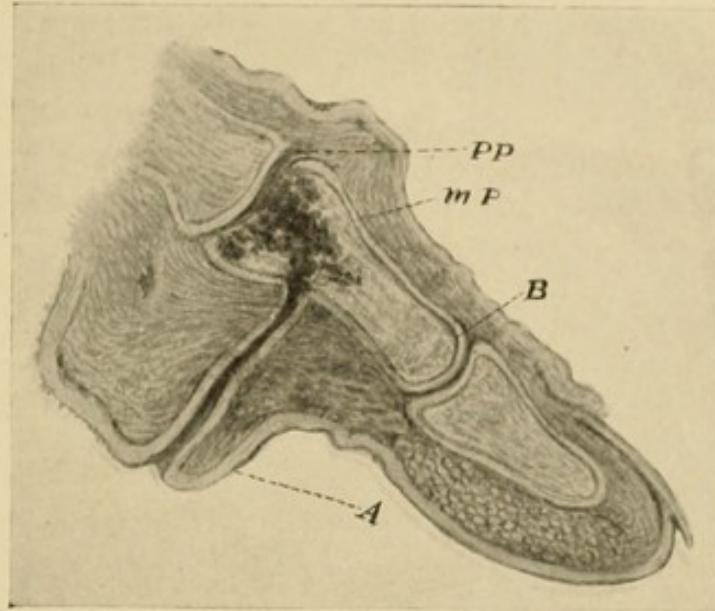


In this case the metacarpophalangeal joint was intact, although the tendon sheath was involved and a sinus had opened at its proximal end through the palmar fascia, all of the distal and part of the middle phalanx had been lost and the proximal interphalangeal joint was extensively destroyed.

produces an excessive deposit of granulation tissue, building up a small volcano-like structure, from which oozes forth a constant stream of pus, and through which winds a tortuous canal leading down to the necrotic bone. Where bone alone is involved, I have seen this crater clearly defined, occupying no greater extent than the length of one phalanx and raised above the surface for a distance half the diameter of the finger. This characteristic picture, however, is seldom seen, owing to the very frequent involvement of the tendon

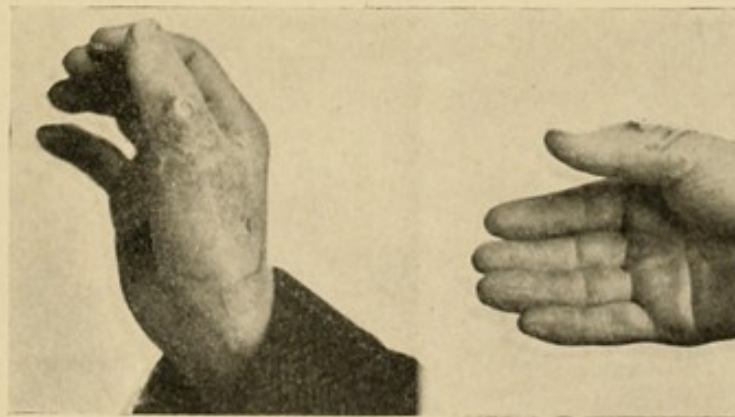
or the joint in the same process. Here, while the development of granulation tissue is still excessive, the

FIG. 119



Drawing from pathological section, showing sinus leading down to carious bone. An associated tenosynovitis has increased the extent of the granulation tissue and destroyed in part the typical volcano-like picture of an uncomplicated palmar bone sinus.

FIG. 120

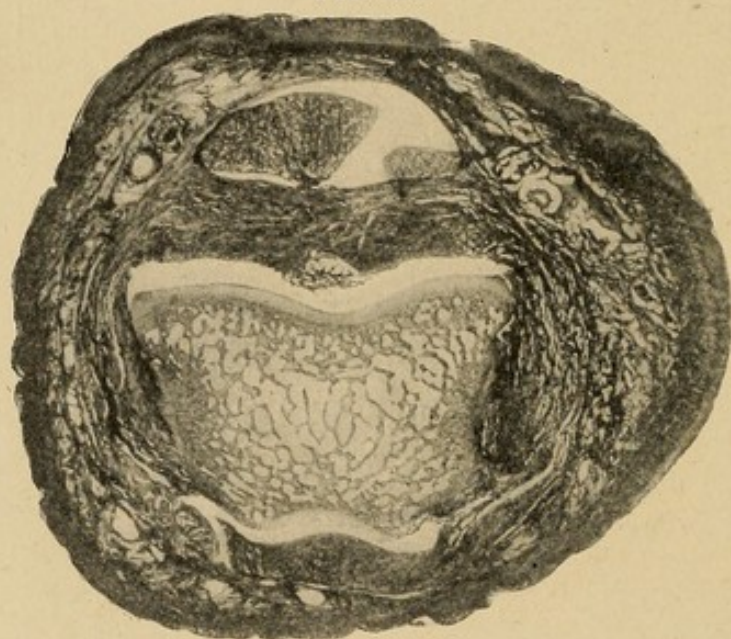


Uncomplicated bone sinus on dorsum of phalanx.

mouth of the crater is generally much wider, owing to the excessive discharge from the tendon sheath. The granulation tissue is not so circumscribed, although

very abundant. Moreover, the picture loses some of its force, owing to the associated swelling of the finger along the tendon sheath, the absence of which in the first case serves to accentuate the local tumor formation. Again, if the sinus be upon the dorsum there is less granulation formation, owing both to the smaller amount of connective tissue and probably also to the great reduction in the number of lymphatics (Fig. 120).

FIG. 121

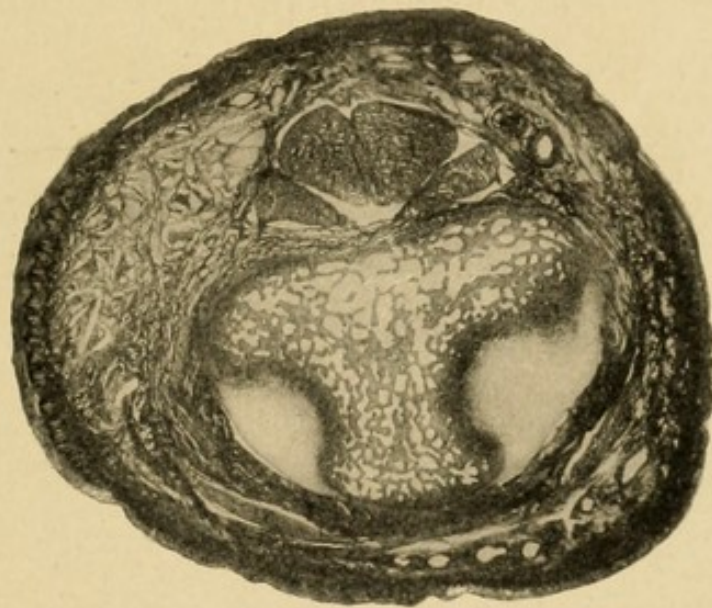


Cross-section through the joint, showing head of the proximal phalanx. Notice the large amount of tissue between the tendon and the joint cavity as compared to Fig. 122.

It is not necessary to go into the minute pathology of osseous necrosis, since that process is well known and described in the ordinary text-books. However, a few details peculiar to these two phalanges should be mentioned. We so often see three processes in conjunction, so that it is difficult to say in what sequence they developed—namely, tenosynovitis, arthritis of the proximal interphalangeal joint, and necrosis of the middle phalanx. The cross-sections here presented (Figs. 121 and 122) demonstrate the close proximity of the tendon sheath to the bone and joint respectively.

From the character of the tissue it would seem reasonable to assume that first the joint is involved, and the phalanx sequentially. In the few early cases that I have been able to observe discriminatingly, the joint seemed to have the more extensive involvement of the two. However, if that be true, why does the middle phalanx suffer so much more than the proximal one, a fact which I have had the opportunity to verify frequently. Is it that the point of invasion is the

FIG. 122



Cross-section through the epiphysis of the middle phalanx. Notice the loose mesh and the small amount of connective tissue between the tendon and the bone.

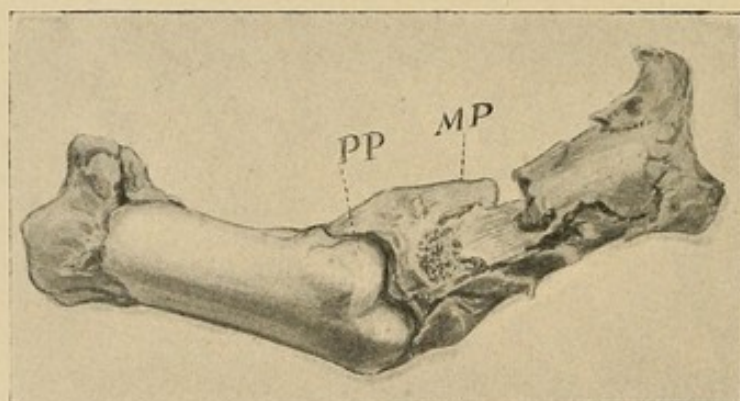
epiphysis of the middle phalanx? Does the fact that that phalanx only has an epiphysis articulating with the joint have any bearing on the subject? This question must be left for further study.

Again, destruction of the epiphysis is frequently noted, while the diaphysis is only partly involved (Fig. 119). The anatomical relation of the sheath of the tendon to the joint capsule and the epiphysis may help to explain this, but it is possible that the vascular nature of the epiphyseal tissue may have considerable

bearing, since the involvement may have its origin through the blood supply rather than by direct erosion. That isolated destruction of a diaphysis of a phalanx may occur at times cannot be questioned, and a study of the cross-sections demonstrates how easily this can occur if the tendon sheath be eroded.

What we most often find upon operation in these cases is a suppurative arthritis with extensive destruction of both the epiphysis and shaft of the middle phalanx, while the proximal surface of the joint, that is, the head of the proximal phalanx, may be only

FIG. 123



Drawing from a pathological specimen, showing destruction of the epiphysis of the middle phalanx, with pinhead-sized areas of the necrosis on the head of the proximal phalanx.

slightly or not at all eroded (Fig. 123); at least, the articular surface is still clear and shining, with possibly one or two minute foci of destruction. Frequently it has shown a larger area of necrosis upon the shaft just at the point where the ligaments of the joint are attached. Indeed, at times, either upon the volar or dorsal surface, varying with the site of the original infection, I have scooped out at this site an area the size of a small pea, the articular surface apparently being free, while the epiphysis of the middle phalanx was almost entirely destroyed.

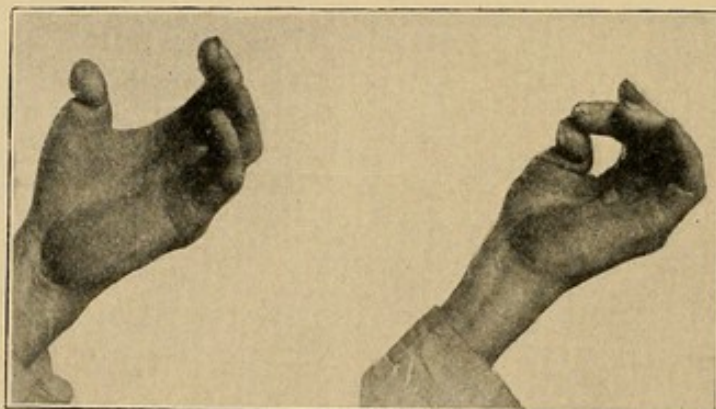
TREATMENT.—In the chronic processes involving the finger proper, the diagnosis must be made first as to the structure involved. If the tendon sheath, it must be opened throughout its extent to give perfect drainage. Frequently it will be necessary to remove the tendon in these chronic cases. The possibility of localized involvement must always be borne in mind. In these cases a plastic exudate forms and prevents extension along a sheath; here only so much of the sheath as has been involved should be exposed. If the joint be invaded, some judgment is called for, since in the very earliest stages it may recover with partial restoration of function if the infection is a mild one, the joint surfaces not destroyed, and other structures which might prolong the suppuration are uninvolved. In a great majority of the cases, however, considerable destruction of the proximal phalanx will have taken place when the case comes to operation, and the question arises whether an amputation should be advised. Certain sociological factors come into consideration. If the patient be a laboring man, with a family dependent upon him, and at examination we find an extensive destruction of the joint with a tenosynovitis, amputation offers the quickest method of giving a serviceable hand. If, however, the patient desires to preserve the finger, in a majority of the cases one can be assured that the finger may be preserved, but that it will be somewhat shortened. Exceptionally the finger may be preserved with considerable function. In certain cases it becomes imperative to make the attempt, as, for instance, in infections of the thumb. This member is so valuable that some sacrifice is justifiable in the attempt to preserve it. In Case XLVII, quoted below, the articular surfaces and a considerable portion of the shaft of the proximal phalanx were removed. There was no involvement of the tendon

sheath. A fairly serviceable opposing member was thus saved to the hand.

CASE XLVII.—Primary paronychia of thumb, secondary suppurative arthritis of interphalangeal joint, resection, ultimate recovery, with preservation of the thumb.

C. H., treated in the Northwestern University Medical School Dispensary, May, 1902. Infection began on the thumb under the nail at the side and developed into a typical "run-around." When he applied at the dispensary, four weeks after the begin-

FIG. 124

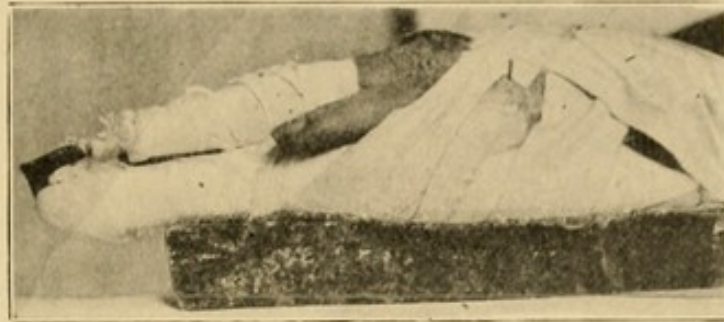

Photograph showing thumb in which joint has been resected. Notice the opposing ability of the member. (Case XLVII, Hamilton, reported above.)

ning of the infection, a chronic suppurative arthritis had developed, involving the interphalangeal joint. Under narcosis the epiphysis of the distal phalanx and about half of the distal portion of the proximal phalanx were found partially destroyed. All this involved bone was removed with a curette, the nail was removed, silkworm-gut drain inserted, hot boric dressings applied. The tendon sheath of the flexor longus pollicis was not involved. The patient returned repeatedly for dressings, and after four weeks all discharge ceased. The patient was discharged with the thumb shortened half

an inch, with ability to flex the distal phalanx 20 degrees, complete function in the metacarpophalangeal

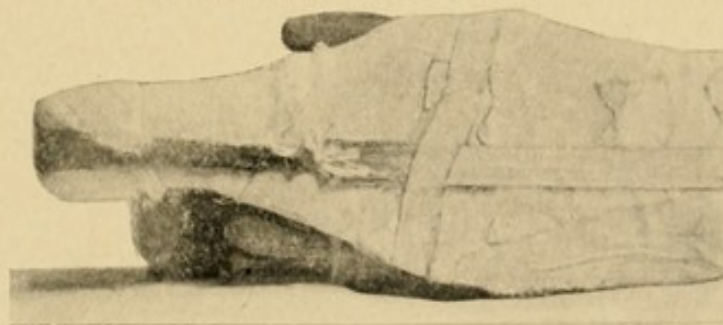
FIG. 125



A photograph of a finger with a chronic suppurative arthritis of the middle metacarpophalangeal joint, dressed in extension produced by an ordinary rubber band attached to the end of the finger by means of a string tied to it and the ends fastened through the eyes of a button, the latter being attached to the finger by narrow adhesive strips running around the finger up to the middle metacarpophalangeal joint—a gauze roller around the adhesive strips. Extension is secured by fastening the rubber band on the back by a piece of adhesive plaster, as shown in Fig. 126. The board splint on the palmar surface is prevented from being displaced up the arm or laterally by adhesive strips as shown in the figures. It is a modified Buck's extension. The relief from discomfort and rapid recovery under its use is often remarkable.

joint. There was little strength to the flexion of the distal phalanx, but it served admirably as an opposing member when using the fingers (Fig. 124).

FIG. 126. (See FIG. 125)



The procedure when the proximal interphalangeal joint of the fingers is involved is as follows: Owing to the frequent destruction of the proximal end of the middle phalanx, this is chosen for attack, and the entire

epiphysis and generally about half of the shaft is removed. If the articular surface of the proximal phalanx is intact, it is not disturbed, otherwise this may be removed also, my desire being in the first place to remove all necrotic bone, and secondly to separate the ends of the bone so far that only a fibrous union will take place, thus allowing some motion at this joint if the tendon is intact. Otherwise no motion can be promised. These fingers are dressed in slight flexion, so that if no function results they will not be in the way and will still be of some use, at least for cosmetic purposes. In some cases I have tried, with moderate success, a variety of extension on a straight splint. The proximal end is fastened at the wrist, and at the distal end, adhesive straps are fastened to the end of the splint and the distal portion of the finger, so that the ends of the necrotic bones are separated. The details of this mechanical contrivance may be seen by examining Figs. 125 and 126. This aids in preserving the functioning joint, although it is somewhat difficult to retain in position. Not much can be promised in the way of function in a majority of cases. That in exceptional cases these fingers can be saved with a moderate amount of function, even in some cases of combined suppurative arthritis and tenosynovitis, is demonstrated by Case XLVIII.

CASE XLVIII.—Limited tenosynovitis of index finger, arthritis of proximal interphalangeal joint, osteomyelitis of middle phalanx, resection of phalanx, recovery, with preservation of the finger and slight motion at the joint.

Miss C. W. Seen in consultation with Dr. C. E. Boddiger. Infection had begun in the index finger by a prick of a needle while sewing two weeks previously, and the soft parts had been opened over the middle phalanx.

Condition upon Examination.—Suppurative tenosynovitis of the index tendon extending to the metacarpophalangeal articulation, but no farther. Tendon exposed. Suppurative arthritis of the proximal interphalangeal joint, with destruction of the proximal end of the middle phalanx. Distal phalanx not involved, articular surface slightly clouded, but not eroded.

Operation.—Tendon sheath opened throughout extent of infected area. Middle phalanx resected to one-half its extent. Dorsal counterincision made at side for thorough drainage, and hot boric dressings applied.

Course.—After three weeks, the finger had entirely healed; flexion at metacarpophalangeal and distal phalangeal joints perfect; flexion at proximal interphalangeal joint 15 degrees. Six months after operation atrophy of soft tissues of distal and middle phalanges. The patient states that the finger is not of great service, but, on the other hand, is not in the way, and she is very glad, for cosmetic reasons, that it was saved.

Where there is only a destruction of the synovial covering of the joint, resection is not indicated. It is probable that a functioning joint can be restored in case of ankylosis if the tendon sheath is not involved, although I have not had the opportunity to demonstrate it. If the destruction of the adhesions by repeated flexion of the finger by passive motion, which I have used with more or less success at various times, does not succeed, the implantation of periosteum from the tibia, as suggested by Hoffman,¹ is worthy of consideration, or the transplantation of a pad of tissue and fat may be used with satisfaction.

Suppuration is uncommon in the metacarpopha-

¹ Arch. f. klin. Chir., vol. lxxx, No. 2, p. 311; Zur Behandlung der knöchernen Ankylose im Elbogengelenk.

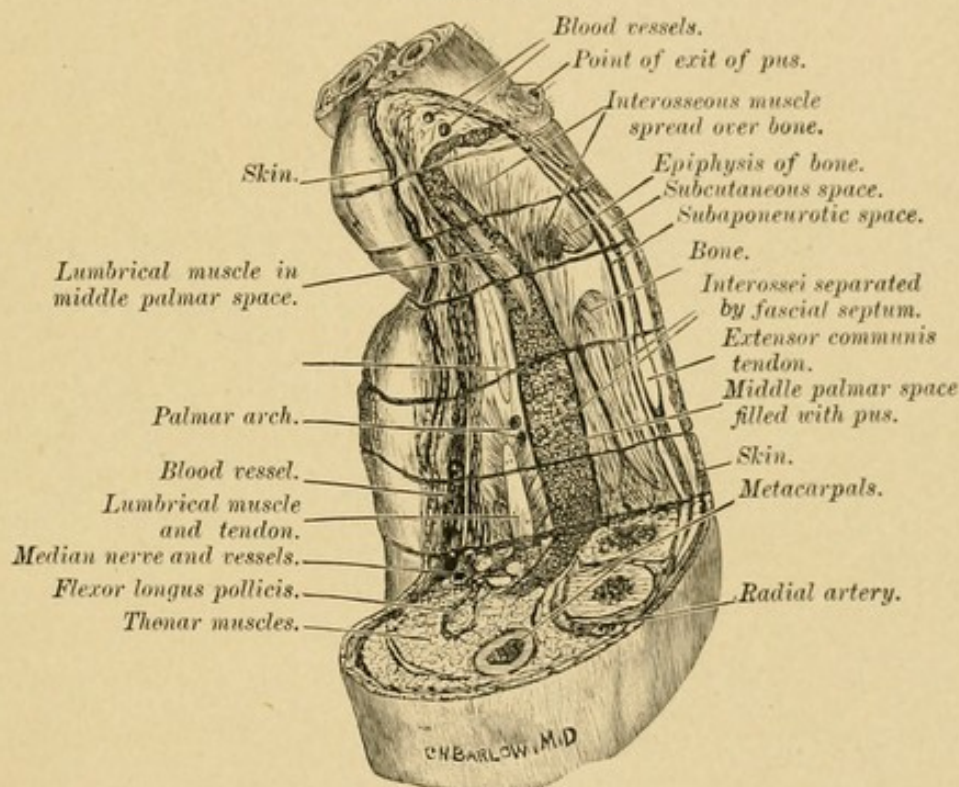
langeal joint, but here also resection may be resorted to if the tendon is intact. If this be involved, in a majority of cases, I, myself, at the present time would amputate the finger.

INVOLVEMENT OF THE HAND PROPER AND THE METACARPALS AND CARPALS

PATHOLOGY.—The third type of chronic osseous lesion is that in which the bones of the hand proper are involved. Here, unless modified by an original wound or operative procedure, the picture is again different, owing to the dense aponeurosis upon the palmar side and the sheet of dense tissue upon the dorsum uniting the tendons of the extensor communis digitorum. These dense sheets, particularly upon the palm, prevent the free egress of pus, and, as a consequence, it is more likely to burrow a considerable distance from the site of origin before exit (Fig. 127). This diffuses the reactive inflammation, and even if the exit is found near the site, the dense sheet prevents the crater-like elevation of granulation tissue noted in the second or phalangeal type. Hence, we are more likely to find a diffuse swelling of the whole palm or dorsum with multiple ostia, any of which may be open for a time and discharge, while another may be closed. There is often only a small amount of granulation tissue about the openings. In these cases of early osseous involvement often no sinus will appear upon the palmar surface, unless the soft tissues of the palm have been seriously involved primarily, or the infection has spread into the wrist-joint, and this is generally preceded by palmar phlegmon or tenosynovitis. Therefore, in these cases of osteomyelitis of the metacarpal bones dorsal sinuses are most common. They may appear at any point on the dorsum, but have a pre-

dilection for the sides and distal part near the knuckles (Fig. 128), owing to the dense sheet of tissue before mentioned. It is a well-known fact, however, that frequently this sheet has areas where it is not complete, particularly in the lower third between the tendons; and through these pus may discharge. But it is not

FIG. 127

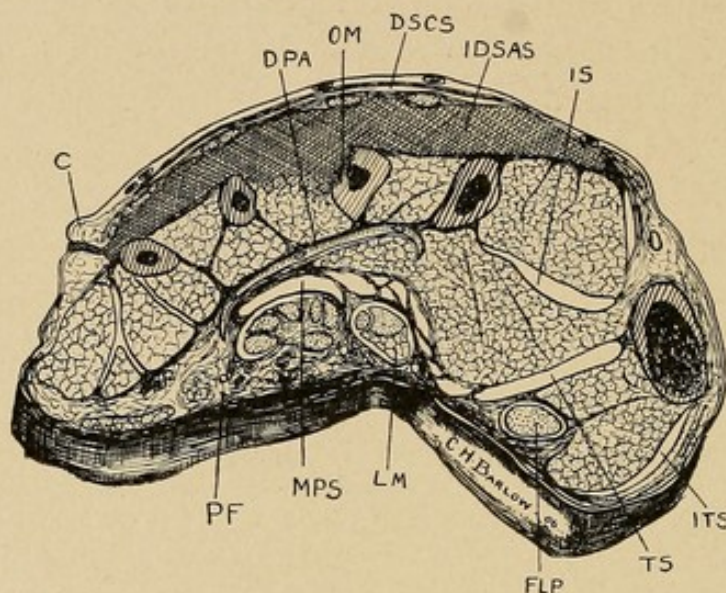


Drawing showing the relation of pus in the middle palmar space to the tendons. Also showing course pus pursues in its course along the lumbrical muscle to point on the dorsum near the web. Serial sections of the hand were made as shown, the tissues teased out, and middle palmar space filled with plaster of Paris. Sections restored to normal position and sagittal section made between ring and middle metacarpal of all sections except the proximal. Heavy dotted area shows position pus would occupy.

at all an uncommon thing to see a sinus ostium at either side over the index and little finger metacarpal, and one or two at the distal end between the knuckles, from a single focus of infection in either the middle or ring metacarpal (Fig. 64), as will be shown clearly by x-ray picture. Again, these ostia on the dorsum at the

knuckles may be due to a chronic process in the palm discharging through the lumbrical canals (see Fig. 127).

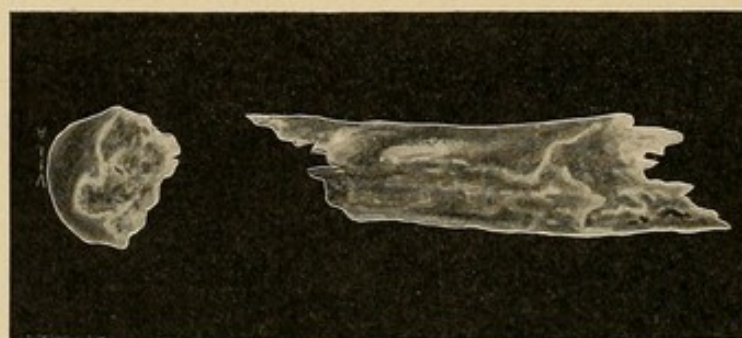
FIG. 128



Schematic drawing, showing pus under dorsal aponeurosis with ostium at the side: *PF*, palmar fascia; *MPS*, middle palmar space; *LM*, lumbrical muscle; *FLP*, flexor longus pollicis; *TS*, thenar space; *ITS*, indefinite thenar space; *IDSAS*, infected dorsal subaponeurotic space; *DSCS*, dorsal subcutaneous space; *OM*, osteitis of the metacarpal; *DPA*, deep palmar arch; *C*, site of discharge of pus.

So far as I have observed, there is no peculiar pathological destruction of the metacarpal bones in

FIG. 129



Drawing of fragments of metacarpal removed by Dr. W. E. Schroeder.

these cases (Fig. 129). There is one clinical fact, however, worth remembering from a therapeutic stand-

point, and that is the relative immunity from involvement of the metacarpophalangeal joint; this is possibly owing to the dense ligaments surrounding the joint, which protect it from invasion by way of the synovial sheath and adjacent phlegmons. As a consequence of this we are often able to preserve a functioning finger, although a considerable destruction of the metacarpal may be present; isolated necrosis of a metacarpal is uncommon except in tuberculosis or syphilis.

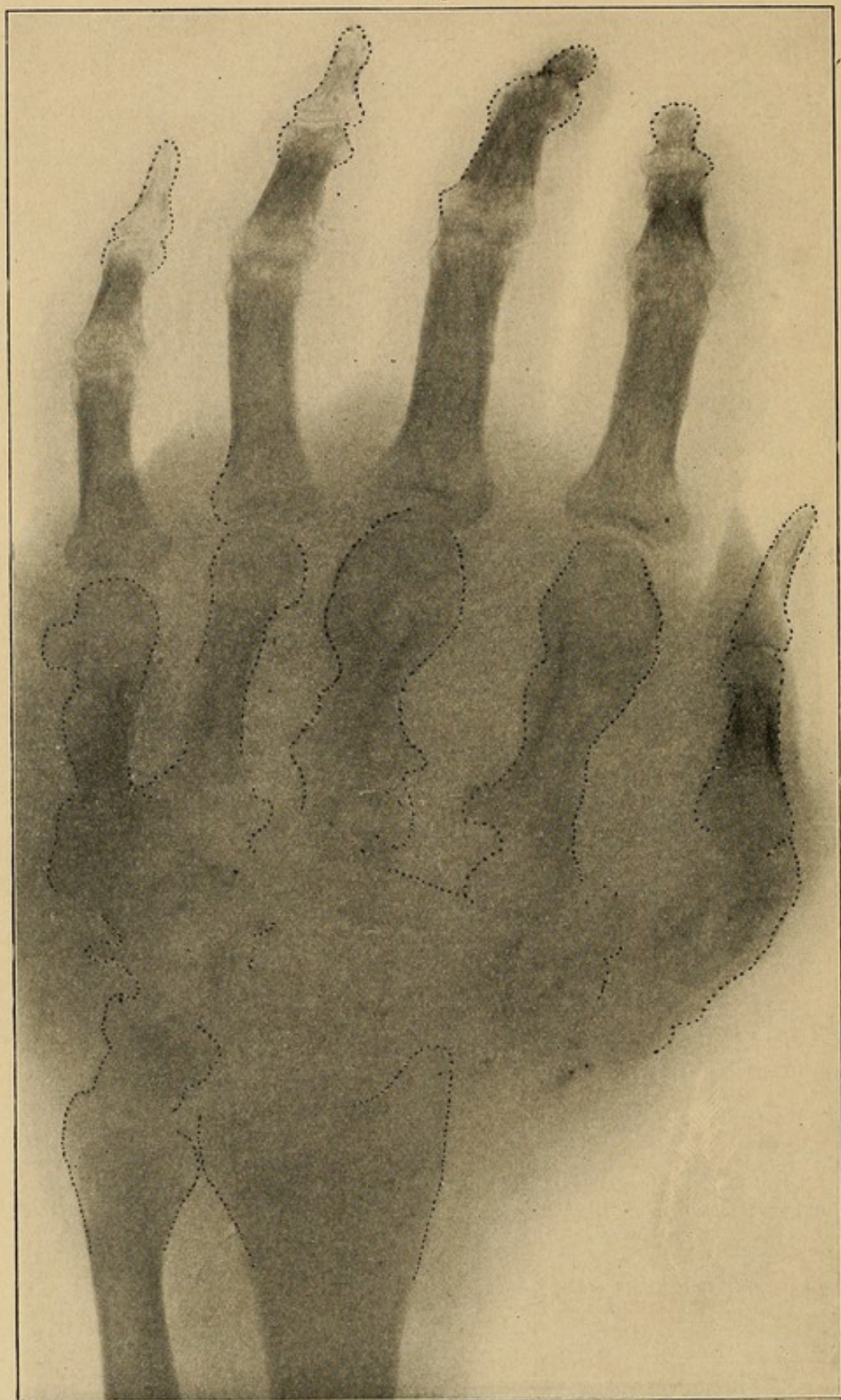
Involvement of the wrist-joint in chronic processes is characterized by multiple foci on both the dorsal and palmar surface.

I append the *x*-ray photograph of the hand of S. (Fig. 130).

CASE XLIX.—S., Post-Graduate Hospital, December, 1910. The patient suffered from a previous tendon-sheath infection of the ulnar and radial sheaths. I saw him after three months of chronic infection, when there were multiple sinuses both on the dorsum and flexor surface of the wrist from the joint, with lateral and distal sinuses upon the dorsum of the hand from osteomyelitis of the metacarpals of the index, middle, and little fingers. There was no involvement of the metacarpophalangeal articulations, in spite of the long-continued infection and extensive osteomyelitis. The *x*-ray picture clearly showed the location of the foci. All of the carpal bones were removed and the necrotic part of the metacarpals. The hand rapidly recovered. All discharge ceased within four weeks. Almost all function was lost. I have been surprised to find that now after three months he is developing some flexion of the fingers and hand, so that he can now hold a glass and perform other gross functions with the hand.

The following history of a patient in the practice of Dr. H. B. Baumgarth, with whom I saw the case in

FIG. 130



X-ray photograph of hand (patient S., see Case XLIX). Necrotic bone was removed from the wrist and the three metacarpals. Sufficient function was recovered to grasp gross objects. Thirty degrees of flexion of fingers at present, and function is growing better.

consultation, illustrates the course of these chronic cases when untreated.

CASE L.—Chronic infected process. Middle palmar abscess, later involving the ulnar bursa, associated with sinuses along the lumbrical canals. Case untreated surgically.

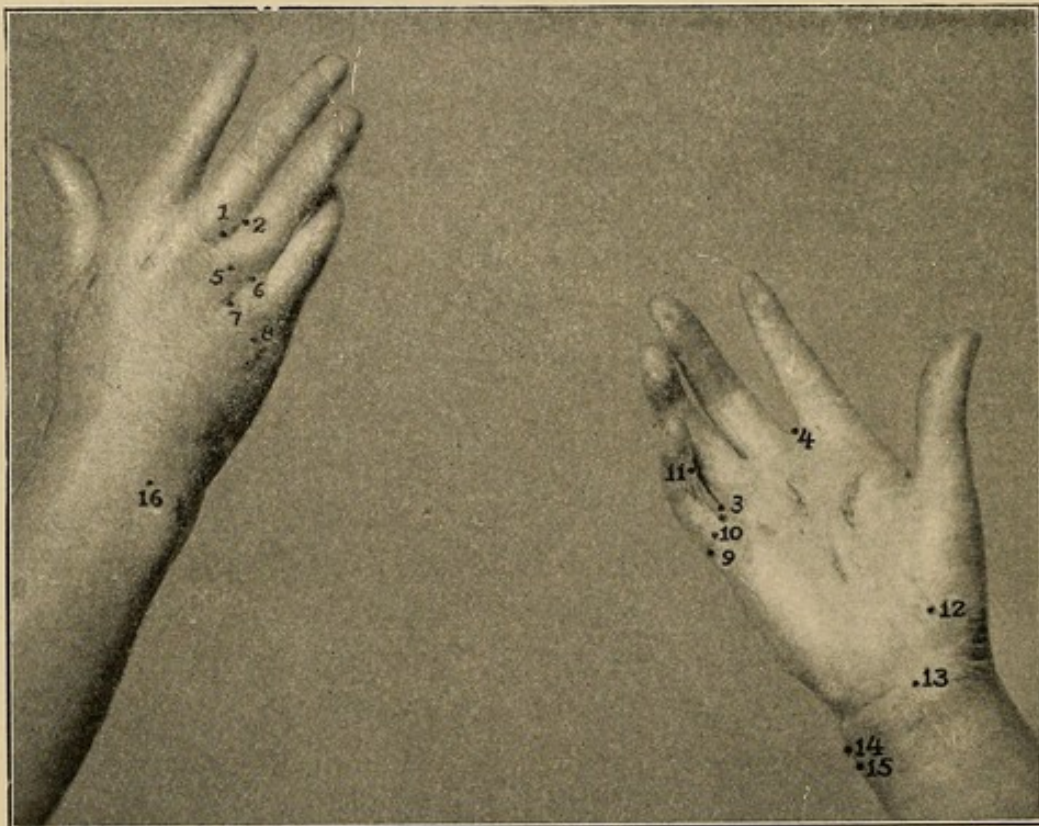Mrs. G., diabetic, received infection September 5, 1904, at web between the middle and ring fingers. The patient consulted a magnetic healer and remained under his care for seven weeks, when she applied to Dr. Baumgarth, who obtained the following history and drained the hand properly. Twenty-one days after the receipt of the infection, point 2, noticed on the dorsum, opened up; a few days later, points 3 and 4 opened, slightly more on the dorsal surface than on the palmar. Points 5, 6, 7, and 8 appeared successively in the next few days. After an interval of a few days, points 9 and 10 appeared, followed in succession by 12 and 13, and after an interval of several days, 14, 15, and 16, at which time the patient applied to Dr. Baumgarth, who thoroughly drained the pockets, and the patient made a tardy recovery. The atrophy of the distal phalanx of the index finger is due to a previous felon. The atrophy of the other fingers followed as a sequence of the present infection.

On February 25 adhesions were broken up under nitrous oxide, which benefited the movement of the finger and wrist to a slight extent only.

A careful study of this case serves to point out the pathological sequence which occurred as a result of the infection (Fig. 131). Points 1 and 2 were the original site of the infection, which spread from there, without doubt by lymphatic extension or continuity of tissue, along the lumbrical canal into the midpalmar space; from here in turn it retraced its course through the

lumbrical canals to the base of the index finger, point 4, and the base of the little finger, point 6. The ulnar bursa evidently became involved, and points 9 and 10 show the site of rupture from the sheath, the other areas at the base of the palm developing as a rupture of the proximal end of this bursa. This point was corroborated by Dr. Baumgarth at the time of opera-

FIG. 131



Photograph of Dr. Baumgarth's case. Figure numbers on the photograph represent the various sinuses and their approximate order of development by which the course of the infection can be traced. (See Case L.)

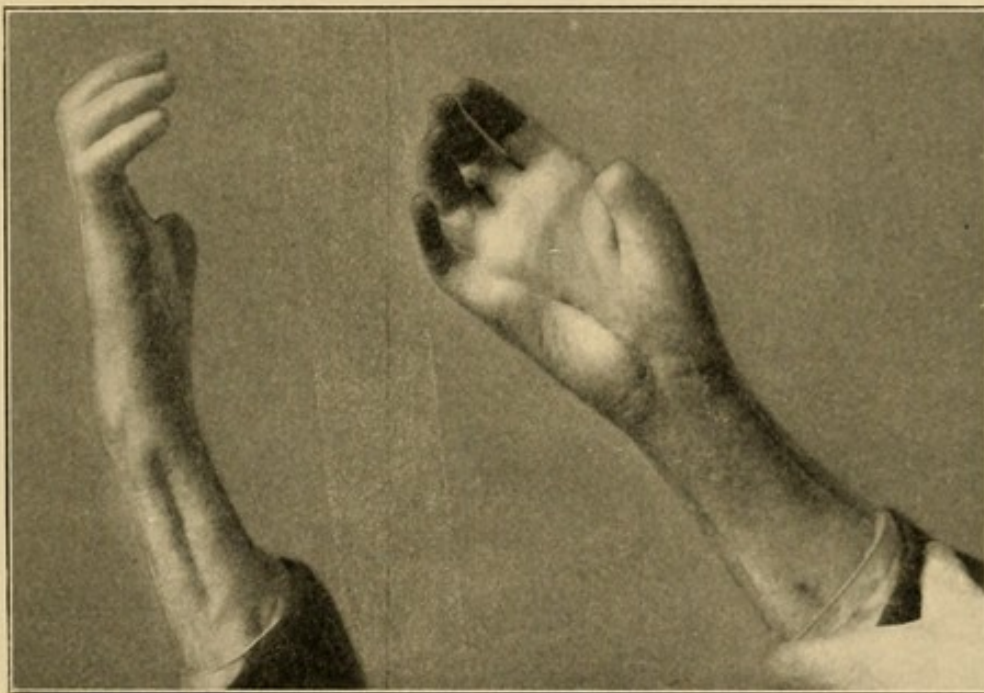
tion, since pus was found above the annular ligament in this synovial sac. It is to be noted that all the primary points of rupture from 1 to 8 appeared upon the dorsal surface of the base of the webs of the fingers. The characteristic claw hand seen in neglected tendon-sheath infection is shown in Fig. 132.

In those exceptional cases in which the pus has,

extended to the dorsum between the metacarpal bones, there is generally some destruction of bone requiring attention. It is at times seen in advanced cases accompanying wrist-joint invasion.

TREATMENT OF CASES INVOLVING THE HAND PROPER.—The treatment in those cases in which the chronic process lies in the palm may be confusing. We should determine first the location of the pus. Does it lie in the synovial sheaths or in the fascial space? Are the

FIG. 132



Photograph showing claw hand in neglected tendon-sheath infection.

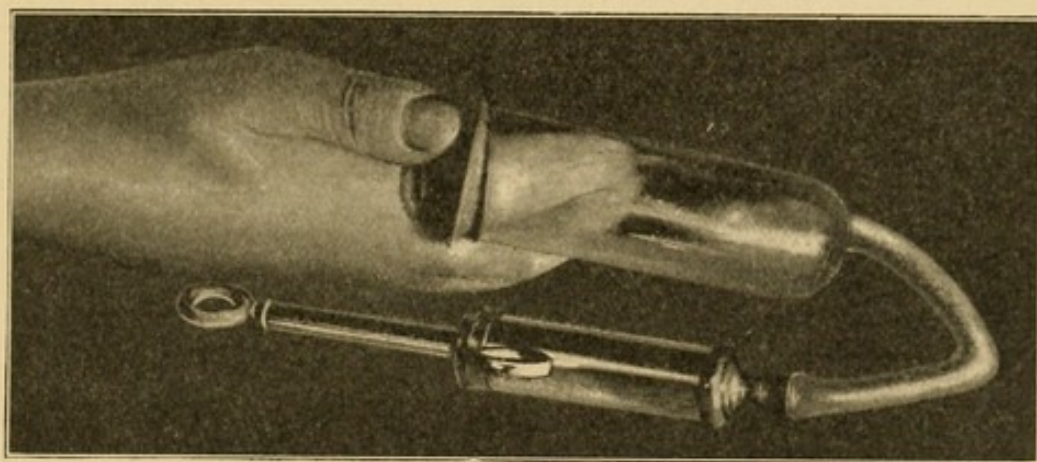
bones or the wrist-joint involved? While theoretically difficult to determine, it is not so confusing as in the acute cases, since there are generally sinuses which can be followed down to the hidden pockets. X-ray photographs may show necrotic bone. Complete anesthesia is essential. No operation upon infected hands should be begun without it. The ramifications should be followed up carefully and with patience. I shall not speak in detail of the factors which lead us to diag-

nosticate the presence of pus in the various sites, since this has already been discussed exhaustively in the previous chapters.

Various sinuses leading from the tendons to the surface will be followed down to the respective synovial sheaths. The sinuses found at the most proximal point of the finger sheaths designate the corresponding sheath, and this should be cut down upon and followed distally along the finger until every part of the tendon bathed in pus is exposed. Where the little finger tendon is involved, the extension of the sheath in the palm should be borne in mind, and the opening continued proximally over this when the grooved director inserted into the infected sheath on the little finger passes up into this without obstruction. Here the sheath should be opened throughout its extent up to the annular ligament, the incision lying to the ulnar side of the tendons. The incision should be limited to the annular ligament until the decision has been made as to whether the infection has extended under this into the proximal end of the sheath above the annular ligament. If this is diagnosticated, the ligament should be cut and the incision be continued into the forearm as far as the upper end of the sheath. Instead of this last incision the upper end of the sheath may be drained by incisions upon the ulnar and radial side of the forearm as described in the chapter on Forearm Involvement. It is not wise to open the sheath above and below the ligament and leave this latter intact. Having thoroughly opened this, the question then arises: Has the radial bursa, *i. e.*, the sheath of the flexor longus pollicis, become involved? If so, this must be opened throughout its extent down to a thumb's breadth, distal to the annular ligament. The incision should stop here for fear of injuring the motor nerve to the thenar area.

If the tendons have become necrotic, removal is indicated; on the other hand, one is often surprised at the amount of vitality present in the tendons which have lost their synovial covering, therefore after opening a sheath considerable conservatism is justifiable when it comes to a question of preserving or removing a tendon. Some of the chronic sluggish processes in the fingers have seemed to be benefited by the Klapp suction cup (Fig. 133).

FIG. 133



Showing Klapp's aspiration cup used in some old chronic infections of the fingers.

If the fascial spaces are involved, they should be drained after the methods described in Chapter XVII.

In considering the treatment of those cases in which the suppurating ostia appear upon the dorsum, particularly between the knuckles, I have already pointed out that in a majority of cases these are really sinuses leading from the palm along the lumbrical canals (Fig. 127), and the perfect drainage of the palm along the lumbrical canals, as already mentioned, will end in rapid recovery if uncomplicated by tendon or bone involvement.

If the bones of the hand or wrist are involved, they should be removed or the necrotic part curetted out.

In treating the wrist-joint the general principles as to the removal of bones, which have been enunciated in Chapter XXVII, when dealing with carpal involvement, should be borne in mind. These should not, however, interfere with the paramount rule that all dead bone should be removed.

ATROPHY AND CONTRACTURE

The anatomical and clinical evidence already adduced shows the tendency for the infection to extend in juxtaposition to the bloodvessels and nerves. The former leads to contracture about the veins and lymphatics, and consequently a persisting distal edema. The most serious sequelæ, however, ensue because of the extension along the nerves—metacarpal, ulnar, and median—leading secondarily to trophic changes in the part. This secondary change follows probably upon contraction of the scar tissue about the nerves, since they are not likely to be destroyed by the process. At times we see the median nerve persisting, partly isolated from the surrounding tissue, although in conjunction with the tendons it may be destroyed at the wrist-joint from pressure necrosis by the non-distensible annular ligament.

This secondary change is particularly noticeable in the atrophy of the distal phalanges, and even of the whole hand (Figs. 131 and 132). This sequela of nutritive and trophic disturbance yields slowly or not at all to the restorative processes of nature. Massage, passive motion, and constant use of the hand carried out systematically under the careful personal supervision of the surgeon may aid nature. Adhesions between the joints, when they are not the result of the destruction of the synovial coverings, may be treated by repeated non-violent passive movements under nitrous oxide

anesthesia, or by the various appliances designed to produce passive motion, particularly those which act by exhausting the air, and hence, in addition to producing mobility, favor active congestion of the parts (Figs. 85 and 86, p. 280). In case of neglected tendon-sheath infection one expects to see the characteristic claw hand. Experimental investigations as to the restoration of destroyed tendons have been carried out, but as yet nothing definite can be recommended in cases of loss of finger tendons, although something may be hoped for in the future. Experience has taught me that scientifically made incisions based upon the anatomy I have pointed out will provide complete drainage of all the pockets and in the end will give a much more serviceable hand than we have had the fortune to secure in the past. It cannot be urged too strongly that we should make careful study as to the possible position of pus in the hand, to the end that we may make early and radical incisions and thus prevent these cases of atrophy and contracture.

RÉSUMÉ—CHRONIC INFECTIONS

Necrosis of the distal phalanx ordinarily ends in sloughing of the diaphysis alone. Joint function should be preserved. Incision should be made laterally instead of upon the volar surface (see Chapter I).

The proximal interphalangeal joint is most commonly involved. The proximal phalanx escapes while the epiphysis and part of the diaphysis of the middle phalanx are destroyed.

Conservative operations may be done with some success.

Isolated involvement of the tendon sheaths may be present. Incision of the sheath should expose all involved parts.

Chronic palmar abscesses frequently point on the dorsum, passing along the lumbrical canals. Palmar abscesses may be opened along these canals.

Chronic dorsal abscesses may point at a distance from the focus, owing to the dorsal aponeurotic sheet.

The carpal joints are frequently invaded from the radial bursa; abscesses and sinuses appear upon the dorsum, as well as upon the flexor surface. Every effort should be made to preserve the integrity of the tissue between the first and second row of carpal bones. (See Chapter XXVII.)

Serious forearm abscesses lie dorsal to the flexor profundus digitorum, and may be opened either in front, in connection with an incision in the palm, or by lateral drainage.

Trophic changes result from the tendency of the pus to extend along the nerves and bloodvessels.

Complete function can be promised patients suffering with palmar abscesses uncomplicated by tendon-sheath or osseous infection.

Neglected tendon-sheath infections give rise to the claw hand. Tendon-sheath infections operated upon early give good function, except that flexion of the two distal phalanges may be lost.

INDEX

A

- ABSCCESS**, collar-button, 52
 treatment of, 55
 in course of lymphatic vessel, 319
 deep, of forearm, 384
 distal palmar, 52
 of fascial spaces, after-treatment of, 296
 treatment of, 281
 of forearm, treatment of, 405
 localized, 55
 hypothener space, 55
 thenar space, 55
 location of, in forearm, 385
 of middle palmar space, treatment of, 282
 periglandular, treatment of, 362
 of radial lymphatics, 175
 shirt-stud, 52
 subaponeurotic space, treatment of, 295
 subclavicular and shoulder, treatment of, 362
 subcutaneous, in forearm, 383
 treatment of, in lymphangitis, 361
 subepithelial, 37
 thenar space, treatment of, 293
Absorption of virulent toxins, prevention of, 251
Adhesions, prevention of, 295
 in tenosynovitis, 203
 prevention of, 278
 treatment of, Bier's, 280
Alcohol dressings, 249
Anatomy, cross-section, distal to web, 84
 one-half centimeter proximal to the joint, 87
 taken at wrist, 96
 three centimeters above joint, 90
 through base of palm, 94
 distal part of thenar eminence, 93
 epiphysis of proximal phalanx, 85

- Anatomy**, cross-section, two centimeters above joint, 88
 of forearm, 150
 five centimeters above radial styloid, 151
 nine centimeters above radial styloid, 153
 seven centimeters above radial styloid, 153
 three centimeters above radial styloid, 150
 of forearm in relation to infections, 149
 of hand and forearm, 79
 of hypothener space, 95
 of lymphatics, 302
 of middle palmar space, 90
 of thenar space, 91
Anesthesia in operations, 251
Annular ligament cut in hand infections, 252, 261, 269
 extensions of pus matter, 177
Anthrax, 379
Arthritis, 199, 414, 420
 metacarpophalangeal, 186
Atrophy, 414, 436
Axillary glands, source of involvement, 320

B

- BACILLUS** *aërogenes capsulatus* infection, treatment of, 378
 of malignant edema, differentiation of, 377
Bacteria of gas bacillus infections, differentiation of, 377
 influence of types of, in lymphangitis, 316
Bier's hyperemic treatment, 71, 234, 251, 277, 353
 treatment of adhesions, 280
Bloodless field in operations, 251
Bone involvement, 418
Bones of finger, treatment of, when involved, 423
 of wrist-joint, necrosis of, 411
Bursitis, radial, diagnosis of, 214

C

- CARBOLIC acid gangrene, 249
 Carbuncles, 38
 anatomical considerations of, 38
 pathogenesis of, 38
 pathology of, 38
 site of, 38
 treatment of, 41
 Carpals, involvement and treatment of, 426
 Cautery to open abscesses, 76
 Claw-hand, 203
 Collar-button abscess, treatment of, 55
 Contractures, 414, 436
 Cross-sections of hand and forearm.
 See Anatomy.

D

- DISTAL palmar abscess, 52
 Diverticula of each of definite spaces, 115
 Dorsal abscess, diagnosis of, 223
 as extension from thenar space infection, 183
 from middle palmar abscess, 182
 subaponeurotic space, 99
 experimental study of boundaries and position of secondary abscesses in case of rupture from, 142
 subcutaneous space, 99
 boundaries, diverticula, and position of secondary abscess in case of rupture from, 147
 experimental study of boundaries and position of secondary abscess in case of rupture from, 140
 Dorsum of hand and forearm, lymphangitis and, 320
 infections beginning in, 194
 tendon sheaths of, 112
 infection of, treatment of, 276
 Drainage in incisions in forearm, 262
 in infections, 75
 in palmar abscess, 283
 in tenosynovitis, 251, 276
 at wrist, 262
 Dressing, alcohol, 249
 dry, in tenosynovitis, 277
 hot moist, in lymphangitis, 351
 in tenosynovitis, 248, 277

- Drugs, antagonistic, in lymphangitis, 356
 Durillon forcé, 314

E

- EDEMA of dorsum, differentiated from erysipelas, 320
 mistaken for pus, 182
 malignant, 378
 in tenosynovitis, 203
 Embryology of hand, comparative, 143
 Epitrochlear glands, source of involvement, 320
 Erysipelas, 373
 differentiated from edema of dorsum, 320
 from lymphangitis, 352
 gangrenous, 373
 treatment of, 373
 Erysipeloid, 374
 Esmarch bandage, 321
 Excretion, stimulation of, in infections, 77
 Extensor carpi radialis longior and brevior, tendon sheath of, 112
 ulnaris, tendon sheath of, 112
 communis digitorum, tendon sheath of, 112
 indicis, tendon sheath of, 112
 longus pollicis, tendon sheath of, 112
 minimi digiti, tendon sheath of, 112
 ossis metacarpi pollicis, tendon sheath of, 112

F

- FASCIA palmaris, isolated necrosis of, 235
 Fascial spaces, 22, 99
 abscess of, acute, prognosis and résumé of, 297
 after-treatment in, 296
 diagnosis of, 215
 pathogenesis of, 163
 pathology of, 196, 198
 surgical considerations of, 163
 symptoms, signs, and diagnosis of, 201, 215
 treatment of, 281
 immobilization in, 296
 experiments as to boundaries, diverticula, and extensions from, 143

- Fascial spaces, extension of, from one to another, 177
 position of secondary abscess in, 127
 of forearm, experimental injection of, 154
 infection of, 63
 direct implantation of infection in spaces, 169
 etiology of, 163
 relation to lymphangitis, 173, 301
 involvement of, 168
 recapitulation as to source of, 176
 normal boundaries of, 127
 relation of, to synovial sheaths, 114
 to tendon sheaths, 126
 study of, by serial cross-sections, 83
- Felons, 25
 after-treatment of, 31
 etiology of, 25
 pathogenesis of, 26
 pathology of, 26
 treatment of, 29
- Filleaux, 237, 238
- Fillmans, 240
- Finger, index, diagnosis of extension from infections beginning in, 209
 experimental study of extension after rupture from tendon sheath of, 124
 infection involving, 185
 tendon sheath of, 102
 extensions from infections in, 187
 relation of, to thenar space, 103
 tenosynovitis of, treatment of, 253
 infectious processes of, 415
 course of lymphatic from each, 320
 extensions from primary foci on, 185
 involving sides of, 175
 involvement of, 421
 little, diagnosis of extensions from infections beginning in, 193, 204
 experimental study of extension after rupture from tendon sheath of, 120
 infection of, incision in, 256
 tendon sheath of, 105
 relation of, to middle palmar space, 103
- Finger, little, tenosynovitis of, treatment of, 255
 and ulnar bursa, extensions from, treatment of, 262
 middle, diagnosis of extension from infections beginning in, 191, 209
 experimental study of extension after rupture from tendon sheath of, 117
 extensions from tenosynovitis of, treatment of, 255
 tendon sheath of, 102
 relation of, to middle palmar space, 103
- ring, diagnosis of extensions from infections beginning in, 192, 209
 experimental study of extension after rupture from tendon sheath of, 118
 extensions from tenosynovitis of, treatment of, 255
 tendon sheath of, 102
 extensions of, 194
 relation of, to middle palmar space, 103
- Flexor longus pollicis, tendon sheath of, 104
 tenosynovitis of, 213
- Forearm, abscess of, deep, 384
 diagnosis of, 224
 subcutaneous, 383
 treatment of, 405
 anatomy of, 79
 in relation to infections, 149
 dissection and experimental injections of, 159
 incisions in, drainage in, 262
 infections of, treatment of, 263
 injections of fascial spaces of, 154
 involvement of, abscess formation without complications, 385
 associated with wrist-joint invasion, 391
 following tenosynovitis of thumb, treatment of, 266
 incision in, 260
 from infections of hand, pathology and diagnosis of, 383
 from middle palmar space, 177
 secondary hemorrhage and, 400
 treatment of, 405
 to little finger infection, 204, 207

Forearm, involvement of, from ulnar
bursitis, treatment of, 258
lymphatics of, 310
serial cross-sections of, 150
Forssell, 226, 230
Friedrich, 241
Frog-felon, 52

G

GANGRENE, carbolic acid, 249
Gangrenous erysipelas, 373
Gas bacillus infection, 375
Gauze in treatment of infections, 75
Gonorrheal tenosynovitis, 226
Gutta-percha in treatment of infections, 75

H

HAND, anatomy of, 79
chronic processes in palm of,
treatment of, 426
and forearm, lymphatic vessels
of, 304
infections, diagnosis of differential,
225
Heineke, 236
Helferich, 242
Hemolysis in streptococcus infections,
317
Hemorrhage in forearm involvement,
401
secondary, treatment of, 264, 413
Hyperemic treatment, Bier's, 71, 234,
251, 277, 353
Hypothenar space, 95, 99
abscess of, treatment of, 281
anatomy of, 95
boundaries, diverticula, and
position of secondary abscess in case of rupture
from, 146
experimental study of boundaries, diverticula, and position of secondary abscesses
in cases of rupture from, 143
infection of, diagnosis of, 233
relation of, to infection in middle palmar
space, 182
involvement of, source of,
176

I

ICE bag in axilla in treatment of infections, 249

Immobilization in fascial space abscesses, 296
in tenosynovitis, 277
Incision in forearm involvement, 260
errors in making, 261
in infections, prophylactic, 74
in little finger infections, 256
in lymphangitis, 354
in tenosynovitis, 251
in ulnar bursal infections, 256
Index finger. *See* Finger, index.
Infections. *See also* Tenosynovitis, Lymphangitis, Fascial-space infection.
carbuncular, 38
chronic, repeated, 363
staphylococcus, 48
classification of, 17
diagnosis of, general, 57
drainage in, 75
grave, 57
passive hyperemia in, 71
simple localized, 25
spread of, from any given primary focus, 185
from one fascial space to another, 177
from sides of fingers, 175
subepithelial, 37
treatment of, Bier's, 71
boric acid solution in, 72
cautery to open abscesses in, 75
drainage in, 75
drugs in, 70
gauze in, 75
general principles of, 70
gutta-percha in, 75
hot moist dressings in, 72
Klapp suction cup in, 77
massage in, 77
passive hyperemia in, 71
prophylactic incision in, 74
rest in, 70
rubber tubes in, 76
types of, 17

Intermediary palmar sheath, anterior, 110
posterior, 109
Interosseous artery, anterior, lymphatic abscesses and, 175
Interphalangeal joint, proximal, relation of, to tendon sheath, 102

J

JOINTS, interphalangeal, 210
proximal, treatment of, when involved, 423
involved, secondary to little finger infection, 204

Joints, metacarpophalangeal, involvement and treatment of, 426
preserving function of, in tenosynovitis, 278

K

KARENSKI, 230
Kausch, 229
Klapp, 72, 227, 228, 435
König, 239

L

LACUNÆ of lymphatics, relation of, to subcutaneous abscess, 320, 355
Lejars, 242
Leukocytosis, increase of in lymphangitis, 358
Lexer, 240
Little finger. *See* Finger, little.
Lumbrical muscles, extension to thenar space from middle palmar space, 182
involved from infection of middle finger, 192, 210
of tendon sheath, 169, 188, 210
in web, 193
from middle palmar space, 177
from ring finger tendon sheath, 193, 210
secondary to index tenosynovitis, treatment of, 253, 254
to little finger infection, 208
involvement of, source of, 177
relations of, to infections of middle palmar space, 102, 172, 254
tenosynovitis and, 252
Lymphangitis, 58
acute, simple, 329
with minor local complications, 329
with serious local complications, 330
with systemic involvement, 333
bacteria and, 316
in central part of palm, 194, 195
complications of, treatment of, 359

Lymphangitis, deep, 334
differentiated from erysipelas, 352
dressing in, 351
drugs in, antagonistic, 356
etiology of, 314, 325
extension of, in infection of middle finger, 192
of thumb, 192
frequency of localization in, 333
hot moist dressings in, 361
incision in, 354
leukocytosis in, increases of, 358
pathogenesis of, 314, 325
pathology of, 314, 325
phlegmonous, 332
prognosis of, 347
relation of, to fascial space infection, 301
to other types of infection, 301
to tenosynovitis, 301
septicemia and, 302
symptoms and signs of, 328
systemic involvement from, 337
treatment of, 351
normal salt solution in, 356
peptonized food in, 356
types of, 301, 329
Lymphatic abscess along arteries, 175
experimental injections and, 323
dilations, sacciform, 304
infections, treatment of, 351
rest in, 353
Lymphatics, anatomy of, 302, 304
influence of, on course of infection, 318
course of, 174
deep, 312, 322
fascial space infection and, 173
history of, 18
relation of, to tendon sheaths, 321
superficial, 304
termination of, 311

M

MALIGNANT edema, 378
Mascagni, 302
Massage in treatment of infections, 77
Mauclaire, 241
Median nerve, relation of, to bursæ, 108
Metacarpal bones, extension of infection of, to dorsum, 182
fifth, relation of, to infection of hypothenar space, 172
involvement and treatment of, 426
of middle finger, 192

- Metacarpal bones, osteomyelitis of,
193, 194
relation of, to infections of
middle palmar space, 172
Metacarpophalangeal arthritis, 186
joint and the tendon sheath, 102
Middle finger. *See* Finger, middle.
palmar space. *See* Palmar space,
middle.

N

- NECROSIS of bones of wrist, 411
of tendons, 197, 266
Nerves to thenar muscles, relation of,
to tendon sheath, 265
Nicaise, 233, 247
Normal salt solution in lymphangitis,
356

O

- OIDIOMYCOSIS, 45
diagnosis of, 47
Osteomyelitis, 414
metacarpal bones, 193, 194

P

- PALM, infections beginning in, 194
lymphatics of, 309
relation of, to infections, 318
wound of, punctured, 134
Palmar abscess, drainage in, 283
fascia, relation of, to abscesses,
194
sheath, intermediary, anterior, 110
posterior, 109
space, middle, 90, 99
abscess of, treatment of,
282
anatomy of, 90, 96
boundaries, diverticula,
and position of second-
ary abscesses in case
of rupture from, 144
experimental study of
boundaries
and position
of secondary
abscesses in
case of ex-
tension from,
127
of site of rup-
ture and ex-
tensions into
forearm, 157

- Palmar space, middle, infection of,
after results of, 198
diagnosis of, 216
by direct implanta-
tion, 169
extension from, 177
to thenar space,
181
to ulnar bursa, 183
relation of, to hypo-
thenar space, 182
involved from infection
spreading from
sides of fingers,
175
secondary to fascial
space infec-
tion, 183
to little finger
infection,
208
to middle and
ring finger
tenosyno-
vitis, 168,
193, 211
to ring finger
infection,
192
to tenosyno-
vitis, treat-
ment of, 254,
263
involvement of, source
of, 176
and subaponeurotic
spaces, combined in-
volvement of, treat-
ment of, 289
and thenar space, com-
bined in-
volvement
of, treat-
ment of, 285
interrelation of,
96
Parona, 242
Paronychia, 31
pathology of, 32
treatment of, 33
types of, 32
Peptonized food in lymphangitis, 356
Periglandular abscess, treatment of,
362
Phalanges, distal, 25
infection of, 25
involvement of joints of,
treatment of, 253
Phalanx, 423
involved secondary to little finger
infection, 204

Phalanx, middle, 210
 Phlegmon of dorsum, treatment of, 361
 Phlegmonous lymphangitis, 332
 Poirier, 302
 Poulsen, 245
 Punctured wound of palm, 194

R

RADIAL artery, abscesses along, 175
 bursa, 104
 anatomy peculiar to infections of, 392
 communication of, with ulnar bursa, 109
 diagnosis of extensions from infections beginning in, 213
 experimental study of site of rupture and extension into forearm from, 155
 infections of, extension of, to ulnar bursa, 166
 treatment of, 265
 involved secondary to little finger infection, 204, 207
 to tenosynovitis of throat, 214
 bursitis, diagnosis of, 214
 lymphatics, abscesses of, 175
 Rheumatism of wrist, 225
 Ring finger. *See* Finger, ring.
 Rubber tubes in treatment of infections, 76
 "Run-around" paronychia, 31

S

SACCIFORM lymphatic dilatations, 304
 Sappy, 302
 Scheide, 236
 Schleich, 244
 Schüller, 237, 247
 Septicemia, 337
 Serum and vaccine treatment in lymphangitis, 357
 Shirt-stud abscess, 52
 Sinuses in chronic processes, 427
 treatment of, 434
 Sporotrichosis, 322
 Staphylococcic tenosynovitis, 203
 Streptococcic tenosynovitis, 203
 Streptococcus infections, hemolysis in, 317
 Subaponeurotic space, abscess of, treatment of, 295

Subaponeurotic space, boundaries, diverticula, and position of secondary abscesses in case of rupture from, 146
 infection from, extension of, 183
 secondary changes following, 200
 source of, 173, 183
 treatment of, 289, 295
 Subcutaneous abscess following radial bursal inflammation, treatment of, 266
 tenosynovitis, treatment of, 264
 tissue, source of infection, 173
 Subepithelial abscess, 37
 Symbiosis, effect of, on course of infection, 317
 Synovial sacs, accessory, 109
 sheaths of dorsum, infections of, treatment of, 276
 fascial spaces and, relation between, 114
 of wrist-joint, 411

T

TENDONS, necrosis of, 197, 266
 treatment of, 435
 prevention of adhesions of, in tenosynovitis, 278
 prolapse at wrist prevented after incision, 278
 sheaths, anatomical distribution and relations of, 101
 upon dorsum, 112
 extension to fascial spaces from, 168
 from little finger, 194
 of extensor carpi radialis longior and brevior, 112
 ulnaris, 112
 communis digitorum, 112
 indicis, 112
 longus pollicis, 112
 minimi digiti, 112
 ossis metacarpi pollicis, 112
 to fascial spaces, relations of, 126
 of flexor longus pollicis, 104
 experimental study of extension after rupture from, 125
 surface, 101
 tendon of little finger, 105

- Tendon sheaths of index finger,
 experimental study of
 extension after rupture
 from, 124
 intercommunication, of, 109
 of little finger, 105
 experimental study
 of extension after
 rupture from, 120
 of middle finger, experimen-
 tal study of ex-
 tension after
 rupture from, 117
 infection involv-
 ing, 192
 of ring finger, experimental
 study of extension after
 rupture from, 118
 rupture of, relation of, to
 fascial spaces, 117
 of thumb, anatomical study
 of relation of, to
 motor nerves of the-
 nar muscles, 265
 spread of infection in-
 volving, 191
 of thumb, removal of, 267
- Tenosynovitis, 59
 acute suppurative, treatment of,
 248
 adhesions in, 203
 prevention of, 278
 after-treatment of, 276
 position of hand in, 278
 by aspiration, diagnosis of, 253
 diagnosis of, 201
 drainage in, 251, 276
 dressing in, dry, 277
 hot moist, 248, 277
 edema in, 203
 etiology of, 163
 extension of, from one sheath to
 another, 165
 of flexor longus pollicis, 213
 extension from, 213
 following lymphangitis, treat-
 ment of, 359
 gonorrheal, 226
 incision in, 251
 of index finger, treatment of, 251,
 253
 involvement of various sheaths
 in, 164
 of little finger, treatment of, 255
 lumbrical space and, 252
 of middle finger, treatment of, 251
 relation of, to lymphangitis, 301
 pathogenesis of, 163
 pathology of, 196
 preserving function of joints in,
 278
 prognosis of, 297
- Tenosynovitis, relation of lymphan-
 gitis to, 301
 of ring finger, treatment of, 251
 staphylococcic, 203
 streptococcic, 203
 subcutaneous abscess following,
 treatment of, 264
 surgical considerations of, 163
 symptoms and signs of, 201
 tenderness in, 202
 of thumb, treatment of, 248
 treatment of, 227, 248
 elevation of part in, 249
 immobilization in, 277
 passive and active move-
 ments in, 278
 rest in, 249
- Thenar area, involved secondary to
 index tenosynovitis, treatment
 of, 253, 254
 space, 91
 abscess of, treatment of, 293
 anatomy of, 91, 96
 boundaries, diverticula, and
 position of secondary ab-
 scesses in case of rupture
 from, 145
 experimental study of
 boundaries and position
 of secondary abscess in
 case of rupture from, 133
 infection of, diagnosis of, 216
 extension of, to middle
 palmar space, 183
 to other spaces, 183
 from tendon sheath, 188
 involved from infection from
 sides of fingers, 175
 from metacarpophalan-
 geal arthritis, 186
 from middle palmar
 space, 181
 secondary to index
 finger tenosyno-
 vitis, 211
 to tendon sheath
 infection, 169
 involvement of, source of, 176
 middle palmar abscess and,
 treatment of, 285
 space and, inter-
 relation of, 96
- Thiersch graft after carbuncles, 45
- Thrombophlebitis, 345
- Thumb, infection involving, 191
 tendon sheath of, 104
 extension of rupture
 from, 125
 tenosynovitis of, treatment of,
 265
- Toxins, virulent, prevention of ab-
 sorption of, 251

U

- ULNAR artery, abscesses along, 175
hemorrhage and, 404
bursa, 105
communication of, with
radial bursa, 110
with tendon sheath of
ring, middle, and
index finger, 110
experimental study of site
of rupture and extension
into forearm, 156
extensions from, treatment
of, 262
infection of, extension of, to
radial bursa, 166
incision in, 257
involved from middle palmar
space infection, 183
secondary to little finger
infection, 204
to radial bursal in-
fection, diagnosis
of, 214
tenosynovitis of, treatment
of, 255


- Ulnar sheath infection, secondary to
radial bursal inflammation,
treatment of, 267

V

- VON VOLKMANN treatment of teno-
synovitis, 277


W


- WEB of finger, infection from, 193
involved secondary to tenosyno-
vitis, treatment of, 254
space, 100
Wound of palm, punctured, 194
Wrist-joint, bones of, necrosis of, 411
infection of, preservation of func-
tion in, 412
secondary to little finger
involvement, 204
involvement of, 391
treatment of, 410
Wrist, rheumatism of, 255





Price - \$ 3.75





COLUMBIA UNIVERSITY LIBRARIES (hsl.stx)

RD 551 K13 1912 C.1

Infections of the hand:



2002096870

