

**The harmful effects of acetanilid, antipyrin, and phenacetin / By L.F. Kebler  
... with the collaboration of Drs. F.P. Morgan and Philip Rupp.**

**Contributors**

Kebler, Lyman F. 1863-  
Morgan, F. P.  
Rupp, Philip  
Augustus Long Health Sciences Library

**Publication/Creation**

Washington : Govt. Print. Off, 1909.

**Persistent URL**

<https://wellcomecollection.org/works/qabag9r5>

**License and attribution**

This material has been provided by This material has been provided by the Augustus C. Long Health Sciences Library at Columbia University and Columbia University Libraries/Information Services, through the Medical Heritage Library. The original may be consulted at the the Augustus C. Long Health Sciences Library at Columbia University and Columbia University. where the originals may be consulted.

This work has been identified as being free of known restrictions under copyright law, including all related and neighbouring rights and is being made available under the Creative Commons, Public Domain Mark.

You can copy, modify, distribute and perform the work, even for commercial purposes, without asking permission.



Wellcome Collection  
183 Euston Road  
London NW1 2BE UK  
T +44 (0)20 7611 8722  
E [library@wellcomecollection.org](mailto:library@wellcomecollection.org)  
<https://wellcomecollection.org>

COLUMBIA LIBRARIES OFFSITE  
HEALTH SCIENCES STANDARD



HX64090108

QP971 .K23 1909 The harmful effects

**RECAP**

Kebler

...The harmful effects of acetanilid, antipyrin  
and phenacetin.


QP971      K23      1909

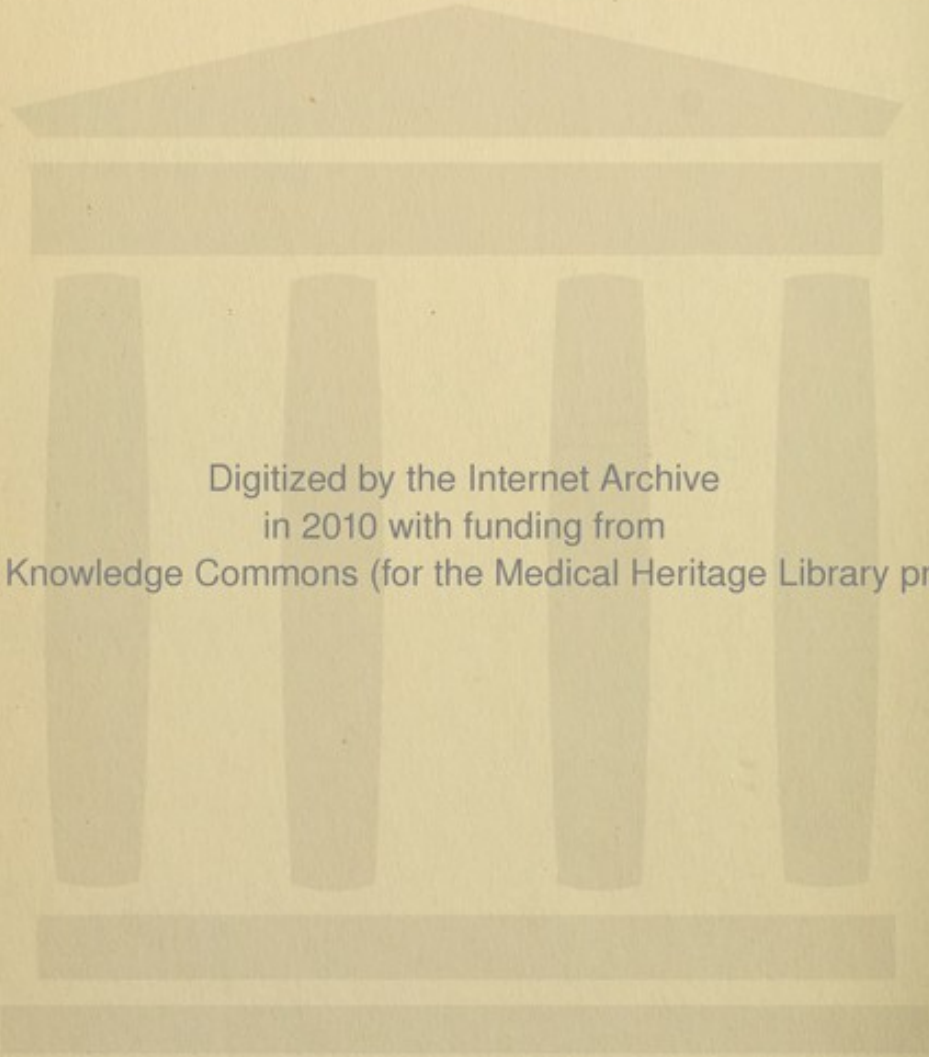
**Columbia University**  
**in the City of New York**

THE LIBRARIES



**Medical Library**





Digitized by the Internet Archive  
in 2010 with funding from  
Open Knowledge Commons (for the Medical Heritage Library project)

Issued July 3, 1909.

U. S. DEPARTMENT OF AGRICULTURE,  
BUREAU OF CHEMISTRY—BULLETIN No. 126.  
H. W. WILEY, Chief of Bureau.


THE HARMFUL EFFECTS OF ACETANILID,  
ANTIPYRIN, AND PHENACETIN.

By

L. F. KEBLER, PH. C., M. D.,  
*Chief, Division of Drugs,*

WITH THE COLLABORATION OF

DRS. F. P. MORGAN AND PHILIP RUPP,  
*Assistant Chemists.*



WASHINGTON:  
GOVERNMENT PRINTING OFFICE,  
1909.

## ORGANIZATION OF BUREAU OF CHEMISTRY.

H. W. WILEY, *Chemist and Chief of Bureau.*  
F. L. DUNLAP, *Associate Chemist.*  
W. D. BIGELOW, *Assistant Chief of Bureau.*  
F. B. LINTON, *Chief Clerk.*  
A. L. PIERCE, *Editorial Clerk.*  
M. W. TAYLOR, *Librarian.*

### Division of Foods, W. D. BIGELOW, *Chief.*

Food Inspection Laboratory, L. M. TOLMAN, *Chief.*

Food Technology Laboratory, E. M. CHACE, *Chief and Assistant Chief of Division.*

Oil, Fat, and Wax Laboratory. [Not appointed.]

### Division of Drugs, L. F. KEBLER, *Chief.*

Drug Inspection Laboratory, G. W. HOOVER, *Chief.*

Synthetic Products Laboratory, W. O. EMERY, *Chief.*

Essential Oils Laboratory. [Not appointed.]

Pharmacological Laboratory, WM. SALANT, *Acting.*

### Chief Food and Drug Inspector, W. G. CAMPBELL.

### Miscellaneous Division, J. K. HAYWOOD, *Chief.*

Water Laboratory, W. W. SKINNER, *Chief.*

Cattle-Food and Grain Laboratory, J. S. CHAMBERLAIN, *Chief.*

Insecticide and Fungicide Laboratory, C. C. McDONNELL, *Chief.*

Trade Wastes Laboratory, *under Chief of Division.*

### Contracts Laboratory, P. H. WALKER, *Chief.*

### Dairy Laboratory, G. E. PATRICK, *Chief.*

### Food Research Laboratory, M. E. PENNINGTON, *Chief.*

### Leather and Paper Laboratory, F. P. VEITCH, *Chief.*

### Microchemical Laboratory, B. J. HOWARD, *Chief.*

### Sugar Laboratory, A. H. BRYAN, *Acting.*

### Nitrogen Section, T. C. TRESCOT, *in Charge.*

### Special Investigations:

Physiological Chemistry (Animal), F. C. WEBER, *in Charge.*

Physiological Chemistry (Vegetable), J. A. LE CLEEC, *in Charge.*

Bacteriological Chemistry, G. W. STILES, *in Charge.*

Enological Chemistry, W. B. ALWOOD, *in Charge.*

### Food and Drug Inspection Laboratories:

Boston, B. H. SMITH, *Chief.*

Buffalo, W. L. DUBOIS, *Acting.*

Chicago, A. L. WINTON, *Chief.*

Cincinnati, B. R. HART, *Acting.*

Denver, A. E. LEACH, *Chief.*

Detroit, H. L. SCHULZ, *Acting.*

Galveston, T. F. PAPPE, *Acting.*

Honolulu, Hawaiian Islands, R. A. DUNCAN, *Acting.*

Kansas City, Mo., A. V. H. MORY, *Acting.*

Nashville. [Not appointed.]

New Orleans, C. W. HARRISON, *Chief.*

New York, R. E. DOOLITTLE, *Chief.*

Omaha, S. H. ROSS, *Acting.*

Philadelphia, C. S. BRINTON, *Chief.*

Pittsburg, M. C. ALBRECHT, *Acting.*

Portland, Oreg., A. I. KNISELY, *Acting.*

St. Louis, D. B. BISBEE, *Acting.*

St. Paul, A. S. MITCHELL, *Chief.*

San Francisco, R. A. GOULD, *Chief.*

Savannah, W. C. BURNET, *Acting.*

Seattle, H. M. LOOMIS, *Acting.*

Issued July 3, 1909.

U. S. DEPARTMENT OF AGRICULTURE,

BUREAU OF CHEMISTRY—BULLETIN No. 126.

H. W. WILEY, Chief of Bureau.

---

# THE HARMFUL EFFECTS OF ACETANILID, ANTIPYRIN, AND PHENACETIN.

By


L. F. KEBLER, PH. C., M. D.,

*Chief, Division of Drugs,*

WITH THE COLLABORATION OF

DRS. F. P. MORGAN AND PHILIP RUPP,

*Assistant Chemists.*



WASHINGTON:

GOVERNMENT PRINTING OFFICE.

1909.

QP 971  
K23  
1909

## LETTER OF TRANSMITTAL.

---

U. S. DEPARTMENT OF AGRICULTURE,  
BUREAU OF CHEMISTRY,  
*Washington, D. C., February 6, 1909.*

SIR: I have the honor to submit for your inspection and approval a report containing the results of inquiries made by the Division of Drugs in order to obtain reliable information in regard to the harmful effects of acetanilid, antipyrin, and phenacetin. The investigation was undertaken at this time because the attention of the Bureau of Chemistry has been drawn to the subject in connection with the labeling in accordance with the food and drugs act, of drug products containing one or more of these agents. I recommend that this report be published as Bulletin 126 of the Bureau of Chemistry.

Respectfully,


H. W. WILEY,  
*Chief of Bureau.*

Hon. JAMES WILSON,  
*Secretary of Agriculture.*

# CONTENTS.

---

	Page.
Summary of data collected.....	5
Reports of physicians with regard to personal experience in the use of acetanilid, antipyrin, and acetphenetidin (phenacetin).....	9
An inquiry regarding the importance of ill effects of these agents, conducted by the British Medical Association .....	20
Literature on poisoning by acetanilid, antipyrin, and acetphenetidin (phenacetin) .....	21
Acetanilid .....	21
Introductory résumé.....	21
Abstracts of acetanilid cases.....	25
Antipyrin .....	46
Introductory résumé .....	46
Abstracts of antipyrin cases .....	47
Acetphenetidin (phenacetin) .....	79
Introductory résumé .....	79
Abstracts of acetphenetidin (phenacetin) cases.....	80



## THE HARMFUL EFFECTS OF ACETANILID, ANTIPYRIN, AND PHENACETIN.

### SUMMARY OF DATA COLLECTED.

Acetanilid, antipyrin, and acetphenetidin (phenacetin) were introduced as remedial agents in 1886, 1884, and 1887, respectively. They were at first used almost exclusively for the reduction of the body temperature in the febrile diseases, but as time went on they were employed less and less for this purpose, particularly in asthenic cases, because of their depressing effects. On account of their analgesic properties, however, they gradually came into use more and more for the relief of pain, and at the present time this may be said to constitute their most important field of usefulness. At the time when they were employed principally as antipyretics their use was directed by the physician, and they were administered with medical skill and judgment. In time, however, these agents became better known as analgesics and were used more and more by the public at large, without medical supervision, for the relief of headache and other minor aches and pains, and at the present time they are used extensively in this way, largely in the form of proprietary preparations. The indiscriminate and often ill-advised use of these drugs by the laity has been productive of bad effects in many instances. Furthermore, the number of reported cases of poisoning by these agents or preparations containing them has increased notably during the last few years.

Since the passage of the food and drugs act, June 30, 1906, the attention of the Department of Agriculture has been directed to this subject, particularly in connection with the branding of drug products containing one or more of these agents, and an attempt has been made to obtain full and reliable information in regard to their poisonous qualities. That there is considerable diversity of opinion on this subject is evident from the testimony given by the medical experts in the recent case of the United States *v.* R. N. Harper. Mr. Harper was the proprietor of a remedy known as "Harper's Cuforhedake Brane-Fude," which contained among other ingredients acetanilid and antipyrin. At this trial one of the physicians testified that whereas he had formerly used acetanilid rather freely he now prescribed it very guardedly, because of the unexpected and untoward effects which had been found to follow its use. Another expert testified that whereas he had formerly used it in his practice he did

not use it now, because in his experience it had proven uncertain in effect and untrustworthy. Still another said he did not use it at all, and when asked why, said, "I am afraid of it." But a fourth physician stated that he employed it to good advantage, and that though he often noted "bluing of the skin," or cyanosis, he regarded this symptom merely as a "signal" or warning as to the further administration of the drug.

Recent investigation indicates that all three of these drugs are now used less than formerly by medical practitioners. Of the physicians who gave information on this subject in reply to an inquiry by the Department of Agriculture, 66 per cent state that they use acetanilid less frequently than formerly, nearly 66 per cent made the same statement with regard to antipyrin, and 51.2 per cent with regard to phenacetin. The reason given referred in almost every instance to the toxic properties of these agents, particularly their depressing effect upon the heart. The fact that they are poisons in the true sense of the word is recognized by members of the medical profession, but it is doubtful whether the general public is aware either of this fact or that they possess any possibilities for harm whatever. Certainly there is nothing to indicate an appreciation of these qualities on the part of the laity if one can judge from the ever-increasing sale to the public of these drugs and preparations containing them. It therefore appears that the people in general should be informed of their poisonous properties and of the injurious effects which may follow their ill-advised, prolonged, or habitual use. To this end, the Department has recently instituted an investigation to determine as far as possible the status of acetanilid, antipyrin, and phenacetin as toxic agents. The investigation was conducted along two lines: First, an inquiry addressed to medical practitioners in the United States with regard to their personal experience with these drugs; and second, a study of the cases of poisoning recorded in medical literature. The results of this investigation are set forth in the following pages.

The purpose of the inquiry was not to depreciate in any way the value of these substances as medicinal agents, but rather to furnish information to the public which would enable them to understand that these remedies should be employed with caution in the absence of reliable medical advice, as can readily be seen from the following correspondence which passed between the Department and one of the physicians who furnished information in reply to inquiries with regard to his personal experience with these drugs:

I have been using acetanilid now nearly eleven years, observing the following rules without any but the desired results, either immediate or remote, as far as my observation goes.

Never give more than 2.50 grains at a dose.

Never give acetanilid or any like preparation when there is reason that some drug should be given to support the heart while this drug is acting.

Give it as a rule for its sedative effect on the nervous system during sthenic fevers rather than as an antipyretic.

You have not asked for the above, but I can not help thinking that the war made on these drugs is carrying the matter to the extreme, and that their disfavor is due rather to the excessive dosage and promiscuous usage than to the fact that they are drugs not to be used at all, and in your investigation I would ask your earnest consideration of this aspect of the case.

To this communication the Department of Agriculture replied as follows:

Your favor of June 9 at hand and in reply we desire to thank you for the information submitted. With regard to the effects of acetanilid we would say that our views accord fully with your own as set forth in your communication, and we would be pleased to publish your letter in the forthcoming bulletin of the Department of Agriculture if it can be used to advantage and if you have no objection. We agree with you that the harm done by acetanilid does not result from its proper use under the direction of the physician, but is mainly the result of the promiscuous and indiscriminate use of the product by the laity. The object of our investigation is not to conduct a war against acetanilid and similar drugs, as you suggest, but rather to throw safeguards around the public and thus prevent, as far as possible, a repetition of the many unfortunate accidents which are reported to have resulted from the ill-advised use of these remedies in the past.

Much has already been accomplished along this line through the agency of the food and drugs act, which requires that the label of medicinal preparations shall contain information relative to the quantity or proportion of certain ingredients, which are enumerated in the law, and their derivatives and preparations. By far the greater number of manufacturers have shown a disposition to comply with the law in declaring the prescribed drugs, but an investigation shows that many preparations containing these or other dangerous agents bear statements which transgress the section of the law on misbranding. The misrepresentation in many instances takes the form of assertions to the effect that the remedy is harmless or that it contains no poisonous or harmful ingredients. Again, the public is given to understand in many cases that the medicine can be taken practically ad libitum until the desired effect is obtained.

Some of the manufacturers of acetanilid preparations, not content with claiming that their products contain no poisonous or harmful ingredients, go even further and assert that the medicine, in addition to being an efficient remedy, acts as food or nourishment for the up-building of some particular part of the body; that it is, in short, a "nerve food" or a "brain food." With regard to this use of the word "food" the judge in the case above referred to in his charge to the jury spoke as follows:

If that word ["brain food"], spelled in the two different ways that it is spelled, would convey to the ordinary citizen the idea that it was a food for

the brain as contradistinguished from the idea of a food for the whole body, then it is—and I so charge you in this first prayer—misleading, and therefore a violation of the law.

The information submitted in the following pages with regard to the number of instances quoted in the literature of the subject in which poisoning, death, or habitual use has been known to result from the administration of acetanilid, antipyrin, and acetphenetidin is summarized in section A of the table following.

The information as tabulated in section B was furnished by 400 physicians, in reply to letters of inquiry issued by the Department. Nine hundred and twenty-five of these letters were sent out, and 400 replies were received. Granting that the 525 physicians who did not reply had no cases to report, the question may profitably be asked, if 925 physicians have observed 814 cases of poisoning by these drugs, 28 deaths which were attributed to their use, and 136 instances of habitual use, how many such cases have in all probability been observed by the 125,000 physicians scattered throughout the United States? The first summary, C, includes both the number of cases recorded in medical literature and those reported by physicians.

*Cases in which deleterious or fatal effects have been produced by acetanilid, antipyrin, and acetphenetidin.*

A. CASES RECORDED IN MEDICAL LITERATURE, 1884-1907.

Substance.	Poisoning.	Deaths.	Habitual use.
Acetanilid.....	297	13	32
Antipyrin.....	488	10	.....
Acetphenetidin.....	70	3	1
Total.....	855	26	33

B. DATA REPORTED BY PHYSICIANS.

Acetanilid.....	614	16	112
Antipyrin.....	105	5	7
Acetphenetidin.....	95	7	17
Total.....	814	28	136

C. TOTAL OF COLLATED CASES (A AND B).

Acetanilid.....	911	29	144
Antipyrin.....	593	15	7
Acetphenetidin.....	165	10	18
General total.....	1,669	54	169

REPORTS OF PHYSICIANS WITH REGARD TO PERSONAL EXPERIENCE IN THE USE OF ACETANILID, ANTIPYRIN, AND ACET-PHENETIDIN (PHENACETIN).

For the purpose of obtaining information with regard to the poisonous effects of acetanilid, antipyrin, and phenacetin from the viewpoint of personal experience and observation, the following letter of inquiry was addressed by the Department of Agriculture to medical practitioners in the United States:

UNITED STATES DEPARTMENT OF AGRICULTURE,  
BUREAU OF CHEMISTRY,  
*Washington, D. C., June 1, 1908.*

DEAR SIR: We are collecting information relative to the poisonous nature of acetanilid, antipyrin, and phenacetin, and in order to make the data as complete as possible I am sending you a number of questions and would ask that you supply the information requested at your earliest convenience. If there is not sufficient space allowed to give all the data you may possess it is expected that you will use the blank pages of the folder, making the statement as concise as possible.

The information requested is for the use of the Department in compiling a bulletin, and general credit will be given for all data supplied. An early reply will be much appreciated.

Respectfully,

H. W. WILEY, *Chief.*

Following are the questions referred to in this communication, the inquiries relating in each instance to the three drugs—acetanilid, antipyrin, and phenacetin:

1. To what extent do you use these drugs in your practice?
2. What dose do you ordinarily prescribe for adults?
3. Do you prescribe them more or less frequently than formerly? Why?
4. What is your opinion with regard to the relative safety of these three drugs?
5. Have you observed instances of acute or chronic poisoning or cyanosis caused by these drugs? How many of each?
6. In what form was the drug administered?
7. About what dates did the poisoning occur?
8. Were the patients adults or children?
9. For what ailment was the drug taken?
10. Was it ordered by a physician?
11. Was it used internally or externally?
12. Quantity taken?
13. Give brief history of cases observed by you, omitting details.
14. Have you observed any cases of habitual use of any of these drugs or of any preparations containing them?
15. In what form was the drug taken?
16. Were there any ill effects? Give brief description.
17. Were there any protracted ill effects?
18. Give a brief clinical history of each case.

This letter of inquiry was sent to physicians throughout the United States, the object being to secure information which would represent

as closely as possible the conditions existing among the people at large, so far as the harmful effects of acetanilid, antipyrin, and phenacetin are concerned. Much information relative to poisoning by these drugs could have been obtained from the records of hospitals, particularly those located in the larger cities, but it was thought that information from this source would not be of a strictly representative character. The conditions affecting hospital patients differ from those surrounding patients in private homes, and this difference is particularly marked in the case of the drugs under consideration. For this reason it was deemed advisable to secure the desired information from physicians at large rather than from hospital records.

Four hundred replies were received to the 925 letters sent out, and the information submitted is set forth in the following pages.

QUESTION 1.—TO WHAT EXTENT DO YOU USE THESE DRUGS (ACETANILID, ANTIPYRIN, PHENACETIN) IN YOUR PRACTICE?

Extent of use.	Number of replies.		
	Acetanilid.	Antipyrin.	Phenacetin.
Frequently .....	90	9	109
Moderately .....	30	11	38
Occasionally .....	62	51	73
Rarely .....	100	99	86
Only in pertussis .....		14	
Externally .....	6	8	
Never .....	112	208	94
Total number of observers .....	400	400	400

From this it would appear that acetanilid is used frequently or moderately by 120, or 30 per cent, of the physicians; antipyrin by only 20, or 5 per cent; and phenacetin by 147, or 36.7 per cent. On the other hand, 112, or 28 per cent, of the physicians state that they do not use acetanilid at all; and 100, or 25 per cent, use it but rarely; 208, or 52 per cent, never use antipyrin, and 90, or 25 per cent, use it but rarely; 94, or 23.5 per cent, of observers never use phenacetin; and 86, or 21.5 per cent, employ it but rarely.

Thus, of the three drugs phenacetin appears to be most used by physicians, with acetanilid second, while antipyrin is apparently used to a much less extent than either of the others, only 5 per cent of the physicians stating that they employ it frequently or moderately. The reason for the more extensive use of phenacetin is undoubtedly to be found in the fact that it is generally regarded as being the least harmful of these agents. This was indicated particularly in the answers to question No. 4.

## QUESTION 2.—WHAT DOSE DO YOU ORDINARILY PRESCRIBE FOR ADULTS?

Acetanilid.		Antipyrin.		Phenacetin.	
Dose.	Number of observers.	Dose.	Number of observers.	Dose.	Number of observers.
<i>Grains.</i>		<i>Grains.</i>		<i>Grains.</i>	
0.5.....	1	0.5 to 2.5.....	1	0.5 to 5.....	1
0.5 to 1.....	2	1.....	1	1.....	1
0.5 to 10.....	1	1 to 2.....	2	1 to 2.....	1
1.....	1	1 to 10.....	1	1 to 2.5.....	1
1 to 2.....	2	1.5.....	1	1 to 5.....	2
1 to 3.....	7	2.....	1	1.5 to 2.5.....	4
1 to 5.....	2	2 to 3.....	2	2.....	10
1.5.....	1	2 to 4.....	3	2 to 3.....	13
2.....	25	2 to 5.....	5	2 to 4.....	5
2 to 3.....	15	2.5.....	4	2 to 5.....	31
2 to 4.....	9	3.....	3	2 to 6.....	1
2 to 5.....	19	3 to 5.....	15	2 to 7.5.....	1
2 to 7.5.....	1	3 to 10.....	1	2 to 10.....	1
2.5.....	18	3 to 15.....	1	2 to 20.....	1
2.5 to 3.....	9	3.5.....	1	2.5.....	16
3.....	32	4.....	1	2.5 to 7.5.....	1
3 to 3.5.....	3	4 to 5.....	1	3.....	4
3 to 4.....	2	4 to 6.....	1	3 to 5.....	27
3 to 5.....	39	5.....	25	3 to 6.....	2
3 to 6.....	2	5 to 7.5.....	8	3 to 8.....	3
3 to 7.5.....	1	5 to 10.....	26	3 to 15.....	1
3.5.....	9	5 to 15.....	5	4.....	3
4.....	6	7.5.....	5	4 to 5.....	2
4 to 6.....	1	7.5 to 15.....	8	4 to 8.....	4
4 to 12.....	1	8.....	2	5.....	87
5.....	38	8 to 10.....	1	5 to 6.....	1
5 to 7.5.....	3	10.....	16	5 to 7.5.....	14
5 to 8.....	6	10 to 12.5.....	1	5 to 8.....	2
5 to 10.....	12	10 to 15.....	2	5 to 10.....	35
6 to 10.....	1	10 to 20.....	2	5 to 15.....	3
7.....	1	12 to 15.....	1	6.....	2
7.5.....	2	12.5.....	1	7 to 8.....	1
7.5 to 10.....	1	15.....	1	7 to 10.....	2
10.....	1	Up to 20.....	1	7.5.....	1
				8.....	2
				8 to 10.....	1
				10.....	7
				10 to 12.....	1
				10 to 20.....	2

## SUMMARY.

Number stating dose..	274	Number stating dose..	150	Number stating dose..	297
Number who did not..	14	Number who did not..	42	Number who did not..	9
Number who used drug.....	288	Number who used drug.....	192	Number who used drug.....	306
Number who did not..	112	Number who did not..	208	Number who did not..	94

From this it would appear that out of 274 observers who stated that they use acetanilid 17, or 6.2 per cent, employ less than 2 grains as a minimum dose for adults; 113, or 41.2 per cent, employ 2.5 grains or less as a minimum dose; and 155, or 56.5 per cent, employ from 3 to 5 grains as a minimum dose. Two hundred and forty, or a little over 87.5 per cent, never exceed a dose of 5 grains, and 34, or not quite 12.5 per cent, employ doses exceeding 5 grains.

With regard to antipyrin only 23, or 15.3 per cent of the 150 observers who stated that they use this drug, exceed a dose of 10 grains, while 66, or 44 per cent, never exceed a dose of 5 grains;

and 109, or 72.6 per cent, employ 5 grains or less as a minimum dose.

Out of 297 observers using phenacetin 10, or 3.3 per cent, employ less than 2 grains as a minimum dose; 90, or 30.3 per cent, employ 2.5 grains or less as a minimum dose; 188, or 63.3 per cent, employ from 3 to 5 grains as a minimum dose; 89, or 29.9 per cent, use doses exceeding 5 grains; while 208, or 70 per cent, never exceed a dose of 5 grains.

From this it seems reasonable to conclude that the doses of these remedies which are prescribed to-day are much smaller than those which were formerly employed. The report of the therapeutic committee of the British Medical Association with regard to the ill effects of acetanilid, antipyrin, and phenacetin, published in 1894, a summary of which appears on page 20, made a deep impression on the medical mind, and undoubtedly did much to bring about a more conservative use of these drugs, particularly so far as dosage is concerned. The committee concluded from its investigation that the ill effects which had been ascribed to these remedies were very largely the direct result of injudicious and excessive dosage, and in harmony with this conclusion they suggested that they should be used with greater caution in the future. Since that time the doses employed have been smaller than before, and it has been noted that coincidentally with this change the number of accidents resulting from the ingestion of these remedies has fallen off to a remarkable extent. A point of interest in connection with the subject of dosage and frequency of administration was brought out in a recent trial, which involved the misbranding of a certain headache remedy containing among other ingredients acetanilid and antipyrin. The evidence presented showed that the directions for use accompanying many of these acetanilid preparations are not sufficiently definite to safeguard the consumer against a too frequent repetition of the dose, and, in fact, that many of them advised a repetition of the dose until the desired result should be obtained. An examination of a number of prescriptions for adults on file in various pharmacies in Washington, D. C., brought into court as evidence, supplied the following information on these points: (1) The average dose of acetanilid prescribed was 2.43 grains, and of phenacetin 1.92 grains; (2) the average interval between doses was, in case of the two remedies, 3.03 hours.

QUESTION 3.—DO YOU PRESCRIBE THEM MORE OR LESS FREQUENTLY THAN FORMERLY? WHY?

Data.	Number of observers for—		
	Acetanilid.	Antipyrin.	Phenacetin.
Less frequently .....	179	89	143
More frequently .....	13	4	46
To same extent .....	79	42	90
Total number answering this question.....	271	135	279
Total number not answering this question .....	129	265	121

From these figures it would appear that acetanilid is used less frequently than formerly by 66 per cent of the observers, antipyrin by 65.9 per cent, and phenacetin by 51.2 per cent. Acetanilid is employed to about the same extent as formerly by 29.1 per cent, antipyrin by 31.1 per cent, and phenacetin by 32.2 per cent of observers. Only 4.7 per cent use acetanilid and 16.4 per cent use phenacetin more frequently than formerly. The reasons given for the less frequent use of these drugs are in most instances their toxicity and particularly their depressing effects.

QUESTION 4.—WHAT IS YOUR OPINION WITH REGARD TO THE RELATIVE SAFETY OF THESE DRUGS?

Fifty-eight observers replied that acetanilid was the least dangerous, 18 named antipyrin, and 231 named phenacetin. Thirty-seven, or over 10 per cent, stated that in their opinion there is but little difference between the three as far as toxicity is concerned, one being about as powerful a depressant as the others. Fifty-six did not reply to this question. The figures indicate that phenacetin is regarded as the least dangerous of these three agents by 231 out of 344 observers, or 67.4 per cent; acetanilid by 58 observers, or 16.8 per cent; and antipyrin by 18, or 5.2 per cent.

QUESTION 5.—HAVE YOU OBSERVED INSTANCES OF ACUTE OR CHRONIC POISONING OR CYANOSIS CAUSED BY THESE DRUGS? HOW MANY OF EACH?

Effects produced.	Number of cases.		
	Acetanilid.	Antipyrin.	Phenacetin.
ADULTS.			
Acute poisoning.....	284	69	48
Chronic poisoning .....	42	.....	2
Cyanosis.....	213	14	28
Acute, fatal .....	10	4	6
Total number of cases reported .....	549	87	84
CHILDREN.			
Acute poisoning.....	54	17	10
Cyanosis.....	4	.....	.....
Acute, fatal .....	7	1	1
Total number of cases reported.....	65	18	11
Total number of cases, adults and children.....	614	105	95

Out of 288 practitioners who submitted an answer to this question in regard to acetanilid, 219, or 76 per cent, stated that they had observed instances of poisoning following the use of this drug. These 219 observers report 614 cases of poisoning, including 17 deaths. Eighty-nine, or 46.3 per cent, of the 192 physicians who submitted similar information with regard to antipyrin stated that they had observed toxic effects and reported 105 cases, including 5 deaths. Of 306 physicians who submitted data on phenacetin, 66, or 21.5 per cent, reported 95 cases of poisoning, including 7 deaths.

Of the 614 cases of poisoning which are said to have resulted from the ingestion of acetanilid, 17, or 2.7 per cent, terminated fatally; of the 105 cases of antipyrin poisoning, 5, or 4.7 per cent, resulted fatally; and of the 95 cases of poisoning by phenacetin, 7, or 7.3 per cent, terminated fatally. Additional information with regard to the fatal cases follows:

## ACETANILID.

Pneumonia (child)-----	One-half grain every two hours until 2 grains were taken.
Capillary bronchitis (child) --	Small doses frequently repeated.
Capillary bronchitis (child) --	Small doses frequently repeated.
Typhoid-----	Five grains every four hours.
Headache-----	About 20 grains.
Headache-----	Thirty grains (?)
Headache-----	"Orangeine" taken freely.
Headache-----	Thirteen or fourteen 5-grain doses in twelve hours.
Headache-----	Bromo-seltzer.
Neuralgia-----	Dose not given.
Neuralgia of heart-----	Five 5-grain doses in five hours.
Burn-----	Boroacetanilid applied freely.
Burn (infant)-----	Acetanilid applied freely to umbilical cord.
Headache-----	Excessive dose of "bromo-seltzer."
Typhoid (child)-----	Five grains.
Typhoid (child)-----	Dose not given.
Malaria (child)-----	One and one-half grains.

## ANTIPYRIN.

Pneumonia-----	Ten grains every two to three hours. Death on third day.
Fever (child)-----	Twenty grains. Death in two hours.
Acute rheumatism-----	Antipyrin dispensed instead of "Aspirin." Quantity not stated. Patient died suddenly.
Headache-----	Ten grains, followed by 15 grains in an hour.
Neuralgia-----	Five grains every three to four hours. One drachm taken in two days.

## PHENACETIN.

Pneumonia.....	Seventy grains daily for two days; died suddenly.
Influenza.....	Five grains every three hours; not over 6 doses.
Bronchitis (1 year).....	Two grains every three hours; five doses; died twelve hours after last dose.
Typhoid.....	Two and one-half grains every two hours until 1 scruple was taken.
Headache.....	Ten grains.
Headache (cerebral tumor).....	Fifteen grains in twelve hours.
Woman, aged 76.....	Two 3-grain doses two hours apart.

## QUESTION 6.—IN WHAT FORM WAS THE DRUG ADMINISTERED?

[In cases of poisoning.]

Form.	Number of cases.		
	Acetanilid.	Antipyrin.	Phenacetin.
Powder.....	425	86	81
Tablets.....	163	1	10
Pills.....	6	.....	.....
In solution.....	4	11	1
Form not stated.....	16	7	3

The form in which the drug was administered in the cases of poisoning above mentioned is set forth in the accompanying table. Proprietary preparations containing acetanilid were reported to have been used in 77 or 12.5 per cent of the cases.

## QUESTION 7.—ABOUT WHAT DATES DID THE POISONING OCCUR?

Year.	Number of cases.			Year.	Number of cases.		
	Acetanilid.	Antipyrin.	Phenacetin.		Acetanilid.	Antipyrin.	Phenacetin.
1888.....	6	5	.....	1901.....	16	.....	.....
1889.....	1	1	.....	1902.....	16	2	3
1890.....	6	3	.....	1903.....	26	.....	3
1891.....	2	4	.....	1904.....	17	1	5
1892.....	2	1	2	1905.....	32	.....	5
1893.....	7	.....	2	1906.....	25	1	4
1894.....	4	6	.....	1907.....	18	3	7
1895.....	8	3	2	1908.....	18	.....	3
1896.....	7	7	1	No date	.....	.....	.....
1897.....	13	3	.....	given.....	325	55	52
1898.....	28	5	5	Total...	614	105	95
1899.....	10	3	.....				
1900.....	27	2	1				

## QUESTION 8.—WERE THE PATIENTS ADULTS OR CHILDREN?

Age of patient.	Number of cases.		
	Acetanilid.	Antipyrin.	Phenacetin.
Adults.....	549	87	84
Children.....	65	18	11
Total.....	614	105	95

## QUESTION 9.—FOR WHAT AILMENT WAS THE DRUG TAKEN?

Ailment.	Number of cases.			Ailment.	Number of cases.		
	Acetanilid.	Antipyrin.	Phenacetin.		Acetanilid.	Antipyrin.	Phenacetin.
ADULTS.				CHILDREN.			
Headache.....	380	25	41	Headache.....	3	.....	.....
Pain.....	46	15	4	Fever.....	44	5	11
Fever.....	83	43	34	Pertussis.....	.....	10	.....
Vomiting.....	.....	.....	1	Colic.....	1	.....	.....
Pertussis.....	.....	1	.....	Convulsions.....	.....	1	.....
Accidentally.....	1	.....	.....	Externally to wounds.....	5	.....	.....
Suicidal intent.....	1	.....	.....	Not stated.....	12	2	.....
Externally to wounds.....	9	.....	.....	Total.....	65	18	11
Not stated.....	29	3	4				
Total.....	549	87	84				

## QUESTION 10.—WAS IT ORDERED BY A PHYSICIAN?

Administration.	Number of cases.		
	Acetanilid.	Antipyrin.	Phenacetin.
By order of physician.....	289	79	69
Without physician's prescription.....	325	26	26
Total.....	614	105	95

These figures show that in more than one-half of the cases of poisoning the drugs were taken by direction of a physician. This fact is especially significant in connection with the ever-increasing sale of these agents, and preparations containing them, directly to the public. In such cases the remedy is taken by the patient without proper medical advice and supervision, and its administration is not surrounded by the safeguards which ordinarily attend the ingestion of medicine which has been prescribed by a physician. Under these circumstances it is not strange that ill effects are observed with comparative frequency. If, moreover, poisoning occasionally results from the use of these remedies even as prescribed by the physician, should not the greatest caution be observed by the laity in taking them without the safeguard of medical advice? The first and most important step in the prevention of these accidents appears to be to impress on the members of the community the fact that these drugs are by no means harmless, but, on the contrary, are capable of producing serious ill effects when used injudiciously.

## QUESTION 11.—WAS IT USED INTERNALLY OR EXTERNALLY?

How used.	Number of cases.		
	Acetanilid.	Antipyrin.	Phenacetin.
Internally.....	600	105	95
Externally.....	14	.....	.....
Total.....	614	105	95

Poisoning resulted from the external application of acetanilid in 14, or nearly 2.3 per cent, of the cases. This is interesting as it illustrates the toxic power of the drug. No poisonous effects are reported to have been observed from the local application of either antipyrin or phenacetin.

## QUESTION 12.—QUANTITY TAKEN IN CASES OF POISONING.

## ADULTS.

Acetanilid.		Antipyrin.		Phenacetin.	
Dose (grains).	Number of cases.	Dose (grains).	Number of cases.	Dose (grains).	Number of cases.
0.5.....	1	2 to 5.....	1	2 to 5.....	1
1.....	1	5.....	2	3.....	2
2.....	8	5 to 10.....	3	3 to 5.....	1
2 to 5.....	1	8.....	1	5.....	10
2 to 10.....	3	10.....	15	5 to 10.....	4
2.5.....	4	10 to 15.....	1	5 to 15.....	1
3 to 3.5.....	11	10 to 20.....	2	10.....	16
3 to 10.....	5	10 to 30.....	5	10 to 12.....	3
4.....	3	15.....	15	10 to 20.....	10
5.....	55	Less than 20.....	5	12.....	1
5 to 6.....	7	20.....	10	15.....	1
5 to 8.....	3	30.....	1	20.....	2
5 to 10.....	91	40.....	1	30.....	2
5 to 15.....	5	45.....	3	70.....	1
7.....	9	60.....	3	90.....	3
10.....	18	Fatal cases <sup>a</sup> .....	4	100.....	1
10 to 15.....	21	Dose not stated.....	15	Fatal cases <sup>a</sup> .....	6
10 to 20.....	8			Dose not stated.....	19
10 to 60.....	1				
12.....	12				
15.....	13				
15 to 20.....	15				
15 to 25.....	6				
15 to 30.....	21				
20.....	5				
25.....	2				
30.....	23				
40.....	5				
60.....	5				
90.....	1				
120.....	3				
200.....	1				
Teaspoonful.....	1				
External cases.....	9				
Fatal cases <sup>a</sup> .....	10				
Dose not stated.....	162				
Total.....	549	Total.....	87	Total.....	81

## CHILDREN.

0.66.....	1	0.5.....	1	2.....	2
1.....	3	3 to 5.....	1	5.....	1
2.....	2	5.....	1	10.....	1
2 to 3.....	1	8 to 10.....	3	Fatal cases <sup>a</sup> .....	1
3.....	12	10.....	1	Dose not stated.....	6
5.....	6	Fatal cases <sup>a</sup> .....	1		
5 to 6.....	1	Dose not stated.....	10		
Less than 10.....	2				
External cases.....	5				
Fatal cases <sup>a</sup> .....	7				
Dose not stated.....	25				
Total.....	65	Total.....	18	Total.....	11

<sup>a</sup> See page 14.

Out of the 368 cases in which the dose of acetanilid administered to adults was stated, the poisoning was caused by doses of 5 grains or more in 331, or 89.9 per cent; with antipyrin the ill effects were caused by doses of 10 grains or more in 89.7 per cent of the cases, while with phenacetin the toxic effects were caused by doses of 10 grains or more in 67.8 per cent of the cases, and by doses of 5 grains or more in 93.2 per cent of the cases.

In 85.7 per cent of the cases the poisonous effects of acetanilid administered to children were caused by doses of 2 grains or more; with antipyrin the ill effects were due to doses of 3 grains or more in 85.7 per cent of the cases, while with phenacetin no ill effects were reported to have resulted from doses under 2 grains.

QUESTION 13.—GIVE BRIEF HISTORY OF CASES OBSERVED BY YOU, OMITTING DETAILS.

The information submitted in answer to this inquiry is given in connection with the replies to the remaining questions.

QUESTION 14.—HAVE YOU OBSERVED ANY CASES OF HABITUAL USE OF ANY OF THESE DRUGS OR OF ANY PREPARATION CONTAINING THEM?

An endeavor was made to obtain information with regard to the extent to which these drugs are used habitually, as it has long been known that acetanilid, antipyrin, and phenacetin are habit-forming drugs, particularly acetanilid. The habit is acquired in most instances through the use of the remedy without the supervision of the physician for the relief of minor aches and pains, especially headache. These affections are usually of a recurrent character and, the remedy exerting but a palliative effect, the dose after a time must be repeated and in time the patient may become dependent on the drug. Furthermore, the prolonged or habitual use of these agents tends to produce an impaired condition of the general health which, as in all such cases, is accompanied by a lessened resistance on the part of the body to disease. Under these circumstances the affection for which the remedy was originally taken assumes greater proportions than ever, and as a result there is additional call for the drug. Thus a vicious circle is established—more drug, impaired bodily health, lessened resistance, more pain, more drug.

It has been said that in its baneful effects on the system and in the difficulty which is experienced in giving up the use of these drugs in many instances, the habit ranks as an evil with the opium habit. Whether this is true or not, there can be no reasonable doubt that their prolonged or habitual use is decidedly harmful to the system. In spite of this fact, the habitual use of these agents is spreading among the people and it is becoming more and more apparent

that an effort should be made to acquaint the general public with the ill effects which may reasonably be expected to follow such use.

In reply to the inquiry by the Department, 112 instances of the acetanilid habit were reported, 7 of the antipyrin habit, and 17 of the phenacetin habit. It should be remembered, however, that neither these cases nor those which are recorded in medical literature give an adequate indication of the extent to which these drugs are used habitually, inasmuch as only those cases have been reported in which the ill effects were so marked as to call for the services of a physician. Interesting information with regard to the habitual use of these drugs can be obtained by consulting the original reports of the cases recorded in medical literature.

QUESTION 15.—IN WHAT FORM WAS THE DRUG TAKEN?

[In the case of habitual users.]

Form—	Number of cases.		
	Acetanilid.	Antipyrin.	Phenacetin.
Powders.....	29	7	12
Tablets.....	25		4
In solution.....			1
Proprietary preparations containing acetanilid.....	50		
Form not stated.....	8		
Total.....	112	7	17

From this it appears that proprietary preparations were used in at least 50, or 44.6 per cent, of the 112 instances of the habitual use of acetanilid.

QUESTION 16.—WERE THERE ANY ILL EFFECTS? GIVE DESCRIPTION.

The number of cases in which ill effects were observed from the use of acetanilid was 85, from antipyrin 2, and from phenacetin 7. The chief symptoms observed from the habitual use of these drugs may be briefly classified as follows: Nervous depression, 44 cases; cyanosis, 27 cases; anemia, 15 cases; cardiac depression, 18 cases; dyspnea on exertion, 8 cases; insomnia, 4 cases; constipation, 3 cases; loss of memory, 3 cases; icterus, 1 case; muscular twitchings, 1 case; loss of sexual power, 1 case; edema, 2 cases, and increased headache, 2 cases.

QUESTION 17.—WERE THERE ANY PROTRACTED ILL EFFECTS?

The replies submitted in answer to this question show that protracted ill effects were observed in the case of acetanilid in 38 instances, with antipyrin in 2 instances, and with phenacetin in 5 instances. The chronic symptoms most often noted were anemia, general debility, nervousness, and weak and irregular heart action.

## QUESTION 18.—GIVE A BRIEF CLINICAL HISTORY OF EACH CASE.

The information submitted in answer to this question is embodied in the data presented in the preceding pages.

**AN INQUIRY REGARDING THE IMPORTANCE OF ILL EFFECTS OF THESE AGENTS, CONDUCTED BY THE BRITISH MEDICAL ASSOCIATION.**

In 1894 a committee of the British Medical Association known as the "therapeutic committee," of which Dr. D. J. Leech was chairman and Dr. William Hunter honorary secretary, conducted an inquiry with regard to "The importance of the ill effects which occasionally attend the use of the three chief antipyretic and analgesic agents, phenazone (antipyrine), acetanilide (antifebrin) and phenacetin." For the purpose of this investigation a letter of inquiry was sent to medical practitioners in Great Britain requesting information based on personal experience with these drugs. The replies received in answer to this letter furnished much valuable information and the report of the committee<sup>a</sup> contained descriptions of a number of cases of poisoning. The following summaries are taken from the report of the committee, and contain information with regard to the principal effects noted by the different observers.

*Ill effects from the administration of acetanilid, antipyrin, and phenacetin, as observed in Great Britain.*

[When the actual dose which occasioned the ill effect is not stated, the usual dose employed by the observer is given within parentheses.]

Nature of ill effects.	Grains administered.
ACETANILID.	
Alarming collapse more than once.....	(4).
Excessive sweating, cyanosis, feebleness of pulse, and partial collapse, comparatively frequent.....	(2 to 5).
Cyanosis after repeated doses.....	(5 to 10).
Cyanosis on two occasions.....	7 every 4 hours.
Cyanosis and collapse, once after a double dose.....	(10).
Collapse in two children.....	(6 to 10).
Cyanosis and collapse in one or two cases.....	Not stated.
Cyanosis and depression.....	(5).
Do.....	(10).
Cyanosis.....	7½.
Collapse and death.....	Not stated.
Collapse after continuous doses of 7½ grains.....	(5 to 10).
Collapse after 10 grains.....	(2 to 3).
Undue perspiration and depression.....	(5).
Do.....	(8).
Collapse.....	(8 to 10).
Depression.....	(6 to 8).
Palpitation and collapse.....	(2 to 20).
Severe cyanosis after 2 doses of 10 grains each.....	(5 to 8).
Cyanosis once.....	(4 to 8).
Cyanosis, profuse perspiration, and partial collapse.....	(10).
Cyanosis and collapse.....	(8 to 10).
Do.....	(3 to 10).
Do.....	(5 to 10).
Do.....	(8 to 10).
Collapse in phthisis even after 2 grains.....	2.
Alarming collapse in a child by a second dose.....	3.

<sup>a</sup> Brit. Med. J., London, 1894, 1: 85.

*Ill effects from the administration of acetanilid, etc.—Continued.*

Nature of ill effects.	Grains administered.
<b>ANTIPYRIN.</b>	
Weakness and shakiness .....	(20 to 40).
Serious collapse in a case of typhoid fever.....	30 twice.
Syncopal attack on one occasion .....	15.
Symptoms of collapse .....	20.
Enfeebling in its action .....	(5 to 20).
Depressant .....	(12 to 20).
Do.....	(20).
Cardiac weakness and irregularity.....	15 every 4 hours.
Great depression .....	30 at hourly intervals.
Great depression and exhaustion .....	15 every 4 hours.
Alarming depression .....	45 in 8 hours.
Cyanosis and dangerous cardiac depression.....	20.
Do.....	20.
Depressant on heart.....	(15 to 20).
Excessive sweating, cyanosis, and partial collapse .....	(20).
Vasomotor pains, lividity, profuse perspiration, tendency to collapse and to pneumonic congestion.....	(30).
Collapse and death in a case of rheumatic fever.....	80 in 5 hours.
Alarming faintness in anemic individuals.....	(15 to 20).
Languor and depression .....	(15).
Weakening effect in 10 per cent of cases.....	20, repeated in an hour.
Serious collapse in a case of typhoid.....	2 doses of 30.
Loss of speech, lasting 24 hours, in a case of commencing meningitis which subsequently proved fatal .....	7.5, repeated in an hour.
A condition of mania from long-continued use of the drug, recovered from when drug was withheld.....	
Dyspnea and much nervous excitement once out of many hundreds of cases.....	5.
Salivation with urticarial rash twice in same patient .....	10.
Dizziness and loss of power in legs.....	3.
<b>PHENACETIN.</b>	
Collapse on one occasion .....	5 every 3 hours for 3 days.
Extreme weakness, cyanosis, and feebleness of pulse .....	(10 to 15 every 4 hours.)
Cyanosis once .....	7 every 4 hours for 3 days.
Slight giddiness once.....	(5 to 10).
Depression, although not often .....	(5 to 10).
Lividity and diaphoresis.....	(10 to 20).
Subnormal temperature, coldness, shivering.....	(5 every 4 hours).

**LITERATURE ON POISONING BY ACETANILID, ANTIPYRIN, AND ACETPHENETIDIN (PHENACETIN).****ACETANILID.****INTRODUCTORY RÉSUMÉ.**

The following bibliography contains references to the recorded cases of poisoning by acetanilid and preparations containing it, from the date of its introduction as a medicine in 1886 to the end of the year 1907, together with a brief abstract of each case. It was found to be difficult in some cases to draw the line between cases of actual poisoning and cases in which the symptoms were hardly severe enough to justify the use of the word "toxic" in describing them. The word "poisoning" as used in the subsequent pages is intended to include all cases in which unexpected, undesired, and deleterious effects resulted from the ingestion of acetanilid. Thus the recorded cases in which cyanosis was the only untoward symptom observed were included in this report, inasmuch as the cyanosis was an unexpected and undesired effect of the ingestion of the drug in each case and a manifestation of its harmful qualities.

The total number of cases of poisoning herein described is 297 or more, reported by 177 observers. The exact number of cases can not be determined with accuracy, inasmuch as some of the authors refer to the number of cases observed by them under such indefinite terms as "several," "many," "a few," etc. The number of cases reported for each year is set forth in the following table:

*Cases of acetanilid poisoning recorded, 1886-1907.*

Year.	Number of cases.	Percentage of total number of cases by the three agents.	Year.	Number of cases.	Percentage of total number of cases by the three agents.
1886 .....	20	6.7	1898 .....	3	1.0
1887 .....	94	31.5	1899 .....	2	.6
1888 .....	21	7.0	1900 .....	2	.6
1889 .....	23	7.7	1901 .....	6	2.0
1890 .....	27	9.0	1902 .....	2	.6
1891 .....	9	3.0	1903 .....	4	1.3
1892 .....	5	1.6	1904 .....	1	.3
1893 .....	5	1.6	1905 .....	9	3.0
1894 .....	7	2.3	1906 .....	19	6.3
1895 .....	6	2.0	1907 .....	8	2.6
1896 .....	20	6.7			
1897 .....	4	1.3	Total .....	297	.....

Of the total number of cases recorded, 114, or more than one-third (38 per cent), were reported during the year and a half following the advent of acetanilid as a medicinal agent in August, 1886, and 185, or more than one-half (62.2 per cent), were reported during the first four and a half years of its history. The occurrence of so large a proportion of the cases during this period was undoubtedly due in part to the fact that at this time the toxic properties of acetanilid were not understood and its possibilities for harm were not known or appreciated. This is shown by the fact that it was at first used almost entirely as an antipyretic in febrile diseases and was administered rather freely to sthenic and asthenic patients alike, to those suffering from debilitating diseases like typhoid fever, as well as to robust patients suffering merely from minor aches or pains. The results of this free administration were disastrous, and the number of instances in which death was hastened by ill-advised use of acetanilid during the early years of its history can only be surmised. After the drug had been more thoroughly studied, however, and after its injurious effects in many cases had been brought to the attention of the profession, partly through personal experience and partly through reports published in the medical press, its possibilities for harm came to be more fully appreciated and it was used more and more conservatively, particularly in asthenic cases. As a result, the number of cases of poisoning fell off rapidly and during the thirteen years

following 1891 the number averaged but six annually. Since the year 1904, however, there has been a notable increase in the number of cases reported as well as in the number of fatalities. This can be adequately explained by the fact that during recent years the control of acetanilid as a remedial agent has rapidly passed from the hands of the medical profession to those of the laity, owing largely to the advertising efforts of the manufacturers of proprietary medicines, and the increase in the number of cases reported and in the number of fatalities is undoubtedly mainly due to the ill-advised and promiscuous use of acetanilid preparations by the laity for the relief of headache and other minor ills.

Of the 297 cases reported, 13, or 4.3 per cent, terminated fatally. The number of deaths occurring each year is set forth in the following table.

*Fatal cases of acetanilid poisoning, 1886-1907.*

[No cases reported for the years omitted.]

Year.	Number of fatal cases reported.	Percentage of total number of fatal cases.	Year.	Number of fatal cases reported.	Percentage of total number of fatal cases.
1887.....	1	7.6	1905.....	1	7.6
1888.....	1	7.6	1906.....	2	15.2
1890.....	1	7.6	1907.....	3	22.8
1891.....	1	7.6			
1896.....	2	15.2	Total.....	13	.....
1898.....	1	7.6			

It is interesting to note that although 185, or 62.2 per cent, of all the cases were reported during the first four and one-half years of the history of acetanilid as a medicine, the number of deaths from acetanilid poisoning which occurred during this time was only 3 or 1.6 per cent; whereas during the last three years, since the drug has been used more or less indiscriminately by the public, the percentage of fatalities reported has been 16.6 per cent.

In 26, or 8.7 per cent, of the cases reported, poisoning resulted from external application. These cases are of particular interest as they afford an illustration of the toxic power of acetanilid. In one of these cases the poisoning resulted fatally.<sup>a</sup> The following abstract taken from a report by Gartman and Ball in 1897<sup>b</sup> gives an illustration of the clinical picture in this class of cases:

Child, 3½ years old. A scalded area of skin was dressed with three ounces of a 10 per cent ointment of acetanilid. Two days later three ounces were again applied, and the child began to turn blue. The cyanosis deepened until the skin and visible mucous membranes were of a blackish-blue color, and symptoms

<sup>a</sup> Rook, C. W. Poisoning by acetanilid. J. Amer. Med. Assn., 1896, 26: 239.

<sup>b</sup> A case of acetanilid poisoning. Philadelphia Polyclinic, 1897, 6: 381.

of collapse appeared. The ointment was discontinued and the symptoms gradually disappeared.

The symptom which appears most frequently in the recorded cases of poisoning by acetanilid is cyanosis. With but very few exceptions it is a constant symptom, the depth of the discoloration ranging from a mere dusky hue of the skin or mucous membrane to a color which is described as "blackish-blue" or even "black." This symptom was observed from the first and even in Cahn and Hepp's original article, which marked the advent of acetanilid in the world of medicine, cyanosis is casually mentioned as a side effect of the administration of the drug. At that time but little significance was attached to its occurrence. We now know, however, that it is an exceedingly undesirable symptom, inasmuch as it is due to a deterioration in the quality of the blood caused directly by the presence of decomposition products of acetanilid. Accompanying the cyanosis there was observed in most of the cases prostration, which varied in degree from mere depression of the bodily functions to actual collapse.

In addition to these symptoms there were observed in many instances vertigo, faintness, lividity of the face, a pinched and anxious expression, dyspnea, excessive restlessness, increased perspiration, coldness of the extremities, rapid and feeble heart action, and in severe cases, stupor or coma. The occurrence of an eruption on the skin is mentioned in only a very few of the recorded cases. This is also true of disturbances of vision and of the functions of the kidneys.

The habitual use of acetanilid is specifically mentioned in 32, or 10.7 per cent, of the recorded cases of poisoning. This gives no conclusive information, however, as to the actual extent of the acetanilid habit, inasmuch as only those instances of habitual use are recorded in which the ill effects were probably so severe as to cause the patient to seek the advice of a physician. A consideration of the relative number of cases occurring in different years is of value, however, and shows a marked increase in the number of cases of habitual use during recent years, as indicated in the following table:

*Cases of habitual use of acetanilid reported, 1890-1907.*

[No cases reported for the years omitted.]

Year.	Number of cases reported.	Percentage of total number of cases of habitual use.	Year.	Number of cases reported.	Percentage of total number of cases of habitual use.
1890.....	1	3.12	1903.....	4	12.50
1894.....	2	6.24	1905.....	5	15.60
1896.....	2	6.24	1906.....	13	40.62
1899.....	1	3.12	1907.....	2	6.24
1900.....	1	3.12			
1902.....	1	3.12	Total.....	32	.....

The increasing use of proprietary remedies containing acetanilid since the year 1904 is indicated in the published reports, as follows:

*Cases in which the patient is reported to have taken a proprietary preparation, 1891-1907.*

[No cases reported for the years omitted.]

Year.	Number of cases reported.	Percentage for each year.	Year.	Number of cases reported.	Percentage for each year.
1891.....	1	3.7	1906.....	12	41.3
1895.....	1	3.4	1907.....	7	24.1
1896.....	3	10.3			
1905.....	5	17.2	Total.....	29	.....

The use of proprietary preparations containing acetanilid is not mentioned in the reports of cases published during the eight years preceding the year 1905, but in the reports published during 1905 the use of these preparations is indicated in 55.5 per cent of cases. In 1906 the use of these preparations is indicated in 63.1 per cent of the recorded cases, and in 1907 in 87.5 per cent. It is interesting to note that accompanying this rapid increase in the use of proprietary acetanilid preparations during recent years, which indicates a more indiscriminate use of acetanilid by the general public, there has been an increase in the total number of cases of poisoning reported, in the number of fatalities, and in the number of instances of habitual use. In this connection a comparison of the four preceding tables is of interest.

#### ABSTRACTS OF ACETANILID CASES.

1886.

BERNHEIM. L'antifébrine. Rev. méd. de l'est, Nancy, 1886, 18: 699.

One-half of the patients taking acetanilid had cyanosis of the face and extremities; 3.75 grains given to a child produced chills and collapse. Three patients had a chill when the temperature began to rise again.

CAHN, A., und HEPP, P. Das Antifebrin, ein neues Fiebermittel. Centrbl. klin. Med., Leipzig, 1886, 7: 561.

Cyanosis of the face and extremities, varying in intensity, was the only perplexing symptom observed during the administration of acetanilid.

EISENHART, H. Beobachtungen über das Antifebrin. Münch. med. Wochenschr., 1886, 33: 851.

Ingestion of acetanilid was followed by the appearance of a papular eruption covering the entire body.

KRIEGER, G. Antifebrin (Acetanilin) als Antifebrile und Antisepticum. Centrbl. klin. Med., Leipzig, 1886, 7: 761.

Cyanosis of the cheeks and visible mucous membranes was the only ill effect observed during the administration of acetanilid.

LÉPINE, R. Sur l'action de l'acetanilide (antifébrine). *Semaine méd.*, Paris, 1886, **6**: 473.

Doses of more than 7.5 grains of acetanilid, continued for several days, caused cyanosis of the face and extremities.

MOUISSET. Note sur l'emploi de l'acétanilide dans le traitement de la fièvre typhoïde. *Lyon méd.*, 1886, **53**: 309.

Three out of seven cases of typhoid, treated with acetanilid in doses of 7.5 grains, presented symptoms of cyanosis.

RIESE, H. Zur Wirkung des Antifebrin. *Deutsche med. Wochenschr.*, Berlin, 1886, **12**: 835.

Cyanosis of the face and extremities appeared in several cases, particularly in phthisis, following the use of acetanilid. In two cases of pneumonia and one of typhoid the pulse became weak and irregular. Collapse occurred after a single dose of 11.5 grains of acetanilid in a case of phthisis.

#### 1887.

BAUER, F. M. The dangers of antifebrin. *Therap. Gaz.*, Detroit, 1887 (3), **3**: 788.

Author had several times seen cyanosis produced in women by three or four doses of 3.75 grains of acetanilid.

BIRÓ, E. Az acetanilid (antifebrin) hatásáról. *Gyógyászat*, Budapest, 1887, **27**: 217. (Transl. Abs., *Pest. med.-chir. Presse*, Budapest, 1887, **23**: 446.)

(1) Ingestion of 7.5 grains of acetanilid was followed by a severe rigor and an irregular, small pulse. (2) After taking acetanilid for eleven days the patient presented the same symptoms as in case 1, and, in addition, clonic convulsions of the lower extremities.

BOROSNYÖI, L. Az antifebrin mint eskörelleses szer. *Orvosi hetil.*, Budapest, 1887, **31**: 1663. (Transl. Abs., *Pest. med.-chir. Presse*, Budapest, 1888, **24**: 103.)

Author observed cyanosis in all cases of epilepsy treated with large doses of acetanilid.

BOULTON, P. Antifebrin. *Brit. Med. J.*, London, 1887, **1**: 761.

On two occasions marked prostration followed the administration of 15-grain doses of acetanilid to feeble patients.

CAULDWELL, C. M. Antifebrin in the treatment of phthisis. *Med. Rec.*, New York, 1887, **31**: 426.

Cyanosis of the lips and finger nails was noted in 2 cases out of 30 treated with acetanilid, in 7 to 10-grain doses.

DEMIÉVILLE, P. De l'antifébrine comme nervin. *Rev. méd. de la Suisse Rom.*, Genève, 1887, **7**: 305.

(1) In an alcoholic epileptic, 51 years of age, 7.5 grains of acetanilid three or four times a day caused delirium and hallucinations. (2) Several 15-grain doses of acetanilid caused lachrymation and a prickling sensation about the eyes.

DOLL. Mittheilungen aus der Praxis. *Deutsche Med.-Ztg.*, Berlin, 1887, **8**: 817.

Ingestion of 25 pfennigs' worth of acetanilid, about 1.5 tablespoonfuls, in two portions in close succession was followed in about three hours by vomiting, syncope, and collapse.

DUJARDIN-BEAUMETZ. De l'acétanilide comme médicament sédatif du système nerveux. *Bul. gén. therap. (etc.)*, Paris, 1887, **112**: 241.

Author had observed cyanosis following the administration of doses of 7.5 grains of acetanilid in febrile cases, particularly in typhoid.

DULÁCSKA, G. Az acetanilid hatásáról. *Gyógyászat*, Budapest, 1887, **27**: 193. Transl. Abs., *Pest. med.-chir. Presse*, Budapest, 1887, **23**: 444.

Two 3-grain doses of acetanilid at two-hour intervals caused epistaxis in one case and profuse uterine hemorrhage in another. After taking acetanilid a phthisical patient became drowsy and the lips showed moderate cyanosis. In all cases the ingestion of the drug was followed by marked prostration.

EDITORIAL. Antipyrin and antifebrin. *New Orleans Med. and Surg. J.*, 1887, **15** (1): 50.

A patient with remittent fever took 7.5 grains of acetanilid every hour until 0.5 drachm was taken. The temperature fell to 95° and the patient became almost pulseless.

EISENHART, H. Beobachtungen über das Antifebrin. *Münch. med. Wochenschr.*, 1887, **34**: 448.

A 15-grain dose of acetanilid produced cyanosis, and smaller doses caused a mild bluish discoloration of the face. The ingestion of 4 drachms of acetanilid within six days in a case of rheumatism was followed by the development of a morbilliform eruption.

FAURE, J. L. Notes sur les effets de l'acétanilide dans le traitement de "épilepsie. *Compt. rend. soc. biol.*, Paris, 1887 (8), **4**: 401.

The administration of from 7.5 to 37.5 grains of acetanilid daily caused well-marked cyanosis.

FAUST, W. Ueber Antifebrin. *Deutsche med. Wochenschr.*, Leipzig and Berlin, 1887, **13**: 358.

Two doses of 7.5 grains of acetanilid reduced the temperature to 94.2° without symptoms of collapse.

FISCHER, G. Antifebrin gegen lancinirende Schmerzen. *Münch. med. Wochenschr.*, 1887, **34**: 425.

In 2 cases out of 10 cyanosis followed the administration of 7.5 to 22.5 grains of acetanilid.

GOLOUSCHEW. Discussion of paper by Ansserow on "Antifebrin, Antipyrin, und Thallin als Mittel zur Regulirung des Wärmeverlustes bei Fiebernden." *Deutsche med.-Ztg.*, Berlin, 1887, **8**: 234.

Ingestion of 4.5 grains of acetanilid caused collapse.

GUTTMANN, G. Antifebrin, in seiner mannigfaltigen Wirkungsweise. *Berl. klin. Wochenschr.*, 1887, **24**: 942.

In 4 out of 248 cases the ingestion of acetanilid was followed by cyanosis of the lips and cheeks, disappearing within an hour.

HAILES, C. Antifebrin, *Brit. Med. J.*, London, 1887, **1**: 1253.

The administration of 4 grains of acetanilid to a scarlet-fever patient 8 years of age was followed by a rapid fall of temperature and collapse.

HEINZELMANN, H. Zur Casuistik der Antifebrinbehandlung. Münch. med. Wochenschr., 1887, **34**: 36.

Ingestion of 3.75 grains of acetanilid was followed in one case by dilation of the pupils, in another by chilliness and profuse perspiration, and in still another by weakness of the pulse. In a fourth case partial deafness and headache followed the ingestion of 7.5 grains of the drug.

HEUSLER, E. Das Antifebrin. Allg. med. Centr.-Ztg., Berlin, 1887, **56**: 1074.

In 50 cases of typhoid and pneumonia treated with acetanilid, cyanosis occurred in one instance. Average dose, 3.75 grains every six hours.

HUBER, A. Ueber Antifebrin. Cor.-Bl. f. schweiz. Aerzte, Basel, 1887, **17**: 2.

Typhoid. Ingestion of 7.5 grains of acetanilid daily for two days was followed by a papular rash especially marked on the forehead, forearms, and hands. Author had also observed instances in which cyanosis and collapse followed the ingestion of acetanilid.

JACOB, A. Étude clinique sur l'antifébrine ou acétanilide. Nancy, 1887.

In 72 cases, cyanosis was observed in 12 instances following the ingestion of 3.75 to 7.5 grains of acetanilid. Collapse occurred in 2 instances after the ingestion of acetanilid by typhoid-fever patients; once after the administration of 7.5 grains, and again after 3.75 grains. In a case of hemiplegia, a dose of half a drachm was followed by intoxication and nausea lasting four hours. Three and three-fourths grains produced syncope in case of a tubercular patient.

JUNKERMANN, F. A. Antifebrin als Febrifugum und Nervinum. Würzburg, 1887.

In erysipelas, cyanosis was observed to follow the ingestion of doses of 7.5 grains of acetanilid.

MACMULLEN, J. C. On the action of acetanilide. Australas. Med. Gaz., Sydney, 1886-7, **6**: 269.

In at least three cases, a condition closely resembling collapse followed the ingestion of acetanilid.

MATUSOFSZKY, A. Ueber den Heilwert des Antifebrin. Orvos-természettud. Ertesítő. Kolozsvár, 1887. No. 1. (Transl. Abs., Pest. med.-chir. Presse, Budapest, 1887, **23**: 466.)

(1) Cyanosis occurred in a case of phthisis after the ingestion of 0.75 grain of acetanilid four to five times a day. (2) Typhoid. Four doses of acetanilid, 6 grains each, every half hour causes cyanosis and collapse.

MÜLLER, J. Meeting of Soc. de méd. de Strasbourg, Jan. 6, 1887. Gaz. méd. de Strasbourg, 1887, **46**: 35.

Administration of 7.5 grains of acetanilid to a patient with erysipelas 9 years of age caused intense cyanosis of the face.

PÁVAI-VAJNA, G. Ueber die Wirkung des Acetanilid oder Antifebrin. Centrbl. gesam. Therap., Wien, 1887, **5**: 481.

(1) Man, 25, phthisis: Fifteen grains of acetanilid caused cyanosis and collapse. (2) Man, 28, typhoid: Three and three-fourths grains caused cyanosis. (3) Man, 27, pneumonia: Three doses of 3.75 grains at hourly intervals caused profuse perspiration and cyanosis.

SALM, A. Ueber Antifebrin als Antiepilepticum. Neurol. Centrbl. Leipzig, 1887, 6: 241.

Nearly all of 11 epileptic patients treated with acetanilid, 15 to 45 grains a day, presented cyanosis and a dark discoloration of the urine.

SCHTSCHERBAKOW. Ueber den Gebrauch von Antifebrin und Naphtha bei Schwindelkranken. Deutsche med. Ztg., Berlin, 1887, 8: 234.

Acetanilid given by inhalation produced collapse in several cases.

SECRETAN, L. Note sur l'antifébrine. Rev. méd. de la Suisse Rom., Genève, 1887, 7: 36.

(1) Rheumatism: Collapse followed the second dose of 7.5 grains of acetanilid. (2) Tuberculosis: Collapse followed a single dose of 7.5 grains of acetanilid.

SEIFFERT, E. P. A. Ueber Antifebrin und seine Anwendung beim akuten Gelenkrheumatismus. Berlin, 1887.

Youth, 18: Ingestion of 7.5 grains of acetanilid four times a day for two days was followed by cyanosis.

SEXTON, J. C. Acetanilid "Antifebrine." Cincinnati, Lancet Clinic, 1887 (n. s.), 19: 184.

Acute miliary tuberculosis. The ingestion of 15 grains of acetanilid was followed by cyanosis and collapse.

SIPPEL, H. Ueber Antifebrinbehandlung. Münch. med. Wochenschr., 1887, 34: 215.

(1) Three and three-fourths grains of acetanilid caused severe itching of skin. (2) Ingestion of about 100 grains of acetanilid within five days by a phthisical patient was followed by nausea, dizziness, buzzing in the ears, and cyanosis. In one patient 3.75 grains produced partial deafness.

TROST, J. A. Antifebrin. Kansas City Med. Index, 1887, 8: 228.

Remittent fever. Acetanilid, 8 grains every six hours, at end of third day caused cyanosis and collapse.

TRUSSEWITSCH. Discus. of Ansserow: Vergleichung der, die Wärmeverluste ausgleichenden, Wirkung des Antifébrin in fiebernden Organismen mit der des Antipyrin und Thallin. Congress russ. Aerzte zu Moskau. Therap. Monatsh., Berlin, 1887, 1: 107.

Seven and one-half grains of acetanilid caused collapse in a typhoid fever patient 13 years of age.

VINEBERG, H. N. A caution in regard to acetanilide. New York Med. J., 1887, 46: 219.

A typhoid fever patient was given 10 grains of acetanilid every four hours. After 6 doses marked cyanosis appeared, with symptoms of collapse.

VON QUAST, E. A death from antifebrin. (Note by editor of Index.) Kansas City Med. Index, 1887, 8: 229.

The administration of 4 grains of acetanilid every two hours during the day to a child was followed by cyanosis, collapse, and death.

WEILL. De l'action physiologique et thérapeutique de l'acétanilide. Bul. gén. therap., etc., Paris, 1887, 112: 150.

Seven and one-half grains of acetanilid produced cyanosis in a case of typhoid.

WEINSTEIN, N. Ueber Calomel-Antifebrin-Kawa. Wien. med. Bl., 1887, **10**: 305, 340.

(1) Seven and one-half grains of acetanilid produced cyanosis of the face in a woman 22 years of age, with puerperal fever. (2) The same dose caused marked cyanosis in a woman 43 years old, with erysipelas.

WIDOWITZ, J. Antifebrin bei fieberhaften Erkrankungen der Kinder. Wien. med. Wochenschr., 1887, **37**: 572.

Boy, 12, pneumonia: Intense cyanosis of the face and finger tips followed the ingestion of each dose of 3 grains of acetanilid.

WINNETT, H. J. Was it antifebrin? Therap. Gaz., Detroit, 1887 (3), **3**: 646.

Five grains of acetanilid every four hours were ordered for tonsillitis. After 3 doses had been taken there appeared marked cyanosis with rapid and feeble pulse.

1888.

APOTHEKER Ztg., 1888. Poisoning by antifebrine. Abs. in Med. News, Philadelphia, 1889, **54**: 45.

Ingestion of 0.5 drachm of acetanilid twice in twenty-four hours was followed by cyanosis, anxiety, cold perspiration, and great depression.

BRINGIER, J. T. Antifebrine. Med. World, Philadelphia, 1888, **6**: 377.

In typhoid acetanilid in 4-grain doses caused copious sweating, depression of the heart, thoracic oppression. The rise in temperature was in every case accompanied by coldness of the extremities.

DEMME, R. Ueber die Anwendung und Wirkung des Salols, Antifebrins, und Urethans im Kindesalter. Abs. in Internat. klin. Rundschau, Wien, 1888, **2**: 118.

Boy, 11, phthisis: One and one-half grains of acetanilid five times a day causes cyanosis. Acetanilid produced profuse diarrhea and nausea in a girl and a boy suffering from erysipelas.

FREUND, C. S. Ein Fall von Antifebrinvergiftung. Deutsche med. Wochenschr., Leipzig, 1888, **14**: 834.

Man, 29: Took 45 grains of acetanilid at 11 a. m. and again at 2 p. m. By 5.30 p. m. he was deeply cyanotic and his pulse had increased in rapidity to 152. Cyanosis lasted about four days.

HARDY. Brit. Med. J., London, 1888, **1**: 661.

Report of a case in which sudden death followed the eighth administration of a 15-grain dose of acetanilid.

KLIPPEL, C. Antifebrin—Its value as a therapeutic agent. Kansas City Med. Rec., 1888, **5**: 441.

(1) Woman, age 21, acute metritis: Three 4-grain doses of acetanilid at intervals of three hours caused cyanosis and dyspnea; 3-grain doses subsequently gave similar symptoms. (2) In two other cases the symptoms were like those mentioned above, but not so marked.

KRONECKER. Einige Beobachtungen über die Neben-Wirkungen des Antifebrins. Therap. Monatsh., Berlin, 1888, **2**: 426.

Youth, 18, typhoid: Profuse perspiration and collapse, passing into coma, followed the administration of 3 grains of acetanilid.

LÖWENTHAL, L. Zur Wirkung des Antifebrin. Therap. Monatsh., Berlin, 1888, **2**: 428.

Child, 1 year old, pneumonia: Three-fourths of a grain of acetanilid caused severe collapse. After four hours the temperature rose rapidly. There was a tetanic spasm lasting for half a minute.

MERKEL, G. (Handverkauf des Antifebrin.) Münch. med. Wochenschr., 1888, **35**: 899.

(1) Ingestion of ten powders, each containing 7.5 grains of acetanilid, was followed by severe collapse, the patient's life being saved with difficulty. (2) Collapse followed the ingestion of 1.5 drachms of acetanilid taken in divided doses at frequent intervals.

MEYER, J. Antifebrin-Vergiftung. Therap. Monatsh., Berlin, 1888, **2**: p. 259.

Man, 38: Ingestion of 30 grains of acetanilid was followed by cold sweat, dizziness, and headache; cyanosis of the face and mucous membranes, and rapid and feeble pulse.

SCHAPER. Ueber Antifebrin. Deutsche Mil.-ärztl. Zts., Berlin, 1888, **17**: 160.

In typhoid, 7.5 grain doses of acetanilid (45 grains in twelve hours) produced well-marked cyanosis. In pneumonia, acetanilid caused cyanosis.

VOLK. Münch. med. Wochenschr., 1888, **35**: 819.

After taking several doses of acetanilid from the end of a knife blade the patient, a man, became deeply cyanosed, and passed into a condition of collapse and weakness which lasted for several days.

VON HÖRMANN. Antifebrin-Intoxication. Vereinsbl. pflälz. Aerzte, 1888, **4**: 188.

Ingestion of about 0.5 drachm of acetanilid by a woman was followed by deep cyanosis.

#### 1889.

ALISCH. Ueber einen Fall von Antifebrinvergiftung. Therap. Monatsh., Berlin, 1889, **3**: 340.

Man took three doses of acetanilid of 3.75 grains each at hourly intervals. This was followed by a severe headache and dizziness, and later a chill, cyanosis, clonic contractions of the muscles, and rapid, feeble pulse.

ALLISON, W. R. A case of poisoning by antifebrin. J. Amer. Med. Assn., Chicago, 1889, **12**: 103.

Man took by mistake at 5 a. m. about 17 fluid drachms of a mixture containing 1 ounce of acetanilid to 6 ounces of compound elixir of taraxacum. In thirty minutes there was intoxication and desire to sleep. Slept until 10 o'clock. At 3 p. m. he sought a physician, who found deep cyanosis, great prostration, giddiness, cold perspiration; pulse 110, respiration 30.

BRIEGER, L. Eine Antifebrinvergiftung. Therap. Monatsh., Berlin, 1889, **3**: 384.

Patient took 15 grains of acetanilid, and in an hour 7.5 grains more. This was followed by vomiting, deep cyanosis, twitching of the muscles, and double vision.

CHAKANOW. Ein Fall von Vergiftung mittelst Antifebrin. St. Petersburg. med. Wochenschr., 1889, **14** (N. F., **6**): 369.

A dose of 15 grains of acetanilid night and morning was followed by cyanosis, nausea, weakness, shivering, and irregular heart action.

FÜRTH, E. Eine Antifebrinvergiftung. Wien. med. Presse, 1889, **30**: 652.

Sixty-two grains of acetanilid in one dose caused persistent vomiting, cyanosis, shallow and slow breathing, dilation of the pupils, great restlessness, muscular twitching, delirium, and coma.

GIBBONS, J. E. Poisoning by antifebrin. Maryland Med. J., 1889, **21**: 183.

A drachm of acetanilid taken in one dose caused cyanosis and mild collapse.

GREENE, W. S. Failure of antifebrin as an antipyretic. Univ. Med. Mag., Philadelphia, 1888-9, **1**: 228.

Ten grains of acetanilid seriously affected the heart in the case of a well-nourished adult.

HAIGH, J. Effects of antifebrine upon memory. Med. World, Philadelphia, 1889, **7**: 423.

Report of two cases in which gradual loss of memory was caused by the long continued administration of acetanilid.

HALEY, R. A case of antifebrine poisoning. Weekly Med. Rev., 1889, **20**: 371.

Young woman took 4-grain doses of acetanilid frequently for three days. On the third day she suddenly fell from the chair unconscious. Could not talk at first, and later only with difficulty. The face was blue, skin cold, and there was much dyspnea.

HENSCHEN, S. E. Om s. k. konträr verkan af febermedel. Upsala Läkaref. Förl., 1888-9 (4 s.), **24**: 263. Transl. Abs. Schmidt's Jahrb., Leipzig, 1889, **223**: 241.

Two cases in which the administration of acetanilid in doses of 11.25 and 3.75 grains, respectively, was followed by a rise of temperature in typhoid fever patients.

MAHNERT, F. Ueber Intoxicationen mit Antifebrin. Memorabilien Heilbronn, 1889 (N. F.), **9**: 321.

(1) Girl, tuberculosis: Ingestion of 6 grains acetanilid was followed by profuse perspiration, lividity, and cyanosis. (2) Youth, 16, headache: Ingestion of 15 grains acetanilid in 2 doses with a half-hour interval was followed by cyanosis, clammy perspiration, accelerated respiration, and rapid heart action.

MARÉCHAUX. Ein Fall von acuter Antifebrinvergiftung. Deutsche med. Wochenschr., Leipzig, 1889, **15**: 845.

Child, 5 months old, was given 3.75 grains of acetanilid. In two and a half hours there was unconsciousness, cyanosis, and collapse.

MEYER. Fall von Antifebrin-Intoxication. Allg. Med. Centr.-Ztg., Berlin, 1889, **58**: 805.

Girl, 13, headache: Ingestion of less than 15 grains of acetanilid was followed by cyanosis and palpitation of the heart. On another occasion 10 grains in 2 doses, with an interval of one hour, caused similar symptoms.

PAUSCHINGER. Ein Fall von Antifebrin-Vergiftung. Münch. med. Wochenschr., 1889, **36**: 332.

Man, 34: The ingestion of five 15-grain powders of acetanilid at hourly intervals caused vertigo, chilliness, diarrhea, and cyanosis.

PENNEY, E. W. Antifebrin. Times and Register, Philadelphia, 1889, **20** (1): 183.

Two 5-grain doses of acetanilid one hour apart caused collapse in a typhoid-fever patient.

SAYLOR, A. L. Is antifebrin dangerous? Times and Register, Philadelphia, 1889, **20** (1): 134.

A dose of 4 grains of acetanilid to a child 3 years old produced symptoms of collapse.

SEMBRITZKI. Zur Wirkung des Antifebrin. Therap. Monatsh., Berlin, 1889, **3**: 267.

Woman, 28, typhoid fever: Administration of 4.5 grains of acetanilid caused severe symptoms of collapse.

STEIN, J. Zur Kenntniss des Antifebrins und seiner Dosirung. Prag. med. Wochenschr., 1889, **14**: 559.

Author observed that a dose of 1.5 grains of acetanilid produced hallucinations in the weak and aged.

WILDING, J. Toxic effects of 10 grains of antifebrin. Brit. Med. J., London, 1889, **2**: 600.

Young man, pulmonary tuberculosis: Ten grains of acetanilid caused collapse.

1890.

ARMSTRONG, S. T. A case of acetanilide poisoning. Therap. Gaz., Detroit, 1890 (3), **6**: 245.

Man, 28: Took 2 drachms of acetanilid in 8 powders at one-half hour intervals for pain. Although he vomited freely, there followed cyanosis, coma, and symptoms of collapse.

BOKENHAM, T. J., and JONES, E. L. On two cases of poisoning by anilides (Exalgine and Antifebrin). Brit. Med. J., London, 1890, **1**: 288.

Woman, 43, headache: Ingestion of 0.5 drachm of acetanilid in divided doses within two and one-half hours was followed by headache, symptoms of intoxication, cyanosis, and unconsciousness.

FAVRAT, A. Ueber die Anwendung des Antifebrins in refracto dosi beim Typhus Abdominalis und beim Fieber der Phthisiker. (Bern) Leipzig, 1890.

Doses of from 0.75 grain to 1.5 grains of acetanilid given every hour produced chills and cyanosis in 2 cases of typhoid fever.

FERRIS, A. W. Poisoning with acetanilid. Med. Record, New York, 1890, **37**: 587.

Woman, 45: Ingestion of 15 grains of acetanilid at 8 and 10.30 a. m. was followed by deep cyanosis, a pinched expression, depressed temperature, and marked prostration.

HARTGE, A. Eine Antifebrinvergiftung. St. Petersb. med. Wochenschr., 1890 (N. F.), 7: 69.

Student who had been drinking heavily took for insomnia teaspoonful doses of acetanilid from an ounce box until all was taken. Symptoms resembled those of anilin poisoning. Recovery was probably due in part to the fact that the stomach contained so much liquid.

HATTON, J. B. Some untoward effects from antifebrin. Med. Surg. Reporter, Philadelphia, 1890, 62: 372.

(1) Boy, 16, typhoid: Administration of 4 grains of acetanilid was followed by cyanosis and collapse. (2) Man, 52, sciatica: Two 4-grain doses of acetanilid four hours apart caused cyanosis and collapse.

HERMANN, E. Beobachtungen über die Wirkungen und die Anwendungsweise des Antifebrins. Deutsche Med.-Ztg., Berlin, 1890, 11: 865, 875.

(1) Young woman: Two doses of 15 grains of acetanilid with a half hour interval were followed by cyanosis. (2) Following the ingestion of 2 doses of 15 grains of acetanilid the patient felt very weak and was prone to fall asleep whether walking or standing. (3) Ingestion of 1 drachm of acetanilid with suicidal intent was followed by great weakness, cyanosis, and persistent vomiting. (4) Girl, 22, acute rheumatism: The ingestion of 7.5 grains of acetanilid 3 times daily until 5 doses had been taken was followed by the appearance of an urticarial eruption.

MOLLOFF. Discussion of paper by Khakanoff, 1889. Trans. Med. Surg. Reporter, Philadelphia, 1890, 62: 83.

In two cases collapse followed the ingestion of one 7-grain dose of acetanilid.

MOREHOUSE, O. E. Antifebrin rash. Montreal Med. J., 1890-91, 19: 46.

(1) Man, 45, pneumonia: Was given 8 grains of acetanilid, and four hours later 8 grains more. An erythematous rash appeared upon the entire body, lasting six days. (2) Girl, 19, typhoid: Six grains of acetanilid caused the appearance of a rash resembling urticaria on face and chest. Four hours later 5 grains more caused the rash to spread to the arms. Temperature fell, accompanied by sweating. Rash disappeared after five days.

PREININGER, V. Otrava antifebrinem. Časopis lékařů v českých, 1890, 29: 225. Abs., Sajous, 1891, 5: A-2.

Report of a case of poisoning in which acetanilid appears to have had a cumulative effect.

SCOTT, J. T. Some peculiar results following the use of acetanilide in typhoid fever; report of three cases. Cincinnati Lancet-Clinic, 1890 (n. s.), 24: 65.

(1) Child, 3 or 4 years old, typhoid: Six grains of acetanilid 3 times a day caused chills and cyanosis of the entire skin, lasting from one-half hour to one and one-half hours after each dose. Subsequently 3 grains caused a chill, and the administration of the drug was discontinued. (2) Youth, 24, typhoid: Acetanilid, 6 grains 3 times daily, caused on 2 occasions severe chills and profuse sweating. Drug discontinued. (3) Typhoid patient was given from 18 to 24 grains of acetanilid daily. Chills appeared and increased in number and severity until the patient was having 4 or 5 a day. Acetanilid was discontinued and the rigors ceased.

SUTTLE, I. N. Case of antifebrin habit. New Orleans, Med. and Surg. J., 1889-90 (n. s.), 17 (2): 896.

The case is reported to illustrate the insidious onset of the acetanilid habit and its pernicious effect on the blood. Man, with necrosis of the tibia, took acetanilid in large doses for pain. He became addicted to its use, and is said to have taken as much as a teaspoonful at a time. The evil effect on the blood was shown by the excessive pallor of the skin.

TAYLOR, W. H. Report of toxic effect of acetanilid. Cincinnati Lancet-Clinic, 1890 (n. s.), 24: 683.

(1) Woman, 26, advanced in pregnancy, urine contained albumin: At 5 p. m. and 7 p. m. she took 5-grain doses of acetanilid. At 10 p. m. her physician found her greatly prostrated with deep cyanosis, pinched features, subnormal temperature, cool moist skin, and headache. Her temperature remained subnormal for ten days. (2) Woman, 19, six months pregnant: Was given 10 grains of acetanilid for fever. Her temperature fell rapidly to 95°, pulse ran up to 120, and skin became moist and cool. There was slight cyanosis and some prostration.

THOMAS, W. H. Acetanilid. Report of a fatal case. Indiana Med. J., Indianapolis, 1890, 9: 67.

(1) Author expresses the opinion that 5 grains of acetanilid caused the death of a woman suffering from neuralgia of the head and stomach. May 1, at 4 p. m., the patient's temperature was 104 and her pulse 120, full and strong. She was sponged and given 5 grains of acetanilid. Her temperature fell rapidly, accompanied by symptoms of collapse, and she died nine hours after taking the dose. No record of autopsy. (2) Ingestion of 10 grains of acetanilid was followed by symptoms of collapse.

VIERHUFF, J. Ein Fall von Antifebrinvergiftung. St. Petersburg, med. Wochenschr., 1890 (N. F.), 7: 139.

Woman took two teaspoonfuls of acetanilid on an empty stomach. She vomited after drinking milk and then a solution of alum, but cyanosis appeared, and she went into a state of collapse which lasted three hours.

WOLFF, J. Ein Fall von Antifebrinvergiftung. Deutsche Med.-Ztg., Berlin, 1890, 11: 535.

Woman, 40: Took 7.5 drachms of acetanilid with suicidal intent. This was followed by collapse and coma, and in addition hematuria.

#### 1891.

BRONNER, H. Case of pus in the pericardium treated by incision and drainage. Brit. Med. J., London, 1891, 1: 350.

Girl, 11: A single dose of 7.5 grains of acetanilid caused a rapid fall in temperature and symptoms of collapse.

CARE, J. R. Clinical observations of acetanilide. Med. Surg. Reporter, Philadelphia, 1891, 65: 729.

Girl, 14: A 4-grain dose of acetanilid caused cyanosis and collapse.

DUNAGAN, T. M. Subnormal temperature from antifebrin. Memphis Med. Month., 1891, 11: 123.

Man, 40: The ingestion of 14 grains of acetanilid in 2 doses caused cyanosis and subnormal temperature.

EASLEY, E. P. Fatal case of acetanilide poisoning. (Letter to editor.) *Amer. Pract. and News*, Louisville, 1891, **12**: 178.

Woman, 22, took by mistake 24 grains of antikamnia, supposed to represent 18 grains of acetanilid. In a few minutes she was wildly delirious. She then became unconscious. Death occurred about ten hours after ingestion of the drug. There was deep cyanosis of the entire body. Autopsy failed to show any lesion as a cause for death.

HARE, H. A. *Fever: Its pathology and treatment by antipyretics*. Philadelphia and London, 1891, p. 89.

A dose of 5 grains of acetanilid caused collapse in a case of typhoid fever.

HAWKINS-AMBLER, G. A. Antifebrin in typhoid fever. *Brit. Med. J.*, London, 1891, **1**: 172.

(1) Woman, 49, typhoid: Four grains of acetanilid caused collapse.  
(2) Woman, 35, typhoid: A dose of 4 grains of acetanilid caused marked prostration.

HORTON, F. Prolonged subnormal temperature following the administration of antifebrin. *Med. News*, Philadelphia, 1891, **59**: 712.

A typhoid fever patient was given 4 grains of acetanilid and three-fourths of a grain of camphor at 10 a. m., and the same dose at 3 p. m. At 6 p. m. the temperature, which had been 104°, was 97°. It ran between this and 94.6° for forty-eight hours, when it rose rapidly to 104°.

SPENCER. Poisoning by antifebrin. *Canad. Pract.*, Toronto, 1891, **16**: 163.

Child, 5, whooping cough: Ingestion of a drachm of acetanilid taken by mistake caused deep cyanosis and slowed respiration.

#### 1892.

GRIER, W. F. The toxic effects of antifebrin complicated with alcoholism. *Med. Rec.*, New York, 1892, **42**: 511.

Woman, 45: Ingestion of 40 grains of acetanilid within eleven hours caused marked cyanosis, increasing rapidity of the pulse, swelling of the tongue, and great restlessness.

J. W. C. Case of acetanilide poisoning. *Med. Rev.*, St. Louis, 1892, **25**: 412.

Woman, 36, influenza: Took about 40 grains of acetanilid in divided doses within four hours. There followed cyanosis of the face and lips, semi-consciousness, delirium, and symptoms of collapse.

KRONFELD, A. Ueber Antifebrinvergiftung. *Wien. med. Wochenschr.*, 1892, **42**: 1457.

Man, 24: Took 3 drachms of acetanilid with suicidal intent. Within thirty minutes this was followed by dizziness, nausea, pain in the region of the stomach, unconsciousness, and slight cyanosis.

WARFVINGE, F. W. Redogörelse för de förgiftningsfall som förekommit å Sabbatsbergs sjukhus under åren 1879-91. Antifebrin. *Hygiea Stockholm*, 1892, **54** (1): 238.

Reports two cases of poisoning by acetanilid. Both patients recovered.

1893.

BELL, G. Vier Fälle von Antifebrinvergiftung. *Memorabilien*, Heilbronn, 1893, **38** (N. F. 13): 535.

(1) Man, past 70: Ingestion of a heaping teaspoonful of acetanilid was followed by cyanosis and symptoms of depression. (2 and 3) Each patient took one-half teaspoonful of acetanilid. One complained of dizziness, weakness, shortness of breath, and cyanosis of the finger nails, and the other slept for two hours. (4) Woman, 75: Ingestion of an ounce of acetanilid in five days, in teaspoonful doses, was followed by weakness, drowsiness, and dyspnea.

KOKAWA, B. Antifebrin jutokusei Shiken (antifebrin poisoning). *Tokujima Igakkwai Zashi*, 1893, No. 13, p. 8.

1894.

DAVIS, J. S. A report of three cases of addiction to the coal-tar derivatives. *Amer. Med.-Surg. Bul.*, 1894, **7**: 1490.

(1) Man, 63: Chronic bronchitis and cardiac palpitation for two years. Pulse 160 and weak, becoming irregular upon exertion. Anorexia, constipation, cyanosis, varying in degree at different times. Had been addicted to the use of acetanilid for a year, taking 40 to 60 grains daily. Last two months he had been running down until he was confined to bed. Dose of acetanilid was reduced to 10 grains daily. He gradually improved and at end of a year was in fairly good health. (2) Man, 32: Suffered from cyanosis, coldness of extremities, insomnia, anorexia, constipation, nervousness, and anemia. Urine: Specific gravity 1.012, albuminous. Heart, rapid and feeble. Had been taking acetanilid for eight months, 12 to 40 grains daily, and his health had failed rapidly. The drug was entirely withdrawn and after a month he was in fairly good condition. After abstaining for eight months he again contracted the habit and his health again became impaired.

HILBERT, R. Hochgradige Amblyopie nach Gebrauch von Acetanilid. *Memorabilien*, Heilbronn, 1894 (N. F.), **14**: 65.

Ingestion of three 15-grain doses of acetanilid at short intervals caused vertigo and dimness of vision. After twenty-four hours the sight was again normal.

LYNBOMNDROFF, P. F. Sluchai otravleniya antifebrinom (Antifebrin poisoning). *Voyenno-Med. J.*, St. Petersburg, 1894, **181** (unofficial pt., sec. 2): 29.

MORTON, T. S. K. Acetanilid as an antiseptic. *Proc. of the Phila. Co. Med. Soc.*, 1894, **15**: 469.

(1) Infant, 14 months: Large wound in hip, packed with 10 per cent acetanilid gauze. In four hours the temperature dropped 5°, with symptoms of marked depression. (2) Man, 57: Extensive superficial scald. Two drachms of acetanilid dusted over the surface caused cyanosis, excessive yawning, delirium, and symptoms of depression.

WOODS, G. W. The use of acetanilid in medicine and surgery. *J. Amer. Med. Assoc.*, Chicago, 1894, **23**: 100.

The application of acetanilid powder to an ulcerated surface was followed by deep cyanosis of the nose, lips, and tips of the fingers and toes.

1895.

BRIGGS, W. A. Poisoning from the local application of acetanilid. *Occidental Med. Times*. Sacramento, 1895, 9: 596.

The use of acetanilid as a dressing for circumcision in an infant 1 week old was followed by deep cyanosis, pinched expression, and cold extremities.

BROBERG, J. A. Toxic effects from acetanilid applied topically. *Med. News*, Philadelphia, 1895, 67: 664.

The application of acetanilid to the skin of the groins for irritation caused cyanosis.

CARMALT, W. H. Toxic effects from acetanilid applied topically. *Yale Med. J.*, New Haven, 1895-96, 2: 131.

Girl, 18: Acetanilid, applied to an ulcer every four hours for twenty-four hours, caused cyanosis.

HUBBARD, S. D. A case of poisoning due to antikamnia. *Codex Med. Philadelphia*, 1895-96, 2: 198.

Woman, 40: Ingestion of five powders containing antikamnia, 15 grains each, was followed by pallor of face, cyanosis of the nose, ears, eyelids, and extremities, unconsciousness, and symptoms of collapse.

ROSENBERGER, R. C. A case of acetanilid poisoning; recovery. *Philadelphia Polyclinic*, 1895, 4: 460.

Infant, 16 days old: Hemorrhage from umbilicus. Application of a powder of equal parts of acetanilid and boric acid twice daily for three days caused marked cyanosis of face, lips, fingers, and toes, cold extremities, and labored breathing.

SAUTER, C. Cyanotic symptoms after local application of acetanilid. *Louisville Med. Month.*, 1895-96, 2: 341.

Child, 3 years, eczema of neck: A powder consisting of 1 part acetanilid and 3 parts bismuth subnitrate was applied 3 times daily. Second application of a new supply caused deep cyanosis, with labored breathing and other evidences of distress. Symptoms followed every application of the powder.

1896.

——— Acetanilid poisoning. *Med. Brief*, 1896, 24: 86.

Man: Ingestion of eight doses of acetanilid, 15 grains each, within six hours, caused deep cyanosis.

BIGELOW, B. Acetanilid poisoning. *Med. Brief*, 1896, 24: 703.

Ingestion of acetanilid by two patients, both women, caused deep cyanosis, black discoloration of the lips, tongue, intense dyspnea, and complete prostration.

BRINDLEY, A. E. Antifebrin poisoning. *Brit. Med. J.*, London, 1896, 2: 653.

Woman, 33: Admitted to hospital for spinal disorder. Skin and mucous membranes cyanotic. Had been taking kaputine powders secretly for a year. The powders were found to consist mainly of acetanilid. Upon withdrawal the cyanosis disappeared.

BRODNAX, B. H. Poisoning by acetanilid and bismuth. *J. Amer. Med. Assoc.*, Chicago, 1896, 26: 788.

Six cases of cyanosis in children under 18 months of age following the administration of acetanilid.

BUNCE, W. C. Acetanilid poisoning. *Columbus Med. J.*, 1896, **17**: 505.

Man: Ingestion of a heaping tablespoonful of acetanilid caused vertigo, deep cyanosis, unconsciousness, rigidity of the body, and collapse.

EDITORIAL. Poisoning by antifebrin. *Brit. Med. J.*, London, 1896, **2**: 89.

Refers to the death of a young woman from taking "daisy powders" for headache. The powders were found to contain from 3 to 10 grains each of acetanilid.

NEWTON, R. C. A case of poisoning from the external use of acetanilid. *Med. Rec.*, New York, 1896, **49**: 333.

Girl, 4: Application of acetanilid to an ulcer on the hand on two occasions caused vomiting, cyanosis, and collapse.

RINGER, S. Case of antifebrin poisoning. *Brit. Med. J.*, London, 1896, **2**: 195.

Woman, 28: Habitual use of acetanilid in the form of Ellis's daisy headache powders caused cyanosis and headache which required hospital treatment.

ROOK, C. W. Poisoning by acetanilid. *J. Amer. Med. Assoc.*, Chicago, 1896, **26**: 239.

(1) Baby, 4 days old: Powder consisting of equal parts of acetanilid and bismuth was applied in the afternoon and evening to an inflamed area of the skin. Next morning the body was deeply cyanosed, and the child died a few hours later. (2) Application of a similar powder in case of an infant 2 days old caused intense cyanosis.

SPEED, J. M. Acetanilid poisoning. *Med. Brief*, 1896, **24**: 837.

Child, 1 year old: Application of a powder consisting of equal parts of acetanilid and boracic acid to an ulcer caused deep cyanosis and depression and energetic treatment was required to save the child's life.

VOITSEKHOVSKI, N. F. (A case of poisoning by antifebrin.) *Voyenno-med. J.*, St. Petersburg, 1896, **185** (2 Sec.): 16.

WAS, L. Overdose of acetanilid. *Med. Brief*, 1896, **24**: 854.

Three cases of poisoning by acetanilid characterized by slow, weak, and irregular pulse.

1897.

BOLAND, E. S. A caution against the use of antifebrin on extensively blistered surfaces. *Boston Med. and Surg. J.*, 1897, **137**: 95.

Youth, 19: Application of acetanilid to a burned area on the back was followed by general cyanosis and collapse.

GARTMAN, L. N., and BALL, M. V. A case of acetanilid poisoning. *Philadelphia Polyclinic*, 1897, **6**: 381.

Child, 3½ years: A scalded surface was dressed with 3 ounces of 10 per cent ointment of acetanilid. Two days later 3 ounces were again applied and the child began to turn blue. Cyanosis deepened until the skin and mucous membranes became blackish-blue, and symptoms of collapse followed.

SLIFER, G. B. A case of acetanilid poisoning. *Therap. Gaz., Detroit and Philadelphia*, 1897, (3), **13**: 360.

Woman, 21: Took a little acetanilid on the end of a spoon twice, and then a teaspoonful. This was followed by vertigo, faintness, cyanosis, semi-consciousness, and symptoms of collapse. There was suppression of urine until noon of the following day.

SNOW, I. M. Acetanilid poisoning in a newly born infant: Absorption from the umbilicus. *Med. and Surg. Reporter, Philadelphia*, 1897, **76**: 794.

Application of about a drachm of acetanilid to the umbilicus of an infant 7 days old caused deep cyanosis and symptoms of collapse. The child lost 1 pound in three days.

#### 1898.

BALLOU, P. V. Unusual symptoms following the administration of antifebrin. *Med. News, New York*, 1898, **72**: 791.

Man, 45: Ingestion of 10 grains of acetanilid was followed by the appearance of a general eruption, resembling that of scarlatina, with intense itching, irregularity of the pulse, and a sense of impending danger.

BROWN, P. K. A fatal case of acetanilid poisoning. *Pacific Rec. Med. and Surg., San Francisco*, 1898-99, **13**: 197.

Man, 37: Brought to hospital thirty-six hours after he had taken 50 grains of acetanilid within a few hours. Was kept alive nine days. Frequent vomiting, general hyperesthesia, deep cyanosis of lips, gums, and extremities, increased reflexes, lowered blood pressure, the pulse rate steadily rising until just before the end. All the symptoms of collapse. Progressive destruction of red corpuscles to 1,116,000, with 30 per cent of hemoglobin on day of death. Leucocytosis. Alkalinity of the blood reduced 80 per cent. Hemoglobinuria began twenty-four hours after ingestion. Suppression of urine three days before death. Acute diffuse nephritis. Hemorrhage from intestines. Acute progressive jaundice.

BUEHLER, G. V. Case of acetanilid poisoning. *Atlantic Med. Weekly, Providence*, 1898, **9**: 276.

Man, 21, burn of entire back: Application of not more than 1 to 1.5 drachms of acetanilid was followed by cyanosis, unconsciousness, and collapse.

#### 1899.

GILMORE, A. W. Acetanilid habit. *Philadelphia Med. J.*, 1899, **3**: 1423.

Woman, 58: For pain and insomnia took acetanilid regularly for twenty months. At first she took 2.5 grains at a dose, but gradually increased it to 10.

WESCOTT, T. S. A case of acetanilid poisoning from external absorption in an infant. *Pediatrics, New York*, 1899, **7**: 539.

Application of a dusting powder consisting of acetanilid in the folds of the groin and thighs for chafing, caused deep cyanosis.

#### 1900.

GAINES, G. W. A case of acetanilid habit. *New Orleans Med. and Surg. J.*, 1900-1901, **53**: 30.

Adult negro: Had been taking acetanilid for rheumatic pain for four years, and recently had been taking as much as 2 ounces each week.

SUMMERS, O. R. Acetanilid idiosyncrasy. *Indiana Med. J.*, Indianapolis, 1899-1900, **18**: 382.

Woman, 26: Ingestion of 8 grains of acetanilid in 2 doses with an interval of one-half hour caused nausea, vertigo, dyspnea, deep cyanosis of lips and finger tips, and all the symptoms of collapse. There were also periods of convulsive movements with partial loss of consciousness.

1901.

EARP, S. E. A case resembling morbus cæruleus probably due to a dusting powder containing acetanilid. *Pediatrics*, New York, 1901, **12**: 93.

Child, one month old: Thought at first to have morbus cæruleus. Cyanosis of skin and mucous membranes. Lips and tongue almost black. Cold, clammy skin, mental dullness, slowed respiration. Later it was ascertained that a raw area of skin had been dusted for several days with a powder consisting of equal parts of acetanilid and boric acid.

MANASSES, J. L. Two cases of acetanilid poisoning in children from absorption from external wounds. *Internat. Med. Mag.*, New York, 1901, **10**: 278.

(1) Child, 6 weeks old: Frequent application of a powder consisting of equal parts of acetanilid and subgallate of bismuth to an inflamed area on the buttocks was followed by deep cyanosis of the entire skin. (2) Boy, 2½ years: Similar powder dusted on a scalded surface caused cyanosis of lips, ears, and finger tips, extending to the entire skin, and symptoms of depression.

STEWART, F. T. Toxic effects of acetanilid. *Philadelphia Med. J.*, 1901, **8**: 379.

(1) A denuded surface, made by taking skin grafts, was copiously dusted with acetanilid. Next morning the patient was cyanotic, collapsed, and unconscious. (2) Child, 4 months: Application of a powder consisting of one-half drachm of calomel and two drachms each of bismuth subgallate and acetanilid to the skin was followed by intense cyanosis.

TRACY, E. A. Acetanilid poisoning. *Pediatrics*, New York, 1901, **12**: 385.

Baby, few days old: Application of a powder consisting of equal parts of acetanilid and stearate of zinc to a raw area on the buttocks several times in twenty-four hours was followed by intense cyanosis.

1902.

CABOT, R. C. Methemoglobinemia due to acetanilid but without any marked constitutional symptoms. *Philadelphia Med. J.*, 1902, **10**: 848.

Man, 35, entered hospital in July in a condition of intense cyanosis. Six months before he had begun to take acetanilid for pain, and had continued to take about six 5-grain powders daily. Blood drop, chocolate colored; urine brownish-red and gave spectrum of methemoglobin.

KLEINPETER, E. A. Acetanilid cyanosis. *New Orleans Med. and Surg. J.*, 1902-3, **55**: 166.

Adult, male: Five grains of acetanilid administered every four hours for three days caused marked cyanosis of lips, gums, and mouth, and marked prostration.

1903.

HALL, J. N., and MCGRAW, H. R. Chronic cyanosis from acetanilid poisoning. *Boston Med. and Surg. J.*, 1903, **149**: 626.

Man, 50: Habitual use of acetanilid, 30 to 40 grains daily, for six months caused a loss of 20 pounds in weight, cyanosis of face and mucous membranes, deterioration in the quality of the blood, and marked general weakness.

LUCE, T. W. The acetanilid habit—Report of two cases. *Amer. Med.*, Philadelphia, 1903, **6**: 502.

Two cases in which the habitual use of acetanilid by women caused cyanosis, emaciation, general debility, and invalidism. In the case of one of the patients there were convulsive seizures.

STENGEL, A., and WHITE, C. Y. A report of a case of chronic acetanilid poisoning, with marked alterations in the blood. *Univ. Penn. Med. Bul.*, 1902-3, **15**: 462.

Woman, 25: Habitual use of acetanilid for about seven years caused cyanosis varying in degree according to the amount taken, deterioration in the quality of the blood, and general debility amounting to invalidism.

1904.

ELMQUIST, A. G. J. En stor Dosis Antifebrin. *Hosp.-Tid.* Kjöbenhavn, 1904, **4**. R., **12**: 350.

Recovery followed the ingestion of 120 grains of acetanilid taken by a woman with suicidal intent.

1905.

MILLER, J. L. Poisoning by orangeine. *J. Amer. Med. Assoc.*, Chicago, 1905, **44**: 1989.

A young woman, physically sound, had been taking orangeine powders for several weeks for insomnia. Her family noticed that she was cyanotic and sent for a physician, who found deep cyanosis of face, lips, and extremities. She was also faint and chilly. Had taken 6 of the powders within eight hours. Her family promised that she should obtain no more, but three days afterwards she was found dead in bed in the morning. Coroner's verdict: "Death was from the effect of an overdose of orangeine powders administered by her own hand, whether accidentally or otherwise unknown to the jury."

PROBASCO, E. B. Acetanilid poisoning. *New York State J. Med.*, 1905, **5**: 318.

(1) Man, 25, suffering from an attack of typhoid: Five-grain doses of acetanilid every three or four hours caused cyanosis and prostration. (2) Girl, 13, influenza: Acetanilid in 5-grain doses every three or four hours caused cyanosis and prostration. (3) Woman, 30: Ingestion of antikamnia tablets caused cyanosis and collapse. (4) Man, 33: Ingestion of 10 migraine tablets, each containing 2.5 grains of acetanilid, between 10 a. m. and 2 p. m., was followed by deep cyanosis and collapse.

STENGEL, A. Chronic acetanilid poisoning; report of two additional cases. *J. Amer. Med. Assoc.*, Chicago, 1905, **45**: 243.

(1) Man, 38: Habitual use of acetanilid in the form of cephalgin for a year caused progressive loss of flesh and strength, somnolence, cyanosis, increasing weakness, irritability of temper, and irregular heart action, the pulse becoming rapid on slight exertion. (2) Woman, 27: Habitual use of about 20 grains of acetanilid daily in the form of headache tablets caused progressive loss of health and strength, with cyanosis, dyspnea, headache, palpitation of the heart, increasing rapidity of the pulse and respiration especially on exertion, and deterioration in the quality of the blood.

STEWART, D. D. Chronic poisoning by acetanilid. J. Amer. Med. Assoc., Chicago, 1905, **44**: 1725.

(1) Man, 40: Habitual use of acetanilid for two years caused gradual loss of health, cyanosis, general debility with loss of cardiac tone, and deterioration in the quality of the blood. (2) Man, 50: Habitual use of acetanilid for two years caused progressive loss of flesh and strength, the weight falling from 140 to 116, frequent vomiting, cyanosis, deterioration in the quality of the blood, mental dullness, and general debility amounting to invalidism.

1906.

AUSTIN, A. E., and LARRABEE, R. C. Acetanilid poisoning from the use of proprietary headache powders. J. Amer. Med. Assoc., Chicago, 1906, **46**: 1680.

Woman, 43: Habitual use of nervease powders (about 5 grains of acetanilid each), often 6 to 10 daily, caused intense cyanosis and deterioration in the quality of the blood. (2) Woman: Habitual use of 6 nervease powders daily caused nausea, general debility, cyanosis, and deterioration in the quality of the blood.

BERGMAN, N. Remarks on acetanilid. Clinique, Chicago, 1906, **27**: 271.

(1) Administration of two 5-grain doses of acetanilid with an interval of one hour to a baby 2 weeks old was followed by coma, cyanosis, and collapse. (2) Two hundred grains of acetanilid taken within twenty-four hours caused cyanosis, profound coma, and death.

BLACKBURN, A. E. Acetanilid poisoning from bromo-seltzer. J. Amer. Med. Assoc., Chicago, 1906, **46**: 1767.

Man, 22: Habitual use of bromo-seltzer over a period of six months caused mental dullness and depression, general weakness and indisposition to exertion, and cyanosis. The expression was vacant, the breath fetid, pulse rapid on exertion.

CASSADY, D. Acetanilid poisoning by headache tablets. J. Amer. Med. Assoc., Chicago, 1906, **47**: 2012.

Woman, 45: Accustomed to taking "Stearn's Headache Cure." One wafer an hour for three hours caused cyanosis and symptoms of collapse.

GOEPP, R. M. A case of acetanilid poisoning from absorption. J. Amer. Med. Assoc., Chicago, 1906, **47**: 359.

Woman, 37: (1) For eleven months she had dressed an ulcer of the leg with acetanilid, and during this time she had run down in health and lost 70 pounds. Suffered from cyanosis, abdominal pain, general nervousness, dyspnea, nausea and occasional vomiting, headache, and dizziness. Urine of a dark, amber tint. Blood examination showed anemia. (2) Habitual use of an amount of bromo-seltzer, equivalent to about 50 grains of acetanilid daily.

HEMENWAY, H. B. Death from bromo-seltzer; case of acetanilid poisoning. J. Amer. Med. Assoc., Chicago, 1906, **47**: 2158.

Woman, 31: During the last month she had suffered from headaches for which she took bromo-seltzer. On October 12 she took an unknown quantity. Vomited before arrival of physician. Examination showed a poorly nourished woman, breathing regularly and deeply. Eyes closed, body relaxed, lips and fingers blue. Pulse 80, soft and regular. Area of heart dullness slightly increased, right ventricular dilated. Pupils dilated. She sank suddenly and died at 7.45. Verdict of coroner's jury: "Death from acetanilid poisoning from taking bromo-seltzer." Autopsy showed softening of the kidney from parenchymatous inflammation. This condition had given no symptoms during life.

HERRICK, J. B., and IRONS, E. E. Chronic acetanilid poisoning with report of a case due to absorption of the drug from an ulcer of the leg. *J. Amer. Med. Assoc.*, Chicago, 1906, **46**: 351.

Woman, 50: For seven years had applied acetanilid to a large ulcer of the leg. During this time she suffered from general nervousness, mental depression, weakness, dyspnea, cyanosis, and palpitation. Sudden withdrawal of the drug caused maniacal excitement, proving addiction. Liver and spleen enlarged. Blood showed secondary anemia. Urine dark and gave test for paramidophenol. Gradual withdrawal of acetanilid. Recovery.

MORGAN, W. G. Remarkable dosage. *Amer. Med.*, Philadelphia, 1906 (N. S.), **1**: 245.

The ingestion of 47.5 grains of acetanilid three times daily caused cyanosis.

PUCKETT, C. Acetanilid poisoning. *Oklahoma Med. News-J.*, 1906, **14**: 208.

Man, 49: Ingestion of about a teaspoonful of acetanilid in 4 doses at hourly intervals was followed by vertigo and general weakness. Slept all night, but the next day he was in bed with intense cyanosis and all symptoms bordering on collapse.

QUIGLEY, D. T. Acetanilid in bromo-seltzer. *J. Amer. Med. Assoc.*, Chicago, 1906, **46**: 454.

Ingestion of a heaping tablespoonful of bromo-seltzer by a man caused cyanosis and symptoms of collapse.

SUTHERLAND, E. L. Acetanilid poisoning. *Med. Sentinel*, Portland, Oreg., 1906, **14**: 466.

(1) Woman, 34: For six weeks she had suffered from vertigo, shortness of breath, anorexia, nausea, and severe headaches. Her physician found her unconscious, cyanosed, and in profound collapse. Inquiry showed that she had been taking bromo-seltzer for two weeks in tablespoonful doses for pain. (2) Woman, 32: Ingestion of perfection headache wafers over a period of three weeks caused nausea and vertigo, attacks of syncope, cyanosis, loss of memory, and difficulty in concentrating the thoughts. Pulse, 135, soft and intermittent; urine scant, 1.028. Convalescence lasted two months. (3) Woman, 39: Habitual use of headache powders containing 6 grains of acetanilid powder each, caused nausea, general nervousness and debility, cyanosis, and rapid intermittent pulse. (4) Woman, 69: Case similar to the preceding. (5) Woman, 36: Had been taking bromo-seltzer in tablespoonful doses for headache for two months. Collapsed in the street. Symptoms resembled those in preceding case.

TYRRELL, J. B. Acute acetanilid poisoning. *J. Amer. Med. Assoc.*, Chicago, 1906, **46**: 955.

Man, 52: Ingestion of one-half teaspoonful of acetanilid was followed by intense cyanosis, syncope, and collapse.

#### 1907.

DOBSON, L. A case of poisoning by antikamnia. *West London Med. J.*, 1907, **12**: 226.

Man, 54: Took twelve 5-grain tablets of antikamnia at night. He was found in bed the next morning and was at first thought to be dead. There was an intense degree of cyanosis and severe symptoms of collapse.

GLAZEBROOK, L. W. Chronic acetanilid poisoning from Harper's "brain food." J. Amer. Med. Assoc., Chicago, 1907, **49**: 1673.

Woman, 45: Habitual use of acetanilid in the form of Harper's brain food caused general malaise, drowsiness, fatigue on slight exertion, numbness of lower extremities, impaired locomotion, cyanosis and puffiness of the skin, tremor and rapid pulse.

LOEWENTHAL, P. Death from Koehler's headache powders. J. Amer. Med. Assoc., Chicago, 1907, **48**: 813.

Two powders caused the death in an hour and a half of James Tobias, New York, who "came to his death by acetanilid poisoning administered \* \* \* in Koehler's headache powders \* \* \* ." Each powder is said to have been composed of acetanilid 76 per cent, caffeine 22 per cent.

ROOKER, A. M. Case of poisoning by headache powders (Shac). J. Amer. Med. Assoc., Chicago, 1907, **49**: 1675.

Woman, 45, headache: One Stearn's headache wafer was followed in half an hour by dizziness and in an hour by unconsciousness, cyanosis, and prostration.

SANFORD, M. J., and VAN WAGMAN, D. V. Death from Taylor's antiheadache powders. J. Amer. Med. Assoc., Chicago, 1907, **48**: 1693.

Boy, 7, was given a Taylor's powder containing about 4.5 grains of acetanilid at 9 a. m., 10.15, and 11 o'clock. He soon became faint, the lips and tongue became very blue, the face yellowish, and the eyes staring and protruding. At 12.15 convulsions set in and he died at 1 o'clock, before the arrival of a physician.

SMEDLEY, A. L. Death from acetanilid poisoning. J. Amer. Med. Assoc., Chicago, 1907, **48**: 1433.

Man, 29, weight 190: Took three headache powders between 9 and 12 o'clock, each containing acetanilid 2.5 grains, caffeine citrate 0.5 grain, and sodium bicarbonate 3 grains. He vomited twice and became very weak and cyanotic, with slow pulse, slow shallow respiration, and intense headache. The cyanosis deepened, collapse supervened, and he died in a convulsion at 4 p. m. Autopsy showed edema of lungs, dilatation of heart, congestion (acute cloudy swelling) of the kidneys. Urine in bladder showed traces of albumin.

STRICKLAND, C. G. A case of chronic acetanilid poisoning. Pennsylvania Med. J., Athens, 1907-8, **11**: 31.

Woman, 26: For six months had been freely dusting a large leg ulcer with acetanilid, using a half pound weekly. For three months she suffered from headache, palpitation, nausea and vomiting, dyspnea, insomnia, cyanosis, and abdominal pain. Liver and spleen were enlarged, and a cardiac murmur was present. Blood was chocolate colored and showed marked diminution in number of red cells to 1,860,000. Urine was almost black and gave test for paramidophenol. Withdrawal of the drug was followed by recovery.

WYNN, F. B. A case of acetanilid poisoning from headache capsules with extreme tachycardia the dominant symptom. J. Amer. Med. Assoc., Chicago, 1907, **49**: 1027.

Woman, 44: Case in which the ingestion of 6 neuralgic capsules (acetanilid and caffeine) within a few hours was followed by nausea, prostration, dyspnea, precordial anguish, pallor, and extreme rapidity of the pulse. Rate as determined by sphygmograph was 210.

## ANTIPYRIN.

## INTRODUCTORY RÉSUMÉ.

In the following bibliography of poisoning by antipyrin an attempt has been made to classify the cases according to the pathological effect produced. Thus, under the heading "Cutaneous Eruptions" there are grouped the cases in which symptoms of the skin appear from the published reports to have played the most prominent and important part in the history of the cases. This method has been adopted because it gives more information with regard to clinical history than the mere title of the published report would convey, and because it has been found to be impracticable to publish a full abstract of each recorded case of poisoning by antipyrin. It will readily be seen, however, that nothing approaching accuracy can be secured in this way. In some of the cases no one symptom or group of symptoms appears from the published reports to have stood out very prominently in the clinical picture. What appears to have been the most important feature of the case is often attended by symptoms in other parts of the body which are almost if not equally important. Thus many of the skin cases present in addition to the cutaneous symptoms marked systemic depression or abnormal symptoms of the kidneys, the digestive tract, or of other parts of the body. Likewise, the cases grouped under the heading "Collapse" often present also cutaneous or other symptoms. In spite of the difficulty of classifying the cases accurately, however, it is believed that the method possesses distinct advantage over a mere alphabetical or chronological classification. The references are arranged alphabetically and chronologically under each heading.

The total number of cases of poisoning by antipyrin herein recorded is approximately 488. As already stated, it is practically impossible to determine the number of cases with accuracy, owing to the indefinite character of some of the reports. The cases were reported by 299 observers. Of the 488 cases 10, or about 2 per cent, are reported to have resulted fatally. The distribution of the recorded cases by years from the time of the introduction of antipyrin as a medicinal agent, in 1884, to the end of the year 1907, is shown in the accompanying table.

*Cases of antipyrin poisoning reported annually.*

Year.	Number of cases reported.	Number of observers.	Year.	Number of cases reported.	Number of observers.	Year.	Number of cases reported.	Number of observers.
1884.....	33	19	1893.....	13	10	1902.....	4	4
1885.....	68	28	1884.....	16	16	1903.....	8	8
1886.....	48	18	1895.....	28	17	1904.....	7	6
1887.....	37	27	1896.....	13	13	1905.....	3	3
1888.....	55	41	1897.....	31	20	1906.....	5	5
1889.....	24	18	1898.....	22	11	1907.....	2	2
1890.....	22	8	1899.....	2	2			
1891.....	12	11	1900.....	0	0			
1892.....	34	11	1901.....	1	1	Total.	488	299

These figures indicate either that there has been a considerable falling off in the use of antipyrin during recent years, or that the drug has been employed with greater caution and discrimination, and undoubtedly both of these factors have played an important part in reducing the number of cases of poisoning. The inefficiency of the drug in the treatment of some of the affections for which it was formerly recommended and the uncertainty of the effect of its administration may have contributed to this decrease. A review of the cases herein recorded will show that in a number of instances a single dose of antipyrin of 5 grains or less has produced alarming symptoms in adults, while a dose of 10 or 15 grains has produced serious collapse. In many cases of harmful results the dose appears to have been neither unduly large nor too long continued, and there seems to have been little, if any, direct relation between the size of dose and the occurrence and severity of the ill effects. Furthermore, untoward symptoms have appeared so promptly in many cases as to lead some observers to believe that the manifestations are largely reflex in character, inasmuch as there appeared to be almost no time allowed for absorption of the drug from the stomach between the time of ingestion and the appearance of the symptoms. This uncertainty of results has undoubtedly been an important factor in bringing about a more conservative use of the drug.

#### ABSTRACTS OF ANTIPYRIN CASES.

##### CUTANEOUS MANIFESTATIONS.

Under this heading are grouped the recorded cases of antipyrin poisoning in which the cutaneous symptoms appear to have occupied the most important place in the clinical history. They are, however, not necessarily the only ones described in the published reports, and cutaneous manifestations are recorded in many of the cases which have been grouped under other headings.

A review of the reported cases shows that the cutaneous symptoms presented themselves most often in the form of a rash or eruption, often accompanied by swelling and severe itching. The eruption appeared in widely different forms, and varied much in the different cases as regards character, time of appearance, duration, part of the body affected, severity, etc. The form which appears to have been observed most frequently was that of urticaria, accompanied by severe itching. In other cases the eruption resembled that of scarlet fever, in others that of measles, and in still others that of herpes, eczema, or pemphigus. In most of the cases the symptoms appeared promptly after the ingestion of one or two doses of the drug; in some, however, they were delayed, and in not a few instances the cutaneous manifestations did not make their appearance until after

the drug had been taken in fairly large doses for days. Whether they appeared early or late, the symptoms usually came suddenly and lasted only a few hours, with the exception of two or three cases, when they continued for several days. In not a few instances their disappearance was followed by desquamation. The distribution of the eruption presented many variations. In some of the cases it appears to have affected the skin of the entire body, while in others it attacked only a comparatively small area—for instance, the back of the hand or knee. In the mild cases the eruption was a mere erythematous blush, causing, however, much discomfort; but in the severe cases the skin was red, swollen, and hot, and the sensation of heat and itching was distressing.

Besides an eruption, the skin manifestations in poisoning by antipyrin included edema. The swelling in most cases affected first the face, especially the skin around the eyes, and the statement frequently occurs in the reports that the patient's face became so swollen that he was unrecognizable. The swelling in not a few instances involved the skin of the entire body. Cyanosis was observed in only two or three cases, and pruritus without the appearance of a rash in a very few instances.

#### 1884.

ALEXANDER. Zweiter Bericht über die Wirkungen und Nebenwirkungen des Antipyrins. Breslau ärztl. Zts., 1884, 6: 169.

Four cases of typhoid fever in which the administration of antipyrin was followed by the appearance of an eruption.

BIELSCHOWSKY, E. Beiträge zur Antipyrin-Behandlung. Breslau. ärztl. Zts., 1884, 6: 193.

Two cases of typhoid fever in which the administration of antipyrin was followed in one case by an erythematous eruption and in the other by collapse.

CAHN, A. Ueber Antipyrin und Antipyrinexanthem. Berl. klin. Wochenschr., 1884, 21: 569.

Two cases, one of typhoid fever and the other of phthisis, in which the ingestion of antipyrin was followed by the appearance of an erythematous rash.

DEBOVE, cited by DENUX, M. Étude sur la valeur thérapeutique de l'antipyrine. Paris, 1884.

Ingestion of antipyrin was followed by the appearance of a morbilliform eruption.

DEMME, R. Physiologische und therapeutische Beiträge zur Kenntnis des Antipyrins. Fortschr. d. Med., Berlin, 1884, 2: 689.

Two cases in children, one of acute rheumatism and the other of typhoid fever, in which the administration of antipyrin was followed in one case by the appearance of an erythematous rash, and in the other by symptoms of marked depression.

DOEBNER. Ein Antipyrinausschlag. Aertzl. Int.-Bl., München, 1884, **31**: 571.

Woman, 28 phthisis. After the ingestion of 3.25 drachms of antipyrin during twelve days, a morbilliform eruption made its appearance.

ERNST, P. Antipyrinexanthem. Centrbl. klin. Med., Leipzig, 1884, **5**: 521.

Two cases of typhoid fever in which the administration of antipyrin was followed by an eruption upon the skin.

GEIER, A. Zur Wirkung des Antipyrin bei Kindern und Erwachsenen. Deutsche med. Wochenschr., 1884, **10**: 730.

Man, 39, typhoid: After taking antipyrin for nine days an erythematous rash appeared. Erythema on back and extremities.

MEISSEN. Antipyrin bei Phthise. Deutsche med. Wochenschr., Berlin, 1884, **10**: 827.

An eruption appeared immediately after resuming the use of antipyrin, after an interval of eight days.

PŘIBRAM, A. Ueber das Antipyrin. Prag. med. Wochenschr., 1884, **9**: 422.

In four cases, erythema followed the use of antipyrin for three days in doses of 15 and 30 grains. In a case of tuberculosis, collapse occurred after the injection of 1 drachm of antipyrin.

RANK, C. Ueber den therapeutischen Werth des Antipyrins. Deutsche med. Wochenschr., Berlin, 1884, **10**: 373.

The injection of antipyrin was followed by an eruption resembling urticaria.

SECCHI. Zur Wirkung des Antipyrin bei Phthise. Exanthem nach Anwendung desselben. Breslau. ärztl. Zts., 1884, **6**: 184.

In two cases a morbilliform eruption with severe itching followed the ingestion of 15-grain doses of antipyrin.

SUÑER, E. Mas sobre la antipirina. Génio méd.-quir., Madrid, 1884, **30**: 494.

Erythema with severe itching appeared on the fourth day, after the ingestion of 45 grains of antipyrin.

WISING, P. J. Om biverkningar af antipyrin. Hygiea, Stockholm, 1884, **46**: 716. Abs. Lancet, London, 1887, **2**: 85.

A rash of bluish-red spots on the face following the ingestion of antipyrin.

1885.

DE GASSICOURT, C. Discussion of paper by Descroizilles. L'emploi de l'antipyrine chez les enfants. J. méd., Paris, 1885, **8**: 911.

Two cases in which the ingestion of antipyrin was followed by the appearance of an eruption of bright red spots.

DRAPER, W. H. Antipyrin and its effects. Med. Rec., New York., 1885, **27**: 414.

An eruption resembling that of measles occurred in 6 out of 20 cases of typhoid treated with antipyrin.

FERNAGUT, E. Essai sur l'action de l'antipyrine dans la fièvre typhoïde. Paris, 1885.

A roseola followed the prolonged use of antipyrin in typhoid fever.

GIORGIERI, C. Sull' eruzione cutanea per l' uso dell' antipirina. Gazz. med. ital. lomb., Milano, 1885 (8. s.), 7: 273.

Two cases in which an eruption followed the ingestion of antipyrin.

GUTTMANN, P. Ueber antipyretische Mittel. Berl. klin. Wochenschr., 1885, 22: 401.

In 6 cases out of 297 an exanthematous eruption followed the ingestion of antipyrin.

KAATZER, P. Antipyrin bei Phthisis. Deutsche med. Wochenschr., Berlin, 1885, 11: 270.

In 2 cases the ingestion of antipyrin was followed by the appearance of an exanthematous eruption.

PUSINELLI. Ueber Antipyrin. Deutsche med. Wochenschr., Berlin, 1885, 11: 145.

In 7 cases of typhoid the ingestion of antipyrin was followed by the appearance of an exanthematous eruption.

ROLLET, M. F. Note sur l'antipyrine chez les tuberculeux. Lyon med., 1885, 49: 453.

An eruption appeared in 1 out of 5 cases of tuberculosis treated with antipyrin.

ROUX-SEIGNORET. Sur un cas de fièvre typhoïde, traité par l'antipyrine. Eruption rubéoliforme au dixième jour. France méd., Paris, 1885, 2: 921.

Typhoid: The ingestion of antipyrin was followed on the tenth day by the appearance of a morbilliform eruption, covering the entire body.

SARTORIUS, E. Antipyrin in der Kinderpraxis. Erlangen, 1885.

Child, 6: Ingestion of antipyrin was followed by the appearance of an exanthematous eruption.

SECRETAN, L. Antipyrine et rhumatisme. Rev. méd. Suisse Rom., Genève, 1885, 5: 718.

The ingestion of antipyrin was followed by the appearance of a morbilliform eruption, covering the entire body.

SHATTUCK, G. B. The results of the use of antipyrine at the Boston City Hospital. Boston Med. and Surg. J., 1885, 113: 78.

In a small proportion of cases the exhibition of antipyrin was followed by the appearance of an eruption.

WELT, S. Klinische Beobachtungen über die antifebrile Wirkung des Antipyrins und Thallin nebst Bemerkungen über individuelle Antipyrese. Deutsches Arch. klin. Med., Leipzig, 1885-6, 38: 81.

Thirteen out of 122 patients treated with antipyrin developed an erythema.

ZITEKE, J. X. Antipyrine. Therap. Gaz., Detroit, 1885 (3. s.), 1: 517.

Author observed cases in which exanthematous eruptions followed the prolonged use of antipyrin.

1886.

BLOMFIELD, J. E. Two cases of antipyrin-rash. Practitioner, London, 1886, 36: 261.

Two cases of acute phthisis in which the ingestion of from 7 to 12 grains of antipyrin 3 times daily was followed by the appearance of an eruption upon the skin.

CATTANI, G. Dell' esantema antipirinic. Gior. ital. d. mal. ven., Milano, 1886, **21**: 129.

Six cases in which an eruption followed the ingestion of antipyrin.

DE RENZI, E. Eruzione cutanea prodotta dall' antipirino. Riv. clin. e terap., Napoli, 1886, **8**: 57.

Male, typhoid: Ingestion of 4.5 drachms of antipyrin within three days was followed by an erythematous eruption.

FRAENKEL, A. Ueber Antipyrinbehandlung des acuten Gelenkrheumatismus. Deutsche med. Wochenschr., 1886, **12**: 772.

Man, 39, articular rheumatism: The ingestion of 1.25 drachms of antipyrin daily for six days was followed by the appearance of an erythema covering the entire body.

FRANKENBERG, J. H. Antipyrine. Med. Rec., New York, 1886, **29**: 585.

Seven cases in which the ingestion of antipyrin was followed by an eruption on the skin. In one the quantity taken was 5 drachms within two weeks in 15-grain doses. In the other the quantity was 1 to 3 ounces in the same period of time.

FRUITNIGHT, J. H. Kairine and antipyrine. Med. Rec., New York, 1886, **29**: 647.

Acute phthisis: Five grains of antipyrin given every four hours produced a bright red miliary eruption.

GOLBIEWSKI, E. Ueber die Wirkung von Antipyrin bei Gelenkrheumatismus. Berl. klin. Wochenschr., 1886, **23**: 463.

In about 70 cases there were only 2 instances in which an exanthem resembling urticaria followed the use of antipyrin.

LAACHE, S. Ein Fall von "konträrer" Antipyrinwirkung. Centrbl. klin. Med., Leipzig, 1886, **7**: 545.

Man, phthisis: The ingestion of 0.5 drachm dose of antipyrin was followed by a chill and rise of temperature. On the next day a scarlatiniform eruption appeared upon the skin.

LAURE. Étude clinique sur la valeur de l'antipyrine spécialement appliquée à la thérapeutique infantile. Rev. mens. mal. l'enf., Paris, 1886, **4**: 57.

On four occasions a morbilliform eruption was observed in children following the ingestion of antipyrin.

MASIUS ET SNYERS, P. Contribution à l'étude de l'antipyrine. Bul. Acad. roy. méd. Belg., Bruxelles, 1886 (3. s.), **20**: 547.

Case in which an exanthematous eruption followed the ingestion of antipyrin.

1887.

DALLY, E. O. Rash produced by antipyrin. Brit. Med. J., London, 1887, **1**: 111.

Two cases in which a morbilliform eruption followed the ingestion of antipyrin.

HAYEM. Modes d'administration de l'antipyrine. J. méd. Paris, 1887, **12**: 708.

Ingestion of 0.5 drachm of antipyrin gave rise to an intense erythema.

HAYS, J. M. Sloughing following a hypodermic injection of antipyrin. Med. Rec., New York, 1887, **32**: 486.

Injection of 12 grains of antipyrin dissolved in water was followed by a severe urticarial eruption, and a slough the size of a silver quarter.

JOZEFOWICZ. On the antipyrin rash. Proceedings of the Kovno Medical Society, 1886, No. 2, p. 17 (Abs. Lond. Med. Record, 1887, 15: 264).

Two cases of exanthem following the ingestion of antipyrin, one with and the other without severe itching.

LEITZMANN, G. Eine Nebenwirkung des Antipyrin. Berl. klin. Wochenschr., 1887, 24: 531.

Woman, pneumonia: A dose of 15 grains of antipyrin was followed in four hours by a chill and vomiting, and later by an erythema.

MARTINI, V. Orticaria per antipirina. Boll. d. sez. d. cult. d. sc. med. n. r. accad. d. fisiocrit. di Siena, 1887, 5: 114.

Urticaria and intense itching followed the ingestion of antipyrin.

PAGET, W. S. Rash produced by antipyrin. Brit. Med. J., London, 1887, 1: 210.

The ingestion of antipyrin for eight days on an average of 1 drachm daily was followed by the appearance of a bright red rash.

SCHWARZ. Ein Fall von Antipyrinexanthem. Münch. med. Wochenschr., 1887, 34: 59.

Woman, 27, typhoid: Ingestion of 9 drachms of antipyrin in fourteen days was followed by a severe chill and then by a morbilliform rash with severe itching.

SÉE, G. De l'antipyrine contre la douleur. Compt. rend. acad. sci., Paris, 1887, 104: 1085.

Author had observed an eruption resembling that of scarlatina or urticaria following the ingestion of antipyrin in doses of from 1 to 1.5 drachms daily.

SPITZ, B. Ein eigenthümlicher Fall von Dermatitis hervorgerufen durch Antipyrinbehandlung. Therap. Monatsh., Berlin, 1887, 1: 347.

Girl, 20, typhoid: One-half drachm doses of antipyrin were followed by a morbilliform rash with subsequent desquamation.

VICTOR, P. Antipyrin rash. Indian Med. Gaz., Calcutta, 1887, 22: 241.

Boy, 14, typhoid: Between June 26 and July 6 received 300 grains of antipyrin. A vesicular and papular rash appeared over the whole body, and lasted six days.

WHITEHOUSE, J. S. A case of antipyrin poisoning. Med. Rec., New York, 1887, 32: 706.

The ingestion of 7.5 grains of antipyrin was followed in two minutes by severe gastric pain and soon after by the appearance of an urticarial eruption and symptoms of collapse.

#### 1888.

BARBER, C. F. Some toxic effects of antipyrine. Med. Rec., New York, 1888, 33: 14.

Ingestion of 15 grains of antipyrin was followed by the appearance of an urticarial eruption with intense itching. The face was much swollen, features being obliterated.

BOKENHAM, T. J. Some therapeutic uses of antipyrin. *Practitioner*, London, 1888, **40**: 266.

(1) Ingestion of 20 grains of antipyrin 3 times a day for fourteen days by a child was followed by malaise and the appearance of an eruption resembling that of both urticaria and scarlatina. (2) Ingestion of antipyrin was followed by drowsiness, vertigo, delirium, and diarrhea. (3) The first dose of antipyrin was followed by symptoms of depression. (4) Antipyrin caused the appearance of a rash like that described in case 1.

CEHAK. Zur Wirkung des Antipyrins. *Allg. Wien. med. Ztg.*, 1888, **33**: 316.

Ingestion of 15 grains of antipyrin was followed by severe sneezing, dyspnea, and swelling of the entire face and inside of the mouth. In 2 cases erythema followed the ingestion of antipyrin.

CLAREMONT, C. C. Antipyrin rashes. *Brit. Med. J.*, London, 1888, **2**: 943.

In 2 cases an eruption followed the ingestion of antipyrin in typhoid fever.

DURAND, J. Eruption scarlatiniforme causée par l'antipyrine. *Gaz. hôp. Toulouse*, 1888, **2**: 225.

Man, 55, neuralgia: A scarlatiniform eruption followed the ingestion of 0.5 drachm of antipyrin.

DUTT, U. K. Idiosyncrasy with regard to antipyrin. *Brit. Med. J.*, London, 1888, **1**: 1147.

Ingestion of antipyrin was followed by violent itching, tingling, and burning of the throat and skin, and sneezing. No eruption.

GROGNOT. Sur un cas d'oedème consécutif à l'absorption de l'antipyrine. *Bul. gén. thérap. [etc.]*, Paris, 1888, **115**: 134.

Man, 35, facial neuralgia: Fifteen minutes after taking 15 grains of analgesin, edema of the face developed.

HARDY. Sur l'emploi thérapeutique de l'antipyrine et de l'acétanilide. *Bul. Acad. méd.*, Paris, 1888 (2. s.), **19**: 245.

Man, 30: Developed a scarlatiniform eruption after taking antipyrin.

JENNINGS, O. On poisoning by antipyrin. *Lancet*, London, 1888, **1**: 364.

(1) Ingestion of 2.5 grams of antipyrin daily for eight days was followed by the appearance of an eruption over the whole body, swelling of the face, symptoms of collapse and prostration. (2) Young woman took 5 grams of antipyrin a day for rheumatism. On the second day she was found swaying back and forth, and repeatedly crying that she had lost her memory and was going mad. She subsequently had an attack of gastro-enteritis. (3) Woman. The ingestion of antipyrin was followed by a swelling of the body, dyspnea, and the appearance of an eruption.

LANPHEAR, E. A peculiar effect of antipyrin. *Kansas City Med. Index*, 1888, **9**: 155.

Woman, 52: Ingestion of 1.5 ounces of antipyrin in one week was on 2 occasions followed by deep cyanosis and swelling of the face and extremities.

MACDONALD, A. Antipyrin and idiosyncrasy. Brit. Med. J., London, 1888, **1**: 296.

Girl, typhoid: Ingestion of 3 doses of antipyrin daily for twelve days was followed by the appearance of an urticarial eruption over the entire body except the face.

MAHNERT, F. Studien und Erfahrungen über Antipyrin. Mittheil. Ver. Aerzte in Steiermark, 1888, **24**: 62.

Author states that he had seen but 1 case in which a morbilliform rash followed the ingestion of antipyrin.

MAYET. Bul. mém. soc. de thérap., Paris, 1888 (2. s.), **15**: 33.

Ingestion of 45 grains of antipyrin was followed by an intense urticarial eruption; 7.5 grains taken later caused swelling of the eyelids and entire face.

MAZZOTTI, L. Esantema antipirinic per iniezioni sottocutanee d'antipirina ed eruzione di herpes zoster sopra di esso. Gior. ital. mal. ven., Milano, 1888, **23**: 210.

An eruption followed the subcutaneous injection of antipyrin.

OLIVER, T. Clinical experience of some of the more recently introduced drugs. Lancet, London, 1888, **1**: 868.

A herpetic eruption followed the ingestion of antipyrin taken for neuralgia.

OLLIVIER, A. Bul. Acad. méd., Paris, 1888 (2. s.), **19**: 229.

Child, chorea: Ingestion of antipyrin was followed by the appearance of an erythematous rash.

ORY. Contre-indications de l'antipyrine, son emploi dans la polyurie. J. méd. Paris, 1888, **14**: 486.

Forty-five grains of antipyrin taken during the day gave rise to a miliary eruption over the entire body.

STACK, J. J. Antipyrin. Lancet, London, 1888, **2**: 1112.

On 3 occasions the ingestion of a 10-grain dose of antipyrin caused the appearance of an urticarial eruption over the entire body with itching and a disagreeable sense of uneasiness.

TISNÉ. Éruption due à l'usage de l'antipyrine. J. méd. Paris, 1888, **15**: 327.

The ingestion of antipyrin was followed by the appearance of a scarlatini-form eruption.

WILSON, J. C. Note on antipyrin as an analgesic. J. Nerv. Ment. Dis., New York, 1888 (n. s.), **13**: 42.

In two or three instances a transient scarlatiniform eruption followed the use of antipyrin.

WINDELSCHMIDT. Ueber die Wirkung des Antipyrin bei der Menstruationscolik. Allg. med. Centr.-Ztg., Berlin, 1888, **57**: 1029.

Boy, 7: A dose of 4.5 grains of antipyrin was followed by the appearance of an urticarial eruption and high fever.

## 1889.

AMON, H. Subkutane Antipyrin-Injektion bei akutem Gelenksrheumatismus. Internat. klin. Rundschau, Wien, 1889, **3**: 123.

A small superficial patch of gangrene of the skin followed the subcutaneous injection of antipyrin.

BOUCHER. Eruption due à l'antipyrine. Bull. soc. méd. Rouen, (1889) 1890 (2. s.), **3**: 29.

A morbilliform eruption followed the ingestion of antipyrin.

GRANDCLÉMENT. Indications et dangers de l'antipyrine. Lyon méd., 1889, **60**: 414.

Man, 65: One or 2 doses of antipyrin of 7.5 grains each were followed by the appearance of an eruption upon the skin. It reappeared every time the patient took antipyrin.

PERRET, S., and DEVIC, E. Des éruptions rubéoliformes dues à l'antipyrine. Province méd., Lyon, 1889, **3**: 301.

Girl, 5: A morbilliform eruption followed the ingestion of antipyrin.

WATKINS, W. Antipyrin; results following its administration. Lancet, London, 1889, **2**: 903.

Woman, 37, headache: A dose of 10 grains of antipyrin was followed by great swelling of the upper lip.

## 1890.

DUBOUSQUET-LABORDERIE. Traitement de la coqueluche par l'antipyrine. Semaine méd., Paris, 1890, **10**: 154.

Ill effects were noted in 15 out of 300 cases treated with antipyrin, principally a scarlatiniform eruption or gastric disturbance.

LEWIS, D. C. Five hours with 15 grains of antipyrine. Med. Brief, St. Louis, 1890, **18**: 282.

Half an hour after taking 15 grains of antipyrin the patient's face became swollen, the sight blurred, the hearing indistinct, and an urticarial eruption made its appearance.

## 1891.

DE MOLÈNES, P. Érythème antipyrinique. Ann. dermat. syph., Paris, 1891 (3. s.), **2**: 384.

An erythematous eruption lasting about six days followed the ingestion of antipyrin.

GLIAZSTEIN, I. K. Kazuist t. n. lekarst. sypei. (So-called drug exanthem). Meditsina, St. Petersburg, 1891, **3**: 405. Cited by Fournier, 1892, p. 496.

(1) An erythematous eruption followed the ingestion of 7.5 grains of antipyrin. Subsequently another dose of the drug was followed by similar symptoms. (2) On 2 occasions an eruption appeared after the ingestion of 3 doses of antipyrin, 2.5 grains each, in the case of a child.

GRANCHER. Eruption fébrile due à l'antipyrine. J. méd. chir. prat., Paris, 1891, **62**: 334.

Child for eight days was given 37.5 grains of antipyrin daily. This was followed by a morbilliform rash with fever. It disappeared two days after the drug was discontinued, and reappeared when it was again taken.

LALOY, L. Deux cas d'exanthème par absorption de substances médicamenteuses. *J. méd. chir. prat.*, Paris, 1891, **62**: 921.

Woman, 45, headache: A dose of 15 grains of antipyrin was followed by the appearance of a morbilliform rash.

#### 1892.

CASPARY. Ueber Arzneiausschläge. *Monatsh. prakt. Dermat.*, Hamburg, 1892, **14**: 326.

Five cases in which eruption followed the ingestion of antipyrin.

EICHHORST, H. Zur Kenntniss des Antipyrinexanthems. *Therap. Monatsh.*, Berlin, 1892, **6**: 381.

Two cases of typhoid in which the administration of antipyrin was followed by the appearance of an eruption.

FOURNIER, H. Notes pour servir à l'étude des éruptions déterminées par l'antipyrine. *J. mal. cutan. syph.*, Paris, 1892, **4**: 488.

Four cases in which an eruption followed the administration of antipyrin.

LEMONNIER. Érythème scarlatiniforme dû à l'antipyrine. *Ann. dermat. syph.*, Paris, 1892 (3. s.), **3**: 734.

An erythema appeared two hours after the ingestion of antipyrin.

LEBOUX, cited by Fournier, 1892, p. 499.

In 16 cases an eruption followed the ingestion of antipyrin in chorea.

MOELLER, J. Zur Kenntniss des Antipyrinexanthems. *Therap. Monatsh.*, Berlin, 1892, **6**: 580.

A dose of 15 grains of antipyrin was followed by the appearance of an erythematous eruption, with swelling of the lips, nose, and eyes.

PETRINI. Éruption pemphigoïde antipyrinique. *Ann. dermat. syph.*, Paris, 1892 (3. s.), **3**: 170.

A pemphigoid eruption followed ingestion of antipyrin.

SHORT, T. S. On the toxic effects of antipyrin. *Birmingham Med. Rev.*, 1892, **31**: 340.

On three occasions the ingestion of a 5-grain dose of antipyrin was followed by redness and swelling of the face, the appearance of a scarlatiniform rash and the formation of ulcers in the mouth.

#### 1893.

CHILDE, C. P. Rash caused by taking antipyrin. *Brit. Med. J.*, London, 1893, **2**: 944.

On four occasions the ingestion of antipyrin was followed by the appearance of an eruption.

FREUDENBERG, A. Oedematöse Schwellung des Praeputium als Nebenwirkung des Antipyrin. *Centrbl. klin. Med.*, Leipzig, 1893, **14**: 97.

Man, 30: A dose of 7.5 grains of antipyrin was followed by a sensation of burning in the urethra and itching and swelling of the prepuce.

LEVISEUR. Discussion of Pollitzer's case (1893). *New Yorker med. Monatsschr.*, 1893, **5**: 519.

A case similar to the one described by Pollitzer (1893), in which 7.5 grains of antipyrin were taken.

POLLITZER. Eine seltenere Form von Antipyrinexanthem. New Yorker med. Monatsschr., 1893, 5: 519.

Ingestion of 30 grains of antipyrin within two hours caused swelling of the lips and tongue and the appearance of a vesicular eruption upon the face, dorsum of the hand, and glans.

1894.

BENZLER. Ueber Arzneiexanthem besonders nach Antipyrin. Deutsche mil. ärztl. Zts., Berlin, 1894, 23: 253.

Man, 36: A dose of 15 grains of antipyrin was followed by the appearance of an erythematous eruption on the back of the hand.

BROCQ, L. Éruption érythémato-pigmentée fixe due à l'antipyrine. Ann. dermat. syph., Paris, 1894 (3. s.), 5: 308.

Ingestion of antipyrin was followed by an eruption of dark-red plaques.

DU CASTEL. Discussion of paper by Brocq, *ibid.*, p. 312.

On three occasions the patient suffered from erythematous patches on the glans and left eyelid after taking antipyrin.

FOURNIER, A. Pseudo-syphilide palmaire déterminée par l'antipyrine. Bul. soc. franç. dermat. syph., Paris, 1894, 5: 175.

A dose of antipyrin, from 7.5 to 15 grains, produced an eruption in the palm of the hand which closely resembled syphilis.

HALLOPEAU. Récidive in situ d'un érythème polymorphe. Bul. soc. franç. dermat. syph., Paris, 1894, 5: 481.

Ingestion of 7.5 grains of antipyrin was followed by great restlessness and the appearance of an erythematous and vesicular eruption.

HARTZELL, M. B. Urticaria following the administration of antipyrin. Arch. Pediat., New York, 1894, 11: 371.

Boy, 2: Administration of 0.75 grain of antipyrin was followed by the appearance of an eruption. A second dose, given experimentally, produced a similar result.

HOOD, J. J. Toxic symptoms produced by antipyrin. Australas. Med. Gaz., Sydney, 1894, 13: 150.

Patient, a woman, had an itching lichen ruber. Ingestion of 10 grains of antipyrin caused an aggravation of the symptoms and the appearance of a general erythematous eruption.

JADASSOHN. Discussion of paper by Brasch, 1894, p. 624.

Man, 70: A few doses of antipyrin caused the appearance of a bullous eruption on the lips, hands, and genitals.

JULLIEN, cited by Brocq, 1894, *ibid.*, p. 313.

Case of antipyrin exanthem like that described by Brocq.

MOELLER, J. Zur Kenntniss des Antipyrin-Exanthems. Therap. Monatsh., Berlin, 1894, 8: 565. (See also Moeller, 1892.)

Ingestion of 7.5 grains of antipyrin was followed by the development of small blisters on the hands and genitals.

SCHIFF. Arch. Dermat. Syph., Wien, 1894, 27: 315.

A papular erythema followed the administration of antipyrin to a child 10 months old.

WICKHAM, L. Érythème provoqué par l'antipyrine; pseudo-roséole syphilitique. *Ann. dermat. syph.*, Paris, 1894 (3. s.), 5: 337.

The ingestion of 0.5 drachm of antipyrin was followed by the development of a roseola resembling that of syphilis.

1895.

BALLIN. Description d'une assez bizarre éruption antipyrrique. *Lyon méd.*, 1895, 80: 388.

On a number of occasions the ingestion of antipyrin by the same patient was followed by an eruption of red patches involving the greater part of the body.

BAUDOUIN, G. *Bul. soc. franç. dermat. syph.*, Paris, 1895, 6: 121.

Two cases in which an itching eruption followed the ingestion of antipyrin.

BODIN, L. Éruptions bulleuses emphigoïdes dues à l'antipyrine. *Presse méd.*, Paris, 1895, p. 487.

Case in which an eruption followed the ingestion of 15 grains of antipyrin.

DUBREUILH, W. Érythème fixe causé par l'antipyrine. *Arch. clin. Bordeaux* 1895, 4: 383.

Each time the patient took 22.5 grains of antipyrin a red infiltrated patch appeared on the left cheek.

GASTOU. Éruption d'antipyrine. *Méd. mod.*, Paris, 1895, 6: 271.

Ingestion of 15 grains of antipyrin was followed by the appearance of an urticarial eruption with the formation of bullae and subsequent ulceration.

KNIGHT, E. Peculiar susceptibility to the effects of antipyrin. *Brit. Med. J.*, London, 1895, 1: 1132.

A dose of 10 grains of antipyrin in one case caused the appearance of an urticarial eruption and in another violent sneezing, swelling of the nose and throat, and dyspnea.

MOREL-LAVALLÉE, A. Placards pigmentés indélébiles consécutifs à un érythème antipyriné récidivant sur place. *Ann. dermat. syph.*, Paris, 1895 (3 s.), 6: 325.

The ingestion of 15 grains of antipyrin was followed by an eruption resembling nettle-rash.

PAYNE, W. H. *Brit. Med. J.*, London, 1895, 1: 1132.

A case in which 10 grains of antipyrin caused an urticarial eruption within fifteen minutes after the ingestion of the drug.

RUGE, H. Ueber einen Fall von Idiosynkrasie gegen Antipyrin. *Charité-Ann.*, Berlin, 1895, 20: 245.

Woman, 35: A dose of 15 grains of antipyrin was followed by a rise in temperature of 4.5° and the appearance of an eruption.

RUSSELL, W. M. Peculiar susceptibility to the effects of antipyrin. *Brit. Med. J.*, London, 1895, 1: 1019.

The ingestion of 3 grains of antipyrin (which was vomited almost immediately) was followed by soreness of the gums and the development of an eruption upon the body.

SEDGWICK, W. Antipyrin rash. *Brit. Med. J.*, London, 1895, **1**: 58.

On two occasions the ingestion of 10 grains of antipyrin was followed by the appearance of a bright red rash.

SUSS. Note sur deux cas d'érythème phlycténulaire produit par l'antipyrine. *France méd.*, Paris, 1895, **42**: 177.

(1) The ingestion of 45 grains of antipyrin in divided doses was followed by the appearance of irregular purplish spots upon the extremities. (2) Antipyrin taken for headache caused the appearance of a rash upon the body.

TALAMON, C. Éruptions médicamenteuses. *Méd. mod.*, Paris, 1895, **6**: 212.

(1) The ingestion of 30 grains of antipyrin was followed by the appearance of a scarlatiniform eruption. (2) The ingestion of antipyrin was followed on the third day by the appearance of a morbilliform rash. (3) Administration of antipyrin to a typhoid patient caused an eruption which was purpuric in character. (4) Author had seen a papular erythema, more or less abundant, following the administration of antipyrin to tubercular patients in five or six instances.

#### 1896.

ARMAIGNAC. *Mém. bul. soc. méd. chir. Bordeaux*, 1896, p. 416.

On three occasions, following the ingestion of 30, 45, and 60 grains of antipyrin, respectively, a girl suffered from an eruption of small, slightly indurated papules.

BRIQUET. A propos d'un cas exceptionnel d'intolérance pour l'antipyrine. *J. méd. chir. prat.*, Paris, 1896, **67**: 929.

Youth, 24: A severe pruritus lasting two days followed the ingestion of 15 grains of antipyrin. Subsequently a similar affection followed the ingestion of 7.5 grains.

COULON, CH., ET VERNY, G. Un cas d'intolérance antipyrinique. *Bull. méd. nord*, Lille, 1896, **35**: 301.

Youth, 23, headache: Four hours after taking 15 grains of antipyrin an eruption of reddish spots appeared upon the body.

DESCHEEMAKER. Nouvel exemple d'urticaire antipyrinique. *Bul. méd. nord*, Lille, 1896, **35**: 562.

Man, 59: The ingestion of 15 grains of antipyrin was followed by the development of an urticarial eruption around the right eye, and severe headache.

GALEWSKI. *Arch. Dermat. Syph.*, Wien, 1896, **34**: 105.

The ingestion of 15 grains of antipyrin was followed by an eruption upon the skin, necrotic patches in the mouth and throat, fever, and bleeding.

KUSS, reported by Dalché. *Bul. mém. soc. méd. hôp. Paris*, 1896 (3. s.), **13**: 707.

Man, 34, headache: The ingestion of antipyrin was followed after ten hours by an intense itching with redness at the right ala of the nose, on the right middle finger, and the scrotum, followed by the formation of blisters.

MARTIN. Mém. et bul. soc. méd. chir. Bordeaux, 1896, p. 416.

The ingestion of antipyrin in 2.5 grain doses was followed by a general pemphigoid eruption.

SPIETSCHKA. Discussion. Verhandl. deutsch. dermat. Gesell., 1896, p. 151. Wien and Leipzig.

Woman, 34: Took from 15 to 22.5 grain doses of antipyrin for years. At present 4.5 grains produce urticaria and edema of the face.

WEBBER, H. W. A case of antipyrin eruption. Lancet, London, 1896, 1: 1562.

Woman, 53: A morbilliform eruption followed the ingestion of 10-grain powders of antipyrin twice daily, for three weeks.

1897.

CLÉMENT, V. Des accidents dus à l'emploi de l'antipyrine. Paris, 1897.

Five cases in which an eruption upon the skin followed the administration of antipyrin, and one in which ingestion of the drug was followed by marked prostration.

DRANSART. De l'antipyrinisme: Cas d'eczéma bulleux généralisé consécutif à une faible dose d'antipyrine; deux cas de contractures musculaires. Echo méd. nord, Lille, 1897, 1: 144.

(1) Man, 40: Two grains of antipyrin produced a general bullous eczema, lachrymation, and the symptoms of coryza. (2) In two cases the administration of 7.5 to 15 grains of antipyrin was followed by rapid contractions of the muscles of the legs and arms.

DUHOURCAU. Accidents dus à l'antipyrine. Méd. mod., Paris, 1897, 8: 103.

On two occasions the ingestion of antipyrin produced an erythematous eruption in the case of a girl.

EHRMANN, S. Die lokalisirten Erytheme im Allgemeinen und die lokalisirten Antipyrinerhytheme im Besondern. Wiener med. Wochenschr., 1897, 47: 1697.

Three cases in which antipyrin caused the development of a skin eruption, in one of which it produced swelling of the right eyelid and itching and enlargement of the papillæ of the tongue.

GOLDSCHMIDT, D. Cas d'intolérance excessive pour l'antipyrine. Bul. gén. thérap. (etc.), Paris, 1897, 132: 277.

Young woman, headache: Ingestion of a dose of migrainine was followed by itching of the extremities, lips, and eyelids. On the next day there was swelling of the affected parts and on the third day blisters appeared upon the hands and feet.

HUBER, A. Nebenwirkungen von Arzneimitteln. Cor.-Bl. f. schweiz. Aerzte, 1897, 27: 737.

The ingestion of migrainine in 15-grain doses was followed by severe cutaneous symptoms and ulceration with the formation of pseudo-membranes in the mouth.

LEROUX, C. Purpura généralisé, stomatite pemphygoïde hemorrhagique, troubles trophiques des ongles consécutifs à l'ingestion d'un gramme d'antipyrine. J. clin. thérap. inf., Paris, 1897, p. 606.

Woman, 32: A general pemphigoid eruption with the formation of blisters in the mouth and trophic disturbances of the nails followed the use of antipyrin.

MIBELLI, V. Su gli eritemi fissi da antipirina. Gior. ital. mal. ven., Milano, 1897, **32**: 575.

RUYSSEN, C. Érythème rubéoliforme dû à l'antipyrine. Echo méd. nord, Lille, 1897, **1**: 359.

Girl, 23, tuberculosis: A single dose of 15 grains of antipyrin daily caused the appearance of a morbilliform rash.

TONNEL ET RAVIART. Érythèmes bulleux dus à l'ingestion d'antipyrine; leur pathogénie. Echo méd. nord, Lille, 1897, **1**: 18.

Woman, 57: The ingestion of 15 grains of antipyrin was followed on three occasions by a bullous eruption.

VIDAL, A. Intolérance exceptionnelle pour l'antipyrine. Gaz. hebd. sci. méd. Bordeaux, 1897, **18**: 51.

An eruption of red edematous patches followed the ingestion of between 15 and 30 grains of antipyrin.

#### 1898.

APOLANT, H. Die Antipyrinexantheme. Arch. Dermat. Syph., Wien and Leipzig, 1898, **46**: 364.

The author took 15 grains of antipyrin for headache. After ten minutes there appeared erythema, edema of the eyelids, and itching of the genitals. The symptoms recurred when the dose was repeated.

BLASCHKO. See Lesser, 1898.

Five cases in which the ill effects following the ingestion of antipyrin were exhibited by the skin or mucous membranes.

BRONGNIART, G. Sur un cas de roséole médicamenteuse due à l'antipyrine prise par la voie gastrique. Echo méd. nord. Lille, 1898, **2**: 404.

A dose of 15 grains of antipyrin daily caused the appearance of a morbilliform eruption on the eighth day.

BRUCK. See Lesser, 1898.

A patch the size of a half dollar appeared on the right side of the abdomen each time the patient took antipyrin.

GEBERT. See Lesser, 1898.

Two cases in which herpes progenitalis followed the ingestion of antipyrin.

LESSER. Ueber Antipyrin-Exantheme. Dermat. Zts., Berlin, 1898, **5**: 243.

Two cases in which the use of antipyrin was followed by skin symptoms. In one they consisted of erythematous papules, and in the other of an oval brown spot on the abdomen.

SIBUT, L. Éruption antipyrinique. Bul. soc. franc. dermat. syph., Paris, 1898, **9**: 188.

Antipyrin in 15-grain doses caused the appearance of an eruption upon the skin.

WECHSELMANN, W. Ueber Antipyrinexanthem. Deutsche med. Wochenschr., Leipzig and Berlin, 1898, **24**: 335.

Five cases in which the ingestion of antipyrin was followed by manifestations on the part of the skin.

## 1899.

- D'AULNAY, G. R. Intoxication par la migrainine. *Bul. gén. de thérap. [etc.]* Paris, 1899, **137**: 857.

The ingestion of 7.5 grains of migrainine was followed by pain in the stomach, urticaria, diarrhea with tenesmus, burning on micturition, rapid pulse, and accelerated respiration.

## 1901.

- TROISFONTAINES, P. Éruption pemphigoīde antipyrinique. *Belgique méd., Gand. Haarlem*, 1901, **8** (2): 1.

Man, 38, headache: Two 15-grain doses of antipyrin with a two-hour interval were followed by vomiting and diarrhea, and the appearance of an itching scarlatiniform eruption.

## 1902.

- BERNARD, J. Accidents consécutifs à l'absorption d'antipyrine. *Gaz. méd. Picardie, Amiens*, 1902, **20**: 407.

A nervous patient, 35 years of age, took 10 grains of antipyrin and 3.75 grains of hydrobromate of quinine. Purpuric spots appeared upon the palm, sole, and fingers, followed by desquamation. There was also redness of the urethra and glans, with discharge.

- CARDOSO, A. Um caso de idiosyncrasia para a antipyrina. *Méd. mod., Porto*, 1902, **9**: 250.

- CROUZEL, E. Sur un case d'idiosyncrasie. *J. med. Bordeaux*, 1902, **32**: 794.

Every time that the author took antipyrin, 3.75 grains, there appeared on the dorsum of the left hand a red erythematous patch, painful on pressure.

## 1903.

- CLAVERIE. Éruption, érythémato-bulleuse due à l'antipyrine. *Rev. méd. l'Afrique du nord, Alger*, 1903, **6**: 2228.

Man, 72, headache: Six hours after the ingestion of 15 grains of antipyrin erythematous spots appeared all over the body, with the subsequent development of vesicles and bullæ.

- DANLOS. Éruption à type d'érythème polymorphe produite par l'antipyrine. *Bul. soc. franç. dermat. syph., Paris*, 1903, **14**: 233.

On two occasions the ingestion of antipyrin was followed by nervousness, insomnia, a skin eruption, and the development of blisters in the mouth and upon the genitals.

- DARIER. Antipyrinides. *Rev. internat. méd. chir., Paris*, 1903, **14**: 362.

A bullous eruption upon the dorsum of the hands, and vesicles upon the auricle and knee followed the use of antipyrin.

- NAGATOMI, J. (Antipyrin exanthemata.) *Chingai Iji Shinpo, Tokio*, 1903, p. 515.

- ROUX. Un cas d'intoxication par l'antipyrine. *Poitou méd., Poitiers*, 1903, **18**: 18.

Woman, 54, headache: Two 7.5-grain powders of antipyrin were followed by dyspnea, and great redness and swelling of the skin of the face and body.

- SHISHIDO, S. (Antipyrin exanthemata.) *Chingai Iji Shinpo, Tokio*, 1903, p. 217.

## 1904.

BEHAEGEL. Érythème pigmenté fixe dû à l'antipyrine. J. méd. Bruxelles, 1904, 9: 420.

An eruption of reddish-brown spots followed each dose of 22.5 grains of antipyrin.

DUBOIS-HAVENITH. Érythème pigmenté fixe dû à l'administration de l'antipyrine. Presse méd. belge, Bruxelles, 1904, 56: 731.

An erythematous eruption followed the ingestion of 22.5 grains of antipyrin.

LÖWY, K. Ueber zwei Fälle von Antipyrin-Exanthem. Arch. Dermat. Syph., Wien, 1904, 68: 167.

(1) The ingestion of a teaspoonful of headache powder was followed by general pruritus, an eruption upon the skin, and marked depression. (2) A dose of 15 grains of antipyrin was followed by a morbilliform eruption and great swelling of the face.

MALHERBE, H. Verge noire par éruption antipyrinique. J. mal. cutan. syph., Paris, 1904, 16: 499.

The ingestion of 22.5 grains of antipyrin was followed by an almost black discoloration of the genital organs, which was slow in disappearing.

## 1905.

BRÜNING. Zur Pathogenese der Antipyrinexantheme. Charité-Ann., Berlin, 1905, 29: 787.

Each time the patient took antipyrin he suffered from ulceration of the mucous membrane of the mouth and a vesicular eruption upon the body, including the genital organs.

YAMADA, K. Noch einmal über die Antipyrinexanthema. (Ausz., fac. 4.) Hifubyog. Kiu Hiniokibyog. Zasshi, Tokyo, 1905, 5: 423.

## 1906.

DEGLE, H. Eine eigentümliche Form einer toxischen Dermatose nach Antipyringebrauch. Wien. med. Presse, 1906, 47: 2154.

The ingestion of 15 grains of antipyrin twice daily was followed by the appearance of an eruption resembling miliaria rubra.

## 1907.

GILLES. Intoxication par l'antipyrine chez une accouchée. Toulouse med., 1907 (2 s.), 9: 26.

A dose of 7.5 grains of antipyrin was followed by the appearance of an erythematous eruption. On the next day there was edema of the lower extremities and profuse diarrhea.

## CASES OF COLLAPSE.

In the following instances collapse formed the most prominent feature of the clinical history. The symptoms exhibited were in most cases the usual ones of pallor of the skin, coldness of the extremities, cold perspiration, rapid and feeble pulse, and an anxious and pinched expression, the severity of the symptoms depending on

the intensity of the poisoning. In many of the cases the skin, digestive tract, or other parts of the body presented abnormal symptoms in addition to those of collapse. Cyanosis, however, appeared in only a very few instances.

## 1884.

HUCHARD. Nouveaux faits relatifs à l'action physiologique et thérapeutique de l'antipyrine. *Bul. mém. soc. therap.*, Paris, 1884 (2 s.), 11:205.

Child, 7, typhoid: Collapse followed the ingestion of 12 grains of antipyrin. The case resembled one of carbolic-acid poisoning.

ISRAEL, E. Om Antipyrinet. *Hosp.-Tid.*, Kjöbenhavn, 1884 (3 s.), 2: 1129.

Boy, 13, typhoid: Collapse followed the ingestion of antipyrin.

MAY, F. Antipyrin, das neueste Antipyreticum. *Deutsche med. Wochenschr.*, 1884, 10: 390.

Man, 25, pneumonia: One-half drachm of antipyrin at 7 and 8 p. m., and 15 grains at 9 p. m. were followed by severe collapse.

## 1885.

BLORE. Death after the use of antipyrin; necropsy. *Lancet*, London, 1885, 1: 382.

Woman, 35: At 3 p. m., her temperature being 103° and pulse 132 and feeble, she was given 35 grains of antipyrin, and three hours later one-half of this quantity. By 11 p. m. her temperature was normal. She passed a restless night, with diarrhea and vomiting, fell into a condition of collapse, and died thirty-two hours after taking the antipyrin.

BOLDT, see Draper, W. H. *Med. Rec.*, New York, 1885, 27: 414.

In 2 cases of puerperal septicemia the ingestion of 1 drachm of antipyrin was followed by prostration and semicoma. The symptoms resembled those of carbolic-acid poisoning.

COSSMANN. Collaps nach Antipyrin. *Prakt. Arzt*, Wetzlar, 1885, 26: 106.

Girl, 19, typhoid: Collapse followed the ingestion of 1 drachm of antipyrin in 2 doses, with a two-hour interval.

FAVRE, C. De l'antipyrine dans la fièvre hectique des tuberculeux. *Lyon*, 1885.

Pulmonary tuberculosis. A dose of 22.5 grains of antipyrin was followed by nausea, chills, and coldness of the lower extremities. Later, a drachm administered within five hours produced a tendency to collapse.

GÖTZE. Einige Bemerkungen über die Wirkung des Antipyrin. *Berl. klin. Wochenschr.*, 1885, 22: 145.

(1) Five hours after taking 1.25 drachms of antipyrin in 3 doses the temperature fell to 96.6°, with cyanosis and symptoms of collapse. A similar result followed the ingestion of 1 drachm, and later 0.75 of a drachm. (2) Boy, 14: The ingestion of 37.5 grains of antipyrin in 3 doses was followed by symptoms of collapse and a fall in the temperature of 9°.

HUMBERT-MOLLIÈRE. Discussion of paper by Rollet. *Lyon méd.* 1885, 49: 472.

Collapse followed the ingestion of antipyrin in the case of an old tuberculous woman.

JACCOUD. Sur les effets antithermiques de la thalline. *Bul. acad. méd., Paris*, 1885 (2. s.), **14**: 1443.

Phthisis: (1) Ingestion of 0.5 drachm of antipyrin daily caused, on the third day, a fall of  $9^{\circ}$  in the patient's temperature within three hours. (2) Serious collapse followed the ingestion of 7.5 grains.

MASON, A. L. Typhoid fever at the Boston city hospital in 1884-1885; with remarks on the use of antipyrine. *Boston Med. and Surg. J.*, 1885, **113**: 535.

Out of 100 typhoid-fever patients treated with antipyrin, 6 showed symptoms of collapse within an hour after the ingestion of 20 or 30 grains of the drug.

SCHÜLLER, G. Collaps nach Antipyrin. *Prakt. Arzt, Wetzlar*, 1885, **26**: 145. Youth, 21, typhoid: Severe collapse followed the use of antipyrin.

SCHULZ, R. Behandlung des Typhus abdominalis mit Antipyrin. *Deutsche med. Wochenschr.*, Berlin, 1885, **11**: 333.

The ingestion of 1 drachm of antipyrin in 2 doses was followed by symptoms of collapse.

STRAUSS. Zur Wirkung des Antipyrins. *Berl. klin. Wochenschr.*, 1885, **22**: 562.

Typhoid: The ingestion of 1.25 drachms of antipyrin in 3 doses was followed by collapse.

1886.

SUCHARD. Soc. vaudoise de méd., Oct. 10, 1885, *Rev. méd. de la Suisse rom.*, Genève, 1886, **6**: 56.

Phthisis: Collapse, followed by death, resulted from the ingestion of about 12 grains of antipyrin during the night.

BUNGEROTH. Beobachtungen über das Antipyrin bei infectiösen Erkrankungen der Kinder. *Charité-Ann.*, Berlin, 1886, **11**: 599.

(1) In 22 cases of typhoid fever in children mild collapse followed the administration of antipyrin in 3 cases; severe collapse in 3 cases; dangerous cardiac weakness in 2 cases; and a rubeola-like eruption in 1 case.

DEMIÉVILLE. Soc. vaudoise de méd., Oct. 10, 1885. *Rev. méd. de la Suisse rom.*, Genève, 1886, **6**: 56.

Serious collapse, with coma lasting three days, followed the ingestion of 45 grains of antipyrin in 2 doses within two hours.

GRAHAM, W. Unpleasant effects of antipyrin. *Canada Lancet*, Toronto, 1885-1886, **18**: 138.

Twelve grains of antipyrin taken every three hours produced severe collapse and an eruption of purpuric maculæ upon the back.

POSADSKY, S. Antipyrin bei crupöser Pneumonie. *Deutsche med. Wochenschr.*, Berlin, 1886, **12**: 636.

Lobar pneumonia: In 5 cases out of 25 collapse followed the ingestion of a few doses of antipyrin. In 2 cases there was also an erythema.

REIHLEN, M. Ueber Antipyrin. *Deutsches Arch. klin. Med.*, Leipzig, 1885-6, **38**: 534.

Two cases of collapse in 89 cases treated with antipyrin; 1 in tubercular meningitis, the other in gangrene of the lung.

WELCH, W. M. Clinical note on the use of antipyrin. *Med. News*, Philadelphia, 1886, **48**: 10.

A single dose of 10 grains of antipyrin administered in typhoid fever produced symptoms of collapse.

1887.

BERNOULLI, D. Zur Kenntniss der Nebenwirkungen des Antipyrin. *Cor.-Bl. f. schweiz. Aerzte*, Basel, 1887, **17**: 357.

Woman, 52, rheumatism: A dose of 15 grains of antipyrin was followed by mild collapse and vomiting. A month later a similar dose produced vomiting, cyanosis of lips, dyspnea, and a scarlatiniform eruption.

BROOKS, L. J. Clinical value of antipyretics. *Med. Times*, Philadelphia, 1886-87, **17**: 794.

(1) Boy, 9: The ingestion of 10 grains of antipyrin was followed by cyanosis and symptoms of collapse. (2) Symptoms of collapse followed the ingestion of two 10-grain doses of the drug. (3) A morbilliform eruption appeared after the use of antipyrin.

CHÉRON, P. Contribution à l'étude du danger de l'antipyrine. *Union méd.*, Paris, 1887 (3. s.), **43**: 907.

Typhoid: Collapse followed the ingestion of 15 grains of antipyrin in two doses with an interval of five hours.

HAYS, G. D. A caution as to the use of antipyrin. *New York Med. J.*, 1887, **45**: 100.

Three cases of collapse following the ingestion of antipyrin. One was a case of acute rheumatism, and the other two of typhoid fever.

HENDERSON, R. B. Two cases of poisoning from antipyrine and nux vomica. *Med. Rec.*, New York, 1887, **31**: 95.

Report of two cases of poisoning, in which both antipyrin and nux vomica were administered. Both were characterized by prostration, and in one death resulted.

Note on collapse following antipyrin. *Indian Med. J.*, Lahore, 1887 (n. s.), **1**: 273.

The ingestion of 10 grains of antipyrin by a soldier to reduce temperature was followed by cyanosis and collapse.

JACOBY, G. W. *Med. Rec.*, New York, 1887, **32**: 581.

Author had seen collapse follow a dose of 20 grains of antipyrin.

LUTAUD. Contribution à l'étude des dangers de l'antipyrine. *J. méd.*, Paris, 1887, **12**: 825.

The ingestion of 15 grains of antipyrin in two doses, with a three-hour interval, was followed by collapse.

MENDEL. Die Anwendung des Antipyrin bei Nervenkrankheiten. *Therap. Monatsh.*, Berlin, 1887, **1**: 259.

Author had observed collapse following the ingestion of antipyrin in two cases.

WEILL, E., and CHABANNES. Observation de fièvre typhoïde traitée par l'antipyrine et terminée par la mort. *Lyon méd.*, 1887, **56**: 426.

Typhoid: The ingestion of 9.5 drachms of antipyrin was followed by a relapse, during which the patient received 6.25 drachms in seven days. This was followed by collapse and death.

WILSON, J. C. Note on antipyrin in the treatment of sciatica. *Med. Times, Philadelphia*, 1887-88, **18**: 48.

Alarming prostration followed the administration of 5 grains of antipyrin to a very fat woman with weak heart walls.

1888.

BINET, P. *Soc. méd. de Genève*. 5 Sept., 1888. *Rev. méd. de la Suisse rom., Genève*, 1888, **8**: 635.

Author cites a case in which a dose of 7.5 grains of antipyrin was followed by swelling of the eyelids, an itching eruption, nausea, vertigo, precordial pain, and loss of consciousness.

D'ESPINE, cited by Cordet in discussion of paper on "Des accidents produits par l'antipyrine." *Rev. gén. clin. thérap., Paris*, 1888, **2**: 709.

Author states that he had seen collapse in children with pneumonia follow the ingestion of even small doses of antipyrin.

DRASCHE. *Ueber die Nebenwirkungen des Antipyrins*. *Wien. klin. Wochenschr.*, 1888, **1**: 571.

Typhoid: An enema containing 0.5 drachm of antipyrin was followed by a copious hemorrhagic exanthem and collapse, which ended fatally.

HAFFTER, E. *Cor.-Bl. f. schweiz. Aertze, Basel*, 1888, **18**: 743.

Man, 63, pneumonia: Fatal collapse occurred one hour after the ingestion of 15 grains of antipyrin.

MOLLIÈRE, H., cited by Peter in "Les traitements de typhoïdiques." *Bul. méd., Paris*, 1888, **2**: 551.

(1) Typhoid patient, 52 years of age, after taking antipyrin for fifteen days, died of cachectic purpura and debility induced by the drug. (2) Ingestion of antipyrin by a typhoid-fever patient 26 years old caused uremic convulsions, which ended fatally.

LOEBL, J. M. *Erfahrungen über Antipyrin*. *Wien. med. Presse*, 1888, **29**: 121.

Child, 6, typhoid: Ingestion of four doses of antipyrin, 3.25 grains each, was followed by cyanosis and symptoms of collapse.

MÜLLER, H. *Ueber toxische Nebenwirkungen des Antipyrin*. *Cor.-Bl. f. Schweiz. Aerzte, Basel*, 1888, **18**: 681.

Girl, 10, acute articular rheumatism: Each dose of 11 grains of antipyrin was followed by nausea, dizziness, itching, and a tendency to collapse.

PAYNE. Discussion of paper by R. H. Lewis. *North Carolina Med. J., Wilmington*, 1888, **21**: 297.

Ingestion of 8 grains of antipyrin was followed by collapse.

RAPIN, E. *Accidents dus à l'antipyrine*. *Rev. méd. de la Suisse rom., Genève*, 1888, **8**: 687.

Woman, 28, sciatica: The ingestion of 1-grain doses of antipyrin for six days was followed by cyanosis, symptoms of collapse, and the appearance of an itching eruption.

ROUSSEAU. *Des accidents causés par l'antipyrine*. *Rev. gén. clin. thérap., Paris*, 1888, **2**: 515.

The ingestion of 7.5 grains of antipyrin was followed by itching of the face, swelling of the eyelids, and symptoms of collapse.

SYKES. Discussion of paper by R. H. Lewis. North Carolina Med. J., Wilmington, 1888, 21: 297.

(1) Two doses of 10 grains each of antipyrin caused collapse and death in a girl of 10. (2) Typhoid: Ten grains of antipyrin caused coma and collapse.

1889.

CROMBIE, A. The comparative value of antipyrin, antifebrin, and phenacetin as antipyretics. Practitioner, London, 1889, 43: 270.

A case in which collapse followed the ingestion of antipyrin.

v. KOGERER. Antipyrinbehandlung des hektischen Fiebers. Wien. klin. Wochenschr., 1889, 2: 778; 802.

Out of 100 cases of phthisis in which antipyrin was given, erythema was noted in 2 instances and collapse in 1. The administration of antipyrin to the same patient on two occasions was followed by collapse.

PURDON, C. S. Intolerance of antipyrin. Brit. Med. J., London, 1889, 1: 1345.

Man, 50, sciatica: A 5-grain dose of antipyrin was followed by severe nervous symptoms, cyanosis, and collapse.

WINGRAVE, T. Ill effects of antipyrin. Lancet, London, 1889, 2: 313.

Woman, 21: A dose of 10 grains of antipyrin was followed by dyspnea, loss of power on the left side, the appearance of an eruption, and symptoms of collapse.

1890.

SCHWABE. Fall von akuter Antipyrinvergiftung. Deutsche Med.-Ztg., Berlin, 1890, 11: 501.

Woman, 22, neuralgia: A dose of 15 grains of antipyrin was followed by dyspnea, complete blindness lasting thirty minutes, and symptoms of collapse.

SPITZER, F. Selbstmordversuch mit Antipyrin. Centrbl. ges. Therap., Wien, 1890, 8: 134.

The ingestion of 2 drachms of antipyrin within an hour was followed by swelling of the face and eyelids and symptoms of collapse.

1891.

WATKINS, R. L. A case of antipyrine poisoning. New York Med. J., 1891, 54: 314.

Woman, 30: A dose of about 20 grains of antipyrin was followed by symptoms of cyanosis, collapse, and an eruption of white blotches. The after effects lasted two months, during which time she suffered from weakness, palpitation of the heart, and an occasional reappearance of the eruption.

1892.

GUTTMANN, P. Ueber einen Fall von Antipyrin-Vergiftung. Therap. Monatsh., Berlin, 1892, 6: 560.

The ingestion of 2.5 drachms of antipyrin, in 15 doses, twice daily, was followed by transient blindness, the appearance of an eruption, and symptoms of collapse.

1893.

KRYSINSKI, St. Przypadek otrucia antypiryna. Gaz. lek., Warszawa, 1893 (2 s.), 13: 1031. (Abs. Sajous, 1895, 5: A-33.)

Girl, 20: Ingestion of 81 grains of antipyrin was followed by symptoms of collapse.

PATERSON, D. R. The untoward effects of antipyrin, acetanilide, and phenacetin. Practitioner, London, 1893, **51**: 241.

Several cases of antipyrin poisoning in which the symptoms were mainly those of cyanosis and collapse.

TURNBULL, L. A. Case of collapse caused by antipyrin. Memphis Med. Month., 1893, **13**: 313.

(1) Man, 52, acute articular rheumatism: After the second dose of 10 grains of antipyrin the patient became unconscious and passed into a state of collapse. (2) Woman: A dose of 10 grains of antipyrin was followed by symptoms of collapse.

1894.

MELVILLE, S. Domestic drugging; a case of antipyrin poisoning. Lancet, London, 1894, **2**: 1515.

Ingestion of 30 grains of antipyrin within a few hours by a young woman was followed by collapse.

1896.

HAYES, H. W. McC. A case of poisoning by antipyrin. Brit. Med. J., London, 1896, **1**: 269.

Following the ingestion of 10 grains of antipyrin, the patient became cyanosed and passed into a condition of collapse.

1897.

EISENMANN, A. Ein Fall von Antipyrinvergiftung. Therap. Monatsh., Berlin, 1897, **11**: 233.

Youth, 20, headache: Ingestion of 7.5 grains of antipyrin was followed by dyspnea, a scarlatiniform eruption, cyanosis, and symptoms of collapse.

NEWTON, D. G. Notes on two cases of poisoning from antipyrin. Quart. Med. J., Sheffield, 1897-98, **6**: 133.

(1) Man, 32: Took 10 grains of antipyrin for headache. Within two minutes he was seized with alarming symptoms—a feeling of suffocation, swelling of the face so that the eyes were closed, lachrymation, and dyspnea. The tongue was much swollen and the speech thick. There was no eruption. He was at work the next day with a slight swelling of the face. He had previously suffered from a similar attack, probably caused, as in this instance, by antipyrin. (2) Woman, 54: Ten grains of antipyrin caused temporary blindness, unconsciousness, convulsions, and symptoms of collapse.

#### CASES OF PROSTRATION.

Under this heading are grouped the cases in which the systemic depression was very marked, but the symptoms were hardly severe enough to warrant classifying them under the term "collapse."

1884.

TILMAN, O. Antipyrin das neueste Antipyreticum. Berlin, 1884.

In two cases, one of phthisis and the other of typhoid fever, the administration of antipyrin was followed by symptoms of marked depression.

## 1885.

BARIÉ, E. Note sur la valeur comparative de l'antipyrine et du sulfate de quinine, dans le traitement de la fièvre typhoïde. *France méd.*, Paris, 1885, **2**: 1727.

Two cases of typhoid fever in which the administration of antipyrin was followed by mild symptoms of collapse.

FEDÉLI, C. Di alcuni fenomeni susseguiti all' uso dell'antipirina in un caso di febbre etica. *Raccoglitore Med.*, Forlì, 1885 (s. 4), **24**: 414.

Following the ingestion of antipyrin the patient's temperature rose to 106.6°, accompanied by chills and syncope.

## 1886.

JOHNSON, R. Clinical observations on the action of antipyrin and thallin. *Lancet*, London, 1886, **2**: 388.

(1) Phthisis: Marked prostration followed the ingestion of antipyrin in three doses of 10, 20, and 20 grains, respectively. (2) Three 15-grain doses at intervals of one hour caused similar symptoms in a boy, with the addition of a scarlatiniform eruption.

## 1887.

GUTTMANN, P. Zwei Beobachtungen über Nebenwirkungen des Antipyrin. *Therap. Monatsh.* Berlin, 1887, **1**: 214.

Report of two cases of antipyrin poisoning, one characterized by cyanosis and marked prostration, and the other by an itching eruption.

SEIFERT, O. Ueber Antipyrin als Nervinum. *Centrbl. klin. Med.*, Leipzig, 1887, **8**: 649.

(1) Ingestion of 15 grains of antipyrin was followed by pains in the extremities, dizziness, and headache. (2) A dose of 15 grains of antipyrin given at 7 p. m. was followed by a severe buzzing in the ears, which prevented sleep for several hours.

WEIR, A. H. Dangers of antipyrin. *Med. News*, Philadelphia, 1887, **51**: 166.

A dose of 7 grains of antipyrin was followed in five minutes by roaring in the ears, lachrymation, a burning sensation about the neck and face, precordial distress, and dyspnea. On another occasion 7 grains, and later, 3.5 grains, produced a similar train of symptoms.

## 1888.

MAYOR, A. Abs., *Brit. Med. J.*, London, 1888, **2**: 787.

Author states that he had repeatedly observed instances in which serious toxic symptoms followed the ingestion of antipyrin in doses as small as 7.5 grains.

MONOD, L. Accidents déterminés par l'absorption d'une faible dose d'antipyrine. *Tribune méd.*, Paris, 1888, **20**: 113.

A dose of 7.5 grains of antipyrin was followed by symptoms of coryza, dyspnea, aphonia, swelling of the eyelids, lachrymation, and general weakness, without fever or eruption.

## 1889.

BERGER, H. Ueber einen Fall von Antipyrinintoxikation. *Therap. Monatsh.*, Berlin, 1889, **3**: 185.

Ingestion of 15 grains of antipyrin by a patient 22 years of age was followed by dyspnea, palpitation, swelling of the face, profuse salivation, increased secretion of tears, and perspiration, and a feeling of paralysis which lasted for several days.

B., H. The danger of antipyrin. *Med. Rec.*, New York, 1889, **36**: 431.

Woman, facial neuralgia: Thirty grains of antipyrin in three equal doses, six hours apart, caused marked prostration and convulsions.

FEENY, M. H. Remarkable action of antipyrin in renal disease. *Lancet*, London, 1899, **2**: 431.

Two cases of renal disease in which antipyrin in 3-grain doses caused increased irregularity of heart and syncope.

HAHN, F. Ein Fall von Antipyrinexanthem. *Centrbl. klin. Med.*, Leipzig, 1889, **10**: 849.

Ingestion of 0.5 drachm of antipyrin was followed by dysphagia, cyanosis, and swelling of the lips. Erythema developed the next day.

HUCHARD, H. Contre-indications de l'antipyrine pendant la période menstruelle. *Rev. gén. clin. therap.*, Paris, 1889, **3**: 52.

Administration of 15 grains of antipyrin was followed by cyanosis and symptoms of depression.

NORTHROP, W. P. A case of antipyrin poisoning. *Med. News*, Philadelphia, 1889, **54**: 461.

The administration of 15 grains of antipyrin to a hysterical woman caused sneezing, vomiting, diarrhea, and marked prostration; 5 grains caused sneezing, dyspnea, and an urticarial eruption.

#### 1890.

MITCHELL, cited by Falk, E. Ueber Nebenwirkungen und Intoxicationen bei der Anwendung neuerer Arzneimittel. *Therap. Monatsh.*, Berlin, 1890, **4**: 97.

The ingestion of 1 drachm of antipyrin in three doses at hourly intervals was followed by persistent vomiting and marked prostration.

YOUNG, E. W. Poisoning with antipyrin. *Med. Rec.*, New York, 1890, **37**: 409.

Man, 43: A dose of 6 grains of antipyrin with a teaspoonful of whisky and water was followed by dyspnea, vertigo, dimness of vision, an urticarial eruption, and marked prostration.

#### 1891.

PORTO DE CAHY. Syncopes produites par l'antipyrine. *Bul. soc. méd. prat.*, Paris, 1891, p. 29.

Girl, 20: A dose of 15 grains of antipyrin was followed by vertigo and marked depression. Two months later a dose of 7.5 grains produced similar symptoms. Upon a third occasion syncope followed the ingestion of 15 grains.

#### 1892.

PIGNOT, cited by Fournier, 1892, p. 495.

A scarlatiniform eruption and marked depression followed the ingestion of antipyrin.

#### 1893.

CERNÉ. Accidents dus à l'antipyrine. *Normandie méd.*, Rouen, 1893, **8**: 273.

Girl, 11: Each dose of antipyrin was followed by vomiting, nose bleed, and depression.

1894.

LEPINE, R. Sur les accidents produits par l'antipyrine. *Semaine méd.*, Paris, 1894, **14**: 121.

Woman, 53: On three occasions a 5-grain dose of antipyrin was followed by enormous swelling of the lips and tongue, coma, involuntary evacuations of bladder and bowels, and marked prostration.

SUTTON, A. Toxic symptoms induced by antipyrin and chlorate of potash. *Australas. Med. Gaz.*, Sydney, 1894, **13**: 43.

Young woman, headache: A dose of 5 grains of antipyrin was followed by the appearance of a bright red rash and symptoms of marked depression.

1896.

SCHEEL. Ein Fall von Antipyrinvergiftung. *Cor.-Bl. allg. Mecklenb. Aerzte*, Rostock (1896), 1893-97, Nos. 151-187, p. 389.

Woman, 50, headache: Ingestion of 8 grains of migrainine was followed by swelling of the tongue, upper lip, pain in the eyes and lachrymation, a scarlatiniform eruption, and marked prostration.

1897.

DUCHENNE. Intolérance excessive pour l'antipyrine. *Méd. mod.*, Paris, 1897, **8**: 167.

The ingestion of 12 grains of migrainine was followed by marked prostration and the appearance of an erythematous rash with the subsequent development of blisters.

WALLACE, F. G. Poisoning by antipyrin; recovery. *Lancet*, London, 1897, **1**: 409.

Woman, convalescent from typhoid: Administration of 10 grains of antipyrin in aromatic spirits of ammonia and water was followed by temporary blindness, a bright red eruption, dyspnea, and great depression.

WEBSTER, E. Antipyrin poisoning. *Brit. Med. J.*, London, 1897, **1**: 458.

Ingestion of 5 grains of antipyrin in a sedative mixture was followed by great swelling of the face, dyspnea, cyanosis, an eruption, and marked prostration.

1902.

SEILER, D. Ein Fall von Antipyrin-Intoxikation. *Cor. Bl. f. schweiz. Aerzte*, Basel, 1902, **32**: 470.

Woman, 26, acute rheumatism: After having taken about 3 drachms of antipyrin in divided doses there appeared edema of the face and a scarlatiniform eruption with marked depression.

1904.

LANDRIEUX ET ROUSSEAU. Intoxication par l'antipyrine. *Bul. méd.*, Paris, 1904, **18**: 357.

The ingestion of 0.5 drachm of antipyrin was followed by very intense dyspnea, swelling and redness of the face, coryza, and prostration.

1907.

AZÉMA. Sur un cas d'intoxication par l'antipyrine. *Toulouse méd.*, 1907 (2. s.), **9**: 111.

Woman, 42: Six doses of antipyrin of 7.5 grains each within three hours were followed by vertigo, persistent vomiting, unconsciousness, and marked prostration.

## NERVOUS SYMPTOMS.

In these cases the nervous symptoms appear to have been very prominent. The symptoms varied widely in the different cases. For example, there was in one case what appeared to be temporary paralysis, and in several, excessive restlessness or convulsions. In others there were disturbances of sensation, like numbness, tingling, formication, and sensation of prickling. In still others there were disturbances of hearing or speech, great mental excitement, excessive sneezing, vertigo, delirium, or coma. In one or two instances the symptoms resembled those of hysteria.

## 1888.

GIQUEL. Les accidents de l'antipyrine. *Gaz. hebd. méd.*, Paris, 1888, **25**: 183.

Ingestion of 15 grains of antipyrin was followed by itching of the gums, persistent sneezing, and a tickling sensation in the larynx, causing cough and hoarseness. This was followed by symptoms of coryza. On another occasion 3.75 grains caused similar symptoms, but milder in degree.

PETERS, S. Poisoning by a ten-grain dose of antipyrine. *Med. Reg.*, Philadelphia, 1888, **3**: 275.

Woman, 25, headache: Ingestion of 10 grains of antipyrin was followed by distressing nervous symptoms, including pain in the head, excessive sneezing, swelling of the eyes and lachrymation, and maniacal excitement.

ROBB, J. T. Idiosyncrasy with regard to antipyrin. *Lancet*, London, 1888, **2**: 163.

Woman, headache: A dose of 15 grains of antipyrin was followed by nausea, sneezing, symptoms of coryza, dyspnea, and aphonia.

STURGE, W. A. Idiosyncrasy with regard to antipyrin: A warning. *Brit. Med. J.*, London, 1888, **1**: 243.

The ingestion of 5 grains of antipyrin by a young woman was followed by the appearance of an urticarial eruption and disagreeable nervous symptoms, including excessive sneezing, dyspnea, profuse sweating, coppery taste and smell, ringing in the ears, etc.

## 1889.

BATTEN, R. D., and BOKENHAM, T. J. A contribution to our knowledge of the physiological action of antipyrin. *Brit. Med. J.*, London, 1889, **1**: 1224.

(1) In each of 3 cases of poisoning by antipyrin there was great restlessness, anxiety, and giddiness, and a sensation of prickling in the feet. (2) A girl taking 45 grains of antipyrin daily for chorea became, on the third morning, drowsy, dizzy, and finally delirious, with slow, labored breathing.

## 1892.

COHN, M. Antipyrinintoxication. *Therap. Monatsh.*, Berlin, 1892, **6**: 624.

A dose of 7.5 grains of antipyrin was followed by dizziness, incoherent speech, and vomiting.

## 1895.

LEWIN, G. *Berl. klin. Wochenschr.*, 1895, **32**: 727.

(1) Antipyrin taken for headache caused convulsions and delirium. (2) The ingestion of antipyrin was followed by severe dyspnea.

1904.

DANCOURT, C. Un cas d'intoxication profonde par l'usage immodéré de l'antipyrine. Nord. méd., Lille, 1904, **10**: 89.

Patient, 55: Habitual use of 0.5 drachm of antipyrin daily had a detrimental effect upon the nervous system, causing abolition of the reflexes and slight paralysis.

## MOUTH SYMPTOMS.

In these cases the toxic symptoms were exhibited chiefly by the mucous membrane of the mouth. There was, in most instances, a burning, prickling sensation, which was followed by swelling and the development of small blisters upon the tongue, inside of the cheeks or gums, with subsequent ulceration. In most cases the ulcers healed kindly. In one of the cases a number of abscesses formed in the mouth.

1889.

BOURNS, D. C. G. Unusual effects of antipyrin. Brit. Med. J., London, 1889, **2**: 818.

A dose of 20 grains of antipyrin was followed by cyanosis of the lips, swelling of the tongue, and the development of small ulcers within the mouth.

1890.

SALINGER, J. L. A case of antipyrine poisoning, with the formation of membranes in the mouth, and symptoms of *Laryngismus stridulus*. Amer. J. Med. Sci., Philadelphia, 1890 (n. s.), **99**: 489.

Woman, 53: A dose of 5 grains of antipyrin was followed by dyspnea, an urticarial eruption, swelling of the lips and tongue, coma, and symptoms of collapse. On the third day a white membrane formed upon the tongue, lips, and pharynx, and soon after 13 abscesses the size of a chestnut or smaller developed in the mouth. On two subsequent occasions the ingestion of 5 grains of the drug was followed by similar symptoms.

1891.

VEIEL. Ein seltener Fall von Blasenausschlag in Folge von Antipyrin. Arch. Dermat. Syph., Wien, 1891, **23**: 33.

Man, 33, headache: Ingestion of 15 grains of antipyrin was followed by itching of the palms and soles, swelling of the lips, and the formation of blisters in the mouth. Similar symptoms appeared whenever the patient took antipyrin.

1893.

GOURIN, E. Des accidents dus à l'antipyrine. Paris, 1893, p. 59.

Ingestion of 15 grains of antipyrin was followed by swelling and ulceration within the mouth.

1894.

BRASCH, M. Zum Capitel der Antipyrinexantheme. Therap. Monatsh., Berlin, 1894, **8**: 565.

Ingestion of 30 grains of antipyrin was on four occasions followed by swelling of the lip with the formation of blisters and the appearance of white plaques on the tongue.

1895.

SENATOR. Berl. klin. Wochenschr., 1895, **32**: 727.

Girl, 16: Ingestion of 45 grains of antipyrin within three days was followed by a burning sensation in the eye, mouth, tongue, and pharynx, and the appearance of vesicles. At the same time an urticarial eruption developed upon the body.

1896.

DALCHÉ, P. Accidents causés par l'antipyrine. Stomatite ulcéro-membraneuse. Bul. mém. soc. méd. hôp., Paris, 1896 (3 s.), **13**: 704.

Man, 26: A dose of 15 grains of antipyrin resulted in the appearance of vesicles in the mouth followed by ulceration.

STEINHARDT. Idiosynkrasie gegen Antipyrin. Therap. Monatsh., Berlin, 1896, **10**: 629.

The ingestion of 15 grains of antipyrin was followed by swelling of the lower lip and the development of ulcers within the mouth.

1897.

LYON. Dermatitis et stomatitis pemphigoides dues à l'antipyrine. Méd. mod., Paris, 1897, **8**: 167.

Woman, 32: The ingestion of 15 grains of antipyrin was followed by the appearance of a pemphigoid eruption around the knee and elbow. There was also an eruption upon the mucous membrane of the mouth.

1898.

IMMERWAHR, R. Ein Fall von Antipyrinintoxication. Berl. klin. Wochenschr., 1898, **35**: 751.

On two occasions the ingestion of 0.5 grain of antipyrin was followed by the appearance of vesicles within the mouth.

MARTYN, G. K. Stomatitis following the administration of antipyrin. Brit. Med. J., London, 1898, **2**: 807.

Ingestion of antipyrin was followed by the appearance of patches of superficial stomatitis.

1899.

DELOBEL. Stomato-Glossite herpétiforme consécutive à l'absorption d'antipyrine. J. sci. méd. Lille, 1899, **1**: 25.

After taking 30 grains of antipyrin, and again after 15 grains, the patient suffered from an eruption of herpetic vesicles in the mouth.

1903.

LEREDDE ET PAUTRIER, L. Étude expérimentale d'une éruption médicamenteuse, due à l'antipyrine; existence de lésions sanguines. Compt. rend. soc. biol., Paris, 1903, **55**: 910.

The ingestion of 3 grains of antipyrin was followed by pruritus of the genital organs, an urticarial eruption, nasal catarrh, and patches in the mouth and upon the lips.

1905.

LOEBL, H. Seltene Lokalisation eines Antipyrinexanthems. Med. Bl., Wien, 1905, **28**: 315.

Following the ingestion of antipyrin the interior of the mouth became covered with small blisters, which burst, giving rise to confluent ulceration.

1906.

LEVIN, E. Zur Kenntniss der Migräninvergiftung. Berl. klin. Wochenschr., 1906, **43**: 766.

Ingestion of 15 grains of migrainine was followed by swelling and ulceration of the mucous membranes of the mouth and profuse salivation.

## EYE SYMPTOMS.

Under this heading are included the cases in which the acuity of vision was diminished or the sight temporarily lost, and also the cases characterized by the symptoms of coryza, with swelling of the lids, lachrymation, and, in some instances, photophobia. The symptoms in most cases appeared promptly, sometimes, it seemed, almost as soon as the drug reached the stomach.

1906.

HOTZ, F. C. A case of antipyrin amaurosis induced by one hundred and thirty grains taken in forty-eight hours. Arch. Ophth., New York, 1906, **35**: 160.

Man, 33: Had taken antipyretics for pain for three years. One hundred and thirty grains of antipyrin within forty-eight hours caused his sight to become dim, and within two days it was lost completely. It returned slowly and in two months he was practically well again.

INOUE, M. Antipyrin keratitis. Ophthalmol., Milwaukee, 1905-6, **2**: 618.

Woman, 48: Ingestion of 25 grains of antipyrin in 2 doses was followed by the development of 41 superficial infiltrations upon the cornea, 25 upon the right and 16 upon the left. The author also reviews a case reported by Mizno,<sup>a</sup> in which ulcers developed upon the cornea as a result of the ingestion of antipyrin.

## GENITO-URINARY SYMPTOMS.

Under this head are grouped the cases in which the toxic effects of antipyrin were exhibited chiefly in some part of the genito-urinary tract. The symptoms presented were principally albuminuria, suppression or incontinence of urine, or symptoms of urethro-cystitis.

1884.

MÜLLER, F. Beobachtungen über Antipyrin. Centrbl. klin. Med., Leipzig, 1884, **5**: 569.

Drowsiness and involuntary micturition appeared in two cases after the ingestion of antipyrin.

1885.

HAVEN, H. C. Discussion of Mason's paper. (1885.) p. 538.

Infant: Ingestion of at least four 10-grain doses of antipyrin at intervals of half an hour caused vomiting and complete suppression of urine for over twenty-four hours.

<sup>a</sup> Nihon-Gankwa-Gakkwai-Zasshi, 1904, vol. 8, No. 11.

1887.

DE TULLIO, P. L'antipirina nel reumatismo articolare acuto. *Progresso med.*, Napoli, 1887, 1: 913.

The ingestion of antipyrin by a patient suffering from articular rheumatism was followed by a transient albuminuria.

1888.

ROULIN, L. Observation d'accidents fébriles produits par l'antipyrine. *Bul. mém. soc. méd. prat.*, Paris, 1888, p. 478.

Ingestion of 7.5 grains of antipyrin hourly for four hours was followed by a severe chill, delirium, vomiting, and suppression of the urine.

1891.

BIGGS, H. M. Notes on a case of poisoning by antipyrine. *New York Med. J.*, 1891, 53: 35.

Man, 35, headache: Soon after the ingestion of 60 grains of antipyrin within thirty hours the urine became dark olive-green in color. It contained a small quantity of albumin and a few casts. Secretion scanty. Symptoms disappeared in the course of two or three days. No evidence of previous renal disease.

TOMPKINS, E. L. Albuminuria caused by antipyrine. *Virginia Med. Month.*, Richmond, 1891-92, 18: 105.

Man, locomotor ataxia: Took for pain each night about 60 grains of antipyrin. Entered the hospital with edema of the legs and eyelids. The urine was so full of albumin that it solidified on boiling. Albumin was abundant in the morning and scanty in the evening. When the drug was discontinued the albuminuria disappeared and the edema diminished.

1895.

RAMOS, D. Albuminuria produzida por altas doses de antipyrina. *Brazil-med.*, Rio de Janeiro, 1895, 9: 233.

1897.

SPANODIS, J. Dangers de l'antipyrine dans l'erysipèle. *Semaine méd.*, Paris, 1897, 17: 42.

Three cases in which the ingestion of antipyrin was followed by anuria, with great restlessness and marked depression. One case terminated in death.

1898.

BESNIER. *Bul. soc. franç. dermat. syph.*, Paris, 1898, 9: 193.

An intense general urticaria followed the ingestion of antipyrin, and an antipyrin tampon inserted for epistaxis caused vesication and symptoms of urethro-cystitis.

## SYMPTOMS OF CORYZA.

1888.

TAYLOR, H. C. Idiosyncrasy to antipyrin. *Brit. Med. J.*, London, 1888, 1: 695.

Woman, headache: On two occasions the ingestion of antipyrin was followed by symptoms of coryza and severe paroxysms of coughing.

## 1897.

GROLL ET MEUNIER. Intoxication par l'antipyrine. Dauphiné méd., Grenoble, 1897, **21**: 38.

The ingestion of 22.5 grains of antipyrin was followed by symptoms of coryza.

## 1903.

ALBAREL. Accidents dus à l'antipyrine. Rev. gén. clin. thérap., Paris, 1903, **17**: 612.

On two occasions the ingestion of a 7.5-grain dose of antipyrin was followed by coughing, burning, and dryness within the mouth, and symptoms of severe coryza.

## MISCELLANEOUS.

## 1888.

BRANDENBERG, F. Nebenwirkung des Antipyrins. Cor.-Bl., f. schweiz. Aerzte, 1888, **18**: 611.

Man, acute articular rheumatism: Ingestion of 15 grains of antipyrin was almost immediately followed by odontalgia, severe otitis, and lachrymation. On another occasion one-half of the above dose produced similar symptoms.

## 1889.

TUCZEK, F. Schwere Antipyrinvergiftung bei einem Kinde. (Antipyrinepilepsie.) Berl. klin. Wochenschr., 1889, **26**: 373.

Boy, 4, whooping cough: Antipyrin, 18 grains in 3 doses daily for three weeks, was followed by vomiting, drowsiness passing into coma, convulsions, and the appearance of a macular erythema.

## 1890.

DUFFUS, J. C. G. Parotitis caused by antipyrin. Brit. Med. J., London, 1890, **2**: 733.

Young woman, influenza: A dose of 10 grains of antipyrin was followed by dyspnea and swelling of the parotid glands.

## 1891.

COMBEMALE. Un cas d'antipyrinisme chronique. Bul. méd. nord, Lille, 1891, **30**: 364.

A case of persistent use of antipyrin in which the patient took from 15 to 30 grains daily for four years.

VERNEUIL. Gangrène partielle du pied, consécutive à des injections hypodermiques d'antipyrine. Bul. acad. méd., Paris, 1891 (3. s.), **26**: 602.

Man, 39, neuralgia: Gangrene followed the hypodermic injection of antipyrin.

## 1893.

CAPPELLETTI, L. Un caso di antipirina mania. Riv. sper. di freniat., Reggio-Emilia, 1893, **19**: 100.

Mania for antipyrin in a neurotic girl aged 23. Took small doses for headache, and gradually increased the amount up to 2 drachms daily, causing increase in the severity of the headaches, anorexia, hysterical convulsions, and symptoms of depression.

1895.

GONZÁLEZ Y CAMPO, J. Intoxicacion por la antipirina a dosis terapéutica. *Rev. de med. y cirug. práct.*, Madrid, 1895, **36**: 209.

Case in which the poisonous effects of antipyrin may have been brought about by a cumulative action due to imperfect elimination.

1897.

PAPILLON, G. E. Note sur un cas rare de dermatoneurose consécutive à l'ingestion d'antipyrine. *Echo méd. nord*, Lille, 1897, **1**: 97.

Girl, 19: Habitual use of antipyrin. Gradually increased the amount until she was taking from 1 to 1.5 drachms daily. The symptoms resembled those of ulcer of the stomach.

### ACETPHENETIDIN (PHENACETIN).

#### INTRODUCTORY RÉSUMÉ.

Following is a list of the recorded cases of poisoning by acetphenetidin (phenacetin) from 1887 to the close of the year 1907, with a brief abstract of each case. During this period 70 or more cases were reported by 41 observers. As already stated, it is practically impossible to determine the number of the cases with accuracy, owing to the indefinite character of some of the reports. Of the total number of cases, 3, or 4.2 per cent, are reported to have terminated fatally. This number, 70, is notably less than the reported number of cases of poisoning by either acetanilid or antipyrin, and this fact tends to substantiate the common belief that of the three drugs acetphenetidin is, under ordinary circumstances, the least liable to produce ill effects.

The number of cases of poisoning reported in each year since the introduction of acetphenetidin as a remedial agent, together with the number of observers, is shown in the following table:

*Cases of acetphenetidin (phenacetin) poisoning reported annually, 1887-1907.*

[No cases reported for years omitted.]

Year.	Number of cases.	Number of observers.	Year.	Number of cases.	Number of observers.	Year.	Number of cases.	Number of observers.
1887.....	1	1	1893.....	2	1	1903.....	1	1
1888.....	23	10	1894.....	3	3	1904.....	2	2
1889.....	11	6	1895.....	6	4	1905.....	2	2
1890.....	6	3	1896.....	1	1	1907.....	1	1
1891.....	5	2	1899.....	1	1			
1892.....	4	2	1901.....	1	1	Total.	70	41

It will be seen that 23, or 32.8 per cent, of all the cases were reported during the year following the advent of acetphenetidin as a medicine in 1887, and that 40, or 57.1 per cent, were reported during the years 1888, 1889, and 1890. The large proportion of cases reported during this period was undoubtedly due in part, as in case of acetanilid and antipyrin, to the fact that at this time the depressing effect of acet-

phenetidin was not fully appreciated, and it was administered more or less freely in asthenic as well as sthenic affections. This method of administration resulted in the production of ill effects in not a few cases. After the year 1890 the number of cases of poisoning reported annually was, upon the average, only two or three cases, and the number appears to have decreased rather than increased as the years passed.

The ill effect which appears to occupy the place of greatest importance in the recorded cases is general systemic depression. This symptom appears to have been present in 27, or 38.5 per cent, of the cases. In 12 cases, or 17.1 per cent, it amounted to actual collapse, and in 15, or 21.4 per cent, it was present in a milder form. Cyanosis was reported in 34.3 per cent of the cases, and the comparatively frequent occurrence of this symptom indicates the close pharmacological relationship which exists between acetphenetidin and acetanilid. Skin affections of various kinds were noted in 30 per cent of the cases, dyspnea in 14.3 per cent, and disturbances of the functions of the kidneys in 10 per cent.

#### ABSTRACTS OF ACETPHENETIDIN (PHENACETIN) CASES.

1887.

KOBLER, G. Das Acetphenetidin als Antipyreticum. Wien. med. Wochenschr., 1887, **37**: 868.

In a phthisical patient two doses of phenacetin of 4.5 grains each within two hours caused the patient's temperature to fall rapidly to 95° in the rectum, with profuse perspiration and a feeling of chilliness.

1888.

CARSLAW, J. H. Phenacetine as an antipyretic. Glasgow Med. J., 1888, **30**: 64.

A single dose of 5 grains of phenacetin caused collapse in three out of five tubercular patients to whom the drug was administered.

CATTANI, G. La fenacetina. Gazz. med. ital. lomb., Milano, 1888, **48** (9 s. vol. 1): 455.

The author had twice observed hematuria and nephritis following the ingestion of phenacetin. He had also observed an acne-like eruption.

HOPPE, H. Ueber die Wirkung des Phenacetin. Therap. Monatsh., Berlin, 1888, **2**: 160.

(1) Anemic girl took 19 grains of phenacetin, and after four hours a second powder. This was followed by dizziness, shivering, yawning, chilliness, blueness of the nails, and some nausea. (2) Woman, 44: The ingestion of 15 grains of phenacetin for headache was followed by chills and dizziness. (3) Thirty grains of the drug taken by a healthy student were followed by persistent yawning, nausea, insomnia, general weakness, feeble pulse, and inability to stand. The symptoms lasted for three hours. (4) Woman, 26: The ingestion of 15 grains of phenacetin for headache was followed in fifteen minutes by chilliness, coldness of the extremities, severe palpitation, and a sensation of intense fear. The symptoms passed off after six hours.

- V. JAKSCH, R. Ueber die neueren Antipyretica und ihre Wirkung am Krankenbette. *Therap. Monatsh.*, Berlin, 1888, **2**: 189.

Author had observed that the administration of 1.5 to 3 grains of phenacetin to children in a number of cases produced profuse sweating, severe cyanosis, and even symptoms of collapse.

- LINDMANN. Unangenehme, bedrohliche Nebenwirkungen des Phenacetin. *Therap. Monatsh.* Berlin, 1888, **2**: 307.

Woman, 34: Soon after taking 15 grains of phenacetin she felt dizzy, cold, and nauseated. Her headache became worse, and after three hours she took another phenacetin powder. This was followed by an aggravation of the symptoms; the nausea and sensation of chilliness increased, the hands, lips, and cheeks were deep blue, and there was cold perspiration and dyspnea.

- MAHNERT, F. Ueber Phenacetin vom klinischen und physiologischen Standpunkte. *Deutsche med. Wochenschr.*, Leipzig, 1888, **14**: 1051.

A nervous woman, after taking 13.5 grains of phenacetin for headache, developed a well-marked urticaria on the face and chest.

- MASIUS. Contribution à l'étude de propriétés thérapeutiques de la phénacétine. *Bull. acad. roy. méd. belg.*, Bruxelles, 1888 (4 s.), **2**: 815.

(1) Girl, 19, typhoid: Was given 7.5 grains of phenacetin at 3 and at 8 o'clock a. m. About an hour after the second dose she complained of thoracic oppression, a sensation of intense heat, marked prostration, and deep cyanosis. The cyanosis passed off on the following day. On the preceding day the patient had taken 30 grains of phenacetin without ill effect. (2) Girl, 15, typhoid: Five hours after taking two doses of phenacetin of 3.75 grains each the patient's temperature rose rapidly with a severe chill. There was also slight cyanosis of the extremities. (3) Woman, 24: The ingestion of three doses of phenacetin of 7.5 grains each was followed after four hours by a severe chill and cyanosis of the lips and skin around the eyes. (4 and 5) In two instances the ingestion of phenacetin by tubercular patients produced ill effects, principally chills and cyanosis. In one case the dose was 15 grains, and in the other 6 grains.

- MÜLLER, F. Ueber Acetphenetidin. *Therap. Monatsh.*, Berlin, 1888, **2**: 355.

Author observed cyanosis and methemoglobinuria in two patients who were taking from 1.5 to 2 drachms of phenacetin daily.

- RUMPF. Ueber das Phenacetin. *Berl. klin. Wochenschr.*, 1888, **25**: 459.

The ingestion of 15 grains of phenacetin was followed on several successive days by a feeling of thoracic oppression and slight dyspnea.

- VALENTIN, A. Ein Fall von Phenacetinexanthem. *Therap. Monatsh.*, Berlin, 1888, **2**: 330.

Two hours after taking a dose of 15 grains of phenacetin the patient felt a sensation of heat and by the next day the entire skin was covered with red spots. The eruption was especially marked upon the extremities. It disappeared after twenty-four hours.

1889.

- HENSCHEN, S. E. Om s. k. konträr verkan af febermedel. *Upsala Läkaref. Förh.*, 1888-89, **24**: 263.

Author observed in a patient a rise of temperature after the administration of phenacetin.

HIRSCHFELDER, L. Beitrag zur Wirkung des Phenacetins. Deutsches Arch. klin. Med., Leipzig, 1888-89, **44**: 434.

The ingestion of phenacetin was followed by the appearance of red confluent macules, accompanied by a sensation of burning and prickling. The symptoms disappeared on the following day.

HOLLOPETER, W. C. Phenacetine poisoning. Med. News, Philadelphia, 1889, **55**: 335.

Woman, 30: Took three doses of phenacetin of 7.5 grains each within six hours. She passed into a state of collapse, with severe precordial pain, great dyspnea, lividity of the skin, and great restlessness. The cyanosis persisted for three days.

HORVÁTH, Á. A'datok a phenacetin hatásához. Orvosi hetil., Budapest, 1889, **33**: 474. (Abs. Pest. med.-chir. Presse, Budapest, 1889, **25**: 1134.)

Report of two cases in which the use of phenacetin was followed by an eruption upon the skin.

OEFFINGER. Eine eigenthümliche Nebenwirkung des Phenacetin. Aerztl. Mitth. Baden, Karlsruhe, 1889, **43**: 110.

The ingestion of 30 grains of phenacetin in two doses with an interval of three hours caused edema of the lower eyelids. A few days later 45 grains in three doses caused edema of the face and fingers.

TRIPOLD, F. Ueber die therapeutische Wirkung des Phenacetin und Thallin. Wien. klin. Wochenschr., 1889, **2**: 151, 178.

Author states that in his experience doses of 4.5 grains of phenacetin had produced deep cyanosis of the face and hands and profuse perspiration in children suffering from tuberculosis. In a case of pneumonia a dose of 4.5 grains caused severe collapse, with cyanosis. Even 3 grains caused chills, collapse, and cyanosis in two cases in children.

#### 1890.

COLLISCHONN. Phenacetin als Antirheumaticum. Deutsche med. Wochenschr., Leipzig, 1890, **16**: 97.

The ingestion of phenacetin was followed by repeated vomiting, so that the administration of the drug had to be stopped.

RIFAT. Traitement du rhumatisme aigu et biennorrhagique par la phénacétine à haute dose. Bul. gén. thérap. (etc.), Paris, 1890, **118**: 410.

(1 and 2) In two cases pneumonia and tuberculosis, respectively, doses of 4.5 grains of phenacetin caused profuse perspiration, a tendency to syncope, and great restlessness. (3) In a case of typhoid fever, cyanosis followed the administration of large doses of phenacetin. (4) Woman, 65, articular rheumatism, with arteriosclerosis: The ingestion of 75 grains of phenacetin daily was followed on the fourth day by the appearance of uremic symptoms. There were vomiting, severe dyspnea, fear, and almost complete suppression of the urine.

UBALDI, A. Sull' aumento dell'acido solforico accoppiato nelle urine in seguito alla somministrazione di fenacetina. Azione tossica della fenacetina. Riforma med., Napoli, 1890, **6** (1): 752.

#### 1891.

DEMME. Ueber die Wirkung und Dosirung der hauptsächlichsten neueren Antipyretica, mit Beziehung auf das Kindesalter. Therap. Monatsh., Berlin, 1891, **5**: 160.

Author had observed an eruption resembling that of measles, and cyanosis of the cheeks and mucous membranes in children after the use of phenacetin.

HARE, H. A. Fever: Its pathology and treatment by antipyretics. 1891, Philadelphia and London, p. 122.

The author mentions two cases in which the ingestion of 5-grain doses of phenacetin was followed by the appearance upon the skin of large wheals, like those observed in urticaria.

1892.

FERNÁNDEZ DE IBARRA, A. M. Un caso de envenenamiento con fenacetina; curación. *Gac. méd. catal.*, Barcelona, 1892, **15**: 229.

TINGLEY, W. K. Peculiar vasomotor disturbance after the administration of phenacetine. *Med. Rec.*, New York, 1892, **42**: 341.

The author had observed three cases with almost identical symptoms. In each of them phenacetin alone produced no disturbance, but if champagne were taken in addition, even after the lapse of some hours, the patient's face became flushed, the eyes suffused, and the conjunctiva bright red. White spots appeared irregularly over the neck, face, and chest, and vertigo was present. Whisky, brandy, and claret alone did not produce these effects.

1893.

ILLOWAY, H. Does phenacetin possess convulsivant properties? *Med. News*, Philadelphia, 1893, **63**: 240.

Report of two cases in which 5 grains of phenacetin produced typical hystero-epileptic convulsions in women.

1894.

HAROLD, J. Unpleasant effects of phenacetin. *Practitioner*, London, 1894, **53**: 444.

The patient, a woman, took from 5 to 8 doses of phenacetin of 10 grains each within twenty-four hours. Almost immediately she complained of palpitation of the heart; her face, except the bridge of the nose, became scarlet; her pulse became very rapid, and she suffered from headache and shortness of breath.

KNOWLES, F. E. Symptoms of poisoning from a probable overdose of phenacetine. *Med. Rec.*, New York, 1894, **46**: 564.

Patient took headache powders of unknown composition, and then 10 grains of phenacetin. There followed a chill, prostration with marked cardiac depression, cyanosis, particularly of the extremities, and cold perspiration. The pulse was 40 and scarcely perceptible at the wrist. Recovery after three hours.

DAVIS, J. S. A report of three cases of addiction to coal-tar derivatives. *Amer. Med. and Surg. Bul.*, 1894, **7**: 1490.

Woman: Had been addicted to the phenacetin habit for about seven months, daily quantity being between 15 and 20 grains. Addiction was discovered by her husband when her supply of the drug gave out and the local pharmacist also ran out of a supply temporarily. Violent convulsive and hysterical seizures followed and continued until phenacetin was secured for her. Pulse, 170, and very weak. Respiration, 30, spasmodic. Pupils widely dilated; pallor, cold perspiration. She had more than a dozen convulsions and vomited freely. Before beginning the habit she was "a healthy, buxom country girl." Examination made after the attack above described showed some anemia, complexion bad, circulation weak, pulse 124, restless and troubled sleep, impaired digestion, occasional vertigo.

1895.

CERNA, D. Phenacetin as a toxic agent. Tr. Texas Med. Assoc., Galveston, 1895, p. 126.

Infant, 5 days old, was given seven 2-grain phenacetin powders within two days. It became fretful, weak, and cyanosed. On the next day the conjunctiva was jaundiced, the skin cyanosed, and the child very restless. On the day following there was extreme cyanosis, and bloody urine was passed in large quantity.

KRÖNIG, G. Phenacetin-Vergiftung mit tödtlichem Ausgang. Berl. klin. Wochenschr., 1895, 32: 998.

Boy, 17: After taking 15-grain doses of phenacetin for headache for three weeks, a dose caused vomiting, followed on the next day by prostration, cyanosis of the face, weak pulse, and diarrhea. Jaundice followed, and the cyanosis spread to the extremities. The urine consisted of almost pure blood. Death occurred, after two days, from methemoglobinemia.

LACKIE, J. L. Note on phenacetin as causing dyspnoea and orthopnoea. Med. Press and Circ., London, 1895, 60: 208.

(1) Dyspnea and great restlessness followed the ingestion of phenacetin every two hours in 15-grain doses. (2) The ingestion of 20 grains of phenacetin every two hours caused marked dyspnea, which lasted for one hour.

WEST, R. M. Two cases of phenacetin rash. Lancet, London, 1895, 1: 91.

(1) Ingestion of two 5-grain tabloids of phenacetin by a man 28 years of age was followed in three hours by the appearance of a scarlatiniform rash upon the face, chest, and arms. It disappeared in two hours. (2) A young woman took phenacetin in doses of from 5 to 15 grains for neuralgia. On each occasion an urticarial rash appeared, chiefly upon the face and neck, after a lapse of one or two hours.

1896.

BETTS, W. A. A case of phenacetin idiosyncrasy. Brit. Med. J., London, 1896, 1: 146.

Patient took 8 grains of phenacetin every three hours for headache. After the third dose he felt very ill, and his face became pale. This was followed by shivering, dyspnea, cold perspiration, and the development of wheals on the back of the hands and on the right shoulder. The face was of a mahogany color and swollen. Dread of death. Recovery.

1899.

GULEKE, H. Taubheit in Folge von Phenacetinmissbrauch. Zts. prakt. Aerzte, Frankfurt, 1899, 8: 765.

Male, 48: Ingestion of 10.5 grains of phenacetin every two hours until 10 doses had been taken caused cyanosis and complete deafness.

1901.

KIBBE, M. E. Ecchymotic spots and pruritus due to phenacetin. Occidental Med. Times, San Francisco, 1901, 15: 371.

Woman, 50: Ingestion of six 5-grain powders of phenacetin during the evening and morning caused itching of skin over abdomen and limbs. On the fourth day large areas of ecchymosis appeared on the inner surface of each thigh, and smaller ones on the abdomen and extensor surfaces.

## 1903.

- WHITE, A. T. A case of acute dysentery, in which death occurred from acute cardiac dilatation probably due to chronic phenacetin poisoning. *J. Trop. Med.*, London, 1903, **6**: 176.

The ingestion of about 3,000 grains of phenacetin in 5-grain doses within sixty days for fever was accompanied by great depression and a rapid dilation of the heart followed by death. The result may fairly be attributed to the inordinate use of the drug.

## 1904.

- LAURENCE, S. M. Case of poisoning by phenacetin and antikamnia. *Brit. Med. J.*, London, 1904, **1**: 545.

The ingestion of 75 grains each of phenacetin and antikamnia was followed by vomiting and malaise. The face became pinched and pale, and the expression anxious. The eyes were small and the lips and fingers purple. Marked prostration with cold perspiration.

- LÖBL, V. Aspirin-és phenacetinmérgezések. (Aspirin and phenacetin poisoning.) *Budapesti orv. ujság.*, 1904, **2**: 803.

- HIRSCHFELD, M. Ein Fall von chronischer Phenacetin-Vergiftung. *Deutsche med. Wochenschr.*, Leipzig, 1905, **31**: 66.

The ingestion of phenacetin for headache was followed by the appearance of an eruption of petechial spots upon the legs, followed in the course of a week by ulceration. The ulcers healed rapidly when the drug was discontinued, and appeared again after another dose of 22.5 grains.

- MEURICE, J. Contribution à l'étude de la toxicité de la phénacétine. *Ann. soc. de méd. de Gand.*, 1905, **85**: 199.


The ingestion of 15 grains of phenacetin every two hours for twenty-four hours was followed by great weakness and then symptoms of collapse, with tendency to syncope, vertigo, dyspnea, cyanosis of the extremities, precordial pain, nausea, and rapid and feeble pulse. The skin was of a yellowish-gray color, and on the next day there appeared a macular erythema. Recovery after five days.


## 1907.


- TOBEY, GEORGE L. Fatal poisoning by phenacetin in headache tablets. *Monthly Bulletin of the State Board of Health of Massachusetts*, January, 1908.


On Friday, December 13, 1907, at 9.20 p. m., a girl of 16.5 years, in good general health, but having a headache and feeling that she had taken cold, took 2 headache tablets and went to bed. Later, her mother heard her coughing and went to her. There was nothing at this time to cause alarm, but a little before 11 o'clock the girl's lips and face began to become blue, and in consequence a physician was sent for. He responded at once, and found the girl with great weakness of the heart and edema of the lungs. Before he could administer any remedy she was dead.

The box with the remaining tablets was sent to the office of the state board of health for examination. The tablets were found to contain phenacetin. The box was labeled "Danbury's Headache Tablets."









## COLUMBIA UNIVERSITY LIBRARIES

This book is due on the date indicated below, or at the expiration of a definite period after the date of borrowing, as provided by the library rules or by special arrangement with the Librarian in charge.

[illegible]

Gaylord

PAMPHLET BINDER

Syracuse, N. Y.  
Stockton, Calif.

COLUMBIA UNIVERSITY LIBRARIES



0041081390

Kebler

QP971

K23

1909

The harmful effects of acetanilid,  
antipyrin, and phenacetin.

OCT 19 1955 C. U. BINDERY

Q971

K23

1909

NOV 9

