

Principles and methods of orthodontics : an introductory study of the art for students and practitioners of dentistry / by B. E. Lischer ... illustrated with 248 engravings.

Contributors

Lischer, Benno Edward, 1876-1959.
Augustus Long Health Sciences Library

Publication/Creation

Philadelphia and New York : Lea & Febiger, 1912.

Persistent URL

<https://wellcomecollection.org/works/gh9kfuah>

License and attribution

This material has been provided by This material has been provided by the Augustus C. Long Health Sciences Library at Columbia University and Columbia University Libraries/Information Services, through the Medical Heritage Library. The original may be consulted at the the Augustus C. Long Health Sciences Library at Columbia University and Columbia University. where the originals may be consulted.

This work has been identified as being free of known restrictions under copyright law, including all related and neighbouring rights and is being made available under the Creative Commons, Public Domain Mark.

You can copy, modify, distribute and perform the work, even for commercial purposes, without asking permission.

**wellcome
collection**

Wellcome Collection
183 Euston Road
London NW1 2BE UK
T +44 (0)20 7611 8722
E library@wellcomecollection.org
<https://wellcomecollection.org>

COLUMBIA LIBRARIES OFFSITE
HEALTH SCIENCES STANDARD



HX00020745



RK521

L68

Columbia University
in the City of New York

School of Dental and Oral Surgery



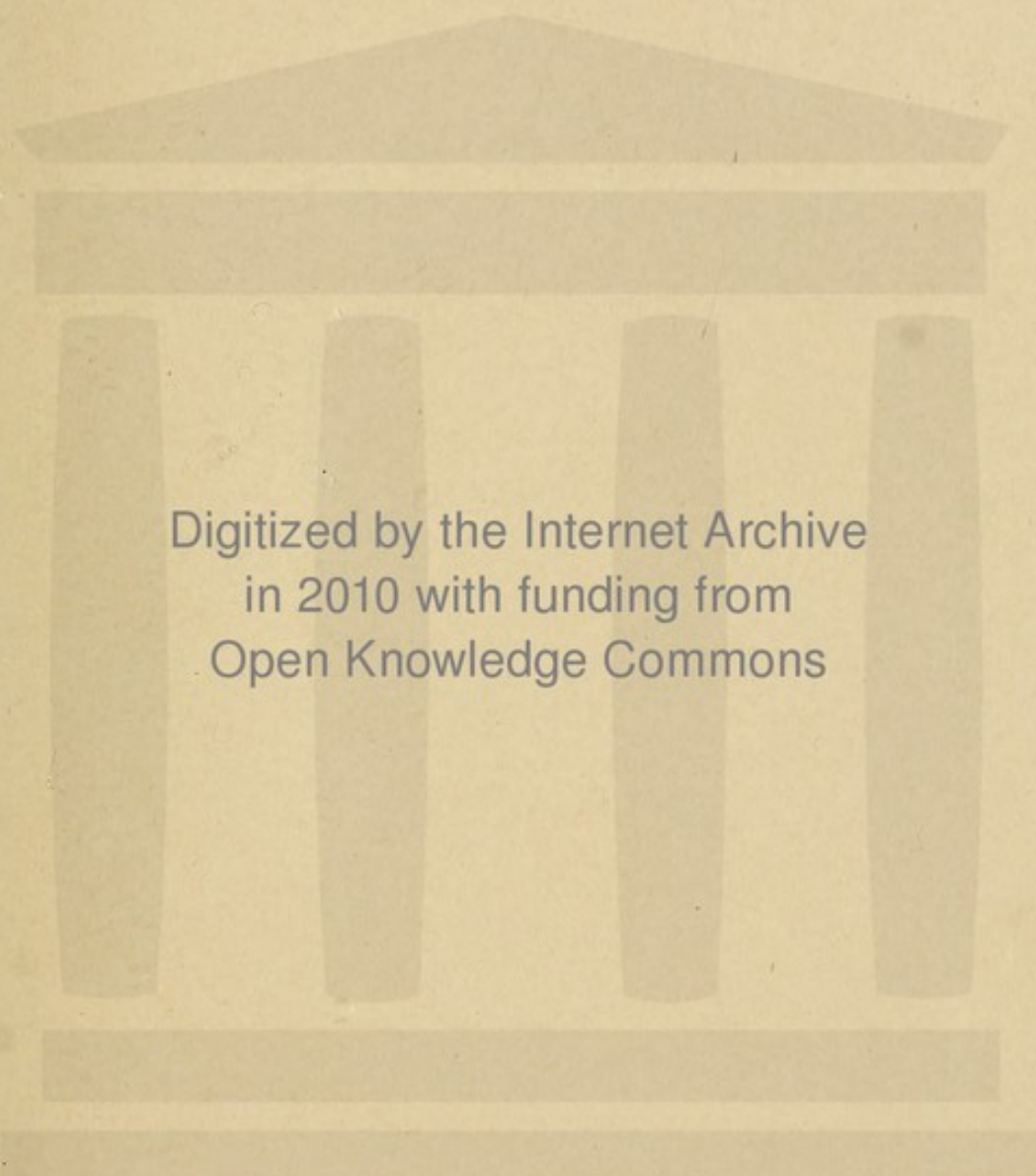
Reference Library











Digitized by the Internet Archive
in 2010 with funding from
Open Knowledge Commons

No one who has written a book has of himself become what he is; everyone stands on the shoulders of his predecessors; all that was produced before his time has helped to form his life and soul.

—FREYTAG

COLUMBIA
UNIVERSITY
LIBRARY

PRINCIPLES AND METHODS
OF
ORTHODONTICS


AN INTRODUCTORY STUDY OF THE ART
FOR STUDENTS AND PRACTITIONERS
OF DENTISTRY

BY

B. E. LISCHER, D.M.D.

PROFESSOR OF ORTHODONTICS, WASHINGTON UNIVERSITY DENTAL SCHOOL; MEMBER
OF THE AMERICAN SOCIETY OF ORTHODONTISTS; AUTHOR OF
"ELEMENTS OF ORTHODONTIA," ETC.

ILLUSTRATED WITH 248 ENGRAVINGS



LEA & FEBIGER
PHILADELPHIA AND NEW YORK

LIBRARY
UNIVERSITY
COLUMBIA

Entered according to the Act of Congress, in the year 1912, by
LEA & FEBIGER
in the Office of the Librarian of Congress. All rights reserved.

TK 521
L68

P R E F A C E

THE introductory study of the art here offered to students and practitioners of dentistry was begun with the intention of furnishing a plain statement of present-day tendencies. But the author soon found it impossible to proceed without adopting a point of view which implied a more or less "independent reconstruction of the existing situation." This necessitated the omission of details which, historically at least, are of great significance.

Many of the fundamental facts of the science (which have been appropriated from such cognate studies as anatomy) have likewise been omitted, on the assumption that every student has had adequate previous training in them. Similarly was it deemed advisable to eliminate the description of such technical phases as plaster model construction, details of soldering, etc., with which every dentist is conversant and which rightfully belong to the laboratory course. Nor has there been any attempt made to present the more recent discussions and debates with which our journal literature abounds. The dental school course does not permit of, nor does the beginner require, such minute exposition of the subject. In brief, the author presents the volume in that limited sense which its subtitle implies, and with the hope that its pages will prove both interesting and instructive.

The author desires to express his thanks to the publishers for the many courtesies shown him during the preparation of the volume; to other publishers and authors for the use of several cuts; and to his friend and collaborator, Dr. M. N. Federspiel, of Milwaukee, for his valuable counsel.

B. E. L.

WASHINGTON UNIVERSITY DENTAL SCHOOL,
ST. LOUIS, 1912.

CONTENTS

INTRODUCTION

CHAPTER I

THE STUDY OF ORTHODONTICS

Definition and Scope of Orthodontics	17
The Literature of Orthodontics	20
The Practice of Orthodontics	23
The Technique of Orthodontics	26

PART I

PRINCIPLES OF TREATMENT

CHAPTER II

PREPARING THE MOUTH FOR TREATMENT

Examination of the Patient	32
The Relief of Pain	35
Cleansing the Teeth	36
Instruction in Oral Hygiene	37
Treatment of Caries	38
The Extraction of Teeth	40

CHAPTER III

KEEPING RECORDS OF THE TREATMENT

Written Records	43
Plaster Models	46
Photographs	49
Radiographs	50

CHAPTER IV

THE ETIOLOGY OF MALOCCLUSION

Definition	52
Classification of the Factors	52
Intrinsic Factors	55
Extrinsic Factors	66
Unknown Factors	77

CHAPTER V

THE DIAGNOSIS OF MALOCCLUSION

First Principles	80
Definition	83
General Outline of the Anomalies of Dentition	84
Differentiation of the Various Forms	85
Summary	96

CHAPTER VI

FACIAL DEFORMITIES DUE TO MALOCCLUSION

Normal Variations of the Head Form	97
Abnormal Variations of the Profile	108
Orthodontic Conceptions and Ideals	118
Diagnostic Methods	126

CHAPTER VII

THE PROGNOSIS OF MALOCCLUSION

Definition	130
General Considerations	131
Special Considerations	133
Clinical Summary	138

CHAPTER VIII

THE EVOLUTION OF METHODS

Methods of the Past	144
Rise of the Systems	148
Lines of Advance	151
Details of Design	152

CHAPTER IX

PRINCIPAL ELEMENTS OF MODERN METHODS

The Plain Band	154
The Anchor Band	156
The Alignment Wire	159
Ligatures and Elastics	162
Miscellaneous Accessories	163

CHAPTER X

PRINCIPLES OF APPLICATION

Forms of Anchorage	164
Stationary Anchorage	165
Reciprocal Anchorage	166
Intramaxillary Anchorage	167
Intermaxillary Anchorage	168
Extramaxillary Anchorage	170

CHAPTER XI

DETAILS OF APPLICATION

The Anchor Band	173
The Plain Band	175
The Alignment Wire	176
Ligatures and Elastics	181

CHAPTER XII

PRINCIPLES OF RETENTION

Tissue Changes Caused by Tooth Movement	183
Definition of Retention	184
Maintenance of Tooth Position	186
Maintenance of Arch Form	187
Maintenance of Arch Relation	189

PART II

METHODS OF TREATMENT

CHAPTER XIII

TREATMENT OF MALPOSITION OF THE TEETH

Labioversion and Buccoersion	191
Linguoersion	195
Distoersion	198
Mesioersion	201

CHAPTER XIV

TREATMENT OF MALPOSITION (CONTINUED)

Torsoersion	203
Infraersion	208
Supraersion	210
Persion and Transersion	212

CHAPTER XV

TREATMENT OF NEUTROCLUSION

Simple Neuroclusion	213
Complex Neuroclusion	226

CHAPTER XVI

TREATMENT OF DISTOCLUSION

Bilateral Distoclusion	245
Unilateral Distoclusion	265

CHAPTER XVII

TREATMENT OF MESIOCLUSION

Bilateral Mesioclusion	272
Unilateral Mesioclusion	281

CHAPTER XVIII

TREATMENT OF MALFORMATIONS OF THE JAWS	284
--	-----

COLUMBIA
UNIVERSITY
LIBRARY

ORTHODONTICS

INTRODUCTION

CHAPTER I

THE STUDY OF ORTHODONTICS

DEFINITION AND SCOPE OF ORTHODONTICS

ORTHODONTICS is a term proposed by Sir James Murray, the eminent philologist, to cover that branch of dentistry which deals with the principles and practices involved in *the prevention and correction of malocclusion of the teeth*, and such other malformations and abnormalities as may be associated therewith. Dr. Frederick B. Noyes¹ defines it as "the study of the relation of the teeth to the development of the face, and the correction of arrested and perverted development." It is of dental origin, having been reared by dental practitioners, and is a crowning achievement of the dental progress of the last generation. The terms *Orthodontia*, *Odontorthosia*, *Dental Orthopedics*, and *Dental Orthomorphia*, which are less acceptable from a linguistic standpoint, are

¹ The Dental Cosmos, January, 1911.

also used. Like general dentistry, orthodontics is a part of the vast field of medicine, and when we recall "that all sciences which deal with life, with force, and with chemical composition" enter into the study of medicine, we may fairly comprehend the breadth of its base.

Orthodontics as a Science.—As a science it is closely related to many of the medical sciences, the basis of which is biology, the science of life. "Life, that strange, unknown something which flies through the viewless air, flashes through the ocean's depths, blushes in the petals of a rose, and manifests itself in thousands of marvellous forms—can science grasp, define, or explain it?" In the present stage of our knowledge probably not completely; but it teaches us that all vital processes, including man and all his characteristics, as well as those of all other species, are the result of the interaction of certain laws. To define these laws, to test them in the crucible of observation and experiment, and then to express them in terms of human experience—this is the mission of science.

Now, the treatment of dental anomalies involves us in countless difficulties, hence "we seek truth not merely for the pleasure of knowing, but in order to have a lamp for our feet. We toil at building sound theory in order that we may know what to do and what to avoid." Thus *the process of dentition*, its mechanism, causes, and various developmental stages, as exemplified by comparative studies, is not without meaning, but furnishes a field of compelling interest to every intelligent dentist. It is further apparent that a comprehensive knowledge of the *development of the jaws*, and of the nasal passages and their accessory sinuses (which are so intimately related to them), is also desirable. A frequent attribute of malocclusion of the teeth is a marked *inharmony*

of the facial lines. The true basis of a differential classification of such deformities is a wide familiarity with *ethnic variations of the head form*. A valuable aid in the study of the various forms of *malocclusion* of the teeth is an inquiry into the classification of all anomalies, the relations of anomalies to disease, and the foundations of teratology in general. Again, a consideration of *the causative factors* opens a large field of inquiry to the student of orthodontics, owing to their intimate connection with *the theories of inheritance, the transmission of acquired characters*, and other allied Darwinian factors and biological problems. Another essential to a scientific comprehension of treatment is a careful consideration of *the tissues of attachment, i. e.*, the alveolus and pericementum, and the changes they undergo during and after tooth movement.

All these are questions for the scientific orthodontist to investigate, and, if possible, to explain; he must search for the laws underlying them, tell why they are so, and indicate the place they occupy in the scheme of things. Finally, to render our studies less difficult, and to perfect the *nomenclature* of orthodontics, we must strive to develop a greater accuracy of expression and uniformity of usage of the terms we employ in our speech.

The practice of medicine, in any of its branches, constitutes a remedial art; for art consists in doing, in the application of knowledge. "The subject matter of art is life, life as actually is; but the function of art is to make life better. Operations become arts when their purpose is conscious and their method teachable."

Orthodontics as an Art.—As an art, orthodontics is concerned with the principles and methods of treatment; what these are the present volume briefly tries to show.

THE LITERATURE OF ORTHODONTICS

All endeavors to find adequate treatment of our subject in the earliest historic times have been fruitless. Thus, Farrar¹ writes of a review by Litch (1839), based upon some four hundred works on dentistry, and all they contained relating to the subject could have been gathered in one volume of moderate size. And though Celsus (A.D. 30) is said to have recommended finger pressure for the correction of malposition of the teeth, we can find no attempts at systematic treatment of the subject until the publication of Fauchard's² admirable book. The work of this eminent pioneer was not exclusively devoted to orthodontics, but he regarded the subject of sufficient importance to describe various methods of treatment and to dwell upon the etiology of malocclusion.

The earliest recorded special work is that by the German dentist, F. C. Kniesel, entitled *Der Schiefstand der Zähne*, in the German and French languages, and published in Berlin in 1836. During the interval embraced by the dates of publication of these two books the field of orthodontics was variously treated by dental authors, notable among whom were Bunon (1742), Bourdet (1757), Berdmore (1770), Fox (1803), Delabarre (1806), and Catalan (1808). The joint treatment of its subject matter with other phases of dentistry continued the prevailing custom for many decades, in fact, up to the present. Among the more prominent dental texts that continued thus to treat it are the following: *Handbuch der Zahnheilkunde*, Linderer, 1842; *Systematisches*

¹ Irregularities of the Teeth, vol. i, p. 12.

² Le chirurgien dentiste, Paris, 1728.

Handbuch der Zahnheilkunde, Carabelli, 1844; *American System of Dentistry*, vol. ii, Litch—Guilford, 1887; *American Text-book of Operative Dentistry*, Kirk—Angle and Case, fourth edition, 1911; *Dental Surgery*, Tomes, fifth edition, 1906; *A Text-book of Operative Dentistry*, Johnson—Pullen, 1908.

In 1880 Dr. Norman Kingsley, of New York, published the first American text on orthodontics, entitled *Oral Deformities*. The volume embraced several chapters on malocclusion of the teeth, their etiology, diagnosis, and treatment; besides a consideration of cleft palates and fractures of the maxillæ and their treatment.

In 1888 appeared the two-volume work of Dr. J. N. Farrar, of New York, entitled *Irregularities of the Teeth*. These volumes are a veritable mine of orthodontic data, and cannot be otherwise regarded than epoch-making.¹ This eminent pathfinder of the art was the founder not only of the "systems," but of present-day methods of treatment.

In the meantime, general dentistry was making rapid progress; every department was being influenced by the vast extension of human knowledge during the last half of the nineteenth century. The growth of dental literature was now to proceed, and orthodontics claimed many enthusiastic workers. It will be convenient to arrange all recent writers according to nationality, and by continuing our discussion of American authors we come to the work of Talbot, *Irregularities of the Teeth*, fourth edition, 1901. The book is said by its author to be "an outgrowth of researches which tended to oppose the too prevalent theory that irregularities of the teeth and jaws were the result of local, not

¹ Pfaff, *Lehrbuch der Orthodontie*, 2d ed., p. 373.

constitutional causes." Most of us believe this to be extreme teaching; but it should be read, owing to its treatment of the subject of degeneracy. *Orthodontia*, by S. H. Guilford, fourth edition, 1905, has been a favorite introduction for many years. *Malocclusion of the Teeth*, by E. H. Angle, seventh edition, 1907, is an exposition of the *Angle System*, and, like other works published in the last decade, open to criticism because of its exclusive originality of presentation. The works of Knapp, *Orthodontia Practically Treated*, 1904; of Jackson, *Orthodontia and Orthopedia of the Face*, 1904; and of Case, *Dental Orthopedia*, 1908, are treatises of the same group, each volume being a presentation of the author's methods. These remarks, however, are not intended as an index of the relative value of these works, since they contain much that the student cannot afford to ignore. The work by MacDowell, *Orthodontia*, 1901, concludes the list of American authors.

The foreign literature, though not so large, is a creditable showing for a specialty as young as orthodontics. In England there is the excellent little volume of essays by Wallace, entitled *Irregularities of the Teeth*, 1904; and the more pretentious text by Colyer, of the same title, published in 1900.

In Germany there is the work of Walkhoff, *Die Unregelmässigkeiten in den Zahnstellungen und Ihre Behandlung* (1891), and the texts by Jung (1906), Pfaff (second edition, 1908), Herbst (1910), and the excellent little manual by Körbitz (second edition, 1911).

In France the art is represented by the works of Gaillard (1909), Martinier (1903), and Donogier (1895). Spanish dentists have recently (1909) welcomed a work by Subirana, entitled *Anomalies de la Oclusion dentaria y Ortodoncia*.

Controversial writings, the reports of cases, and modifications of technical details (whose proper place is in the journals) have been liberally presented by dental magazines, many of them conducting departments of orthodontics.¹ In Germany a monthly journal exclusively devoted to the art has recently (1907) been established, entitled *Zeitschrift für Zahnärztliche Orthopädie*.

Much of the recent periodical literature represents the proceedings of societies and scientific associations. In the general bodies, such as State, national, and international societies, sections are frequently organized for the more deliberate consideration of orthodontic problems. Among the societies exclusively devoted to orthodontics, mention may be made of the American Society of Orthodontists, the British Society for the Study of Orthodontics, and the Deutschen Gesellschaft für Orthodontie, etc.

Thus the art, though hardly out of its teens, has, nevertheless, an extensive library; and at its present rate of growth bids fair to equal in content, as well as in volume, the literature of other branches of dentistry. The recent proposal of A. D. Black² that the profession adopt the Dewey decimal system of classification for dental literature will render available the countless articles in our magazines, covering every phase of the subject.

THE PRACTICE OF ORTHODONTICS

Recent advances in the methodology of the art and the consequent extension of its boundary lines have abundantly

¹ Items of Interest, New York.

² Proc. Inst. Dent. Pedagogics, Sixteenth Annual Report.

justified its separation from general practice in all communities capable of supporting the specialist. The many advantages of specialization are so well known that a restatement of them here is deemed unnecessary. Orthodontic services by their very nature readily constitute a special and ample field. Hence the point we wish here to emphasize is the dependence and independence of the two fields, their limitations and relations, and to indicate the course one ought to follow if one contemplates the practice of orthodontics. This theme has been the subject for numerous articles in the journals, though rarely has it been so ably presented as in the paper by Dr. Ottolengui, entitled "The Sphere of the Dentist in the Field of Orthodontia," from which we quote the following:¹

"I respectfully submit it is my view that the best orthodontists of the future, as in the past, must be forthcoming from the ranks of such men as begin in the regular practice of dentistry, and gradually choose to practise orthodontia exclusively from a pure love of the work, and especially because of their inherent love for, and patience with, children.

"If this be true, it follows as a logical sequence that the dentist has the moral as well as the legal right to practise orthodontia; but he should have no legal right, as surely he has no moral right, to undertake orthodontic work without a full and competent knowledge of the present requirements and technique. Any physician may treat the eye, the nose, the throat, or do any operation in surgery if he has the ability to do so successfully; but he may be mulcted in heavy damages if he attempt such work and fail, because of

¹ Items of Interest, November, 1909, p. 819.

lack of proper training or skill. The medical degree is no protection to the malpractitioner.

“It is the same in dentistry. Any dentist may undertake the treatment of malocclusion, but he is guilty of malpractice in some degree if he does not first acquire the needed training and knowledge.

“The sphere of the dentist in orthodontia is, therefore, to be considered from a dual aspect: (1) The general practitioner who elects to treat malocclusion occasionally, and (2) the dentist who decides to refer all such cases to the specialist. The first man should have exactly the same knowledge as the specialist himself. For, if the dentist treat but one case a year, he is morally bound to know how, or else refer the patient elsewhere.

“On the other hand, the general practitioner who decides not to treat malocclusion, but elects to recommend a specialist, should at least inform himself sufficiently of the art to be a competent judge of the success or failure of the specialist into whose hands he takes the responsibility of placing the management of the teeth and jaws of a growing child. For, it should be remembered, there are degrees of excellence in all crafts, and the mere fact that a man may announce that he has decided to ‘restrict his practice to orthodontia’ does not prove that he is competent.”

As an additional word of caution, it is well to state that no one should attempt the exclusive practice of orthodontics without adequate preliminary training in general dentistry, because a liberal knowledge in the treatment of the two main groups of oral diseases (*i. e.*, caries and lesions of the pericementum, which can only be acquired in general practice) is absolutely indispensable. It is imperative that we learn by experience what it means to keep a mouth well.

Finally, when combined with general dentistry (a necessity in all outlying districts and rural communities) it will be necessary to so systematize the office routine that a definite number of hours be exclusively devoted to its practice. This should be regarded as a pleasant duty by all conscientious dentists; for it has been estimated that fully 50 per cent. of the children in every community are afflicted with some form of malocclusion of the teeth, which, in the aggregate, means a vast army of countless thousands upon whom, for obvious reasons, the specialist can never smile. And last, but not least, the mastery of orthodontics implies postgraduate study, which the dental hospitals of our larger universities should liberally provide. Such departments are worthy of the most liberal endowments, and it need hardly be emphasized that they should be open to graduate students the year around.

THE TECHNIQUE OF ORTHODONTICS

Many of the earlier works on general dentistry contained chapters on "Irregularities" and "Regulation," probably because the correction of malocclusion has always been regarded as a function of the dentist. A noteworthy characteristic of these texts was the prominence given to the technical phases of the art, the details of appliance construction being constantly kept in the foreground. The treatment of malocclusion being a mechanical process, in which technical methods play an exceedingly important part, it seems quite natural that the technique should have been regarded as an important division. Indeed, it is still so regarded; but the dawn of another era is upon us, the

day of "home-made" appliances is rapidly approaching its twilight, and an appreciation of greater possibilities is directing our attention and energy to other problems. The mechanisms of former days were usually manufactured by the operator, which consumed a great deal of his time, and so magnified the details of construction that the principles utilized were frequently lost sight of.

The following prophecy from the pen of Dr. J. N. Farrar¹ appeared in 1878: "Although the simplification of regulation has been a great desideratum for many years, it has for some time been evident to me (though by most people thought to be impracticable) that the time will come when the regulation process and the necessary apparatus will be so systematized and simplified that the latter will actually be kept in stock, in parts and in wholes, at dental depots, in readiness for the dental profession at large, so that it may be ordered by catalogue numbers to suit the needs of the case; so that by a few moments' work at the blowpipe in the laboratory the dentist may be able, by uniting the parts, to produce any apparatus, of any size desired, at minimum cost of time and money."

That prediction has been fulfilled; orthodontics has passed through its elementary stages, and finally reached as high a degree of development as other departments of dentistry. There was a time when the operator made his pluggers and other instruments, and the prosthodontist his plate gold and solders; similarly was it considered an orthodontist's duty to invent and construct the appliances for a case in hand. But after years of ceaseless toil, "of immeasurable devotion of energy and time and genius" to a most


¹ The Dental Cosmos, January, 1878.

worthy art, certain facts of experience have finally been systematized. Indeed, the whole spirit of effort of the last decade has been a reaction against former methods, and has been characterized by a demand for a new arrangement, for some settled principles in the art. A mere heaping together of disconnected, confusing methods has long since ceased to satisfy all serious students. Thus, there comes the concession from all sides that appliances are but the means to an end—the remedies, as it were—with which the operator should so familiarize himself as to master their use and manner of application, not their manufacture.

“Systems.”—From the standpoint of this new and higher perspective, and in response to the urgent demands of progress, several so-called “systems” have been offered to the profession, every one of which embraces much that is good. But a system, at best, is but a compilation of certain definite principles, elements of design, and methods of treatment, and these rarely are the product of a single mind. It usually represents the results of the separate efforts of several individuals, and may even be compiled for private gain. On the other hand, a system may have a higher motive, and tersely emphasize the advantages of simplicity of technique, or the achievements of unusual skill. Doubtless their influence upon our technique has been salutary, though our resultant methods continue to impose definite technical attainments. Hence, laboratory courses in orthodontics, similar to those of operative and prosthetic dentistry, of chemistry and bacteriology, have become permanent fixtures in the dental curriculum.¹ The student frequently underestimates the importance of this phase of the subject, and

¹ Lischer, *Elements of Orthodontia*, St. Louis, 1909.

defers its accomplishments until launched in private practice; when the demands of a growing patronage and the unavoidable difficulties of treatment militate against the acquirement of that special dexterity so essential to success. Moreover, it is immaterial which method of treatment an operator will ultimately adopt—whether it be a system as such, or a combination of several—the technical training enjoined in either case will always be considerable. Thus, the application of appliances for treatment, the accepted methods of keeping records, and the construction of retention appliances demand a very high order of skill; and one arrives at skill only by patient labor, by the practice of an exacting discipline. Let every student of orthodontics remember, therefore, that the laboratory course is always designed for a definite purpose, that it fits well into the plan of things, and that there is no short cut across the plane of accomplishment.



PART I

PRINCIPLES OF TREATMENT

CHAPTER II

PREPARING THE MOUTH FOR TREATMENT

SURGICAL cleanliness on the part of the operator and his equipment is the first rule in all operative procedures. Since the founding of bacteriology by Pasteur, and its wonderful development by medical scientists, leading to the discovery of the relations of bacteria to animals in health and disease, it has received a new interpretation. Were it not for the fact that its omission continues the prevailing custom with far too many operators, it would not receive mention here. Indeed, its presentation is hardly appropriate in a work on orthodontics.

Following the reception of the patient, the adjustment of the operating chair and its accessories, should come the preparation of the field of operation. In orthodontic practice this has a special significance, and embraces a number of important preliminary considerations. The aim of these several preliminary details is the establishment of oral health—in so far as this is possible prior to orthodontic treatment—and to facilitate the treatment.

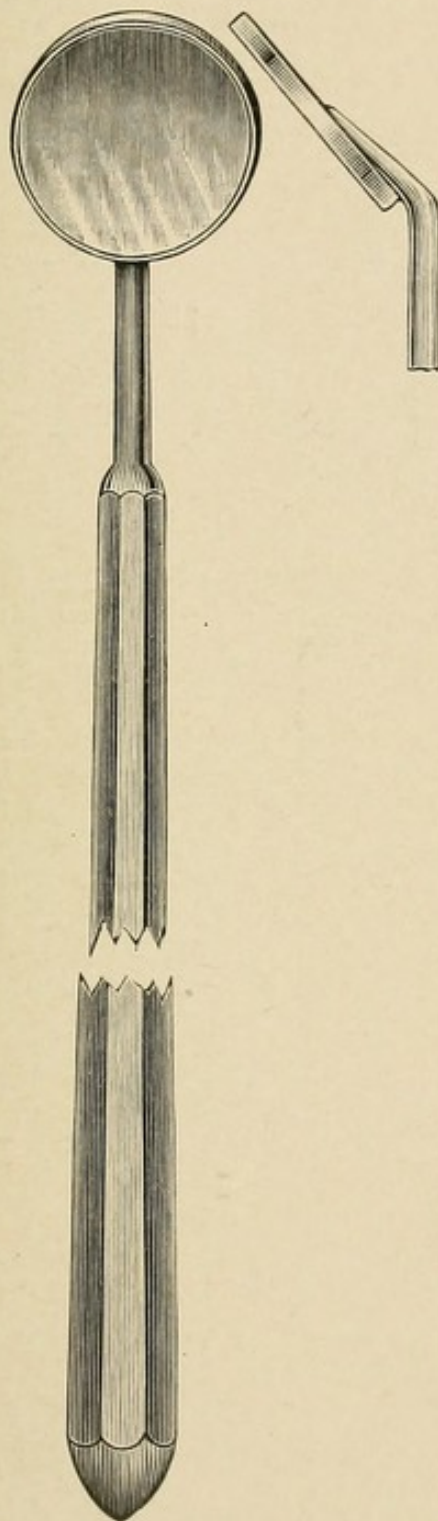
EXAMINATION OF THE PATIENT

The fundamental importance of a careful examination of every individual applying for treatment need hardly be emphasized, for it forms the very basis of every intelligent diagnosis. A cursory consideration of the general health and physical development of the patient constitutes the first step of such examination. Should any doubt regarding it arise, the patient (or parent) should be questioned and a record made of recent recovery from serious ailment. Such interrogations frequently prompt parents to relate the presence (or removal) of adenoids, and other conditions etiologically connected with the malocclusion. The attention of the operator is commonly directed toward some "prominent" incisor or cuspid, which he will for the present ignore, and consider later in the course of a definite routine.

The thorough examination of the oral cavity should now proceed, and include, besides the superior pharynx, the nasal passages and form of the nose; the function of the lips; the facial lines and expression; the jaws beyond the immediate alveoli; the relative immunity or susceptibility to caries; the condition of the gums and pericementa; the form of the palate; the frena of the lips and tongue; and all surfaces of the crowns of all teeth. Though a differential diagnosis of the malocclusion suggests itself here, it is usually best to defer the same until accurate models have been constructed.


Instruments.—The instruments required for an examination consist of a mouth mirror (Fig. 1), of non-magnifying type, with metal handle. A plain, long-handled exploring instrument, of a pattern as shown in Fig. 2, is used for the location and exploration of carious cavities. The use of

FIG. 1



Mouth mirror.

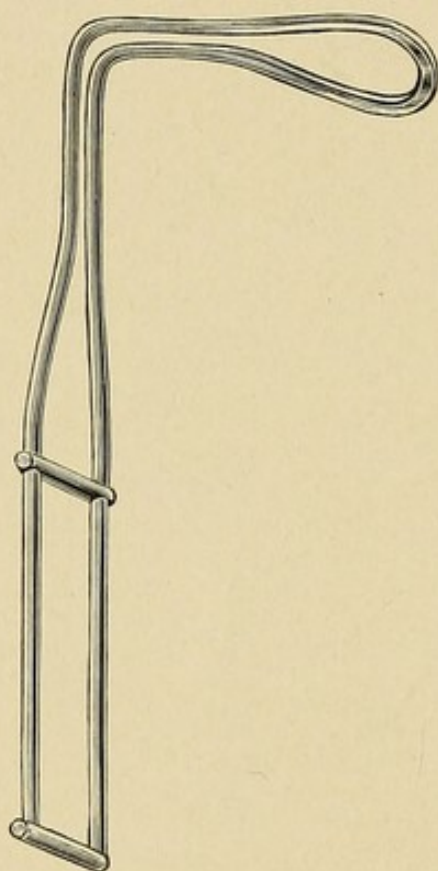
FIG. 2



Exploring instrument.

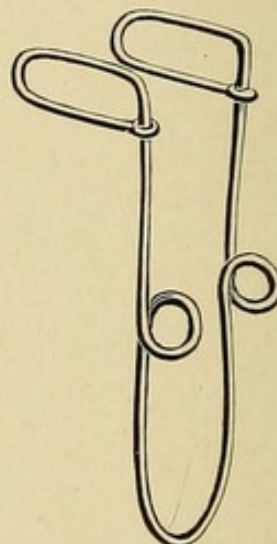
floss silk in the interproximal spaces and contact areas is also advised. A tongue depressor of simple design (Fig. 3) is used for the examination of the superior pharynx. Pathological conditions of the nasal passages which may stand in causal relation to the malocclusion and require the services

FIG. 3



Tongue depressor.

FIG. 4



Nasal speculum.

of a rhinologist may frequently be detected with a nasal speculum (Fig. 4). A pair of operating pliers and some aseptic absorbent paper, for the drying of tooth surfaces, are useful accessories. All of these instruments should be in readiness upon the operating table, and all unnecessary appliances removed. Finally, a memorandum of all obser-

vations should be made upon a record card conveniently placed upon an adjoining table or desk. The form of this card is described in Chapter III.

THE RELIEF OF PAIN

The value of early treatment for malocclusion is increasingly being appreciated, hence many of the patients in an orthodontic practice are children in whose mouths temporary teeth are still present. And though the treatment of temporary teeth is more widely practised than formerly, extensive caries, pulp exposure, and its *sequelæ* are all too frequently met with. The proper treatment of such conditions should invariably be insisted upon; and in this connection let it be remembered that reckless extraction is not the remedy. Indeed, the exigencies of many cases demand their conservation, especially if we view the denture as a whole, and always from an orthodontic standpoint. The disastrous results following the neglect and early loss of temporary teeth will be discussed in the chapter on Etiology.

The temporary teeth are frequently the seat of pain, which many of the younger patients fail to mention. "In every instance where there is suffering the manifest duty of the professional man is to relieve it at once if possible, no matter in what form it may present itself" (Johnson). The subsequent application and operation of the appliances for tooth movement are of sufficient annoyance to make the above imperative. The student should therefore make a study of the causes of pain and of all therapeutic aids and methods employed for its alleviation. Such service is always appreciated, and goes far in the promotion of confidence.

CLEANSING THE TEETH

Cleanliness and health are synonymous terms in oral hygiene, hence the next important preliminary consideration is a careful cleansing of the teeth. "Dentists are not living up to the highest possibilities of their art when they fail to consider the importance of maintaining the tissues around the teeth in a state of health, and this cannot be done short of a careful removal of all extraneous material which may be found adherent to the teeth." (Johnson.) Probably no two operators will exactly agree as to the instruments to be used and the particular methods to be followed in cleaning the teeth; but all must agree on the fundamental importance of the procedure. The author is not aware of any definite statistics regarding the matter, but he feels certain that only one patient in every hundred presenting themselves practises oral hygiene to the extent that orthodontic treatment could be instituted without first cleansing the teeth.

But aside from the beneficial effects upon the general health of the oral cavity which every cleaning promotes, it must further be emphasized that appliances are shortly to be adjusted. These are to be securely anchored to a number of teeth, and in many instances remain for a period of weeks, or even months. Upon their removal, after tooth movement has been accomplished, retention appliances are to be inserted for another prolonged period. Not infrequently the anchorage of the latter are upon the same teeth previously utilized. It is obvious, therefore, that only by the utmost cleanliness during the entire period of orthodontic treatment can the health of the oral cavity be maintained and caries of the teeth prevented.

INSTRUCTION IN ORAL HYGIENE

The maintenance of physical vigor is a duty of every human being, and implies the practice of a rigid personal hygiene. Among its many requirements few are of greater importance than the proper care of the mouth. The vast majority of individuals suffering from dental diseases is incompetent in the practice of an efficient oral hygiene; hence it becomes the duty of the operator carefully to instruct patients in this important detail. The most opportune time for this instruction is immediately after the teeth have been cleansed. It is an opportunity the conscientious practitioner never neglects, and it should always be regarded as an essential detail of a carefully planned routine, because all regulating appliances interfere with the normal functions of the mouth and favor the lodgement of food particles, thus promoting caries of the teeth.

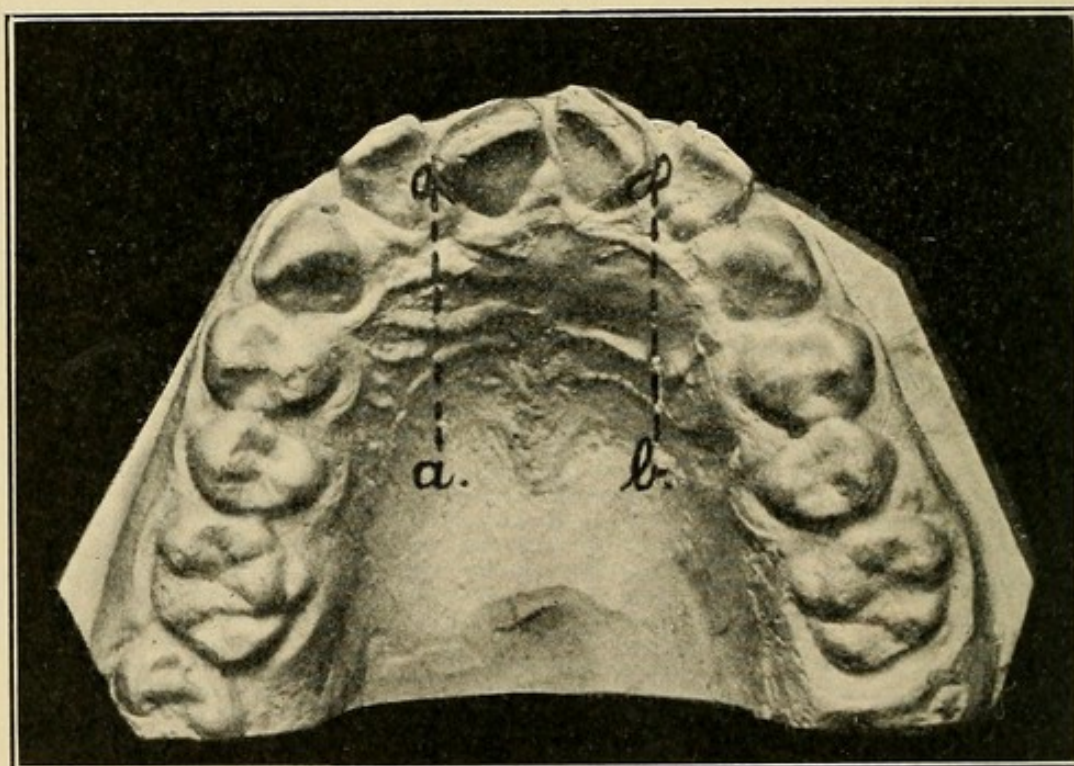
Owing to the rapid rise of orthodontics as a specialty, this discussion brings us to the line of demarcation between the fields of the specialist and general practitioner. An orthodontist extends his acquaintance and wins patronage in any one of three legitimate ways; patients are referred to him (*a*) by the family dentist, (*b*) by the family physician, or (*c*) by a member of the laity. Of course, if the orthodontic treatment is instituted by the family dentist there can be no question as to when, or how, and by whom these services are to be rendered—they belong to the general practitioner. On the other hand, if the specialist is consulted, or if the case is referred to him by the dentist, the entire treatment can be rendered with greater dispatch if both can agree on a definite plan, since all of these preliminary

services should always be rendered prior to any orthodontic treatment. But the specialist must not underestimate responsibilities during the period his services are being rendered, and in all cases showing a high degree of susceptibility to caries he should encourage the most liberal consultation with the family dentist.

TREATMENT OF CARIES

All carious cavities, in both temporary and permanent teeth, should be treated prior to tooth movement and in the

FIG. 5



Carious cavities rendered extremely inaccessible by the malocclusion.

best manner the conditions will permit. The choice of a filling material is at times rendered difficult, since the factor of accessibility may enter into consideration. Fig. 5 shows an occlusal view of the upper arch of a patient, aged twelve

years, with cavities in the right and left centrals and laterals as indicated by *a* and *b*. It is obvious that the insertion of gold foil or other permanent repair is out of the question. A plastic like oxyphosphate of zinc is here indicated, and will be protected by bands placed upon the teeth for their movement. After the orthodontic treatment has been completed they will be normally accessible, and will then permit of permanent restoration.

In cases of extensive caries, requiring crowns and bridges, the operator must likewise come to a definite conclusion as to the most opportune time for their insertion. Accessibility, though still a factor, now gives way to anchorage; for should the affected tooth, or teeth, be required for anchorage of the regulating appliance, they should be restored before orthodontic treatment is attempted. Fortunately, the necessity for such extreme remedial measures is decreasing, and their consideration in orthodontic practice is becoming extremely rare.

The author has recently treated a case of bilateral distoclusion, accompanied by labioversion of the upper incisors, for a boy, aged twelve years, who, owing to an accident resulting in fracture, had a porcelain crown inserted upon the left upper central during his ninth year.¹ The behavior of the root during orthodontic treatment did not appreciably differ from those in which the pulps were vital. Numerous similar experiences, therefore, predicate the conclusion that if caries has progressed so as to affect the pulp, or to a stage demanding an artificial crown, it should receive the customary treatment; that non-accessibility, or extreme malposition, may occasionally postpone the more permanent restorations until tooth movements have been accomplished.

¹ See Case K, Figs. 207 and 208.

THE EXTRACTION OF TEETH

The subject of the extraction of teeth prior to or during orthodontic treatment divides itself into that (*a*) of temporary teeth, (*b*) of supernumerary teeth, and (*c*) of permanent teeth.

Temporary Teeth.—Temporary teeth too extensively decayed to warrant attempts at conservation, and whose retention would seriously affect the health of the oral cavity, should always be removed prior to treatment. But in many instances, especially in the very young, when several years might elapse before the eruption of their successors, every effort should be made to retain them. Again, in cases of arrested development or “contracted” arches, with firm temporary teeth present and postponement of treatment inadvisable, their movement and subsequent retention should proceed with that of adjacent permanent teeth to induce growth of the alveoli and jaws beyond, and to promote the normal eruption of their successors. Extraction is indicated in every case of prolonged retention, provided there are no symptoms of deficiency in the number of permanent teeth, or where the successor is in process of eruption.

Supernumerary Teeth.—Supernumerary teeth should always be extracted, especially when they operate as a cause of malocclusion. It is best, however, to defer all extractions until accurate models have been constructed. Every operator should strive to record as many cases as his practice affords.

Permanent Teeth.—The extraction of permanent teeth for the facilitation of the orthodontic treatment is a question regarding which many incisive papers, and more incisive rejoinders, have been written. Prior to the development of our present methods for the correction of arch malrelation,

removal of certain permanent teeth was widely practised, even regarded as a necessity. But with the perfection of the details of arch movement as well as tooth movement, the group of cases in which extraction is now permissible has been greatly restricted. The literature pertaining to this subject is voluminous, immensely interesting, and of the utmost value, though the following two rules by Professor Guilford¹ serve as an excellent abbreviated version of the entire discussion.

“1. Do not decide to extract until a careful study and restudy of the case have been made from articulated models and the patient in person, and until every available method of procedure without extraction has been carefully considered.”

“2. If extraction seems unavoidable, adopt the best method of correction without it, and when, in the course of the operation, it becomes absolutely evident that the desired result cannot be obtained in that way, it will still be time to extract and change our method of procedure.”

Finally, it must ever be remembered that the loss of even a single tooth produces a break in the continuity of the arch; that the adjoining teeth always tend to move toward the space thus created; that the abnormal inclination of the adjacent teeth is accompanied by loss of contact in more remote places in the arch; that a reduction in the size of the lower arch is frequently followed by a deepening of the “bite” and an increase in the difficulties of retention; and that the harmony of facial form rarely permits of the sacrifice. The numerous clinical phases of this subject can be more appropriately dealt with in subsequent chapters on the methods of treatment.

¹ *Orthodontia*, 4th ed., p. 48.

CHAPTER III

KEEPING RECORDS OF THE TREATMENT

MANY of the advances in medical practice have been based upon hospital statistics, where the facilities and methods for keeping records have always surpassed those adopted by individual practitioners. It is, perhaps, not inaccurate to state that in dentistry the reverse is true. Dental clinics, in most instances, are usually conducted for the purpose of furnishing opportunities for experience to students and to serve those in need, being only incidentally utilized as centres of research. It is but fair to add, however, that the hospitals furnishing the largest and most trustworthy mass of clinical data for medicine are not, necessarily, the school hospitals; and that the funds at the command of such institutions far exceed those of the dental infirmaries. For purposes of scientific research it is always advisable to procure clinical data from both public and private records, though under existing dental conditions the private records of practitioners are preferable. It is to be hoped that an enlightened interest in human health and an appreciation of the sociological significance of preventive medicine (which should be provided for all the people by the strong arm of the State) will revolutionize this phase of dental service in the not distant future.

Now, it is not at all unusual for an average practice to extend over a period of from thirty to forty years, thus affording ample opportunities for the compilation of valuable

data upon which scientific deductions and advances in treatment can be based. It is exceedingly important, therefore, that the beginner adopt some plan for the keeping of records, and the points to be emphasized are that such records should be accurate, concise, and practical. When they comply with these requirements, their value can hardly be overestimated. They should be so designed as to provide for the special needs of an orthodontic practice, which may briefly be enumerated as consisting of written records, of plaster models, of photographs and radiographs, and such illustrations or appliances as are deemed worth recording.

WRITTEN RECORDS

Among the many methods that can be employed for the keeping of written records, a specially designed card system has been found most convenient. It should be of standard size, preferably 5 x 8 inches, and provided with a filing cabinet so arranged as to permit of comprehensive classifications. Figs. 6 and 7 exhibit the essential items of such a record card. All of the scientific phases of a case, including the patient's name and the case number, are placed upon the face of the card. The reverse side is arranged for the practical phases of the treatment. Several of the items upon the front of the card are compiled from the reverse side after completion of the case, or at the operator's convenience. In addition, the author uses plain ruled cards of the same size as the record for the compilation of all data of scientific interest. These are reclassified by the use of extra guides, and can be compiled by any competent assistant.

This system of records renders available for immediate use or study all the material his practice affords. For example, it enables one to instantly state the number of patients of any given age, or sex; the number of cases where the influence of a given etiological factor is exhibited in the models, *e. g.*, premature loss of temporary teeth. All models, photographs, radiographs, etc., are numbered and recorded on the record card. Thus all items of interest of any given case, or of a series of cases, can instantly be brought together for comparison and study.

The possibilities of the card system are so numerous that it appeals to every operator who values his records at their true worth; it is so elastic in its application that any inquiry or investigation may easily be carried out by its use.

PLASTER MODELS

In 1756 Ph. Pfaff¹ introduced the use of plaster of Paris for model construction. That its use did not become general, however, is evinced by the fact that Kneisel,² eighty years later, still relied on sulphur, though both employed wax as an impression material. The latter frequently resorted to the use of metallic models in the construction of his appliances. These were made of fusible alloy and obtained from *plaster impressions* of his sulphur models.

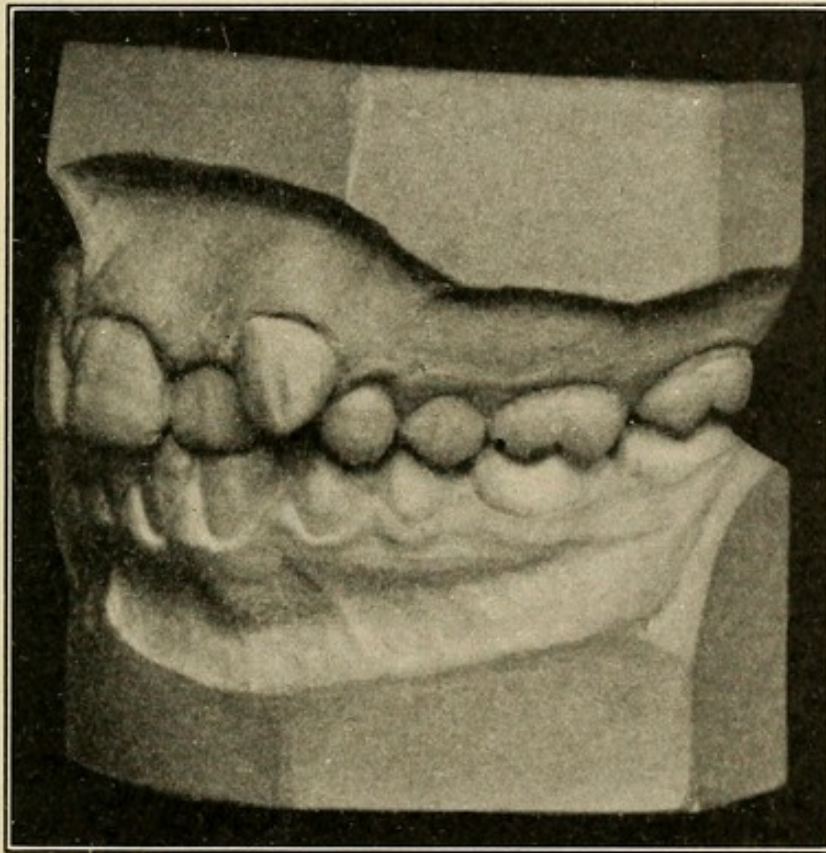
The construction of accurate plaster models of the upper and lower teeth and adjacent parts is now considered a necessary detail of every orthodontic record (Fig. 8), and, as Angle has clearly emphasized, their value is enhanced in

¹ Zähne des Menschl. Körpers, Berlin.

² Der Schiefstand der Zähne, Berlin, 1836.

proportion to their accuracy. To obtain this accuracy plaster should invariably be used for the impression from which the model is made. When accompanied by written records, they are of the greatest scientific value, especially to the owner who is familiar with many of the unrecorded details of their history.

FIG. 8



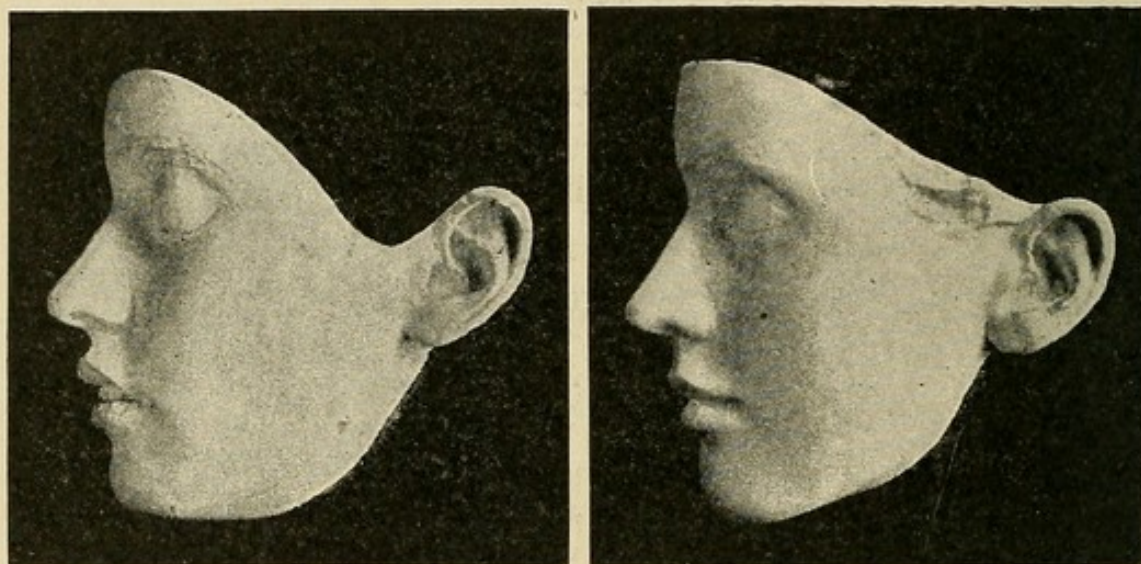
A plaster model of a case of malocclusion prior to treatment.

Clean, perfect models are an incentive to render better service and mark the dividing line between the amateur and artist. They are absolutely necessary in making an intelligent diagnosis; are useful in a study of the etiology and prognosis; and particularly in planning the treatment and designing the retention appliances. Tooth movement usually extends over a period of several months, and is only

ultimately successful if adequate retention is provided. The latter is an extremely difficult phase of every treatment, and is practically impossible without the aid of accurate models of the original conditions. No operator can afford to rely on his memory as to the exact nature of these original conditions.

Facial deformities are frequently due to anomalies of dentition, and their correction now occupies a large place in orthodontic practice. A record of such service, for which

FIG. 9



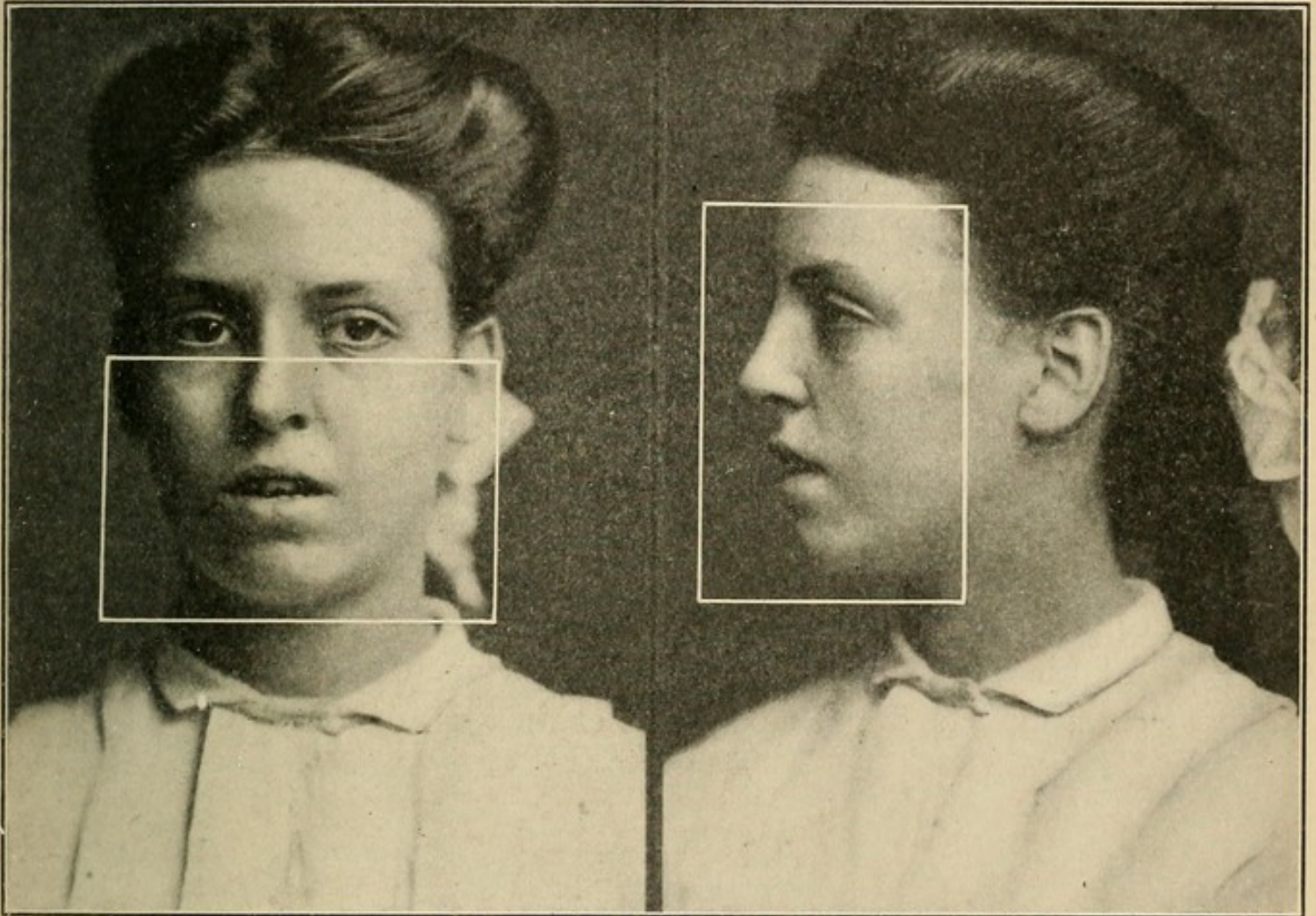
Plaster models of the face before and after treatment. (After Case.)

two methods are at our disposal, is eminently desirable. Professor Case¹ recommends plaster models of the facial lines. These may be made in full front and profile views, and are of natural size (Fig. 9). But the construction and filing of these models present difficulties which many operators have sought to avoid. This has given rise to the

¹ Dental Orthopedia, Chicago, 1908.

adoption of the photographic method, a process introduced by Professor John W. Draper, of the University of New York, in 1839.

FIG. 10



Shows size of the unmounted photographs and the lines to which they are cut before mounting on the record cards.

PHOTOGRAPHS

When made according to certain definite requirements, photographic records of the facial lines answer every purpose, and for convenience are mounted on cards of the same size as the record. The requirements are simply these: The same photographer should make all photographs of

any given series; he should use the same lens in every case and adopt a uniform size and pose. The prints should always be made upon the same kind of permanent paper, and delivered unmounted. A good plan is to instruct the photographer as to what is wanted, laying special emphasis upon the fact that under no circumstances shall he retouch any of the operator's negatives.

To avoid variation in size, particularly in the various prints of any given case, the author has taken the precaution to provide the photographer with a card upon which accurate measurements are marked. It is advisable further to agree on the kind of background to be used, a dark ground being usually best, because it affords the proper contrast.

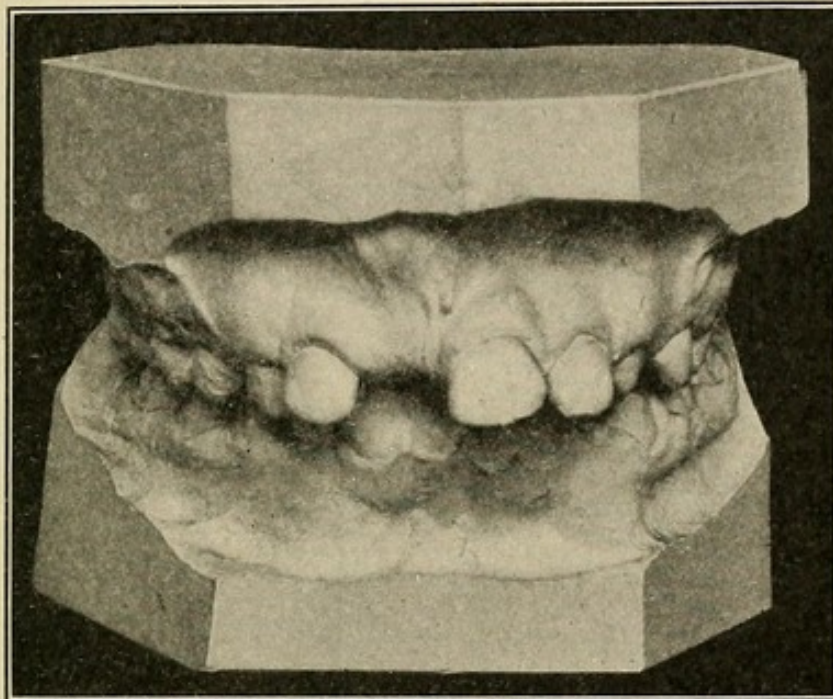
In mounting, many of the unnecessary features of the prints (such as dress, shoulders, hair ornaments, etc.) may be eliminated by using a pattern cut from transparent celluloid, and marking to exact size before cutting (Fig. 10). All prints of any given case may then be mounted upon a 5 x 8 card, numbered and filed in the cabinet with the records.

RADIOGRAPHS

In the treatment of malocclusion of the teeth one frequently meets with anomalies of number, or of eruption and form. To establish certainty in the diagnosis of such cases the x -rays (discovered by Professor Röntgen in 1895), in combination with photographs, are of the greatest value. Indeed, for the elimination of guesswork they are invaluable, since by their use it is possible to determine definitely deficiency or redundancy in the number of teeth, and to ascertain the peculiarities of anomalies of form and eruption. The difficulties encountered in the movement of teeth may at

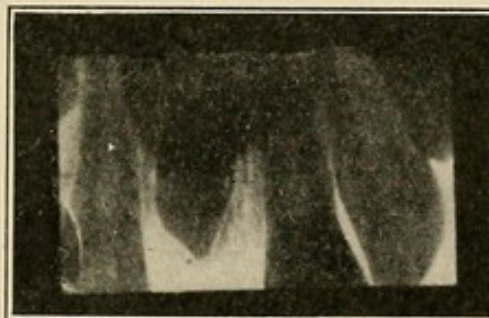
times be due to the fusion or malformation of their roots; tardy eruption may occasionally be caused by perverted position; a negative or indefinite history of premature extraction rendered intelligible, instead of construed into

FIG. 11



Shows tardy eruption of the right central incisor due to the supernumerary tooth shown in Fig. 12.

FIG. 12



Radiograph of case shown in Fig. 11.

deficiency of number. Many cases might here be introduced to illustrate the wide range of their usefulness, but Figs. 11 and 12 will suffice, for they clearly show the presence of a supernumerary tooth as the cause of tardy eruption of the right upper central incisor in a girl, aged eleven years.

CHAPTER IV

THE ETIOLOGY OF MALOCCLUSION

Definition.—In medical science, the study of the origin of disease and abnormality is termed etiology. It embraces a consideration of all causative factors, and of the provisional theories advocated when the causes remain obscure. And since it is the mission of orthodontics *to prevent*, as well as correct, certain anomalies of dentition, it is obvious that all knowledge relative to their causation is of the very first importance. From time immemorial, therefore, observant operators have endeavored to ascertain and remove these agencies, believing this to be the first aim of every rational treatment. Unfortunately, this phase of the art frequently presents problems exceedingly difficult of solution.

CLASSIFICATION OF THE FACTORS

In order to diminish these difficulties, several authors have attempted a classification of the etiological factors; though a review of the literatur pertaining to this subject impresses one with the fact that a quite general disagreement yet exists. Some writers accept the time-honored division into *hereditary and acquired*, finding little difficulty in formulating definitions for these two terms. Others exhibit a very evident skepticism regarding the "influence of heredity," and thus lean strongly toward the acquired group.

Heredity and Predisposition.—Of course, there was a time when heredity explained it all, when it served as a cloak for our ignorance; when most diseases and abnormalities were believed to have been transmitted from parents to offspring. But the *physical basis* of heredity (a mechanism existing within the germ cell) is now fairly well established. Many of the recent advances in biology have fostered a strong opposition to the old views, forcibly emphasizing the influence of environmental (acquired) factors, which cannot be ignored. “As to the inheritance of the effects of extrinsic forces upon the individual, we find little in the way of direct evidence. Mutilations of any sort are not inherited.” (Jordan and Kellogg.) This new teaching, it must be admitted, has served as a healthy antidote; it was needed.

On the other hand, the claim of the opponents of heredity—“that nature never transmits the abnormal,” that all anomalies are but the result of certain lapses in nature’s processes, always due to local and extraneous influences—is equally untenable. In the light of modern biological science either view is now considered extreme.

Unfortunately, in these days of the “systems,” with their truly wonderful achievements in technique, we are prone to rest content with our superficial calculations—for we love to cling to seeming bounds. But accepting, as we must, the physicochemical explanation of life, we are constrained to adopt those causomechanical factors of its flux which are recognized by biologists generally, and which “involve no philosophical assumptions.” These are heredity, variation, adaptation, selection, isolation, and (probably) mutation. With the first of these we are here briefly concerned.

Heredity may be defined as “the genetic relation between successive generations, as the transference of similar char-

acters from one generation of organisms to another, as a process affected by means of the germ cells." All peculiarities or characteristics that are imparted to an individual through these germinal cells of the parents are spoken of as *inherited*. Any peculiarity that is imparted after conception has taken place is spoken of as *acquired*. If before birth, it is termed an intra-uterine acquisition; after birth, an extra-uterine acquisition.

All inherited peculiarities are also said to be congenital, whether recognizable at birth or not. Likewise, all intra-uterine acquisitions are congenital; whereas extra-uterine acquisitions are spoken of as extragenital. The careless use of the term *congenital* (many writers believing it to be synonymous with hereditary) has been the cause of much confusion.

Concerning *predispositions*, Professor Orth, of Berlin, says: "Every incapacity of the body to resist the external causes of disease, every peculiarity of the constitution which renders the latter unable in the struggle of the body with the cause of disease to maintain the normal course of the vital phenomena, every such peculiarity of the constitution may be designated as a tendency, as a predisposition, to disease. All these predispositions to disease must be congenital and inherited, for they are a result of the phylogenetic development; they have their origin in the general characteristics inherent in the germ cells. This conception of what constitutes predisposition to disease does not contain anything mystical; it is not beyond the domain of science, and is just as capable of scientific treatment as any other pathogenetic question, though we must admit that our knowledge of the predispositions to disease does not go much beyond a few generalities."

Heredity, therefore, is not as definite a factor as formerly, though we must continue to regard it as of great importance in the study of organic continuity. "Heredity repeats strength or weakness, good or ill, with like indifference." (Jordan and Kellogg.) Furthermore, one phase of this vast theme stands out very prominently, viz., all dental research relative thereto, and thus far conducted, is entirely inadequate. For this reason alone we should pause long before boldly denying its probable "influence" in the causation of malocclusion of the teeth. Another very plausible reason why we should be less hasty in excluding the hereditary factors is, that many anomalies of other organs of the body (notably the eyes, *e. g.*, errors of refraction, imbalance of the ocular muscles, etc.) are largely congenital and frequently transmitted from generation to generation. Surely, the teeth and jaws are not exempt from the "influences" which control such maldevelopments.

"Our present plight seems to be exactly this, we cannot explain to any general satisfaction" all the causes of malocclusion of the teeth without the help of some hereditary factors; "and on the other hand, we cannot assume the actuality of any such factor in the light of our present knowledge of heredity." In view of this very unsettled state of our knowledge the author has, for some years past, preferred the terms *intrinsic* and *extrinsic*, instead of hereditary and acquired.

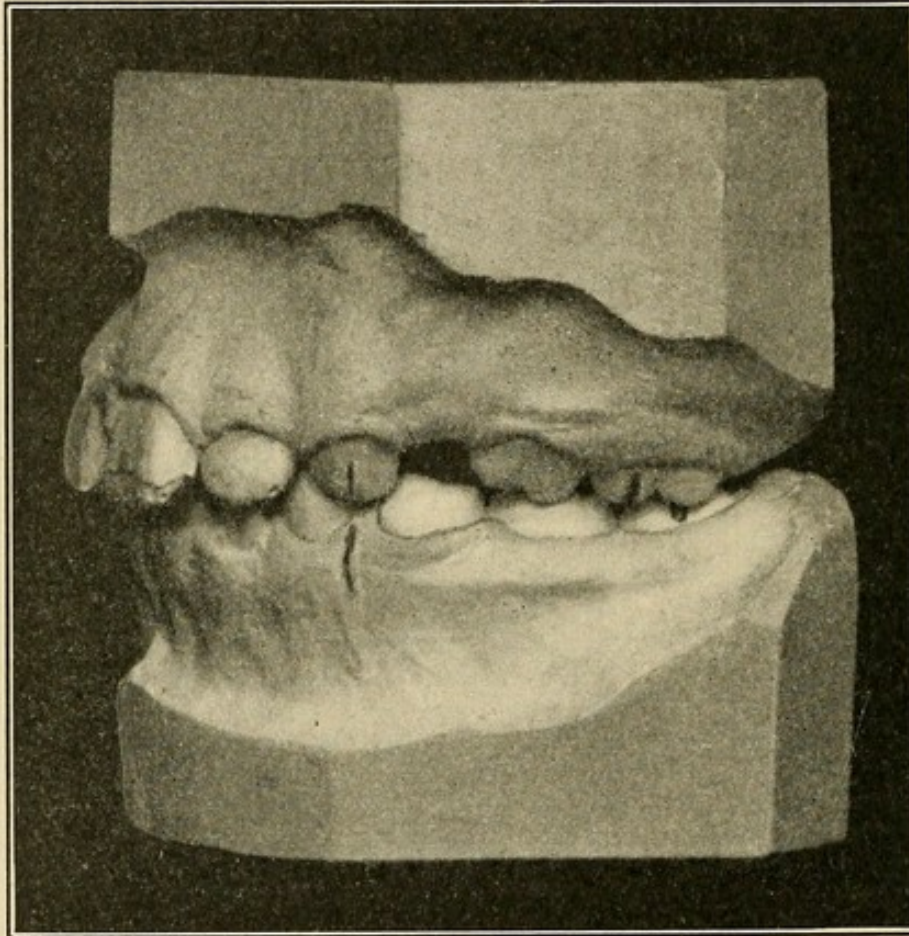
INTRINSIC FACTORS

Several anomalies of dentition, and sundry constitutional peculiarities, causing malocclusion of the teeth, are due to certain inherent, systemic influences. We term these the

intrinsic factors; some of them being congenital, and probably inherited, others not.

Anomalies of Number.—These are found in both the temporary and permanent series, and frequently stand in causal relation to a malocclusion. Thus there may exist a *deficiency*

FIG. 13

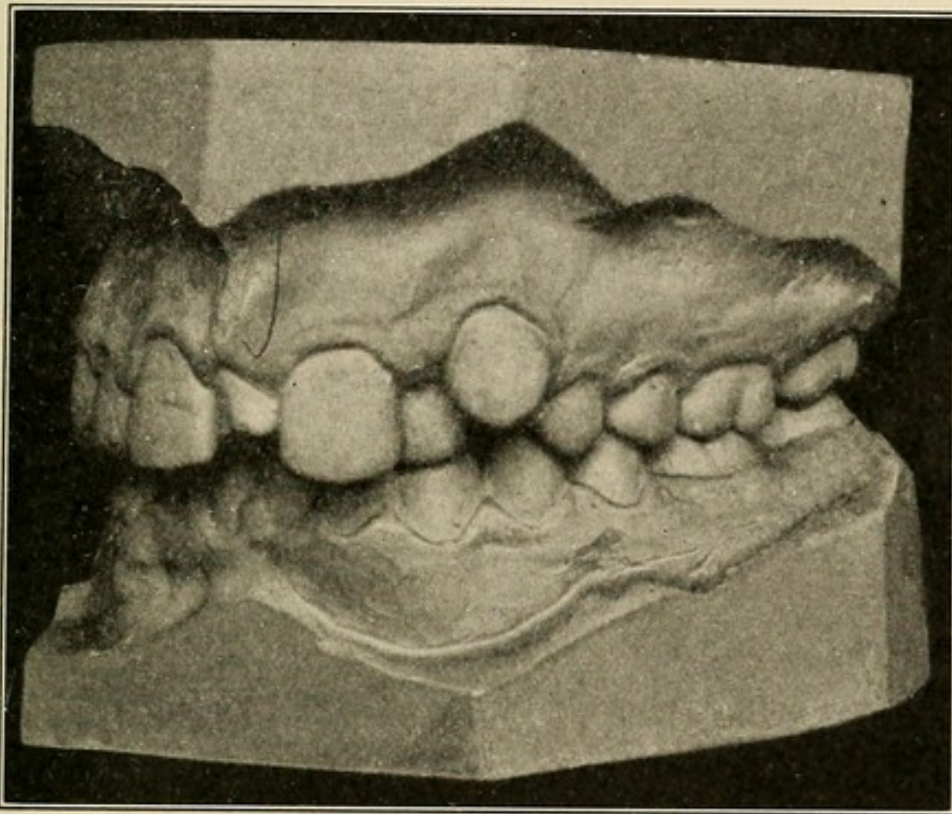


Congenital absence of the left upper temporary first molar, permitting the mesioversion of the second temporary and first permanent molars.

in the number of teeth (Fig. 13) which permits the adjoining members to migrate into abnormal positions. When more than twenty teeth appear in the temporary dentition, or more than thirty-two in the permanent, we term it *redundancy*. This may lead to a crowded arrangement of them in their respective arches (Fig. 14).

According to Busch,¹ there are three kinds of supernumerary teeth: (a) Those with conical crowns and root; (b) tubercles; and (c) supplemental teeth, or those of normal form (Hollander). Premature extraction of a temporary tooth, or other traumatic influence, might occasionally be

FIG. 14



Shows the result of redundancy of number; note the supernumerary tooth between the upper centrals.

responsible for a deficiency in the permanent set, but it is obvious that most anomalies of number are not due to extraneous causes. Atavism has long been regarded as a cause of redundancy; and more recently, their budding off from the common dental lamina has been suggested as a probable explanation of supernumerary teeth. But according

¹ Deutsch. Monatsschr. f. Zahnheilk., 1886-87.

to Tomes,¹ "our present knowledge of the subject will not enable us to recognize the cause which has produced" anomalies in the number of teeth, though syphilis, rickets, and other maladies have frequently been mentioned.

McQuillen,² Tomes,³ and many other investigators have recorded numerous cases where anomalies of number were transmitted through several generations of the same family. Fig. 15 shows the model of the upper arch of a father and Fig. 16 that of his daughter, taken from the author's collection. Frequently the histories of such cases are so vitiated by premature loss of teeth, *i. e.*, by caries and extraction, that they are of little value. Yet it is undoubtedly true that, in most cases, they are congenital and therefore transmissible.

Anomalies of Form.—Though rarely met with, anomalies of form occasionally enter into a malocclusion, and they suggest interesting morphological questions. They may express themselves in various ways, *e. g.*, deficiency, redundancy, dichotomes, etc. When affecting the anterior teeth they usually present a disfigurement, and frequently cause malocclusion of the adjoining teeth. Fig. 17 shows the models of a boy, aged nine years, exhibiting a fusion of the upper centrals and laterals. Fig. 18 illustrates a case of redundancy of form in a right upper central incisor, being fully one-third longer than the left central. Irregularity of size may also be complete, affecting the entire tooth, or partial, being limited to the crown or root.

Abnormal Frenum Labium.—Occasionally, cases present themselves with an abnormal space (diastema) between the central incisors.⁴ In the upper arch it is usually due to

¹ Dental Surgery, 5th ed.

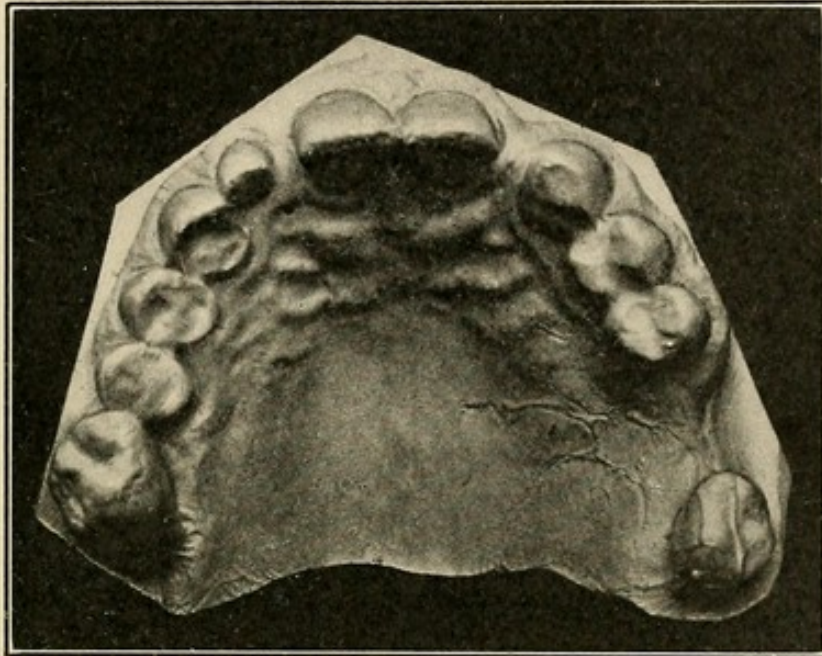
³Ibid.

² Dental Cosmos.

⁴ Angle, Dental Cosmos, 1899.

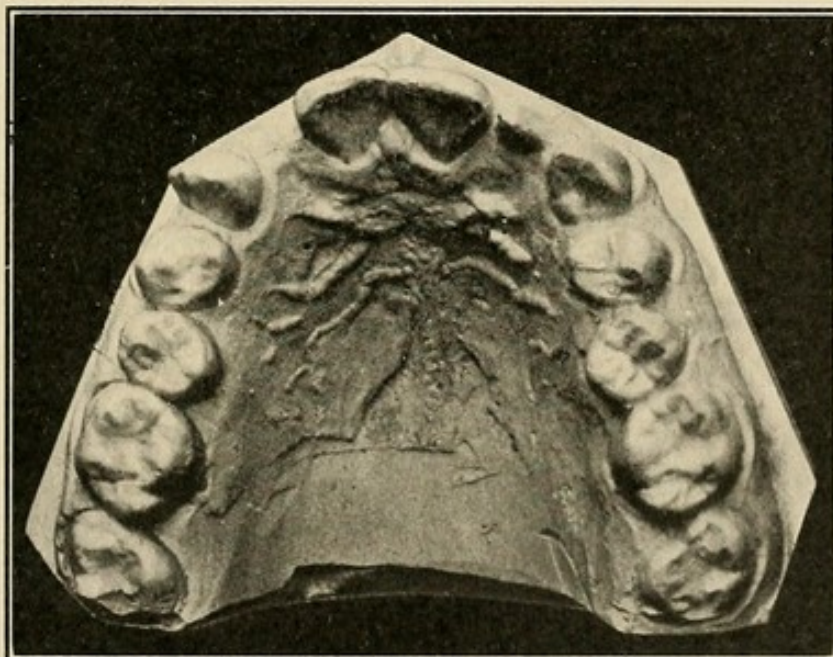
an excessive development of the frenum of the lip. The fibers of this muscular attachment are of sufficient density,

FIG. 15



Shows model of a father with deficiency in size of the right upper lateral, and of number of the left lateral.

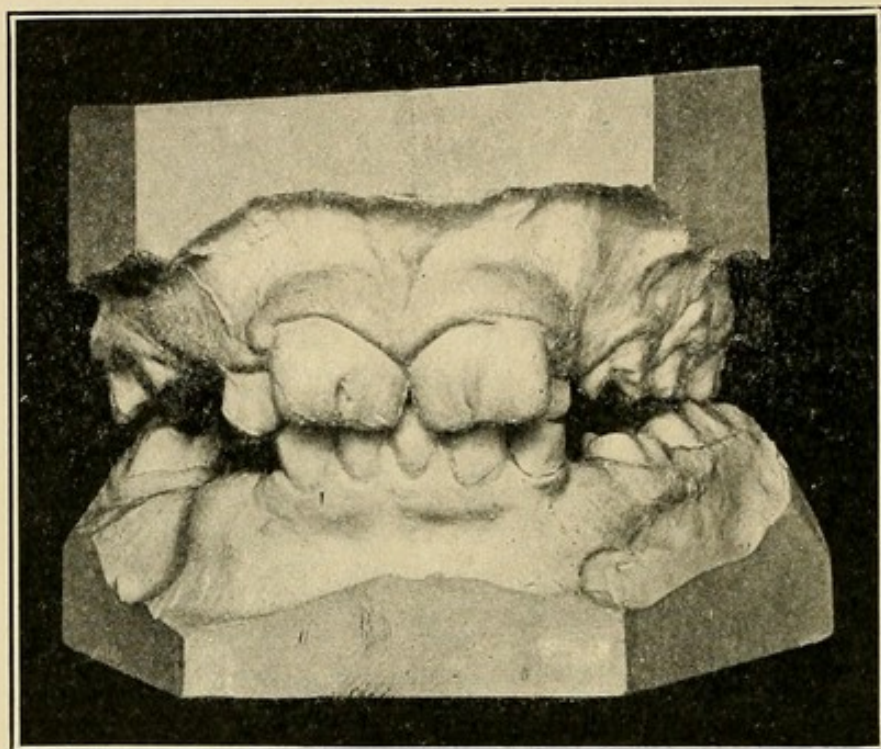
FIG. 16



From the upper arch of his daughter, exhibiting the same anomalies, though on the opposite side of the mouth.

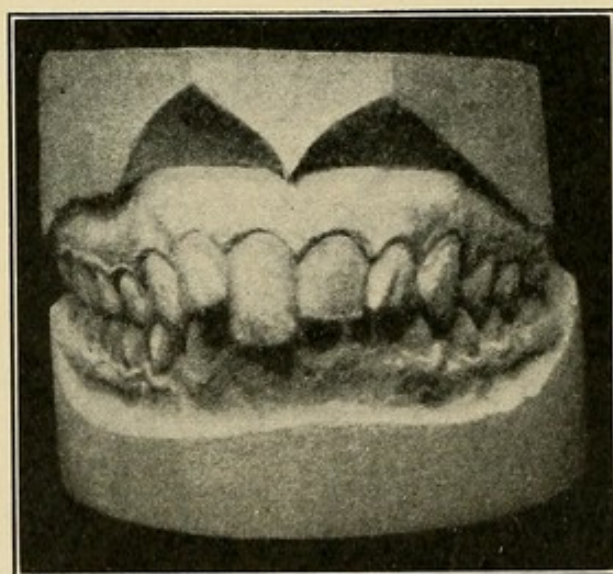
and its movements so constant, that it prevents the teeth from coming into normal contact.

FIG. 17



Anomaly of form due to the fusion of tooth germs.

FIG. 18



Redundancy of form in a right upper central incisor. (After Lukens.)

This factor is usually classified as an acquired cause, or as a "local" cause, but the author is fully convinced that this is an error. Clinical experience uniformly tends to show that in all cases brought under early observation the same abnormal conditions exist during the period of the temporary dentition. Wiedersheim¹ has shown that the raphe and papilla palatina are more highly developed in the embryo and during early infancy than in later life. This papilla has been investigated by Merkel,² who found it to be a sensory organ, and that it probably assists the palatine ridges in the trituration of food. Wiedersheim has also offered the suggestion that the raphe is "the remains of palatal teeth handed down even to man."

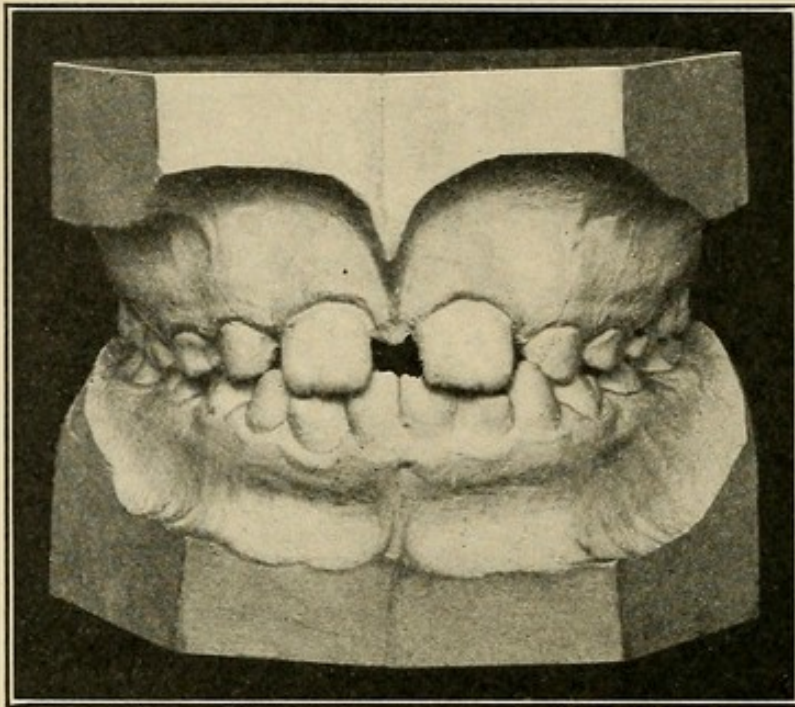
In the absence of any authentic cases showing that an abnormal frenum is due to extraneous influences, we are constrained to regard it as an evidence of faulty development during embryonic life. Atavism suggests itself as a probable cause of such faulty development; but whatever the cause, it is plain that it is intrinsic. Fig. 19 shows the models of a case, aged eight years, in which the frenum of the upper lip was found to be the cause of the very wide space between the upper centrals. Ketcham's extended investigations with the *x*-rays conclusively demonstrate that such maldevelopments are in no wise related to an opening of the maxillary suture.

Cleft Palate.—A congenital malformation of the palate usually so interferes with the development of the maxilla that if allowed to persist to the completion of the permanent dentition a malocclusion is an inevitable sequela. Fig. 20 shows the models of a girl, aged fourteen years, in which

¹ The Structure of Man, p. 155.

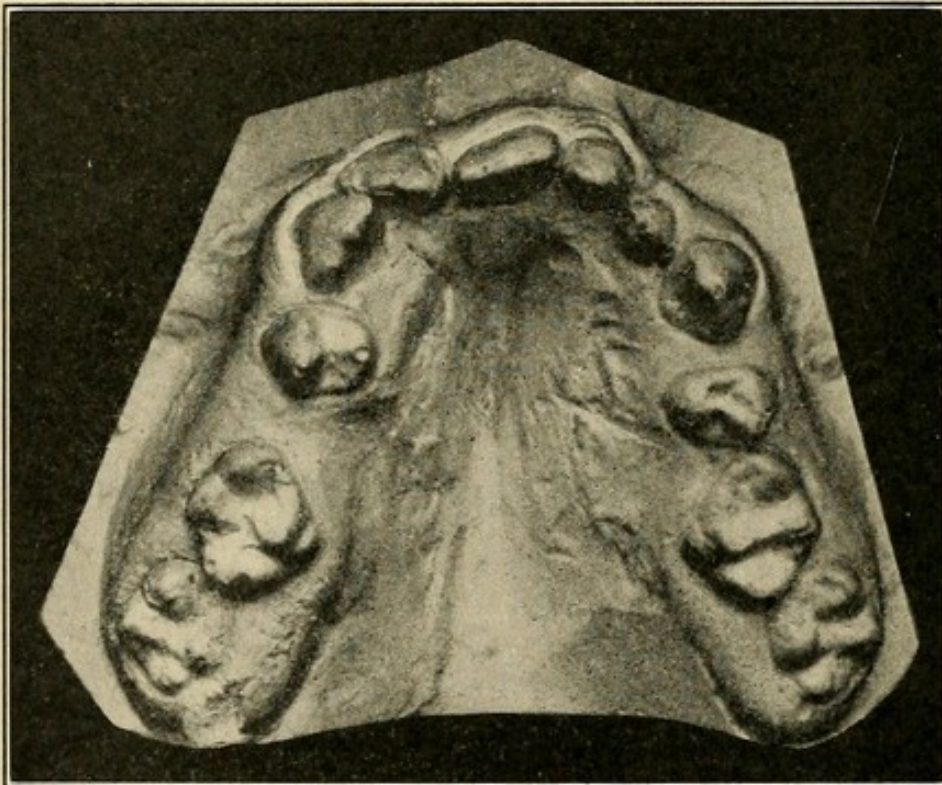
² Ibid, p. 146.

FIG. 19



Abnormal frenum labium.

FIG. 20



Upper arch of a case of malocclusion after an operation for cleft palate.

this deformity and the accompanying malocclusion are very evident. Fortunately, such cases are rare, though, as Bland Sutton¹ long ago pointed out, they are transmissible. He says: "Cleft palate has been known to occur in offspring of affected members, and if it were possible to practise selective breeding in man as in dogs, a race of men with cleft palates and harelips could be produced." The treatment of the maxillary deformity usually falls to the oral surgeon, though subsequent orthodontic interference may occasionally be indicated. Dr. Dunn has reported the treatment of such a case to the American Society of Orthodontists (Denver, 1910).

Anomalies of Position.—As already intimated, recent studies by orthodontists tend to emphasize the extraneous influences which are responsible for malocclusion. There remain a few forms of malposition, however, which cannot be attributed to them. I refer to transposition and those extreme forms of impaction for which Grevers² has suggested the term *perversion*.

Fig. 21 shows the cast of a denture, sixteen years of age, in which the upper laterals, canines, and first bicuspid have exchanged places. Fig. 22 is from Dr. Cryer's collection, showing two impacted canines in the intermaxillary region. The causes of such anomalies are unknown, though obviously intrinsic.

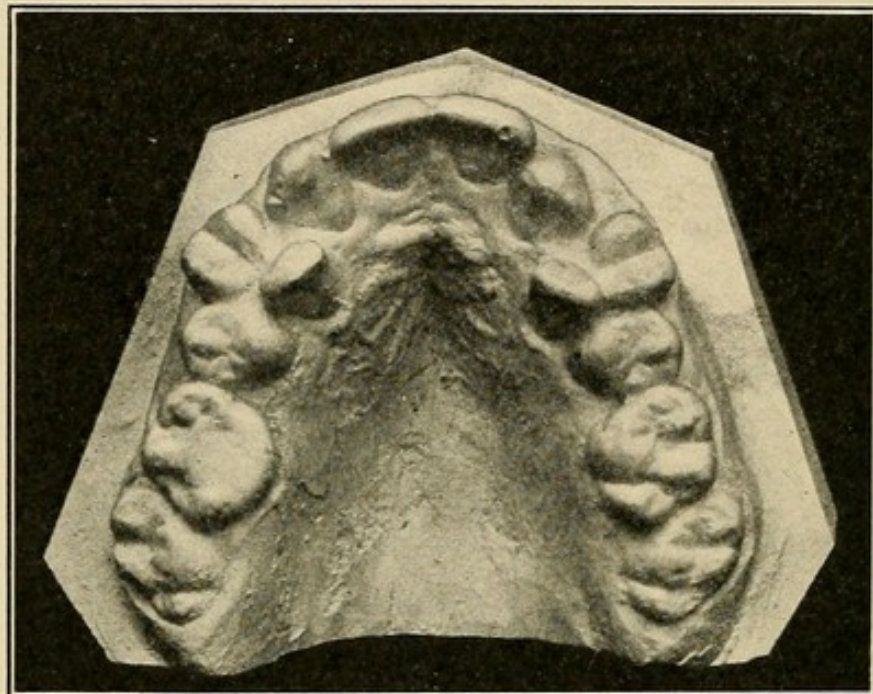
Asymmetry of the Jaws.—The jaws, or foundation structures upon which the teeth and their alveolar processes are placed, may, according to Talbot, be malformed in approximately 30 per cent. of apparently normal individuals. It is clear that if these structures are inharmoniously developed to

¹ Evolution and Disease.

² IV International Dental Congress, St. Louis, 1904.

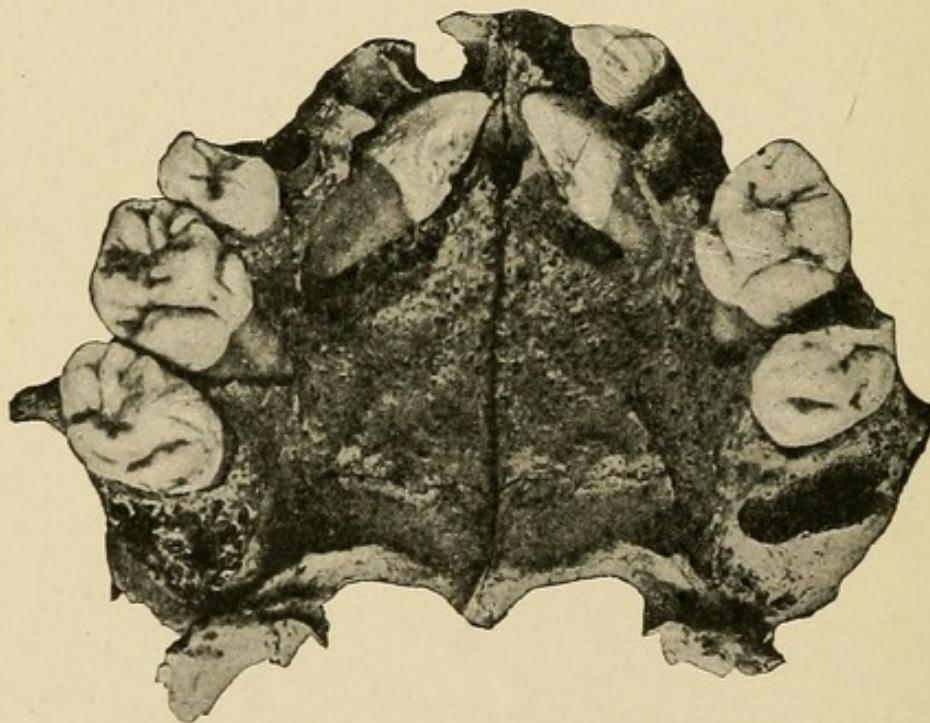
any considerable degree, the superimposed teeth are very apt, upon closure, to come into malocclusion. Both the

FIG. 21



Transversion of the upper lateral incisors, canines, and first bicuspids.

FIG. 22



Perversion of the upper canines. (After Cryer.)

upper and lower jaw may be thus affected, and while many arrests of development are traceable to abnormal occlusion, and therefore abnormal function (which speedily corrects itself after orthodontic treatment), there are rare instances which cannot be so easily disposed of. The causes of such developmental disturbances are not well understood. (See Chapter V.)

Anomalies of the Tongue.—Congenital anomalies of the tongue, which have been described by Virchow, Holt, and others, exert their abnormal influences upon the dental arches, resulting in deformity. Schendel¹ and Angle² have reported cases of this kind. When the tongue is excessively developed (macroglossie) it tends to enlargement of the dental arches, causes a spreading of the teeth, and consequent loss of contact with their neighbors. When arrested development exists (microglossie) the full normal influence of its muscular action is absent, which is usually followed by a crowded arch. (Compare Fig. 28.)

Nutritional and Specific Infectious Diseases.—Diseases of nutrition, like rachitis, scorbutus, and marasmus, generally affect the process of dentition, though they are usually confined to the period of infancy. Congenital syphilis very often affects the permanent teeth, and, according to Hutchinson, “typical syphilitic teeth have notches in their incisal edges and *are dwarfed both as regards their length and breadth.*” According to Keyes, Black, and others, such teeth are not invariably an evidence of this disease. It has also been claimed by Hill,³ Saleeby,⁴ and other English

¹ Deutsch. Monatssch. f. Zahnheilk., 1903.

² Malocclusion of the Teeth, 7th ed., 1907.

³ Heredity and Selection in Sociology, London, 1907.

⁴ Parenthood and Race Culture, New York, 1909.

writers that racial poisons, like alcohol and lead, are capable of producing malformations. And the late Herbert Spencer¹ suggested the deleterious influence of vaccination as a probable cause of the alarming increase in teeth and eye affections among the inhabitants of Great Britain.

EXTRINSIC FACTORS

The factors embraced in this group are more readily recognized, probably because the operator comes in daily contact with them. A thorough knowledge of them is also imperative, since it enables one to successfully combat their action and thus obviate the development of many forms of malocclusion.

Premature Loss of Temporary Teeth.—The necessity for the conservation of the temporary teeth during their allotted period is a truth that is gaining wide acceptance. The cumulative evidence of the disastrous results following their early loss through promiscuous extraction, or neglected progressive caries, is becoming a sufficient argument to all conscientious practitioners. Premature loss and pulp exposure due to neglected caries tend seriously to interfere with normal function; and in the development of the denture and its related structures normal function plays the leading role. Furthermore, the loss of a single tooth, or even of a part of a tooth, produces a break in the continuity of the arch and permits abnormal movements of the adjacent teeth.

Premature Loss of Permanent Teeth.—The early loss of permanent teeth, especially of the first molars, is now

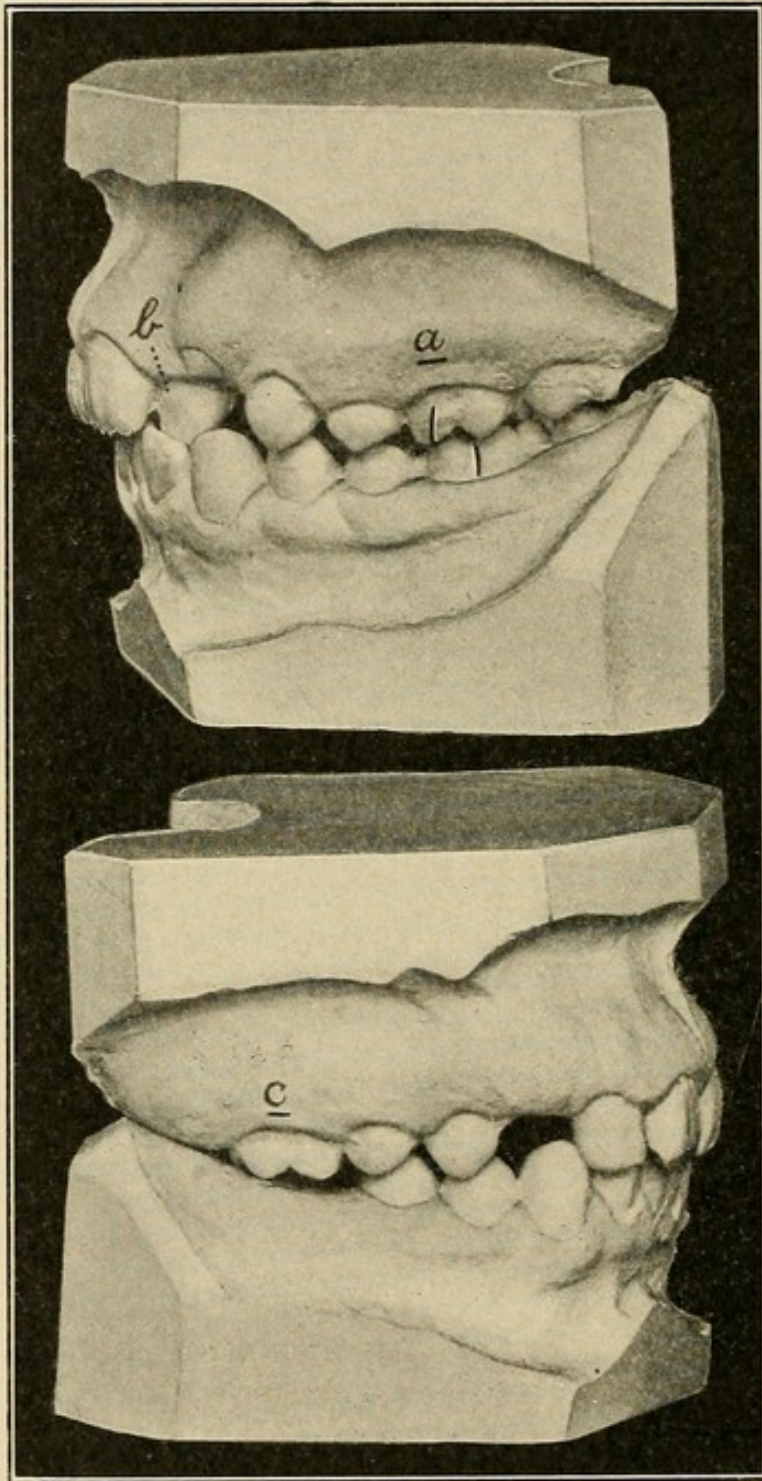
¹ Facts and Comments.

regarded as an established etiological factor of malocclusion. In action it is similar to the loss of temporary teeth as described above, and is very frequently accompanied by a deepening of the "bite," or a destruction of the normal plane of occlusion.

Prolonged Retention of Temporary Teeth.—The prolonged retention of temporary teeth, should they persist long after the need which occasioned them has ceased, is another prolific factor in the causation of malocclusion. An erupting tooth is suspended, as it were, by its soft attachment tissues, and the slightest pressure, if it be constant, is sufficient to deflect it in its course. The orifice through which a tooth passes in its journey of eruption is greatly enlarged by the absorption of the crypt walls. Of course, we have our eruption tables, but many teeth deviate from the averages there set forth; and clinical observation teaches us that there is an opportune time for the exfoliation of each temporary tooth. The operator should, therefore, exercise judgment in every case of removal of temporary teeth. Fig. 23, *a*, shows the evil results of the premature loss of temporary molars, permitting the mesial eruption of the upper first molar. Subsequently, the first and second bicuspid were also forced into mesioversion, and thus encroached upon the space the cuspid should occupy, which came at a still later period. The left upper temporary lateral was retained too long, causing a linguoversion of its permanent successor (*b*). On the right side (*c*) the elongated first molar is noted coming in contact with the lower gingival ridge, which is due to the early loss of the lower first permanent molar.

Nasal Obstruction.—The importance of normal respiration and of a rational nasal hygiene, particularly during

FIG. 23



a, mesioversion of the upper permanent molar resulting from premature loss of temporary molars; *b*, linguoversion of the upper lateral due to prolonged retention of its predecessor; *c*, beginning supraversion of an upper molar which has been deprived of occlusal contact.

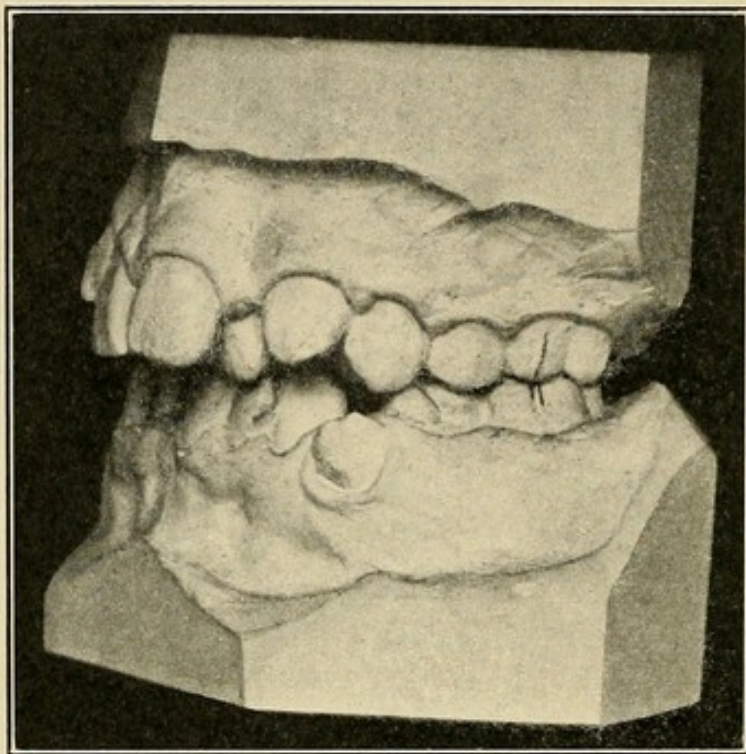
the developmental period, can hardly be overestimated. "Obstruction of the free passage of air through the nose is one of the most frequent and important consequences of nasal disease. The obstruction may be partial or complete, periodical or constant. When chronic nasal obstruction occurs at an early age, it exercises deleterious effects on the neighboring parts, on the general well-being, and on the development and growth of the whole body. The full consequences of nasal obstruction are most frequently seen in children suffering from adenoids." It may be due to one or more of the following anomalous conditions: (a) *Adenoids*, (b) *deformities of the septum*, (c) *hypertrophies of the turbinates*, and (d) *nasal polypus*. Another condition frequently met with, and very often associated with lymphoid hyperplasia of the nasopharynx, is *hypertrophy of the tonsils*, constituting an hypertrophy which includes what has been called the "lymphoid ring," or "ring of Waldeyer."

The more important direct effects of nasal obstruction Lack¹ places as follows: *Loss of nasal function, the open mouth and its mechanical consequences, deficient oxygenation of the blood, and deformity of the chest walls*. The symptoms due to a constantly open mouth, and which especially appeal to the orthodontist, he enumerates thus: *The typical facies, malformation of the jaws, malposition of the teeth, and collapse of the alæ nasi*.

In Figs. 24 and 25 are shown the models and photographs of a girl, aged twelve years, which are typical of the conditions under discussion. In his very able investigation of this type of deformity Lack concludes as follows:

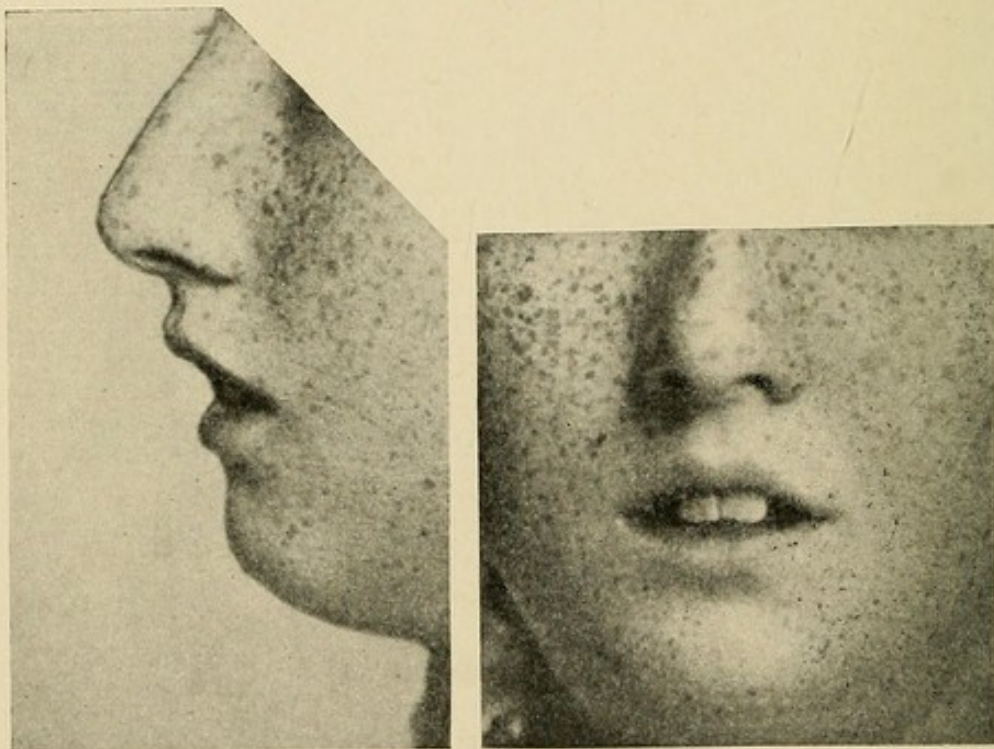
¹ Diseases of the Nose, p. 56.

FIG. 24



Malocclusion resulting from nasal obstruction.

FIG. 25



Facial deformity accompanying case shown in Fig. 24.

“Thus most observers agree that the deformities in question are frequently, if not invariably, associated with mouth breathing. Ziem’s experiments demonstrate conclusively that they may result from it. He obstructed the nostrils of puppies and other young animals, and found that great deformity of the bones of the face resulted in later life. There seems every reason to believe that nasal obstruction precedes and causes the facial deformity. The latter is never congenital, but it follows after years of mouth breathing; the changes can be arrested, and will even retrogress, if the cause be removed.”

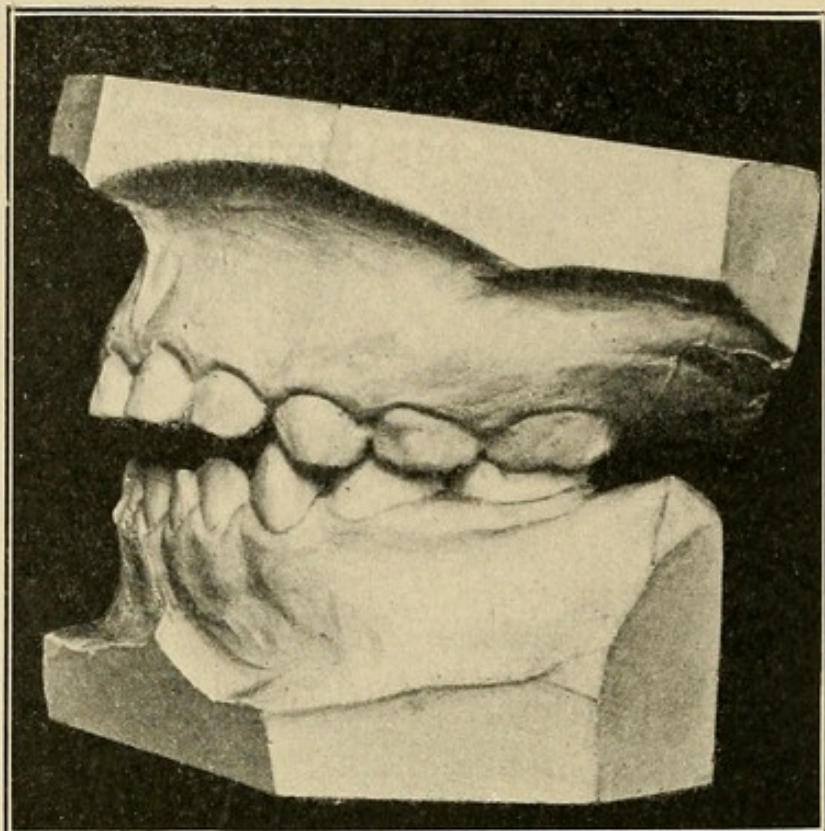
Vertical and mesial malrelations of the lower dental arch, and malformation of the mandible, are frequently associated with *mouth breathing*. Case¹ suggested the latter as a cause, and that hypertrophy of the tonsils frequently stands in causal relation to them.

But the subject of nasal obstruction is a vast one, forming a large part of the field of rhinology, and it would carry us far beyond the confines of the present chapter to attempt a detailed treatment of it. For further study, the student is referred to text-books on diseases of the nose and throat.

Habits.—Another rather fruitful cause of malocclusion are sundry habits of childhood. Foremost among these may be mentioned the habits of thumb and tongue sucking, and that of lip biting. The first is probably the most common, and very frequently hardest to discontinue. They are usually acquired during infancy, when the parents or nurse regard them as harmless, or even pleasing. But when we reflect on the mechanics of maxillary development, on the ease with which growing tissues are moulded into form, and

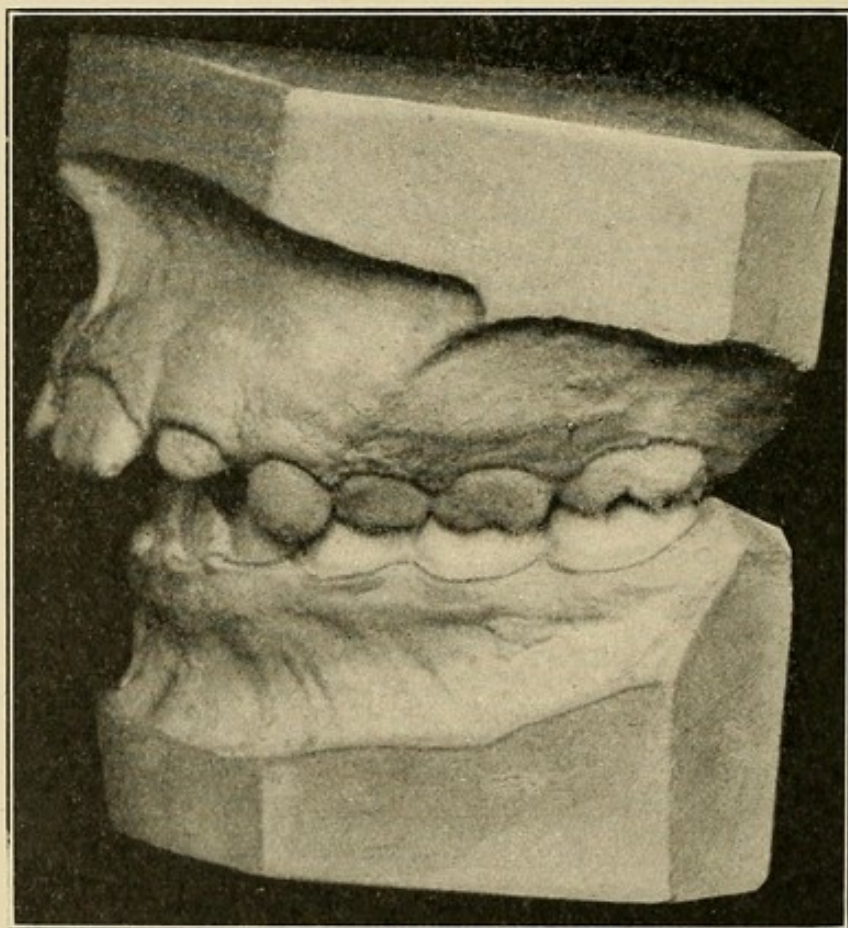
¹ Dental Review, July, 1894.

FIG. 26



Thumb sucking.

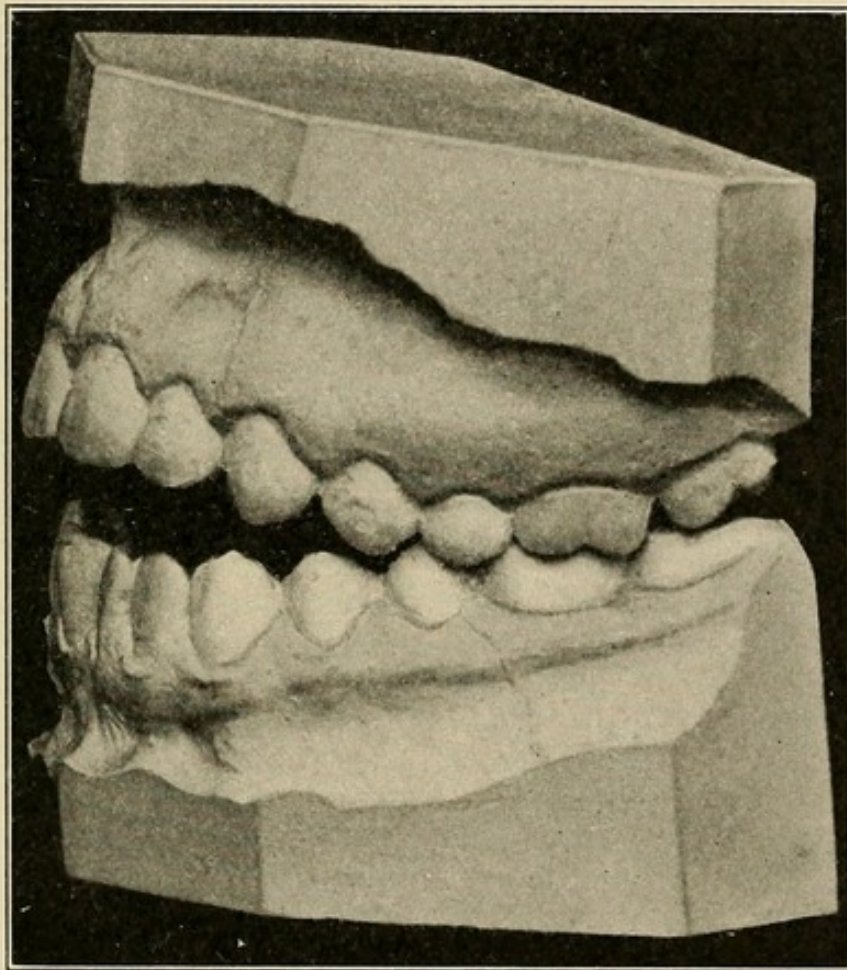
FIG. 27



Lip biting.

on the constancy of these subtle influences, we readily appreciate their gravity and source of harm when continued for a long period. Fig. 26 shows the influence of thumb sucking, causing the labioversion of the upper incisors and the lingual inclination of the lower. The constant biting and sucking

FIG. 28



Tongue sucking.

of the lower lip causes similar deformity, as shown in Fig. 27. Tongue sucking, though less common, permits the elongation of the posterior teeth (allowing an abnormal elevation of their occlusal planes) and prevents the normal contact of the anterior teeth. Fig. 28 shows a case of this type.

Some writers have classified mouth breathing as a habit,

though it is obvious that it is but a symptom of pathological conditions of the respiratory tract. Herbst¹ also mentions the probable influence of the following, which are frequently overlooked: The use of pacifiers during infancy, the sucking of cheeks, the biting of the upper lip in mesiocclusion of the lower arch, resting the cheeks upon the hands, resting the chin upon the hand, and sleeping on one side. According to this author, Peckert has suggested the biting of cigar tips as practised by cigarmakers; Palltorf the biting of threads among seamstresses; the playing of musical instruments like the flute, etc., and the artificial deformities of the teeth as practised by many primitive races (Schröder), as causing deformities of secondary importance.

Accidents and Traumatic Influences.—Falls, or violent blows upon the teeth, and fractures of the alveolar processes and maxillæ, may cause malocclusion if their treatment is neglected; though Angle and other writers have conclusively shown that such deformity can readily be prevented if the proper treatment is provided. Tomes² reports a case of malocclusion accompanied by malformation of the mandible, in a patient, aged twenty-one years, which was due to a burn about the neck and chest at the age of five. Fig. 29, taken from the author's collection, shows the casts of a youth, aged eighteen years, who was kicked in the mouth by a mule during his eighth year.

Dr. Chilcott,³ of Bangor, Me., presents a paper in which he describes an "Obstetrical Deformity of the Mandible," which he attributes to a breech presentation. It is claimed that such presentations may cause a *straightening* of the

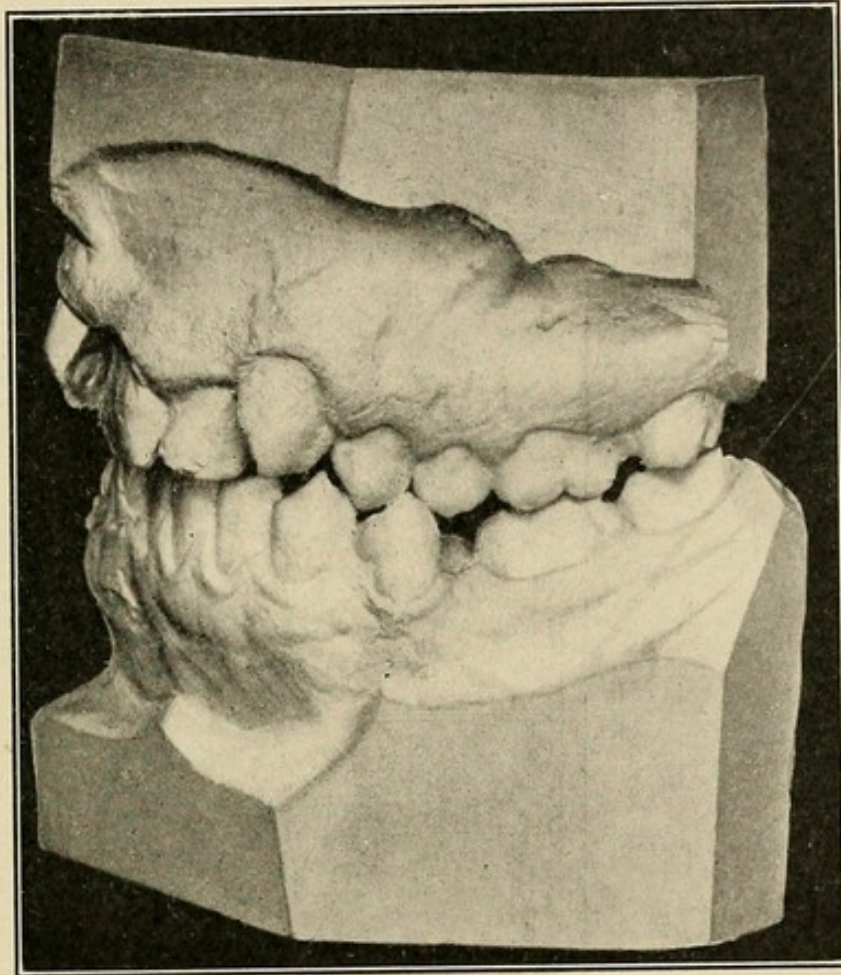
¹ Zahnärztl. Orthopädie, p. 84.

² Dental Surgery, 5th ed. p. 166.

³ Dental Cosmos, March, 1906.

mandible, resulting in mesiocclusion of the lower arch and malformation of the mandible.

FIG. 29

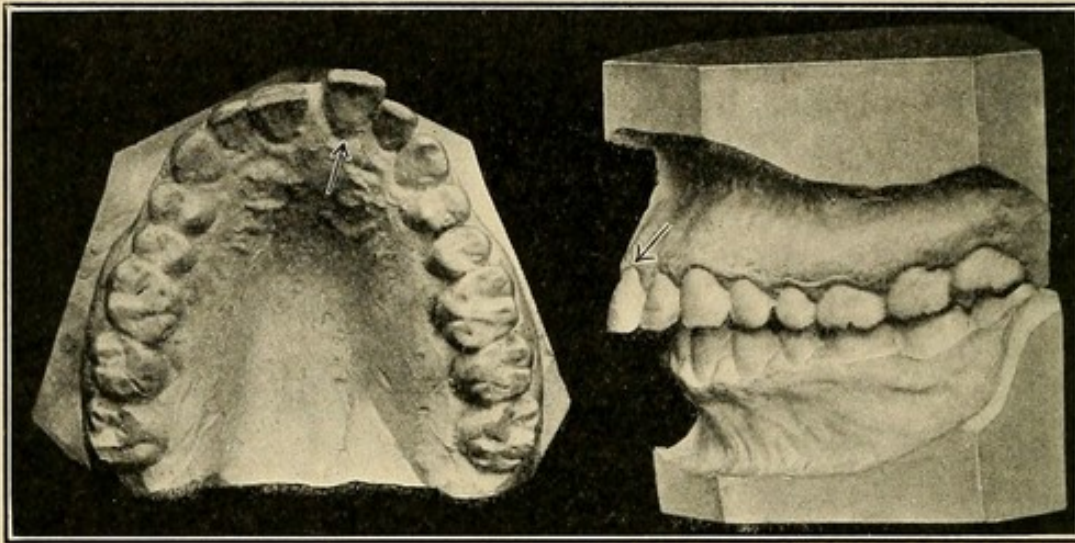


Malocclusion due to an accident.

Pericemental Affections.—It is well known that chronic infections of the pericementum and alveolar processes, commonly termed pyorrhea alveolaris, or alveolitis, may cause malposition of the teeth. Fig. 30 shows the cast of a denture, thirty-eight years old, in which the upper incisors were the seat of such infection, and which had gradually caused their labial movements during a period of two years. The distoclusion of the lower arch (which is evident) must not, however, be attributed to this cause, but to nasal

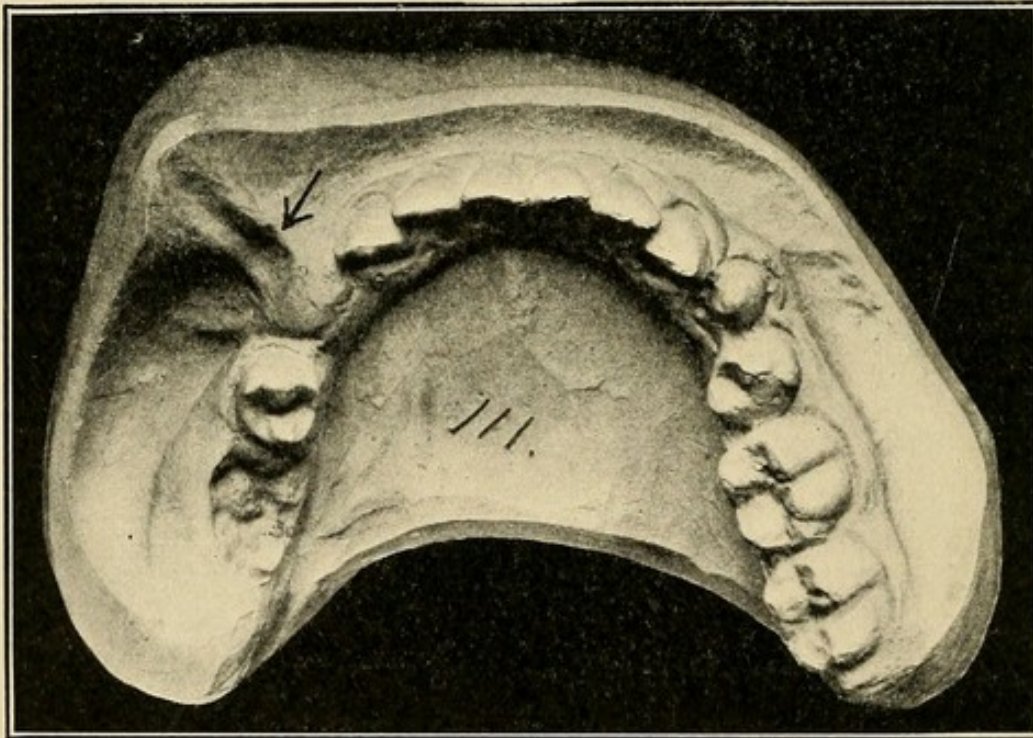
obstruction in childhood, which the history of the case clearly established.

FIG. 30



Malalignment due to alveolitis.

FIG. 31



Hyperplastic formation of connective tissue preventing the eruption of a lower bicuspid.

Neglected progressive caries of the deciduous teeth usually leads to pulp exposure and infection, and to chronic abscesses

discharging in a sinus. At the meeting of the Missouri State Dental Association for 1906, the author reported a case of a youth, aged sixteen years, who suffered from such neglect during his eighth year. The point of infection was in the left lower deciduous first molar, and caries soon destroyed all of the remaining tooth tissue that was not resorbed. The membranous surfaces of the adjacent tissue being inflamed, together with a cessation of suppuration, so coalesced as to result in a fibrous adhesion. This *hyperplastic formation of connective tissue* caused the impaction of the first bicuspid, completely preventing its eruption (Fig. 31).

Disuse and Artificial Nursing.—Disuse of the dental organs during childhood or the developmental period, and the artificial nursing of infants, are frequently mentioned as causes of arrested development of the maxillæ and their processes. The modern methods of cooking food and neglected caries are also said to be largely responsible for the prevalent practice of improper mastication.

In his study on *The Mechanical Formation of the Denture*, Körbitz¹ has carefully analyzed such influences as active muscular pressure; the passive pressure of the soft parts; atmospheric pressure; pressure of the adhering tongue, as noted by Cryer; the functional influence of occlusion, etc., all of which are minimized, or even perverted, in cases where the above-mentioned factors are operative.

UNKNOWN FACTORS

The author has tried to enumerate all of the accepted factors of causation, yet he realizes that the facts here

¹ Oest.-Ungar. Vierteljahrsch. f. Zahnheilk., 1906.

presented form but the merest outline of this subject. The problems of causation represent a field so vast that its boundary lines are hardly discernible. Many of the truths therein enclosed are reserved for future investigation. Some of the causes already mentioned, and others less generally accepted, might quite advantageously be grouped into a class and labeled as *unknown*.

Some authors contend that civilization is a cause, that our modes of life in contrast with primitive man make for retrogression and degeneration. But there is little in the way of direct evidence regarding this, and it is probably only "one of those delightfully vague suggestions which are thoughtlessly advanced."¹ Wallace very significantly adds: "Knowing, as we do, that 'thousands' of Chinese skulls have been examined, and only one trivial case of irregularity has been observed, and knowing also that the Chinese belong to the most ancient civilization extant, and, further, having been taught that irregularities are frequent among Hawaiians, we must be careful about laying too much credence on the idea that civilization is anything more than a frequent concomitant of irregularities."

Race mixture has been suggested as a cause, especially in America, which has very aptly been called "The Melting Pot." It has been claimed that in mixed types, "the product of a cross between a broad- and a long-headed race, one contributes the head form, while the other the facial proportions." Anthropologists have frequently reported disharmonisms of this kind, but the data upon which similar deductions regarding the teeth are based are very scanty.

In conclusion, it may be worth emphasizing the one great

¹ Wallace, *Irregularities of the Teeth*, p. 98.

difficulty confronting investigations of this kind, viz., the lifetime of an observer is too brief to comprehend more than three generations; and even in cases where this is possible the data are frequently so vitiated that they are of little value. Our greatest hope for the future, therefore, must lie in the realm of experiments on the lower animals.

CHAPTER V

THE DIAGNOSIS OF MALOCCLUSION

FIRST PRINCIPLES

THE dental axiom that *only a normal denture can perform normal functions* is gaining wide acceptance. This not only implies immunity to caries and the absence of sundry lesions of the oral tissues, but a denture whose architectonic form approaches the ideal. To perform the complex functions in response to which the teeth were brought into being, they develop characteristic forms and assume very appropriate anatomical positions. An intimate knowledge of these fine symmetrical relations is very essential in orthopedic practice, for in the correction of every malocclusion we are confronted with the two queries:

(a) What is the nature and extent of the abnormality to be corrected?

(b) What is the condition we wish to establish?

Ultimately, these inquiries always lead us to ask the further questions:

(c) What movements will be necessary?

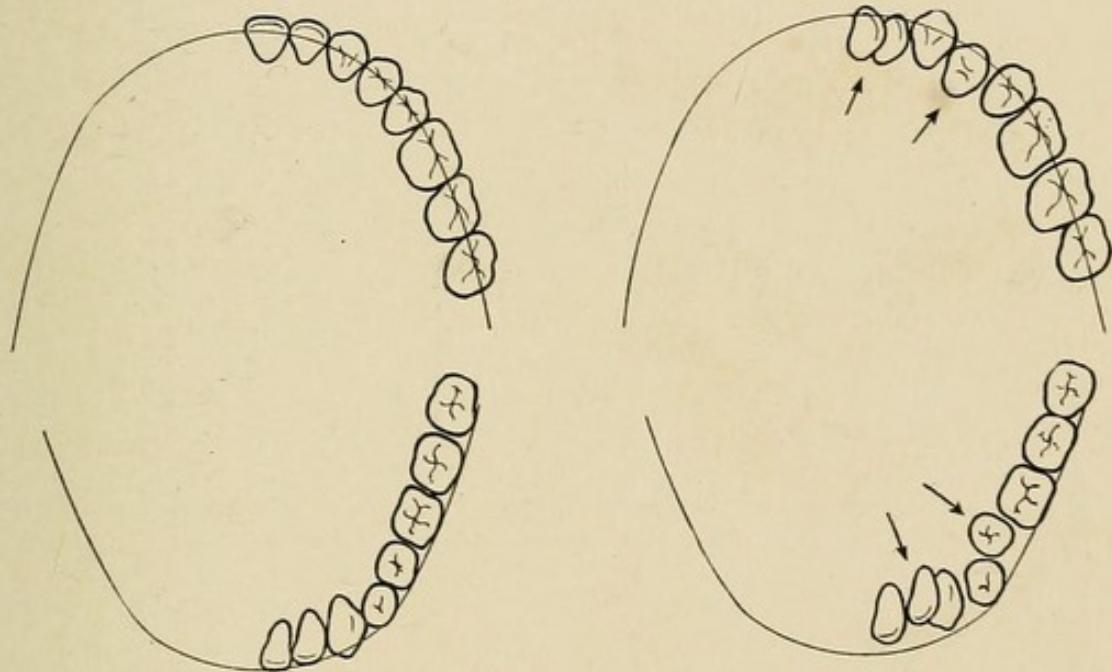
(d) What method of treatment will best accomplish these movements?

To the beginner the selection of the remedy, or the answer to question (d), seems most important; but it requires very little experience to show that this is an error, and that the only logical approach to the problems is in the order in which they are here presented.

The answer to the first query (*a*) implies an accurate diagnosis, an interpretation of the abnormality on a basis of normality; and since the aim of every treatment is the establishment of normal relations, the significance of what constitutes a normal denture becomes evident.

The arrangement of the teeth in the form of two parabolic curves within the alveolar processes of the jaws is called their *alignment*. When a tooth deviates in its position from this

FIG. 32



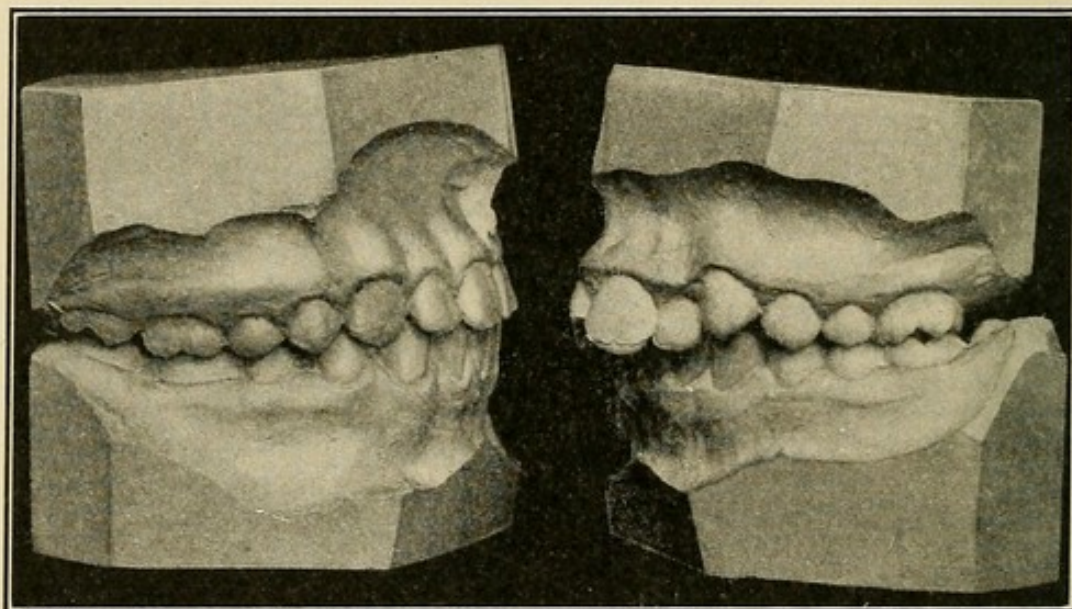
Alignment and malalignment.

ideal line, it is said to be in *malalignment*, or *malposition* (Fig. 32). When brought together in the act of mastication, normally arranged teeth are found to interdigitate very accurately. This intimate relationship existing between the cusps of the lower teeth in normal contact with those of the upper is termed *occlusion*. It is a primal function of the teeth, and is dependent upon their position. When a tooth occupies an abnormal position, and hence, on closure, comes into abnormal contact with its antagonists, it is said to be

in *malocclusion* (Fig. 33). The latter is a generic term used to collectively designate the various abnormal forms of occlusion. Occasionally, teeth assume such extreme malpositions that they are actually in *non-occlusion*, failing in contact with their antagonists (Fig. 28).

Malocclusion of the teeth presents itself in an almost endless variety of forms, and for many years it was an accepted belief that their classification constituted a hopeless task. Fortunately, numerous investigators were not similarly

FIG. 33



Occlusion and malocclusion.

minded, but endeavored to bring order into this apparent confusion, to detect similarity in so vast a number of deviations from normality. They realized that a comprehensive classification constituted the main problem in the difficult art of diagnosis, and hence devised systems for this purpose. The first recorded attempt was by the German dentist, Kneisel,¹ who proposed the two groups, *partial* and *complete*.

¹ Der Schiefstand der Zähne, Berlin, 1836.

By the term *partial*, he meant malposition of the individual teeth; and by *complete*, he had reference to the abnormal relations of the dental arches. From among the many other methods proposed since then, we may mention those by the following authors as the most important: Carabelli,¹ Magitot,² Iszlai,³ Sternfeld,⁴ Angle,⁵ Welcker,⁶ Grevers,⁷ Herbst,⁸ Zsigmondy,⁹ and Villain.¹⁰

Most of these efforts at conceptual shorthand are more or less comprehensive, and are largely based upon pathological manifestations. Many others proposed from time to time were based upon the treatment to be instituted, and were, needless to state, fallacious. Furthermore, several of these schemes contained proposals for an improvement in our nomenclature, embracing systems of terms which, by their very etymology, would convey a picture of the conditions implied. But desirable as such efforts appear, they have not altogether removed our difficulties, and, at the present writing, not one of them has gained universal acceptance.

DEFINITION

Broadly interpreted, every diagnosis implies a consideration of several general conditions, *e. g.*, the age, general and oral health of the individual, the relative degree of growth and development, the recognition of causative factors, etc.

¹ Handbuch der Zahnhl., Wien, 1844.

² Traité des anomalies du système.

³ Internat. Med. Cong., London, 1881.

⁴ Ueber Bißzerten und Bisanamolien, München, 1888.

⁵ Dental Cosmos, 1899.

⁶ Archiv f. Anthropologie, 1902.

⁷ IV Internat. Dental Cong., St. Louis, 1904.

⁸ Deutsch. Zahnärztl. Woch., 1904.

⁹ Oestr. Zeit. f. Stomatologie, Wien, 1905.

¹⁰ Zeit. f. Zahnärztl. Orthopädie, Berlin, 1910.

Custom, however, limits the use of the term to the art of differentiating one affection from a group of abnormalities having similar symptoms. Thus in orthodontic practice it embraces: (a) The distinguishing of one form of malocclusion from another; (b) the detection of anomalies of dentition (and of the jaws and related structures) other than those of position and occlusion; and (c) the degree of facial deformity associated therewith.

GENERAL OUTLINE OF THE ANOMALIES OF DENTITION

In 1877 the French dentist Magitot¹ proposed a comprehensive scheme for the many deviations from normality found in the denture of man. Though based upon the records of 2000 cases, it was formulated prior to the introduction of many of our present methods of treatment, which latter have greatly extended the field of dental orthopedics. He therefore omitted mention of the deformities of the facial lines, and of the maxillary structures beyond the teeth, presenting a classification substantially as follows: (a) Anomalies of eruption; (b) anomalies of number; (c) anomalies of form and structure; and (d) anomalies of position.

The anomalies of eruption may be further classified into premature and tardy; those of number, into deficiency and redundancy; those of form and structure, into partial and complete, etc. Orthodontic art occupies itself largely with the correction of what Magitot termed the anomalies of position, but it should not be forgotten that any of the other forms mentioned above (and anomalies of the jaws) may be found associated with them.

¹ *Traité des anomalies du système.*

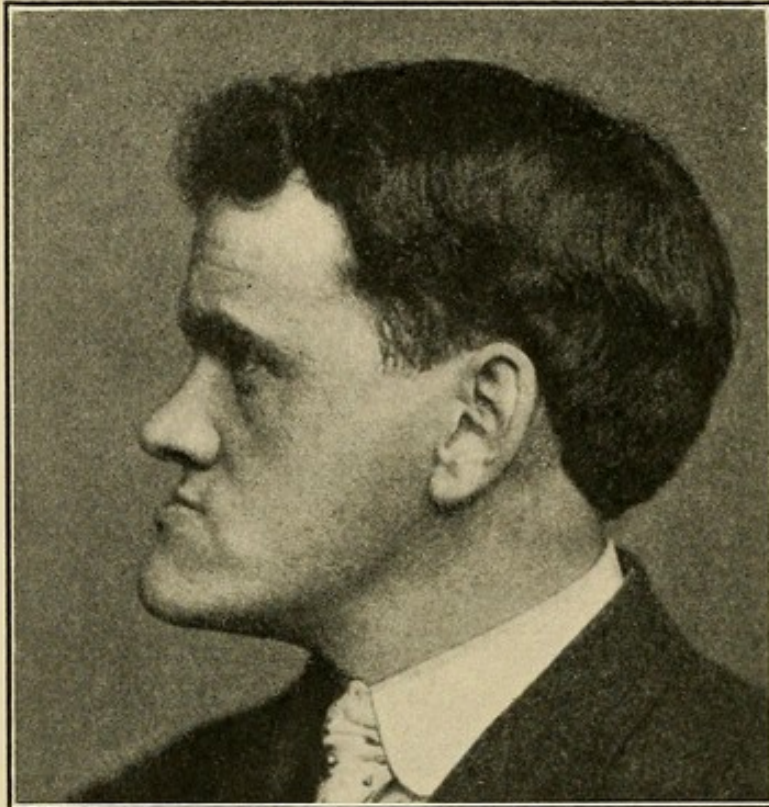
THE DIFFERENTIATION OF THE VARIOUS FORMS

Let us first ask ourselves, What conditions usually enter into a malocclusion? The answer to this question must be stated as follows: There are just three conditions which may conjoin in a malocclusion—conditions so fundamental that most writers now recognize their basic significance—and each one of these conditions is reducible into elementary divisions, regardless of their manifold combinations. Concisely expressed, these three conditions are: (1) *Malformation of the jaws and their processes*; (2) *malrelation of the dental arches*; and (3) *malposition of the teeth*. Let us briefly consider these three conditions in the order of their gravity.

Malformation of the jaws is the most serious condition we have to deal with, and at times constitutes a deformity so severe that its correction lies outside of our domain. Therefore, when a case presents a pronounced malformation of one or both jaws, it should be emphasized and receive first mention in the naming of the deformity (Fig. 34).

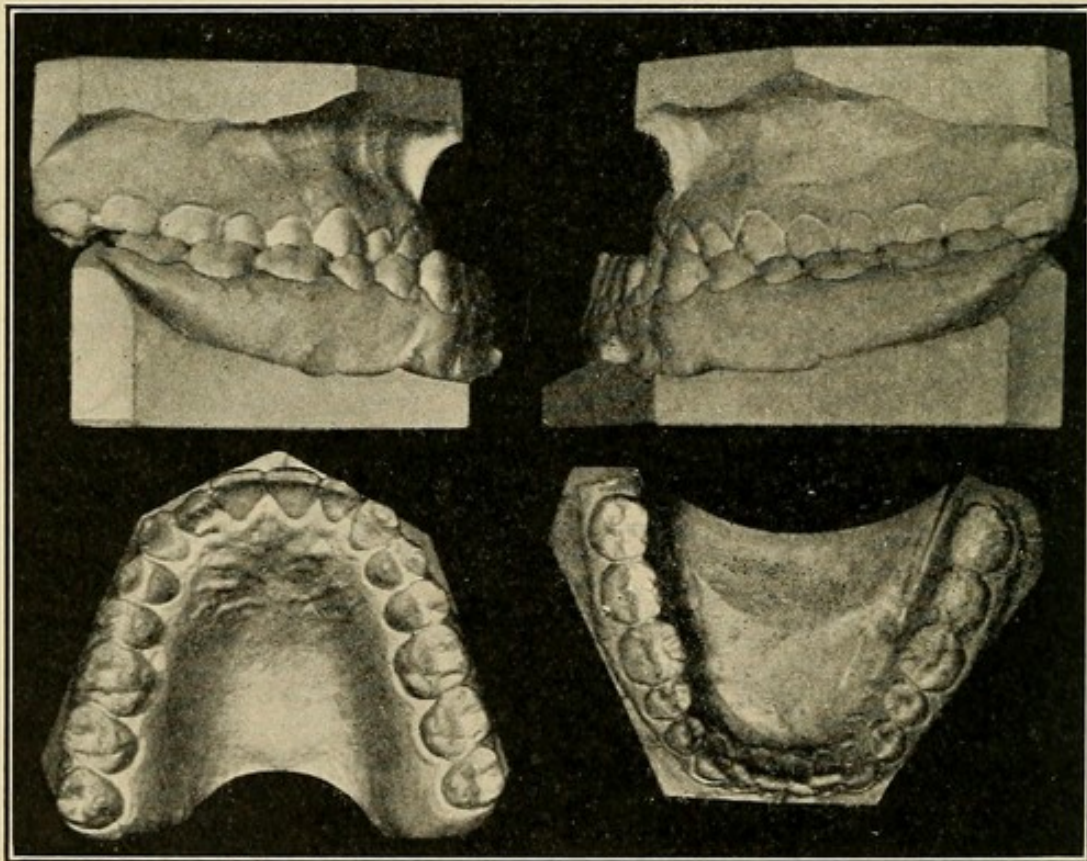
If we could remove all of the soft, overlying tissues from the mandible in such a case, exposing it to full view, there can be no doubt that the general deformity of this bone, and not the superimposed teeth and their occlusion, would attract our first attention (Fig. 35). And as we ponder over it, how futile all orthodontic efforts at correction would seem, especially if they blindly ignored this foundation. Of course, the age of the patient is an important factor in the treatment of these cases; and recent developments in the methodology of our art have established the fact that early treatment of malocclusion (by securing normal dental function),

FIG. 34



Mandibular prognathism.

FIG. 35



Shows the malocclusion of Fig. 34. The bilateral mesioclusion is but a symptom of the jaw deformity.

invariably corrects the menacing deformity beyond the teeth and their alveoli.

It is obvious, moreover, that malformations of the jaws may express themselves in several ways, hence it is desirable to enumerate the various kinds and to adopt a satisfactory terminology. Now, medical literature has for years recognized the congenital deformities of the jaws under the group-term *polygnathism*, embracing epignathism, agnathism, hypognathism, etc. And continental European writers have used the ending *gnathia* (meaning jaw) quite liberally, so that it is not entirely new in dental science. The author, therefore, suggests its adoption in this connection.

Deformities of the jaws may unfold themselves as overdevelopments, for which the term *macrognathism* serves admirably; or they may express themselves in arrested development, in which case it is termed *micrognathism*. When confined to the upper jaw, it may be indicated by the word *maxillary*; or, if confined to the lower, it is termed *mandibular*. When both jaws are similarly affected, the term *bimaxillary* is used. Furthermore, the author is of the opinion that these terms should only be used for those extreme deformities which are not amenable to orthodontic procedure.

The arrangement of the teeth in the form of two arcades or graceful curves (an upper and lower, each with its right and left sides) demands a fine adjustment of the individual members of each if a symmetrical, well-balanced ensemble is to be established. Bearing in mind that we are here dealing with bilateral symmetry, we can readily see how all of the upper teeth, or all of the lower, could be in perfect alignment in their respective arches, and yet, on closure, fail to come into normal occlusion. In other words, either

arch (even though it retain a normal form) may be so displaced upon its osseous base that normal contact with antagonists becomes impossible. We term this condition *arch malrelation* (Fig. 36). It is obvious that this is invariably accompanied by malposition of the teeth, though the latter frequently exists without the former. Differently expressed, in cases of simple malposition, accompanied by normal relation of the arches, we have to deal only with *anomalies of arch form*.

Since the publication of Kneisel's book many writers have recognized a few of the various forms of arch malrelation, but it remained for Angle to emphasize their far-reaching significance and to discover the unilateral and bilateral deviations. He also proposed diagnostic points, by means of which the mesial and distal variations may easily be detected. The mesiodistal relationship, or occlusion, of the first permanent molars is thus made to serve as an aid in the diagnosis of the mesial and distal forms. Of course, in mutilated cases allowance must be made for the possible abnormal position of these teeth.

Angle's Classification.—Of all the schemes alluded to above, the Angle classification is the most widely accepted. It proposes a division of all forms of malocclusion into three classes as follows:

Class I. Normal mesiodistal relation of the arches.

Class II. Distal relation of the lower arch.

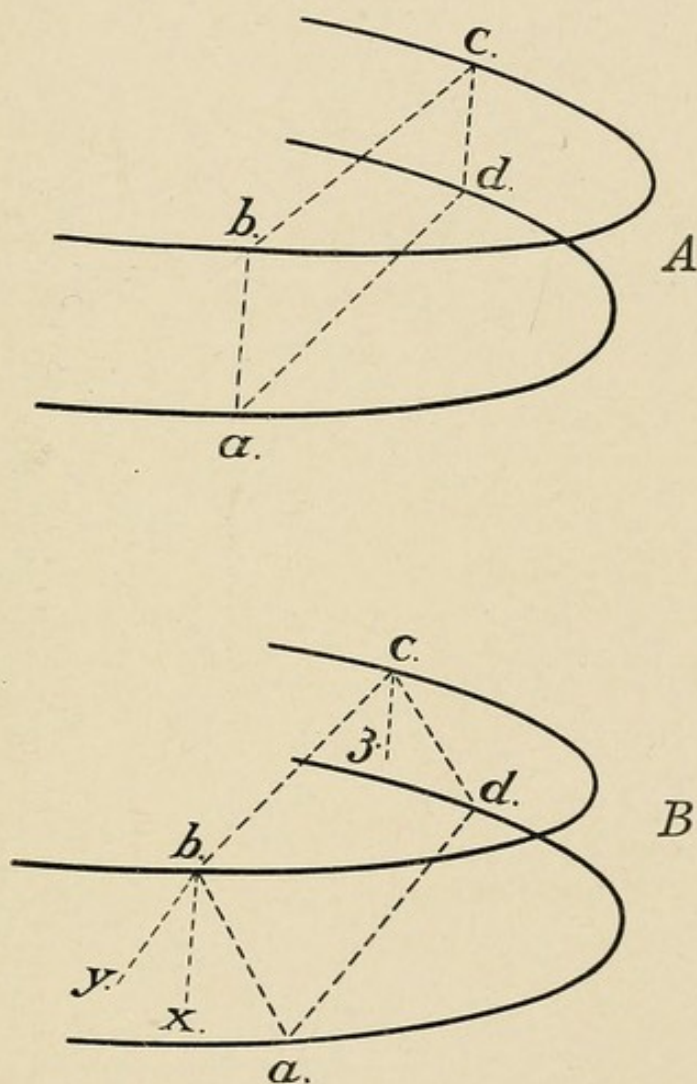
Class III. Mesial relation of the lower arch.

In its essence, therefore, it is a classification based upon the relations of the two dental arches (an exceedingly important distinction), though its numerical terminology does not indicate this.

Now, in a consideration of arch relation we base our

differentiation upon normal closure, or occlusion, hence the ending *clusion* may readily serve us in our terminology for designating the various forms. To this ending we

FIG. 36

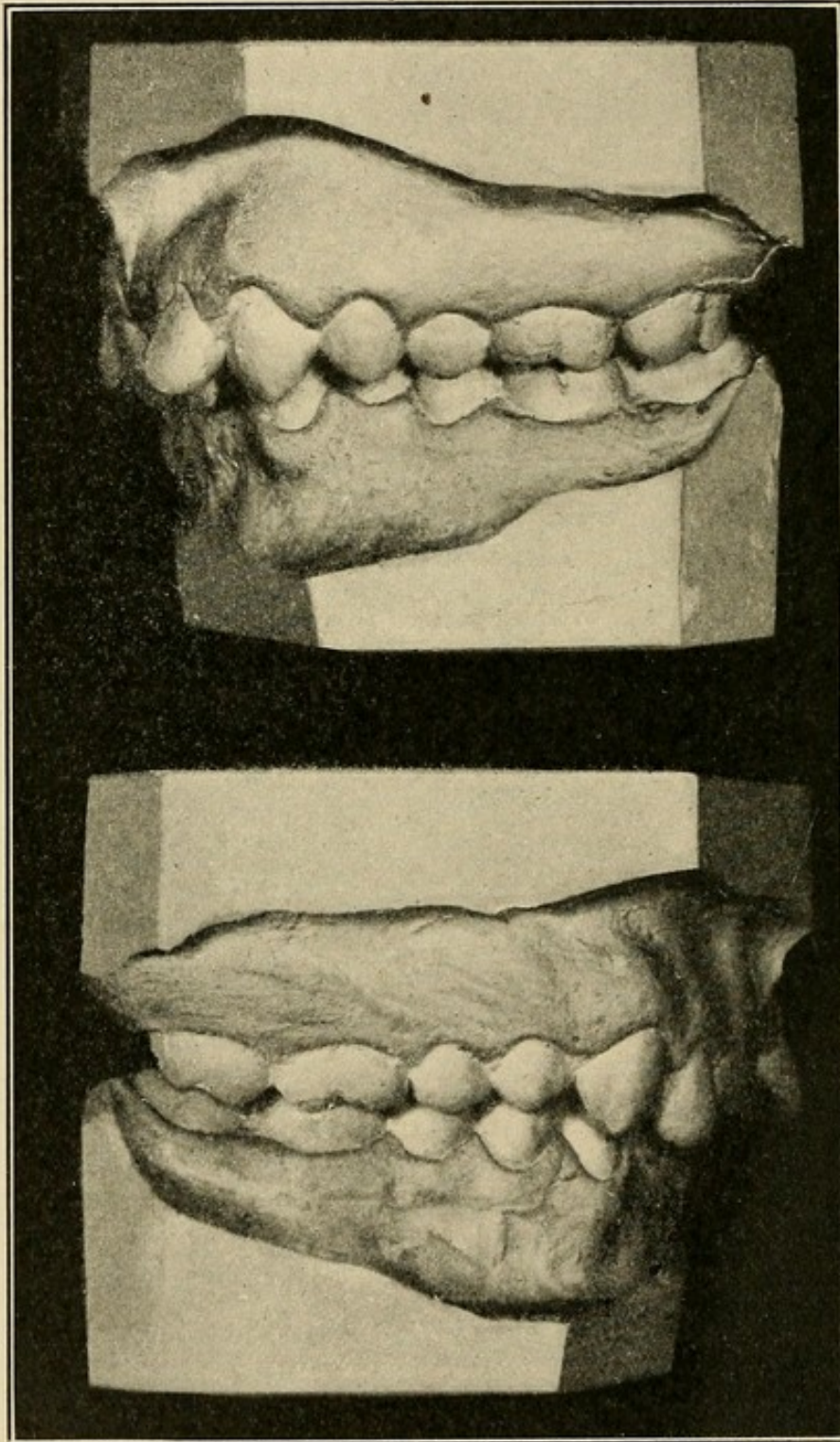


Normal and abnormal arch relation. A is diagrammatic of their normal relation, as indicated by the plane *a, b, c,* and *d*; in B their relation in a bilateral mesiocclusion is set forth, the perpendicular *b x* indicating the normal. The line *b y* suggests their relation in distocclusion.

prefix well-known anatomical terms, and thus get the following: *Mesiocclusion*, when the lower arch is mesial in its relation to the upper (Fig. 36); *distocclusion*, when it is

distal to normal (Fig. 37). As stated above, both sides of an arch may be affected, when it is termed a *bilateral*

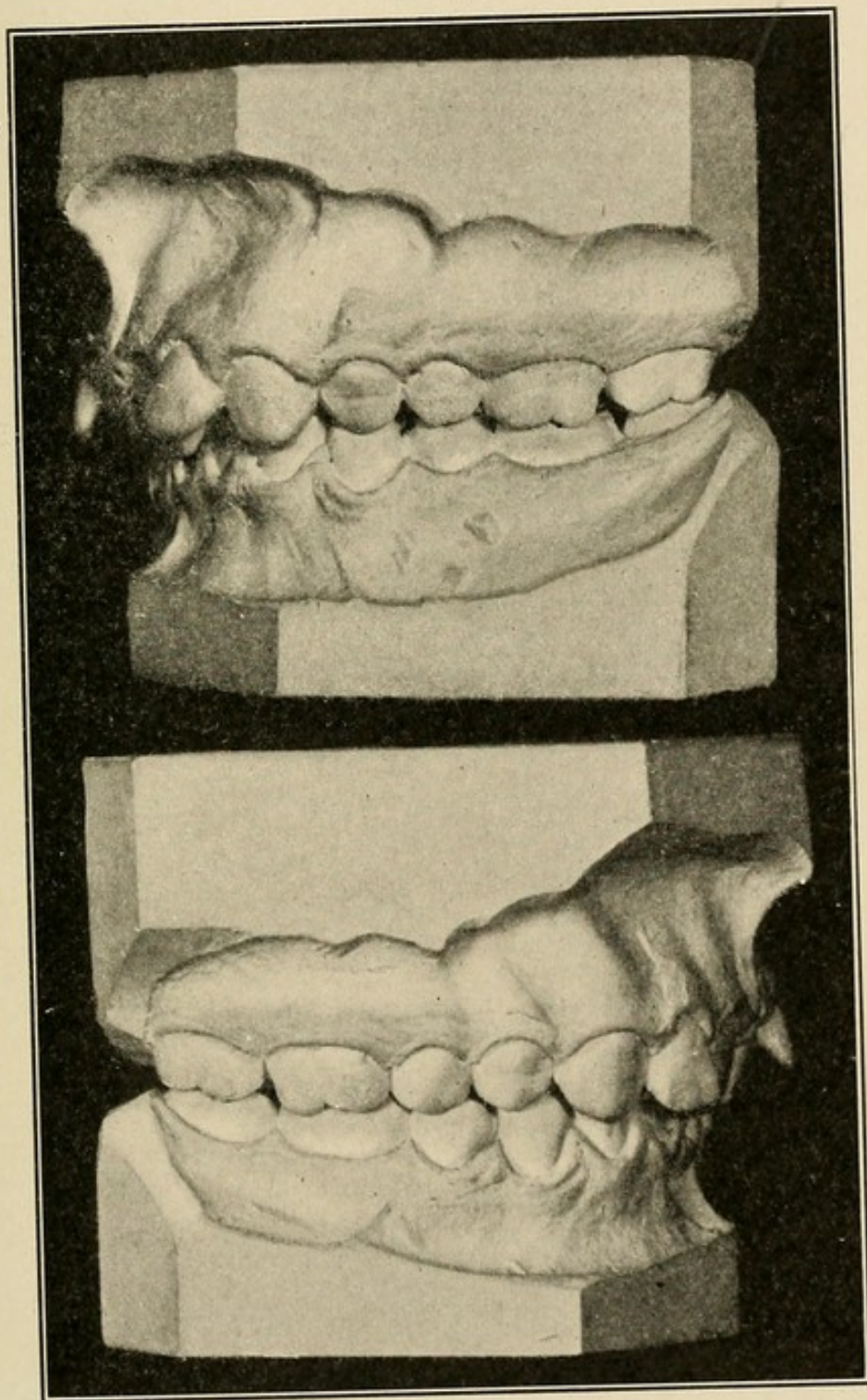
FIG. 37



Bilateral distocclusion complicated by linguoversion of the upper central incisors.

mesioclusion or *distoclusion*. Or, if only one side is involved, we term it a *unilateral mesioclusion* or *distoclusion* (Fig. 38).

FIG. 38



Unilateral distoclusion.

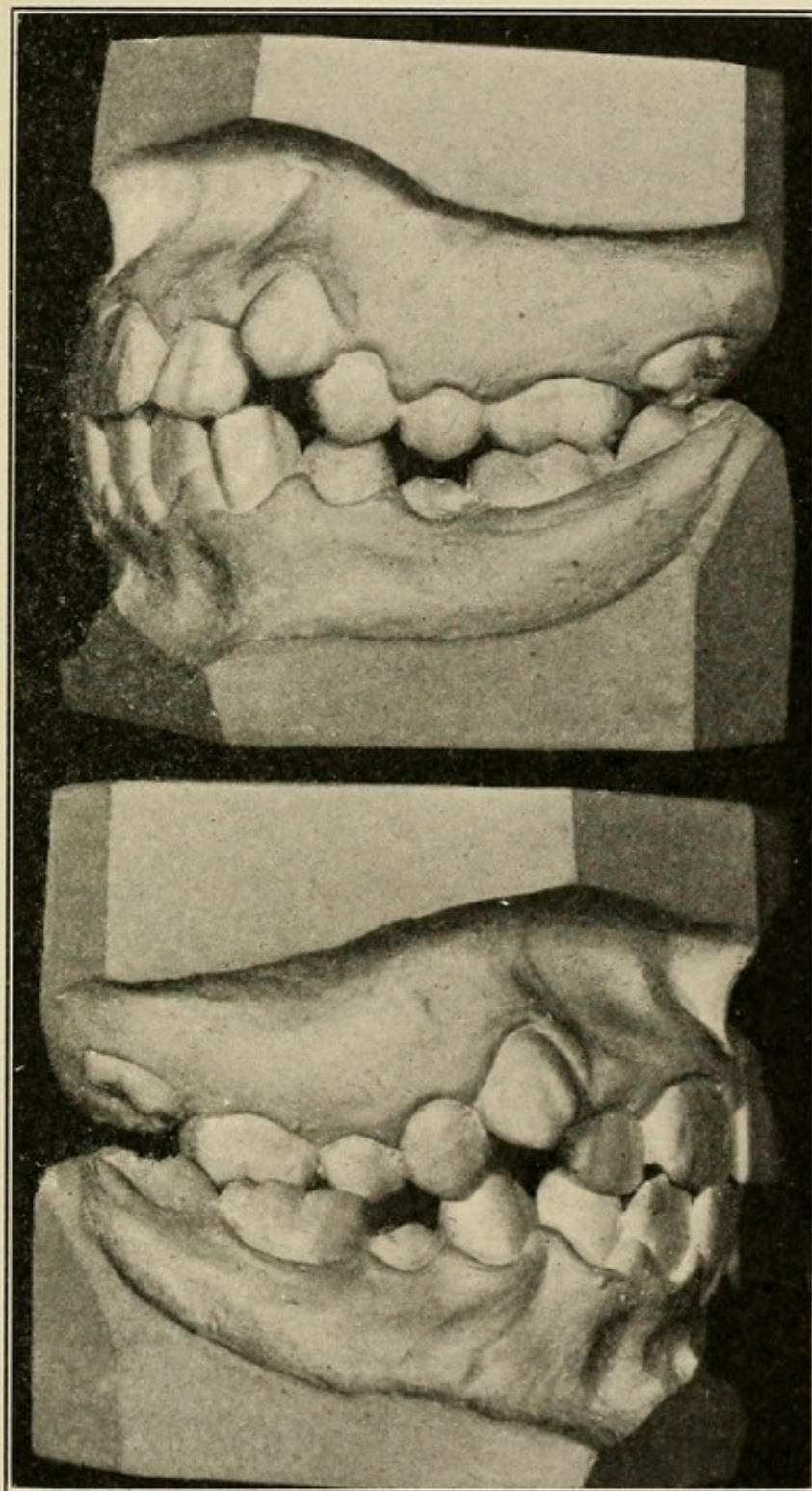
In a consideration of 1000 cases of malocclusion, Angle found 692 in which the mesiodistal relations of the arches were normal, the main difficulty being a malposition of the individual teeth, or an anomaly of arch form. In other words, one or more teeth were in malalignment, hence malocclusion, a condition recognized by all writers and loosely termed "irregularities." That there were several kinds of malposition was generally known, but again it remained for Angle to enumerate seven primary forms, and to call special attention to their possible combinations. Unhappily, this writer has become so enamored of the word *occlusion* that he makes it serve in this instance by prefixing anatomical terms to it for the designation of these seven deviations. The author firmly believes that it would be a distinct advance if an ending denoting position were used instead, because the spoken word should be measurably descriptive.

Again, having adopted the ending *clusion* as appropriate for the designation of malrelation of the arches, it becomes necessary to use another term to denote malposition of the individual teeth. Hence the author suggests that the widely used medical ending *version* (Lat. *vertere*, to turn, to change position) be used to denote malposition of individual teeth. This gives the following terms: *Labioversion* or *buccoversion* to denote labial or buccal malposition; *linguoversion*, when a tooth is lingual to normal; *mesioversion*, when mesial to normal; *distoversion*, when distal to normal; *torsoversion*, when rotated on its axis; *supraversion*, to denote elongation; *infraversion*, for depression (Fig. 28); *perversion*, for impacted teeth (Fig. 22); and *transversion*, for transpositions (Fig. 21).

Now, the mere fact that approximately 70 per cent. of all forms of malocclusion exhibit neither extreme malformation

of the jaws nor mesial or distal malrelation of the arches, emphasizes the advantage of a separate term for this large

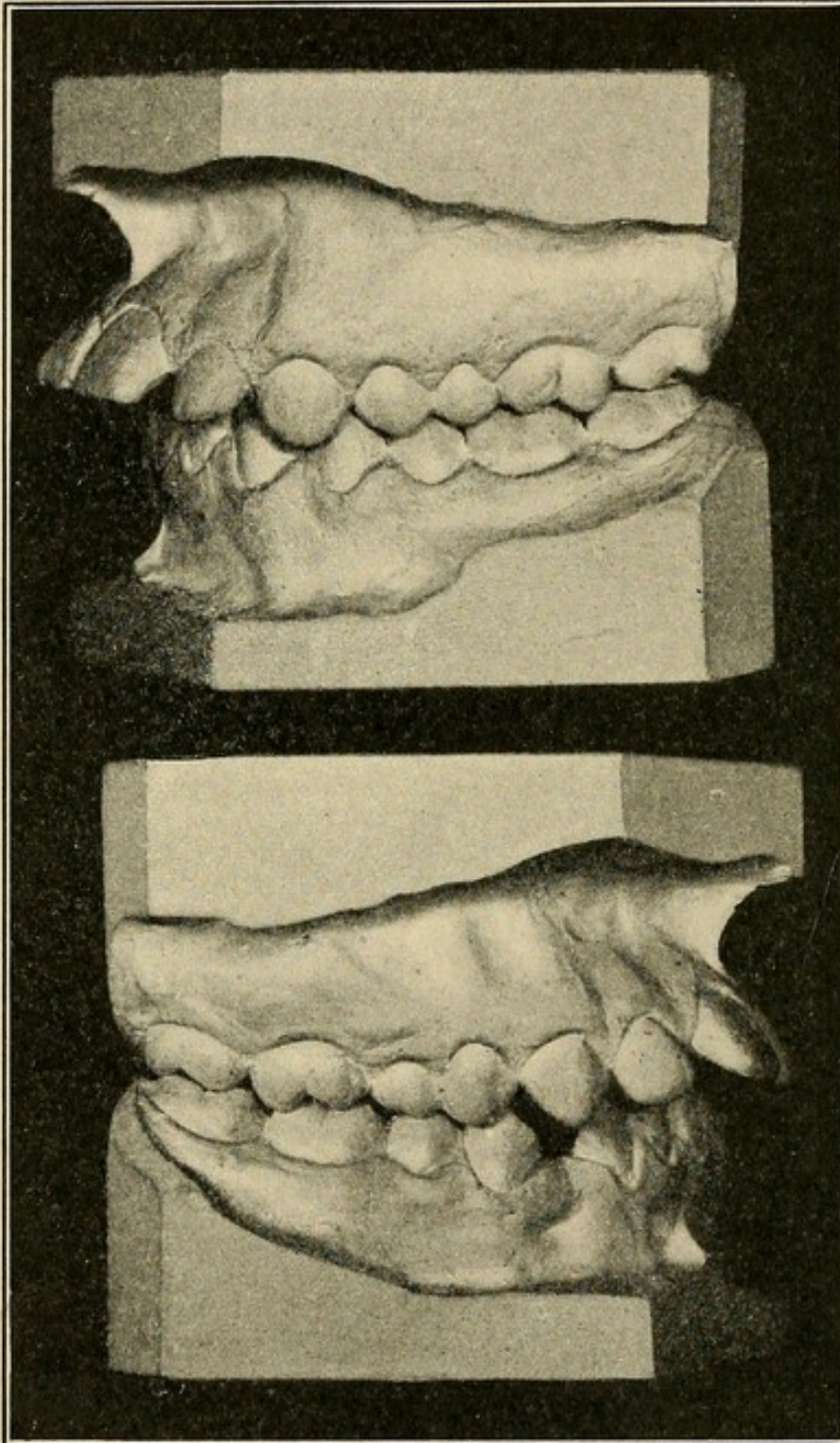
FIG. 39



Typical neutroclusion.

class (Class I, Angle). The author,¹ therefore, suggested that the word *neutroclusion* (Lat. *neutro*, in neither direction;

FIG. 40

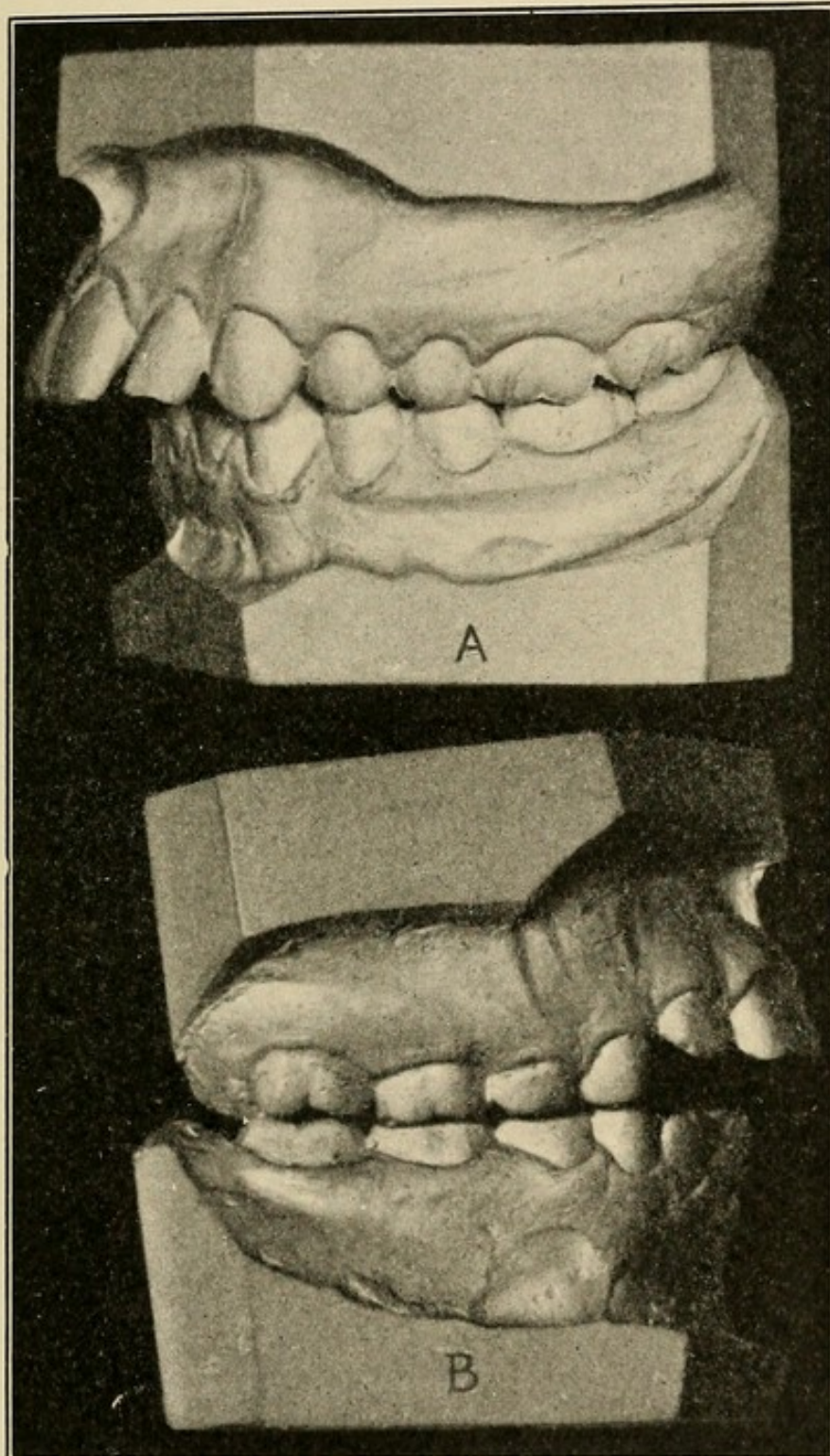


Neutroclusion complicated by extreme labioversion of the upper incisors.

¹ Dental Cosmos, April, 1911.

occlusio, to close) be used for the naming of this group (Fig. 39).

FIG. 41



A, bilateral distoclusion complicated by extreme labioversion of the upper incisors;
B, bilateral distoclusion complicated by infraversion of the upper incisors.

SUMMARY

In confirming the diagnosis of a malocclusion we proceed by excluding all possible conditions in the order of their gravity. Thus dentofacial deformity, which is always serious, is first considered. Owing to the fact that it comprises a large field and involves many grave points, it was deemed best to treat it separately (Chapter VI). Next in importance comes a consideration of malformation of the jaws; then the relation of the arches, or the totality of their alignment and occlusion; then the occlusion and alignment of each tooth, which necessarily implies the form of each arch; and such other anomalies as may be present.

Finally, the naming of these deformities should be governed by the following rules:

1. Jaw deformities so extreme as to be beyond the scope of orthodontic treatment should receive first consideration. Their accompanying malocclusions are merely symptoms.

2. Arch malrelations amenable to orthodontic treatment are next in importance.

3. All cases of malocclusion accompanied by a *neutral* relation of the arches are spoken of as *neutroclusions*.

4. The individual peculiarities of any given case are best expressed by adding such qualifying phrases as "complicated by *labioversion* of the upper incisors," or "*infraversion* of the upper incisors," etc. (Figs. 40 and 41).

CHAPTER VI

FACIAL DEFORMITIES DUE TO MALOCCLUSION

NORMAL VARIATIONS OF THE HEAD FORM

As intimated in Chapter I, a frequent attribute of malocclusion is a marked inharmony of the facial lines. A rational basis for conclusive deductions regarding these deformities is a knowledge of the normal variations of facial form. To a large extent all faces are similarly formed, and their likenesses are patent to everyone; yet there exist in every face certain lineaments of character which stamp it with individuality. Indeed, in probably no other part of the human form is the variability of features so evident.

The normal variations of organic beings have long been a subject for careful study; and since Darwin's day with renewed earnestness. It remained for Blumenbach,¹ Camper,² and Prichard³ to first draw attention to the relationship existing between the teeth and their osseous base and the profile or facial lines of man. This phase of scientific inquiry now forms an important division in anthropology, where, in common with other elaborate systems and classifications, it is termed anthropometry, the science of human measurements. The comparative study of the variable morphological aspects of the skull comprises a subdivision termed craniometry. When the measurements are made upon the

¹ Göttingen, 1775.

² Berlin, 1792.

³ London, 1836.

FIG. 42

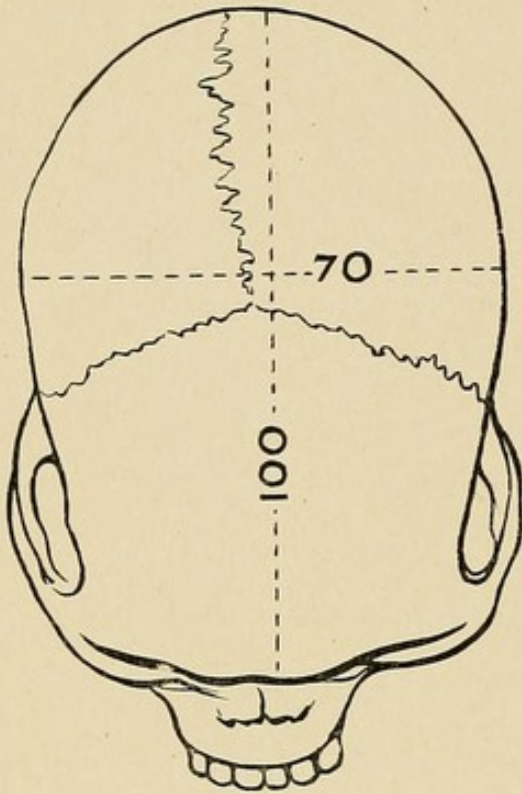


FIG. 43

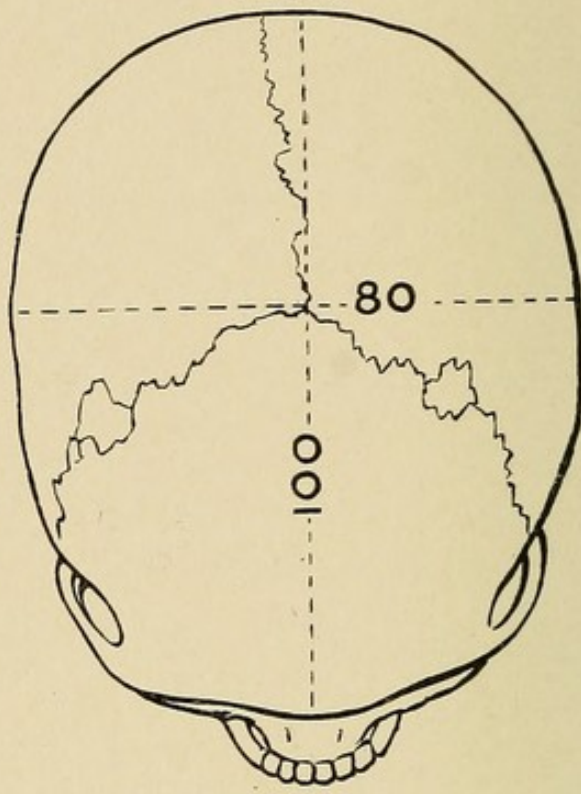
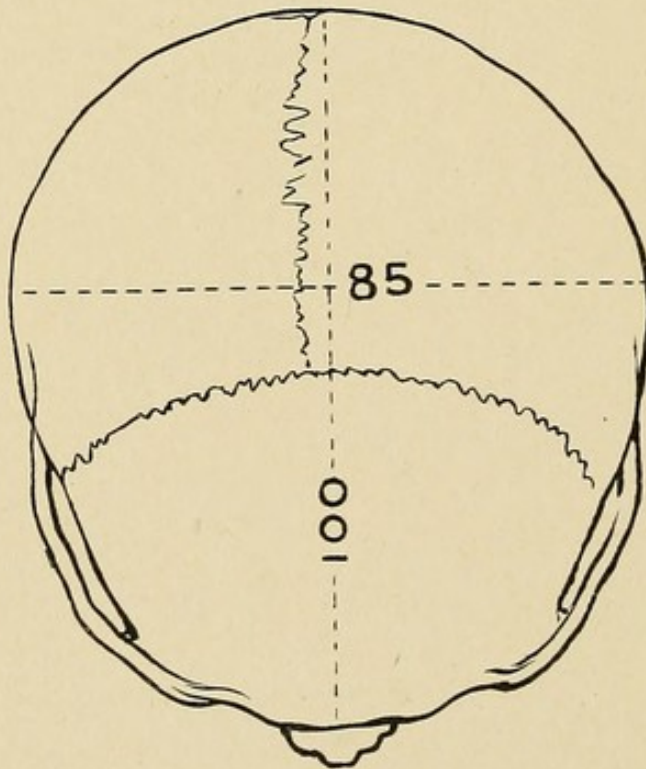


FIG. 44



Top view of skulls: Fig. 42, negro, index 70, dolichocephalic, Fig. 43, European, index 80, mesocephalic; Fig. 44, Samoyed, index 85, brachycephalic. (After Tyler.)

living head it is termed cephalometry. Numerous methods for measuring the features have been devised, though very few have been sufficiently standardized to win universal acceptance. Much of the development of this branch of science we owe to the French anthropologist Broca.

Cephalic Index.—In comparing a number of skulls even the beginner experiences little difficulty in detecting differences of shape. “The form of the head is for all racial purposes best measured by what is technically known as the cephalic index. This is simply the breadth of the head above the ears expressed in percentage of its length from forehead to back. Assuming that this breadth is 100, the width is expressed as a fraction of it. As the head becomes proportionately broader—that is, more fully rounded, viewed from the top down—this cephalic index increases. When it rises above 80, the head is called *brachycephalic*; when it falls below 75, the term *dolichocephalic* is applied to it. Indexes between 75 and 80 are characterized as *mesocephalic*.”¹ Figs. 42, 43, and 44 are diagrammatic of these variations of form.

Other Systems of Measurement.—Among the other systems proposed for the determination of differences of shape, mention may be made of Camper’s method for the measurement of the facial angle (Figs. 45 and 46), Flower’s gnathic index, and Turner’s dental index.² By means of the gnathic index, which is used to determine the amount of projection of the lower part of the face, the races of mankind may be divided into three groups, as follows: *Orthognathous*, when below 98; *mesognathous*, when 98.1 to 103; *prognathous*,

¹ Ripley, *The Races of Europe*, New York, 1899.

² Tomes, *Dental Anatomy*, 5th ed., p. 517.

FIG. 45

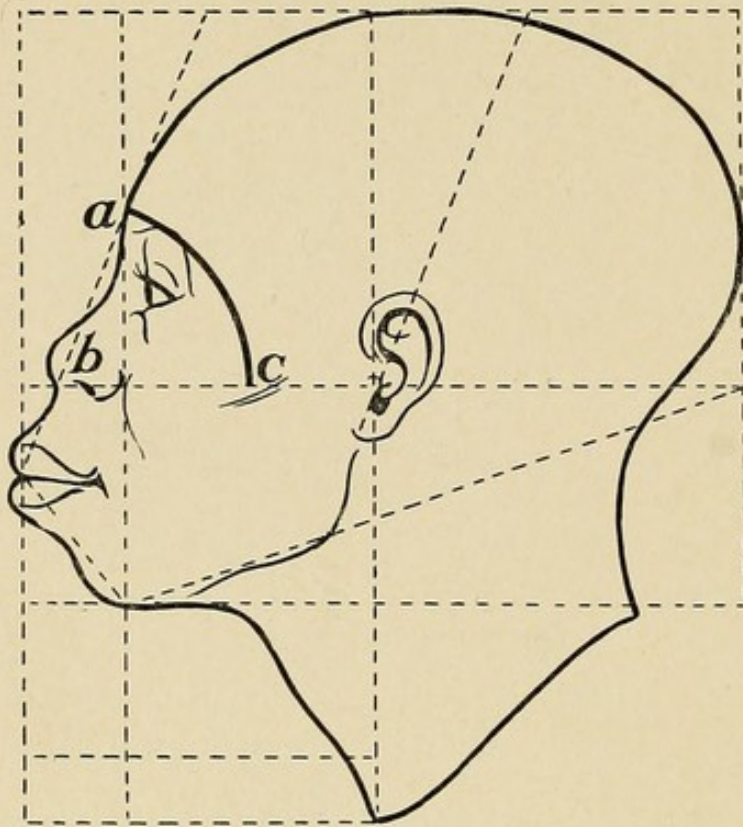
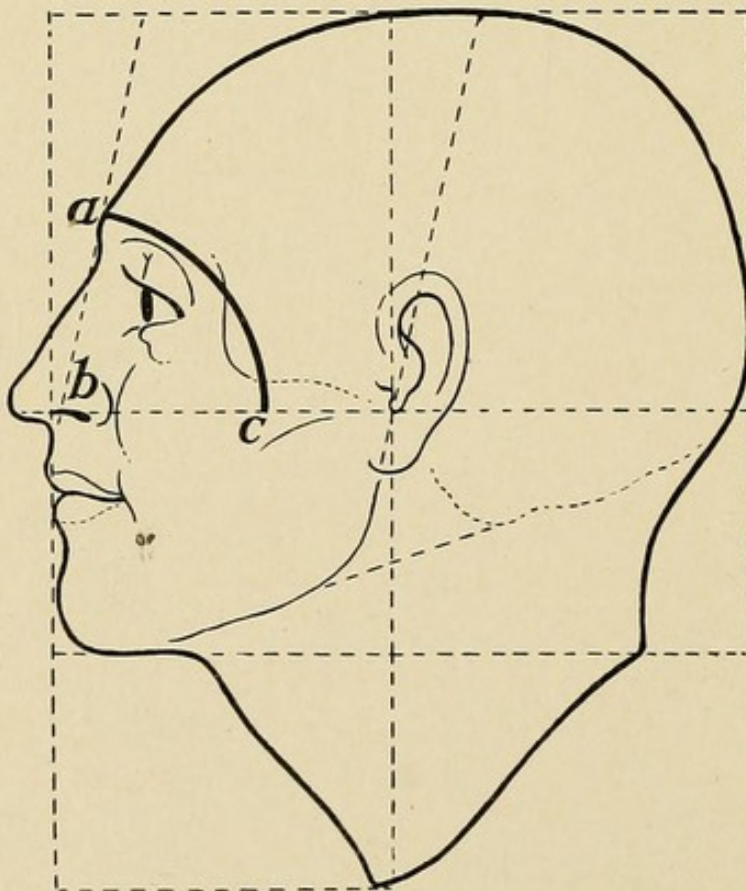


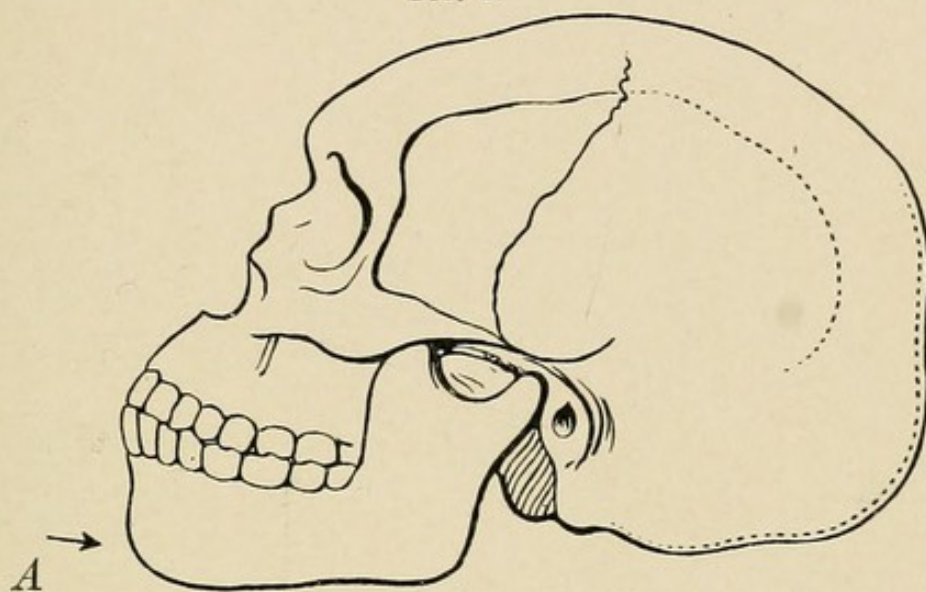
FIG. 46



Camper's measurements of the facial angle.

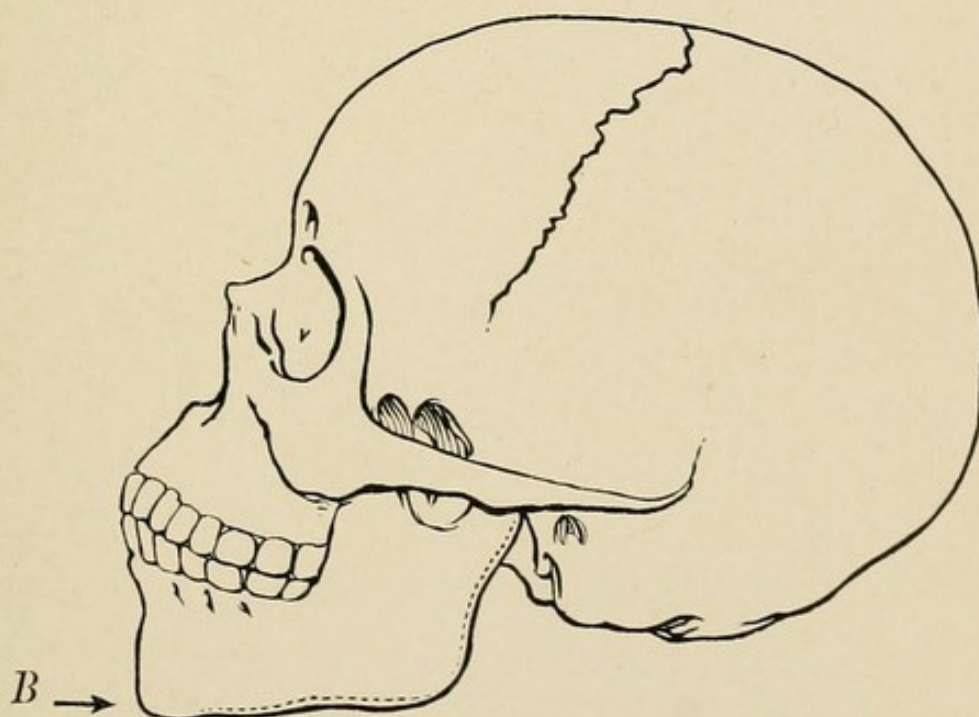
when above 103. With the dental index we determine "the relation of the size of the teeth to that of the skull," and get the three groups termed *microdont*, index 42; *mesodont*, index 43; and *megadont*, index 44 and above.

FIG. 47



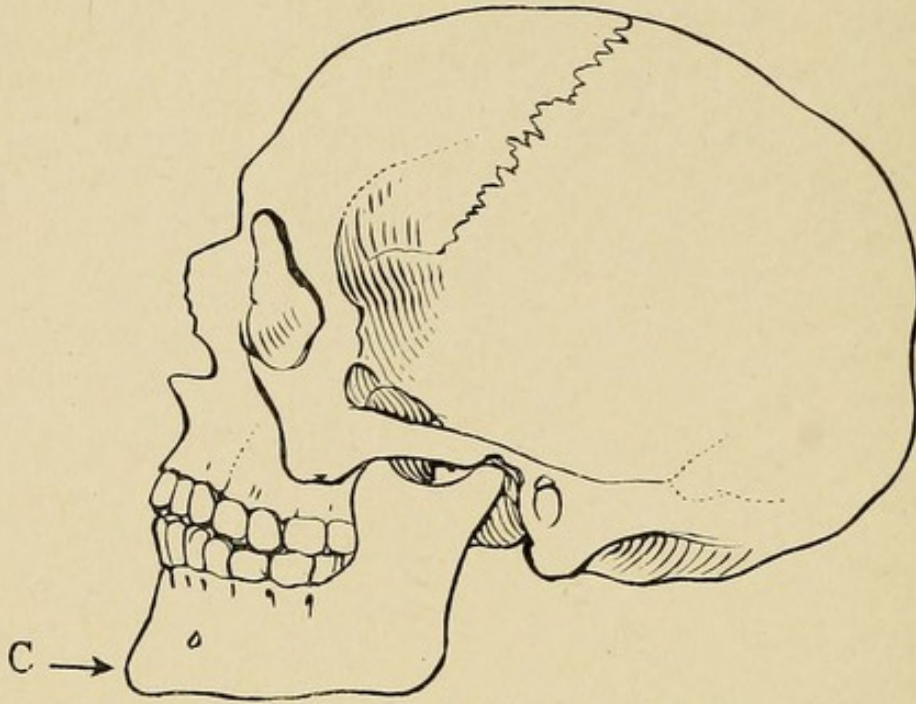
Normal variation of the symphyseal angle.

FIG. 48



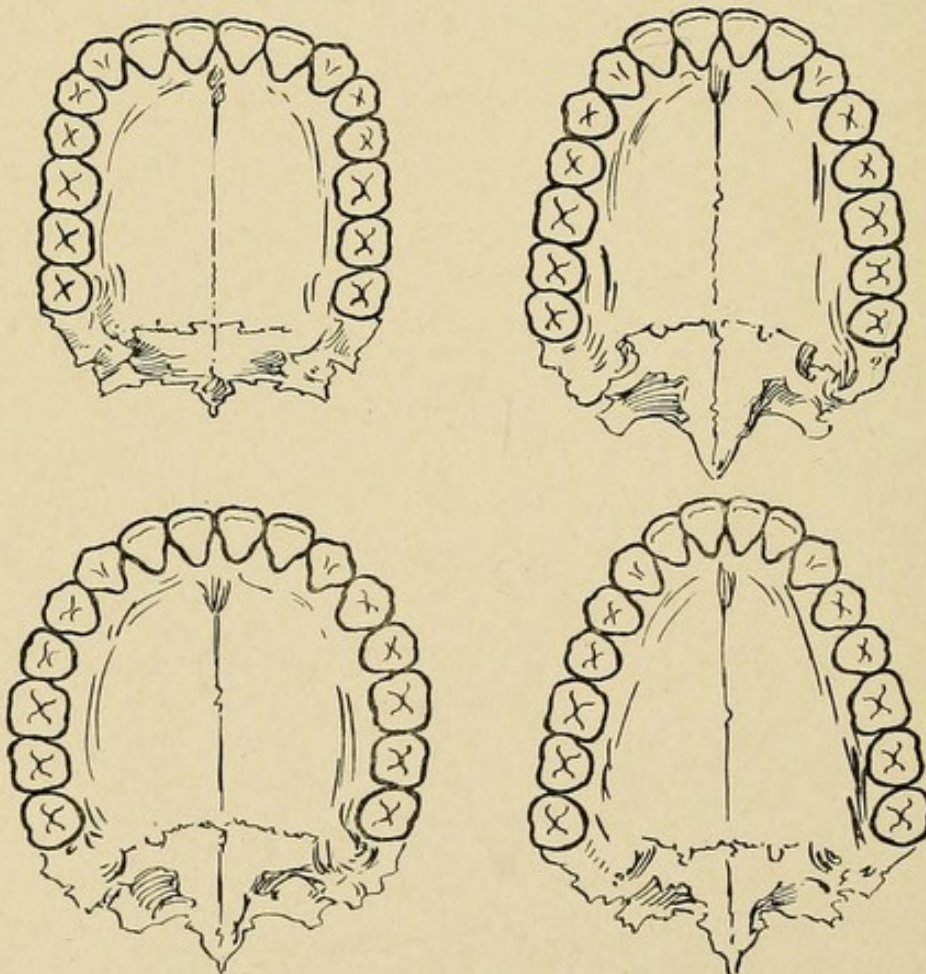
Normal variation of the symphyseal angle.

FIG. 49



Normal variation of the symphyseal angle.

FIG. 50



Normal variations of alignment of the upper teeth. (After Broca.)

FIG 51

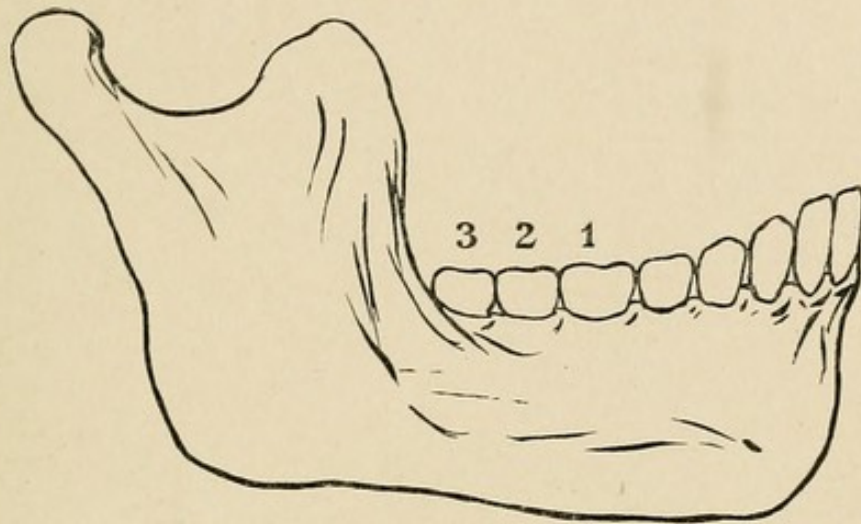


FIG. 52

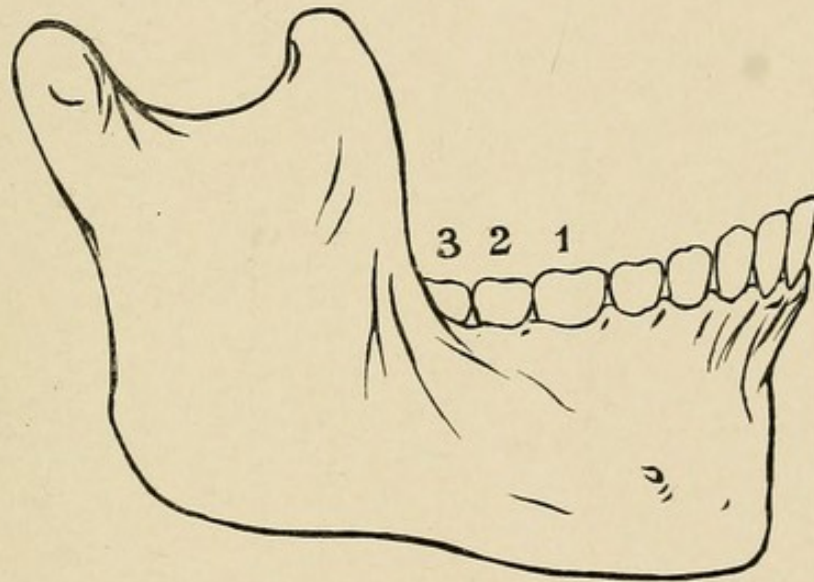
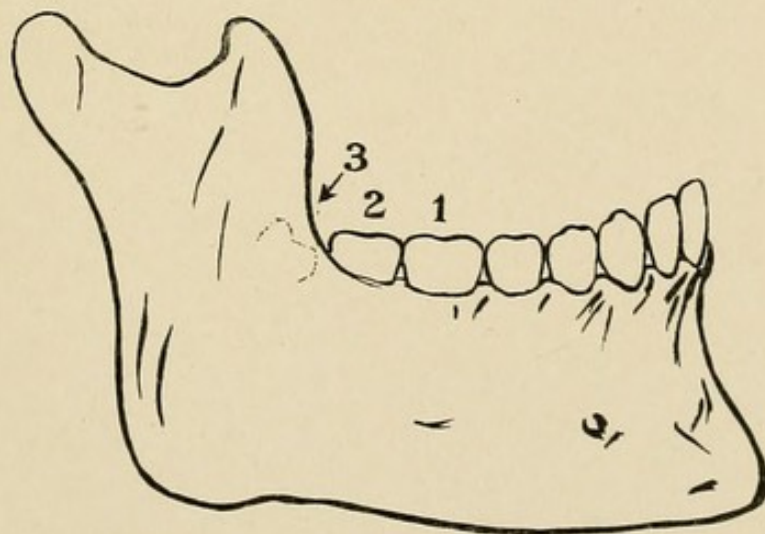


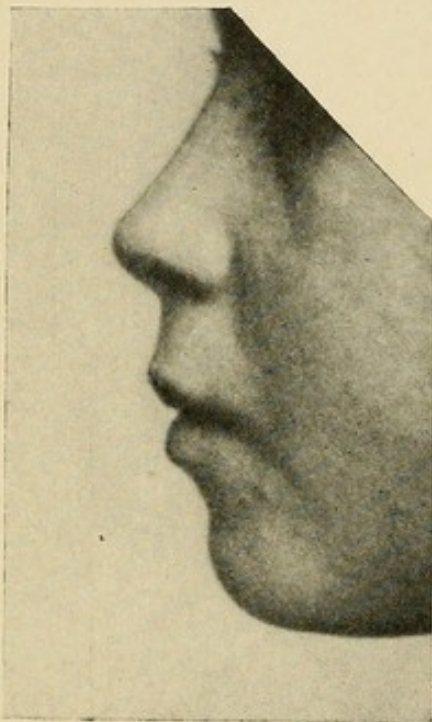
FIG. 53



Showing variations in the relative position of the lower third molar.

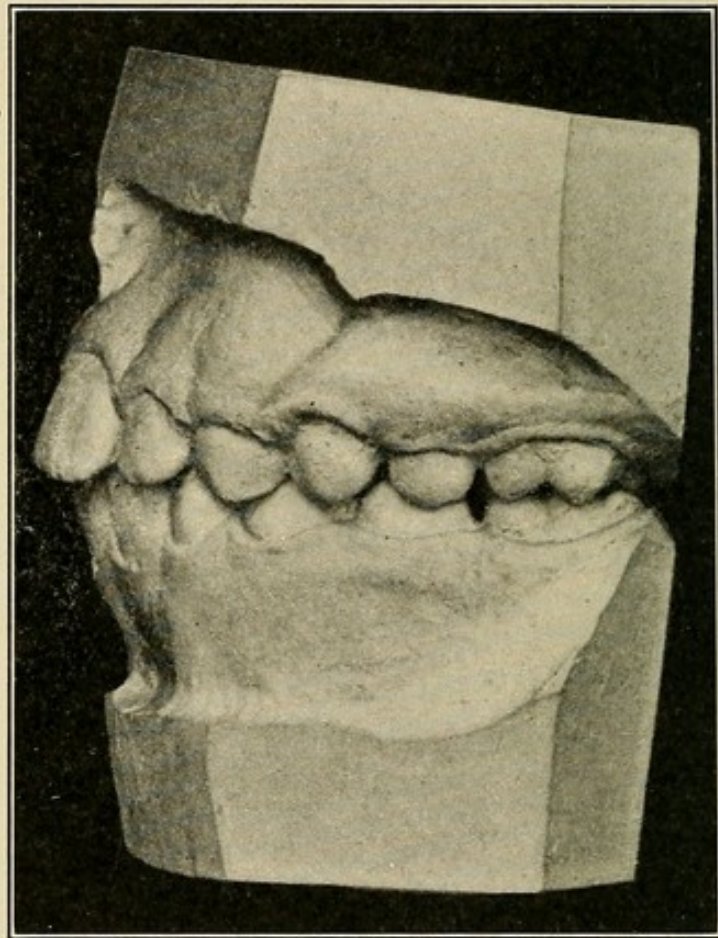
Still other differences of interest are the anthropological varieties of the palate, termed by Turner *dolichuronic*, *mesuronic*, and *brachyuronic*; and the variations due to the development of the muscles of mastication. The latter are readily recognized in the changeable position of the

FIG. 54



Normal variation of the profile taken from life.

FIG. 55



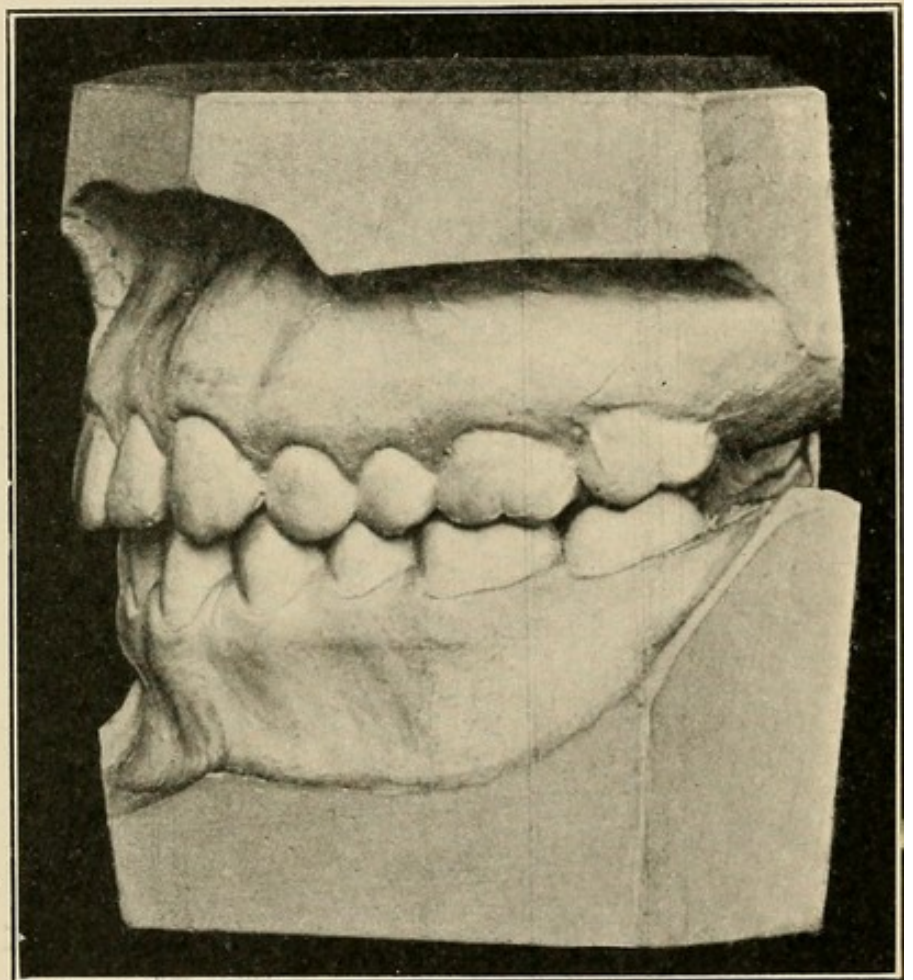
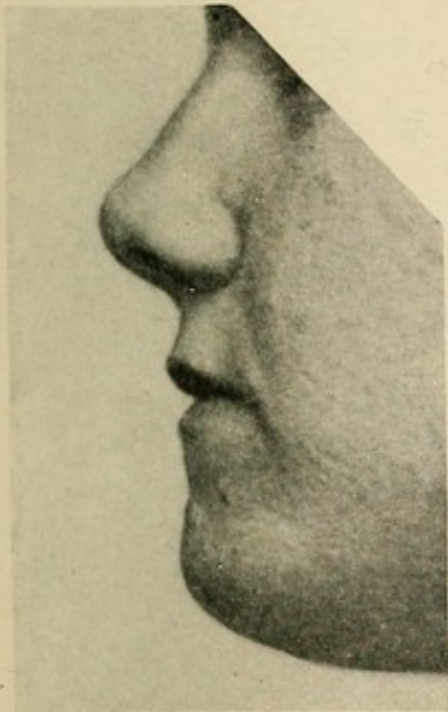
Dental model of the case shown in Fig. 54.

temporal ridge; the differences in width of the ascending rami of Europeans when compared with the aborigines; the varying degrees of parallelism of the borders of the rami; and the outward and inward everted angles of the lower jaw, which affect the width of the lower part of the face. Other and even more important facts of interest are the normal

variations of the symphysean angle (Figs. 47, 48, and 49), and the ethnological deviations observed by Broca in the forms of the dental arches. Of the latter there are four varieties, which he designated *parabolic*, *hyperbolic*, *elliptical*, and *U-shaped* (Fig. 50).

FIG. 56

FIG. 57



Normal variation of the profile taken from life.

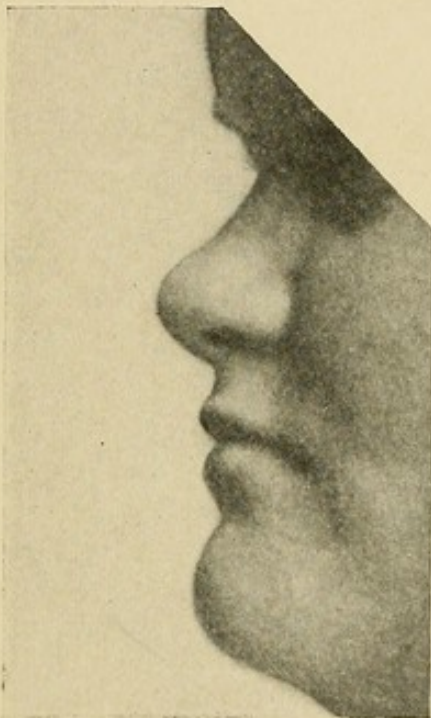
Dental model of the case shown in Fig. 56.

A still further evidence of variability is to be found in the relative position of the lower third molars. Thus in the aborigines it usually is in front of the anterior border of the coronoid process, while in the Europeans it may be partly, or entirely, hidden (Figs. 51, 52, and 53). The teeth and

bones, as well as the accessory sinuses of the nose, differ also in their size and form.

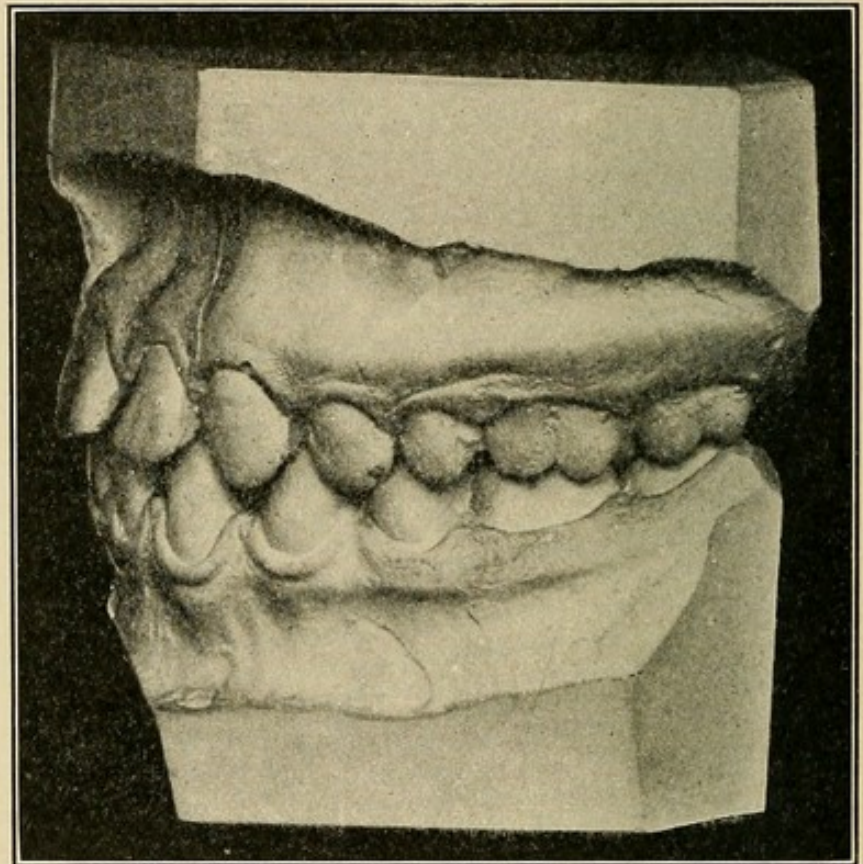
Summary.—In his measurements of the facial lines, Camper discovered that in an Australian black they approached an angle of 85 degrees; in a European, 95 degrees; and in the beautiful forms of Greek art, 100 degrees or more. This

FIG. 58



Normal variation of the profile taken from life.

FIG. 59

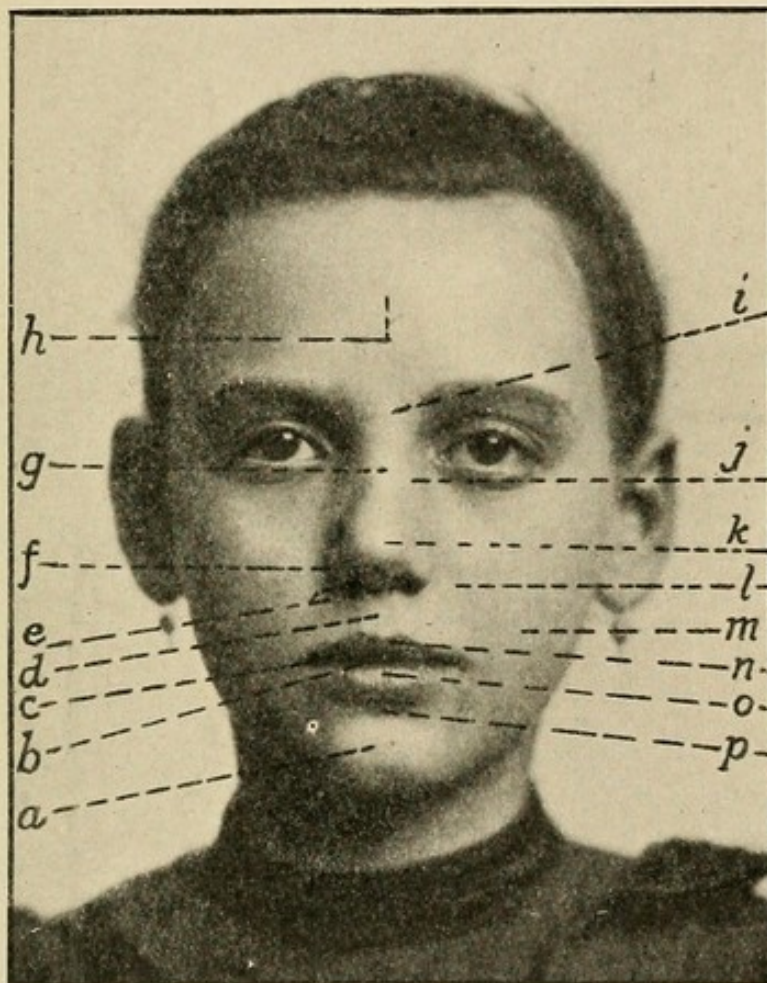


Dental model of the case shown in Fig. 58.

variation is largely due to the backward sloping of the symphysis, which in the lower races approaches the chinless form of the anthropoid ape. The degree of prognathism, or position of the denture in its relation to the skull as a whole, must also be taken into consideration. These osseous variations affect all skulls in varying degree, and in Figs. 54, 56,

and 58 we see three photographs which, though unlike in general contour, are normal from a purely orthodontic standpoint. The dental models of these three profiles are shown in Figs. 55, 57, and 59, and it will be seen that in each instance the teeth are in approximately normal occlusion.

FIG. 60

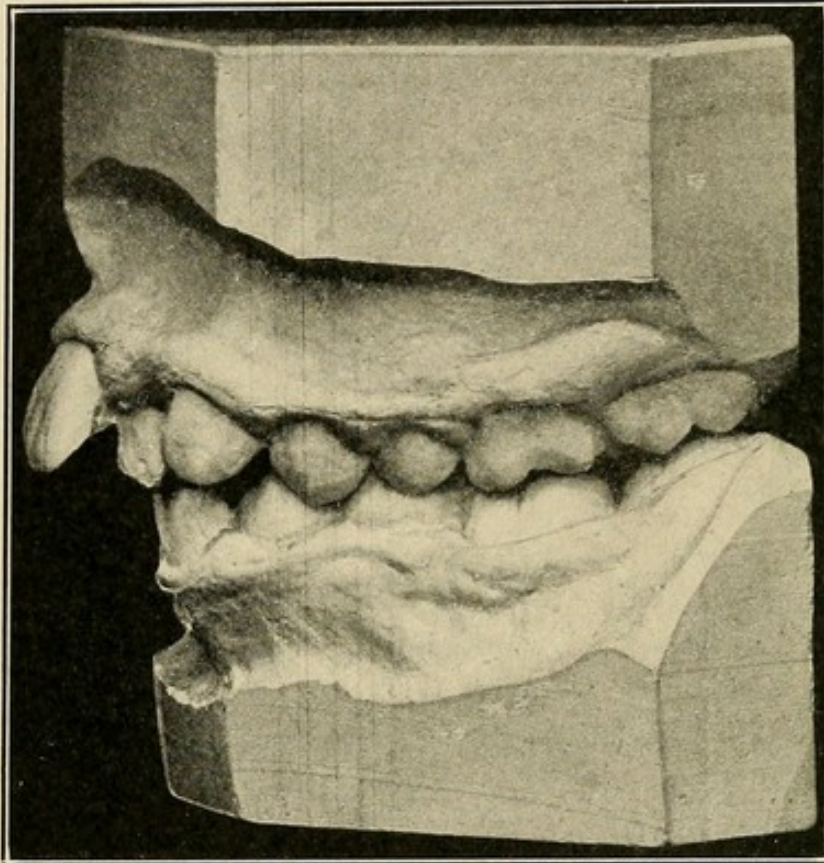


Showing parts of the face of special interest to the orthodontist: *a*, chin (*mentum*); *b*, aperture (*rima oris*); *c*, angle (*angulus oris*); *d*, philtrum; *e*, nostrils (*nares*); *f*, ala (*ala nasi*); *g*, dorsum (*dorsum nasi*); *h*, frontal eminence; *i*, root (*radix nasi*); *j*, base (*basis nasi*); *k*, tip (*apex nasi*); *l*, nasolabial sulcus; *m*, cheek (*bucca*); *n*, upper lip; *o*, lower lip; *p*, mentolabial sulcus.

But prior to a consideration of the effects of malocclusion upon the facial lines the student should study Fig. 60, which represents the face of a young girl, with the more important parts marked in the area which is so frequently

affected by orthodontic treatment. Some of the normal variations in the arrangement of these parts have been recognized by orthodontists.

FIG. 61



Neutroclusion complicated by labioversion of the upper and linguoversion of the lower incisors. (Compare with Fig. 62.)

ABNORMAL VARIATIONS OF THE PROFILE

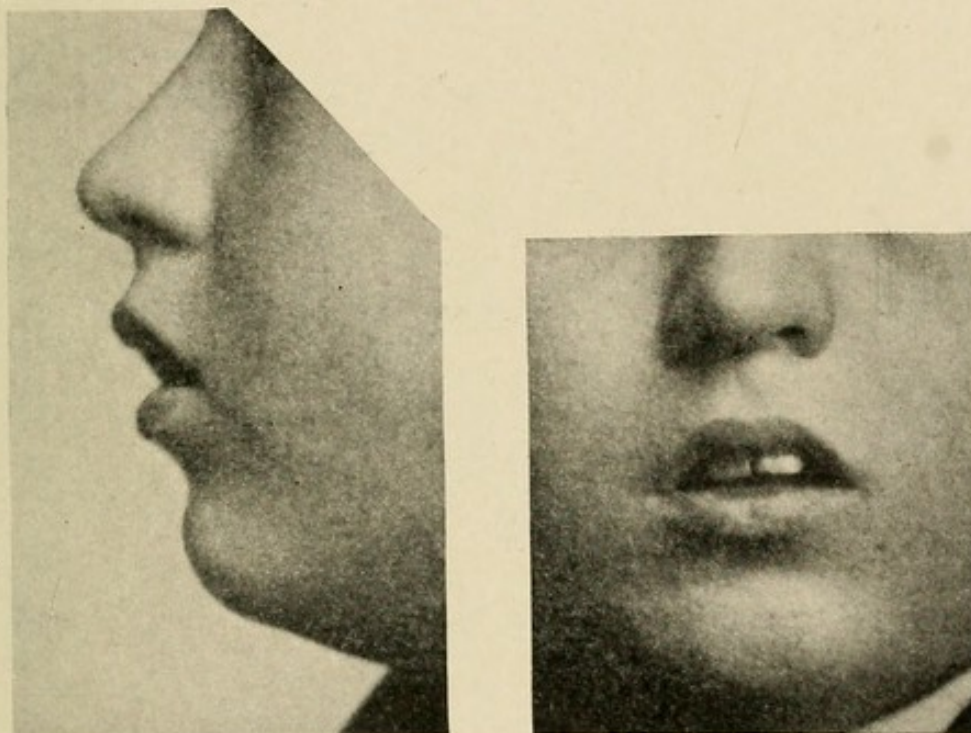
The various anomalies of dentition which may combine in a malocclusion were outlined in Chapter V, and it now becomes necessary to describe in detail the deformities of the face resulting therefrom.

In Fig. 61 a photograph is shown of a dental model exhibiting a pronounced labioversion of the upper incisors. Obviously, such deformity must always affect the contour

of the soft and yielding tissues of the lips, particularly the upper. It will be observed that the occlusion of the first molars is normal, there being no arch malrelation, and it may, therefore, be classified as a case of neutroclusion. The consequent distortion of the facial lines is shown in Fig. 62.

A similar though frequently more]pronounced type of deformity is shown in Fig. 63. This must not be confused

FIG. 62



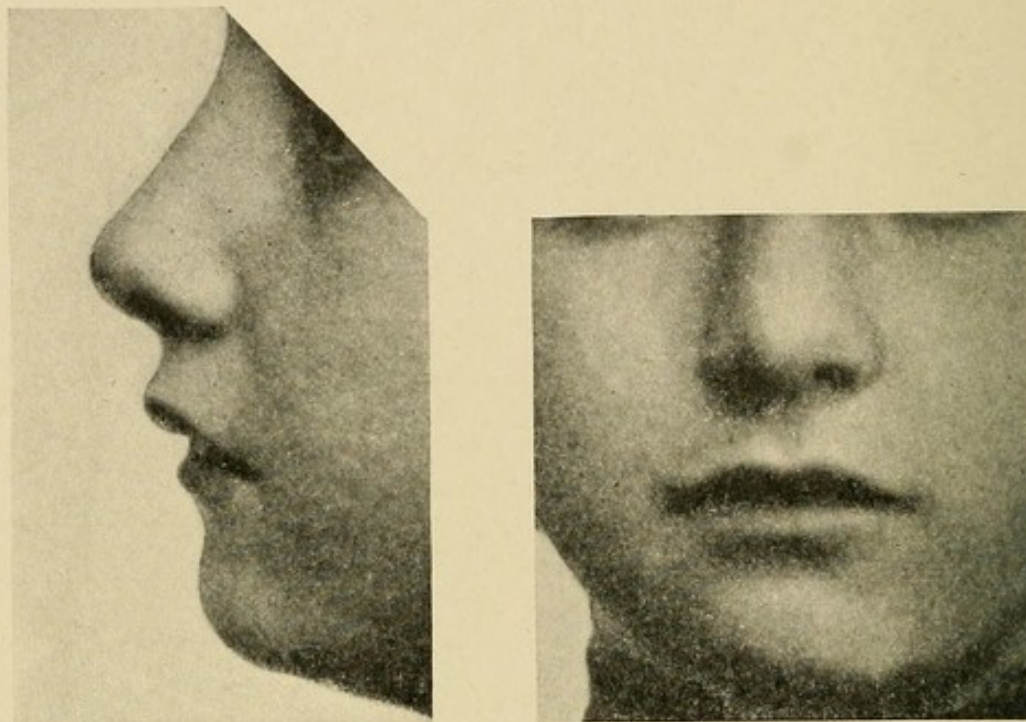
Facial deformity resulting from the malocclusion shown in Fig. 61.

with the former, however, for upon closer examination it will be seen that though we again have a labioversion of the upper incisors, there exists in addition a bilateral distocclusion of the lower (Fig. 64). Any attempt at correction of the facial deformity and of the labioversion of the upper incisors would prove futile if it did not take into consideration the distal malrelation of the lower arch.

Further complications in these types, especially in patients

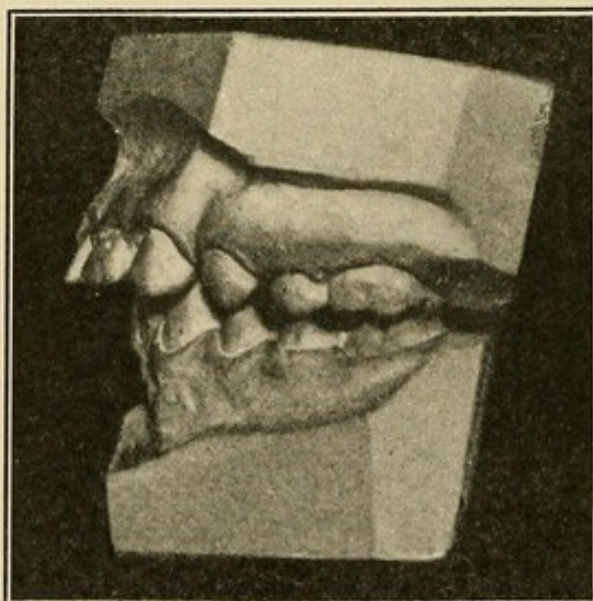
beyond the developmental period, are an abnormal growth of the lips, an arrest of development in the alveolar processes, and malformations of the jaws. On the other hand, if

FIG. 63



Facial deformity resulting from the malocclusion shown in Fig. 64.

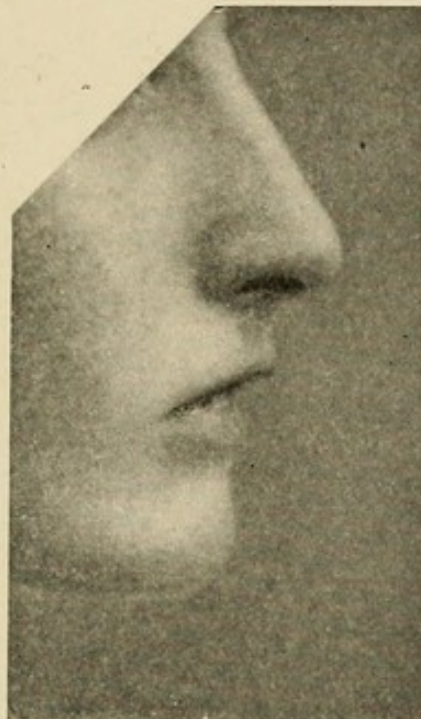FIG. 64



Bilateral distoclusion complicated by labioversion of the upper incisors.
(Compare with Fig. 63.)

correction of the malocclusion is instituted early, a restoration of normal function and subsequent growth of the bony structures will take care of the accompanying inequalities of facial contour. This rarely, if ever, follows when treatment is too long postponed. In Fig. 65 a profile is shown of a girl, aged sixteen years, with such a deformity completely established. Suffering from mouth breathing for a number of years, the upper lip, by continual stretching, was arrested

FIG. 65

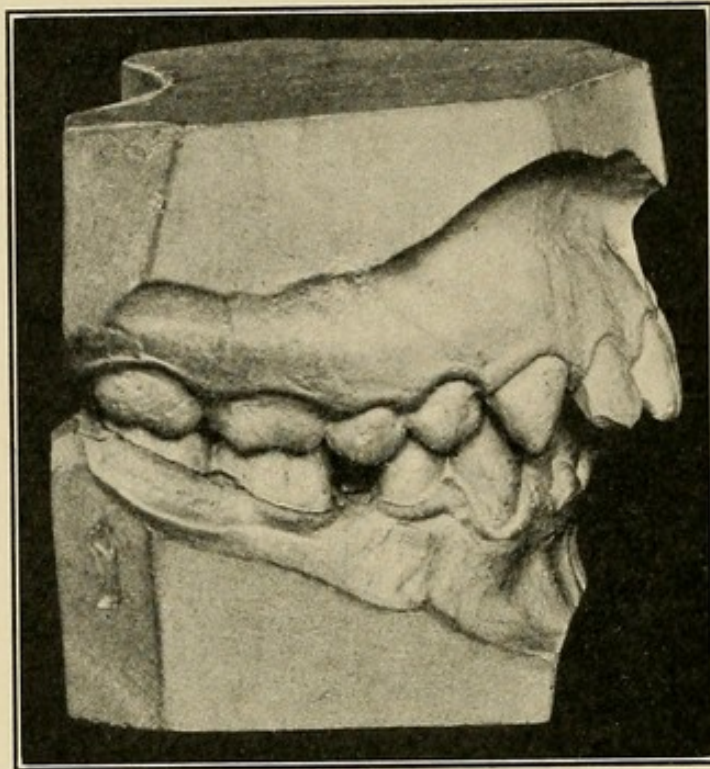


Permanent deformity of the upper lip resulting from postponement of treatment of the malocclusion shown in Fig. 66. (Compare Fig. 25.)

in its development, and now remains too short and too thin. The lower, on the other hand, found lodgement in the space between the upper and lower incisors, and thus, through abnormal function, overdeveloped (Fig. 66).

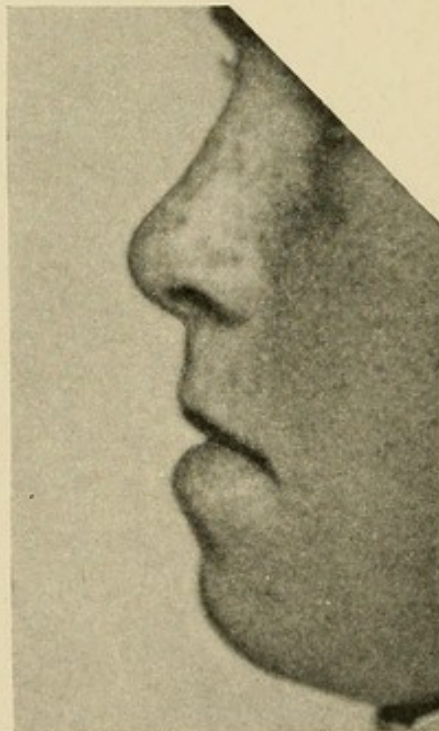
The reverse of this type of deformity is found in neutroclussions complicated by a linguoversion of the upper incisors; in mesioclussions; in arrested development of the maxilla;

FIG. 66



Models of the case shown in Fig. 65.

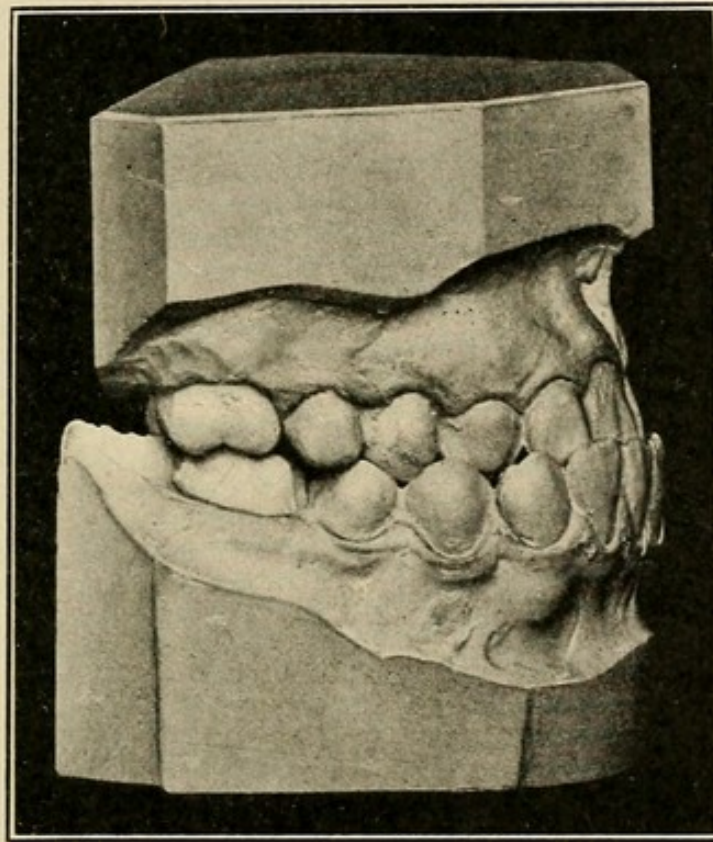
FIG. 67



Facial deformity accompanying the malocclusion shown in Fig. 68.

and in cases of macrognathism of the mandible. Figs. 67 and 68 show the casts and photographs of a lad, aged thirteen years, where the lack of prominence of the upper lip is very apparent. An extreme form of micrognathism of the maxilla, with distoclusion of the upper arch and infraversion of the anterior teeth, and the consequent facial deformity,

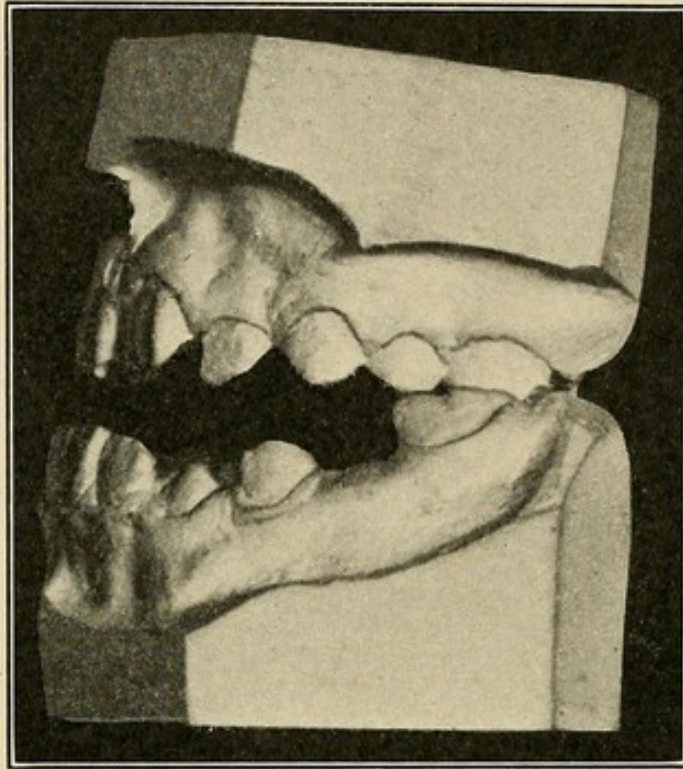
FIG. 68



Unilateral mesioclusion, resulting in deformity of the profile shown in Fig. 67.

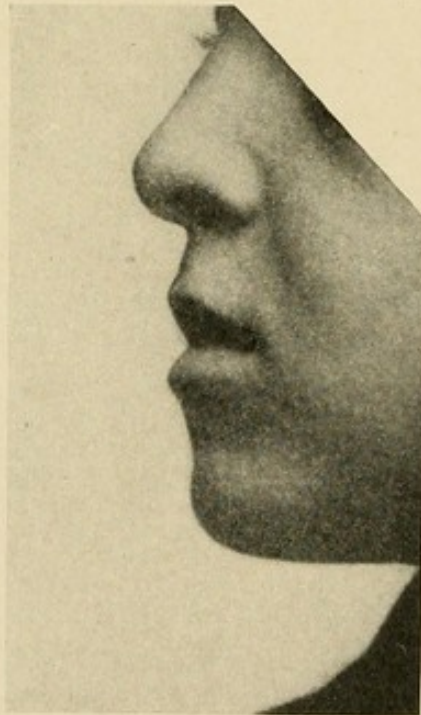
are shown in Figs. 69 and 70. Though similar to the former in outward appearance, the latter must not be considered as belonging to the same group, or to the next and even more serious type (Figs. 34 and 35). The latter is a case of mandibular macrognathism, of which the accompanying mesioclusion of the lower arch and mesioversion of the lower teeth are but symptoms. To overlook the mandibular

FIG. 69



Maxillary micrognathism.

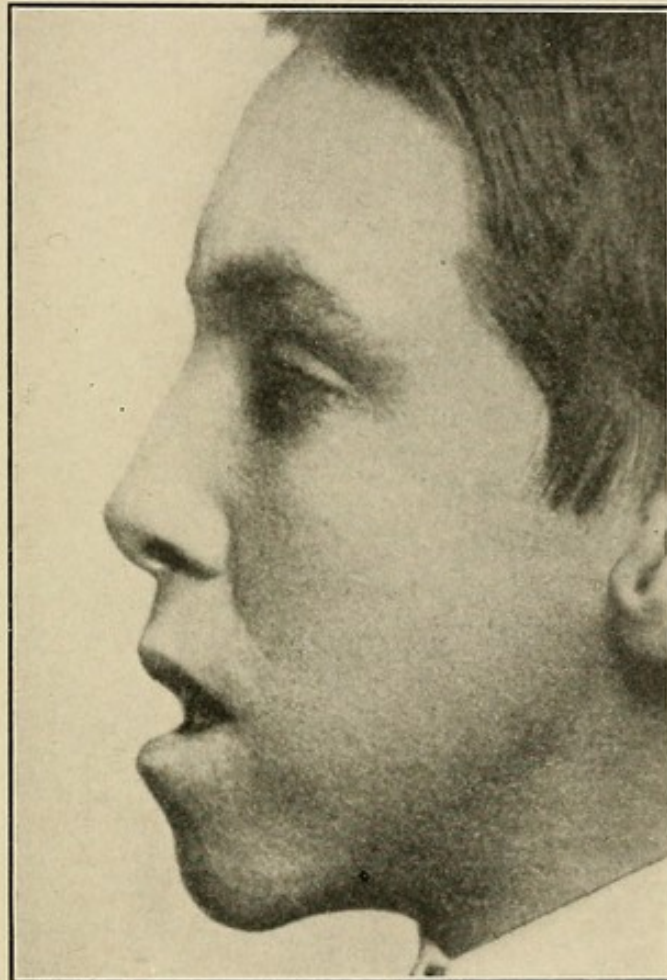
FIG. 70



Profile of case shown in Fig. 69.

deformity in such a case is to utterly fail in the diagnosis. Indeed, all dentofacial deformities, of whatever type, are but symptoms of the underlying, and therefore more fundamental, dental anomalies.

FIG. 71



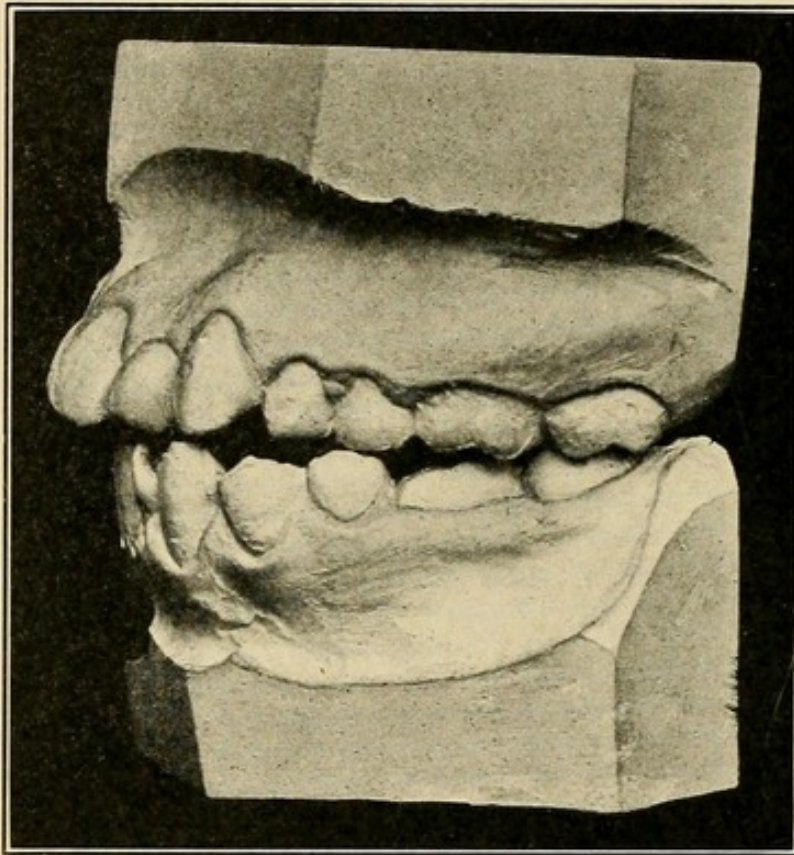
Deformity due to curvature of the mandible.

The so-called "open bite" (Fig. 41, *B*) is a deformity commonly associated with nasal obstruction, and may complicate either neutroclusion, mesioclusion, or distoclusion. Very rarely it may be due to a curvature of the body of the mandible (Fig. 71). Attention must also be directed to the fact that in the unilateral forms of distoclusion

and mesiocclusion the same facial deformities may exist as in the bilateral types, though they are usually less severe.

Another type of deformity is that associated with supra-version of the incisors, which may be symptomatic of neutroclusion or of distocclusion; and in all of these the outer contour of the facial muscles involved, particularly of the lower lip,

FIG. 72



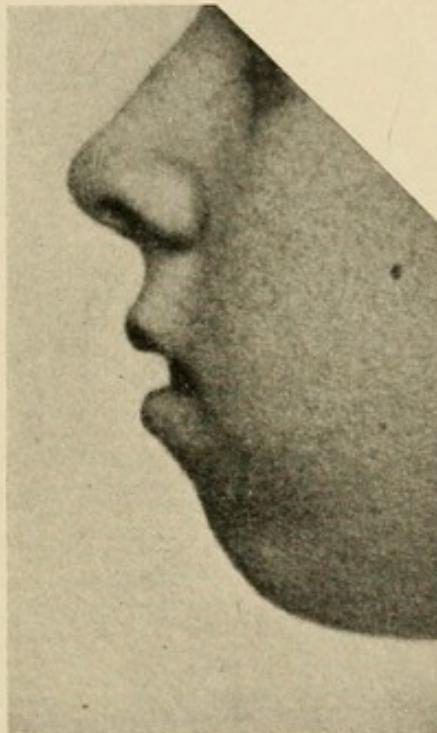
Neutroclusion accompanied by the facial deformity shown in Fig. 73.

appear so crowded that it suggests overdevelopment. But this is usually more apparent than real, because after the correction of the malocclusion they readily assume a normal form. The author is convinced, moreover, that the really serious condition met with in many of these cases is a lack of perpendicular development in the region of the symphysis. In other words, the distance from the gingival line of a lower

central incisor to the mental eminence of the chin is too short. This condition is the source of much annoyance to the operator during treatment, and extremely difficult to permanently correct.

The normal variations of the symphysian angle have already been referred to. Figs. 72 and 73 show a case where, besides exhibiting considerable malocclusion of a type

FIG. 73



Showing extreme deficiency of the symphysian angle.

ordinarily demanding a liberal expansion of both the upper and lower arches, a compromise in treatment would seem to be indicated. The receding chin, in this instance, is a fundamental osseous condition which must be reckoned with, and which no amount of tooth movement at this late period (the patient being sixteen) would ever correct.

ORTHODONTIC CONCEPTIONS AND IDEALS

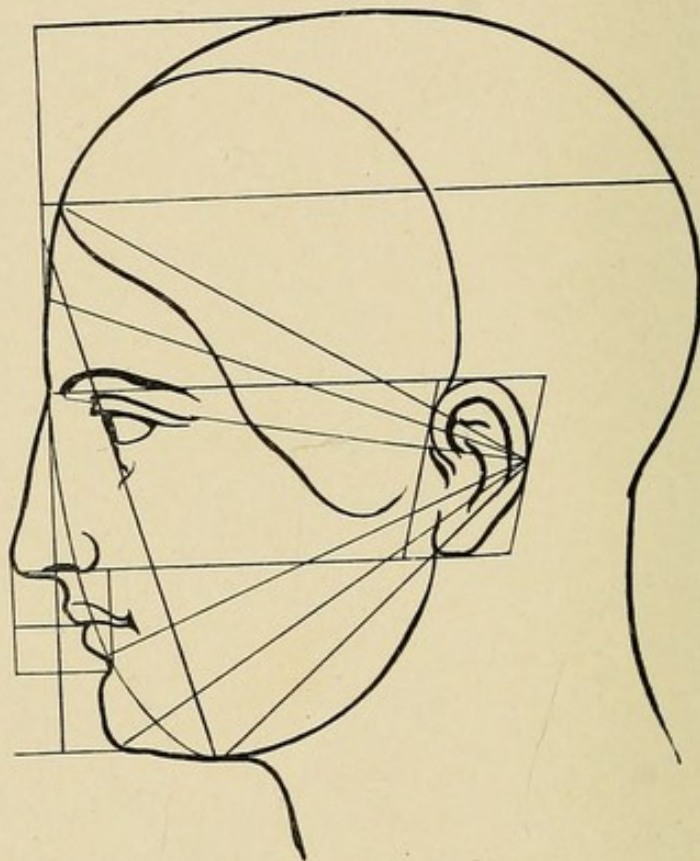
The mere fact that orthodontics embraces methods for the correction of deformities of the face predicates the desirability of a standard, or criterion of judgment.

FIG. 74



Classical profile of Apollo.
(After Farrar.)

FIG. 75



Measurements employed by artists.
(After Wiegall.)

“The duties of the orthodontist force upon him great responsibilities, and there is nothing in which the student of orthodontia should be more keenly interested nor better informed than in the study of the artistic proportions and relations of the features of the human face; for each of his efforts, whether he realizes it or not, makes for beauty or ugliness, for harmony or inharmony, for perfection or

deformity."¹ Furthermore, besides forming an important phase of the difficult art of diagnosis, it involves us in "the most remarkable problem of esthetics," viz., that of *beauty of form*. Ignorance of these requirements has led numerous operators into the unenviable position of having permanently marred the beauty of an otherwise handsome face.

In the works of Kingsley, Farrar, Jackson, etc., the need for some standard as an aid in diagnosis was plainly felt. The classical profile of the Grecian mythological god Apollo (Fig. 74) and the lines of division employed by artists in the study of esthetics (Fig. 75) have been widely used for this purpose. But not until Case² and Angle³ developed their comprehensive systems did we approach methods of tolerable accuracy. Unfortunately, a review of the works of these two authors reveals the fact that their conclusions are diametrically opposed to each other.

Case's Ideal.—A large experience and much careful observation have led Professor Case to formulate the following principles:

"The portion of the human face that it is possible to change with dental regulating apparatus may be said to lie between two diverging lines which arise at a point below the ridge of the nose and curve downward to enclose the alæ and depressions on either side; thence laterally to encircle a portion of the cheek, and downward to enclose the entire chin (Fig. 76). This area may be termed the *changeable area* in contradistinction to the more stable features, or *unchangeable area*. For convenience of ready reference, the features in that portion of the changeable area which are

¹ Angle, Amer. Text-book of Oper. Dentistry, 3d ed., p. 694.

² Dental Orthopedia, 1908.

³ Malocclusion of the Teeth, 7th ed., 1907.

bounded laterally by the nasolabial lines may be divided into four segments, as follows:

“Segment 1. The end of the nose and the upper portion of the upper lip, including the nasolabial depressions.

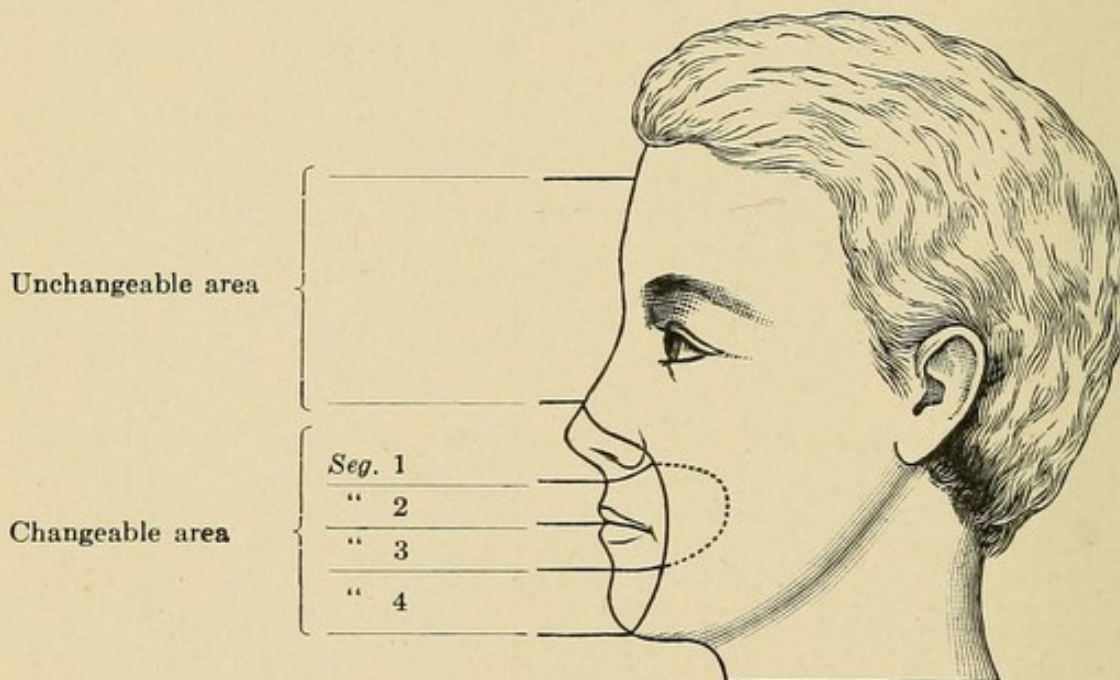
“Segment 2. The lower portion of the upper lip.

“Segment 3. The lower lip.

“Segment 4. The chin.

“These four segments are changeable in their relations to each other, and also in their individual relation to features in the unchangeable area.”

FIG. 76

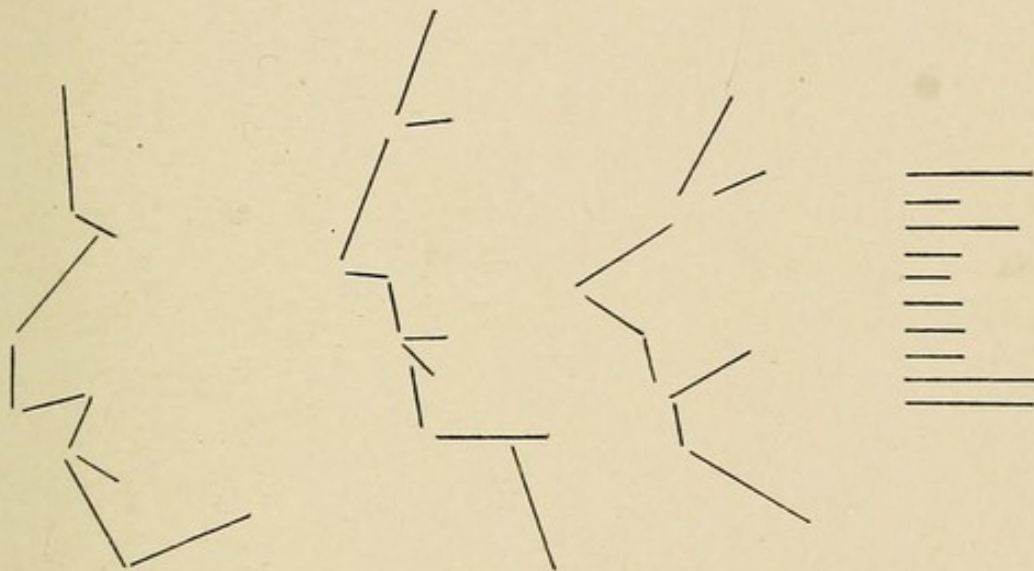


Method of measurement. (After Case.)

Dr. Case further maintains that the relations of these areas to each other must be determined prior to treatment by the trained eye of the operator, and the deviations, if any, noted. Following this the treatment must be planned so as to produce the best possible exterior effects or contour of these parts. In other words, the operator's ideal of facial

form is the standard or criterion he would have accepted. It is presumed, of course, that this be a cultivated ideal, carrying with it that fine discretionary ability to say when teeth shall be extracted, or moved bodily, for the improvement of facial balance. According to this author, the full complement of teeth is not necessary in the treatment of certain types of malocclusion; in some instances extraction of one or more teeth is positively indicated.

FIG. 77



Shows the unrelatedness of beauty of form and beauty of elements.
(After Santayana.)

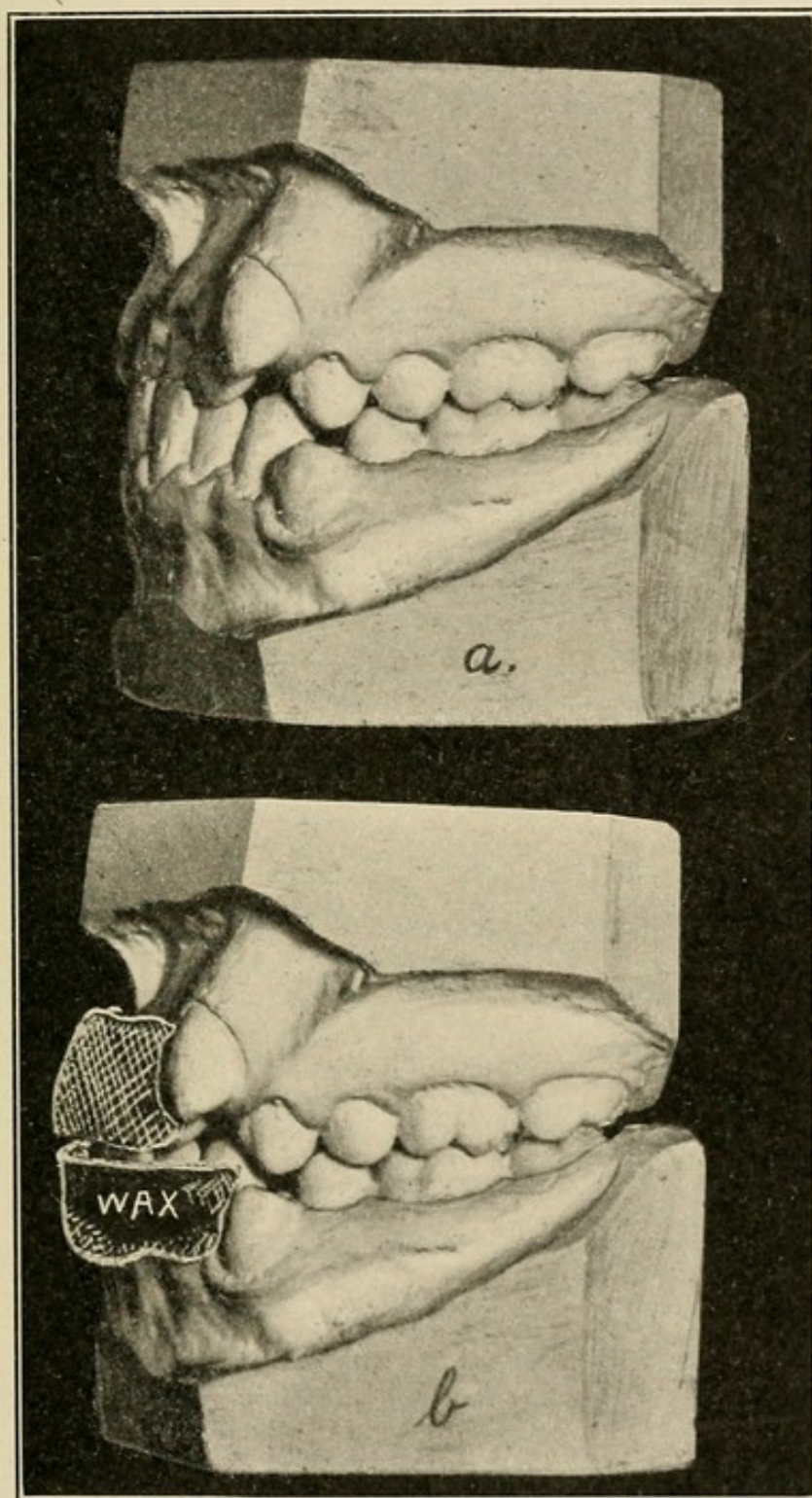
Theoretically, this is perhaps true, because "Beauty of form cannot be reduced to beauty of elements. All marble houses are not equally beautiful." Similarly, all profiles, even though they are moulded over an ideal occlusion of all the permanent teeth, are not equally beautiful. "All ideal forms have an emotional tinge. Beauty of form is due to expression, and all expression, ultimately, is something else than beauty—some practical or moral good." For example, "take the ten meaningless short lines in Fig. 77,

and arrange them in the given ways intended to represent the human face; there appear at once notable different esthetic values. Two of the forms are differently grotesque, and one approximately beautiful. These effects are due to the *expression* of the lines; not only because they make one think of fair or ugly faces, but because, it may be said, these faces would in reality be fair or ugly according to their expression, according to the vital and moral associations of the different types.”¹

Angle's Ideal.—But according to Angle, “We must be able to detect whether the features—that is, the forehead, the nose, the chin, the lips—of each individual face balance, harmonize, or whether they are out of balance, out of harmony, and especially whether the mouth is in harmonious relations with the other features, and if it is not, what is necessary to place it in balance. The faculty of determining the proper balance of the features is a difficult one to attain.” Quoting Professor Wuerpel, he further says: “Only one in two or three hundred art students ever succeed in mastering it, and these only after much observation and practice in sketching and modelling of faces. Unpromising as this seems, it is doubtless correct; yet we have a rule for determining the best balance of the features, or, at least, the best balance of the mouth with the rest of the features, that artists probably know nothing of, and one that for the orthodontist is more unvarying and more reliable than even the judgment of the favored few—a rule so invariable and with so few exceptions that we may consider it a law, and if it be not applicable in all cases, the exceptions will be so very rare that they are hardly worth considering. It is,

¹ Santayana, *The Sense of Beauty*.

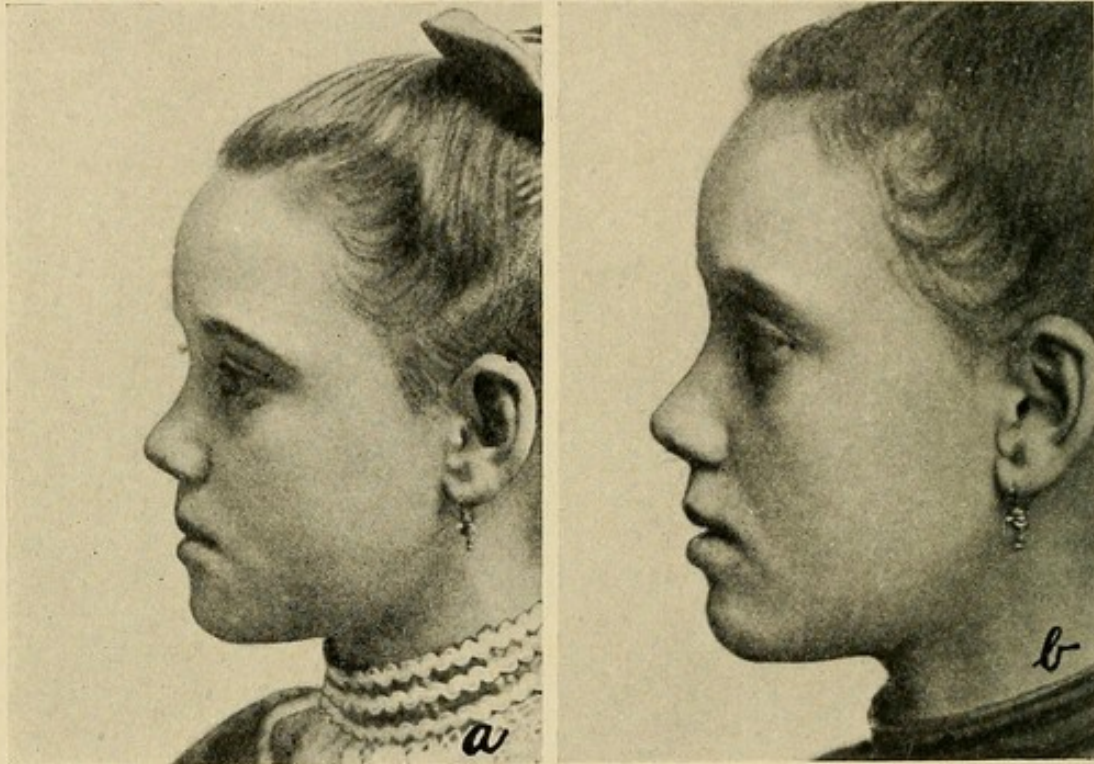
FIG. 78



Shows the author's method for estimating in advance the probable effect of an orthodontic treatment. (Compare with Fig. 79.)

furthermore, a rule so plain and so simple that all can understand and apply it. It is *that the best balance, the best harmony, the best proportions of the mouth, in its relations to the other features, require that there shall be the full complement of teeth, and that each tooth shall be made to occupy its normal position—normal occlusion.*”

FIG. 79

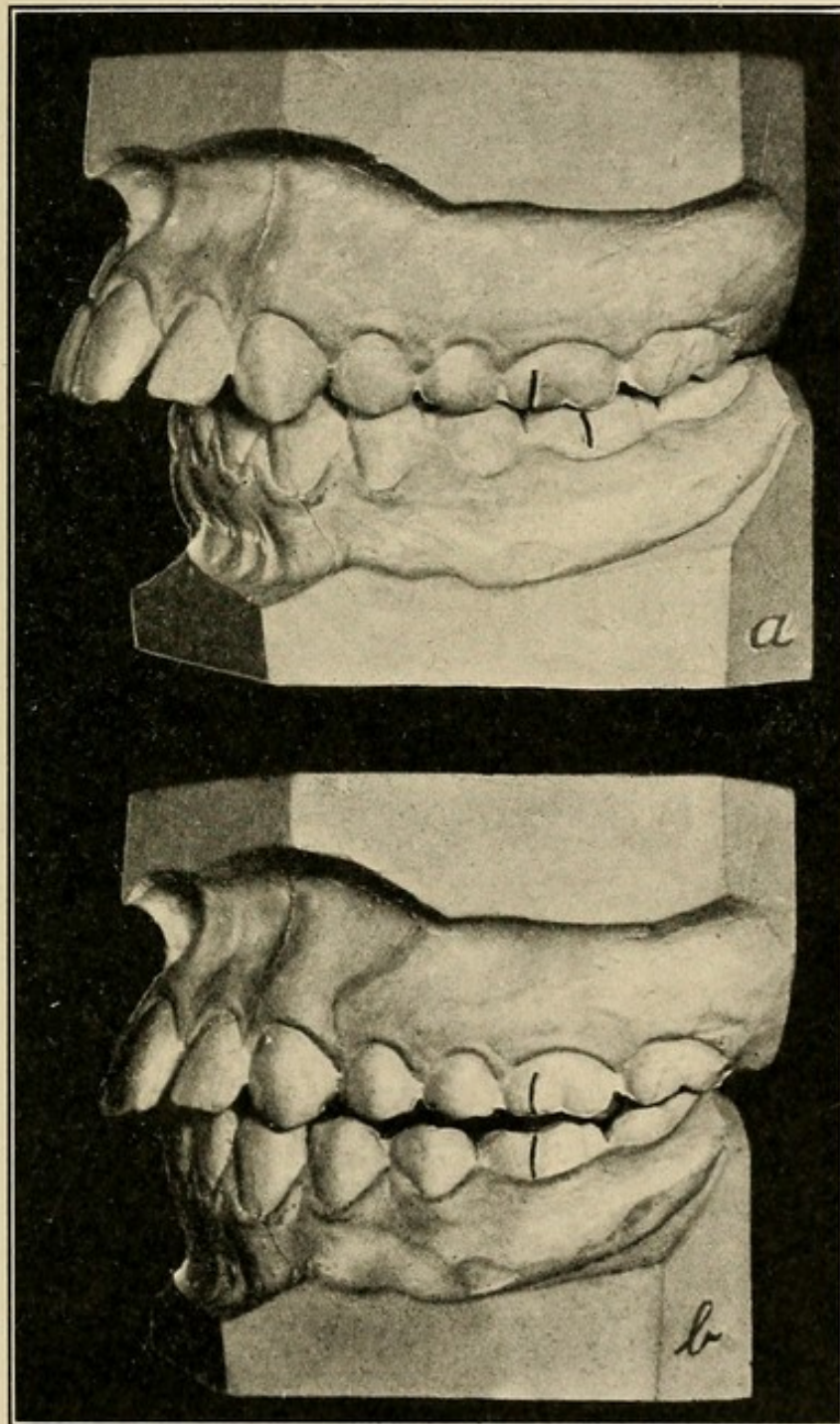


Photographs of the patient before and after the use of the wax mould shown in Fig. 78.

Expressed differently, Angle maintains that the outward form of the changeable area of the face is dependent upon the relative normality of the denture within; and that, as a rule, it is best to establish normal occlusion (which implies the presence of each tooth), and thus strike a balance which is rarely wrong. Theoretically, this is not absolutely true; and it can hardly be called a law, using the word in its scientific sense. But many operators of wide experience are practically unanimous in support of his contention, hence it

has become a fundamental postulate in orthopedic practice. In other words, it is true because it ought to be true, and because the opposite practice of sacrificing teeth for the

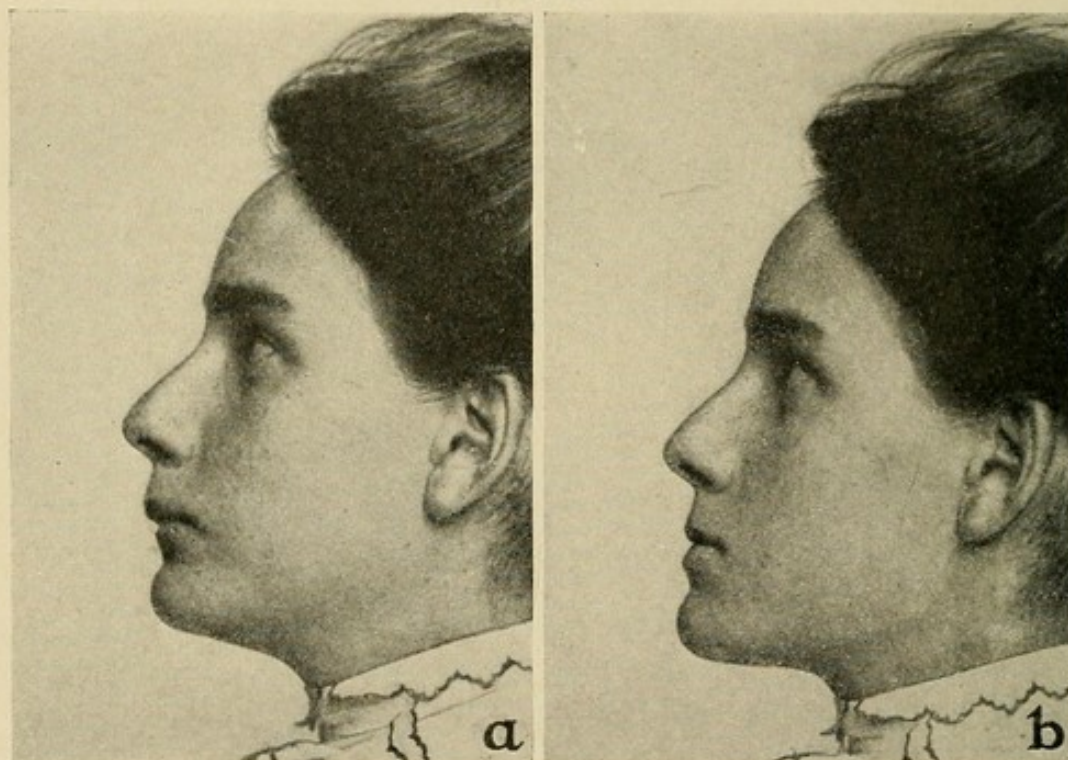
FIG. 80



Method employed in distocclusions. (Compare with Fig. 81.)

improvement of facial contour is rarely necessary, and seldom advantageous. Indeed, the necessity for the extraction of one or more teeth is so infrequent that its practice has become almost obsolete. This is particularly true in all cases where the treatment is instituted during the developmental period. The development of the surrounding osseous structures subsequent to tooth movement is usually to be expected in young patients; hence their profile must never be considered as a fixed line (at least not immediately after treatment), but one in which further changes will continue to take place.

FIG. 81



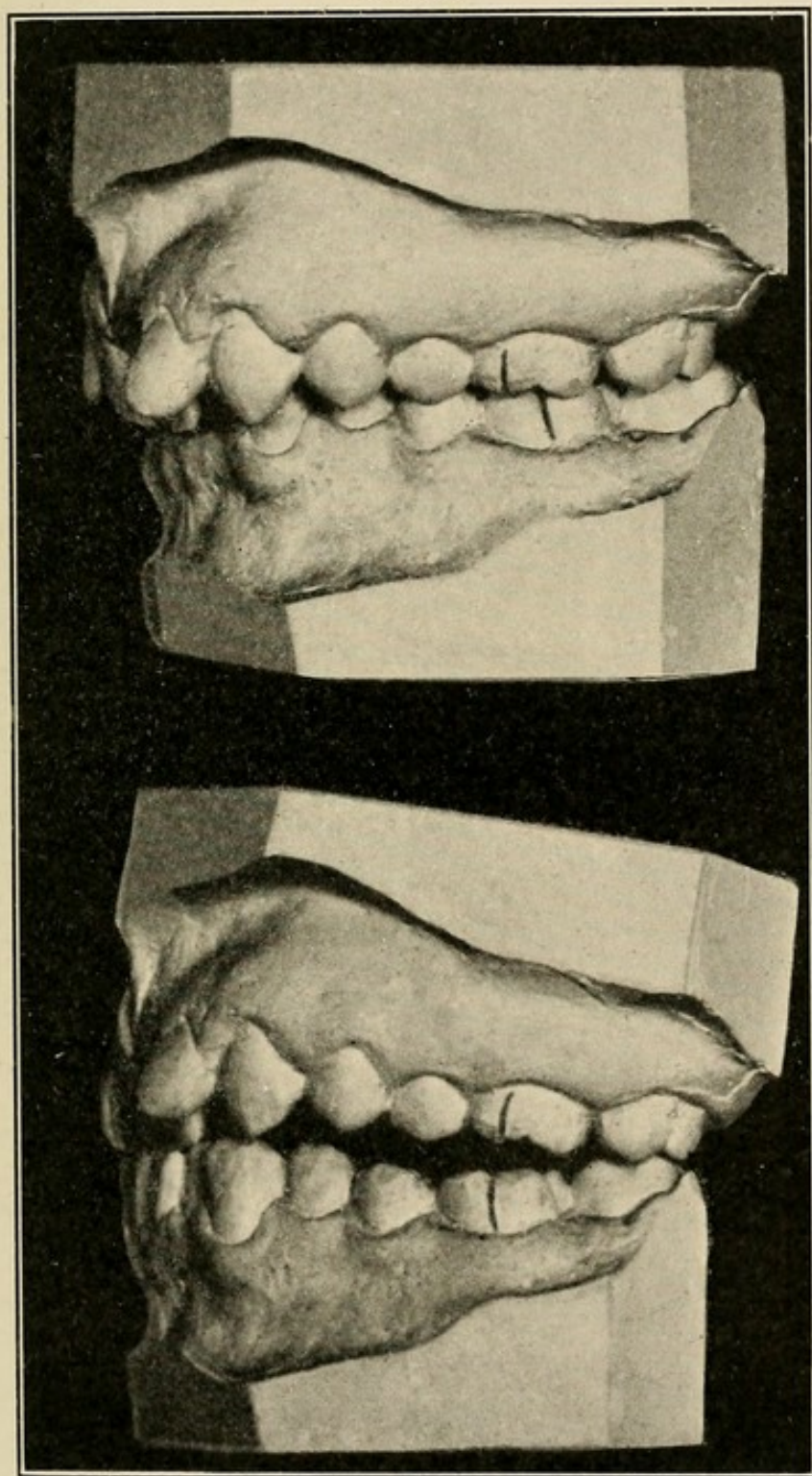
Shows temporary effect upon the profile.

DIAGNOSTIC METHODS

In order to ascertain in advance the probable effect of treatment upon the facial lines, the author has used the following methods whenever applicable:

In cases of neutroclusion accompanied by linguoversion of the incisors, a piece of softened wax is moulded over the

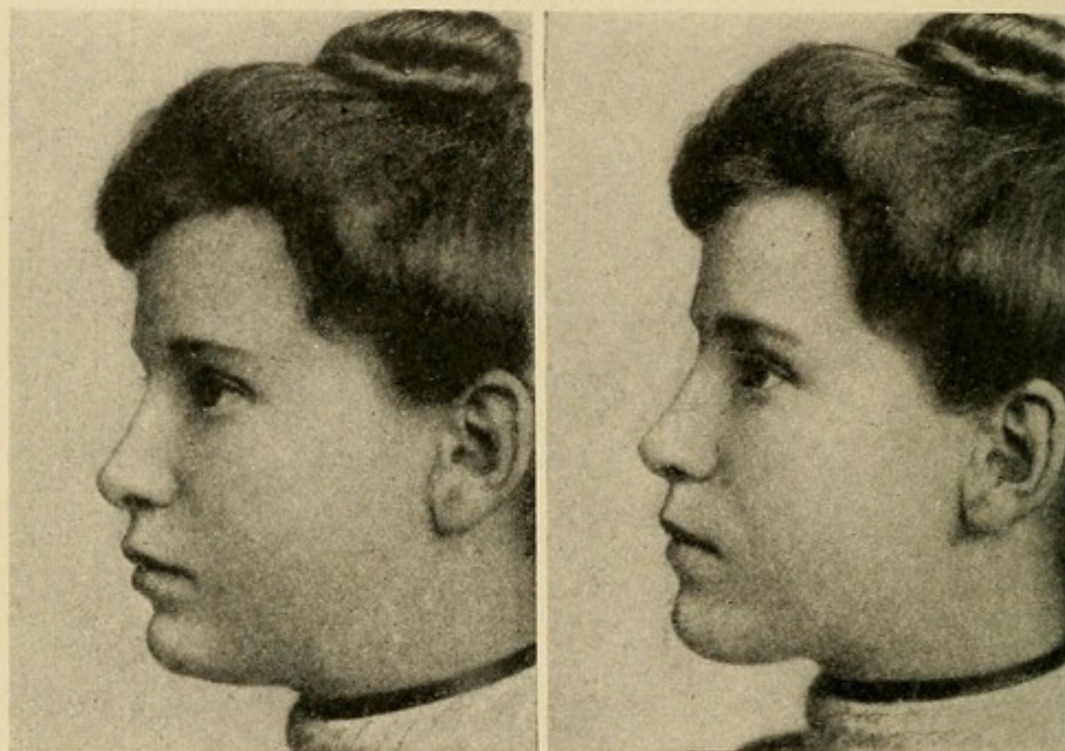
FIG. 82



Same method as in Fig. 80.

occluded models and trimmed to a form approaching the future alignment of these teeth (Fig. 78). After it has been allowed to cool it is placed in position in the mouth. The patient is now asked to relax all tension of the lip muscles, which allows the facial lines to assume the form which the treatment will ultimately produce (Fig. 79).

FIG. 83



Photographs of case shown in Fig. 82.

In distoclusion accompanied by labioversion of the upper incisors (Fig. 80, *a*) the patient is requested to bite mesially, so as to bring the first molars into normal mesio-distal relations. Fig. 81 clearly shows the effect upon the facial lines, representing photographs of the patient with the teeth in the positions shown in Fig. 80, *a* and *b*. Similar preliminary studies can be made of patients presenting a distoclusion accompanied by linguoversion of the upper incisors. The latter type frequently combines with supra-

version of the incisors and infraversion of the molars and bicuspids, for which Dr. Case¹ has suggested a temporary "opening of the bite." If necessary, pieces of modelling compound, or wax, are previously inserted to prevent complete closure, and while in this position a study of the profile can be made (Figs. 82 and 83).

In the more serious cases of facial deformity, *e. g.*, those due to mandibular macrognathism or to infraversion of the incisors, these methods are inapplicable.

¹ Dental Orthopedia, p. 323.

CHAPTER VII

THE PROGNOSIS OF MALOCCLUSION

DEFINITION

THE medical term *prognosis* is used to denote the probable result of, or prospective recovery from, a disease or abnormality. It is an opinion concerning the duration, course, and termination of a disease and of the outcome of the treatment. And while such judgments necessarily vary in accordance with an operator's experience, they are, nevertheless, dependent upon conditions inherent in each case.

In orthodontic practice it frequently becomes necessary to render an intelligent opinion in advance of treatment; and it is well to remember that a favorable prognosis depends largely upon an early diagnosis, when conditions are such that a comparatively simple treatment will suffice. Formerly it was customary to postpone most treatments until all of the permanent teeth had erupted, for it was believed that *nature* would assist in the correction of the malocclusion, and that most patients would "outgrow" the deformity. Many bitter disappointments have taught us the error of such advice, and strongly emphasize the fact that the severe forms of malocclusion do not develop over night, but are of slow growth. Hence it follows that years before even an intelligent parent recognizes the impending deformity, the alert diagnostician can advise ways and means for its prevention.

GENERAL CONSIDERATIONS

Age and Health.—Age and health may be regarded as fundamental considerations in every prognosis. Thus a macrogathic mandible, accompanied by mesiocclusion of the lower arch, might readily yield to treatment between the eighth and tenth years. On the other hand, if such a condition is neglected until the twentieth year the deformity might then be so severe that orthodontic measures for its correction would prove futile. Similarly, if treatment is attempted in two cases of the same age and type, but with widely divergent conditions of general and oral health, their response to treatment might vary considerably. Let us suppose that in one case immunity to caries had always existed; that the patient's robust health permits the operator to carry the treatment to a rapid and successful conclusion. In the other, we find caries very progressive, and the oral secretions markedly abnormal; the patient is hypersensitive and enfeebled by prolonged illness. It is obvious that in the latter, response to treatment will be extremely slow or plainly doubtful, even though it be administered by the same experienced hands. To be able to detect such differences in advance is often difficult, and the ability to do so can only be acquired by a wide experience and much careful observation.

Sex.—Dr. Guilford¹ has pointed out that the question of sex may enter into a prognosis, and claims that "a robust boy can undergo an operation that in a tender girl might result in nervous shock or even greater physical harm." He rightly maintains that a "loss of general health could

¹ *Orthodontia*, 4th ed., p. 41.

never compensate for an improvement of the dental organs, however great." Other writers assert that sex is of little consequence, and they are unwilling to accept a comparison between a "robust boy" and a "tender girl," because there are many robust girls who make better patients than tender boys. However, it appears self-evident that the advent of puberty in females, with its frequent disturbances of bodily equilibrium, requires the exercise of more than ordinary care and attention; all of which emphasizes the necessity for early treatment.

Furthermore, the methods of today are such that, when properly administered, they do not act as a hardship on the patient. It is unfortunate, therefore, that the cry of an ignorant laity should raise an echo in the profession, leading to a denunciation of orthodontics, and the claim that its treatments seriously undermine the health of many individuals. Dr. Ketcham¹ and others have gathered data in refutation of these false assertions, and have found that practically all patients gained in weight during the entire period of orthodontic treatment; many of them improved rapidly in their studies at school, and few failed to respond favorably to treatment. This ought not to cause surprise when we consider that most parents are sufficiently careful not to demand orthodontic services for their *sick* children.

A well-meant, though misdirected, enthusiasm has prompted some operators to ignore entirely the factors of age and sex, and to accept cases of advanced years. Most of these patients are women who suddenly desire amends in facial expression, but with expectations entirely beyond the achievable. Though a carefully executed orthodontic

¹ Dental Cosmos, September, 1910.

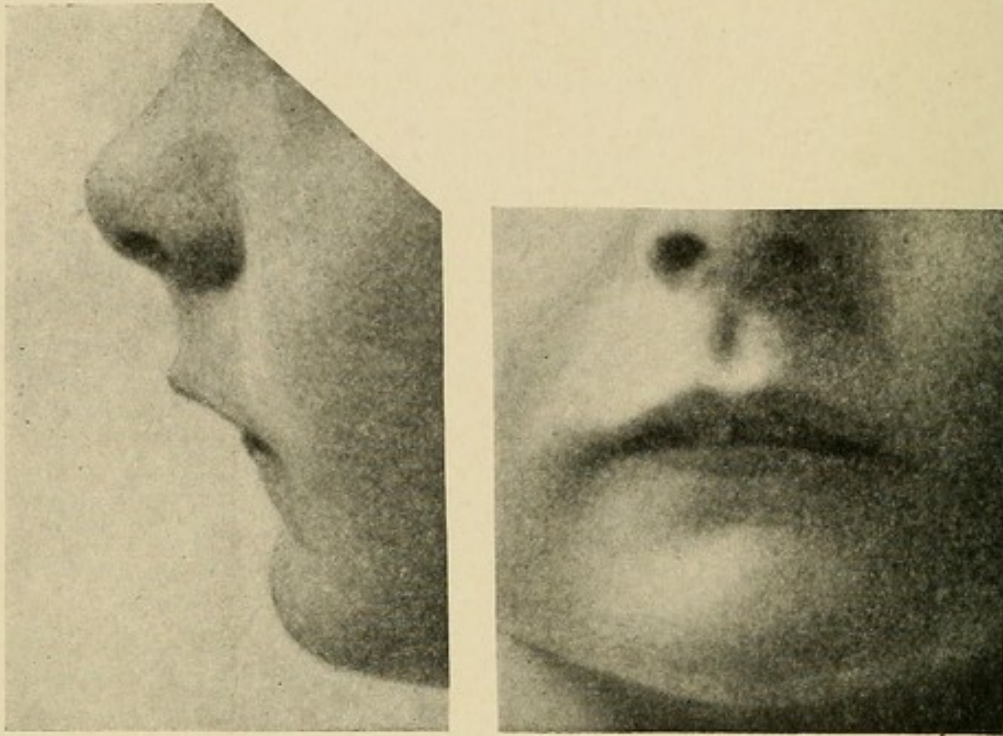
operation usually improves the facial lines, there are many instances where the results could hardly be called beautiful, and for which the operator is in no wise responsible. Let the beginner beware, therefore, of all mature cases with a doubtful prognosis; especially in the cases of married women, with the ever-present possibility of an intervening pregnancy. The latter constitutes an exceedingly unfavorable condition, rendering post-treatment maintenance extremely doubtful, if not impossible.

SPECIAL CONSIDERATIONS

One of the most important factors entering into a prognosis is that of cause, the ignoring of which has led to many failures. The removal of the cause, whenever possible, is the first step in successful treatment. Of course, in a great many instances (owing to our limited knowledge of this subject) we are unable to proceed in this manner; but this makes it all the more imperative to do so in all cases where the cause is readily recognized. By way of illustration, let us consider the case shown in Figs. 84 and 85, exhibiting abnormal breathing. This symptom connotes nasal obstruction, which usually stands in causal relation to the malocclusion. Its presence and neglect in early childhood invariably leads to malocclusion of the permanent teeth, and in all cases associated with mouth breathing the competent treatment of the abnormal nasal conditions should be insisted upon. (Compare with Fig. 41, *A*, which is from a patient of similar type at the age of sixteen.)

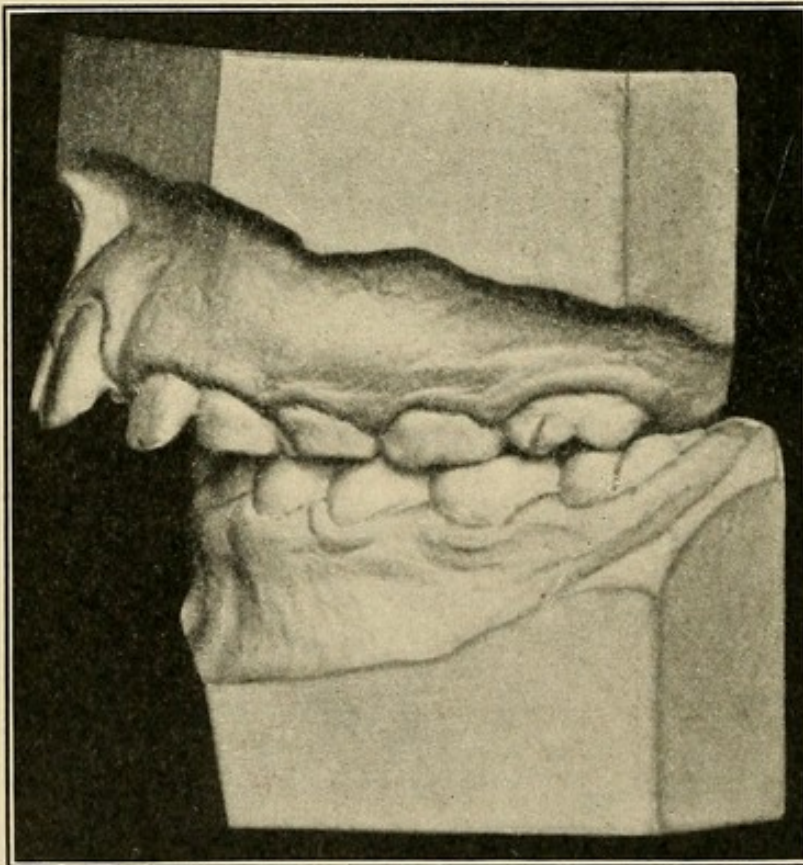
Owing to the mechanical aspects of dentition, the self-correction of most forms of malocclusion is an impossibility.

FIG. 84



Facial deformity in a lad of eight years suffering from nasal obstruction.

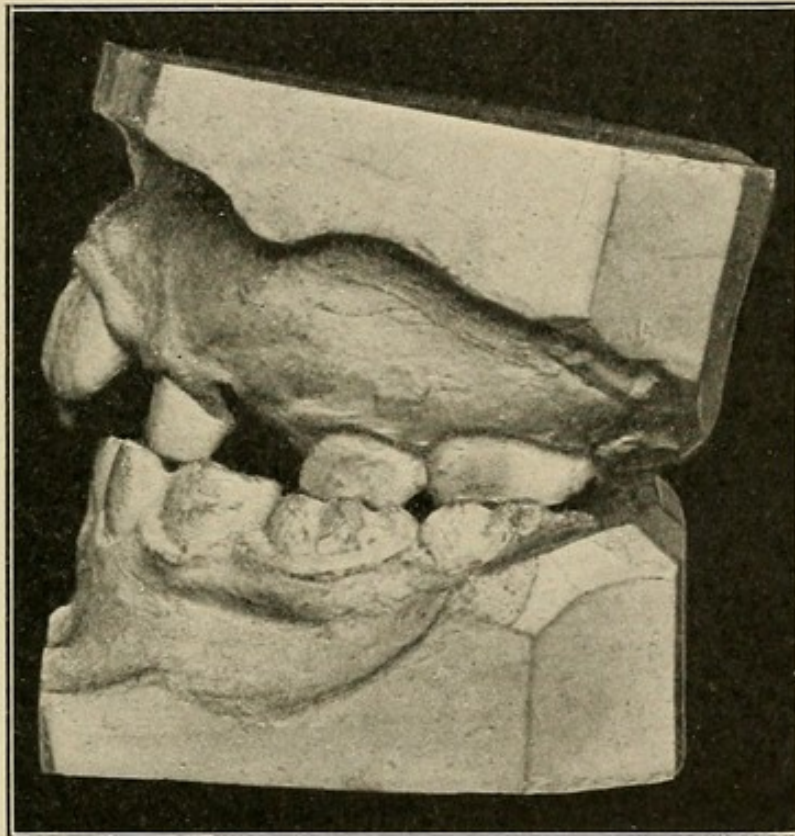
FIG. 85



Denture of case shown in Fig. 84.

Nature and time rarely exercise a corrective influence upon them. To the usual questions, then, which parents so frequently ask in first consultation, a negative answer is uniformly best. The accompanying facial deformities, which are often the immediate reason for their inquiries, grow steadily worse. Fig. 86 shows the models of a lad, aged

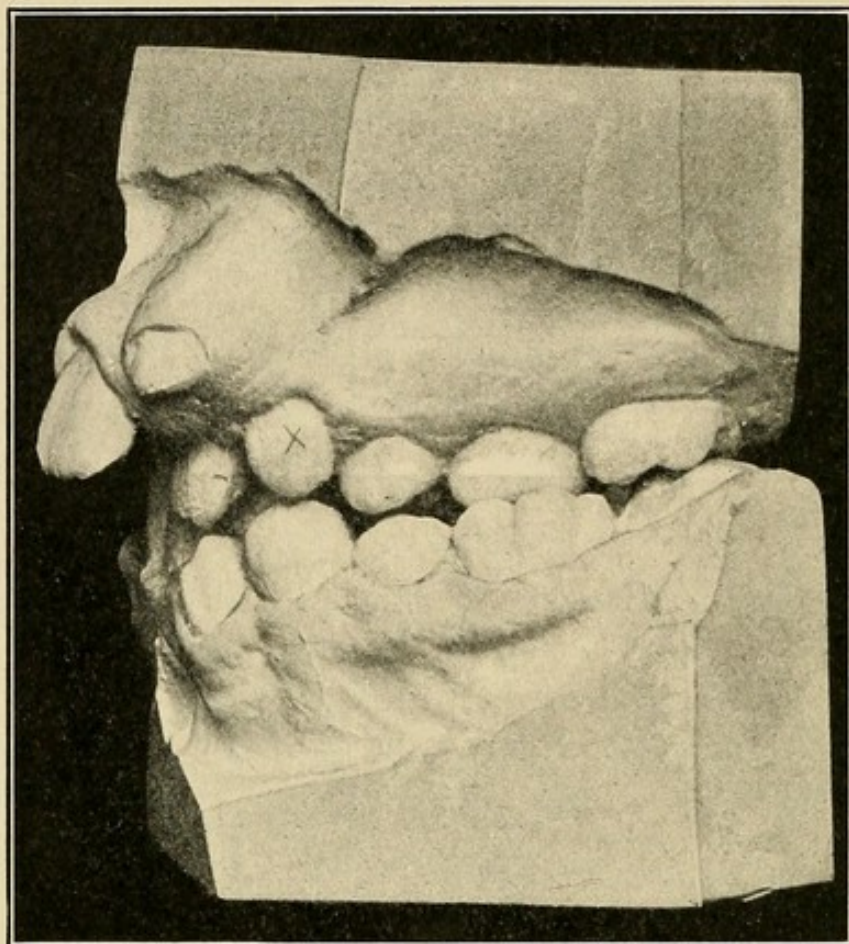
FIG. 86



Incipient unilateral distocclusion at eighth year.

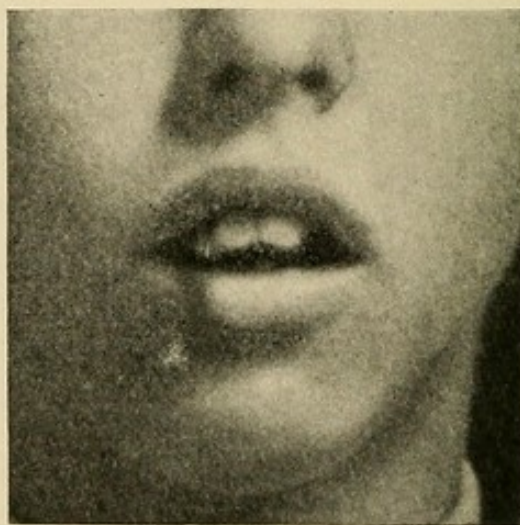
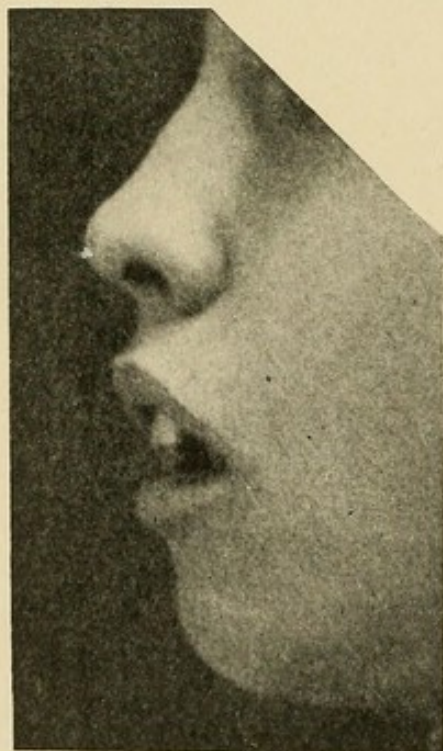eight years, whose parents found it convenient to heed the advise of an ignorant dentist: "*He'll outgrow that in a few years. I wouldn't advise any treatment now.*" These and many similar assertions are soothing to a father's purse. During the few minutes this boy occupied the author's operating chair, and while his remarks on the urgent necessity for treatment were slowly and emphatically expressed,

FIG. 87



Same case as Fig. 86 at age of fourteen.

FIG. 88



Facial deformity accompanying case shown in Fig. 87.

the impressions from which these models were made were taken. Under pressure, probably, of the conflicting social and economic tendencies of our age, this lad and his parent disappeared from the immediate scene. Six years elapsed before their return, during which time the models rested peacefully in their place in the cabinet. Another dentist is now caring for this family's dental ills, and their return to the author's office is not an unusual or unexpected incident. Fig. 87 shows the same denture at the age of fourteen, and Fig. 88 the pronounced deformity of the face which time and nature, unaided, had wrought. The history of many similar maldevelopments could here be introduced; they are all too common, even in this day. But multiplication is unnecessary. Every fact gleaned from a study of the process of dentition substantiates the orthodontic axiom that *malocclusion and its accompanying deformities are progressive, not static*. In short, the prognosis of malocclusion is equally as unfavorable as of caries of the enamel; the evil consequences are equally certain. The old adage, "An ounce of prevention, etc.," is decidedly *apropos* in a consideration of malocclusion of the teeth.

The one great lesson, then, which recent orthodontic progress teaches is that all forms of malocclusion develop slowly; that during childhood they are ever in process of development. To appreciate this *evolution of types*, to detect them in their incipiency, and to divert the underlying forces into channels of normality—this is the highest mission of orthodontics. But there is another lesson which must be more widely taught than formerly, and which has been too much neglected, namely, the important relation a normal denture bears to health. In earlier periods orthodontic efforts were appreciated mainly for their esthetic conse-

quences; the desire for an improvement of facial harmony was the prime motive in most instances. More recently we have come to a realization of the fact that a normal denture implies normal occlusion, without which its efficiency is greatly reduced.

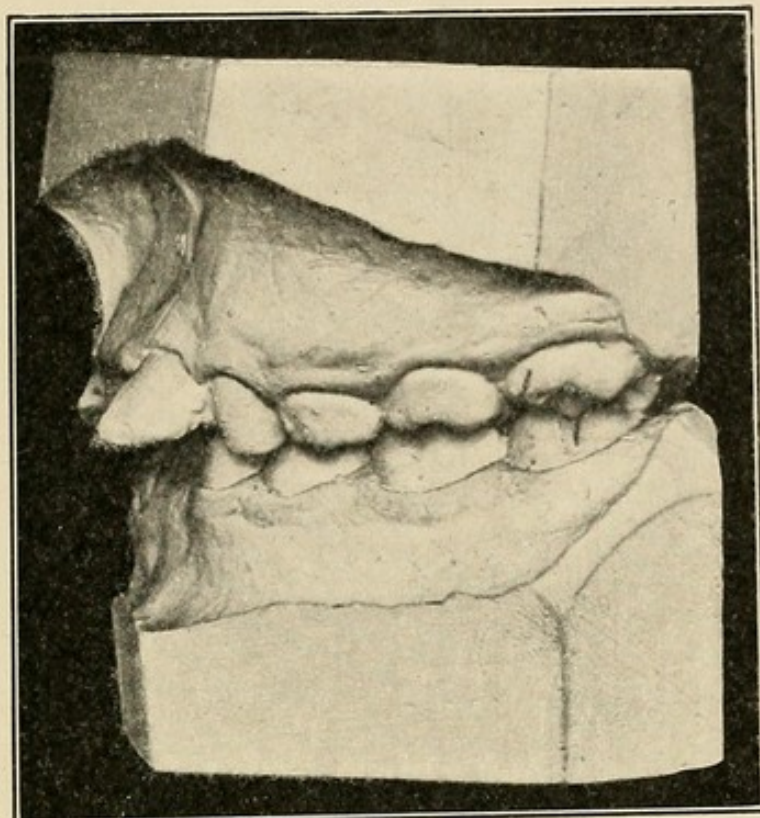
The recent experiences of many practitioners have led us to a keener appreciation of the "golden age for treatment," by which we mean that time in an individual's life when the change from the temporary to permanent dentition takes place. This covers the period from the sixth to the fourteenth year. In rare instances (those cases which early exhibit a tendency toward extreme malformation of the jaws) it has been found advisable to begin treatment prior to the sixth year. And in most cases of mesioclusion or distoclusion it is best to institute treatment as soon as it can be diagnosed, *i. e.*, immediately after the eruption of the four first permanent molars.

The establishment of the alveoli and the complete calcification of the roots of the teeth; the development of the temporomandibular articulation; the lengthening of the rami and the development of the body of the mandible—all these are considerations which must be reckoned with.

CLINICAL SUMMARY

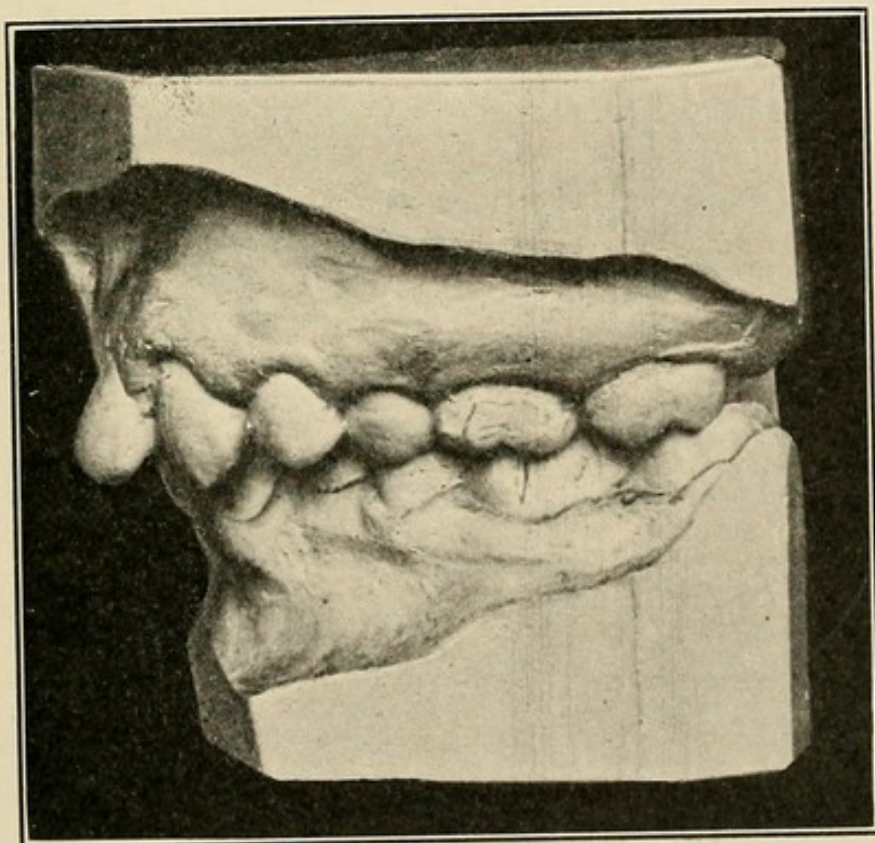
A brief study of the various forms readily establishes the conclusion that in their earliest stages all are comparatively simple. Figs. 89 and 90 show two cases of distoclusion; one aged nine years, the other fourteen. In Fig. 89 it will be noticed how the linguoversion of the upper central incisors prevents a normal mesiodistal relation of the lower

FIG. 89



Incipient bilateral distoclusion at nine years.

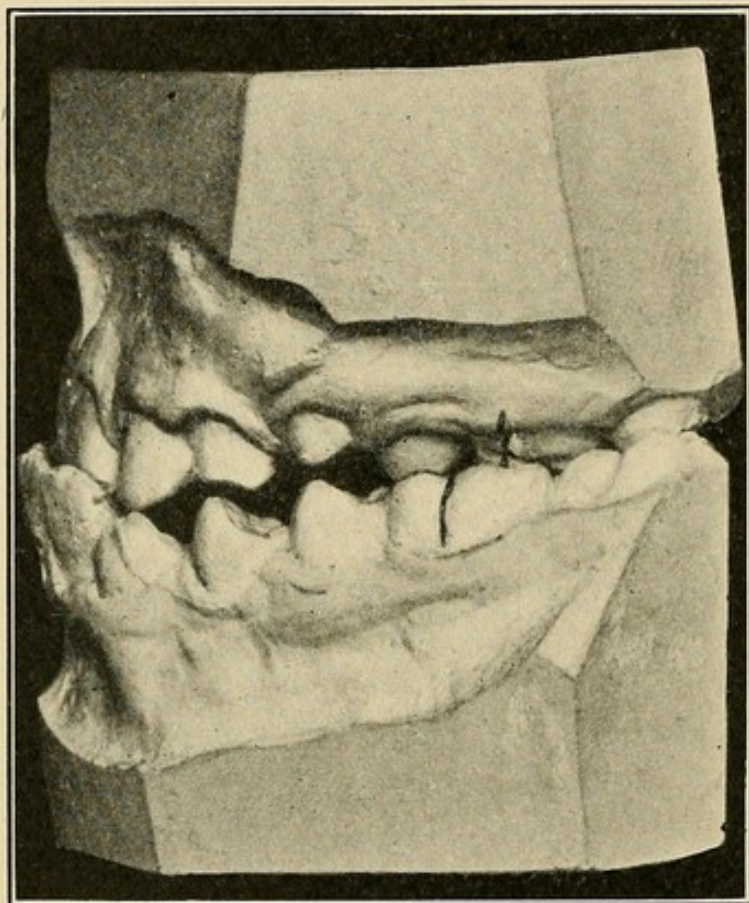
FIG. 90



Same type of malocclusion at fourteen years.

arch; the tendency is toward an arrest of development of the mandible. Note further how the molars are thereby prevented from coming into normal occlusion. A moment's comparison establishes the inference that the older case (Fig. 90) passed through a similar stage.

FIG. 91

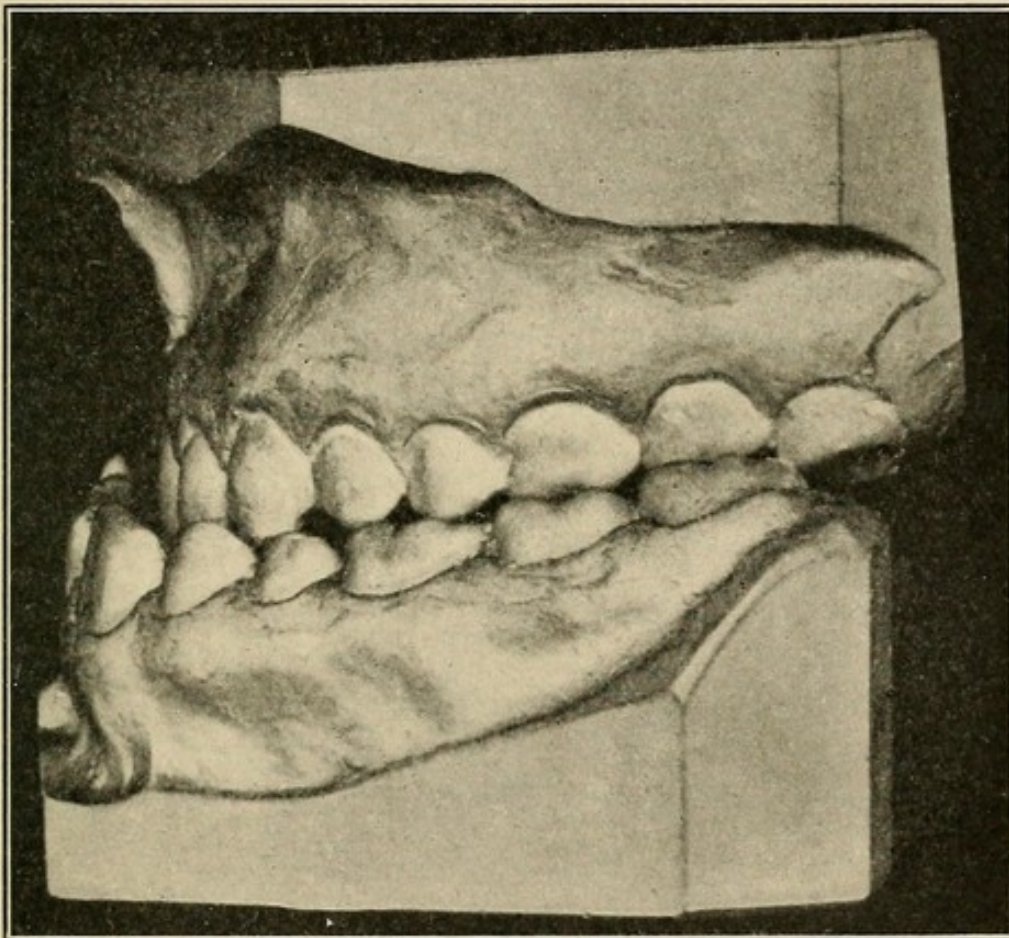


Bilateral mesioclusion at eleven years.

That the history of mesioclusion is similar is equally certain is shown by a comparison of models in Figs. 91 and 92. Fig. 91 is made from the denture of a boy, aged eleven years, while Fig. 92 is from an adult, aged twenty-eight years. It is inconceivable how neglect could prove beneficial to Fig. 91; it is the surest way toward a multiplication of difficulties. If the influences of abnormal function, of the

impacts during use, are considered, it becomes evident that the omission of treatment constitutes a "penny-wise and pound-foolish policy." How an intelligent dentist, intrusted with the care of the mouths of growing children, could permit such abnormal developments under his very eyes and not remonstrate against them is incomprehensible. The probable

FIG. 92



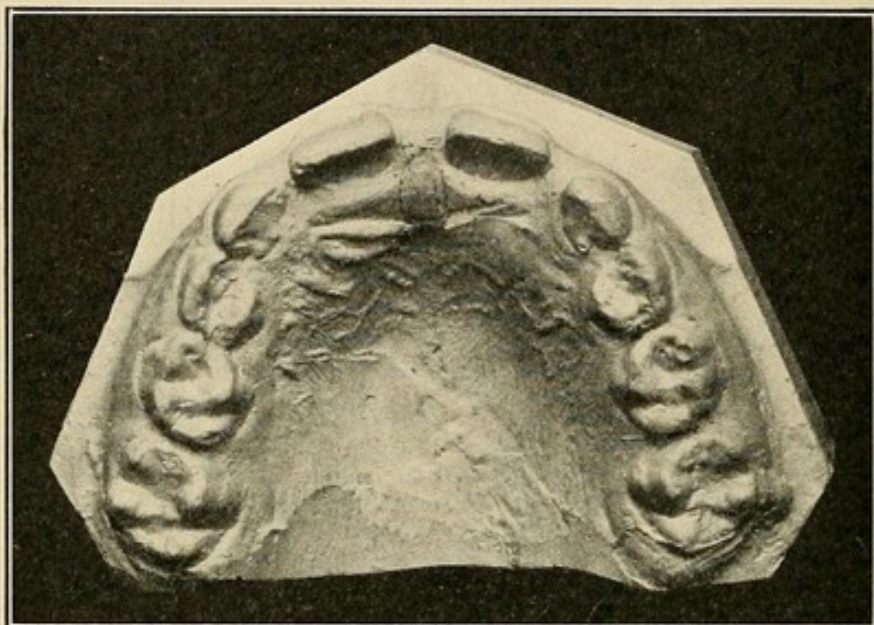
Mandibular macrognathism at twenty-eight years.

result of treatment for Fig. 91 is exceedingly favorable; the correction of the mandibular macrognathism of Fig. 92 lies beyond the domain of orthodontics. (See Chapter XVIII.)

In the next illustration (Fig. 93) we note a distoversion of the upper centrals in a girl, aged eight years, due to an

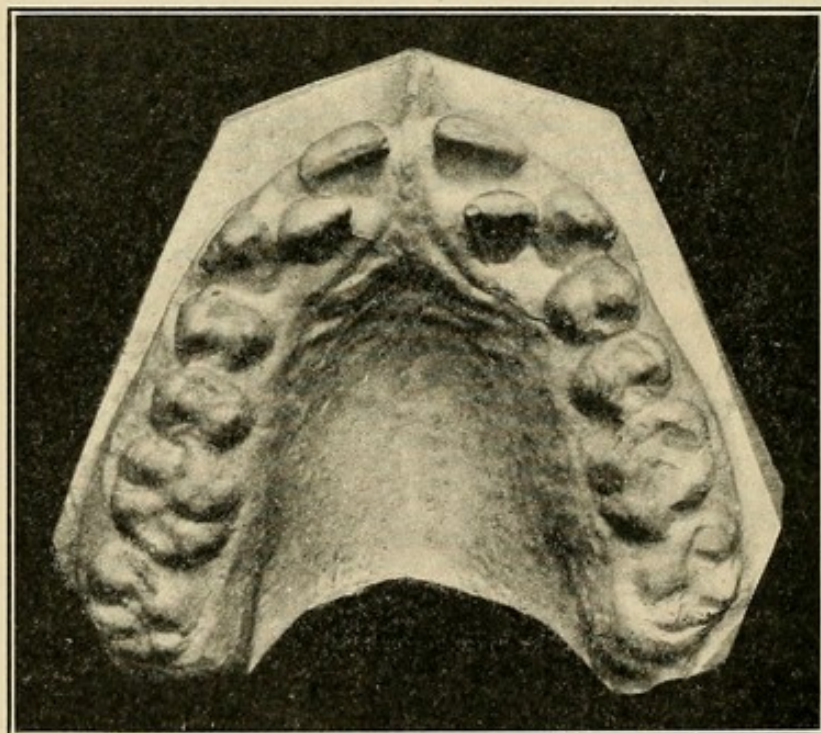
abnormal frenum labium, and another (Fig. 94) at the age of twelve. Four years of neglect have again demonstrated their evil consequences. The diastema between the

FIG. 93



Denture of a girl, aged eight years.

FIG. 94



Similar type at the age of twelve.

centrals caused an encroachment upon the lateral spaces, and when the latter finally appeared they readily erupted lingual to normal. A further study of many similar cases might here be introduced, but the lesson from each would be substantially the same. To the question then, Is early treatment always advisable? the uniform reply is Yes. Should postponement of treatment be desirable in a given case, the operator should be accorded the privilege of the decision.

As to treatment, MacDowell¹ has suggested a classification of cases into three groups, as follows:

The possible: all cases between the ages of eight and fourteen.

The probable: mesiocclusions and distocclusions after the age of fourteen.

The impossible: most cases beyond the age of sixteen.

Skilful orthodontists regard this as a very conservative classification, because a wide experience enables them to considerably extend the age limit of each group. But the beginner will find it a valuable guide, it being the part of wisdom to err on the side of safety.

¹ Orthodontia, xvii.

CHAPTER VIII

THE EVOLUTION OF METHODS

METHODS OF THE PAST

SCIENTIFIC progress during the last half century has so altered our conceptions regarding the theory of life and the growth of society, that we are forced to re-write history and adapt it to the evolutionary philosophy (Pearson¹). Present-day standards require history to be more than antiquarian; the real profit in tracing the development of an art must rest in something else than a mere knowledge of what has happened in chronological order; it must dwell in an understanding of the *principles* that have promoted the developments of the past, in the *meaning* of certain events. This advance in our conceptions is due to the epoch-making labors of Darwin, "who made all reasoning since his day follow his method."

Now, in tracing the evolution of orthodontics the aim should be to view its development from the standpoint of this new and higher perspective. In no other division of its subject matter is this more desirable than in the methods of treatment. Not that the tracing of its remedial measures constitutes the whole of its history; the evolution of the science and the history of its theoretical foundations are equally important. But a greater unanimity of opinion

¹ The Grammar of Science.

regarding these fundamentals has always existed. Indeed, the principles of the science are readily traced; in these fields a greater harmony prevails than a first survey seems to justify. Not so with the art. The steep activity up which we have so slowly traveled measures a progress not without interest or strife. The desire for supremacy on the part of several of our leaders has added its bitterness as well as charm.

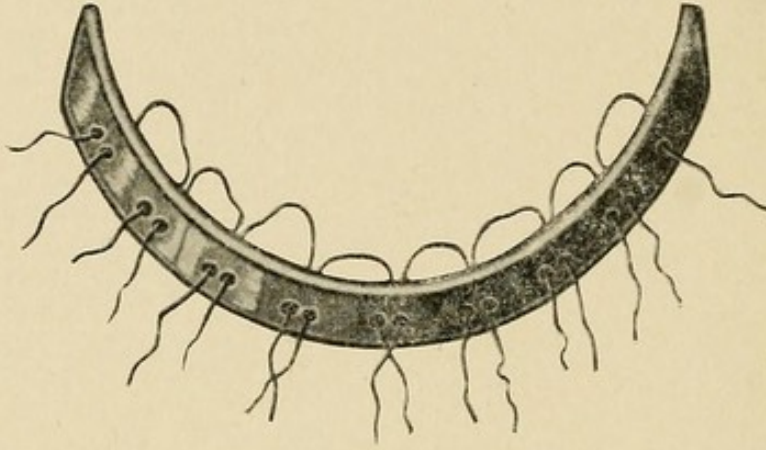
The delineation of the methods of treatment is difficult not only because they have been as varied as could well be imagined, but because they comprise an overwhelming mass of trivial details. Formerly, the dentist only occasionally dabbled in matters orthodontic, and thus failed to grasp the principles underlying the technical details of treatment. Prior to diagnostic systems each case constituted a class by itself, so that the designing and constructing of a mechanism for treatment often taxed to the utmost the inventive capacities of the practitioner. Thus the birth of the new order was painfully prolonged, and the rudiments of present-day methods unwittingly obscured.

But in 1878 Dr. Farrar, of New York (see page 27), prophesied lines of advance which have since been followed with increasing advantage and favor. The import of his prediction was not readily grasped, though it stipulated the standardization of appliances and their being carried in stock by dealers. Indeed, this ideal is not yet fully achieved, though its influence thus far has been nothing short of revolutionary. It has forever relegated appliance manufacture where it rightfully belongs, has freed the mind of the operator of many petty details, and furnished the necessary leisure for the investigation of more important matters.

Viewed in this wise, it is not difficult to imagine the

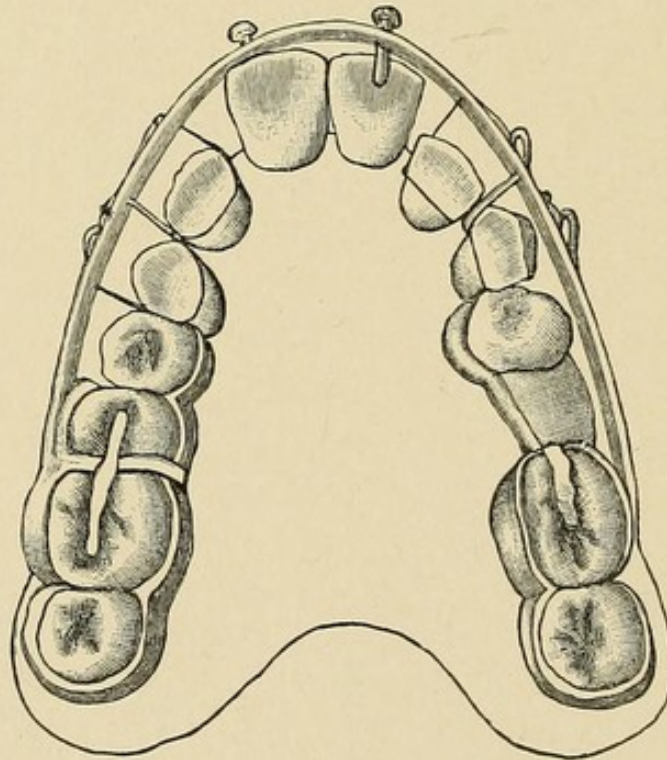
probable present status of a department like operative dentistry had not the manufacturer long ago come to the

FIG. 95



Fauchard's metallic alignment band (1728). (After Pfaff.)

FIG. 96



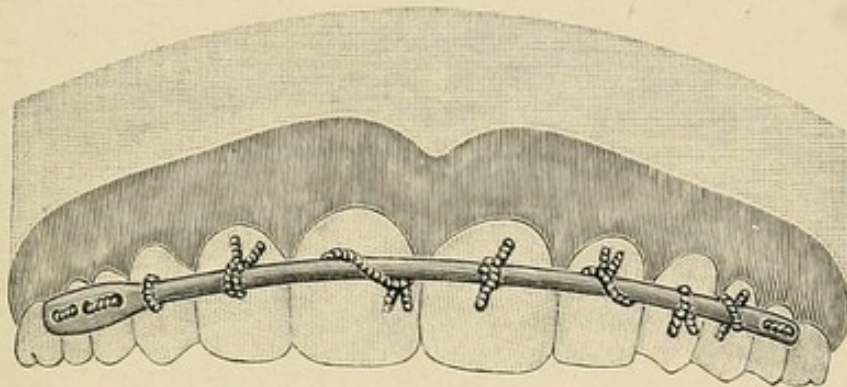
Schange's appliance (1840). (After Pfaff.)

rescue. The wonder of it, then, is not how little, but how much the past has achieved. Truly, a sincere review of the

work of the pioneers and pathfinders awakens the deepest reverence; their labors must ever be regarded as indispensable stepping stones. Though they are now fading from twilight into dusk, let us not forget that they ushered in that golden dawn which made the present possible.

Fig. 95 shows an appliance used by Fauchard (1728), and exhibits the principle of our present-day alignment wire. Fig. 96 shows an appliance designed by Schange (1840), and embodies the essentials of mechanisms in use today. A

FIG. 97



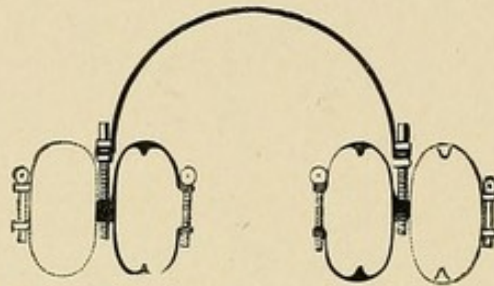
Flagg's round alignment wire (1865). (After Pfaff.)

similar, though greatly simplified, apparatus is shown in Fig. 97, being a design by Flagg (1865). It represents the *round alignment wire*, with flattened ends anchored to the molars, and serves as a goal toward which the malposed teeth are moved by means of ligatures. A comparative study of other elements might easily be here introduced, though a sufficient number have been shown to demonstrate their gradual evolution. Some systematists have studiously avoided such comparative study, and utilized well-chosen contrasts to their own advantage.

RISE OF THE SYSTEMS

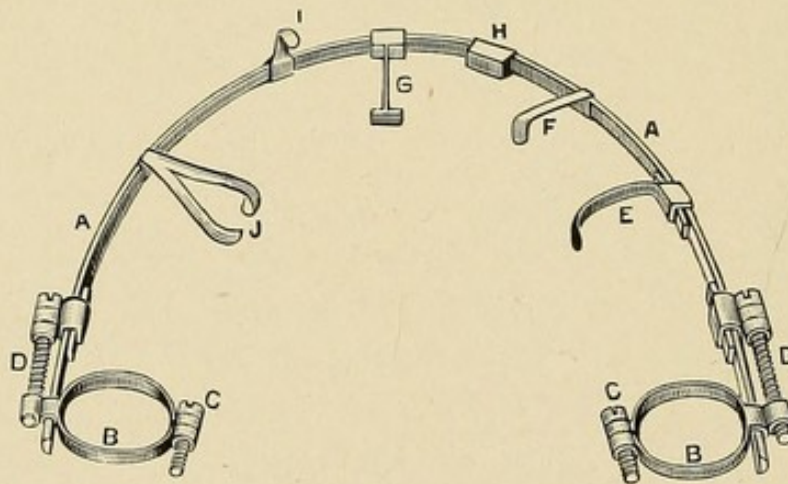
Following the epoch-making labors of Farrar, the introduction of stock appliances was inevitable. The wholesale construction of standard mechanisms with interchangeable parts, to be placed upon the market for sale, was now

FIG. 98



Farrar's "labial bow" and clamp bands.

FIG. 99

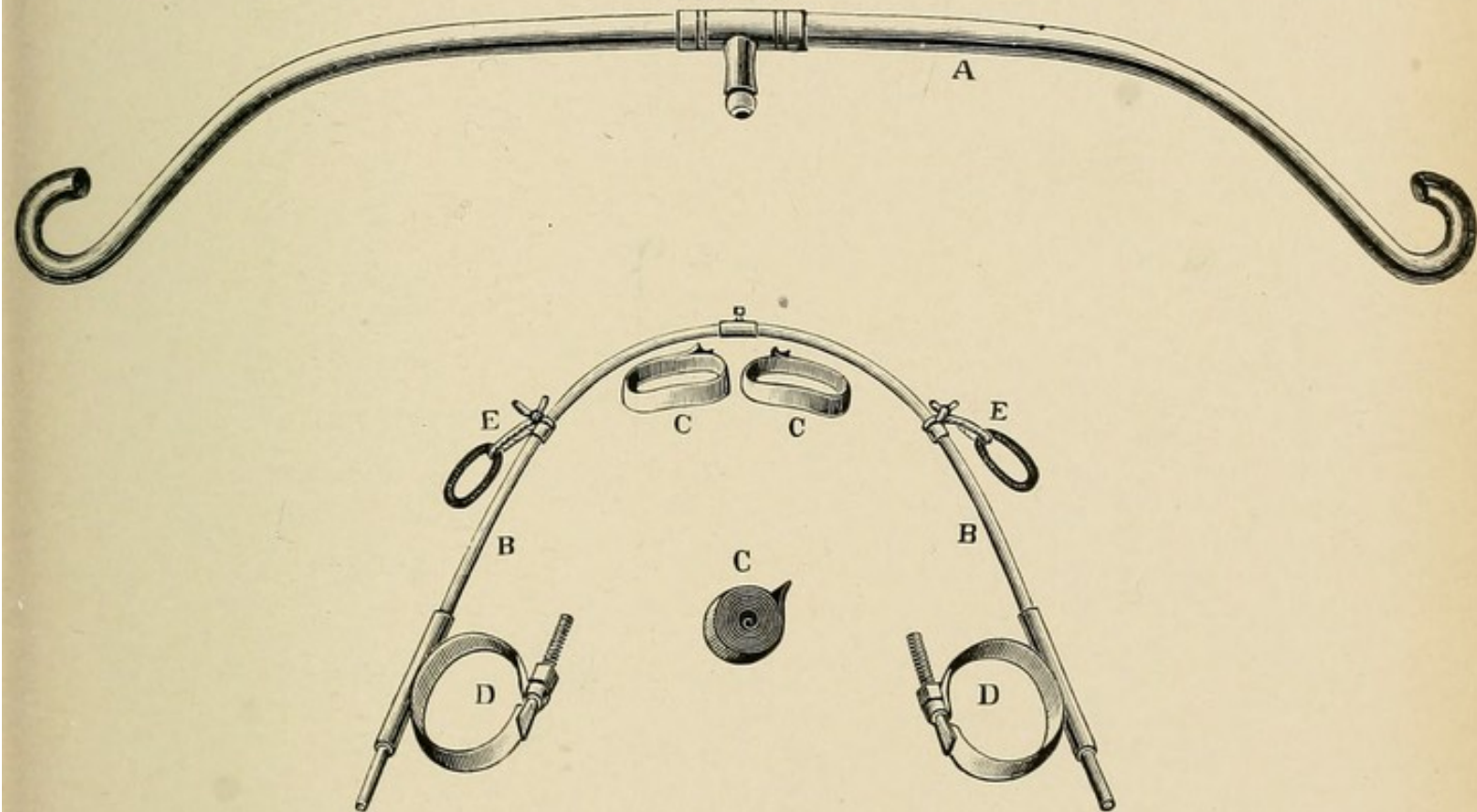


Patrick's appliance.

demanded. Naturally, many of the earlier efforts in this direction were very incomplete and unsatisfactory, and in untrained hands often proved a failure. They were usually brought forth in the shape of a "system," and represented the more commonly used methods of their author.

In 1876, in response to these demands, Dr. Farrar offered duplicates of many of the appliances he had used in his practice (Fig. 98). For a time they enjoyed an extended sale, but were soon displaced by devices of simpler design, notably those by Patrick in the early 80's (Fig. 99). A study of this illustration reveals the principle of the alignment wire anchored to the molars by means of adjustable bands with buccal tubes.

FIG. 100



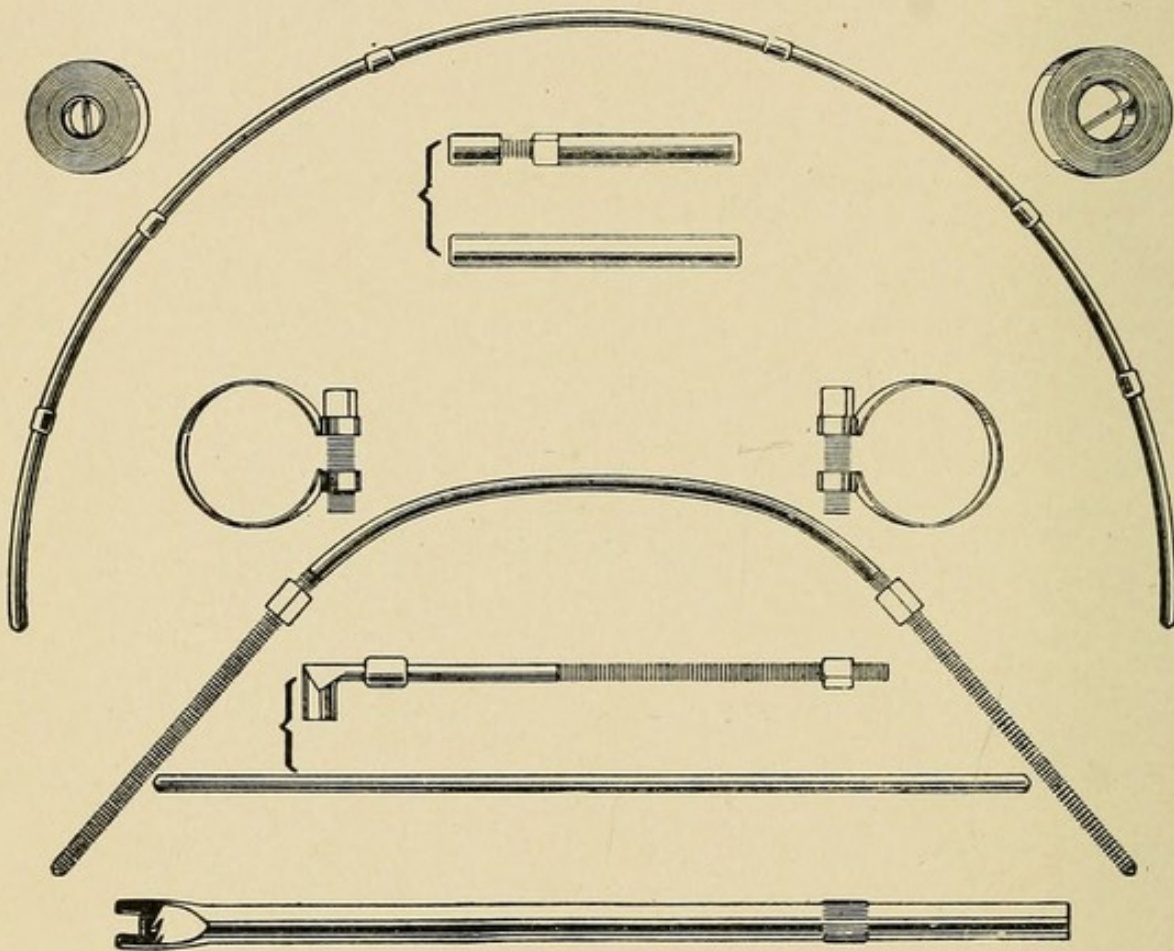
Angle appliance of 1887.

In 1887 Angle introduced a system which embodied sundry of these old principles, though greatly simplified by a reduction of parts (Fig. 100).

Among the many other methods brought forward during this unusually productive period were the systems of Jackson, Case, Lukens (Fig. 101), and Knapp.

Recent adverse criticism has created considerable ill feeling in opposition to these so-called systems, which could easily have been avoided had their originators adhered to the principles of historical method. Their tacit claims of

FIG. 101



Lukens' appliance.

having suddenly, and by original methods, revolutionized the art and brought it to an approximate finality, are directly traceable to the wilful omission of the work of many predecessors.

In Chapter I attention was called to their achievements, to their influences toward the simplification of methods;

and so the struggle which they themselves engendered may be regarded as a passing cloud—for systems are wholly foreign to the democracy of science. Hence the thought that they must finally die, that upon their shattered dreams of finality a greater and grander art will rise, is encouraging, and not at all dispiriting. Indeed, this forward movement has now begun.

LINES OF ADVANCE

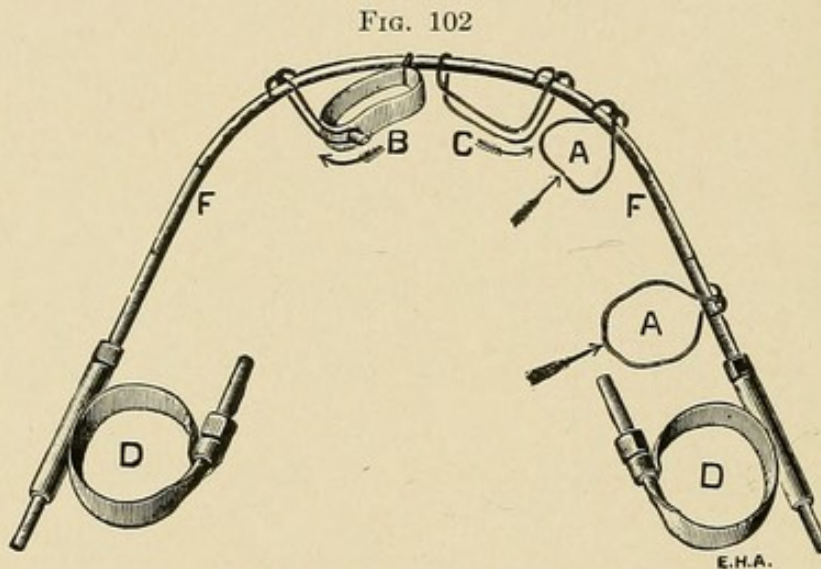
The comprehension of the importance of a differential diagnosis, the designing of a definite treatment for all cases belonging to a given class, and the simplification and mastery of the technical details of every such definite treatment, may be said to constitute the core of what has been termed the *new movement* in orthodontic practice.

The systems (particularly the efforts of Angle) have been largely responsible for promoting this advance in our progress. And though they were unbecomingly dogmatic, they possessed the saving grace of showing the wide range of applicability of a limited number of very simple mechanisms. Hence the burden of their claims was, after all, a very laudable one; by insisting on the mastery of a few essentials and their manifold combinations, orthodontics made a progress hitherto unattainable. In fine, to be a master in the application and use of a few appliances, rather than the slave of many, is a worthy lesson the systematists have tried to teach. Ever since the dawn of this tendency toward simplicity and the unification of methods, orthodontics has witnessed a wholesome elimination of many unnecessary and impractical procedures. Though this process of elimination still continues, at the present writing it is very

evident that certain mechanisms (those embodying advanced principles of design) are tending rapidly toward universal acceptance.

DETAILS OF DESIGN

Fig. 102 is diagrammatic of a modern appliance, combining many of the essential elements in use today. These elements may briefly be summarized as follows: The plain band (*B*), anchor band (*D*), alignment wire (*F*), ligatures (*C* and *A*), and a number of minor miscellaneous accessories



Modern appliance. (After Angle.)

not shown in the illustration. By the skilful and judicious combination of these elements we are enabled to treat most cases of malocclusion. Only rarely are we obliged to employ other and more complicated appliances.

From the earliest times, several of the noble metals, viz., gold, platinum, silver, and their alloys, have been used in the construction of regulating appliances. In recent years base metal alloys like German silver have been widely employed. Iron, steel, nickel, aluminum bronze, and

vulcanite rubber have all been recommended. German silver, however, possesses many of the virtues which should be embodied in an appliance, such as temper, adaptability when annealed, inexpensiveness, etc. On the other hand, Pullen¹ and Grieves² have recently called attention to its shortcomings, which are as follows: Discoloration and disintegration, and, occasionally, the formation of metallic stains upon the tooth surfaces.

Alloys of iridium and platinum, and of gold and platinum, are therefore preferred by many operators, because they are not affected by the acid fluids of the oral cavity, or by any of the medicaments employed in practice (such as hydrogen peroxide, solutions of silver nitrate, tincture of iodine, etc.).

When attention was first called to the corrosion of German silver, its advocates proclaimed this a virtue, believing the consequent liberation of metallic salts had a favorable prophylactic influence, promoting an immunity to caries of the enamel. Grieves,³ on the other hand, has shown that the amount of metallic salts thus set free and swallowed by the patient frequently proves deleterious by unfavorably affecting the physiological action of the ptyalin and enzymes. He claims zinc is the most objectionable of all the metals which enter into alloys used for appliances.

The introduction of aluminum bronze into dentistry by Sauer, and its recent revival for regulating appliances by Treyman,⁴ resulting in the so-called "non-corrosive" appliances, will doubtless lead to the discovery of base-metal alloys with virtues equal to those of the noble metal group. The latter, however, possess all of the requisite qualifications except that of cost.

¹ Proc. Amer. Soc. Orthodontists, vol. vii.

² Ibid., vols. viii and ix.

³ Loc. cit.

⁴ Vierteljahr. f. Zahnk., July, 1909.

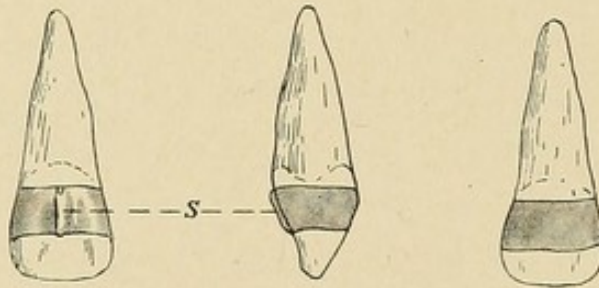
CHAPTER IX

PRINCIPAL ELEMENTS OF MODERN MECHANISMS

BANDS

The Plain Band.—The individual movement of malposed teeth and the correction of arch form constituted the sum total of orthodontic efforts for many decades. Only recently have the possibilities of arch movement been developed. Even in those earlier stages of progress was the need plainly felt for some form of attachment to the teeth to be moved. Owing to the unfavorable forms of many of the teeth, the use

FIG. 103



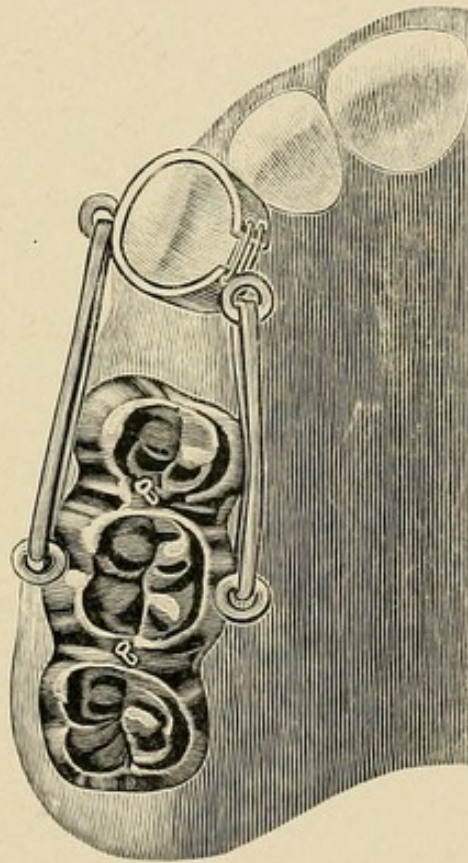
The plain band.

of simple ligatures often proved inadequate for the movements required. To gain secure attachment at the point of attack, regardless of the kind of mechanism employed, is the first requisite of successful therapy. Hence the plain band was invented (Fig. 103). It consists of a ribbon of metal 36 to 38 gauge, accurately adapted to the crown of the tooth for which it is designed, after which its free ends

are united by solder (*S*) to form a continuous band, or ferrule.

As early as 1815 Delabarre¹ suggested the use of metallic caps, or crowns, for the teeth to be moved, and to which the various attachments were soldered. In 1848 Jos. Linderer² advocated ribbons of metal for the same purpose. These had perforations in their ends, through which ligatures were passed, making them adjustable as to size (Fig. 104).

FIG. 104



Linderer's adjustable band on the canine. (After Pfaff.)

Magill and Gilmer have been credited with the honor of introducing the plain band as used today, and of advocating its secure attachment by means of cement. While many

¹ *Odontologische Beobachtungen*, Paris, 1815.

² *Handbuch der Zahnheilk.*, Berlin, 1848.

minor tooth movements are possible without its use, it is evident that the plain band with its various attachments will always occupy a prominent place in the technique. A detailed consideration of these various attachments and their uses will be found in the chapters on treatment.

The Anchor Band.—This essential element of an appliance has passed through many stages, all of which can readily be grouped under the two divisions of *adjustable* and *non-adjustable*. The non-adjustable designs were the first to be used, and were variously described as crowns, cribs, clasps, and ferrules. They were constructed by the operator, and prior to the introduction of cement were very insecure in their anchorage, besides promoting caries of the enamel.

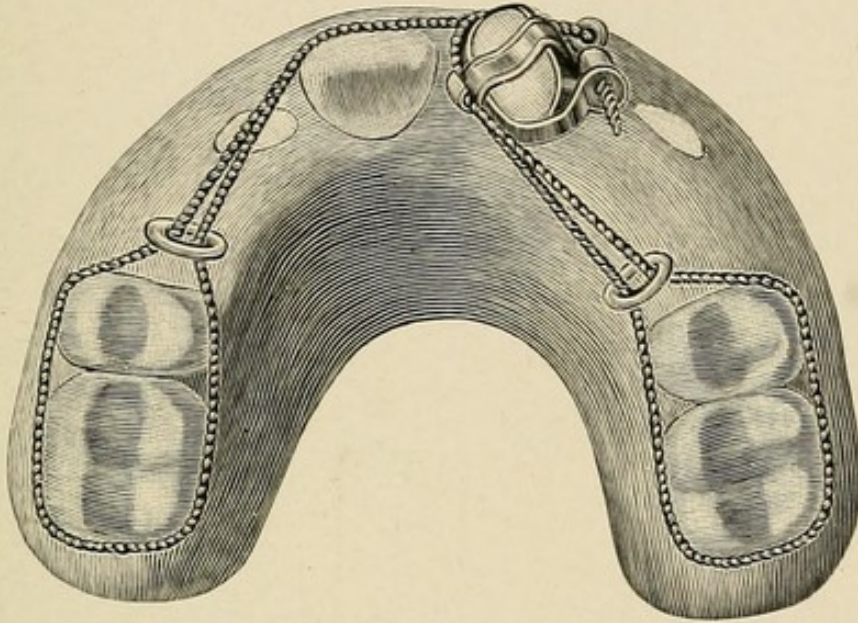
The ferrule design, which, in reality, was a plain band, proved the most efficacious of these, and still continues in use. With the introduction of the adjustable form of anchor band, it was claimed that an accurate adjustment was more readily obtained. Owing to the fact that anchorage is usually applied to the molars, the crowns of which are less accessible than those of the anterior teeth, the adjustable designs readily met with great favor. Furthermore, the wide use of stock appliances aided materially in their adoption.

As stated, Linderer was probably the first to use an adjustable band. A decided advance in design is shown in Fig. 105, which was introduced by Schange in 1841.¹ He adopted the principle of the threaded bar, or screw, for adjusting the size of the band. Later, in the hands of Farrar, it passed through various stages (Fig. 106). The screw-block on the buccal surface was modified by Patrick (Fig. 107) and Angle (Fig. 108) into the tube in use today.

¹ *Precis sur le redressement des dents*, Paris, 1841.

Even this tube, which provides anchorage for the alignment wire, has been modified in design by Knapp, Kemple, Ottolengui, and others. An ingenious modification is shown in the design by Lukens (Fig. 109), in which the tube is threaded

FIG. 105



Schange's adjustable band on the central.

FIG. 106

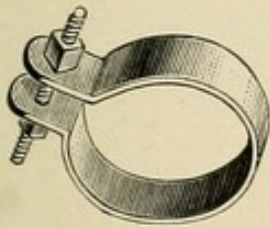
Farrar's adjustable anchor
band for molars.

FIG. 107

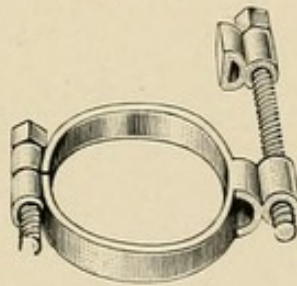
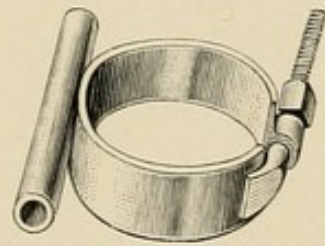
Patrick's adjustable
anchor band.

FIG. 108

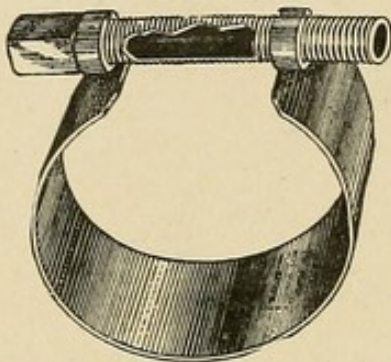
Angle's adjustable anchor
band.

on its outer surface and thus made to serve as the screw-post, which does away with the attachment of the latter on the lingual surface.

Fig. 110 shows the so-called all-closing, or continuous

form suggested by Barnes. This feature is widely used today, because it constitutes an additional precaution against caries of the enamel. The recent introduction of the "seamless band" has been favorably received, especially

FIG. 109



Lukens' adjustable anchor band.

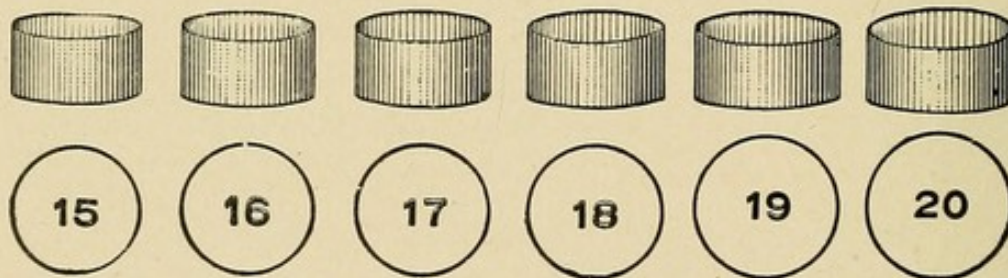
FIG. 110



All closing or continuous band. (After Barnes.)

for the treatment of young patients. The advantage of a smooth lingual surface, as emphasized by Lukens, has prompted manufacturers to furnish seamless bands in such a variety of sizes that an accurate fit is readily obtained in most instances (Fig. 111).

FIG. 111



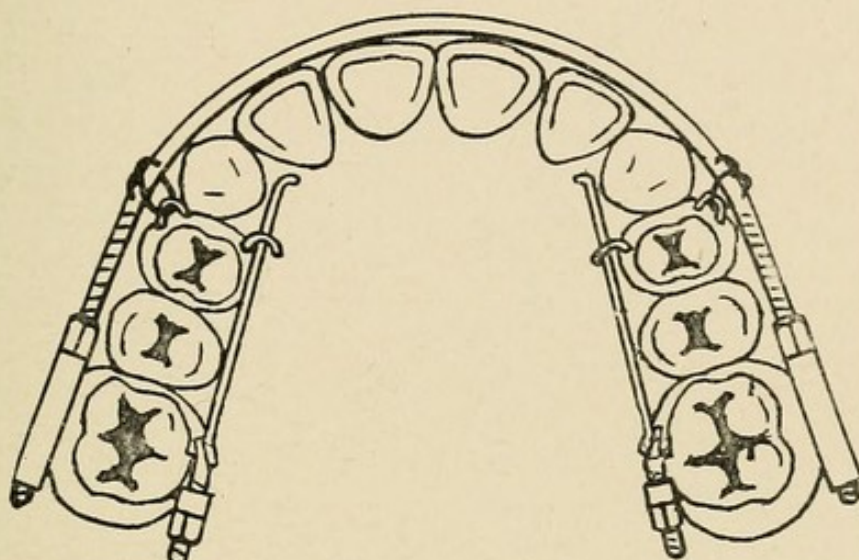
Seamless ferrules, from which non-adjustable anchor bands can be constructed.

The use of lingual extension wires, as advocated by Hawley,¹ for the buccal movement of teeth mesial to the first molars (Fig. 112), marks another step in advance.

¹ Proc. Amer. Soc. Orthodontists.

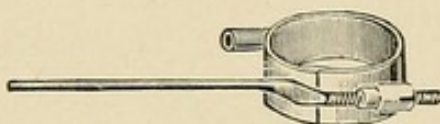
Pullen has recently suggested a modification of this principle by extending the screw-post (Fig. 113).

FIG. 112



Lingual extension wires. (After Hawley.)

FIG. 113



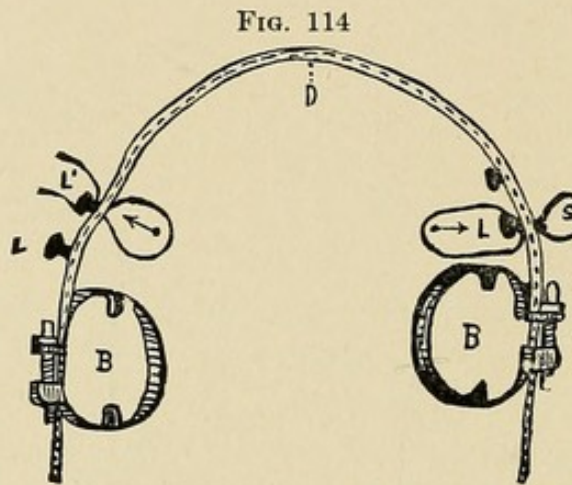
Showing continuation of the clamping bolt. (After Pullen.)

THE ALIGNMENT WIRE

According to Farrar, this element was used in the earliest times, when it was made of wood or strips of bamboo. Fauchard was probably the first to apply it in the shape of a metal strip, as shown in Fig. 95. Many of the mechanisms employed by Fox, Schange, Carabelli, Harris, Patrick, Farrar, and others embodied this element, when it was called the *labial bow*. In the design by Flagg (Fig. 97) it is seen in its simplest form. Farrar and Patrick employed it frequently, and developed many of its attachments.

Fig. 114 shows the attachment of spurs for preventing the slipping of ligatures, as advocated by Farrar.¹ This detail has recently been improved by Lourie, whose spur-cutting pliers for this purpose are excellent (Fig. 115).

Angle's conclusive demonstrations regarding its wide range of applicability mark an epoch of no small moment in the treatment of malocclusion. Through his efforts we have learned that this simple wire establishes a line of



Farrar's spur attachments to the alignment wire to prevent ligatures from slipping.

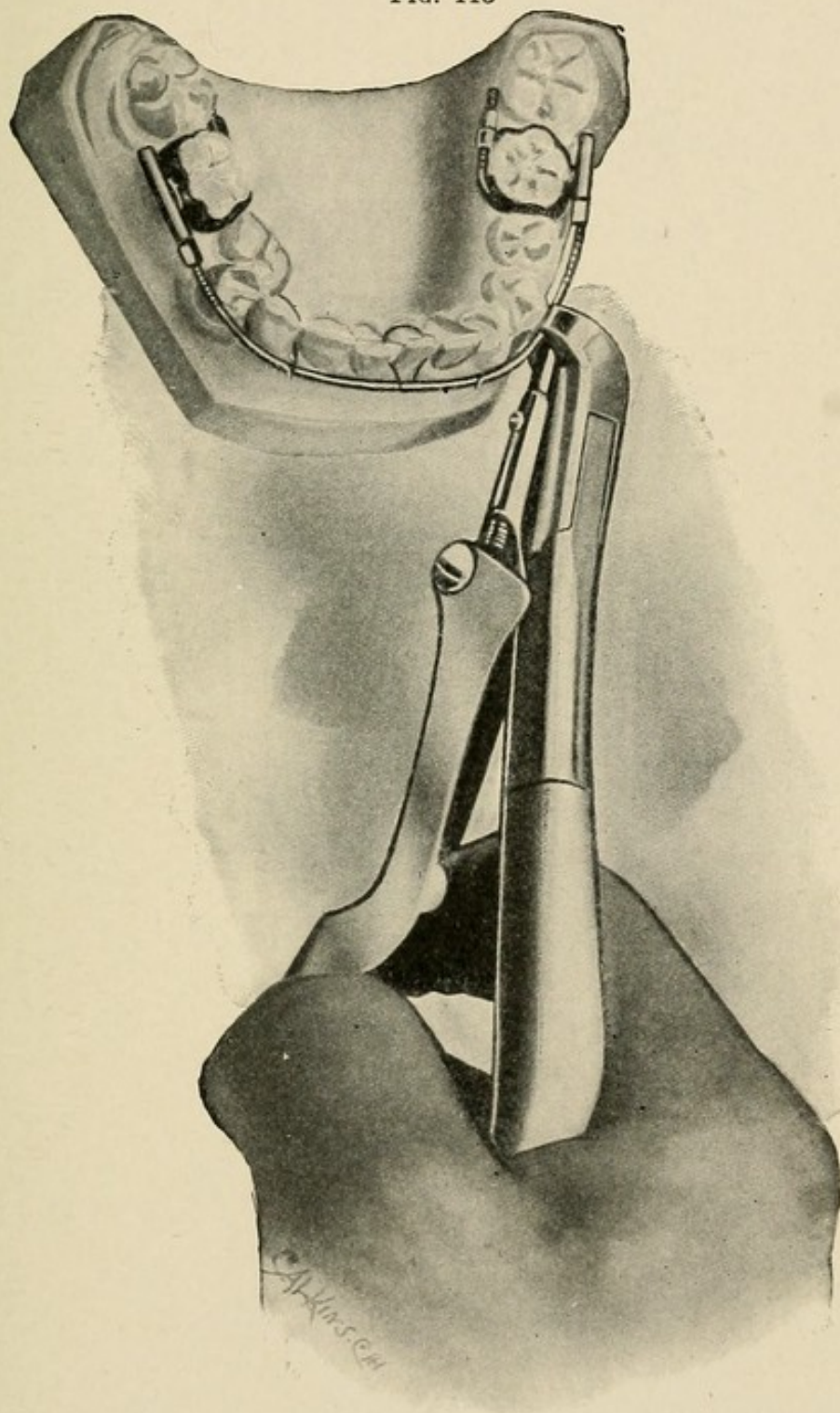
alignment for the correction of arch form in advance of tooth movement; that it serves as a working basis for most of the individual tooth movements; that it may be utilized both for expansion and contraction of the dental arch; that it is the most efficient means, when properly manipulated, for arch movement; and finally, in the first stages of retention, it serves as an excellent retaining device.

The plain form, with threaded ends and nuts, answers every purpose in most cases, and Nos. 16 and 18 gauge represent the sizes in general use. Occasionally, in patients above ten years of age, the dental arch may be so contracted

¹ Irregularities, 1888.

that lateral expansion in the region of the canines can be more readily accomplished by the use of a divided wire (Fig. 116), a design advocated by Bethel and Pullen.

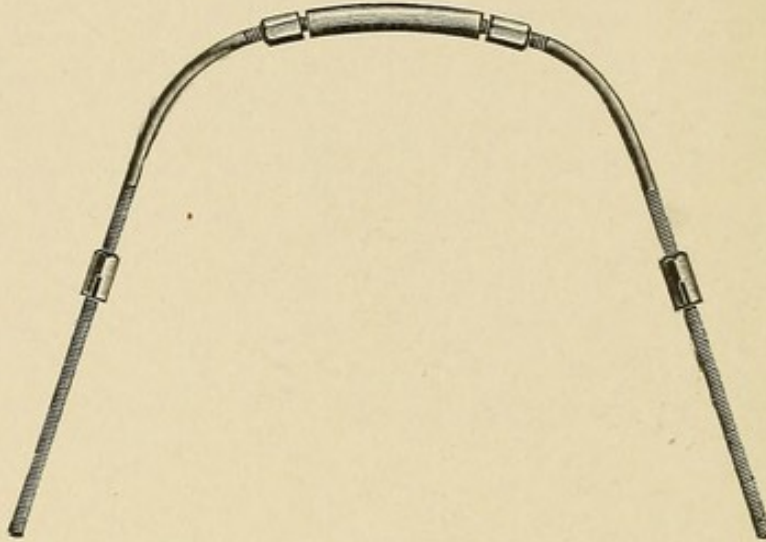
FIG. 115



Lourie spur-cutting pliers.

An attachment of great value (Fig. 117) is that known as a *tube hook*. The tube fits the wire accurately, and is attached

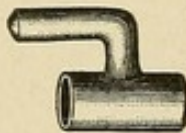
FIG. 116



Divided alignment wire. (After Bethel and Pullen.)

by means of solder in the region of the canines. This hook engages elastic bands, the uses of which are fully described in the chapters on Treatment.

FIG. 117



Intermaxillary tube hook. (After Angle.)

LIGATURES AND ELASTICS

The use of ligatures for tooth movement have been advocated from time immemorial. In the works of Fauchard, Bourdet, Jourdain, Linderer, etc., we find illustrations showing the manner of their application. Silk and linen threads were first employed for this purpose, as well as wires of iron, gold, and silver.¹ Angle, in connection with his appli-

¹ Pfaff, Lehrbuch.

ances of German silver, advocated the use of soft brass wire, ranging in size from 25 to 30 gauge. On the other hand, many operators now prefer the so-called silk grass line, recommended by Hawley.¹ This revival of the silk ligature is prompted largely by the present use of the noble metals, the rapid oxidation of which the brass wires promote; and by the tendency toward earlier treatment, when the force required is considerably less.

The use of elastic rubber bands was advocated by Fox in 1814, who employed them in his practice. Lachaise, Tucker, Kingsley, and others continued their use to the present. While they are still largely employed for the various movements of individual teeth, their greatest value is in connection with arch movement. Case, Lourie, Baker, and Angle have recently developed this important detail of treatment, the importance of which can hardly be overestimated. (See Chapters XVI and XVII.)

MISCELLANEOUS ACCESSORIES

Among the countless mechanisms that have been designed for the treatment of malocclusion, there have been very few, indeed, which have achieved survival. As intimated in Chapter VIII, only rarely are we obliged to use appliances other than those which can be constructed out of the elements enumerated above. And in these rare instances a very few additional elements will suffice, such as the lever, the skull cap for extramaxillary or occipital anchorage, the "Case contouring apparatus" for the bodily movement of teeth, etc. The use of these can best be described in the chapters on Treatment.

¹ Proc. Amer. Soc. Orthodontists,

CHAPTER X

PRINCIPLES OF APPLICATION

IN the application of every appliance we are forced to comply with certain fundamental mechanical requirements. The main points to be considered in this connection are: (a) The teeth to be moved (or the points of attack), (b) the forces employed (or the means by which movement is affected), and (c) the utilizable resistances (or anchorage of the means). Pullen¹ has defined anchorage as "the resistance selected as a base from which force is to be delivered for the movement of teeth." Körbitz² has very aptly stated that "The art and difficulty of orthodontic technique does not consist in the production of the acting forces, but of the advantageous utilization of the resistances present." Continuing he says: "In the masticating apparatus there is no fixed point from which we are able to act upon the individual teeth. The production of a movement always requires a point of anchorage; the forces employed act with the same power upon this point of anchorage as upon the point to be moved."

FORMS OF ANCHORAGE

The resistances utilized in the movement of teeth may be classified as follows:

¹ Operative Dentistry, Johnson.

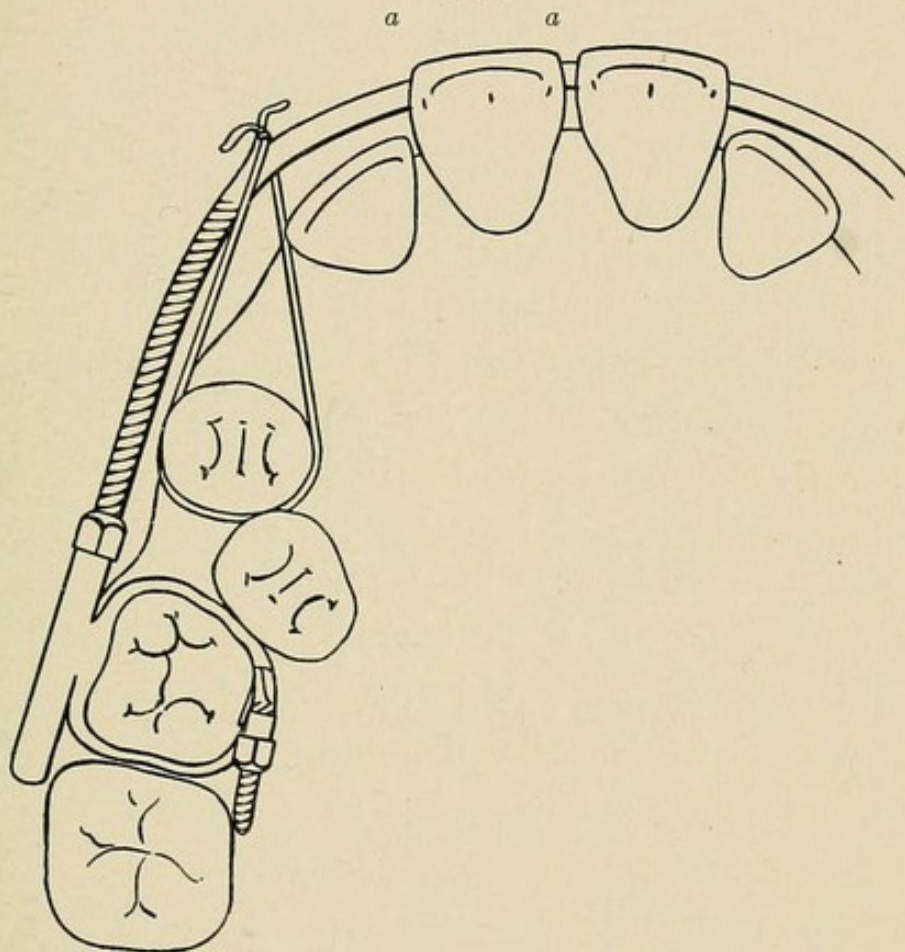
² Kursus der Orthodontie.

(a) As to method, into *stationary* and *reciprocal*.

(b) As to source, into *intramaxillary*, *intermaxillary*, and *extramaxillary*.

Stationary Anchorage.—This term is a merely relative one, since there is no absolutely fixed point in the dental

FIG. 118



Exemplifies stationary and reciprocal anchorage.

arches. It may be described as a rigid resistance at “the point of departure,” which may be due to the greater size and more abundant osseous support of the tooth utilized, to the manner of attachment of the appliance, or to the direction of the force employed.

The appliance shown in Fig. 118 is intended to effect a

mesial movement of the first bicuspid. This is accomplished by the use of a ligature attached to the alignment wire. The latter is anchored to the molar by means of an anchor band. If the nut on the wire is brought to bear upon the mesial end of the tube, the molar exemplifies stationary anchorage. Besides being larger, and offering greater resistance than the first bicuspid, it has the additional support of the second molar. The cuspid has not yet erupted, and hence the resistance mesial to the first bicuspid will yield. On the other hand, if the crown of the first bicuspid were inclined distally, and the first molar were unsupported by the second, the tendency for a distal movement of the first molar might readily assert itself.

Reciprocal Anchorage.—A further study of the case reveals a labioversion of the central incisors. The aim will be to move these lingually, which can easily be accomplished if the nut is released at the mesial end of the tube. By so doing, the alignment wire will glide distally within the tube until it bears upon the labial surfaces of the incisors at the points *a a*. The load imposed by the tension of the ligature from the bicuspid is now shared by the incisors, whose combined resistance is less than that of the molars. Hence we no longer have stationary anchorage; the incisors, like the bicuspid, will yield under this stress. We term this reciprocal anchorage, by which means the force is utilized at both “the point of attack” and “the point of departure.”

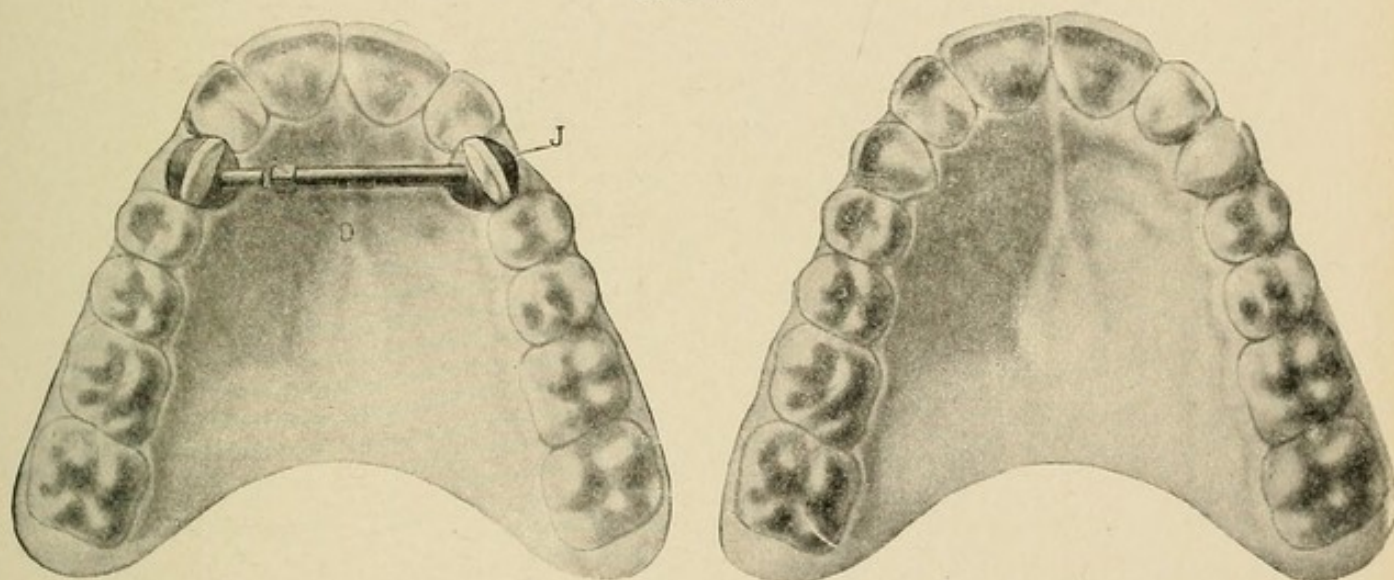
“In reciprocal anchorage the reciprocity of the resistance points is never quite perfect. This is due to the diversity of the resistances and to the variety of the deviations.”
(Körbitz.)

If we release the nut prior to ligating the bicuspid, and

then subsequently tighten it, we can utilize both forms simultaneously. Indeed, this is the aim in most instances. The use of stationary anchorage *per se* is very limited, and rarely as satisfactory as the reciprocal form. Furthermore, if the anchor teeth are not carefully guarded, they rarely remain stationary.

Intramaxillary Anchorage.—Many of the required tooth movements can readily be performed by the use of anchor bands and the alignment wire in combination with ligatures.

FIG. 119



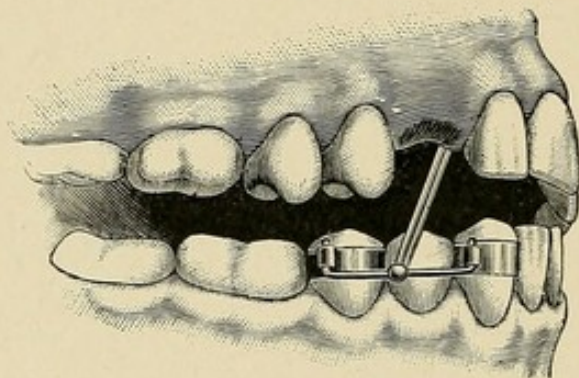
Reciprocal anchorage.

Previous to its insertion within the buccal tubes, it is bent to that ideal form we wish ultimately to establish. The teeth in each lateral half are then forced into normal alignment by ligation, and by the alternate and simultaneous use of stationary and reciprocal anchorage. Occasionally we seek the necessary resistance on the opposite side of the dental arch, as shown in Fig. 119. The two upper cuspids being similarly malposed, we resort to the most direct method of the jack-screw. This is a good example of reciprocal anchorage, resulting in the simultaneous movement of the cuspids.

In all cases where the resistances selected are in the same dental arch as the teeth to be moved the term intramaxillary anchorage is applied.

Intermaxillary Anchorage.—There are many forms of malocclusion which cannot be so readily disposed of, and for which we are forced to seek anchorage in the opposing jaw. Whenever we employ an anchorage thus located, we term it intermaxillary anchorage. This is also used in both the stationary and reciprocal forms.

FIG. 120



Direct intermaxillary anchorage. (After Angle.)

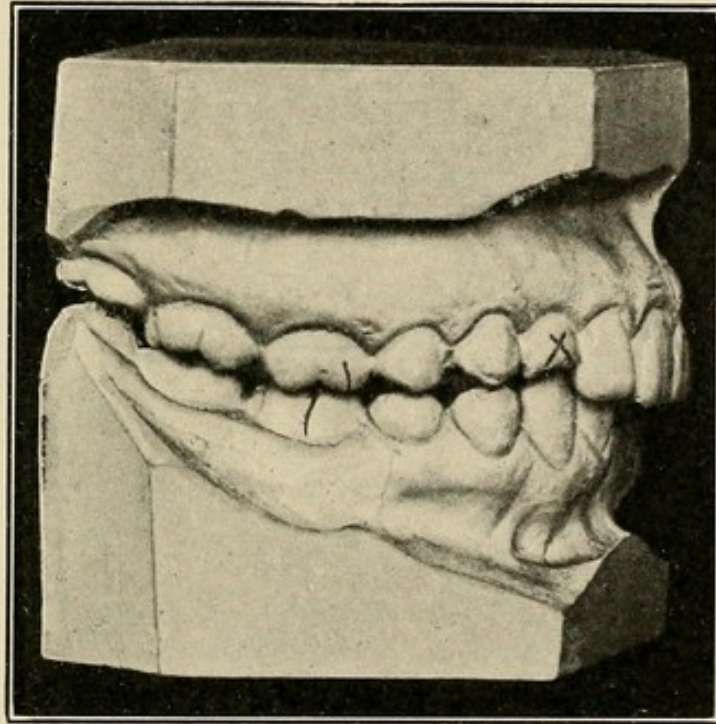
In the case shown in Fig. 120 we observe a lingual perversion of the right upper cuspid. After removing the superimposed gum tissue and providing an attachment to the cuspid, we can force its eruption by means of a small elastic-rubber ring anchored to the lower bicuspid and cuspid. This constitutes the simplest and most direct form of intermaxillary anchorage after the manner indicated by Angle¹ in 1891.

Fig. 121 shows a similar case complicated by a mesioversion of the right upper bicuspids and molars, and linguoversion of the permanent canine due to prolonged retention

¹ Dental Cosmos, September, 1891.

of its temporary predecessor. Hence the first step in the treatment is a distal movement of bicuspids and molars. This cannot be accomplished in the ordinary manner; the resistance offered by the incisors to the mesial is not equal to the task. Nor would an anchorage point on the opposite side of the same dental arch be of any value. We therefore search for the necessary resistance in the opposing arch, as suggested by Lourie¹ (Fig. 122). In this instance we secure

FIG. 121



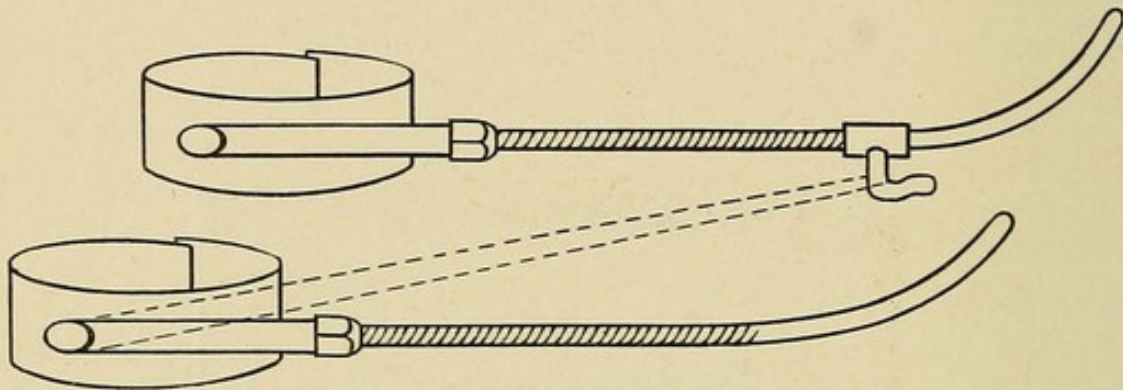
Case requiring the use of intermaxillary anchorage for its correction.

stationary anchorage in the lower by ligating several of the anterior teeth to the alignment arch and so adjusting the nut that it comes into contact with the mesial ends of the buccal tube. In the upper arch the nut is adjusted so that the alignment wire does not touch the labial and buccal surfaces of the teeth mesial to the molars. Hence the

¹ Amer. Soc. Orthodontists, 1902.

combined resistances of the lower teeth, by means of the elastic bands, is thrown against the upper molar, forcing it distally. After sufficient distal movement of the molars has been gained, the attachment is changed to the bicuspids and these in turn moved distally.

FIG. 122

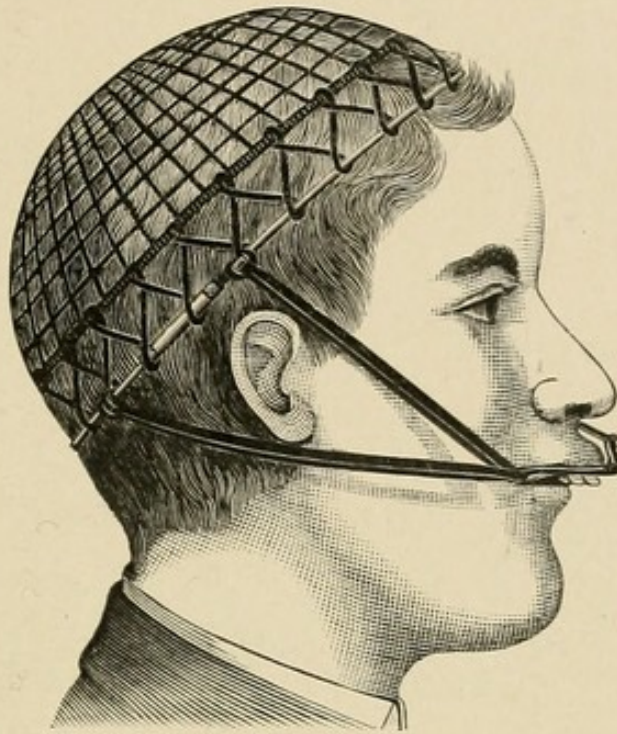


Mechanism employed for intermaxillary anchorage.

Recent advances in the use of intermaxillary anchorage have so enlarged its field of application that it has become the most valuable of all. The wide range of its applicability constitutes one of the most important steps in orthodontic progress; without it, the correction of arch malrelation would be extremely difficult, if not impossible. (See Chapters XVI and XVII.)

Extramaxillary Anchorage.—Prior to the perfection of intermaxillary anchorage, many of the pronounced forms of malocclusion (such as mesiocclusion and distocclusion) were treated by means of occipital anchorage. This was obtained by the wearing of a cap, or network with frame, adjusted to the back of the head, to which the chin cap or cross-bar was attached by means of heavy elastics (Figs. 123 and 124). This form constitutes the best type of stationary anchorage, but unfortunately is under the patient's control. It is extremely annoying and conspicuous, and is now

FIG. 123



Extramaxillary anchorage. (After Angle.)

FIG. 124



Extramaxillary anchorage. (After Angle.)

rarely employed, owing to the recent advances in the use of intermaxillary anchorage.

To the beginner, a discussion of the problems of anchorage may seem as a mass of trivial reflections; in reality, they constitute some of the hardest lessons to be learned. A mastery of these principles enables one to accomplish truly remarkable results with the very simplest mechanisms. Ignorance, on the other hand, yields consequences quite unexpected. An exhaustive study of the principles of anchorage, theoretical as well as practical, is therefore advisable. "They must be transfused into our flesh and blood, so that we may employ them automatically in our practice; just as we use the multiplication table in calculation." (Körbitz.)

CHAPTER XI

DETAILS OF APPLICATION

IN preceding chapters many of the preliminaries for treatment were described. The next step is a detailed consideration of the plan of treatment, which should always be carefully worked out beforehand and in accordance with a definite routine. An operator must always be mindful of the many necessary details, and then firmly resolve to carry them out.

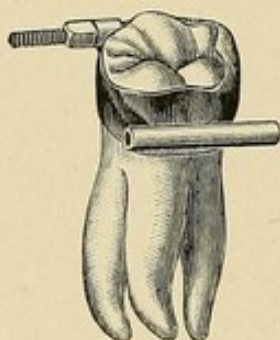
BANDS

The Anchor Band.—As intimated in Chapter X, a compliance with fundamental mechanical principles is imperative; hence the anchorage of the appliance should receive first consideration. In view of the fact that this is provided in most instances by the use of anchor bands, the details of their application are important. A very limited experience readily emphasizes the fact that the first permanent molars are preferable to any other teeth in the arch for purposes of anchorage, owing to their large size and early calcification. Only in rare instances, owing to the absence of these teeth, are we compelled to utilize the second molars or bicuspid.

After a decision has been reached as to the teeth to be utilized, the selection of an anchor band should be made. The author prefers an all-closing adjustable band, as shown in Fig. 110. Prior to its insertion it is contoured to approxi-

mate the form of the tooth upon which it is to be placed. It is frequently necessary to bend the screw-post on the lingual side, so that it closely embraces the tooth to the mesial. In case the second molars have erupted, and lateral expansion in this region is indicated, it may be advisable to place the band so that the bolt will point in a distal direction (compare Fig. 118). The protrusion of the screw-post into the oral space toward the tongue is never necessary if care is exercised in the adjustment. The mesial portion of the band should always be forced well up under the gum,

FIG. 125



Shows correct adaptation of anchor band to a molar. (After Angle.)

and the distal slightly burnished over the distal marginal ridge to prevent displacement.¹ The tubes being soldered parallel with the borders of the band, this manner of adjustment will effect a proper occlusogingival alignment of the buccal tubes (Fig. 125).

In very young patients (owing to a superabundance of gum tissue), and in cases of infraversion of the molars, it is best to use a seamless band. This is first adjusted without a tube, which latter is soldered on subsequently.


All anchor bands should be of the proper size and accurately adjusted, and they should invariably be set with

¹ Angle, Malocclusion of the Teeth.

cement. Cementation is always deferred until the second sitting, when the anchor teeth are again thoroughly cleansed with pumice and washed with alcohol, the saliva excluded by means of cotton rolls, and dryness maintained.

The Plain Band.—The next step is to determine which teeth will require plain bands, and the various attachments for each band. The form of a tooth and its required movements will usually settle this. For most patients the adaptation of the band metal is readily accomplished; but if firmly established contact points interfere with the adaptation, it is best to separate the teeth by means of a separator, or by the insertion of tape, for twenty-four hours.

FIG. 126



Double end burnisher (Woodson No. 3).

After all the bands in one arch are thus prepared, they are laid to one side, and the anchor bands of that arch are adjusted. The patient is now dismissed, and during the interim prior to a subsequent visit the plain bands are constructed and finished. Upon the patient's return each band so constructed is placed upon the tooth for which it was prepared. This can usually be effected with the fingers and one or two gentle blows from a mallet on a band driver. A more accurate fit can now be obtained by frequent burnishing with the double end instrument shown in Fig. 126.

The bands are now removed without changing their form, and placed upon the operating table. Their inner surfaces are cleansed with alcohol, and the operating table prepared

for cementing them into place. The teeth to be banded are again thoroughly cleaned with powdered pumice, and a polishing point in the dental engine, after which they are isolated with a napkin or cotton roll. After washing the tooth with alcohol and drying with compressed air, the inner surface of the band is lined with a coat of cement and placed in position. The final adjustment is best accomplished with a band driver and mallet and the burnisher. The surplus cement is now removed and the exclusion of moisture continued until the remaining cement has thoroughly hardened.

In cases where there is considerable crowding, and where two or more adjoining teeth all require bands, the double thickness of metal in each interproximal space will occasionally interfere with their ready insertion. A good plan in such instances is to adjust the bands without cement, and to dismiss the patient for twenty-four hours, after which sufficient separation will have been gained.

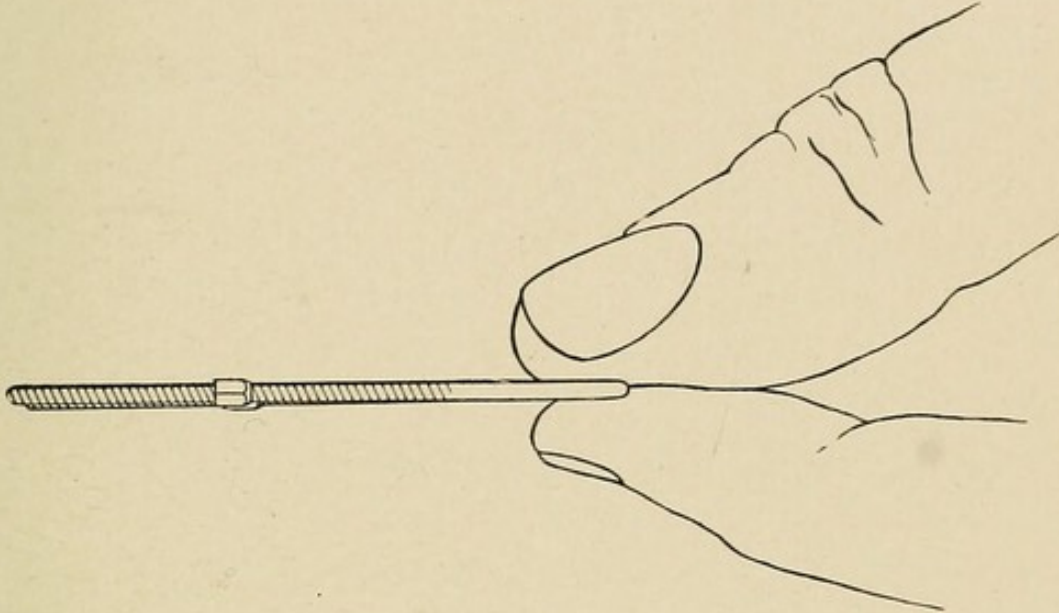
All bands should fit accurately, and all attachments should be well soldered and highly polished.

THE ALIGNMENT WIRE

Following the adjustment of the plain and anchor bands, an alignment wire is adapted to complete the appliance. The sizes in common use are of 16 and 18 gauge, and they are furnished sufficiently long for all cases. They are shaped to an ideal form by the manufacturer, and must, therefore, be bent to conform to the requirements of a given case and cut to exact length. This preliminary adaptation can partly be executed on the model, and partly by trial insertions in the mouth.

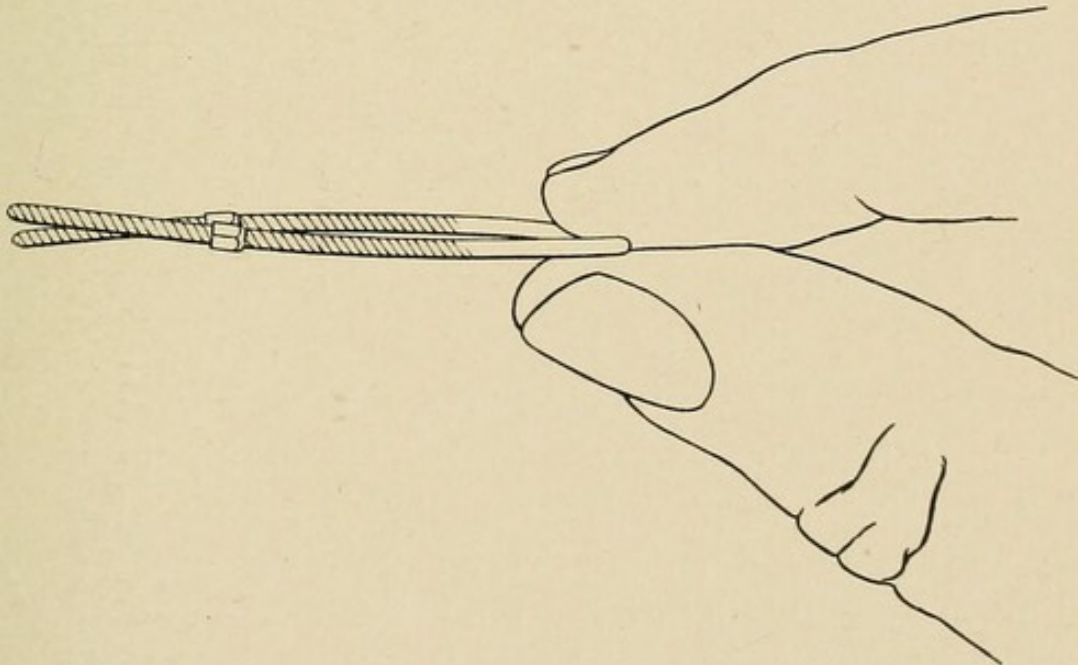
During the adjustment of the anchor bands the subsequent insertion of the wire within the tubes must be kept

FIG. 127



Properly shaped alignment wire.

FIG. 128




Improperly shaped alignment wire.

in mind. In other words, the two buccal tubes on opposite sides of the dental arch should occupy a common plane,

with the mesial ends of the tubes pointing slightly toward the gingival. Viewed in their buccal, or horizontal, aspects, the threaded ends of the wire appear as in Fig. 127. The careless adjustment of the buccal tubes and of the alignment wire will result in the improperly shaped appliance shown in Fig. 128.¹


Occasionally, it is permissible to bend the wire mesial to the nuts (Fig. 129), or in the region of the cuspids (Fig. 130), to effect the proper alignment in the incisal area. In

FIG. 129



Bending the wire immediately mesial to the buccal tubes to gain correct alignment.

FIG. 130



Bending the wire in the region of the cuspids.

cases where intermaxillary anchorage is employed, it is best to avoid this, and to procure correct alignment by resoldering the anchor tubes.

Viewed from an occlusal aspect, the free ends of the alignment wire must again receive careful attention. A proper relation to the dental arch can readily be secured by bending with a pair of clasp pliers, and by repeated trials of one end within a tube, as shown in Figs. 131 and 132. By means of the pliers we can produce an expansion or con-

¹ Körbitz, Kursus der Orthodontie.

traction of the wire, in whole or in part, depending on their position and manner of application.¹ (Figs. 133 and 134.)

FIG. 131

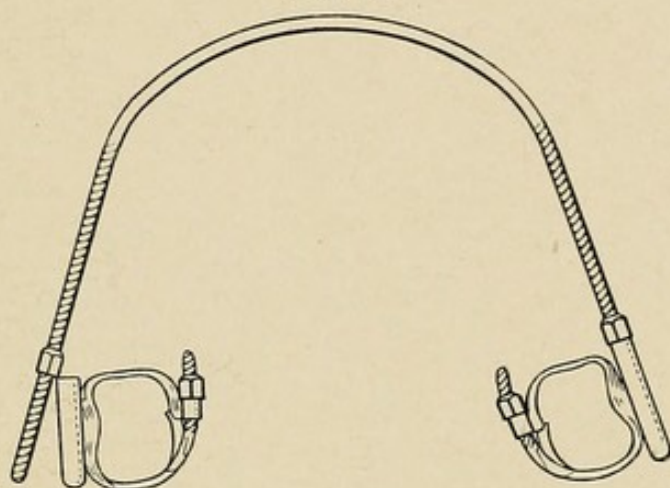
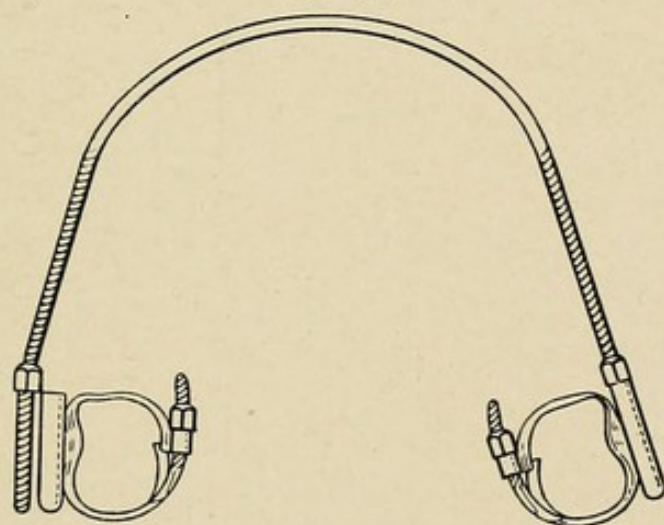


FIG. 132

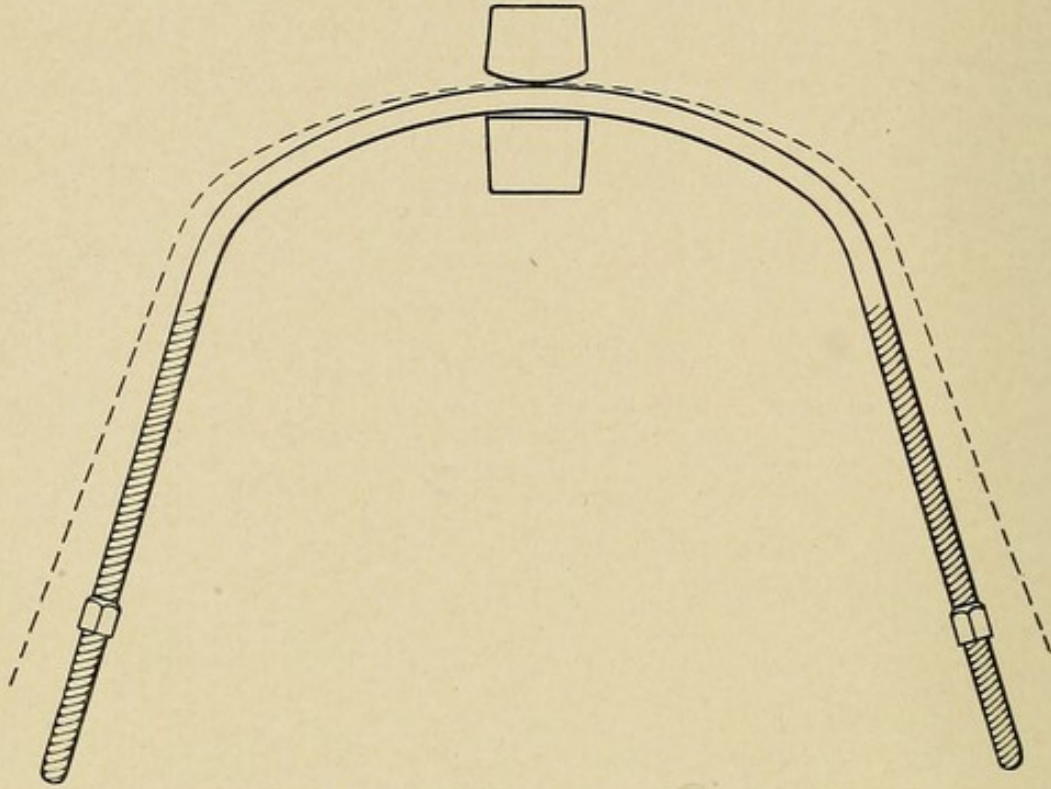


Shows the adaptation of the ends of the wire.

After a correct adaptation has been effected, the wire is inserted in both tubes and allowed to remain in a merely passive state, our first aim being to accustom the patient to its presence within the mouth. In cases where it must encircle an extreme labioversion of one or more teeth it may be necessary to give it a decidedly abnormal form, to avoid

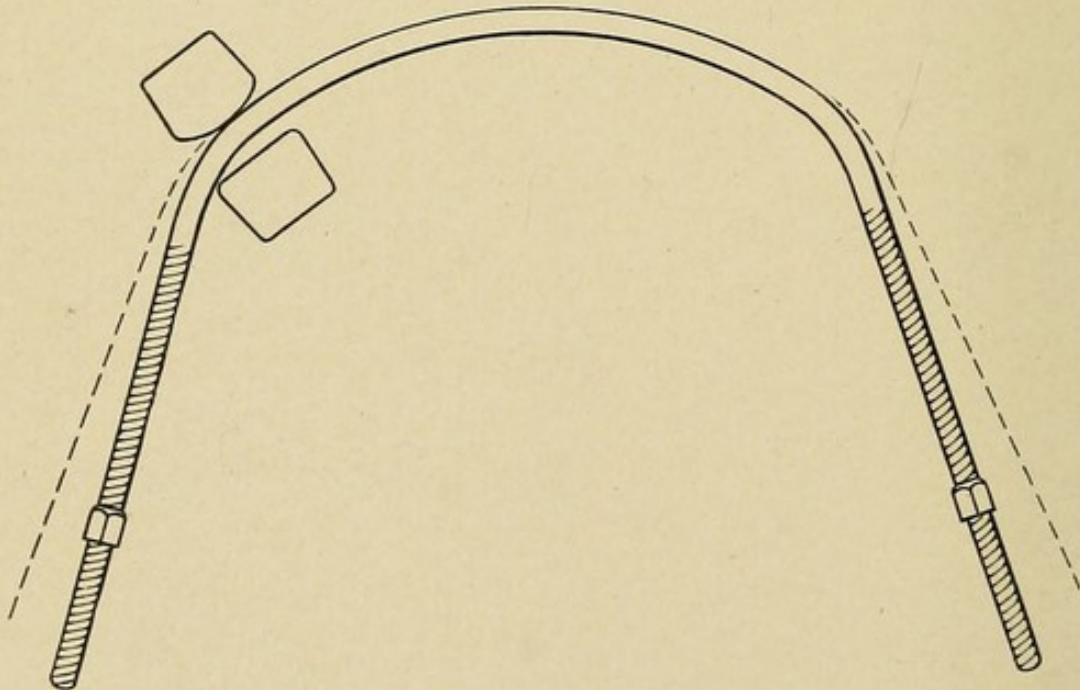
¹ Körbitz, Kursus der Orthodontie.

FIG. 133



Producing an expanding action over its entire length.

FIG. 134



Restricting the expanding action; by reversing the beaks of the pliers a contracting action can be obtained.

undue prominence. Only subsequently, after considerable movement of the adjoining teeth, do we give it that ideal form we wish to establish.

LIGATURES AND ELASTICS

Many movements of the teeth are accomplished by the use of ligatures. As previously stated, the silk grass line (which comes in three sizes, heavy, medium, and light) is widely used for this purpose. Occasionally, owing to the position and form of a tooth (particularly lower cuspids), a wire ligature is more effective. These are usually from 25 to 30 gauge thick, and made of soft, annealed brass.

All ligatures should be of generous length, to permit of a firm grasp while applying them. Wire ligatures are tightened by twisting, and silk ligatures by tying in a surgical knot. The more important ways of using a ligature are shown in Fig. 102. Owing to the absorption of moisture, the silk ligature continues in its tension for a considerable period, often a week or more. The spring of the alignment wire also aids in prolonging their action. Wire ligatures can be tightened by additional twisting, thus obviating their frequent renewal.

Elastic rubber bands are widely used in present-day practice, particularly in intermaxillary anchorage. Occasionally, they are of value in intramaxillary anchorage, *e. g.*, in rotation of a bicuspid (Fig. 163). A liberal supply should always be kept in stock, varying in size from an "election ring" to those made from $\frac{1}{8}$ -inch pure rubber tubing. The former are used principally in the treatment of mesiocclusion and distocclusion, for reënforcement of anchorage, and for reduction of extreme labioversion of the upper incisors. The

small sizes are employed for direct intermaxillary anchorage for the correction of infraversion (Fig. 120). In the latter method they are usually limited to the hours of sleep, while in the former they can be worn constantly. The patient should be taught the manner of their application, and provided with a sufficient number for frequent renewal. Owing to the fact that their action is constant, they require careful supervision to prevent undue displacement of the anchor teeth, as well as the teeth to be moved.

CHAPTER XII

PRINCIPLES OF RETENTION

TISSUE CHANGES CAUSED BY TOOTH MOVEMENT

DURING tooth movement a number of very important changes are produced in the tissues of attachment. All authorities are agreed that the immediate result of the application of force is a compression of the fibers of the pericementum on the side toward which a tooth is moved, and a stretching of those on the opposite side. In the first stages following pressure a feeling of pain is frequently induced, due to mechanical irritation of the nerves in this membrane. This speedily ceases if the pressure is constant, and is followed by hyperemia. Later, an absorption of the resisting alveolar plates is produced by osteoclasts, or "bone-destroying" cells, which make their appearance. The mechanism of this process of destruction is not yet fully understood, though many theories have been advanced as to the probable cause of the molecular dissolution of the osseous support.

Some observers have maintained that in many instances a bending of the alveolar plates (and even fracture) takes place; and occasionally an opening of the maxillary suture has been induced by rapid lateral expansion of the upper arch for young patients.¹

The manifold functions of the pericementum exercise an exceedingly favorable influence during these serious stages

¹ See Proc. Amer. Soc. Orthodontists, 1911.

of destruction and the repair which follows. The deposition of bone on the side from which a tooth is moved is controlled by osteoblasts, or "bone-building" cells, but is far less rapid than absorption and tooth movement.

DEFINITION

Owing to the fact, then, that the osseous support of the teeth is more or less destroyed by the process of absorption, and the subsequent formation of new bone considerably prolonged, it leaves them suspended by their soft, pericemental attachments in greatly enlarged sockets. The length of this period of inadequate maintenance varies in different individuals, during which time the fibers of the pericementum tend to force the teeth back to their former abnormal positions. This necessitates the application of mechanisms for the purpose of *retaining* the teeth in their new positions until this tendency has subsided and socket repair has been completed. Retention may, therefore, be defined "as the maintenance of sufficient antagonism to the forces tending to cause the return of a corrected malocclusion to its original condition, to insure permanency of the normal relationships of occlusion which have been established." (Pullen.¹)

Other factors besides that of age which may influence the time required and the ultimate success of retention, are the general and oral health of the individual, the kind and extent of movement accomplished, the detection and removal of causative factors, and the occlusal contact established. Pathological conditions of the pericementum militate

¹ Items of Interest, April, 1907.

against successful retention. Nasal obstruction, pernicious habits, and other causative factors, when present, must always be removed or corrected. And Walkhoff¹ long ago pointed out that "the placing of the teeth into normal articulation (occlusion) is a fundamental postulate in the treatment of malocclusion, insuring permanent results." Or, as Angle² puts it, "It cannot be too strongly insisted upon that the permanency of the teeth in their new positions cannot be hoped for, regardless of the length of time the retaining devices have been worn, unless such occlusion has been established as will enable the inclined planes of the cusps to ultimately act in perfect harmony for mutual support."

In designing a retaining appliance it is imperative that we study the probable movement of each individual tooth in its tendency toward its original position. This can only be done by comparing the original models with the ideal that has been established. In the words of Angle, the underlying principle of design should be "*to antagonize the movement of the teeth only in the direction of their tendencies. Very slight antagonism is required, but its exercise must be constant.*"

The time required for successful retention varies from three weeks to three years, and in rare instances it is necessary to resort to permanent retention. All uncemented contact points of a retention appliance should be reduced to the minimum, to prevent caries of the enamel, and all bands securely cemented to the teeth to which they are attached.

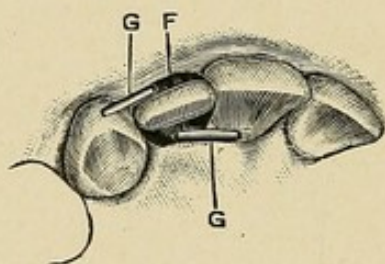
¹ Die Unregelmässigkeiten in den Zahnstellungen, Leipzig, 1891, p. 37.

² Malocclusion of the Teeth, 1907, p. 263.

MAINTENANCE OF TOOTH POSITION

Innumerable mechanisms for retention have been suggested, dating back to the ferrule, or plain band, used by Disarabode in 1823. The appliances in use today are the result of countless efforts, and they have passed through many modifications. There can no longer be any doubt, however, that plain bands and their many combinations, as suggested by Farrar, Guilford, Case, Angle, and others, constitute the best and most widely used designs.

FIG. 135



Plain band with two spurs for maintaining a corrected torsion. (After Angle.)

Fig. 135 shows a band (*F*) upon an upper lateral which has been rotated. After accurate adaptation the band is removed and one or two spurs (*G*) are attached with solder, as may be indicated. The spurs should be of sufficient length to engage the adjoining teeth (though not too long) after which the appliance is polished and set with cement. In most cases of malocclusion the treatment involves the movement of several adjoining teeth, hence the retainer should be planned so as to include as many as possible, thereby gaining simplicity of design. Figs. 136, 137, and 138 illustrate designs by Angle in which this principle has been carried out. They consist of plain bands united by

connecting wires, the dotted lines indicating the preëxisting malocclusions.

FIG. 136

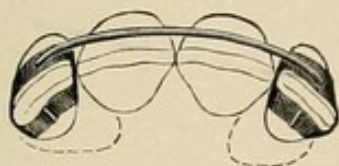

FIG. 137

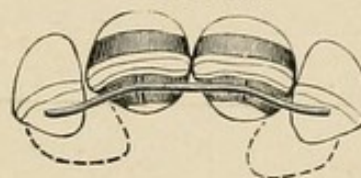
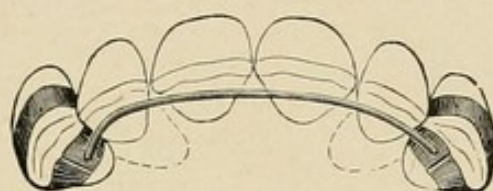


FIG. 138



Showing advantageous combinations of the plain band with connecting wires.
(After Angle.)

MAINTENANCE OF ARCH FORM

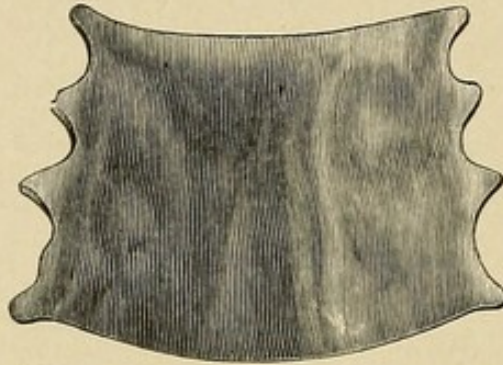
The treatment of malocclusion invariably implies the correction of arch form, and in all cases where this is extensive the posterior teeth are necessarily involved. Not infrequently this includes the buccal movement of bicuspid and molars, whose subsequent lingual tendencies must therefore be counteracted. In 1873 Farrar¹ introduced vulcanite plates for this purpose, which have been in use ever since (Fig. 139). Such plates have passed through a variety of designs, and many convenient attachments to them have been recommended. But as Guilford² says: "Their use is open to certain objections. All plates, used either for correction or retention, must be removed at frequent intervals for cleansing. The very necessity for their removal affords opportunity for the patient to

¹ Irregularities, i, 366.

² Orthodontia, 4th edition, p. 129.

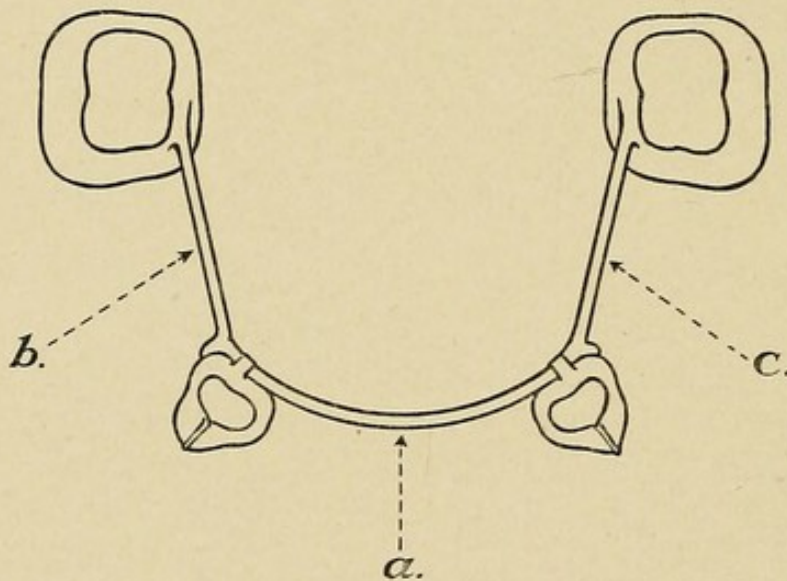
remove them at other times, and possibly forget or wilfully neglect to reinsert them for a longer or shorter period, thus causing delay in the reparative process."

FIG. 139



Vulcanite plate advocated for maintenance of arch form in the posterior teeth.

FIG. 140



Retention apparatus embracing the entire arch.

Owing to their unreliability, they have therefore been largely discarded and replaced by non-removable appliances. For maintaining the corrected arch form the lingual extension wires advocated by Case, Watson, and Lourie have found general favor. Fig. 140 shows the author's modification, and consists of two molar bands and an 18- or 20-gauge

iridioplatinum wire constructed in three sections. Section *a* accurately follows the arc described by the six anterior teeth, and its ends are extended into the interproximal spaces distal to the cuspids. Sections *b* and *c* connect this with the anchor bands. The bands on the cuspids are provided with spurs to prevent displacement of the wire, but are not attached to it. These bands are cemented into place prior to inserting the remaining apparatus. This appliance permits of many modifications, which will be referred to in the chapters on Treatment.

MAINTENANCE OF ARCH RELATION

The correction of arch malrelation (mesio- and distoclusion), without resorting to the extraction of permanent teeth, probably dates back to Catalan's *planum inclinatum* and Kingsley's *bite-plate* for "jumping the bite." Recent advances in the

FIG. 141

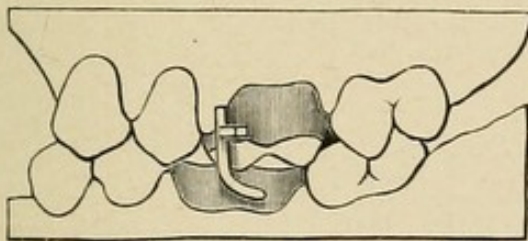
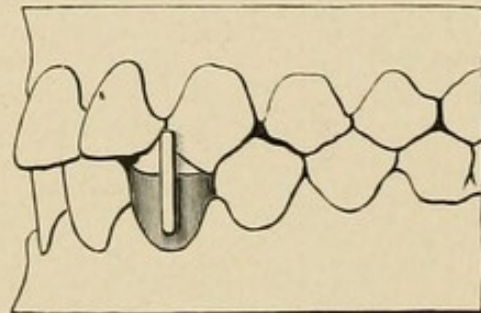


FIG. 142



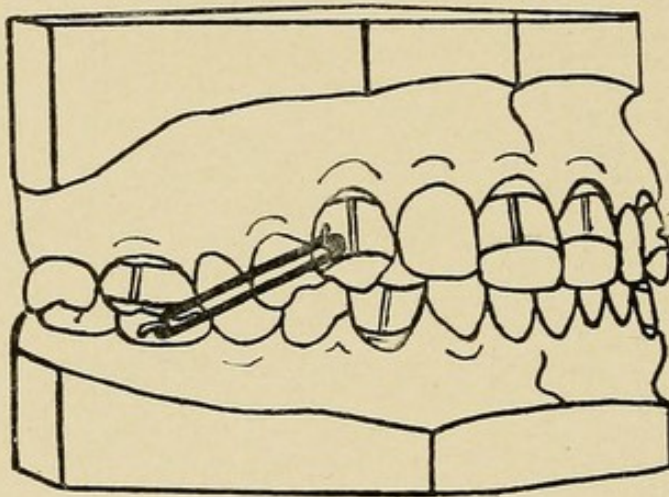
Antagonizing spur retainers. (After Angle.)

treatment of these deviations necessitated improvements in the methods of retention. The principle of this inclined plane in the form of antagonizing spurs (Figs. 141 and 142) has been advocated by Angle for this purpose. This method imposes a severe strain upon the anchor teeth, and frequently results in their displacement. Many operators have sought to avoid this, and now place chief reliance in a continuation of

the intermaxillary anchorage used in correction, though in a weakened and modified form.¹

Fig. 143 shows an appliance designed for this purpose in a case of bilateral distoclusion. Each arch is provided with an appliance for the maintenance of the corrected arch form. On the upper, canine bands with delicate hooks of 20-gauge iridioplatinum wire are provided for the attachment of light elastic rings. The latter are stretched to hooks on the buccal surfaces of the lower molar bands, and

FIG. 143



Showing the continuation of the intermaxillary elastic for the maintenance of a corrected distoclusion. (After Pullen.)

are worn at night. During the last stages of retention the elastics are worn on alternate nights.

In mesioclusions the attachments are placed on the lower cuspid and upper molar bands, and the stretching of the elastics is reversed. In unilateral deviations the elastic is worn only on the side originally abnormal. For further designs and their modification the reader is referred to the chapters on Treatment.

¹ See Watson, Proc. Amer. Soc. Orthodontists, 1908; Rogers, *ibid.*, 1909 and 1910.

PART II

THE METHODS OF TREATMENT

CHAPTER XIII

TREATMENT OF MALPOSITION OF THE TEETH

TECHNICALLY, every treatment of malocclusion embraces two or more of the following rudimentary principles: The correction of (*a*) tooth position, (*b*) arch form, (*c*) arch relation, and, conjointly, of jaw and face deformity. It has already been pointed out that a tooth may occupy any one of nine possible malpositions and their various combinations, and we now approach the technical details of their treatment.

LABIOVERSION AND BUCCOVERSION

The term *labioversion* is used to denote labially malposed incisors and cuspids, and *buccoversion* for buccal malpositions of the bicuspid and molars. These two terms are here grouped together because their treatment is similar, implying a lingual (or inward) movement in each instance. Formerly, the use of special apparatus for the treatment of these deviations was considered a necessity (Figs. 144 and 145); but it rarely happens that only one tooth is in mal-

occlusion. A careful study of occlusal relation usually leads to the discovery of malposition in adjoining and opposing teeth. Furthermore, the wide range of applicability of the alignment wire and its accessories (by utilizing the various forms of anchorage) has rendered it possible to carry out

FIG. 144

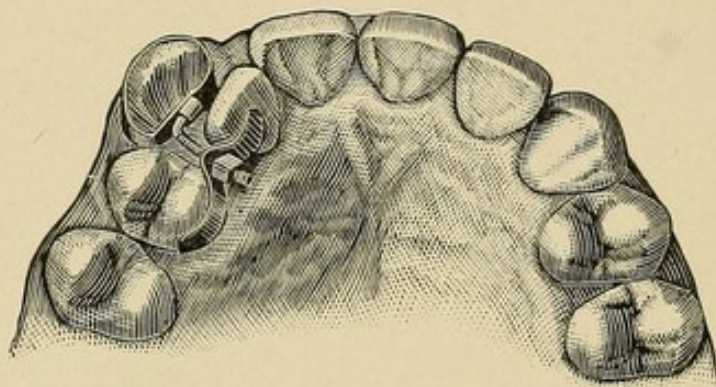
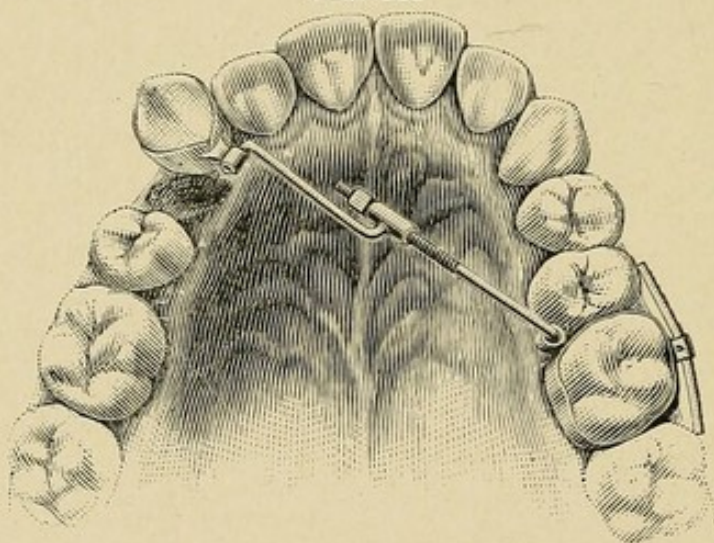


FIG. 145



Discarded methods for the correction of labioversion.

most lingual movements without resorting to the use of special mechanisms. In fact, it is our constant aim to avoid special appliances, and to design new uses for those already employed.

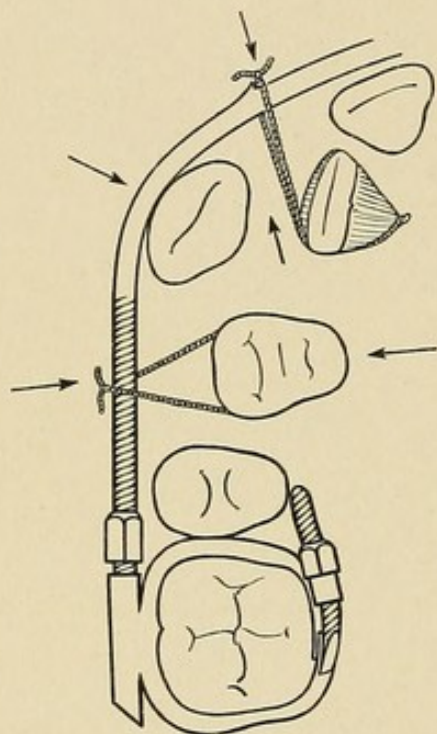
Happily, in most instances the teeth immediately mesial and distal to a labioversion are in linguoversion. The

undue prominence of a labioversion may thus be advantageous, permitting the use of reciprocal anchorage. In adjusting the alignment wire for a case as shown in Fig. 146, it invariably fails to come in contact with the labial and buccal eminences of the teeth adjoining the cuspid. The labial movements of the lateral incisor and first bicuspid are accomplished by ligation to the wire, which is so adjusted as to come in contact with the labial ridge of the cuspid. By previously releasing the nut mesial to the buccal tube, it will be permitted to rest passively, and glide "inwardly," within the tube. The force exerted upon the lateral and bicuspid will be equally delivered upon the cuspid, producing a lingual movement in the latter. In attempting a movement of this kind, it should always be remembered that the necessary mesiodistal spaces for each tooth must be within the range of possibility. Considerable expansion of the dental arch is, therefore, frequently indicated, and clearly impossible if we employ a mechanism as shown in Fig. 144. The extraction of the first bicuspid for the accommodation of the cuspid, as shown in Fig. 145, is rarely if ever considered justifiable.

Frequently, in crowded arches, the complete labial movement of the incisor and buccal movement of the bicuspid will not progress uniformly with the final adjustment of the cuspid, in which event we resort to the use of the rubber wedge (Fig. 147). The ligatures employed for the lateral and bicuspid, and the nut in front of the buccal tube, will provide stationary anchorage for the alignment wire, and thus afford the necessary resistance for the rubber. This is a very effective method for accomplishing lingual movements in cuspids, and through reciprocal action, labial movements of the adjoining teeth. A further utilization of this principle

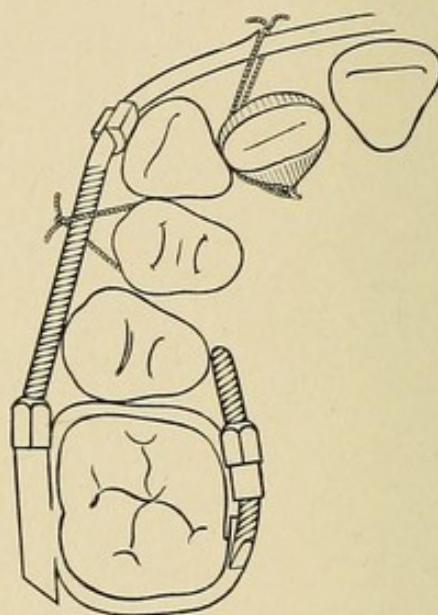
is shown in Fig. 148, for the correction of buccovercion of a second bicuspid and linguoversion of a first bicuspid. The use of intermaxillary anchorage for the reduction of labioversion of the incisors in neutroclusion and distoclusion is described in subsequent chapters.

FIG. 146



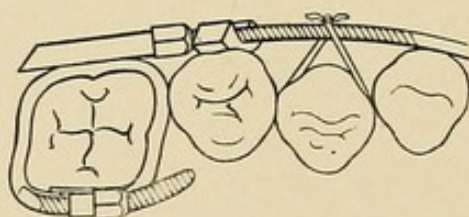
Illustrates the use of reciprocal anchorage.

FIG. 147



Intensifying the pressure by means of the rubber wedge.

FIG. 148



Advantageous utilization of reciprocal anchorage.

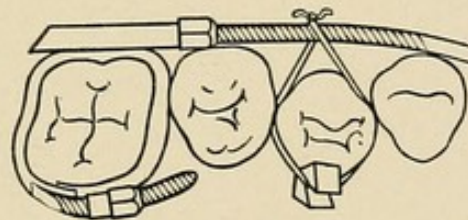
Buccoversion of the molars is comparatively rare, and can, in most instances, be corrected by utilizing the spring temper of the alignment wire. By reversing the beaks of the pliers shown in Figs. 133 and 134, a contraction of the arch can be effected.

LINGUOVERSION

This is a very common form of malposition, and the methods for its correction are numerous. One of the most powerful and satisfactory methods at our command is illustrated in Fig. 119. However, such instances are extremely rare; linguoversion is usually associated with labioversion of the adjoining teeth. Hence the alignment wire, by means of which we can accomplish all of the various movements, is to be preferred.

As previously intimated, outward movements can readily be accomplished simultaneously with lingual or inward movements. The tension of a ligature employed for this purpose may likewise be increased if used in combination with the rubber wedge, as shown in Fig. 149. The reciprocal form

FIG. 149

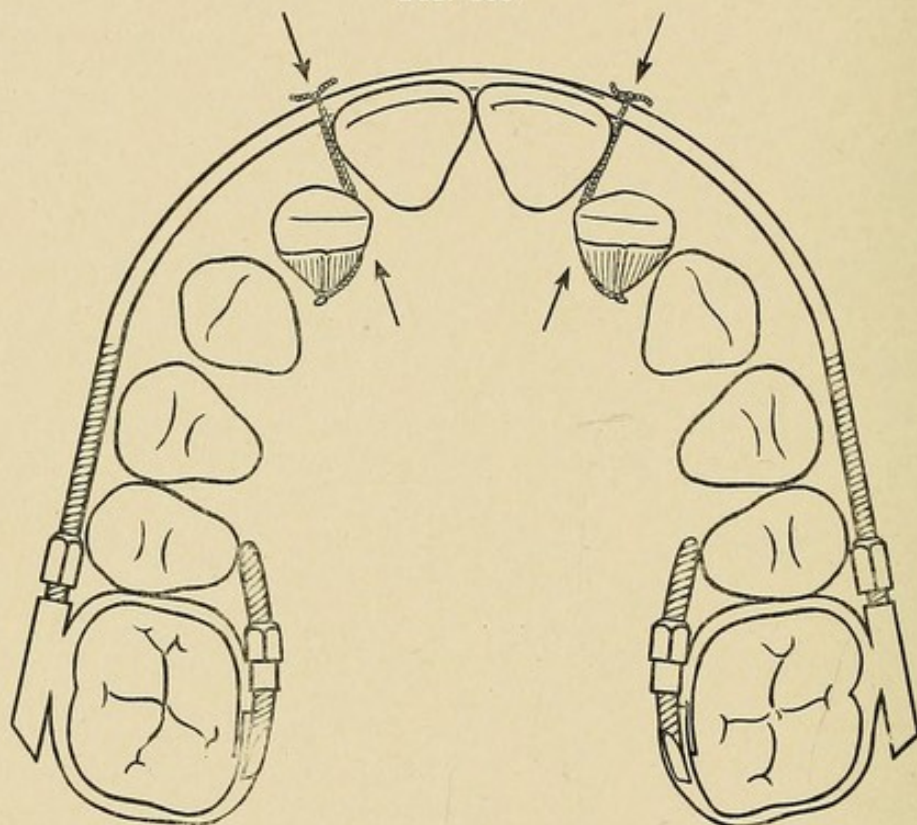


Correction of linguoversion.

of anchorage should be employed whenever possible, for if it is neglected at the outset the difficulties occasioned by the adjoining labio- or buccoversion are increased. For example, let us assume that we neglect such an opportunity in the case shown in Fig. 150, and attempt to correct the linguoversion of the lateral incisors by utilizing the stationary anchorage of the molars. Now, a more detailed consideration of the case reveals the labioversion of the central incisors. But suppose we had completed the labial move-

ments of the laterals before realizing this fact; it at once becomes clear that the reduction of the labioversion of the centrals has become more difficult. Hence, if we are mindful of our advantages in advance, we can, by releasing the nuts mesial to the buccal tubes (thus allowing the alignment wire to rest upon the labial surfaces of the centrals), utilize reciprocal anchorage.

FIG. 150



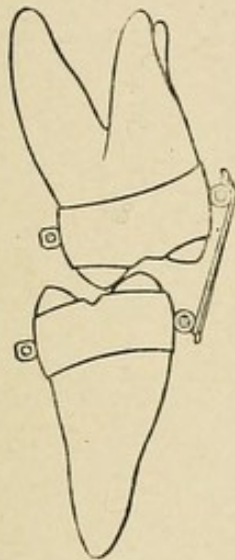
Reciprocal anchorage for correction of linguoversion and labioversion.

The buccal movement of molars is readily accomplished by utilizing the spring temper of the alignment wire (see Figs. 133 and 134). Such movements may be required on one side of either the upper or lower, or on both sides, and in both upper and lower arches simultaneously. But in either event the movement must be carefully guarded to prevent undue speed. Should it proceed too rapidly, it may be counteracted by reducing the expansion pressure

of the wire by reversing the pliers, and by resorting to direct intermaxillary anchorage, as shown in Fig. 151.

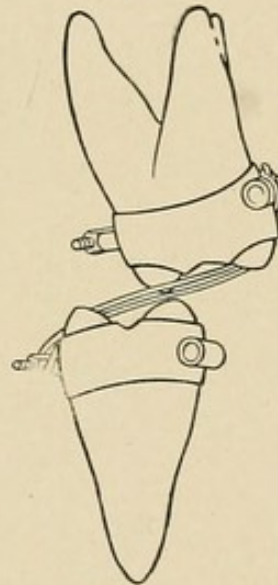
To prevent undue tipping of the incisors during labial movements, it frequently becomes necessary to adapt the alignment wire close to the gingival line, as shown in Fig. 153. In extreme cases a modification of the Case contouring apparatus, as suggested by Körbitz,¹ can be employed (Fig. 154). Again, unfavorable tipping may assert itself in rapid

FIG. 151



Intermaxillary anchorage used as an auxiliary in case of unexpected displacement of the anchor teeth.

FIG. 152



Increased stretch of the rubber in combination with alignment wires for the correction of linguoversion and buccoversion of molars. (After Reoch.)

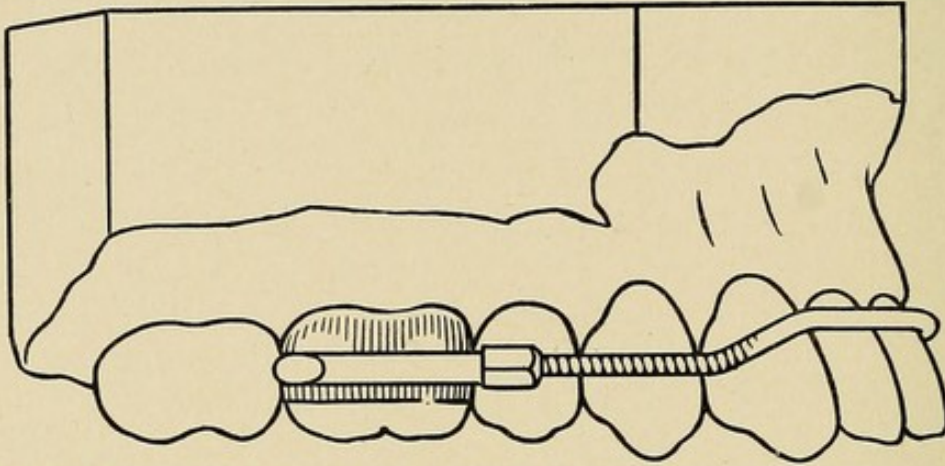
buccal movements of the molars, and thus cause extremely undesirable difficulties of occlusion. To avoid the use of the direct intermaxillary anchorage already referred to (which is annoying to the patient), and in anticipation of such undesirable movements, we may employ the square tubing on the molar bands, as suggested by Kemple.² Various other forms of molar anchorage for this purpose have

¹ Kursus der Orthodontie.

² Proc. Amer. Soc. Orthodontists, 1909.

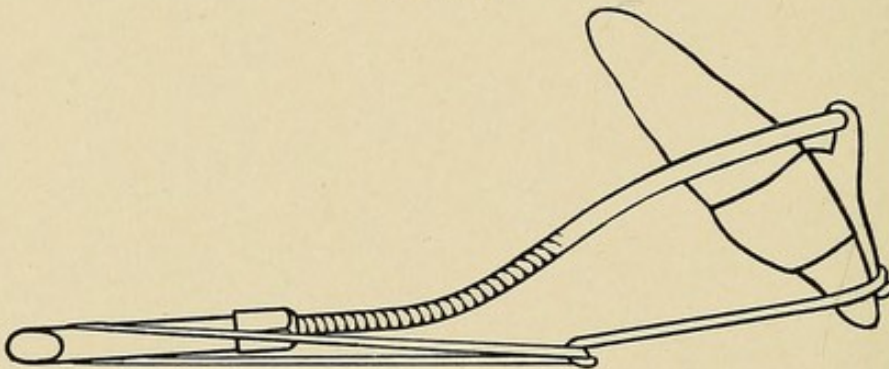
been suggested by Barnes, Hawley, and Ottolengui.¹ These latter forms may all be advantageously employed for the

FIG. 153



High adjustment of the alignment wire to prevent tipping of the incisors during labial movements.

FIG. 154



Körbitz's modification of Case's contouring apparatus.

bodily buccal movement of the molars, thereby inducing desirable lateral development in the osseous structures, whenever that is indicated.

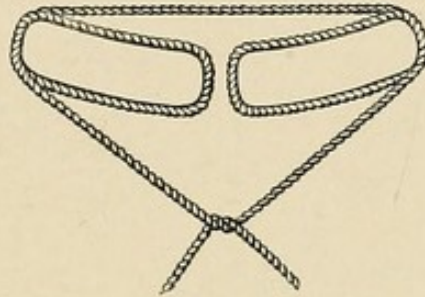
DISTOVERSION

The correction of a distoersion implies a mesial movement within the line of the arch. One of the simplest

¹ Proc. Amer. Soc. Orthodontists, 1909.

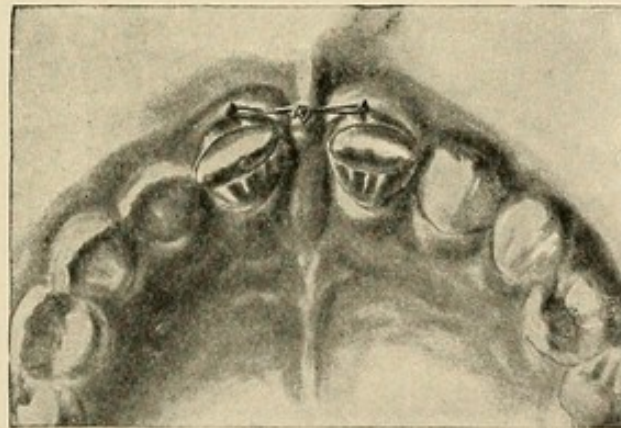
instances of this kind is shown in Fig. 155, illustrating the method of correcting two upper centrals in distoversion as a result of an abnormal frenum labium. The silk ligature, owing to its prolonged tension in a moist environment, is admirably adapted for this purpose. Occasionally, it may be advantageous to construct a plain band for each incisor,

FIG. 155



For mesial movement of the central incisors.

FIG. 156



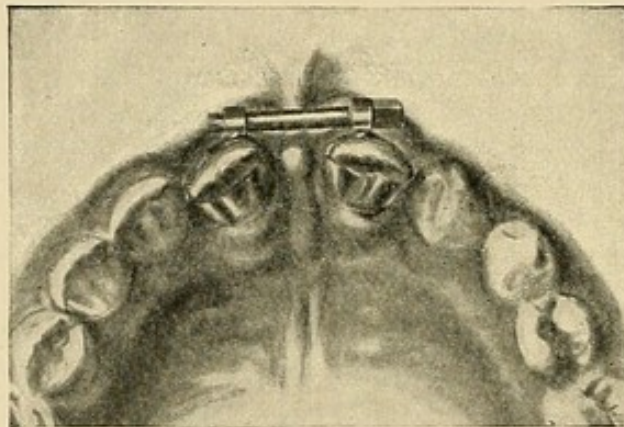
For mesial movement of the central incisors. (After Lukens.)

with a labial spur (Fig. 156) for the attachment of a wire ligature, which is applied in the form of a figure eight. Such ligatures should be about one foot long, permitting a firm grasp with the hands while twisting their knots. The silk ligature already referred to may occasionally be carried beyond the centrals and include the laterals and cuspids.

Small spaces between the six anterior teeth in either jaw may readily be closed in this manner. The skilful use of the silk ligature is an important detail of treatment, even though it be difficult to master.

In all cases where the separation between the centrals is very marked the use of a ligature is contraindicated. Its hinge-like attachment favors tipping instead of bodily movement. The latter can be accomplished by substituting the screw bolt anchored to bands by means of tubes, as shown in Fig. 157.

FIG. 157



For bodily mesial movement of the central incisors. (After Lukens.)

The mesial movement of bicuspids may also be affected by ligatures in combination with notches on the arch (Fig. 118). After all mesial movements anterior to the molars have been accomplished, during which the anchorage was provided by these teeth, the nuts may be released and the molars moved mesially if indicated. This is usually best accomplished by means of intermaxillary anchorage (Fig. 122 for lowers, and Fig. 230 for uppers).

MESIOVERSION

Though rarely met with in incisors, and only occasionally in cuspids, it is frequently found affecting bicuspids and molars. When it extends to the anchor teeth the difficulties of treatment are considerably increased. A single anterior tooth, such as a central or lateral, may usually be moved distally by ligation to a wire provided with a spur in a suitable location. Cuspids only slightly in mesioversion (which are almost invariably associated with linguoversion of the lateral incisors) are readily reduced by means of the rubber wedge (Fig. 147). The rubber must, in such instances, be applied toward the mesiolabial angle. In extreme mesioversion of a cuspid the latter method would prove inadequate, hence we are occasionally compelled to employ the traction screw (Figs. 158 and 159).

FIG. 158

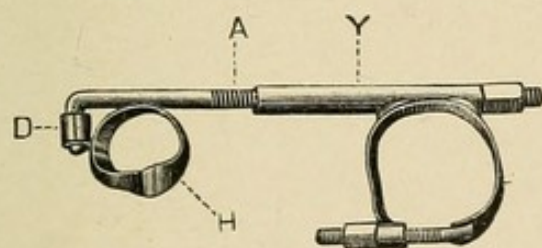
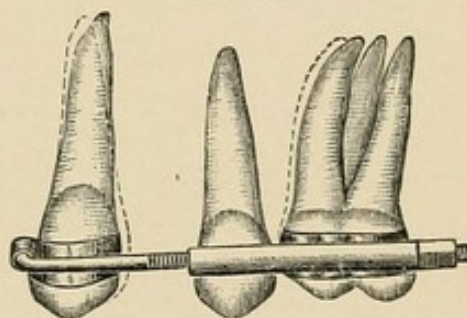


FIG. 159



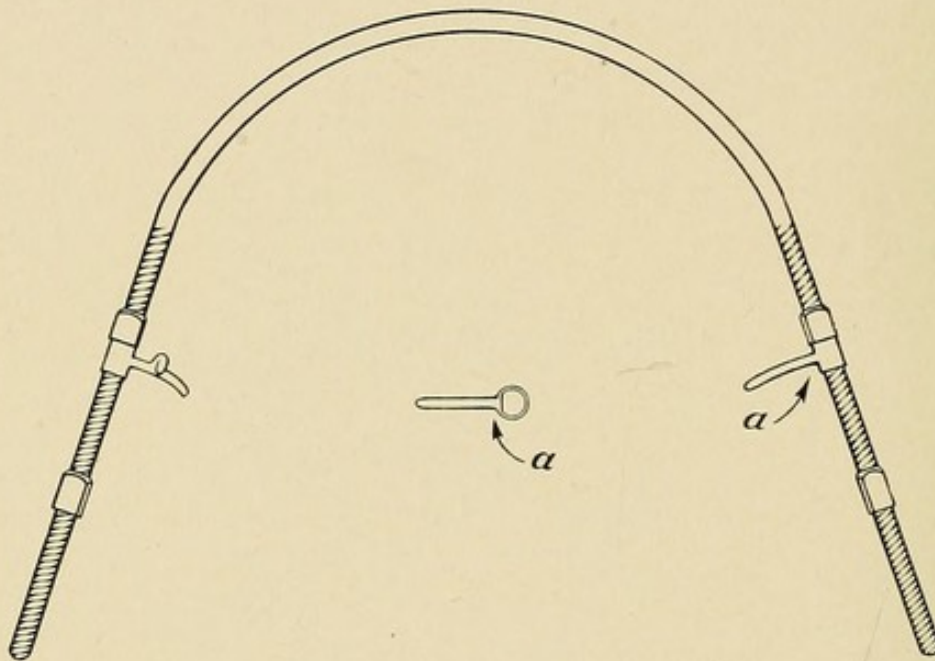
Angle's method for effecting a distal movement of the canine.

Not infrequently, owing to a premature loss of deciduous cuspids and first molars, the first bicuspids erupt mesial to normal. In all cases where other treatment is in progress during such a period, the author uses the method shown in Fig. 160. The illustration shows an arm extended from the alignment wire which is moved distally by means of a nut. The arm is made from an ordinary tube hook and prevented

from dropping occlusally, or being forced gingivally, by flattening the alignment wire with a file along its lingual surface and subsequently adapting the tube to it. This appliance is also applicable in the correction of distoversion.

Mesioversion of a first permanent molar may, in rare instances, be corrected by utilizing all of the anterior teeth for anchorage, *e. g.*, where the second deciduous molar was

FIG. 160



Author's method for correcting mesioversions and distoversions of bicuspids.

lost prematurely. The combined resistance of the anterior teeth, after secure ligation to the alignment wire, may thus be pitted against the first molar by turning distally the nut in front of the tube. Finally, the distal movement of the anchor teeth can be accomplished by use of intermaxillary anchorage—as in mesiocclusion, and in cases of distocclusion—and in rare instances by means of extramaxillary anchorage. These are described in subsequent chapters.

CHAPTER XIV

TREATMENT OF MALPOSITION (CONTINUED)

TORSOVERSION

THIS is a very common form of malposition, and its treatment dates back to Delabarre¹ (1815), who used a lever for its correction, and Linderer (1834) and Schange (1841), who accomplished the same end with the ligature. The lever was also employed by Linderer, and has recently been revived, in a somewhat modified form, by Angle.² Its use is, however, rarely indicated, because it possesses a distinct disadvantage in that it causes an outward movement, as well as rotary action.³ Furthermore, the mere fact that we rarely have to deal with malposition of only one tooth compels us to employ other mechanisms; hence the alignment wire, with its limitless possibilities, again merits our attention.

On the other hand, the principle of the lever is still worthy of our consideration, especially in a restricted or localized sense. It is well known that a corrected torsoversion is hard to maintain in a normal relation, and it is in such instances that the modified lever plays an important role. The retainer of a torsoversion frequently embodies a spur of wire, which can be pressed into service should a tendency

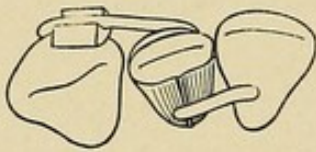¹ Pfaff, Lehrbuch der Orthodontie.

² Proc. Int. Med. Congress, Washington, 1887.

³ See Körbitz, Kursus der Orthodontie.

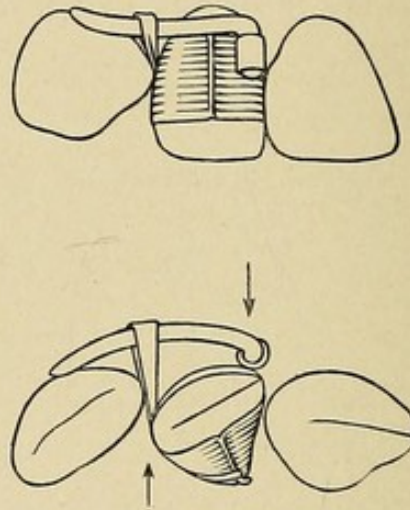
toward a former malposition assert itself. Fig. 161 shows an application of this principle during the retention period. Körbitz¹ has recently suggested a modification of it for the treatment of a simple torsoversion, provided the necessary space can be gained by the purely local action (Fig. 162). He maintains that the rubber elastic shown in the illustration exerts the necessary sideward, or separating, action. The tube attachment of the lever provides a hinge-joint, which permits the rotary movement.

FIG. 161



For effecting slight rotary movements.

FIG. 162



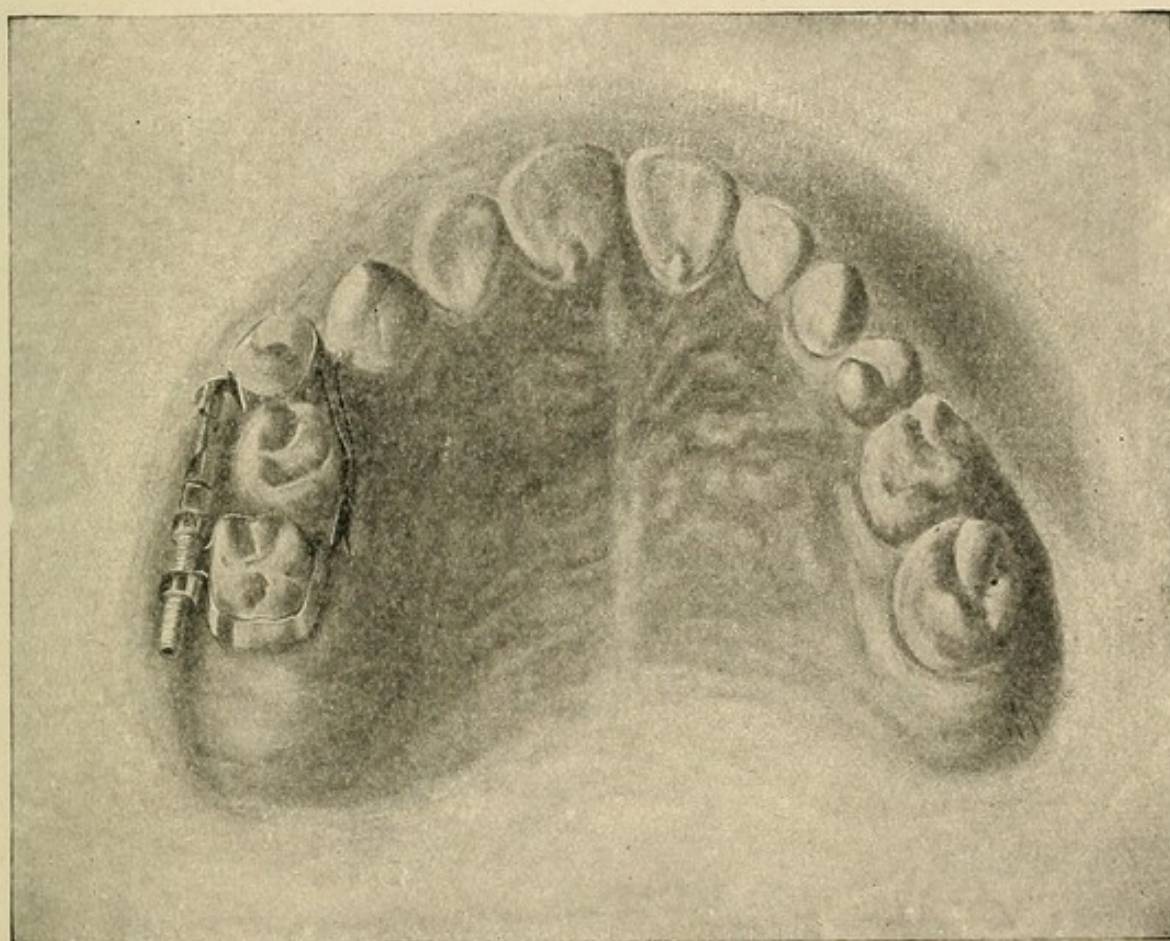
Hinge appliance for rotation. (After Körbitz.)

The roots of bicuspids present oblong forms on cross-section, and offer considerable resistance to a rotary movement. It occasionally becomes necessary, therefore, to apply extreme measures to accomplish the desired results. Fig. 163 shows a case of this kind from the collection of Dr. Lukens, and exhibits the pushing action of a jack-screw on the buccal side, and the pulling action of a rubber ring on the lingual.

¹ See Körbitz, *Kursus der Orthodontie*.

In rare instances, the molars will require rotation, and, if confined to the anchor teeth, this can readily be accomplished with the ends of the alignment arch (Figs. 131 and 132). Should the second molar be in torsoversion, the draught of an elastic ring can be called into service after the manner suggested by Körbitz¹ (Fig. 164).

FIG. 163



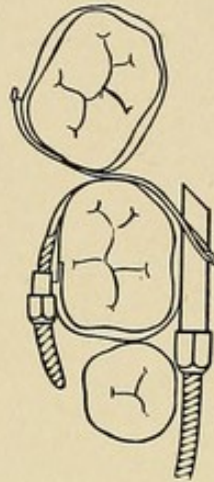
Forcible correction of torsoversion of a bicuspid. (After Lukens.)

The rotation of incisors, cuspids, and bicuspid can generally be affected by means of the ligature, and we now pass to the details of its application. Fig. 165 shows the

¹ Kursus der Orthodontie.

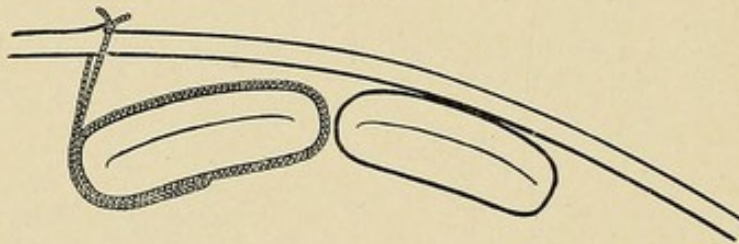
application of a silk ligature for the correction of a simple torsoversion in an upper central incisor, the ligature being applied in the form of a loop. Fig. 166 shows the applica-

FIG. 164



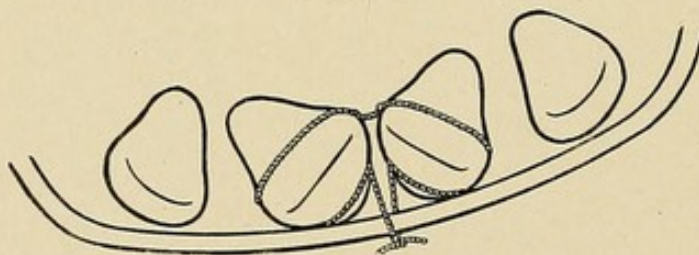
Correction of torsoversion in the second molar. (After Körbitz.)

FIG. 165



The silk ligature applied for correction of torsoversion in an upper central.

FIG. 166

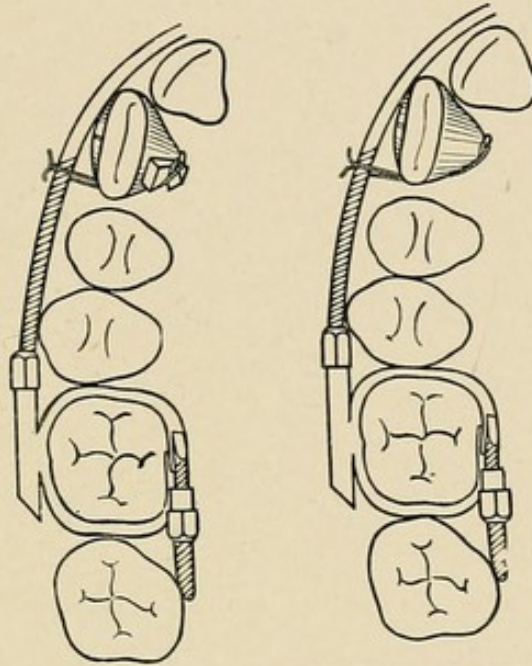


The silk ligature applied for reciprocal action in correcting lower centrals in torsoversion. (After Körbitz.)

tion of a silk ligature to the lower central incisors. In all cases where the lower centrals are of sufficient length and of favorable form, this method will prove efficacious.

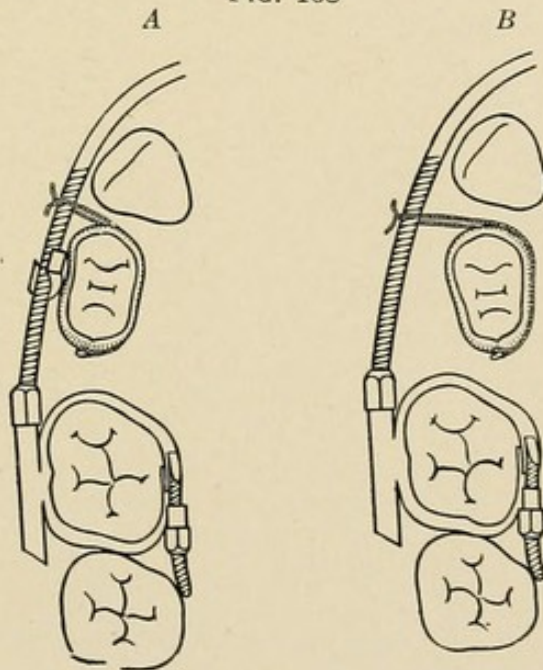
Both upper and lower cuspids, owing to their unfavorable form, usually require the use of bands and spurs to prevent the ligatures from slipping and from becoming disengaged.

FIG. 167



For torsoversion in upper cuspids.

FIG. 168



For torsoversion in bicuspids.

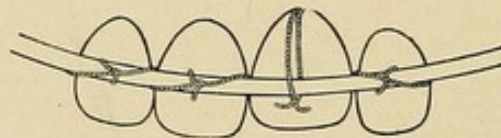
Fig. 167 illustrates two ways of treatment for torsoversion in upper cuspids, by means of a ligature in combination with the rubber wedge. The wire ligature is preferable to the silk ligature in the rotation of cuspids, and can be rendered more certain and prolonged in its action when combined with the rubber.

The rotation of a bicuspid is shown in Fig. 168. In *A*, the rotation is accomplished by means of a ligature in combination with the rubber wedge; in *B*, a buccal movement is also indicated, hence the ligature only is used. The rubber wedge is not only inapplicable in such a case, but contraindicated in the first stages.

INFRVERSION

As suggested by Körbitz,¹ this form of malposition may be either *relative* or *absolute*. A tooth is relatively too short when its crown is fully exposed and alveolar development has been arrested. A tooth is absolutely too short when its crown is not fully exposed and alveolar development apparently normal.

FIG. 169



For absolute infraversion in a central incisor.

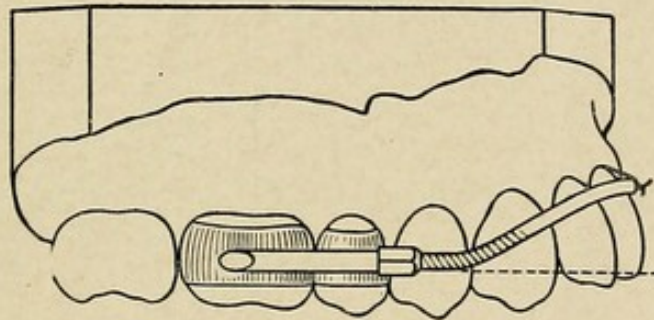
The correction of infraversion is usually accomplished with the alignment wire and stationary, reciprocal, or intermaxillary anchorage. Fig. 169 shows a case of absolute infraversion of an upper central which is being elongated by

¹ Kursus der Orthodontie.

means of the ligature fastened to the alignment wire. The adjoining teeth are securely ligatured to the wire, after which the ligature to the malposed central is applied high toward the neck, and then to the wire. The silk ligature is preferable in such instances, and should invariably be passed above the cervical ridge of enamel. In lateral incisors and cuspids it frequently becomes necessary to adjust bands with spurs to prevent the ligatures from slipping.

In cases of relative infraversion, as, for instance, in the so-called "open bite," the spring temper of the alignment wire is utilized. The wire is inserted in such a manner that

FIG. 170

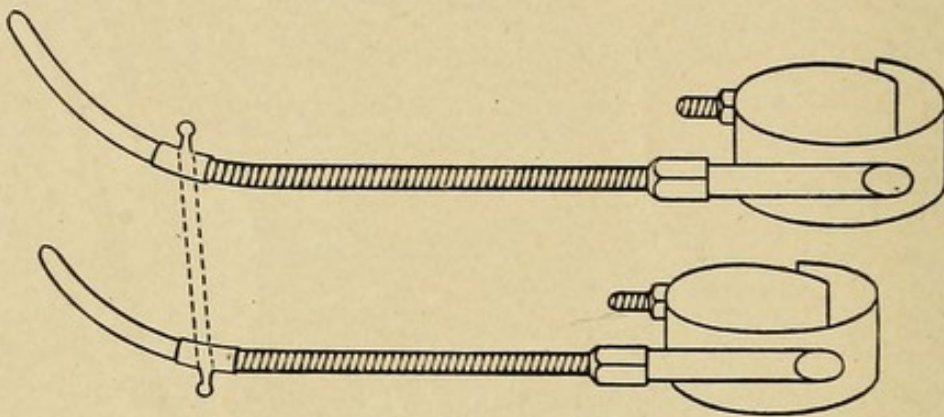


For relative infraversion of the incisors.

it approaches the incisal edges of the teeth to be elongated, and during the process of ligation is held well toward the gingival line, until the ligatures of all the teeth to be elongated have been attached. Upon being released, its tendency will be toward its original position, thus forcing the elongation of the teeth fastened to it (Fig. 170). It must not be overlooked, however, that such action might also cause a mesial tilting of the molars; hence a more secure form of stationary anchorage is occasionally indicated, as shown in the illustration. An additional anchor band is provided for the second bicuspid, and the buccal tube soldered to both. Such precaution renders the anchorage more secure.

Intermaxillary anchorage may be used in either its stationary or reciprocal form, depending upon the requirements of the case. If the teeth of one arch only are to be elongated, the alignment wire in the opposing jaw is securely attached to many teeth; and only to two or four in the arch to be treated. On the other hand, in cases where the teeth of both arches are to be lengthened, we can advantageously employ reciprocal intermaxillary anchorage (Fig. 171).

FIG. 171



Direct intermaxillary anchorage for infraversion.

The elongation of molars can also be effected by means of intermaxillary anchorage, either by direct stationary, or the reciprocal form. (Compare Figs. 173 and 200.)

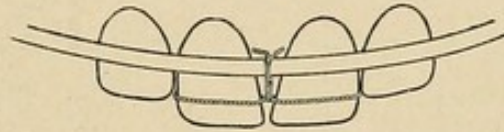
SUPRAVERSION

Though supraversion is by many regarded as a common form of malposition, other writers maintain that it is extremely rare. The latter assert that supraversion is more apparent than real; that, in most instances, we have to deal with infraversion in more remote places in the arches. For example, the cases shown in Figs. 37 and 38 are said to exhibit only an apparent supraversion of the incisors; the

real difficulty—so some writers believe—is an infraversion of the bicuspid and molars.¹

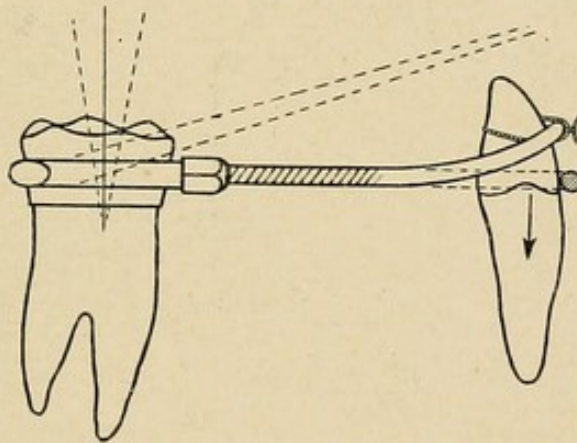
The correction of supraversion is extremely difficult, and can only be executed to a very limited extent. Occasionally, such action can be procured with the alignment wire and ligatures, as shown in Fig. 172. The wire is inserted into

FIG. 172



Ligature applied for reduction of supraversion in upper centrals.

FIG. 173



The reduction of supraversion in lower incisors intensified by means of inter-maxillary elastics.

buccal tubes whose mesial ends point gingivally. It is thus brought close to the gingival line, and the ligature, being passed around the teeth toward their incisal edges, is tied while the wire is pulled incisally. Its spring causes it to return toward the gingival line, thus carrying the attached teeth with it.

Lower incisors can be shortened in similar fashion; and

¹ Rogers, Items of Interest, January, 1911.

where the intermaxillary anchorage is employed simultaneously (which is frequently the case in distoclusion) the action can be intensified (Fig. 173).

The opposite application of the intermaxillary, *e. g.*, in mesioclusion, can also be utilized, though mesioclusions rarely present supraversion of the upper incisors. It is important to remember that in the application of a ligature for a shortening action, we must adjust it well toward the incisal edge, *i. e.*, above the neck; and that such action is not obtainable in bicuspid. Owing to their unfavorable forms, being cone-like, they invariably require the use of bands with spurs, to prevent the slipping of ligatures.

PERVERSION AND TRANSVERSION

These two forms are, fortunately, extremely rare (particularly the latter), and our means for their correction even more limited than in the case of supraversion. For transversion there are, practically, no methods at our command; though theoretically, transplantation suggests itself. Perversion, on the other hand, is so often combined with linguo- or labioversion that it is frequently operable. Fig. 120 shows the most common form met with, and one of the best methods yet devised for its correction.

CHAPTER XV

TREATMENT OF NEUTROCLUSION

SIMPLE NEUTROCLUSION

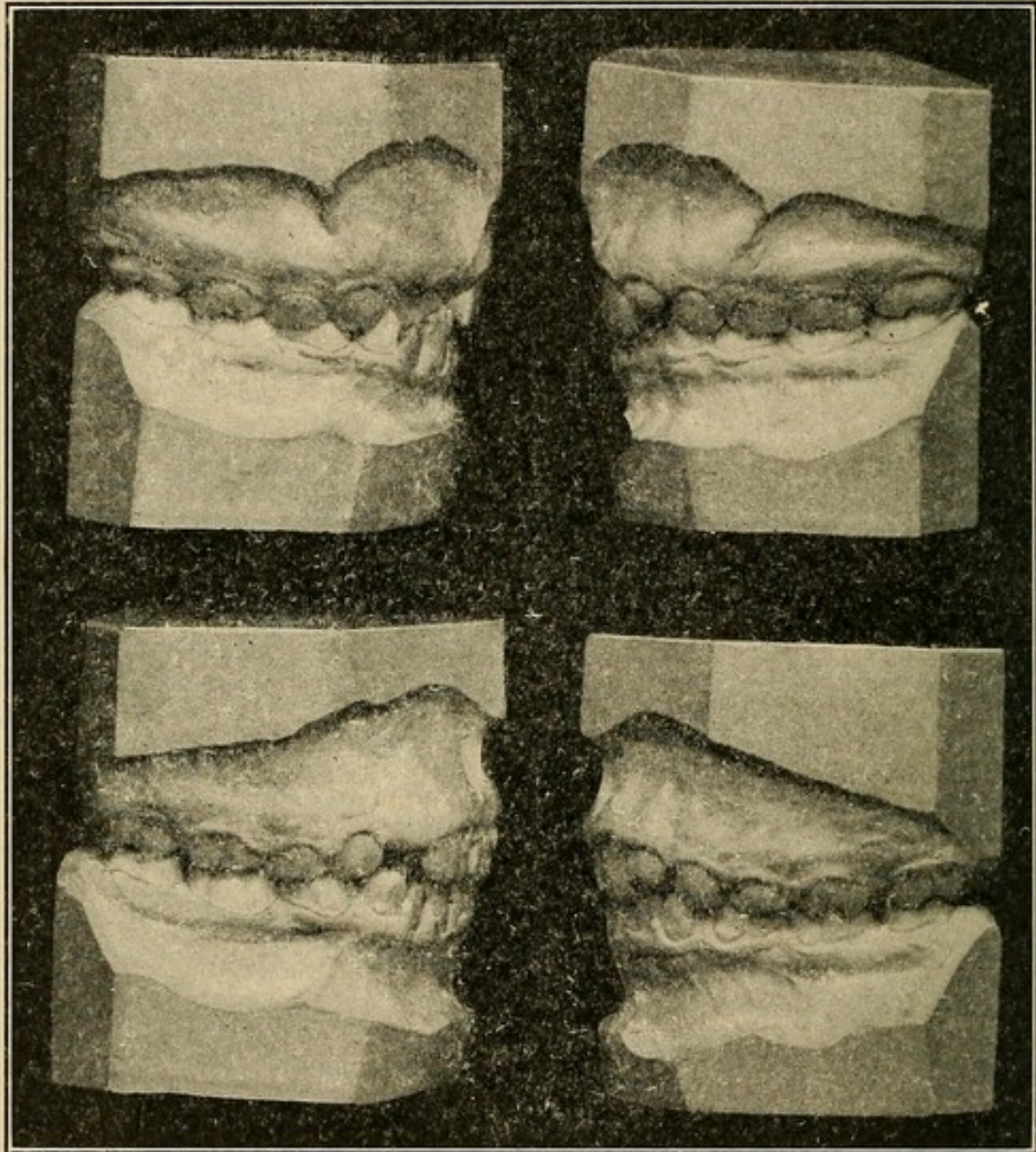
As intimated in Chapter XIII, the treatment of a malocclusion may embrace the correction of (*a*) tooth position, (*b*) arch form, (*c*) arch relation, and, conjointly, jaw and face deformity; and though each of these details is worthy of separate consideration, it is obvious that the goal can best be reached by the establishment of normal occlusion. This implies that each case be considered in its entirety, that all its various problems receive contemporaneous treatment. Hence we pass to a consideration of the various types.

As elsewhere noted, most malocclusions develop slowly; in their early stages all are comparatively simple. We shall begin, therefore, with a few of the simpler forms.

Case A.—A robust girl, aged eight years (Figs. 174 and 175); the illustrations presenting side and occlusal views before and after treatment. The history of the case is entirely negative; the temporary teeth have never been affected by caries, having received regular dental attention. The mother of the patient believes in exercising every precaution, and has had the nose and throat examined by a rhinologist, who found them normal. Infancy was uneventful, being free from any of the serious infectious diseases of that period of life. The family history is also negative, both parents having normal dentures; hence the question of cause remains obscure.

Formerly it was common practice to postpone treatment in such cases until after the eruption of bicuspids and cuspids, for it was deemed impracticable, if not unwise, to

FIG. 174

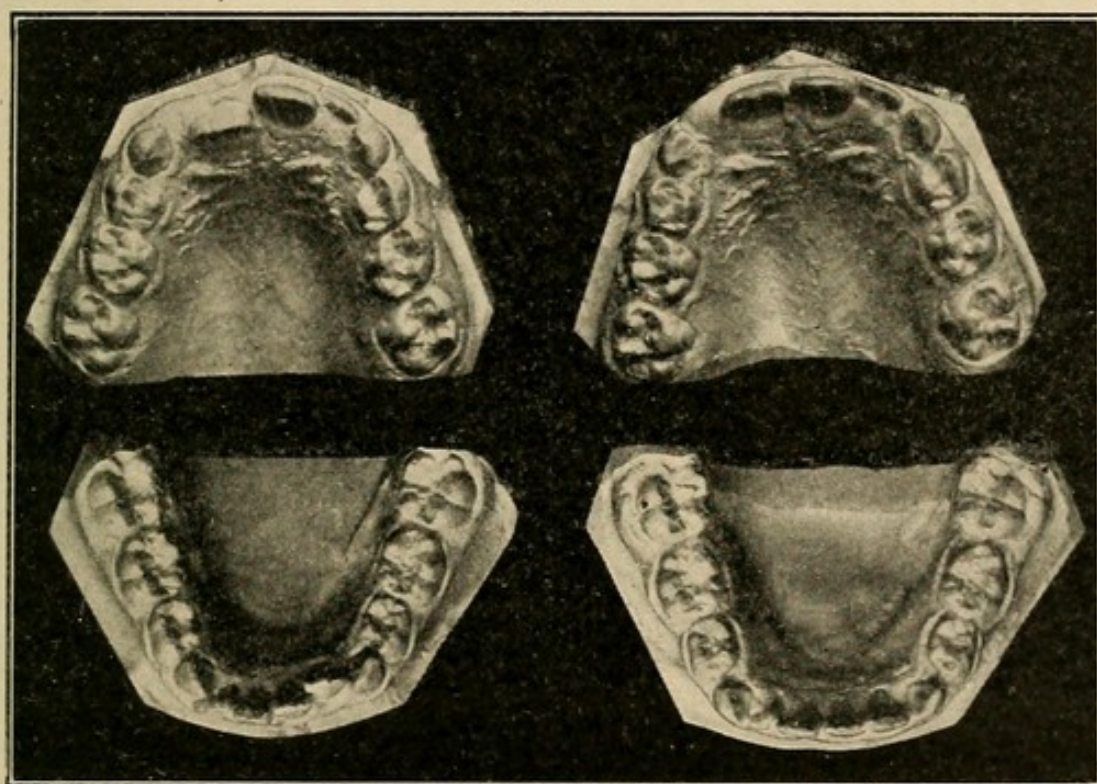


Right and left views of denture before and after treatment. (Compare with Fig. 175.)

move their temporary predecessors. A moment's comparison of the models readily establishes the conclusion that it is good practice to administer treatment thus early. It is, of course, true that the denture of this child will require

further observation, and probably treatment, depending on the subsequent normal or abnormal eruption of the now unerupted teeth. But it is obvious that the enlargement of the dental arches has greatly increased the probability of their normal eruption. And further, it must be equally clear that the malocclusion already existing in the incisors will never correct itself, no matter how long the treatment is postponed.

FIG. 175



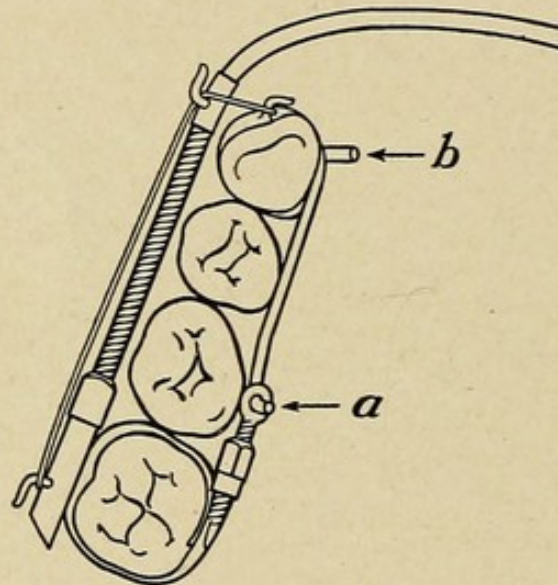
Occlusal views before and after treatment of denture shown in Fig. 174.

Again, the treatment of this denture did not constitute a hardship, and was no reason for its postponement. The appliances used consisted of four adjustable anchor bands for the first permanent molars (Fig. 113), and applied after the manner indicated in Fig. 112, though spurred bands at the mesial ends of the extension wires were considered unnecessary. The ends of the extension wires, after being cut to exact length, were bent at sharp right angles to

engage silk ligatures tied to the alignment wires. The movement of the right upper central incisor was also effected with a silk ligature, which was renewed at weekly intervals. The entire treatment consumed less than four months.

Maintenance of the corrected condition is now being provided by an appliance on the lower arch similar in design to that shown in Fig. 140, though it is anchored to the second temporary molars. Bands with spurs for the pre-

FIG. 176



Modification of appliance as advocated by Körbitz.

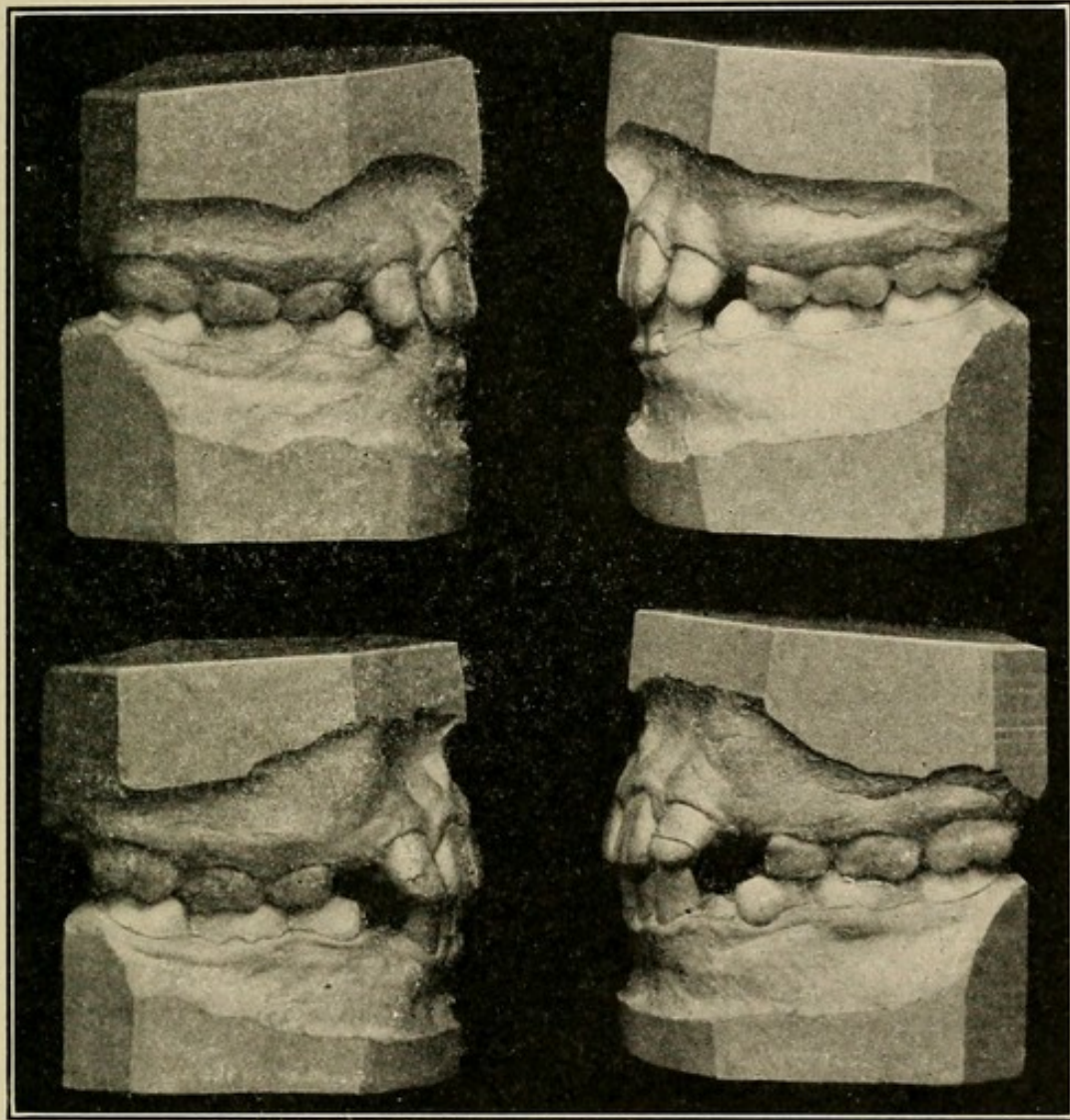
vention of anterior displacement were placed upon the lateral incisors, instead of the canines as illustrated. In the upper arch maintenance is largely provided by the occlusion of the lower, and by a plain band with spurs upon the left central after the manner indicated in Fig. 135.

An ingenious and very excellent modification of this plan of treatment has recently been advocated by Körbitz¹

¹ Zeitschr. f. Zahnärztl. Orthopädie, September, 1910; Deutsch. Monatssch. f. Zahnheilk., November, 1910.

(Fig. 176). He uses the hinge-joint at (*a*), which is procured by soldering an 18-gauge tube to the free end of the clamping bolt, which thus removes all possibility of rotation of the molars. He further advocates anchorage of the mesial end

FIG. 177

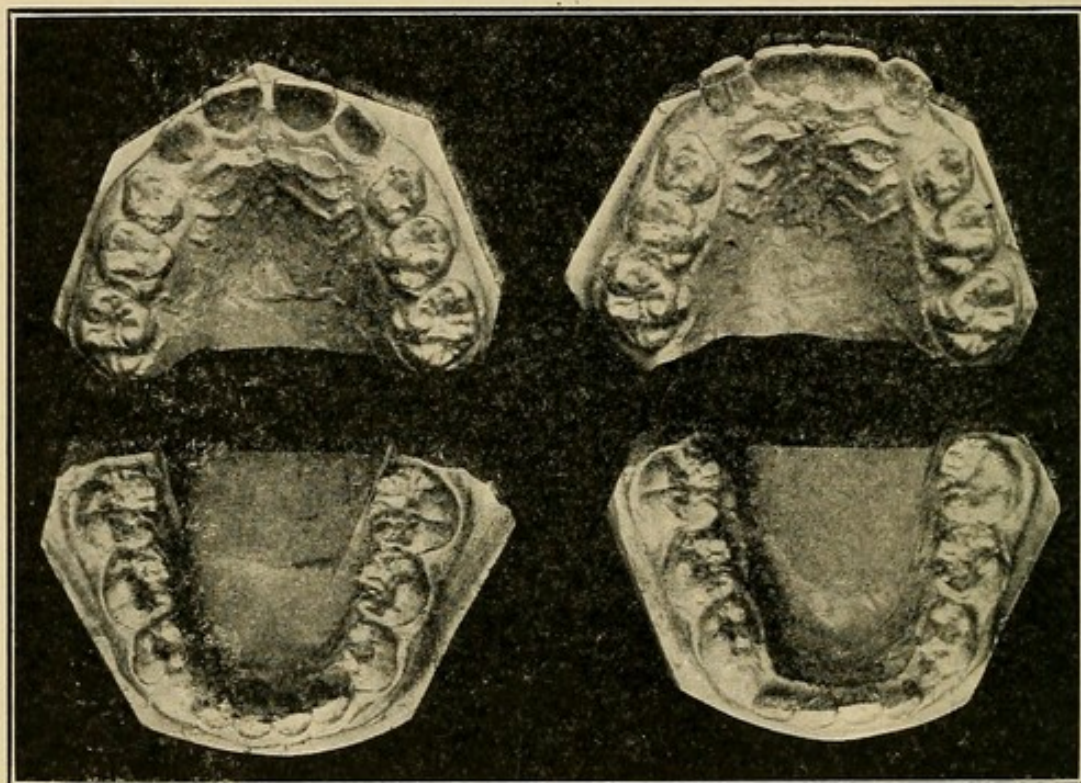


Side views of case, aged nine years, before and after treatment. (Compare with Fig. 178.)

of the lingual wire to a canine band, to which he solders another such tube (*b*) at right angles. The latter is in anticipation of retention, when it will carry an 18-gauge section of wire extending to its fellow on the opposite side, thus

maintaining the newly established arch width. The buccal movement of the temporary teeth is accomplished with an elastic rubber band attached to a hook on the gingivolabial border of the canine band, then passes over a tube hook on the alignment wire, and on to the anchor band, all as shown in the illustration. The form given to the alignment wire controls the ultimate form of the dental arch.

FIG. 178



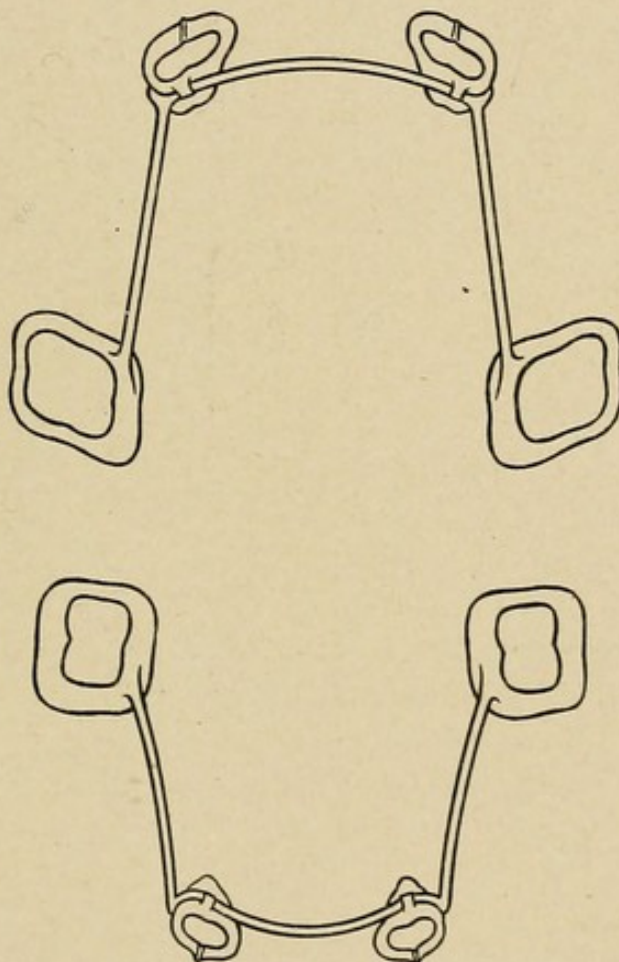
Occlusal views of case shown in Fig. 177.

Case B.—An anemic girl, aged nine years (Figs. 177 and 178), who related a history which gave no clue as to the probable cause. Indeed, such local arrests of development as the denture of this child exhibits are difficult to account for. The linguoversion of the incisors could hardly be the result of premature loss of the temporary cuspids; the mouth presented an unusually healthy condition in every other respect, being immune to caries. Though the canines have

been exfoliated, it would be interesting to learn *the cause of their early loss*, which might then serve as *causa prima*.

The plan of treatment was, in many respects, similar to that outlined for Case A, though the incisors were differently malposed and necessitated a slight change in the details. It is evident that both arches required expansion, and that all incisors be moved labially. The upper incisors are also in distoverision, with wide spaces between them.

FIG. 179



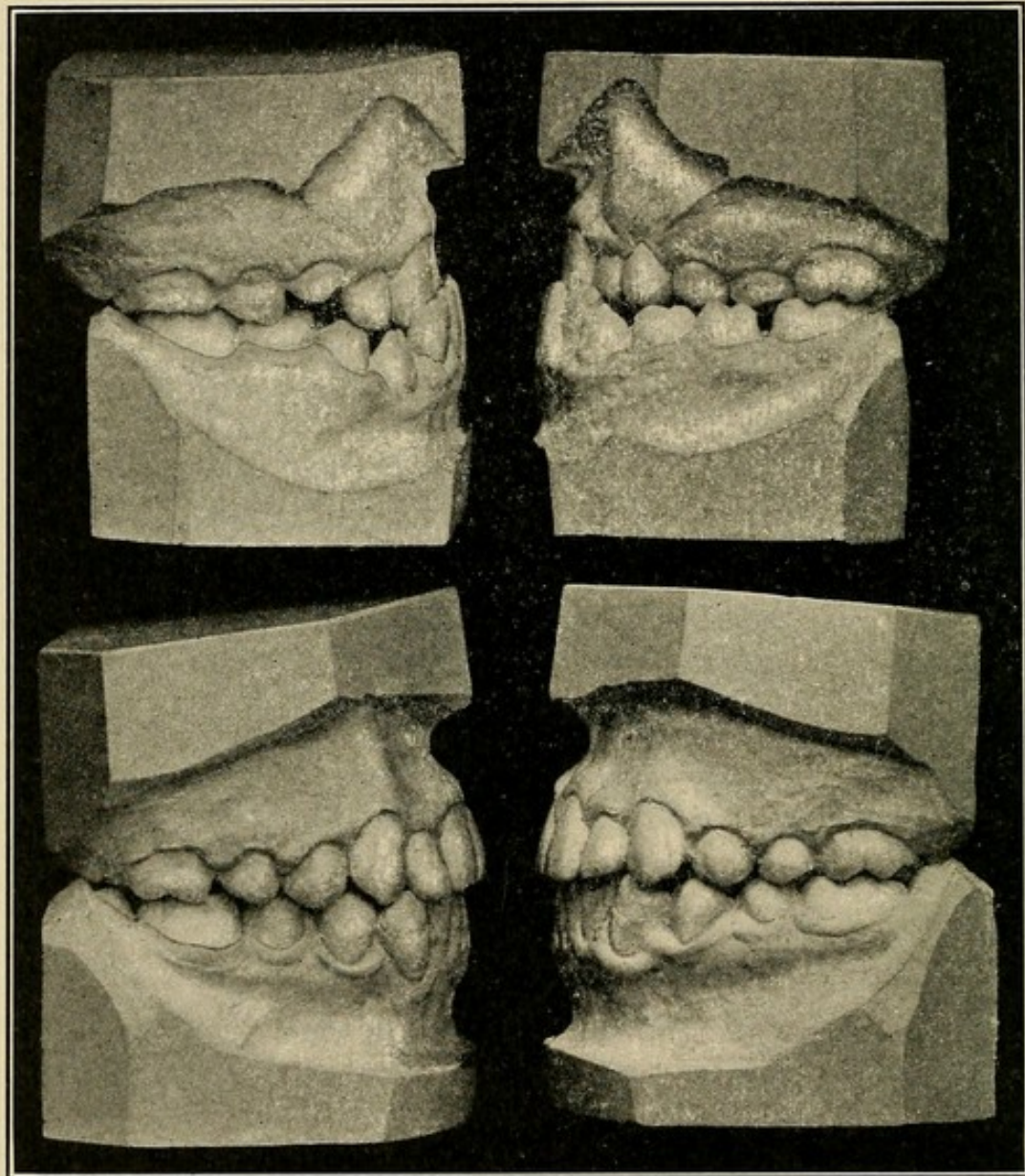
Maintenance appliances used for the case shown in Figs. 177 and 178.

The appliance consisted of four molar anchor bands with extension wires, two 18-gauge alignment wires, and four plain bands with spurs for the lateral incisors. The expansion of

each arch is very noticeable in the after treatment models, and resulted in gaining the necessary spaces for the cuspids.

Maintenance of the corrected condition was provided by the appliance shown in Fig. 179. The bands upon the lateral

FIG. 180



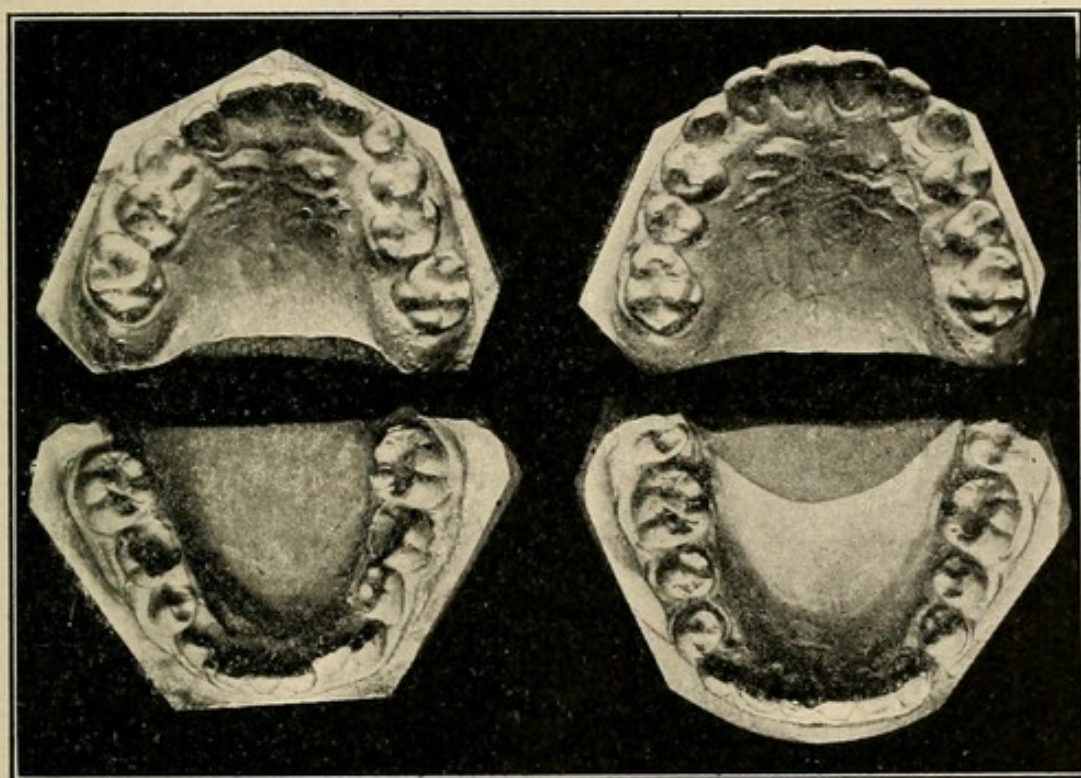
Side views of case, aged eleven years, before and after treatment.

incisors are the same as those used for movement; and the anchor bands upon the molars are reduced in parts by removal of the buccal tubes and clamping bolts, after which

the free lapping ends are united with solder to form a continuous band of exact size.

Case C.—A boy, aged eleven years (Figs. 180 and 181), who has suffered much from dental caries, and to whom mastication has for years been both difficult and painful. His mother related an operation for hypertrophy of the tonsils performed during his ninth year. Thus it is very

FIG. 181



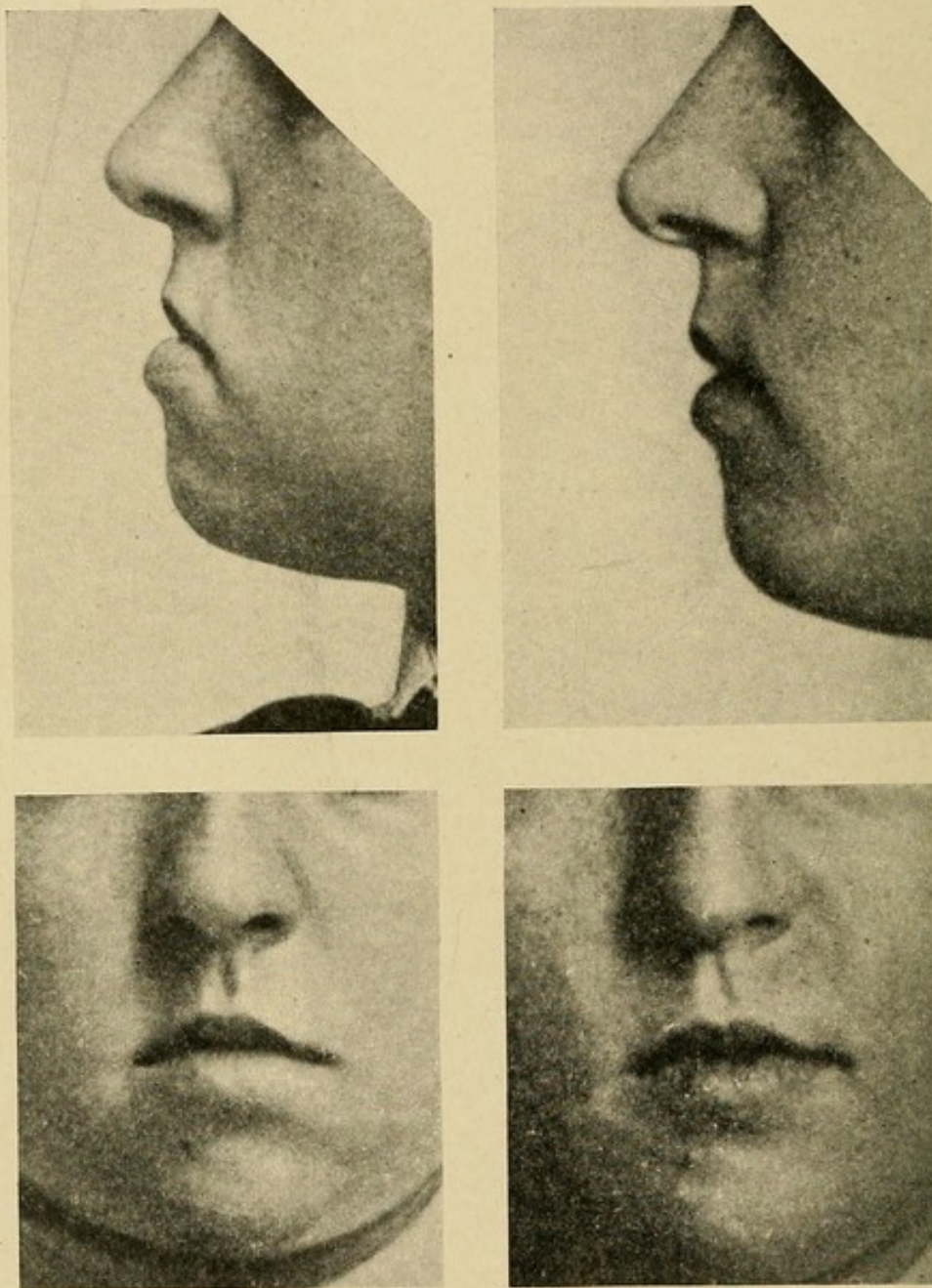
Occlusal views of case shown in Fig. 180.

probable that the arrest of development in the upper arch is a result of the ailments just enumerated.

The treatment was again similar in plan to that described for Cases A and B, though the lower canines were also involved. Hence they are included in the treatment by providing them with spurred bands as already described. Most of the temporary teeth remaining are so badly decayed that their immediate removal is indicated. By means of

the anchor bands, 16-gauge alignment wires and ligatures, with all of which the reader is now somewhat familiar, expansion of both arches was achieved as shown in the models.

FIG. 182



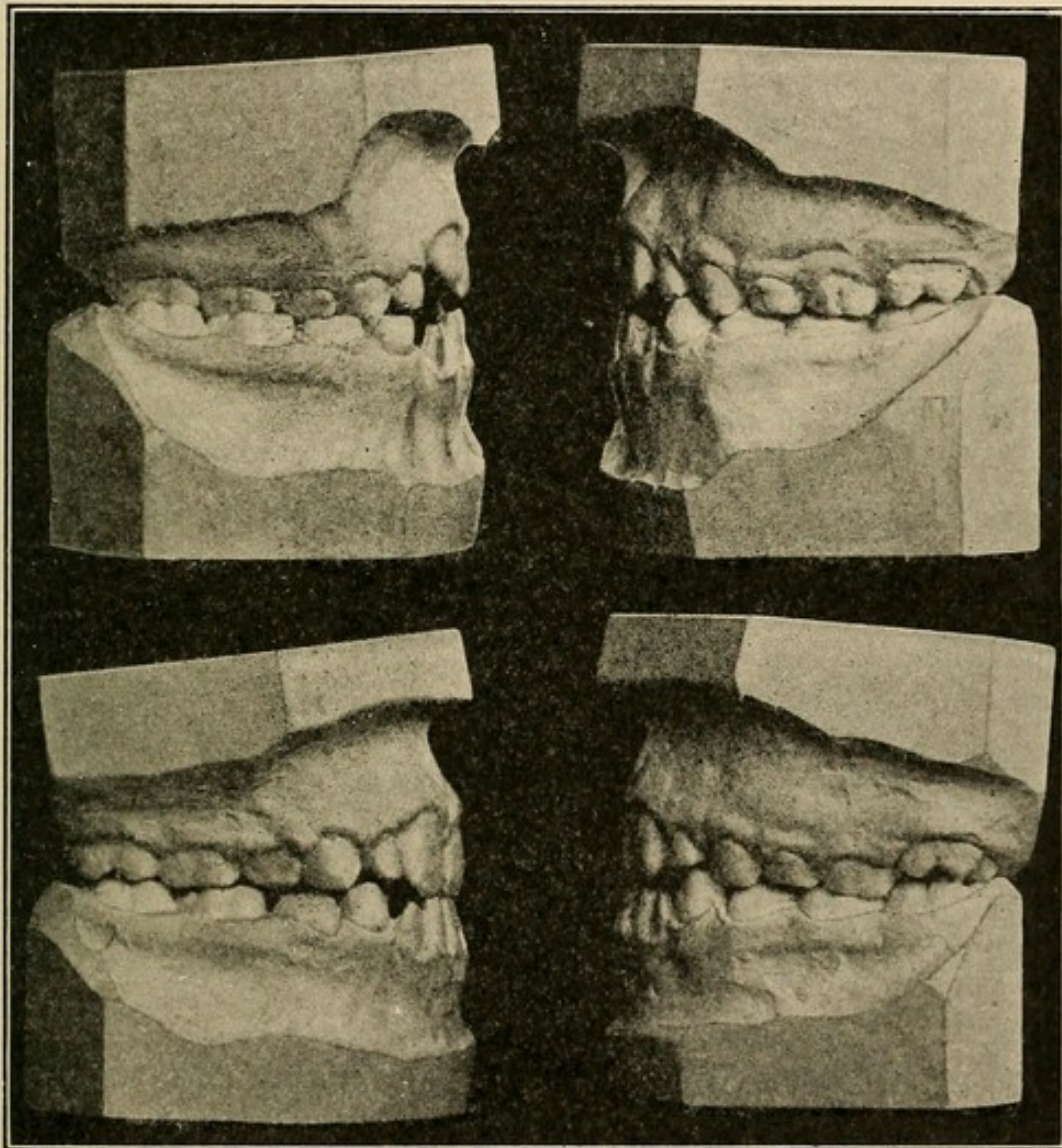
Facial relations before and after treatment of case shown in Figs. 180 and 181.

Maintenance was provided for the upper arch by an appliance as shown in Fig. 179, and for the lower by one like Fig. 140.

Fig. 182 shows the facial relations before and after treatment.

Case D.—A boy, aged nine years (Figs. 183 and 184), slightly below the average in height. Inquiry into his

FIG. 183



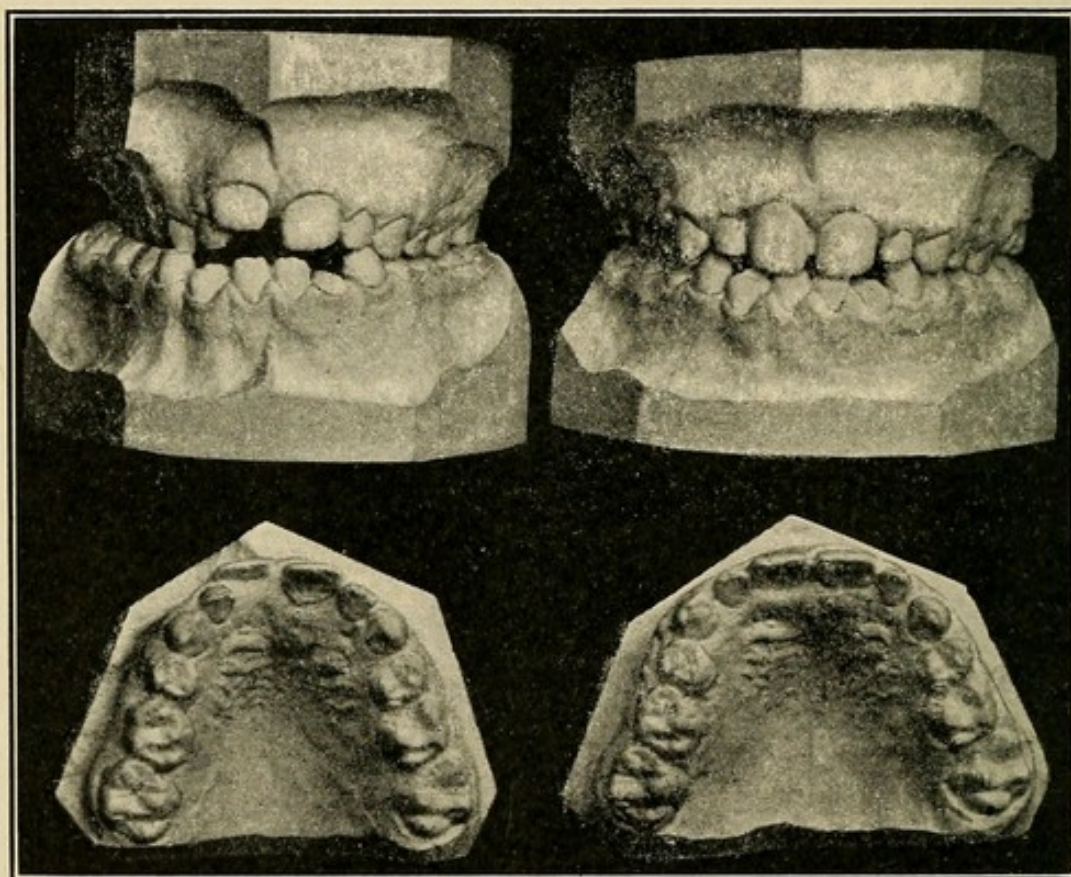
Side views before and after treatment of case, aged nine years. Note the lingual relation of the entire right upper lateral half.

history revealed the fact that his persistent mouth breathing and noticeable facial deformity had led his mother to consult a rhinologist, who removed an adenoid and enlarged

tonsils about six months previously. His father, whom he resembles in facial expression, hair, and eye color, has a malocclusion of the same type, which is comparatively rare.

The arches are in normal mesiodistal relation, though the entire right upper lateral half is lingual to the lower. The lower arch is of ideal form, and was not involved in the

FIG. 184

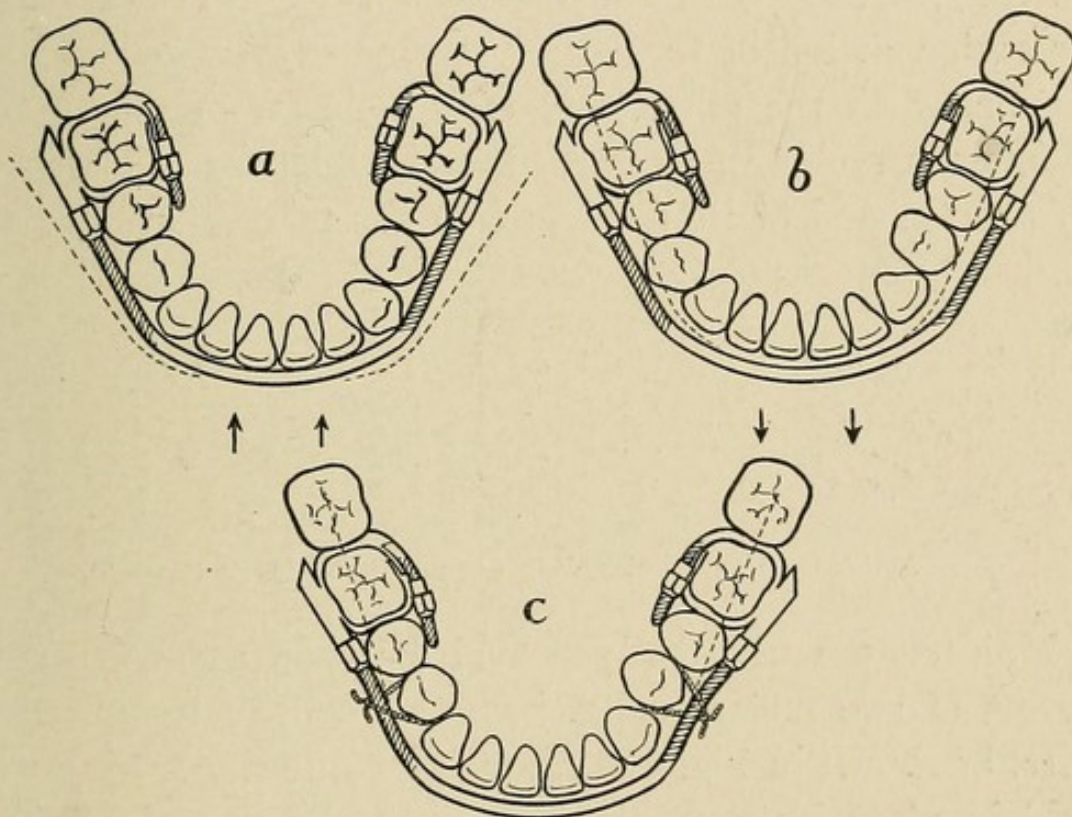


Front and occlusal views of case shown in Fig. 183.

treatment. But the upper arch presents a feature that is interesting in its anchorage requirements. Only one lateral half requires a buccal movement, though the expanding action of the alignment wire acts with equal pressure (as ordinarily applied) upon both sides. Let us briefly consider its various methods of application, and of this controlled action in particular. Fig. 185 is diagrammatic of the action

of the alignment wire in the various ways in which it is ordinarily applied. In *a* the dotted lines indicate its expansive power toward the buccal in each lateral half, when introduced with that intent. Under such circumstances it also tends to glide distally within the tubes, resulting in a lingual movement of the incisors, as shown by the arrows, unless such action is prevented by contact of the nuts against

FIG. 185



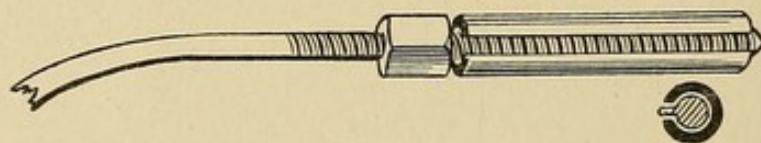
Shows the action of the alignment wire in its various applications.

the mesial ends of the buccal tubes. If applied for contraction of the arch, as in *b*, its tendency in the incisal area will be in a labial direction, as indicated in the drawing. In *c* the distribution of the load on the molars imposed by the tension on the bicuspid is shown.

The case under discussion requires that the bilateral buccal action of the alignment wire as shown in *a*, Fig. 185,

be rendered unilateral. This can readily be accomplished if the anchorage of the wire in the tube on the normal side is changed to complete stationary form. By soldering a buccal tube to the left anchor band, as shown in Fig. 186, and by providing it with a lingual extension wire as already described, the resistance was so increased as to effectually overcome the expanding action of the wire on the normal side. Its effect, therefore, was to move the right molar buccally, which occurred within a month's time. The expansion action of the wire was now slightly reduced by bending with the pliers, and after re-insertion the second temporary molar was attached. The buccal movement of this tooth, and of its neighbors to the mesial, was accomplished by means of ligatures.

FIG. 186



Abell's modification of Kemple's square tube. (After Hawley.)

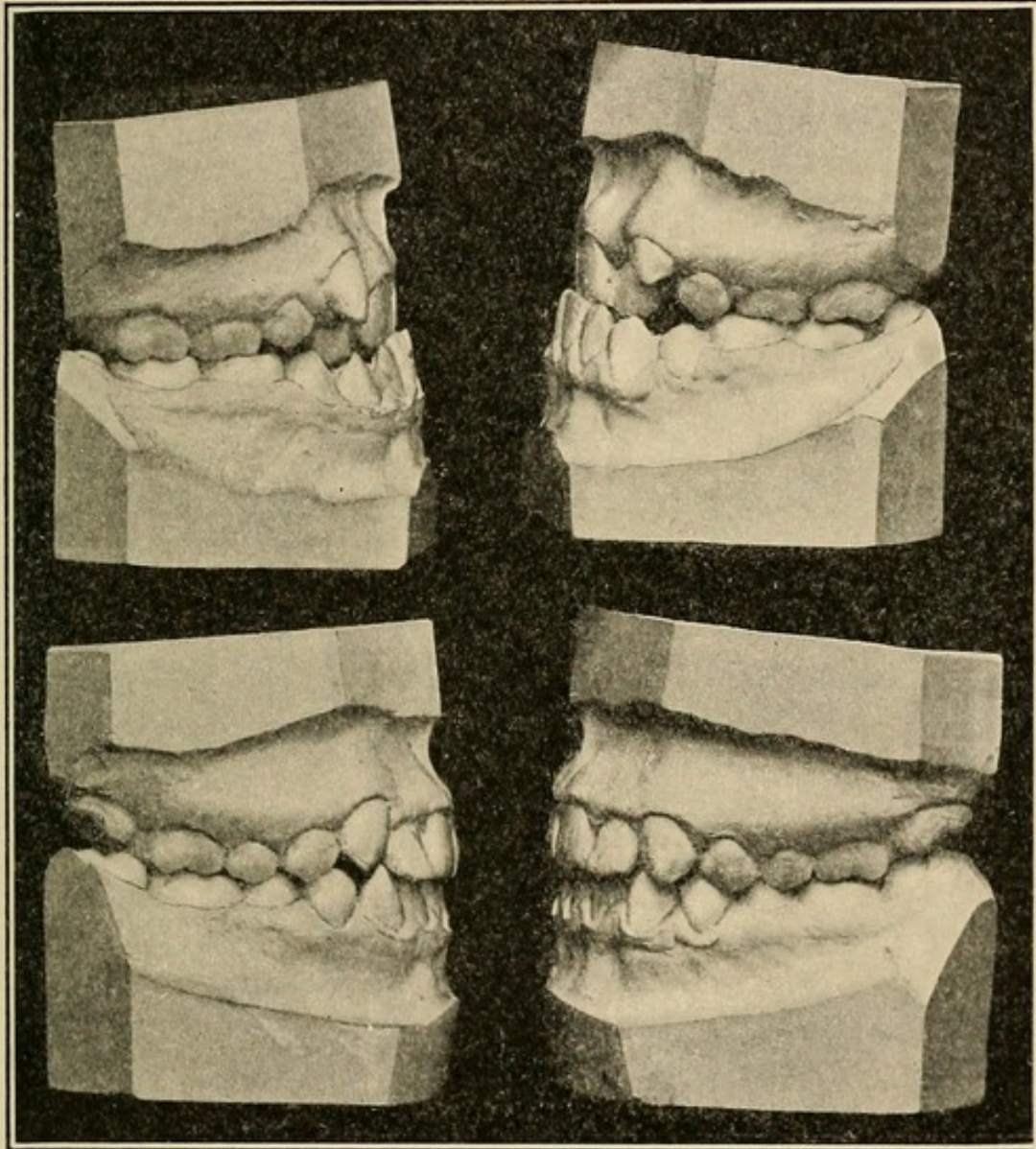
Maintenance was easily provided by an appliance consisting of two molar anchor bands with lingual connecting wire, as shown in Fig. 179, though its anterior section was held in place by spurred bands upon the centrals. These bands were also united with solder at their mesial contact points, thus combining their resistance and providing maintenance for the corrected infraversion of the right central.

COMPLEX NEUTROCLUSION

Cases belonging to this group differ from the foregoing only in their minor symptoms, being identical in the funda-

mental characteristic, viz., the normal mesiodistal relation of the lower arch to the upper. They are usually older, however, consequently more teeth are involved, and their

FIG. 187

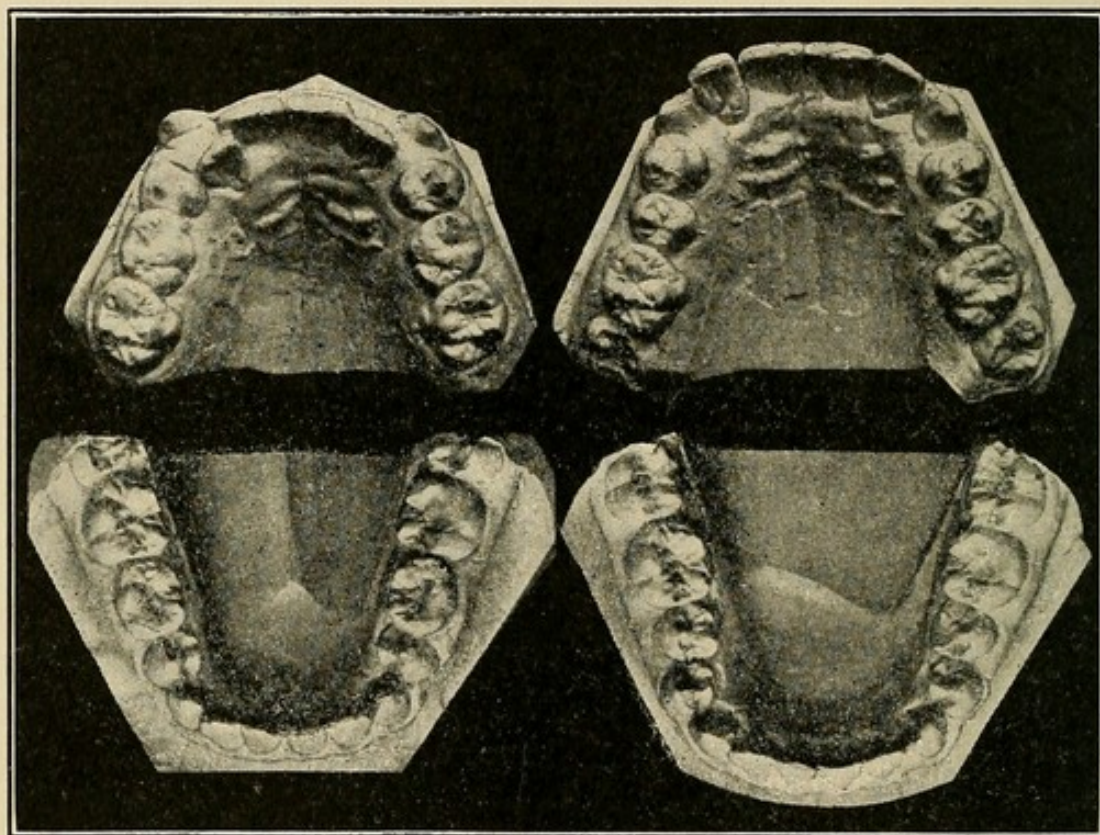


Side views before and after treatment of case, aged thirteen years.

various features are usually emphasized in the terminology by the addition of qualifying phrases. The division is, therefore, purely arbitrary.

Case E.—*Neutroclusion complicated by pronounced linguo-version of the upper incisors and infraversion of the upper cuspids.* A strong, healthy girl, aged thirteen years (Figs. 187 and 188), whose non-resonant voice and marred facial expression before treatment (Fig. 189) were symptomatic of arrest of development of the intermaxillary bone and nasal passages, was requested to consult a rhinologist. The exami-

FIG. 188



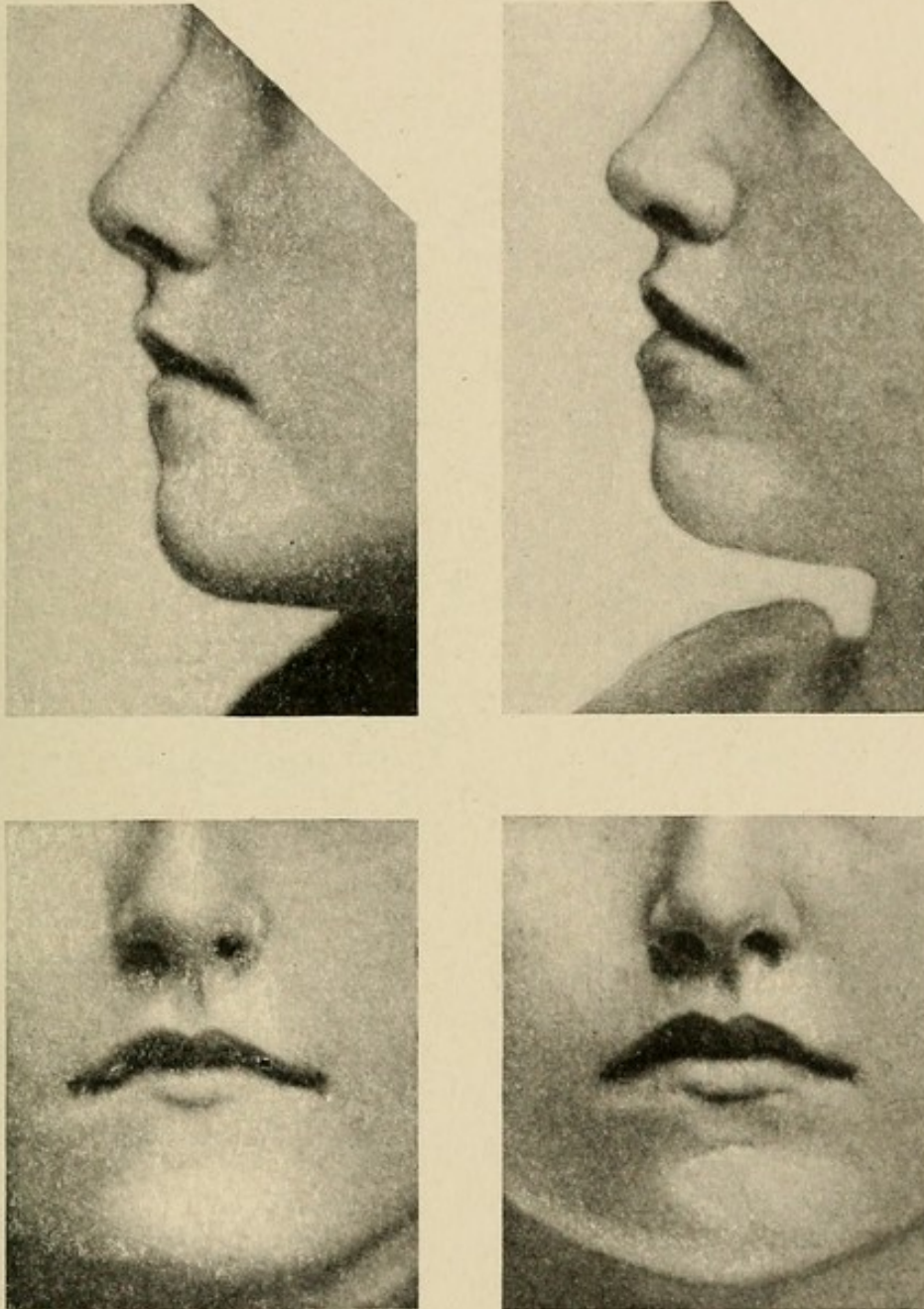
Occlusal views of case shown in Fig. 187.

nation revealed the presence of adenoids in the nasopharynx and hypertrophy of the inferior turbinates. After removal of this hypertrophied tissue by the rhinologist, the treatment of the malocclusion was begun.

The appliances consisted of four molar anchor bands with buccal tubes; plain bands with spurs on the disto-gingival border of their lingual surfaces for the upper lateral

incisors and lower cuspids; and two 16-gauge alignment wires. The molar bands were of a design as shown in Fig. 113.

FIG. 189



Facial relations before and after treatment of case shown in Figs. 187 and 188.

The adjustment of the entire appliance consumed six short semiweekly visits, after which tension was applied. The alignment wires were given a slight expansive spring; the

extension wires were fastened to the alignment wire after the manner indicated in Fig. 112, and ligatures applied to the lower incisors and two upper centrals. After a period of three weeks considerable movement had been gained, which in a measure liberated the interlocked upper laterals. Ligatures were now applied to these teeth, as well as to the lower cuspids. After another period of four weeks sufficient movement had been accomplished to permit of a more favorable adjustment of the upper alignment wire. By careful bending after the manner indicated in Fig. 130, it was possible to carry it sufficiently to the gingival line, so that it embraced the seemingly prominent canines. Its length was so adjusted that it rested firmly upon their labial eminences, thus relieving the strain upon the upper molars, and aiding materially in reducing the developing supra-version of the upper laterals, which was now asserting itself. It may be worthy of mention to state that the second upper temporary molars were extracted during the patient's second visit, which resulted in the immediate eruption of their successors.

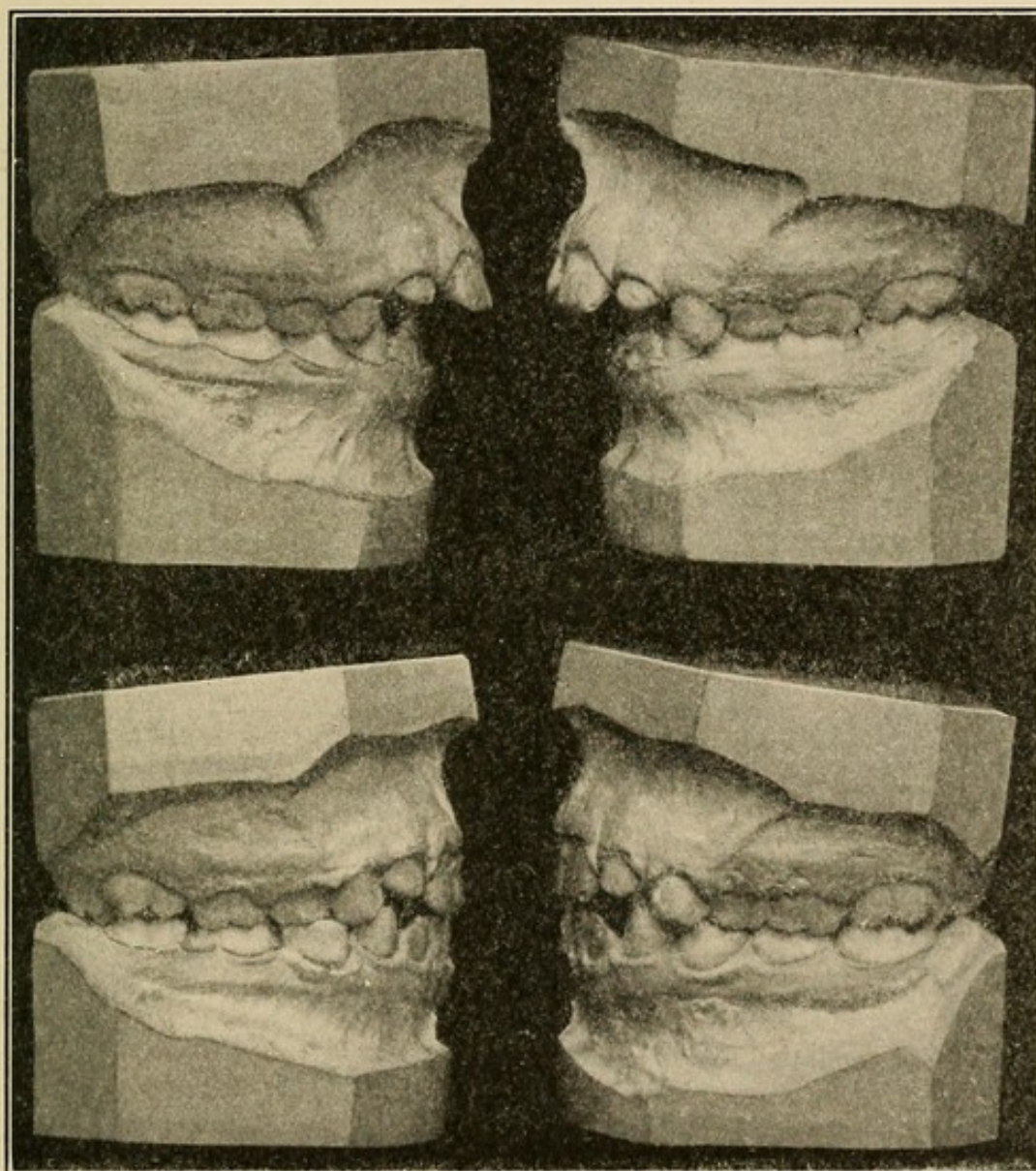
Maintenance has been sustained by an appliance for the upper arch, as shown in Fig. 179 (upper diagram), and for the lower as shown in Fig. 140. The improved facial lines resulting from the treatment are shown in Fig. 189.

Case F.—*Neutroclusion complicated by extreme labioversion of the upper incisors.* A boy, aged nine years (Figs. 190 and 191), addicted to the habit of sucking his lower lip. Several acute attacks of rhinitis a year previous had led the mother to consult a rhinologist, who failed to detect any lymphoid hyperplasia in the nasopharynx. And though the deformity is typical of an adenoid child, we are thus forced to conclude that the habit already alluded to is the sole cause of the

malocclusion. The facial deformity in this instance was very marked, presenting an enlarged lower lip.

Treatment was executed by the use of appliances identical with those employed for the previous cases, with addition

FIG. 190

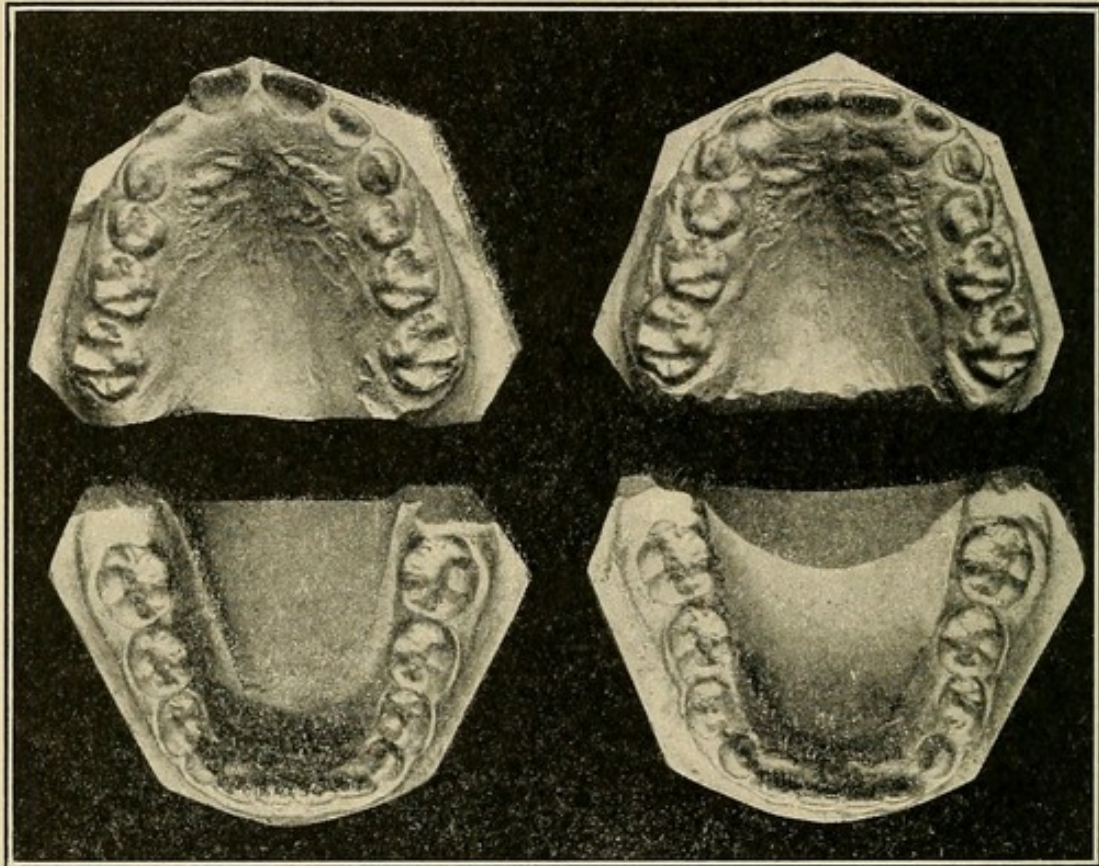


Side views of Case F, before and after treatment.

of two tube hooks on the upper alignment wire. These were soldered at points opposite the interproximal spaces between laterals and cuspids. Rubber elastics were anchored

after the manner indicated in Fig. 122, after which the nuts on the upper alignment wire were released. This action resulted in a lingual movement of the upper incisors. In the meantime the lower arch was liberally expanded over its entire length, and the upper temporary cuspids and molars moved buccally.

FIG. 191



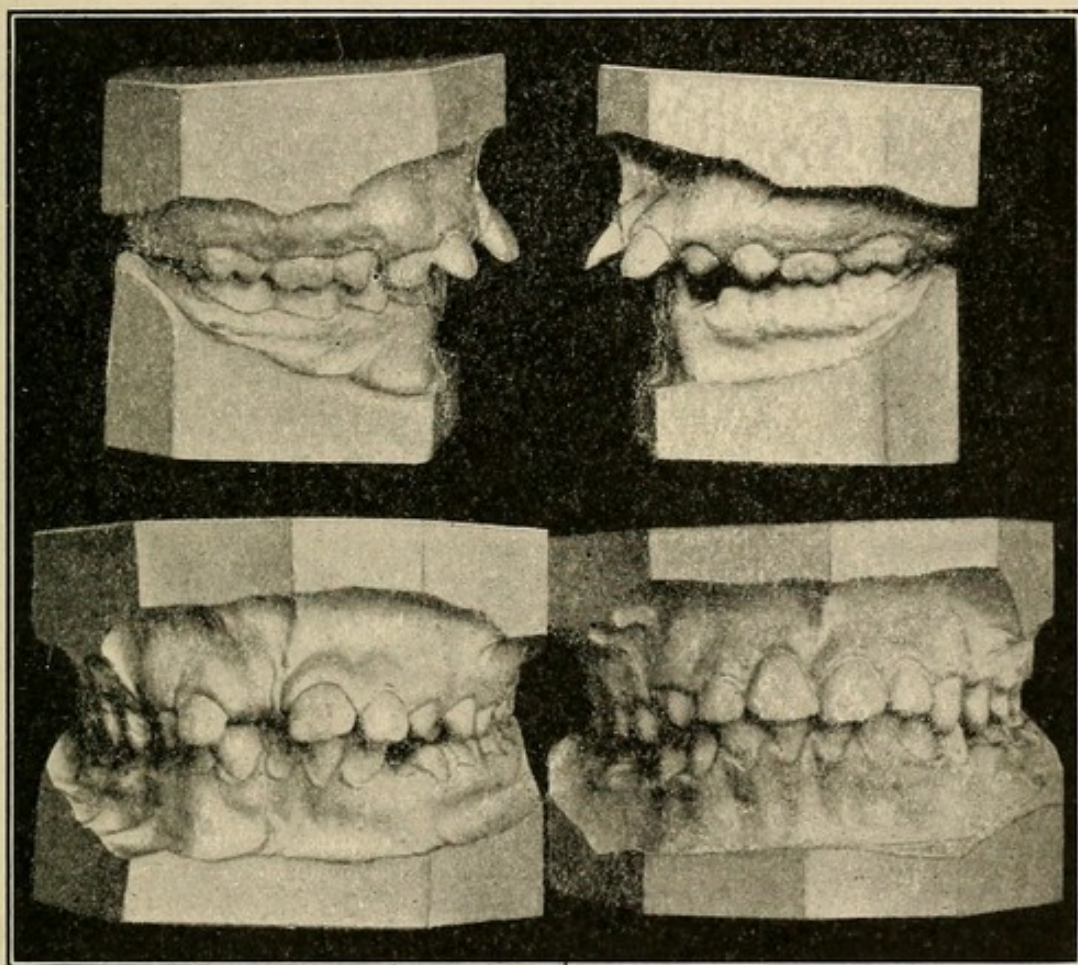
Occlusal views of case shown in Fig. 190.

Post-treatment maintenance is being effectually supplied by an appliance similar to that shown in Fig. 127, which provides for a continuation of the intermaxillary elastics. There being no permanent cuspids to anchor to in the upper arch, the hooks were in the nature of an extended arm from the two central bands (Fig. 214).

Case G.—*Neutroclusion complicated by labioversion of* $\overline{2}$, $\overline{1}$, $\overline{2}$, *and perversion of* $\overline{1}$. A girl, aged twelve years

(Figs. 192 and 193), whose "prominent" upper incisors and consequent facial deformity led her parents to a consultation. They also felt certain that the delayed eruption of the right upper central was abnormal. A hard mass could plainly be felt at this point, Fig. 192, which gave assurance to the belief that the tooth was impacted. The father then

FIG. 192

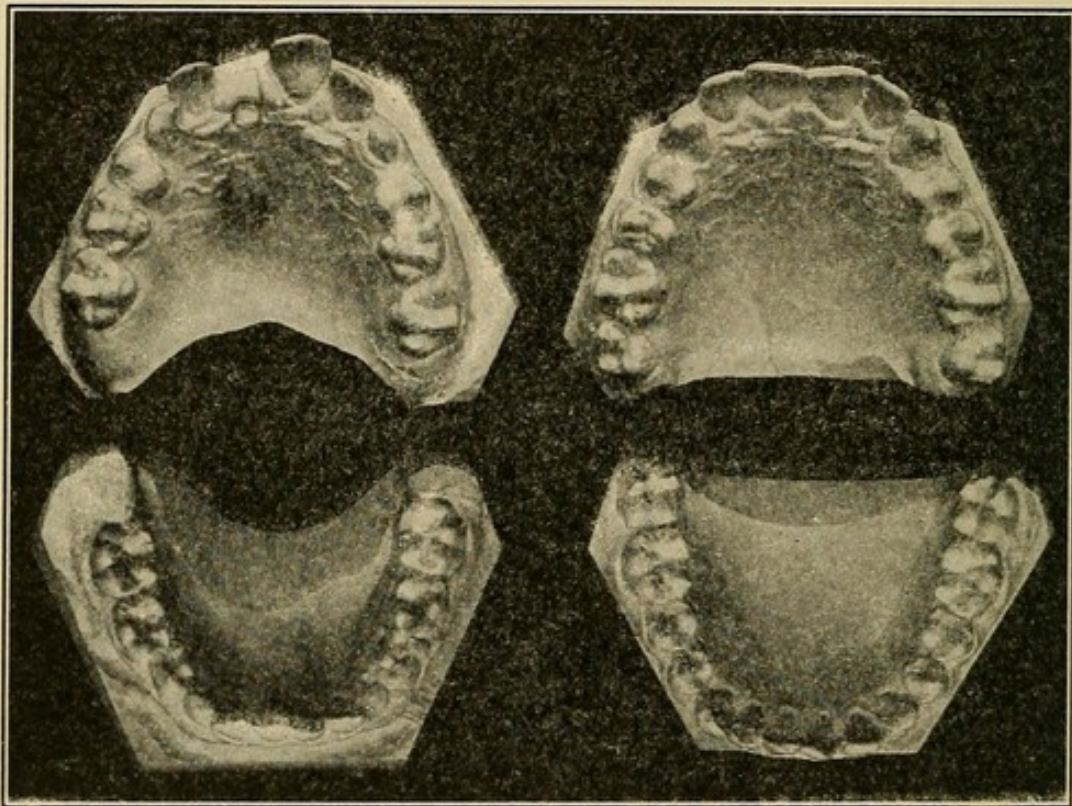


Side and front views of Case G, before and after treatment.

related the following history: He had a similar "space" on his left upper side, and during his seventeenth year two teeth erupted simultaneously, one considerably lingual to normal. Upon examination, his left central was found in labioversion, and he stated that the "extra tooth" was

extracted shortly after its appearance. The mother presented a normal denture. Models of the father's teeth were now constructed, and a radiograph advised for the daughter, with the result shown in Fig. 12. This clearly revealed the presence of a supernumerary tooth, though on the opposite side to that of the father. After the construction of his models he was asked to locate, as nearly as possible, the

FIG. 193



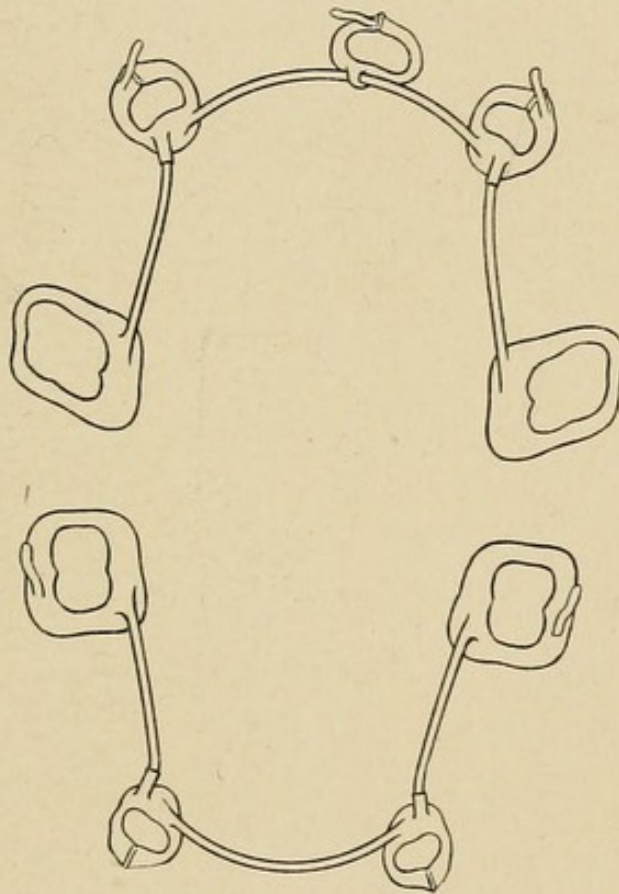
Occlusal views of case shown in Fig. 192.

point at which his "extra tooth" erupted. He marked same with a pencil at a point opposite to that shown in Fig. 193. An anesthetic was now administered to the daughter, an incision made, and the supernumerary tooth removed. After a week's delay, during which the wound had completely healed, the appliances were adjusted.

Treatment of the malocclusion was practically identical

with that provided for Case F, except that it included the extraction of all remaining temporary teeth, which the age of the patient justified. After several weeks of treatment the impacted tooth made its appearance. This was treated by means of a plain band and ligature as soon as it had erupted sufficiently, and thus brought in normal alignment.

FIG. 194

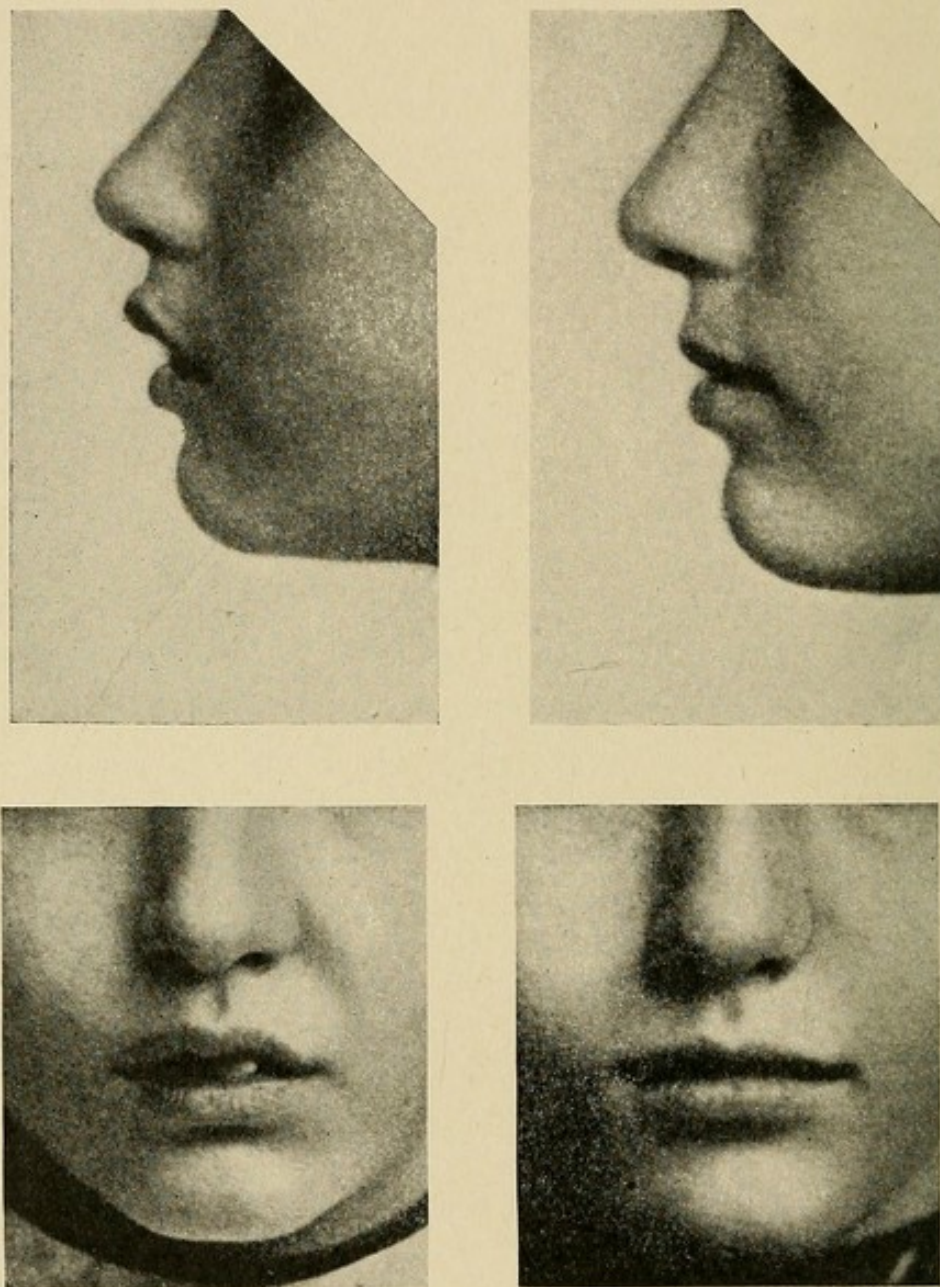


Retaining appliance which was modified for use in Case G.

Maintenance was effectually provided by the appliances shown in Fig. 194, omitting the band upon the central incisor. The right central was maintained in its corrected position by means of a wire ligature tied around the lingual connecting wire. The hooks upon the upper canine and lower molar bands, for use with elastic rubbers, were also dis-

pensed with. The facial deformity and its correction are shown in Fig. 195.

FIG. 195

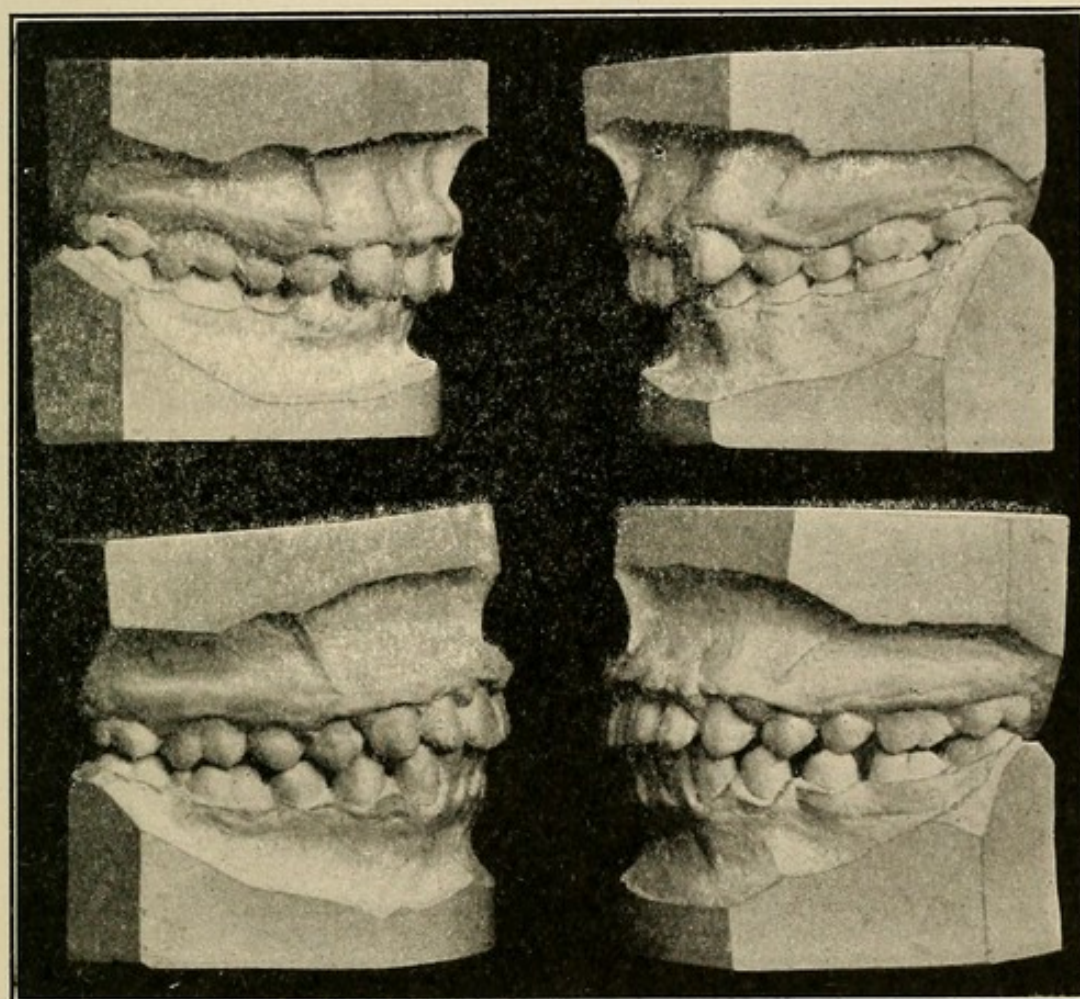


Facial relations before and after treatment of Case G.

Case H.—*Neutroclusion complicated by supra-linguoversion of the incisors.* An anemic boy, aged thirteen years (Figs. 196 and 197), who has frequently been troubled with severe attacks of tonsilitis. Examination revealed a pronounced

hypertrophy of the tonsils, for which treatment by a rhinologist was requested. Their removal having been executed, the malocclusion was corrected by simultaneous expansion of both arches.

FIG. 196



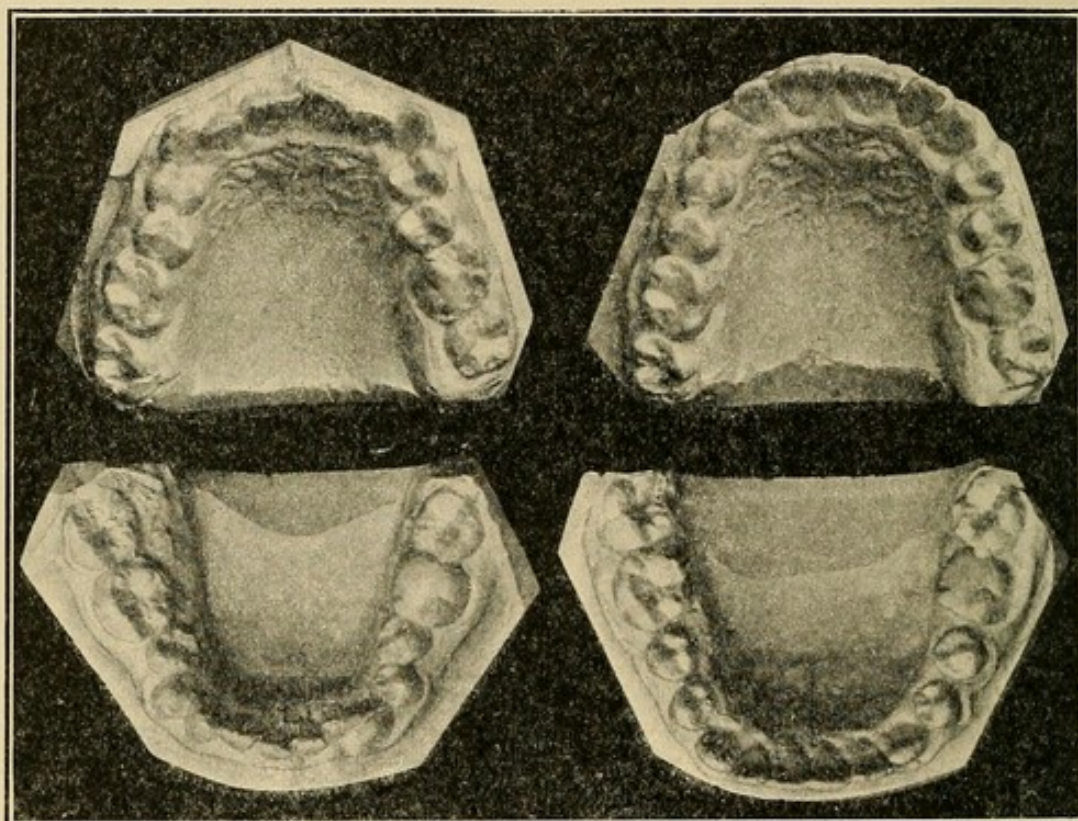
Neutroclusion complicated by supra-linguoversion of the incisors, before and after treatment, Case H.

The appliances for treatment consisted of four anchor bands and two 16-gauge alignment wires applied as in Fig. 112 for the upper, and Fig. 167 for the lower. The right lower first and second bicuspids were provided with plain bands and spurs for their rotation, as in Fig. 168. The lower canines were similarly banded. The upper incisors

were carried labially by means of silk ligatures without banding.

In the lower arch the four incisors were first attached. After considerable labial movement the cuspids were included, with rotary action. Subsequently the bicuspids were ligated to the wire. The anchor bands had been so adjusted that their clamping bolts embraced the second

FIG. 197



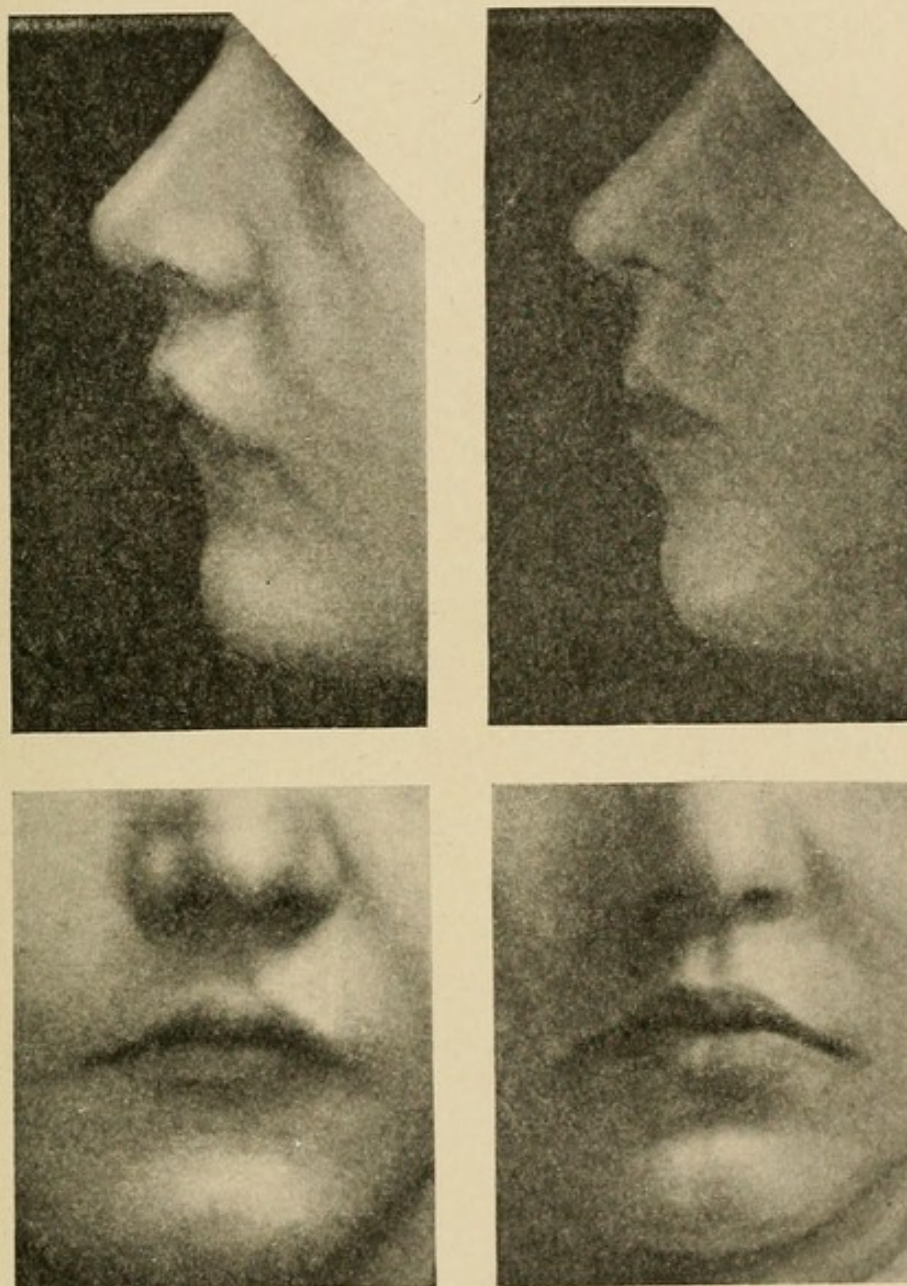
Occlusal views of models in Fig. 196.

molars, thus enlisting their additional support. But it will be noted that the left lower lateral half has moved slightly distal to normal, notwithstanding the fact that intermaxillary anchorage was applied as soon as this tendency asserted itself. Hence its continuance was provided for in the retention appliance.

Maintenance appliances consisted of an apparatus for

the lower as illustrated in Fig. 140, with a hook attached to the buccal surface of the left lower molar band for the

FIG. 198

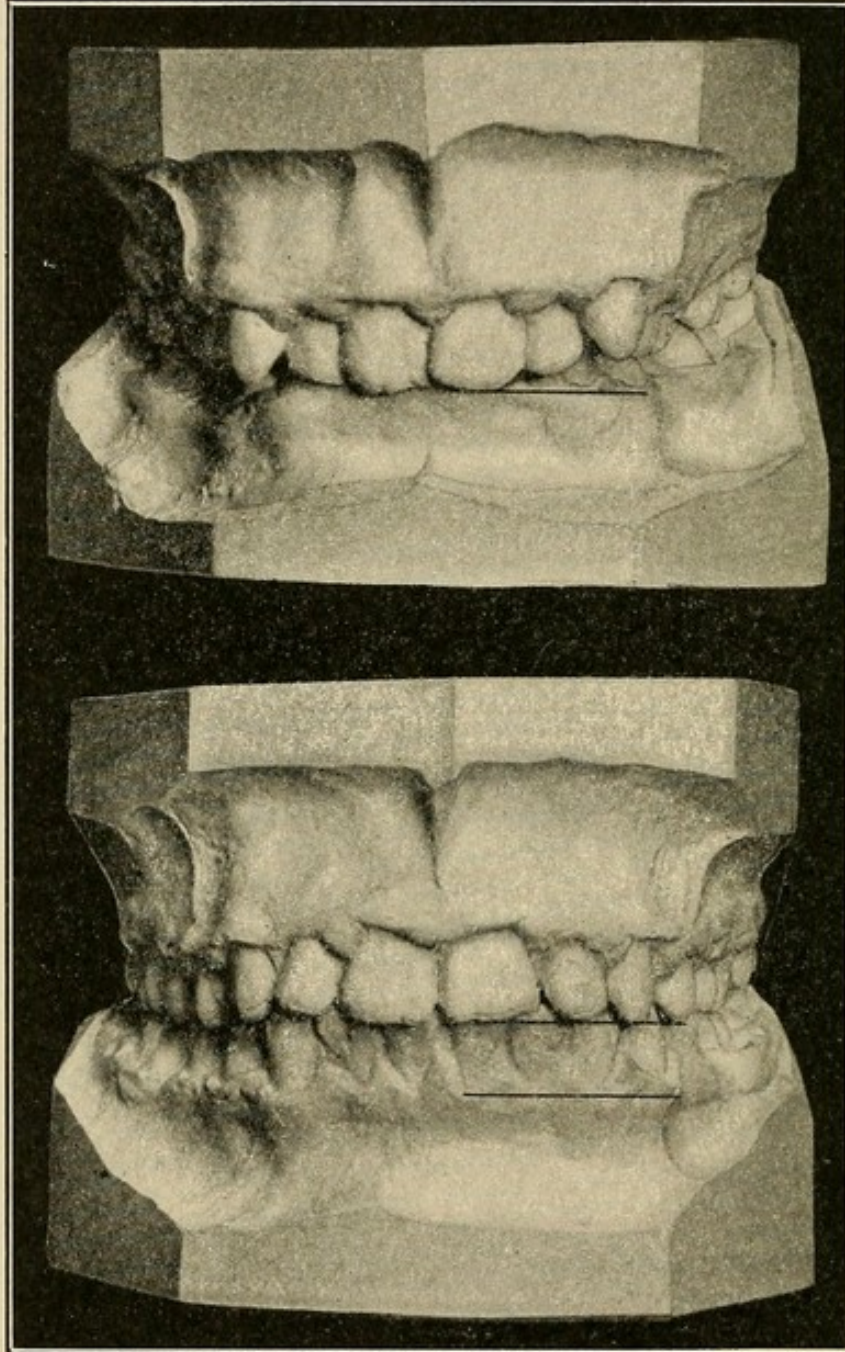


Facial relations before and after treatment in Case H.

intermaxillary elastic, and the union of the two bands on the right lower bicuspid. These bands were united with solder at their points of contact, and then reset with cement.

In the upper arch an appliance like Fig. 194 (upper diagram) was applied, with the exception that the spur on the right

FIG. 199

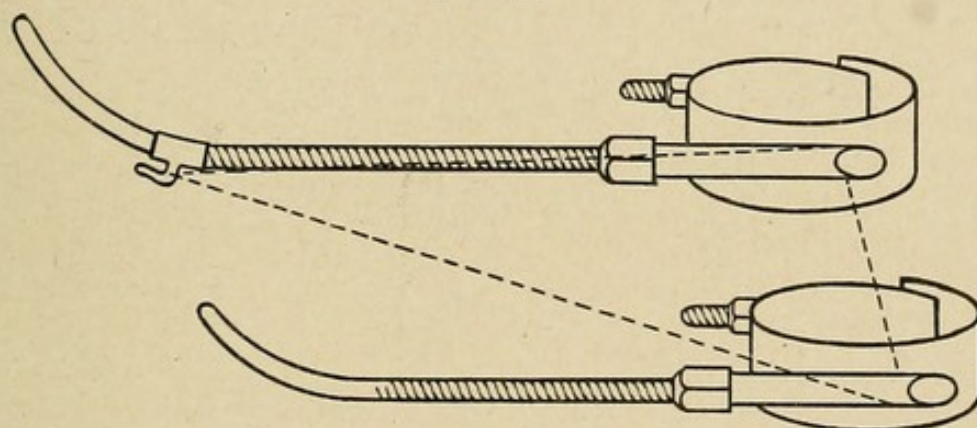


Front views of the models of Case H, before and after treatment.

upper cuspid band was dispensed with. Similarly, the incisor band shown in the drawing was prepared for the right central, instead of the left.

The vast improvement in his facial expression and general well-being is clearly shown in the photographs in Fig. 198. The correction of the occlusal plane, which had been totally destroyed in the anterior region of the arches by the marked "overbite," is shown in Fig. 199. This was only partly affected by the manner of application of the ligatures to the upper incisors (see Fig. 172); and by the action of the alignment wire on the lower (see Fig. 173). The most effective aid for the removal of such deviations is shown in Fig. 200, which promotes an elongation of the posterior teeth.

FIG. 200



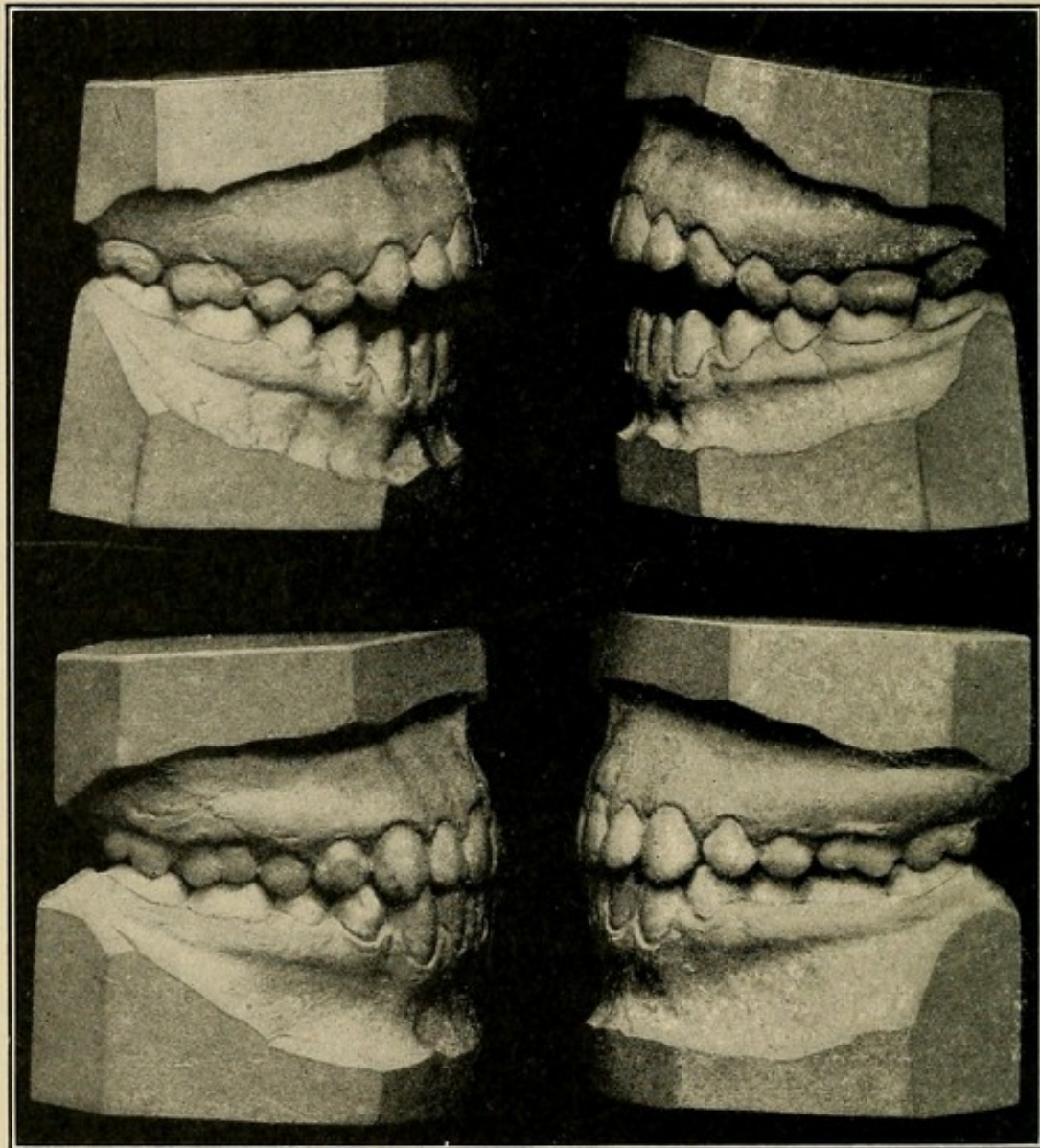
Intermaxillary anchorage modified to effect elongation of the molars.

Case I.—*Neutroclusion complicated by extreme infraversion of the incisors, cuspids, and first bicuspids.* A girl, aged sixteen years (Figs. 201 and 202), who was referred by a rhinologist after having been operated on for adenoids. It is extremely doubtful, however, whether they had any causal relation to the malocclusion. The arches are too symmetrical to indicate nasal involvement. Examination revealed an unusually large tongue, and the patient admitted being addicted to the habit of nursing same.

Aside from the elongation required for all the teeth involved, the arches need slight alteration in form by widen-

ing in the region of the cuspids, and a rotation of the lower centrals, which are in torsion. The infraversion is, moreover, too extensive to warrant an attempt at correction

FIG. 201

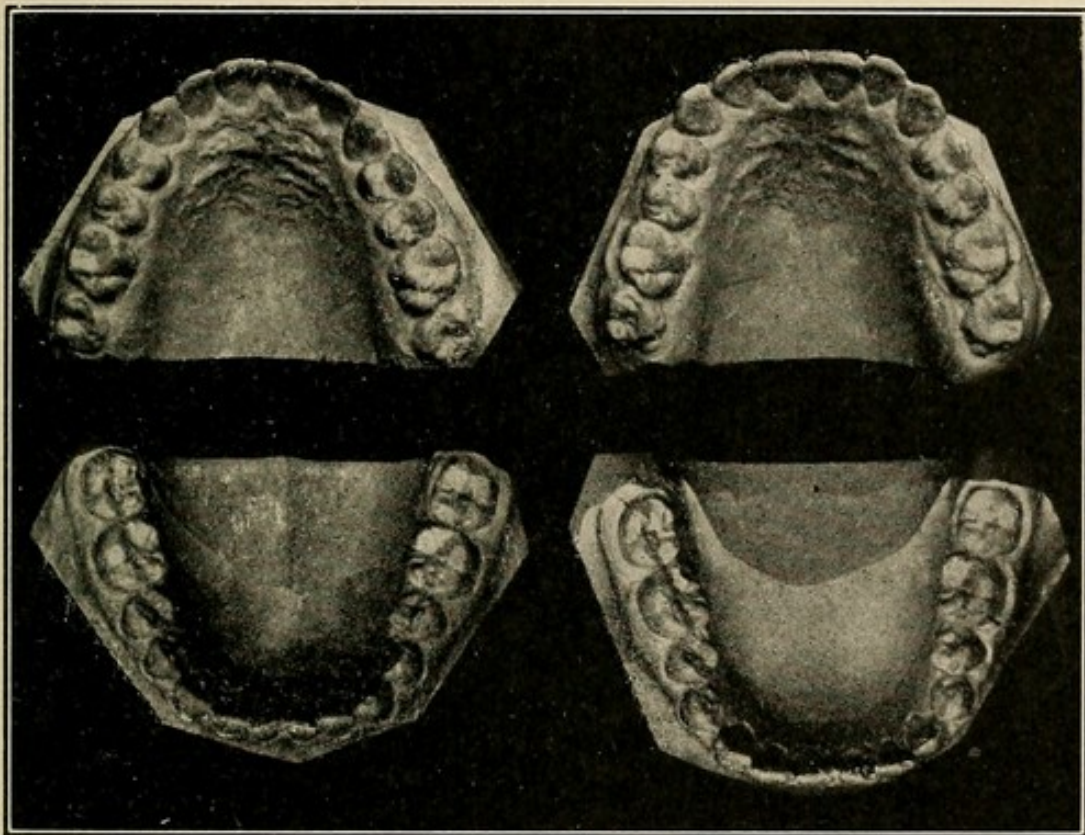


Side views before and after treatment of Case I.

by using only the spring of the alignment wire. Such an attempt would surely result in displacement of the molar teeth (see Fig. 170). Hence the use of direct intermaxillary anchorage (Fig. 171) was resorted to. The incisors and

canines were provided with bands spurred as in Fig. 203. These afforded secure adjustment for the alignment wires, and were carefully prepared and set with cement, so that they were all on the same plane. The intermaxillary elastics were worn constantly during the hours of sleep and during as many of the waking hours as was compatible with the patient's necessary comforts.

FIG. 202

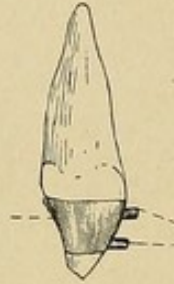

Occlusal views before and after treatment of case shown in Fig. 201.

During the first stages of treatment the elastic bands were cut from one-eighth-inch rubber tubing, and were so thin as to exert only gentle pressure. Gradually their thickness was increased, and ultimately two were applied to each side. These extra precautions were exercised to prevent death of the pulps. The treatment occupied a period of six months.

Maintenance has now been effectually provided by appliances of a design as shown in Fig. 140. Small hooks, constructed of 20-gauge wire, were soldered to the labiogingival borders of the canine bands, to which light elastics were applied at night, and subsequently on alternate nights. In

FIG. 203



Shows band used for anchorage of the alignment wires in treating Case I.

addition, the central incisors were provided with plain bands with spurs on their lingual surfaces, so placed as to overlap the lingual connecting wire. These bands were also united with solder before cementing into position, thus adding strength to the upper, and retaining the lower corrected torsoversions.

CHAPTER XVI

TREATMENT OF DISTOCLUSION

BILATERAL DISTOCLUSION

THE distinguishing characteristic of this type of deformity is a bilateral distal relation of the lower arch when the teeth are brought into occlusion. This may be due (*a*) to disto-version of the lower teeth, (*b*) to arrest of development of the mandible, or (*c*) to a posterior development of the glenoid fossæ, resulting in a posterior position of the lower jaw.¹ The various minor peculiarities which usually complicate cases belonging to this class are practically identical with those of complex neutroclusion.

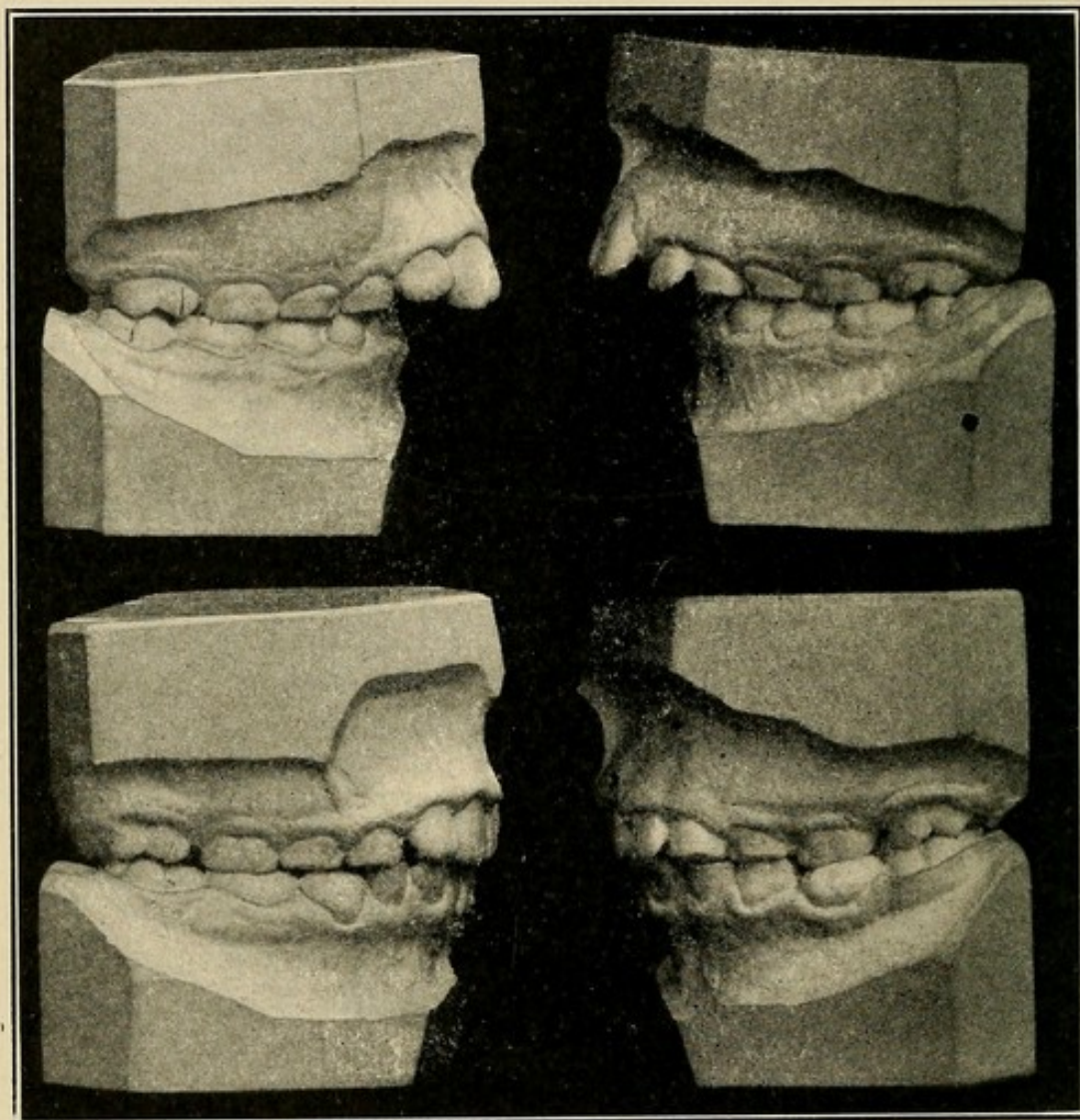
Bilateral Distocclusion. Complicated by Extreme Labioversion of the Upper Incisors

Case J.—A delicate and timid boy, aged eight years (Figs. 204 and 205), who had adenoids removed during his fifth year by a rhinologist. He has, from infancy, been troubled with rhinitis and mouth breathing which the above-mentioned operation and continued nasal treatment failed to cure. He had recently been placed under the care of another rhinologist, who immediately recognized the extreme dentofacial deformity and the utter futility of nasal treatment unassisted by orthodontic treatment. The facial deformity and arrest of development of the mandible at this time are clearly

¹ Federspiel, Proc. Amer. Soc. Orthodontists, 1911.

shown in Fig. 84. The narrowing of the upper arch (which is symptomatic of such an abnormal nasal condition) is shown in the upper occlusal view of Fig. 205 (left upper corner).

FIG. 204

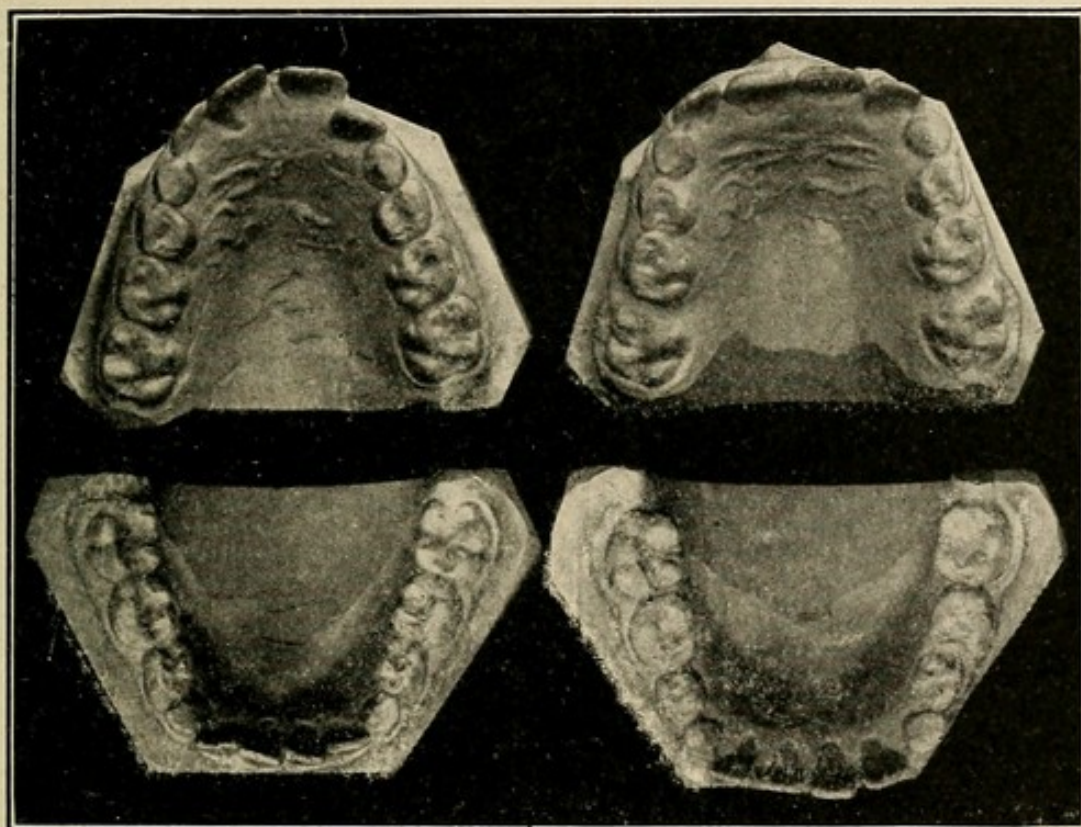


Side views before and after treatment of Case J.

The plan of treatment adopted in this case was after the method suggested by Angle, for which an appliance composed of the following elements was used: Four molar anchor bands with buccal tubes and lingual extension wires, as previously described, were anchored to the first permanent

molars; two 16-gauge alignment wires with tube hooks for the upper; four plain bands with spurs on the distolingual borders of their lingual surfaces for the upper incisors. The lower incisors were tied to the alignment wire with silk ligatures. The lingual extension wires were similarly fastened to the alignment wire for the expansion of the lower arch.

FIG. 205



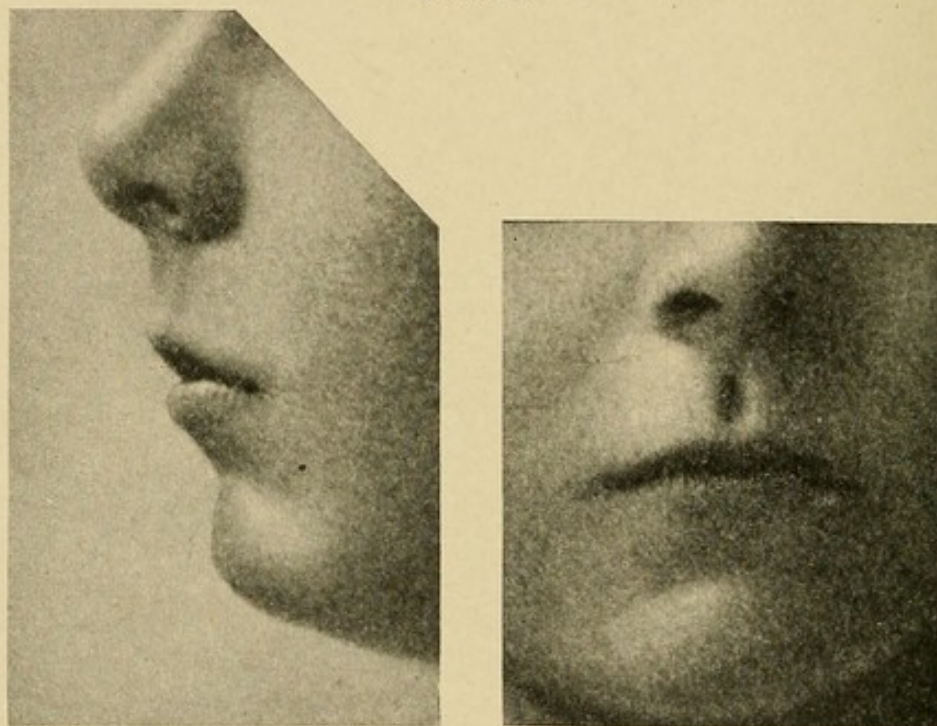
Occlusal views of Case J.

This apparatus furnished the source of anchorage for intermaxillary elastics attached to the tube hooks on the upper wire (see Fig. 122).

In the early stages of treatment only the lingual wires were tied to the upper alignment wire, to promote buccal movement of the upper temporary teeth. The nuts mesial to the buccal tubes were so adjusted that the alignment wire

on the upper arch failed in contact with the labial surfaces of the incisors. Hence the pressure of the intermaxillary elastics was entirely exerted upon the upper first permanent molars, resulting in their full distal movement. This being accomplished, the nuts were released and the alignment wire allowed to rest upon the incisors, which resulted in a reduction of their labioversion. Finally, ligatures were

FIG. 206



Facial relations of Case J after four months of treatment. (Compare with Fig. 84.)

passed from the lingual spurs on their bands to the alignment wire to effect their rotation. Such ligation in the earlier stages must always be dispensed with, to avoid undue elongation.

The treatment up to the time of maintenance occupied a period of four months. The occlusion of the teeth at this time is shown in the illustrations already referred to, and the vast improvement in facial balance is set forth in Fig. 206.

It may be of interest to note that mouth breathing ceased entirely during the second month of orthodontic treatment.

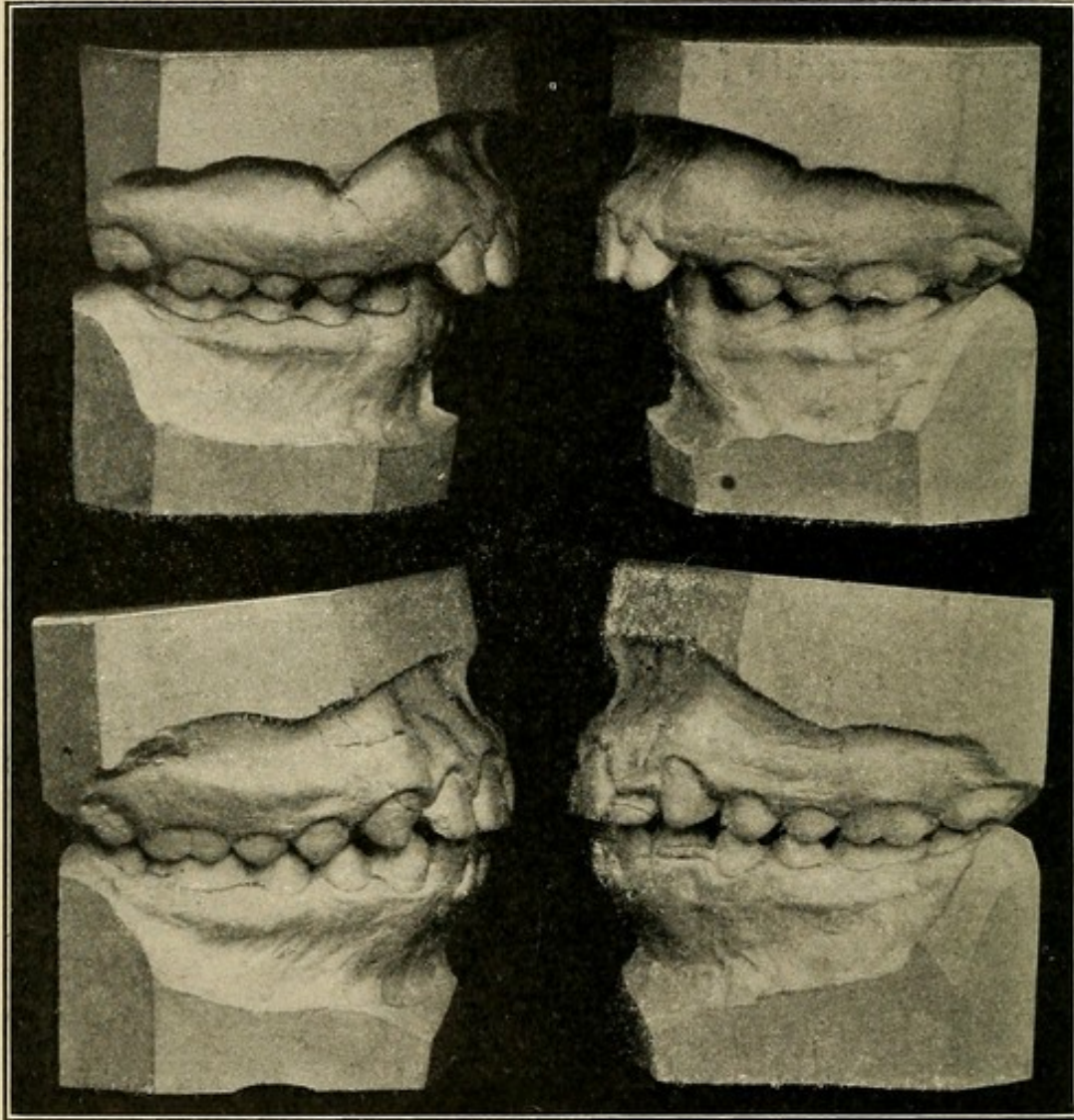
Maintenance is being successfully accomplished by an appliance similar to that shown in Fig. 179, though the following minor alterations were necessitated by the distoclusion. The lower molar bands were provided with small hooks constructed of 20-gauge iridioplatinum wire attached to their mesiobuccal angles, close to the gingival margin. The two bands upon the upper lateral incisors were connected with a labial wire of the same gauge, which was bent into hook form at each end, immediately distal to the canine embrasure. During the first month of retention, delicate elastics were worn continuously. Subsequently their use was limited to the hours of sleep, and in the last half of the first year to the sleeping hours on alternate nights only.

The entire appliance was now removed and the teeth thoroughly cleansed, after which it was reset. The latter precaution was for a twofold purpose; partly to maintain the form of the arches, but more especially to exert a controlling influence on the erupting bicuspids. In this stage of retention the lingual wire is of inestimable value. The growth in the mandible during the last year has been very marked.

Case K.—A strong boy, aged twelve years (Figs. 207 and 208), whose history does not relate nasal treatment. Nor did an examination by a rhinologist reveal any pathological nasal condition, though he is a confirmed mouth breather. It will be noted, too, that the occlusal views of the pre-treatment models (Fig. 208) exhibit rather symmetrical arches with very little arrest of development. The facial deformity is not nearly as severe as in Case J. There can be

no doubt that this deformity was easily recognizable during his sixth year, possibly earlier, though on this point his parents are not certain. Such malocclusions are frequently

FIG. 207



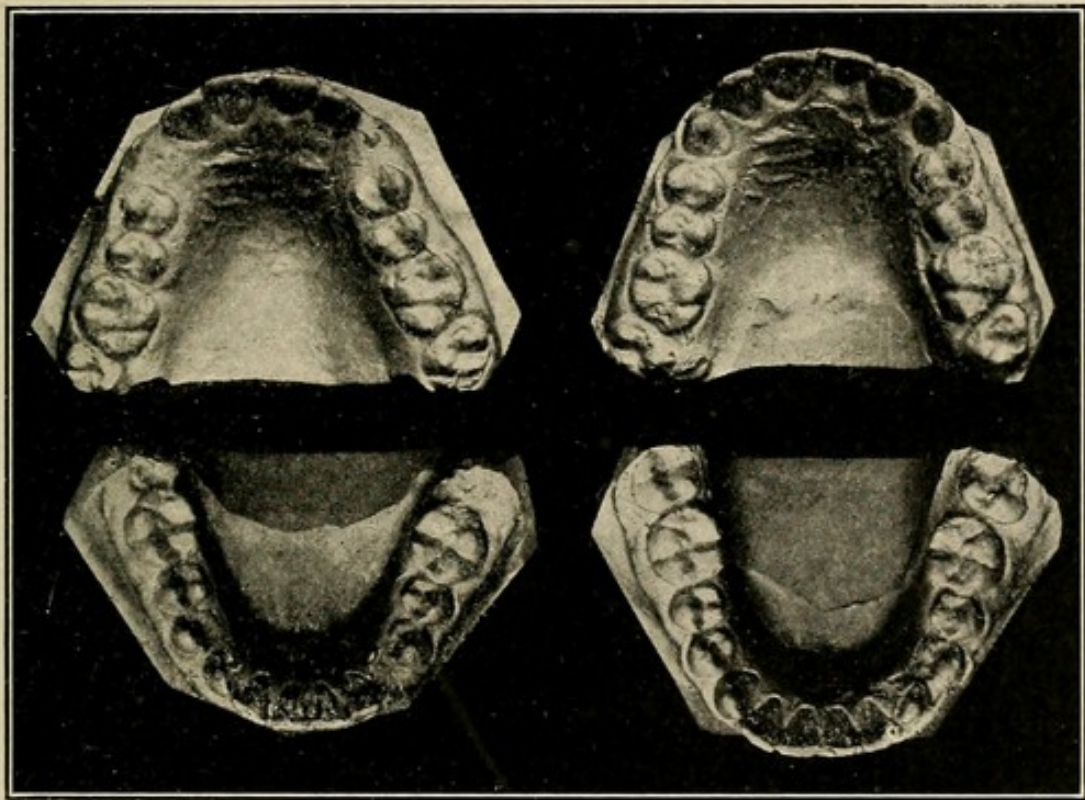
Side views before and after treatment of Case K.

attributed to nasal obstruction, and explained on the hypothesis that adenoid vegetations were undoubtedly a contributing cause during childhood, and that their resorption (which is known to occasionally take place) has removed

every trace of them. But that is purely an hypothesis and difficult of conclusive demonstration.

Furthermore, this boy provides the following interesting family history: His father is dark haired, of English descent, presents an extreme bilateral distoclusion of a type under consideration, and a very decided dolichocephalic head form. In short, his is a typical adenoid face. His mother,

FIG. 208



Occlusal views of Case K.

on the other hand (whom he strongly resembles in complexion, hair and eye color, as well as in tooth form), is of Celtic extraction, of the reddish blonde type, with freckled skin, with prominent malar bones, brachycephalic head form, and prognathous denture (though normal in occlusion). Hence the temptation to blame heredity for the deformity, to speak of it as an inherited disharmonism. But this would

again be purely an hypothesis and equally difficult of verification.

Treatment was similar to that described for Case J, though the lingual extension wires were dispensed with in the upper arch. The molar anchor bands were adjusted with their clamping bolts pointing distally. After the normal mesiodistal relations between the molars had been established by means of the intermaxillary elastics, the upper molar bands were removed and bands placed upon the second bicuspids. The first bicuspids were attached to these with wire ligatures. After their distal movement, the nuts were released and pressure brought to bear upon the upper incisors. In the meantime the lower arch was gradually enlarged for the accommodation of the left canine.

An interesting feature of the case was a porcelain crown upon the left upper central incisor, but which did not become the seat of any discomfort. There being no torsoversion present in any of the upper incisors, plain bands were contraindicated.

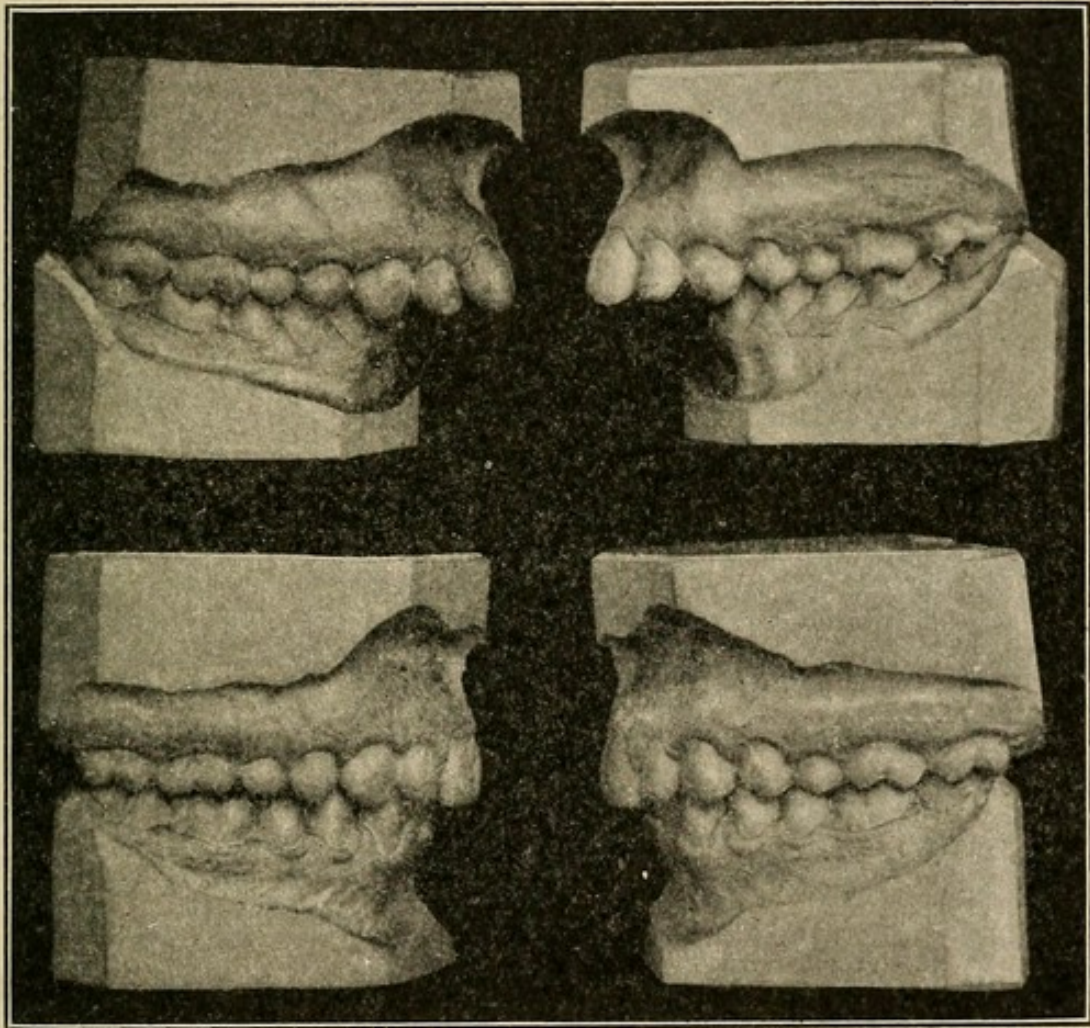
The retention appliance was identical in design to that described for Case J. The bands shown in the after treatment models of the illustrations were substituted for same at the close of the period of retention.

Case L.—A youth aged nineteen years (Figs. 209 and 210), showing complete distoclusion as a result of postponement of treatment. Note the extreme narrow upper arch, and the pronounced labioversion of the upper incisors. This case is a fine exhibition of the axiom set forth in the chapter on Prognosis, that nature and time rarely exert a corrective influence on a malocclusion.

The improvements in the occlusion of the teeth shown in

the illustrations were accomplished in the short period of four months. The case is one of the first the author ever attempted to treat, and as he now reflects over his seeming achievement, he is quite convinced that a radical change in the temporomandibular articulation, viz., the mounting

FIG. 209

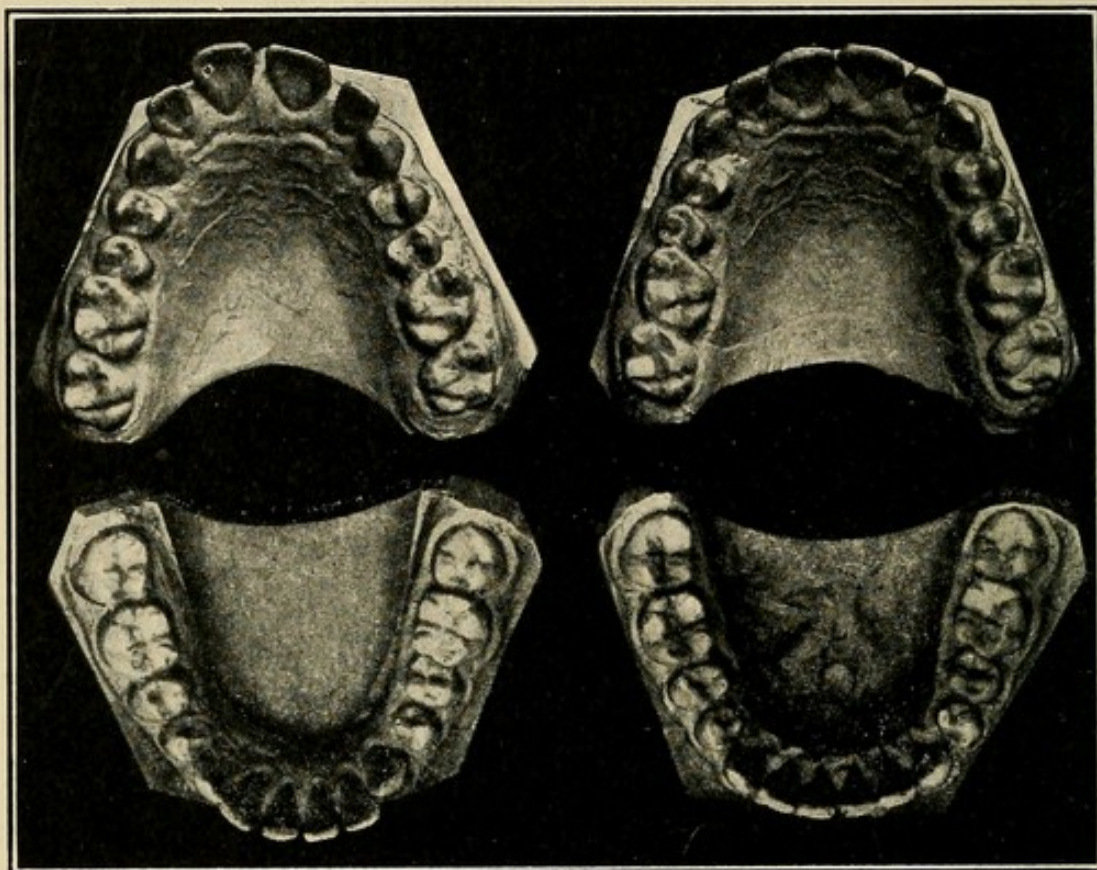


Side views before and after treatment of Case L.

of the condyles on the eminentia articularis, was largely responsible for the results.

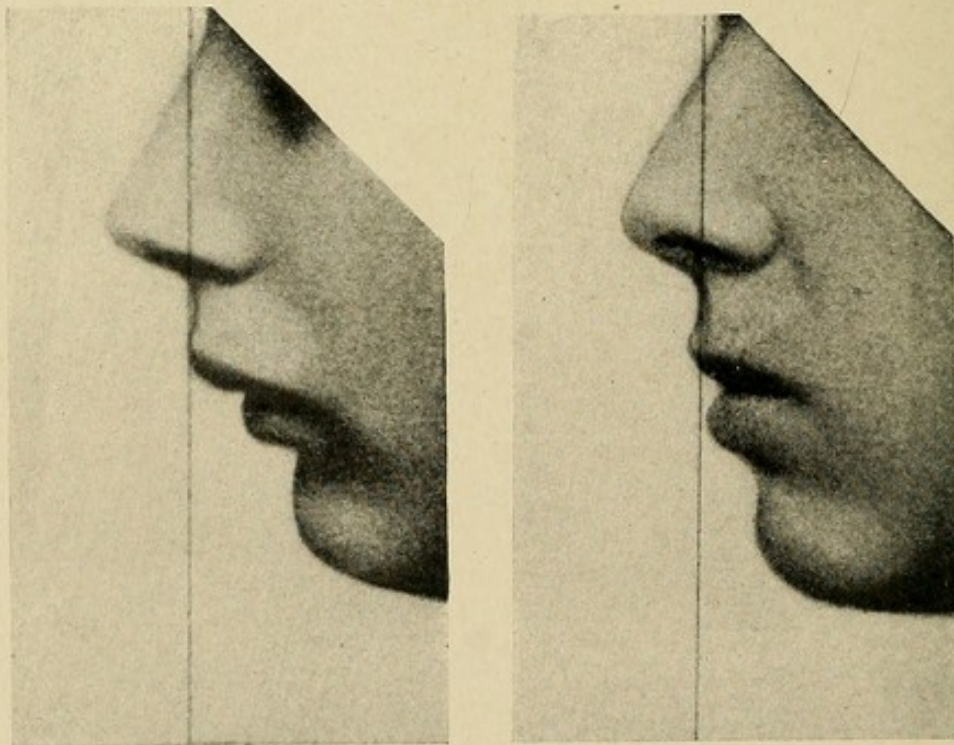
The treatment was identical to the plan already described, though retention was provided with vulcanite plates with labial wires. The effect upon the facial lines is shown in

FIG. 210



Occlusal views of Case L.

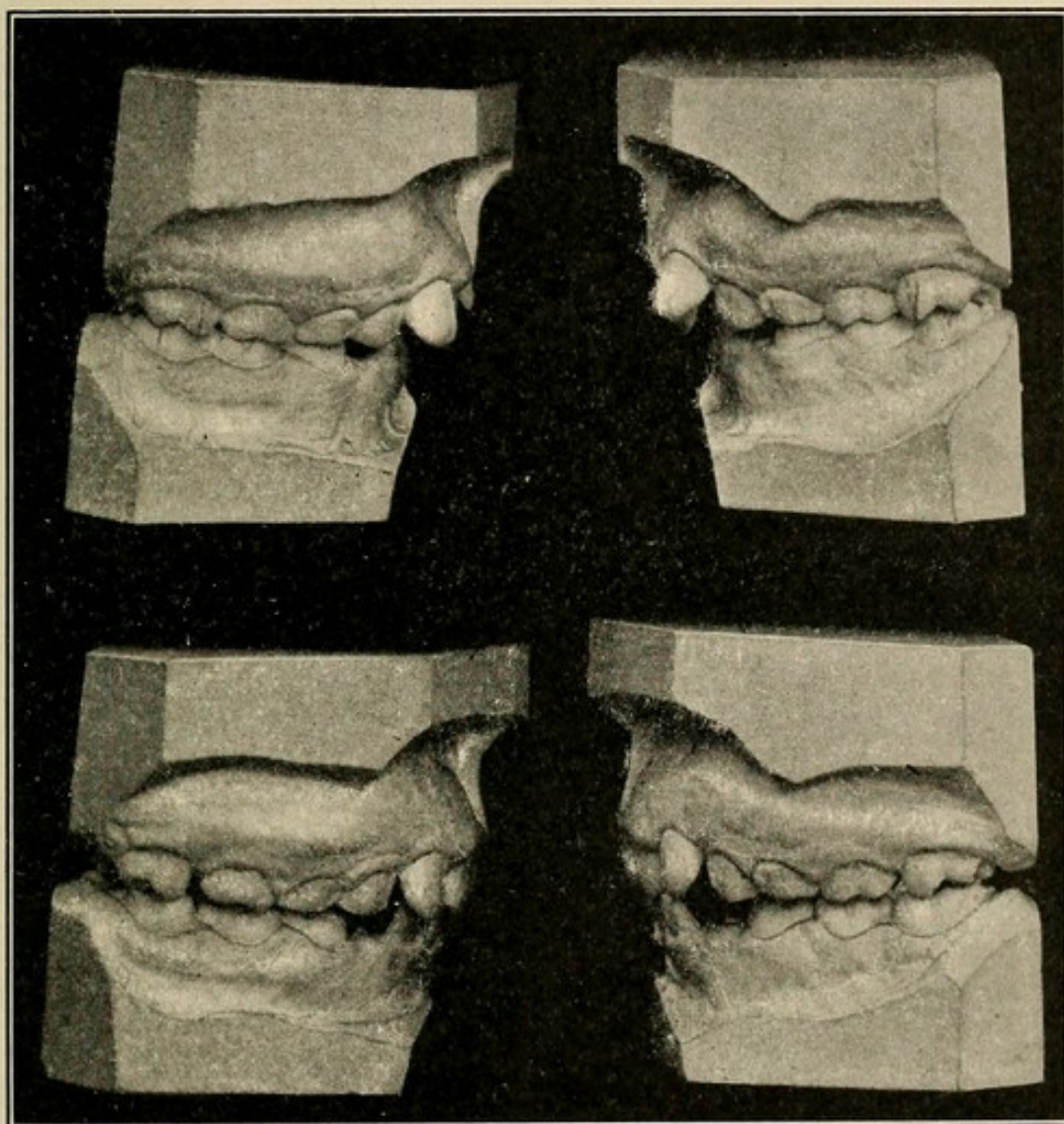
FIG. 211



Profile of Case L, before and after treatment.

Fig. 211. The corrected condition was readily maintained for two years, during which time the patient was under the author's care. Since then he has lost all trace of him, and he regrets that the ultimate results are not now available.

FIG. 212



Side views of Case M.

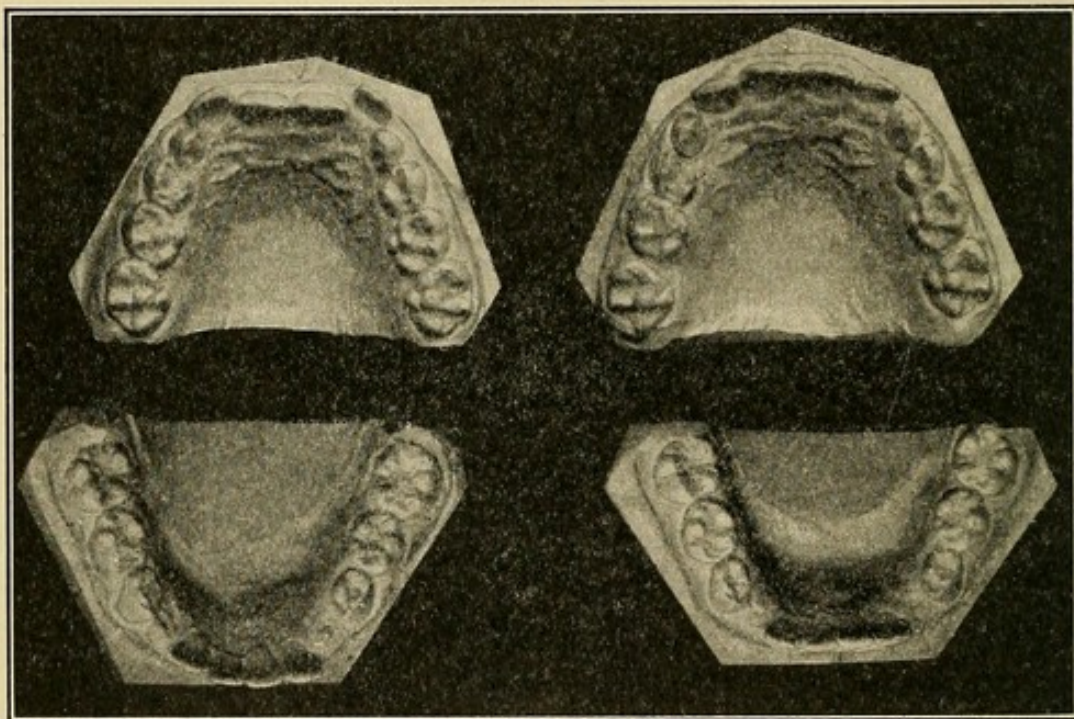
Such extreme deformities form interesting studies from various points of view. First, they recall the inclined plane of Catalan and Kingsley for "jumping the bite;" second, they emphasize the many recent criticisms directed against

that plan of treatment; third, they forcibly impress one with the necessity for early treatment, since they offer convincing proof that neglect frequently results in jaw deformity, after which the accompanying malocclusions are but symptoms. (See Chapter XVIII.)

Bilateral Distocclusion Complicated by Linguoversion of the Upper Incisors

Case M.—A girl, aged ten years (Figs. 212 and 213), with negative history. The facial deformity was marked, and of a type as illustrated in Fig. 83. The prognosis of cases

FIG. 213

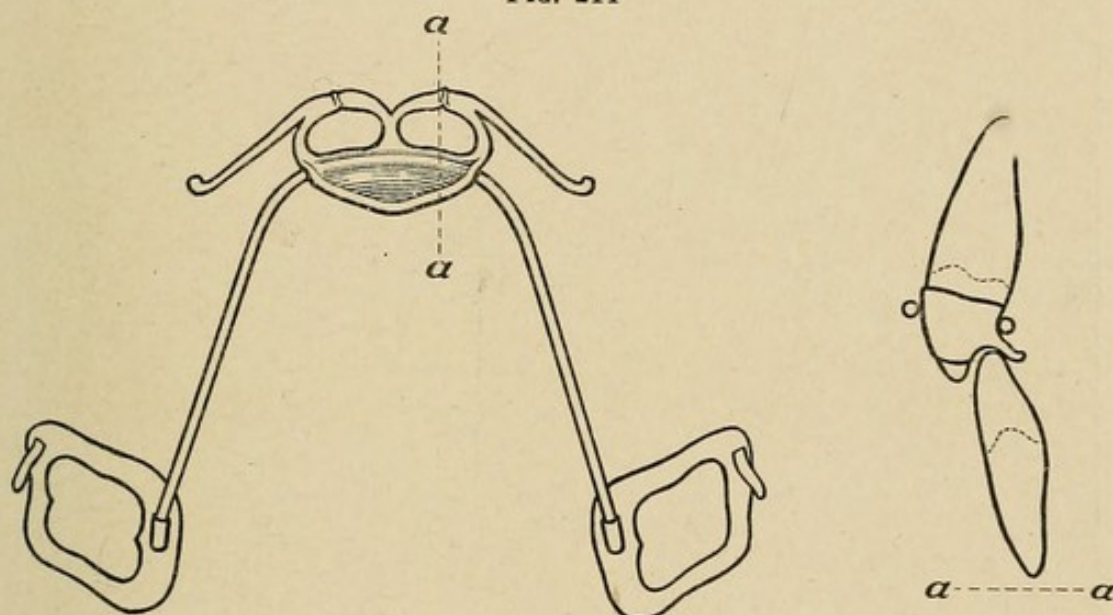


Occlusal views of Case M. (The lower models should be transposed.)

belonging to this group has previously been emphasized, the tendency being toward an arrest of development in the mandible (see Fig. 89). Postponement of treatment would unquestionably result in an aggravation of the deformity.

Treatment was instituted by means of anchor bands, alignment wires, plain bands for the upper incisors, and intermaxillary elastics. The details of application are in many respects similar to those described for the former group, though there is need for less widening of the arches. Furthermore, the upper centrals require a labial movement, which can easily be accomplished by reciprocal anchorage in combination with the lingual movement of the adjoining laterals (see Fig. 147).

FIG. 214



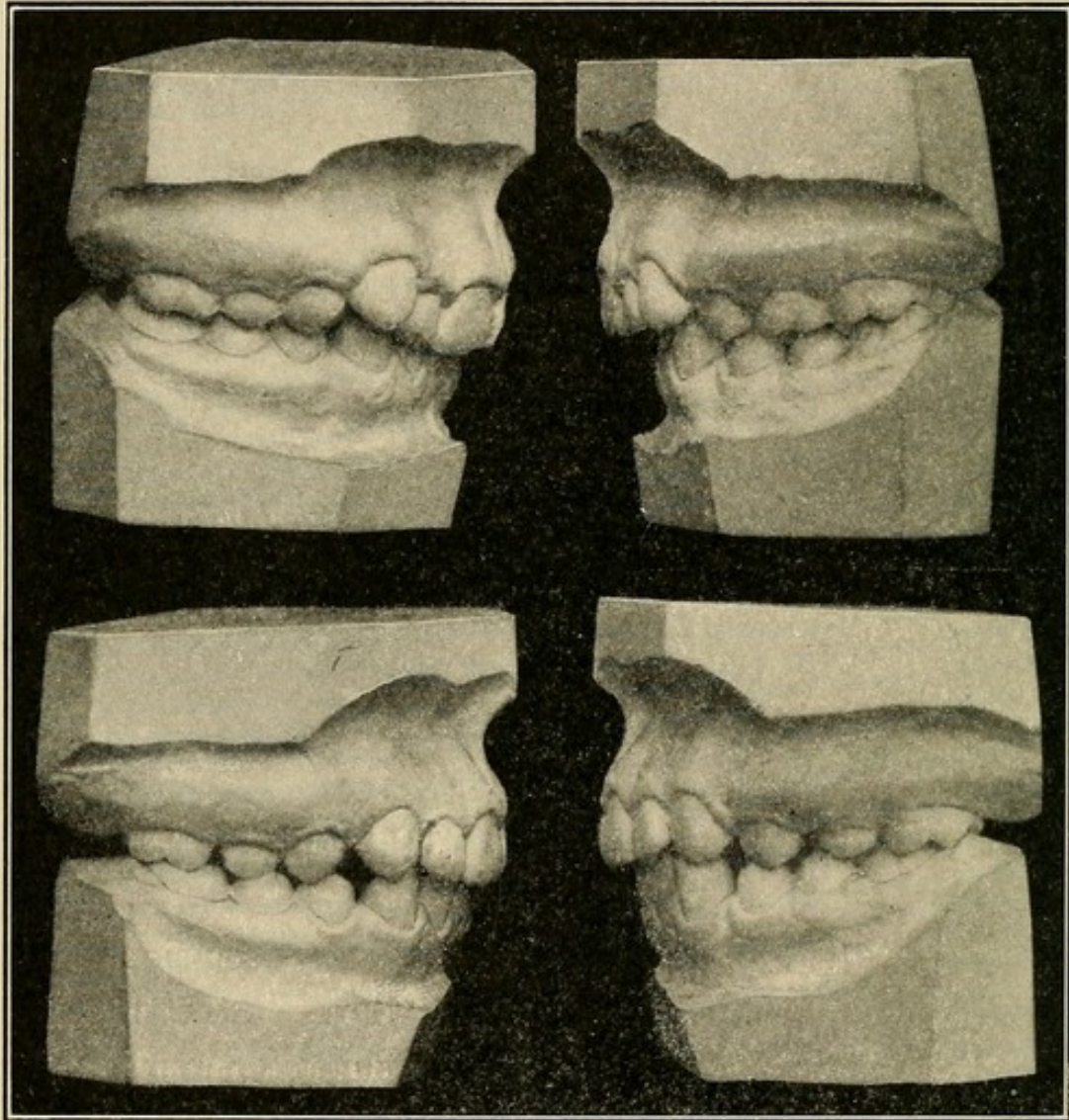
Retaining device for the upper arch of Case M, providing for a continuance of the intermaxillary elastics. (After Rogers.)

As pointed out by Angle, the loss of occlusion of the anterior teeth permits their elevation, so that the treatment should aim at a reduction of their supraversion. But in view of the fact that such action is extremely difficult to obtain, and a growth of the mandible especially desirable, the plan illustrated in Fig. 200 (resulting in an elongation of the molars) has been widely accepted.

Such continued action of the intermaxillary elastics is now provided for in the retaining appliance (Fig. 214). The

bands upon the centrals are united and attached to the lingual wire, which extends to the molar bands, thus providing for maintenance of arch form. In addition, an inclined plane of metal is provided, and so adjusted that the

FIG. 215



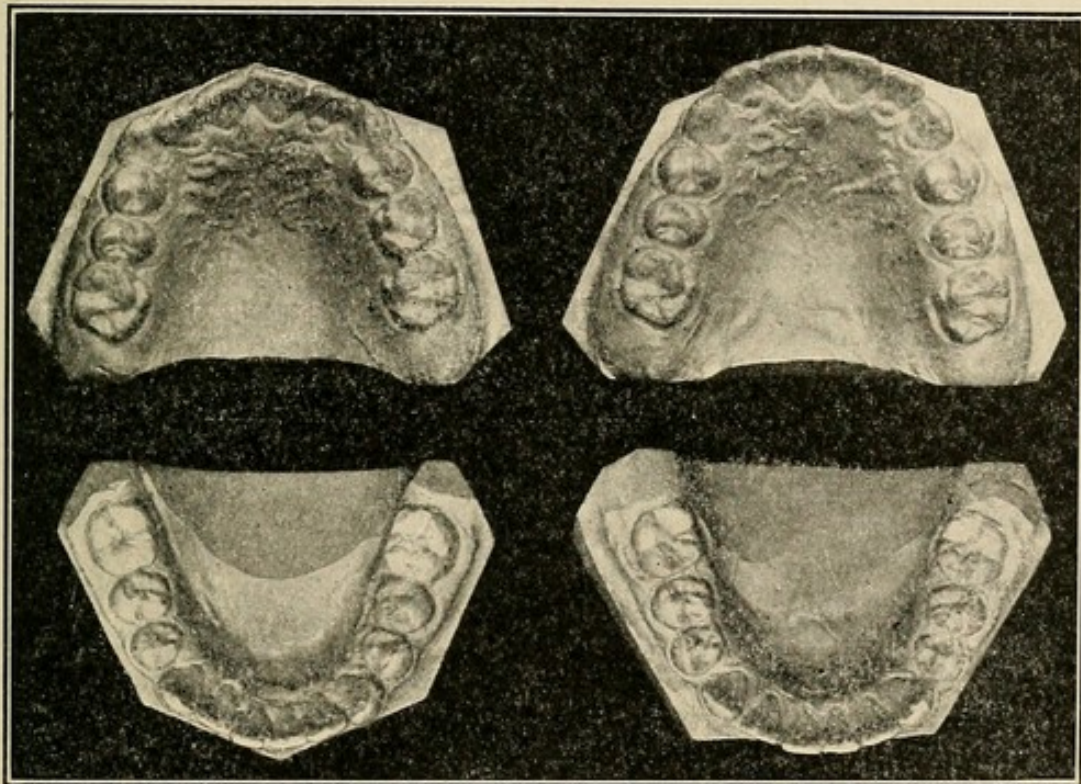
Side views, before and after treatment, of Case N.

“bite” will remain open to the desired height (section *a-a*). On the labial surfaces of the incisor bands extended hooks are provided for the fastening of the elastics, which are also attached to hooks on the upper and lower molar bands. In

the lower arch the appliance usually follows the design illustrated in Figs. 140 and 179, depending on whether the canines have, or have not, erupted.

Case N.—A girl, aged thirteen years, the daughter of a physician, with negative history (Figs. 215 and 216). The etiology in such cases is still obscure; they are in all probability due to intrinsic factors which we have failed to recog-

FIG. 216



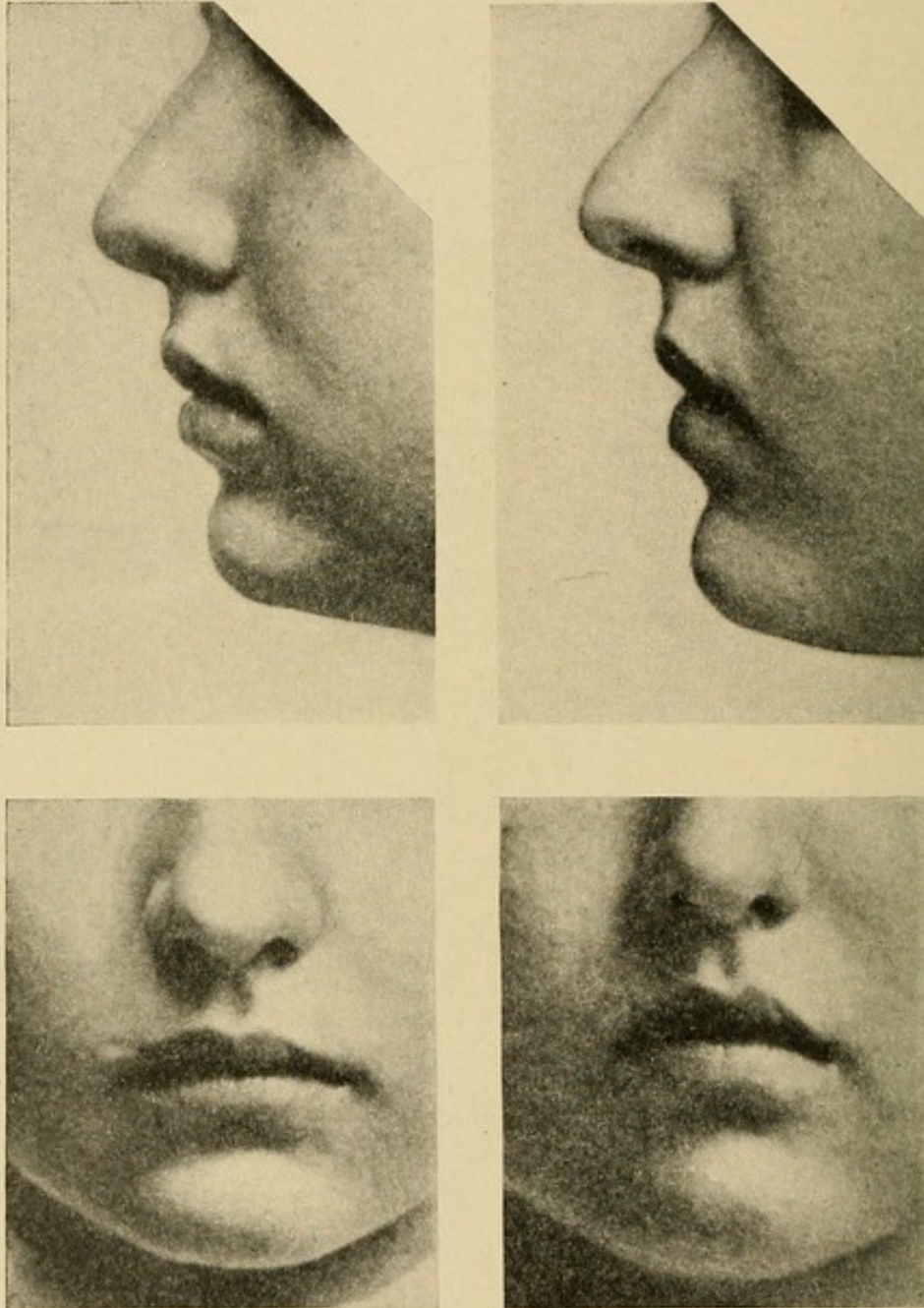
Occlusal views, before and after treatment, of Case N.

nize. The normal nasal and lip function accompanying this type naturally implies facial deformities less severe than in the group complicated by labioversion of the upper incisors and nasal obstruction. A well-developed mental eminence in this case especially precluded the possibility of severe facial deformity (Fig. 217).

The details of treatment were practically the same as

for the former case, except that the laterals were carried labially with the centrals, and the rubber wedge for reciprocal action applied to the canines. The bicuspid were carried

FIG. 217

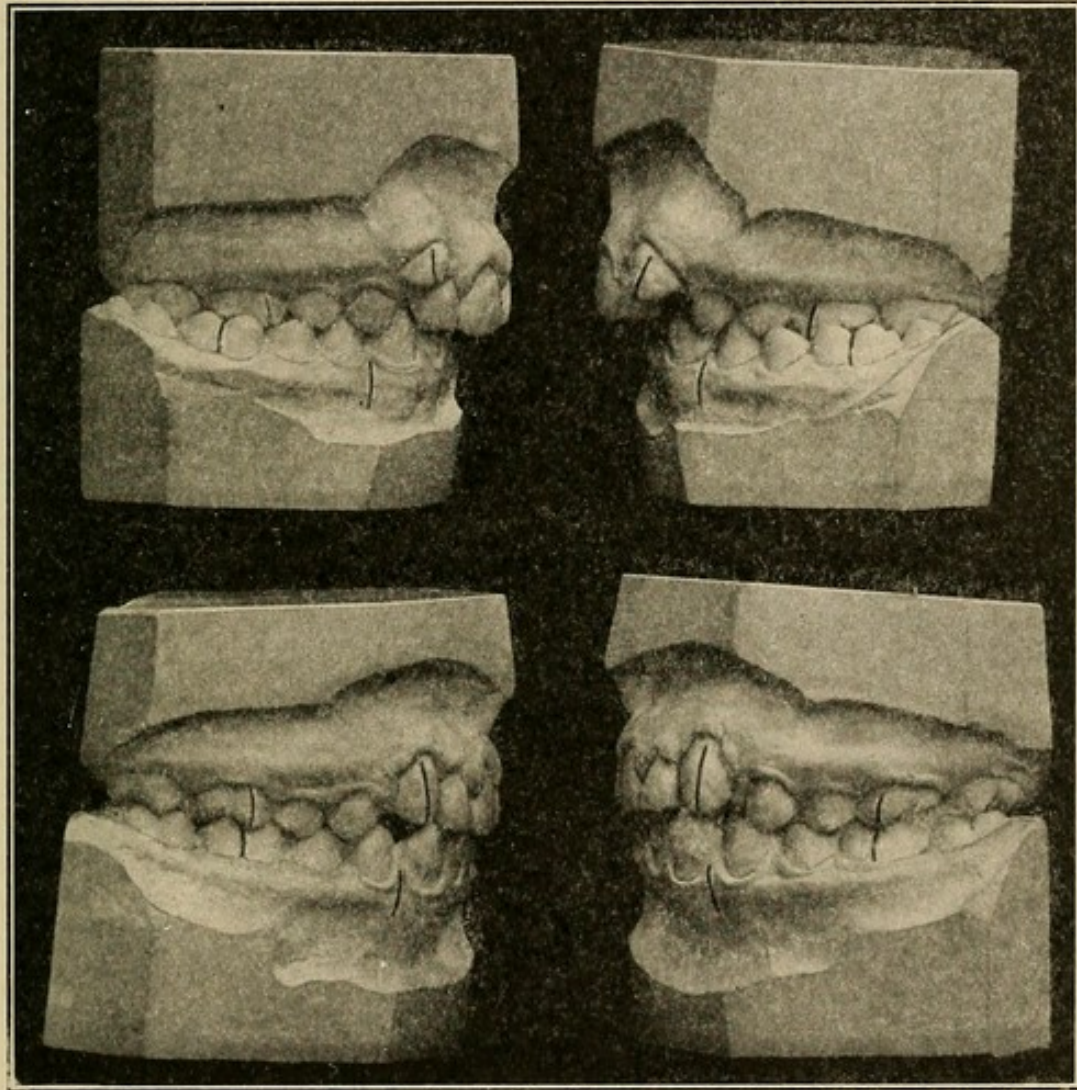


Facial relations, before and after treatment, of Case N.

slightly buccally, and distal movement of the upper and mesial movement of the lower molars affected by intermaxillary elastics.

For maintenance after tooth movement, an appliance as shown in Fig. 140 was applied to the lower arch, with the addition of hooks to the buccal surfaces of the molar bands. In the upper arch a plain band upon each lateral was connected with a wire on the labial extending distally beyond

FIG. 218

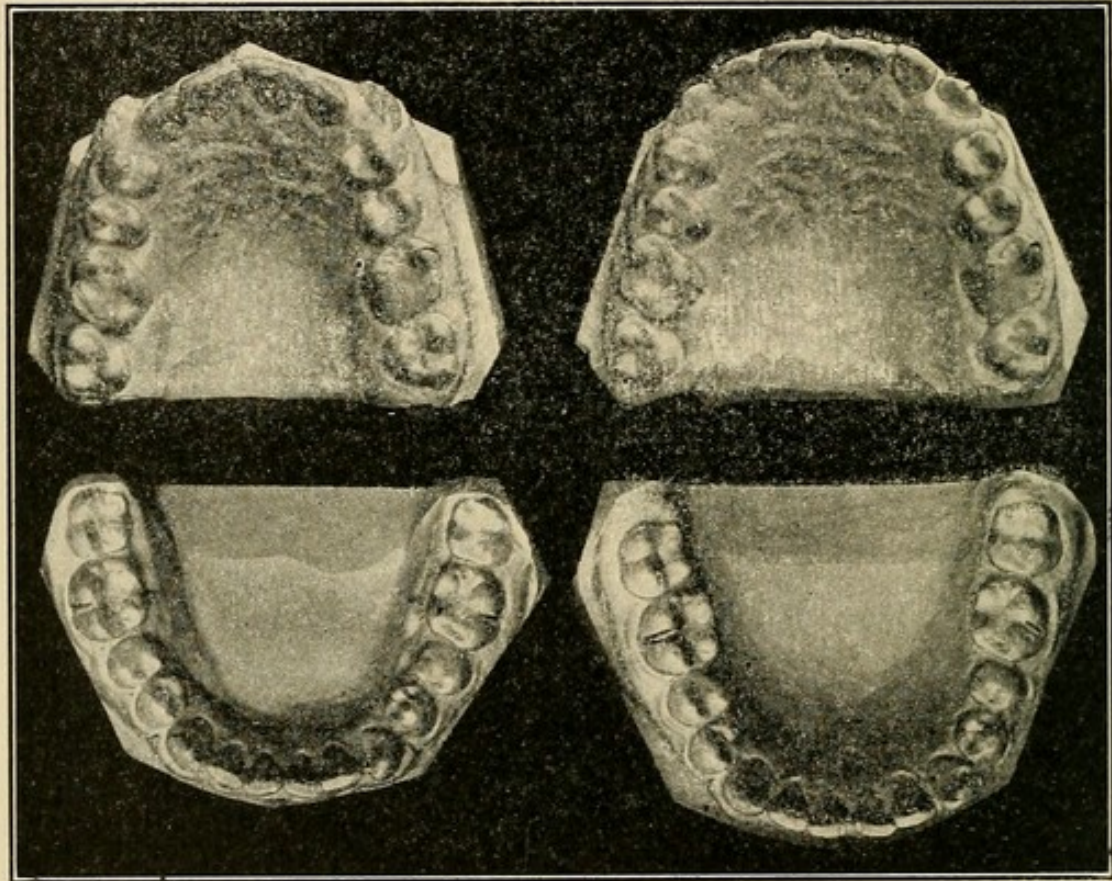


Side views, before and after treatment, of Case O.

the labial eminences of the canines and ending in a hook, for the reception of intermaxillary elastics anchored to the lower molars. These were worn during the sleeping hours for a period of six months, then on alternate nights only for the remainder of a year, after which all appliances were removed.

Case O.—A boy, aged fourteen years (Figs. 218 and 219), who presents an extreme deformity. An unusual feature of the case is the arrest of development of the arches, with linguoversion of the upper molars and bicuspids. This rarely is so severe in cases with linguoversion of the incisors.

FIG. 219



Occlusal views, before and after treatment, of Case O.

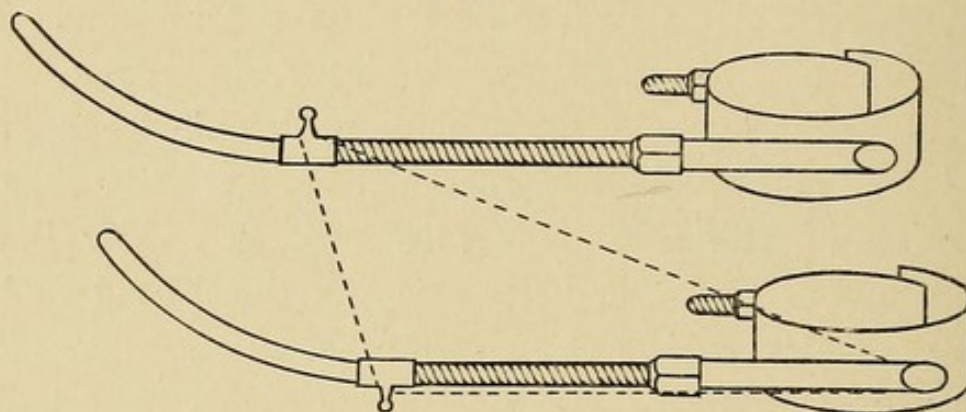
A study of the case readily reveals the requirements of treatment; both arches require considerable expansion; the lower arch a mesial movement; the upper a distal movement for molars, bicuspids, and canines, and labial movement for the lateral incisors. The upper central incisors occupy an approximately normal position, labiolingually, though all four incisors demand a correction of their torso-

version. The various details were carried out as follows: Molar anchor bands were fitted to the lower first molars and bands adapted to the lower canines, with spurs on the distogingival borders of their lingual surfaces. The clamping bolts on the anchor bands were allowed to point distally, thus embracing the second molars (Fig. 167). After all the lower teeth were tied to the lower alignment wire, and expansion of the lower arch thus prepared for, the upper molar anchor bands with buccal tubes were similarly placed. An alignment wire with tube hooks opposite the upper canines was now inserted as high, gingivally, as the canines would permit, though not encircling them, and the nuts so adjusted that it failed to rest upon the incisors. The application of intermaxillary elastics from lower molar tubes to upper hooks (first one for each side, then two), caused a distal movement of the upper molars. The expanding action of the alignment wire produced their buccal movement, the clamping bolts carrying the second molars. This occupied a period of two months. The upper molar bands were now removed, and similar bands placed upon the upper second bicuspid, with their clamping bolts pointing mesially to embrace the first bicuspid. The latter were tied to the anchor bands by means of wire ligatures, gauge 26. The upper alignment wire was reinserted and its adjustment so controlled that it encircled the canines and rested firmly on their labial eminences. The incisors were now attached with silk ligatures as in Fig. 165, and the action of the intermaxillary elastics resumed until the relations shown in the after-treatment models were established.

The lower arch was provided with an appliance as in Fig. 140, though the clamping bolts on the molar bands were retained. Hooks were also soldered to the buccal surfaces

after the buccal tubes were detached, as previously described. In the upper arch an appliance similar to that in Fig. 179 (upper diagram) was adjusted. The anchor bands originally used on the upper first molars were employed, and their clamping bolts pointing in a distal direction allowed to remain. The two plain bands upon the laterals were connected with a labial wire bent into hook form at each end, and of sufficient length to embrace the canines. The maintenance of the corrected arch form was thus provided for, as well as the arch relation by continued use of the intermaxillary elastics.

FIG. 220



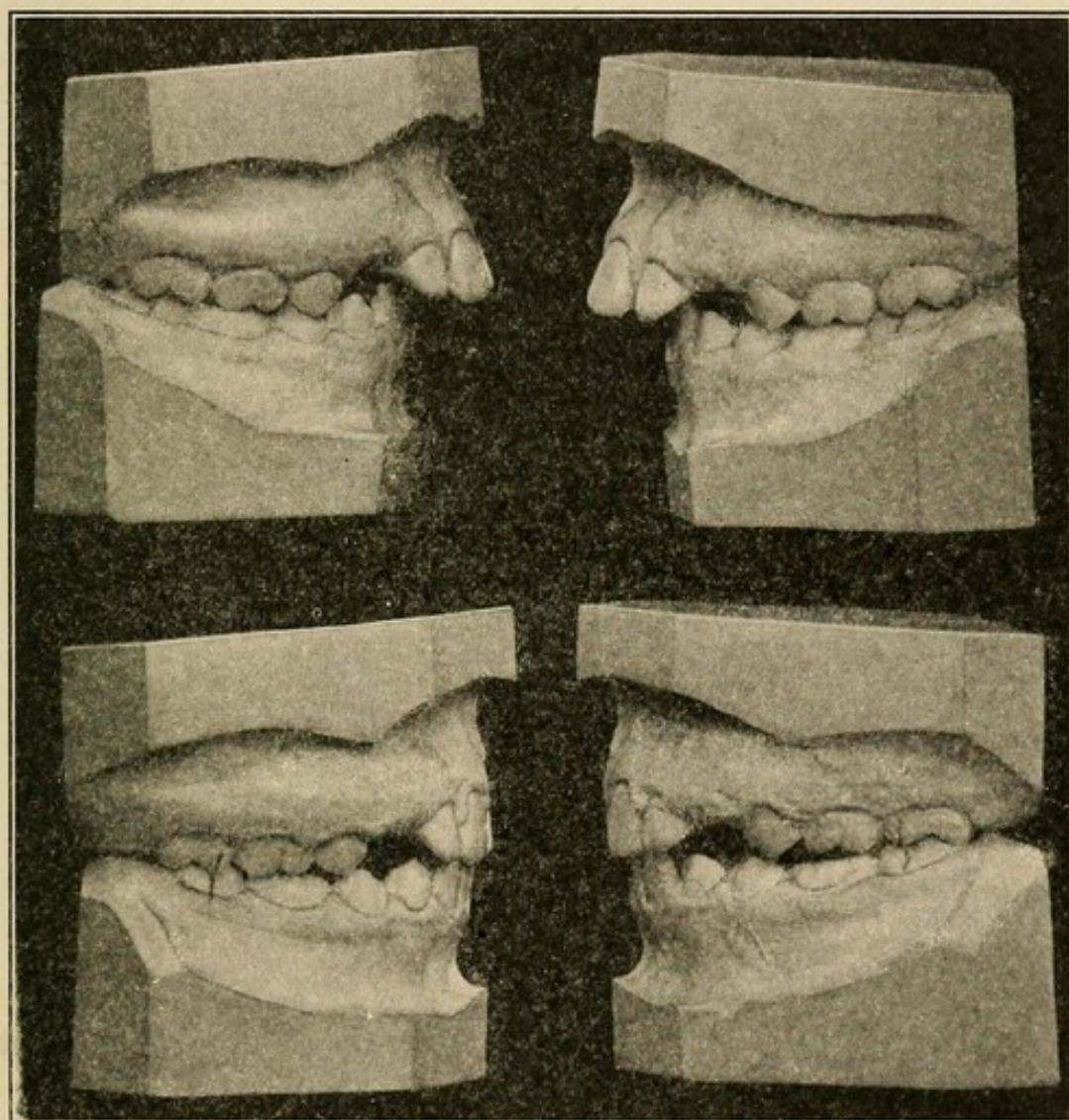
Modification of intermaxillary force for correction of labio-infraversion complicating distocclusion.

Bilateral Distocclusion, Complicated by Labio-infraversion of the Upper Incisors

This type of malocclusion is exceedingly rare. Fig. 41, *B*, shows the right view of a case from the author's practice, being a girl, aged nine years. The central incisors began erupting during the seventh year, but the pernicious habit of tongue-sucking prevented them from assuming a normal length. The patient was also afflicted with hypertrophy of the tonsils and inferior turbinates. In the treatment,

the ligation of the incisors is not only immediately desirable (which was contraindicated in the cases previously described), but should even be intensified by the application of the elastics as in Fig. 220.

FIG. 221



Side views, before and after treatment, of Case P.

UNILATERAL DISTOCLUSION

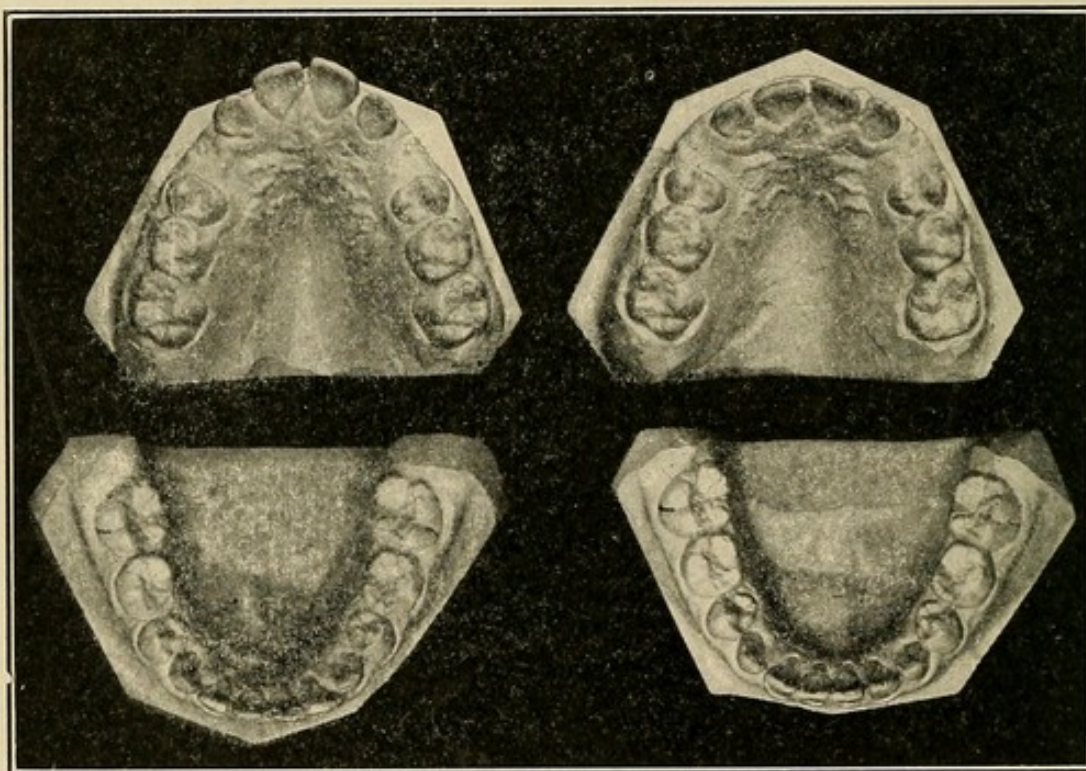
As its name implies, cases belonging to this group present a distal relation of the lower on one side only,

the other side being as in neutroclusion. The complications are similar to those affecting the bilateral types.

Unilateral Distocclusion, Complicated by Labioversion of the Upper Incisors

Case P.—A boy, aged twelve years (Figs. 221 and 222), who had an operation for adenoids performed during his tenth year, and who is still under treatment for chronic rhinitis. The distal closure of the lower is readily seen in

FIG. 222

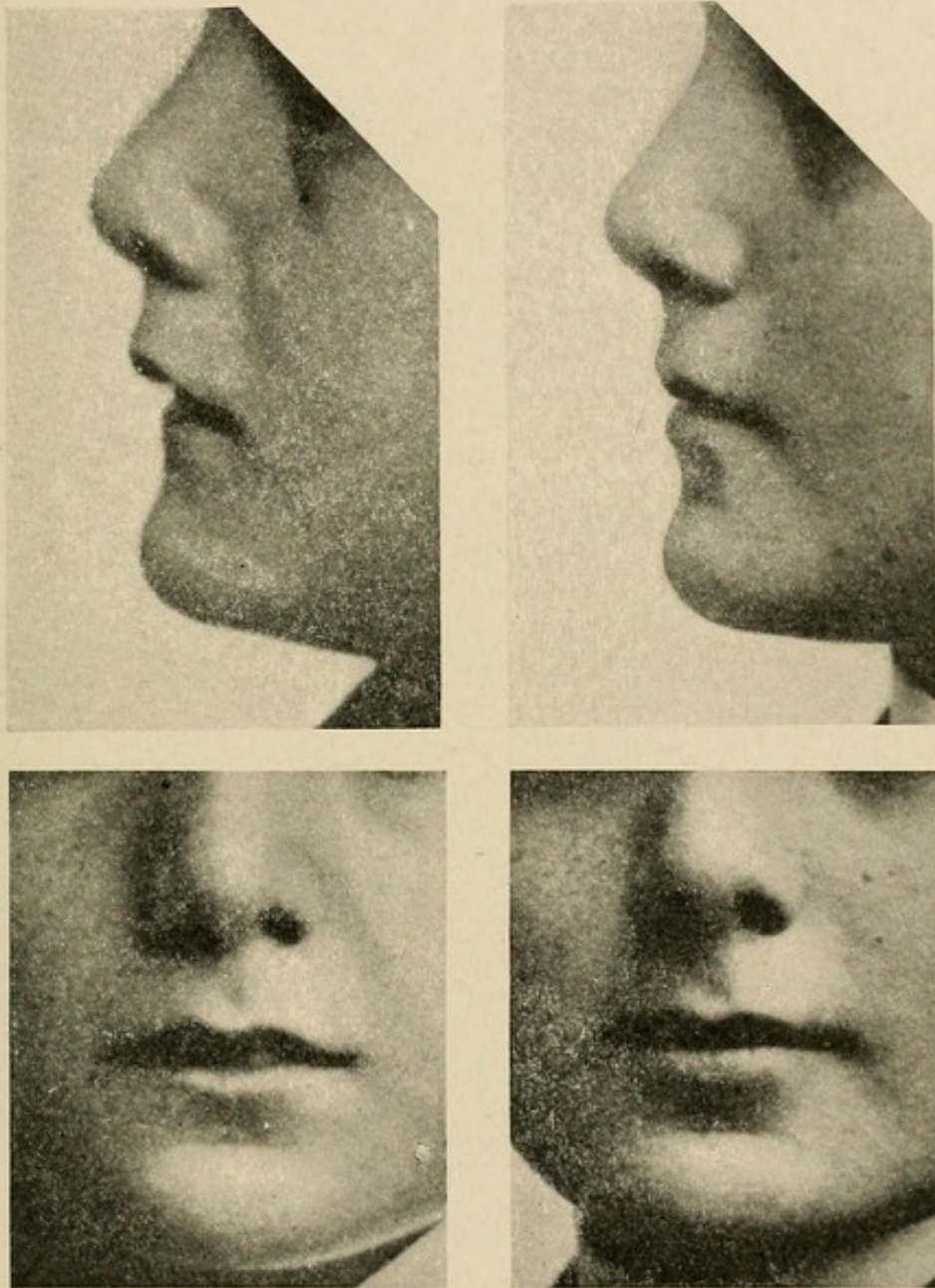


Occlusal views, before and after treatment, of Case P.

the right view of the pre-treatment models, as are also the other minor complications with which the reader has become familiar through a consideration of the bilateral type. These are briefly enumerated by Angle as follows: Narrowing of the upper arch, elongation of the upper

incisors, abnormal nasal and lip function, and distortion of the facial lines. (Compare with Figs. 204 and 205).

FIG. 223

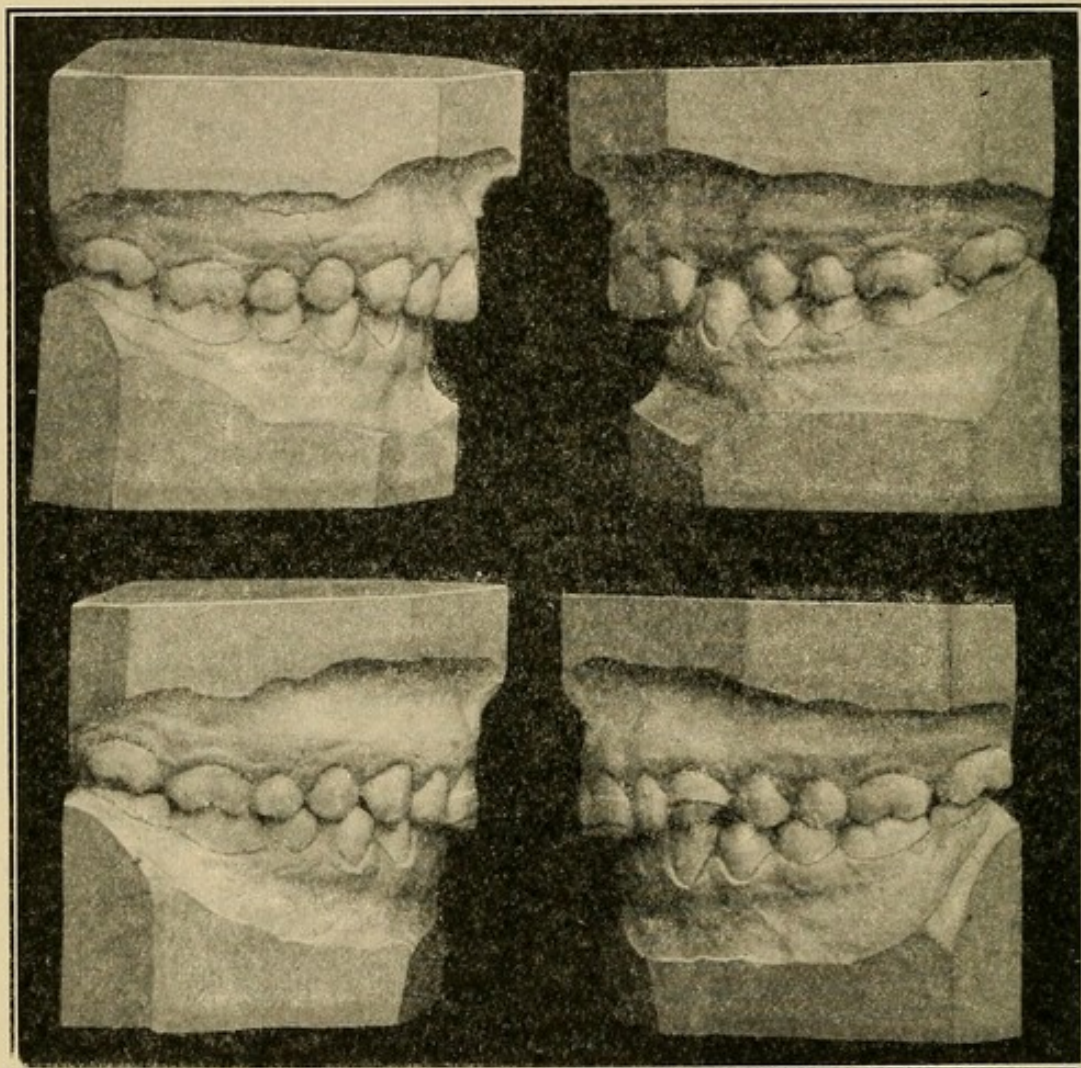


Facial relations, before and after treatment, of Case P.

The first requirement of the treatment which naturally suggests itself is the mesiodistal shifting of the right lower and upper first molars, by means of reciprocal intermaxillary

anchorage. Following this should come the widening of the arches, especially in the bicuspid region, as well as a correction of their mesiodistal relation on the affected

FIG. 224



Side views, before and after treatment, of Case Q.

side. The nuts on the upper arch are now released and pressure allowed to fall upon the protruding incisors, for the reduction of their labioversion.

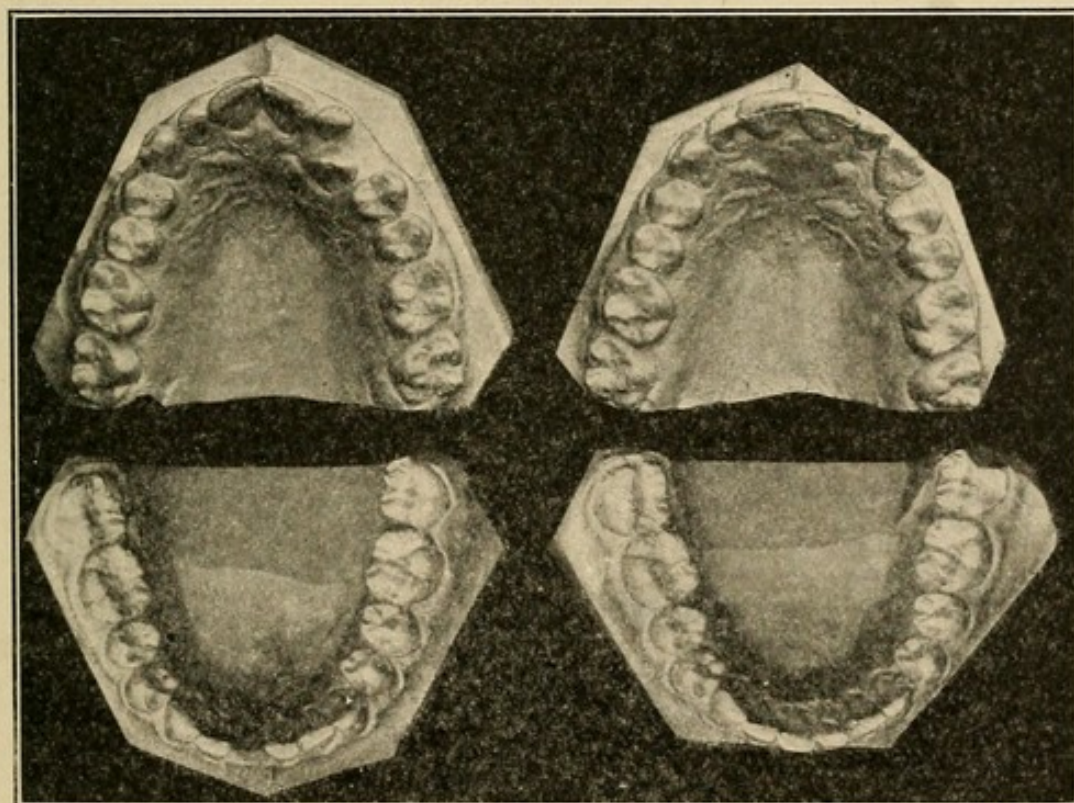
Maintenance was in every respect similar to that described for Case J, with the exception that the continuance of

intermaxillary force during the sleeping hours was provided only for the right, or previously abnormal side. Fig. 223 shows the marked improvement in the facial relation.

Unilateral Distocclusion, Complicated by Linguo-supraversion of the Upper Incisors

Case Q.—A young miss, aged sixteen years (Figs. 224 and 225), with negative history, presenting normal nasal and lip function, and but slight distortion of the facial lines.

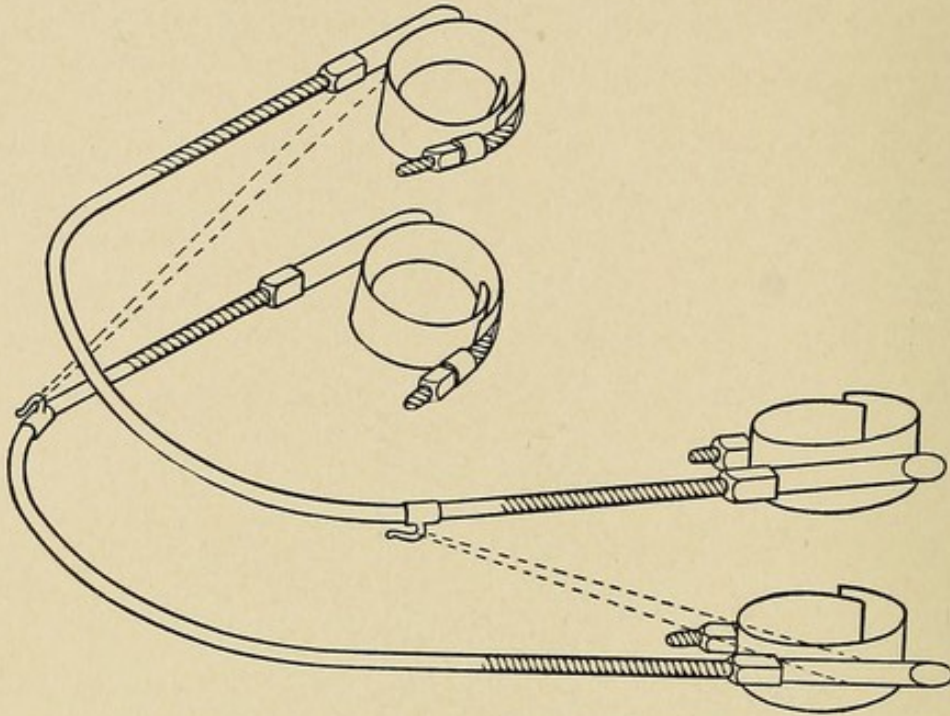
FIG. 225



* Occlusal views, before and after treatment, of Case Q.

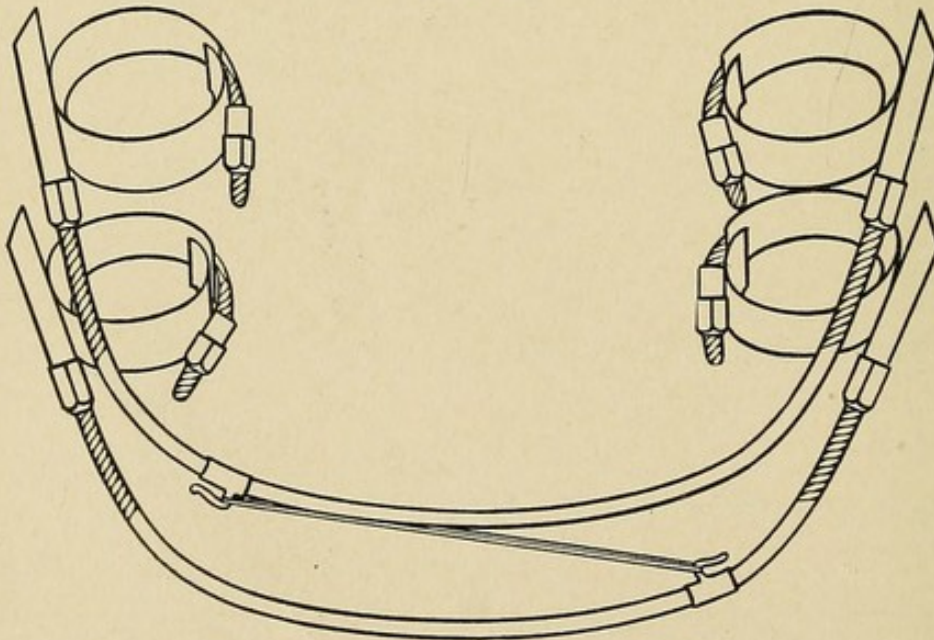
Treatment consisted in first moving the left upper molars and bicuspid distally (as previously described), after which the upper incisors were moved labially, and by a continuation of the intermaxillary elastics a mesial tipping of the lower

FIG. 226



Modified application of intermaxillary anchorage for median line deviations.
(After Reoch.)

FIG. 227



Modification for simpler deviations. (After Angle.)

left side was effected. The left upper canine, having previously been provided with a plain band with a spur upon its lingual surface, at its mesioingival angle, was likewise moved into normal position in the arch.

The corrected torsoversion in the upper central incisors was maintained with two plain bands united by solder at their mesial contact points. The band upon the left upper canine was replaced after a hook had been attached to the distolingival angle of its labial surface. The left lower molar band was provided with a similar hook on its buccal surface after the buccal tube was detached, and an elastic was then applied to them nightly. This was continued for some eight months, after which they were removed, with the occlusion improved to a normal relation.

In extreme cases of unilateral distoclusion pronounced deviations of the median line frequently exist. To overcome such marked deviations, particularly in older patients, the application of an elastic on the normal side, as in Fig. 226, may at times be indicated. In less severe cases, but which do not yield after continued application of the elastic on the normal side, and in cases of neutroclusion and unilateral mesioclusion which may present such deviations, the application of an elastic as in Fig. 227 is indicated.

CHAPTER XVII

TREATMENT OF MESIOCLUSION

BILATERAL MESIOCLUSION

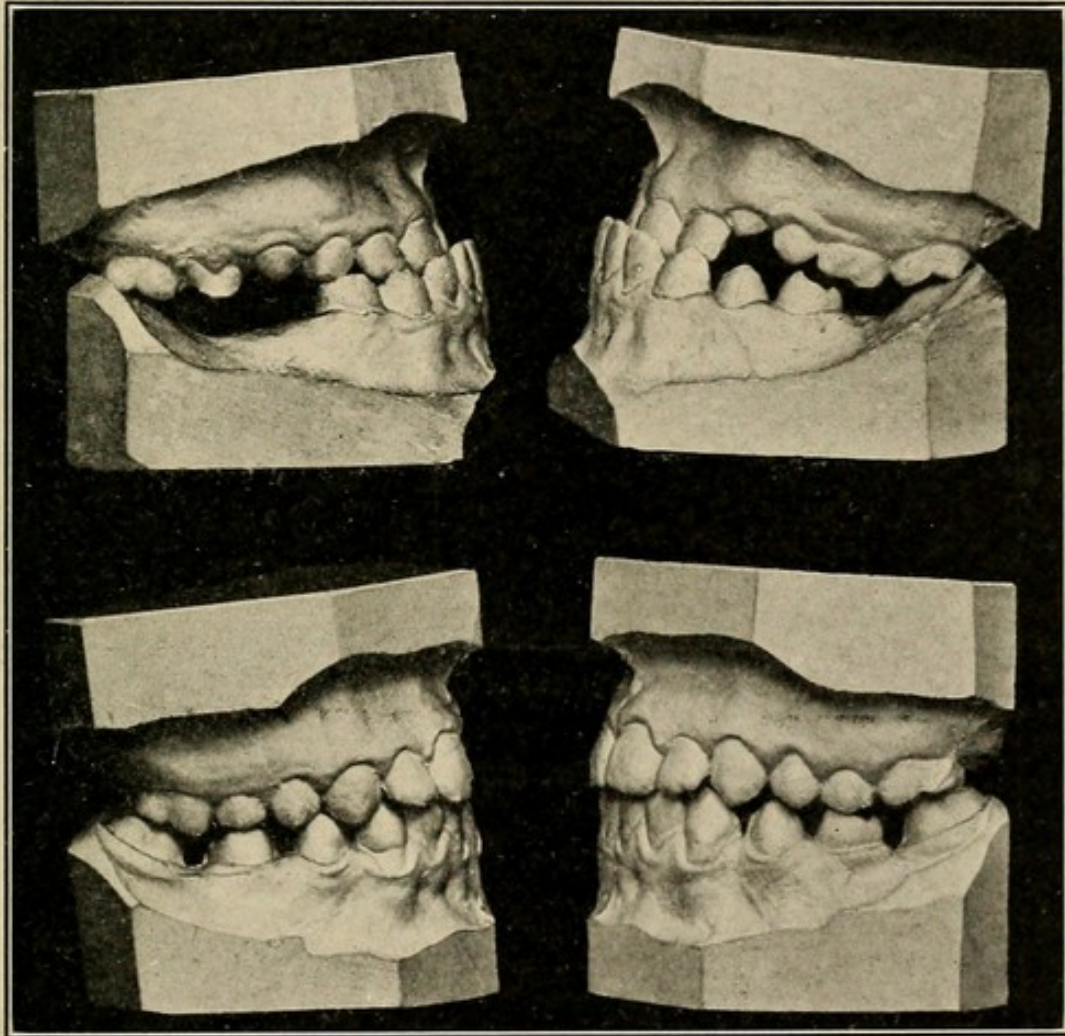
IT will be recalled that the cases comprising this group are characterized by a bilateral mesial relation of the lower arch. This may be due to (*a*) mesioversion of the lower teeth, (*b*) to a forward position of the mandible and its articular fossæ, or (*c*) to an overdevelopment of the bone, either in its body or ascending rami, or both. And though very little is definitely known regarding their etiology beyond the factor proposed by Case (see page 71), all observers agree that deformities of this type begin at an early age. Not infrequently arrest of development of the maxilla, as well as various versions of a number of the teeth, are found as complications. Extreme conditions in patients of advanced years are more properly classified as presenting mandibular deformities, the alleviation of which lies beyond the scope of orthodontics (see Chapter XVIII).

The accompanying facial deformities are often pronounced, and naturally the reverse of those aggravating distocclusions. Some of the milder forms resemble those of neutroclusions complicated by linguoversion of the upper incisors (compare Figs. 182 and 236).

Case R.—A girl, aged ten years (Figs. 228 and 229), afflicted with hypertrophy of the tonsils, gave a history of

chronic "sore throat." She was referred to a rhinologist for removal of the enlarged tonsils and such treatment of the nose and throat as to him seemed necessary. The improvement of the voice and breathing which followed

FIG. 228

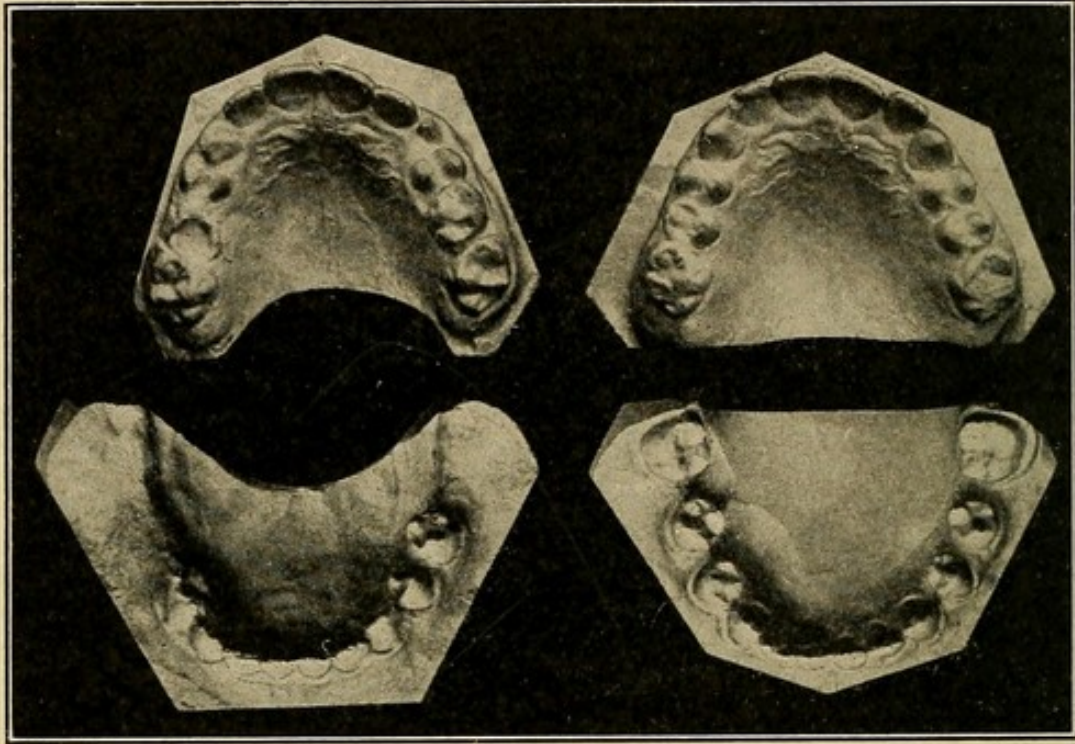


Side views of Case R.

was marked. Attention is also directed to the premature loss of the lower first permanent molars, which occurred during her sixth year. These were affected by extensive caries and consequent pulp exposure, but their extraction was a serious blunder, and not only failed to correct the

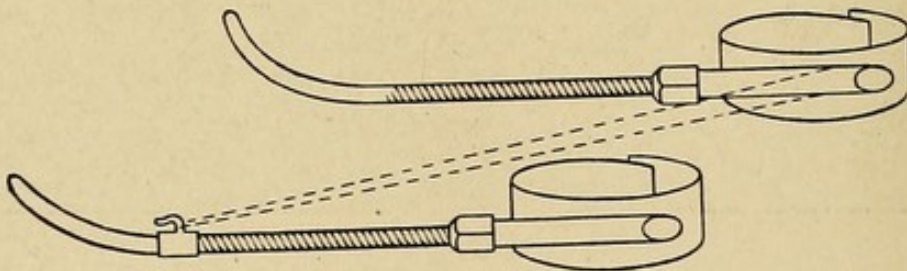
deformity, but undoubtedly aggravated it by compelling mastication with the anterior teeth.

FIG. 229



Occlusal views of Case R.

FIG. 230

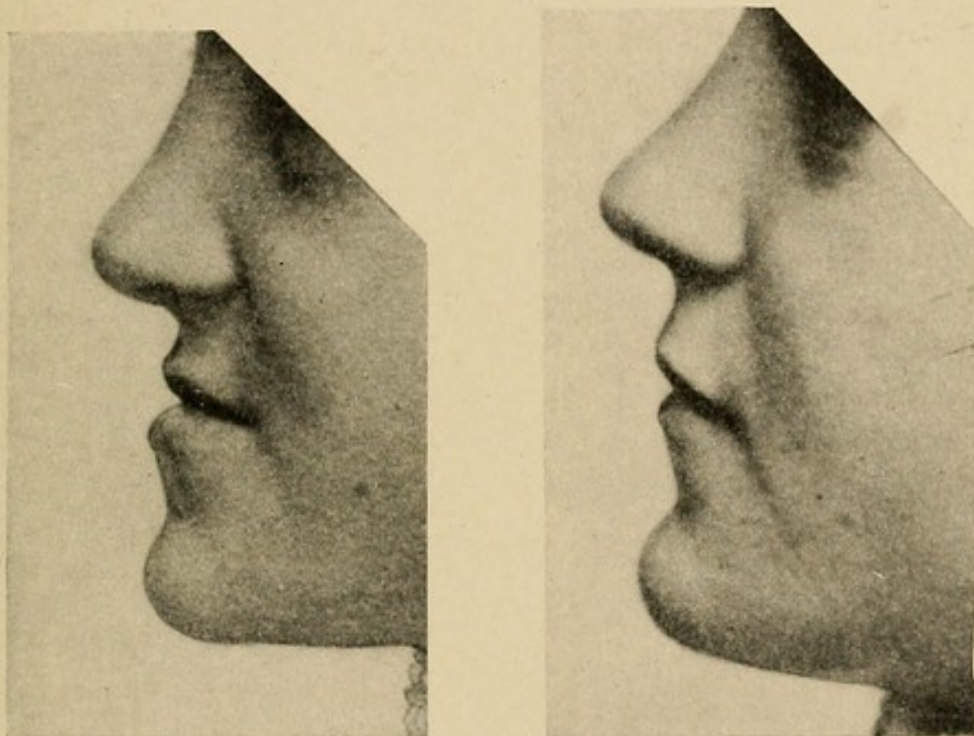


Manner of applying intermaxillary anchorage for mesioclusions.

The best plan for the treatment of these cases is illustrated in Fig. 230, being a reversal of the intermaxillary anchorage employed in distocclusions. In the case under discussion the upper arch was provided with molar anchor

bands and alignment wire after the manner already described. In the lower a decided modification was necessitated by the absence of the permanent first molars. Hence the canines were provided with plain bands with lingual seam, which were then united by a labial wire soldered to their gingival margins and terminating in a well-formed hook at each end. The latter offered anchorage for the intermaxillary elastics

FIG. 231

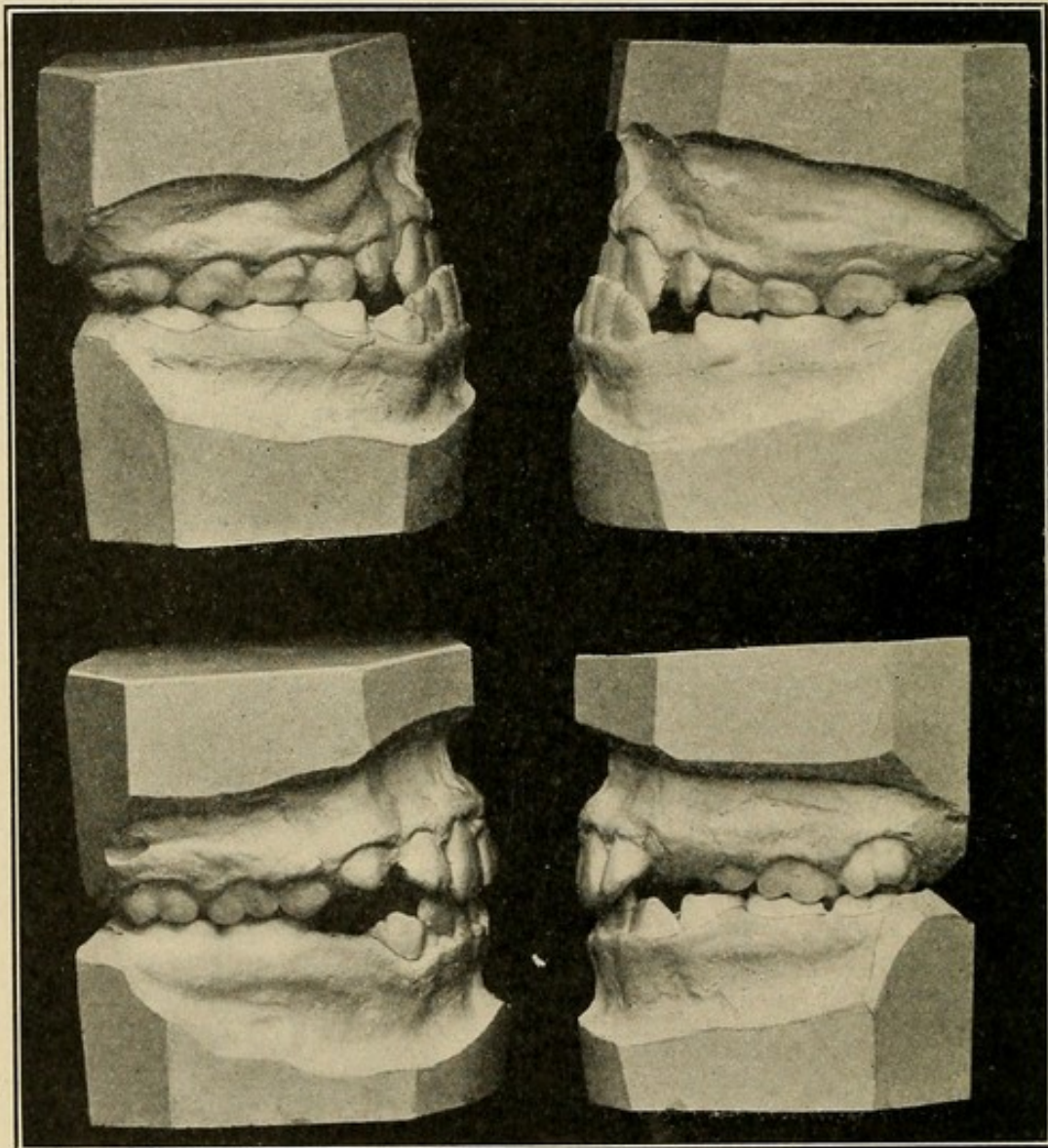


Facial relations of Case R, before and after treatment.

stretched from the buccal tubes of the upper molar bands. The author's first aim was to induce development of the upper arch and to restore occlusion of the anterior teeth—to bring them under the control of normal influences. Semi-weekly visits extending over a month's time readily accomplished this, with a change in the profile as shown in Fig. 231. This result was so gratifying that the author felt confident the complete control of the deformity was now assured.

Hence the upper appliance was removed and a retainer after the design shown in Fig. 179 (upper diagram) substituted. The molar bands were provided with buccal hooks pointing in a distal direction, thus offering attachment for continued use of the elastics.

FIG. 232

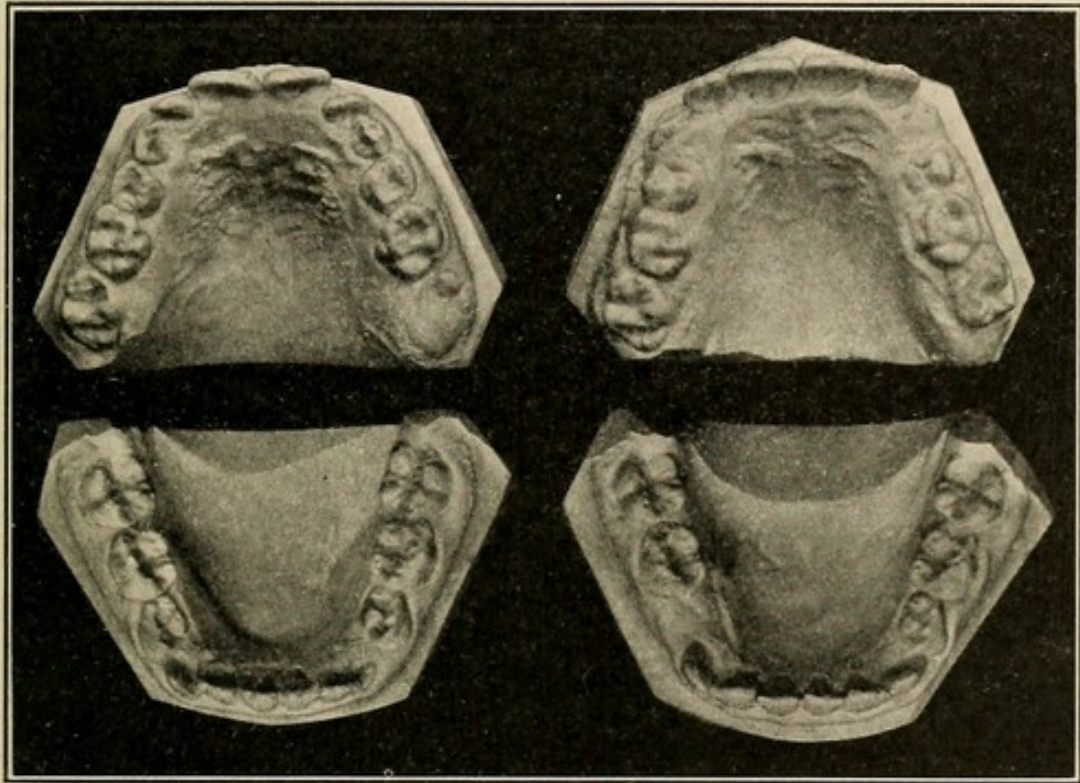


Side views of Case S, showing the progress attained during three and one-half months.

The case was now dismissed, with the request for monthly visits. At the close of the first year the post-treatment

models shown in the half-tones were constructed, and further treatment is now in progress. The eruption of the second molars has taken place, as will be noted, and treatment of the remaining versions rendered less difficult.

FIG. 233

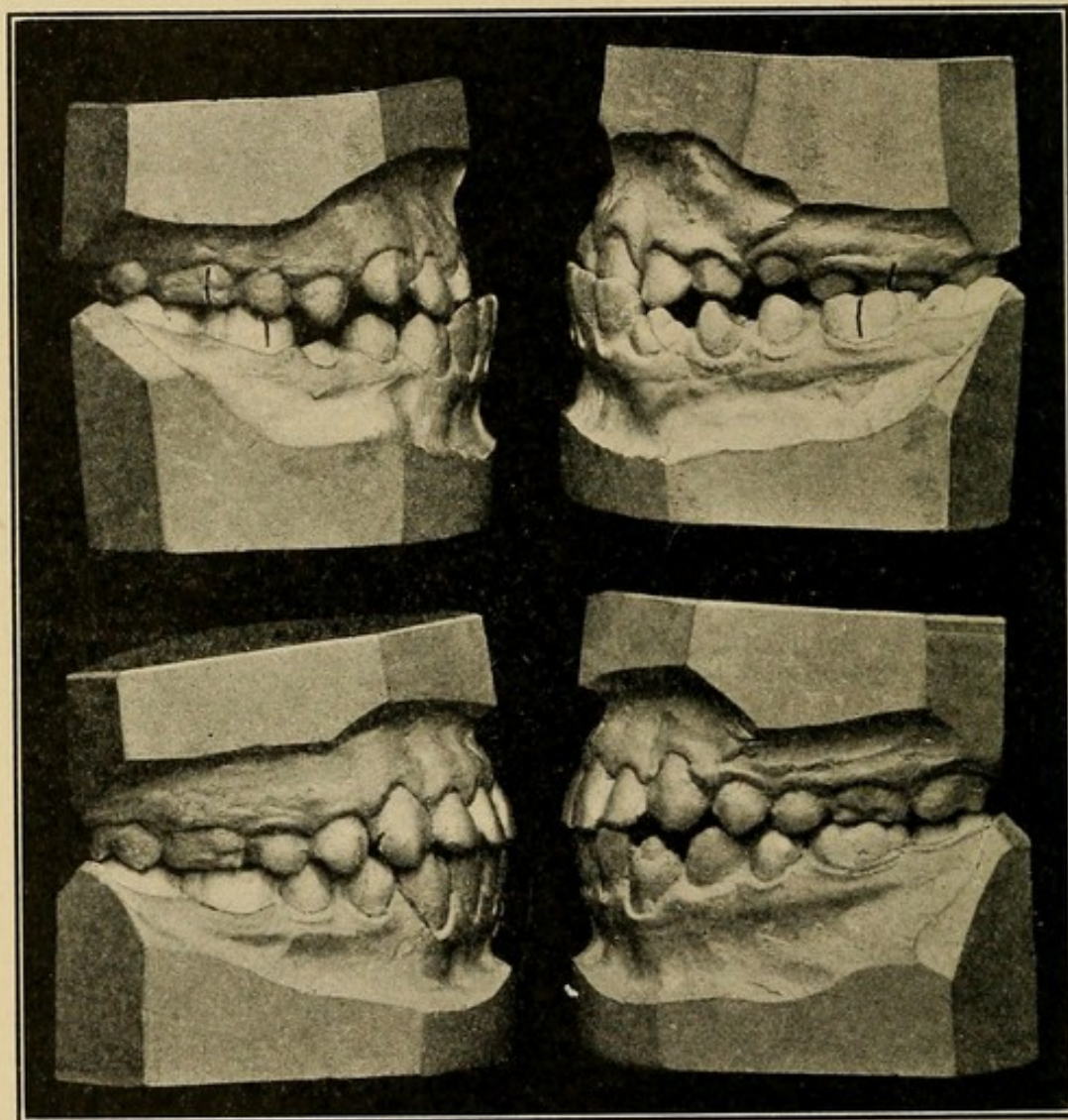


Occlusal views of Case S.

Case S.—A girl, aged ten years (Figs. 232 and 233), who had hypertrophied tonsils removed during her sixth year. Orthodontic treatment was postponed for one year with the hope that the left upper first permanent molar would make its appearance. But not until the tenth year did this occur (see left view in right upper corner of Fig. 232). Treatment was begun February, 1911, and the left upper temporary molar used for anchorage, this tooth being still very firm. The second models shown in the illustrations were made in May (current year) just prior to the patient's departure for an extended trip.

A gratifying change in the progress of the first molar is noticeable; in fact, the eruption has so far progressed that the temporary retaining device was anchored to it. The eruption of the upper canines and first premolars was pro-

FIG. 234



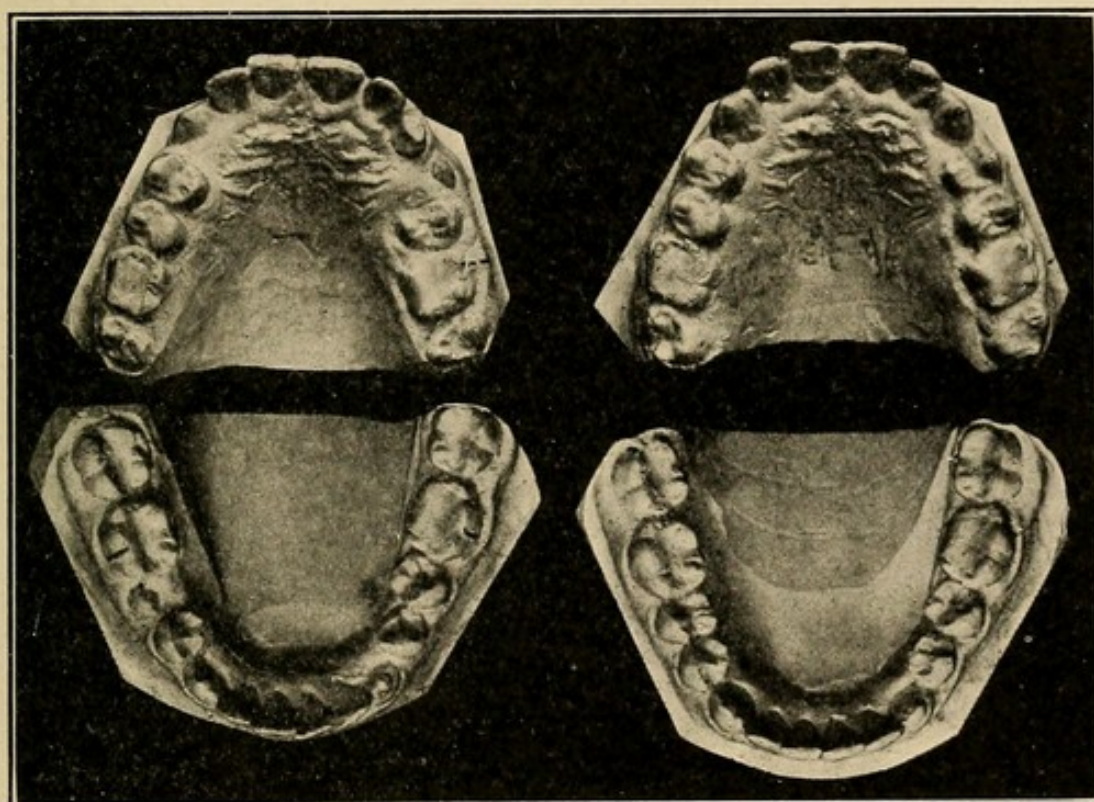
Side views, before and after treatment, of Case T.

moted by the extraction of their temporary predecessors immediately after the first models were made.

The maintenance provided is similar to that for Case R, though the upper left lateral band has a spur of 20-gauge

wire attached to its labial surface which extends over the erupting canine. The labial wire on the lower arch is attached to bands upon the lateral incisors, and extends distally to embrace the erupting canines. The use of intermaxillary elastics has been advised during the entire vacation period to promote growth, as well as maintenance, of the established relations. A resumption of treatment for a short

FIG. 235



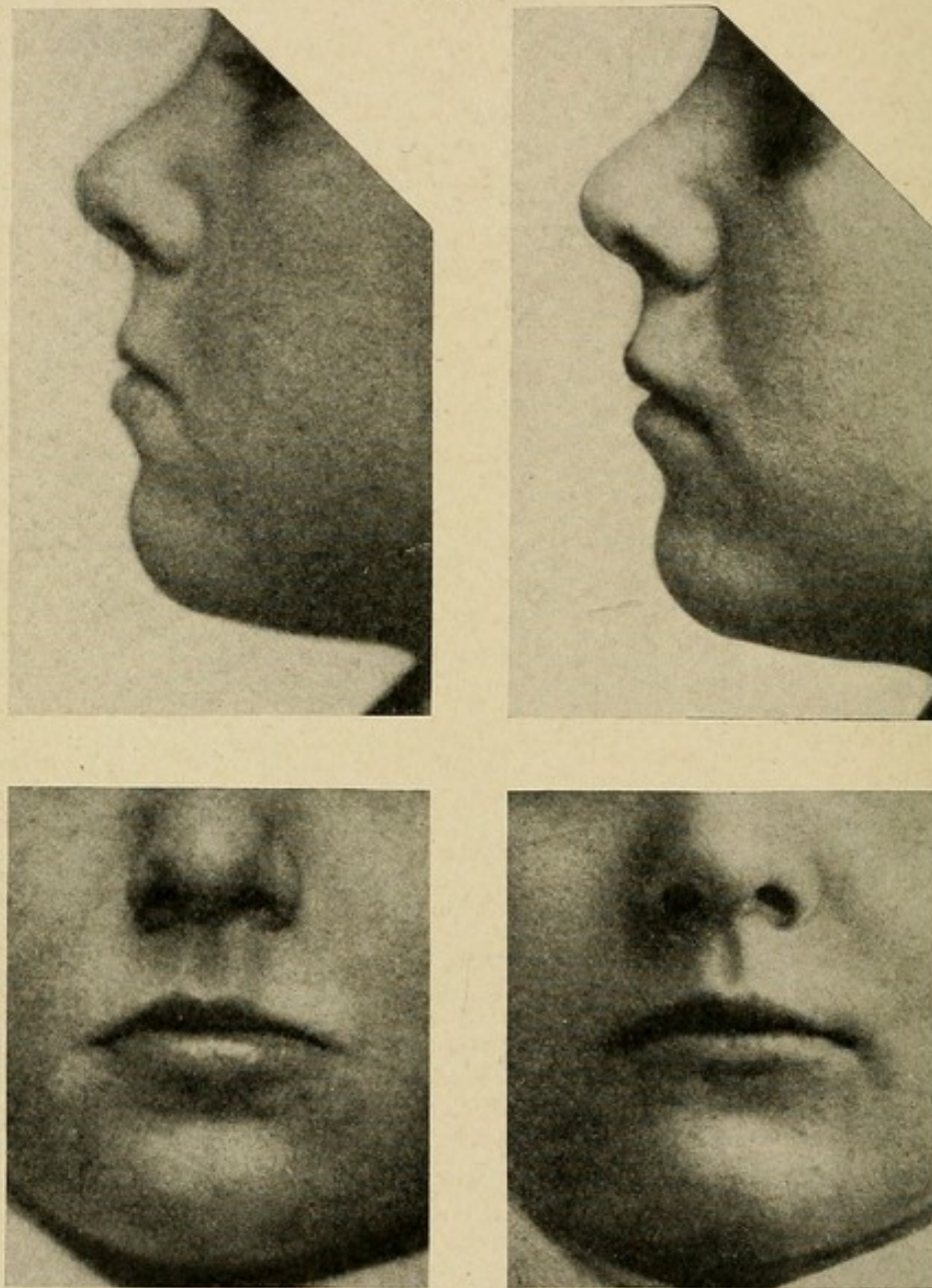
Occlusal views, before and after treatment, of Case T.

period during the coming autumn will effect a complete cure. The change in the facial relations were equally as gratifying as in Case R.

Case T.—A boy, aged eleven years (Figs. 234 and 235), who was referred by a rhinologist after being treated for hypertrophy of the tonsils. Treatment after the manner outlined for Cases R and S not only improved the facial expression (Fig. 236), but his general health as well.

Maintenance was provided by an appliance as shown in Fig. 194, omitting the band upon the upper central incisor and reversing the attachment of the hooks for

FIG. 236



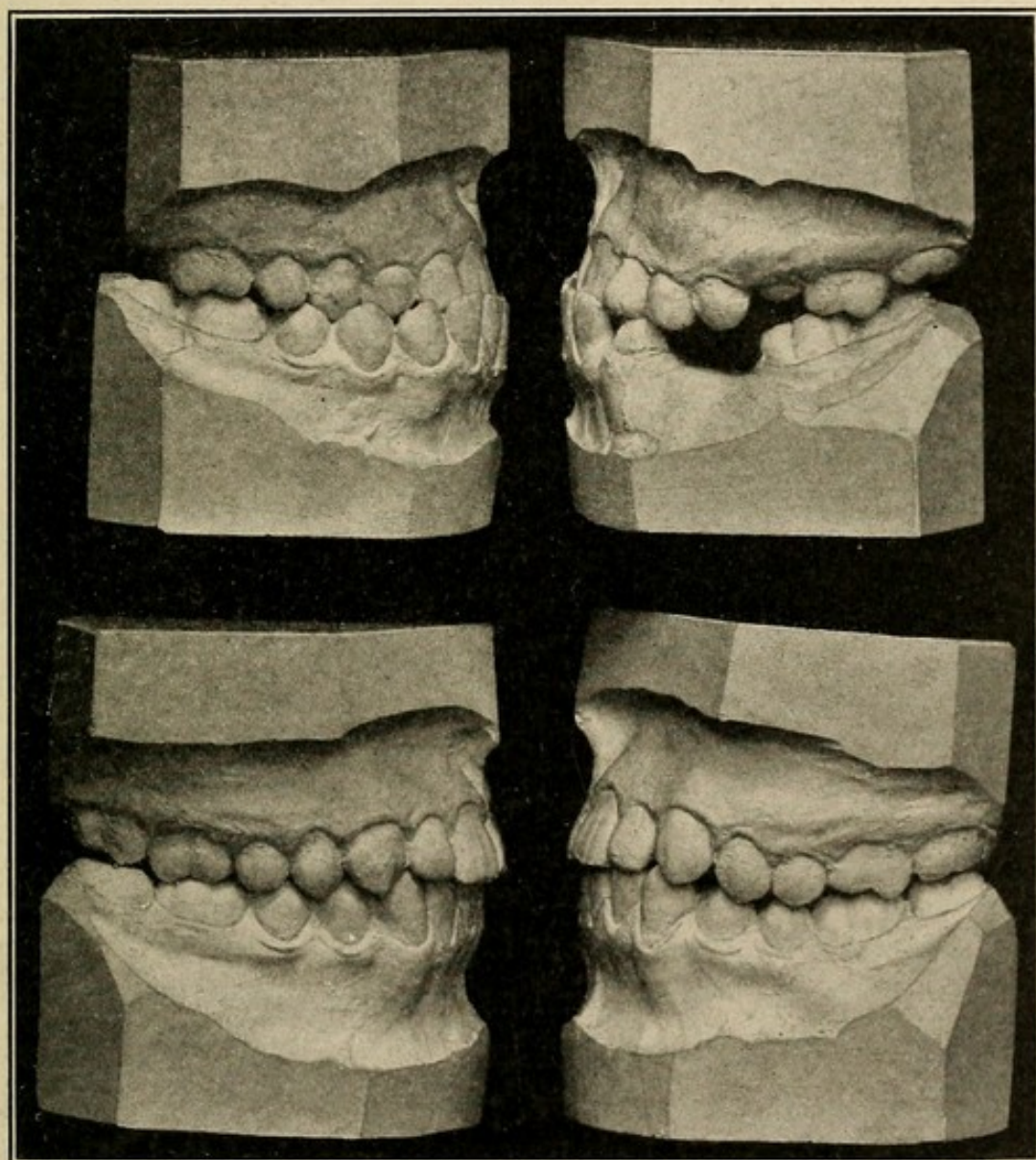
Facial relations, before and after treatment, of Case T.

reversal of the intermaxillary elastics. In other words, the lower canines and upper molar bands were utilized for anchorage of the rubbers.

UNILATERAL MESIOCLUSION

As its name implies, this type of malocclusion presents mesial closure of the lower arch on one side only, the relation

FIG. 237

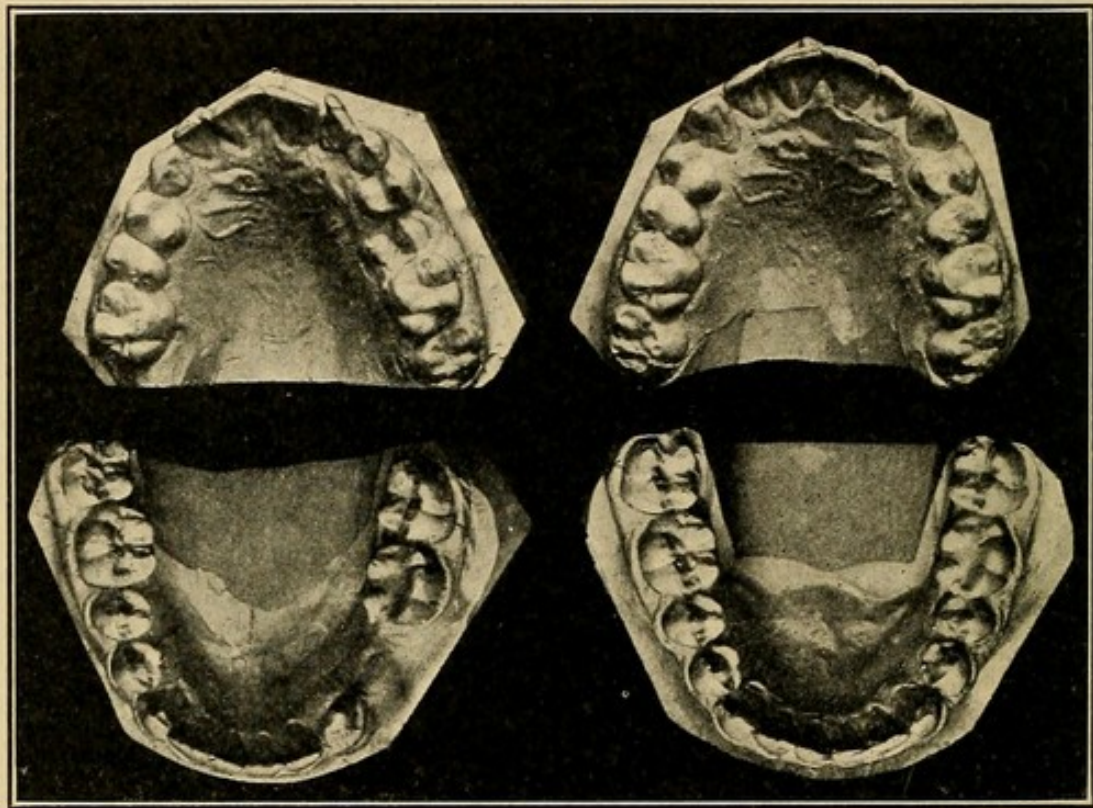


Side views, before and after treatment, of Case U.

being neutral upon the other. Its possible combination with a unilateral distocclusion—mesiodistocclusion—constitutes what Angle has designated as Class IV.

Unilateral mesioclusions are extremely rare, and their accompanying complications are usually less pronounced than in the bilateral types. The etiology is even more obscure, though the treatment is decidedly easier, and rarely, if ever, beyond orthodontic technique.

FIG. 238



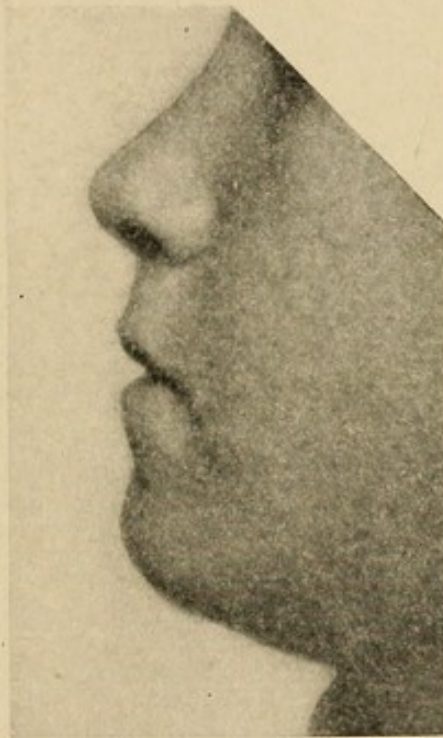Occlusal views, before and after treatment, of Case U.

Case U.—A boy, aged thirteen years (Figs. 237 and 238), with negative history so far as his childhood and infancy are concerned, but whose father has a malocclusion of identical form. There was a time when heredity would have explained this otherwise unexplainable phenomenon, but we have learned “not to spell heredity with a capital ‘h.’ We no longer think of it as a power or as a principle, as a fate or as one of the forces of nature.” Heredity is now merely regarded as a “convenient term to express the genetic rela-

tion between successive generations," and though we know infinitely more about it than formerly, we have not yet succeeded in "measuring and weighing" such resemblances.

Treatment consisted in the application of molar anchor bands and alignment wires for the development of each arch and for the application of an elastic on the left side as in Fig. 230. The upper incisors and lower canines were

FIG. 239



Profile of Case U after treatment. (Compare with Fig. 67.)

provided with plane spurred bands for the more secure attachment of their ligatures and to effect rotation, as well as labial movement, of the incisors.

Maintenance was procured by an appliance like that shown in Fig. 140 for the lower, and Fig. 179 (upper diagram) for the upper. The improvement in the facial balance can readily be noted by comparing Fig. 239 with Fig. 67.

CHAPTER XVIII

TREATMENT OF MALFORMATIONS OF THE JAWS

THOUGH the achievements of orthodontics are truly wonderful, it is well that we recognize its limitations. Indeed, its methods are now conceded to be inadequate for the treatment of those extreme deformities which involve the jaws, and to which the reader's attention has already been called. Fortunately, the skill of the oral surgeon frequently offers much hope to those afflicted with these very distressing disfigurements.

In view of the fact that malocclusion of the teeth invariably accompanies such deformities and frequently stands in causal relation to them (thus demanding the coöperation of the orthodontist), it seems eminently appropriate to close the volume with a brief review of recent advances in this field. But the remedial measures about to be described are entirely of a surgical nature, which precludes a detailed discussion of their technique. Moreover, the author confidently believes that no definite set of rules can be laid down for guidance; such decision must rest entirely with the surgeon. However, it is of the utmost importance that the operator carefully consider the degree of deformity, the anesthetic, the most suitable operation for a given case, the best method for postoperative immobilization of the parts, etc. In the latter phase, the orthodontist can frequently render invaluable service.

Oral deformities requiring surgical interference were partly enumerated in Chapter V as follows:

1. Macrogathism, overdevelopment of a jaw.
2. Micrognathism, arrested development of a jaw.

These may be more specifically designated according to their location by the addition of such prefixes as mandibular, maxillary, and bimaxillary, and by combinations of them. To this list (as was then intimated) must be added all those deformities with which the oral surgeon has to deal. The latter include:

3. Malposition of the mandible.
4. Curvature of the mandible.
5. Congenital deformities, such as clefts of the palate, agnathism, polygnathism, etc.
6. Deformities due to abnormal extraneous influences, such as blows, burns, fractures, etc.
7. Deformities resulting from disease—fibroma, ankylosis, etc.

The most pertinent of these are mandibular macrogathism, micrognathism, curvature, and malposition.

The historical development of the surgical measures proposed for the alleviation of these deformities was briefly set forth by Babcock¹ in a paper read before the ninth annual meeting of the American Society of Orthodontists held in Cleveland, October, 1909, from which the following is a quotation:

“As to the history of what has been done in these operations on the jaw, a brief summary may be permitted. It is, indeed, surprising how few operations have been done. Starting in 1848, Dr. S. P. Hullihen,² of Wheeling, W. Va.,

¹ Items of Interest, June, 1910.

² Amer. Jour. Dental Science, 1849, p. 157.

did the pioneer operation for an elongated jaw, with prognathism. We should name him with a great deal of pride. He had to do with a patient who had been under the care of some of the best surgeons in New York, only to meet with failure and rather an increase of the deformity. Anesthesia was not generally available, the germ theory and antiseptics were not understood, hemostatic forceps had not been invented, and much in the way of surgical technique was yet to be evolved, but this man had the hardihood to go ahead and do a series of very extensive operations upon this girl's jaw and neck, which resulted in a remarkable improvement, if not a complete restoration. The case was that of a girl, aged twenty years, who fifteen years before had been so badly burned over the neck that the jaw was pulled down upon the chest, and there had been produced an elongation of the mandible, a protrusion of the lower incisors, and marked eversion of the lower lip.

“With a small saw V-shaped sections were resected from each side of the jaw, the section upon the left side including the bicuspids. The V-shaped sections extended two-thirds of the way through the bone, the apices being below (Fig. 240). From the apices the saw was turned horizontally forward, completing the section, and leaving the upper two-thirds of the anterior portion of the mandible attached to the soft tissues of the lip only. With the removal of the two V-shaped sections of bone the mobilized portion of the jaw could be pushed back into place, securing an occlusion of the incisors (Fig. 241). From an impression taken in soft wax a silver plate was then struck up, which, when applied, held the section of the jaw in proper position. Union rapidly occurred, and Dr. Hullihen then boldly proceeded to correct the defect in the neck. A large flap of skin from the shoulder

and arm was transplanted to the neck, enabling the head to be raised, and finally by two further operations the everted and deformed lower lip was made sightly and useful. All of these operations are said to have been successful.

FIG. 240

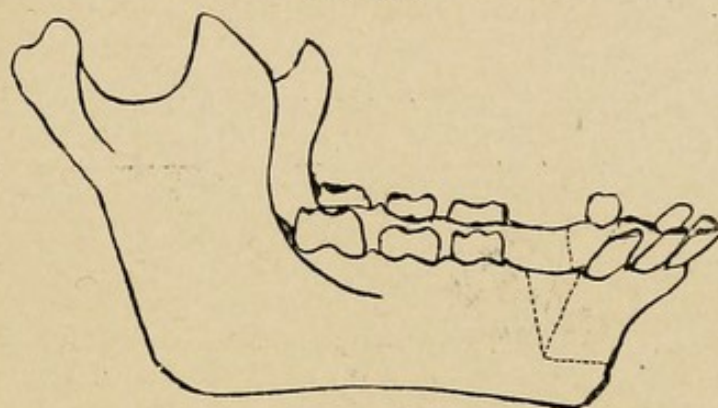


Diagram showing type of deformity in Hullihen's case, the dotted lines indicating the lines of bone section and the triangular segments of bone to be removed. (After Babcock.)

FIG. 241

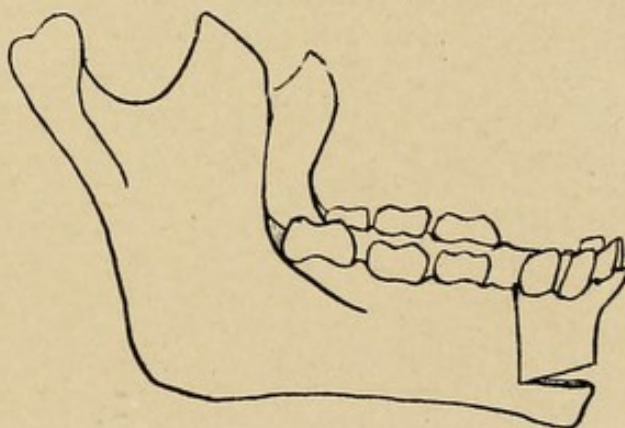


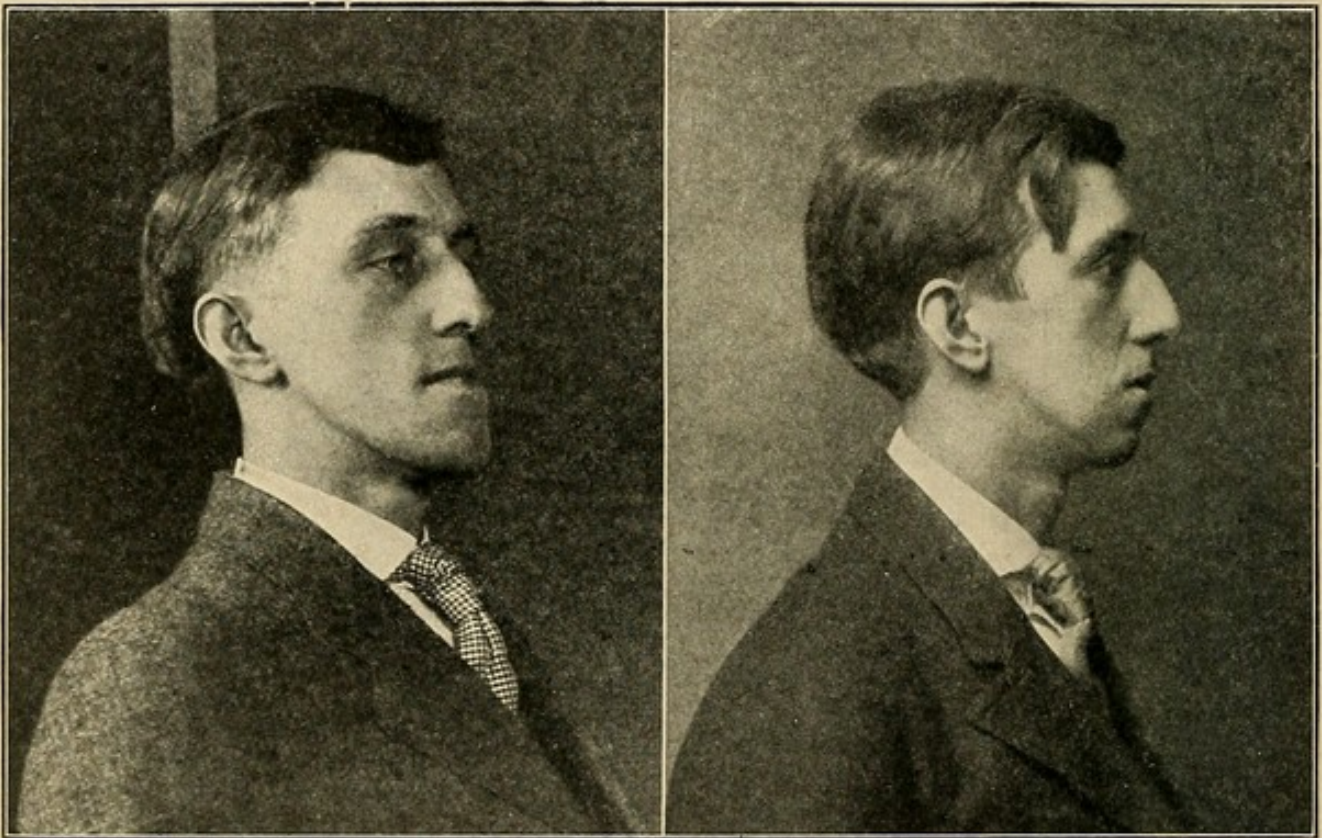
Diagram of Hullihen's case, showing his method of correction. (After Babcock.)

“Nearly fifty years elapsed before bilateral resection of the mandible was again suggested. In 1896 Dr. R. Ottolengui,¹ in discussing the subject, suggested the feasibility of such a procedure, and the following year Dr. James W.

¹ Dental Cosmos, 1897, p. 143.

Whipple,¹ of St. Louis, referred to Dr. Edward H. Angle a patient, a young man, with a progressive type of prognathism. After studying this patient, Dr. Angle advised a bilateral resection of the elongated portions of the jaw, between the first molar and second bicuspid on the right side, and the first and second bicuspid on the left side, the sections

FIG. 242



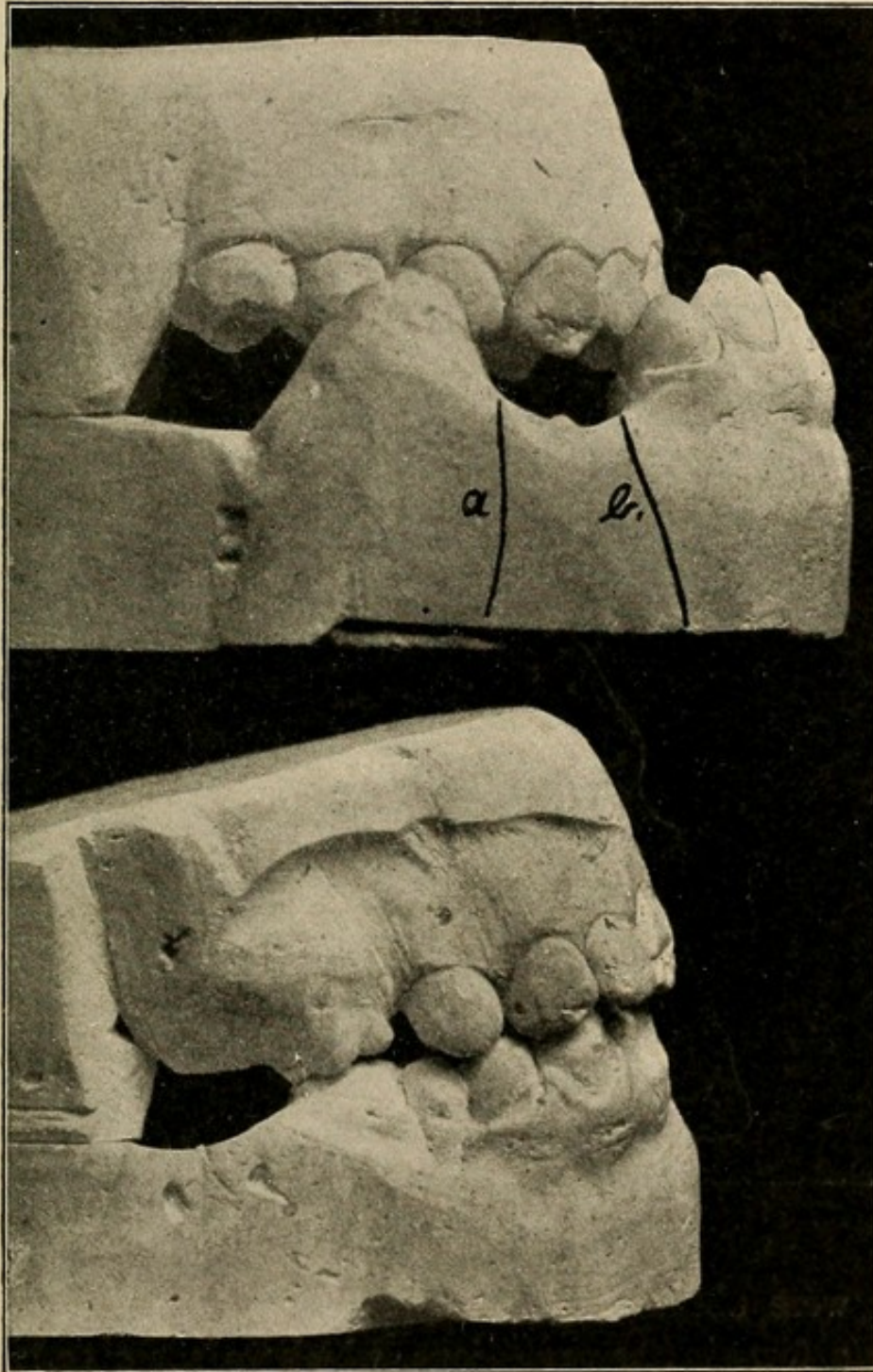
Profiles of patient before and after double resection of the mandible. (After Ballin.)

removed differing from those removed by Hüllihen, inasmuch as the removed segments passed through the entire depth of the body of the jaw. This operation was not performed by Dr. Angle, and the patient finally came under the care of a surgeon, Dr. V. P. Blair, who resected a quadri-

¹Dental Cosmos, 1898, p. 552.

lateral section from each side of the jaw, brought the teeth into occlusion, wired them in place, and then found great

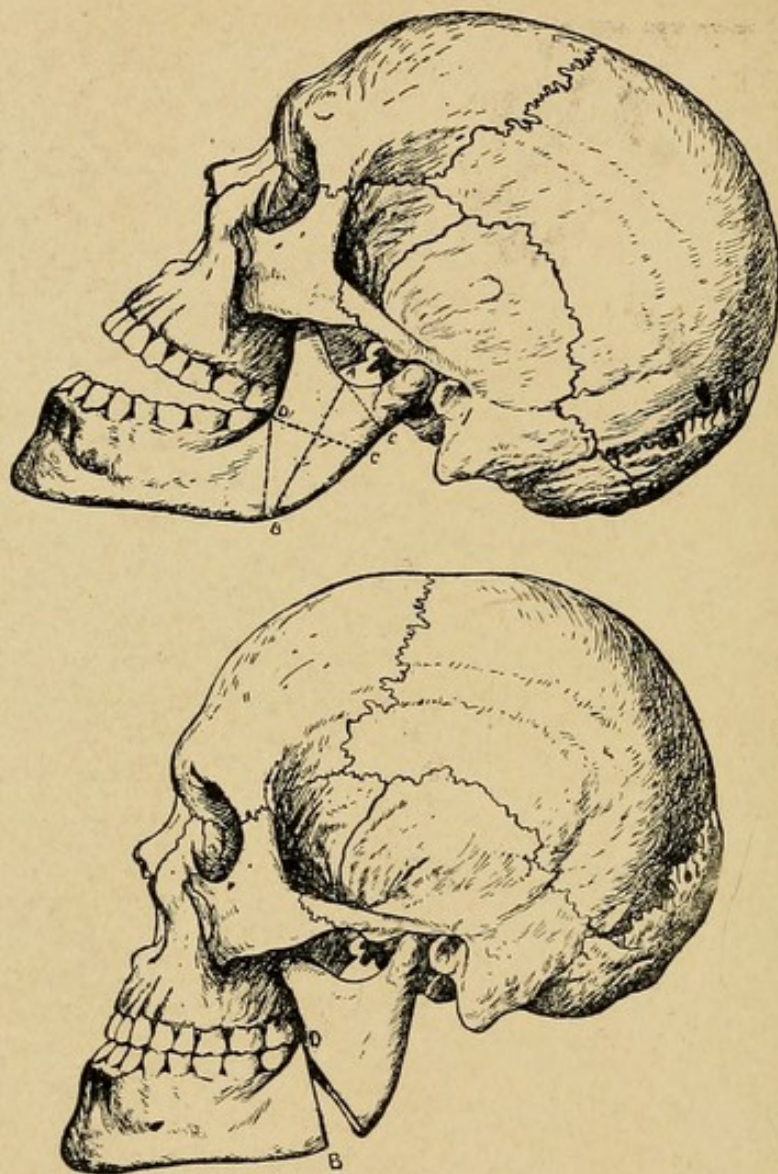
FIG. 243



Dental models before and after operation; the lines *a* and *b* indicate section removed. (After Ballin.)

difficulty in holding all the fragments of the jaw in occlusion. However, after nine quite troublesome weeks from suppuration and some necrosis, bony union and a very creditable

FIG. 244



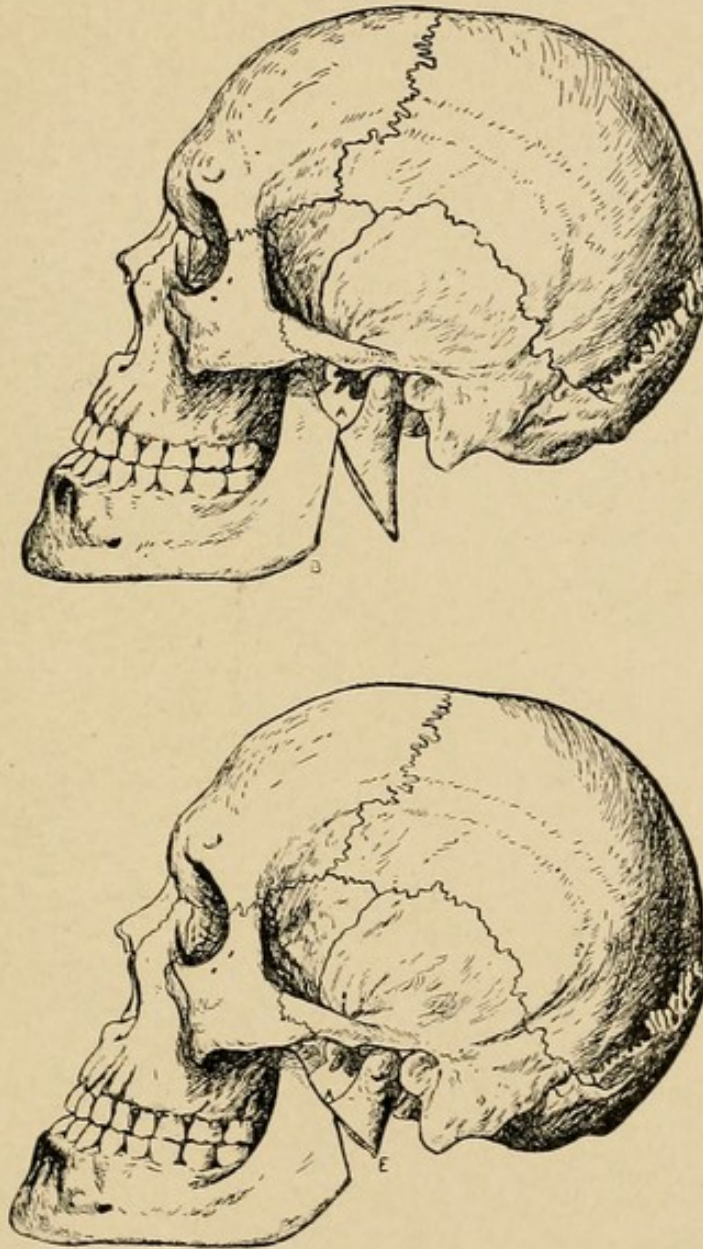
Typical deformity, with dotted lines indicating the various possible sections.
Section made from *b* to *d*. (After Babcock.)

result were obtained.¹ The publication of this operation led to a few similar operations, which in some cases were

¹ Dental Cosmos, August, 1906,

followed by necrosis, one patient in New Orleans losing the mandible from this cause. Although this operation is

FIG. 245



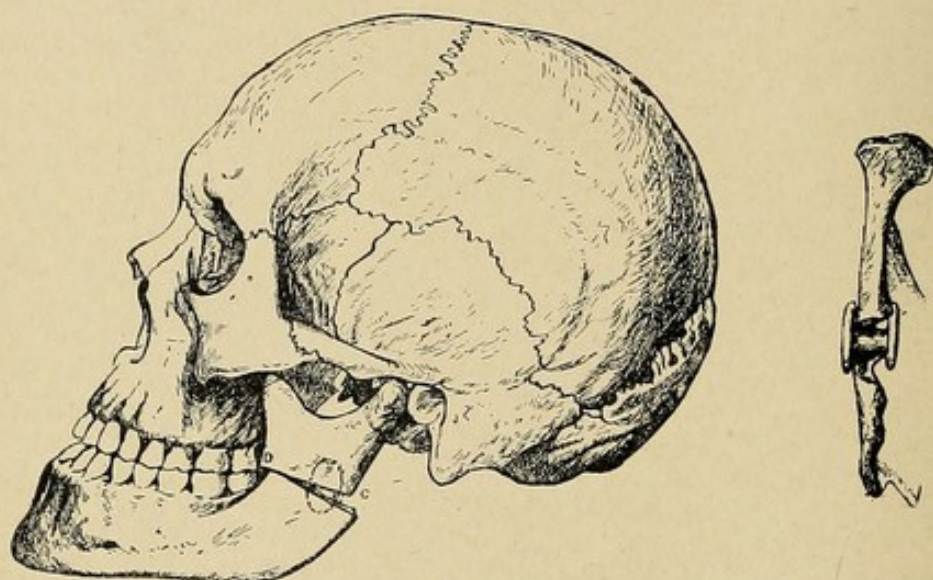
Shows possible correction after sections *a-b* or *a-c*. (After Babcock.)

performed through incisions from below the jaw, the two compound fractures into the mouth which are produced are so objectionable that a preliminary extraction of teeth,

to be followed later by submucous resection of the bone, has been advised."¹

The operation has also been performed by von Bergmann, Ballin² (see Figs. 242 and 243), Babcock, Cathcart, and others. The difficulties encountered by these pioneers has led to improvements in method. Figs. 244, 245, and 246 show a skull exhibiting a typical deformity, with dotted lines and cuts drawn upon the ramus to indicate several

FIG. 246

Correction according to section *d-c*. (After Babcock.)

possible ways for resection, all of which are far enough removed from the body of the bone to exclude any possible involvement of the teeth. From these it can readily be seen that a correction of the deformities above referred to are quite within the range of surgery, and that they offer the only feasible plan for a cure.

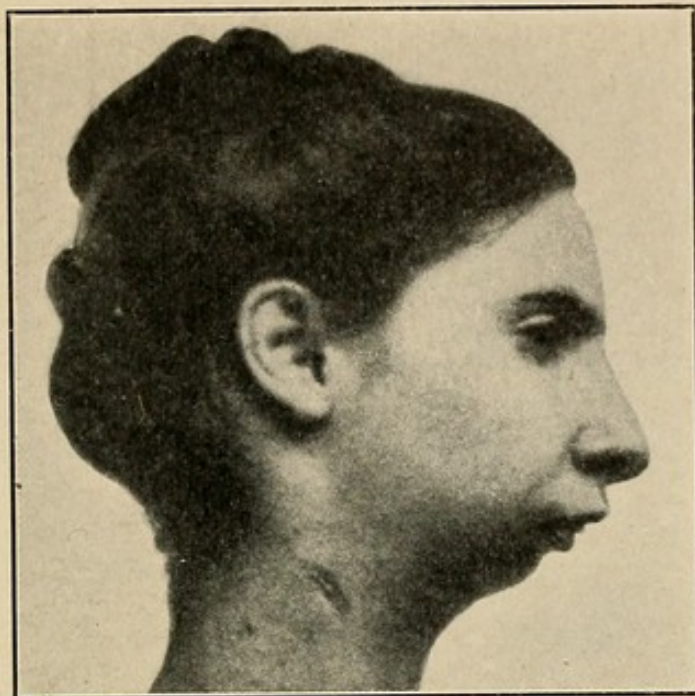
Dr. Blair³ reports an original method of transplantation

¹ See Blair, *Dental Era*, April, 1907.

² *Proc. Amer. Soc. Orthodontists*, seventh annual report.

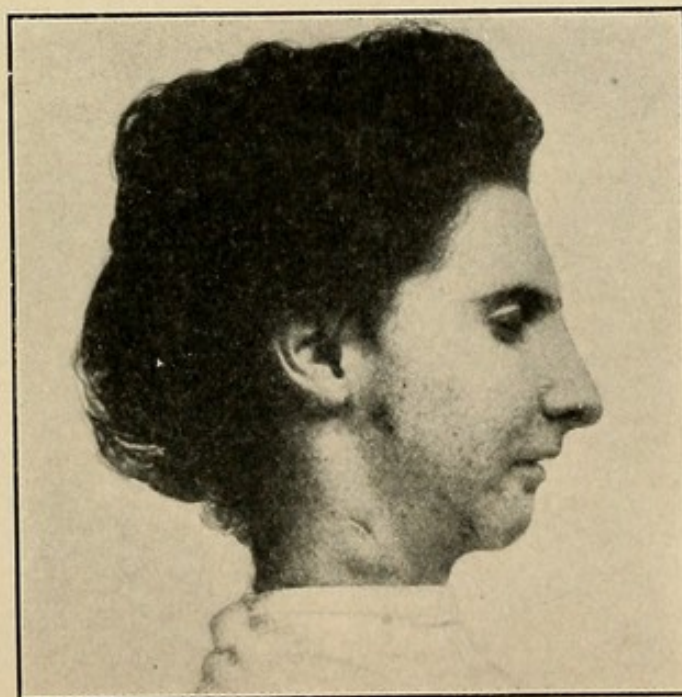
³ *Jour. Amer. Med. Assoc.*, July 17, 1909, pp. 178 to 183.

FIG. 247



Profile of Dr. Blair's patient prior to operation.

FIG. 248



Profile of Dr. Blair's patient after double resection and transplantation of costal cartilage.

of the curved part of the eighth costal cartilage, with its perichondrium, to the mental eminence of a chin in a patient suffering from mandibular micrognathism. This was for improvement of the facial lines, which a bilateral transverse section of the rami had previously failed to entirely correct. The vast improvement of the profile is clearly shown in Figs. 247 and 248.

For a further elucidation of the subject the reader is referred to the original monographs enumerated above.

INDEX

A

- ABNORMAL frenum labium, 58, 61
Accidents causing malocclusion, 74
Acquired malocclusions. *See* Etiology.
Adenoids, 69
Age best for treatment, 138
Alignment, definition of, 81
 variations of, 105
 wire, 147, 159, 160, 161, 176, 224, 225
Aluminum bronze for appliances, 153
Alveolar process, changes in, 183
Alveolitis as a cause of malocclusion, 75
Anchorage, definition of, 164
 extramaxillary, 170
 intermaxillary, 168
 intramaxillary, 167
 reciprocal, 166
 stationary, 165
Angle's appliances, 149
 classification of malocclusion, 88
 system, 149
Anomalies of eruption, 84
 of form, 58
 of the jaws, 84
 of number, 56
 of position, 63
 of structure, 84
 of the tongue, 65
Appliances, 152
 Angle's, 149
 Case's, 163
 Farrar's, 148
 Fauchard's, 146
 Flagg's, 147
 metals used for, 152

- Appliances, Patrick's, 148
 Schange's, 146
Arch form, correction of, 191
 maintenance of, 187
Artificial nursing as a cause of malocclusion, 77
Asymmetry of the jaws, 63

B

- BANDS, anchor, 156
 application of, 173
 attachments to, 157
 introduction of, 156
 kinds of, 156
 uses of, 156
 plain, 154
 application of, 175
 introduction of, 154, 155
 uses of, 154
 retaining, 186
Beauty of form, definition of, 121
Buccoversion, definition of, 92
 treatment of, 191

C

- CARIES, prevention of, 36
 treatment of, 38
Case contouring appliance, 163
 modification of, 197
Cells of construction and destruction, 183
Cephalic index, 99
Civilization as a cause of malocclusion, 78
Cleansing of the teeth, 36
Cleft palate as a cause of malocclusion, 61

D

- DECIDUOUS teeth, premature loss
of, 66
prolonged retention of, 67
Dental index, 99
Dentition, anomalies of, 84
Diagnosis, definition of, 83
methods of, 83
nomenclature of, 83
rules governing, 96
Diseases causing malocclusion, 65
Disharmonisms, causes of, 78
Distocclusion, definition of, 89
post-treatment maintenance of,
189
treatment of, 245
Distoversion, definition of, 92
post-treatment maintenance of,
186
treatment of, 198
Disuse of teeth, 77

E

- EARLY treatment, reasons for, 130,
137
Elastic rubber bands, 163, 181
Etiology of malocclusion, 52
definition of, 52
extrinsic factors, 66
intrinsic factors, 55
unknown factors, 77
Examination of mouth, 32
Extraction of teeth, 40
evils of, 41
rules governing, 41

F

- FACIAL angle, 99
deformities, 97
diagnosis, 126
harmony, 119, 122
models, 48
photographs, 49
Farrar's appliances, 148, 149
Fauchard's appliances, 146
Flagg's appliances, 147
Forces, anchorage of, 164
Frenum labium, abnormal, 58
causes of, 61

G

- GERMAN silver for appliances, 153
texts. *See* Literature.
Gilmer plain band, 155
Gnathic index, 99
Gold for appliances, 152, 153

H

- HABITS causing malocclusion, 71
Health as a factor in treatment,
131
Hereditary transmission, 53, 282
Hyperplastic formation of connec-
tive tissue, 77

I

- IMPRESSIONS for models, 47
Infraversion, definition of, 92
treatment of, 208
Intermaxillary anchorage, 168
Intramaxillary anchorage, 167
Iridioplatinum for appliances, 152

J

- JACKSCREW for reciprocal anchor-
age, 167
for torsoversion, 205
Jaws, asymmetry of, 63
deformities of, 87
prevention of, 85
treatment of malformations of,
284

K

- KINGSLEY'S inclined plane, 255
Oral Deformities, 21
Knapp's system, 149

L

- LABIOVERSION, definition of, 92
post-treatment maintenance of,
187
treatment of, 192
Lever for treatment of malocclu-
sion, 163, 203
Ligatures, 162

- Ligatures, application of, 181
 Linguoversion, definition of, 92
 post-treatment maintenance of, 187
 treatment of, 195
 Lip-biting as a cause of malocclusion, 73
 Literature of orthodontics, 20
 American, 21
 English, 22
 French, 22
 German, 22
 Spanish, 22

M

- MACROGNATHISM defined, 87
 Magill, plain band, 155
 Malalignment defined, 81
 Malformation of jaws, 85
 treatment of, 284
 Malocclusion defined, 81
 differentiation of, 85
 Malposition defined, 81
 kinds of, 92
 treatment of, 191
 Malrelation of the arches defined, 85
 treatment of. *See* Distocclusion and mesiocclusion.
 Mechanical formation of denture, 77
 Megadont defined, 101
 Mesiocclusion defined, 89
 treatment of, 272
 Mesioversion defined, 92
 treatment of, 201
 Mesodont defined, 101
 Mesognathous defined, 99
 Microdont defined, 101
 Micrognathism defined, 87
 Models, facial, 48
 plaster, 46
 uses of, 47
 Mouth, examination of, 32

N

- NASAL obstruction, 67
 consequences and symptoms of, 69

- Neutroclusion defined, 94
 treatment of, 213
 Noble metals used for appliances, 153
 Nomenclature of orthodontics, 19
 Non-occlusion defined, 81

O

- OBSTETRICAL deformity, 74
 Occipital anchorage, 170
 Occlusion defined, 81
 importance of, 124, 138, 184, 185
 Oral hygiene, 37
 Orthodontics defined, 17
 journals of, 23
 literature of, 20
 nomenclature of, 19
 postgraduate study in, 26
 practice of, 23
 societies of, 23
 specialization in, 24
 synonyms of, 17
 technique of, 26
 Osteoblasts, 184

P

- PAIN, relief of, 35
 Palatal index, 104
 Patrick's appliances, 148
 system, 149
 Pericemental affections, 75
 Pericementum, fibers and functions of, 183
 Perversion defined, 92
 treatment of, 212
 Photographs, 49
 Plaster models, 46
 Platinum, uses of, 152, 153
 Predisposition, 53, 54
 Premature loss of teeth, 66
 Preparation of mouth for treatment, 31
 Profile, abnormal variations of, 108
 normal variations of, 99
 Prognathous defined, 99
 Prognosis defined, 130

Prolonged retention of temporary teeth, 67
Pulpless teeth requiring movement, 39

R

RACE admixture as a cause of malocclusion, 78
Radiographs, 50
Reciprocal anchorage, 166
Records of treatment, 42
Resorption in tooth movement, 183
Retaining appliances, 186, 187, 188, 189
Retention defined, 184
 of arch form, 187
 relation, 189
 of tooth position, 186
 time required for, 185
Rotation of teeth. *See* Torsoversion.
Rubber elastic bands, 163, 181
 vulcanite plates for retention, 187

S

SCHANGE'S appliance, 146
Sex, consideration of, in treatment, 131
Skiagraphs. *See* Radiographs.
Skull cap, 163, 170, 171
Supraversion defined, 92
 treatment of, 210
Symphysis, variations of, 105
Systems of treatment, 28
 Angle's, 149
 Case's, 149
 Farrar's, 149
 introduction of, 148
 Jackson's, 149
 Knapp's, 149
 Lukens', 149
 Patrick's, 149

T

TECHNIQUE of orthodontics, 26
Thumb-sucking as a cause of malocclusion, 71

Tissue changes caused by treatment, 183
Tongue-sucking as a cause of malocclusion, 73
Tonsils, hypertrophy of, 69
Torsoversion defined, 92
 treatment of, 203
Transversion defined, 92
 treatment of, 212
Traumatism, 74
Treatment of buccoversion, 191
 of distocclusion, 245
 of distoversion, 198
 of infraversion, 208
 of labioversion, 191
 of linguoversion, 195
 of malformation of the jaws, 284
 of mesiocclusion, 272
 of mesioversion, 201
 of neutroöcclusion, 213
 of perversion, 212
 records, 42
 of supraversion, 210
 of torsoversion, 203
 of transversion, 212
Tube hooks, 162
Tubes, buccal, 174, 178
Turbinates, hypertrophy of, 69

V

VARIATIONS of alignment, 102
 of the facial angle, 106
 of the head form, 97
 of lower third molars, 105
Vulcanite plates, uses of, 187


W

WIRE alignment, 147, 159, 160, 161, 176, 224, 225
 ligatures, 162, 181

X

X-RAYS. *See* Radiographs.







AUG 26 1925

SOUTH PROPERTY

RK521

L68

Lischer

COLUMBIA UNIVERSITY LIBRARIES (hsl, stx)

RK 521 L68 C.1

Principles and methods of orthodontics:



2002398427

