

Ionic surgery in the treatment of cancer : with a chapter on ionization in surgical tuberculosis and in hemorrhoids / by G. Betton Massey.

Contributors

Massey, G. Betton 1856-1927.
Augustus Long Health Sciences Library

Publication/Creation

New York : A.L. Chatterton, 1910.

Persistent URL

<https://wellcomecollection.org/works/pf92v9de>

License and attribution

This material has been provided by This material has been provided by the Augustus C. Long Health Sciences Library at Columbia University and Columbia University Libraries/Information Services, through the Medical Heritage Library. The original may be consulted at the the Augustus C. Long Health Sciences Library at Columbia University and Columbia University. where the originals may be consulted.

This work has been identified as being free of known restrictions under copyright law, including all related and neighbouring rights and is being made available under the Creative Commons, Public Domain Mark.

You can copy, modify, distribute and perform the work, even for commercial purposes, without asking permission.



Wellcome Collection
183 Euston Road
London NW1 2BE UK
T +44 (0)20 7611 8722
E library@wellcomecollection.org
<https://wellcomecollection.org>

COLUMBIA LIBRARIES OFFSITE
HEALTH SCIENCES STANDARD




HX00034487

~~Ex Libris~~
William Benjamin Snow



HEALTH
SCIENCES
LIBRARY



Digitized by the Internet Archive
in 2010 with funding from
Open Knowledge Commons

~~Ex Libra~~
William Bellham Snow

IONIC SURGERY

IN THE TREATMENT OF CANCER

With a Chapter on Ionization in Surgical
Tuberculosis and in Hemorrhoids

By G. BETTON MASSEY, M.D.

ATTENDING SURGEON TO THE AMERICAN ONCOLOGIC HOSPITAL; AUTHOR
"CONSERVATIVE GYNECOLOGY AND ELECTRO-THERAPEUTICS";
FELLOW AND FORMER PRESIDENT OF THE AMERICAN
ELECTRO-THERAPEUTIC ASSOCIATION;
MEMBER OF THE AMERICAN
MEDICAL ASSOCIATION;
ETC., ETC.



NEW YORK
THE A. L. CHATTERTON CO.

1910

1910

COPYRIGHT 1910
BY
G. BETTON MASSEY, M.D.

PREFACE.

This work embodies the results of sixteen years' surgical employment of the electrically diffused ions of zinc and mercury in the destructive sterilization of cancerous growths, and contains a description of the latest technical and operative details of the method, which was first presented to the medical world by the author in a paper read before the Philadelphia County Medical Society January 9, 1895, and published in the *Medical News* in the following March. To this technical consideration of the subject is appended a detailed report of all cases treated, whether the results were successful or not, arranged in accordance with the portion of the body affected. Believing that the recent increase in the attention bestowed on cancerous affections warrants it, a brief recapitulation of the known facts concerning these affections is given in the first portion of the book. A final chapter has been added on the ionic treatment of tubercular adenitis and of hemorrhoids.

While the report of a large number of cases of cancer may be dry reading to some who may peruse these pages, it was considered necessary to picture the results in full, for the method, though still a new one, has been employed for a sufficient time to obtain results by which to test the claims made for it. A statement of these claims will be found in Chapter VIII. The case histories, moreover, should be of particular value to those who have begun to use the method or who propose doing so, making it possible for them to avoid the errors and mistakes of the originator of the procedure.

In compiling these notes of cases, with their final terminations or the present conditions of their subjects, the author has thought it best to confine himself to his personal experience alone, on account of the extra labor involved in ascertaining the present condition of the patients reported by others, though he is well informed of the successful use of major ionic operations for cancer by a number of colleagues, of whom the most notable are: Dr. Amédée Granger, of New

Orleans, who has reported his results in a large number of cases in several communications to state and national societies, which were duly published in the medical press; Dr. Frederick C. Keck, of San Francisco, Calif.; Dr. Frank E. Peckham, of Providence, R. I.; Dr. Frederick O. Marsh, of Cincinnati, Ohio; Dr. W. D. McFee, of Haverhill, Mass.; Dr. R. Wiss, of Meridian, Miss.; Dr. C. R. Dickson, of Toronto, Can.; Dr. A. R. Pingle, of London, Ontario, Can., and others. Descriptions of the method are also contained in Boardman Reed's work on "Diseases of the Stomach and Intestines," and in H. Lewis Jones' work on "Electro-Therapeutics."

A portion of the book has appeared in serial form in the pages of *The Journal of Advanced Therapeutics*, New York, and of *Archives of the Roentgen Ray*, London, England.

One of the motives uppermost in the author's mind in the preparation of this work was the hope that it would be the means of calling renewed attention to the early stages of cancerous growths, that earlier diagnoses may be made, and the patients brought under treatment during this favorable period; for, though the call for early diagnosis and treatment has become a conspicuous note in the recent literature of malignant disease, it is believed that a great awakening is still needed, in order that this increasing menace to humanity may be robbed of some, at least, of its victims while we are waiting for that clearer knowledge of its nature that will lead to effective prevention.

1831 CHESTNUT ST., PHILADELPHIA.

CONTENTS.

	PAGE
INTRODUCTORY	xiii

CHAPTER I

THE NATURE OF MALIGNANT GROWTHS

Cellular nature and histologic characteristics—Classification—Nature of the cancerous process—The autocytic theory—The parasitic theory—Clinical evidences that cancer is due to the invasion of an extrinsic germ	I
--	---

CHAPTER II

THE SEARCH FOR POSSIBLE CANCER GERMS

Soil conditions—Mode of infection—Life history—Local dissemination—Regional dissemination—General dissemination	10
---	----

CHAPTER III

THE DIFFERENTIAL DIAGNOSIS OF MALIGNANT GROWTHS

Clinical evidences of malignancy and of the species of a malignant growth—Clinical examination—Microscopic diagnosis	21
--	----

CHAPTER IV

THE DESTRUCTION OF MALIGNANT GROWTHS BY THE LOCAL CATAPHORIC DIFFUSION OF METALLIC IONS

Cancer a curable disease in early stages—Difficulties attending removal—Value of author's method—How the method was discovered—Reserve necessary in estimating actuality of cure	30
--	----

CHAPTER V

THE PHYSICS OF THE IONIC STERILIZATION PROCESS, AS EMPLOYED IN THE DEVITALIZATION OF DISEASE AREAS

PAGE

Electrolysis—Phoresis—Experimental demonstration of mercury diffusion within flesh 40

CHAPTER VI

SELECTION AND INSTALLATION OF APPARATUS REQUIRED FOR IONIC SURGERY

Source of current—Direct current mains—Alternating current mains—Dry cells—Control of current—Measurement of current—The Ionization Table—Dispersing pad—Active electrodes—Insulation of electrodes—Amalgamation—Arrangement of portable apparatus 46

CHAPTER VII

OPERATIVE DETAILS OF IONIC APPLICATIONS

Major monopolar operation—Maximum currents safely applied by it—Major bipolar operation—After care of patients—The minor application—After observation—Post-operative radiotherapy and phototherapy 73

CHAPTER VIII

CONCERNING THE CHOICE OF METHOD IN THE TREATMENT OF MALIGNANT GROWTHS IN VARIOUS SITUATIONS AND STAGES

Indications governing the choice between ionization and other methods—Comparative advantages of ionization—Comparative disadvantages of ionization—Conclusions as to choice of method—Choice of major or minor ionic methods 91

CHAPTER IX

APPLICATIONS TO THE FACE 98

CHAPTER X

	PAGE
APPLICATIONS WITHIN THE MOUTH AND NOSE	138

CHAPTER XI

APPLICATIONS TO THE LIPS	174
------------------------------------	-----

CHAPTER XII

APPLICATIONS TO THE BREAST	180
--------------------------------------	-----

CHAPTER XIII

APPLICATIONS TO THE CERVIX UTERI	199
--	-----

CHAPTER XIV

APPLICATIONS TO THE RECTAL AND ANAL REGIONS	208
---	-----

CHAPTER XV

MISCELLANEOUS CASES OF MALIGNANT DISEASE IN WHICH ZINC-MERCURY IONIZATION WAS USED	226
---	-----

CHAPTER XVI

SURGICAL IONIZATION IN ACCESSIBLE TUBERCULAR DEPOSITS AND IN HEMORRHOIDS	234
---	-----

LIST OF ILLUSTRATIONS.

FIG.		PAGE
1.	Diagram of Monopolar Ionic Operation in Cancer of the Breast	34
2.	Motor-Transformer of Holtzer-Cabot Type Suitable for Ionic Surgery	47
3.	Diagram of Connections on Dynamo of Motor-Transformer	48
4.	Portable Dry-cell Battery with Switchboard	49
5.	Portable Dry-cell Battery with Switchboard Raised	50
6.	Pocket Ammeter	51
7.	Massey Universal Graphite Controller	52
8.	Plan of Wiring of Graphite Controller	53
9.	Diagram of the Several Paths or Shunts of a Controller	54
10.	Massey Type of Weston Meter	55
11.	Ionization Table	57
12.	Rear View of Ionization Table	59
13.	Kaolin Pads	61
14.	Copper Sterilizer for Kaolin Pads	62
15.	Author's Zinc-mercury Cancer Electrodes	67
16.	Major Spade-shaped Uterine Electrode, Insulated	69
17.	Diagram of Arrangement of Portable Apparatus	71
18.	Diagram of Zones in Bipolar Operation	78
19.	Diagram of Plate Zinc employed as Bipolar Negative Electrode	79
20.	Negative Bipolar Electrode for External Situations	80
21.	Case No. 50 Before Treatment	102
22.	Case 28 Before Treatment	104
23.	Case 28 Nine Months after Treatment	104
24.	Case 93 Before Treatment	105
25.	Case 93. Appearance Four and One-half Years After Treatment	105
26.	Case 234 Before Treatment	108
27.	Case 234 After Treatment	109
28.	Case 307 Before Treatment	110
29.	Case 307 After One Bipolar Treatment	111
30.	Case 347 Before Treatment	112
31.	Case 347 After One Major Application	113
32.	Case 347 After Separation of Bone and Final Healing	113
33.	Case 364 Before Treatment	114
34.	Case 364 After One Dispensary Treatment	114
35.	Case 354 Before Treatment	116
36.	Case 354 as Scar Appears Three Years Later	117
37.	Case 420 Before Treatment	118

FIG.		PAGE
38.	Case 420 Four Months Later	119
39.	Case 529 Before Treatment	122
40.	Case 529 Four Months Later	123
41.	Case 89 Before Treatment	126
42.	Case 89 One Year and Four Months Later	126
43.	Case 653 Before Treatment	128
44.	Patient shown in Fig. 43 Five Days Later	129
45.	Patient Shown in Fig. 43 as Part Appears 2 Years Later	129
46.	Endothelioma of Eyelids Before Treatment	130
47.	Endothelioma of Eyelids One Year After Treatment	131
48.	Epithelioma of Face Before Ionic Treatment, Case 763	132
49.	Case 763 One and a Half Years After Treatment	133
50.	Carcinoma of Face Before Ionic Treatment, Case 765	134
51.	Case 765 as Part Appears One and a Half Years After Treatment	135
52.	Epithelioma of Face Before Treatment, Case 855	136
53.	Case 855 One Year After Treatment	136
53a.	Author's Ionization Table, as Made by Victor Electric Co.	139
54.	Case 183 Showing Outline of Lower Jaw Four Years After Operation	150
55.	Photograph of Tongue Scar as It Appears Three and a Half Years After Treatment	152
56.	Deformity After Ionic Destruction of Lower Jaw	156
57.	Case 460 as Mouth Appears Three Years After Destruction of Epithelioma	158
58.	Case 830 After Separation of Slough, Sixteen Days After Operation	166
59.	Case 830 Showing Appearance of Scar One Year After Operation	167
60.	Case 697. Horny Growth on Lip, with Epithelioma of Mouth	168
61.	Case 697. Scar One and a Half Years After Operation	169
62.	Epithelioma of Lower Lip, Case 609	176
63.	Case 609 Two Years and Four Months After Ionic Operation	177
64.	Epithelioma of Lip, Case 647	178
65.	Appearance of Lip in Case 647 Two Years After Ionic Operation	178
66.	Photograph of Scars in Breast and Axilla Four Years After Operation	189
67.	Photograph of Wound After Separation of Slough, Case 676	196
68.	Photograph of Case 676 After Complete Healing	197
69.	Diagram of Median Section of Pelvis Showing Sarcoma of Sacrum	216
70.	Sarcoma Tissue and Coccyx After Separation	218
71.	Photograph of Scar of Sarcoma of Sacrum Six Years After Operation	219
72.	Lymphoma of Neck	226
73.	Photograph of Patient Shown in Fig. 72 Four Years Later	227
74.	Sarcoma of Neck, Case 320	228

FIG.		PAGE
75.	Appearance of Scar in Case 320 Three and a Half Years Later	228
76.	Sarcoma of Arm, Case 474	229
77.	Scar of Sarcoma of Arm, Case 474, Three Years After Treatment	229
78.	Carcinoma of Vulva, Case 772	230
79.	Scar of Case 772 One and a Half Years After Ionic Operation	231
80.	Hard-rubber Rectal Speculum, with Spiral Fenestrations .	238

PLATES.

I.	Pope-Massey Special Wall Plate, Frank S. Betz Co. . . .	63
II.	Author's Ionic Switchboard, as made by Williams, Brown & Earle	65

INTRODUCTORY.

That the terrible scourge of humanity embraced in the various malignant affections commonly called cancer demands our earnest attention, as a profession and as a people, needs no emphasis when the figures showing its increase in civilized lands are considered. The double showing of recently established facts, which indicate that cancerous diseases are on the increase and that they are primarily local, places an immense responsibility on the members of the medical profession, who can no longer fold their hands with honest sorrow on the discovery that a valued life is threatened by a malignant growth. Their sorrow cannot be entirely free from a sense of unfulfilled duty if it has been in their power to remove the disease soon after its inception; and if this may not have been in their power by reason of the ignorance or inattention of the patient, who for these reasons failed to seek aid in time, the responsibility of the medical profession, as a whole, still remains, for it is the duty of educated physicians to correct the popular impression that cancer is a hopeless disease from its inception in the great majority of cases. Indeed, in view of recent legislation in the interest of public health, it would seem appropriate that the attention of the various state legislatures be called to this subject in order that proper measures be adopted to arrest an apparently endemic affection so greatly on the increase as to be rivaled by but three other maladies as a destroyer of mankind—an affection, indeed, that is even more fatal than tuberculosis in its inroads on the adult population. But, whether the aid of the authorities in stamping out this disease can be properly secured at present or not, the most powerful instrumentality in attaining this end will remain in the medical profession, which should educate its patients and the public to the point that would lead to the early destruction of all suspicious growths. That physicians who tell their patients "Don't touch a cancer until you have to" are more than derelict in this duty is evident. Nothing better can be expected until a higher sense of responsibility leads to a closer acquaintance with the modern facts involved in the formulation of an opinion. Until then we

shall continue to see a host of incurable patients who were not urged to seek early relief, and the knife, as well as newer, and it is to be hoped, better methods, will be sought only when it is too late.

This hopeless attitude towards cancer is largely due to incorrect views of its nature, and to incorrect views of the importance of heredity in its prevalence. The old idea that its local manifestations were the "pointings" of a constitutional disease was never really held by those who were in the best position to know anything of the matter, and it is high time that the impression that this is so be definitely displaced by the teaching of scientific facts in favor of the view that the disease is a primarily local foreign invasion. To complete this important change in the popular conception of the disease it is necessary that statisticians also recognize these facts and no longer class cancer among the constitutional diseases, as now generally done.

Concerning heredity, we are now in a position to deny that cancer is actually transmitted by inheritance, even in cases occurring in infants and clearly congenital, for, like the instances to be found in this work, these children are born of parents showing no sign of the disease. The greater prevalence of cancer in certain families apparently means merely that these families inherit a type of cell structure that presents less resistance to the implantation of the germ. It follows from this that a person who springs from a family in which a number of cases has occurred is not necessarily doomed to the same experience, but merely possesses a constitution which demands that greater care be observed in the maintenance of robust health, and a constitution that exacts greater vigilance in the early recognition and prompt destruction of suspicious growths. With proper attention to these two factors of prevention, there is no reason why an individual with this family history should not secure greater exemption from malignant disease than the general public, even in the present state of our knowledge of the causation of the affection. It is quite possible, even, that some of these instances of successive infections in the same family may not be due to a less-than-average immunity but to an exposure to the same source of infection, whatever that may be.

In spite, therefore, of our still incomplete knowledge of certain important scientific relations of the cancer cell, it is utter

folly to allude to the subject of cancer as still a *terra incognita*. As a profession and as a people we know far more about cancer than we act upon. We know, with absolute certainty, that cancer begins as a purely local growth, with at this time only such relation to the rest of the body as is involved in the probable susceptibility to the implantation or development of this local growth. Destroy or remove this local growth in this stage, and the remainder of the body will be as free from the disease as if it had never been present.

The prevalent attitude of many well-meaning physicians who practically fold their hands and wait for the discovery of some wonderful antitoxin to help the vital forces to throw off this disease is as sensible as would be the conduct of a gardener who allowed weeds to grow in his garden while experimenting with substances to render the soil inimical to them. The gardens worked on this plan would make a sad showing alongside those in the hands of practical men, who destroyed the invaders at their first appearance.

It is probable that the human body will be kept free from the virulent weeds or animal organisms of the cancerous affections by a similar system of early eradication for years to come; and that, as our specific knowledge of its nature increases, the only hope of a broader relief from the disease lies in the line of prevention.

IONIC SURGERY IN THE TREATMENT OF CANCER.

CHAPTER I.

THE NATURE OF MALIGNANT GROWTHS.

A malignant growth, like all true tumors, reveals on microscopic investigation a structure in which the protoplasmic bits of life known as cells are the chief feature. All tumor tissues share with the general body structures in the essential characteristic of being composed of a collection of individual cell entities, each cell being possessed of a quasi-independent existence under the general correlating government of the nervous system. Some of these cell entities of the normal body possess the power of independent locomotion even, as, for instance, the leucocytes, and in many respects resemble the single-celled animals, the amebæ, which, composed only of a formless mass of nucleated protoplasm, lead an active and apparently independent existence in their normal habitat.

Special cancer cells have been described, but the most recent consensus of pathologists is to the effect that the cells of most, at least, of cancerous growths do not differ in shape from the cells of normal tissues. The principal difference is in their position with reference to the other structures or stroma when in their normal habitat, or to their being outside their normal habitat, or heterotopic. In other words, the ordinary microscopic evidence of malignancy that is most conclusive is that which shows an erosion of surrounding structures by invading cell masses in more or less excess.

The histologic characteristics of malignancy are therefore closely analogous to the clinical characteristics, and indicate that malignancy is evidenced by the excessive reproduction of cells which erode surrounding structures or organs, destroying them and replacing them with their own progeny in a mob-like aggregation. The later clinical evidences of malignancy are a natural extension of the histologic changes into macroscopic proportions, showing to the ordinary senses a progressive, usu-

ally painless, growth of the aggregation, which tends to destroy, more or less rapidly, the life of the host by the development of toxins, but also more especially by the development of intravascular thrombi which are mechanically washed to more vital organs in which they form secondary erosive growths that terminate life.

The conditions involved in these characteristics of erosion, so-called metastasis, and rapid growth, are therefore the distinguishing points between malignant and benign tumors, and constitute an illimitable chasm between them. In accordance with these facts it will invariably be found that a benign tumor possesses a capsule made up of condensed surrounding tissues or other limiting membrane, distinctly separating it from contiguous structures, and that it can only displace the latter by pressing them aside; it cannot give rise to similar tumors in the same person by autoinfection; and it is of relatively slow growth.

CLASSIFICATION.—A convenient classification for tumors, including malignant growths, has been arranged by referring all tumors into the same group which are derived from the same germinal layer of the embryo. Those cancers arising in tissues derived from the epiblast and hypoblast, the epithelial and glandular structures, are therefore classed as carcinomas, while those derived from the mesoblast, the connective tissue type, are classed as sarcomas.

The following arrangement of malignant tumors has been adapted from the classifications of the most recent writers on the subject:

CLASSIFICATION OF MALIGNANT TUMORS.

<i>Histogenetic Situation</i>	<i>Group</i>	<i>Chief Varieties</i>
Epiblastic and hypoblastic tissues, producing Epithelial type.	Carcinoma	<ul style="list-style-type: none"> Rodent cancer (epithelioma of the short-hair follicles) Squamous-celled carcinoma Cylindrical-celled carcinoma Glandular carcinoma
Mesoblastic tissues, producing Connective-tissue type.	Sarcoma.	<ul style="list-style-type: none"> Round-celled sarcoma Spindle-celled sarcoma Lympho-sarcoma Myeloid sarcoma Myxoma Melano-sarcoma

To get a clear comprehension of this classification of malignant tumors it should be remembered that carcinoma is prop-

erly the name of a group, of which epithelioma, etc., are varieties; and that this group includes the only varieties to which the name "cancer" is strictly applied, the several varieties of sarcoma not being included. This restriction of the designation to carcinomas alone in exact phraseology has given rise to the general impression among some physicians that sarcomas do not possess the same degree of virulence as carcinomas—an impression that is often greatly at variance with the facts. The truth is that this classification should convey no such impression, for it serves only for purposes of identification. The classification is, in fact, somewhat artificial, like the Linnean classification of plants by botanists, which places the potato and the deadly nightshade in the same family. The carcinoma group includes genera and species of every degree of virulence, as does also the sarcoma group. The words "cancer" and "cancerous" might well apply to the more virulent members of each group, and are so employed when speaking comprehensively of malignant affections in this work.

Carcinomas are cancers that arise primarily in situations where epithelial cells are normally found. Sarcomas are cancerous processes arising primarily in the connective tissues. The degrees of virulence of the several varieties of each group are extremely variable, and this peculiarity of a given variety has no real relation to the embryonal layer in which it has its origin. What is probably the true reason for the degree of virulence possessed by each genus will be referred to later.

One of the most important characteristics of malignant growths is the formation of daughter tumors by a process of colonization, either in contiguous or remote parts of the body, this process being accomplished by the entrance of the cells of the mother tumor into eroded lymphatics or blood vessels and their conveyance therein to the secondary sites of growth. These daughter tumors are said to be invariably composed of cells resembling those of the mother tumor. For instance, if the primary tumor arises in the glandular cells of the breast the daughter tumor will show exactly similar cells, somewhat similarly arranged, even if situated in the liver or kidney; the cells of a tumor of the rectum will be faithfully reproduced in its daughter tumors in the spleen, etc.

Moreover, a primarily malignant tumor always grows by the reproduction of cells of its own kind, destroying neighboring

tissues and organs at its periphery by an erosive process, and replacing the cells normal to the part by its own special variety. A carcinoma may therefore extend far beyond the tissues derived from the epiblastic or hypoblastic layers in which it had its origin, replacing the connective tissue cells by its own conquering progeny; and the same is true of a sarcoma, which, though necessarily arising in connective tissues, may invade tissues derived from any germinal layer when highly malignant.

NATURE OF THE CANCEROUS PROCESS.—What, then, is the true nature of the cancerous process? The answer to this question, it is believed by the author, can be determined by the clinical evidence as necessarily parasitic; and this deduction is in a fair way to be proven by culture experiments, if not already proven. Before reciting the circumstances leading to this conclusion, it is best to briefly review the older theory of the nature of cancer, which is yet maintained by some writers on the subject.

THE AUTOCYTIC THEORY.—This theory, which ascribes the cancer process to a reversion of certain cells to their primitive amebiform condition after having thrown off the control of the nervous system, is thus explained by Dr. Herbert Snow, who still adheres to it as the best working hypothesis.*

“The human body is wholly composed of cells, pure and simple; of modified cells; and of products formed within cells. Its complex machinery has been built up from a single cell as the starting point.

“The ameba is a tiny animal which maintains an independent existence, and yet consists of but a solitary cell. It is composed of a jelly-like substance, entitled protoplasm, anent whose properties we practically know nothing. If we did, we should go far towards solving the mystery of life. A small portion of this protoplasm, the nucleus, is differentiated from the rest, it has higher vital and different chemical properties, and acts as a governing center to the whole. Some individuals, but not all, have a further differentiation of ecto-sarc and endo-sarc—that is, of cell-wall compact, and of cell-contents more fluid.

“The ameba exhibits on a microscopic scale all the phenomena shown by the largest member of the animal kingdom. It takes food into its substance, digests it, excretes the useless por-

*“Cancerous and Other Tumors.” By Herbert Snow, M.D. (Lond.) Baillière, Tindall & Cox, London, 1898.

tions. It moves about by contracting and extending its body, these motions responding to excitation from without and to impulse from within. It reproduces by fissiparous division, commencing, as a rule, in the nucleus. Lastly, it may be said to breathe, the metabolic processes which nourish it being largely processes of oxidation.

"All cells are fundamentally constructed upon the same ground plan as the ameba; and all through some part of their existence are practically distinct organisms, moving in the same way, and leading a quasi-independent life. The leucocytes of the blood are from beginning to end no more than amebæ.

"The whole body is evolved from clusters of ameboid cells. Many of these primordial organisms are, of course, eventually developed into the various tissues: nerve, muscle, cartilage, bone, etc.; but many never pass beyond the primary universal stage of cell-life. It is among these or their descendants that cancer arises.

"Organization of the cell-clusters into formed tissue takes place under the control of the nerve centers, and by means of some regulating mechanism inherent in the latter.

"Emancipation from the presiding authority of the central nervous system during the period of development involves structural aberration, such as the various deformities or 'freaks.'

"Weakness or derangement of the central power, after the organism has reached maturity, results first in disordered function, *i. e.*, in ill-health; secondly, and generally after some continuance of the former stage, in organic morbid changes, *i. e.*, in disease. It is hardly too much to say that all maladies not directly induced by extraneous agency are primarily nerve derangements."

After thus reviewing the principal facts of cellular physiology, Dr. Herbert Snow continues:

The autocytic theory ascribes cancer to a reversion of the natural cells or cell elements to that primitive amebiform condition from which all have emerged, and in which a few still persist. Each cell then casts off its allegiance to the nerve centers, which cease to exert over it the least control. It becomes a quasi-independent parasite, or rather autocyte.

"The malignant or 'cancer' cell now preys, exactly as a parasite would, upon the healthy parts around, devouring these,

and appropriating the nutriment destined for them. Its life is not as their life, and involves sooner or later their death. Ultimately it brings about the somatic death of the whole organism.

"A runaway horse furnishes an apt, if homely, exemplar of cancerous disease, as conceived by the autocytic theory.

"The numerous species of cancer depend on the particular kind of cell subjected to this morbid reversion, the cancer process."

Such is a succinct statement of a "working hypothesis" of apparent importance in the elucidation of the problem of the true nature of cancer. It must be admitted that it offers a comprehensible explanation of the fact that cancer cells resemble the cells of the organ in which they primarily appear. Yet it is hard to understand how a simple release of a given group of cells from nervous control could produce the enormous change of character involved in the conversion of these useful bits of protoplasm into the microscopic ravening beasts of malignancy. Such miraculous character transformations are scientifically inconceivable, even admitting a full reversion to the amebiform independence alluded to, for the physical basis of a man's fixedness of character has been well established by biologists as an almost changeless product of hereditary traits, and what is true of the somatic individual must be an even less complicated fact of the minute protoplasmic entities of which he is composed.

If the essential elements of cancer are the cells, which resemble the normal cells at the initial point of development and are so faithfully reproduced as to character and grouping in distant colonies, there must be some profound change in their character to constitute the malignancy. Can this profound change (which may be summarized as an added power of growth and new powers to erode and colonize) be produced by a mere withdrawal from nervous influence?

THE PARASITIC THEORY.—The search for a demonstrable parasite that will produce a cancer when inoculated into the bodies of the lower animals or of man is now actively under prosecution by a number of laboratory workers in America and elsewhere, and definite announcements of success have recently been made by Sanfelice, in Italy, Plimmer, in England, and Gaylord, of Buffalo, N. Y. Sanfelice announced that a blastomycetic fungus, like that of the yeast plant, is the responsible agent of the growth, while Plimmer and Gaylord believe they

have isolated and cultivated a protozoon that produces cancer growths. It is probable that pathologists themselves are not yet in a position to pass judgment on any of the questions thus propounded. Mere students of the literary contributions of these investigators are further disheartened by a very long list of similar claims by previous workers during the past twenty years, many of which failed to be corroborated. The careful observer must, therefore, still keep his judgment in suspension, even though he believes the probabilities all favor the parasitic origin of these growths.

The difficulties in the way of the investigation are indeed enormous, and almost unprecedented, in comparison with other work in the artificial cultivation of disease germs. Practically all of the recent cultivation discoveries in the elucidation of the causation of disease have been concerned with quickly-growing plant life; a few days, or at most, weeks, being sufficient for the development of the disease within the animal or in artificial cultures. In cancer, months or years are required for the development of the disease in the human body, hence an equal time may be required in artificial cultures, with methods totally different from those employed in bacteriology. If the germ belongs to the animal kingdom the example of malaria at once occurs, where no real progress was made until the extra-human portion of the life cycle of the plasmodium was made plain by the discovery of the anopheles mosquito as an essential host.

Clinical Evidences that Cancer is Due to the Invasion of an Extrinsic Germ.—The efforts of the practical physician to control malignant diseases need not, however, be arrested while the laboratory workers are yet engaged in their important researches. Certain clinical evidences point so surely to their parasitic nature that to treat them otherwise is the extreme of unwisdom. Many of the well-known infectious germ diseases have been treated for ages as parasitic on the strength of positive clinical evidences, yet their specific germs are still undiscovered. The absence, or extreme infrequency of evidences of infectiousness has been the chief bar to a recognition of the specificity of cancer, yet our recently acquired knowledge of the rôle of intermediate hosts, and of the longer life histories and special environments of protozoal organisms may easily account for this.

Some of the clinical evidences of the parasitic nature of cancer may be summarized as follows:

1. *Erosion, the chief cause of malignancy, is impossible of explanation except by the possession of a life power on the part of the cancer cell that is independent of that possessed by the surrounding normal cells.*—Erosion means devouring, practically, when used as descriptive of the method by which a malignant growth extends at its periphery into the surrounding tissues, and this pathologic process is only found to exist in affections caused by extrinsic or parasitic germs. Benign tumors displace contiguous organs and structures by pressure, pushing aside the latter, while malignant tumors eat into and destroy them. The malignant growth represents an irrepressible conflict between a foreign and a domestic army; the triumph of the invading forces meaning the total destruction of the defenders in the vicinity of the combat and the re-population of the contiguous territories by the invaders, with final death of the whole commonwealth by a combined process of local extension of the invasion and general political poisoning. No truce, or peaceful occupation of a province from which the inhabitants are driven, can occur, as happens in analogous manner with benign tumors, though the enemy may be locally checked and walled off, as it were, in very rare instances. An example of the latter condition is seen in the so-called stone cancers of the breast, which are the result of unusual vigor in the phagocytic connective tissue cells, whose interlacing fibrils choke the malignant cell growth. The conflict usually has but one ending, unless outside force is invoked to destroy the invaders.

2. *Malignant growths show, when classified, a division into related families, genera and species similar to those characteristic of living integers in both the animal and vegetable kingdoms.*—This classification is more significantly similar also than is usually supposed. The zoological classification of dogs and lions together and cats and tigers is paralleled by the inclusion of the spindle-celled sarcoma and melano-sarcoma in the same family; of the rodent ulcer and the quickly-growing epitheliomas; of the ordinary acinous cancer of the breast and the fulminating variety. The botanical classification of poisonous and non-poisonous plants in the same family is well-known, such as tobacco, belladonna, the potato and the tomato

in the order solanacea; the edible agaricus campestris and the poisonous amanita in the sub-order of mushrooms, etc.

3. *The immutability of species is as marked a characteristic of malignant growths as in any other order of life. Like produces like in cancers as surely as in all other living things, whether of the animal or vegetable kingdom.*—The relation of parent and progeny is not only evident in the reproduction of malignant cells incident to the growth and local extension of a cancer, but, most significantly, in the resemblance between parent colony and daughter colony in the mode of extension miscalled metastasis * in which a graft from a cancer of the breast, for instance, when arrested in the capillaries of the lung, liver, or elsewhere, reproduces cells resembling the mother tumor.

But this last mentioned clinical evidence of the parasitic nature of cancer—the similarity between the cells and their arrangement in the mother tumor and daughter tumors—is, at first sight, a stumbling block to the parasitic hypothesis, for the reappearance of the special type and arrangement of the mammary cells in the daughter tumor seems to support the autocytic theory of a mere change in their character. The answer to this is that the main point, after all, is the reproduction of this special form of “changed character,” which is a far more significant phenomenon than the persistence of the histologic type. It is probable that we have two reproductions to deal with: the reproduction of the cell of the organ primarily infected, and the reproduction of the parasitic cell-inclusion, and that the latter hereditary trait is by far the most important.

It may be tentatively stated, therefore, that a cancer grows and reproduces itself by the reproduction of cells which have become changed in character by reason of the presence of parasitic germs, and that each generation of cells thus changed contains new generations of the infecting germs.

* The word colonization describes the transference of a portion of a disease to another place, without change in the original seat of the disease, better than the term metastasis, which is more strictly applied to the disappearance of a condition at one point and its reappearance at another, as in acute rheumatism.

CHAPTER II.

THE SEARCH FOR POSSIBLE CANCER GERMS.

No "Quest of the Holy Grail" compares in altruistic value to the human race with the labors of our modern knights of the laboratory, who with unwearied patience must question all things of the earth, air, and waters beneath for the germs themselves or their possible hosts in living plants or vegetables, from contact with which susceptible persons may be infected. The old theory of the tomato having an etiologic connection with cancer is suggestive but may tentatively be dismissed as improbable. Sanfelice, of Italy, announced several years ago that he had discovered the germ in a blastomycetic fungus, that others later found in the yeast-like rust of lemons, and Gaylord still later investigated the tumors on certain cabbage roots. A fruitful field for further research is indicated in these directions, and the research should include the many forms of distorted vegetable cells found in diseased corn, rye, and the so-called cancerous tumors of trees.

Alfred Haviland, of England, has made an inquiry into the geologic surface formations of various portions of the British Isles with reference to the distribution of cancer, and has embodied the results in several works and journal articles showing that cancer is more prevalent in wooded river valleys with clay subsoil, in which the rivers occasionally overflow their banks. These conclusions have been rejected by others, who point out that the river valleys mentioned were the seat of large towns containing infirmaries and hospitals to which patients were attracted, thus artificially swelling the mortality statistics. In a more recent paper published in the Practitioner for April, 1899, a closer study of the question is made, small districts being compared with each other in which large hospitals did not exist, and the conclusion was distinctly evident that the limestone districts presented the lowest mortality from cancer, while flooded clays presented the highest.

Mode of Infection.—The method by which the parasite gains

entrance into the body is as dark a secret as its external habitat. That it *may* be contracted by one person from another is evidenced by several well-authenticated instances, reported by Kuhn, Hyatt, Gross, and Budd. Gnelliott has, according to Park, collected twenty-eight cases of transmission to husbands of cancer from their wives, and it is said that at least five French hospital surgeons have died from cancer—presumably acquired in the practice of their profession.

Against the theory of direct contagion may be cited the general experience of physicians and surgeons brought in contact with numberless cases of the disease, which practically negatives the possibility of this method being the usual one in which cancer is acquired.

That the parasite may gain entrance into the body through the natural channels is indicated by the greater prevalence of carcinomas at or near the natural openings, as in the lips, mouth, throat, stomach, nipples, cervix uteri, and rectum.

The effect of irritation in preparing a nidus for the parasite is generally conceded: as bad teeth or unwholesome gums, continuous cigar smoking, and the presence of scars and inflammatory irritations within the cervix uteri and rectum. On the other hand, J. M. Fadgean points out that cancer of the penis in horses occurred in geldings, not stallions; that carcinoma is rare in the udders of milch cows notwithstanding the handling and irritation these organs are subjected to in these animals; and that of thirty-one cases of carcinoma in the horse not one had the starting point in any of those parts of the animal which are specially exposed to the irritation of friction by the harness or otherwise.

The possibility of cancer parasites infecting houses and thence propagating themselves within the tissues of successive residents, somewhat as Flick has demonstrated in Philadelphia in the case of tuberculosis, has been recently pointed out by several writers. Behla* reports seventy-three deaths from cancer in the small town of Luckau during twenty-three years, all within an area no larger than two or three city squares, as many as four deaths occurring in one house. D'Arcy Power's maps of a "cancer field" in the number of the Practitioner referred to are most suggestive, showing the grouping of the cases in the houses of a certain district in England, where the

* Centralblatt für Bakteriologie, Nos. 21 to 24, 1898.

geologic conditions found by Haviland to favor cancer—a clay soil and numerous sluggish water courses—were typically present. In one of these houses three deaths from malignant disease occurred successively among persons not related, and in the paper a number of similar instances are given. The most remarkable instance is, however, the localization of a series of three cases of unrelated persons in a single room. The account given of these cases is as follows:

Miss B., aged forty-five, lived in a certain house in a suburb of London for thirteen years, and died of cancer of the stomach in 1884. Miss T., aged forty-seven, then succeeded to her place and occupied her bedroom. She had lived in the house for twenty years, and died of cancer of the liver in October, 1885. Mrs. J., aged sixty-seven, who had lived in the house for eight years, succeeded to the place and bedroom successively occupied by Miss B. and by Miss T. Mrs. J. died of cancer of the breast and uterus in 1893. Each of these patients appeared to be in perfect health until they took one another's place as housekeeper to the barmaids of the establishment in which they had lived so long a time. There was no blood relationship between them. One of the sons of the house, who is a nephew of Miss T., has a keloid which has been removed three times. No further cases of cancer had occurred in this house since the rooms have been disinfected with sulphur and the bedding burnt.

But the most apparently conclusive evidence of the possibility of the contact, or house, infection of cancer has been presented in the recently observed instances of cancer occurring as epidemics among small animals confined in cages for laboratory purposes or otherwise. Borrel, Michaelis, and Loeb have contributed observations on this point, but the most interesting recent report on the subject is that of Gaylord and Clowes,* who, after reporting the occurrence of three similar sarcomas in rats placed in a cage in the New York State Laboratory at Buffalo from which Dr. Loeb had removed sarcomatous rats nearly two years before, the cage not having been sterilized, the rats being unrelated to Dr. Loeb's rats, and no sarcomas having been observed in one hundred rats in other cages in the laboratory under similar conditions, gives the following interesting account of an endemic of cancer in a certain cage of mice in

* *Journal American Medical Association*, January 5, 1907, p. 15.

the establishment of a dealer who had been engaged in the raising of these animals for several years in Springfield, Ohio:

"One of us visited the establishment in question June 8, 1906, in the company of Dr. Rand, of Springfield, who heard the entire statement made by Mr. Landes, the owner of the establishment and a man of intelligence. The statement which he gave us regarding the occurrence of these tumors, many of which came under our own personal observation, appeared to be perfectly logical and entirely free from discrepancies. In the course of the previous year Mr. Landes had sent this laboratory six white mice with spontaneous tumors, which proved on microscopic examination to be adenocarcinomata of the breast. They were all in females and all located on the abdominal aspect. We found on inquiry that Mr. Landes recognized the fact that the source of these tumors was one old cage, built of wood, one end of which was screened off with netting. He stated that the cage was 3 years old and that it had contained for 3 years an average of about 100 old mice. He estimated that these mice bred to such an extent that he was able to get between one and two thousand young ones out of this cage, annually.

"The history of this cage is as follows: It was built in July, 1903, at his place of business, which was then at the corner of Shafer and Columbia Streets, $2\frac{1}{2}$ miles distant from its present location. It was kept in a barn, the boards of which were poorly matched, and the place was cold and windy in winter. It remained nearly a year in this barn and contained during this period about 100 mice. During the course of the winter he found one or two mice with tumors in the cage. In April, 1904, he moved to the corner of Light and Cedar Streets, two or three squares from the first location, and the cage was kept in a large coal shed, which was warm and comfortable. It remained from April to November, 1904, in this locality and during that period he removed from the cage 25 to 30 mice with tumors. In November, 1904, he moved to his present location, $2\frac{1}{2}$ miles distant from the first two mentioned. Before the cage was removed from Light and Cedar Streets he observed 12 mice at one time with tumors, and for the purpose of ridding himself of this unfortunate development of tumors he decided to change entirely the stock in the cage. All the mice which had occupied the cage were removed and 12 adult,

healthy mice, 10 females and 2 males, were imported from Washington, D. C., and introduced into the cage, which was placed in a small, detached outhouse, at least 50 feet distant from the present location of the cage. During the course of this winter 3 or 4 tumors developed.

"Since the spring of 1905, the cage has been in a large room 30 by 50 feet in size, which was previously a dance hall, and it now stands on a table 6 to 7 feet from a window where the conditions of light and ventilation are excellent. It previously stood in a different position in the room about 20 feet from its present location. During the last year he has removed between 25 and 30 mice with tumors from the cage, several of which have been sent to us. Owing to a misunderstanding on his part he had the idea that only tumors between the front legs were what we desired, and those which appeared on the flanks or lateral aspect of the abdominal region, he killed. At the time of my visit one mouse was in the cage with 2 large tumors on the right abdominal aspect. He pointed this out as an example of the kind of tumors which he thought we did not require. He states that he has never seen a tumor on the back of any mouse. He thinks they were mostly females, and in several instances when he examined them as to their sex he found they were females. He has never seen a male with a tumor. The tumors have frequently grown to great size.

"Besides the old cage, his establishment contains 12 or 15 other cages of similar construction. One of these is 2 years old, the remainder 1 year old. They are regularly stocked from the old cage. His custom is to remove from the old cage 12 or more females with one or two bucks and place them in the new cages and allow them to remain there until each cage contains approximately 100 mice. The half and three-quarters grown offspring are removed and sold. In the cage which is now 2 years old he has during the past year observed 4 to 6 mice with tumors. So far no tumors have appeared in mice in the other cages in the establishment. He remembers having seen one or two tumor mice in some of his old cages in his previous establishments, but these cages were always stocked from the old cage already described, which seems to have been the source of all his operations, and which he referred to as his incubator. The cage was purchased by the laboratory and brought to Buffalo with the mice in it. On reaching the

laboratory it was found to contain 3 mice with large tumors. The interior of the cage is dark and damp, incrustated with excreta, and presents a generally unhygienic appearance. Examination on the date of sending this manuscript for publication, August 3, shows that the cage contains 28 adult and perhaps twice as many half-grown and young mice. On the floor of the cage is the carcass of a mouse which has apparently been dead some hours, with a large tumor on the abdominal aspect. This is ulcerated and shows evidence of having been gnawed. A second mouse with a tumor the size of a large hazelnut protruding between the hind legs and evidently springing from the posterior part of the mammary tissue is also found. The skin over this tumor is adherent and the tumor is evidently far advanced.

"Briefly stated, the facts in the above case are as follows: A cage has been discovered in which upwards of 60 spontaneous tumors have occurred in the course of 3 years. The fact that the location of the cage was frequently changed, and the stock entirely renewed on at least one occasion without any permanent interference with the production of tumors, makes it apparent that the cage itself was the source of infection.

"Besides these observations which point directly to the cage as the source of infection, the endemic occurrence of cancer among mice in breeding establishments is well known and is illustrated to a remarkable degree in our own experience. For instance, from January, 1905, until the present time, this laboratory has had a standing reward of twenty-five dollars for any small animal affected with cancer. This offer, as already stated, was sent to 325 dealers in pet animals. It is possible that many of them have not appreciated the significance of the offer, or have overlooked cases of cancer in their stock, but during this period we have had constant business relations with seven dealers in different parts of the country, from whom we have purchased large numbers of mice, and who, we feel perfectly certain, have fully appreciated the monetary value of cancer mice. From one of these dealers we have received no less than eighteen female mice with cancer of the breast; from a second dealer, five of the same nature and sex; from two other dealers, one each, and from three from whom we have had repeated shipments of mice, none whatsoever. From one

of these dealers from whom we have received in the last two years not less than 1,200 normal mice, we learn that he has never, in his own stock, seen an example of cancer of the mouse, but that he was able to recognize the affection was shown by his having secured for us from another dealer a single specimen.

"These figures conclusively indicate that in certain breeding establishments cancer in white mice is endemic. The condition of affairs in the breeding establishment of a dealer in Massachusetts is interesting when compared with that of the Springfield dealer, where the evidence pointed to a single cage as the source of infection. This Massachusetts dealer has shipped to us, in all, eighteen cancer mice, in lots of nine, four, and five, and it is of great interest that the tumors in all of these mice were of relatively the same size. On inquiry as to where the tumors had developed, if they could be traced to a given cage or group of cages, we were notified that the mice were scattered indiscriminately through the entire establishment. This condition of affairs was so interesting that we made a trip to Massachusetts to personally inspect the premises, whereupon it was found that this dealer, in order to combat infectious and contagious diseases had her stock distributed among a large number of small boxes. These mice were moved about from box to box and the different families were regularly subdivided and used for the purpose of forming new families. This practice is entirely different from that of the Springfield establishment and easily explains the general distribution of the tumor mice through the different breeding boxes. The fact that the tumors have developed in lots of half a dozen or more at one time and that in the various shipments to us the tumors have been of relatively the same size, suggest that small epidemics have occurred at frequent intervals. The attempt to trace the origin of the infection to any particular box in the establishment is, of course, under the present system, impossible, and it is not improbable that this method has led to the dissemination of the contagion through a large number of the boxes.

"The foregoing observations indicate that both sarcoma in rats and carcinoma of the breast in mice must be looked on as contagious, and when considered in conjunction with the classical observations of Loeb and Borrel, in which, however, it

was impossible entirely to exclude the factor of heredity, should lead us to pay more serious consideration to the interesting statistics constantly accumulating which show the probable infection of the surroundings of human cancer cases in so-called "cancer houses." It should also lead to earnest consideration of the desirability of sterilizing the dressings of cancer cases and the complete sterilization of rooms which patients have occupied, and it should, at least to no inconsiderable extent, offset the recent statement of Hansemann, that we have no right to add to the difficulties of the cancer patient by the unnecessary suspicion that he is suffering from an infectious disease. It should tend to combat the belief among pathologists that there are no grounds for even suspecting an infectious factor in malignant tumors."

LIFE HISTORY OF A CANCEROUS GROWTH.

In spite of our still imperfect knowledge of the source, intermediate host of germ, and mode of infection of malignant diseases, we are in possession of definite facts as to the life history and clinical behavior of these affections from their inception in the human body that are very valuable in prognosis and treatment. The most important of these affirms that all malignant diseases are strictly local in their inception and not, in this stage, in any sense constitutional. Whatever the nature of the malignant growth, it is strictly limited at first to the locality in which it arises, and may in this stage be eradicated by destruction or removal of all of the infected cells. If this be neglected, impossible, or but imperfectly accomplished, the growth not only enlarges in accordance with its special character for virulence, but spreads by *local dissemination*, *regional dissemination*, and *general dissemination* until such time as the life of the human host is terminated by its encroachments.

Local Dissemination.—By local dissemination is meant the migration of malignant cells into the tissues in the immediate neighborhood of the original seat of the growth. There is every reason to believe that all of the more malignant cells possess a distinct power of locomotion, equal at least to the extra-vascular motility of the leucocytes, and that the process of erosion of neighboring tissues, whether soft parts, cartilage or bone, is due to the actual burrowing power of young cells,

which freely penetrate surrounding parts and there reproduce their kind by kariokinetic segmentation, the tumor itself growing partly by a coalescence of the colonies begotten by each emigrant germ-cell in its rapid proliferation, and partly by similar reproduction of the cells within the edge of the principal mass. The rapidity and virulence of this growth vary greatly with the several genera and species, and are at times controlled somewhat by the physiologic resistance (phagocytic resistance) of the tissues of the host. It results in the formation of an outlying zone of dissemination surrounding a malignant tumor, made up of distinct colonies which have planted themselves in normal tissues, which they consume and from which they drain nutriment and trophic force, and the leucocytes of an inflammatory process which the body forces always marshal more or less strongly against the diseased cells. The rapidity and extent of this local dissemination vary with the particular species of growth, great differences being found among both sarcomas and carcinomas.

Regional Dissemination.—A carcinoma is disseminated beyond the immediate neighborhood of the mother tumor almost exclusively by means of the lymphatics. In the process of erosion at the primary seat of the growth the migrating cells invade the lymphatic spaces and vessels and are washed along by the current until mechanically arrested, which may occur at the valves in these vessels but necessarily so at the lymphatic glands. It has been said that the larger size of the cells in sarcoma is the reason why this mode of dissemination is mainly confined to the carcinomata. Since the lymphatic glands are the filtering points, as it were, in this system, it is within their glandular structure that the infective emboli are usually first arrested. Further migration is here stayed until sufficient erosion of the gland tissue results to permit an entrance of the cells into the distal lymphatics leading to other glands in the chain, and it is generally not until the whole chain is affected that the migratory cells at last gain entrance into the general vascular circulation, permitting general dissemination to many organs of the body. The practical effect of regional dissemination, therefore, delays general dissemination by a most important interval, though it proves that the original focus of infection no longer contains within itself the whole number of malignant cells. An important lesson to be learned from this

barrier or filter action of the lymphatic glands, and the fact that only the glands nearest the growth are first affected, is the un wisdom of removing or destroying the glands of a region in which a primary cancer exists unless they are themselves palpably affected—a mistake not infrequently made in the attempted thoroughness of modern knife operations.

The regional dissemination of a sarcoma is usually accomplished by a directly continuous, or but slightly discontinuous, growth of the tumor along the fasciæ, blood vessels, or nerve sheaths—it is a local dissemination on a large scale with a special preference in certain directions. A sarcoma may, however, be disseminated through a region by the lymphatics in the same way as a carcinoma.

General Dissemination.—A malignant growth does not become constitutional in any sense until general dissemination has occurred; for so long as the migrating cells are confined to the seat first attacked, and even to the lymphatic glands of the region, the affection is a strictly local disease. When the erosive process has permitted young cells to escape into the blood current, either directly or by means of the venous terminal of the lymphatics, the cells become a portion of the circulating fluid and tend to lodge as emboli in the capillaries of various internal organs, particularly the liver, the lungs, and the red marrow of the bones, and there proliferate and produce daughter tumors in every respect like the original growth. By reason of the number of the daughter tumors thus added to the primary malignant invasion, or usually by reason of the vital character of the internal organs thus attacked, the blood becomes quickly deteriorated and the characteristic cachexia of malignant disease appears.

The appearance of this cancerous cachexia is therefore a sure sign of internal dissemination of a malignant growth, and usually presages a certain failure of any efforts yet devised to check the course of the affection. A moderate amount of cachectic discoloration of the skin may be present in some cases while the disease is still local, nevertheless, and the disappearance of this incipient cachexia during the use of the author's method of treatment on several occasions, *pari passu* with the destruction of the malignant cells, makes it apparent that the true nature of the cachexia, in part at least, is that of an auto-intoxication from the excretions of the cancer cells.

General dissemination may occur early or late in the history of the primary growth, in accordance with the virulent characteristics of the particular species, though the proneness to early metastasis does not always correspond to the local virulence, since the most hopeless general infection may be found to exist in a case in which the primary growth has been neglected on account of its small size and slight symptoms. The diagnosis of the presence of early general dissemination, when but one or two internal metastases have occurred, is at times most difficult, and the surgeon is often compelled by the dictates of humanity to give a patient the benefit of the doubt and proceed to destroy the primary growth, only to find later the inexorable evidences of the existence of an internal graft implanted some time before the destruction of the mother tumor. Such cases remain as sad examples of the importance of the early treatment of malignant disease.

The wisdom of destroying the primary growth while in doubt as to the presence of internal metastasis, is, however, at times based on other grounds, for the clinical features that render the diagnosis difficult—the absence of pain, hemorrhage, fetor, etc., traceable to the internal growth—render the destruction of the primary tumor a valuable palliation of the last days of the patient.

CHAPTER III.

THE DIFFERENTIAL DIAGNOSIS OF MALIGNANT GROWTHS.

The differential diagnosis between benign tumors and the several varieties of malignant growths assumes added importance in view of the necessity for early treatment of the latter in accordance with the present views of their local origin. It is indeed easy for the layman to diagnose an external cancer in its last stages, but the success of any rational means of cure is at present dependent on the recognition of the disease in a much earlier stage of its progress. The early recognition of malignant local infections is therefore one of the most pressing duties of general practitioners, for it is usually the family physician who is the first to be appealed to by the patient, and the practical usefulness of early diagnosis is greatly increased by the facility with which a small growth may be eradicated by the methods described in this work, without necessarily destroying or removing the organ in which it is situated.

With this means at hand the physician is in a position to adopt the altered aphorism, "When in doubt, destroy the growth," in all small tumors of the skin and mucous membranes and all suspicious nodules in glandular organs, for in these cases the destruction produced by the application is limited to the growth itself and its immediate peripheries, and the disturbance of the patient is no greater than would be necessary if the growth be really benign, the methods being adapted to the destruction of the latter as well. The use of cataphoric methods greatly simplifies the decision to destroy small suspicious growths, therefore, relieving the surgeon from the two-horned dilemma of leaving a small focus of malignancy to develop further, meantime possibly leading to metastasis, in order that the removal of the whole organ may be justified without doubt, on the one hand, or, on the other, of sacrificing an entire organ for what turns out to be only a benign neoplasm.

CLINICAL EVIDENCES OF MALIGNANCY AND OF THE SPECIES OF A MALIGNANT GROWTH.—As has been stated, the chief

clinical evidence of a neoplasm being of a cancerous nature is its tendency to indefinite increase by the erosive destruction of neighboring organs; and while the microscopic evidences of this condition, shown by the cells being misplaced, in greater abundance than normal, and unprovided with a membrana propria, must be regarded as the standard for the formation of an absolute diagnosis, there are many clinical evidences of great value in reaching a presumptive diagnosis, and many circumstances in which the latter alone must be depended on in the absence of a skilled microscopist and where delay would endanger the patient. The clinical evidences are in certain cases even superior to histologic evidences. In two cases under the author's observation, one of carcinoma and the other of sarcoma, the patients ultimately died of repeated recurrences in spite of the failure of several skilled histologists to find microscopic evidences of malignancy.

Probably the most important point in the diagnosis of early malignant growths is that, contrary to the prevailing impression among the people, these growths are rarely painful in the stage in which they are most curable. This fact is one of the most fruitful causes for that fatal delay which yet paralyzes remedial effort. A slight stinging, or uncomfortable sensation, is usually the only complaint made, until, the quickly proliferating cells having finally reached sensory nerve trunks or filaments, the severe and continuous pains of advanced local disease are suffered.

The age of the patient is an important factor in reaching a presumptive diagnosis. A suspicious lump is not likely to be a cancer if the patient is under thirty years, though exceptions to this rule are occasionally met with, particularly in cases of quickly growing so-called congenital sarcoma in children. The writer has met with a large sarcoma of the orbit in an infant of six weeks and in two children of five and six years, and a very large sarcoma of the ovary in a girl of fourteen. Carcinoma is more rarely found than sarcoma in these early years, though fulminating, highly parasitic, quickly-growing acinous carcinoma of the breast may be encountered in women as young as twenty-seven to thirty, particularly as a sequel to miscarriage or normal pregnancy.

Rapidity of growth is of course a marked feature of a malignant tumor, yet this fact is at times apparently wanting

in those carcinomas to which the older name of scirrhus was given, the truth being that in these cases the progress of the disease in its primary site is held in check by the physiologic resistance of the individual, which permits the phagocytic cells to develop into connective tissue fibers which intersect and compress the cancer cells, giving rise to the hardness. Metastasis is, however, an ever-present danger of these slowly growing carcinomas, as of the more cellular or encephaloid variety. The rapidity of growth of a cancer is a product, therefore, of two opposing factors: the degree of malignancy of the particular germ, and the phagocytic, deterring quality of the type of cell of the individual. A rapidly growing carcinoma must be carefully differentiated from inflammatory infection, the latter being accompanied by much more pain, heat, and tenderness, and finally by fluctuation. It must also be differentiated from gummas, tuberculosis, actinomycosis, and chronic supuration.

A primary malignant growth is very rarely multiple, as so frequently happens in benign tumors.

The mobility and contour of a small tumor of the breast are important evidences for or against malignancy. In advanced stages the diagnosis of breast cancer is exceedingly easy, even before the appearance of pain, for in addition to the lack of tenderness, the whole breast is immovably fixed to the subglandular tissues. When it is, on the contrary, yet but a small nodule situated within a lobule of the glandular tissue it is still movable, though it does not slip so readily between the fingers as a benign, encapsulated adenoma. Even in this stage the edges are more nodulated, showing the peripheral prolongations. At a later stage the overlying skin becomes attached to a carcinoma, forming a dimple, which later alters in color and texture by an extension of the malignant process to the derm itself. From chronic lobular mastitis it is differentiated by better defined edges, and by the absence of tenderness.

The retracted nipple, when its fellow is normal, is a valuable diagnostic sign in the more advanced cases of contracting scirrhus acinous carcinoma. At times the nipple is pulled aside in the direction of the most affected lobule of the breast as well as retracted.

The principal points of clinical difference between carcinoma and sarcoma are: that carcinoma invariably arises in situations

where epithelial tissues are situated, and causes regional dissemination by way of the lymphatics, while sarcoma arises invariably beneath the unchanged skin or mucous membrane where connective tissues are normally prevalent, and causes regional dissemination mainly by way of the blood vessels and cellular planes of the tissues.

The following table presents the characteristic differences between sarcoma and carcinoma in a synoptical form:

	SARCOMA.	CARCINOMA.
Origin.	Connective tissue.	Epithelium.
Composition.	Immature con. tis.	Epithelial cell, fibrous stroma.
Age.	Before middle life.	After 35.
Sex.	More common in men.	More common in women.
Heredity.	No influence.	May influence.
Seats.	Connective tissues.	Epithelial surfaces and glands.
Metastasis.	By blood vessels.	By lymphatics.
Growth.	More rapid, often intermittent.	Usually slower.
Outline.	Rounder, more circumscribed.	Nodular, irregular.
Local Infiltration.	Less marked.	Widespread.
Cut section.	Convex.	Concave.
Adipose tissue.	Absent.	Usually present.
Juice.	Often absent.	Present.
Color.	Reddish grey, more translucent.	Greyish white, granular.
Melanosis.	Not uncommon.	Rare.
Ulceration.	Uncommon, superficial.	Common, deep.
Adjacent skin.	Often uninvolved.	Infiltrated.
Intercellular substance.	Always present.	Absent.
Alveolar structure.	Uncommon.	Constant.
Cells and stroma.	Intimate association.	No close connection.
Blood vessels.	Between cells.	In stroma only.
Blood vessel walls.	Often imperfect.	Well formed.
Lymphatics.	Absent.	Present.

Clinical Examination with Reference to Stage of Growth and Advisability of Surgical Intervention.—In the practical examination of a growth palpation is of the greatest importance, as by the educated touch we may determine its limits; whether cystic or solid (transillumination being at times a valuable means of verifying fluctuation); whether pulsation is present in the growth or is communicated to it by underlying arteries (by lifting it away from the latter); the nearness of important vessels; whether the malignant process is still confined to an organ or is diffused beyond it; and, most important of all, whether the glands draining the part are enlarged or not.

The local examination should also be preceded or followed by a general examination of the patient, directed especially to determine the presence or absence of secondary growths in the chest or abdomen; the condition of the arteries and of the kidney excretion; and a blood count should be made.

The blood examination is of but little value in the earlier stages of a growth, but in the presence of metastasis the number of red blood cells is decreased, falling sometimes to 1,500,000 to the cubic millimeter, though usually not getting lower than 3,500,000. Should the hemoglobin index fall to 50 per cent. the patient is apt to be too weak for any form of operation.

The leukocytes are usually unaffected in the absence of metastasis, though when this is present they may be increased, as in any wasting disease. In carcinoma in certain situations, such as the uterus, the kidney, and particularly the pancreas and thyroid, there may be a marked increase in the leukocytes.

Microscopic Diagnosis.—Although much can be learned from the clinical history and the examination of the patient, yet the very early recognition of the existence of malignant disease can be made only by means of the microscope. When the condition has advanced to the point where the diagnosis can be made by the clinician the hope of helping the patient is reduced to a minimum.

In making a diagnosis of malignancy by the microscope certain characteristics of the various growths must be taken into consideration.

As already mentioned, malignant tumors may be classified under two headings according to the layer of the blastoderm from which they are developed. There are the epithelial tumors, the carcinomata, and the mesoblastic or sarcomatous growths.

In the carcinomas there is a distinctly atypical arrangement of the epithelium and the connective tissue. The epithelial elements are arranged either in solid nests or masses surrounded by adult connective tissue, or else there is an abnormal arrangement of imperfect acini.

The carcinomas differ greatly in appearance according to the part of the body that they occupy. When on the surface of the body they are generally flat or slightly nodular. It is such tumors as these that frequently undergo inflammatory

change and ulceration on account of their being so exposed to injury.

The growths arising from the mucous membranes are usually rather soft and present frequently a cauliflower appearance. They may also undergo inflammation, or they may appear primarily in the form of an ulcer.

When a carcinoma develops within a glandular organ of the body it generally appears as an irregular infiltrating mass, that will be hard or soft according to the amount of cellular tissue present.

The type of the cell that forms the carcinoma depends upon the variety from which it grew. In the squamous epitheliomata the cells resemble those of the squamous variety, such as are found covering the skin. The cells are large and flat, with a large vesicular and centrally located nucleus.

In those arising from the glandular mucous membranes and from the glandular organs the cells are usually columnar or cuboidal.

It was formerly thought by some investigators that the diagnosis of malignancy could be made from the cells alone on account of their atypical appearance. Such, however, is not the case, the abnormalities of the shape and size of the cells being accidental conditions, resulting probably from the compression brought about by the growth of the tumor.

The diagnosis of malignancy depends rather on the general relation of the tissues than upon individual characteristics of the cells.

Normally, in an acinus of a gland the epithelial cells generally occur in a single layer resting upon a very thin but well-formed basement membrane of adult connective tissue that separates them from the surrounding tissues. In a so-called adeno-carcinoma the cells are found to have done either or both of two things. They may have undergone such a proliferation as to have more or less completely filled up the acinus. In such a condition instead of a single layer of uniform cells there will be many layers of atypical ones. These epithelial tumors are frequently classified as Simple, Scirrhus, and Medullary, according as to whether the amounts of connective tissue and epithelium are about equal, or the former or latter elements predominate.

On the one hand, the basement membrane may have suc-

cumbed to the malignant effects and the cells will have invaded the surrounding tissues. According to the plane of the section examined, there may be found these masses of atypical cells isolated from any acinus, or the point of rupture through the basement membrane may be disclosed.

In the so-called epitheliomata the papillæ of the skin will be found to extend deeply into the underlying tissues. The restraining power governing the growth of the cells is apparently destroyed and the epithelium infiltrates the surrounding structures. In many places the cells will be found concentrically arranged, forming the epithelial pearls. In these areas the cells will frequently have undergone a transformation into keratin.

It should be remembered, however, that these pearls do not indicate malignancy; they show nothing more than that the particular growth arose from squamous epithelium. Carcinomata, having grown to some size, very commonly show various forms of degeneration, the most frequent being a fatty change. Like all other epithelial structures, a parenchymatous degeneration of the cells is often found. The protoplasm will be swollen and cloudy, and the nuclei may be very indistinct or even completely concealed.

The connective tissue present may undergo a myxomatous change and give rise to the so-called colloid cancer, an incorrect definition, as the change is not within the epithelium but within the fibrous stroma.

Occasionally the cancer may become cystic, either by a blocking up or absence of an excretory duct, or by degeneration of the growth itself.

There may be a deposit of lime salts within the degenerated areas.

There may also be secondary inflammatory changes, brought about by the infection of the tumor by some organism, particularly the streptococcus or staphylococcus.

The sarcomata, or malignant mesoblastic tumors, are composed of tissue that in its form resembles to a certain extent embryonal connective tissue. It, however, differs from it in that in the sarcoma the cells never attain an adult condition, and they do not all originate as round cells, as do normal varieties of connective tissue. The growth may be composed from its earliest stages of spindle cells and not show any attempt at

true connective tissue formation, no matter how long the tumor might exist.

A sarcoma is generally more circumscribed and nodular than a carcinoma, and is frequently decidedly pinkish in color on account of the amount of blood present. It may vary in hardness, depending upon the amount of intercellular substance present. It may become soft through degenerative changes.

These tumors may arise wherever there is a pre-existing connective tissue. Consequently they may be found in any part of the body, externally, or within the internal organs.

The microscopic examination shows why metastasis in the sarcoma takes place by means of the blood vessels. The tumor is made up of undeveloped connective tissue, and the blood vessels, instead of having well-formed walls, have usually a single layer of flat endothelial cells. Even this slight protection is often absent, the endothelium being present in a very imperfect condition. Consequently the blood channel is often surrounded by nothing more than a mass of tumor cells. As a result of this, very slight degenerative changes in the tumor allow the cells to be set free within the circulation. They are then carried to the small capillaries, in which they lodge and grow.

In carcinomata, on the other hand, the connective tissue that is present in varying amounts between the collections of atypical epithelial cells is fully developed, and it is there that the blood vessels are found. They are thus separated from intimate contact with the tumor cells, and consequently metastasis of carcinoma by the blood is comparatively rare.

In sarcoma there is little or no tendency towards fibrous tissue formation. There is, however, a great multiplication and increase in the number of cellular elements.

According to the variety of cell, the sarcoma may belong to one of the following types: Round cell, spindle cell, or giant cell. It may be known as an angio-sarcoma if it has had its origin from the adventitia of the blood vessels, or it may be a melanotic sarcoma if pigment in the form of melanin is present. This pigment differs from the coloring matter of the blood in that it does not contain iron. The round-cell sarcoma is composed of cells that may be either large or small. In them there is very little intercellular substance, the cells greatly pre-

dominating. They are grayish or pinkish in color, and frequently exude a milky fluid. They are always malignant, and the smaller the cell the more marked is the predisposition to general involvement.

The spindle-cell form may also be divided into large or small according to the size of the cell present. They are usually comparatively firm, and sometimes the intercellular substance is so well marked that the tumor may be called a fibrosarcoma. At times it is very difficult to decide whether or not the tumor is sarcomatous or fibrous. As a rule, they are not very malignant; quite frequently they do not give metastasis.

The giant-cell sarcoma usually arises from the periosteal covering and gets its name from the fact that in it we find many cells containing two or more nuclei. Incidentally, it should be remembered that the term giant cell wherever met with does not refer to the size of the cell; it indicates only that there are more than one nucleus. These tumors are slow in growth, usually quite hard, and are practically benign, very seldom giving rise to metastasis.

The angio-sarcoma is seen to consist of irregular masses of cells surrounding blood vessels. They frequently undergo a myxomatous degeneration, and hemorrhage into the surrounding tissues may result. As a general rule, they do not tend to give metastasis.

The melanotic sarcoma is one that may be made up of cells of any variety and of any arrangement, but it contains melanin. This coloring matter may occur either within or between the cells. This form most frequently arises in pigmented moles of the skin or within the eye. It is exceedingly malignant, grows very rapidly, and gives extensive metastasis, particularly in the liver, the secondary growths frequently containing more pigment than the primary tumor.

CHAPTER IV.

THE DESTRUCTION OF MALIGNANT GROWTHS BY THE LOCAL CATAPHORIC DIFFUSION OF METALLIC IONS.

Whatever truth may be uncovered by the further study of malignant disease, there can be only corroboration and explanation of at least one or two facts already in our possession, the correctness of which has been amply proven. Of these the most important relates to the purely local character of the primary growth at its first appearance, and the possibility of its eradication in this stage by the use of effective means. We may be as yet unaware of the reason why the cells of a cancerous tumor possess the power of migrating into and eroding surrounding tissues—the central fact of malignancy—but we do know that the potential energy of a cancer resides within or between these cells, and that this potential energy may be destroyed by the complete removal or destruction of all abnormal activity in the affected region.

It may be unequivocally stated, therefore, that, in spite of our ignorance of the true nature of the cancer cell, *an incipient cancerous growth in an accessible situation, which has not given rise to metastasis, may be totally destroyed by appropriate means, thus curing the patient.* Cancer is, therefore, curable, under the conditions mentioned, and the full realization of this fact is of the utmost importance to sufferers. Of equal importance is the knowledge that *internal metastases occur very early in many forms of cancer, and that when this has been permitted to happen through delay there is at present no known means of cure.*

Referring, therefore, wholly to growths still local, or with but slight and yet accessible regional dissemination, the question of greatest importance relates to the best method of destruction or removal, for at present no other means of cure exists. It is to this class of so-called operable cases that this work is intended mainly to refer, though many of the cases recorded in these pages show the difficulty of selecting them

while yet in this stage, and illustrate the value of the method as at least a palliative in the inoperable class.

The recent history of radiotherapy indicates that the hopes entertained at first for x-radiation as an effective method in operable growths have resulted in disappointment, except for epitheliomas of the skin. The feeling is apparently general that the rays should be preceded, at least, by more positive operative methods when possible. A fuller recognition of the dangers of metastasis occurring during the prolonged treatment by this method should accentuate this reluctance to trust to it alone in the classes most liable to this sequel. Until massive ionic sterilization was proposed for certain cases we were, therefore, thrown back on the knife, thermocautery, and caustics as the surgical remedies promising operative cure.

Removal of all affected cells and intercellular substances by the knife, thermocautery, and caustics has unquestionably been accomplished in some instances, particularly since the adoption of the modern extensive knife operations in which all surrounding tissues are removed at the same time with the growth, and there can be no question but that a larger number of successful results would follow an earlier resort to the latter form of operation than the usual dread of the knife permits. But the continuing disfavor of the knife in the treatment of cancer is doubtless in part due to unwise attempts to employ it where complete removal is impossible, or where the act of removing the growth has resulted in such handling of the tumor, still laden with living cancer cells, as to result in an operative reimplantation of the cells in the cut edges of the wound. It is at least certain that what progress has been made of late in the knife treatment of cancer is along lines that make this reimplantation unlikely. Unless the growth has been removed to its remotest prolongations, together with all infected glands, *without wounding the growth itself or permitting the tumor juices to come into contact with the cut edges of the healthy tissue*, the results will be no better than those attained in the past—results that were indicated in the statement of the late D. Hayes Agnew that he had removed a cart-load of cancerous tumors in his time, but that all the patients from whom they had been removed had ultimately died of the disease.

How difficult this complete removal without reimplantation is of accomplishment in some cases only the practical surgeon knows. In many situations, particularly within cavities, it is essentially impossible; and much attention has, therefore, been given to the thermocautery, either alone or following an attempt at removal with the knife. Used alone, the thermocautery or caustic pastes cannot be relied upon to secure sufficient penetration; when used after the attempted extirpation with the knife or curette it is extremely likely that the cancer cells have already been aspirated into the cut veins or lymphatics to set up regional or general metastases.

With the sole exception of the wide-sweeping knife operation, the surgical methods mentioned are, therefore, ineffective or prone to cause operative reinfection, and thus not only fail of their object, but lead directly to an intensification of the disease.

That wide-sweeping knife operations are at times themselves ineffective can only be due to the fatal delay that permits metastases to be implanted before operation in cases that should have been operated upon many weeks, months, and even years before consent was given. Against this form of mental delinquency on the part of sufferers no operative remedy is of avail.

THE AUTHOR'S METHOD.—What, then, are the conditions to be met in those cases where the wide-sweeping knife operation is inadmissible?

For effective results in such cases we must have a method that acts as quickly and thoroughly as the knife in a favorable case for that method, and yet is capable of application through the growth itself, from within outwards, enabling us to reach the actual periphery of the latter by a combined destructive and occlusive agency, devitalizing all cells *in situ* and sterilizing the outermost edge while at the same instant sealing the absorbents, thus effectually preventing operative reinfection. If the growth be within a cavity, this force must be conveyed along a conductor that is of small caliber and often tortuous, and the conductor must be capable of thorough insulation of the force when traversing non-affected parts, thus permitting the destructive effect to be directed and controlled at will. If this agency be also absolutely bloodless, and leaves as a product of its action sufficient antiseptic chemicals interstitially diffused throughout the growth, and in chemical union with its devital-

ized cells, to maintain an absolutely aseptic condition until the *débris* separates—it would seem to be a most valuable method where a perfect knife removal is impossible.

Not only are each and every one of these indications met by the massive diffusion of the ions of mercury and zinc by powerful electric currents, as devised and developed by the author during the past sixteen years, but still another result of value follows the production of such an area of sterilization coterminous with a malignant growth: for beyond this area of total necrosis the diminishing density of the diffused ions will produce a zone of reaction of slightly further dispersion, sufficiently infiltrated with the ionized chemicals to destroy outlying latent cancer cells while only arousing the physiologic resistance of the normal tissues.

The basal facts developed by the author in the study of this process are that, in the utilization of the electrolytic and phoretic powers of a strong electric current for dissolving and ionizing zinc points or needles coated with mercury and thrust into the growth, a quantity of ionized mercury and zinc may be interstitially diffused throughout a tumor in a few minutes, with the patient usually under an anesthetic, that will be sufficient to kill all malignant cells and their accompanying germs, if the latter be present; and that by prolonging the process sufficiently these microbicidal substances will be driven further than the apparent boundaries of the growth in sufficient strength to kill outlying colonies and lines of dissemination in the immediate neighborhood, without serious detriment to the healthy tissues in this situation. In other words, while all tissues will be necrosed *en masse* near the electrode, producing an *area of sterilization*, the diffusion may be so regulated and directed that a sufficient quantity will pass beyond the line of demarcation and kill outlying cancer cells by arousing the tissue defenses, forming thus a narrow *zone of reaction* beyond the area of sterilization.

The diagram, Fig. 1, illustrates what happens in a surface growth under a strong current with a free supply of zinc-mercury points. The evident portion of the tumor will become shrunken, and softer, and will change in color to a grayish-white in from five minutes to one hour, under a current appropriate to the size of the growth, all living structures being bloodlessly devitalized. The limits of total necrosis are sharply

defined, and become later the site of the line of demarcation as nature throws off the dead material.

In spite of the employment of a current that will develop large quantities of ionized mercury and zinc and impregnate considerable areas with it, the general system of the patient is protected from the absorption of all but a minute quantity by reason of the sealing of the absorbents by the necrosing action

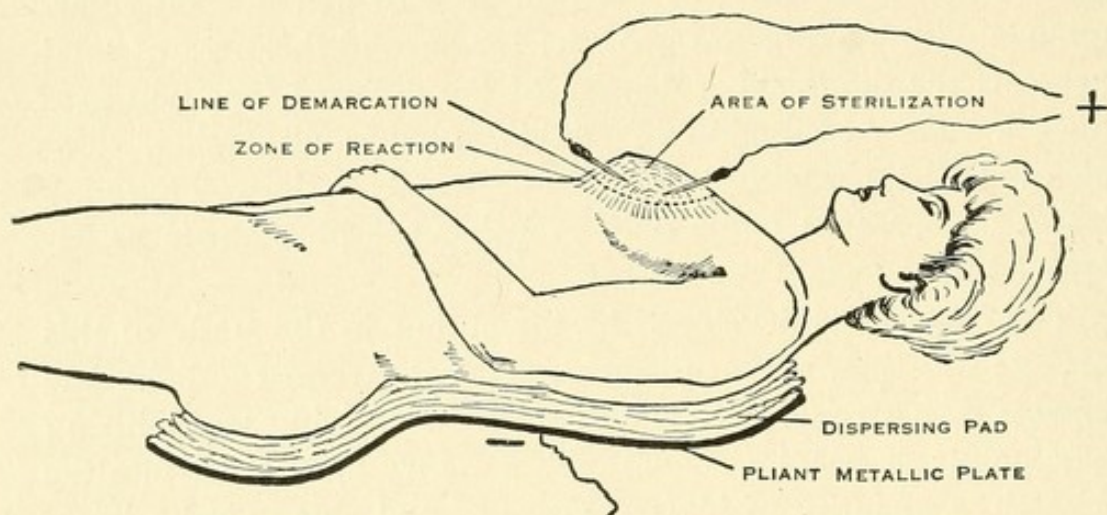


FIG. 1.—Diagram of monopolar ionic operation in a case of cancer of the breast.

of the metallic ions where densely diffused. None of that deposited within the area of sterilization can, therefore, be absorbed, theoretically, and clinical experience shows so little, if any, absorption after the most extensive operations that it is probable that the portion deposited beyond the line of demarcation comes away in the discharges during the process of healing, in large part. In fact, it has seemed to the author that the small portion of these antiseptic chemicals thus probably absorbed within the system and eliminated by the emunctories may account for the quick improvement in the general health after operation in cases showing a preoperative anemia without metastasis, though this improvement may really be due to the immediate destruction of the toxin-generating malignant cells.

The subsequent history of a growth subjected to the major application with strong currents is most interesting. On the completion of the application it will be noted that the whole mass of the tumor is of a grayish-white color, and that if odor has been present it no longer exists. All tendency to bleeding has also been arrested, of course.

On emerging from the anesthetic the patient experiences no

pain, but considerable soreness. By the next day a puffy, reddened zone will be found surrounding the area of sterilization and occupying the situation of the zone of reaction. This is somewhat tender on pressure. By the third day a tendency towards the formation of a blister is seen along the site where the line of demarcation will form, and when this line forms some days later a lead-colored, odorless serous discharge will appear and continue until the separation of the dead mass, the latter event occurring from seven days to three weeks from the date of operation. The cavity thus made heals quickly by granulation and cicatrization, and with a soft and comparatively small scar, there being none of the tedious delays and uncertainty incident to x-ray burns.

HOW THE METHOD WAS DISCOVERED.—During the summer of 1893 the author attempted the treatment of an adenocarcinoma of the groin in a gentleman, at his request, destroying at first the mass of the tumor by ordinary bipolar electrolysis, and then changing the method to positive cauterization with a blunt electrode of carbon. But slow progress was being made under the use of currents of about 100 milliamperes applied daily, this strength being made endurable by the simultaneous cataphoric dispersion of cocaine solution from the cavity, when it was noticed that the carbon electrode showed signs of roughening under its repeated employment as a positive pole. It now occurred to the author that a zinc electrode would be better, since the materials formed by its erosion would assist in the destructive process. This had been either done or suggested in other diseases than cancer by a number of writers on cataphoresis, particularly Gautier of Paris and Morton and Cleaves of this country. A suitable instrument was accordingly fashioned from a Leclanché zinc rod and applied, without any appreciable change in the effect with the current strength used. As, however, the active surface of the zinc was found to be blackened and roughened by the formation of oxides from the contained ferric impurities of commercial zinc, it now occurred to the author that a free amalgamation of the zinc with mercury would be of the same value here as when the zinc is employed within a battery: *i. e.*, keep it clean by reason of being coated with a layer of pure zinc in mercuric solution. The thought also arose, but distinctly secondary, that possibly the mercury could also be chemically changed and

diffused with the zinc, though it was known that this did not occur within the battery. This was accordingly done, and with a hundred milliamperes turned on there soon appeared a whitish pellicle beneath and around the instrument, distinctly different from that following the previous use of the zinc. The next day the importance of the discovery thus made was evident when it was noticed that the unpleasant odor, which had begun to issue from the eroded cavity, had ceased, and that the area of induration on the side of the cavity against which the electrode had been applied was lessened. The method was now continued in this mild form with most notable effects, as detailed elsewhere,* and though the ultimate result was not a cure in this case, enough was seen of the effects of the method to encourage further trial. It was not until the spring of 1896, and after the successful application of this mild method to one case of sarcoma of the palate in 1894, that the stronger method under an anesthetic was essayed, and again the results were most important, though first seen in a case that was then failing from internal metastasis.

The effects observed in this latter case demonstrated incontestably and for the first time that a zone of infiltration would form beyond the area devitalized by the more densely diffused chemicals, and that within this zone a reaction would occur, accompanied by a disappearance of malignant characteristics in this situation. A current of one thousand milliamperes was applied in a bipolar manner, several zinc-mercury electrodes connected together and to the positive pole being thrust into the periphery of the tumor, while the circuit was completed by a cotton-covered disk saturated with Fowler's solution connected with the negative pole and placed against its center. This resulted in the diffusion of zinc-mercury ions from each anode in the periphery, and of arsenic ions from the negative disk in the center. Areas of devitalization appeared in a few minutes in each situation, namely: a large one beneath the disk in the center, and smaller ones around each zinc-mercury electrode in the periphery, accompanied by a general shrinkage of the growth. After fifteen minutes the current was turned off and the patient put to bed. On removing the dressing the next morning I was surprised to find that the indurated tissues that lay between the small areas of necrosis had

* Transactions American Electro-Therapeutic Association, 1900.

changed color from a purplish to a pink tint, and were puffy. Two days later this puffiness had largely subsided; and what had been an elevated, indurated, malignant-looking zone at the edge of the growth was now quite pink, flat, and devoid of malignant appearance. It was evident that *some material or influence had passed through this tissue, beyond the line limiting total devitalization, which was sufficient to destroy malignant cells while only acting as an irritant to the normal histologic elements.* The subsequent history of the case fully established the fact that at least a greater portion of these cells had been killed, for the tissue never regained its malignant characters, though this patient was finally carried off by the continued progress of metastatic deposits in various internal organs that had been implanted some time before the application was made.

The discovery that pure mercuric ions could be produced and diffused from a gold instrument was the result of subsequent experiment, when it was found also that this diffusion was so rapid, by reason of the action being confined to the mercury, gold being unattackable, that it was necessary to devise some means of keeping the active surface of gold supplied with its mercury coating, even under a moderate current. This was finally done by employing tubular instruments made of pure 18 karat gold, through the caliber of which an excess of the quicksilver was injected with a glass syringe after the instrument was in position in the tumor.

Anodes composed of iron, metallic arsenicum, copper, and of silver—the last two coated with mercury—have also been experimentally used, but it was found that all, except silver, were inferior in a most marked degree to the first accidental combination of zinc and mercury. The exact value of silver-mercury ions has not as yet been determined.

GENERAL PROGNOSIS OF CANCEROUS GROWTHS UNDER IONIC STERILIZATION.—This method is not one that acts by producing a mysterious effect at a distance through air-space and tissue, as in the case of Roentgen rays, but a simple application of the laws of phoretic diffusion to surgery, with possibilities only greater under certain conditions than the grosser art of tissue severance with the knife. The results are, therefore, due to the adaptation of a new surgical method to the varying anatomical problems of individual growths, and these

problems have thus far received the close attention of but a handful of operators in a limited number of cases, the latter often badly chosen in the absence of a clear knowledge of the limitations of the method.

The results already attained show, nevertheless, that ionic surgery has a wide field of usefulness as a preferable method in the destruction of incipient growths in many portions of the body, judging from the small number of this class that have been placed under it. That the opportunities to employ it in this class have been so few is probably due to the general neglect of early treatment, added to which is the natural tendency of physicians to turn to a new treatment only in the most desperate cases, and after all other means have failed.

Cases properly classifiable as inoperable by the knife and by every other known method have therefore been the main source of the author's material in the development of the method, many having been undertaken in order that the patient might have the benefit of the doubt that still surrounded the possibilities of the method and the uncertainty of the presence of metastasis. Under such conditions it has been most gratifying to the author, in reviewing his more than sixteen years' work with the method, that a large proportion of the patients treated have been greatly benefited; that a very small proportion have not been benefited or have been made worse; and that a few have had their lives saved, and have been actually cured when this result could not possibly have been secured by the use of any other known means.

In view of these facts it is evident that the classification of a given malignant tumor into the operable or inoperable lists will require new studies with ionic surgery available, for the possibly operable class is distinctly enlarged by this method.

In the end, it will be found that the most valuable sphere of ionic surgery will be to render treatment in the operable stage more attractive than it has been to the patient in the past, and thus to induce early resort to the surgeon; for in this stage it often offers a less fearsome prospect of blood and mutilation, with equal or better prospect of cure.

As to what constitutes a cure, great caution must be employed. To permit patients to believe that a cure has been reached as soon as the parts have healed with no disease manifest is most dangerous to their ultimate welfare. They should

be distinctly warned that it is their duty to remain under regular periodical expert inspection for at least three years before a cure can be affirmed, though freedom from evidence of a pre-existent metastasis for one year after destruction of a tumor, with no local recurrences ascertainable by *expert* inspection, gives reasonable assurance of success.

This three-year limit for the development of latent germs of the growth in the locality of the wound, and of indubitable evidences of a pre-operative internal metastasis, is, of course, entirely arbitrary and subject to occasional exceptions. The greatest number of local and regional recurrences appear in the first three months when a sharp lookout is given the case, and the three-year limit means that each successive period of time is so increasingly free from new growth *not observable on close inspection in previous periods of time* as to reach a reasonable certainty of its non-appearance by the end of three years.

It is the author's belief that there has been too little expert post-operative inspection of these cases, and that recurrences credited to the end of one and two years could have been discovered and destroyed within a few weeks or months after the operation.

So important is the need of mutual attention to these points on the part of both surgeon and patient, and a full realization of their true position on the part of patients, that those now discharged in good condition from the Oncologic Hospital are given a printed slip reading as follows: "In consideration of the absolute need of full co-operation between physician and patient that the best results may be attained in treatment, I hereby promise that when discharged from the hospital in good condition I will present myself to the surgeon in charge of my case, or to his delegated representative, at periods not less than three months apart for three years, and that if directed to return for further treatment I will make the utmost endeavor to do so."

CHAPTER V.

THE PHYSICS OF THE IONIC STERILIZATION PROCESS, AS EMPLOYED IN THE DEVITALIZATION OF DISEASE AREAS.

A clear conception of the electro-chemical reactions occurring in living tissues during the employment of the method described in the preceding chapter requires some attention to the phenomena of electrolysis. These phenomena are under very active study at the present time, both from theoretical and practical points of view. The theoretical aspects of the subject have been studied anew, since 1887, by Van't Hoff, of the University of Berlin, and by Arrhenius, a Swedish physicist, resulting in entirely new conceptions of electrolysis and its correlative sequences: anaphoresis and cataphoresis. The practical aspects of the subject have been even more comprehensively developed in the immense strides made in the manufacture of synthetic compounds and electrolytically separated chemicals in Germany and at Niagara Falls, at the latter place the current from the great power plant being utilized for the purpose.

The basis of the method employed in the ionic sterilization of diseased foci is the fact that the living tissues, particularly the highly cellular and vascular growths under consideration, are made up of various salts in organic combinations held in solution in water. The large proportion of water present is shown by the fact that, by weight, the soft parts are three-quarters water and but one-quarter solids.

Now, these newer facts of electro-chemistry teach us that when a salt is in solution in water it is, in a sense, no longer a salt as we know a salt in the dry state, but an ionized solution of the atoms of which it is composed. That is: that the molecules of chloride of sodium, for instance, are largely dissociated when in solution in water, the atoms of chlorine and sodium, as well as most of the component atoms of the water molecules themselves, being no longer simple atoms, but, by reason of possessing an electric charge, ions. The hydrogen of the water and the sodium of the NaCl possess a positive

charge, and hence tend to seek the negative pole if a current of electricity traverses the compound; they are therefore called cations. The oxygen of the water and the chlorine of the NaCl possess a negative charge, and are hence anions, or anode seekers. Whether a current of electricity is passing through such a solution or not, this dissociated or ionized condition of salts and most acids and bases exists whenever they are in solution in that great solvent, water, without which neither chemical action nor life itself could continue. Such solutions are known as electrolytes.

Water itself is but slightly dissociated or ionized unless it contains a trace at least of some one of these substances; therefore pure water will not conduct electricity, since it is the ions alone that conduct this force. As a side remark, it may be said here that watery solutions of many substances do not conduct electricity because these substances are not ionized by this solvent.*

To return to the question at issue: When a current is passed through the ionized or dissociated body of molecules constituting the basal constituents of a living growth, a powerful directing movement is given to the ions everywhere present, the oxygen, chlorine and other anions being impelled toward the anode (the active electrode, or electrode within the growth), where they give up their — charge, becoming simple atoms. These atoms, no longer in the condition of ions, attack the least refractory elements of opposite sign at hand, in this case the mercury and zinc of the electrode, or the mercury alone if it is held in place by a gold electrode, forming oxides and chlorides of the metals. These metals being now in solution in water and thus ionized, are but lightly held by the oxygen and chlorine, and being themselves charged with + electricity, become cations, seeking at once the negative pole on a distant portion of the body. The released oxygen and chlorine remain near the active electrode, forming water, hydroxyl and other compounds, while the mercury and zinc ions radiate outwards, uniting and dis-uniting in turn with the oxygen and chlorine of the tissues as they spread, destroying the vitality of cells and germs as they proceed, since zinc

* An instance of this is sugar, a solution of which in water will neither conduct nor be electrolyzed by an electric current, showing the low value of this substance in the life chemistry of the body.

and mercury in the ionized state are poisonous to protoplasm. As their progress is relatively slow they do not reach a great distance, betraying their course by a characteristic grayish white necrosis wherever sufficiently dense to do so.

The exact nature of the diffused salts has been determined by Gautier, of France, with reference to copper, which was found diffused as both oxides and chlorides when living animals were subjected to the process. That there is an abundance of combined oxygen for these purposes in the soft tissues of the cancer is shown when we remember that 72 per cent. of the body as a whole is composed of oxygen (Marshall).

Turning to the reactions simultaneously occurring at the negative pole, resting in good, moist contact with a distant portion of the body surface, it should be noted that an exactly equal amount of electro-chemical change occurs here, though of opposite sign, hence this electrode contact must be very large in order that the reactions, by being spread over a great surface, may not do more than stimulate the skin and underlying tissues. The cations that actually reach this electrode (during the moderate time that the process is employed) are the sodium, potassium and other bases of the nearby tissues, which, approaching the tin plate as cations, give up their charge and lose themselves as atoms of these bases in the abundant water of the large pad interposed between the tin plate and the body surface, the water itself being dissociated into oxygen and hydrogen. Of this dissociated water the oxygen is diffused inwards into the body as an anion while the hydrogen appears free as a gas. The only real accumulation of cations in the pad, of any moment, are therefore the free alkaline bases, and these do no harm to the skin if the pad is thick and sufficiently broad.

The interpolar tissues of the general body traversed by the current suffer no change, other than a general quickening of the chemical processes.

Recurring to the electrochemical changes at the site of ionic diffusion within the growth, the anodic region of the body electrolyte, it should be said that the nearer a given cell or germ lies to the electrode the denser will be the flow through it of the zinc-mercury ions, resulting in more certain destruction. In the actual conditions encountered in practice—the use of a third of an ampere to one ampere dur-

ing a time varying from a half-hour to one hour—the sterilizing cations never reach the relatively distant cathode on the patient's back. The most distant are probably but one or two inches (three to five centimeters) beyond the point where their density ceases to devitalize all the tissues (at which point the line of demarcation will develop several days later). It is in this wider circle of less dense diffusion that the purer effects of reaction without necrosis occur, the lowly constituted malignant cells being destroyed alone for probably a half cm. beyond the point of total destruction, while a portion at least of the normal cells are only subjected to a strong irritation.

The speed at which these mercury and zinc ions are made to traverse the tissues has not yet been accurately determined, but is dependent on the voltage of the current, the amount transferred being dependent on the amperage. Kohlrausch discovered that each ion has its own rate of motion in a given liquid, independently of what it may happen to have been combined with, hydrogen traveling faster than any other ion. Lodge* gives the subjoined table of the speed of ions of the substances mentioned when urged by a potential of one volt per lineal centimeter of electrolyte.

Table of Cataphoric Speed of Ions at One Volt per Centimeter.

Hydrogen	1.080	centimeters	per hour.
Potassium	0.205	centimeter	per hour.
Sodium	0.926	"	"
Lithium	0.946	"	"
Silver	0.166	"	"
Carbon	0.213	"	"
Iodine	0.216	"	"

The two substances in which we are most interested, mercury and zinc, are unfortunately not mentioned in this table, though all ions probably have a rate bearing some relation to their combining equivalents, as suggested by Prof. Dolbear in a conversation with the author. This question is one of great importance in the clinic room, and so far as concerns mercury, it may be roughly said that 5 grains (1-3 gram) of metallic mercury will be diffused one centimeter into the flesh

* "Modern Views of Electricity," Lodge, p. 87.

by a current of 50 milliamperes at 50 volts in ten minutes. By doubling the voltage the same current should transfer a similar amount of mercury twice the distance in the same time. If these figures are only approximately correct it will be seen that not only are currents of large volume required in this work, but they must be at a sufficient pressure and maintained long enough for the lethal material to reach the outlying portions of the growth, and particularly the branch-like prolongations. The completeness of the protoplasmic devitalization is due to the density of the current, it is true, but no matter how densely a strong current may diffuse the medicament, a sufficient time must be allowed for its due penetration, and the prompt devitalization of the affected cells in the more distant portions of the growth. This may be assisted at times by the use of more than one active electrode; in fact this should invariably be done in the larger growths, in order that the time in which the patient is kept under anesthesia be lessened, but it should not be forgotten that each additional active electrode will necessitate a corresponding increase in the current to keep the local action of each electrode up to a properly effective concentration. Two electrodes will require twice as much current as one, and three will require three times as much.

The use of too many electrodes, or of a broad, active surface pressed against an ulceration, has the disadvantage of either dividing up the current into ineffective portions, resulting in a lack of concentrated action, or of requiring more current than convenient to make each effective. The author's experience has shown also, that a moderate amount of the ions inserted beneath the surface, directly amongst the cells, by means of a puncturing electrode, is more effective than much more material diffused from a broad electrode placed against the surface.

EXPERIMENTAL DEMONSTRATION OF MERCURIC DIFFUSION WITHIN FLESH.—To demonstrate the diffusion of mercury ions within beef is both interesting and easy. The piece of beef should be of sufficient size, fresh, and preferably made up of muscular tissue or other non-fatty parts. It should be laid on a porcelain dish or other non-conducting surface, and a metallic instrument of any metal thrust into one end connected with the negative cord of the battery. The active electrode must be

of gold, well amalgamated with mercury, and after it is thrust into the opposite end of the beef an additional supply of mercury should be poured or dropped on it so that it will not become bared by the action of the current.

From five hundred to one thousand milliamperes should now be turned on from an appropriate source and maintained about fifteen minutes. The meat nearest the anode will be seen to change color at once, very much as in living flesh, the discoloration radiating in all directions from the electrode but mainly towards the opposite pole. When sufficient effect has been obtained the current is turned off and a longitudinal section of the meat is made, passing through the points at which the electrodes were inserted. The extent and effect of the diffused chemicals can then be easily traced, so far as these can be shown in dead flesh. The limits of the area of sterilization can be easily made out, shading off into unchanged surrounding flesh, but the zone of infiltration-reaction, as it would be in living tissues, can only be traced in part by the discoloration produced by the chemicals. To discern what would be its extent the following expedient may be employed: Remove the electrodes and cords from the battery and connect a pair of copper wires to the binding posts of the battery, the wires being bared and brightened at their ends. With the same amount of current turned fully on these wires (500 to 1000 ma.), their ends should be held about a centimeter apart and pressed into the beef for some moments at various points, beginning near the negative polar region and gradually working towards the positive polar region. As soon as a portion of the meat is reached holding the mercuric salts, even though in insufficient quantity to cause discoloration of the meat, there will be a deposit of metallic mercury on the *negative* copper wire, shown even in small quantity by the silver color of this wire compared with its fellow, and proving the extensive penetration of the chemical.

CHAPTER VI.

SELECTION AND INSTALLATION OF APPARATUS REQUIRED FOR IONIC SURGERY.

Source of Current.—Careful consideration must be given to the current source in the major operation of zinc-mercuric ionization, employing as it does from 300 to 1500 milliamperes, or even more, during a continuous application extending from fifteen minutes to an hour or more. All of the old-fashioned batteries were grievous failures in the author's earlier work, the most painstaking care being insufficient to prevent faults and failures even after a patient was under the anesthetic. The current mains of an incandescent lighting system are the best possible source of power for this work, and if the system is one employing the 110 volt direct current a suitable controller and meter are the only applying apparatus needed.

If the street mains at hand furnish the alternating current, as is generally the case in the smaller towns and cities, it will be necessary to procure also a motor transformer to transform the alternating current into the direct current of the voltage mentioned.

Should neither form of current be available, as in towns without an electric lighting system or at isolated residences, ample power may be obtained from 40 to 60 freshly manufactured dry cells of approved make, and these may often be depended on to do full work for several months.

Direct Current Mains.—Having a direct current supply of 110 volts which is steady and reliable during the hours for this work, the current may be taken from any lamp receptacle by substituting a plug to which is attached a double conducting cord leading to the controller. At the first use of any particular receptacle or socket the polarity of the conducting cords should be ascertained as follows: Before inserting the plug into the socket unwind two or three inches (5 or 6 centimeters) of the end of the cord, bare the end of each wire, and bend them apart so that they will not come into accidental contact;

now insert the plug into the receptacle and turn on the current if there be a key for this purpose, then insert both wire ends in water in which a little salt has been dissolved. The active decomposition of the water that results at once will show that one wire gives off twice as much gas as the other; this wire is therefore of course the negative pole, and should be so marked as soon as the current is turned off, a bit of




FIG. 2.—Motor-Transformer of Holtzer-Cabot Type, suitable for ionic surgery and other electrotherapeutic work.

adhesive plaster with an N marked on it in ink being a permanent mark when twisted about the wire. The polarity of these wires should be tested anew whenever a new receptacle is used.

Having ascertained and marked the polarity of each wire, they are inserted in the P and N inlet posts of the special controller described below, or into the appropriate inlet posts of the ionization table. The wires should be left permanently attached to the latter, disconnection being made by removing the plug from the receptacle.

Alternating Current Mains.—To transform the alternating current to the 110 volt direct current a motor transformer is employed. This consists of a one-half horsepower alternating current motor, suitable to the phase and number of alternations of the local system, and a $2\frac{1}{2}$ ampere 110 volt direct current

dynamo coupled directly together and mounted on the same base (Fig. 2). A snap switch in the leads from the mains enables the apparatus to be started and stopped with ease. The dynamo is usually supplied with a rheostat placed in circuit with the field winding. This enables us to vary the voltage of the output somewhat, and is a useful auxiliary to the therapeutic controller. In the Holtzer-Cabot apparatus the

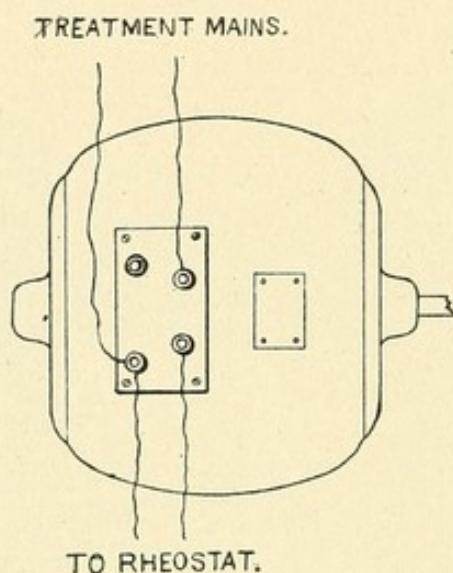


FIG. 3.—Diagram of Connections on Dynamo Portion of Motor-Transformer, to show proper connections.

current for treatment is taken from the dynamo at the poles indicated in the diagram, Fig. 3, and the polarity is ascertained in the manner described in the paragraph relating to the direct current.

The current as taken from the dynamo is exactly similar to that from the 110 volt direct current street mains. It is, however, unnecessary to have a dynamo give an output greater than two and a half amperes (2500 milliamperes), as this size of dynamo will fully cover the needs of ionization work.

Dry Cells.—As before stated, a battery of freshly manufactured commercial dry cells of ordinary size and reliable make furnishes a possible means of power for the performance of a number of major operations. From 40 to 60 are necessary, and if these are assembled in portable boxes of strong build we are enabled to perform major operations at any point within reach of the railroads or other means of transportation, the applying mechanism described below being also portable. The author has traveled thousands of miles with such an out-

fit, keeping a sharp eye on the battery boxes at every change of baggage car, the apparatus being ready for action within a few minutes of its arrival at the residence of the patient or the local hospital. These battery boxes may be supplied with a switchboard as in Fig. 4, or with two simple binding posts

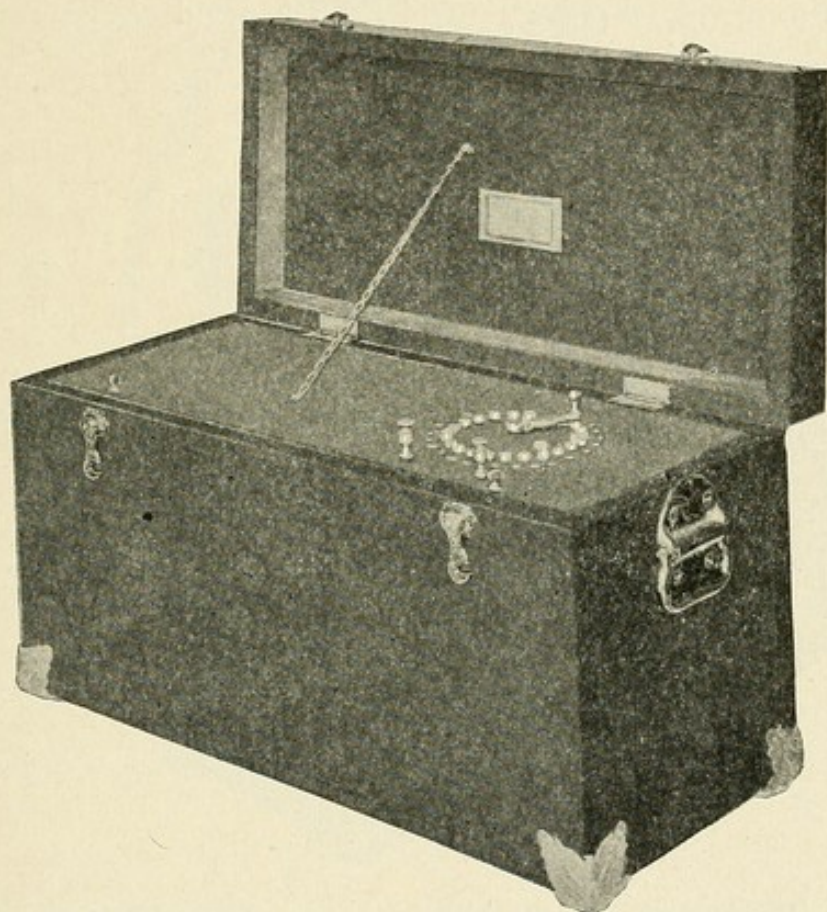


FIG. 4.—Portable Dry Cell Battery with Switchboard.

to each box, to one of which a wire is led from the carbon pole to the first cell. From the zinc pole of this cell a wire is led to the carbon pole of the next, and so on, the final zinc pole being connected with the other binding post of the battery box. The binding posts of the box should now be each marked with their appropriate signs.

When the batteries are to be used the N post of the first box is connected by wire with the P post of the second; the N post of the first box and the P post of the second then being the final poles of the battery. From these posts wires are carried to the controller as described for the direct current of the street mains.

An automobilist's pocket ammeter is useful to detect any

weakening of these cells. The voltage is maintained in these cells near the 1.4 volts per cell longer than the amperage, which should not fall below 8 or 10 amperes when short-circuited through these small ammeters. If any cell falls below 5 amperes it should be thrown out before an operation is attempted.

No other form of primary cell than a good commercial dry

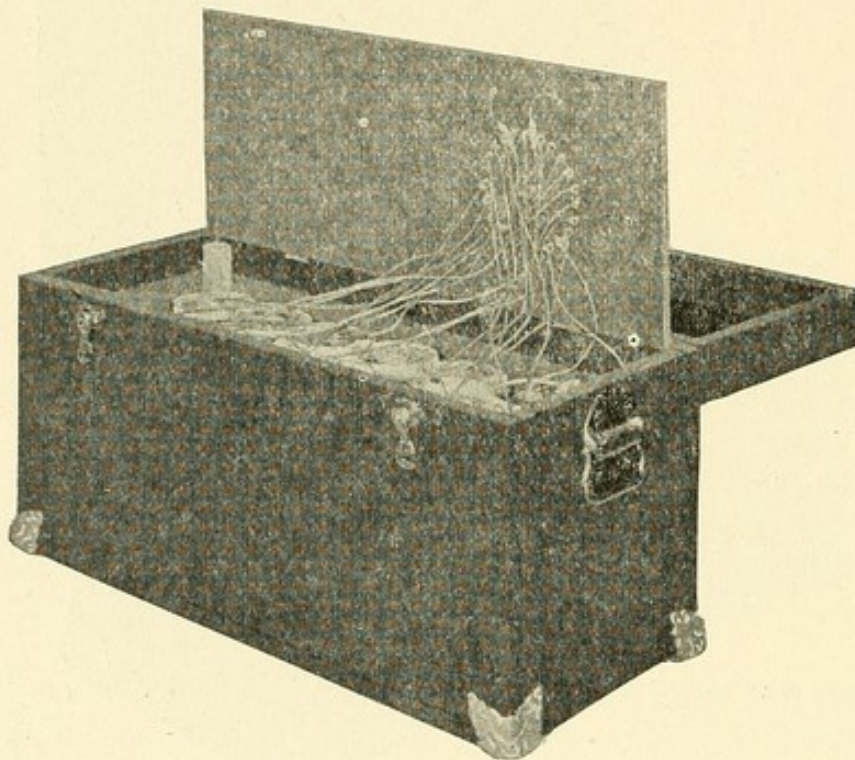


FIG. 5.—Portable Dry Cell Battery with Switchboard Raised, showing connections.

cell should be used for this purpose. Storage cells would, of course, be an excellent source of power, but the large number of these heavy cells needed to obtain the voltage required makes it impossible to employ this source of current in a portable apparatus.

Control of Current.—Cataphoric diffusion of ionized substances is accomplished by the continuous flow of a direct current of sufficient volume, even in the heaviest major applications, and there is therefore no need and no excuse for shocks due to rapid variation of the current. All sudden variations or interruptions of the current are to be carefully guarded against. The only certain way to avoid shocks is the use of an efficient graphite controller of the type long known as the

Massey graphite controller. The standard instruments of this type are, however, too small to control currents over 250 milliamperes in strength. For currents over 250 milliamperes we must employ the enlarged Universal Graphite Controller first described in a recent edition of a work by the author.*

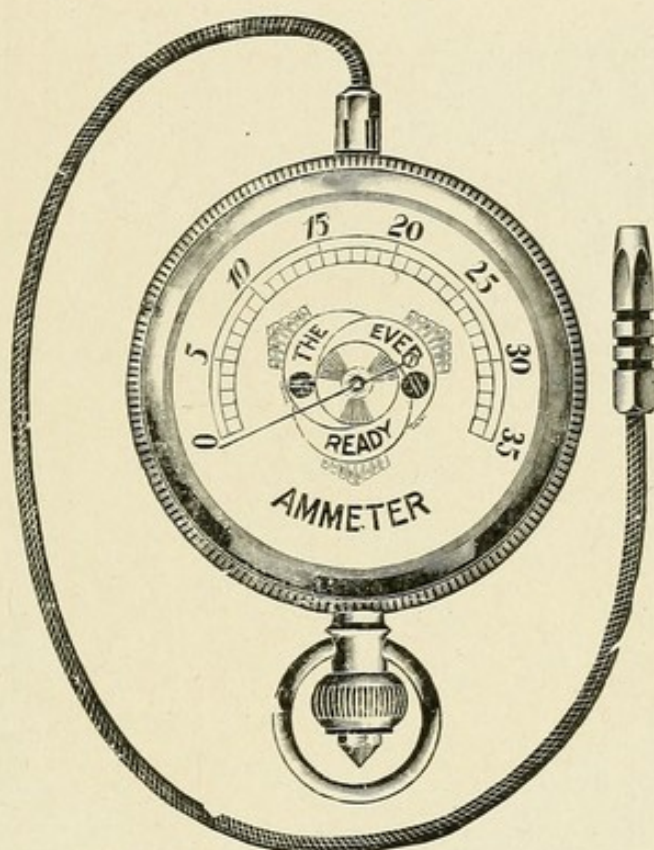


FIG. 6.—Pocket Ammeter.

This instrument (Fig. 7) is manufactured by Williams, Brown & Earle of Philadelphia, and the Frank S. Betz Co. of Hammond, Ind. It will permit a current to be turned on in the most gradual manner from zero to 2000 milliamperes, and is therefore not only necessary in the work under consideration but fills all the purposes of a controller for lesser currents, both constant and induced, in ordinary office practice. It is somewhat unwieldy as a portable instrument, but can be readily transported when supplied by the manufacturer with a suitable case.

This latest and most perfect graphite controller has been made much larger than the standard instruments of the last ten years to adapt it for the control of the heavy currents of

* "Conservative Gynecology and Electro-Therapeutics," by G. Betton Massey, M.D., Sixth Edition, F. A. Davis Co., Philadelphia, Pa., 1909. The author is now experimenting with wire controllers.

a major ionic application, yet if the graphite coating at the "start" is sufficiently light the initial increase of the current as it is turned on is quite gradual.

A further development of this instrument, made possible by its ample size, is such an arrangement of the circuits traversing

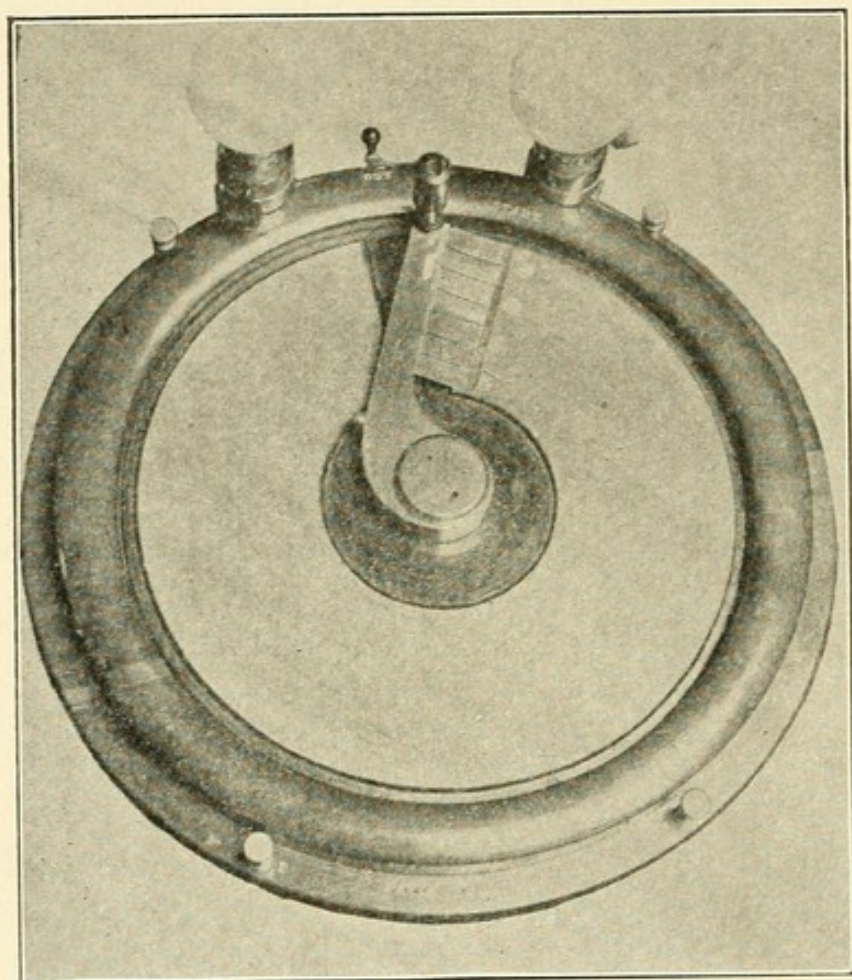


FIG. 7.—Massey Universal Graphite Controller. The lamp to the left is the series resistance lamp; that to the right, the shunt lamp. Both lamps should be used in minor applications. In major operations both are cut out, or turned off.

it as will transform it at the will of the operator into a more delicate controller of weak currents than even the small controllers. This is done by cutting down the amperage delivered to it from the mains by inserting a *series lamp* (see Figs. 8 and 9) between the controller and the mains, and a *shunt lamp* (also shown in Figs. 8 and 9) parallel with the patient, but not in the meter circuit. The result of placing this shunt lamp parallel with the patient is the division of the current delivered

by the controller between the lamp and the patient, and as even a 16 candlepower lamp presents far less resistance than the tissues of the patient, under the usual circumstances, the bulk of the current traverses the lamp and a lesser amount the

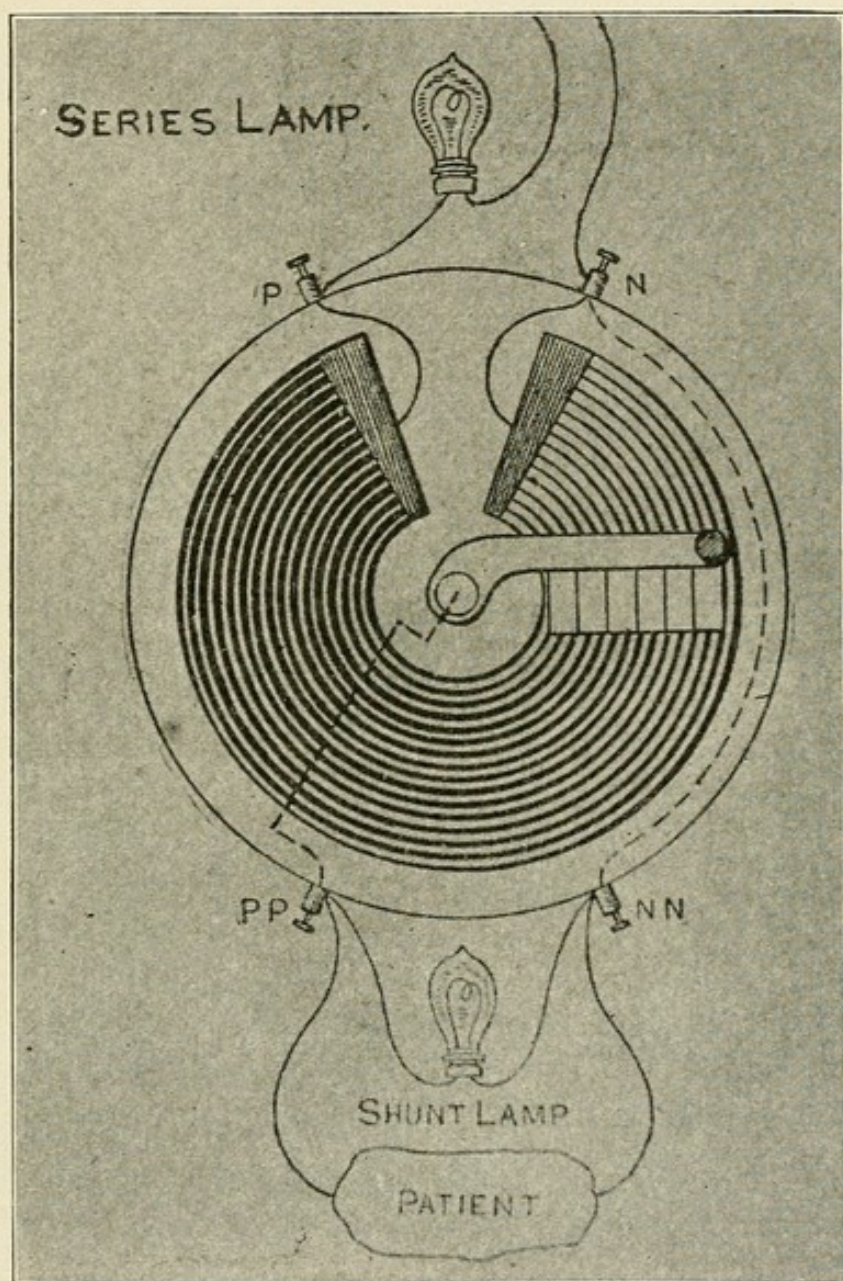


FIG. 8.—Plan of wiring of Universal Therapeutic Controller.

patient, thus permitting of a most delicate graduation of a minor current and its most gradual "turn on," thus minimizing pain.

A necessary result of this division of current between two paths is the division of the voltage equitably between them. The use of such a shunt constitutes the instrument therefore

a *volt controller* as well as a milliamperere controller. It is well known that a control of voltage is most desirable when making minor applications in painful situations—that 2 milliamperes, for instance, is less painful from 4 volts than from the whole voltage of the 110 volt circuit.

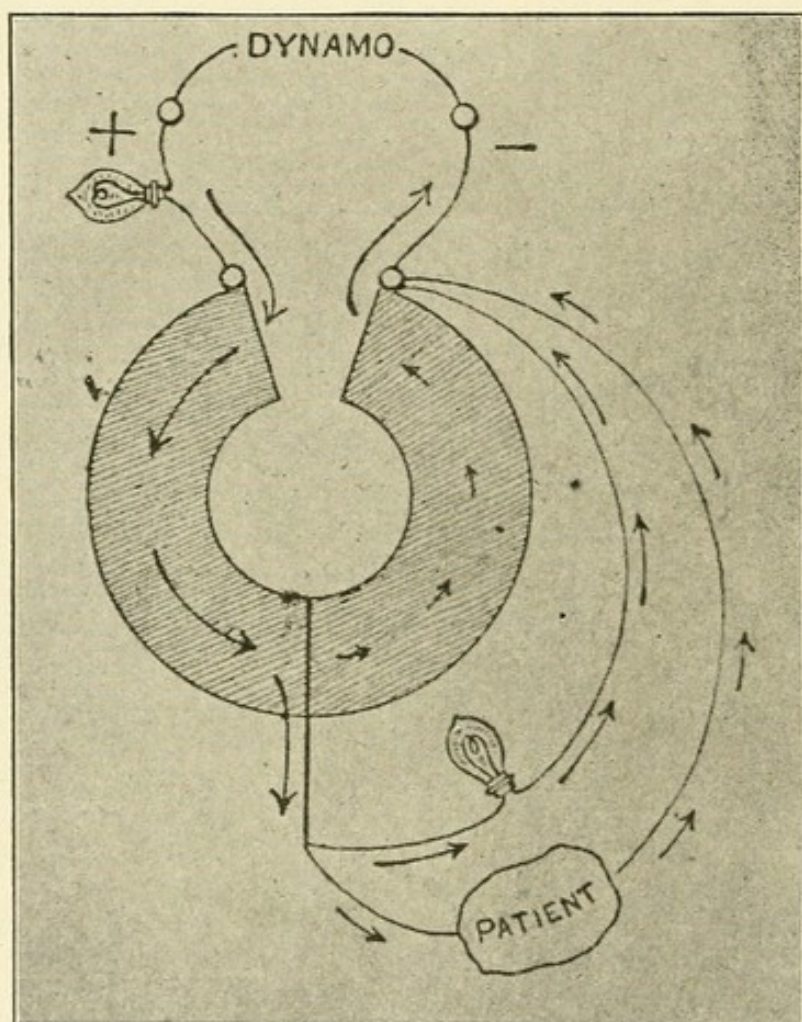


FIG. 9.—Diagram of several paths or "shunts" of the circuit of Universal Graphite Controller. The size of the arrows shows approximately the relative proportions of the current in the several paths, though this varies with kind of application. (The cut should show the meter in the "patient" shunt.)

Besides filling the absolute necessities of a controller for heavy currents, it will therefore be seen that this instrument has valuable qualities as a general controller of therapeutic currents, and especially the more delicate applications of ionization to painful localities.

This controller is adapted to be used with a battery of dry cells exactly as with the current of the mains. By throwing

a portion of the work on all the cells equally it conserves their life and causes equality of wear, as compared with the old-fashioned cell collector, while its gradual variation of the current makes it as essential when employing cells as when using the mains. To use the shunt lamp with cells is nevertheless

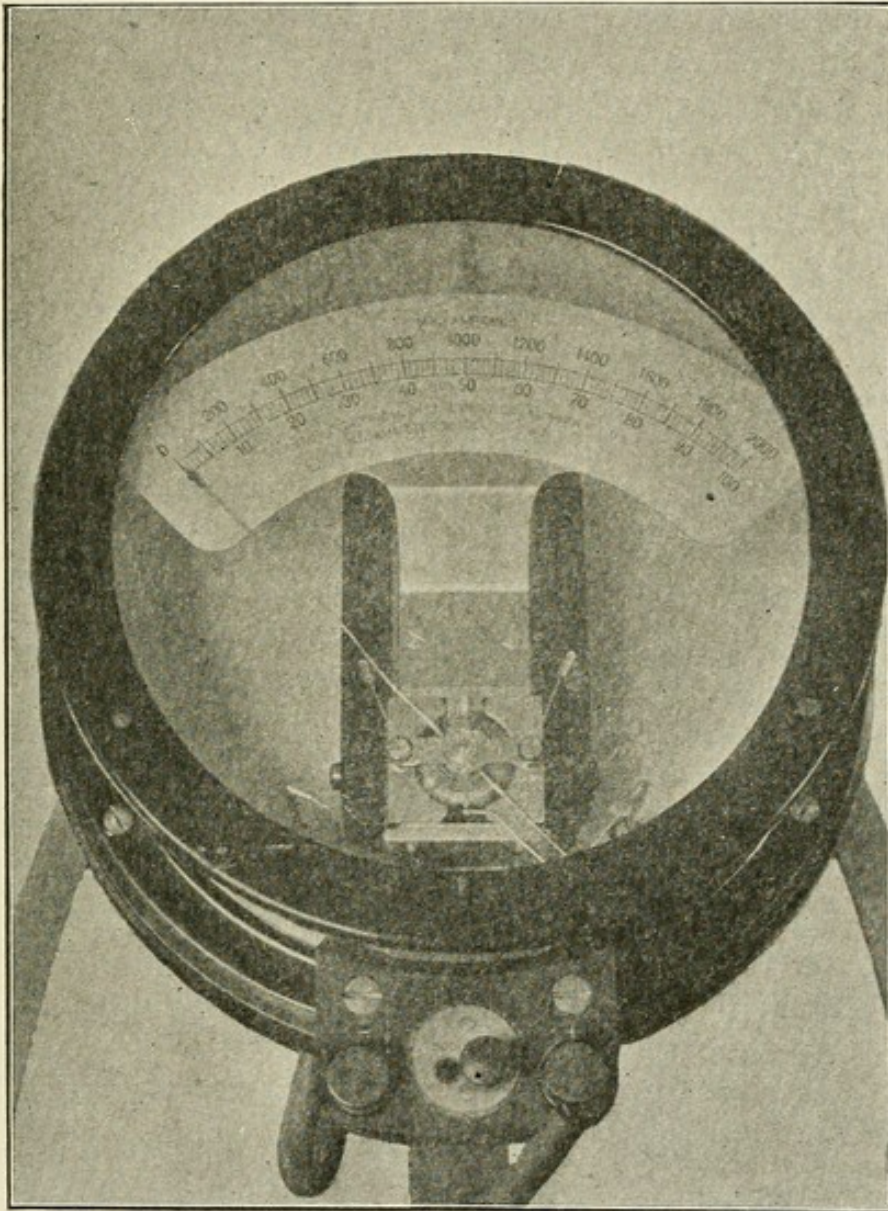


FIG. 10.—Massey Type Weston Milliampere Meter. The divisions of the scale may be seen some yards from instrument, and extend, on the two scales, from 0 to 100 and 0 to 2000 milliamperes, being capable of being read to 1-2 milliampere. To select scale place plug in appropriate socket shown in lower portion of cut.

a severe strain on their lasting qualities. When not in use this controller should always be cut off from the cells by opening a double knife switch.

In using this instrument with the 110 volt current the following variations are possible, giving great range to its capabilities for heavy or fine work:

1. *With both lamps turned off, or "out" of circuit*, it is adapted to control the full 110 volts by mere variation of resistance to produce currents varying from 0 to 2000 milliamperes. This adapts it to heavy current work, and also for the control of induction currents.

2. *With the series lamp*, which is usually placed at the left, turned "in" and the shunt lamp turned "out" of circuit, the apparatus is more safely placed in the hands of inexperienced persons, as the amount of current delivered through it by accidental short circuit is limited by the resistance of the lamp. This amount may be varied by using a 16 C. P. lamp for lesser currents and a 32 or 50 C. P. lamp for greater currents. The use of this series lamp adapts the controller particularly for the delivery of gynecological currents from the mains, with a range of variation from 0 to 250 milliamperes. The series lamp should not be used when employing a battery of dry cells, or with the induced currents.

3. *With both the series and shunt lamps turned "in" circuit* it is adapted to control the voltage as well as milliamperage, giving a less painful current for the finer work, such as minor applications of zinc-mercury ionization and electrolysis, epilation, etc., and with the lamps in this position the controller will light 4 and 6 volt lamps safely from the 110 volt current.

Measurement of Current.—The development of heavy current work in the ionic treatment of cancer made the use of a meter of higher range than usual imperative. That such a meter should be reliable was also absolutely essential, particularly when investigation revealed a most disgraceful lack of reliability among the meters sold to physicians.

As a result, the author employed at first a specially ordered portable Weston meter, with two scales:—0 to 1000 milliamperes and 0 to 2000 milliamperes. This instrument, while reliable, has still been under the disadvantage of having to be specially ordered when wanted. Further experience showed, also, that the scale and index of this portable instrument were too small to be easily seen by the operator standing or sitting several yards away, and that the lower scale was not high enough for minor ionic work.




FIG. 11.—Ionization Table, an aseptic, movable mounting of the Author's Controller and Meter, with multiple-attachment binding post for the active electrodes. Designed for both major and minor applications.

The Weston Electrical Instrument Co. of Waverly Park, N. J., was therefore induced to construct and place on the market at a moderate price, an instrument designed by the author to meet these objections (shown in Fig. 10). This meter can be confidently recommended as specially adapted to both major and minor ionization applications. As its improved features are equally valuable in other applications of the constant current, this meter should be preferred to other styles in stationary apparatus of all kinds, such as the Ionization Table, Wall Plates and Cabinets, and may be specially arranged for portability, if desired, though somewhat large for this purpose.

The scales of this meter are about seven inches long, giving great range, and the index may be seen across the room. In spite of this large size of the index, however, currents on the lower scale, which reads from 0 to 100 in single milliamperes, may be read to one-half milliampere, and the increase to the maximum is most gradual. On the upper scale, which reads from 0 to 2000 milliamperes, each division of the scale has the value of 20 milliamperes, but considerable space is allotted to each hundred, permitting the turning on of a heavy current to be quite gradual.

The Ionization Table.—The desirability of having all the furniture in a modern operating room aseptic, simple, and free from wood or other absorbent material, induced the author to design the current applying table shown in Fig. 11, for use in the electrical operating room of the Oncologic Hospital.

The table is constructed of white enameled iron and has a top of extra heavy glass with an ordinary glass shelf beneath. On the top plate a Universal Controller is mounted directly on the glass, with all connections beneath. In front of the controller there is ample space for the glass tray containing the mercury, acid, and water glasses, the active electrodes, etc. The meter is mounted on a brass arm fixed at an angle above the controller, and capable of being seen by the operator at any position. The two binding posts are on the front of the table, mounted on the glass plate, and a special feature is that the two poles are permanently designated by differently-appearing posts, the positive having five binding screws for attachment of as many wires leading to active electrodes, and the negative two binding screws for attachment of

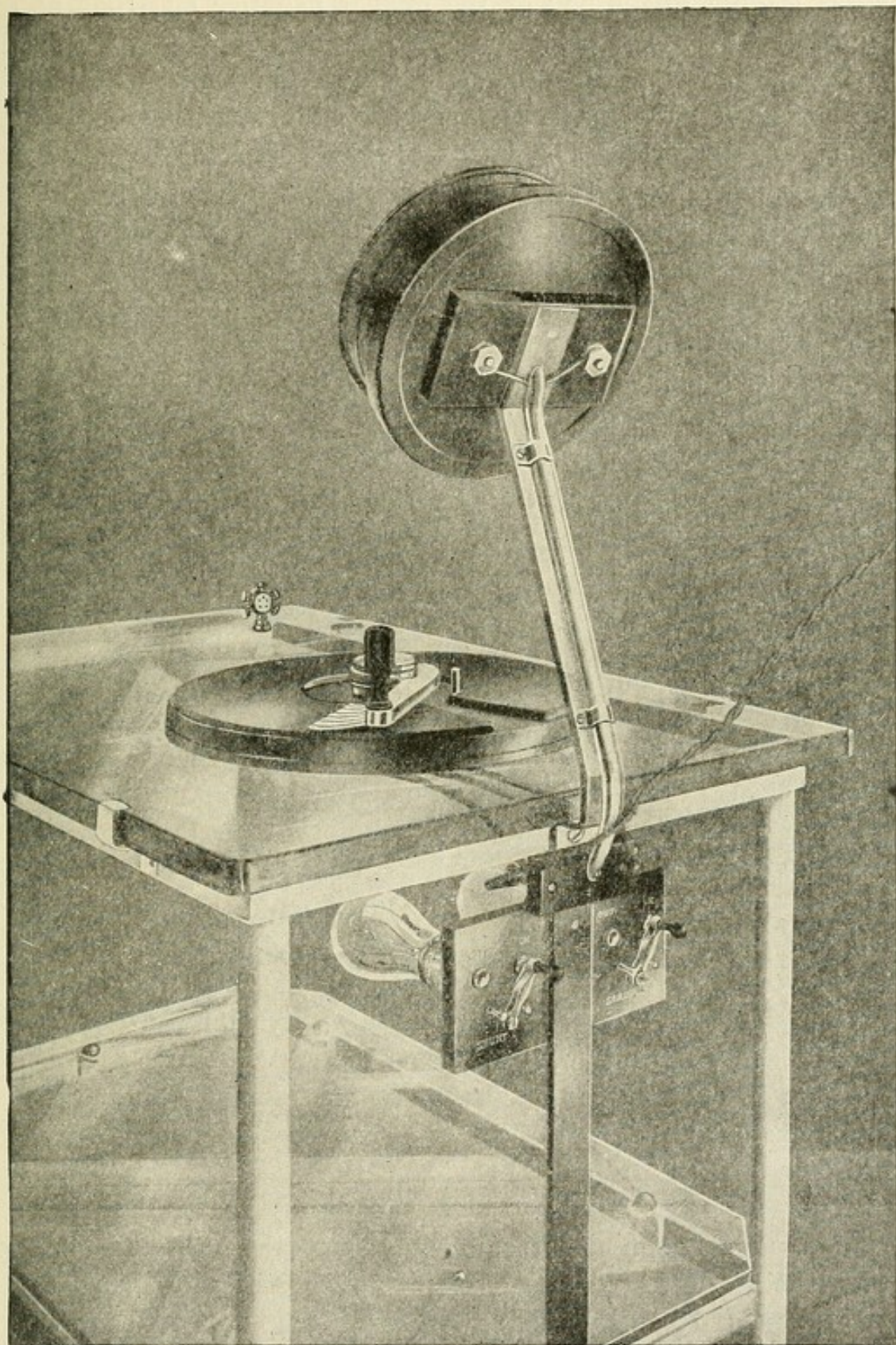


FIG. 12.—Rear view of Ionization Table, showing switches for using series and shunt lamps in minor applications.

wires leading to the pad or the bipolar negative electrode at will.

Fig. 12 shows a rear view of the Ionization Table, with the fiber plate, on the inner side of which the series and shunt lamps are attached. The lamps project under the top plate of the table well out of the way, while the switches for throwing them "in" or "out" are accessible from the rear of the table. Just above this switchboard are the inlet binding posts of the table, to which the cords from a lamp socket or battery of cells are attached.

With both lamp switches turned to "in," and the plug beneath the meter in the "100" socket, the apparatus is ready for minor applications. With both switches turned to "out" and the plug in the "2000" socket, it is ready for a major application.

The table may be used with the direct current of the mains, the transformed direct current from alternating current mains, or with a battery of cells. It is furnished by Williams, Brown & Earle, Philadelphia.

The Indifferent Pole Dispersing Pad.—The indifferent or dispersing pole in a cataphoric operation or application is of course always connected with the negative pole of the apparatus, and when the application is a minor one it may consist of any good dispersing pad, such as those suitable in electrogynecology. For the heavy current of a major monopolar operation a much larger dispersing pad is required to render this pole free from more local action than a mere reddening of the skin. If this pad be too small, or so improperly arranged as to permit unequal dispersion of the current over the skin surface, alkaline eschars will form in the skin at this situation that are slow to heal and give the patient much discomfort.

After experiment with various materials the author has settled upon kaolin pads as in every way the best, this material being preferred as possessing the qualities of fine pulverization and neutral chemical reaction that best adapt it to physically absorb the alkaline chemicals that appear at this pole, as well as freedom from the possibility of staining white clothing. The intimate contact secured by all clay electrodes with the minute inequalities of the skin, thus broadening the area of practical contact between the skin and the electrode,

is of course the chief value of this form of electrode. Kaolin is at present largely employed medically as the base of glycerine-bearing poultices.*

For convenience of handling, the kaolin is inclosed in flat bags made of crash toweling, and two such pads are usually




FIG. 13.—Kaolin Pads of various sizes, for use as Dispersing Electrode. The thin metal plate is shown on one.

required in the heaviest operations. Each pad, when filled properly with kaolin, should measure about 14 by 20 inches (35 by 50 centimeters), and possess a uniform thickness of one inch ($2\frac{1}{2}$ cm.). An additional pad of oval shape with extreme diameters of 8 by 12 inches (15 by 30 cm.), and of the same thickness, is a most useful size for minor applications as well as for gynecological applications.

In making these pads the material is cut somewhat larger than necessary and is securely stitched on the wrong side, leaving an opening in one end through which the kaolin powder may be subsequently poured, and is then turned and stitched around the edge, making what is called a "French"

* Kaolin may be obtained in suitable quantities from Wm. M. Wilson's Sons, 225 Dock St., Philadelphia.

seam. The dry kaolin is then poured in and carefully distributed with a flat roller until the bag is evenly filled about an inch ($2\frac{1}{2}$ cm.) thick. The opening is then securely sewn up. Before wetting the pad the upper and lower surfaces should be tacked together at points about two inches apart by




FIG. 14.—Copper Sterilizer with perforated Inner Movable Bottom, designed for keeping the kaolin pads warm, moist, and clean. Length 20 inches, width 14 inches, depth 7 inches.

passing the needle through and through, for the purpose of keeping the pad of a uniform thickness throughout.

The completed pads are kept permanently immersed in water in a copper sterilizer of proper size possessing a perforated copper tray supported on short legs, permitting circulation of water beneath the pads (Fig. 14). Before use the sterilizer is placed on a gas, electric, or other heater and warmed to a proper temperature. If the water within the sterilizer is occasionally brought to the boiling point the pads are kept fresh and clean.

Pads thus made and kept continually wet are always soft and pliant, and the heaviest currents may be passed through them for long periods without harm to the skin. One of the large pads with its metal backing is sufficient for 500 to 600 milliamperes when applied to a broad skin surface, such as that of the back, but if a stronger current is to be applied for a long period both pads should be used, placed sidewise, and the wires connected with the metal plates should be carried together to the negative binding post of the apparatus.

Beneath the pad, furthest from the skin, a metal plate is placed. This plate is best made of thin alloy, such as is now largely employed as a protection in x-ray applications. The metal plate should be absolutely pliant and smooth, about two




PLATE I.—Pope-Massey Special Wall Plate, with Weston Meter. This apparatus can be employed in major and minor ionic applications. (Frank S. Betz Co.)

inches (5 cm.) less in both diameters than the pad, and should be connected with the negative binding post by a sufficient length of No. 26 copper wire, the wire being attached to the plate by threading it, duly bared, through some holes in the corner of the plate, and wrapping the plate over it several times. Care should be observed to cover this connection between the wire and plate with a small piece of rubber cloth before laying the pad upon it, as otherwise the current may short-circuit from the thinly covered wire through this portion of the pad directly to the patient.

The detailed method of placing this pad for an operation will be found in the next chapter.

The Active Electrodes.—In the development of the ionization treatment of cancer the author was accidentally led to employ zinc coated with mercury as the material for the soluble electrodes. It was later found that pure mercury could be diffused as an ion from electrodes of pure, or 18 karat, gold, the mercury being temporarily united with the gold by amalgamation, and that with heavy currents the mercury would disappear so rapidly from the gold instrument that provision had to be made for an extra supply by injecting it into the tissues in immediate contact with the instrument through a tunnel in the latter. The gold was never acted upon itself by the current, and when the supply of mercury and the alloys in the gold were diffused it remained as an unattackable electrode.

Comparative tests of pure mercuric ionization from these gold electrodes and of the mixed zinc-and-mercury ionization from pointed zinc instruments showed later, nevertheless, that the latter were more effective in necrosing results and equally good in sterilization. The pointed zinc instrument merely coated with mercury was also a more controllable instrument than the pointed cannulas of gold, which required the presence of additional liquid mercury, the latter being kept in the place desired only with much difficulty at times. The result has been that the zinc-mercury instruments are exclusively employed at present.*

Minor Application Electrodes.—The minor electrodes,

* For a description and illustration of the gold-mercury electrodes see the author's work "Conservative Gynecology and Electro-Therapeutics," Sixth edition, F. A. Davis Co., Philadelphia, 1909, p. 218.

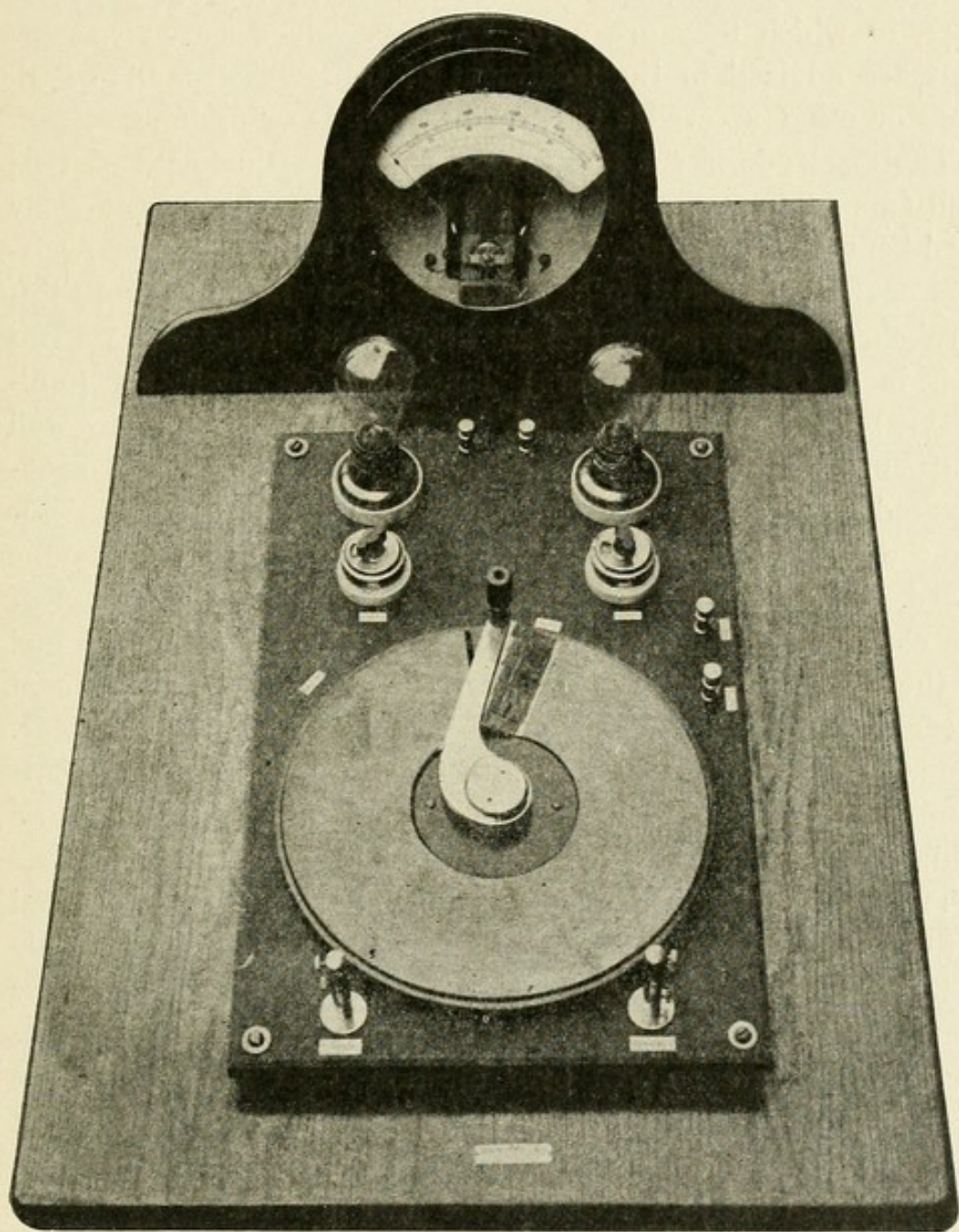


PLATE II.—Author's Ionic Switchboard with author's type of Meter,
as made by Williams, Brown & Earle of Philadelphia.

shown in the upper portion of Fig. 15, are furnished in sample only by the manufacturers, as they are readily made by the surgeon or an assistant, and the shape and length are largely determined by the particular case, or even the stage of the case, in which they are used. These electrodes are also those that are advised in the treatment of tubercular glands of the neck or other accessible tubercular cavities or nodules.

The electrode is cut from sheet zinc of a thickness of 1-64 inch (approximately $\frac{1}{2}$ millimeter), being the thickness largely used beneath stoves, etc. A long-handled pair of surgical scissors enables the metal to be cut easily into slivers, though tinners' shears of superior steel are better, the slivers being about $1\frac{3}{4}$ inch ($4\frac{1}{2}$ centimeters) long and $\frac{1}{8}$ inch (4 millimeters) wide at the butt end, tapering to a fine point, well sharpened by filing. A suitable length of No. 32 cotton-covered copper wire is then prepared to act as the conductor for the current by baring a short portion at each end. One bared end of this wire is wrapped tightly about the butt of the electrode and clamped firmly in place by turning the end of the electrode over it with a pair of pliers. The instrument is then complete as an uninsulated, or No. 1, minor electrode. Immediately before insertion into the growth the active tip is amalgamated by dipping it for an instant in weak sulphuric acid, into metallic mercury, and into plain water, in turn.

The No. 2 minor electrode is a similar instrument coated with insulating wax except at its tip. This is done by gently heating it over a Bunsen burner or alcohol lamp and at the same time melting the end of a stick of sealing-wax and fusing the latter in an even coat over the non-active portions of the electrode. The result is an exceedingly delicate instrument for applications beneath non-diseased edges and in cavities, the insulation limiting action to the part desired.

The fine wire advised as a conductor of the current is selected for mechanical reasons, such as the dragging weight of a heavy wire on the electrode, the instrument itself being too light for the heavier conductor. Its conducting power is more than ample for any currents capable of being employed with these electrodes. A further precaution to insure against the added pain caused by any motion of the instrument from accidental movements of the patient is the expedient of applying a steadying guy to the wire near its attachment to the elec-

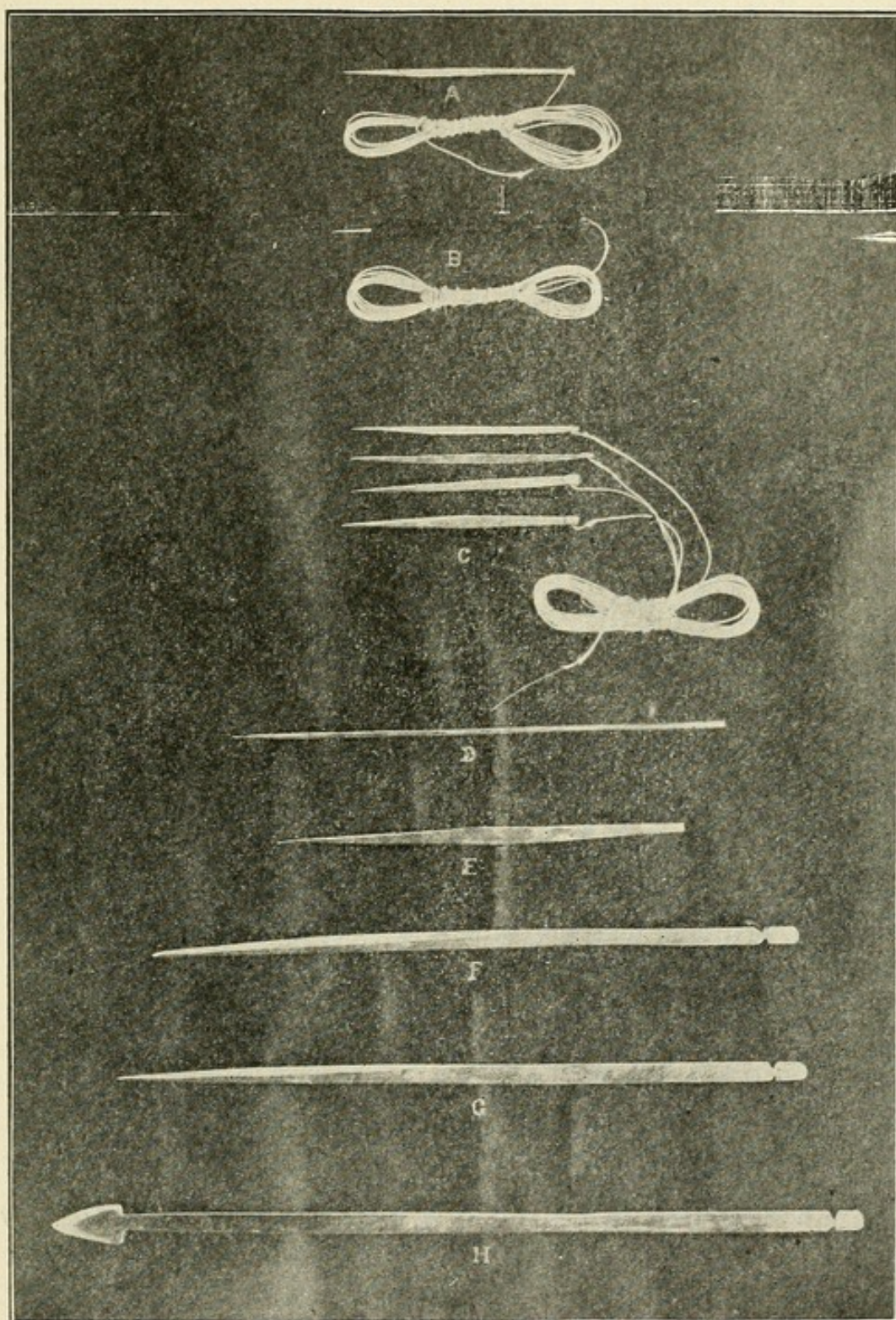


FIG. 15.—Author's Zinc-Mercury Cancer Electrodes (one-half natural size). A. No. 1, Minor electrode. B. No. 2, Minor electrode. C. Leash of medium-size external electrodes. D. Minor mouth, uterine or rectal electrode, uninsulated. E. Major breast or external electrode. F. and G. Major mouth, uterine, or rectal electrodes. H. Spade-pointed major uterine or rectal electrode. (Procurable of Williams, Brown & Earle, Philadelphia.)

trode; this is done by attaching a small piece of adhesive plaster to the wire near the electrode, and sticking the ends of the plaster to the skin of the patient in such a way that the wire will not touch the skin. This arrangement will permit the patient to move at will during a prolonged application without disarranging the electrode.

These electrodes may be employed as *multiple points* in a major application when a large surface of moderate depth is to be sterilized. For this purpose a leash of conductors is prepared by cutting from four to a dozen short lengths of No. 32 or 30 wire and attaching their bared ends to the bared end of a longer length of No. 26 wire, which is attached at its other end to the positive binding post. The point of junction of these wires, after being tightly twisted, is carefully insulated by covering it with a small piece of adhesive plaster. A dozen such points can stand a current of 20 milliamperes per point, or a total of, say, 250 milliamperes, during a prolonged application, thus conserving time in the treatment of a broad surface growth.

The instruments described above, and the smaller ones of those described below, should be used once only, and then discarded as too brittle for further work.

External or Breast Electrodes.—With the exception of the minor electrodes just described, the remaining zinc-mercury electrodes are primarily intended for the major application, though the smallest external size may at times be advantageously used in a minor one. These electrodes are made from either 1-32 inch (1 millimeter) plate zinc, in which case they may be cut by the surgeon or his assistant by means of a pair of tinner's shears, and attached to No. 28 wire in the same way as mentioned for the minor electrode; or they may be made of still heavier zinc 1-16 inch (1½ millimeters) thick; in the latter case being procured from the manufacturers or other artisan, and being attached to No. 28 conducting wires by the latter being wound tightly about a neck filed near the butt of the electrode. In width these electrodes vary from 3-16 inch (4 millimeters) to a fine point, and in length from 3 to 5 inches (8 to 12 centimeters). It is at times useful to cover the butt end of these electrodes with fused sealing-wax to protect the wire joint from the action of the mercury, which would make the wire brittle.

This makes a convenient handle also. No. 28 wire is the most suitable size for the shorter lengths of this weight of electrode. Each electrode is usually attached to a single conducting wire, or, when a large growth is to be attacked, from two to six of the same length may be attached to a leash of wires as described in the last paragraph. They should be bent to the curve desired, if a curved instrument is needed, before amalgamation.




FIG. 16.—Major Uterine Electrode, insulated.

Mouth and Throat Electrodes.—The longer lengths of the electrodes just described are also suitable for use in cavities, not deeply situated, if the fused wax insulation is carried over the whole instrument except the centimeter or centimeter and a half at the active point. Any shape desired may be given the instrument before insulating it, whether curved on the flat or edge, the latter shape being suggested by Dr. Amédée Granger of New Orleans, who points out that sharply pointed instruments have the advantage in mouth operations of being self-sustaining when properly curved. Attachment to the conductor may be made by a spring socket, as in Fig. 16, or, as more recently preferred by the writer, by a suitable length of No. 28 wire attached tightly to the butt by wrapping and twisting.

Cervical and Rectal Electrodes.—A minor application may be made to the cervix uteri of as much as a hundred milliamperes by the use of an electrode similar to those advised for the mouth and throat, though somewhat longer, made of the middle thickness of zinc described above and properly insulated.

In a major application to the same parts the active tip must be made larger owing to the tendency to overheating when a heavy current is confined to a small area of active surface, hence the selection of the pointed, spade-shaped electrode shown in the cuts when but one instrument can be used at a

time. Like all the instruments, it may be bent at any angle desired before amalgamation.

Insulation of Electrodes.—All active electrodes employed within cavities should have those portions of their surfaces which are intended to be non-active coated with an insulating material. This confines the whole effect to the spot designed to be destructively sterilized and protects non-diseased surfaces from useless and painful erosion. The ability to thus carry the action to any spot desired within a cavity, or, indeed, beneath any tissue safely penetrable by an electrode, is one of the chief advantages of the ionization method. This insulation is best accomplished in all electrodes not injured by heat by the employment of sealing-wax, a non-conducting material when free from metal coloring, but particularly in the instruments under consideration, as the act of properly coating the heated shank or non-active parts with hot wax not only secures perfect insulation but perfect asepsis also. When so prepared an instrument capable of use more than once is rendered perfectly fresh and new for a second application. This aseptic coating is, moreover, more convenient in practice than tube coverings or other methods of permanent insulation, as it presents no shoulder to catch in the tissues, the melted wax shading off in thickness at this point.

Black sealing wax (Dennison's No. 4 Black Express wax being an excellent variety) presents a seemly appearance, and is readily obtained at most stationery stores in convenient and inexpensive sticks when procured in pound lots.

To apply the wax, heat the electrode over the flame of a Bunsen burner or alcohol lamp—very gently if a minor electrode is to be coated, as zinc readily burns—and when it is hot, melt the end of the stick of wax in the flame and bring the surfaces together: a small portion of hot wax will adhere to the instrument. Apply other portions similarly to various surfaces and edges, and gently reheat the electrode until the coating is even, smooth, and complete. It is often necessary to retouch the shank of the instrument in order to cover the sharp edges which the hot wax is liable to leave. A little practice soon leads to expertness, and one can readily coat a long and slender instrument, such as required in the nostril, for instance, with great ease.

An instrument capable of being used more than once re-

quires a fresh insulation, which also asepticizes it before being used on a second case. All necessary changes in curve should be given the electrode before insulation.

Amalgamation.—The amalgamation of an electrode is the union of metallic mercury with it at its active surface. The

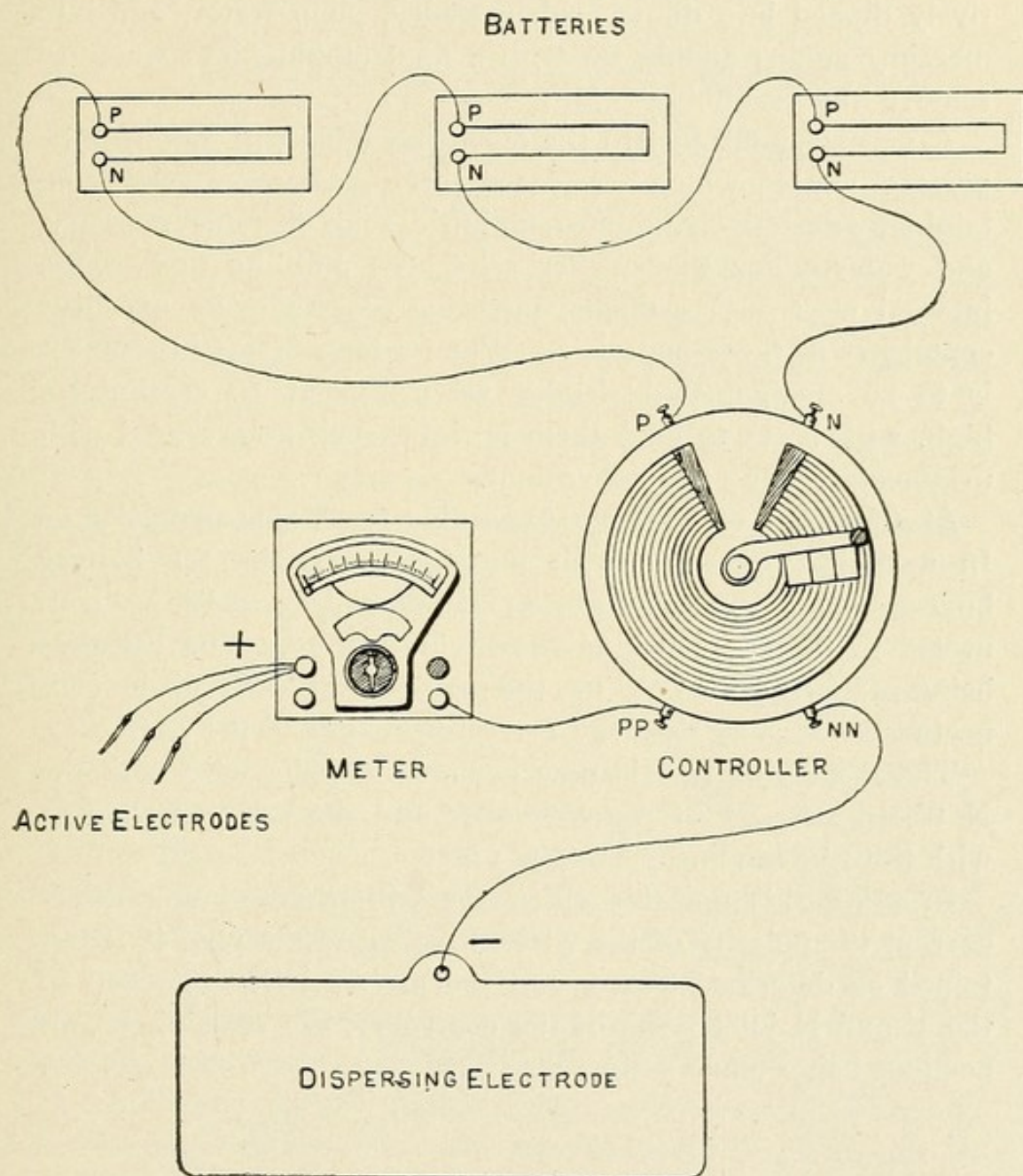


FIG. 17.—Diagram of arrangement of Portable Apparatus for monopolar ionic operation.

mercury unites with the metal to some distance beneath the surface, and as this renders the zinc quite brittle, *the electrode should not be amalgamated until it has been curved and insulated and the patient is ready for the operation.* Metallic mercury unites with a bright, clean zinc surface as soon as

the latter is dipped into it. As the average electrode tip is slightly tarnished by oxidation, however, it is most convenient to dip it into a dilute solution (25 to 50 per cent.) of sulphuric acid. If it is then dipped into the mercury the maximum amount of the latter will adhere to it, particularly if alternatively dipped into dilute acid, mercury, plain water, and into mercury again; ending up with a final dipping into water to remove any remaining acid.

A necessary adjunct to the operating table will therefore be a glass tray on which are placed three glass receptacles, containing, respectively, dilute sulphuric acid, metallic mercury, and water. For the smaller electrodes and the tips of the internal electrodes ordinary medicine glasses make excellent containers of these materials. When a long breast instrument is to be amalgamated slender vessels about 10 centimeters high, with bases to keep them upright, such as are used with urinometers, are most convenient.

Arrangement of Portable Apparatus for Major Operation.—

In a major operation with portable apparatus the battery boxes, containing from 30 to 60 commercial dry cells, are connected to the controller as shown in Fig. 17. The batteries being properly connected up, the meter is put in circuit by connecting its + post with the P treatment post of the controller.

The dispersing pad is now connected by its wire with the N treatment post of the controller and the active electrodes with the free binding post of the meter.

In using this portable apparatus with the 110 volt direct current the polarity of the wires attached to the plug is ascertained as described above, and the proper wires attached to the P and N inlet posts of the controller, the remaining connections being made as just described.

CHAPTER VII.

OPERATIVE DETAILS OF IONIC APPLICATIONS.

The author's personal experience in the ionic treatment of malignant growths, together with that of his colleagues using this method in the Oncologic Hospital, has indicated the desirability of varying the nature of the operation in certain cases by varying the position of the negative pole. In the operation chiefly referred to in the preceding pages, the large dispersing pad constitutes the negative pole, and is usually placed beneath the patient's back, or, at times, on the thighs. The end in view is the removal of this pole as far as possible from the active electrodes, in order that the ions diffused from the latter will penetrate deeply towards the base and periphery of the growth. Such penetration of the ions occurs in the lines of current flow, of course, and this means in large growths the inward transmission of a considerable bulk of current that must pass through neighboring nervous and muscular structures before it is widely dispersed, with the risk of temporarily tetanizing muscular structure and inhibiting nerve action. More than an amount suitable to a minor application is, therefore, to be avoided when the heart lies directly beneath, as in operations on the left breast; when important nerves in the neck lie close; or when such a current must traverse the brain structures with the active electrodes in the orbit. This difficulty may be generally avoided by abandoning this monopolar method in major operations in such cases and using the bipolar method, in which the negative pole is placed on or in the center of the growth itself, the active, positive electrodes being thrust into the periphery of the growth. Effective work may be accomplished by this bipolar method, though possibly at times inferior to that done by the monopolar, for the ions will be dispersed to some extent from all sides of the active electrodes, fairly sterilizing the periphery of the growth, while its center succumbs to the simple electrolytic action of the negative pole.

OPERATIVE TECHNIC OF MAJOR MONOPOLAR OPERATION.

The propriety of general anesthesia having been determined by examinations of the urine, the blood, and the condition of the arteries, the patient is prepared for anesthesia the night before the operation by the administration of a saline laxative, and is directed to eat no breakfast on the morning of the operation, or a light breakfast and no lunch if the operation is to be performed in the afternoon. No local preparation of the growth itself is necessary, though an aseptic condition of the surrounding skin surfaces is best secured by applying a moist antiseptic compress for six or eight hours previous to the operation in purulent cases. Elaborate scrubbing of the growth should be interdicted as unnecessary and liable to cause metastasis by forcing malignant cells into the lymphatic or general circulation.

Before beginning the administration of the anesthetic all preparations of the apparatus for the operation should be completed. If portable apparatus is to be used, it is brought into the operating room and connected up as described in Chapter VI. If the Ionization Table is to be used, it is merely placed in proper position with reference to the part of the body to be operated on. When any doubt exists as to whether the current will pass freely through the apparatus, it should be tested by connecting the final poles directly with a wire, turning the current on at the controller, and noting the deflection of the meter index; but if this is done the controller handle should be turned back at once to prevent the possibility of an involuntary shock to the patient subsequently.

The active electrodes should now be selected and prepared, if this has not been already done. Each electrode or leash of electrodes should be laid separately on a tray placed on the ionization table or on a side table alongside the operating table, with their wires separately coiled and their ends attached to the one treatment binding post, ready for instant use at any time during the operation without interruption of the current. All electrodes liable to be used during the operation should be attached to this binding post before the operation is begun, unless the Ionization Table is used, with its special facilities for multiple attachments.

Having the apparatus in readiness, the operating table is

prepared for the dispersing pad by placing a blanket on it, folded to serve as a cushion, over which is laid a waterproof sheet. On the sheet is placed the metal plate with wire attached, and over the point of attachment of the wire (which should be firmly connected to the plate) is laid a small piece of rubber sheeting to cover the wire as it lies beneath the edge of the kaolin pad. The plate is now ready for the warm pad to be placed on it, the pad meantime having been left in the sterilizer, where it has been kept warm and moist until the patient has been so far anesthetized as to be ready to be placed on the table.

The proper dispositions having been made and the patient anesthetized, the pad is placed on the plate and smoothed with a rolling pin to a uniform thickness. The patient is now placed on the table with the pad beneath his back, and the proper coaptation of the pad and the patient's back is noted, care being observed that no portion of the metal plate comes in contact with the skin. In large operations two pads should be used, the wires from both pads being attached to the negative binding post, or else a large kaolin mattress may be used to render the dispersion of the current as great as possible at this point.

If a microscopic examination of the tissue is to be made, it is necessary to remove the specimen before beginning the operation, as the action of the chemicals will render an examination impossible later. Aside from this necessity the operation is usually bloodless.

With everything in readiness, the electrodes are freely amalgamated and one is inserted directly into the periphery of the growth by simple pressure, the sharp points of the electrodes making this easy in spite of the brittleness produced by the mercury. The handle of the controller is then moved slowly until 50 milliamperes is shown by the meter. This amount is gradually increased, while the tolerance of the patient is tested by constant observation of the pulse and respiration, until 150 milliamperes is reached. At this early stage any intolerance is a mere pain reaction under a moderate stage of anesthesia. If more electrodes are to be used another is now inserted and the current increased, additional electrodes being inserted as the increased current warrants; it being remembered that effective work cannot usually be done when

employing the major size of electrode with less than 100 to 150 milliamperes per point.

As the phenomena described in Chapter V. develop, the electrodes that seem to have accomplished their purpose are removed, one at a time, re-amalgamated, and inserted at fresh points. In this way the whole of the growth is gradually brought under the influence of the diffused ions, while a proper concentration is maintained.

In a period of time, varying from twenty minutes to an hour, in accordance with the size and situation of the growth and with proper placement of the electrodes, the whole of the apparent limits of the diseased tissues will be included in the area of necrosis. The completeness of this effect can be ascertained by both sight and touch, the change of color to a whitish gray being absolute. The change to touch—a distinct softening of the brawny induration—is particularly valuable in situations where inspection by sight is difficult, as in the vagina and rectum, though this change is a valuable test in growths in any situation. All evident extensions of the disease should be included in the area of necrosis if possible, the surrounding zone of tissue reaction being depended on for the destruction of the non-evident prolongations only.

In external growths special attention is paid to the periphery, particularly that portion extending toward the situation of possibly infected glands. Enlarged glands should be attacked at the outset of the application and the intervening tissues usually destroyed also, as the possible lurking place of infected cells.

When the application is made to the head, neck, or near the heart, the pulse and respiration need special attention, as large currents tend to depress both of these vital functions. Should irregular action be observed, an immediate turning down of the current, without unnecessary suddenness, will cause an instant revival of both force and regularity. In fact, though the steady action of a heavy current is a depressant, the act of turning it off is a most valuable stimulant to the vital functions when depressed by the anesthetic alone. This is owing to the well-known fact that nerve and muscle respond to any change in the volume of a current traversing them, whether an increase or decrease, rendering an ionic operation safer in this respect than other operations, aside from simi-

lar advantages of conservation of blood and absence of shock.

As to the proper current strengths to be employed, much will depend on the condition of the patient, but more on the location of the growth. The author's personal experience indicates that the following amounts may be safely employed in the several situations mentioned, growths too large to be necrosed quickly by these currents requiring either that the current be continued for a sufficient time to obtain a full effect, or that the monopolar method be changed where possible to the bipolar method, with which much stronger currents may be used:

Maximum Currents Safely Applied by the Monopolar Method.

To the Head, Mouth, Throat, and Neck. . . . 300 to 400 ma.
 To the Left Breast . . . Minor monopolar applications only.
 To the Right Breast and Thorax generally, 400 to 800 ma.
 Below the Waist. 800 to 1,600 ma.

Special procedures relating to the insulation of electrodes, and cooling the site of application when necessary in applications within contracted cavities, will be found in the chapters devoted to the destruction of malignant tumors within the vagina and rectum.

The proper effect having been gained after an appropriate current-strength and duration, the current is slowly turned off finally, the electrodes removed, and a dry sterile dressing applied.

OPERATIVE TECHNIC OF MAJOR BIPOLAR OPERATION.

The term "bipolar operation" is employed to designate a major application in which the negative pole is applied on the center of the growth, while the active, positive electrodes are inserted either just beyond the periphery of the growth or as close to it as possible. This expedient, while inferior to the monopolar application in the production of the zone of reaction, permits the employment of much stronger currents in the necrosis of large growths of the head, neck, and left breast. Since weaker lines of current-flow curve backward from the active electrodes in wide curves, as shown in Fig. 18, in addition to the stronger and direct lines between the electrodes, a

slight zone of reaction may be secured on the distal sides of the active electrodes.

As it is often wise to end a bipolar operation with a weaker monopolar current to increase the extent of the zone of reaction, the patient is placed on the pad as described above, but the wire leading from the pad is not connected at first with the negative binding post. Instead, a bipolar negative elec-

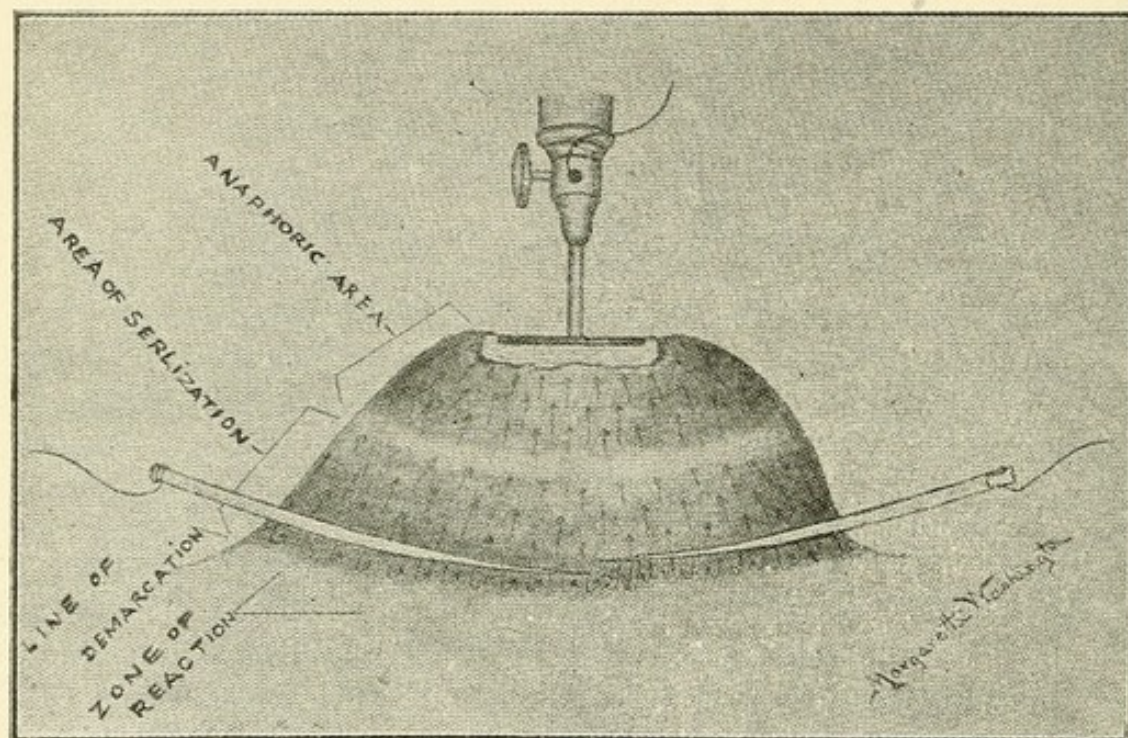


FIG. 18.—Diagram of cataphoric and anaphoric zones in bipolar operation.

trode (described below) is connected with the negative binding post by means of a piece of No. 26 wire.

Bipolar Negative Electrode.—When first employing this method the author used an old-fashioned disk electrode held against the center of the growth by a nurse. This was found to have two disadvantages: In a heavy application the flow of hydrogen-laden, alkaline, frothy liquid is so great as to obscure the work and even to scald healthy skin on which it might flow. The fixation of the electrode in its soapy situation was, moreover, uncertain, particularly when the attention of the nurse wandered.

For external applications, therefore, the self-retaining, cation-absorbing, negative electrode shown in Figs. 19 and 20 was devised. This is conveniently made of either of the

thinner sheets of zinc of which minor electrodes are made (the nature of the metal being, of course, indifferent, as the negative pole will not drive metals inward), by cutting out with a pair of shears a piece shaped as shown in Fig. 19 and of a size suitable to the growth to be destroyed. This is

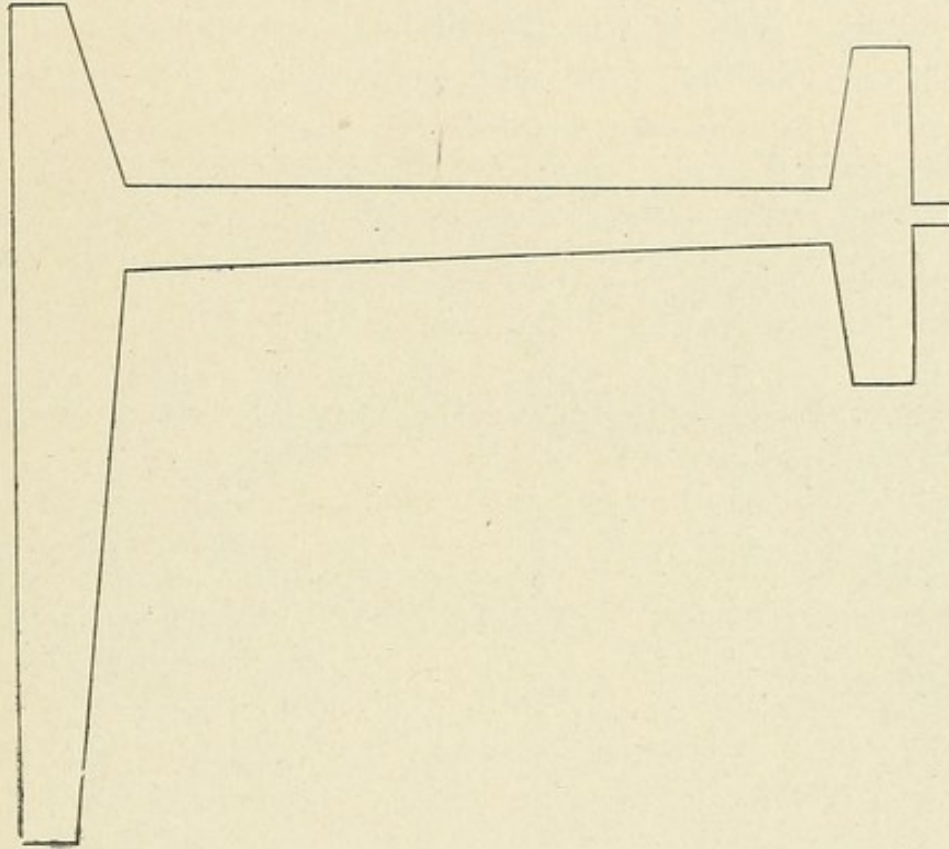


FIG. 19.—Diagram of piece of plate zinc used in making Bipolar Negative Electrode.

curved to form a spiral at the larger end, the shank being then bent to the exaggerated resemblance of a spoon, Fig. 20, but with the edge of the spiral pointing downwards, to be placed in contact with the center of the growth. After attaching the conducting cord to the small tip at the opposite end, the shank is completely and heavily insulated by covering it with melted sealing wax. A strip of thick gauze is now inserted between the turns of the spiral, and it is nearly saturated with a mixture of equal parts of sulphuric acid and water, which, resting on the center of the growth, will absorb the cations of the tissues as they reach the electrode, thus securing a practically dry application. The instrument is so placed that the insulated shank will rest on healthy skin beyond the field of operation, and it is secured firmly in place, with

slight pressure on the tumor, by means of strips of adhesive plaster passing over both the end and the arch of the shank.

During a prolonged or heavy operation the acid becomes neutralized, shown by the appearance of froth, and may be added to the gauze from time to time by means of a glass dropper.

Within cavities, if the growth be large enough to make the bipolar operation feasible, a spade-shaped electrode (Fig.




FIG. 20.—Negative Electrode of bipolar ionic operation in external situations.

16) may be prepared to act as the negative pole by covering it with cotton, kept moist with the acid, and pressed into the center of the growth.

The active electrodes are similar in every way to those employed in the monopolar operation described in preceding paragraphs and are used in a similar manner, except that greater care should be used in inserting them beyond the periphery of the growth, if possible, and that more of them may usually be employed simultaneously on account of the far greater current that it is possible to use in a bipolar application.

About twice as much current may be employed in the several portions of the body by the bipolar method as compared with

the monopolar, with even less influence on the reflex centers, thus greatly reducing the time during which the patient is kept under the anesthetic.

Should it be thought wise to follow the bipolar with the greater peripheral diffusion of a moderate monopolar application, after the completion of the former, the current is turned off, the central negative electrode is removed, and the wire from the pad connected instead with the negative binding post, a gentle current being turned on and maintained without further increase of the anesthesia.

After a bipolar operation with a heavy current, it should be remembered that the central portion of the slough is simply necrosed by electrolysis, and is, therefore, more likely to give rise to odor during separation. The periphery will show full infiltration with the zinc-mercury ions.

AFTER CARE OF PATIENTS FOLLOWING IONIC OPERATION.

During Separation of Slough.—The after treatment of a patient who has received a major application of electrochemical sterilization is extremely simple. Pain is rarely felt after emergence from the anesthetic in large growths, particularly if they were painful prior to operation, though soreness or tenderness will last for several days. In smaller growths, where much of the chemical effect has been expended on healthy surrounding parts, enough pain may be experienced during the first twenty-four hours to render a small dose of morphia desirable. The puffy reaction beyond the zone of sterilization may also at times render cold compresses useful.

The first dressing may be left on for twenty-four or forty-eight hours, as the site of the application is dry and will remain so for some days. The infiltrated ions have rendered the field of operation practically sterile, and this condition will persist for about fourteen days. During this time the line of demarcation is in process of formation, and the serous discharge will later demand more frequent changes of the gauze dressing, even though no odor appears. Where the slough is large, and has been formed from a growth in a necrotic condition, the antiseptic salts may drain away during the third week in sufficient quantity to permit a reappearance of a modified odor, though such an odor is never more than infinitesimal compared with the previous emissions of

an ulcerated growth. To prevent this reappearance of odor in such a case it may be well to cover the crust with a powder made of one dram of carbolic acid rubbed up with a quarter of a pound of powdered oxide of zinc, or the devitalized part may be kept covered with a moist bichlorid dressing.

The slough will separate spontaneously on or about the 21st day, if the growth was external and largely fibrous, or from the 7th to the 14th day, if the growth was soft and composed mainly of the neoplastic cells. When bony structure has been invaded by the growth it is a participant in the necrosing effects and will separate from the healthy bone also spontaneously in from 13 to 26 weeks. When the slough is large, whether of soft parts or bone, it may harbor germs of decomposition by re-infection during the latter portion of these periods, after the deposited chemicals have in part drained away, and it may, therefore, be wise to cut away the greater portion of the slough before it separates, for the patient's greater comfort, but in no case should the natural line of demarcation be interfered with, the cutting being done in the dead tissue only.

Secondary Hemorrhage.—In those growths where the line of separation forms early and occurs in highly vascular tissue, and particularly when it occurs in diseased tissue as a result of incomplete operation, there is some danger of secondary hemorrhage at this time, due to incomplete closure of the vessels. This may be said to be almost the only danger attending ionization operations, and it is best prevented in certain localities, particularly in large carcinomas of the upper or lower jaw, by subjecting the patient to the operation of ligation of the main artery supplying the part, the operation being performed about two weeks before the carcinoma is destroyed by ionization and being done in healthy tissue; though at times both operations may be done seriatim, with the one anesthesia. This precaution is seldom required outside the localities mentioned, however, the time required for the physiologic separation of the slough being usually sufficient for the spontaneous closure of the smaller vessels.

In cases where more or less hemorrhage is feared on account of the probable inclusion of vessels abnormally enlarged in the neoplastic growth, a careful watch should be maintained on the patient from the 7th to the 16th day after

operation, or until separation has occurred, the patient being meantime kept at rest in bed, and no traction should be made on the slough until the vessels have been occluded by the natural process. Should this rare accident occur, nevertheless, the best treatment is the immediate application of a bichlorid compress of sufficient thickness to exert firm pressure on the bleeding vessel when held in place by a tight bandage. When the bleeding is thus controlled the compress should be allowed to remain in place for several days. If the site of the hemorrhage be within a cavity, such as the mouth or rectum, a small quantity of Monsell's Solution, to which 3 per cent. of carbolic acid has been added, should be applied to the bleeding point with a glass syringe or on pledgets of cotton, and allowed to remain for several days.

After Separation of Slough.—When the slough of an external wound has separated spontaneously, or by the final clipping of devitalized fibers, a painless excavation is revealed in which granulation should be fostered and stimulated, with such exclusion of foreign germs as is possible without interference with the granulation process. Such a surface does not heal kindly under granulation-destroying dry gauze, even if the gauze is scrupulously sterile, while antiseptic solutions are equally irritating. The author has found, after much experience, that the best dressing for the wound at this stage is a mixture of equal parts of zinc-oxide ointment and vaseline. This exerts a gentle stimulus to the granulating surface, while protecting it from contamination, and favors the filling of the cavity and the inward extension of new skin from its edges in the shortest possible time. Later, the zinc-oxide may become too stimulating, shown by excessive redness of the granulations, when it should be replaced by a 20 per cent. mixture, or simple petroleum ointment until the part has skinned over.

Appearances indicate that these wounds, so treated, heal with remarkable promptness compared with wounds otherwise produced, rarely requiring skin grafting even when large surfaces are denuded, and resulting finally in soft scars of extremely small area compared with the original wound. The general tendency is the formation finally of a simple linear or Y-shaped scar, of slight conspicuousness, the only disadvantage being a tendency to distortion of the mouth or eyelid when the wound is very close to either of these openings.

In the latter case a plastic operation may be resorted to later for cosmetic reasons.

A few days after the separation of the slough the daily critical observation of the wound should begin, to discover any evidences of a portion of the growth having escaped the destructive process. The characteristic appearance of these disease granulations is somewhat difficult of description, but it may be said that they are larger, rounder, harder, and paler than normal granulations. When disease is left in the edges of the wound the latter are almost invariably raised, hard, and usually excavated (though at times rounded), while healthy edges are flattened, continuous with the surrounding skin or mucous membrane, and show the bluish-white color of new epidermis.

In the presence of any reasonable doubt, the granulations should be attacked at once by a series of minor applications, which are quite painless at some distance from the edges of the wound. If the edges themselves are doubtful, a second major application should be arranged without delay.

THE MINOR APPLICATION.

The minor application of zinc-mercury ionization is the designation applied to all applications made without general anesthesia. Any form of local anesthesia may be used. They may be made at the office, in the hospital or dispensary, or at the patient's residence.

The apparatus required is a current source and applying mechanism equal at least to the ordinary demands of the constant current in gynecology, having a good graphite controller of approved pattern and a delicate and accurate meter registering to 100 milliamperes on a wide scale. The Ionization Table, the Pope-Massey Wall Cabinet, and the improved portable apparatus described in connection with the technic of the major application, present almost equal advantages in the minor application, the chief being the very gradual and painless turn-on possible with them.

The patient lies on a couch with the part to be treated exposed, and the clothing is loosened sufficiently to enable a kaolin pad to be placed on the abdomen or back.* On the side

* When the application is below six or seven milliamperes the kaolin pad may be placed on a table and contact made by the patient resting the palms of the hands on it while in the sitting position.

of the pad furthest from the skin the thin metal plate is placed, of appropriate size, and connected by a No. 26 wire with the negative binding post. The next step, if the site of the proposed application is external, denuded of skin and sensitive, is the placing of several drops of a strong solution of cocaine at the site of the puncture, dropping a minute bit of absorbent cotton on it to hold the solution in place if necessary. This will serve to benumb sensation very materially if left in place while the active electrode is being prepared.

The minor electrode is now prepared as described above, sharpened and attached to the piece of No. 32 copper wire to serve as conductor. If the tissue to be destroyed is beneath healthy tissue, and a sinus exists, it is insulated as described for the No. 2 electrode. Should the surface to be destroyed be large, several such electrodes may be attached to the leash of wires described, but more than one electrode is only employed in situations where enough current can be used to give each point from seven to ten milliamperes, at least.

The electrode or electrodes are now amalgamated, attached to the positive binding post of the battery, and gently inserted into the growth, care being observed to make the pressure of insertion vertical to avoid breaking the instrument, which is now quite brittle from its mercurial coat.

Perfect stability of the electrode in the position given it is best secured by attaching a guy of adhesive plaster to the wire about four inches from the electrode, and sticking the ends of the plaster to a neighboring skin surface in such a way that the wire itself will not rest on the skin, since its insulation is slight.

The electrode or electrodes being in position and incapable of being disturbed by slight movements of the patient, a current is slowly and gently turned on, to the limit of the patient's comfort. This will vary greatly with the sensitiveness of the part, and should also bear some relation to the quantity of metal capable of being attacked without disappearance of the point during the application, thus suddenly interrupting the current. In practice the limits will vary from 2 or 3 to 80 or more milliamperes. Judged from the point of view of current bulk and electrode surface, there should be some adjustment of the size of the points to the current, as the most effective results are attained when the points are nearly, but

not quite, dissolved during the application. With small currents, very fine points should therefore be used.

A minor application for malignant disease should continue for thirty minutes, invariably, when one of a series with others to follow, counting from the time when the current is turned on. In tuberculous deposits fifteen minute applications will be sufficient. The current should be turned off as slowly as it was turned on, as any sudden variation is painful.

The part is dressed with the half-strength zinc-oxide ointment on gauze, held in place with a bandage or strips of zinc-oxide plaster.

The minor application is quite effective in destroying small growths in one séance, if the growths are not situated in sensitive regions, the part being duly inspected after separation of the slough and the application repeated until no doubt of the destruction of the growth exists. In larger growths of low malignancy it will maintain a practical asepsis, and if repeated daily or every other day, may ultimately eradicate the whole of the diseased area.

Local anesthesia may be employed with this method in two ways. If the skin must be punctured for the insertion of the electrodes, it should be chilled with the chloride of ethyl spray. A straight Hagedorn needle makes an excellent bistoury for incising the skin. When the electrode has been inserted, a small drop of a strong solution of cocaine in water is placed on the opening alongside the needle; the cocaine in the solution will be carried by cataphoric action into the wound along with the zinc and mercury ions, doing much to lessen the burning sensation that develops at the point where the ions attack the skin. When the puncture is into granulations at some distance from the skin, neither the spray, Hagedorn needle, nor the cocaine will be necessary, as diseased granulations are quite insensitive and easily penetrated by the zinc needles.

A more extensive local anesthesia may be produced when considerable skin surface is to be destroyed by using the endermic injection method; but where cocaine is to be thus employed, it should be in the weak Schleich solution, which contains morphia, cocaine, and common salt, and may be freely injected into the skin itself.

The No. 1, or non-insulated electrode, should be used when

a sinus is to be created through healthy tissues for subsequent treatment, and when the growth is a surface one and therefore does not require that the instrument be insulated. The No. 2, or insulated electrode, is to be used when further action on the walls of a sinus is not desired, and we wish to confine the action to the underlying tissue alone.

Value of Zone of Reaction produced by the Minor Applications.—Daily diffusions of even moderate doses of the ions of mercury and zinc are often practicable in somewhat large growths of low malignancy, such as rodent and other slowly growing epitheliomas, and in these cases both the operator and patient become soon convinced of the reality of the zone of reaction by unmistakable signs. Under these applications, with needles at each application passed into the insensitive growth itself, a sense of discomfort and burning will be perceived by the patient in the edges of the growth in a few days that can only be explained as the result of the repeated transmission outwards of the ions diffused at the previous applications. The physical conditions are that of concentric waves of material diffusion from the electrode or electrodes, each wave halting in its outward progress at the termination of the treatment, but being started up again by the next one. After ten such applications, therefore, the eleventh will be found to start up ten radiating waves of diffusion due to previous applications, the density of the ions diminishing as the circle of the wave widens, with consequent weakening of effect towards the periphery.

This secondary effect of such frequently repeated applications is often quite notable in surface growths, such as those mentioned, leading finally to a complete reversal of the insensitive conditions prevailing in these growths. The surrounding tissue becomes reddened and tender. The arousing of the physiologic resistance of the tissues thus indicated cannot be other than of great service in the destruction of outlying malignant cells, and thus contributing towards ultimate cure, but when the growth is too large or too virulent for this process to overwhelm it, the reaction only increases the virulence of its growth. In such cases a major application should be used without delay.

AFTER OBSERVATION.

One of the most imperative duties of the surgeon is that of repeated inspection of a patient after an operation for the destruction of a cancer to ascertain if the work has been complete and thorough. With the possibilities of minor ionization at hand to quickly and simply destroy local foci overlooked in the major application before a considerable regrowth has occurred, the importance of after inspection is greatly increased, for it enables us to snatch many a victory from otherwise certain defeat. It is half the battle in this form of war against cancer; and the same may, in fact, be said of any surgical method.

This after inspection may be divided practically into two periods: that between the separation of the slough and the healing of the wound; and that between the healing of the wound and the expiration of three to five years after the healing.

The first period is one of the most valuable features of the ionization method. During this time the painless wound is open for the most thorough observation, and an opportunity is given the surgeon to apply his highest skill in the detection of doubtful nodules and prominences. No trained application of both sight and touch could be of more value to the patient, and both of these senses should be developed by the worker in this field to their highest perfection.

Practice only can develop this nice discrimination between a healthy granulation and an unhealthy one, but the important points are that *indurated, rounded granulations should be regarded with suspicion*—a suspicion that should lead to their destruction at once by a minor application. A wound that is mainly healthy will furnish discharges that are entirely free, also, from the characteristic odor of cancer. *Any return of a previously present odor should, therefore, dictate additional treatment*, either a series of minor applications at once, or a second major application at the earliest opportunity—usually in about four weeks from the first. Finally, the approach of a normal epidermization in the edges is shown by a flattened, soft border of a whitish-blue color, with a tendency to a puckering contraction. *A nodular, raised, dark-colored edge, showing no tendency of the wound to contract, indicates the imperative necessity for further treatment.*

Any doubt that may exist as to the true nature of such granulations should be decided in favor of intervention; like Cæsar's wife, normal, post-operative granulations should be absolutely above suspicion. To suspect should be to condemn.

Should the doubtful granulations be at some distance from the sensitive edges of the skin or mucous membrane, towards the middle of the excavation, they are readily destroyed by a prompt series, or at times a single, minor application, the insensitive granulations permitting from 50 to 75 milliamperes to be used without pain. If the edges show disease, a major application is imperative, owing to the pain that would be produced by the minor method.

The second period of after observation, extending from the healing of the wound until the expiration of three to five years, is fully as important as the first period, and I fear is greatly neglected by surgeons at present, who would find evidences of recurrence much earlier than common if they were systematically looked for. To obtain full coöperation of the patient he should not be discharged at this time as cured, but merely as *without manifest evidence of disease*, as is the rule at the Onco-logic Hospital, being obligated in writing to return for inspection monthly during the first year and quarterly during the second and third years after discharge.

POST-OPERATIVE RADIOTHERAPY AND PHOTOTHERAPY.

Some radiotherapeutists lay stress on the value of post-operative radiation to insure destruction of latent cells in the region of the wound. This would seem to be a most excellent procedure, and there is no doubt of its importance in some cases; but it has the disadvantage in others of producing a dermatitis, while in all cases there is a disturbed nutrition in the wound that may interfere with the detection of slight recurrences near the surface that could be instantly destroyed by a minor application if discovered promptly. The conditions of each case must dictate the proper course to pursue, the author having recourse to radiation in a small proportion of cases only for the reason given. If re-treatment by ionization seems inadequate in a given case of recurrence the rays should be begun at once.

Phototherapy, on the other hand, may be employed to assist the healing process in any large denudations, and it has seemed to the author to be valuable to quicken the healing, and to assist in the determination of the question whether the granulations and edges of the wound are healthy or not.

CHAPTER VIII.

CONCERNING THE CHOICE OF METHOD IN THE TREATMENT OF MALIGNANT GROWTHS IN VARIOUS SITUATIONS AND STAGES.

There is to-day no more important question in medicine than the proper method of convincing the public, and possibly also many members of the medical profession, of the supreme importance of early and vigorous removal of all accessible cancerous growths in their earliest incipency. This means, with the exception of certain skin cancers, and possibly certain sarcomas, their operative removal. The exceptions relate entirely to those epitheliomas which even in their incipency are best treated by Roentgen rays, and to sarcomas in inaccessible situations. No other treatment now known, including all the recent fads, need be considered for a moment, for none have verified their ability to do more than cause fatal delay in operable cases.

In thus stating the inevitable need of operation in all but the excepted cases, and immediate operation is emphatically meant, the author includes of course the methods described in the preceding pages, for the ionic destruction of cancer cannot be regarded in any other light than operative removal of the disease, even though it may not be accompanied by the loss of blood usually associated with operative procedures.

In the vast majority of incipient growths the question is therefore not "Shall this or that be tried before operation?" but "What form of operation is best suited to the individual case?"

To answer such a question to the best advantage requires usually more than the experience of any one operator, for few men are capable of comprehending adequately the work of another greatly differing from their own. This difficulty is one that is, nevertheless, readily met in the manner anciently dictated in the ethical procedures of the medical profession. Consultation is the key to the best results, provided only that experience and judgment be both secured for the conference.

INDICATIONS GOVERNING THE CHOICE BETWEEN IONIZATION
AND OTHER METHODS.

Taking a broad view of the subject, some remarks may therefore be made in this place on the comparative suitability of ionization and other methods in individual cases, after briefly enumerating the general advantages and disadvantages of several methods.

This choice of operative method, it should be understood, is based mainly at present on the situation and stage of the growth rather than its type or variety, though considerations based on the variety dictate important modifications of technic.

Comparative Advantages of Ionization.—As compared with excision by the knife, this method presents the following advantages: The cancer cells or germs are killed *in situ* at once and the surrounding absorbents sealed, preventing the operative re-infection of the cut edges that has been said to accompany the former method when the incisions are performed close to the edges of the growth; it permits of the destruction of a small growth in certain organs, such as the breast or tongue, without the removal of the whole of the organ; in spite of scepticism natural to those who have not observed the method, it may be depended on to destroy infected glands in the axilla (not too close to the axillary vessels) more thoroughly than incision; it is bloodless, and hence may be employed in highly vascular growths without the weakening effect of loss of blood; and, most important of all, it permits of a strictly localized, bloodless destruction of growths within accessible cavities—such as the nose, mouth, vagina, and rectum—by the use of insulated electrodes, without disturbance of overlying healthy tissues or the extensive operations necessary particularly in the first two cavities mentioned, and in these cases, without the danger of septic pneumonia from insufflation of blood, as often happens during excision.

No comparison is possible with the curette in the treatment of cancer, as this instrument should be looked upon as capable only of aggravating a malignant growth, and should never be used in such cases. A minor ionization application is a complete substitute for curettement, accomplishing all that curettement may do, with a total absence of its disadvantages and power of harm.

As compared with the thermocautery and caustic pastes, the ionization method is more controllable and may be made to reach the periphery of the growth at once, under anesthesia, and thus painlessly and accurately accomplish in a few minutes what is sought to be done blindly by caustics during weeks of acute suffering. It is employed as easily within cavities as externally. The periphery (which is the vital portion of the growth) is sterilized and sealed in the ionization process. Finally, the slough produced is sterilized by added sterilizing ions rather than temporarily by heat, as in the thermocautery, and remains sterile and odorless the greater portion of the time until separation occurs, while the intensely odorous sloughs produced by the thermocautery are well known.

The amelioration, and at times actual cure, already observed in many cases of malignant disease under Roentgen rays, make a comparison of this method with zinc-mercury ionization also most appropriate at this time. The question of selection between the two methods is one largely depending on the variety of the growth, though its situation is of great importance. In cases that present but little difficulty in their immediate eradication by ionization or excision, and in which delay would increase the chances of internal dissemination, the selection of one of the two latter methods is surely the part of wisdom. Should ionization fail to eliminate all of the disease in the first application, and show little sign of success after prompt repetition or repetitions, the rays should be begun at once. But no case that may be easily brought within the powers of the quicker method, particularly no case presenting a liability to metastasis from delay, should be subjected to the uncertainties that yet surround the radiation method. It should be remembered, also, that certain obscure dangers attend repeated radiation that are not found in connection with the ionic method.

Comparative Disadvantages of Ionization.—As compared with the knife, one disadvantage of this method is the cost of the apparatus and the necessity for the possession of a working knowledge of medical electrophysics by the operator. This need but to be mentioned to be dismissed, since the cost of both requisites is too slight to be put into the scale with life itself. A real disadvantage in a highly operable breast case, for instance, is the time necessarily spent in the

hospital while the slough separates, as compared with the much shorter time required in hospital after excision. Its real indication in breast cases, aside from the eradication of small carcinomas in young women with preservation of the breast, is in the treatment of breast and axillary invasions that are past, or still on, the border-line of knife operability, and in these cases the time required for the wound to close is a distinct advantage, as it permits of an observation that often enables us to secure success in the face of impending failure by showing the need of additional minor applications.

Minor ionic applications can rarely be successfully made to deep-seated growths in the neck. In this situation a major application has distinct dangers, both by interference with the pneumogastric nerve, thus endangering respiration and circulation, and through the possibility of the inclusion of large veins in the destructive process, with the consequent risk of secondary hemorrhage. This subject will be further discussed in the chapter on applications to the mouth.

As compared with caustics and the thermocautery, the ionic method has no disadvantage whatever.

Compared with x-rays, the ionization method has the disadvantage of requiring anesthesia at times, and of always producing a wound at the site of the growth; but this wound is intelligently made, and unlike the possible wounds produced by x-rays, is sterile and heals very easily. It is also hoped that radiotherapy will be found to possess the advantage of favorably affecting sarcomatous growths within the abdomen or chest which are beyond the reach of the ionization method. But a most important advantage of x-rays over ionization, in skin cancers that have been found to be amenable to the rays, is the fact that a large surface may be simultaneously treated by the rays, while the growth may be of such slight depth as to be capable of being treated by ionization in a minor form only, and by many repetitions in small areas. Alternate employment of each method may be of value in such cases. A disadvantage of ionization in the treatment of epitheliomas near the eyelids is the tendency to distortion of the latter in the healing process. When such growths respond to the rays this sequel does not usually follow.

CONCLUSIONS AS TO CHOICE OF METHODS.

A statement of the author's conclusions concerning the selection of the best method among those now known for the treatment of a definite case of cancer would therefore read as follows:

1. The knife, being preferred as the simplest remedy, offers the best or the quickest relief in the following situations: All operable growths still confined to the interior of organs that it is impossible to conserve safely and that are capable of complete removal, such, for instance, as the eyeball; the uterus (when confined to the body, but not the cervical variety); the ovary; the testicle; all strictly internal organs; and the highly malignant sarcomas of the extremities where high amputation is possible (if accompanied by ionic sterilization of the infected lymphatic glands above the seat of amputation). A mammary carcinoma without advanced infection of the axillary glands—in other words, a “highly operable” case, in which so much of the gland is affected as to preclude the possibility of saving the greater portion of the breast—should be removed by the knife together with the tissues of the axilla, provided a wide-sweeping operation be done, for this procedure should be as free from chances of recurrence as a thorough ionic destruction, and convalescence is shorter.

2. Ionization should be employed in most operable and some inoperable external growths where experience has shown that the prevention of recurrence is difficult after knife operations, or where, as in the face, tissue may be successfully saved and a better cosmetic result secured by this method. In all small incipient growths of the skin it is both more easily applied, more successful, and less abhorrent to the patient; and as it is more likely to be accepted by patients in earlier stages of the growth than the knife, an additional chance of cure of great importance is presented by it. In mammary carcinoma an early or doubtful cancerous nodule in a young woman may be eradicated by ionization without loss of the breast, and the same may be said of a cystoma of the breast. It is also believed by the author to promise the better result as compared with the knife in advanced, semi-adherent carcinomas of the breast with well-defined masses in the axilla (if the higher axillary glands are not affected). But, far and above any other method, ionization is most suitably

applied to malignant growths in the accessible cavities of the body: the nasal cavities, the mouth, vagina, and rectum.

Finally, in so-called inoperable cases in many situations it presents a valuable means of palliation, though its use for this purpose is likely to prejudice its employment in the true sphere of its greatest usefulness: the destruction of incipient growths.

3. Radiotherapy should be used in extensive skin cancers of low virulence and slight depth, where ionization would be tedious or impracticable: it should be tried in epitheliomas near the eyelids, where ionization or other methods might cause distortion of the lids; it often succeeds where all other methods have failed in surface growths; and it has caused the disappearance of some internal sarcomas.

4. A combination, or serial employment, of two or more of the methods mentioned, as conditions arise, is at times the wisest course to pursue in the treatment of an intractable case, leading possibly to an eradication of a still local cancerous growth that would not have yielded to any one method alone.

CHOICE OF MAJOR OR MINOR IONIC APPLICATIONS IN A GIVEN CASE.

The question whether a case for which the ionic method is selected can be successfully treated by the minor method, or demands a major operation, is one at times difficult of determination, though the general principles of choice are clear. *No highly malignant carcinoma or sarcoma in any situation, should be subjected to the risk involved in the delay, and possible aggravation essential to the minor method unless it is so small as to be eradicable in from two to three applications—preferably in one application.* This at once places the majority of carcinomas and sarcomas, in the late stages in which we at present first see them, in the list of those requiring the major application.

The minor method may, nevertheless, be effective in very extensive growths of low malignancy where the major application is inadvisable because of the feebleness of the patient, or because a thorough application by the major method would be too extensive a wound for subsequent cosmetic reasons; but such cases must be of the kind that have existed for years without the appearance of metastasis or of extension to over-

lying skin or mucous membrane. Of the more virulent varieties, those of the small size mentioned above, when in insensitive situations, may be effectually destroyed by minor applications, as well as those recurrent nodules found just beneath the skin after amputation of the breast for carcinoma. These nodules are no larger than a pea, if diligently searched for during the first weeks after the operation, and represent either unnoted pre-operation tissue colonies, infected lymphatic valves, or direct re-implantations of cells during the cutting operation. Carcinoma of the cervix uteri in its earlier stages is also suitable for what is, in this situation, a minor application, though the insensitive nature of this area permits the stretching of the term "minor" to cover applications without anesthesia of one and two hundred milliamperes for thirty minutes. Rodent cancer of the face is often best treated by the minor method, though when the growth is extensive many applications extending over a long time may be required, the particular advantage of the minor method in this instance being the lessened scar that finally results. The minor method is, of course, applicable to all small growths that are properly classed as but moderately malignant.

Distinctly virulent growths, even of small size, require the major method when situated in sensitive areas such as the lip, breast, anus, etc., though complete sterilization may be effected in a few minutes, as the pain produced by the minor application in these situations precludes its use.

Finally, we must be prepared to promptly apply minor applications to suspicious granulations appearing before the healing of large wounds after the separation of the slough of major applications, as our best results may be thus snatched from impending defeat. The open wound of the ionic method becomes from this point of view one of its chief advantages.

CHAPTER IX.

APPLICATIONS TO THE FACE.

The author's experience in the actual employment of electrochemical methods in malignant growths indicates the need of considerable variation in the technic, in accordance with the local situation of the neoplasm, and to a less extent with its variety. A special treatment of the subject from this point of view is therefore necessary, and this special consideration is best emphasized by a full report of some cases illustrating each region, so far as possible.

Basis of Selection of Cases for Illustration.—In selecting these cases, only those that were finally cured will be reported in detail from the first series of cases treated, or those extending from 1893 to 1905, as this series of seventy-nine cases was largely experimental, and many of them would now be rejected as unsuitable for the demonstration of the value of a novel method; the total number treated in each portion of the body will nevertheless be given. Of the second series, embracing those placed under treatment since January 1, 1905, all will be reported in the order of their admission, special space being given to those having a teaching value.

The classification into "operable" and "inoperable" is based entirely on the apparent operability of a case by the knife and has no reference to its operability by the ionization method. Such a classification is modified by the personal equation of the surgeon making it, of course, yet it is of much service in differentiating the curative or merely palliative value of a new method, to which physicians are apt to turn for the relief of desperate cases only, after other methods have been tried and have failed.

Epitheliomas of the face are peculiarly well adapted to complete destructive sterilization by zinc-mercury ionization, and when the growth is small it may be destroyed with such delicate limitations of the destructive process to the actually diseased cells, particularly when the minor method is em-

ployed, that the resulting scar is less conspicuous than that produced by any other method except the x-ray. This adapts it to the effective destruction of small growths near the eyes, or in situations where unnecessary loss of substance will lead to conspicuous deformity. By repeated employment of from 3 to 5 milliamperes for the regular half-hour durations the malignant tissue alone is destroyed, resulting in a minimal scar, and only such loss of normal tissue as had been actually destroyed by the malignant process. In some cases a pucker at the site of the growth will follow healing if much tissue had been destroyed by the morbid process.

The same reasons that make the minor applications peculiarly valuable in small epitheliomas render them of great service also in early recurrences, particularly of rodent cancer (epithelioma of the short hair follicles), which, if primarily of small size, may be destroyed by one or more minor applications in the beginning, but in any case will require careful watching for some months after healing in order that the minute pearls of recurrence on the surface may receive additional applications from time to time until a final cure has been attained. When the rodent cancer is extensive a major application of 200 to 300 milliamperes should be made at once, with twenty or more fine points attached to a leash of No. 32 wire; but in all cases the minor method will be likely to be needed to complete the cure.

When the growth is close to the eye or ear the importance of turning the current on and off gradually is greater than elsewhere, especially in the minor method without general anesthesia, as harmless but unpleasant flashes or dizziness are sure to accompany a rapid increase or decrease even with a few milliamperes, and a sudden interruption is quite disconcerting. The minor method is nevertheless very effective in cases of slight virulence at the actual margin of the eyelids or in the immediate vicinity of the auditory apparatus. The technic of applications within the orbit will be referred to later.

If the epithelioma be large, a major application is necessary, unless the virulence of the growth is very slight. Since only from 200 to 350 milliamperes are advisable by the monopolar method, large epitheliomas of the face should be destroyed by the bipolar method, as from 500 to 800 milliamperes

may be thus used, with great saving of time under the anesthetic and a greater certainty of eradicating the growth.

Epitheliomas of the lips demand a major application under general anesthesia, either bipolar or monopolar, if at all extensive, owing to the exaggerated tenderness of this region and the usual virulence of labial cancer.

Carcinomas and sarcomas of the regions under consideration are often capable of effective treatment by ionization. If deep-seated the facial artery should be ligated before the application to prevent secondary hemorrhage. In these cases search should be made for enlarged glands in the neck, which, if found to be still movable, should be raised from their bed by passing a threaded curved needle beneath them, using the thread as a tractive agent to draw them away from the vessels and nerves, passing the active needles beneath them and applying a strong bipolar current with the negative held against the skin over the gland and within the loop of thread. The ionic method should not be employed if the infected glands be immovable or deep-seated.

The active electrodes in face cases should be short, to avoid interference with the anesthetic, light in weight so that they will remain in position, and with sharp points for ready insertion. They should be attached in sets of two or four to No. 32 wire and so anchored by plaster guys to the near-by skin that they will not be dislodged by accidental movements of the patient.

The dispersing electrode, when bipolar, should be about half as large as the surface of the growth, and supplied with absorbent gauze to retain the anion-absorbing acid. In monopolar operations the dispersing pad should be beneath the back.

FIRST SERIES.

NO. 45, PRIVATE CASE BOOK. *Epithelioma of Side and Bridge of Nose, with Metastasis to Neck.*—Mrs. L., aged 84, was referred by Dr. D. F. Woods, of Philadelphia, September 9, 1901. There is an open cancerous ulceration on left side of the nose, eroding the bones of same and a portion of the right side, and opening both nostrils. The erosion extends to the inner commissure of the left eye and threatens to invade the orbit. There is a very large pyramidal swelling on the left side of the neck, below the jaw, which is evidently due to the

coalescence of a number of infected glands. The latter growth is immovably fixed in the deep structures of the neck, is the source of more pain to the aged and enfeebled patient than the primary growth, and is absolutely inoperable. The relatives asked simply that the nasal growth be arrested, if possible, before it attacked the eye.

A major monopolar application was therefore made to the primary growth, 200 to 300 millamperes being applied with 6 to 12 fine points for one hour and twenty minutes, under general anesthesia, assisted by Drs. Richard Woods, Hermance, and Okie. The ether was badly borne, and the patient was quite weak for some weeks.

October 12. All sloughs, with some spicules of bone, have separated, leaving a wound with healthy edges. Patient no longer suffers from pain in site of original disease, but has great pain in the metastatic growth in the neck.

The patient died during the following winter from extension of the secondary growth, but there was no sign of recurrence in the nasal region, and the eye was saved.

NO. 50, PRIVATE CASE BOOK. *Carcinoma of Bridge of Nose*.—Mrs. S., aged 68, referred by Dr. Wm. B. Ulrich, of Chester, Pa., December 23, 1901. Six weeks before this date a small pimple had appeared on the right side of the bridge of the nose. It was painless, but its rapid growth induced Dr. Ulrich to send the patient to Prof. Duhring, of the University of Pennsylvania, for diagnosis. Dr. Duhring pronounced the growth an epithelioma, and advised its removal by electricity.

A photograph of the growth was taken at this time (Fig. 21), it being about the size of a pea, resting on a raised and indurated base the size of a penny. The minor method was begun, with very fine zinc-mercury needles and tri-weekly applications of as much current as the patient could easily stand, with cocaine solution at point of insertion—about three to ten milliamperes. It was soon seen, however, that these mild applications were worse than useless, seeming, in fact, to stimulate the growth, which rapidly enlarged. We had evidently to deal with a rapidly growing cancer of a virulent type.

A major monopolar application was therefore made January 16, 1902, 200 ma. being used with fine points for 40 minutes under ether, with the assistance of Drs. Ulrich and Her-

mance. This resulted in complete destruction of the growth, which was found to involve the nasal bones, the upper surface of which separated spontaneously three months later, leaving a healthy base which healed over nicely. A small opening into the left nostril remained, with healthy edges, but the

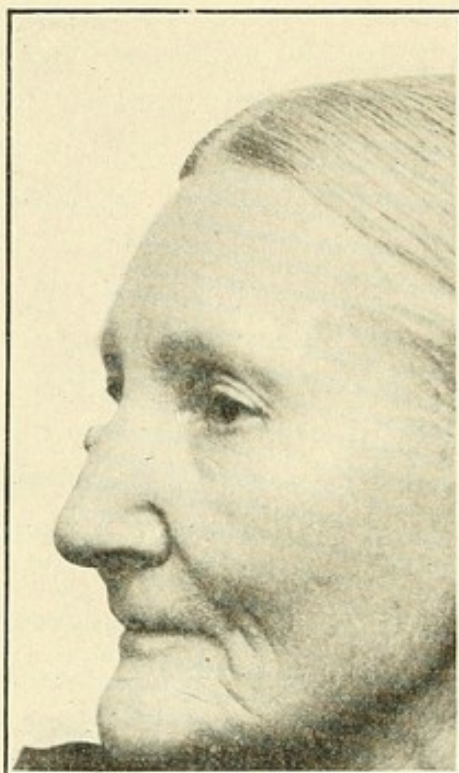


FIG. 21.—Case No. 50 before treatment.

patient was contented with the cosmetic result without the intervention of a plastic operation, which was advised.

There was no recurrence up to the time of her death from heart disease five years later, in her 74th year.

NO. 51, PRIVATE CASE BOOK. *Epithelioma of the Chin.*—John McW., electrician, aged 56, was referred by Dr. Chas. E. Taylor, of Irwin, Pa., March 3, 1902. Three years ago what appeared to be a pimple on the chin was cut in shaving, after which it grew rapidly. There is a raised, indurated patch on the corner of the chin that is plentifully supplied with tortuous vessels, 3 cm. in breadth, and ulcerated in the center. It is painless. As the patient was compelled to return to Pittsburgh at once, the growth was destroyed by a minor application in the office, sensation being lessened by the injection of a weak cocaine solution into the part. A current of

forty milliamperes was used for one hour and twenty-six minutes.

June 14, 1908. Patient returns with a small recurrence in edge of scar. Twenty ma. for one hour and ten minutes.

July 15, 1908. Patient reports by letter that the wound has healed, and that he does not think any disease remains.

No. 64, PRIVATE CASE BOOK. *Epithelioma of Cheeks*.—Miss S. B. I., aged 44, was referred by Dr. Leonard Judd, of Philadelphia, August 19, 1903. For two years she has had a slowly growing skin tumor on the right cheek beneath the eye. One year ago she was under the care of a prominent dermatologist of this city, who failed to arrest its growth. In June she saw Prof. Duhring, who made a diagnosis of epithelioma. There is a raised, proliferating growth the size of a penny, with indurated base and covered with a crust.

August 19, 1903. Minor application, 20 ma. for 30 minutes.

August 1, 1908. No recurrence to date.

SUMMARY OF FIRST SERIES OF FACE AND SCALP CASES.

<i>Operable Cases.</i>			
Without manifest evidence of disease at latest report	Ameliorated	Failed	Died under treatment
4	1	0	0
<i>Inoperable Cases.</i>			
Without manifest evidence of disease at latest report	Ameliorated	Failed	Died under treatment
0	4	0	0

SECOND SERIES.

No. 28. ONCOLOGIC HOSPITAL. *Rodent Epithelioma of Upper Lip*.—Mrs. H. B. B., aged 73. Admitted to dispensary January 23, 1905. She had had the erosion on the upper lip, shown in Fig. 22, four years. She received a minor zinc-mercury application of 1 to 3 milliamperes for thirty minutes, once a week, for three months, being in feeble health. The second photograph, Fig. 23, was taken October 7, 1905.

December 3, 1907. Patient reports through daughter-in-law that there is no recurrence.

No. 93. ONCOLOGIC HOSPITAL. *Rodent Epithelioma of*

Face.—F. W., aged 55, was admitted to dispensary March 30, 1905, with an ulceration on one side of the nose near eye, shown in Fig. 24. It had appeared two years before, had the characteristic raised edges of a rodent cancer, and was $1\frac{1}{4}$ cm. in diameter. X-ray treatment had been applied by an expert for nine months with temporary benefit and recent increase in

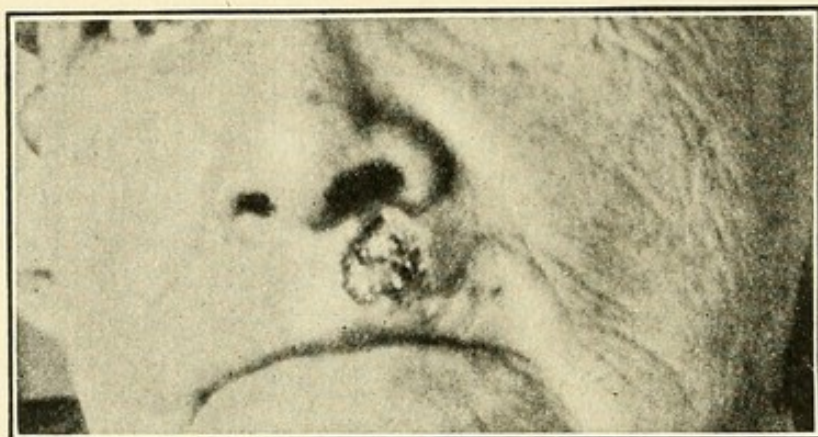


FIG. 22.—Case 28 before treatment, January 23, 1905.

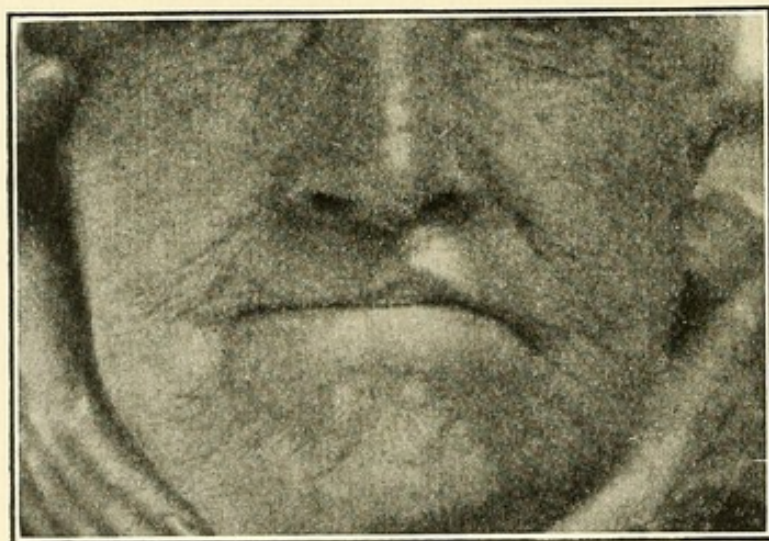


FIG. 23.—Case 28 nine months after treatment. No recurrence three years later.

size. A minor application of 4 milliamperes was made for a half-hour with two needles, several drops of cocaine solution having been placed on the wound. Two weeks later the scab came off, showing no sign of disease.

November 20, 1905. Patient reports with one small pearl of recurrence. Minor application by Dr. McClary of 2 milliamperes for ten minutes.

December 7, 1907. Reports at dispensary without manifest

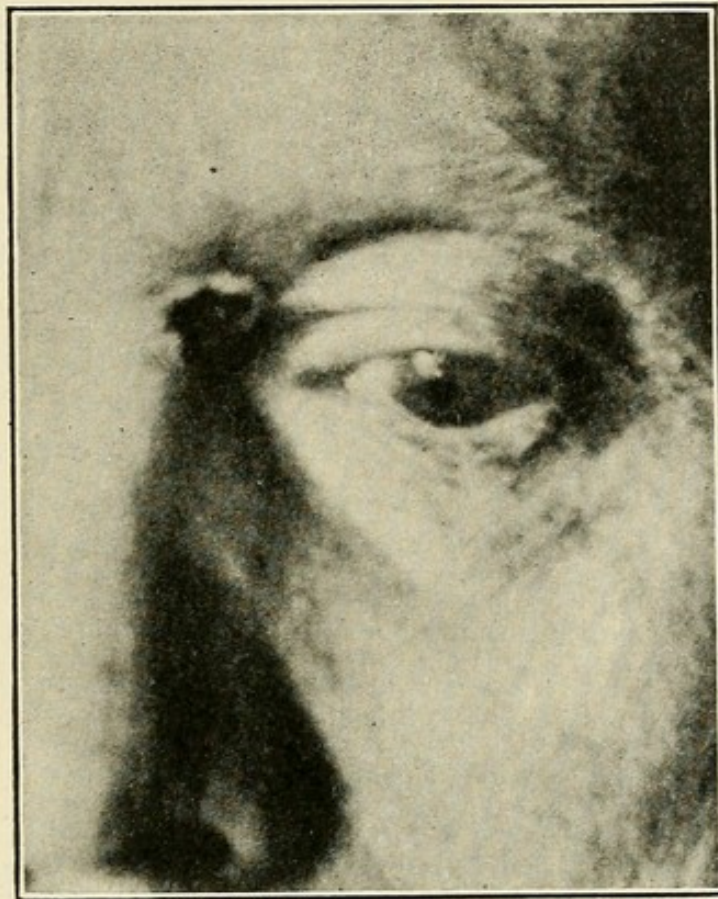


FIG. 24.—Case 93 before treatment, March 30, 1905.




FIG. 25.—Case 93. Appearance four and one-half years after treatment.

evidence of disease. The photograph, Fig. 25, was taken at this time.

October 27, 1909. Patient seen at his home. Scar remains exactly as shown in Fig. 25.

No. 133. ONCOLOGIC HOSPITAL. *Epithelioma of Cheek, of Small Size*.—Mrs. J. A., aged 60, admitted to the dispensary May 9, 1905. A scaly elevation, 1 by one-half cm., has been present seven or eight years. X-rays applied in near-by city had no effect. Minor application of 10 ma. for half-hour, two needles. Returned to dispensary by request February 13, 1906, showing no manifest evidence of disease.

No. 140. ONCOLOGIC HOSPITAL. *Rodent Epithelioma of Forehead*.—Mrs. M. C., aged 46, admitted to dispensary May 23, 1905, with several isolated nodules of the disease covering a surface about 4 by 5 cm., recurrent after x-ray treatment. The disease had existed four years, and she had had the x-rays for 9 months. Minor applications of 4 to 5 ma., with 4 needles, have been given on ten different occasions, as the patient returned for treatment, with great improvement. No sign of disease now for a year.

No. 163. ONCOLOGIC HOSPITAL. *Rodent Epithelioma of Nose*.—J. C., aged 69, admitted to house June 26, 1905. The tip and both sides of the nose were the seat of a deep erosion, leaving but about two-thirds of the external nose unaffected. The disease had been present for sixteen years, during ten of which extensive progress had been made. Caustic paste had been applied one year before, and the x-rays at a city hospital.

Minor applications proving too painful, he was placed under ether July 12, and a major monopolar application made of 350 to 400 milliamperes for 50 minutes, about 12 very small needles being used. Recovery was uneventful, and he was discharged August 1st. There was no recurrence, the patient dying a year later of pneumonia.

No. 164. ONCOLOGIC HOSPITAL. *Lupus of Face*.—J. O., aged 49, admitted to dispensary June 26, 1905, with a lupoid patch on left cheek. Minor applications of 3 to 5 ma. were made on several occasions, when the patient abandoned the treatment. In December, 1907, reported at dispensary by request in excellent condition, having received x-ray treatment at a hospital near his residence.

No. 187. ONCOLOGIC HOSPITAL. *Epithelioma of Skin of Nose*.—Mrs. E. P., aged 53, admitted to the house from Gibbsboro, N. J., July 17, 1905, with an ulceration on side of nose near canthus of left eye, of some years' duration. It was $1\frac{1}{2}$ cm. in diameter, and had the characteristic raised edges of rodent cancer. Monopolar application under chloroform, 25 ma. for fifteen minutes. Discharged to dispensary for observation August 11th.

November 26, 1906. Reported at dispensary with a single pearl of recurrence. Minor application.

No. 219. ONCOLOGIC HOSPITAL. *Lupus of Nose*.—Mrs. E. H. S., aged 72, was admitted to dispensary August 28, 1905, with a chronic ulcer on the tip of the nose clinically resembling lupus. It had resisted remedial efforts for five years. Minor application of 20 ma. was made for half-hour. Five ma. were applied similarly November 7th, and six ma. November 28 of same year. Reported at hospital without recurrence in November, 1906.

No. 234. ONCOLOGIC HOSPITAL. *Epitheliomatous Patches on Face and Ears*.—C. H. S., aged 63, applied to dispensary June 26, 1905, with multiple senile epitheliomata on left cheek (Fig. 26), and on the helices of each ear, of two years' duration. Under cocaine a minor application of as much as 40 ma. for 30 minutes was made to the principal growth, and on a subsequent occasion each of the other growths received applications of 8 ma. for 15 minutes and 3 ma. for 10 minutes. Fig. 27 shows the condition September 14, 1905.

January 10, 1908. In response to letter patient states that there has been a recurrence of the growth on the cheek, but that he is confined to bed with rheumatism and unable to return for further treatment.

No. 243. ONCOLOGIC HOSPITAL. *Recurrent Carcinoma of Scalp*.—Mrs. S. D., aged 50, was referred by Dr. Eckman, of Philadelphia, October 3, 1905, with a proliferating growth on the occiput about 4 cm. in diameter. For 20 years she had had a wen on the site of the growth which she says gave her "no trouble" until one year ago, when it became painful and was opened by a physician. It failed to heal, and was later curetted (in March, 1905). In April it was removed by excision. She suffered from severe headaches.

October 4, 1905. Major monopolar operation, 250 to 300

milliamperes for 65 minutes. Microscopic examination: Carcinoma.

October 21, 1905. Patient discharged with some evidence of disease in wound and no relief of headaches. During November and December the patient received eight minor appli-




FIG. 26.—Case 234 before treatment, June 26, 1905.

cations varying from 25 to 45 milliamperes, and ceased attendance owing to weakness.

The patient died several months later of extension to the brain.

No. 256. ONCOLOGIC HOSPITAL. *Small Epithelioma of Bridge of Nose.*—A. McL., aged 70, admitted to dispensary October 30, 1905, with a growth clinically resembling epithelioma and about the size of a pea, on the bridge of nose. Minor application, 6 to 9 ma. for 18 minutes.

February 26, 1906. Reports at dispensary with no evidence of disease.

No. 85, PRIVATE CASE BOOK. *Multiple Senile Epitheliomata.* J. M. R., aged 77, of Camden, Dela., was referred by Dr. Leonardo Judd, of Philadelphia, December 5, 1905. His father had callosities on hands, and a maternal uncle died of cancer. For 8 or 10 years he has had an epithelial growth with crusts just above the inner canthus of the left eye. He had a similar growth excised five years ago.

The growth is an epithelial ulceration surmounted by a crust, about $1\frac{1}{2}$ by 2 cm. in size. Minor application, 7 ma. for 20 minutes, 4 points.

January 29, 1907. There is a small nodule in scar of previous application. There is also a new growth on the side of cheek about the same size as the one over the eye when first treated. Both spots received a simultaneous minor application of 10 ma. for one hour.

September 13, 1907. Perfect scar at site of growth on cheek. In the scar over left eye 1 milliampere is applied for 20 minutes.

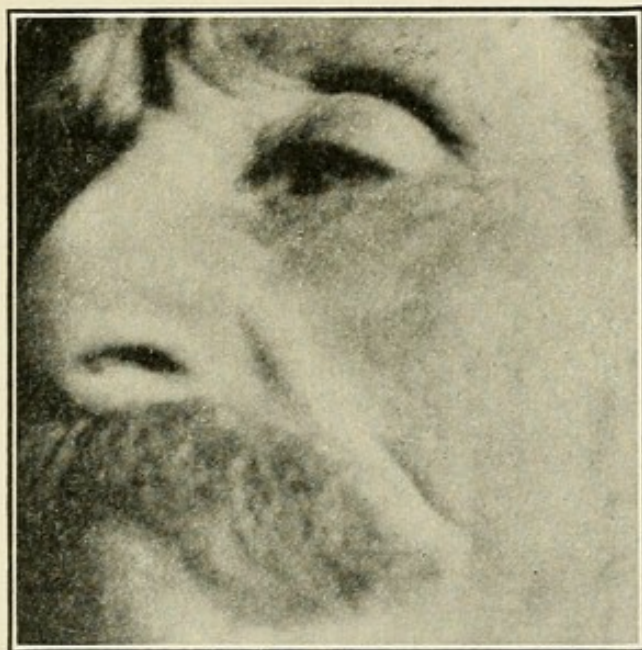


FIG. 27.—Case 234 after treatment, September 14, 1905.

July 18, 1908. Returns with both scars in perfect condition, but with a new growth, the size of a dime, high up on forehead at border of hair. This growth shows distinct evidence of malignancy in a raised base abundantly supplied with vessels. Minor application, 7 ma. for 30 minutes.

April 23, 1909. Patient visits office, showing no sign of the disease in either locality.

No. 307. ONCOLOGIC HOSPITAL. *Epithelioma of Scalp*.—T. J. O., aged 80, applied at dispensary February 5, 1906, with the growth shown in the photograph, Fig. 28. It had appeared eighteen months before, and had given rise to no sensation until within two or three months, when pricking sensations and itching developed. As the patient was quite feeble it was decided to attempt the removal of the growth

without general anesthesia, a bipolar minor application being used to lessen pain. A small negative surface was therefore held against the center of the growth, with patient reclining, and two small needles inserted into it near the base. Eighty milliamperes were gradually turned on and maintained for 45 minutes. After resting the patient went home. A microscopic

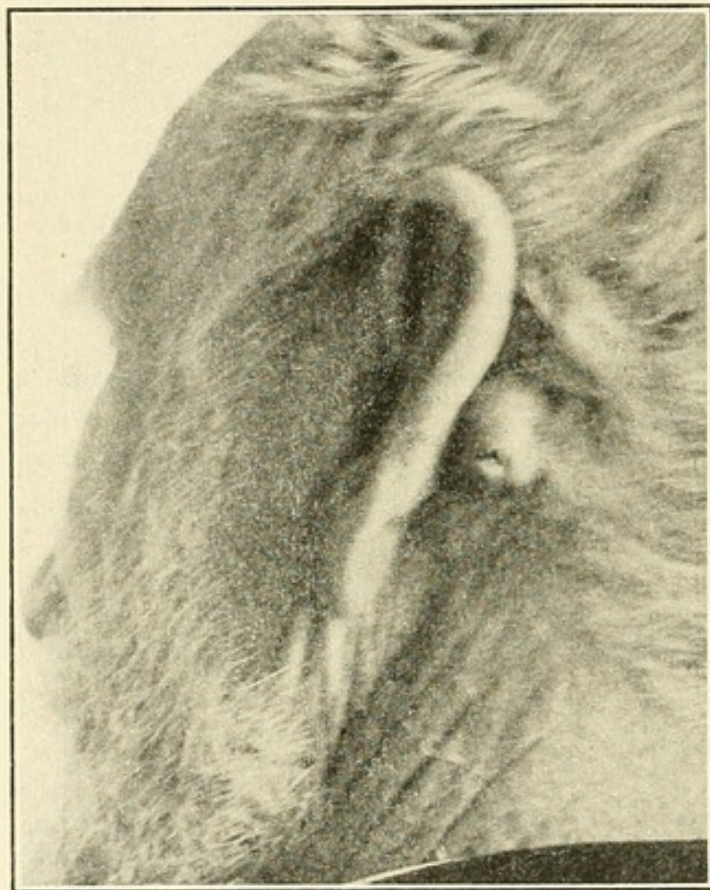


FIG. 28.—Case 307 before treatment, February 5, 1906.

examination showed the tumor to be a squamous-celled epithelioma.

February 15, 1906. Slough came away. Wound dressed with diluted zinc ointment.

March 15, 1906. Wound healed and showed no evidence of disease.

December 6, 1907. Visits dispensary, showing no evidence of disease. A photograph, Fig. 29, was taken at this time.

No. 328. ONCOLOGIC HOSPITAL. *Rodent Epithelioma of Forehead*.—Mrs. J. S. C., aged 56, was admitted to the dispensary March 29, 1906, with a patch of rodent epithelioma over left eye covering about one-third of forehead, superficial, with several areas that had cicatrized under Dr. Hartzell's

treatment. A spot at outer canthus of eye threatens invasion of the orbit.

She was placed under minor ionic applications, 4 ma. with 4 needles, and attended dispensary irregularly for 6 months, at end of which time there was but little disease evident, and that attacking outer canthus of eye quite healed over.

February 18, 1908. Patient returns with distinct relapse except at the corner of eye. As the x-ray had not been tried on this case, she was referred to Dr. Newcomet.

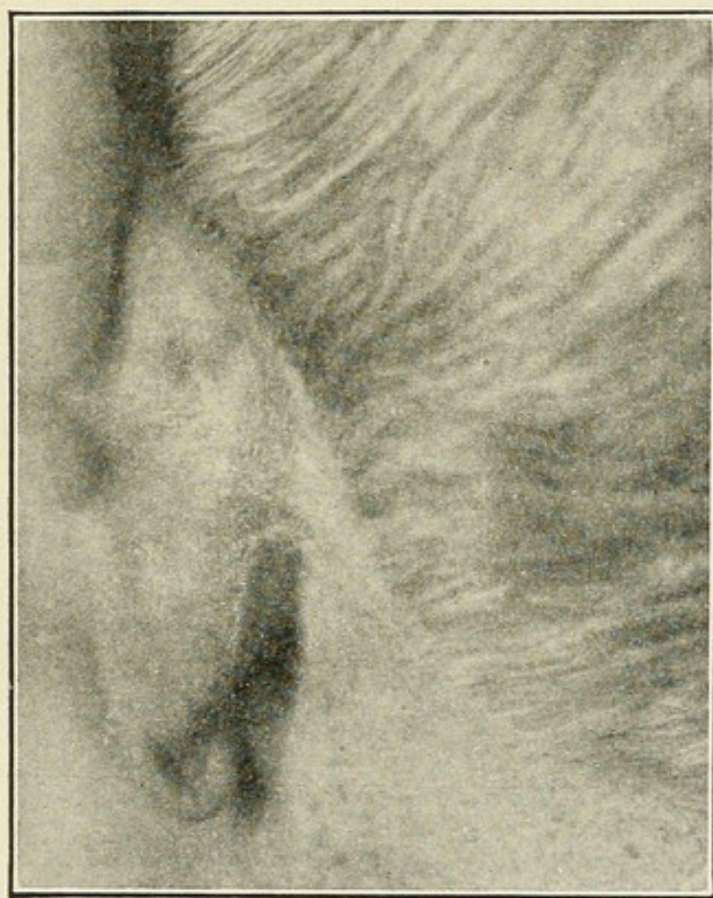


FIG. 29.—Case 307 after one bipolar application. Photograph taken one year and ten months later.

No. 42. ONCOLOGIC HOSPITAL. *Rodent Epithelioma of Face, Recurrent*.—Mrs. Z. R., aged 50, was referred by Dr. Addinell Hewson, May 5, 1906. The patient had been admitted to the hospital one year before and the disease, then recurrent, had been excised. It had existed three years before admission to Dr. Hewson's service, and had resisted various methods of treatment. X-ray treatment had been used for a time after excision.

On date above mentioned a major monopolar application of 200 ma. was made under general anesthesia. Some nodules of disease remaining after healing, the patient was placed under minor ionization treatment in the dispensary, from 1 to 3 ma. each, varied by three re-admissions to the hospital for major applications varying in strength from 25 to 100 ma. Patient still under observation and occasional treatment.

No. 347. ONCOLOGIC HOSPITAL. *Epithelioma of Cheek.*—Jas. O'D., aged 70, was admitted July 10, 1906, with the large fungating growth shown in Fig. 30. The growth began six

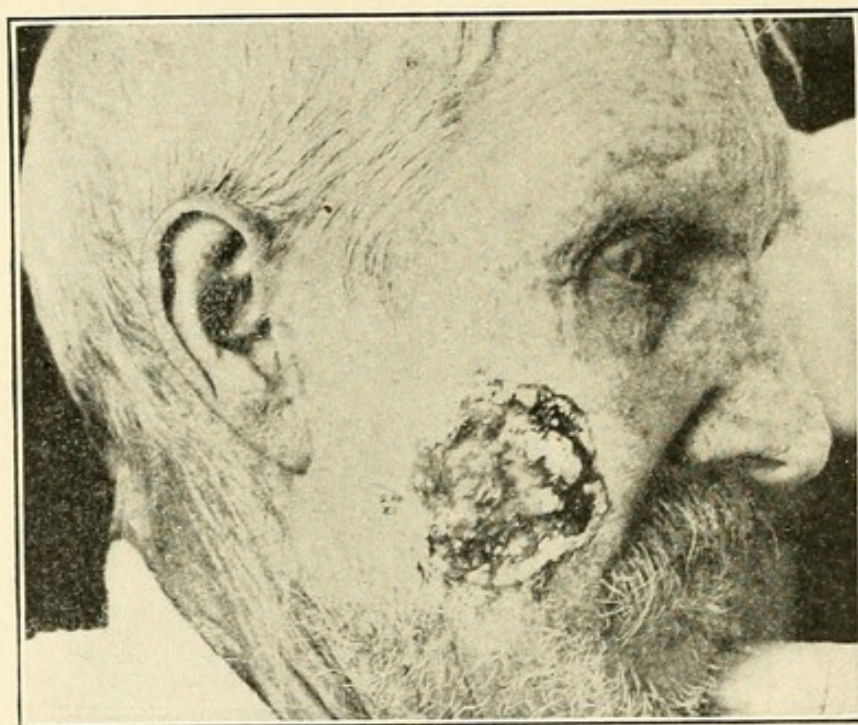


FIG. 30.—Case 347 before treatment, July 10, 1906.

years before, and has rapidly grown during the past year, in spite of x-ray treatment persistently applied for nine months. Unfavorable prognosis had been given by several prominent surgeons, who declined to operate. The microscopic examination showed squamous-celled epithelioma. The patient's arteries were rigid, and his general condition indicated senile degeneration.

July 11. The patient was placed under general anesthesia and a bipolar major application made of 500 ma. for 50 minutes.

August 21. Minor application of 18 ma. to suspicious spot.

August 23. Discharged from hospital to dispensary, with dead bone showing (Fig. 31).

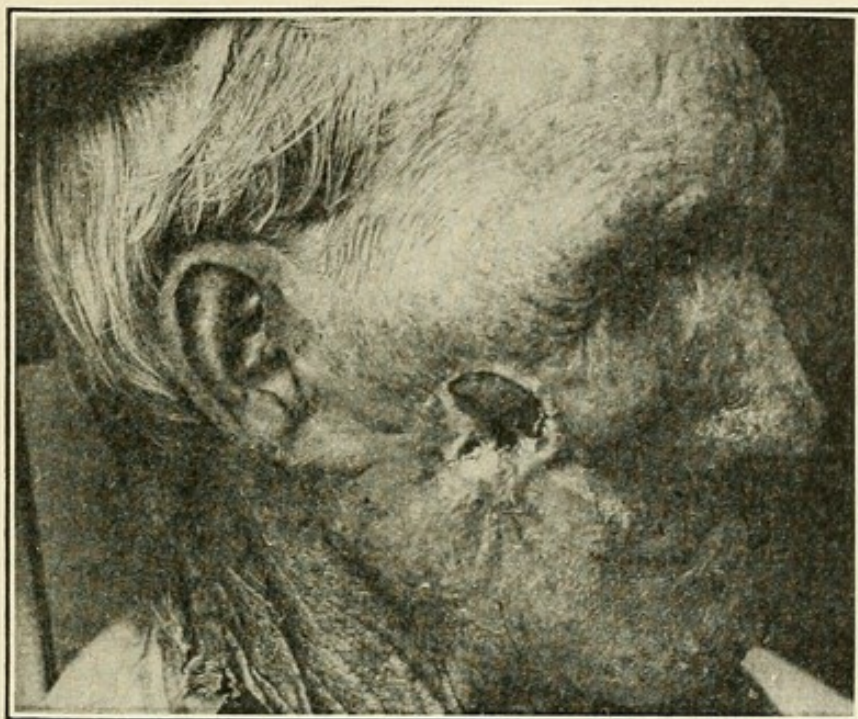


FIG. 31.—Case 347 after one major application. Dead bone showing in photograph taken August 23, 1905.

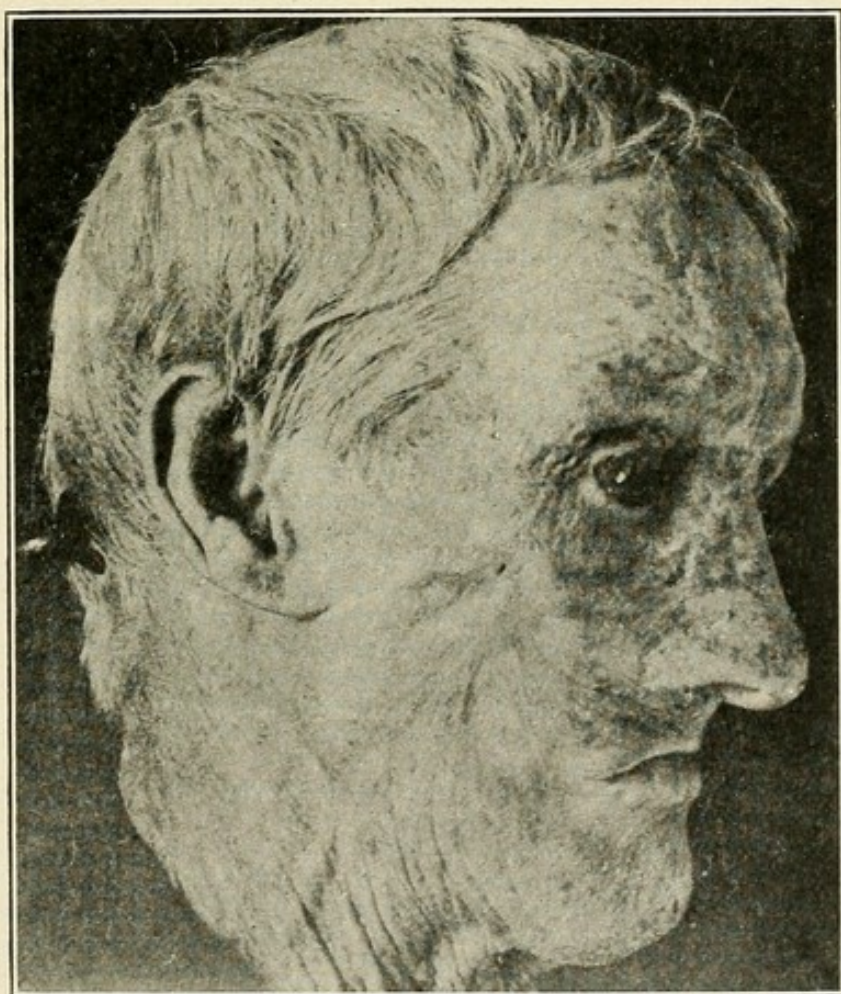


FIG. 32.—Case 347 after separation of bone and final healing. Photograph taken one year and three months after treatment.

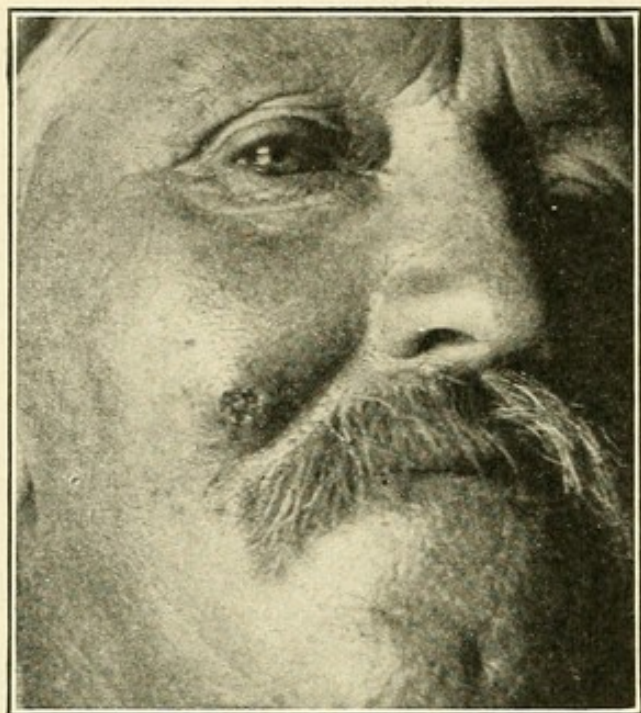


FIG. 33.—Case 364 before treatment, June 12, 1906.

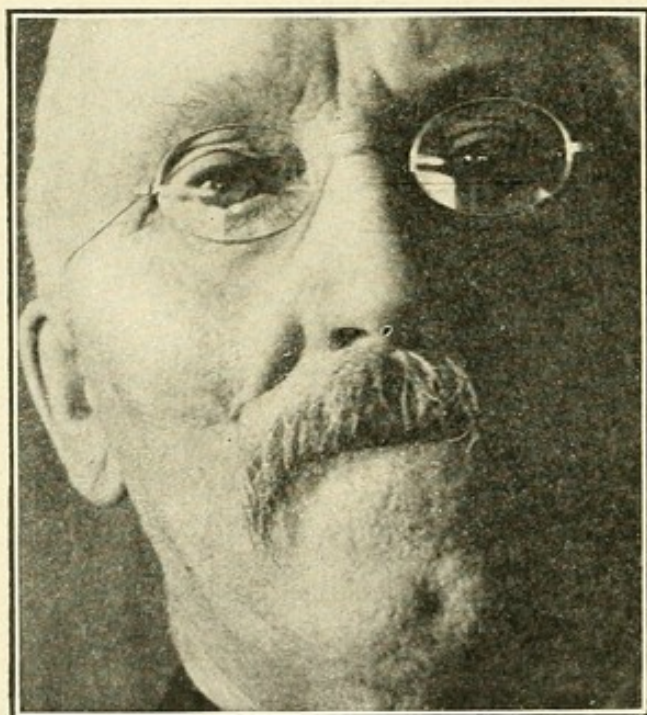


FIG. 34.—Case 364 after one dispensary application. Photograph taken five months later.

September 15. Dead bone removed. Edges of wound healthy.

December 2, 1907. Photograph taken (Fig. 32), showing no evidence of disease.

No. 364. ONCOLOGIC HOSPITAL. *Probable Epithelioma of Cheek*.—Robert T., aged 65, was brought to the dispensary by Dr. J. E. Hurff, of Blackwood, N. J., June 12, 1906. The growth (Fig. 33) had been increasing gradually in size since its first appearance, ten months before. Under local cocaine anesthesia a minor application was made reaching 80 milliamperes, 3 needles, for 45 minutes. No further treatment was required, the photograph (Fig. 34) being taken 5 months later. No recurrence reported in letter dated December 7, 1907.

No. 354. ONCOLOGIC HOSPITAL. *Epithelioma of Forehead*.—Mr. S. O., aged 67, clerk, admitted to hospital September 26, 1906. Four years ago the growth shown in Fig. 35 began, apparently as a result of a slight injury. A caustic plaster applied by an irregular practitioner two years later caused increased and more rapid growth. A specimen on examination was pronounced squamous-celled epithelioma.

September 26, 1906. Major bipolar application under general anesthesia, of 500 to 600 milliamperes for 25 minutes.

October 12. Slough removed, showing fibers of temporal muscle partly involved.

October 25. Discharged from hospital.

October 20, 1909. Patient reports at hospital by request, showing no evidence of disease. The photograph, Fig. 36, was taken at this time.

No. 369. ONCOLOGIC HOSPITAL. *Recurrent Epithelioma of Cheek*.—M. E. D., aged 74, was admitted to hospital July 6, 1906, with a growth beneath the left eye recurrent five years after removal by excision, which was done over six years ago. The growth was in the scar, and was about 2 x 2 cm. in size. Microscopic examination negative.

July 7, 1906. Major monopolar application, 200 ma. for 25 minutes.

July 24. Slough removed.

August 3. Discharged from hospital.

December 12, 1907. Reports in letter, by request, that the scar is healthy and shows no evidence of disease.

No. 399. ONCOLOGIC HOSPITAL. *Epithelioma of Forehead*.—Mrs. M. C., aged 72, was referred to the hospital from the Camden (N. J.) Almshouse, July 24, 1906, by Dr. J. E. Hurff. There was a large, fungating growth on the upper

portion of the forehead, about the right eye. Her general health was poor. Microscopic examination: carcinoma.

August 1, 1906. Major bipolar application, 500 ma. for 30 minutes.

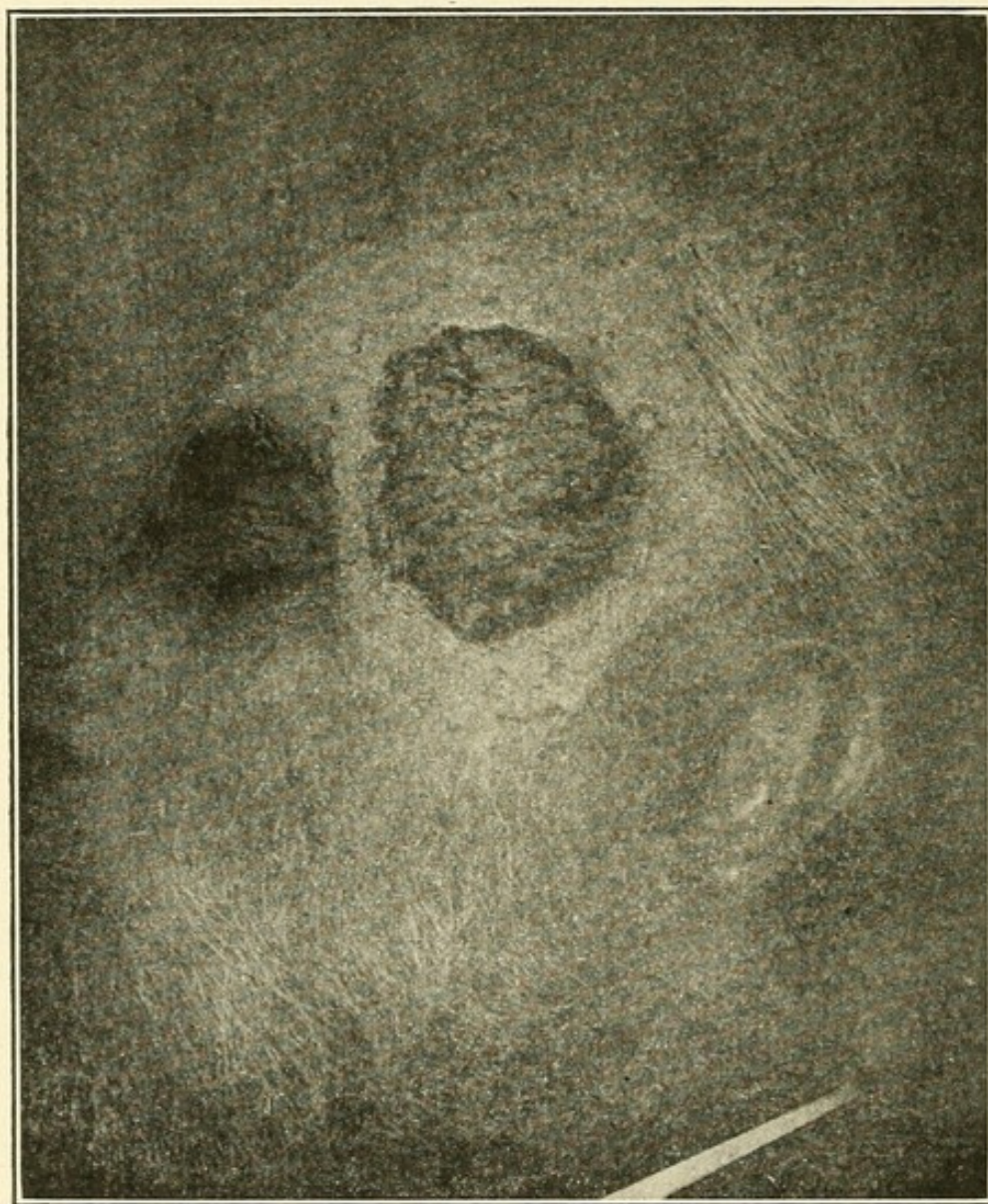

FIG. 35.—Case 354 before treatment, September 26, 1906.

August 28. Discharged from hospital with outer table of skull denuded, but general health improved. There was no evidence of disease remaining.

December 6, 1907. Dr. Hurff writes that the patient developed a growth of apparently similar character on the left side of face and died of an accidental fall. There was no local recurrence on the forehead.

No. 420. ONCOLOGIC HOSPITAL. *Epithelioma of Skin of*

Nose.—Mrs. C. Z., aged 77, was admitted August 24, 1906, with a protruding growth on the bridge of the nose about the size of a hazel nut. It had an indurated base and had been of slow growth (Fig. 37).

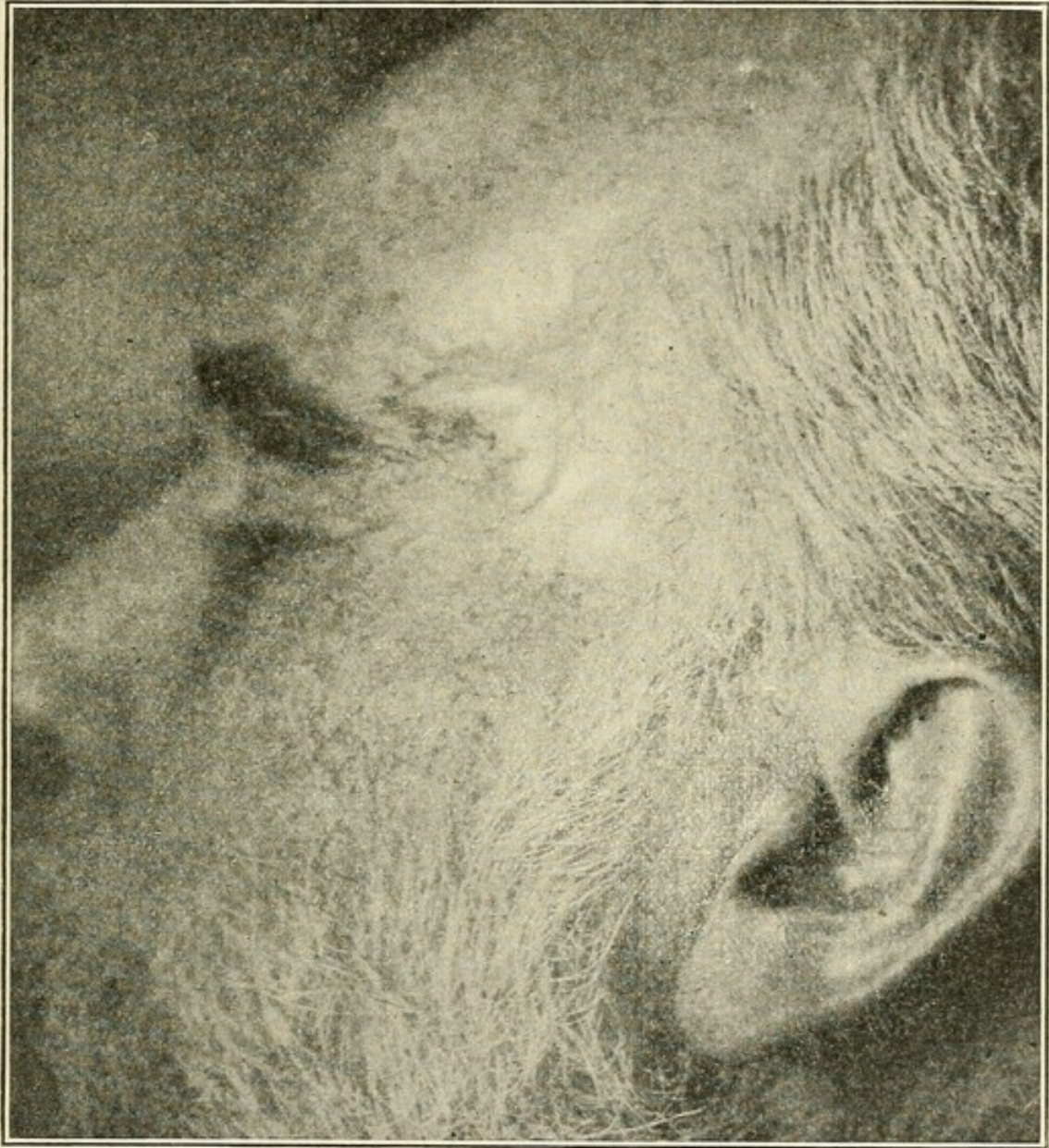


FIG. 36.—Case 354 after one major bipolar application, as scar appears three years later.

August 24, 1906.—Major monopolar application, 150 ma. for 25 minutes.

September 21. Discharged from hospital.

December 19, 1906. No evidence of disease remaining. Photograph (Fig. 38), taken at this time.

No. 426. ONCOLOGIC HOSPITAL. *Epithelioma of the Face.*

—Mrs. M. M., aged 72, was referred by Dr. John A. Steinwandel, of Philadelphia, September 13, 1906, with a fungating growth about the size of a silver dollar just below the left lower eyelid. It had existed for eight years, and had grown rapidly during the last six months.

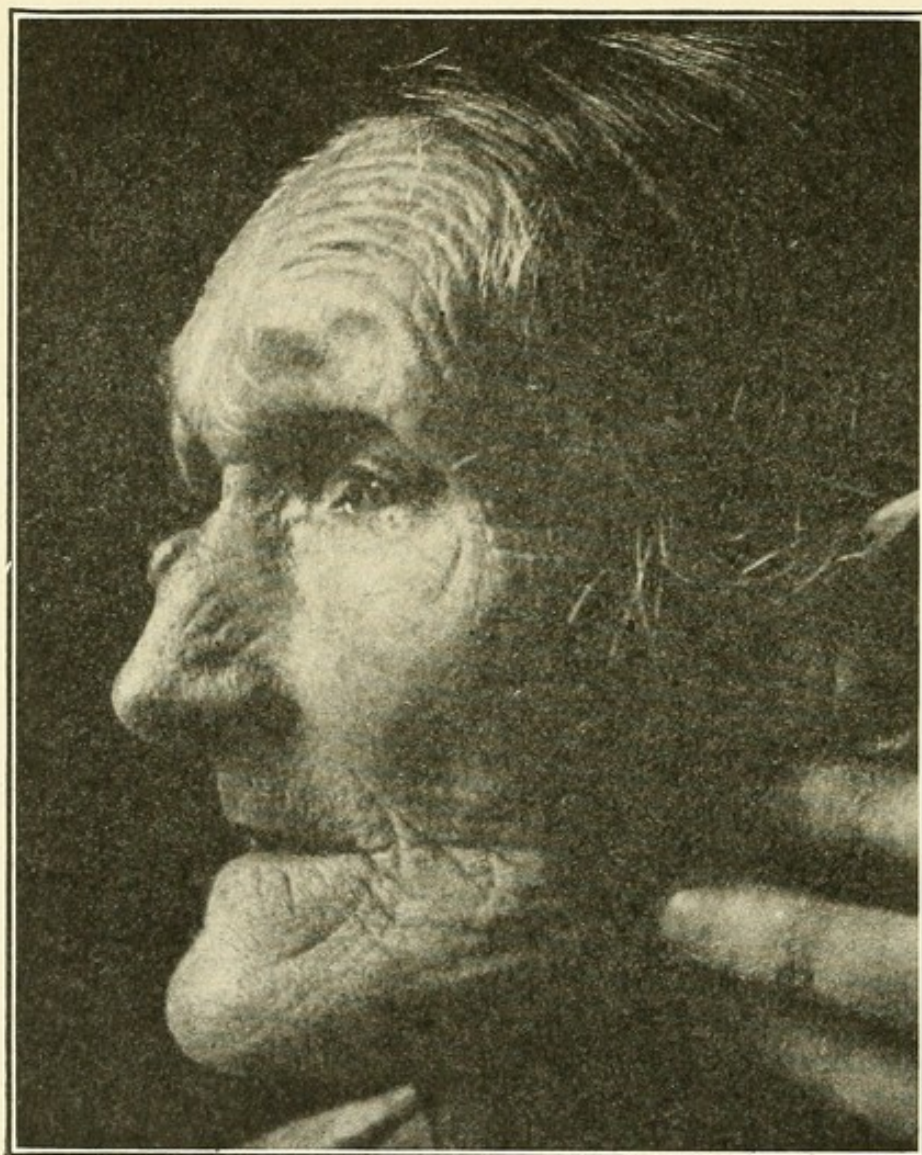


FIG. 37.—Case 420 before treatment, August 24, 1906.

September 19, 1906. Major bipolar application, 400 ma. for 20 minutes, under general anesthesia. On separation of the slough it was seen that some disease remained at the bottom of the wound, and the patient was placed on minor applications of 5 to 10 ma. daily. As she was restive under these applications, complaining of the pain they produced, a consultation of the staff advised the use of x-rays. The latter treatment appeared to be effective in the edges of the growth,

but failed to arrest the invasion of the orbit, which took place some months later, with apparent extension to the brain. In this condition the patient later committed suicide by leaping from the roof to a brick pavement.

No. 437. ONCOLOGIC HOSPITAL. *Probable Lupus of Face.*
—J. S., aged 48, was referred by Dr. G. H. Gildersleeve, of

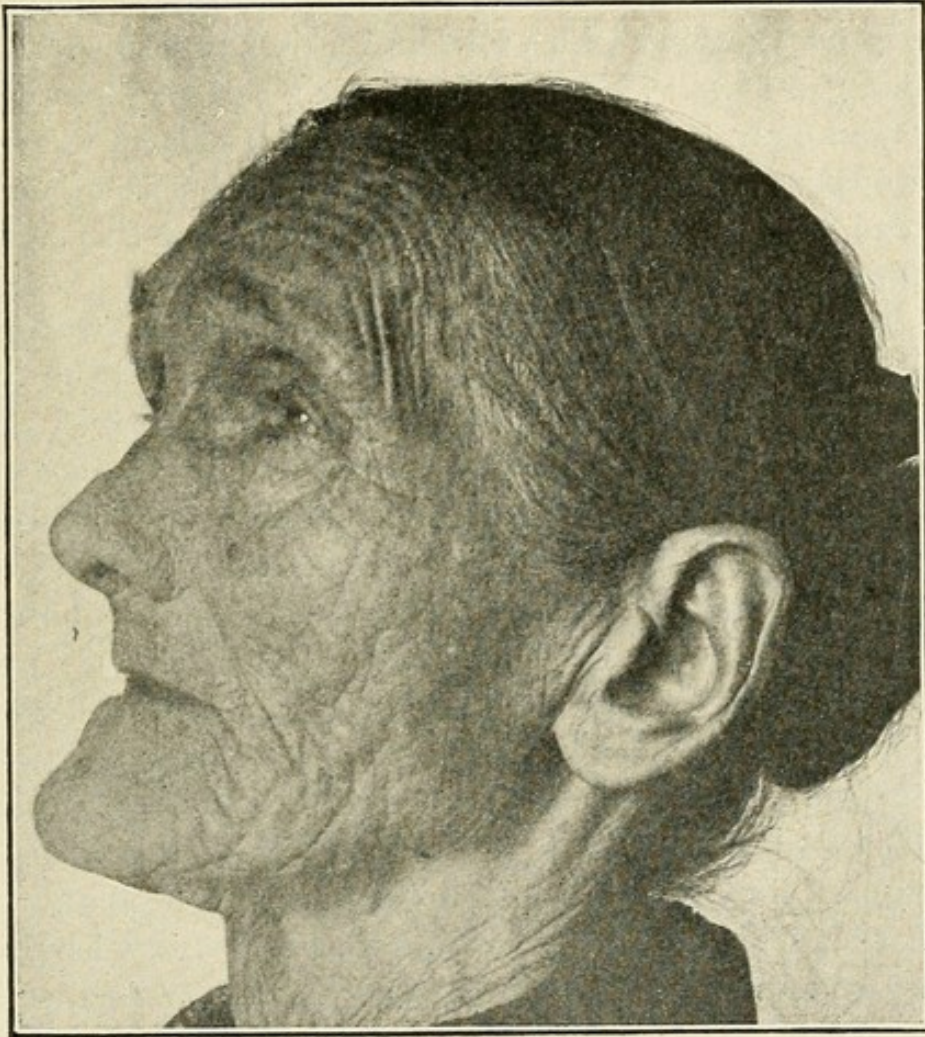


FIG. 38.—Case 420 after treatment, four months later.

Philadelphia, September 24, 1906, with an indolent ulceration on the cheek, below the inner canthus of left eye. It had raised, indurated edges, was about the size of a penny, and had been first noticed eighteen months before. Various caustic applications had been used ineffectually. Eight minor applications of 20, decreasing to 4 milliamperes, were made, and the patient discharged without manifest evidence of disease.

December 9, 1907. Patient reports at dispensary by request, showing no evidence of recurrence.

NO. 86, PRIVATE CASE BOOK. *Epithelioma of Cheek, Penetrating Mouth Cavity.*—Mrs. H. L., aged 85, was referred by Dr. W. H. Walling, of Atlantic City, N. J., September 30, 1906. A daughter had recently died of cancer of the breast. Twenty years ago a growth appeared in the middle of the left cheek, and it has gradually increased since. Three months ago it penetrated the mouth cavity.

There is an opening through the cheek into the mouth, $4\frac{1}{2}$ cm. long by $3\frac{1}{2}$ wide, with proliferating, indurated edges. No enlarged glands can be found in the neck, and the disease has not spread more than two or three centimeters from the edges of the opening. The patient is in good health considering her advanced years. Microscopic examination showed squamous-cell epithelioma.

September 30, 1906. A major bipolar application was made at the patient's residence, 300 to 400 milliamperes being used for 50 minutes, under chloroform. The negative electrode was a pigeon egg shaped electrode covered with absorbent cotton wet with dilute sulphuric acid and held in the opening against the edges of the growth, while the eleven needles used were inserted just beyond its periphery. The patient bore the operation well, the slough coming away in ten days.

December 4. The edges of the wound appear healthy, but there is an area above it, between the left eye and ear, which is indurated. This area is about the size of a quarter. A second bipolar application was made to-day to this area, 100 to 300 ma. being used for 35 minutes, with ten needles.

The slough of the second operation came away leaving a healthy wound, succeeded by a healthy scar. The further history of the original wound is as follows: During 1907 and to date of writing in 1909 the wound has continued to contract until now it is but 2 cm. long and a mere slit in width; its edges are healed over in the main, and there is no odor or discharge. To combat distinct evidences of recurrence in the edge next the ear she received seven minor applications in 1907 and four in 1908, averaging 5 to 7 milliamperes. Treatment finally abandoned owing to her feebleness.

NO. 442. ONCOLOGIC HOSPITAL. *Probable Epithelioma of Skin of Nose.*—Mrs. H. K., aged 70, was referred to dispensary by Dr. E. H. Farlow, of Laurel, Del., October 1, 1906, with a small growth on the bridge of the nose. One minor

application of 9 milliamperes for 15 minutes was made on above date. Patient reported at dispensary November 25, 1907, with perfect scar.

No. 467. ONCOLOGIC HOSPITAL. *Small Epithelioma of Eyelid.*—Mrs. O., aged 44, referred by Dr. Ladd, of Towanda, Pa., November 21, 1906. Six months before a small growth was noticed on the conjunctival border of lower right eyelid. On admission the lump was found to be about the size of a grain of wheat, with raised indurated base. It had grown rapidly during the past month. On above date 3 ma. was applied with two needles for half-hour.

December 17, 1906. Some of the disease remains. One milliampere for 20 minutes, two needles.

December 9, 1907. A remnant, size of small bird-shot, remains; $2\frac{1}{2}$ milliamperes for 25 minutes.

No. 473. ONCOLOGIC HOSPITAL. *Recurrent Rodent Epithelioma of Bridge of Nose.*—Mrs. S. R., aged 47, admitted November 20, 1906. The growth, which was an excavated ulcer with raised edges about 2 cm. in diameter, was situated on the bridge of the nose. It had first appeared three years before, and had been partly destroyed by arsenical paste 18 months before admission.

Major monopolar application November 26, 1906, 25 ma. for 15 minutes.

August 28, 1907. Minor application of 2 ma. for 10 minutes.

March 19, 1908. Called at hospital, showing no evidence of disease.

No. 483. ONCOLOGIC HOSPITAL. *Small Incipient Epithelioma of Eyelid.*—C. C. H., aged 39, admitted to dispensary December 3, 1906, with a painless growth on conjunctival border of lower right eyelid about size of a split pea. It had an indurated, raised base, with numerous blood vessels. It was not painful, had existed two months, and was slowly increasing in size. On admission, $1\frac{1}{2}$ milliamperes for 10 minutes, 1 needle.

January 1, 1907. Five ma. for 10 minutes.

January 19, 1907. Five ma. for 10 minutes.

No. 87, PRIVATE CASE BOOK. *Senile Epithelioma of Skin of Nose.*—H. C., aged 82, was referred by Dr. J. Gaunt Edwards, of Williamstown, N. J., December 2, 1906. His mother had

cancer of the shoulder. For 18 months he had had a scabby growth on the tip of the nose. Eight months ago a raised and indurated base about the size of a dime appeared beneath the scab.

December 8, 1906. Minor application, 5 to 6 ma. for one hour.

June 10, 1909. Patient visits office with perfect scar, and no recurrence.

No. 509. ONCOLOGIC HOSPITAL. *Epthelioma of Forehead and Upper Eyelid*.—Jas. R., aged 58, railroad foreman, was

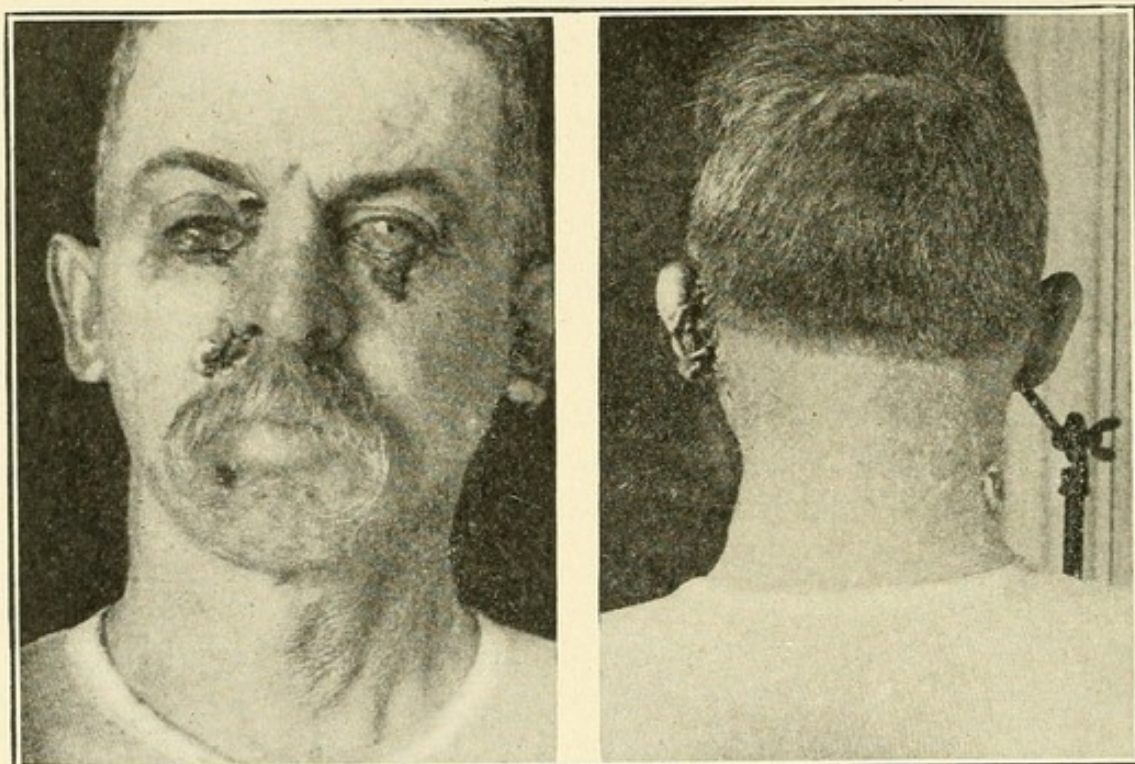


FIG. 39.—Front and rear views of case 529 before treatment, March 30, 1907.

referred by Dr. Alex. P. O'Malley, of Wilkes Barre, Pa., July 7, 1906. Six or more years before he had been wounded in the forehead by a hot coal from the smokestack of a locomotive; a growth appearing later in the unhealed wound. Dr. O'Malley had treated the growth with caustics and fuming nitric acid, with some benefit, but patient had been irregular in attendance. Bipolar electrolysis had recently been used by Dr. O'Malley.

July 8, 1906. Major monopolar application, 150 milliamperes, 30 minutes, to supra-orbital region. Palpebral portion left for minor applications owing to nearness of eyeball.

During July and August twenty-two minor applications made of 5 to 10 milliamperes for 30 minutes each.

October 2, 1906. Patient sent home temporarily, greatly improved.

February 4, 1907. Readmitted for minor applications.

September 22, 1907. Patient went home against advice. Minor applications had so far failed to eradicate disease close to eye, but supra-orbital region remains free of disease. X-ray advised at his home.

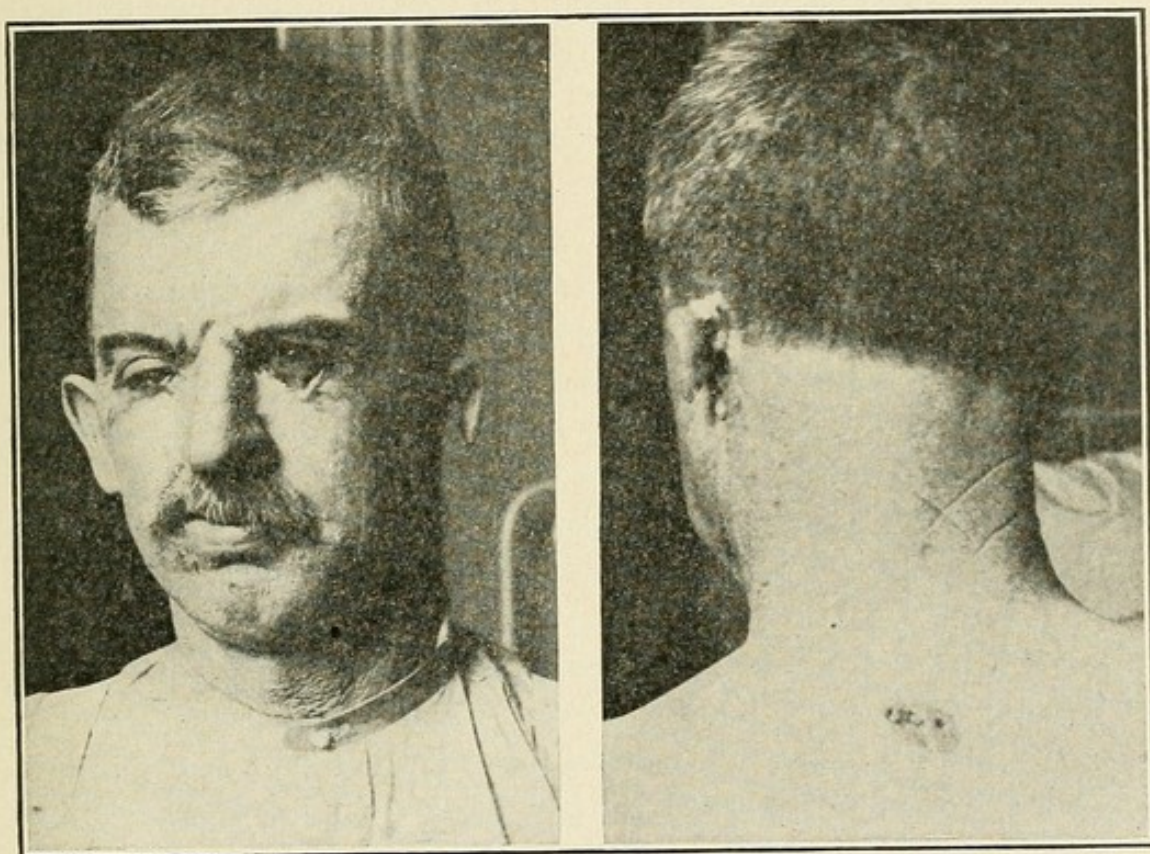


FIG. 40.—Views of case 529 four months later.

No. 529. ONCOLOGIC HOSPITAL. *Multiple Recurrent Epitheliomas of Face, Ear, and Neck.*—I. P., aged 45, referred by Dr. Williams, of Danville, Ill., March 30, 1907, with the multiple epitheliomas beneath each eye, at the side of the nose, behind each ear, and in the neck, shown in Fig. 39. The growths were first noticed twelve years before, and those beneath the eyes had been removed ten years ago, ineffectually.

The lower lids of both eyes had been destroyed, the growth extending into the orbit of right eye beneath the conjunctiva.

But little normal tissue remained in one ear. There were other nodes of growth about face and neck of small size, totaling 12 or 13 separate centers of growth.

A microscopic examination showed the growths to be squamous-celled epithelioma.

April 1, 1907. Major monopolar application under ether. With several points in growth beneath right eye the current was brought up to 250 milliamperes, some needles being later transferred to growth beneath left eye, while the current was gradually raised to 400 milliamperes. With careful watching no spot received too much current. Later, during the application, the needles were transferred, one at a time, to other foci, during a total monopolar application of 1 hour and 20 minutes. A bipolar application of 400 to 700 milliamperes for 26 minutes was then made to the growths back of the ears, beneath the nose, and on the neck.

During May and June the patient received six minor applications to smaller centers of growth not reached in the major application, with currents varying from 3 to 8 milliamperes for a half-hour each, and Dr. McClary made a plastic operation to improve the appearance of the left ear.

August 16, 1907. Discharged without manifest evidence of disease. The photographs shown in Fig. 40 were taken at this time.

December 22, 1907. Letter received from patient states that there is no evidence of disease recurring.

August 16, 1908. Patient returns for treatment of a minute recurrence in inner canthus of right eye and on the back, in scar shown in Fig. 40. All other scars healthy.

No. 542. ONCOLOGIC HOSPITAL. *Senile Epithelioma of Skin of Face*.—B. R. B., aged 78, was referred by Dr. Glenn, of Berwick, Pa., April 18, 1907, with several scaly epitheliomata on the right side of the face. They had been present for twenty years, and had resisted caustic applications.

April 18, 1907. Minor application of 10 milliamperes for 30 minutes.

May 4, 1907. Minor application, 3 milliamperes for 30 minutes.

May 21, 1907. Discharged temporarily.

December 3, 1907. Reports by letter that one spot size of pea still persists.

February 3, 1908. Readmitted with recurrence size of a split pea. Minor application, 3 milliamperes for 40 minutes.

No. 546. ONCOLOGIC HOSPITAL. *Recurrent Epithelioma of Face*.—J. M., aged 76, admitted to dispensary April 22, 1907, with a granular recurrence about scar of wound made in operation for removal of growth near left angle of mouth. The growth was of twelve years' duration, and had been removed at two local hospitals. It had been increasing somewhat rapidly during the past year.

During April, May, June, and August, 1907, the patient received twenty-six minor applications (with 2 or more needles) of 2 to 10 milliamperes for 30 minutes each. The treatment was painful on account of the superficial nature of the growths, and when it had been decided to resort to x-ray applications the patient abandoned treatment, somewhat improved.

No. 555. ONCOLOGIC HOSPITAL. *Small Epithelioma of Skin of Face*.—Mrs. M. A. W., aged 55, was referred by Dr. G. Oram Ring, of Philadelphia, May 13, 1907, with a scaly epithelioma just beneath left eye about the size of a grain of wheat. It had been under x-ray treatment for a year at the Episcopal Hospital, the original size having been $1\frac{1}{2}$ cm. The improvement had ceased on contraction to its present dimensions.

May 13, 1907. Minor application, 2 ma. for 25 minutes.

March 7, 1908. Patient reported at hospital by request. No evidence of disease to be found.

No. 89, PRIVATE CASE BOOK. *Epithelioma of Inner Canthus of Right Eye*.—R. H., aged 76, was referred by Dr. C. A. Groff, of Philadelphia, May 20, 1907. The erosion, with indurated edges, shown in Fig. 41, had been first noticed two years ago, and had resisted ordinary treatment.

May 20, 1907. Minor application, 20 milliamperes for $\frac{1}{2}$ hour, 4 needles.

September 10, 1908. Patient visits office by request, with excellent wound. The photograph, Fig. 42, was taken at this time.

May 20, 1909. Patient reports, with no return of disease.

No. 582. ONCOLOGIC HOSPITAL. *Recurrent Epithelioma of Skin of Nose*.—Mrs. A. B. C., aged 45, was referred to dispensary by Dr. G. H. West, of Philadelphia, with a scar on

the side of the nose with edges in which nodular masses were evident. An attempt had been made by the patient to have the growth removed by caustics.

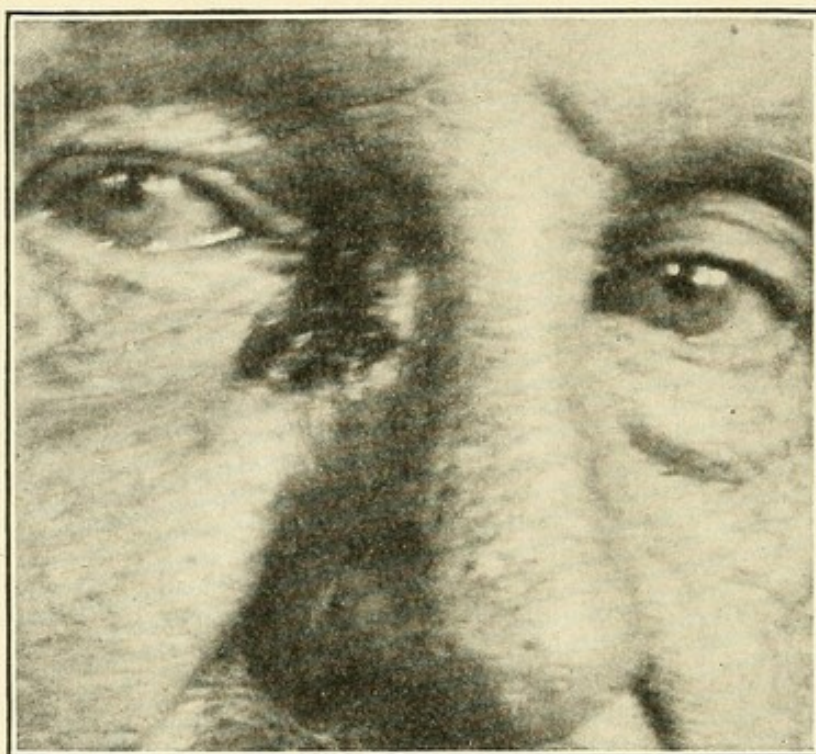


FIG. 41.—Case 89 before treatment.

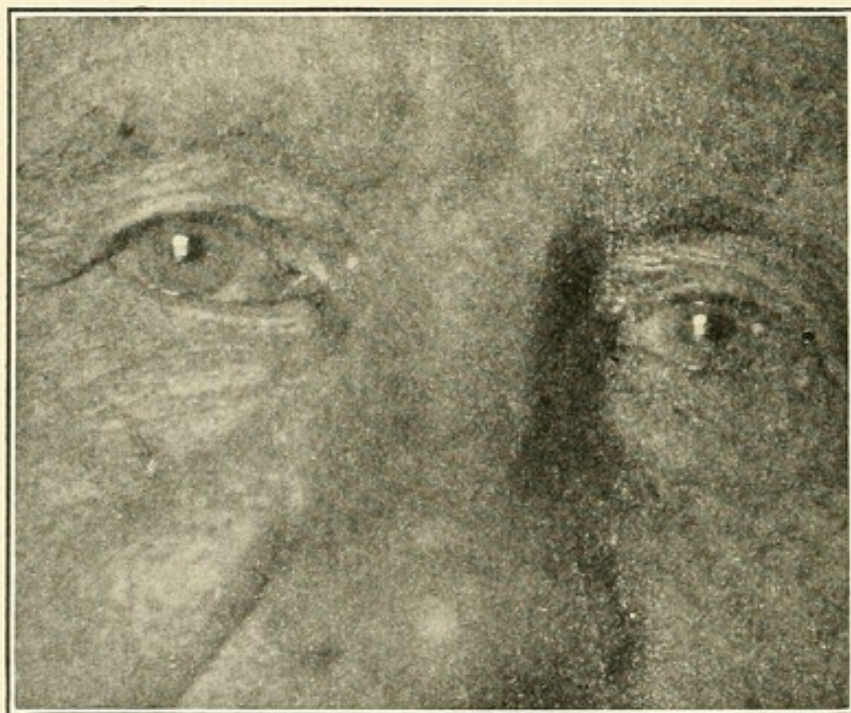


FIG. 42.—Case 89 one year and four months later.

June 27, 1907. Minor application, 4 milliamperes for 20 minutes.

June 27, 1907. Minor application $2\frac{1}{2}$ ma. for 15 minutes.

June 3, 1909. Patient reports at office, with no return of disease.

No. 606. ONCOLOGIC HOSPITAL. *Recurrent Epithelioma of Face.*—O. B., aged 73, was admitted from the Soldiers' and Sailors' Home at Erie Pa., August 30, 1907, with a large growth on the left side of the face. The patient had a caustic paste applied to an epithelioma of the upper lip one year before, the present growth appearing only two months ago. It has grown rapidly during the last two weeks. The patient is feeble, and suffers from locomotor ataxia.

A microscopic examination showed the growth to be an epithelioma.

September 3, 1907. Major bipolar application, 1,100 milliamperes for 10 minutes.

September 24, 1907. Second major bipolar operation, 900 to 1,100 ma. for 18 minutes.

October 7 to 30, 1907. Fourteen minor applications have been made to remnants of disease, 30 to 40 milliamperes each, for 30 minutes.

November 1, 1907. Third major bipolar operation, 1,200 to 1,400 ma. for 20 minutes.

December 2 to 18. Five minor applications. The patient developing evidences of pulmonary tuberculosis was referred to Dr. Codman of the hospital staff. He died January 3, 1908. The autopsy, made by Drs. McClary and Codman, revealed a cavity in right lung, the size of a hen's egg, with old adhesions.

No. 607. ONCOLOGIC HOSPITAL. *Probable Lupus of Face.*—W. H., aged 69, was admitted from the Soldiers' and Sailors' Home at Erie, Pa., August 30, 1907, with an indolent, infiltrated growth of the skin of the right temple the size of a silver quarter. It had existed five years, and resembled lupus in clinical features.

September 3, 1907. Major monopolar application, 100 to 200 milliamperes for 30 minutes, with 5 needles.

November 2, 1907. Discharged with healthy scar.

No. 92, PRIVATE CASE BOOK. *Small Squamous-Celled Epitheliomas of Face.*—P. S., aged 38, ironworker, applied November 12, 1907, with a small, raised growth on right cheek about the size of a pea, with overlying crust and raised base.

Specimen removed by scissors and minor application of 15 ma. for 16 minutes, six fine needles, under local use of cocaine.

Microscopic examination: epithelioma.

August 10, 1909. Visited office with healthy scar, and no recurrence.

No. 653. ONCOLOGIC HOSPITAL. *Rodent Epithelioma of Inner Canthus of Eye*.—Mrs. M. R., aged 67, was referred by Dr. J. Gaunt Edwards, of Williamstown, N. J., November 23, 1907. The growth was a characteristic rodent cancer of the inner canthus of the left eye (Fig. 43), about the size of a

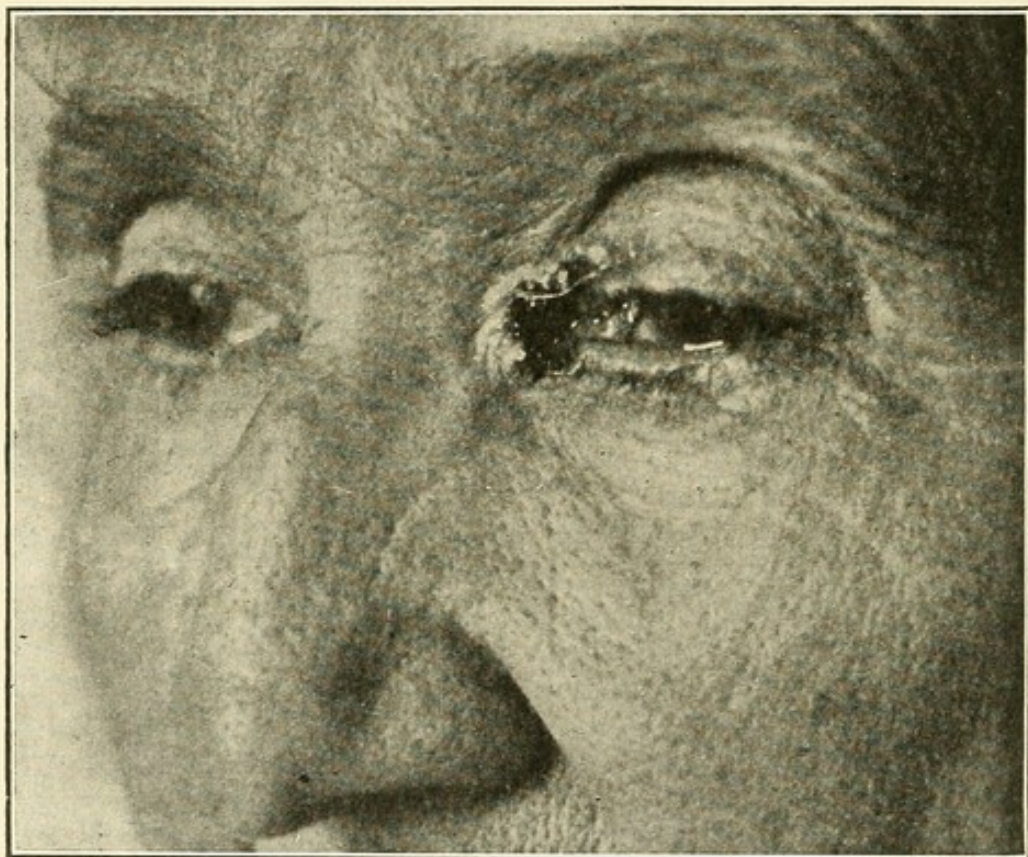

FIG. 43.—Case 653 before treatment, November 23, 1907.

copper cent, and had existed for 8 years. No previous treatment had been employed.

A microscopic examination showed the growth to be a squamous-celled epithelioma.

November 25, 1907. Major monopolar application under chloroform. Fifty to sixty milliamperes were used for 20 minutes, with 5 needles; then 25 milliamperes for 10 minutes longer.

November 30, 1907. Photograph (Fig. 44) taken, showing slough in position.

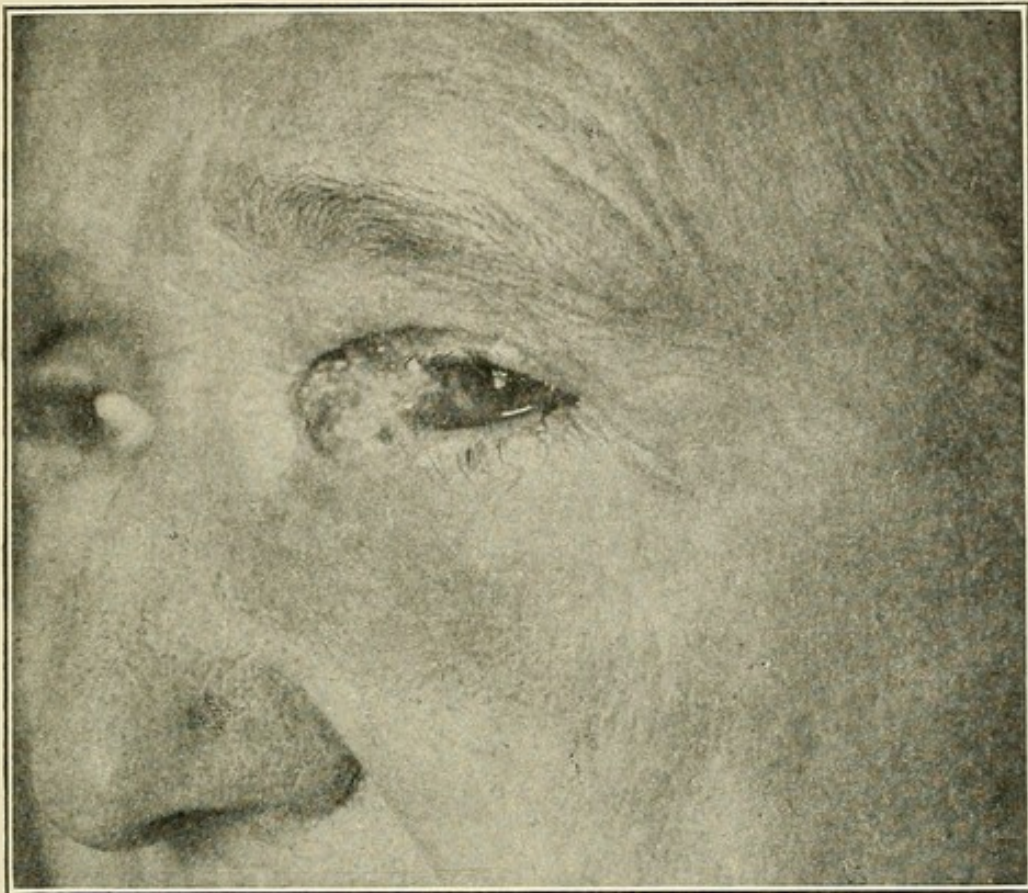

FIG. 44.—Patient shown in Fig. 43 five days later, showing slough in position.



FIG. 45.—Patient shown in Fig. 43 as part appears two years later.

December 5, 1907. Discharged with wound in good condition.

January 23, 1908. Photograph (Fig. 45) taken, showing complete healing.

November 26, 1909. Patient visits office with healthy wound and no evidence of recurrence. Dr. Ring finds nasal duct closed.

No. 709. ONCOLOGIC HOSPITAL. *Endothelioma of Eyelids*

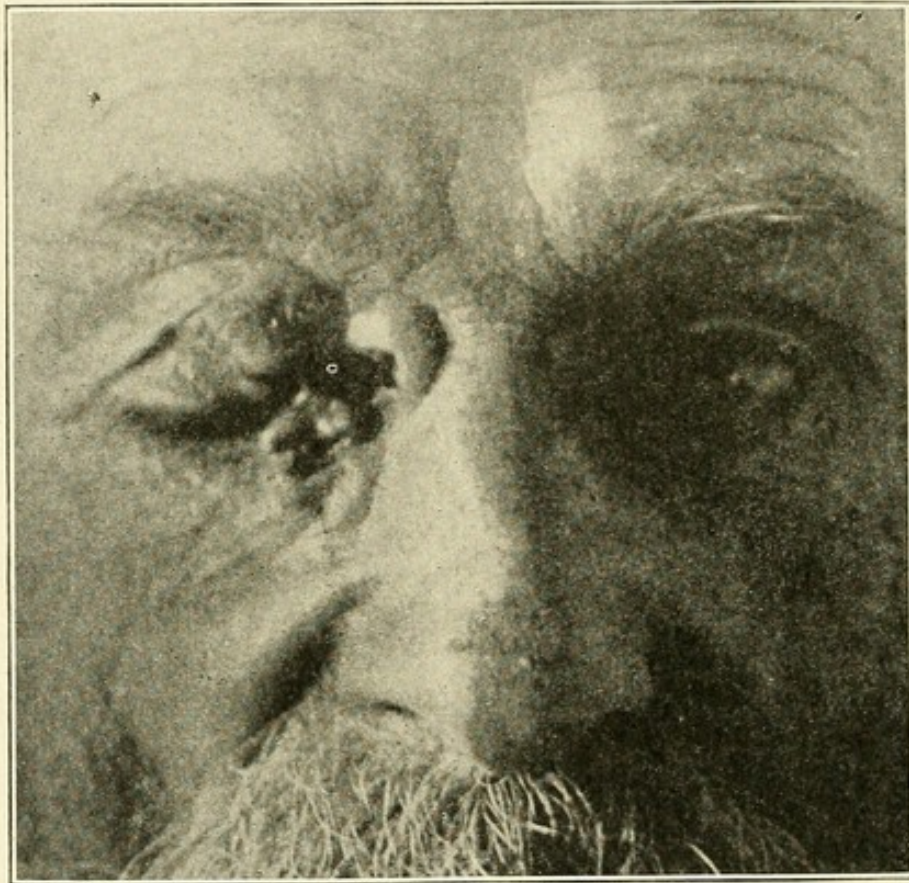


FIG. 46.—Endothelioma of eyelids. Case 709 before treatment.

at Inner Canthus.—B. W., aged 64, was admitted from Seymour, Indiana, March 12, 1908. Of negative personal and family history, and excellent general health, the present growth was noticed eleven years ago, having increased more rapidly during the past four years.

Examination shows a proliferating, ulcerating growth at the inner canthus of the right eye (Fig. 46), with three extensions: towards the bridge of the nose, and in either eyelid. The nasal extension and that in the lower eyelid were ulcerated. The conjunctiva is superficially hazy, and the upper lid could not be raised voluntarily above the pupil. Dr. Swan

reported as follows of a specimen removed before operation: The tumor is composed of collections of cells around trabeculae of connective tissue containing blood vessels. The cells vary in shape and size, the majority of them looking like large round cells, a few like spindle cells. In places the tumor shows blood spaces of varying size, some with and some without an endothelial wall. In other parts of the growth there are distinct hemorrhagic areas. Diagnosis: endothelioma.

Operation.—March 12, 1908. Monopolar application of 150 milliamperes for 50 minutes, with 3 to 8 fine zinc-mercury needles, under general anesthesia, care being observed to limit




FIG. 47.—Case 709 one year after treatment.

the ionic destruction strictly to the diseased tissue. The eye was dressed with boric acid solution immediately after the operation.

Inspection the next day showed that the eyeball was in a healthy condition and the diseased parts well devitalized. On the 17th the boric acid solution was changed to a drop of atropine solution, 14 gr. to oz., washed out ten minutes later by 10 per cent. argyrol solution twice a day. April 4 the boric acid solution compress was changed to 20 per cent. zinc oxide ointment. On April 9 the slough came away, showing an excellent condition except in the nasal side of the wound, where doubtful granulations received minor applications of 5

to 10 milliamperes on six occasions during the remainder of April; of 1 to 3 milliamperes on seven occasions during May; of 4 milliamperes on one occasion in June; and of 2 milliamperes each on one occasion each in July, August and September. After the latter he returned to his home, without manifest evidence of disease.

February 3, 1909. Letter received, inclosing photograph (Fig. 47), taken just previously. The patient states that the eyelids can be opened and closed at will, and that the sight is

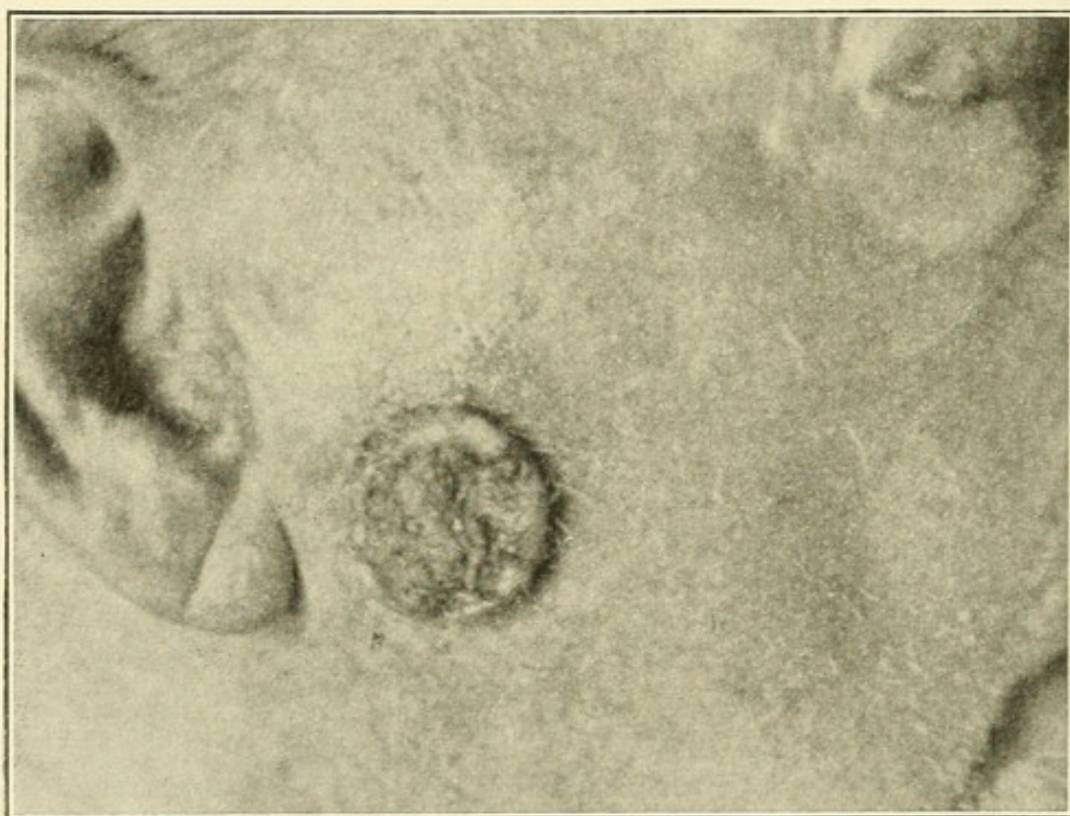


FIG. 48.—Epithelioma of face before ionic treatment. Case No. 763.

excellent. There is no sign of recurrence. A further report in November, 1909, states there is no sign of a return of the growth.

No. 719. ONCOLOGIC HOSPITAL. *Recurrent Epithelioma of Skin of Nose*.—Mrs. A. H., aged 82, was admitted March 23, 1908. Ten years ago she first noticed a growth on the ala of the left nostril. It has been removed twice by excision, the last operation having been done one year ago.

The left ala of the nose has been removed. Extending upwards from the scar, there is a large ulcerated area about the size of a one cent piece, covered with a thick dry crust.

Under consultation the x-ray treatment was advised, as less painful for the aged patient. She was therefore referred to Dr. Newcomet, who removed the crust after applying a poultice of green soap, and began x-ray treatment in 10 minute sittings at 10 inches. Forty-nine applications of the rays were made between the date of admission and June 22, at which time she was sent home to give time for the effect of the rays to fully develop. At this time the ulceration was better, with but a few patches left. A boric-bismuth-lanolin ointment was prescribed.

October 20, 1908. Patient referred back to author by Dr.

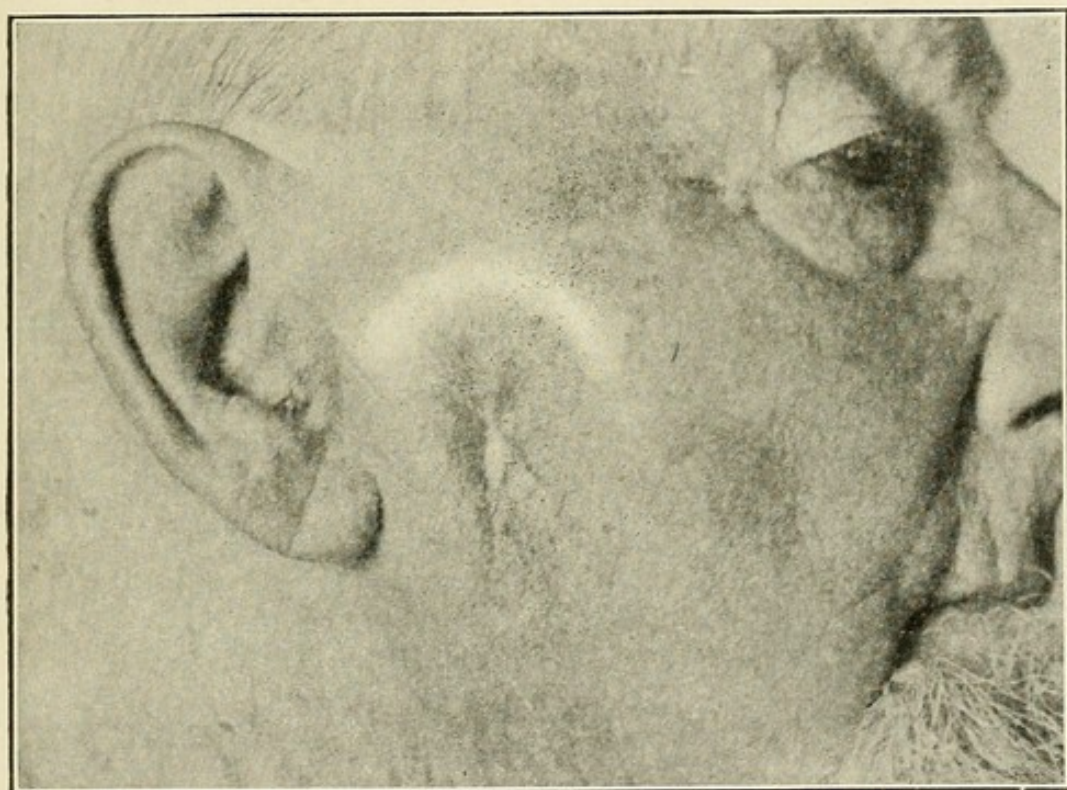


FIG. 49.—Case 763 one and a half years after treatment.

Newcomet, with central portion of the scar showing an ulceration 2 cm. long. With cocaine dropped on the part she was well able to stand a current of 5 ma. for thirty minutes. The subsequent treatments were as follows: November 10, 4 ma. for 30 minutes; November 17, $1\frac{1}{2}$ for half hour; November 20, 2 for 20 minutes; November 23, $1\frac{1}{2}$ for 20 minutes; December 2, $1\frac{1}{2}$ for 15 minutes; December 8, $1\frac{1}{2}$ for 15 minutes; December 10, $1\frac{1}{2}$ for 15 minutes; December 13, $1\frac{1}{2}$ for 15 minutes; January 7, 1909, 1 ma. for 15 minutes; January 14, $\frac{1}{2}$ ma. for 20 minutes. The patient was discharged with

a well healed scar February 11, 1909, and reports no return of the disease in November, 1909.

No. 763. ONCOLOGIC HOSPITAL. *Epithelioma of Face*.—J. F. L., aged 87, was referred to the service of Dr. Codman by Dr. A. W. Ransley of Philadelphia, June 3, 1908. The growth shown in Fig. 48 was first noticed two years ago. It had been treated by caustic pastes and the x-ray.

On the right cheek, at the base of the parotid gland, there is a proliferating epithelioma with an area equal to the size of a 25-cent piece and projecting one inch above the level of the skin. The entire right cheek seems more prominent than the left. Dr. Codman referred the patient to Dr. Newcomet for x-ray treatment.

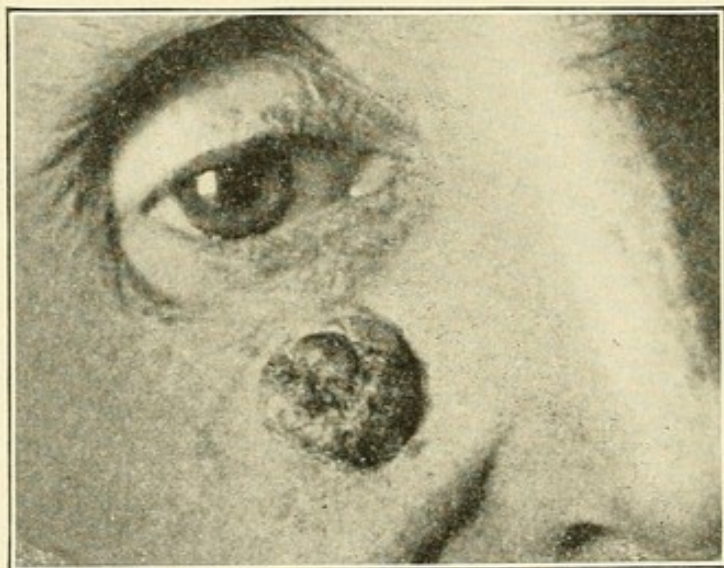


FIG. 50.—Carcinoma of face before ionic treatment. Case 765.

July 8, 1908. Patient referred to the author by Dr. Newcomet for ionic treatment. Minor application, 17 milliamperes for 30 minutes. During the remainder of the month five applications were made, decreasing from 18 milliamperes to 10. During August there were five applications, varying from 16 to 6 milliamperes; during September eight, of 10 to 6 milliamperes; and during October one of 10 milliamperes.

October 13, 1908. Patient discharged from further treatment with an excellent scar and no sign of disease. The photograph, Fig. 49, was taken at this time.

November 16, 1909. Patient visits dispensary by request. The scar is fully as healthy and somewhat less visible than ap-

pears in the second photograph. The patient is in the best of health, in spite of his more than 88 years.

No. 765. ONCOLOGIC HOSPITAL. *Epithelioma of Face*.—Mrs. E. C., aged 53, was referred by Dr. L. E. Taubel of Philadelphia, June 4, 1908. Two and a half years before she had been struck by a toy thrown by a child, and the abrasion made never healed. Five weeks ago a rapid increase in size was noted.

There is a firm, nodular growth on the right cheek immediately below the eye, about the size of a flattened marble (Fig. 50). Pathologic diagnosis by Dr. Swan: carcinoma.

June 9, 1908. Minor application in dispensary, 20 milli-

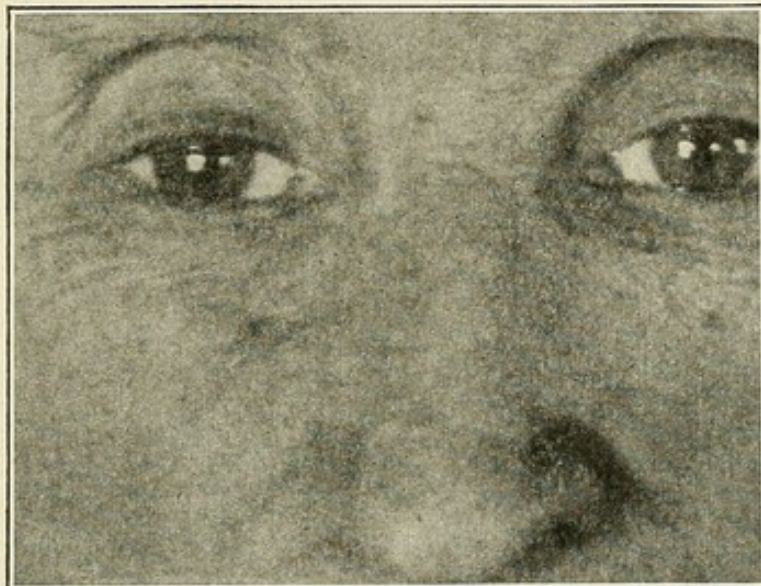


FIG. 51.—Case 765 as part appears one and a half years after treatment.

amperes bipolar for 15 minutes, changed then to 25 milliamperes for an additional 15 minutes, monopolar, under local cocaine. Additional applications were as follows: July 27, 11 ma. for 30 minutes; August 10, 3 ma. for 30 minutes; August 21 and 24, 2 ma. for 30 minutes; September 2, 18, 25 and 29, 2 ma. for 30 minutes; October 6 and 20, 2 and 3 ma. for 30 minutes each.

October 27, 1908. Patient examined, showing no sign of disease.

November 12, 1908. Photograph (Fig. 51) taken.

November 18, 1909. Patient visits dispensary with no sign of recurrence.

No. 855. ONCOLOGIC HOSPITAL. *Epithelioma of Face.*—
W. H. B., aged 53, was referred by Dr. B. F. Coulter of




FIG. 52.—Epithelioma of face before treatment. Case 855.




FIG. 53.—Case 855 one year after treatment.

Philadelphia, December 4, 1908. A red pimple was first noticed on the left cheek four months ago, and it has increased

steadily in size since. It is not tender and has given no pain.

There is a raised, red tumor in the middle of the left cheek, $1\frac{1}{2}$ cm. in diameter and projecting 1 cm. above the surface, with indurated base (Fig. 52). Palpation indicates that it is probably cystic. Pathologic examination by Dr. Swan: epithelioma.

December 7, 1908. Minor application, 15 to 20 milliamperes for 50 minutes, 4 needles. On puncturing the tumor it was found to be more solid than appeared, bleeding freely. There was no evidence of a cyst.

December 30. Small slough has separated and wound seems healthy. Patient directed to return once a week for inspection.

January 20, 1909. Patient discharged from dispensary, without manifest evidence of disease.

February 19, 1909. Photograph (Fig. 53) taken, showing no sign of recurrence.

November 17, 1909. Patient visits dispensary, showing no sign of recurrence.

SUMMARY OF SECOND SERIES OF FACE AND SCALP CASES.

<i>Operable Cases.</i>				
Without manifest evidence of disease at present 26	Ameliorated 3	Still under treatment 0	Failed 0	Died under treatment 0
<i>Inoperable Cases.</i>				
Without manifest evidence of disease at present 8	Ameliorated 4	Still under treatment 1	Failed 4	Died under treatment 0

Or, if the 1 case still under treatment be excluded, together with the 3 showing "no disease" diagnosed as lupus, the corrected figures will show 31 cases successful out of 42, or about 73.8 per cent.

CHAPTER X.

APPLICATIONS WITHIN THE MOUTH AND NOSE.

The conditions attending malignant growths within the mouth and nose render the ionic methods of special value, for, as remarked elsewhere, these methods enable us to destroy the peripheries of the growths by insulated electrodes thrust into them through the natural opening of the cavity, the lips being merely retracted, thus rendering disfiguring operations on the overlying facial structures unnecessary. In favorable cases this enables us to restrict the destruction of tissue more nearly to the diseased parts alone than is possible with any other surgical method, for the ionization process is as readily performed as curettement, without the wounding of living cancer tissues and possible reimplantation of living cells in the edges of the wound as in the latter process.

Additional advantages of the ionic methods over excision in some cases are: the freedom from hemorrhage during the operation, after the bleeding caused by the removal of a specimen for biopsy is checked, thus doing away with the dangers of inspiration pneumonia, and permitting a continuous and clear view of the site of operation during the whole time of its performance; and the fact that the impossibility of at times securing an aseptic field of operation within the mouth or nose will not unfavorably affect the ionic operation, permitting successful results in the presence of septic conditions of the teeth and gums that would militate against an excision operation.

The element of danger attending ionic operations in mouth cases is usually restricted to two factors: (1), Too strong a current in a monopolar operation—a danger eliminated whenever possible by the employment of the bipolar technic; or, (2), secondary hemorrhage, from the inclusion of large vessels in the area of sterile destruction. This latter source of danger may be largely eliminated by preliminary ligation of the external carotid or lingual artery on the affected side, it being possible at times to do the ligation and ionic operation consecutively under the same anesthetization if the first named operation is done quickly. In practice, the ligation may be

neglected if the site of operation presents an easy field for packing in the event of hemorrhage.

This danger of secondary hemorrhage is not great in growths of the anterior portion of the mouth, or, in fact, in any

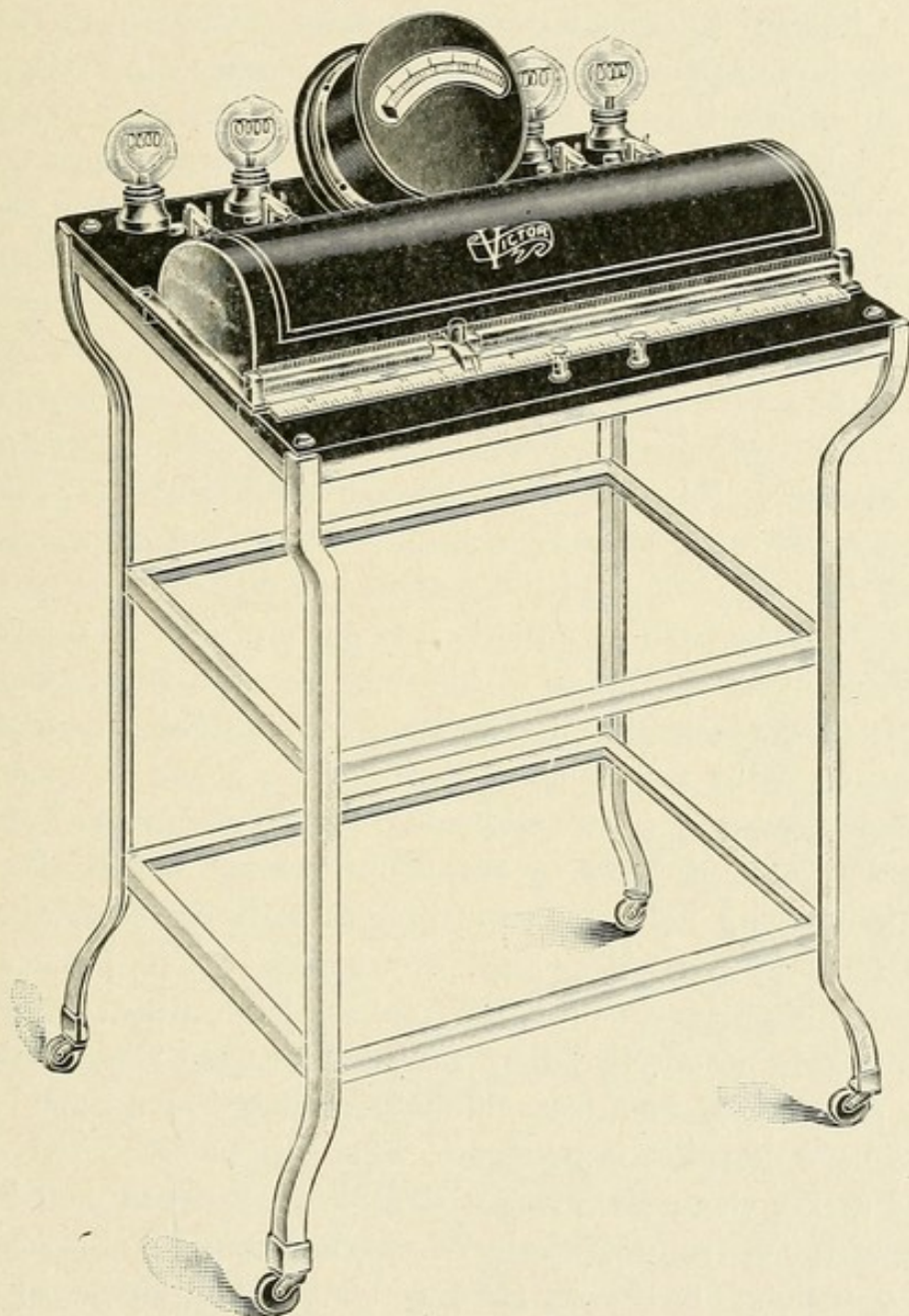


FIG. 53a.—Author's Ionization Table, as made by the Victor Electric Co., for major and minor ionic surgery.

growths in the mouth cavity proper, anterior to the pillars of the fauces. The danger of hemorrhage is great, on the contrary, in all growths within the pharynx or in the tonsillar regions, unless the growth is distinctly superficial, for the necessity for a thorough inclusion of all peripheries of the diseased area in a complete operation makes the danger of hemorrhage in this region a grave peril.

The situation of the growth is therefore a matter of greater importance in the prognosis of cases under ionic operations than the variety, though it should be understood that the virulence of the type of disease, as measured by the quickness of its growth since its first appearance, dictates the extent of inclusion of surrounding tissues necessary to a thorough eradication, with corresponding extension of risk. The presence of infected glands in the neck, usually attending the carcinomas but rarely the epitheliomas, is an exceedingly grave complication, the treatment of which will be referred to later.

Major Operation Within the Mouth.—Having determined that the case is a suitable one for possible eradication by this method, and prepared the patient for general anesthesia as in ordinary operations, the large, warm kaolin pad with conducting plate beneath is placed on the operating table to act as the negative pole in case the monopolar method is used at any time during the operation, and the patient lies on the table with the pad beneath the back. Should these preparations be repugnant to the patient when made in his presence, the anesthetic may of course be administered elsewhere and the patient be placed in position after full anesthesia.

Unless distinctly contra-indicated, the writer prefers chloroform as the anesthetic, preceded one hour before the anesthetization by a hypodermic injection of one-quarter of a grain of morphia and $\frac{1}{100}$ gr. of hyoscin, or, in some cases, one-half this dose, for the reason that the chloroform anesthesia is accompanied by far less salivary secretion than ether anesthesia, and less chloroform itself is needed when the hyoscin-morphia is used.

The active electrodes, which should be prepared well in advance of the operation, consist of slender, pointed, zinc needles, 4 to 6 inches (10 to 14 cm.) in length and made of one-thirty-second-inch (1 mm.) zinc plate, one-eighth-inch (3 mm.) wide and tapering to a fine point. These are attached in sets of two or four to suitable lengths of No. 28 cotton-covered wire connected with the positive pole of the battery or Ionic Table. Each electrode is curved in a suitable manner to reach the growth conveniently through the mouth, and is effectively insulated by a thin coating of fused sealing wax so as to leave uncoated only that portion of the tip that will be buried in the growth. The mercury coating of the active surface is not

applied until immediately before their insertion, as it renders them exceedingly brittle.

With the patient under the anesthetic, the jaws are held apart by a suitable instrument and the lips are retracted with a curved hard-rubber retractor on one side, held by an assistant, and on the other by means of a miniature lamp inclosed in a test tube made of strong glass, the latter being held by the operator to act as both illuminant and retractor, the glass covering permitting a free use of it for that purpose. Before proceeding further in the operation a specimen is now removed for microscopic examination, as none will be available later, and the hemorrhage is stopped by amalgamating and inserting an electrode in the cut surface and turning on the current without delay, either as a bipolar or monopolar operation.

The bipolar method is to be preferred in all operations demanding considerable current, as in this method none of the current traverses the nerves of the neck, thus avoiding embarrassment of heart action and circulation during the flow of the current, and it may be employed whenever there is sufficient substance in the growth to enable us to hold a small spade-shaped cotton-covered negative electrode against it without touching the active needles. The absorbent cotton on this electrode should be dipped in 25 per cent. sulphuric acid and water to absorb the hydrogen ions as liberated, additional acid being added from time to time by means of a glass dropper. When employing the bipolar method in this way the kaolin pad under the back is not in use, of course, a wire attached to the negative electrode within the mouth being connected directly to the negative binding post of the apparatus.

Having amalgamated and placed an active electrode needle in the wound produced in removing the specimen and the negative merely on the growth, a current of 100 to 200 milliamperes is gradually turned on, the mouth being kept free from blood and moisture as far as possible by swabbing with gauze sponges held in hemostats. In from five to ten minutes all bleeding will have ceased, when the field of operation may be cleaned, additional zinc-mercury needles inserted in the peripheries of the growth, and the current increased to from 350 to 500 milliamperes. The remainder of the operation is practically dry, and, being well lit by the miniature lamp, the dispersion of the ions is kept constantly in view until the whole of the growth

and its immediately surrounding tissue is turned a grayish-white in color, which is a sign of complete ionic sterilization. The current is then turned off slowly, and the electrodes are removed for final inspection of the field of operation, and, if no sign of living malignant tissue remains, the patient is put to bed.

If the monopolar method only can be used, the plate beneath the kaolin pad on which the patient lies is connected with the negative pole and the same technic is followed with a weaker current, and without the negative electrode within the mouth.

Such an operation for an average growth will require from thirty to fifty minutes for its completion. Owing to the fact that there is little or no loss of blood, it is never followed by shock. To allay the sensation of heat and burning that would be experienced by the patient on emerging from the anesthetic a hypodermic injection of morphia is directed to be given during the following night, if needed. By morning the patient is usually comfortable and suffering no pain, though the parts present considerable tumefaction and tenderness.

During the separation of the slough, which requires from ten to sixteen days, but slight odor will appear and that in the latter stages of the process. The patient is made comfortable by a weak mouth wash of some antiseptic solution. Should there appear to be danger of hemorrhage on separation of the slough a nurse should be in constant attendance between the tenth and sixteenth days with a carbolyzed Monsell's Solution at hand, and should bleeding occur, pledgets of gauze dipped in the solution should be packed down on the bleeding spot and left in place several days.

The wound left on separation of the slough is painless and heals readily, usually with some contraction. Should the disease have invaded the alveolar processes of the mandible or maxilla, or the bodies of these bones, the diseased bone and contiguous parts will be devitalized by the ions equally with the soft tissues, and will separate also spontaneously, the edges left healing readily. This separation of devitalized bone will require from thirteen to twenty-six weeks.

Major Operations Within the Nose.—Applications to growths within the nasal cavities demand a similar technic, except that the space within which the application is made is so restricted that the monopolar method alone is feasible, with

currents varying between 200 and 300 milliamperes only. But one electrode, or possibly two, can be employed. When properly conducted, no injury need be done to the nostrils or other healthy structures.

FIRST SERIES OF CASES.

Between 1893 and January, 1905, the writer employed some modification of the methods outlined above in 14 cases of malignant growths within the mouth, 2 of which were operable in the ordinary sense and 12 inoperable, most of them hopelessly inoperable. Of these, 4 were cured, including the two operable cases, 3 died during or shortly after the operation, 2 were relieved for a long period of time, but finally relapsed, and 5 were failures to arrest the disease for any length of time. To save space, the four successful cases only of this series are reported in full.

Sarcoma of Maxilla.—Wm. O., aged 39, laborer, applied for treatment October 11, 1897. He was a sugar house worker of strong physique, but anemic. Six months before, a tendency of the molar teeth on the right side of the upper jaw to loosen and fall out while apparently healthy had been noticed, and attracted the attention of his dentist to a growth in this situation. The tumor has grown rapidly since.

Examination showed that four teeth were missing and their position occupied by a smooth, painless tumor that was 4 cm. long, 2 cm. wide, and projected 3 cm. into the mouth. That it replaced the bony tissue of the alveolar process, and extended into the antrum, was made evident by a distinct outward projection of the anterior wall of the antrum and by a flattening of the arch of the hard palate on the side corresponding to the growth.

October 27, 1897. A major monopolar operation was attempted on this date at the patient's home, with the kind assistance of Dr. E. P. Bernardy, but as the electrodes were too short, the effort was abandoned after 500 milliamperes had been used for 14 minutes. The electrodes employed were of 18 karat gold, amalgamated with mercury, and one of the difficulties encountered was the keeping of a sufficient quantity of mercury in contact with the electrodes. Two weeks later the patient was placed on monopolar minor ap-

plications at the office, pointed zinc-mercury electrodes being now used, with a current of 25 to 35 milliamperes for thirty minutes. These applications were continued thrice weekly for two months, when all diseased tissue had apparently been destroyed, both within the mouth and the antrum, the electrodes having been inserted into the antral portion through the sinus that was formed by the destruction of the growth. During these applications a specimen of the growth was removed for microscopic examination, showing it to be a spindle-celled sarcoma.

November 14, 1898. The patient returns with evidence of some diseased granulations within the sinus. Minor applications of 15 to 25 ma. were begun and continued once weekly through the winter. About this time the patient was shown to the Philadelphia County Medical Society. A year later a few more minor applications were made to redundant tissue within the sinus.

February 25, 1905. The patient returns in excellent condition, but showing a ball-valve-like nodule of tissue springing from the anterior side of the sinus, at its entrance into the antrum, the sinus now being only large enough to admit the bulb of a clinical thermometer. The flattening of the palatal arch has disappeared, but there is slight protrusion of the anterior wall of the antrum, as shown by greater prominence of the cheek in this situation. Minor applications of 5 to 8 ma. for 30 minutes were made about once a week, and later once a month, for the following six months.

At the present time (November, 1909), twelve years after the beginning of the treatment, the patient is in excellent health, and there is no evidence of recurrence.

Recurrent Epithelioma of Buccal Surface of Cheek.—G. W. B., carpenter, aged 59, was first seen September 7, 1900, with a proliferating growth on the inside of the left cheek, near the angle of mouth, about the size of a quarter, with raised and eroded surface. The growth was recurrent after partial destruction by a caustic paste, and had been increasing in size for about a year.

September 23, 1900. Monopolar operation under ether, 200 milliamperes for 20 minutes. The result was but a partial destruction of the growth, the technical faults being probably too large an electrode and insufficient time. The disease re-

maining was later attacked in the office by minor applications of 5 to 15 milliamperes on several occasions during the following year, the series of applications being repeated again two years later.

May 17, 1906. Patient admitted to the Oncologic Hospital with a recurrence of the disease in the alveolar process of the mandible beneath the former site. A major monopolar application of zinc-mercury ions was made under chloroform, 350 milliamperes for 30 minutes, with electrode points thrust into the eroded bone.

August 14, 1906. Patient readmitted to the hospital for treatment of suspicious granulations that show in cavity on separation of a small bone slough. Fifty milliamperes were applied for 20 minutes, monopolar.

May 4, 1909. Patient returns by request, showing a retracted scar at site of applications, with tongue drawn down somewhat, but no sign of recurrence.

Epithelioma of Gum.—Miss C. C. M., aged 37, was first seen April 23, 1901, with a small, smooth growth on the gum above the right canine tooth. The patient was referred to Prof. M. H. Cryer for diagnosis, who pronounced it an epithelioma. As the growth was quite small, a series of nine minor zinc-mercury ionic applications were made during April and May, varying from 2 to 5 ma. under the local injection of a weak cocaine solution. A healthy scar resulted, and the patient reports by letter in January, 1909, that there has been no re-growth.

Sarcoma of Gum.—Earl H., aged 6, was referred by Dr. F. Otis Bryant of Chester, Pa., June 2, 1904. About four months previously a lower incisor tooth was extracted. The next day a growth was noticed at the site of extraction, which has increased in size to the present time, when it is about equal to a hickory nut, growing on both sides of an adjacent incisor and apparently springing from the bone. With the assistance of Drs. Bryant and Johnson a major bipolar application was performed under chloroform on the above date, 350 milliamperes being applied with both poles on the growth, and a current duration of 20 minutes. Recovery was uneventful. Dr. Bryant reports recently that he has not heard of any recurrence of the growth. Pathologic report of specimen removed immediately before operation: Sarcoma of the poly-

morphous variety, showing chiefly large spindle cells with a mixture of giant cells.

SECOND SERIES.

(Reported in full as treated.)

No. 41. ONCOLOGIC HOSPITAL. *Epithelioma of Lower Jaw.*—R. E., aged 62, laborer, was admitted February 2, 1905, with a proliferating growth springing from right side of body of mandible and alveolar process, all teeth behind incisors of affected side having been displaced in the progress of the disease. The growth had been first noticed six months before, and was growing rapidly.

An attempt was made to destroy the growth by minor applications, which were too painful. On February 9, 1905, he was placed under chloroform and a bipolar application of 100 to 200 ma. was made to the growth for one hour, followed immediately by a monopolar application of 100 to 200 ma. for 20 minutes. The patient was discharged to the dispensary three weeks later, with evidence of some disease remaining, and received several minor applications of 15 to 30 ma. until May 15, when, doubtless due to the pain produced by these latter applications and lack of intelligence on his part, he ceased to attend.

Vague rumors of a relapse were received later.

No. 47. ONCOLOGIC HOSPITAL. *Epithelioma of Buccal Cavity and Cheek.*—C. P. S., aged 73, was admitted February 24, 1905, with a rapidly-growing cancerous mass involving nearly the entire left cheek without and the left side of the mouth within, the maxilla being evidently involved. The growth had appeared but six months before, simulating an abscess of an upper tooth. Two teeth had been extracted, which resulted in rapidly increasing the growth. It has become much larger during the past two weeks. There was no glandular involvement. Microscopic examination showed squamous-celled epithelioma.

On March 6 a major monopolar application under chloroform was made, 250 to 350 ma. being used for 70 minutes, during 5 minutes of the time the current reaching 500 ma. (Remark: The bipolar method would have been more effective.) Eleven days later there was some bleeding from the

edge of devitalized area, readily controlled by pledgets of cotton dipped in Monsell's Solution. On the fourteenth day the slough was lifted from the wound, revealing much disease beneath. During the following three months forty-six minor applications of 15 to 100 ma. were made, ineffectually, when he was referred to Dr. Newcomet for x-ray treatment. This also failed to arrest the growth, death occurring five months later.

No. 73. ONCOLOGIC HOSPITAL. *Epithelioma of Buccal Surface of Cheek*.—W. M. D., aged 61, laborer, was admitted March 17, 1905, with a proliferating growth on the inner surface of the right cheek about 2 inches in diameter and projecting one inch from surface of mucous membrane. The virulence was apparently great, as he stated that it had been first noticed but 8 or 9 weeks before and had grown rapidly. Microscopic examination showed squamous-celled epithelioma. Urinalysis revealed evidences of chronic nephritis.

March 18, 1905. The patient desiring that something be done, in spite of the condition of the kidneys, he was placed under chloroform and 200 to 400 ma. applied for one hour.

During the following month 11 minor applications of 50 to 100 ma. were made in an effort to arrest the rapid proliferation of the growth, but the patient's general condition becoming worse, uremia appeared, followed by death April 25.

No. 183. ONCOLOGIC HOSPITAL. *Osteosarcoma of Lower Jaw*.—Miss A. G., aged 14, was admitted from Tyrone, Pa., July 14, 1905. Parents both alive and healthy, and family history negative. Six months before the growth was noticed the girl fell against an iron bar, striking the jaw near the site of the present growth. It was first noticed 13 months ago as a tumor of the body of the mandible on the left side, and has increased steadily.

Condition on Admission.—The patient is somewhat slightly built for her age and appears anemic. The left side of the face is greatly deformed by a protrusion in the region of the horizontal body of the mandible. Examination within the mouth shows a smooth, firm growth enveloping the alveolar process and about the size of a hen's egg, one tooth having fallen out and several being raised from their position and pointing at various angles from the tumor, with roots still apparently embedded in bony structure.

Operation.—July 19, 1905. Though the whole structure of

the jaw in this situation showed evidence of being probably involved in the growth, the desirability of avoiding an external scar and of saving as much healthy tissue as possible caused the decision to be formed to destroy the growth by the bipolar ionic operation from within the mouth, the large current necessary to destroy tissue of the considerable cubical measurements involved in this situation rendering the bipolar method desirable for other reasons.

With the patient anesthetized with chloroform, and the lips and tongue drawn aside by means of hard-rubber retractors, a metallic negative electrode was inserted into the center of the growth, encountering penetrable bony tissue just beneath the surface. Two somewhat large, pointed zinc-mercury electrodes connected with the positive pole were then inserted at the extreme ends of the growth, and a current of 500 milliamperes was turned on. As the tissue was whitened and softened in the region of each anode the latter was removed and inserted in a new portion of the periphery, the current still flowing through its fellow, until the whole of the growth was necrosed, the total time required being 50 minutes. The surrounding healthy structures were protected from the action of the current by the insulation on the electrodes above their active surfaces and by the retractors, though with some difficulty.

A specimen removed at the beginning of the operation was sent to the pathologic laboratory and found to be an osteosarcoma.

After History.—The soft parts of the slough showed the usual white color and emitted but slight odor during the process of separation, which was complete for the soft parts in ten days, exposing an irregular, bony framework of the same shape as the tumor and twice as wide as the normal alveolar process. This structure had also been successfully devitalized by the dispersed ions.

The patient was paroled from the hospital to the home of a relative in the city at the end of four weeks, with the devitalized bone still in place and now requiring weak antiseptic irrigation on account of some odor and discharge. A small external opening through the cheek had also developed opposite the lower edge of the mandible, owing to the nearness of the ionic action to the skin.

September 2, 1905. Patient re-admitted for the removal of the dead bone and destruction of some suspicious granulations about it. The bone slough was but slightly attached to the structure beneath, and when removed revealed the lower half of the body of the mandible free from disease and in good condition. A monopolar application of 345 milliamperes was made to the suspicious granulations for 25 minutes, under chloroform.

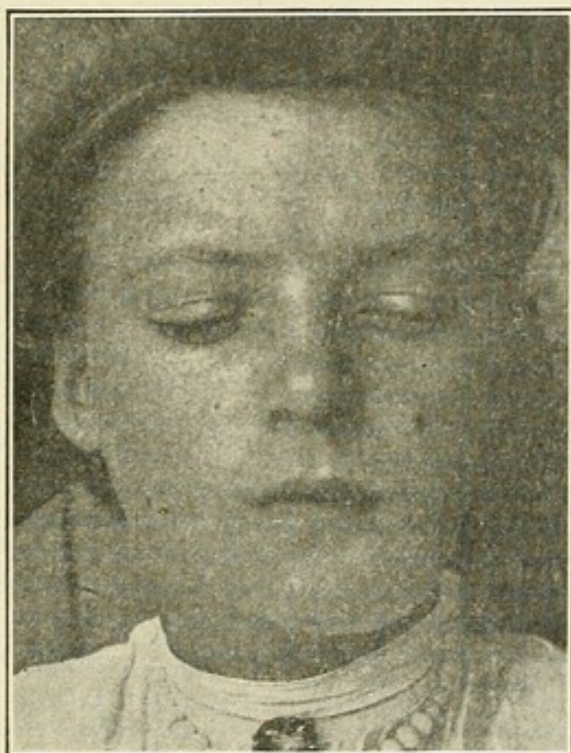


FIG. 54.—Case 183 as outline of lower jaw appears four years after operation.

A month later three minor applications were made to suspicious granulations, without anesthesia.

The patient has been seen or has reported by letter at regular intervals since, but no further applications have been required, the parts presenting a healthy appearance, with the loss of four teeth and their alveolar process as the only evidence of the disease within the mouth. The external sinus closed early with a depression of the skin at its site. The jaw on this side still shows some protrusion, as shown in the photograph (Fig. 54), though materially less than before the operation.

No. 237. ONCOLOGIC HOSPITAL. *Probable Recurrent Myxo-*

fibrosarcoma of Nasal Cavity.—Mr. S., aged 41, was admitted from Allentown, Pa., July 22, 1905. Eight months before admission the patient consulted his family physician for repeated bleeding from the left nostril. He was treated from that time (November, 1904) until March, 1905, by various methods, a growth within the nostril being finally recognized in the latter month and removed with the snare. The growth recurred and was removed again in May. In June the growth again recurred a second time and was removed a third time with scissors, accompanied by alarming hemorrhage.

Condition on Admission.—External examination shows a protrusion on the left side of the nose, corresponding in situation with a tumor occluding the left nasal cavity, with a broad attachment to the turbinal. The patient was in indifferent health and complained of headaches.

Operation.—On July 25, 1905, the patient was placed under chloroform and a major monopolar application made. An insulated zinc-mercury pointed electrode of sufficient length was inserted through the nostril into a small incision in the growth made by scissors to secure a specimen, and a current that finally attained 250 milliamperes was gradually turned on and maintained for 20 minutes. The hemorrhage caused by securing the specimen interfered at first with the proper confinement of the destructive action to the diseased part, but within ten minutes all bleeding ceased, and the remainder of the application permitted of such accurate control that the comparatively strong current was confined to the proper structures and the operation was completed without injury to the nostrils. The anterior edge of the growth was found to begin one inch from the external nostril, and it was about an inch in depth. In the examination of the specimen removed, which was small, and probably made up of overlying mucous membrane alone, neither Dr. McClary nor Dr. Swan could find certain evidence of malignancy.

After Treatment.—The usual headache was somewhat aggravated the next day, but the nostril was open, owing to the retraction of the whitened necrosis. The slough came away during the second week, having been but slightly odorous under weak permanganate irrigation, and the patient was paroled from the hospital under observation. Two months later he was re-admitted for a second major monopolar application to a

portion of the growth that had apparently escaped the first application, on its posterior border. A current of 60 ma. was employed for 15 minutes. It was noted at this time that the septum had been affected by the first application, resulting in the production of a bone slough about a centimeter in diameter, which came away spontaneously October 15.

Dr. G. Oram Ring was now called in consultation to watch for further recurrences, and two minor applications were made to suspicious spots on January 20 and February 10, 1906, of 4 and 3 ma. respectively.

At the present date, July, 1909, four years after treatment, there is no sign of recurrence, and the patient is in excellent health. The projection of the side of the nose disappeared during the first year after treatment.

No. 206. ONCOLOGIC HOSPITAL. *Epithelioma of Tongue.* Mrs. B. W., aged 68, was admitted August 3, 1905, with an epithelioma of dorsum of tongue about the size of a half dollar and presenting a raised, ulcerated surface. It had existed nine months. The patient, whose intelligence is but slight, states that a tumor was removed from the mouth twenty-six years ago. No infected glands can be discovered in the neck under a careful examination.

A major monopolar application was made under chloroform, 350 to 400 milliamperes being employed for 30 minutes, with six needles inserted about the edges of the growth; and one month later a minor application of 7 milliamperes to suspicious granulations completed the eradication.

February 2, 1906. Examinations made on this date showed the tongue to be entirely free from the disease, the scar being healthy and inconspicuous. There is, however, an enlarged gland in the neck beneath the mandible, evidently a pre-operative colony. The patient was advised to re-enter the hospital for operative removal of the infected gland, but failed to do so. No response to letters of inquiry sent later.

No. 312. ONCOLOGIC HOSPITAL. *Epithelioma of Tongue.*—C. W. A., aged 55, retired actor, was referred by Dr. Wm. Benham Snow, of New York, February 15, 1906. Two years ago a white spot appeared on left side of the dorsum of the tongue. He was treated for a time by iodides and mercury, without effect, the spot becoming elevated in the center and growing larger and painful. He was given a prolonged

course with the x-ray and high-frequency, with temporary benefit.

The anterior half of the dorsum was the seat of a leukoplakial patch, and on this, somewhat to the left of the center, there is a proliferating tumor about the size of a half-dollar, the center being elevated about 2 cm. from the surface. Examination of a specimen taken from the central growth showed it to be a squamous-celled epithelioma. No enlarged glands were found.

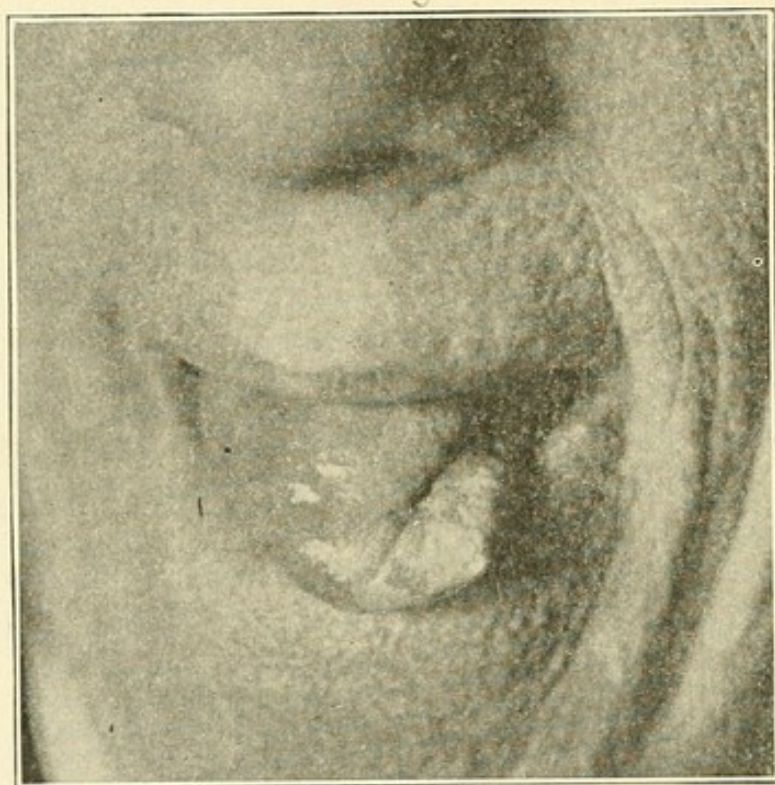


FIG. 55.—Photograph of tongue scar as it appears three and a half years after ionic destruction of epithelioma. Case 312.

February 17, 1906. Major monopolar application under chloroform, 300 milliamperes being used for 30 minutes, eight needles. The tongue was held beyond the lips in the operator's left hand, with a piece of gauze interposed to make the grasp firm, while the right hand manipulated the needles. The slough separated fifteen days later, without hemorrhage. Three days later a small minor application of 7 ma. for 15 minutes was made to a doubtful spot, two needles being used.

May 4, 1908. Patient returns after two years with a doubtful spot on the tongue the size of a split pea, the scar of the

previous wound being healthy. Three milliamperes for 20 minutes, one needle.

June 15, 1908. Patient returns for photograph of tongue (Fig. 55) and for additional minor treatment to spot near tip of tongue.

September 29, 1909. Patient shown at meeting of the American Electro-Therapeutic Association, with excellent scar and no sign of recurrence.

No. 475. ONCOLOGIC HOSPITAL. *Epithelioma of Hard Palate*.—C. L., aged 65, was admitted June 24, 1906, with a proliferating growth projecting 3 cm. into mouth from the hard palate to left of median line, about 3 cm. broad and apparently extending into the bone. The growth had begun several years before. Microscopic examination showed squamous epithelioma.

Treatment was begun by a major monopolar operation June 25, 1906, 350 ma. being given for 50 minutes. When the slough came away, without hemorrhage, there was an apparently healthy opening extending from the mouth into the antrum one and one-half inches (4 cm.) broad, but on the roof of the antrum thus exposed there was evidence of epitheliomatous tissue which apparently extended close to the floor of the orbit. He was discharged to the dispensary and a series of minor applications to diseased spot were begun, averaging about 20 ma. for half-hour durations, the disease being found later to extend also into the left temporal fossa, where an abscess ultimately developed. He was readmitted to the hospital December 6, 1906, and referred to Dr. Hewson for treatment of the abscess, and later Dr. Hewson applied chromic acid to the small area of disease still remaining within the antrum, the disease at this time being about a centimeter in area only. This failed to arrest the growth, which increased steadily and finally spread into the abscess cavity. During several months daily x-ray applications were made by Dr. Newcomet.

July 15, 1907. The disease which for a time had been reduced to such small dimensions, having now invaded the whole abscess cavity reaching slightly beyond the ear, and having become very painful, the patient was re-admitted for a radical bipolar ionic destruction, the external carotid, lingual and facial arteries being kindly ligated at the same operation

by Dr. Despard immediately before the ionic destruction. The disease was included in peripherally inserted electrode needles, and, with the negative placed on the center externally, a current of 1200, decreasing to 600 milliamperes, was employed for 30 minutes. This resulted in destroying all apparent portions of the growth except some near the ear; and later it was discovered that disease also existed within the orbital process of the malar bone (the whole remaining portion of this bone and most of the maxilla having disappeared and the large cavity healed over), and an isolated area also existed in the nasal septum. Between this time and March 18, 1908, the patient was kept in the hospital and minor applications made as often as he could stand them. On the latter date he was placed under chloroform and a monopolar application of 100 to 250 ma. was made to the worst areas of disease, and on April 7 and 18 bipolar applications were made of 100 to 300 ma.

Further treatment was abandoned, at this time, except such as required for the relief of pain and weakness, and he died January 13, 1909, of asthenia from the continued progress of the disease.

No. 429. ONCOLOGIC HOSPITAL. *Epithelioma of Lower Jaw*.—Mrs. L. B., aged 65, was referred by Dr. J. E. McConnell, of Bloomington, Ind., September 15, 1906. For seventeen years she had had a growth on the alveolar process of the right posterior molars of the lower jaw which had extended upwards to the corresponding wisdom tooth of the upper jaw, and recently to the buccal surface of the cheek. Dr. McConnell had employed the x-ray for six months. The growth was 2 x 2 inches (5 x 5 cm.) in diameter and ulcerated.

Treatment consisted of a major bipolar operation under chloroform, 400 to 500 milliamperes for 15 minutes, followed by a monopolar application at the same operation of 300 milliamperes for an additional 15 minutes. The slough separated without hemorrhage and leaving an apparently healthy wound, but with devitalized bone showing at the bottom. The patient was returned to Dr. McConnell's care during the process of separation of the bone, with instructions to make minor applications if necessary, or, in case of doubt, to send her back for further treatment.

During the separation of the bone, which was necessarily

tedious, a sinus opened through the cheek externally, apparently due to the dead bone, but this was thought by her attendants to be free from disease. On learning of this condition, and of the slow separation of the bone, directions were sent requesting the return of the patient to the hospital for removal of the dead bone and a further application of the ions to its site, but other counsels were apparently followed, the patient entering a hospital in Cincinnati in September, 1907, where she was placed under operation of some kind, followed by paralysis and death some hours later. Whether the epithelioma had recurred or not is unknown.

No. 446. ONCOLOGIC HOSPITAL. *Carcinoma of Lower Jaw.*—Wm. McL., aged 55, was admitted from Glassboro, N. J., October 8, 1906. He had had a "sore mouth" for twenty-five years, developing into a well-marked malignant condition about one year before admission. Four months before admission he was admitted into a Philadelphia hospital, where he was given about twenty x-ray exposures. Later, the surgeon in charge ligated the right external carotid artery to cut off nutrition from the growth and discharged him as inoperable. The growth has increased greatly since, and now involves the whole body of the right mandible and overlying soft parts, extending from the symphysis menti to the middle of the ramus. Microscopic examination by Dr. John M. Swan showed it to be a carcinoma.

The treatment of this case extended over more than two and a half years, or from October, 1906, to June, 1909, and consisted of twelve major cataphoric or ionic operations under general anesthesia and a large number of minor applications, each operation failing to eradicate the disease effectually from the cancellous tissue of the bone of the mandible, though keeping it under control. These operations were mainly monopolar and of but 200 to 300 milliamperes, though one was bipolar and of 600 ma. for a short duration, applied directly to the structure of the bone. After the second operation the living end of the ramus of the jaw was effectually freed from the disease and healed over nicely, with some retraction, but the mental end of the bone continued to show disease until January, 1909, when a final application to this site destroyed the bone as far back on the left, or opposite, side of the jaw as the site of the molar teeth on this side. The last application,

in June, 1909, was bipolar and to the edges of a sinus leading from the mouth externally just below the site of the chin.

At the present time both ends of the bone are healed over, showing a loss of about three-quarters of the mandible, and the floor of the mouth is somewhat contracted, but there is no evidence of disease, and the patient is in excellent health. The deformity is not great, as shown in the photograph (Fig. 56).

No. 456. ONCOLOGIC HOSPITAL. *Epithelioma of Mouth.*—T. M., aged 67, a stonemason, was admitted from South Allentown, Pa., October 31, 1906. About two years before ad-

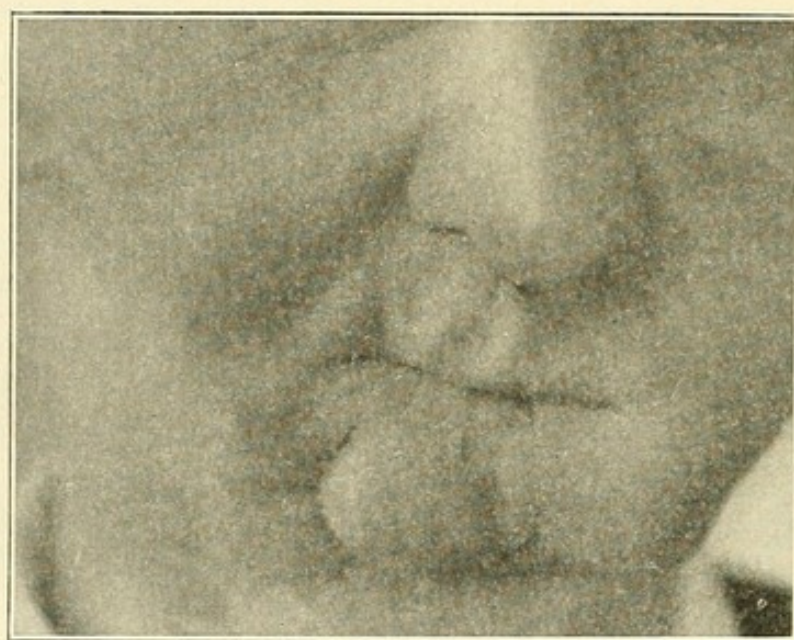


FIG. 56.—Amount of deformity after ionic destruction of epithelioma of lower jaw, with loss of greater portion of mandible. Case 446.

mission he noticed a white spot on the inner gum of the lower jaw, next the lower canine of the left side. Six months ago he entered the Hospital of the University of Pennsylvania, where the x-ray was advised. The growth has increased rapidly of late. Examination revealed a proliferating growth occupying the site of the canine and two bicuspid and involving the alveolar process, surrounded by a leukoplakial patch that extended anteriorly and an equal distance on the opposite side of the mouth. Microscopic examination showed it to be a squamous epithelioma.

A monopolar application under chloroform was made No-

vember 1, 1906, 300 to 400 milliamperes being used for 70 minutes. He was paroled from the hospital December 24, the soft parts having separated nicely, but a bony slough being still in place. This came away January 23, 1907, revealing some suspicious granulations on the surface of the mandible to which minor applications of 10 to 24 ma. were made on five occasions during the following two months. In March there was no evidence of the disease discernible, and the patient was directed to return for observation every three months, which he failed to do, being ignorant and neglectful, though a letter was received a year later in response to inquiry stating that he was all right. A neighbor states that there is a recurrence in the spring of 1909.

No. 460. ONCOLOGIC HOSPITAL. *Epithelioma of Mouth*.—W. G. M., a farmer, aged 73, was referred by Dr. Thaddeus Irwin of Christiana, Pa., November 12, 1906, with a proliferating growth on the buccal surface of the cheek, extending from the middle of the cheek on the right side around to the same point on the left, in front of the gums, the greatest elevation of the growth being above the angle of the mouth on the right. In this situation it was two inches wide and one inch thick ($5 \times 2\frac{1}{2}$ cm.). A portion of the diseased tract seemed to be simple leukoplakia, the latter extending over the external surface of the lower lip. A brother died of cancer of the mouth at 64 years of age, and a sister of cancer of the breast at 59. The growth was first noticed about two years ago, and x-ray treatment had been ineffectual. Microscopic examination showed squamous epithelioma.

A major monopolar application was made under ether November 13, 1906, 160 to 200 milliamperes being used for 45 minutes, with several fine electrodes, a portion of the time being given to following the leukoplakial area with the needles. The result was excellent when separation occurred, though the patient was kept under frequent inspection, with several minor applications to suspicious spots. By the end of a year a final patch of disease in front of the sites of the lower incisors was eradicated by a second major monopolar application, 60 to 100 ma. being used for 40 minutes.

November 22, 1909. Patient returns for regular inspection, showing no evidence of disease and excellent general health, though now past 76 years. The right angle of the mouth is

higher than the left by reason of loss of tissue in the right buccal region (Fig. 57), the site of the major portion of the growth. The scar tissue is soft and thin.

No. 498. ONCOLOGIC HOSPITAL. *Epithelioma of Mouth and Neck, Recurrent.*—W. H. C., aged 63, civil engineer, was referred by Dr. Walter M. James of Philadelphia January 21, 1907.

In February, 1905, his dentist noticed a raised white spot on the side of the gum of the right jaw, next to the first molar tooth. For a time x-ray treatment was employed, and

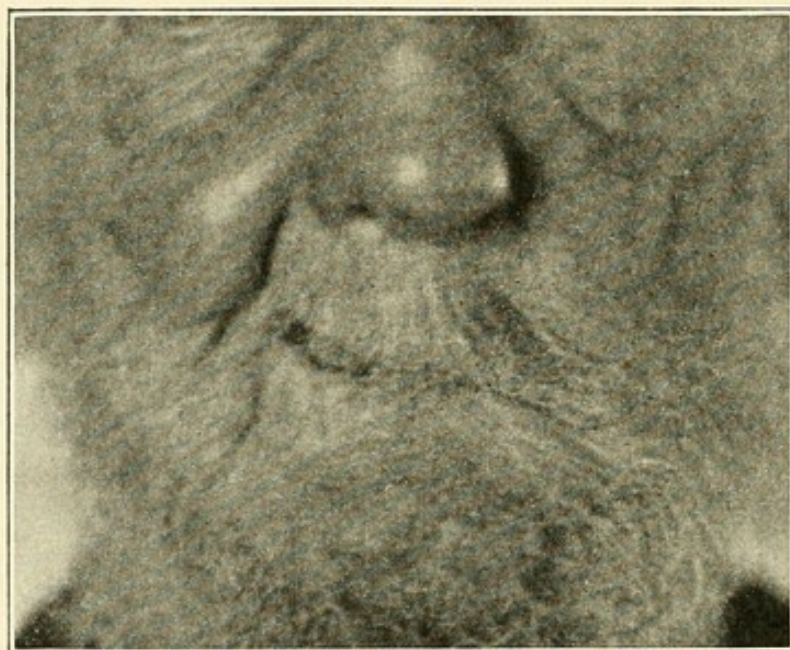


FIG. 57.—Case 460 as mouth appears three years after destruction of epithelioma of mucous membrane above right angle.

he was later placed under operation in a general hospital in the city, the right mandible being removed by excision from its angle to the symphysis menti through an external opening. The wound never closed, recurrence taking place promptly over the whole site of operation.

On admission, a large opening shows in side of face and neck with proliferating edges. Within the wound a mass of epitheliomatous new growth exists about the size of an orange. No glands are apparently involved. On microscopic examination the growth was shown to be a squamous epithelioma.

A major bipolar application was made under chloroform January 22, 1907, the negative being a large oval electrode

covered with absorbent cotton saturated with 25 per cent. sulphuric acid and water to absorb hydrogen gas, etc., and the active ionizing ones, zinc-mercury pointed electrodes of appropriate length inserted around the edges of the growth externally, with longer, insulated ones inserted in the edges of the portion within the mouth through the lips. A current of 1200 to 1600 milliamperes was turned on and maintained for an hour. Seven days later the whole of the slough produced came away, with some hemorrhage from a small skin vessel, controlled by ligature. On the seventeenth day a devitalized piece of the mandible near the chin was lifted from the wound, revealing considerable disease in the lower anterior border of the cavity. This was successfully eradicated February 12 by a second major application of 240 to 400 milliamperes for 25 minutes, this time monopolar.

March 14. Consultation with Dr. Addinell Hewson, with decision that edge of wound nearest neck is healthy. Some disease shows in the upper portion of the wound, in position normally occupied by antrum. This was attacked later (May 14) by a third major monopolar application, and the patient was then directed to return for minor applications, of which 52 were given during May and June. These minor applications were of 10 to 15 milliamperes, but were quite painful as the diseased spot was no larger than a dime, though situated immediately under the floor of the orbit. Following the separation of the slough of one of these minor applications the patient had two severe hemorrhages from the infraorbital artery, expiring during the second hemorrhage.

No. 514. ONCOLOGIC HOSPITAL. *Epithelioma of Mouth*.—G. K., farmer, aged 53, was admitted from Villisca, Iowa, February 12, 1907. For a number of years he had had a leukoplakial patch in the sulcus between the left cheek and the teeth of the lower jaw. Six months ago a growth appeared in the center of the patch and has increased rapidly since, giving rise to soreness and frequent lancinating pains. Examination shows a white, proliferating growth in the sulcus, extending from the first incisor tooth to the intermaxillary commissure and from the margin of the gums up on the cheek. Beyond the commissure the growth extended up on the mucous membrane of the hard palate about 3 cm. Further examination showed that the patient was suffering from incipient

Bright's disease, rendering a major application inadvisable. Microscopic examination showed squamous epithelioma.

It being decided to destroy as much of the growth as possible by the minor method, he received, between the date of admission and September 13, one hundred and thirteen minor applications, varying from 30 ma. for one hour to 3 ma. for half an hour, the later applications being the weaker ones as the growth was destroyed. At this time (September 13, 1907), he was sent home without manifest evidence of disease, healthy mucous membrane having covered the site of growth, but with the injunction to return for further treatment if suspicious granulations appeared.

In a letter dated December 14, 1907, the patient reports a slight evidence of possible disease, but has so far failed to return.

No. 540. ONCOLOGIC HOSPITAL. *Carcinoma of the Mouth and of the Sublingual and Submaxillary Glands, both Sides of Neck.*—Sig. C. A., sugar planter, aged 56, was referred by Dr. C. M. Desvernine, of Havana, Cuba, April 15, 1907.

A little over a year ago a tumor was noticed in the floor of the mouth beneath the tongue, which later ulcerated and increased rapidly in size, with severe lancinating pain. Examination on admission showed an excavation occupying the whole anterior floor of the mouth and under side of the tip of the tongue, with raised and indurated edges. The submaxillary and sublingual glands of both sides were enlarged to the size of chestnuts. The general health was good, except for the presence of considerable albumen and a few casts in the urine.

With a view to a thorough ionic destruction of the cancerous area and glands Dr. Hewson was asked to ligate both external carotids, which was done successfully in two operations on the 25th and 30th of April, in spite of the condition of the kidneys, for which the patient had been placed under appropriate treatment. At these operations the glands were also removed by excision, contrary to my original intention, and the prompt recurrence of the disease in a diffused form on the left side of the neck in the interval of delayed ionic destruction at this site was possibly the chief cause of ultimate failure to eradicate the disease. Microscopic examination of

both the primary growth and removed glands showed carcinoma.

The removal of the glands being for a time apparently successful, the major bipolar ionic operation was proceeded with May 16, but confined to the growth in the mouth alone. Five hundred to 600 milliamperes were employed for 30 minutes, the negative electrode being placed in the center of the excavation and the active needles in turn around the periphery, piercing the tongue and floor of the mouth slightly beyond the disease. The separation of the slough was uneventful, but revealed doubtful tissue at the bottom of the cavity.

On August 6 the site of the excised glands on the left side of the neck showing a diffused, increasing growth, a major bipolar application was made, the tissue being transfixed by a curved needle with a stout ligature, traction on the latter enabling much of the growth to be drawn away from the underlying vessels. The negative electrode was placed over the center and the active electrodes transfixed the growth near its base. A current of 300 to 700 ma. was used for 10 minutes. At the same operation a monopolar application of 300 milliamperes for 20 minutes was made to the remnant of disease within the mouth. On the 16th, during the separation of the mouth slough, a slight hemorrhage occurred beneath the tongue, controlled by cotton pledgets saturated with Monsell's Solution, followed by a severe one on the 19th and another on the 24th, both controlled with difficulty by packing.

On the removal of the packing no disease was revealed within the mouth, but there were evidences of abnormal tissue between the outer and inner sites of application and beneath the outer site, which were attacked by a third major application on October 2, of 200 to 700 ma., bipolar, and 450 monopolar, for 30 minutes each, resulting in eradicating the disease between the mouth and neck situations, but not in the latter, to which site repeated minor applications were made and, on November 4, a fourth major application of 300 milliamperes for 45 minutes, monopolar.

On the 30th of December a piece of devitalized mandible, 5 cm. long, was lifted from the wound, and it was noted that the parts within the mouth remained healthy and that the patient's weight had greatly increased, but that the site of the re-

currence in the left side of the neck was doubtful, and minor applications were resumed.

February 11, 1908. The disease still existing beneath the site of the left submaxillary gland removed in the knife operation, a fifth major application was attempted for its eradication, the disease being deeply situated in the neck. The patient bore the ether very badly, becoming repeatedly cyanotic. From 200 to 400 milliamperes were attained, bipolar, but cyanosis becoming greater the current was reduced to 100 after 15 minutes. The operation was begun at 4.10 P. M.; at 4.30 breathing ceased, and the patient expired in spite of efforts at artificial respiration, intravenous salt solution, and other restoratives.

No. 548. ONCOLOGIC HOSPITAL. *Probable Epithelioma, Associated with Leukoplakia, of Mouth.*—Mr. F., aged 61, a merchant, was referred by Dr. Park Brenneman, of Lancaster, Pa., April 27, 1907. For three years he has had a white patch of leukoplakia on the buccal surface of the cheeks, extending over the whole of the anterior surface of the mouth outside the teeth. It has grown steadily worse in spite of the removal of all of his teeth, the bad condition of which was thought to have produced or added to the trouble. In the sulcus between the gums and cheek the growth resembles epithelioma, but the microscopic examination was negative.

May 2, 1907. Major monopolar application under chloroform. The area was attacked at one end with five fine, zinc-mercury points and a current of 160 to 200 milliamperes, the needles being moved from time to time until the whole of the diseased area was progressively brought under the influence of the radiated ions, the lips and tongue being meantime protected by hard-rubber retractors and the partial insulation of the needles. Since the part to be destroyed was broad and thin, the problem of restricting the ionization to diseased tissue alone was met by inserting the needles parallel to the surface of the growth and not perpendicular, as usually done. The operation was completed in 25 minutes. The slough cleared off nicely by the end of the second week, when he was discharged to the dispensary for observation, minor applications of 5 to 12 ma. being needed on four occasions during the following month.

May 25, 1909. Examination to-day shows smooth and

healthy membrane covering former site of disease, and no evidence of recurrence.

No. 569. ONCOLOGIC HOSPITAL. *Recurrent Epithelioma of Tongue.*—Sig. M., aged 51, sugar planter, was referred by Dr. Desvernine of Havana, Cuba, June 11, 1907. For four or five years he had had a patch of leukoplakia on the dorsum of the tongue. In August, 1906, it ulcerated and grew more rapidly. In February of the present year, after the question of specific disease had been settled in the negative, the growth was removed by excision, with the whole dorsum of the tongue, by a surgeon in Havana, who at the same time ligated both lingual arteries. By May 18 he noticed a recurrence of both the growth and pain, and they are now increasing rapidly. For six days he has been restricted to a milk diet.

Examination.—Patient is anemic, but not surely cachectic. The scar and surrounding portion of remnant of tongue are covered with proliferating elevations and ulcerations. A careful examination of the neck, kindly made by Dr. Newcomet, failed to reveal enlarged glands at this time. Blood count: 5,600 white, 5,000,000 red, and hemoglobin 83 per cent. The microscopic examination was apparently in the negative as to malignancy, but clinical evidences and the final termination of the case removed all doubt.

June 13, 1907. A major monopolar application under chloroform was made, 500 to 600 milliamperes being used for 25 minutes to the affected surfaces, effectually destroying all proliferating tissue, with its base. The slough came away on the twelfth day, accompanied by sufficient hemorrhage to require packing with Monsell's Solution.

July 23. An enlarged gland in the neck has been lately apparent, situated immediately over the bifurcation of the carotid. This was kindly removed to-day by Dr. Despard, by excision. A month later a minor application of 3 milliamperes for 20 minutes was made to doubtful granulations on the tongue and the patient was sent home, without manifest evidence of disease.

February 26, 1908. Letter received from Dr. Desvernine announcing death of the patient from recurrence of the disease in the neck. There was no return of the primary growth on the tongue.

No. 574. ONCOLOGIC HOSPITAL. *Carcinoma of the Tongue.*

—Mrs. L., aged 36, was referred by Dr. W. S. Newcomet June 18, 1907. Five years before the patient had noticed a small "white spot" on the left side of the dorsum of the tongue. One and a half years ago it began to give rise to a burning sensation and increase in size. Dr. Newcomet had used the x-ray during the past winter and spring with some effect, and had also cauterized it.

Examination showed a raised, ulcerated, proliferating growth on the dorsal surface of the tongue near the middle of the left edge, about 4 cm. long, 2 wide, and protruding 2 cm. above the surface of the tongue. The induration beneath it extended through the tongue to the floor of the mouth. There is a movable gland distinctly palpable below the mandible, but Dr. N. thought it due to the treatment, as it had varied in size.

June 20, 1907. Major monopolar application under chloroform, 300 to 360 milliamperes for 40 minutes. Four electrodes were inserted in the periphery of the growth and thrust down through the tongue towards the floor of the mouth. On the sixteenth day the devitalized tissue, measuring 5 by $2\frac{1}{2}$ cm., was lifted bloodlessly from a cavity that extended below the level of the floor of the mouth, and on July 10 she was discharged from the hospital in excellent condition as to the wound, but with a doubtful area in front of it, in the floor of the mouth. During the next two months this area was gradually destroyed by twelve minor applications of 5 to 12 milliamperes for a half-hour each, and by October 10 it was noted that the mouth was free from the disease, with a scar in the tongue that interferes very little with articulation.

March 19, 1909. Patient visited hospital, showing no evidence of the disease within or without the mouth. The enlarged gland below the angle of the jaw is smaller, and on diligent examination a similar palpable gland is found on the opposite side of the neck, both probably due to old tubercular deposits.

No. 576. ONCOLOGIC HOSPITAL.—*Carcinoma of Tongue and Neck.*—J. McD., aged 64, was referred by Dr. Bruce Richards, of Philadelphia, June 20, 1907. Of negative personal and family history and excellent physique, he had bitten his tongue six weeks before, resulting in a sore in the right edge of the latter, which he thought had been made worse by

the sharp edge of a tooth. This was filed down by a dentist four weeks ago, but the sore not only failed to heal, but grew rapidly worse, and a tumor appeared below the ear, in the neck. The opposite parotid gland is evidently enlarged. Pathologic report on specimen removed at subsequent operation: Not malignant; possibly a gumma (?).

June 21. Major bipolar operation under chloroform, 500 to 600 milliamperes for 30 minutes to growth on tongue. The growth on the neck was not touched on account of its deep situation among the neck structures, and also in view of the possibility of its being the seat of a benign inflammation like the parotid gland on the opposite side. The devitalized tissue separated from the tongue on the eighth day, without hemorrhage, leaving a healthy wound; and the swelling in the parotid gland on the opposite side of the neck, after increasing immediately subsequent to the operation, later disappeared. The neck tumor on the affected, right, side nevertheless continued to grow steadily, and the patient was referred to the x-ray department, with the tongue showing no evidence of the disease.

Word was received of the patient's death subsequently at his home, from continued growth of the neck carcinoma.

No. 830. ONCOLOGIC HOSPITAL. *Epithelioma of Mouth and Neck*.—C. S. H., aged 50, applied for treatment July 8, 1907. Eighteen months before he had noticed a rough place on the inner side of the gum and floor of the mouth, next the lower molar teeth of the left side. A year later the growth increasing steadily he consulted a surgeon, who advised removal of the jaw. The growth was examined at this time in the laboratories of the University of Pennsylvania and pronounced a squamous-cell carcinoma.

On examination, an area of proliferation was found on both sides of the lower molar teeth and floor of the mouth, extending on the latter forward nearly to the symphysis menti. No enlarged glands could be found at this time.

The patient was greatly opposed to an anesthetic, and as the growth appeared to be rather superficial, though covering a considerable area, it was decided to attempt its destruction by repeated minor applications in the office. These were accordingly begun, a single slender electrode, properly insulated and curved, being employed at each treatment. The current strength was at first 10 and 15 milliamperes, but later from 5

to 10 only could be borne, the duration being in each case 30 minutes. The treatment covered a year in time, during which fifty applications were made, at increasing intervals as the parts improved. Three months later he was examined and a palpable gland, enlarged to the size of a chestnut, was found beneath the angle of the jaw, and a remnant of the primary growth still existed in the socket of the bicuspid tooth. A through-and-through ionic destruction was advised.

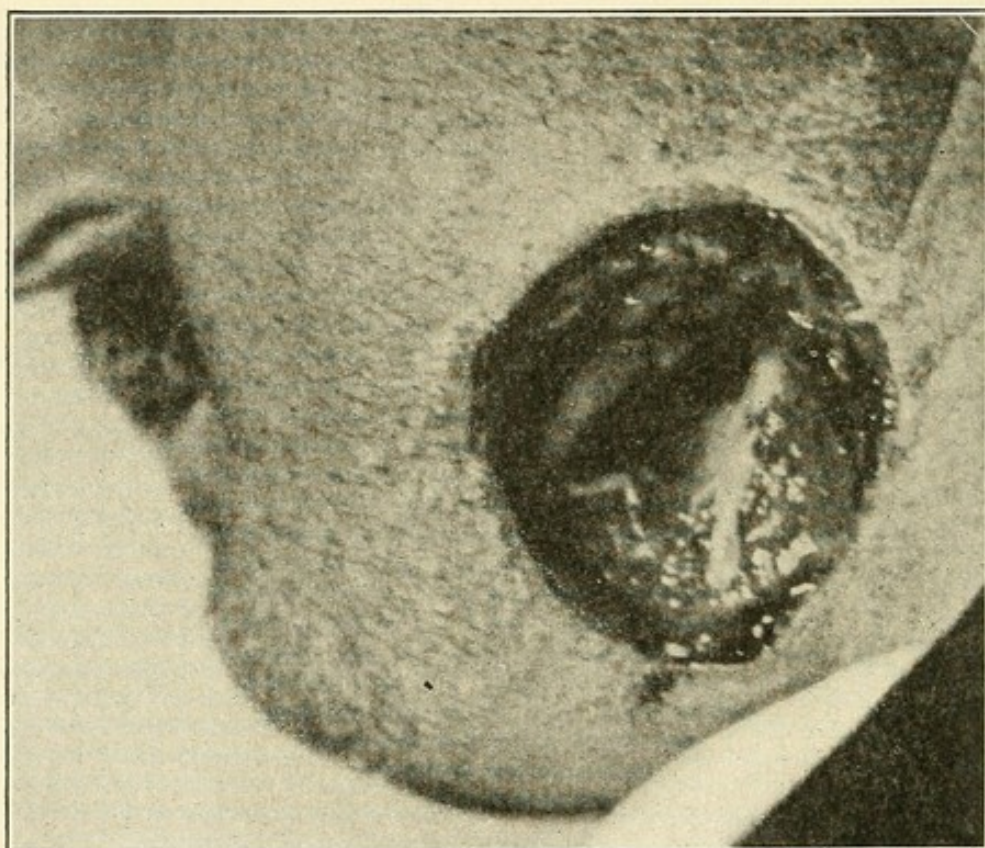


FIG. 58.—Case 830 after separation of slough, showing cavity from which devitalized gland has been removed, sixteen days after operation.

October 16, 1908. Patient admitted to Oncologic Hospital and major bipolar application of 500 to 650 milliamperes was made for 20 minutes, with the negative on the skin over the gland just back of the facial artery, and four insulated needles inserted internally through the floor of the mouth into the affected gland, two on each side of the mandible. The needles were then transferred to the periphery of the gland externally and a monopolar application of 100 to 200 ma. was made for 30 minutes. The area of skin and subdermic tissues destroyed

measured 5 cm. in diameter. At the completion of the operation the tooth that had been surrounded by the disease was drawn bloodlessly.

October 23. The patient's face and neck are greatly swollen, but there is no pain. The pulsations of the temporal artery can be detected to-day.

November 2. Devitalized tissue removed to-day, showing cavity 5 cm. wide, with devitalized bone at the bottom, below

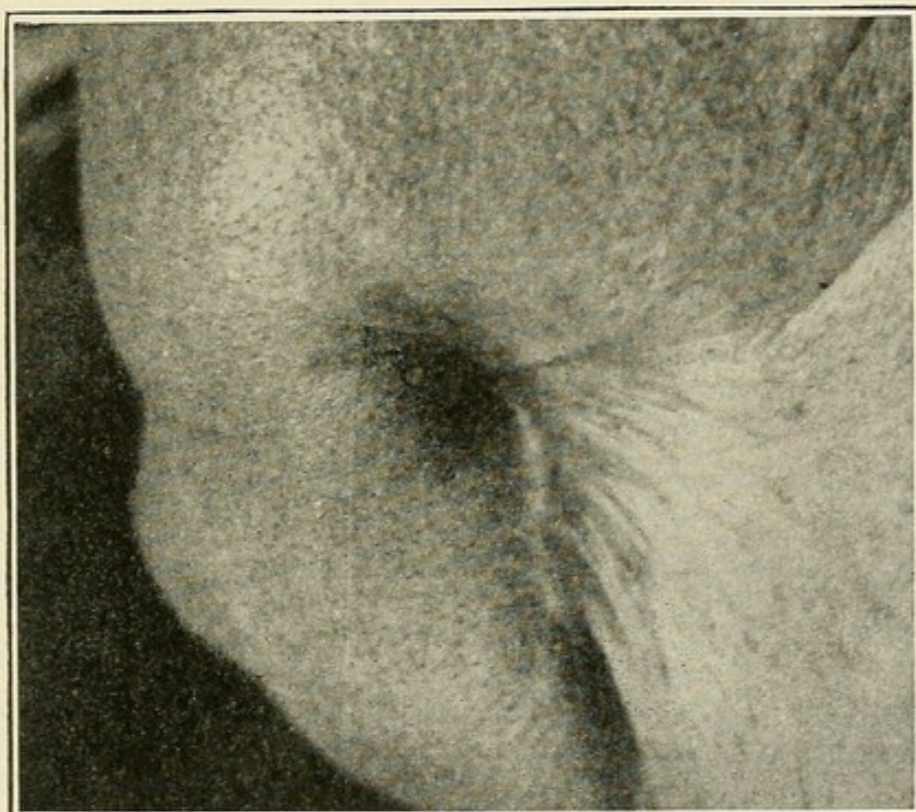


FIG. 59.—Case 830, showing appearance of scar one year after ionic operation for epithelioma of neck gland.

which an opening into the mouth exists (Fig. 58). The devitalized gland resembles punk, and was readily separated from the remainder of the ionized tissue.

December 5. Patient discharged from hospital, to report daily for dressing and irrigation. The external wound has contracted to one-half its size. There is much swelling of the face above the wound.

April 13, 1909. Greater portion of the devitalized body of the left mandible found loose and extracted from wound inside mouth by a pair of forceps.

July 23. Eight minor applications of 5 to 10 ma. have been

made to suspicious tissue back of canine and incisor teeth, and the teeth extracted.

November 8, 1909. Patient reports at hospital with good scar, and no evidence of recurrence. The external conditions are shown in the photograph (Fig. 59).

No. 597. ONCOLOGIC HOSPITAL. *Carcinoma of Mouth and Neck, Virulent Type.*—F. McF., an iron molder, aged 63, was referred by Dr. F. E. Archibald of Philadelphia August 13, 1907. Six months ago the patient noticed for the first time a movable lump in the side of the neck about the size of a lima bean, but did not discover the apparently primary growth in the buccal surface of the cheek, opposite middle molar tooth, until six weeks ago. One week after noticing lump within the mouth (five weeks ago) he had the tooth nearest the growth extracted, resulting in a rapid augmentation of the growth.

On admission, there is a large, proliferant and ulcerated growth in the right side of the mouth, involving both gum and cheek, including the whole thickness of the latter, and a large, immovable tumor externally below the angle of the jaw. Pathologist's report: squamous epithelioma.

August 21. The external carotid artery of the affected side was ligated by Dr. McClary in preparation for the ionization operation, and on the 30th this was proceeded with, 1100 to 1200 milliamperes being employed, bipolar, for 45 minutes. On the separation of the dead tissue a local failure to eradicate was evident, and a second major bipolar application was made September 13, 1000 ma. being used for 16 minutes. This was repeated September 24, followed by 14 minor applications. On October 30 a large portion of the devitalized mandible came away, revealing much disease in neck and face, and further treatment of an active nature was abandoned. December 9 there was a severe spontaneous hemorrhage from the diseased area, which had grown much worse, and on the 20th he died of repeated losses of blood from local extension of the disease.

No. 652. ONCOLOGIC HOSPITAL. *Epithelioma of Mouth.*—E. D., a farmer, aged 80, was referred by Dr. J. C. McClure of Williamstown, N. J., November 23, 1907. Seven months before admission the patient noticed a growth projecting from the buccal surface of the right cheek. In August it became painful.

Examination on admission shows a growth just within the right angle of the mouth on the buccal mucous membrane about the size of a silver dollar and 3 cm. thick, extending from the margin of the gum and angle of mouth upward. The surface showed proliferation and ulceration. Pathologic report: Epithelioma.

November 12, 1907. Monopolar operation under chloroform, 200 to 300 milliamperes for 50 minutes, with six needles. The devitalized tissue separated bloodlessly on the fourteenth day, showing a healthy wound, and the patient was discharged, without manifest evidence of disease, January 22, 1908.

November 15, 1909. No disease found on examination. The site of the wound is covered with a soft, pink cicatrix which limits to some extent the separation of the jaws.

No. 697. ONCOLOGIC HOSPITAL. *Epithelioma of Mouth with Horny Growth of Lip*.—E. M., aged 68, was referred by Dr. Lambert Ott of Philadelphia, March 16, 1908. Four years before a growth appeared, the size of a pea, on the buccal mucous membrane opposite the first lower molar tooth on the left side. It increased slowly and spread to the left corner of the mouth, finally penetrating the cheek and appearing externally. A caustic paste was ineffectually used in July, 1907, and Dr. Ott later used the x-ray for a time.

On the upper lip near the angle of the mouth there are two large horns, 2 cm. in length by 7 mm. in breadth, with blunt tips, corneous in texture and yellowish in color (Fig. 60). Beneath this the greater part of the upper lip is thickened, indurated and covered with crusts. Within the mouth, on the buccal aspect of the cheek, there is a large fungoid mass 4 by 5 cm. broad and involving the whole thickness of the cheek. Microscopic examination: squamous epithelioma.

March 18, 1908. Major application under chloroform, 300 to 400 milliamperes, bipolar, for 13 minutes, negative externally, followed by 300 milliamperes monopolar for an additional 25 minutes. The horns dropped off on the removal of the dressing the following day, and the remainder of the devitalized tissue on the seventeenth day. During the next two months eight minor applications were made to doubtful granulations, of 3 to 11 milliamperes. On October 19 and November 30 he visited the hospital with a well healed scar

that was thought to be thicker than normal, but, under consultation, a waiting policy was followed.

October 17, 1909. Patient visits hospital with a healthy scar that, by its normal contraction, has restored the normal angle to the mouth (Fig. 61). The scar is softer and thinner than a year before, pink in color, and shows no sign of recurrence.

No. 769. ONCOLOGIC HOSPITAL. *Epithelioma of Tongue and Neck*.—E. N., aged 52, was referred by Drs. Newcomet and Blackburn of Philadelphia, June 10, 1908. For ten years




FIG. 60.—Case 697. Horny growth on lip, with epithelioma of mouth.

he had had a leukoplakial patch on the dorsum of the tongue to left of the median line. Five months ago he lifted a crust from its center and noticed an ulceration beneath. The tumor has grown rapidly since, and he suffers from paroxysms of pain extending to whole of left side of head about every three hours.

Examination showed a raised, indurated, proliferating growth occupying about one-third of the dorsum of the tongue, extending from the extreme left border to near the right border, and of equal antero-posterior diameter; ulcerated in

the center and with raised edges. In the left side of the neck there are one or more palpable glands the size of a pea. His appearance was cachectic. Microscopic examination: cylindric-cell epithelioma.

June 12, 1908. Major bipolar destruction of the tongue growth under chloroform, 600 to 1000 milliamperes for 30 minutes. A silk thread was then passed through the skin beneath the enlarged glands in the neck, they were raised, zinc-mercury needles passed beneath, and with the negative on the skin over the glands, the mass was destroyed by 800 to 1000

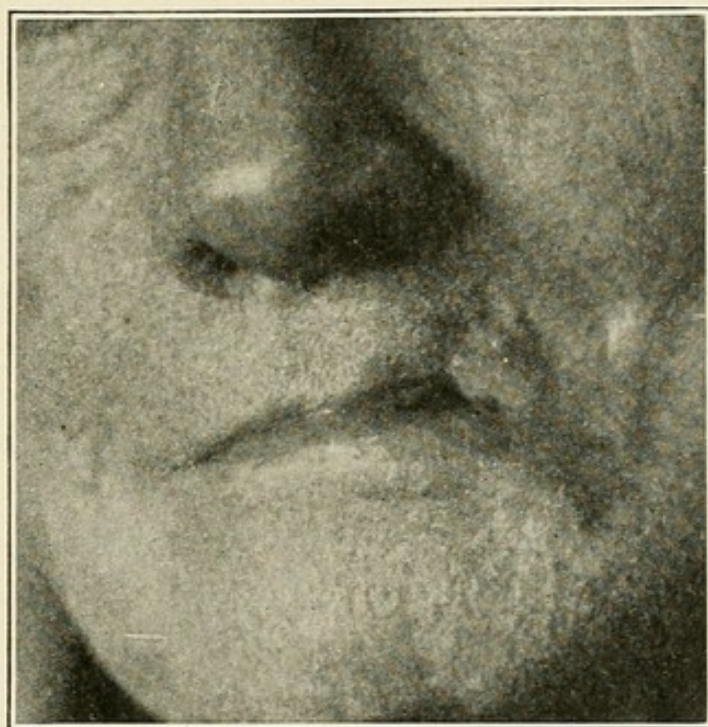


FIG. 61.—Case 697. Appearance of scar one and a half years after destruction of epithelioma of mouth and lip.

milliamperes for 10 minutes. On the separation of the devitalized tissue, which was accompanied by a sharp hemorrhage, a local failure to eradicate the growth from the edges of the wound in the tongue was noted, and later a second enlarged gland was evident in the edge of the neck wound.

August 12. Readmitted with elevated and indurated edges surrounding the tongue wound, an enlarged gland alongside the scar in the neck, and a similar one on the opposite side of the neck. There has been no return of the neuralgic pains. Second major bipolar application to each gland of 800 to 1000 ma. for a total duration of 16 minutes, followed by a monopolar

to the tongue of 50 ma. for 30 minutes. On separation of the devitalized tissue disease was still evident in each situation.

August 31. Third major bipolar application, 500 to 800 ma. for 45 minutes to tongue, and 250 to 300, monopolar, to neck.

September 14. Fourth major bipolar application to tongue and neck, 600 to 800 ma. for 45 minutes.

October 5. Fifth major bipolar application, 200 to 600 ma. for 25 minutes.

November 10. Patient referred to the care of Drs. Newcomet and Codman of the staff as an ionization failure, the severe pains having returned with the local recurrence of the growth. Daily applications of the x-ray begun.

December 3. The x-ray treatment is discontinued and patient placed on supporting treatment alone and for alleviation of the symptoms of the rapidly increasing growth, the three sites having now coalesced into a common proliferation. Death occurred December 22.

No. 926. ONCOLOGIC HOSPITAL. *Carcinoma of Fauces and Neck.*—Judge —, aged 50, was referred by Dr. C. A. Donaldson of Minneapolis, Minn., April 15, 1909. A fissure was first noticed on the anterior pillar of the fauces, right side, in October, 1908, and during the following month an enlarged gland in the neck. In December he was placed on the x-ray, both internally and externally, which has been continued almost daily to the present time. Since midwinter there has been a neuralgic pain in the distribution of the fifth nerve.

Examination.—The jaws can be separated 2 cm. only. On looking within the mouth an excavation is seen on the anterior pillar of the right fauces 2 cm. long, extending to hard palate, with punched-out edges and surrounded by indurated tissue. On the outside of the neck there is a raised, hard tumor beneath the unbroken skin immediately below the right ear and extending to the angle of the jaw. It is immovable, and evidently penetrates deeply into the neck, completing an unbroken area of disease extending from immediately below the skin to the pharynx. Microscopic examination: carcinoma.

April 17. Decision having been arrived at to give the patient the slight chance of a through-and-through ionic destruction being successful, and trusting to pressure as a hemostatic if necessary for secondary hemorrhage (in view of a failure of a previous case to do well on an associated excision operation

for the removal of the infected glands), a major bipolar operation was done on this date, six insulated electrodes being inserted into the growth in the mouth and 600 to 700 milliamperes used for 40 minutes, with negative on the surface of the external growth. At the expiration of this time the internal electrodes were withdrawn from the mouth and short ones inserted in the periphery of the outside growth with the negative still in the previous position, and 200 to 400 milliamperes were applied for an additional 20 minutes.

April 27. A soft mass of devitalized, inodorous tissue was removed from the mouth, leaving some still in position. A communicating opening to the external wound now shows. The difficulty encountered in deglutition is so great that artificial feeding through nasal tube is ordered.

March 1. Shortly after changing the dressings this morning a small amount of hemorrhage was noticed within the mouth and in the external wound, controlled by pledgets of Monsell's Solution and a bandage. About an hour later, however, the patient's pulse became rapid and the heart action weak, succeeded by temporary improvement under heart stimuli, and later by renewed weakness, followed by death in about fifteen hours from the onset of the unfavorable symptoms.

Autopsy by Dr. McClary showed rupture of the carotid artery, which was surrounded by connective tissue showing pearly bodies, and chicken-fat clots of the mitral and aortic orifices.

SUMMARY OF NEW SERIES OF MOUTH AND NOSE CASES.

Without manifest evidence of disease after periods varying from more than one to more than four years: 10 cases, of which but 3 were apparently operable in the ordinary sense, making about 42 per cent. of successes.

Failures to eradicate disease: 10 cases, of which all were inoperable in the ordinary classification.

Died while under operation: 3 cases, making a mortality for the operation of about 13 per cent.

CHAPTER XI.

APPLICATIONS TO THE LIPS.

Epithelioma of the lip is usually removable with ease by excision in its earliest stages, particularly in the lower lip, where a V-shaped incision may be made sufficiently wide of the disease to include the whole of it without danger of re-infecting the cut edges, the shape of the incision permitting the tissues to be approximated with least deformity; yet the major monopolar ionic operation (or bipolar if the growth be sufficiently large) is a ready method of destruction in very incipient growths, in which the ionic destruction need not involve the muscular tissue, and thus results in no deformity at all, with as much security against local recurrence as when extensive removal of contiguous structures is done. Probably an even greater rôle could be played by 'ionic surgery in these incipient cases in offering the patient an alternative to a method greatly dreaded, and thus inducing an early resort to adequate treatment. The mortality from lip cancer is one due to delay alone, as the postponement of removal or destruction may lead at any moment to invasion of the regional glands beneath the mandible, changing a curable case into one in which a cure by any method is problematic. Gland involvement is an early feature of epithelioma of the lower lip in particular.

Where the growth is extensive, and for this reason scarcely operable by excision, the major bipolar operation may still be used with some hope of eradication, particularly if the glands in the neck be not involved.

FIRST SERIES.

Two inoperable cases of lip carcinoma were treated in the first series, both recurrent after excision and caustics, without permanently beneficial results.

SECOND SERIES.

No. 64. ONCOLOGIC HOSPITAL. *Recurrent Carcinoma of Upper Lip.*—W. C. L., aged 50, was admitted February 6,

1905. Fourteen months before he discovered a small lump in the substance of the upper lip, to right of nostril. An attempt to remove the growth by excision was made several months ago.

Examination showed an indurated mass 2 cm. in diameter in right upper lip, with ulcerated surface. The surrounding induration includes about half of the lip. Microscopic examination showed carcinoma with inflammatory infiltration.

A monopolar application of 250 to 350 ma. was made under chloroform for 70 minutes. On separation of the slough, ten days later, a minor application of 8 ma. was made to a doubtful granulation, and February 26 he was discharged to the dispensary.

The doubtful tissue continuing to show immediately above the wound, a second major monopolar application of 300 to 400 ma. was made July 11 for a duration of 60 minutes, to this upper margin.

August 10, 1906. Patient was lost sight of until his appearance to-day. He states that a remnant of the disease persisted at the margin of the nose until he entered a cancer paste establishment in a neighboring state and had the paste applied. There is a clean scar at present, with no sign of the disease showing.

No. 176. ONCOLOGIC HOSPITAL. *Recurrent Carcinoma of Upper Lip.*—W. E. B., aged 62, was admitted from Reading, Pa., July 10, 1905. He had been a sailor and had been for years a heavy drinker. The growth, which was a recurrence after excision, was situated in the left upper lip and angle of mouth, and extended some distance into the facial and buccal structure. It was $3\frac{1}{2}$ inches (9 cm.) in diameter and deeply ulcerated.

The method of operation adopted was the monopolar application, under general anesthesia, the latter being very poorly borne, leading to an imperfect result after each application, and such advance of the disease between operations as to defeat their object. In all, five major applications were made between July, 1905, and January, 1906, each of 300 to 600 milliamperes for about an hour each, together with a large number of minor applications. At the latter date disease existed in the upper portion of the face, threatening the eye, and further active treatment was abandoned. The disease

progressed uninterruptedly, ending in death December 12, 1906.

A review of this case leads to the conviction that the great extent of the growth and the previous history of alcoholism should have dictated the bipolar method as a more hopeful procedure.

No. 609. ONCOLOGIC HOSPITAL.—*Epithelioma of Lower Lip*.—U. L., farmer, aged 66, was referred by Dr. S. T. Day of Port Norris, N. J., August 30, 1907. For twenty years he had had a growth on the lower lip, which had increased greatly

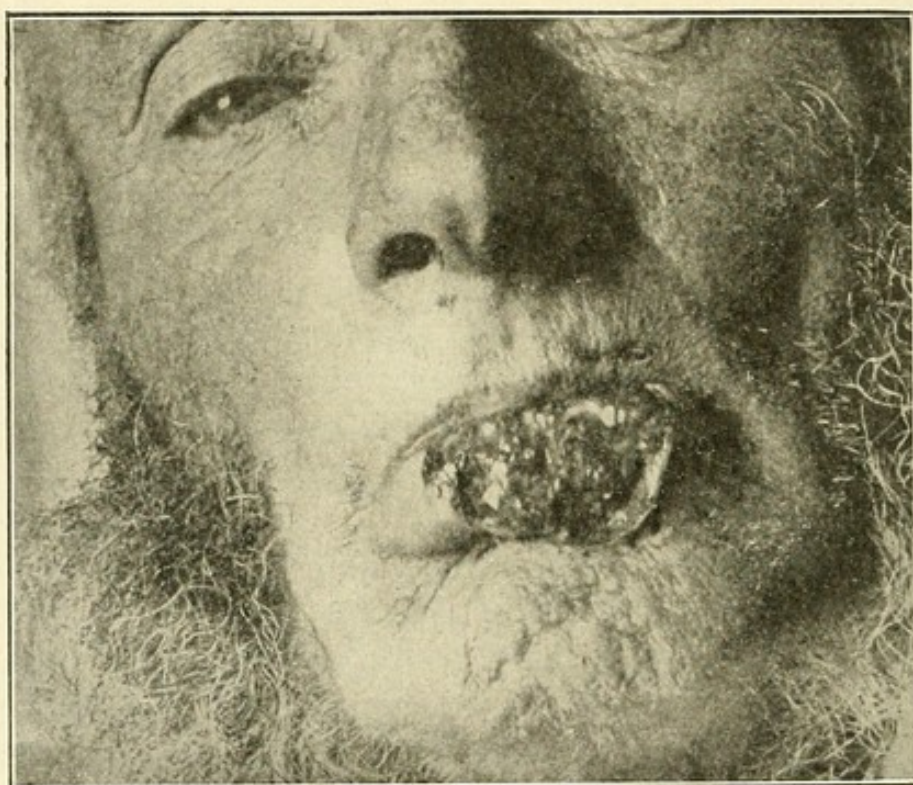


FIG. 62.—Epithelioma of lower lip, August 30, 1907.
Case 609.

during the last five months, during which time he had been under the x-ray treatment. The appearance of the growth on admission is shown in the photograph (Fig. 62). Microscopic examination showed squamous epithelioma.

August 30, 1907. Major monopolar application, 300 ma. for 30 minutes.

September 3. Patient discharged to care of Dr. Day.

December 13, 1909. Dr. Day reports the patient in good health and without recurrence. Photograph (Fig. 63) taken.

No. 638. ONCOLOGIC HOSPITAL. *Small Epithelioma of Lower Lip.*—J. D. H., railroad engineer, aged 62, was admitted to dispensary October 3, 1907, for destruction of a raised lump on the lower lip the size of a pea, with indurated base. It had been observed but a few days, and was not painful. No microscopic examination was made. Two minor applications of 4 and 2 milliamperes for twenty minutes were made one week apart. No sign of disease eighteen months later.

No. 647. ONCOLOGIC HOSPITAL. *Epithelioma of Lower*

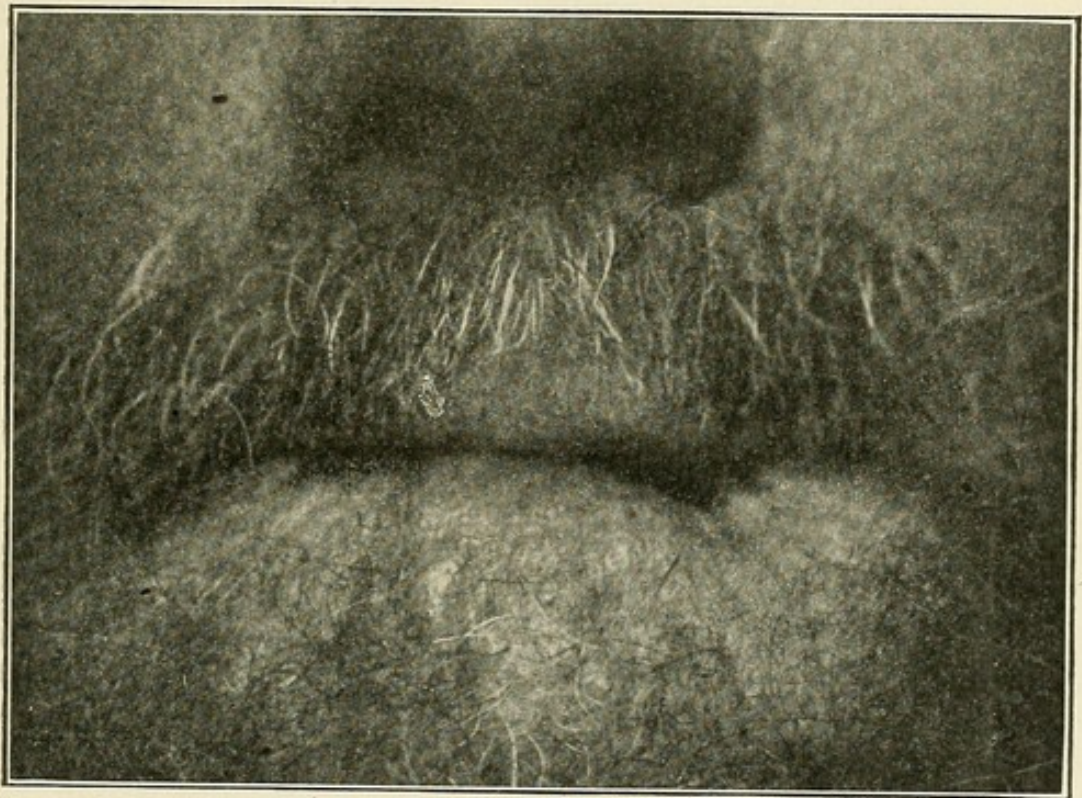


FIG. 63.—Appearance of lower lip in Case 609 two years and four months after ionic application.

Lip.—J. McA., aged 71, retired track foreman, was admitted November 11, 1907. Some thirteen years before he was knocked down by a moving train, and a clay pipe which he was smoking was driven through the lower lip to the right of median line. The wound was stitched, but he neglected to return to the hospital to have the stitches removed, the wound healing by granulation after a time. The present growth appeared eighteen months ago in the scar of this wound, ulceration occurring three months ago. The photograph (Fig. 64) shows the extent and appearance of the neoplasm on admission.

A microscopic examination showed it to be a squamous epithelioma.

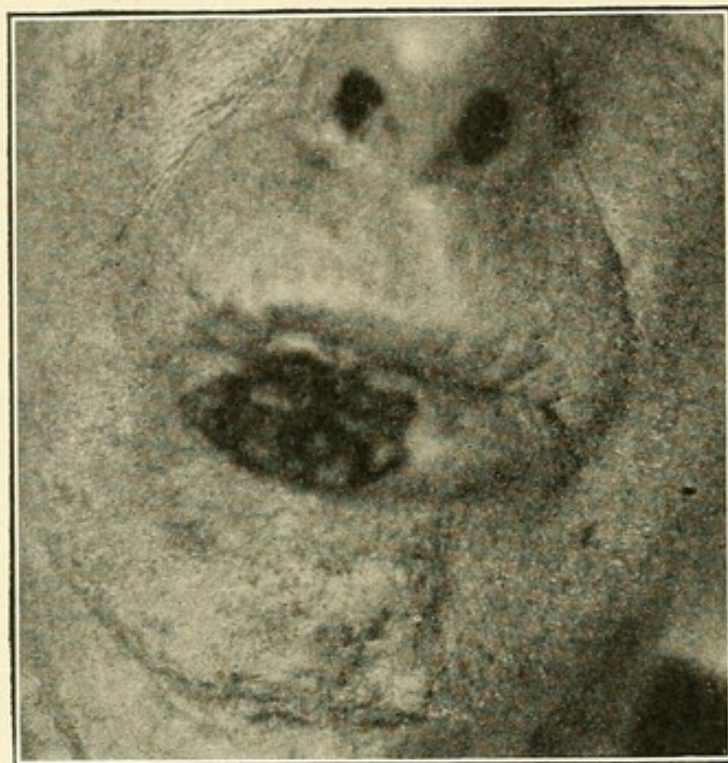


FIG. 64.—Epithelioma of lip. Case 647.

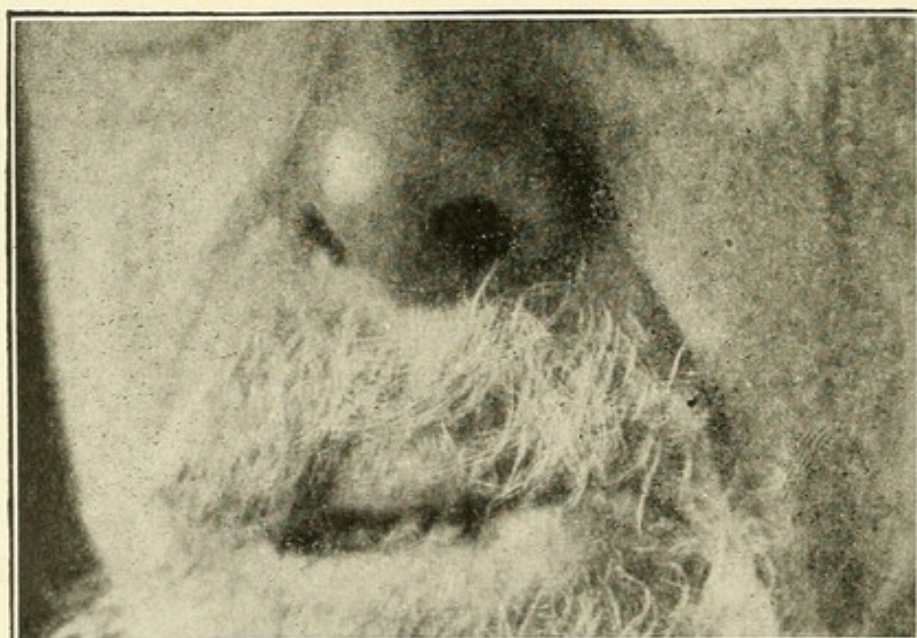


FIG. 65.—Appearance of lip in Case 647 two years after ionic destruction of epithelioma.

November 14, 1907. A major monopolar application was made under chloroform, 100 to 250 milliamperes being used

for 25 minutes. In seven days the slough came away, showing a healthy wound, and on December 24 he was discharged from the hospital with the wound healed and showing no sign of disease.

December 15, 1909. Patient seen, with no recurrence, and the excellent scar shown in Fig. 65.

SUMMARY OF SECOND SERIES OF LIP CASES

<i>Operable Cases</i>		<i>Inoperable Cases</i>	
Without manifest evidence of disease 3	Failed 1	Without manifest evidence of disease 0	Failed 1

CHAPTER XII.

APPLICATIONS TO THE BREAST.

The field of ionic surgery is more restricted in mammary carcinoma than in other portions of the body for two reasons: the success that may attend excision with the knife in the early stages renders the use of this method in these stages less advisable than in some other localities; and the early implantation of mediastinal and other metastases in breast cases is apt to ultimately defeat complete eradication in late cases.

Those surgeons who have the opportunity to do a complete modern excision operation in an incipient carcinoma of the breast, without apparent axillary involvement (the operation being performed with a full appreciation of the dangers of operative reinfection and without a preliminary wounding of the growth for histologic examination), will have such a reasonable percentage of success that a search will not be made for other methods of equally local character; for the chief source of failure will be a pre-existent metastasis in a large proportion of cases, breast carcinoma being peculiarly liable to early metastases.

Two classes of cases, nevertheless, remain for the major operation of zinc-mercury ionization in breast carcinoma. One of them consists of incipient, single nodules of carcinoma in young women, in whom a preservation of the breast with eradication of the carcinoma is highly desirable; and this class includes also those cases in which the diagnosis between a benign growth and malignancy is still somewhat doubtful. The general practitioner, particularly, bears the responsibility of decision in these cases. Shall the breast be sacrificed at once while still in doubt? If a specimen be taken for diagnosis, will not the traumatism and cutting of the veins and absorbents in procuring the specimen lead to metastasis (if not already present) during the time necessary to obtain the opinion of the pathologist? Of one question he will have no doubt, and that is that mere excision of the nodule is not to be thought of for a moment if it is malignant.

Under these circumstances a bipolar destructive ionization of the nodule and its immediate surrounding tissues, within five minutes after taking the specimen for biopsy, is the proper course. To this may be added a similar destruction of any suspicious axillary tissues at the same operation, or later. Should the careful study of the specimen by the pathologist then result in a verdict of benignity, no special harm is done, while a verdict of malignancy finds the patient as perfectly protected, it is believed by the author, as if the breast had been removed and the axilla cleaned out.

If there be cancerous cells in distant portions of the breast this course will fail to remove them, of necessity, and it should be restricted to cases showing a single nodule. Should the nodule prove to be a cyst, as sometimes happens, the ionic destruction is the best course to pursue in this case also, disposing effectually of the possibility of a malignant infection of the cyst subsequently, the process being an excellent method of eradicating a cystoma in this situation. The removal of all disease from the axilla by this method is as certain, if not more certain, than is possible by excision *en masse*.

The other class of cases in which ionic sterilization is preferable are those more advanced carcinomas of the breast, still apparently free from metastasis, in which the growth is so closely adherent to the chest wall, and presents such distinct evidences of axillary involvement, as to present a poor prospect of eradication by excision. There is no question of our ability to eradicate the disease in the deep structures of a semi-adherent growth by these methods in some instances when excision is impossible. Even the outer surfaces of the ribs may be cleared off by ionic sterilization, without danger of operative reinfection; while a bipolar destruction of axillary structures is so thorough and free from re-implantation dangers that it may be employed usefully even when it is thought feasible to remove the breast itself by the knife. It is true, of course, that the final result of all of this latter class of cases is likely to be an ultimate failure of the vital powers by the continued progress of unrecognized, pre-existent metastatic deposits, of the existence of which at the time of the operation we have no means of knowing in spite of blood examinations; yet the patient's sufferings are greatly relieved by a permanent removal of the local disease.

FIRST SERIES OF BREAST CASES

Date of Treatment	Age	Referred by	Description of Growth and Condition on Application	Nature of Operation	Ultimate Result
Mch. 3 1896	36	Inoperable, recurrent sarcoma of right breast, two years after excision. Evidences of metastasis present.	Minor applications, zinc-mercury, 25 to 100 ma., for 15 min., repeated daily.	Local improvement. Patient developed mania and died, shortly after returning home.
Nov. 10 1896	48	Inoperable, recurrent carcinoma of right breast, three years after excision. Pronounced cachexia.	Minor applications, zinc-mercury, 35 to 50 ma., followed later by bipolar major application, 1000 ma. for 15 min.	Local improvement. Cachexia deepened and patient died some months later of general metastasis.
Oct. 14 1897	36	Dr. W. C. Thompson, Plattsburg, N. Y.	Inoperable, fulminating carcinoma of both breasts with axillary infection. Cachexia present from internal metastasis.	Major monopolar, mercury ions from gold electrodes, three operations, 800 ma. for 14 min.; 350 ma. for 10 min.; and 1200 ma. for 30 min.	Immediate shrinkage of growths in both breasts and axilla. Cachexia increased steadily, from which death resulted during year.
Nov. 30 1897	63	Dr. Ida E. Richardson, Philadelphia, Pa.	Inoperable, recurrent carcinoma of right breast and axilla, 10 months after excision. General health poor.	Major monopolar, mercury ions from gold electrodes, 500 ma. for 15 min. Eighteen months later, 200 ma. zinc-mercury for 25 min. to axilla.	Permanent removal of all local disease in both sites and apparent restoration of health, followed later by evidences of mediastinal growth causing death at end of five years, without local recurrence.
Feb. 19 1898	50	Dr. E. H. Pomeroy, Calumet, Mich.	Inoperable, recurrent carcinoma of right breast, three years after excision. Pronounced cachexia present from apparent metastasis.	Major monopolar zinc-mercury ions, with both gold and zinc electrodes, 800 ma. for 50 min.	Local improvement. Patient failed in strength steadily and died of inanition 8 weeks later. Autopsy revealed carcinoma of adrenals.
Nov. 11 1898	51	Operable carcinoma of outer lower quadrant right breast.	Major monopolar, mercury ions from gold instrument, 350 to 475 ma. for 40 min.	Patient living and well, though it is believed that an excision operation was done in axilla some years after ionic operation.
Mch. 29 1899	57	Dr. A. F. Müller, Germantown, Phila.	Inoperable carcinoma of whole of left breast, immovable on chest. Cachexia present.	Major bipolar zinc-mercury, 400 to 800 ma. for 1 hr.	Local eradication. Patient's general health continued to decline and death occurred from metastasis some months later.

FIRST SERIES OF BREAST CASES—Continued

Date of Treatment	Age	Referred by	Description of Growth and Condition on Application	Nature of Operation	Ultimate Result
Apr. 13 1899	44	Dr. J. J. Moylan, Germanatown, Phila.	Inoperable carcinoma of whole of left breast and axilla. Patient in poor health.	Major monopolar, changed to bipolar, zinc-mercury ions, 300 to 500 ma. for 1 hr., divided between breast and axilla.	Scar in breast healthy one year later, but disease noted between the two sites of application. Patient cachectic.
Apr. 27 1899		Inoperable, recurrent carcinoma of right breast, 19 months after excision, with evidences of metastasis.	Major monopolar gold-mercury, followed by zinc-mercury ions, 300 to 450 for 1 hr.	Local eradication, but health remained poor. In bad general condition at last report.
Dec. 8 1899	41	Dr. J. E. Byers, Butler, Pa.	Inoperable, recurrent carcinoma of both breasts and axilla, with cachexia. Has had two operations by excision, last 3 months ago.	Major bipolar, zinc and gold-mercury, 600 to 700 ma. for 2 1-2 hrs.	Local improvement, but ultimate local failure to eradicate. Patient died during year of general carcinomatosis.
Feb. 14 1900	62	Dr. W. E. Duel, Canastota, N. Y.	Inoperable, recurrent carcinoma of front of chest, right side and right axilla, with cachexia.	Major monopolar gold-mercury, 400 to 600 ma. for 2 1-4 hrs., 7 electrodes.	Patient returned home before separation of slough and died of secondary hemorrhage during separation.
Apr. 2 1901	63	Inoperable, recurrent carcinoma of site of right breast, ulceration measuring 11x7 inches and extending to ribs, with axillary involvement. Cachexia marked.	Four major zinc-mercury operations, 500 to 700 ma. for about 1 hr., during 1 1-2 yrs., with many minor applications.	Eradication of disease in breast and axilla and restoration to good health. A spot deep in shoulder remained inaccessible and increased, of which she died about 4 years later.
Aug. 5 1901	36	Dr. F. G. Du- Rose, Selma, Ala.	Inoperable, recurrent carcinoma of right breast, 5 months after excision, with metastasis.	Major bipolar zinc-mercury, 1200 ma. for 2 hrs.	Relief of pain, but no arrest of local growth. Patient died 5 weeks later of metastasis.
Oct. 29 1901	65	Dr. Chas. M. Dalsen, Phila- delphia.	Inoperable carcinoma of right breast with cachexia.	Major bipolar zinc-mercury, 600 to 700 ma. for 3 hrs.	Local eradication. Patient died of continued internal metastasis Sept. 21, 1902, without recurrence.

FIRST SERIES OF BREAST CASES—Continued

Date of Treatment	Age	Referred by	Description of Growth and Condition on Application	Nature of Operation	Ultimate Result
Apr. 21 1902	58	Inoperable, recurrent cancer <i>en masse</i> of right side of chest. Right breast removed by excision 2 years before.	Palliative bipolar applications on two occasions.	No benefit from applications. Disease progressed steadily until death occurred, within a year.
Oct. 7 1902	59	Dr. Theo. Saubury, Burrs-ville, Md.	Inoperable carcinoma of right breast and axilla. General health poor.	Major bipolar zinc-mercury, 600 to 720 ma. for 80 min.	Local eradication remained apparent for 2 years, when diseased glands in neck were noted, followed by general carcinomatosis and death in 1907.
Feb. 14 1904	47	Dr. J. G. Davis, New York.	Inoperable, recurrent fulminating carcinoma of right breast, 2 months after removal of left breast for same. Cachectic.	Major bipolar zinc-mercury, 500 ma. for 50 min.	Eradication not complete locally. X-rays used. Death finally from metastasis.
Apr. 24 1904	49	Inoperable carcinoma of right breast with profound cachexia. Has had prolonged X-ray treatment.	Three major bipolar zinc-mercury operations, 800 to 1000 ma. for 60 min.	Failure to eradicate locally. Patient died of continuance of metastasis 2 months later.
July 2 1904	40	Dr. John W. Daniel, Savannah, Ga.	Inoperable carcinoma of right breast and axilla, with evidence of metastasis.	Major bipolar zinc-mercury, 350 to 500 ma. for 60 min., followed by minor applications by Dr. Daniel.	Patient showed no evidence of disease a year later. Word received subsequently of her death from metastasis.
Sept. 26 1904	44	Inoperable carcinoma of both breasts, with metastasis to mediastinum, and some cachexia.	Major bipolar zinc-mercury, 1200 for 1 hr. to each breast, two operations.	Partial local eradication. Evidence of mediastinal growth increased, followed by death within year.

On the whole, in carcinoma of the breast, as in other portions of the body, excision is to be recommended as quicker and involving a shorter stay in the hospital, *if the disease can be excised entire without wounding its structure*, with the special reservation that this necessarily implies a complete amputation of the organ, and that in certain young women the zinc-mercury ion method renders the latter unnecessary. When the success of the excision is rendered doubtful by fixation to the chest wall or invasion of the axilla the ionic method presents greater possibilities of success in actual eradication, and is more scientific as a palliative.

Contraindications of Ionic Surgery in Mammary Carcinoma.—If the fixation and immobility of the carcinoma are of such character and long duration as to indicate extension of the disease within the chest cavity, ionic or any other kind of surgery will do harm and can do no good. The same is true of infection of the supraclavicular glands, or of the sub-dermic extension of the disease known as cancer *en cuirasse*. Too low a percentage of hemoglobin also contraindicates surgical intervention of any kind.

FIRST SERIES (see Tables, pages 182, 183, and 184).

The most striking facts to be gathered from the above tabulation of the twenty cases of breast carcinoma placed under destructive ionization prior to 1905 are: (1) That though one patient, the sixth on the list, is still living, and her present freedom from the disease may be partly due to the imperfect ionic operation done eleven years ago, none of the patients were cured by these early ionic operations. (2) That, with the above exception, all were inoperable in the ordinary sense when received for treatment, eleven being also recurrent after excision; yet, in spite of these deplorable conditions, eight of the nineteen inoperable cases were greatly relieved in local and general health, and their lives prolonged, while others were temporarily benefited. (3) That these extremely vigorous efforts to ascertain the value of major ionic surgery in unselected cases of inoperable cancer of the breast resulted in but one death from secondary hemorrhage, probably preventable, and no operative deaths.

The failure to eradicate the disease in the one operable

case in the list was evidently due to faulty technic early in the development of the method (1898). In this case a gold-mercury electrode was used, a technic abandoned in more recent cases for zinc-mercury points, it being found impossible to localize the effect so accurately with the gold electrode and fluid mercury as with the zinc-mercury points.

SECOND SERIES.

No. 46. ONCOLOGIC HOSPITAL. *Carcinoma of Breast.*—Mrs. S. G. was referred by Dr. E. C. Hough of Villisca, Iowa, February 8, 1905. Four or five years ago she noticed a tumor in the right breast. During the past year Dr. Hough has applied the x-ray, the last application having been six months ago, when it was stopped by reason of the appearance of a dermatitis.

Examination showed the whole of the breast indurated and fixed to the chest wall, with a large ulceration occupying two-thirds of the tumor. No glands were infected. The patient's color was bad.

February 10, 1905. Under general anesthesia, a monopolar application of 560 milliamperes was made for forty minutes, but as this amount could not be increased by reason of poor respiration the application was then changed to bipolar and a current of 1500 milliamperes applied for twenty minutes, with a dozen electrodes. The separation of the slough was without incident, but showed some induration on the sternal edge of the wound, for which two minor applications of 60 and 100 milliamperes were made during March and April. The induration remaining in the skin itself was attacked April 26 by a second major monopolar application under anesthesia. Two more minor applications to suspicious granulations were required on June 17 and July 14, and the patient was discharged from observation in September with the wound thoroughly healed and showing no evidence of disease. The general health had also improved.

June 3, 1908. Dr. Hough writes that the patient died on this date of an affection of the chest, supposed to be la grippe, of which she had suffered for some months, but that there was no recurrence of the disease apparent.

No. 85. ONCOLOGIC HOSPITAL. *Recurrent Carcinoma of Breast, with Metastasis.*—Mrs. L. W., aged 75, was admitted

September 4, 1905, for local treatment of a large carcinomatous ulceration of the right breast, following a caustic paste application nine years before. Palliation alone was aimed at, as the patient was profoundly cachectic. A major monopolar application of 400 milliamperes was made for 45 minutes. Result: improvement, but not local eradication.

No. 123. ONCOLOGIC HOSPITAL. *Recurrent Carcinoma of Right Breast.*—Mrs. K. E., aged 34, was admitted May 11, 1905. Three years before she had been struck in the affected breast. Three months later a hard lump appeared at the site of the injury and was treated by a caustic plaster, the present growth appearing seven months ago and being more rapid in development than the original one.

There is an ulcerated, proliferating growth involving the whole breast and about the size of an orange. There is some axillary involvement, and radiating pain to shoulder and arm. Microscopic examination showed squamous-cell carcinoma.

A major monopolar application of 600 to 800 milliamperes for one hour was made May 13. The slough separated without incident, and June 9 she was discharged to the dispensary with a healthy wound nearly healed over. The patient failed to return to the hospital again, and diligent inquiry elicited the information some months later that she was in poor health.

No. 125. ONCOLOGIC HOSPITAL. *Carcinoma of Right Breast.*—Mrs. L. H., aged 61, was admitted May 4, 1905, with a complete involvement of the right breast in a proliferating mass, deeply ulcerated. The patient first noticed a lump in the breast thirteen months before, the ulceration being recent. There were no apparent enlargements of the glands, though some evidences of cachexia were present. Microscopic examination showed cylindrical-cell carcinoma.

A major bipolar application of 700 milliamperes for one hour was made May 8, under general anesthesia, the ionic destruction being extended to the apex of the axilla. The slough separated without incident, and she was discharged to the dispensary June 9 with uncertain granulations on the bottom of the wound, being given directions to return regularly for observation.

The patient did not return to the dispensary, and word was received some months later that she was under x-ray treatment in another hospital for a recurrence.

No. 198. ONCOLOGIC HOSPITAL. *Carcinoma of Right Breast, with Metastasis.*—Miss I. E. L., aged 52, was admitted July 31, 1905. Four years before a growth was noticed in the right breast, which was allowed to grow steadily since without effort at remedy. Of late the general health has become poor, and there is evidence of metastasis and cachexia. The growth is the size of half a cocoanut, ulcerated in the center, and slightly adherent to the chest wall. It extends into the axilla and below the axilla on the chest. Microscopic examination showed it to be a carcinoma.

August 2. It was decided to give the patient local relief, and on this day she received a major bipolar application of 1200 to 1600 milliamperes for 75 minutes, under general anesthesia.

October 5. The wound is healthy except at the lower edge. Second major bipolar application of 300 to 350 milliamperes for 10 minutes. The recovery from the anesthetic was prolonged, and shortly after an aphasic condition developed, accompanied by pain in the right leg. She was seen in consultation by Dr. Chas. K. Mills, who thought the aphasic symptoms due to metastasis to the brain. The cachectic condition, which had been marked on admission, gradually returned, and the patient died of general inanition some months later, without local recurrence.

No. 257. ONCOLOGIC HOSPITAL. *Carcinomatous Nodule in Left Breast, with Axillary Involvement.*—Miss I. M. T., aged 25, was admitted October 30, 1905, with a movable tumor in the upper, outer quadrant of the left breast. The tumor had been first noticed two or three years before, was painless, but lately had increased rapidly in size.

Examination shows a movable tumor no larger than a peach stone, with irregular edges. No enlargements of the axillary or supra-clavicular glands could be detected, and the patient's general health is good.

October 31, 1905. The clinical indications pointing to carcinoma of the breast in its earliest stage, which were subsequently verified by the microscopic examination showing squamous-cell carcinoma, it was decided to save the breast, if possible, by destroying the tumor in situ. She was accordingly placed under general anesthesia on this date, a specimen removed for histologic examination, and a bipolar application

of 200 to 350 milliamperes made for 50 minutes. The slough separated without incident and the patient was discharged to the dispensary November 18. On January 10, 1906, a minor application of 10 ma. was made to a doubtful granulation for eight minutes.

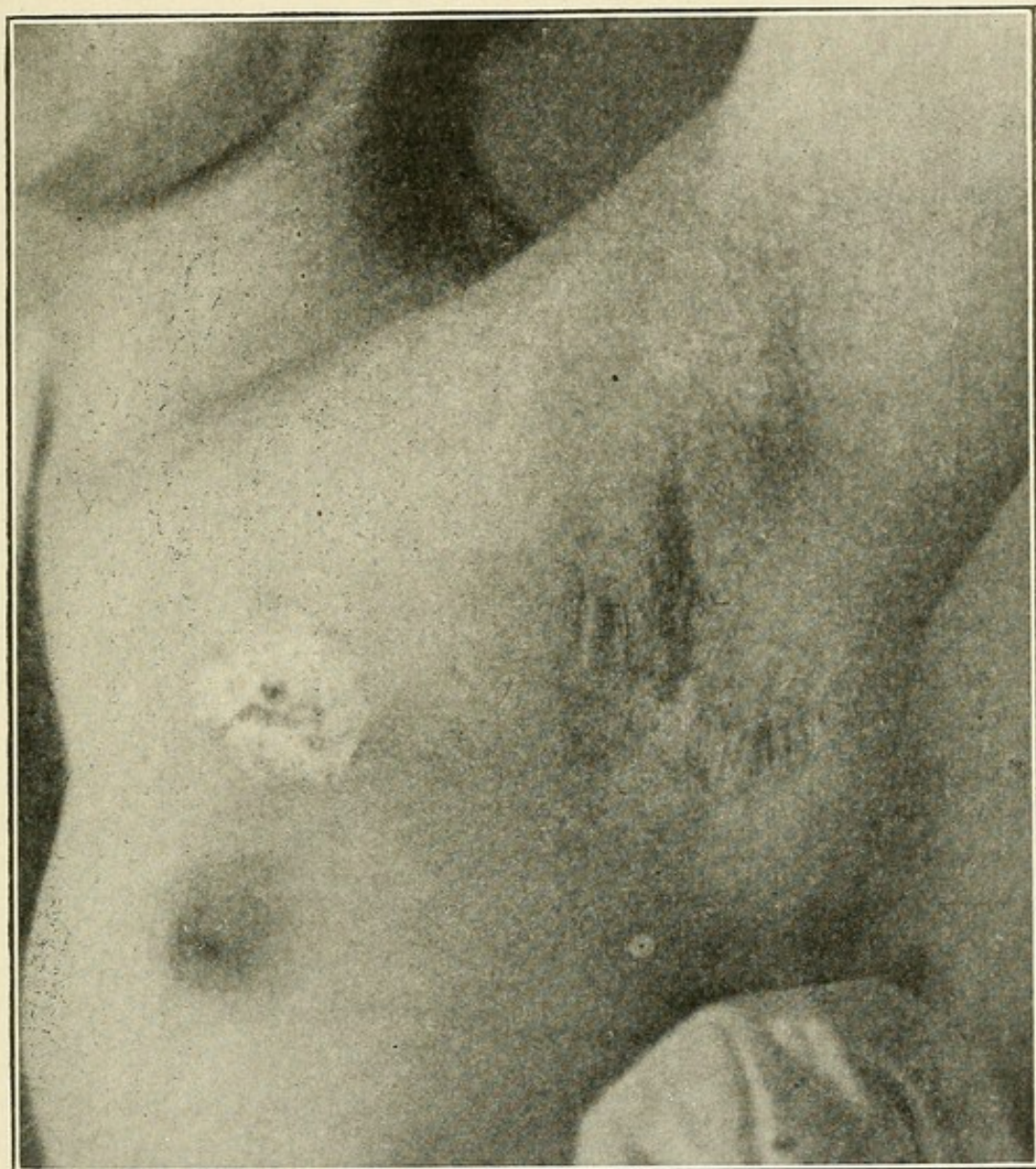


FIG. 66.—Photograph of scars in breast and axilla of a young woman, four years after ionic eradication of carcinomatous nodule in breast and three years after similar eradication of carcinomatous gland in the axilla. The breast is practically intact.

September 25, 1906. Patient re-admitted for the destruction of an enlarged gland in anterior portion of left axilla. In July she was admitted for the same purpose, having been kept under monthly observation for the particular purpose of watching

the axilla, but on placing her on the table at that time the enlarged gland could not be found. It is more evident now, being about the size of a pea. It was decided to destroy all tissues in the axilla as a precautionary measure. She was accordingly anesthetized, an electrode thrust through the skin into the gland, and 300 to 400 milliamperes applied monopolar for 30 minutes with six electrodes to the whole thoracic portion of the axilla. (Remark: There is no reason why the application should not have been bipolar, considering the proximity of the heart, with equally good results.)

The photograph (Fig. 66) shows the four-year-old scar of the first operation in the breast, and the three-year-old scar of the second operation in the axilla, as they appear at present.

The patient is in perfect health and without recurrence at the present time, November, 1909, four years after the first operation and three years after the second.

No. 258. ONCOLOGIC HOSPITAL. *Carcinomatous Nodule in Breast*.—Miss P., aged 46, was referred by Dr. N. E. Smith of Fayette, Mo., November 3, 1905. For two or three years she had noticed a nodule in the left breast which was at first movable, but of late had grown more fixed. It has not given rise to pain. Her mother had died of cancer of the stomach.

Examination shows a flattened induration in upper, inner quadrant of the left breast about two inches in diameter, somewhat adherent to the overlying skin and free from special sensation.

November 4, 1905. A major bipolar application was made under ether, 275 to 450 milliamperes being employed for 20 minutes. The specimen removed showed carcinoma. Separation of slough and healing were uneventful, and the patient was discharged without manifest evidence of disease January 8, 1906.

November 17, 1909. Letter received saying scar is healthy and that there is no sign of recurrence.

No. 275. ONCOLOGIC HOSPITAL. *Carcinoma of Breast and Axilla, with Metastasis*.—Miss K. R., aged 46, was admitted from Pittsburgh, Pa., December 18, 1905. Her mother had cancer of the hand and a sister has cancer of the breast. Six months ago the lump was first noticed in the right breast; but it has grown so rapidly that at the present time the whole

breast is infiltrated and the overlying skin reddened and about to break down. There is a group of enlarged glands in the axilla, and the patient presents evidence of metastasis and moderate cachexia.

December 21, 1905. To give the patient the benefit of the doubt as to the presence of metastasis a major bipolar application was made, under ether, 800 to 1800 milliamperes being employed for 70 minutes to both breast and axilla. After the separation of the very large slough the outer surfaces of three ribs were exposed, and during the healing an obstinate sinus developed in the tissues of the chest wall below the wound. Evidence of metastasis to the brain developed later, and the patient was taken home in a poor mental condition April 7, but with the wound healed and showing no local evidence of the disease. The mental symptoms increased in severity, resulting in death shortly after from metastasis.

No. 277. ONCOLOGIC HOSPITAL. *Carcinoma of Left Breast*.—Miss M. A. H., aged 63, was admitted from Lawrenceville, N. J., December 20, 1905. Five months before she had first noticed a tumor in the left breast near the nipple. It has increased rapidly since, and is the seat of lancinating pains.

The central portion of the left breast is indurated, though movable on the chest wall, and the nipple deeply retracted. A group of enlarged glands is found in the axilla, but no appreciable evidence of infected supraclavicular glands. The general health was poor, with some renal disturbance.

After attempts to improve the general health, a major bipolar application was made, under ether, 800 to 1800 milliamperes being used for 45 minutes to breast and axilla. The slough, apparently including the entire breast and the contents of the axilla, separated January 19 without incident, and the patient was discharged with an excellent scar April 27. The general health improved steadily for a year or more, and no evidence of the presence of metastasis in the supraclavicular glands showed until the expiration of one year and nine months from the operation, when a chain was noticed October 1, 1907, extending from the clavicle to the post-auricular region. She was re-admitted to the hospital a week later, with the cervical glands grown decidedly larger in the interim, and distinct evidence of recurrence in the wound was also noticed. Patient

was placed on the x-ray treatment, but failed steadily, and died a year later.

No. 280. ONCOLOGIC HOSPITAL. *Carcinoma of Right Breast.*—Miss A. B., aged 33, was admitted December 29, 1905. Family history negative. Two years ago a tumor in the center of the left breast was noticed, but its existence was concealed by the patient until she was suddenly attacked by an arterial hemorrhage early in the morning two days ago. She was seen by Dr. John B. Deaver the same day and was referred by him to the Oncologic Hospital.

On examination, the whole of the left breast was found to be infiltrated with the growth, the central portion being broken down into a large cavity, at the bottom of which was a bleeding artery. It was learned that she had been ill for six months past, during which time but little food had been retained on the stomach. Her temperature was 102, and her appearance exsanguine. A severe hemorrhage occurred during the inspection, and she was sent to the hospital at once.

December 29, 1905. On arrival of the patient at the hospital she was placed on the table for a major bipolar operation, which was done without complete removal of the packing and bandages, as it was feared that another hemorrhage would be fatal. A large bipolar negative electrode was placed on the central packing of the cavity, which was wetted with a weak solution of sulphuric acid and water; long active zinc-mercury breast electrodes were inserted between the growth and ribs, the tips meeting in the center; and a current of 1900 to 2000 ma. turned on and maintained for 75 minutes, a specimen being meantime removed for microscopic examination. The procedure was successful in sealing the large artery that had been eroded by the disease, and at the end of the time mentioned the whole of the diseased breast and axillary structures were devitalized and converted into a gray, dry crust. The temperature, which was 101.4 before operation, fell to normal the same night and remained normal several days, rising above normal only a few days during the separation of the slough, which was removed on the fifteenth day, showing a large, healthy wound, to which the violet ray was applied to hasten granulation.

The convalescence of the patient was uneventful, though prolonged on account of the large surface to be cicatrized, the

wound extending well up into the axilla. She was discharged to the dispensary April 13, 1906, with a healthy wound, but with an obstinate sinus extending into the cellular tissues from the lower edge of the wound for which she was referred to Dr. Hewson, being finally discharged from the dispensary without manifest evidence of disease some months later.

The patient died in June, 1908, of spinal meningitis, with a perfect scar and no evidence of recurrence. No autopsy was available.

No. 304. ONCOLOGIC HOSPITAL. *Carcinoma of Breast, Axilla and Supraclavicular Region, with Metastasis.*—Mrs. A. K., aged 77, was admitted February 3, 1906, for temporary alleviation while waiting for admission to the Home for Incurables. There was a large denuded area occupying the site of the right breast, being a carcinoma recently under caustic treatment by an irregular practitioner. The axillary and supraclavicular glands were largely involved. A major monopolar application of 350 ma. for 30 minutes was made to the broken down tissues, followed by a series of ultra-violet ray applications, and the patient was discharged to the Home September 4, in an improved condition.

No. 338. ONCOLOGIC HOSPITAL. *Carcinoma of Right Breast.*—Mrs. T. W., aged 49, was referred by Dr. Frank O. Stem of Berlin, N. J., May 2, 1906. The growth involved the greater portion of the right breast, with greatest protrusion downwards: had existed for two years to the patient's knowledge, becoming painful five weeks ago. It is hard, and the skin is adherent over the most prominent portion, with distinct retraction of the nipple. It extends into the lower axillary space, but there are no separate glandular enlargements in this region nor in the supraclavicular region. Microscopic examination of specimen showed carcinoma. The patient's general health was poor and the urine contained traces of albumen.

After ten days' treatment of the general health, the patient was placed under chloroform and a major bipolar application made of 800 to 1600 ma. for 70 minutes, the electrodes including the axillary projection and most of the axillary tissues in the field of sterilization. The separation of the large slough was uneventful, and by the end of seven weeks the condition of the cicatrizing wound permitted her return home, with in-

structions to report at intervals. This was not done very regularly, and on a visit on December 9, 1907, a suspicious scab was noted in the center of the scar, which, however, did not represent recurrence of the disease, as it healed nicely on removal of the scab and the use of zinc oxide ointment.

At the present time, July, 1909, over three years after treatment, there is no evidence of either recurrence or of a pre-operatively-implanted metastasis.

No. 504. ONCOLOGIC HOSPITAL. *Carcinoma of Breast, Fulminating Type*.—Mrs. S. M., aged 52, was admitted January 3, 1907. Seven months before she injured the lower portion of the left breast by a broken corset steel, a tumor that was painful and quick-growing being recognized at the site of the injury several months later.

Though the known history of the growth is thus covered by seven months, it was found to be a large, reddened cystic mass, 5 by 6 inches (13 by 15 cm.) in diameter and involving nearly the whole of the breast, and apparently adherent to the chest wall. She was placed under a major bipolar operation January 4, under ether, 2000 milliamperes being employed with numerous electrodes for one and a half hours.

The patient recovered strength imperfectly after the operation, evidencing probably general metastasis, and showed, moreover, remnants of the disease in the bottom of the wound after the separation of the slough, these remnants increasing rapidly in extent. Minor applications were begun January 21, as much as 350 and 400 ma. being employed at first, bipolar, without severe pain, and on February 20 another major bipolar operation was done, with 1400 to 1800 ma. for 50 minutes.

On March 13 the increasing weakness as an indication of internal metastasis was supplemented by the appearance of raised, yellowish pink bullæ on a reddened and indurated base in several situations, notably the forehead, arms and fingers, arising apparently in the skin itself and greatly resembling in appearance the original growth. These continued to multiply and grow larger until her death, May 31, of asthenia.

No. 88. PRIVATE CASE BOOK. *Recurrent Carcinoma of Right Breast*.—Mrs. O., aged 42, applied for treatment of a recurrent growth of the right breast, April 9, 1907. The breast had been removed some months before by excision, the growth promptly returning, the site of operation being covered by car-

cinomatous nodules that adhere firmly to the chest wall. The patient was extremely anemic, and probably cachectic from extensive internal metastases, but to give her the benefit of a last resort, was placed under a major monopolar application at her home, April 10. She bore the chloroform badly, and shortly after a current of 300 to 400 milliamperes had been attained, suddenly expired—whether from the anesthetic or from inhibition of the respiratory innervation by the current could not be determined.

No. 676. *Recurrent Carcinoma of Left Breast.*—Mrs. V., aged 50, was admitted January 20, 1908. Four years ago a small tumor was “rolled out” of its capsule in the upper, outer quadrant of the left breast by a distinguished surgeon of the city, who pronounced the growth benign. Six months later the part was accidentally injured by a blow, followed by the development of the present growth. She has had over two hundred x-ray applications during the past eighteen months.

The upper and outer two-thirds of the breast is the site of a raised induration, 5 by 3 inches (13 by 8 cm.) in area, centering around the old scar, with the nipple somewhat fixed and retracted. In the axilla there are at least three enlarged glands, the largest about the size of a hen's egg. The patient's general health indicated the possibility of metastasis, as she was pale and apparently cachectic. Microscopic examination: carcinoma.

January 31, 1908. Major bipolar application, under ether, 1900 to 2000 milliamperes for one hour and fifteen minutes. A large slough separated in the usual time, without incident, but revealing quite an area of diseased tissue that had been missed in the upper angle of the axilla. This was attacked by minor applications beginning February 26 and ending two months later, during which time eighteen applications were made, varying from 60 to 30 milliamperes, for a half-hour each. An attack of erysipelas contracted from another patient interfered with treatment at this time, and on May 14 the patient was discharged to office care, three more small minor applications being made in the following month.

August 21. Photograph (Fig. 68) taken, showing an excellent scar and no sign of disease. The patient has gained considerably in weight and general health, but the ominous paleness persists.

The excellent health gained by the patient began to fail during the following winter, evidently from metastasis of long standing. Difficult respiration finally ensued, and on the 25th of August, 1909, the patient died of asthenia, without local recurrence. No post-mortem examination was available.

No. 808. ONCOLOGIC HOSPITAL. *Recurrent Carcinoma of Left Breast.*—Mrs. M., aged 40, was referred by Dr. W. W.

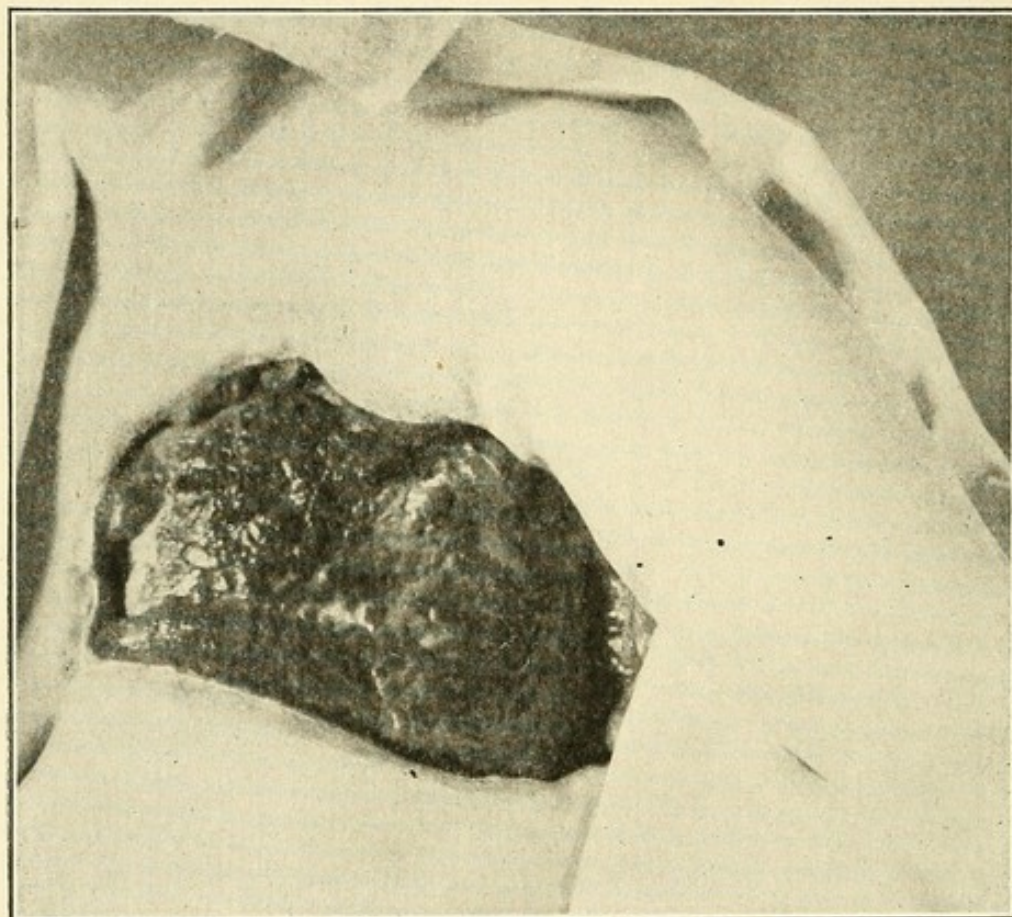


FIG. 67.—Appearance of wound after separation of devitalized tissue in Case 676. The axillary portion of wound shows undestroyed cancerous tissue, subsequently eradicated by minor applications.

Ray of Springfield, Ky., September 3, 1908. The primary growth was removed by excision January 8, 1909, a second operation for recurrent nodules in wound being made in the following July.

There are a large number of recurrent nodules beneath the skin near the scar of the excision operations, and a subdermic abscess beneath the lower angle of the scar. The axilla and supraclavicular regions seem to be free from the disease, but the wasted condition of the patient suggested a strong probability of metastasis to internal organs, though her color was

fairly good. Blood count: Erythrocytes 4,200,000; leukocytes 9,200; hemoglobin 60 per cent.

September 5, 1908. Major bipolar application under ether, 400 to 800 milliamperes, four to six needles to each spot, for a total time of 40 minutes, the negative being held against each spot in turn by an assistant.

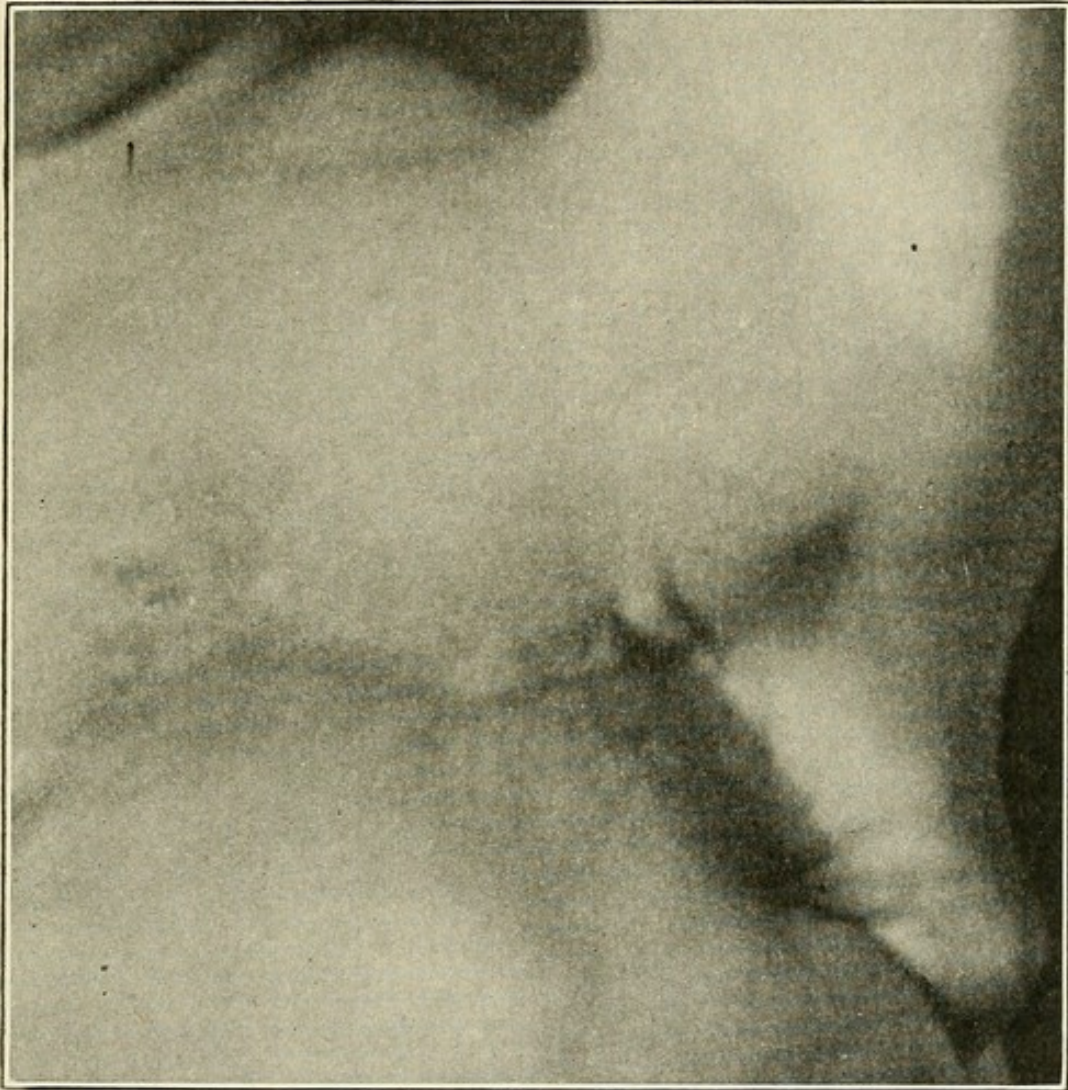


FIG. 68.—Case 676 after complete healing.

October 6. Minor application of 15 milliamperes for 30 minutes to a shot-like body beneath skin above wound.

October 13. Patient discharged to dispensary with healing, healthy wound. Small nodules, the size of bird shot, situated beneath the skin at a distance from the edges of the wound received minor applications October 17 and 20 and November 2, 6, 9, 21 and December 1 and 8. Also, on November 2 a gland beneath the clavicle, just external to outer attachment of the sterno-cleido-mastoid muscle, was found to be enlarged to size of a large pea and was destroyed by an ionic needle in-

serted through the skin, under novocaine local anesthesia, 15 milliamperes being used for 30 minutes.

December 17. Patient went home on account of continuing weakness and evidence of metastasis to the chest, with the local conditions greatly improved. Report received of increasing weakness and difficulty in breathing after her return home, and of her death February 16, 1909.

No. 990. ONCOLOGIC HOSPITAL. *Carcinoma of Right Breast.*—Mrs. J. S., aged 50, was referred by Dr. Stuart C. Runkle July 30, 1909. She had had a small movable lump in the upper, outer quadrant of the right breast since puberty. One year ago it began to enlarge, becoming ulcerated and painful five months ago.

Examination shows a cauliflower-like growth, 4 by 5 inches in diameter, projecting from front of breast, with eroded surface. It is somewhat movable on the chest wall. There is a large tumor in the axilla near its anterior border and several palpable glands, and a distinctly palpable enlarged gland immediately behind the clavicle. The patient is thin, of poor color, and probably cachectic. Blood count: red blood corpuscles 4,444,000; leucocytes 11,440; hemoglobin 80 per cent. Microscopic examination: carcinoma.

July 31, 1909. Major bipolar application under ether, 600 to 2000 milliamperes for one hour, to breast and axilla.

On the separation of the devitalized tissue the whole region occupied by the breast growth appeared free from the disease, but the axilla showed a mass of glands that had been missed in the bipolar operation. These were attacked by monopolar minor applications at once, three applications of 50 to 70 milliamperes for a half hour each being made in September and one November 4.

There is no sign of recurrence at present, an excellent scar covering the site of disease, and the patient's health is distinctly improved.

SUMMARY OF NEW SERIES OF BREAST CASES

<i>Operable Cases</i>		<i>Inoperable Cases</i>				
Without manifest evidence of disease	Failure	Without manifest evidence of disease	Died of metastasis without local recurrence	Improved	Failure	Died under treatment
4	1	2	3	4	2	1

CHAPTER XIII.

APPLICATIONS TO THE CERVIX UTERI.

Cancer of the body of the uterus should be removed by total hysterectomy when diagnosed sufficiently early, and in any stage is unsuitable for any curative application of electrical methods, save only those instances of atrophic endometritis that are found in elderly women that closely approximate malignancy in clinical course, and that often yield to a prolonged series of minor applications of zinc-mercury ions.

Of cancer of the cervix, it may be said, on the contrary, that the only efficient surgical remedy at present known is the method described in these pages, or the galvano-cautery operation of the late Dr. Byrne of Brooklyn, as it is now known that operative re-implantation of the disease is an almost certain accompaniment of a cutting operation in the confined area within which the operator is compelled to work. Yet, in spite of the adaptability of the sterilization method to the destruction of cancers within cavities of this nature, but few cases of the disease can be actually cured at present for the reason that the patients are almost invariably seen for the first time after the disease has advanced beyond the local stage. It is probable that not one case in fifty is diagnosed before a purulent discharge or slight hemorrhages occur, yet these signs indicate that the disease has already progressed to the stage of ulceration, and possibly regional infection of the glands. In the greater number pain also is present at the discovery of the growth, and this indicates an even later stage. It is to be feared that early diagnoses will not be made until general practitioners realize the great value of an educated touch as our best reliance for this purpose, and insist on periodical examinations of all women over forty years of age.

The curative employment of zinc-mercury ions is necessarily confined to the incipient cases, with the disease limited to the cervix alone. Owing to the insensitive nature of this por-

tion of the organ what may be called a minor application is often sufficient, when repeated daily; for as much as 100 to 150 milliamperes may be used, monopolar, without anesthesia, and repeated daily until sufficient sterilization has occurred, or intermitted until the separation of the slough enables the operator to judge the sufficiency of the destruction before starting another series.

The experience indicated below shows that though these methods are often valuable as palliatives in advanced cases, they cannot be depended on to materially check the course of the disease in these stages, whether employed in minor or major form.

The technic of the minor application in the incipient case is as follows: With the patient in the dorsal position, or rarely in the Sims', the cervix is brought into view by means of a cylindrical glass speculum and the slender, pointed electrode shown at D, Fig. 15 (which has had a piece of No. 28 wire attached to the blunt end and been insulated with fused sealing wax to $1\frac{1}{2}$ cm. of the tip, the latter being freshly amalgamated), is inserted into the diseased part parallel with the axis of the cervix, the kaolin pad and its conducting plate is placed on the abdomen, or under the back, and a current of 50 to 150 milliamperes is turned on and maintained for 30 minutes. It is usually necessary to hold both speculum and electrode in place, but in certain cases the insertion may be made by touch, without the speculum, and the electrode held in position by a tension band of adhesive plaster attached above the pubes and to the buttocks, passing over the outer end of the electrode and holding it in place with gentle pressure as an arrow is held in the bow.

When the applications are made with the glass speculum, which is the preferable technic, the field of application may be kept under continuous brilliant illumination by the expedient of placing a 6-volt miniature lamp inclosed in a slender glass tube in the speculum, lying alongside the electrode, thus permitting an accurate visual estimate to be made of the superficial extent of ionic destruction.

The applications are repeated daily until the area of sterilization includes the whole of the disease and the immediately contiguous parts of the cervix, or until from four to six applications have been made, when they should be intermitted until

such time as the slough has separated, and then resumed according to indications. By this method about five or more applications will equal in destructive and sterilizing effect an average major monopolar application, with an opportunity afforded to avoid undue action and to observe the results between treatments. The patient should be kept under weekly observation for at least a year, and the applications renewed on the appearance of suspicious nodules or other evidences of local disease at any time within three years.

The technic of palliative applications in more advanced cases, in which extension to the broad ligaments or to the glands of the pelvis, or the presence of metastasis, renders a cure impossible, is exactly similar, except that a blunt electrode will here suffice to obtain excellent results in control of hemorrhage, lessening of pain, and removal or lessening of odor.

FIRST SERIES.

The first series includes 10 cases, of which 8 were inoperable, 5 being also recurrent after cutting or curetting operations, and 2 operable.

Of the inoperable cases, 7 were alleviated and 1 died of peritonitis following a major monopolar operation. There were six major monopolar operations in these cases.

Of the two operable cases, in both of which minor applications alone were made and in one of which a cure was effected, a full account is appended.

No. 6, PRIVATE CASE BOOK. *Incipient Cancer of the Cervix.*—Mrs. E. A., aged 49, was first seen in June, 1896, with an irregular, deep ulceration of the cervix with proliferating surface. The late Dr. Theophilus Parvin saw the case in consultation and agreed in the diagnosis of squamous-celled epithelioma on the microscopic showing. Treatment was by minor applications of 100 milliamperes with a blunt electrode, the applications having a duration of 10 minutes and being repeated almost daily for six weeks, when the patient was sent home to return for similar applications twice a month for six months. At the end of the course of treatment mapped out, which was carried out with regularity, there was no evidence of the disease, the puckered scar being quite normal in appearance. At one of her regular visits for inspection one year

later she was again seen by Dr. Parvin and the results noted concurred in.

In a letter dated September 14, 1903, Dr. Chavanne, of Salem, N. J., writes that the patient died of phthisis pulmonalis about seven years after the termination of the treatment. There was no recurrence of the disease.

No. 67, PRIVATE CASE BOOK. *Carcinoma of Cervix*.—Mrs. J. E., aged 57, was referred by Dr. Franklin D. Castle of Philadelphia, November 7, 1903. Family history negative. Five years before she had been treated by Dr. Castle for benign uterine trouble; otherwise the personal history was good. Four months ago Dr. C. was again called and instituted local palliative treatment for a condition that he ultimately diagnosed as carcinoma.

The patient, who had been confined to her bed for some time, presented the appearance of good health save for pronounced anemia. *There is much abdominal and pelvic pain*, with dribbling hemorrhage and offensive discharge. Examination revealed a deep ulceration of the cervix with indurated and eroded edges which bled freely on touch, the end of the finger being readily inserted within the cavity produced by the ulceration. The uterus was movable.

As the patient was unable to leave her room, a suitable portable apparatus was sent to the house and proper arrangements made for the strongest mercury ion applications possible without anesthesia. On November 7, 10 and 12 applications of 200 milliamperes were made with a blunt mercury-covered gold anode ($\frac{3}{4}$ cm. by 2 cm.), for 30 minutes' duration, the blunt electrode being held immovably just within the erosion. After each application but little mercury would be left on the gold surface. November 14 the electrode was changed to a zinc-mercury one of the same shape and dimensions, as sufficient destruction had not been secured, and from 100 to 150 milliamperes applied as before for 30 minutes on this date and on the 17th, 19th and 21st. On the 24th the patient was quite weak and treatment was not given. On December 7 a pear-shaped slough, round and hard, was lifted out of a cavity formed by the outer walls of the supravaginal cervix and the corpus, leaving a shelled-out lower segment of the uterus with apparently healthy edges. No bleeding occurred at any time after the beginning of the treatment, and the odor ceased after

the first applications. The slough was shortly after shown to the Northern Branch of the Philadelphia County Medical Society.

The patient was kept under observation for two years and no local recurrence was noted, though she complained of a continuance of the abdominal pain of a somewhat vague character. Her condition three years later was kindly reported to the writer by her physician, Dr. Henry Beates, Jr., in a letter dated March 13, 1909, as one of "carcinomatous infiltration of the pelvic tissues. Her sufferings are sufficiently intense to require careful analgesic measures."

It will be noted that this case presented the unusual symptom of abdominal pain when first seen: a rare phenomenon in the early stages of carcinoma of the cervix, and one that renders the prognosis distinctly gloomy.

SECOND SERIES.

No. 35. ONCOLOGIC HOSPITAL. *Carcinoma of Cervix*.—Mrs. Mary Q., aged 53, was admitted February 1, 1905. She had passed the menopause two years before, but for three months has had a slight "show" every two weeks. Two weeks ago she had a severe hemorrhage.

Examination shows a deep ulceration in the os, with ragged edges distinctly indurated to the touch. The uterus was movable and the adnexæ apparently healthy. It was decided to place her on the strongest minor applications that she could bear, push the method until the affected parts were included in the area of devitalization, and then wait for the separation of the devitalized tissue before renewing the applications.

February 4. An appropriate electrode was selected and insulated to 2 cm. from the tip. With the cervix exposed by means of a glass cylindrical speculum, the electrode was painlessly thrust into one side of the excavation and 150 milliamperes turned on and maintained for 30 minutes. This procedure was repeated February 6, 11, 24 and 28, and March 2 and 8. One hundred milliamperes only were attained March 13, 16, 18, 23, 27 and 30, when a rest was taken on account of the discharge being abundant. April 6 she received 80; April 11, 75; April 15, 100; April 24, 60; April 27, 50. The sloughing was now free, the patient's temperature, respiration and pulse normal.

May 12. Examination showing excellent edges in the wound, no application is made.

May 15. Final application of 25 milliamperes and discharge of patient to the dispensary, with urgent injunction to return to the dispensary at intervals of one week, as the probability of cure was great.

June 8. Forty milliamperes for 30 minutes to uncertain edge.

The patient failed to return after July and was not seen until September, when she was looked up at her home and found to have a recurrence of the disease.

No. 162. ONCOLOGIC HOSPITAL. *Inoperable Carcinoma of Cervix*.—Mrs. K. M., aged 45, was admitted June 24, 1905, with an extensive carcinomatous ulceration of the cervix, which had extended beyond the organ, as the uterus was adherent on the left. Palliative minor applications with a blunt zinc-mercury electrode were decided on. She was able to take 200 milliamperes for 30 minutes on the following dates: July 6; August 1, 7 and 11; September 5, 9 and 26; and October 2, 6, 9, 20, 23 and 30.

In spite of decided palliation the disease remained uncontrolled, and further active treatment was abandoned. She died March 5, 1906.

No. 247. ONCOLOGIC HOSPITAL. *Inoperable Carcinoma of Cervix and Vagina*.—Mrs. A. C., aged 37, was admitted October 20, 1905. One year ago she suffered a miscarriage at three months; a month after recovery her menstruation returned and has continued as a dribble since, with rare periods of relief. Two weeks ago she was admitted to the Lancaster General Hospital at Lancaster, Pa., but after etherization the surgeon decided not to operate.

Examination shows a large growth involving the mucous membrane of the anterior wall of the vagina and the cervix, and a similar growth somewhat smaller in the posterior wall of the vagina, both proliferant and of a whitish-red color on the surface. There are several palpable enlarged glands in the groins. Microscopic examination: carcinoma.

Between October 21, 1905, and April 11, 1906, the patient received four major monopolar applications under general anesthesia, each of 300 to 400 milliamperes, for durations varying from 20 to 30 minutes, and a considerable number of

minor applications, none of which showed lines of demarcation falling entirely within healthy tissue.

May 4, 1906. The results attained appearing to be only palliative, the patient was referred to the x-ray department of the hospital in the hope that more could be done. On the third of June she returned to her home in an unimproved condition, and notice of her death was received some months later.

No. 425. ONCOLOGIC HOSPITAL. *Carcinoma of Cervix Uteri*.—Mrs. S. B. K., aged 36, was admitted April 11, 1907. Patient had been under treatment for uterine trouble of uncertain character, but has been better of late years. Ten weeks ago, while suffering from an attack of influenza, she had a uterine hemorrhage, which has continued during three out of four weeks since. Has pain in the lumbar regions and groins.

Examination shows a deep ulceration in the posterior lip of the uterus, with indurated edges. The uterus was freely movable. A specimen removed showed the disease to be carcinoma.

During April five minor applications were made, varying from 90 to 180 milliamperes each, for durations of 30 minutes. On the 20th there was a profuse hemorrhage in connection with the separation of a portion of dead tissue, controlled at once by the strongest application made. On the 28th a normal menstruation interrupted the treatment.

During May four applications were made, of 100, 160 and 200 milliamperes, varying from ten to thirty minutes in duration. On the 16th an oval slough, resembling inner portion of the cervix, was removed from the vagina.

During June and until July 8 the patient received ten half-hour applications varying from 50 to 75 milliamperes. At the latter date the treatment was intermitted as the parts appeared to be healthy, and on July 30 she was discharged to the dispensary, where she received two applications in August and one in September.

January 4, 1908. Patient examined and parts found apparently free from disease. Directed to return twice a month for examination.

April 21, 1908. Patient has received five applications of 35 to 90 milliamperes since last entry, as the posterior lip appeared to be uncertain and the separation of a slough was accompanied

by free bleeding. There appears to be no disease present at this time.

June 24, 1909. Examination shows no sign of disease. Patient is in excellent health.

November, 1909. Patient still under observation and occasional prophylactic treatment.

No. 596. ONCOLOGIC HOSPITAL. *Carcinoma of Cervix Uteri*.—Mrs. E. C., aged 61, was admitted August 9, 1907, with an atrophied uterus and eroded cavity in the os. The conditions had been present but two months according to the patient, and somewhat resembled senile endometritis, though the destruction of tissue at the os was greater than usual in these cases. The patient complained of moderate pain. A specimen removed from the diseased spot was pronounced benign by the pathologist of the hospital some time later.

November 23. The clinical and histologic diagnoses having conflicted, the patient was placed on minor applications of zinc-mercury ions, 75 to 35 milliamperes for 30 minutes each, nine such applications having been made between the date of admission and the present. The patient has gained six pounds in weight. Treatment intermitted and patient kept in hospital under observation.

January 12, 1908. Patient has recovered from an attack of la grippe, and, under examination to-day, is apparently free from disease, the cervix being greatly contracted as a result of lost tissue. On the 25th she was discharged to the dispensary.

February 10. Minor application of 27 milliamperes for 30 minutes to doubtful tissue at edge of cicatrix.

February 24. No sign of disease on examination. Patient seems disappointed at cessation of treatment, but none given in view of the excellence of the local conditions.

March 31. A friend informed the superintendent of the hospital that the patient felt we had bothered enough with her and went to another hospital in the city, where, the scars being misinterpreted, she was subjected to complete hysterectomy, dying the same day.

No. 603. ONCOLOGIC HOSPITAL. *Atrophic Endometritis (?)*.—Mrs. C., aged 58, was admitted from Waco, Texas, August 26, 1907. For one and a half years she had complained of a persistent leucorrhea, with some lumbar pain. The menopause had been passed several years before.

Examination shows uterus decidedly atrophied, movable, with normal os, but exuding bloody mucus. The sound and bi-manual examination revealed atrophy of the corpus particularly. The appendages appear normal.

She was placed under zinc-mercury intra-uterine applications with a bulbous electrode designed to fit the uterine cavity, the applications being of ten minutes' duration and varying in strength from 50 to 90 milliamperes. She received ten applications, and was sent home October 18 with directions for continuance of treatment by her local physician.

July 12, 1908. Letter received stating that the uterine trouble is apparently well.

SUMMARY OF SECOND SERIES OF UTERINE CASES.

Of the 5 cases reported above, excluding the case of atrophic endometritis, 2 were inoperable and were probably little benefited. Of the 3 operable cases 2 were greatly benefited and would possibly have been cured if the treatment had been continued; and one is without manifest evidence of disease, though still under close observation.

CHAPTER XIV.

APPLICATIONS TO THE RECTAL AND ANAL REGIONS.

A number of physical, physiological, and surgical reasons combine to render zinc-mercury ionization peculiarly adapted to the treatment of malignant growths in the anorectal region. These considerations would render the method invaluable even if it were restricted to these parts alone.

The anorectal region is more than usually vascular, hence the bloodless nature of the operation commends it. The ease with which the destructive force may be carried by insulated electrodes to a point high within the rectum enables us to destroy a growth limited to these parts without interference with the lower sphincter. No large vessels, nerves, or serous cavities are encountered in the region that may not be safely destroyed by the process, hence we may employ the method with unusual boldness. And, finally, the great distance of these parts from the vital centers enables us to use all the current needed to do thorough work, the reflex stimulus of such large currents being, in fact, an element of safety in case the patient does badly under the anesthetic.

An important physical reason also is the fact that here, as in all applications within cavities, the force may be made to act from within outwards; in other words, the peripheries of the growth are reached by currents transmitted from electrodes thrust radially through the growth, thus reaching the growing edges without sacrifice of surrounding normal tissue. This results in effectual sterilization of the diseased parts with least loss of tissue, the inner surface of normal tissues left after separation of the slough being healthy throughout, if the application has been thorough, no matter how extensive and irregular may be the cavity thus made.

This cavity is painless, and contracts ultimately to dimensions that closely resemble the normal rectal channel or anal outlet, with soft edges, covered with mucous membrane or skin. When final contraction has occurred normal retention

usually results, except with liquid stools, with, at times, some tendency to stricture.

MAJOR MONOPOLAR APPLICATION.

For this application the patient should be placed in the lithotomy position, with the legs well elevated by leg holders.

If the operating table be the ordinary metal and glass one of the hospital operating room, care must be exercised to pad it well beneath the waterproof, both for the comfort of the patient during a prolonged treatment and to permit a better adaptation of the kaolin pad to the sides of the trunk; and the operator or head nurse should see that the arms or legs do not come into conducting contact with the metal of the table or leg holders, as these become negatively charged frequently by stray currents and are liable to give rise to burns. This is readily obviated by covering the table completely with the waterproof, and especially by wrapping a piece of rubber sheeting or insulating tape about the portion of the leg holders liable to come into contact with the limbs.

Two pads are often best if a heavy current is to be used, so placed that the edge of the upper one is even with the shoulders. Between the pads a strip of rubber sheeting should be laid as the current tends to seek this route by preference. After the patient has been placed in position a deflated Kelly pad should be slipped beneath the buttocks, between the patient and the pad, to deflect the return current to the more distant portions of the surface of the pad, as there is a tendency to short-circuit at this spot, with damage to the skin.

With the patient anesthetized and in position, and the operator seated between the patient's knees, two or more hard rubber retractors are inserted into the rectum in such a way as to bring the diseased area into view and protect the healthy tissues, the retractors being held by nurses after being placed in position. An electrode is now inserted about a centimeter into the diseased tissue and the current turned on gradually by an assistant.

The active electrodes are made of zinc 1-32 inch wide and 5 to 7 inches long, insulated with wax throughout their extent except for two centimeters from the tip. Each electrode is attached to a separate piece of No. 32 wire attached in com-

mon to the positive treatment binding post, with the wire so coiled as to be easily handled when needed. They should be amalgamated immediately before use.

Owing to the small active surface of the single electrode it is often difficult to get more than 200 milliamperes into the circuit at first, polarization occurring rapidly, so a second, or even a third, is inserted in appropriate spots. In spite of the use of several points a current of 400 milliamperes confined to the growth alone will shortly develop considerable heat. When this is shown by a steaming effect, or is detected by the finger, a little cold water should be carried to the spot by the hard-rubber tip of a fountain syringe, but the water should be allowed to escape at once as soon as the part is cool, as it otherwise tends to convey the current in erratic directions, to be turned on again as soon as the temperature again becomes too high.

As each electrode is ascertained by inspection to have accomplished a probable sufficiency of action at its particular point of insertion it is removed (the remaining electrodes being carefully supported in their position) and a fresh one is inserted in a new spot, until all diseased tissue shown to the eye has been turned to a grayish white color and devitalized to a sufficient depth to reach the upward and lateral extensions of the growth. The depth and amount of tissue thus devitalized must be controlled with care on the anterior wall of the rectum, to avoid in male patients undue inclusion of the prostate and in women the recto-vaginal septum, otherwise a free destruction should be made. The completeness of the destruction is determined from time to time by visual inspection or by the sense of touch, the most reliable estimate being by the *tactus eruditus* of the educated finger, as softening of the growth accompanies its complete ionization. From 40 to 60 minutes of actual current flow will usually be required.

If the diseased spot be high, the following procedure permits of the most exact placement of the electrode: Place the point of the electrode against the palmar surface of the tip of the finger and insert both simultaneously to the site of proposed puncture by touch; with the point of the electrode near by, locate the spot accurately by touch and insert the electrode into the growth guided by the inserted finger. Holding the electrode in place with one hand, now withdraw the

inserted finger and pass the speculum up over the conducting wire and electrode into the rectum until the site of the inserted portion is brought into view. This method permits an exact placement of the electrode by touch, and a most exact confinement of the cataphoric destruction to the diseased area; it makes visual examination possible; and permits of ready cooling of the parts by a stream of water. In many cases, nevertheless, the speculum is unnecessary, the finger remaining near the seat of action to note increase of temperature, which is lowered when perceptibly high by a stream of cool water injected into the rectum through a small hard-rubber tube passed up alongside the finger.

After Treatment.—The parts are covered with a simple perineal pad of gauze. The burning sensation likely to be felt by the patient for some hours after emerging from the anesthetic may be lessened by applying pledgets of cotton saturated with witch-hazel, or, if pain is complained of, a dose of morphine should be given. By the second day there will usually be no great discomfort, unless distress from constipation be felt; when this appears a hot solution of sulphate of magnesia may be administered by mouth, as there is no reason to fear any ill result from keeping the bowels open, if the stools be liquid. This should be repeated daily until the slough comes away, which occurs between the twelfth and sixteenth days. After the slough separates it is more convenient and comfortable to the patient to permit the stools to be solid.

No great amount of after discomfort is experienced at any time, the freedom of the large granulating surface from irritation due to fecal movements being most notable.

The usual post-operative inspections should be made at short intervals after operations in this region as the growths are likely to be highly malignant, and suspicious nodules should be destroyed promptly by a minor application.

MAJOR BIPOLAR APPLICATION TO ANAL REGION.

The bipolar method is rarely applicable to growths within the rectum, but is usually the preferable method in growths involving the whole circumference of the anus, whether extending up to and including the lower third of the rectum or not. The position of the patient and the preliminary preparations

are the same as that described above for the monopolar application, including the kaolin pad or pads, for it may be wise to employ the latter method to some extent at the end of the operation. Instead of attaching the wire from the plate beneath the pad, however, the wire attached to the bipolar negative electrode is attached to the negative binding post of the apparatus, the ionizing electrodes being inserted well beyond the periphery. This rectal bipolar negative electrode is best made of a piece of thin zinc bent into the shape of a short cylinder after numerous holes have been punched in it, the cylindrical form permitting its caliber to be filled with gauze saturated with weak sulphuric acid and water to absorb the hydrogen. If there is an opening in the center of the growth, or the anus is still patulous, though fully diseased, this cylinder may be thrust into the opening and be self-retaining during the operation; otherwise it should be held in place against the center of the growth during the application.

MINOR APPLICATIONS TO THE ANORECTAL REGION.—The technic of the minor application to this region needs no extended description, the chief essentials being that the electrode be as light and fine-pointed as consistent with strength, and that all but the active point be carefully insulated with sealing wax. No local anesthetic is usually needed for applications under 30 milliamperes to the upper portion of the rectum, but as the anal region is extremely sensitive, subdermic injections of weak Schleich solution are best at this point.

AN IONIC KRASKE OPERATION.—The details of an operation by which a sarcoma on the inner surface of the sacrum was destroyed by ionic electrodes inserted through the coccygeal tissues, above the sphincter, is given in the history of Case 66, in which a large sarcoma, situated within the pelvis and attached to the sacrum, was destroyed by two heavy current operations without interference with the sphincter.

FIRST SERIES OF ANORECTAL CASES.

Nine cases of anorectal carcinoma or sarcoma were placed under some form of the ionic method prior to 1905, four being recurrent after excision operations. Of these, 2, reported in full below, are free from the disease at the present time, after the expiration of six and five years, respectively; 2 were local

successes, also reported below, but in each case the patient died within the year from pre-operatively implanted metastasis, both being cachectic when first seen; 4 cases were local failures (three being recurrent at the time of operation); and in one case the ultimate result is unknown, though the immediate result was a valuable palliation of the conditions present.*

Recurrent Carcinoma of Rectum.—The mother of a physician of western Pennsylvania, aged 60, was first seen October 26, 1901, suffering from a recurrent carcinoma in the ischio-rectal region. The original growth involved a portion of the sphincter and had been removed by a Pittsburgh surgeon ten months before by a modified Kraske operation. When seen, a sinus was found to the left of the anus with infiltrated and indurated edges, communicating with a cavity about two inches in depth, the whole growth being about the size of a lemon. The rectal mucous membrane was intact and apparently healthy.

At the application, which was monopolar and made under general anesthesia, the cavity was filled with liquid mercury, and into the mercury was inserted a gold tubular electrode, amalgamated, the two together constituting a mercuric electrode that accurately fitted the cavity in the center of the growth. A current increasing from 400 to 650 milliamperes was turned on and maintained for 1 hour and 50 minutes. During the passage of the current the induration "melted" down, the progress of the sterilization being determined by the progressive disappearance of the induration. The application was well borne, destroyed the odor of the discharge, and relieved the pain. After the separation of the débris the cavity very nearly closed by granulation.

Her condition six weeks later was greatly improved; but it was at this time thought best to make another application, as a part of the wound had not healed and was suspicious.

On December 15 she was, therefore, again anesthetized and the process repeated with from 200 to 300 milliamperes. It was only necessary to keep up this application 40 minutes.

The healing was complete after the second application, and in June, 1902, her son reported the disease apparently cured, though the patient was weak from a recent attack of the grip.

* For full report of some of these earlier cases, *vide* "Conserv. Gyn. & Electro-Ther.," 6th edition, page 247.

She remained in reasonably good health for about a year, when death occurred, probably from metastasis.

Annular Carcinoma of Upper Rectum.—Mr. T., aged 44 years, was brought to me from Campello, a suburb of Boston, Mass., August 1, 1902, with the following history: He had been in the possession of excellent health until about nine months before, when abdominal trouble, supposed to be of a dyspeptic nature, brought him under the care of his family physician. Not finding relief, he went to California in the spring of 1902, and on his return, in April, was found to have lost twenty-six pounds in weight. Obstruction of the bowels finally developed. He was examined by Dr. Cabot of Boston in June, and carcinoma of the rectum was clinically diagnosed, the diagnosis being confirmed by the microscope.

On examination, the finger encountered a firm constriction about five inches from the anus, the lumen of which would not admit the distal phalanx. The constriction was cylindric, apparently more than an inch long, and the edges were ulcerated and emitted the characteristic odor of malignant disease. For some time the ribbonlike stools had been replaced by watery discharges only under the action of salines. The patient's color was good, but he was greatly emaciated and suffered from pain in the left groin.

Notwithstanding the unfavorable clinical evidences of metastasis, the patient was admitted to a private hospital, and on August 3 he was etherized and a major monopolar application of zinc-mercury ionization applied as described, with the assistance of Drs. Hermance and Frank White. A current of 500 milliamperes was gradually attained and kept up for 69 minutes, exclusive of the time necessary to change and readjust the electrodes. At the end of this time all portions of the growth appeared soft to the finger, and examination with a lighted proctoscope showed the diseased area changed to a grayish white.

On the sixth day the general comfort of the patient was disturbed by a rise of temperature to 102 F., with the development of localized swelling in front of the pubes and inability to void the urine naturally. Both of these symptoms persisted for several days, during which time an increasing quantity of débris passed from the rectum, a bedpanful of necrosed tissue finally passing in a single stool, followed by normal fecal

passages. The patient went home at the end of three weeks.

On September 22 I examined the patient and found the parts healed, soft, normal mucous membrane covering the site of the growth, but there was apparently a valvular constriction produced by scar tissue on the anterior aspect. The evidences of general metastasis still persisted, showing that the excellent local result had probably been attained too late for an actual cure.

The general ill health continued after the patient returned to his home, resulting in death at the end of about six months, without recurrence of the disease in the rectum.

Sarcoma of the Sacrum.—Mrs. C. A., aged 26, of Royersford, Pa., applied for treatment October 1, 1903, with a hard tumor nearly filling the pelvis, examination by the vagina and rectum showing it firmly attached in its whole extent to the inner wall of the sacrum.

She had had two confinements, which were terminated by instrumental delivery, both children dying in childbirth, and a more recent confinement terminating seventeen months before being seen, in which the child was delivered normally, without instruments, and was still living. The tumor was not discovered until March, 1903, when the baby was 11 months old.

The progress of the growth was noted by her physician for several months, and she was finally sent to a Philadelphia hospital, where an opening was made in the median line of the abdomen. The true nature of the growth was then discovered by the surgeon, and the wound was closed without effort at removal of the growth, which was pronounced inoperable. This was in September, three weeks before coming under the author's observation. After leaving the hospital she was sent by her former medical attendant, Dr. James C. Mewhinney of Royersford, to Dr. W. W. Keen of Philadelphia, who concurred in the diagnosis of sarcoma of the sacrum, and stated that an operation would probably be fatal, and surely result in paralysis.

The patient's general condition was subnormal, she being anemic, thinner than usual, and beginning to suffer from stricture of the rectum. An attempt to destroy the growth was, nevertheless, determined upon.

October 5, 1903, a major monopolar application was made,

with the kind assistance of Dr. J. E. Porter of Pottstown, and in the presence of Dr. Mewhinney. The patient was placed with her right side resting on a large pad, a portion of which extended up the back between the shoulders and in front on the abdomen, as a large current was evidently needed. It was decided to make an opening through the unaffected skin above the anus with the ionic action itself, with a view to saving

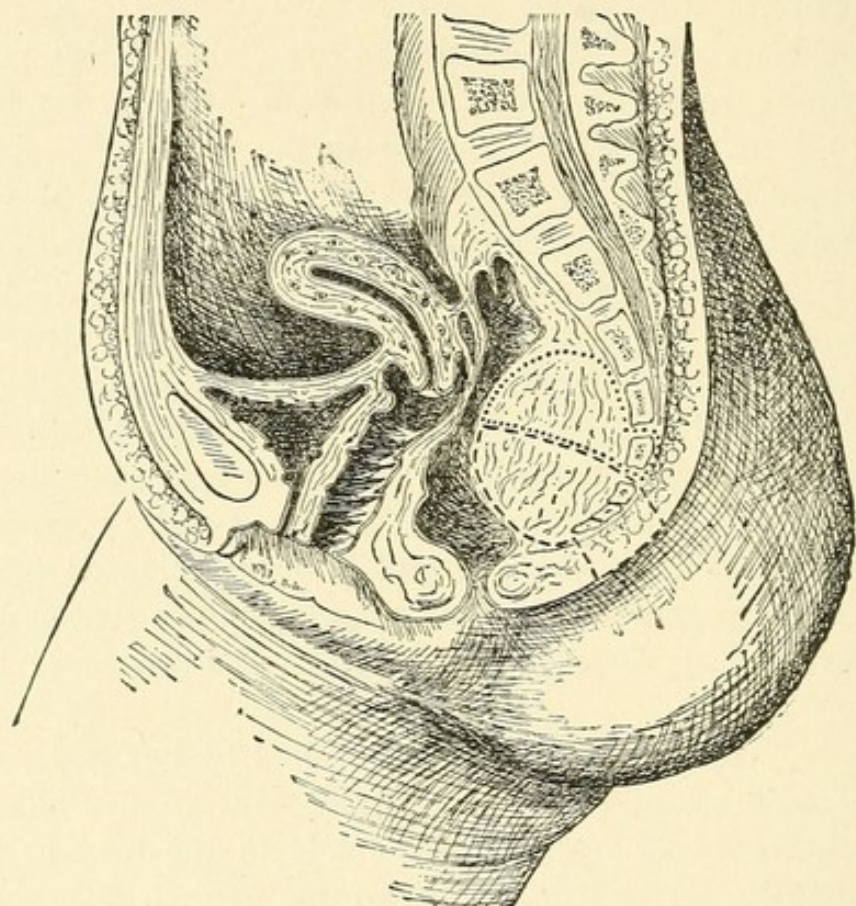


FIG. 69.—Diagram of median section of pelvis showing sarcoma of sacrum. The portion of the tumor destroyed by the first operation is inclosed by a broken line, and includes the last three bones of the coccyx. The remainder of the growth, including the first segment of the coccyx, was destroyed by the second operation, and is indicated by a dotted line.

the anus and sphincter, the formation of a channel through the skin, coccyx, and lower end of the sacrum by the electric action avoiding all opening of vessels. A slit was accordingly made in the skin, and a large, stout, amalgamated zinc electrode with sharp point was thrust into the tumor with a finger in the rectum as guide, grazing the apparently softened coccyx. This instrument was uninsulated, the purpose being to make a wide opening for the subsequent passage of the devitalized

tissue. A strength of 1000 milliamperes was shortly reached, when, the necrosis extending and showing signs of heating, three other more slender electrodes, each about 7 inches long, were inserted alongside the first to a total depth of $4\frac{1}{2}$ inches. The current was then raised to 1600 milliamperes, which was maintained for 3 hours, being lowered somewhat during the last hour.

The application was well borne. At its expiration three burns were found at different points under the negative plate, due to this plate being too stiff to adapt itself properly to the contour of the body. These skin necroses gave the patient more subsequent discomfort than the wound proper, but ultimately were covered with soft cicatrices.*

Aside from the accidental necroses of the skin, the after-condition of the patient was comparatively comfortable, the skin and three segments of the coccyx coming away in sixteen days, and a large portion of the tumor, a piece about the size of a fist, shown on a reduced scale in Fig. 70, coming away on the twentieth day, with a sharp hemorrhage, readily controlled by pressure.

After the separation of the slough, which, by the way, was practically inodorous, having been dressed with carbolized zinc oxide powder, the conditions were as follows: There was an opening about three inches in diameter extending into the rectum, the lower edge being $1\frac{1}{2}$ inches from the intact anus. At the bottom of this opening, which was 2 inches deep, the red tissue of about one-half of the tumor was visible (Fig. 69). That this was a portion of the tumor was clearly shown by vaginal and rectal examination, the finger now being able to be hooked over its upper border.

On November 2 a second major monopolar application was made through the opening, with long electrodes so insulated as to protect the healthy edges of the opening. A current of 1600 milliamperes, later decreased to 800, was employed for $1\frac{3}{4}$ hours, with four electrodes. Careful attention to the dispersing pad prevented accidents in this situation at this time.

The devitalized tumor, about the size of a large fist, came

* Since the date of treatment of this patient the negative pad has been changed from a cotton compress to a kaolin pad, resulting in an entire elimination of burns of this character.

away cleanly without a drop of blood, in seventeen days, leaving, fortunately, no sign of remnants in its former situation. Examination through the wound showed the lower third of the sacrum roughened on its inner wall, and the devitalized

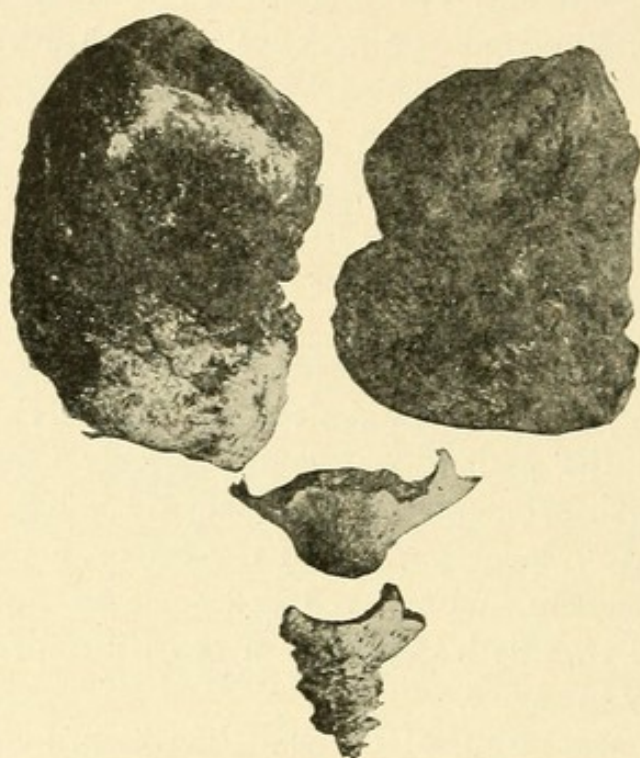


FIG. 70.—The two pieces of sarcoma tissue and the segments of the coccyx, as they appeared after separation (reduced to one-fourth size).

first segment of the coccyx was picked out of the wound painlessly two weeks later (Fig. 70).

During December efforts were made to direct the fecal discharges through the natural anal opening, all discharges having thus far passed through the operative opening owing to the destruction of the posterior rectal wall. Several hard rubber tubes of various sizes and curves were inserted into the rectum through the anus, but all failed of their purpose and were finally abandoned, the fecal discharges continuing to pass through the wound until its gradual narrowing, late in the winter, diverted the feces into the natural channel through the anus.

The patient sat up the second week of December, went downstairs on Christmas Day, and walked out January 10. On January 13 she had the first natural movement through the anus.

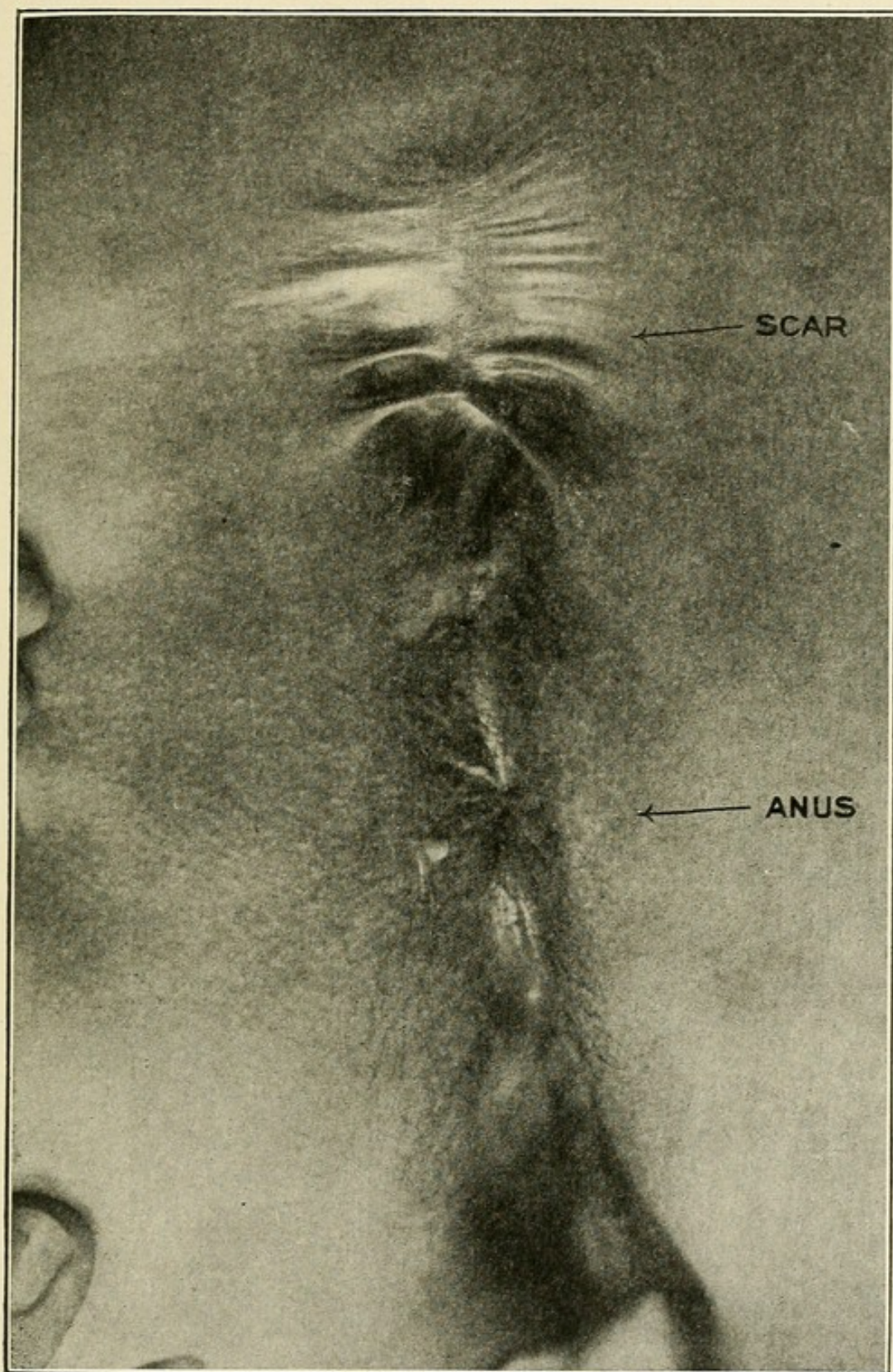


FIG. 71.—Photograph of scar six years after ionic destruction of sarcoma of sacrum.

At the present time, November, 1909, six years after the last application, the patient is in unusually good health, with no evidence of fullness or growth of any kind in the pelvis

or elsewhere. She walks and sits easily, and the opening shown in the photograph (Fig. 71) has long since entirely closed.

At the time of the second application a small portion of the growth was removed and sent to the Philadelphia Clinical Laboratory for histologic examination. The report characterized the growth as a fibromyxosarcoma.

Epithelioma of the Rectum.—Mrs. J. H., aged 57, was referred by Dr. H. R. Swayne, May 4, 1904. In 1902 she was operated on by excision for cancer of the uterus, in its early stages, and an apparent cure effected. For some time she has had a sensation of a foreign body in the rectum, more recently accompanied by pain, and Dr. S. discovered the growth and secured the diagnosis of epithelioma from the private laboratory of Dr. Boardman Reed.

Examination showed a growth on the posterior wall of the rectum about 3 inches above the anus; it had a raised, proliferating surface.

May 4, 1904. Major monopolar operation, with the assistance of Dr. Swayne. Under general anesthesia a spear-shaped electrode was prepared with a proper curve, inserted through the anus into the growth, and 500 milliamperes turned on and maintained for 60 minutes, inclusive of frequent turning off of the current for inspection of the parts, the rectum being kept cool by frequent irrigation of the site of application by cool water carried to the spot by a hard rubber tube. There was considerable secondary hemorrhage on the fourteenth day, on the separation of the slough, readily controlled by an injection of Monsell's Solution in glycerine in the proportion of 2 parts of the solution to 6 of glycerine.

The patient's general condition, which had been poor, gradually improved, while the rectum retained its functions in full, save for a tendency to constipation during the first year, due to the rectal tube being bent sharply on itself at the site of the scar, its posterior wall being attached to the sacrum.

At the present writing, five and a half years after the operation, the patient is in excellent health and without any sign of a recurrence. The contracted spot at the site of the scar seems to be looser, the index finger entering the lumen of the stricture more readily, and there seems to be no difficulty in defecation.

SECOND SERIES OF ANORECTAL CASES.

No. 272. ONCOLOGIC HOSPITAL. *Recurrent Carcinoma of Rectum*.—Mrs. C. A., aged 46, was referred by Dr. T. L. Adams of Philadelphia, December 13, 1906. Five years ago she was operated on by a gynecologist for "tumors on the uterus" (real condition unknown). Six months ago first noticed trouble with the rectum, mainly pain that prevented sleep. Eight weeks ago Dr. Adams found a lump at the edge of the anus the size of a lima bean, and operated on it by the knife and cautery.

Examination shows a proliferating growth about 3 inches in diameter surrounding anus and extending about 2 inches up the rectum, ulcerated and breaking down. The patient complains of pain in the anus, buttocks, and within the abdomen, and has lost flesh of late.

On the 14th a major monopolar application was made under ether, 1000 milliamperes being applied for 80 minutes, with six electrodes thrust just beyond the periphery of the growth to a depth of 2 inches, parallel with the rectal walls. The patient was unable to void urine voluntarily for ten days, but the bowel movements were unimpaired. On the 27th and 30th large sloughs separated, leaving an apparently healthy wound, though six minor applications were made during the following two months to doubtful granulations, the patient being discharged from the hospital February 10.

The patient's general health had remained poor in the hospital, with poor appetite, sleeplessness, and pain within the abdomen. These conditions grew worse after her return home, aggravated by recurrence of the disease in the edge of the wound, and she died of metastatic growths and general inanition several months later.

No. 616. ONCOLOGIC HOSPITAL. *Fibro-Sarcoma, Round-Celled, of Rectum*.—T. H., aged 64, farmer, was referred by Dr. E. L. Moodie of Chatham, Ohio, April 25, 1906. His mother died of cancer of the face. Without previous history of hemorrhoids or other ill health, he noticed bleeding at stool about two years ago and later stools made up of blood alone. About nine months ago he began to have watery discharges from the rectum, with much odor.

Examination shows a large growth within lower rectum,

the lowest point being two inches above anus. Its greatest thickness is posterior, with extension to either side to near neighborhood of prostate. The bowels have refused to move lately in spite of saline cathartics.

April 26, 1906. Major monopolar application under chloroform, 1400 to 1600 ma. for one hour, with insulated electrodes, the anus being retracted by hard rubber retractors.

April 27. Patient had free movements of the bowels during the night following operation. Temperature and pulse normal. Irrigation with weak permanganate solution.

May 13. Small portion of slough came away bloodlessly.

May 19. Digital examination showing the presence of undestroyed disease, minor applications to patient's endurance were begun.

December 23. Patient has remained in hospital under minor applications, thirty in all, of 50 to 300 ma. for half-hour each, with great alleviation of the local condition, but without entirely arresting it. Evidence of metastasis to other structures, with cachexia, are now so marked that further active treatment is abandoned and general treatment alone continued.

January 22. Left hip enlarged and painful; evidently a metastatic deposit.

January 26, 1907. Patient died of inanition.

No. 740. ONCOLOGIC HOSPITAL. *Carcinoma of Rectum.*—Mr. K., aged 63, was referred by Dr. F. H. Morse of Boston, Mass., April 25, 1908. Thirteen months ago the patient began to have bloody discharges from the rectum, mixed with mucus, and eight months ago pain appeared and has grown worse to the present time. During this period constipation has increased until at present only powerful saline cathartics can induce movement. The patient is normally sallow, but of late is much more anemic and probably cachectic.

Examination of the rectum by touch reveals a growth 2 inches from the anus consisting of an annular proliferation surrounding the rectal caliber and of a total dimension equal to a small hen's egg. The inner surface of the growth was eroded, bled easily, and gave rise to a foul discharge. The growth was movable, with apparently no attachment to the pelvic wall. Its caliber would not admit the tip of the finger. Microscopic examination showed it to be a carcinoma. Blood

count: erythrocytes 3,880,000; leucocytes 11,760, hemoglobin 72 per cent.

April 25, 1908. Major monopolar application under general anesthesia, 400 to 600 milliamperes for 35 minutes. The operation was followed by greater freedom of movement of the bowels, but the catheter had to be used to empty the bladder for nine days, after which the urine was readily voided. The separation of the slough was unaccompanied by hemorrhage.

May 13. Examination by touch shows an open tube at site of tumor admitting the finger readily, with soft folds of mucous membrane at edges. Patient now has formed movements showing mucus of obviously higher origin than rectum and indicating an old mucous enteritis. Orphol (Beta-Naphthol-Bismuth) powders prescribed.

June 9. Stools normal and condition greatly improved. The site of disease is occupied by a stricture with normal edges $3\frac{1}{2}$ inches above anus.

July 21. Proctoscopic examination in consultation with Dr. Codman confirms healthy condition of stricture. Dilatation begun by No. 15 dilating urethral catheter.

August 20. Patient referred back to Dr. Morse for further treatment of the stricture. There is no sign of recurrence of the disease.

No. 810. ONCOLOGIC HOSPITAL. *Carcinoma of Rectum, Recurrent.*—Steamboat captain, aged 49, was referred by Dr. W. T. Roberts of Louisville, Ky., September 17, 1908. Personal and family history good, except for an old malarial infection received during a residence in Arkansas years ago. It is possibly due to this that the patient's color is unusually swarthy. Three years ago he had a sudden, painless hemorrhage from the rectum, and one year later a constant inclination to stool was noticed. December 6, 1906, he entered a hospital in Louisville and was operated on by excision, the anus and about 4 inches of the rectum being removed. There was an improvement in the general health, but two small nodules of recurrence were noticed at the edge of the anus as soon as healing occurred. His condition became very bad five months ago. During the last twenty days there has been no movement of the bowels.

Examination showed a mass protruding from the rectal

opening 3 by 2 cm., being an outward extension of an indurated, nodular mass that encircles the anus and extends about 4 inches up the rectum. The index finger could be inserted but 3 inches, encountering indurated walls, which were narrowest at the upper portion of the growth. Anteriorly the growth appeared to be adherent to the prostate. Blood count: erythrocytes 4,200,000; leucocytes 10,200; hem. 70 per cent. Microscopic examination: carcinoma.

September 9, 1908. With a prognosis that included recognition of the probability of metastasis, and of the probability of failing to eradicate the disease next to the prostate (the patient stipulating that the bladder was not to be opened by the ionic process), a major bipolar application was made on this date, 800 to 2000 milliamperes being used for 40 minutes, according to the technic described on page 211, with a cylindric negative thrust into the cavity and 6 electrodes inserted at one time just beyond the periphery of the growth to a depth of 4 inches, avoiding the region of the prostate. Within two hours after being put to bed the bowels moved freely, and during the night there were seven large movements without discomfort. Difficulty in voiding urine was complained of for ten days, and a large slough was passed with the feces on the twelfth day.

January 6, 1909. There are symptoms of failure to eradicate the disease on the left side of the anal opening, and the prostatic region still continues doubtful. Second major operation under anesthesia, the application this time being monopolar as there is but little doubtful tissue to be destroyed, 400 to 500 milliamperes for 40 minutes, 6 electrodes.

February 27. Patient allowed to go home, as all portions of the periphery of the rectum present a normal, healthy scar, soft and pink, except the uncertain prostatic region, several colleagues feeling confident that there is no disease. Directed to return in ninety days.

April 25. Patient returns to hospital at suggestion of Dr. Roberts, having had no fecal movement for four days. Examination shows an indurated, shell-shaped excavation on the prostatic side of the anal opening, probably containing malignant structure; at the depth of 2 inches this ends in a constriction through which the tip of the forefinger may be inserted, but which is filled with prolapsed bowel, like a ball

valve. A soft rubber tube was inserted through the constriction through which fecal movements were secured for a time. Minor applications were made to the malignant growth in the prostate ineffectually, and were finally abandoned, the patient dying from extension of the disease June 19.

No. 999. ONCOLOGIC HOSPITAL. *Recurrent Adenocarcinoma of Rectum.*—Mrs. Y., aged 69, was referred by Dr. Mary Dunning of Newburgh, N. Y., September 3, 1909. She had what was supposed to be hemorrhoids for four years. March 22 last a growth diagnosed microscopically as adenocarcinoma was removed by excision, including the greater portion of the lower rectal wall. One week ago Dr. Dunning discovered a recurrence.

Examination discloses six nodules about the size of marbles in the line of the incision 3 inches above the anus, with a continuous indurated mass at the anal edge. The growths are ulcerated and proliferant.

September 6, 1909. Major monopolar application under ether, 400 to 900 milliamperes for 37 minutes, 8 needles being inserted.

October 12. Examination to-day shows no evidence of disease in rectal wall or anal edges, both of which appear soft and covered with normal tissue. The anus appears particularly normal in its new covering of scar tissue, the sphincter being apparently perfect. One and a half inches above the anus there is an opening between the bowel and vagina admitting the thumb, through which most of the feces pass.

November 1. No evidence of recurrence shown to-day. The anus appears normal, but feces still pass through the rectovaginal fistula, which has contracted somewhat.

SUMMARY OF NEW SERIES OF RECTAL CASES.

Of the five cases treated since 1905, 2 cases are without manifest evidence of disease at present, and 3 were failures.

CHAPTER XV.

MISCELLANEOUS CASES OF MALIGNANT DISEASE IN WHICH ZINC-MERCURY IONIZATION WAS USED.

Lymphoma of Neck.—Mrs. F. J. F., aged 26, applied for treatment May 15, 1903. A tumor in the right side of the neck was first noticed three years ago. It grew rapidly while she was pregnant with her first child, now five months old.

The tumor is situated in the neck below the left jaw. It is ovoid in shape, measuring $3\frac{1}{4}$ by 2 inches (8 by 5 cm.)



FIG. 72.—Lymphoma of neck.

deeply situated beneath the skin, and painless. (See photograph, Fig. 72.)

Believing the growth to be probably tubercular, minor applications of 10 to 15 milliamperes were made through a sinus produced by the first application. This was persisted in for several months, without materially reducing the size and dimensions of the shell of the growth, in spite of the center being favorably changed.

March 9, 1904. Patient returns with tumor slightly larger than when first seen, causing the formation of a clinical diagnosis of malignancy. A major monopolar application was

made at this date at the patient's residence, assisted by Dr. Hermance, 350 to 400 milliamperes being employed, with 6 needles, for 40 minutes.

After the separation of the slough minor applications of 40, 25 and 15 milliamperes were made during the following month.

At the present time, five and a half years later, the patient is



FIG. 73.—Photograph of patient shown in Fig. 72 four years after ionic operation.

well and shows no sign of recurrence. The second photograph (Fig. 73) was taken August 14, 1908.

Sarcoma of Neck. (No. 320, Oncologic Hospital).—Wm. R., aged 47, was admitted to Dr. McClary's service March 6, 1906. The patient came to the hospital from the Home for Incurables, where he had been admitted as an incurable patient. The greater portion of the left side of the neck was the site of a proliferating, ulcerated, foul-smelling growth (Fig. 74) that apparently extended deeply into the tissues of the neck. Microscopic examination: sarcoma.

Dr. McClary made fourteen injections of Trypsin, in ac-

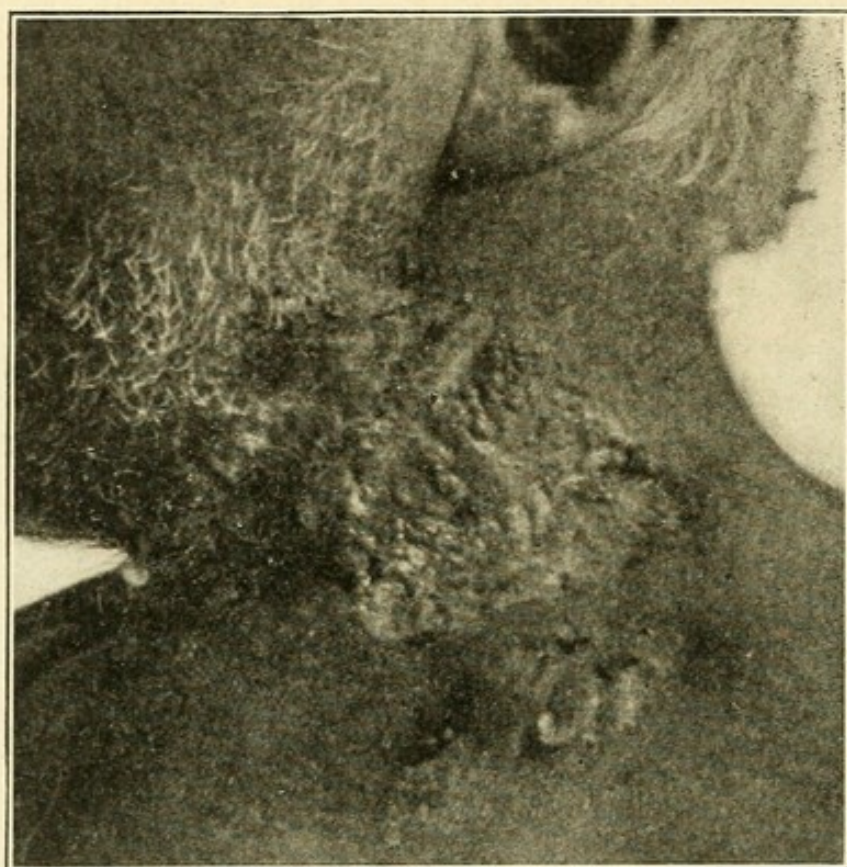


FIG. 74.—Sarcoma of neck. Case 320.

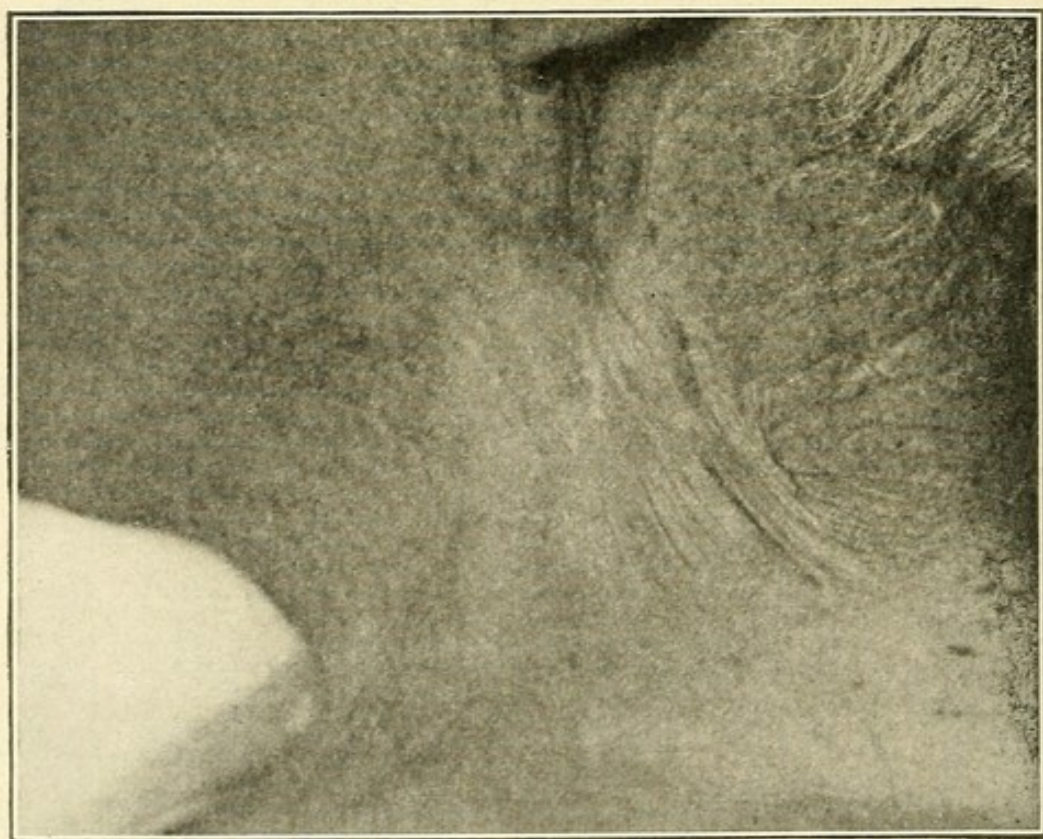


FIG. 75.—Appearance of scar of case shown in Fig. 74 three and a half years after ionic destruction of sarcoma.

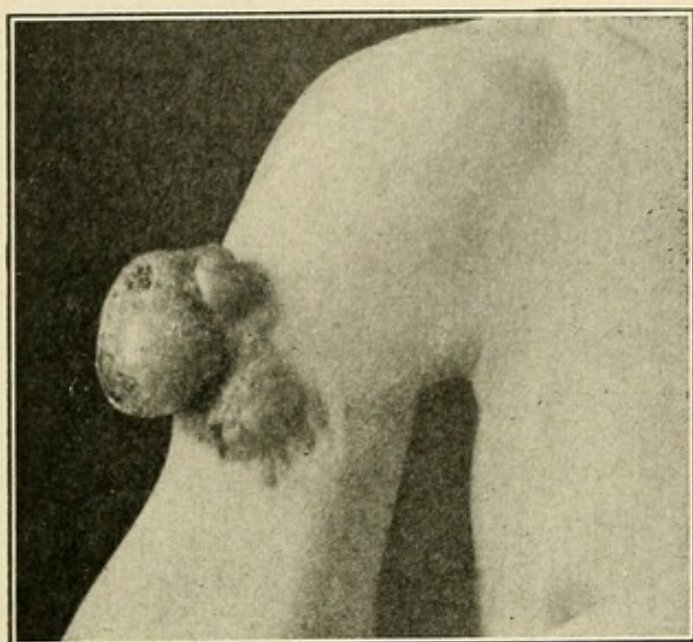


FIG. 76.—Sarcoma of arm. Case 474.

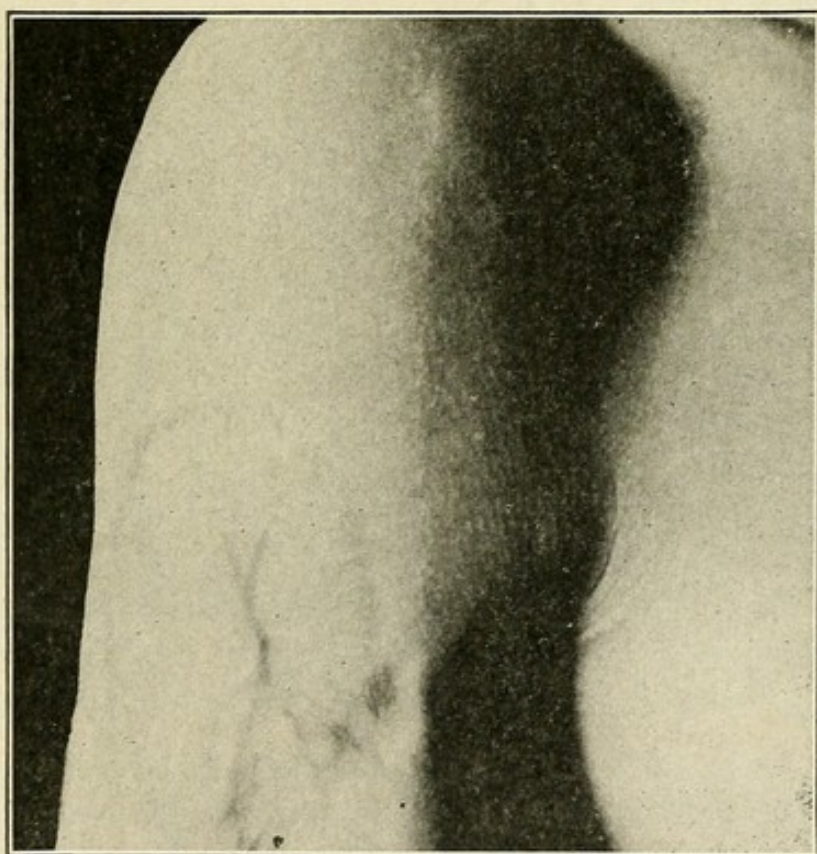


FIG. 77.—Scar of sarcoma of arm shown in Fig. 76
as it appears three years after treatment.

cordance with the Beard method, and, as the growth was not affected in any way, referred the case to the author for an ionic application.

March 30, 1906. Major monopolar application, 500 milliamperes for one hour. The slough separated without hemorrhage, and the patient was discharged from the hospital April 20.

The result was excellent in every way, the scar shown in Fig. 75 representing the condition present at his last visit to the hospital, November, 1909.

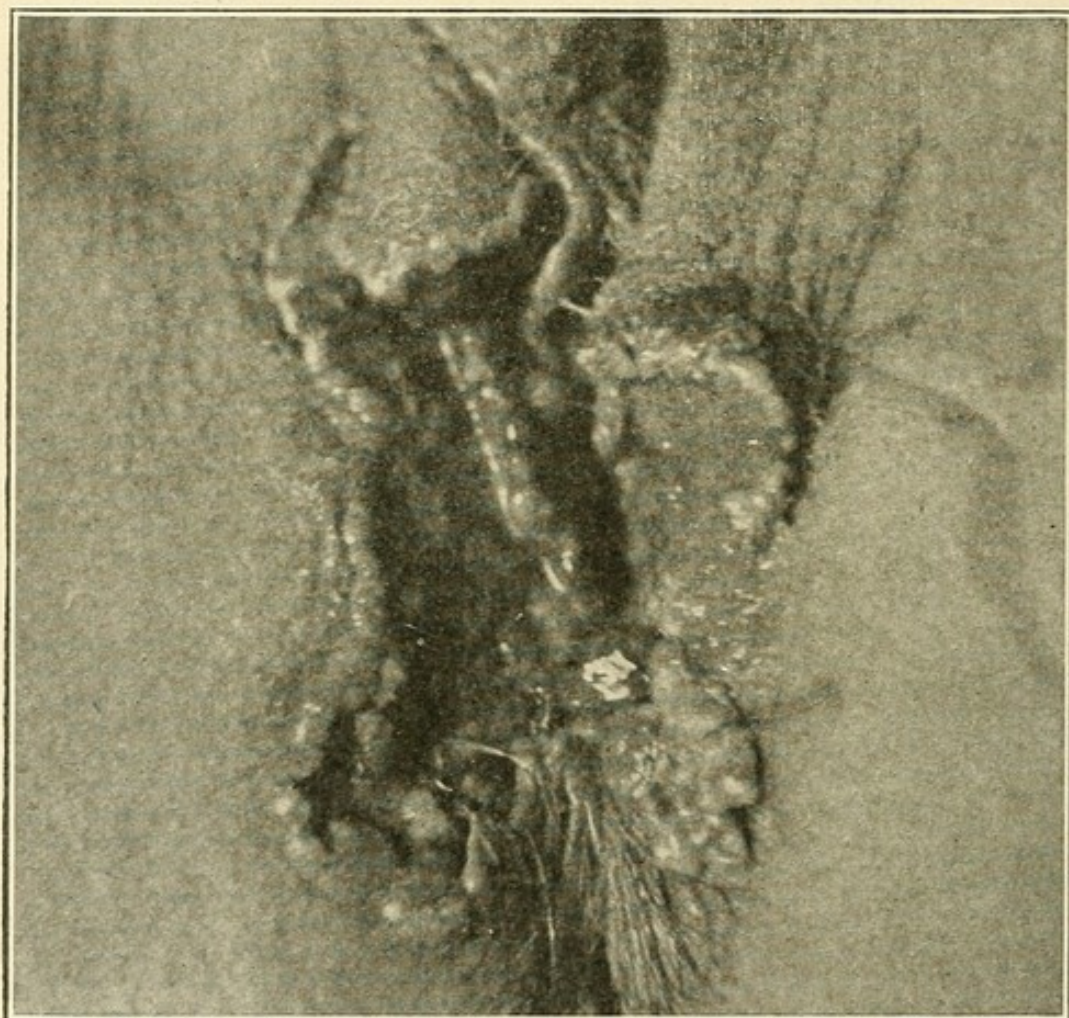


FIG. 78.—Carcinoma of vulva. Case 772.

Sarcoma of Arm. (No. 474, Oncologic Hospital).—J. S., aged 41, was referred by Dr. J. Solis Cohen December 6, 1906. When seven months old he had an abscess resulting from vaccination at the insertion of the right deltoid. Four or five months ago the present tumor appeared in or near the scar. It is painless and has doubled in size during the last two months.

The tumor (Fig. 76) is the size of an apple, and is attached

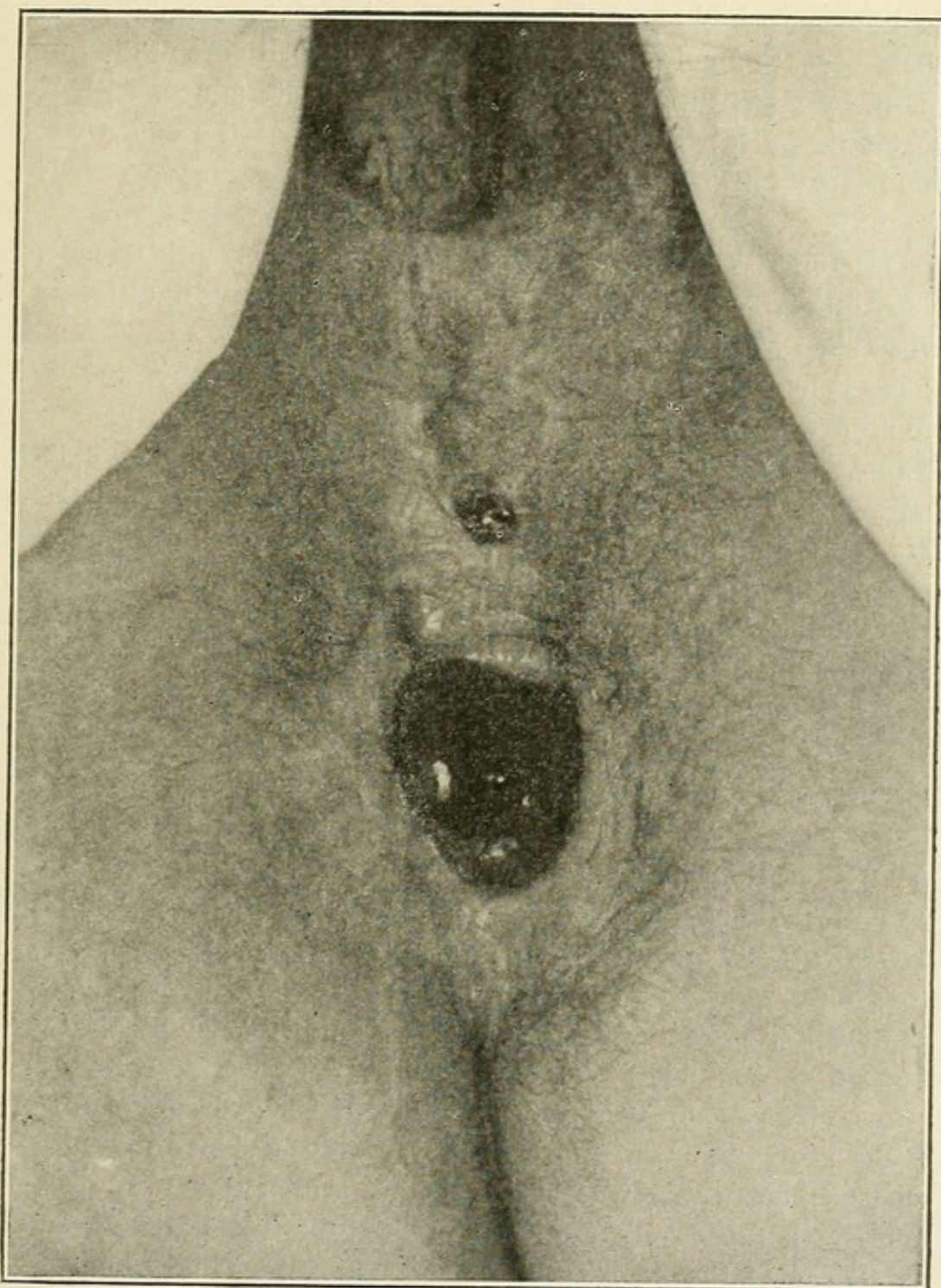


FIG. 79.—Scar of case of carcinoma of vulva shown in Fig. 78, one and a half years after ionic operation. The large opening is the rectum and the small spot above the meatus.

by a broad pedicle to the outer aspect of the arm. It is firm in texture. Microscopic examination: spindle-cell sarcoma.

December 6, 1906. Major bipolar application under ether, 600 to 800 milliamperes for one hour.

During the healing of the large wound attempts were made

to improve on the regular treatment heretofore employed in these cases: namely, the copious use of diluted zinc-oxide ointment, by substituting the use of simple sterile gauze, with the result that cicatrization and epidermization of the edges were retarded. On returning to the ointment healing proceeded steadily.

December, 1907. Patient reports at hospital with excellent scar, quite free from the disease. The photograph (Fig. 77) was taken at this time.

December 20, 1908. Patient reports with healthy scar and no recurrence.

Carcinoma of Vulva. (No. 772, Oncologic Hospital).—Miss E. Z., aged 49, was referred by Dr. Marie Formad of Philadelphia, June 16, 1908. Four years ago a lump the size of a pea appeared on the vulva. It increased in area and ulcerated, and two years ago Dr. Formad sent her to a hospital where a microscopic examination was made and the case pronounced inoperable. During the past two years the increase in size of the growth has been rapid.

The condition on admission is shown in the photograph (Fig. 78), kindly taken by Dr. Longenecker, the disease extending from the clitoris to a point below the rectum, involving the whole vulvar surface and extending some distance into the urethra, vagina, and rectum. No enlarged glands were discoverable.

June 24, 1908. Major monopolar application under ether, 1000 to 1200 milliamperes being used for one hour, with 16 active electrodes inserted in the edges of the growth. On separation of the large mass of devitalized tissue an immense cloaca-like opening was revealed, into which the three outlets coalesced, the cavity extending so far on the patient's right as to reveal the edge of the pubic ramus. The wound was painless and filled in rapidly. By August 18 the patient had regained partial control of both rectum and bladder.

October 14, 1908. Patient complains of sharp pain when sneezing or laughing, due apparently to a cystocele, there being no support for the part. On the 23d Dr. Longenecker kindly operated for the relief of the cystocele, the operation being successful in removing the protrusion and the symptoms.

April 18, 1909. The parts show no sign of disease, but an area surrounding the urethral opening has so far failed to

cicatrize. Patient was referred to Dr. Hewson for a plastic operation, which was done by dissecting a square flap of tissue from the left side of the scar and side of the thigh and transferring it to the freshened surface, an opening being made in the flap to correspond with the urethral orifice. A soft catheter was fastened in the partly artificial urethra thus constructed. The catheter was removed on the 24th, leaving some vesical irritation. The operation was quite successful, and the patient was discharged from the hospital without manifest evidence of disease July 31, 1909.

November 17, 1909. Patient in excellent health and showing no sign of recurrence. Bowels and bladder under good control. The present condition of the parts is shown in the photograph (Fig. 79), taken this day.

CHAPTER XVI.

SURGICAL IONIZATION IN ACCESSIBLE TUBERCULAR DEPOSITS AND IN HEMORRHOIDS.

Surgical ionization has unquestionably a wider field than that indicated in the preceding pages, though these extensions of its usefulness may be of but slight importance in comparison with its value in the more serious malignant conditions. The prime basis of its value in non-malignant conditions is similar to that in malignant processes: the ionic sterilization of accessible deposits of germ life within the body, though it is also of value in other minor surgical procedures, such as the sterile occlusion of hemorrhoidal cavities, nevi, etc.

Zinc-Mercury Ions in Tubercular Adenitis.—The author regrets that a preoccupation in other directions has prevented a fuller presentation of this subject as a contribution to the recent war against tuberculosis, in which it deserves a distinct place. His claim of priority in the matter is based on the treatment of his first case in February and March, 1899, which was reported, with others, in a paper on the subject read before the Philadelphia County Medical Society February 13, 1901 (*Proceedings Philadelphia County Medical Society*, Vol. xxii, page 43). Allusion to the subject was also made in a paper read before the Alabama Medical Association at Birmingham, Ala., April 17, 1902 (*Journal of Advanced Therapeutics*, June, 1902); and a full description of the technic was incorporated in a paper read before the International Electrical Congress at St. Louis, September, 1904 (*Transactions of the International Electrical Congress*, St. Louis, 1904, Vol. iii., page 915). The method is unquestionably applicable to several varieties of surgical tuberculosis, in which the deposits are on or near the surface of the body or within accessible cavities, but has so far been applied by the author only to tubercular glands of the neck.

The technic is based on that of the minor application of zinc-mercury ions in cancer (page 82), with important modifications

due to the difference in the nature of the germ or cell. In tuberculosis we have a bacillus, a vegetable organism, and one of slight vitality, to deal with. The absence of true malignancy in this germ, and the possibility of an aroused physiologic resistance (increased phagocytosis) of the tissues resulting in material aid to the treatment, are important considerations. In sterilizing tubercular deposits by this method, therefore, it is not necessary that every bacillus be destroyed but only the central portion of the deposit, for the radiation of the ions from the center of the tuberculoma will have the secondary action of raising the opsonic condition of the surrounding tissues and of the body generally to a point where the trophic forces of the nervous system will co-operate in producing a cure. As a consequence, the applications need not be as strong, as long in duration, nor repeated as frequently as in the treatment of the mildest forms of epithelioma by the minor method.

These statements are based on clinical observations only, and it is to be hoped that they will be put to laboratory test in connection with institutions devoted to the treatment of the tubercular affections of children, particularly those referring to the probable raising of the opsonic index of individuals subjected to the treatment.

The method may be carried out readily in the office by anyone having a simple constant current apparatus. The patient lies on a couch with the negative dispersing pad (backed with its conducting plate) beneath the back, or may sit in a chair with both hands pressed on the pad, in the latter case a kaolin pad being preferable as making better contact. The active electrode is a needle cut from thin zinc plate, about $\frac{1}{8}$ inch (one-half mm.) thick, 2 inches (5 cm.) long, and tapering in width from three-thirty-seconds of an inch (2 mm.) at the base to a fine point. This is attached to a sufficient length of No. 32 cotton-covered copper wire by winding a bared end of the wire about the base of the needle and clamping the end of the needle on the wire.

Whether the electrode so made should be employed bare, after amalgamation with mercury, or should first be insulated with fused sealing wax except at the tip, depends on whether we wish to make or maintain an open sinus into the diseased gland, or wish to protect the edge of a sinus already existing from the somewhat painful action of the current and con-

concentrate it upon the disease focus alone. Both procedures will be likely to be needed in different stages of the same case. The method of insulation with fused sealing wax is described on page 64.

Having curved the electrode and insulated it if necessary, the tip is dipped in weak sulphuric acid and water, into liquid mercury, and then into clean water; a piece of adhesive plaster is attached to the wire near the electrode and to the skin near the site of application, so that the needle will be supported in position (without the wire touching the skin), and the needle is gently inserted into the sinus. The insertion of the electrode needle will give no pain at first, these open sinuses being usually free from tenderness, but it is significant of the effect of the procedure that normal sensitiveness is soon acquired by the skin edges under these applications, and we must then drop a little four per cent. cocaine solution on the part some ten minutes before inserting the needle, and a small drop of cocaine solution may be dropped beside the needle during the application, the cocaine base being diffused with the basal ions of the metals.

Should the tuberculoma be covered with unbroken skin, an opening through the latter is made with the point of a Hagedorn needle, or small bistoury, under chlorid of ethyl spray.

The application varies in strength from 1 or 2 milliamperes to 5 or 10, according to the sensitiveness of the part, and should last 15 minutes. It should be repeated two or three times a week, except after the first application through healthy skin, when the second should not be made until the small skin slough has separated. The opening is dressed with simple sterile gauze between treatments.

An important feature of the work, of course, is the complete asepsis maintained between applications by the ions that have been deposited within the nodule. Two applications per week will insure asepsis until the gland appears so healthy that mere probing of the wound at proper intervals will insure its healing from the bottom.

If there be a number of enlarged glands the largest should be attacked in turn, preferably selecting those in the distal portion of the lymphatic circulatory system, for it is possible that the ions that are absorbed may act remedially on other glands further along in the chain. After the largest members

of such a group are thus treated the smaller ones may disappear spontaneously, under the influence of improved trophic conditions. The pain produced by this method in the later stage of the treatment is the only objection in very young children, but this is overbalanced by the great advantage of the very small scar that results.

The advantage of this method over excision in certain cases is threefold: It does not require general anesthesia; it produces a less conspicuous scar; and it is a method of treating the tuberculous condition in the individual as a whole, and results in this way in a restoration of the general health. Its chief rival is possibly the x-ray treatment, which may be preferable at times.

The author has treated some nine cases by this method, with complete success in all, after a number of applications varying from 6 to 23. In all the general health of the patients rapidly improved, with a marked increase in the blood count and weight. In one patient, a child of 5 years, the presence of a mass of cheesy material in a neglected abscess cavity made it necessary to administer chloroform for the purpose of removing the cheesy matter with a dull curette, but the débris will usually pass away by drainage.

Zinc Ions in the Treatment of Hemorrhoids.—The author has of late developed an improved technic in the treatment of hemorrhoids by zinc ions, diffused from a zinc needle with its bare point inserted within the hemorrhoid. Since the hemorrhoidal condition, at least in this phase, is purely mechanical, and the object of the treatment is the production of an occlusive local action and not destruction of germ activity, there is no longer need to conjoin mercury ions with the zinc ions, and we may employ the zinc needles uncoated with mercury. This is a distinct mechanical advantage, as the uncoated needle is much less brittle than when coated with mercury, and is thus more readily inserted in a non-ulcerated hemorrhoid. Should the hemorrhoid be ulcerated, nevertheless, there is a possible advantage in conjoining the mercury ions with the zinc, and the tissue is also more readily penetrated.

The technic of this zinc ion treatment of hemorrhoids differs from that described above for tubercular glands only in the fact that it is applied within the cavity of the rectum,

usually requiring a special speculum, and demands a much less number of applications. When the hemorrhoid is external, and partly covered with the sensitive skin of the anal outlet, the same method of chlorid of ethyl freezing may be employed as for the initial insertion of the electrode.

Details of Application.—With the patient in the dorsal or in Sims' position, a pledget of absorbent cotton is saturated with 4 per cent. solution of cocaine and inserted into the rectum in contact with the spot to be punctured, to remain in place during the ten minutes required to prepare and insulate the electrode.

The electrode is made of the thinnest or medium zinc plate, as described on page 64, and is insulated as there described to a quarter of an inch (one-half cm.) of the very sharp point, the insulation being so put on as to permit a portion of the insulated coating to pass beneath the surface of the mucous

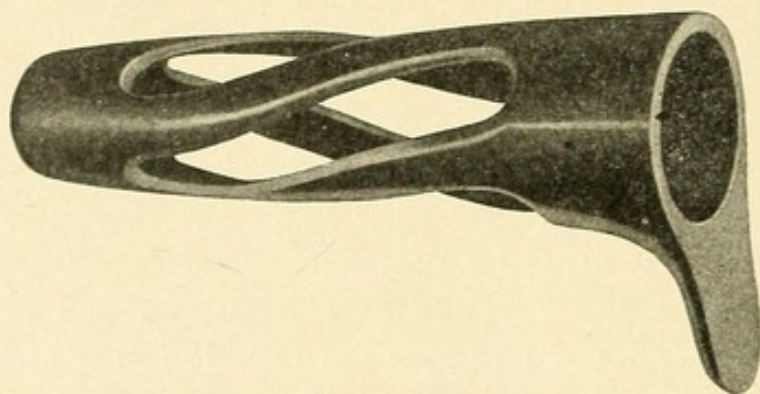


FIG. 80.—Hard-rubber Rectal Speculum, with spiral fenestrations. (One-half size.)

membrane, confining the ionic process very largely to the hemorrhoid itself. The chief recent improvement in the method is the greater rigidity of the simple zinc needle, uncoated with mercury; and having the needle no longer than necessary, in order that it may be self-supporting after insertion (and therefore less painful because of lessened mobility during the flow of current). This immobilization is secured by the expedient described in the paragraph on tubercular glands, of supporting both the needle and its light-weight wire with a guy of adhesive plaster attached near the anus.

Having insulated the electrode and attached the supporting guy of plaster, the pledget of absorbent cotton is withdrawn from the rectum and the hemorrhoid exposed by inserting a conical, fenestrated hard rubber speculum (Fig. 80), by a

spiral motion, the fluted openings in the speculum permitting the hemorrhoid to drop into view in the caliber of the speculum, which is held in place while the needle is inserted and during the passage of the current.

From 5 to 10 milliamperes will usually be sufficient current, and the duration of the application may vary from 10 to 15 minutes. From one to three applications may be necessary for each hemorrhoid.

No special after treatment is required, the discomfort being often very slight, though an antiseptic ointment may be applied daily before and after defecation.

Should the hemorrhoids be extensive, and particularly if they should be so ulcerated as to raise a suspicion of malignancy, a general anesthetic should be administered for a major application of the technic described, with several needles and a current of from 100 to 200 milliamperes for a sufficient time to bring all suspicious tissue under the ionization, 15 minutes being generally sufficient. The after discomfort of such a major application is not great, the patient being about in a few days.

THE END.

INDEX.

- Absence of pain in cancer, 22
- Acid solution for amalgamation, 72
- Active electrodes, 64
- Adenitis electrodes, 64
 - ionization in, 234
- Adhesive plaster guy, 85
- Advantages of ionization, 92
- After care of patients, 81
 - observation, 88
- Alternating current, 47
- Amalgamation of electrodes, 71
- Ammeter, 51
- Anaphoresis, 40
- Anaphoric zone, 78
- Anesthesia, local, 86
- Angio-sarcoma, 29
- Anions, 41
- Anus, applications to, 211
- Apparatus, 46
- Applications to anal region, 211
 - axilla, 181
 - breast, 180
 - cervix, 199
 - face, 98
 - lips, 174
 - mouth, 138
 - nose, 142
 - rectum, 208
- Area of sterilization, 33
- Arm, sarcoma of, 230
- Arrangement of portable apparatus, 71
- Arrhenius, 40
- Arsenic ions, 37
- Author's method, 32
- Autocytic theory of cancer, 4
- Axilla, applications to, 181

- Battery, portable, 49
- Bipolar negative electrode, 80
 - operation, 77
- Breast, applications to, 180
- Breast electrodes, 68
- Byrne method, 199

- Cachexia, 19
- Calcareous degeneration, 27
- Cancer a local disease, 17
- Cancer cells, 1
 - electrodes, 66
- Cancer :
 - emboli, 19
 - houses, 11
 - of vulva, 232
- Cataphoresis, 40
- Cataphoric speed of ions, 43
 - zone, 76
- Cations, 41
- Cauliflower growths, 26
- Cells as current supply, 48
- Cervical electrodes, 69
 - applications, palliative, 201
- Cervix, applications to, 199
- Choice of major or minor method, 96
 - of method, 89
- Classification of cases, 96
 - malignant growths, 2
- Cleaves, Dr. Margaret, 35
- Clinical evidences of malignancy, 1
 - parasiticism, 7
- Clinical examination, 24
- Colonization of malignant growths, 3
- Colloid cancer, 27
- Concentration of ionic action, 44
- Conclusions as to choice of methods, 95
- Connective tissue cancer, 2
- Contraindications in breast cancer, 185
- Control of current, 50
- Controller, graphite, 52
- Controllers, wire (footnote), 51
- Copper ions, 37
- Curability of cancer, 30
- Cure, limitations of, 38
- Current control, 50
- Cylindrical cell cancer, 26
- Cystic degeneration, 27

- D'Arcy Power on cancer fields, 11
- Daughter tumors, 3
- Degeneration of cancer, 27
- Differential diagnosis, 21
- Dimpling of skin, 23
- Direct current, 46
- Disadvantages of ionization, 93
- Dispersing pad, 61
- Dissociation of water, 40
- Dry cells, 48

- Early diagnosis, 21
 Electrodes, active, 64
 adenitis, 64
 breast, 68
 gold, 64
 minor, 64
 mouth and throat, 69
 multiple point, 68
 negative, 60, 76, 78
 rectal, 69
 spade-shaped, 69
 uterine, 69
 Electrolysis, 40
 Electrolyte, 41
 Embryonal layer and malignancy, 3
 Endemics of cancer in mice, 12
 Epiblastic tumors, 2
 Epithelial cancer, 2
 pearls, 26
 Erosion, in cancer, 8
 Evidences of malignancy, 21
 External electrodes, 68

 Fadgean on effect of irritation, 11
 Fatty degeneration, 27
 Fenestrated rectal speculum, 238
 Fibrosarcoma, 29
 Filter action of lymph glands, 19

 Gaylord and Clowes investigations, 10
 General dissemination, 19
 prognosis under ionization, 37
 Gnelliot on transmission of cancer, 11
 Gold electrodes, 64
 Granulations, appearances of, 88
 Graphite controller, 52
 Guy for electrodes, 85

 Haviland, Alfred, 10
 Hemorrhage, secondary, 82
 Hemorrhoids, zinc ions in, 237
 Heredity in cancer, xv
 Holtzer-Cabot transformer, 47
 Hypoblastic tumors, 2

 Immutability of cancer, 9
 Indifferent pole, 60
 Inheritance of cancer, xv
 Insulation of electrodes, 70
 Interpolar action, 42
 Ionic Kraske operation, 212
 Ionization in tuberculosis, 234
 table, 57
 of Victor Electric Co., 139
 Ions, 40
 Iron ions, 37
 Irritation, relation of cancer to, 11

 Kaolin pads, 61

 Life history of a cancer, 17
 Limit of current in operations, 77, 80
 Lips, application to, 174
 Local anesthesia, 86
 dissemination, 17
 Lymphatics in dissemination of cancer, 18
 Lymphosarcoma, 2

 Major bipolar operation, 77
 monopolar operation, 74
 Mammary carcinoma, 180
 Massey type meter, 55
 graphite controller, 52
 Maximum currents, 77, 80
 Measurement of current, 56
 Medullary carcinoma, 26
 Melano-sarcoma, 2, 29
 Metastasis, or colonization, 3, 9, 19
 Mercury ion diffusion, 44
 ions, 37
 Mesoblastic tumors, 2
 Metallic plate for pads, 62
 Mice cancer endemics, 13
 Microscopic evidences of cancer, 1
 specimens, 75
 Miniature lamp, 200
 Minor application, 84
 electrodes, 64
 Miscellaneous cases, 226
 Morton, Wm. J., 35
 Mode of infection, 10
 Monopolar operation, 74
 Monsell's Solution, 83
 Mouth electrodes, 69
 Motor-transformer, 47
 Multiple point electrodes, 68
 Myeloid sarcoma, 2
 Myxoma, 2
 Myxomatous degeneration, 27

 Nature of cancerous process, 4
 Neck, lymphoma of, 226
 sarcoma of, 227
 Negative electrode, bipolar, 78

 Operation, bipolar, 77
 monopolar, 74
 Oxygen content of body, 42

 Pad, indifferent, 61
 Parasitic theory of cancer, 6
 Parenchymatous degeneration, 27
 Pearls, epithelial, 27
 Phagocytic cells, 8
 resistance, 18

- Phototherapy, 89
Physics of ionic action, 40
Physiological resistance, 18
Plastic operations, 84
Plimmer protozoan, 6
Pocket ammeter, 49
Polarity test, 46
Polar reactions, 41
Pope-Massey Wall Plate (Betz), 63
Portable battery, 49
Post-operative treatment, 87
Prevention of cancer, xv
Primary cells, 48
Prognosis under ionization, 37

Radiotherapy, post-operative, 89
Reactions at negative pole, 42
 at positive pole, 41
Rectal electrodes, 69
 speculum, 238
Rectum, applications to, 208
Regional dissemination, 18
Retraction of nipple in cancer, 23
Rheostat, for field winding of dynamo, 48
Rodent cancer, 2

Sanfelice's investigations, 6
Sarcoma, microscopic characters, 27
Scirrhous carcinoma, 23
Sealing wax insulation, 70
Secondary hemorrhage, 82
Series lamp, 52
Shunt lamp, 52

Silver ions, 37
Slough, separation of, 81
Snow, Herbert, 4
Source of current, 46
Spade-shaped electrode, 69
Speculum, rectal, 238
Speed of ions, 43
Sterilizer for pads, 62
Storage cells, 50
Street mains, 40
Squamous epithelioma, 26
Sulphuric acid solution, 72

Transformation of currents, 47
Tuberculosis electrodes, 64
 deposits, ionization in, 238

Universal controller, 52
Uterine electrodes, 69
Uterus, applications to, 199

Van't Hoff, 40
Virulence of malignant growths, 3
Volt controller, 54
Vulva, carcinoma of, 232

Wax, sealing, in insulation, 70
Weston meter, 55
Wire controllers (footnote), 51

Zinc ions, 41
 in hemorrhoids, 237
 in adenitis, 234
Zinc-mercury electrodes, 64
Zinc oxide ointment, 83
Zone of reaction, 33
 in minor applications, 87

COLUMBIA UNIVERSITY LIBRARIES (hsl, stx)

RD 33.5 M37 1910 C.1

Ionic surgery in the treatment of cancer



2002224720

