

**Oral surgery; a text-book on general surgery and medicine as applied to dentistry.**

**Contributors**

McCurdy, Stewart L. 1859-1931.  
Augustus Long Health Sciences Library

**Publication/Creation**

New York : Appleton, 1912.

**Persistent URL**

<https://wellcomecollection.org/works/yrqbyem>

**License and attribution**

This material has been provided by This material has been provided by the Augustus C. Long Health Sciences Library at Columbia University and Columbia University Libraries/Information Services, through the Medical Heritage Library. The original may be consulted at the the Augustus C. Long Health Sciences Library at Columbia University and Columbia University. where the originals may be consulted.

This work has been identified as being free of known restrictions under copyright law, including all related and neighbouring rights and is being made available under the Creative Commons, Public Domain Mark.

You can copy, modify, distribute and perform the work, even for commercial purposes, without asking permission.



Wellcome Collection  
183 Euston Road  
London NW1 2BE UK  
T +44 (0)20 7611 8722  
E [library@wellcomecollection.org](mailto:library@wellcomecollection.org)  
<https://wellcomecollection.org>

COLUMBIA LIBRARIES OFFSITE  
HEALTH SCIENCES STANDARD



HX64052923

RD523 M13

Oral surgery; a text

**RECAP**



RD523

M13

Columbia University  
in the City of New York


College of Physicians and Surgeons


Library



Gift of

Dr. C. F. MacDonald









# ORAL SURGERY





# ORAL SURGERY

A TEXT-BOOK ON GENERAL SURGERY AND  
MEDICINE AS APPLIED TO DENTISTRY

BY

STEWART LEROY McCURDY

PROFESSOR OF ANATOMY AND ORAL SURGERY, SCHOOL OF DENTISTRY, UNIVERSITY OF PITTSBURGH;

CHAIRMAN OF SECTION ON STOMATOLOGY, AMERICAN MEDICAL ASSOCIATION (1910, 1911, 1912);

ORTHOPEDIC SURGEON, PRESBYTERIAN AND COLUMBIA HOSPITALS, ETC., PITTSBURGH.

AUTHOR OF "MANUAL OF ORTHOPEDIC SURGERY," "ANATOMY IN ABSTRACT,"

"EMERGENCIES IN ABSTRACT," "ARTHROSTEOPEDIC SURGERY."

WITH TWO HUNDRED AND TWENTY-EIGHT ILLUSTRATIONS



NEW YORK AND LONDON

D. APPLETON AND COMPANY

1912

*C. Franklin Mac Donald D.M.D.*



RD  
523  
M13  
1912

COPYRIGHT, 1912, BY  
D. APPLETON AND COMPANY

PRINTED IN  
NEW YORK, U. S. A.

TO


JAMES FAIRCHILD BALDWIN, A.M., M.D.

COLUMBUS, OHIO

THE UNCONSCIOUS MONITOR OF MY PROFESSIONAL CAREER

THIS BOOK IS DEDICATED BY THE AUTHOR





Digitized by the Internet Archive  
in 2010 with funding from  
Open Knowledge Commons

## NOTE

THE present volume is the first of a series of text-books which has been planned by the Commission on Text-books of the Institute of Dental Pedagogics. It is intended that the entire subject of dentistry as it should be presented in a standard dental college shall be covered in a definite number of books, each book including only such subjects as properly belong to it. It appeared advisable, however, to most briefly consider the subjects of bacteriology and inflammation and their immediate results to properly introduce the subjects which follow and which constitute the main part of this book. Some of the chapters in this book would be made more explicit if the regional or special anatomy of the part under discussion were briefly given, but the student is referred to the text-book on general anatomy, which will include special and regional anatomy of the face, mouth and head.

*H. C. Friesell*

*A. E. Webster*

*Elleson Hillier,  
Commission on Text Books,  
Institute of Dental Pedagogics.*





## PREFACE

ORAL SURGERY is a well-defined and separate specialty. Whether it belongs to general surgery or to dentistry, or whether the dental student needs more oral surgery and more knowledge of general medicine and surgery or whether the medical student and practitioner needs more dentistry by way of the oral surgical route, is a question. Garretson's "Oral Surgery," which was the first systematic work on this subject, included everything in dentistry and much on general medicine and surgery. This, however, is not the modern idea of the scope of the subject. The present book is divided into two parts, the first part, including the principles of general medicine and surgery, intended for the Junior student, and the second part, for the Senior student, including oral surgery proper. The aim has been to eliminate everything that cannot be directly associated with the practice of dentistry or be of special interest to the dental student and practitioner. Dental pathology does not differ from general pathology, and the student who has been trained in the principles in general is better prepared to appreciate the pathological changes as they appear in the mouth.

The author is indebted to the "American Practice of Surgery," Keen's "Surgery," Bryant's "Operative Surgery," and current dental and medical literature in the preparation of the following pages, and it has been the aim to give credit when extracts or abstracts have been made by using quotation marks. The author especially desires to acknowledge the valuable assistance given in the preparation of the manuscript to the following: A. B. Wallgren, M.D., Bacteriology and Inflammation; George C. Johnston, M.D., X-ray; G. A. Holliday, M.D., Venereal Diseases; and H. B. Kohberger, M.D., General Diagnosis and Vascular Diseases.

STEWART LEROY McCURDY.

Pittsburgh, Pa.





# CONTENTS

## PART I

### PRINCIPLES OF SURGERY

#### CHAPTER I

	PAGES
BACTERIA AND INFLAMMATION AND THEIR IMMEDIATE RESULTS	
Bacteria—Inflammation—Necrosis—Gangrene—Suppurative inflammation . . . . .	3-15

#### CHAPTER II

NON-SPECIFIC INFECTIONS	
Cellulitis—Sapremia—Septicemia—Pyemia . . . . .	16-22

#### CHAPTER III

SPECIFIC INFECTIONS	
Erysipelas—Actinomycosis—Tetanus—Hydrophobia—Anthrax .	23-31

#### CHAPTER IV

GENERAL TUBERCULOSIS	
Etiology—Pathology—Treatment . . . . .	32-34

#### CHAPTER V

THE VENEREAL DISEASES	
Gonorrhea—Chaneroid—Syphilis . . . . .	35-53

#### CHAPTER VI

WOUNDS AND HEMORRHAGE	
Wounds—Hemorrhage—Burns and scalds—Injuries to brain and skull—Foreign bodies . . . . .	54-65



## CHAPTER VII

## BANDAGING

Uses of bandages—Varieties of bandages . . . . .	66-69
--	-------

## CHAPTER VIII

## SHOCK AND MEDICAL EMERGENCIES

Shock—Unconscious conditions . . . . .	70-74
--	-------

## CHAPTER IX

## ASEPSIS AND ANTISEPSIS

Germicides—Sterilization of dressings and instruments—The operating room—The patient—Sutures and ligatures . . .	75-79
---	-------

## CHAPTER X

## GENERAL DIAGNOSIS

Case history—How to obtain a complete knowledge of a disease— Diagnostic signs . . . . .	80-87
---	-------

## CHAPTER XI

## DISEASES AND INJURIES OF THE VASCULAR SYSTEMS

The Heart—Diseases and injuries of the arteries and veins— Lymphatics . . . . .	88-97
--	-------

## PART II

## ORAL SURGERY

## CHAPTER XII

## GENERAL INTRODUCTION

Disturbances due to dentition—Oral hygiene—Complications of extraction—Reflex neuroses from the teeth . . . . .	101-111
--	---------

## CHAPTER XIII

## ALVEOLAR ABSCESS AND ITS MORE GRAVE CONSEQUENCES

Pathology—Alveolar abscess of the maxilla—Treatment . . . . 112-122

## CHAPTER XIV

## MOUTH LESIONS

Local acute stomatitis—Symptomatic mouth lesions—Some affections of the nasal and oral cavities which are related to skin diseases—Vincent's angina . . . . . 123-145

## CHAPTER XV

## DISEASES OF THE TONGUE

Congenital defects—Acquired affections . . . . . 146-159

## CHAPTER XVI

## SURGICAL DISEASES AND INJURIES OF THE FACE

Diseases of the sebaceous glands—Parasitic diseases of the skin—Acute infection of the skin—Wounds of the face and mouth—Neuroses of the face . . . . . 160-170

## CHAPTER XVII

## GENERAL BONE DISEASES

Osteomyelitis—Periostitis . . . . . 171-178

## CHAPTER XVIII

## DISEASES OF THE MANDIBLE

Alveolar necrosis—Periostitis of the body of the mandible—Osteomyelitis of the body of the mandible—Chemical necrosis—Exanthematous necrosis . . . . . 179-192

## CHAPTER XIX

## DISEASES OF THE MAXILLA

Acute suppurative diseases—Tuberculous diseases—Diseases of the bones due to lesions in the central nervous system—Regeneration of bone—Technique of operations upon bones of the face . . . . . 193-208



## CHAPTER XX

## TUBERCULOSIS OF THE FACE, MOUTH AND JAW

- Tuberculosis of the face—Tuberculosis of the mouth—Tuberculosis of the facial bones . . . . . 209-218

## CHAPTER XXI

## SYPHILIS OF THE MOUTH

- The initial lesion—Secondary manifestations—Tertiary lesions. . 219-237

## CHAPTER XXII

## TUMORS IN GENERAL

- Classification—Fibroma—Lipoma—Adenoma—Neuroma—Cysts—  
Non-infective tumors of the soft tissues of the mouth . . . 238-247

## CHAPTER XXIII

## DEVELOPMENTAL TUMORS OF THE TEETH

- Epithelial tumors—Follicular odontomata—Radicular odontomata—  
Composite odontomata—Symptoms—Diagnosis—Treatment . 248-257

## CHAPTER XXIV

- NEOPLASMS OF THE ALVEOLAR SOFT TISSUES AND BONE TUMORS AND CYSTS  
Neoplasms of the alveolar soft tissues—Bone tumors and cysts . 258-274

## CHAPTER XXV

## MALIGNANT TUMORS OF THE MOUTH

- Sarcoma in general—Sarcoma of the mouth—Carcinoma in general—Epithelioma of the mouth . . . . . 275-287

## CHAPTER XXVI

## CYSTS AND TUMEFACTIONS FROM DEVELOPED TEETH

- Impaction of teeth—Cysts from delayed eruption—Cysts from roots of developed teeth . . . . . 288-299



## CHAPTER XXVII

CONGENITAL AND ACQUIRED DEFORMITIES OF THE FACE AND MOUTH IN  
GENERAL

Development of the face and mouth—Median facial cleft—  
Other congenital defects—Acquired deformities in general . 300-309

## CHAPTER XXVIII

## HARE LIP

Clinical varieties—Prognosis—Operation for hare lip . . . . . 310-315

## CHAPTER XXIX

## CLEFT PALATE

History—Etiology—Varieties—Time of operation—Anesthesia—  
Mouth gags—Operations . . . . . 316-333

## CHAPTER XXX

## DISEASES OF THE MAXILLARY AND OTHER SINUSES

Anatomy—Diseases of the antrum . . . . . 334-352

## CHAPTER XXXI

## FACIAL NEURALGIA

Symptoms—Diagnosis—Prognosis—Treatment . . . . . 353-363

## CHAPTER XXXII

## THE SALIVARY GLANDS

Diseases of the salivary glands . . . . . 364-375

## CHAPTER XXXIII

## ANKYLOSIS

Temporary ankylosis—Permanent ankylosis . . . . . 376-388

## CHAPTER XXXIV

## FRACTURE IN GENERAL

Varieties—Etiology—Symptoms—Diagnosis—Prognosis—Treatment . . . . .	389-392
---	---------

## CHAPTER XXXV

## FRACTURE OF THE MANDIBLE

Frequency—Location—Causes—Symptoms—Diagnosis—Complications—Repair—Treatment . . . . .	393-407
---	---------

## CHAPTER XXXVI

## FRACTURE OF MAXILLA AND UPPER PART OF FACE

Fracture of the maxilla—Fracture of nasal bones—Fracture of the malar bone—Fracture of the zygomatic arch . . . . .	408-417
---	---------

## CHAPTER XXXVII

## DISLOCATIONS

Dislocations in general—Dislocation of the mandible . . . . .	418-424
---	---------

## CHAPTER XXXVIII

## X-RAY IN ORAL SURGERY

X-Ray in oral surgery . . . . .	425-432
---------------------------------	---------

## APPENDIX

Questions in oral surgery . . . . .	435-456
-------------------------------------	---------

INDEX . . . . .	459-469
-----------------	---------



## LIST OF ILLUSTRATIONS

FIG.	PAGE
1. Actinomycosis . . . . .	27
2. Initial lesion on the finger of a dentist . . . . .	42
3. Macular syphilide . . . . .	45
4. Syphilitic ulceration of the face and nose . . . . .	46
5. Diffused syphilitic periostitis of hereditary origin . . . . .	50
6. Congenital diffused specific periostitis, suppurating at many points . . . . .	52
7. Roller bandages . . . . .	67
8. Triangular bandages . . . . .	68
9. Location of heart sounds . . . . .	89
10. Atrophy marks on teeth . . . . .	107
11. Case of alveolar abscess . . . . .	114
12. X-ray of alveolar abscess . . . . .	118
13. Granulation from abscess resembling papilloma . . . . .	119
14. The most common alveolar fistula of the maxilla . . . . .	120
15. Method of establishment of naso-oral fistula . . . . .	120
16. Abscess . . . . .	121
17. Alveolar abscess of the mandible . . . . .	121
18. Ulcerative stomatitis . . . . .	128
19. Mycosic stomatitis . . . . .	130
20. Cancerum oris . . . . .	132
21. Strawberry tongue . . . . .	137
22. Follicular tonsillitis . . . . .	137
23. Diphtheritic throat . . . . .	137
24. Koplik's spots . . . . .	137
25. Vincent's angina (Thomson) . . . . .	143
26. Hypertrophy of the tongue (Bryant) . . . . .	148
27. Ludwig's angina . . . . .	151
28. Ludwig's angina . . . . .	151
29. Leucoplakia linguæ . . . . .	153
30. Epithelioma of the tongue . . . . .	157
31. Acne vulgaris . . . . .	162
32. Blastomycosis . . . . .	164
33. Tinea sycosis . . . . .	165
34. Periostitis of mandible . . . . .	181
35. Periostitis . . . . .	182



FIG.		PAGE
36.	Periostitis . . . . .	183
37.	Alveolar process in osteomyelitis . . . . .	184
38.	Alveolar process in osteomyelitis . . . . .	185
39.	Osteomyelitis of the mandible . . . . .	186
40.	Arsenic necrosis . . . . .	189
41.	Schematic outline of bone removed . . . . .	190
42.	Reproduction on mandible of bone destroyed . . . . .	190
43.	Suppurative periostitis of the mandible . . . . .	191
44.	Sequestrum removed from maxilla . . . . .	194
45.	Method of closing naso-oral fistula . . . . .	195
46.	Completed operation for naso-oral fistula . . . . .	195
47.	Final result of operation . . . . .	196
48.	Acromegaly . . . . .	198
49.	Sequestrum representing entire right half of mandible . . . . .	201
50.	Articulation of teeth after removal of sequestrum in Fig. 49 . . . . .	202
51.	Papilla showing necrosis in case of Fig. 50, before operation . . . . .	203
52.	External appearance in complete destruction of bone . . . . .	204
53.	Area bone destroyed . . . . .	204
54.	Teeth together after regeneration of bone . . . . .	205
55.	Mouth open after regeneration of bone . . . . .	205
56.	Entire right half of mandible removed in four fragments . . . . .	206
57.	Result after regeneration of bone . . . . .	206
58.	Cosmetic result . . . . .	207
59.	Mouth retractor . . . . .	208
60.	Tuberculosis cutis . . . . .	210
61.	Lupus vulgaris in early stage . . . . .	211
62.	Periadenitis mucosa necrotica recurrens . . . . .	215
63.	Periadenitis mucosa necrotica recurrens . . . . .	215
64.	Tuberculosis of the mouth . . . . .	216
65.	Chancre of lip . . . . .	221
66.	Chancre of tongue . . . . .	222
67.	Secondary lesion of syphilis with salivation . . . . .	226
68.	Gumma of tongue . . . . .	227
69.	Sclerosing glossitis . . . . .	229
70.	Acquired cleft palate . . . . .	232
71.	Sequestrum . . . . .	233
72.	Appearance of mouth after treatment for syphilis . . . . .	233
73.	Hereditary necrosis . . . . .	235
74.	Cleft palate from hereditary syphilis . . . . .	236
75.	Odontomata, or enamel deposit on a developed tooth . . . . .	251
76.	Odontomata, or enamel deposit on a developed tooth . . . . .	251
77.	Odontoma . . . . .	253



## LIST OF ILLUSTRATIONS

xix

FIG.		PAGE
78.	Microscopic section of odontoma . . . . .	254
79.	Multiple cyst of mandible caused by impaction of two teeth . . . . .	256
80.	Papilloma of alveolus . . . . .	259
81.	Papilloma of alveolus . . . . .	260
82.	Papilloma of alveolus . . . . .	261
83.	Papilloma of alveolus . . . . .	262
84.	Polypus of gum . . . . .	263
85.	Polypus of gum . . . . .	264
86.	Hypertrophy of gum . . . . .	265
87.	Hypertrophy of gum . . . . .	266
88.	Myeloid epulis . . . . .	267
89.	Fibroid epulis before operation . . . . .	268
90.	Fibroid epulis after operation . . . . .	269
91.	Chloroma, lower jaw . . . . .	269
92.	Chloroma, upper jaw . . . . .	270
93.	Osteoma of maxilla . . . . .	272
94.	X-ray of osteoma . . . . .	273
95.	Sarcoma of mandible . . . . .	279
96.	Sarcoma of maxilla . . . . .	280
97.	Epithelioma of lip before X-ray . . . . .	282
98.	Epithelioma of lip after X-ray . . . . .	282
99.	Epithelioma of cheek . . . . .	284
100.	Epithelioma of mouth . . . . .	285
101.	Epithelioma of alveolus . . . . .	286
102.	Carcinoma of mandible . . . . .	287
103.	Aluminum bridgework as substitute . . . . .	287
104.	Impacted central . . . . .	289
105.	Impacted lateral . . . . .	290
106.	Impacted teeth . . . . .	291
107.	Impaction of teeth with abscesses and cysts . . . . .	292
108.	Impaction of teeth with abscesses and cysts . . . . .	292
109.	Impaction of teeth with abscesses and cysts . . . . .	293
110.	Impaction of teeth with abscesses and cysts . . . . .	293
111.	Impaction of teeth with abscesses and cysts . . . . .	293
112.	Impacted bicuspid found in a skull . . . . .	294
113.	Impacted lower molar . . . . .	295
114.	Four impacted teeth in one case . . . . .	296
115.	Impacted upper molar . . . . .	297
116.	Impacted central . . . . .	298
117.	Cyst from erupting tooth . . . . .	298
118.	Root cyst . . . . .	299
119.	Teeth from same cyst . . . . .	299



FIG.		PAGE
120.	Cyst from developed tooth . . . . .	299
121.	Embryonic development of face . . . . .	301
122.	Premaxillary bone . . . . .	301
123.	Cross section of face . . . . .	303
124.	Muscles of the soft palate . . . . .	304
125.	Cleft palate . . . . .	306
126.	Large hypertrophied tonsils and adenoid, the latter visible below the margin of the soft palate . . . . .	307
127.	Congenital microstoma . . . . .	308
128-130.	Nélaton's method of operation in hare lip . . . . .	311
131-133.	Malgaigne's method of operation in hare lip . . . . .	311
134-136.	Mirault-Langenbeck's method of operation in hare lip . . . . .	312
137-139.	Operation for bilateral hare lip . . . . .	312
140.	Bilateral incomplete hare lip . . . . .	313
141.	Result of operation . . . . .	313
142.	Unilateral complete hare lip . . . . .	313
143.	Bilateral complete hare lip, with projecting intermaxillary process . . . . .	314
144.	Result after hare lip operation . . . . .	314
145.	Result after hare lip operation . . . . .	314
146.	Brown's model showing his method of approximating maxil- lary bones . . . . .	320
147.	Rose position . . . . .	320
148-149.	Brophy's periosteal elevators . . . . .	321
150.	Fillebrown's hoe . . . . .	321
151.	Cleft alveolar process . . . . .	322
152.	Result of operation . . . . .	323
153.	Operation for cleft alveolar process . . . . .	324
154.	Cleft palate . . . . .	325
155.	Union of entire cleft after operation . . . . .	326
156.	Cosmetic result of operation . . . . .	327
157.	Method of forming and adjusting flaps in cleft palate operations . . . . .	328
158.	Method of forming and adjusting flaps in cleft palate operations . . . . .	328
159.	Method of forming and adjusting flaps in cleft palate operations . . . . .	329
160.	The three steps of closing the soft palate, and practically the same method of closing the hard palate . . . . .	330
161.	Left superior maxillary bone with associated parts . . . . .	331
162.	Ferguson's operation for unilateral cleft palate . . . . .	331
163.	Ferguson's operation for unilateral cleft palate . . . . .	331



## LIST OF ILLUSTRATIONS

xxi

FIG.		PAGE
164.	Author's method of introducing sutures . . . . .	332
165.	Original curved needle . . . . .	333
166.	Hook and eye . . . . .	333
167.	A section cut vertically in the region of the second molar tooth	335
168.	A transverse vertical section . . . . .	335
169.	A section cut anteriorly to the second molar teeth . . . . .	335
170.	Anterior-posterior section through the antrum near the naso-antral septum . . . . .	
171.	Transverse section just anterior to the ostium maxillare . .	337
172.	Lateral wall of antrum . . . . .	338
173.	X-ray showing disease of antrum on right side with pus . .	345
174.	X-ray showing disease of the antral and frontal sinuses on the left side, with pus . . . . .	346
175.	Mouth after antral operation . . . . .	347
176.	Deep injections for neuralgia . . . . .	358
177.	Method of exposing the supraorbital branch of the fifth nerve	361
178.	Exposed infraorbital branch of the fifth nerve . . . . .	361
179.	Mental branch at foramen as exposed through the mouth . .	362
180.	Operation for salivary fistula . . . . .	367
181.	Operation for salivary fistula . . . . .	367
182.	Model of ranula before operation . . . . .	372
183.	Ranula showing incision . . . . .	373
184.	Sarcoma of the parotid gland . . . . .	374
185.	Impacted third upper molar causing spasmodic ankylosis . .	377
186.	Impacted third molar causing spasmodic ankylosis . . . . .	378
187.	Resection of the mandibular condyle . . . . .	381
188.	Resection of mandible showing Gigli saw in position . . . .	382
189.	Result of operation . . . . .	383
190-192.	Incision through skin and needle passing under maxilla into mouth . . . . .	384
193.	Case of ankylosis before operation. Front view . . . . .	385
194.	Case of ankylosis before operation. Side view . . . . .	386
195.	Case of ankylosis after operation. Side view . . . . .	387
196.	Case of ankylosis after operation. Front view . . . . .	387
197.	Dental splint swaged to fit the teeth and cemented into position . . . . .	396
198.	Angle's bands . . . . .	396
199.	Holding fractured mandible to maxilla with wire around pins on the band . . . . .	397
200.	Holding fragments in position with a screw rod from bands .	398
201.	Drilling the bone in a fractured mandible . . . . .	399
202.	Notched drill and wire . . . . .	399



FIG.		PAGE
203.	Threading drill hole with wire . . . . .	400
204.	Chisel used to freshen ends of bones in old fractures . . . . .	400
205.	Fracture through molars, showing method of making traction to overcome a muscular spasm and approximate the bones . . . . .	401
206.	Double fracture, showing wires in position . . . . .	402
207.	Fracture of ramus, with wires in position . . . . .	403
208.	Fracture of symphysis, with wires in position . . . . .	404
209-210.	Longitudinal fracture of the alveolar process, including four teeth . . . . .	405
211.	Obstetric fracture of mandible . . . . .	406
212.	Fracture of maxilla, showing apparatus . . . . .	409
213.	Fracture of maxilla, showing skull apparatus, method of applying bandage, and result . . . . .	410
214.	Fracture of maxilla and mandible . . . . .	411
215-218.	Four cases in which portions of the maxillæ were broken away in an effort to extract a tooth . . . . .	412
219.	Depressed fracture of the malar bone, before operation . . . . .	414
220.	Depressed fracture of the malar bone, after operation . . . . .	415
221.	Coat hook for elevating depressed fractures of the malar and other bones . . . . .	416
222.	Reducing dislocated mandible . . . . .	424
223.	Epithelioma about the molar tooth . . . . .	427
224.	X-ray technique . . . . .	428
225.	Proper method of taking X-ray of jaw . . . . .	428
226.	Impaction of lower left first molar . . . . .	429
227.	Salivary calculus in the duct of the submaxillary gland . . . . .	430
228.	Cyst of mandible and impacted third molar . . . . .	431

PART I  
GENERAL SURGERY





## CHAPTER I

### BACTERIA AND INFLAMMATION AND THEIR IMMEDIATE RESULTS

#### BACTERIA

With the introduction of the microscope, some order was brought into understanding that group of organisms which Linnæus had termed "chaos." That disease and decay were due to minute organisms had been the theory for centuries. Leeuenhœck was able, by the improved microscope, to demonstrate microörganisms in water, intestinal contents, etc. He made out short, straight and curved rods, and described their mobility. Muler attempted a systematic classification. Rayer and Davaine, in 1815, found rod-shaped organisms in the blood of animals sick with splenic fever. Pasteur established the cause of fermentation and the part played by bacteria in the economy. Davaine then established the nature of splenic fever, or anthrax, which has been the foundation for our knowledge of the relation of bacteria to disease.

**Morphology of Bacteria.**—Bacteria are made up of a cell membrane, cell wall and cell contents. The cell membrane, or capsule, surrounds the organism. The cell wall lies between the capsule and the cell protoplasm, from which it is modified. It is composed of cellulose or an albumin and can easily be demonstrated. The cell content is mainly protoplasm, composed of mycoprotein. As a rule, it is homogeneous, but may contain granules, fluid spaces, fat droplets, pigment, sulphur and chlorophyll.



**Reproduction of Bacteria.**—Reproduction takes place by fission and sporulation. Fission or simple cell division takes place when favorable conditions, such as heat, moisture and nutrition exist, together with the absence of the deleterious effects of other bacteria or their products. The cell elongates, and the cell wall constricts, usually at the cell center, gradually forming a septum that divides the cell into equal parts. This division may take place in one, two, or three planes, depending upon the nature of the bacterium. Division may be completed within fifteen minutes.

**Biology of Bacteria.**—Bacteria cannot arise *de novo*. They must develop from preëxisting bacteria or their spores—one kind of bacterium will not produce another kind. They are classified into saprophytes, or those that live only on dead organic matter; and parasites, or those which live at the expense of living bodies. They cause pathological conditions in the host; therefore, they are called pathogenic. Obligate parasites or saprophytes exist only under one of the above conditions, while facultative parasites or saprophytes can develop under both conditions.

**Bacteria and Products of Bacteria.**—The functions and products of bacteria (vital actions) are destructive ones, splitting up higher nitrogenous and non-nitrogenous compounds into simpler substances. Sometimes such changes are destructive to the bacteria themselves, as when lactic and butyric acids are formed in the media.

Substances found in media of bacterial growth are as follows: 1. *Proteins*. These are components of the bacterial cell proper, and may cause suppuration (pyogenic), fever (pyrogenic), and inflammatory processes (phlogenic). 2. *Ferments*, secretions of the cell, which possess the power of breaking up the more highly organized nitrogenous and non-nitrogenous compounds into simple and more diffusible substances. The action of ferments upon nitrogenous compounds is called fermentation; upon non-nitrogenous compounds it is known as putrefaction, which often pro-



duces odorous gases and ptomaines (complex alkaloids resembling those found in plants). The principal bacterial ferments are: Proteolytic, diastatic, inverting, emulsifying, coagulating, hydrolytic, fat-splitting, oxidizing, and nitrifying. 3. *Substances that are the result of the action of bacteria upon the medium of growth.* (a) *Toxins*, poisonous substances akin to the venom of serpents and other animals, and to certain poisonous principles of plants. They may be divided into (1) those which are within the body of the bacteria and are set free by the disintegration of the organism; and (2) those which are excreted by the bacteria and are found in the surrounding media. (b) *Pigments*. (c) *Photogenesis*. (d) *Fluorescence*. (e) *Odors*. (f) *Gas*.

**Effects of Bacteria** (*Generally Known as Infections*).—When bacteria have gained an entrance into the animal body, the effects may be either local or general. Local effects are of two kinds: (a) *Mechanical*, which by their mere presence in the tissues may cause tissue changes of two kinds—proliferation, due to irritation, and thrombosis (by rapid multiplication) and its consequent conditions; (b) *toxic*, which are due to the action of their toxins upon the cells with which they are in direct contact, and which may result in proliferation, cell degeneration and necrobiosis.

General effects (intoxications) are due entirely to the circulation of the toxins of the bacteria in the blood. This may occur in two ways: (a) From a *primary focus* (point of entrance)—bacteria may remain at the point of entrance and liberate toxins which are absorbed and circulated by the blood, causing disease, e. g., tetanus, diphtheria or the sapremia due to pyogenic organisms; (b) from a *secondary focus*—bacteria may also circulate in the body fluids and find lodgment in any of the organs, causing both local changes in the tissue and general intoxication, such as the bacillus of Eberth (typhoid fever), pneumococcus of



Frankel (pneumonia), diplococcus intracellularis of Weichselbaum (cerebro-spinal fever), streptococcus (septicemia and pyemia).

*Immunity* denotes that condition of an organism which enables it to resist an attack of the particular bacteria and their toxic secretions against which it is said to be immune.

**INFECTIOUS DISEASES DUE TO BACTERIA.**—An infection is the invasion of the body by a disease-producing microorganism. The time when the germ enters the body is not always known to the patient, and some time usually elapses between the time of actual entrance and the appearance of the resulting symptoms. This time is called the period of incubation. There is, at this time, no great distinction between the terms infection and contagion, unless it is that contagion is used to denote infection by personal contact.

Of the suppurative diseases, the staphylococcus group may be divided as follows: (a) *Staphylococcus pyogenes aureus* is found in lesions such as furuncles, abscesses, carbuncles and ulcerations of the skin or mucous membranes. It is frequently seen in suppurative inflammations, such as malignant endocarditis, osteomyelitis, appendiceal abscesses, etc. It is generally found in focal lesions. Other organisms may also be associated in these lesions. (b) *Staphylococcus pyogenes albus* is far less virulent than the *aureus* and is frequently found as a harmless parasite of the skin. Associated with other microorganisms, it occurs generally in abscesses and suppurative diseases. (c) *Staphylococcus pyogenes citreus* is not very common nor virulent.

In the streptococcus group are included various bacteria that resemble each other very closely. (a) *Streptococcus pyogenes* is found distributed much the same as the staphylococci, but not generally in the healthy body. It is found upon the mucous membranes or in the various secretions or excretions of the body and occasionally occurs in focal lesions. It may occur in generalized septicopyemia, infec-



tious endometritis and sometimes in ulcerative endocarditis. It may occur in persons with previous good health or in the course of infectious diseases, such as scarlatina, measles and la grippe; also in sore throats resembling diphtheria (pseudodiphtheria). It is always found in cases of erysipelas. (b) *Streptococcus intracellularis meningitidis*, also called meningococcus or diplococcus meningitidis, is found in meningeal pus, nasal mucus, sputum and urine of those sick with epidemic cerebro-spinal meningitis. Other microorganisms associated in meningitis are the pneumococcus, streptococcus and staphylococcus pyogenes, typhoid and colon bacilli, influenza bacillus, etc.

## INFLAMMATION

Inflammation is the reaction to various forms of irritation which occurs in tissues and is characterized by the cardinal symptoms of heat (calor), redness (rubor), pain (dolor), swelling (tumor) and, later, altered function (functio læsæ). Its etiology includes irritation by mechanical means, as in fractures and wounds; chemical means, as by strong acids; electrical means; thermal means, or opposite, burns and frost bites; microorganisms; metabolic influences, as in gout, etc.; mental influence, as in hypnosis, etc.

The phenomena of inflammation include vascular, exudative, proliferative and degenerative changes.

**Vascular Changes.**—The vascular changes are, first, a probable momentary reflex contraction of the arteries (rarely observed), then a dilatation of the arteries, due to some degeneration of the vessel walls mostly, but in part to nervous reflex. The blood courses quickly at first, followed by a slowing of the current, with sometimes complete stoppage (stasis), brought about by the damaged endothelial cells, which swell and increase in adhesiveness, thus encroaching upon the lumen of the vessel. This condition is followed by exudative changes.



**Exudative Changes.**—The leucocytes in the plasmatic zone of the blood stream increase in number and cling to the vessel wall. The leucocytes then migrate through the vessel wall into the tissues. This is brought about by the leucocytes' own ameboid movement and chemotaxis (positive) and the attractive chemical influence at the site of irritation; and increased permeability of the vessel wall and blood pressure aid to a minor extent. Coincidentally with migration there is exudation of altered blood plasma, the amount and character of which vary with the nature and condition of the tissues affected and the character of the irritant. The exudate is relatively rich in albumen and more coagulable than dropsical fluid. There is also an escape of the red corpuscles (diapedesis of red corpuscle) from the capillaries. It is a passive process due to blood pressure and is most marked when stasis has occurred.

**Proliferative Changes.**—Some authorities hold that proliferative changes are not in reality a part of inflammation, but are for the purpose of tissue repair after inflammation. They will, however, be regarded here as a part of inflammation. In the inflamed area, especially at the periphery, the tissue is infiltrated with round cells resembling lymphocytes or mononuclear leucocytes frequently showing evidences of karyokinesis. They are derived from fixed connective tissue cells and the endothelia of lymph spaces. The newly-formed connective tissue cells become in part wandering and more or less phagocytic in nature; and in part fixed, assuming a regenerative rôle. They are frequently called fibroblastic cells. The appearance of the tissue at this stage is characteristic and is termed round-cell infiltration. Granulation tissue is formed by active proliferative changes, multiplication of new blood vessels and preëxisting vessels' endothelial outgrowth, all surrounded by various forms of round cells. It is frequently seen in the floor of ulcers. It is more properly a regeneration.

**Degenerative Changes.**—The nature of the degeneration



depends upon the severity of the irritation, very powerful irritants causing necrosis at once. Irritants which merely disorder but do not entirely destroy the cells are apt to cause inflammation. The degenerative changes may be physiologic or there may be structural changes, such as cloudy swelling, mucoid degeneration, liquefaction and fatty or coagulation necrosis. These degenerations, though primary, are often followed by a secondary degeneration which may serve to spread and intensify the original inflammation.

**Varieties of Inflammation.**—*Catarrhal inflammation*, *mucous inflammation* or *catarrh*, occurs on the mucous membranes in the nose, throat, bronchi, stomach, bowels, etc. The mucosa is congested, a serous exudation is discharged from the surface, and to some extent it is retained in the tissue, causing edematous swellings. The mucous glands increase their secretion and leucocytes escape.

*Serous inflammation* is characterized by an abundant exudate of serum with little cellular matter. It is seen in pleural or peritonitic effusions and as edema of the larynx, etc.

*Fibrinous (croupous) inflammation* is characterized by a thick deposit of fibrin and occurs on the serous surfaces, as in peritonitis; in the larynx and the bronchi in acute infections, as typhoid fever, smallpox and pyemia; and in the lungs in pneumonia. The term "sero-fibrinous" is applied when the inflammation is associated with serous exudation and "fibrino-purulent" when the exudate is purulent.

*Diphtheritic inflammation* is of the same nature as the fibrinous, but differs in that it is much more severe and there is associated with the coagulated exudate a necrosis of the cells of the part involved.

*Parenchymatous inflammation* is a term applied to an inflammation when it attacks the proper tissues of an organ, as in nephritis, and leads to degeneration of its active cells.



*Productive inflammation* is referred to as interstitial inflammation in contradistinction to the parenchymatous form. The proliferative changes predominate over exudation and degeneration.

*Hyperemia—Congestion.*—Hyperemia, or congestion, is an increase in the quantity of blood in a tissue or an organ of the body, and is divided into active and passive forms. *Active, acute, or arterial hyperemia or congestion* is due to an increase of the blood flow to a part. It occurs physiologically during the functional activity of the organs and pathologically from any condition which interferes with the nervous control of the caliber of the arteries, when it may act (1) through their local nerve plexuses or the vasomotor center in the medulla. Under these conditions it is known as (a) *neuroparalytic hyperemia*, in which the vaso-constrictor fibers of the sympathetic nerves are cut off or compressed by tumors or (b) *neurotoxic hyperemia*, in which the vaso-dilators in the spinal nerves are stimulated as in neuritis. Toxic causes or fevers may act similarly through the vasomotor centers, causing superficial hyperemia. It may act (2) by local affections of the vessel walls, due to injury by heat, traumatism, inflammation, drugs or vascular fatigue, or following temporary stoppage of the circulation, as frequently seen on the removal of the rubber bandage after a bloodless amputation or in the abdominal vessels when the pressure of an ascites or large tumor is suddenly relieved. Arterial hyperemia is the initial phenomenon of inflammation, but transudation takes place only when the capillary endothelium is damaged.

*Passive or venous hyperemia* is due to an obstruction of the outflow of blood through the veins by: failure of the left heart to provide arterial pressure; failure of the right heart to empty the veins; weak heart power following attempts to overcome the obstruction in veins by thrombi; pressure by tumor, etc.; or the resistance of narrowed arteries (atheroma).



**Results of Inflammation.**—An early consequence of inflammation is infiltration, which terminates in either hypertrophy, hyperplasia, atrophy, degeneration, or resolution, in all of which conditions the normal histological structures have been changed.

*Infiltration* is the deposit or accumulation of any solid or fluid morbid product in the midst of tissue elements.

*Hypertrophy* is an increase in the size of the tissue elements without marked alterations from the normal structure, and it is caused by (a) an increase in functional demand, (b) disturbances of the nervous system, and (c) continued congestion.

*Hyperplasia* is an increase in the number of cells while they remain normal in size.

*Atrophy* is a decrease in the size of a tissue or an organ. The cause may be defective development, nerve injury, non-use, occlusion of the blood vessels, or pressure.

*Degeneration* is the retrograde change which takes place in a cell or tissue by which its integrity is altered in the direction of lowered vitality. The protoplasm of the cell may be converted into substances normal to it in kind and quantity. The cell may break down and be absorbed or its altered débris may well remain in one form or another.

*Resolution* is a restoration or a repair after a pathological change from any cause. When resolution occurs, the normal histological structure of the tissues may have been destroyed to some extent, yet the functional usefulness of the parts which have been inflamed may remain normal.

## NECROSIS

Necrosis is the local death of tissue. *Necrobiosis* is the death of individual cells. The causes are: (1) *Circulatory derangements*: (a) Acute and chronic ischemia, produced by embolism, thrombosis, arteriosclerosis, atheroma, extra-arterial blood pressure, cardiac spasms, ergotism and Ray-



naud's disease; (b) venous stagnation; (c) anemia; (d) cachexia; (e) senility; (f) diabetes—(2) *Trophic derangements*, due to trophic disturbances, as bed sores and myelitic cystitis—(3) *Intoxications*, due to animal, vegetable, bacterial and inorganic poisons—(4) *Traumatism*, due to pressure *per se* or the pressure of calculi, concretions, enteroliths or exostoses—(5) *Inflammations*.

**Varieties of Necrosis.**—*Coagulation Necrosis*.—In this necrosis the proteid of the tissue suffers death from changes similar to coagulation. Macroscopically the tissue is of a glazed, opaque, waxy appearance, pale and firm. Later the tissue becomes grayish and is inclined to soften. Microscopically there is a fixed exudate in the tissues. Fibrin granules or fibrils are present. Fibrinoids, which do not react to stains like the fibrin, are also seen. During the early stage the nuclei stain faintly and are of homogeneous appearance. The cell disintegrates and the striations disappear in the muscles. All other cells in the area suffer the fate of the fixed tissues.

*Liquefaction necrosis* or *colliquation* is the death of tissue with liquefaction. It is divided into primary liquefaction necrosis, as seen frequently in the central nervous system, where it follows pathologic conditions which elsewhere would produce coagulation; and secondary liquefaction necrosis, a form in which the areas of coagulation necrosis, cheesy necrosis, inflammation, gangrenous tissue and tumors may become liquefied.

*Caseation* is spoken of where coagulation necrosis takes on a cheese-like appearance. It is secondary to coagulation necrosis and is typical of tuberculosis and syphilis.

*Fat necrosis* occurs in very stout people and is confined to small areas in the normal fat.

## GANGRENE

Gangrene is the putrefaction of areas of necrosis. It may be classed as: (1) Primary, when a particular bac-



terium produces a direct gangrenous result, as in malignant edema, anthrax, etc.; (2) secondary, when saprophytic bacteria decompose an area already dead.

The *varieties* are: *Dry gangrene*, due to arterial disturbance or occlusion, senility, arterial embolism, thrombosis, freezing, ergotism or Raynaud's disease; *moist gangrene*, which generally results from extensive venous occlusion, but in some cases may be due to arterial occlusion; *embolic, diabetic, senile, diphtheritic, hospital* and *malignant edema*.

### SUPPURATIVE INFLAMMATION

Suppurative inflammation is caused by infection with pyogenic microorganisms. It is characterized by an abundance of emigrated leucocytes and the tendency to liquefaction. The most common bacteria producing it are the pyogenic staphylococci and streptococci, but other forms not generally considered pathogenic may also cause it, such as the typhoid and colon bacilli, gonococcus and others. Bacteria, entering the tissue by means of the blood or otherwise, first cause degeneration or necrosis; congestion follows with exudation of leucocytes and plasma and more or less fibrin formation; and finally there is a softening of the whole area involved from the action of the bacteria on the cells, creating a ferment.

*Pus* is a fluid resulting from the process of suppuration and consists of a liquid part (*liquor puris*) and a corpuscular part. The liquid part is made up of a less coagulable blood plasma containing quantities of albumose. The corpuscles are chiefly more or less degenerated polymorphonuclear leucocytes. Pus, in the modern views of pathology, signifies the preëxistence of phagocytes, i. e., the presence of pathogenic bacteria, which must have destroyed the leucocytes after their escape from the blood vessel. The discharge found around the drainage tube from an aseptic



cavity must not be confounded with pus, or considered pus, since it contains no phagocytes, but reparative serum and some leucocytes.

An *abscess* is a circumscribed cavity containing pus. Previous to abscess formation, infection may take the form of cellulitis or an inflammation of the cellular structures under the skin, or lymphangitis; or the passage of the bacteria of infection along the lymphatic vessels may result in infiltration and suppuration of neighboring lymphatic glands. The course of the abscess depends entirely upon the variety of bacterium producing the suppuration. Acute abscess is usually caused by a streptococcic germ, while suppurative changes run a subacute course and are usually dependent upon the staphylococcus, pneumococcus, or the bacillus of typhoid. Other chronic suppurative changes are usually those dependent upon tuberculosis or syphilis.

An *ulcer* is of the same construction as an abscess except that it appears with erosion upon the skin or mucous surfaces. It is pathologically the same as suppuration except that the discharge, instead of collecting in a closed cavity and forming an abscess, escapes immediately upon the surface. The classification of ulcers is based upon their location, as tonsillar, or upon their cause, as tuberculous, syphilitic, gouty or traumatic. Pressure from an artificial denture frequently results in ulceration of the mucous membrane of the mouth.

A *sinus* is an opening from the skin or mucous surface leading into a focus of suppuration or into an abnormal cavity. Characteristic illustrations of sinus are those openings leading into an alveolar abscess which has resulted from a carious tooth or bone disease. Tuberculous sinuses are frequently seen in diseases of the hip, spine and other joints.

A *fistula* is an abnormal canal connecting a normal cavity with the skin or mucous membrane. A fistula results from suppuration or injury. Illustrations of the former



may be found when the antrum communicates with the mouth, the bladder with the vagina, or the stomach with the external abdominal surface. An illustration of fistula from injury may be found when Stenson's duct has been severed in its course by saber wounds or other varieties of injury and the salivary fluid discharges upon the external surface of the face instead of within the oral cavity. Examples of fistula from other causes are vesico-vaginal and recto-vesical. Congenital fistulas are frequently found in the neck and in branchial or unobliterated fetal ducts, as the urachus.



## CHAPTER II

### NON-SPECIFIC INFECTIONS

In addition to the immediate symptoms and conditions following infections, there are occasionally developed rare or remote sequelæ which have typical symptoms and will be given special consideration. These conditions include cellulitis, sapremia, septicemia and pyemia.

### CELLULITIS

Cellulitis is an acute inflammatory infection resulting from the introduction of some organism, commonly the streptococcus pyogenes, into the cellular connective tissue of the tegument, intermuscular septa, tendon sheaths, or other structures. It always arises from inoculation either from a small and superficial injury, such as a pin-prick, or from more extensive lacerations of the skin. Pus formation generally follows, but not always. The extension is usually confined to the areolar tissues and is generally by route of the lymphatics. Sloughing of the tissues of low vitality, such as fat, fascia or tendon, is quite common.

**Clinical Features.**—The first symptom is a distinct chill, followed by a temperature of 103° to 105° F., with a pulse proportionately increased, which is small, feeble, and often irregular. The face is flushed, the tongue is dry and brown, and there is frequently delirium, especially during the night. Local symptoms are swelling and edema of the skin, which assumes a dark red color. To the touch it is firm, hot and tender. There is also local burning pain. Blebs containing



dark serous fluid are frequently found. The approximal lymphatics are usually enlarged and tender. As the pus formation advances, the skin becomes soft and boggy and eventually breaks, permitting the discharge of a thick grumous liquid. Occasionally several pus cavities fuse into a large, distinct fluctuating abscess. When gas is accumulated it gives rise to emphysema. Sloughing of the ligaments, tendons and fascia is quite common. The constitutional symptoms are in proportion to the size of the area of involvement and to the absorption of toxins of the streptococci, a condition of septicemia if present. If secondary abscesses result, a pyemic condition is developed.

A remote result of cellulitis is the destruction of tendons, ligaments and fascia which have been involved in the necrotic area, causing the destruction of functional usefulness of the part, on account of the adhesions and sloughing.

**Treatment.**—The treatment is early and free incision, with disinfection of the infected area with tincture of iodine, alcohol, phenol, permanganate of potash, etc. After free incision, continuous irrigation or continuous immersion in an antiseptic water bath is very proper treatment.

## SAPREMIA

Sapremia is an intoxication produced by the absorption of the products of putrefaction, or decay of a retained material within a more or less closed cavity. After fractures and other injuries and unclean surgical operations, there is thrown out reparative lymph with blood-clot and other disorganized materials, which become infected by saprophytes producing gas and ptomaines. These are absorbed into the lymphatic and general circulation, profoundly impressing the system.

**Symptoms.**—The symptoms begin from twenty-four to thirty-six hours after the time of the accident or operation, the first one being a slight chill or rigor followed by eleva-



tion of temperature, not usually very high. There is dryness of the tongue with coating, flushed face, pyrexia, headache, malaise and mental disturbances. There may be nausea and vomiting, with diarrhea or active purging, or constipation, which is usually found early and may continue until a purgative is administered. The urine contains an excessive amount of solids. The same chain of symptoms may follow the closure of a sinus from an old bone disease, but when the sinus is incised or spontaneously erupts, symptoms disappear in a few hours.

**Treatment.**—The treatment is medical and operative. The former consists in administering a prompt purgative to be followed by diaphoretics and febrifuges. The most important step in treatment is to remove the source of infection. If it is a blood-clot enclosed after an operation, the wound should be opened and cleansed. If it is a compound fracture or injury, free drainage should be secured. When the source of intoxication is removed before parasitic infection occurs and extends to living tissue, symptoms disappear and the patient is restored to a normal condition except for the exhaustion following such intoxication.

Symptoms characteristic of sapremia may follow the extraction of a tooth, the chill and fever being in some instances quite severe. When an unhealthy tooth is filled, or when the operator fails to remove all decay and thoroughly prepare the cavity before filling, there is set up an infection of the root canal, producing typical sapremia symptoms. If drainage is established either by the removal of a filling, when this is the cause, or by making an opening into the center of infection through a root canal or through the alveolus, active symptoms usually subside.

### SEPTICEMIA

Septicemia is an intoxication of the system by bacteria of disease or their products, resulting in constitutional



symptoms, usually appearing with regularity. Sappremia, as above described, disappears generally, but may continue for some days, when the slight intoxication becomes violent. In other cases there may be no symptoms until septicemia is violently ushered in. It begins not earlier than the second, and usually not until the third or fourth day or later, after the injury or operation furnishing the intoxicant.

**Symptoms.**—The first symptom is a chill, which is usually quite severe, lasting for from ten to sixty minutes, depending upon the amount of intoxication. In case a sappremic condition has preceded, even if of a very mild type, there will be loss of appetite, headache and depression. The chill is followed by high temperature, continuous in character throughout the course of infection. Rigors or even chills may recur during the course, resembling malarial chills. As is the case in all continued febrile conditions, the temperature is higher in the afternoon and evening. In many septic infections the entire lymphatic system becomes involved, the glands are enlarged and tender, the vessels thick and swollen, the condition being known as lymphangitis. The lymph nodes continue in this condition until the source of the poison is removed. The spleen is especially involved. The eyes become suffused and the skin red and mottled. The pulse is rapid and loses its usual force. The tongue is coated, the alimentary functions are disconcerted and diarrhea not infrequently develops. The skin, which is hot and dry during the early course, becomes cold and clammy, and the prostration is more marked. The urine is reduced in quantity or may be suppressed entirely. Stupor may pass over into delirium, followed by coma, collapse and death. Such complications and sequelæ as degenerative changes in the kidneys, veins, endocardium, meninges, pleura and the mucous surfaces are not infrequent. The post-mortem changes in the organs are not marked, except the infective enlargement already mentioned. The blood,



instead of coagulating and separating into serum and clot, has the consistency of pine tar and is about the same color or slightly darker.

**Treatment.**—The treatment of septicemia consists in removing the source of the intoxication. First, wounds should be reopened and slough and clots removed, surfaces curetted, irrigated with hot water and thoroughly disinfected with iodine, mercuric chlorid, or some other antiseptic. After the wound is thoroughly cleansed it may be partially closed, drainage being established by the introduction of iodoform gauze or drainage tubes to permit daily irrigation. When gauze is used it should be removed and the cavity repacked every day. A ten-per-cent Lugol's solution of iodine is ideal for daily irrigation.

The general treatment is important and consists in the administration of stimulants and tonics, as tincture of ferric chlorid, or some other form of iron, strychnia, etc. All excretory organs must be kept active by the administration of diuretics, diaphoretics, and cathartics, not to the extent of reducing the vitality, which is already very low, but sufficient to insure healthy action.

### PYEMIA

Pyemia is septicemia to which is added thrombosis, embolism and suppuration in two or more remote parts of the body, developing simultaneously or successively.

In some cases of septicemia there is a tendency to the formation of zoöglea along blood channels, setting up a mycotic phlebitis or thrombo-phlebitis. Portions of a thrombus thus formed are washed from the wall of the vessel and carried along the blood current until they are stopped by the contraction of the channel, plugging the vessel and shutting off the blood supply to the area beyond, resulting in suppuration. When a secondary abscess follows the first, it is known as a metastatic abscess. Small



thrombi may be carried within the heart and cling to the endocardium over the valve or at other points, producing an endocarditis. These abscesses develop from two to six weeks after the onset of the symptoms. Peridental abscesses have been the source of pyemic conditions in other parts of the body.

**Symptoms.**—The symptoms of pyemia are those of septicemia, except that they are more marked and there are recurring chills. The temperature is more vacillating, ranging from 100° to 105° F. The condition is frequently treated as malarial fever, but in the latter the chill returns at the same hour every two or three days, while in pyemia there is no regularity. No parts of the body are exempt, but the most frequent locations for pyemic suppuration are the lymphatic glands, liver, spleen, lungs, the epiphyses of the long bones, and especially the joints and the sinuses of the brain, the symptoms produced being characteristic of diseases of the particular organ or structure involved. A peculiar sweetish odor is emitted from the perspiring skin and is noticeable in the breath. This is observed in no other condition, and is supposed to be pathognomonic.

The *general symptoms* found in the second stage are more pronounced. Hyperesthesia and restlessness are marked. Sweating is extensive. Skin eruptions are common, but there is no uniformity in their appearance. The mouth especially has characteristic signs. The tongue is dry, brown and heavily coated, and sordes accumulate over the teeth and gums. Subsultus tendinum or the twitching of the muscles, so common in typhoid and the infective fevers, is also seen in pyemia.

Post-mortem examination shows that abscesses are usually numerous. When an embolus has been washed away from a thrombus plugging a vessel, the resulting infarction will become necrotic or will suppurate. Joints are found filled with pus. The liver, spleen, kidneys and lungs are sometimes studded with abscesses.



**Differential Diagnosis.**—Differential diagnosis must be made from tuberculous and syphilitic abscess and from acute affections of bones, joints, and glands from other causes.

**Treatment.**—The treatment consists in incising the abscess, irrigating, curetting and otherwise sterilizing the necrotic tissues, establishing and maintaining drainage, and repeating the cleansing process. The constitutional treatment is the same as that given for septicemia.

## CHAPTER III

### SPECIFIC INFECTIONS

#### ERYSIPELAS

Erysipelas is an acute infection of the skin and subdermal structures. In all forms of erysipelas the streptococcus erysipelatis (Fehleisen), which produces the pathological change, is introduced into the tissues by inoculation. This may be done by some instrument or during an injury caused by wood, thorn, nail, etc. In the facial form inoculation may occur in the mucous membrane of the lips or anterior nares.

**Pathology.**—In the superficial form erysipelas presents itself as a dermatitis of scarlet or dark red color. It has a tendency to travel along the lymphatics. The erythema beginning at the point of inoculation extends in every direction, but more rapidly toward the center of circulation. The lymphatics contain cocci and are hyperemic. Phagocytosis goes on at a rapid rate. The germs are rarely found in the blood vessels. When the infection is confined to the skin, suppuration rarely, if ever, occurs. In cellulitis, or when infection extends to the subdermal structures, suppuration is the rule. Extensive areas may be suppurating while the skin remains intact. Cellulitis associated with an amputation of a leg may extend up to the next joint, but seldom beyond that point. The skin will be loose, having underneath a suppurating area with pockets between the muscles and about the vessels and nerves.

The products from such a suppurating surface are



highly virulent, and the surgeon who makes the dressing must be careful that he has no abrasions on his hands or inoculation will result. Erysipelas patients should be isolated from all other cases, and one who has the care of them should not touch a clean case and should never attend an obstetric case.

**Symptoms.**—The principal evidence in the superficial form is a red skin, which is slightly elevated above the surrounding healthy surface. The epithelia are enlarged and the skin is slightly roughened. The dilated blood vessels and hemorrhagic exudate cause the change in color. The margin is uniform and distinct, although it may be irregular. The skin pits on pressure, caused by an edematous condition. The serum accumulates between the epidermis and derma vera, producing vesicles which may coalesce and produce patches of considerable size. They rarely become purulent. The serum escapes and the vesicles collapse, leaving a crust, which eventually desquamates. The most characteristic symptom is the tendency to spread.

*Constitutional symptoms* resemble those in septicemia. There is general debility, headache, loss of appetite and nausea, followed by high temperature. Chill is not always present. The temperature is remittent, fluctuating as intoxication is increased or diminished. In facial erysipelas the symptoms are not very severe, and a fatal termination seldom occurs. In phlegmonous cellulitis the usual symptoms are more marked, and a fatal ending is not uncommon. Septicemia is invariably typically developed in suppurative cases.

When erysipelas extends to the mucous membrane of the mouth and tongue, it is popularly known as "black tongue." It may travel along the nasal cavity to the pharynx and into the stomach and produce characteristic symptoms, or it may extend into the lungs, producing pneumonia.

**Diagnosis.**—This condition must be differentiated from erythemas caused by drugs, and from the eruptive fevers,



and also from the redness of the skin associated with high temperature in continued types of fevers.

**Prognosis.**—In facial and superficial erysipelas the prognosis is favorable, and in many cases there is a tendency to spontaneous recovery, the bacteria apparently having expended their force and died. In the suppurative form the prognosis is grave, and unless the progress of the disease is promptly cut short, death is usually the result in a week or less.

**Treatment.**—Isolation is the first step in treatment. The nurse who assumes immediate charge should be the only person to touch the patient. When the doctor makes an incision, a dressing or an application, he should immediately thereafter cleanse his hands and boil his instruments, or better, never use the latter on a clean case again. Dressings should be burned. The infections are of a most powerful and insidious character and too much care cannot be taken. Medication is principally local, but includes constitutional treatment as well.

*Local treatment* consists of the use of germicides, the principal one being tincture of iodine. In the local, superficial and facial forms, this remedy applied over the red area and several inches beyond will usually prevent extension of the disease, destroying the activity of the existing infection as well. Tincture of iodine should be applied to the skin every four to six hours for forty-eight hours, not only over the infected skin, but for several inches beyond the line of demarcation. Further advance of the infection may thus be prevented. Mercuric chlorid 1 to 1,000 and carbolic acid 1 to 30 are in constant use. Ichthyol has been used to control the activity of the disease. Heat and cold act here as in other infections and are of undoubted value. In suppuration, incisions should be made into every pocket and the parts thoroughly mopped out with tincture of iodine or irrigated with a solution 1 to 3,000 of mercuric chlorid.

*Constitutional treatment* should include all the remedies



required to stimulate the excretory functions. The kidneys, bowels and skin should be made active to eliminate toxins. Nourishment is of great importance and concentrated foods, such as milk, beef tea and artificial foods should be given as freely as they can be taken. Stimulation with ammonia and strychnia helps to carry the patient over the disease. Tincture of iron given in large doses, fifteen to twenty minims every two or three hours, is of special value as a supporting tonic, and is thought by some to have a specific action, particularly in facial erysipelas.

### ACTINOMYCOSIS

Actinomycosis is a very rare destructive disease of men and the lower animals. It is most frequently seen in cattle and is then called "lumpy jaw." It is due to a microörganism belonging to the ray fungus group. It runs a subacute course with gradual involvement of adjacent tissues until life is destroyed. It is accompanied by abscess formation, the bone involved increasing in size as a result of general infiltration of the growing fungus. A macroscopic examination presents a suppurating mass studded with yellowish, gritty particles not found in any other condition. It resembles sarcoma in some respects and is frequently confused with that condition. Throughout the mass are found abscess cavities varying in size. When it involves the skin, pus escapes through many points. Untreated, the infection extends to adjacent parts and to the viscera, the lungs being most frequently attacked, when the sputum will contain the gritty calcareous particles. Almost every tissue of the body and bone of the skeleton may be involved before death arrives.

This disease must be differentiated from sarcoma, syphilis, and tuberculosis. When the disease is suspected, these conditions should be excluded by making a thorough study of the patient's symptoms. The absence of the night pain



of syphilis and the acute pain of sarcoma will do much to exclude these conditions, since there is little, if any, pain, and constitutional symptoms are not marked.

**Treatment.**—Treatment consists in complete extirpation of the disease. If in the skin, it should be cut away, along

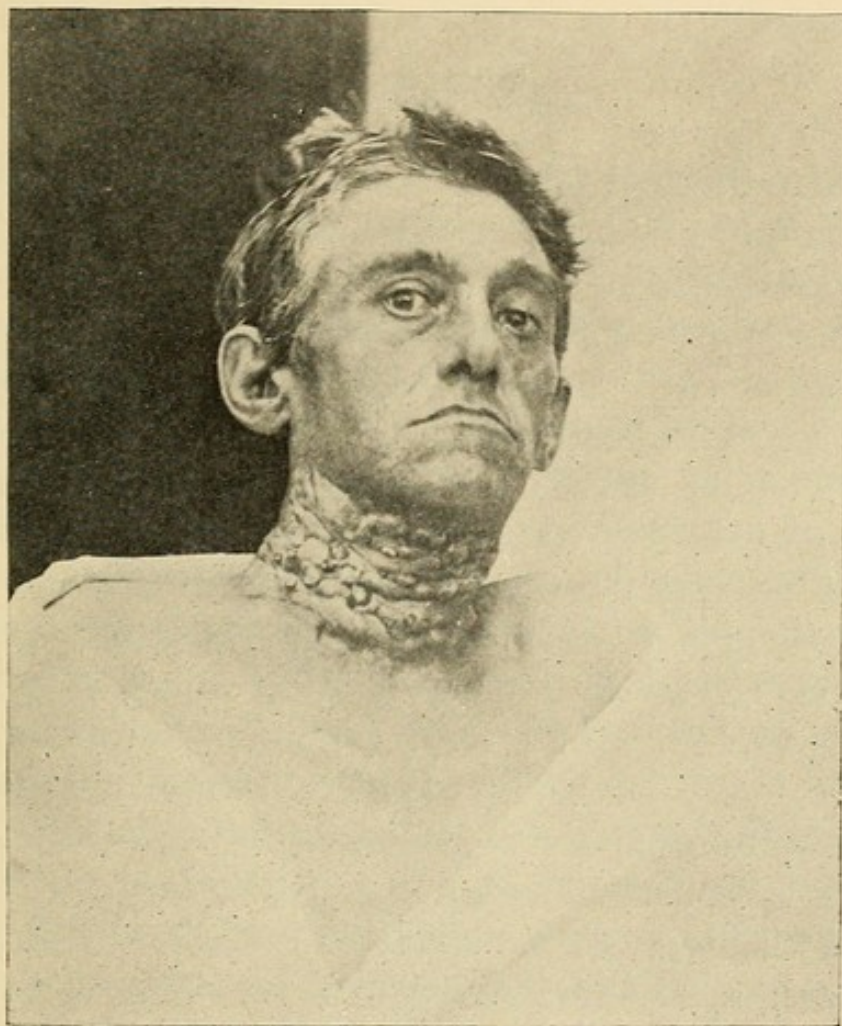


FIG. 1.—ACTINOMYCOSIS. (Dr. J. J. Buchanan.)

with the adjacent areolar tissue. If in the mandible, sufficient of the bone must be resected to include healthy tissue on both sides, even to complete enucleation. The tongue may be amputated beyond the point of infection. In all of these conditions promise of non-return can be made if extirpation has been thorough. When the deeper lymphatics, the viscera or bones of the skeleton are involved, operation is useless except as a palliative measure.



**Illustrative Case.**—The accompanying illustration shows a case of a man, aged about fifty, who was a saddler. He was thought to have been inoculated through the cavity after a tooth extraction. He had a habit of chewing straws which he picked up about his saddlery shop, and which may have been in the mouth of a horse or cow suffering with the same disease.

## TETANUS

This is a general disease, a result of the infection of a wound by a specific microörganism (the bacillus tetani), and is characterized by tonic contractions of one or several groups of muscles, with periodic exacerbations.

**Etiology.**—The bacillus of tetanus is slender and rod-shaped. Each of the bacilli forms a single, large-sized spore, usually at one end, giving to the organism the appearance of a drumstick. These spores are very resistant to chemical germicidal agents and *to conditions of dryness. They are even able to survive boiling for five minutes.*

The organism is a perfect anærobe, is very widely distributed in nature, and is easily found in manure and stable refuse, and in garden earth. It may often be obtained, also, in pus from the wound of infection in patients who have the disease, but it does not invade the body generally. Such wounds are usually small, unhealthy, and lined with necrotic tissue from which the bacillus may be isolated, as well as other organisms (pyogenic or putrefactive) with which it is usually associated.

**Symptoms.**—The symptoms are a stiffness in the muscles of the lower jaw and neck, difficulty in swallowing, and occasionally stiffness of muscles of other parts of the body. The condition develops rapidly with a sudden rise of temperature, retention of urine, profuse sweating, especially as convulsions develop, and extreme pain in the parts involved. There is distortion of the muscles of expression and drooping of the eyelids. The symptoms are fully de-



veloped in twenty-four hours and terminate fatally in forty-eight hours. *Differential diagnosis* must be made from strychnia poisoning.

**Treatment.**—The treatment includes the introduction of anti-tetanic serum, cleansing of the wound with antiseptics, and the administration of diaphoretics and cathartics.

## HYDROPHOBIA

Hydrophobia is an acute infective disease following the bite of a rabid animal. The analogies existing between hydrophobia and other diseases of undoubted bacterial origin justify the belief that this disease is due to a specific organism, although this has not yet been demonstrated. The *disease usually* follows the bite of a dog. The virus appears to be communicated through the saliva of the animal, and the disease is most likely to develop when the patient is infected on the face or some other uncovered part. Only about one person out of three bitten by animals proved to be rabid suffers with the disease. The inoculation period averages about forty days, but may vary from a fortnight to eight months.

**Symptoms.**—The symptoms are general malaise, chills and giddiness, with involvement of the muscles of deglutition and respiration. There is a sudden catch in the breathing due to a spasm of the diaphragm. Occasionally there is a hiccough, which is considered by the laity to resemble the bark of a dog. There is also inability to swallow food. The temperature is elevated, pulse very rapid and intermittent. The urine may contain sugar and albumin.

**Prophylaxis.**—The bite of an animal suspected of being rabid should be cauterized at once by means of the actual or Paquelin cautery, or by a strong chemical escharotic, such as pure phenol, after which antiseptic dressings are applied. It is, however, to Pasteur's preventive inoculation that we must look for our best hope of averting the onset of symp-



toms. "It may now be taken as established that a grave responsibility rests on those concerned if a person bitten by a mad animal is not subjected to the Pasteur treatment" (Muir and Ritchie).

**Treatment.**—When the symptoms have once developed, they can only be palliated. The patient must be kept absolutely quiet and free from all sources of irritation. The spasms may be diminished by means of chloral and bromids, or by chloroform inhalation. There is great difficulty in feeding the patient, and administration may necessarily be by the rectum.

### ANTHRAX

Anthrax, sometimes called malignant pustule, is an acute infectious disease caused by an infection by the anthrax bacillus, a rod-shaped organism, forming spores on the outside of the animal body. It attacks both animals and man, but most frequently the domestic herbivora. It is transmitted from animal to man by inoculation, by respiration and through the food. It is also thought to be transmitted by flies.

The period of incubation is from three to six days. The pustule develops on the skin as a vesicle containing a pinkish to blue fluid, swelling with a purplish or reddish base to the ulcer. The vesicle bursts and a crust is formed as a result of the drying of the secretion. The ulcer varies from the size of a pea to that of a ten-cent piece. The swelling and redness extend into the various parts of the skin. There is burning, itching and tenderness. The disease extends to the lymphatic glands and may extend to the deeper structures of the body, such as the abdominal viscera or the lungs, resulting fatally.

**Diagnosis.**—Diagnosis is based upon an examination of some part of the ulcer and the discovery of the anthrax bacillus.



**Treatment.**—The treatment consists in the administration of Selavo's serum. Subdermal injections of phenol and other antiseptics have yielded satisfactory results.

Other specific infections, which are of little interest to the dentist, are glanders and leprosy. They will not be considered here.



## CHAPTER IV

### GENERAL TUBERCULOSIS

Tuberculosis is an infective inflammation dependent upon the action of the bacillus of tuberculosis. It is the most frequent of all diseases, destroying more lives every year than any other infection, the number being estimated at about twenty-five per cent. of the total number of deaths from all causes. Its ravages attack every tissue in the body of man and in many of the lower animals. Its most common form is tuberculous phthisis. Next in frequency it attacks the skeleton, principally of children, in the form of hip, knee and other joint diseases, and spondylitis, or Potts' disease of the spine. The skin is a common seat of destruction, showing the disease in the form of lupus and other ulcerations. All of the conditions formerly called scrofulous are now considered either syphilitic or tuberculous.

**Etiology.**—The etiological features are: (a) Injury of a slight nature; (b) introduction of the bacillus in the area of injury; (c) reduced resistance as result of previous sickness or dissipation; (d) predisposition of heredity.

The bacilli of tuberculosis are rod-shaped organisms, often occurring in pairs, arranged end to end, but not attached. The bacillus may appear straight or more or less curved and may branch. It is found in man, cattle and fowl, and is the specific cause of tuberculosis in its various forms. The organism may be said to occur in two forms, "human" (which is described above) and a bovine bacillus. The latter is shorter and thicker than the human germ, and does not exhibit the curved or branching form which is common in the human.



The organism multiplies only in the body and excreta of tuberculous individuals. The sputa or other excreta containing the bacillus may dry and retain the bacillus in a dormant state which is still potential. The bacillus is also found in the lesions in all parts of the body.

*Avenues of entrance.*—Infection occurs by introduction into the blood by one of the following routes: (a) From ulcerating tonsils; (b) through the lungs; (c) from the mouth or alimentary tract; (d) through wounds of the skin; (e) secondary to other foci in the lungs, glands, etc. Probably bacilli are in the blood of healthy individuals at all times.

**Pathology.**—A typical tubercle is a non-vascular, grayish neoplasm, composed of: (a) a giant cell in the center, surrounded by (b) epithelial area upon the periphery of which are found (c) leucocytes or small round cells, all of which are held by (d) reticulum. The giant cell may be absent and it may also be found in bone marrow, granulation tissue, sarcoma, gummata, etc. The epithelial cells may become caseous in the process of healing, or as fibroblasts they may be converted into fibrous tissue. Leucocytes are found at the periphery, outlining the field of invasion, and are barriers set up to prevent extension of the disease into surrounding healthy tissue.

Bacilli are found principally in the giant cell and are projected into the epithelial area, but are never found in the leucocytic zone. A tubercle, being without vessels, soon begins to degenerate at the giant cell, becoming fatty, necrotic, caseous, calcareous, or liquefying, forming a "cold abscess." Several tubercles may undergo the same changes simultaneously or successively and coalesce, forming a mass of considerable size. The course is essentially chronic, but it may be subacute, and rarely it is acute. In bone disease the course of destruction and repair has been known to extend over one to two decades without at any time endangering life. Tuberculous glands may remain enlarged for



many years, and periodically, as at certain seasons, the process may become active. The primary focus may be in any structure, and secondary or many foci may develop in other tissues in any part of the body remote from the original infection. The primary focus is usually circular and the secondary usually triangular or conical, or an infarction.

So positively has its infectibility been established that those afflicted with lung infection are isolated as are cases of smallpox, scarlatina, cholera, etc.

Frequent seats of tuberculosis are the lungs, lymphatic glands, bones and joints, mucous membranes of larynx and intestines, serous membranes, prostate, testicle, ovaries, Fallopian tubes, kidneys, uterus, suprarenal capsules, brain, liver and spleen. In some of the latter sites it is usually secondary.

According to Park, the following fates await a miliary tubercle: (a) absorption; (b) encapsulation; (c) cheesy degeneration; (d) calcareous degeneration; (e) suppuration.

**Treatment of Tuberculosis.**—General treatment does not differ from that outlined for tuberculosis of the lungs. Outdoor life in pure air is the first and principal step in treatment. Air of the mountains and the sea contains no germs. In densely populated cities the air contains every variety of bacterium. Forced feeding with concentrated foods, such as milk and raw eggs, should be faithfully carried out. From a quart to a gallon of milk and from three to ten raw eggs daily are not uncommonly tolerated by these patients.

Repair is from within or from the blood, and when its richness can be increased, the protoplasmic cells found in the zone of invasion have a greater resistance, hence the bacilli which are advancing into newer areas to destroy tissues are checked.



## CHAPTER V

### THE VENEREAL DISEASES

The venereal diseases are contagious affections usually transmitted during sexual intercourse, but they may be acquired innocently when some intermediate object serves as the carrier of the virus.

The three venereal diseases are gonorrhea, chancroid, and syphilis.

#### GONORRHEA

Gonorrhea, in the male, is an intense urethral inflammation developing in from three to ten days after infection by the specific organism (the gonococcus or diplococcus of Neisser) and characterized by a profuse discharge. It is the most frequent of the venereal diseases and is essentially of sexual origin. Other mucous membranes are susceptible to the infection—the eye, rectum and anus. Cases have been reported of gonorrheal infection of the mouth and nose, but proof is not conclusive that these mucous membranes are susceptible to infection by the gonococcus.

The urethra is the primary site of the infection in the male, and the disease may extend to the bladder, ascending by the ureters to the kidneys (very rarely), or may involve the sexual organs—the prostate, seminal vesicles, the vasa, epididymes and testes. In the female the vaginal and cervical mucous membranes are affected. The disease may involve the urethra and bladder. When it spreads to the uterus, tubes and ovaries, it becomes a serious affection and often it is not curable except by removal of the diseased



organs by operation. Gonorrhea is responsible for a large percentage of the sterility in women and necessitates a majority of the operations done upon the female sexual organs.

**Complications.**—The complications which may arise during the course of gonorrhea are balanitis, phimosis, paraphimosis, folliculitis, urethral fistula, Cowperitis, prostatitis, vesiculitis, epididymitis, orchitis, and urethro-cystitis. Enlargement of the inguinal glands (bubo) occasionally occurs (especially in the uncleanly), but seldom progresses to suppuration. Stricture of the urethra results from the long continuance of gonorrhea. Systematic infection is manifested by involvement of the joints, muscles, tendon sheaths and bursæ. From the dentist's standpoint, gonorrheal arthritis of the temporo-maxillary articulation, producing ankylosis, is of interest.

Gleet is the term applied to a chronic muco-purulent discharge produced in certain localized areas of the mucous membrane of the urethra which have not healed. A gleety discharge is contagious if it contains the gonococcus.

*Chronic gonorrhea* is usually due to one or other of its complications. The gonococcus may remain latent, giving no symptoms which manifest its presence for years, and again start up acute inflammation or be transmitted to another and produce a virulent infection.

**Treatment.**—The treatment of acute gonorrhea consists of cleanliness, rest, the administration of urinary antiseptics and balsamics, the injection into the urethra of remedies which will inhibit the growth of the gonococcus (especially the organic silver salts—argyrol, protargol, etc.) and irrigation of the urethra by the Janet method. In chronic gonorrhea, irrigations, instillations and the use of sounds and dilators are called for. Thorough treatment of the acute disease to prevent its extension backward along the urethral canal should always be undertaken to insure early recovery and prevent the serious complications which involve the



integrity of the sexual organs and the possibility of latent infection.

### CHANCROID

The chancroid (or soft chancre) is a local contagious venereal ulcer caused by the bacillus of Ducrey. It has no period of incubation, but clinically it manifests itself about the third day after inoculation. It is rarely acquired except by intercourse. It is most commonly seen in hospital practice because of the uncleanly and careless habits of these patients. The pus from the sore is capable of almost indefinite auto-inoculation, and, as a result, the lesions are usually multiple.

It begins as a pustule or ulcer. The edges of the ulcer are ragged, punched-out or undermined and surrounded by an inflammatory areola. The discharge is free, thick and creamy. The floor is rough and uneven (worm-eaten). There may be a thick moist scab. The base of the sore is soft and pliable from inflammatory edema (not indurated).

Adenitis or inflammatory bubo is a frequent complication. The inguinal glands are involved when the lesion is genital, that is, the glands in closest anatomical relation—to which the lymph vessels leading from the infected area lead. The adenitis is usually unilateral. A hard, tender lump develops, which increases in size and becomes adherent to the overlying skin. Fluctuation develops, and unless the lump is incised it ultimately ruptures.

**Treatment.**—Treatment consists in surgical cleanliness and the use of mild antiseptics or cauterizing. Antiseptic powders may be used when the discharge is not profuse. Wet dressings are indicated when the secretion is profuse. The suppurating bubo should be incised, disinfected, and treated as an abscess.

### SYPHILIS

Syphilis is a specific constitutional disease transmitted by heredity or acquired by infection. In the acquired form



it is characterized by the appearance, at the point of inoculation, of a primary lesion, followed in the usual course by eruptive lesions of the skin and mucous membranes, and may ultimately produce symptoms involving one or many of the organs of the body.

In 1903, Metchnikoff and Roux successfully inoculated anthropoid apes. The disease can be transferred from one animal to another, and each is immune to further inoculation.

In 1905, Schaudinn and Hoffman demonstrated a micro-organism (the *Spirochæta* or *Treponema Pallida*) to be of constant occurrence in syphilitic lesions. Their claim that it is the specific infecting organism has since been abundantly verified. The spirocheta is an extremely delicate thread twisted in a spiral form. The spirals are of uniform width and depth. Their ends are sharp and tapering. They are four to ten microns in length. (The red blood corpuscles are 7.9 to 9.3 microns.) They are mobile organisms capable of progression, rotation and bending and twisting. Dr. Noguchi has recently succeeded in growing the *Spirochetes* on artificial media. They lose their virulence when heated to 51° C. for one hour or to 60° C. for one-half hour. Secretions containing the spirocheta soon become innocuous. The spirocheta is found in the secretions from chancres and mucous patches, in the enlarged glands, in the skin lesions, in the blood (several positive findings reported), and in nearly all the organs and tissues, secretions and excretions of the congenitally syphilitic. The semen of a syphilitic in the secondary stage has produced the disease in an inoculated monkey, but in others of the normal secretions in the acquired form of the disease the search for the spirocheta has been negative.

Cover glass preparations can be stained by various methods to show the spirocheta and by the use of dark field illumination it can be seen through the microscope in its living state and its movements observed.



The Wassermann reaction is a blood test which can be made only by competent laboratory workers. Its technique does not concern us. The specificity of this reaction has been questioned, but a positive result is obtained in a large majority of syphilitic patients. In the absence of symptoms this test may give evidence of the presence of the disease and throw light upon many obscure conditions of doubtful etiology. It is being used largely as evidence of the result of treatment or test of cure.

**Modes of Contagion.**—There are four modes of contagion: *Direct*—by contact of an abraded surface with an infectious lesion of a diseased person, as in intercourse, kissing, etc.; *mediate*—when some intermediate object serves as the carrier (for this reason all instruments used should be thoroughly sterilized, preferably by boiling, before being again used, and dental instruments which cannot be boiled should be discarded); *inheritance* from one parent or both; *Choc-en-retour*, syphilis by conception, the infection of a mother conceiving to a syphilitic father. She is infected through the placental circulation and does not manifest the primary lesion.

According to Colles' law, a child begotten by a syphilitic father and born of an apparently healthy mother cannot infect her. Such a mother is immune to infection from being herself syphilitic (latent), or the toxins absorbed from the infected fetus may stimulate in such a mother the formation of immunizing bodies. The majority of such mothers give a positive Wassermann blood test.

**The Stages of Syphilis.**—There are six stages of syphilis, as follows: 1. *Primary incubation*, the time between exposure and the appearance of the primary lesion, averaging about twenty-one days, and varying from two weeks to forty days or more. 2. *The period of primary symptoms*, the time of development of the chancre and its associated adenitis. 3. *Secondary incubation period*, or the time elapsing from the appearance of the primary lesion until



the occurrence of the secondary symptoms, of an average duration of six weeks. 4. *Period of secondary symptoms*, during which the disease is manifested by fever, anemia, neuralgic pains, alopecia, and the superficial syphilides of the skin and mucous membranes. 5. *Intermediate period*, or the time of freedom from symptoms between the secondary and tertiary stages. Tertiary lesions may follow directly upon the secondaries, or they may never develop. 6. *Period of tertiary symptoms*, characterized by the development of gumma or gummatous infiltrations of various organs and structures.

**The Primary Lesion.**—The chancre (initial lesion or sclerosis, hard or infecting chancre, indurated neoplasm, Hunterian chancre) is the lesion occurring as the first manifestation of the syphilitic poison at its point of entrance into the body (at the site of inoculation). It may be on any part of the body—genital or extragenital (elsewhere than on or near the genital organs). It usually develops about the twenty-first day after exposure. Induration is its most characteristic feature. It consists of a sharply circumscribed hardening due to cellular infiltration of the tissues beneath the lesion and extending wide of its margins. The induration is best palpated by pinching, with the fingers placed beyond (or wide of) the superficial margins of the sore. It develops in from five to ten days after the appearance of the chancre and is at its maximum in about two weeks. An adenitis (bubo) of the anatomically associated lymph glands (to which the lymph vessels draining the area of the lesion pass) develops usually by the tenth day. A number of glands are usually easily palpable. Each gland is felt as a rounded, smooth, hard nodule, freely movable beneath the skin. The glands may be slightly sensitive, but are not acutely inflamed and do not suppurate.

The *chancrous erosion* is the commonest form of the initial lesion (75 per cent. of all). The epidermis is exfoliated, and the true skin exposed but not destroyed (not an



ulceration). The surface is polished, eroded, or raw-looking, and a gray, false membrane may cover its central part. It may be level with the surrounding surface or may be slightly elevated. A red areola surrounds the lesion. The discharge is scanty and serous or sero-purulent. The *Hunterian chancre* or *chancrous ulceration* is a crater-like or funnel-shaped excavation. The edges are not abrupt, punched-out or undermined, but slope gradually towards the center. Other forms (indurated papule, silvery spot, herpetiform chancre) are less common than these forms and only occasionally seen. A chancre may heal before the secondary symptoms appear or may persist as an indurated area for months afterward.

In the oral cavity the initial lesion may occur on the lips, the tongue, the mucous membrane of the buccal cavity, the palatal arches, and the tonsils. The lymph glands (submental and submaxillary) become enlarged within the second week and are usually sensitive and give some discomfort. A chancre of the lip is usually a large, prominent, indurated nodule, with eroded raw surface on the vermilion border, commonly quite painful. A chancre of the tongue is usually seen on the dorsum or anterior portion of the border. It is likely to be quite large, and the surrounding tissues may be infiltrated widely by the lymphangitis. Induration is of cartilaginous hardness and subhyoid adenitis develops. Chancre of the gum is exceedingly rare. When occurring on the tonsil, it is likely to be mistaken at first for an ordinary sore throat. It is, however, unilateral. The tonsil is usually swollen and its surface flat, eroded, or ulcerated. Palpation reveals marked induration. Adenitis of the lateral cervical glands develops.

Figure 2 shows the finger of a dentist who had been doing considerable extracting for some time. He presented himself to the author with a small eroded sore near the nail root. This lesion increased in spite of local treatment,



until a typical chancre developed, as the photograph shows. The patient could not discover the source of the infection. The finger was evidently inoculated during an extraction, probably having been injured by the forceps or a tooth, where the *Spirochæta pallida* was present in the mouth, either in the blood or the secretion from a mucous patch whose presence was not suspected. Two other dentists have come under observation, similarly inoculated.

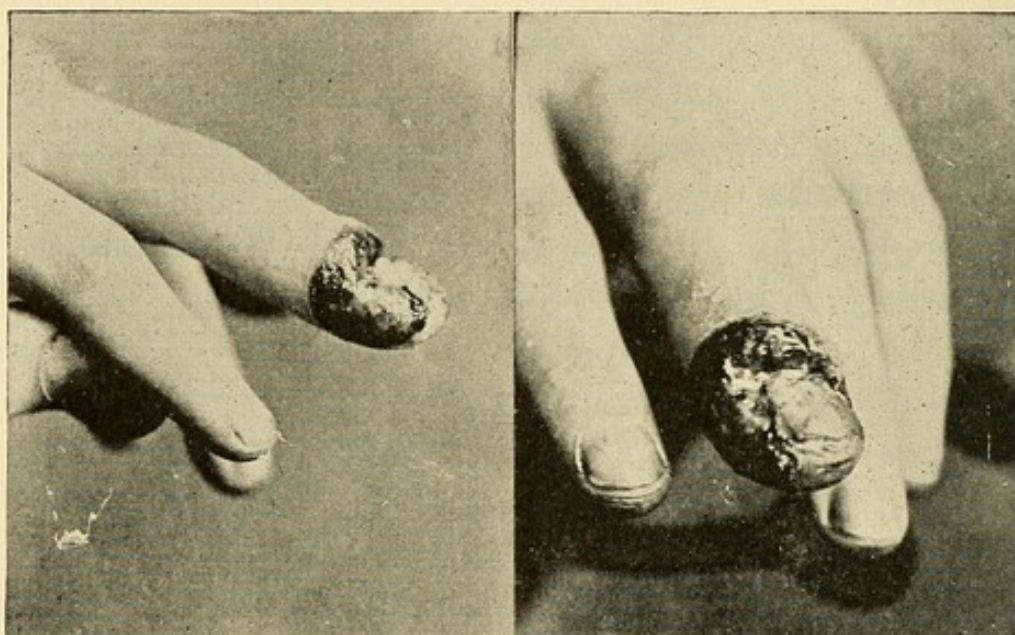


FIG. 2.—INITIAL LESION ON THE FINGER OF A DENTIST.

*Diagnosis* of chancre is based upon the following considerations:

1. Confrontation. Examination of suspected partner.
2. Incubation. Chancre develops after ten days, usually about the twenty-first day, after exposure. It may be as late as forty days or more.
3. Character of lesion. Seventy-five per cent. are erosions.
4. Induration. One of its best diagnostic features. If sore has been cauterized a similar induration may develop.
5. Adenitis. An almost constant symptom.
6. Presence of *Spirochæta pallida*. Detected by microscope, by dark field illuminator, or by staining methods.



7. Secondary symptoms. Their development is conclusive proof.

8. Wassermann reaction. Not always present before secondary symptoms develop.

**Secondary Symptoms.**—The secondary symptoms are: Alterations in the blood. An essential anemia in ninety-five per cent. of the cases.

Erythema of the fauces. The soft palate and pillars of fauces are of uniform, dull red color. A sharp line of demarcation exists between healthy and affected parts.

General glandular enlargement. Evidences of systemic infection. The lymph glands other than those in anatomical relationship with the chancre become enlarged, firm, hard, freely movable under the skin, and are painless. Pea to chestnut in size. The post-cervical, epitrochlear, suboccipital, supraclavicular, submaxillary, submental and pectoral can be palpated.

Syphilitic fever, developing a week or ten days prior to eruptions. This is not frequently seen.

Pains: Headache, neuralgia, osteocopic (bone-tearing) pains, arthralgia and rheumatoid pains.

Alopecia. Occurs as three forms—complete, patchy baldness and general thinning of the hair.

The syphilides appear, on an average, about six weeks after the appearance of the chancre.

These do not give subjective symptoms (are painless and do not itch), are of rounded contour, of raw ham or copper color, and the early eruptions are usually symmetrical and polymorphous (several forms of eruption coexist).

*Forms of Syphilides:*

1. Erythematous (Macular, Roseola).
2. Papular.
  - a. Acuminate. Large. Small.
  - b. Lenticular. Large. Small.
  - c. Moist Papules (mucous patches).
  - d. Papulo Squamous.



3. Vesicular.
4. Pustular.
  - a. Small Acuminate.
  - b. Large Acuminate.
  - c. Small Flat.
  - d. Large Flat.
5. Pigmentary.
6. Bullous.
7. Tubercular.
8. Gummatous.

The commonest form of the secondary skin eruptions is the *macular*. These commence as irregular, rose-red blotches which at first disappear on pressure, but later, when pigmentation develops, leave a brownish stain. They commence on the sides and front of the chest and abdomen and extend to the extremities. They are rarely seen on the face. The *papular* syphilides may coexist. These latter, when occurring early, are symmetrical and generalized, but are grouped on limited areas when occurring late. They vary in size from a pin-head to one-half inch in diameter and from light crimson to a dull copper color. They project above the skin (elevations) and may scale at the top or be surrounded by a collarette of scales. They are firm to the touch, and the surface is shiny.

**Tertiary Symptoms.**—Tertiary manifestations may develop at any time, even years, after the disappearance of secondary symptoms. They appear as infiltrations, involve the deeper tissues of the body, as the visceral and skeletal systems, and are destructive, leaving cicatricial tissue. They differ from secondary lesions, which are superficial, not infiltrative or destructive and leave slight or no scar.

Tertiary syphilides, as *cutaneous gummata* (syphilitic lupus), are circumscribed infiltrations of the skin, involving its entire thickness and projecting above its surface. The surface is flat or rounded and the borders are sharply



defined. When they disappear by resolution pigmented cicatrices remain; but when ulceration occurs thick scabs may form and the cicatrices cause disfigurement. *Subcutaneous gummata* (gummatous syphilides) are circum-

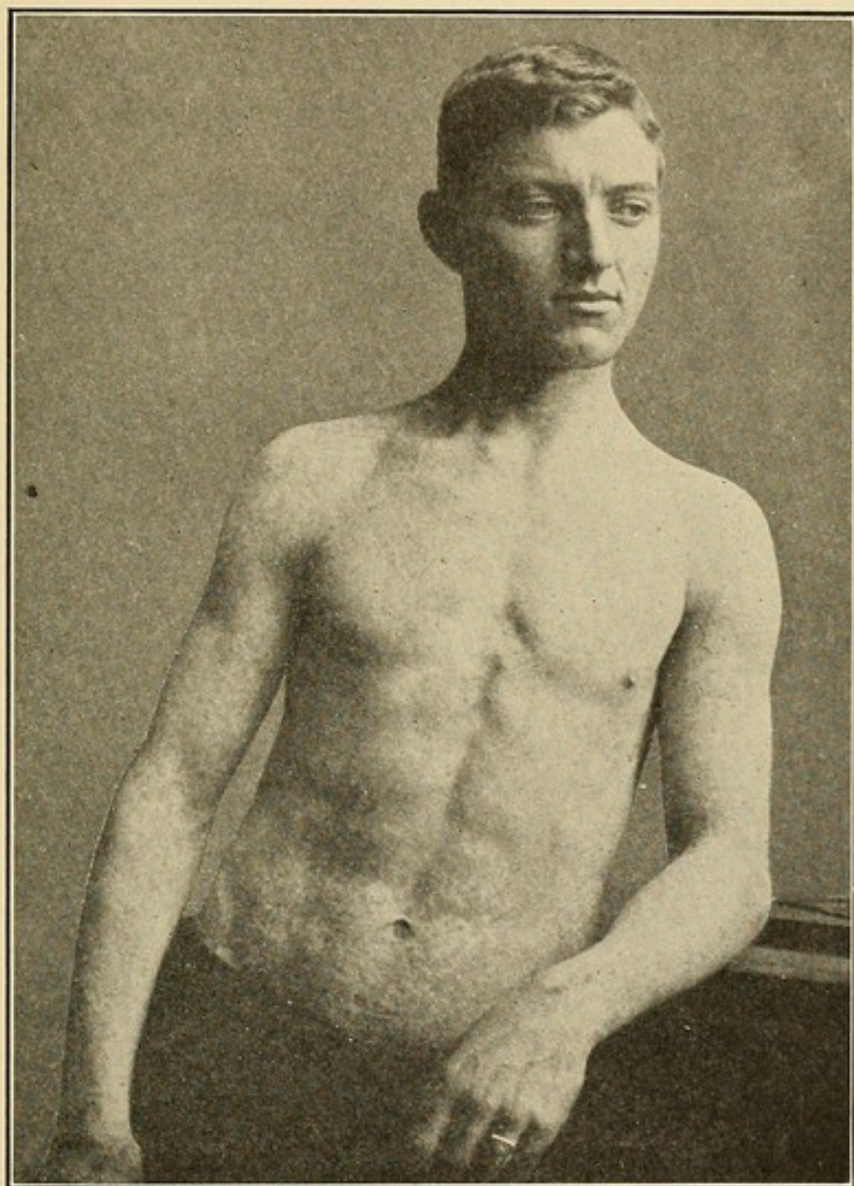


FIG. 3.—MACULAR SYPHILIDE. The early eruption of secondary syphilis.

scribed firm nodules developing in the subcutaneous connective tissue, not primarily involving the skin, which is readily movable over them. At first they are appreciable to the touch only, but they increase in size, producing prominences, and become adherent to the skin. Syphilides of this character often extend to the underlying structures, fascia, periosteum, bone, cartilage and tendons.



Gummata appear in three forms: a single tumor, a group of nodules, or a diffuse infiltrated patch. A gumma is a true tumor or granuloma, which permanently affects the area invaded, whether it disappears by absorption or ultimately ulcerates, as is its tendency. A gumma may take weeks or months to develop and is painless. When it reaches its full size, fluctuation is felt. If lanced, a gummy

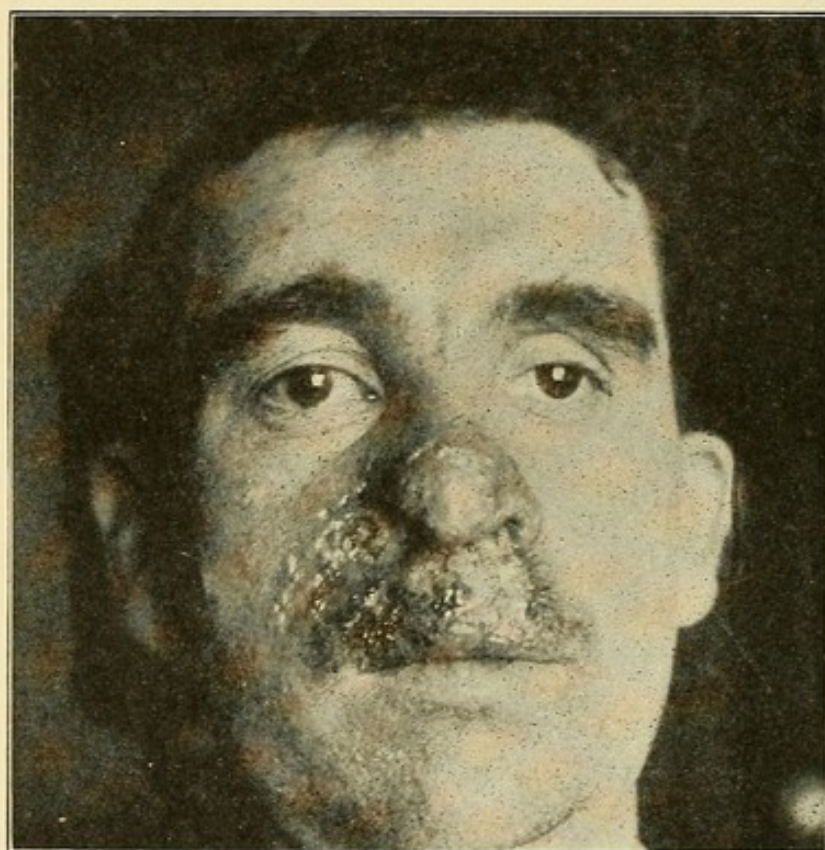


FIG. 4.—SYPHILITIC ULCERATION OF THE FACE AND NOSE. Most characteristic of tertiary syphilis in neglected cases. (Dr. Geo. C. Johnston.)

puriform substance and some blood exude. Absorption may then occur or ulceration may take place from central softening (coagulation necrosis). When a gumma involves the skin and ruptures through, there is no abundant discharge as from an abscess, but the content is adherent by its deeper portions to the subcutaneous tissues, and is thrown off subsequently in the form of sloughs. The ulcer is sharply defined, punched out and surrounded by a dark, indurated hyperemic areola. If, in the cutaneous gumma,



resolution occurs before softening, a slightly depressed area of nearly normal skin remains. If softening has occurred, the depression is marked and the skin is transformed into scar tissue. When ulceration has occurred the cicatrix is depressed, thin, and of pearly white color, and when the ulceration has been deep the scars are much depressed, at first pigmented, and later white and adherent to the underlying structures.

*Arthralgia* is an early manifestation in the joints. Pain is usually worse at night. *Synovitis* (hydrarthrosis) is an early symptom of syphilis of the joints and may be either mono- or poly-articular. There is no febrile disturbance, and pain is not severe. *Tertiary arthritis* is due to gummata and gummatous infiltration of the joint structures, giving impairment of motion, muscular atrophy, and pain.

In *syphilis of bones*, trauma is an evident etiological factor. The facial and cranial bones, clavicle, sternum, tibia, and ulna are favorite seats of the disease. Pain is usually more severe at night. These are nearly always tertiary or late manifestations. In osteoperiostitis there occurs a cellular infiltration on the deeper layers of the periosteum which invades the bone substance, producing elevations (nodes). These nodes are not adherent to the skin, are tender, elastic, well-defined, and sensitive to pressure. When more than one node develops the diagnosis of syphilis is favored, since there is but one node in osteoma, osteosarcoma, tuberculous abscess, and other affections. Many bones may be simultaneously affected. This process may include the entire diaphysis, one-half of the mandible or external surface of the maxilla or a considerable portion of the alveolar process. If treatment does not effect resolution, the skin may become reddened and adherent, and ulcerate. Necrosed bone is cast off and an adherent cicatrix remains. Exostoses may result from new bone deposit. When such nodes develop on the inner tables of the cranial



bones, pressure upon the brain, cord, nerves and vessels may give rise to paralysis, convulsions, neuralgia, and edema. In rarefying osteitis the bone substance is invaded through the Haversian canals and the bone trabeculae are thinned and absorbed. The bony substance is replaced by new cell formation. Formative osteitis may supervene with resulting eburnation. In gummatoses, osteoperiostitis and osteomyelitis, the cellular infiltration takes the form of a gumma, tending to become caseous. If the bone is near the surface, ulceration occurs through the skin, resulting in an adherent scar. Spontaneous fracture of a long bone may result from absorption of its bony substance. When the medulla is involved (osteomyelitis) caries or necrosis and perforation externally or internally result (especially in the frontal and parietal bones of the skull). In bone manifestations X-ray examinations reveal areas of greater or lesser density than the normal.

*Dactylitis* is an affection of the fingers and toes. The process may begin in the soft tissues, but more commonly starts as a periostitis or osteomyelitis. The course is chronic, the integument swollen and tense, but not inflamed nor painful. Absorption of the gummatous deposit may shorten the phalanx, and either a false joint result or, rarely, ankylosis.

In the *muscles*, as a secondary symptom, occur rheumatoid pains, but there is no permanent structural change. The muscles are subject to tertiary changes (gumma and gummatous infiltration), which result in contraction or softening and ulceration. Ninety-five per cent. of all muscle tumors are of syphilitic origin.

The various *organs* of the body are subject to the disease. The liver is more commonly affected than any other of the internal organs. Syphilis of the kidneys is not uncommon. The eye is frequently affected in one or other of its structures. The heart is rarely involved, but myocarditis, endocarditis and pericarditis do occur. The arte-



ries are affected, particularly those of the brain. Syphilis predisposes to arterial sclerosis.

Late lesions of the *nervous system* are the most serious manifestations of the disease. The symptoms may be produced by pressure from affection of the bones, diffuse infiltration or multiple gumma of the meninges, thrombosis, rupture or aneurism from arteritis or by gummata. Cerebral involvement is usually manifested by headache, vertigo, nausea, vomiting, epileptic convulsions, paralysis or hemiplegia. Among the spinal symptoms are pain, hyperesthesia and anesthesia, sensory and vasomotor disturbances, paralysis and atrophy. The parasyphilitic diseases (post-syphilitic degenerative processes) are locomotor ataxia (tabes) and paresis. The presence of syphilis in the system predisposes to these degenerations, but the process is not pathologically syphilitic.

**Inherited Syphilis.**—Inherited syphilis may be transmitted by the father at the time of insemination, by the mother at the time of conception, or later from the mother by the placental circulation (post-conceptional). There may be abortions, miscarriages between the fourth and seventh months, or later healthy children. Five years after the initial lesion syphilis ceases (as a rule) to be transmissible from the father, but a syphilitic mother may transmit the disease for a much longer time.

A syphilitic child is usually small, undeveloped, and has an aged appearance. The skin is loose and wrinkled and of a coffee-colored tint. The nails are ill-developed. The bullous syphilide (pemphigus) is one of the earliest and most marked symptoms. Vesicles containing serous fluid form, the contents become milky or yellowish and sometimes bloody, then burst; greenish-yellow scabs form with ulceration beneath. On the mucous membranes we find excoriations, mucous patches, fissures, and ulcers. Ulcers of the gums may induce caries or necrosis of the bones. A swelling and redness (the snuffles) of the mucous membrane of



the nose are early and marked symptoms. There is a serous discharge which becomes purulent, sanious, and of offensive

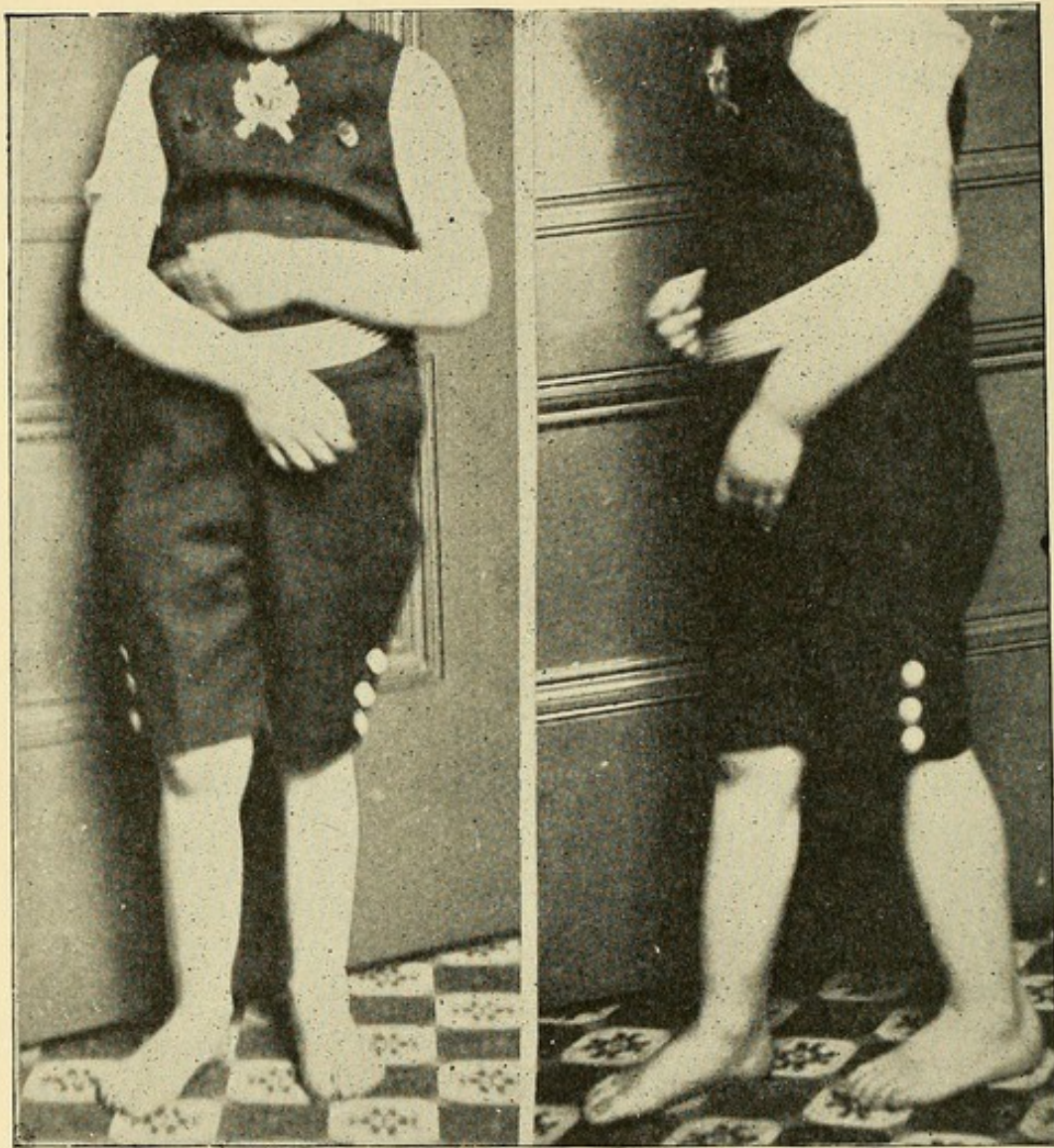


FIG. 5.—DIFFUSED SYPHILITIC PERIOSTITIS OF HEREDITARY ORIGIN. Photographs of a boy eight years old, who has enlargement of both tibia, right radius and left ulna. The case was confounded with rachitical enlargement of these bones. Tuberculosis, hypertrophic osteitis and pyemic periostitis were all considered, and it was only after the case had been placed under specific medication that the diagnosis was made absolute. The interesting feature of the case is that there was little, if any, pain, but a slight tenderness, and the child continued about at play and enjoyed the usual health and freedom of conduct. Iodid of potash treatment was pursued and, in the course of several months, the hypertrophic conditions disappeared and there was no return for 10 years, when other bone lesions developed and required treatment.

odor. Crusts form, beneath which are excoriations and ulcers. Breathing becomes difficult and noisy. The catarrh



may extend to the larynx, making the voice hoarse, husky and stridulous. Otitis media develops painlessly, giving no symptoms except a purulent discharge. Deafness (labyrinthine) develops rapidly and is complete. Iritis and interstitial keratitis are frequent. The upper permanent central incisors have crescentic notches at their free edges (Hutchinson's teeth). The enamel is deficient in the middle of the notch (the bevel being at the expense of the anterior surface). As the teeth wear down with use, the characteristic appearance does not persist beyond about the twenty-fifth year. Other irregularities of the teeth occur, but are not so constantly found. Osteochondritis (exclusively a syphilitic lesion) consists in an infiltration of the diaphysis of a bone at its junction with the epiphysis, producing a swelling at this point. Degenerative changes may occur and ulceration of the skin result. Separation of the diaphysis from the epiphysis may occur, producing "syphilitic pseudo-paralysis" of the newborn. This process begins *in utero*. Periostitis occurs later, and the changes are hypertrophic, producing osteophytic growths (nodes and bosses). The liver, when affected, is enlarged and hardened. The *Spirochæta pallida* is found in greatest numbers in the liver of the syphilitic fetus dead of the disease.

**Prognosis.**—The prognosis of syphilis is good if the diagnosis is made early and efficient treatment instituted. Constitutional disorders, bad hygiene, dissipation, alcoholism and overwork account in great measure for the virulence of the disease. The use of tobacco is largely responsible for the recurrence and persistence of the mouth lesions. The best protection that can be offered against tertiary symptoms is early, thorough treatment. Statistics show that syphilis shortens the expectancy of life.

**Treatment.**—General hygienic measures and outdoor exercise are important. Mercury, arsenic and the iodids are used for the specific effects. Mercury and arsenic heal the lesions and prevent relapses by killing the *Spirochæta*



pallida. The iodids are an adjuvant and of special service in accomplishing the resolution of tertiary manifestations. Mercury is administered by mouth, by inunction, hypo-

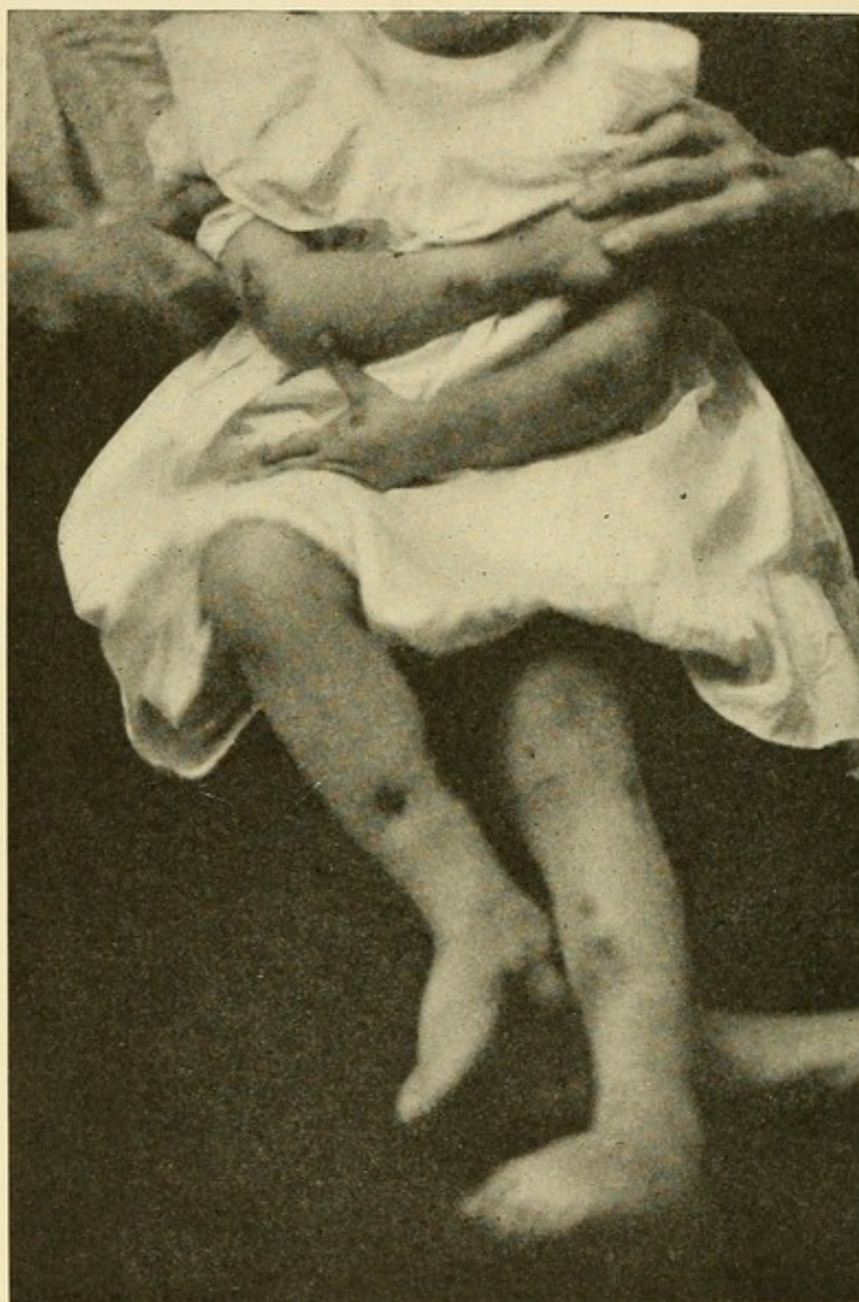

FIG. 6.—CONGENITAL DIFFUSED SPECIFIC PERIOSTITIS, SUPPURATING AT MANY POINTS. Within three months there were twenty-four points broken down and discharging. The sinuses shown over left elbow and head of right radius mark recent large gummata.

dermic injection, fumigation and intravenous injection. Prof. Ehrlich of Frankfort, Germany, has lately presented to the profession the arsenical preparation known as "606" (Dioxy-diamido-arseno-benzol, patented under the name



“Salvarsan”), which is administered by subcutaneous and intramuscular injection and by intravenous transfusion. The results from its use are far superior in the control of symptoms to those attained by mercurial medication. The permanency of its effect cannot be attested, as “606” has been in general use only a few months. The cure of syphilis in the absence of symptoms should be judged of by the Wassermann (or Noguchi) blood test.



## CHAPTER VI

### WOUNDS AND HEMORRHAGE

#### *Surgical Emergencies:*

- (A) Wounds and their treatment.
- (B) Hemorrhage.
- (C) Burns, scalds, frost bites and freezing.
- (D) Injuries to the brain and skull.
- (E) Foreign bodies in the eye, ear, nose and throat.

#### (A) WOUNDS

A wound is an injury of the skin, or the parts underneath, as a result of a blow or some form of violence. Wounds are simple when they remain local, have a tendency to recover instead of spreading to other parts, and produce no appreciable constitutional disturbance. Wounds are infective when they have been inoculated with bacteria, in which event the tendency is to spread or involve other parts and become general, resulting usually in systemic disturbances. These conditions may be considered varieties of inflammation. The latter is commonly known as blood poisoning.

Wounds are divided into: (a) contused; (b) lacerated; (c) incised; (d) punctured; (e) poisoned; (f) gunshot.

(a) **Contusions.**—Contusion is commonly known as a bruise, and is a term applied to injuries of the soft tissues, due to blows, as from a fist, causing a “black eye,” or from a stone or a whip. There is generally some discoloration of the parts, due to transfusion of red blood corpuscles from



the small blood vessels into the surrounding tissue, and swelling is generally found, which is due to the escape of serum and corpuscles from the small blood vessels. The pain is caused by the actual injury of the parts and the pressure produced by the escaped corpuscles and serum. Contusion may be quite simple where a slight abrasion is present, or it may involve an extensive area, as may be seen in railroad accidents.

*Treatment* for simple contusions is rest, simple lotions, as boric acid or normal salt solution, to protect the parts from the air and prevent infection. For extensive contusions cold applications for the first few hours, followed by heat after the acute stage, are good dressings. Anodyne lotions, as laudanum, are also beneficial, since they not only act upon the capillary blood vessels and produce local anesthesia and thus relieve pain, but they are also, as a rule, antiseptic and cause the wound to remain a simple one.

(b) **Lacerations.**—Lacerations are tears of the soft parts made by some blunt object, such as those resulting from railroad or machinery accidents, those produced in fights or made by a policeman's mace.

*Treatment.*—Here the general rule as to the management of all wounds should be observed, viz., use clean cloths, surgeon's cotton or gauze which has been in boiling water, and keep all filthy material from the wound. Slight oozing may be controlled by hot applications. Soap liniment, dilute alcohol, whisky, and laudanum are the best lotions both to control hemorrhage and to prevent inoculation. Adjust the lacerated parts if possible and hold them in position by the use of compress and bandage, taking care not to apply the bandage too tightly.

(c) **Incised Wounds.**—Incised wounds are clean-cut wounds, made by some sharp instrument, such as a knife, and their length is greater than their depth.

*Treatment.*—When small and not too deep, or when not attended by alarming hemorrhage, adjustment of the edges



by the use of adhesive plaster will be sufficient. When extensive, the best that can be expected as a temporary aid is to make an effort to adjust the parts and control the hemorrhage by direct pressure. Suture the skin.

(d) **Punctured Wounds.**—A punctured wound is one where the depth is greater than the surface length. It may be incised when made by a cutting instrument, and lacerated when a hook or other similar instrument pierces the soft parts. Punctured wounds are made by pins, needles, wire nails, thorns, splinters, knives, hooks, glass, etc., and the varieties may be profitably considered separately.

*Pins and needles* usually produce harmless wounds, except when they puncture an important cavity or blood vessel. When inoculation occurs, serious and possibly fatal inflammation may result. When a blood vessel is punctured, internal hemorrhage may occur, producing a condition known as false aneurism, which will require operation (see Hemorrhage). When a needle is driven entirely into, or broken off below, the soft parts of the skin, it is difficult to remove. If the course of the needle is such as to make it possible, the incision should be made half an inch or so from the point of puncture and the knife should strike the side rather than the point of the needle. To cut directly through the point of puncture would, theoretically, be the best method, but in practice it furnishes many fruitless efforts to locate the object of search. Too much damage should not be done to soft parts in a search for a needle, since it is inorganic matter and its presence causes little ill result.

*Thorn and splinter* wounds furnish a different condition, since wood is organic matter and never becomes encapsulated, but acts as an irritant. It should, therefore, be removed promptly. After removal little trouble results and healing takes place promptly. Large splinters produce extensive lacerations, which, after removal of the splinter, should be treated as other lacerated wounds. Splinters un-



der the nails are troublesome and may require the scraping or splitting of the nail before they can be removed. A most dangerous variety of punctured splinter wound is that in which the splinter enters an important cavity of the body, such as the eye, abdomen or pleura.

In wounds due to glass, the *glass* should be removed if this can be readily done, but it causes no injury to the parts, and should be allowed to remain until the arrival of the surgeon when there is any difficulty attending the removal.

When a *fish hook* has entered the soft parts, the point should be pushed out through the skin. The eye will prevent its being carried entirely through. The hook may be broken either by a couple of pliers or wire cutters, when the fragments are withdrawn.

*Nail* wounds, especially the old cut nails, produce most troublesome wounds. Infection is quite common, and erysipelas or other infective inflammation may result; hence, the importance of first treatment. After removal of the nail, the sinus should be injected with tincture of iodine, alcohol fifty per cent., or other antiseptic solution. The wound should be kept open rather than closed, to afford drainage.

For the *treatment* of all of these varieties of incised, punctured and lacerated wounds cleanliness should be observed, hemorrhage controlled by direct pressure, hot or anodyne lotions should be used, and gauze or cotton applied next to the skin, over which a bandage should be placed.

(e) **Poisoned Wounds.**—Poisoned wounds are those which are inoculated at the time they are produced, and must be considered as a variety of infective inflammation from the start. In certain wounds there may be a question as to whether infection has taken place. Bites of dogs, cats and rats may result in infection, but, as a rule, they do not.

Stings from bees and spiders produce swelling and some local disturbance, requiring local applications, but death seldom follows. Stings from tarantulas, scorpions, centi-



pedes, and bites of copperheads or rattlesnakes are poisonous and absorption takes place in a few minutes. Local treatment consists of cauterization by acid, hartshorn, pure alcohol or with a hot needle. When an extremity is wounded in this way it should be encircled above the wound, with a rubber band, or very tight bandage.

Dog bites are seldom poisonous. Of those dogs which appear mad on the street, few are really so. A dog which appears mad and has bitten some one should be caught and penned up for three weeks to definitely determine its condition. (See Hydrophobia.)

(f) **Gunshot Wounds.**—Gunshot wounds almost always involve deep structures, and little can be done or should be attempted toward treatment until the arrival of the surgeon. Rest and antiseptics, and, in case of hemorrhage, pressure to control the same, are about the only means of treatment to be employed by the dentist.

### (B) HEMORRHAGE

Hemorrhage is the escape of blood from a blood vessel. It is internal or concealed, when it cannot be seen, and external when the flow is from an external wound. Bright red blood comes from an artery and usually escapes with an interrupted spurt. Dark red blood which escapes with a continuous flow is from a vein. The reason why one so easily bleeds to death from an artery and not from a vein is that there is nothing to interrupt the flow from an artery, as they have no valves, as do the veins, where no backward flow of blood can occur.

**Control of External Hemorrhage.**—The first principle in the control of hemorrhage from small cuts or lacerations, especially those about the head and face, is to make direct pressure upon or into the wound with a clean piece of gauze or cotton. When the vessel from which the blood is escaping is not too large, such pressure, if kept up for ten or fif-



teen minutes, will control it. When a large blood vessel is severed with a knife, or where a limb is torn from the body and the patulous ends of the vessels are bleeding freely, pressure must be made above the point of hemorrhage. This may be done by making direct pressure upon the artery with the thumb, or when the hemorrhage is from an extremity, it may be girdled with a handkerchief or any kind of fabric tight enough to stop the flow. Such a tourniquet makes pressure best if a stone or other firm object is used, being placed in the folds of the handkerchief and laid directly over the artery. A stick may be tied in the second knot on the opposite side of the leg from the vessel. By turning this, sufficient pressure may be made to control the hemorrhage. In making application of any variety of tourniquet, care must be taken to apply it tightly enough to control the flow, but if applied for many hours gangrene may result.

**Internal Hemorrhage.**—Hemorrhage may occur from the cavities of the body, as the mouth, nose, stomach, lungs, intestines, or from the uterus.

Nasal hemorrhage is the most frequent variety, and is usually from the mucous membrane of the anterior superior portion of the nasal cavity. The most alarming hemorrhages occur from the roof of the cavity well back. Ordinary hemorrhage from the anterior surface may be controlled by making pressure against the side of the nose with the thumb, or by the application of cold cloths to the back of the neck, with the body in the upright position. Astringent douches may be injected up the nose with benefit, but care must be taken not to damage the nasal mucous membrane with the douche tip. Packing the cavity with gauze or plugging the posterior and anterior nares must be left to the physician. Nasal hemorrhage may be a symptom of typhoid fever.

Hemorrhage from the mouth after the extraction of a tooth is not an infrequent complication. It may be con-



trolled, usually, by first cleansing the tooth socket, swabbing with Monsel's solution, and afterward packing it with gauze or cotton.

Hemorrhage in the stomach is only made manifest when the blood is vomited, and then it may be mixed with the food and be difficult to recognize. It is controlled by salt or ice taken into the stomach and cold applications over the pit of the stomach.

Hemorrhage from the bowels in individuals in apparent health, or from hemorrhoids, is, as a rule, not dangerous. It may be controlled by recumbency and applications or injections of iced vinegar.

Hemorrhage from the lungs of those suffering with consumption is most alarming, but from individuals in apparent health is of little consequence. Treatment consists in quiet, administration of ice pills, salt, or a half-teaspoonful of F. E. ergot, repeated in a half hour or less time, if necessary.

Uterine hemorrhage is best controlled by recumbency, with the head lower than the feet, the administration of F. E. ergot, and hot vaginal injections.

A general rule which may be of service is: If the flow is above the heart allow the patient to sit up, and if below have him lie down. The position diminishes the pressure by encouraging gravitation.

### (C) BURNS AND SCALDS

Burns from a flame or acid and scalds are dangerous if two-fifths of the surface of the body is involved; and when more than this amount of skin is destroyed the result is usually fatal. The destruction of a smaller amount of surface than this may terminate fatally when the deep structures are involved or when steam has been inhaled. When the clothing is aflame, the unfortunate should be forced to lie down, and a blanket, coat, carpet, or some fabric large



enough to envelop the body thrown around him. Everything must be done to keep the flames away from the face, so that the hot air may not enter the lungs. The pain and shock are proportionate to the amount of surface destroyed and the depth of the burn, and these conditions increase as treatment is delayed.

**Treatment.**—After the flame is extinguished the burned clothing should be carefully removed and the burned surface exposed, so that dressing may be applied immediately to protect the raw surfaces from the air and thus prevent pain and subsequent shock. Blisters should be punctured near the margin, so that the liquid may escape and allow the epidermis to collapse. The dead skin should be removed, since pus may gather underneath and cause fever. The best immediate dressing is carron oil (linseed oil and lime water in equal parts) applied to the exposed surface with saturating gauze or soft muslin; over this cotton batting should be wrapped, and this dressing held in position with a bandage. Oxid of zinc ointment (1 dram of z. o. to 1 oz. of vaseline) spread on lintine makes the best permanent dressing for burns. This should be changed daily. The first idea of treatment is to make a substitute for the destroyed epidermis at the earliest possible moment. Solutions of baking soda, sweet oil, castor oil, vaseline, lanolin, etc., make good dressings and should be applied as directed above. Gauze or flannel immersed in hot water is an excellent dressing. Stimulants and opiates in proper doses should be administered as necessary.

Acids, such as vitriol, produce painful burns. Burns of this sort should immediately be bathed in soda solution or soap suds, and, after cleansing in hot water, should be dressed as other burns. Alkalies produce an injury similar to the foregoing and require similar treatment, except that vinegar or some other mild acid solution should be applied immediately after the accident.

Burns from gunpowder are treated by first cleansing the



parts with hot water, then briskly rubbing the skin with a towel or sponge, which dislodges the particles of powder not deeply imbedded. The removal of the deep particles should be done by a physician, but if one cannot readily be found, another may remove them with a sharp needle, which should be sterilized by passing it through a flame or immersing it in hot water or alcohol.

Frost bites and freezing are of frequent occurrence in country districts, and railroad and street car employees often suffer from them. Treatment consists in rubbing the parts. The practice of using ice, snow or ice water is all right, but the friction does the good whether it is done with ice or with the hand. Temperature should be *elevated gradually*. When an individual is frozen to stupor, or to unconsciousness, friction and *gradual elevation* of the temperature of the room, with stimulants and artificial respiration, are means most likely to restore life. A bath, with the water slightly warmed and the temperature *gradually elevated*, should be resorted to if necessary, after which the patient should be wrapped in warm blankets.

#### (D) INJURIES TO BRAIN AND SKULL

Fractures of the skull or injuries to the brain, resulting in concussion or compression, have for symptoms incoherent talking, stupor (from which the patient may be aroused) or unconsciousness. In fractures of the skull with compression there will be profound stupor, irregular breathing, irregularly contracted pupils and possibly paralysis of one or more extremities.

In concussion, or where there is a simple "shaking-up" of the brain, the impression is not so great, it usually being possible to arouse the patient sufficiently to respond to questions. The history of an injury, such as a fall or a blow, will assist in making a diagnosis. Brinton gives the following diagnostic points:



*Concussion.*

1. Incomplete insensibility.
2. Partial muscular action.
3. Special senses act partially.
4. Patient can answer questions if aroused.
5. Pulse quick, feeble, and often intermittent.
6. Skin cold; temperature falls to 94 or 95 degrees.
7. Respiration feeble; quiet.
8. Nausea and vomiting.
9. Pupils regular.
10. Eyelids somewhat open.
11. Urine voided; feces retained.

*Compression.*

1. Complete insensibility.
2. Paralysis.
3. Special senses do not act.
4. Patient cannot answer questions if aroused.
5. Pulse slow and laboring.
6. Skin hot and perspiring; temperature 102 to 104 degrees.
7. Respiration is labored, stertorous.
8. No nausea or vomiting.
9. Pupils irregularly dilated.
10. Eyelids irregularly closed.
11. Retention of urine; involuntary escape of feces.

Treatment, until the surgeon arrives, consists in enforcing absolute quiet in recumbency. No whisky should be administered. Cold may be applied to the head and water given the patient to drink if he desires and can take it.

**(E) FOREIGN BODIES**

**In the Eye.**—Foreign bodies in the eye may be removed with a spud or sterile gauze. The lid may be everted by having the patient look down, while the lid is grasped between the thumb and index finger of one hand, and the central part is pushed down with a sterile probe. The lid is then turned up. This exposes the under surface of the lid, where the foreign body is usually found. When the for-



eign body is on the cornea (or ball), if it cannot readily be removed with some blunt instrument, an oculist's services should be sought. If there is much pain, cocain (two per cent.) should be dropped into the eye and impalpable boric acid should be dusted in afterward, if there is much congestion.

**In the Nose.**—Foreign bodies in the nose are usually pushed farther in unless the effort for removal is made with a flat, blunt instrument, such as a bodkin needle, entered above the object. The hand is elevated, dragging the object downward and forward and usually out.

**In the Ear.**—Foreign bodies in the ear do little damage; indeed, they do less damage if left alone than is done by an unskilful effort at removal, as it is not an unusual accident to injure the ear-drum by pushing an object in against it. A physician should be asked to remove foreign bodies from the ear.

**In the Throat.**—Foreign bodies in the throat are, as a rule, due to accidents of childhood, and must be removed at once. This can be done by entering the index finger in the mouth, to one side, and, with the tip, hooking the object out. Care must be taken, as an aimless effort will push the object farther down and do more harm than good.

**In the Larynx.**—When objects pass into the larynx, a most serious condition is presented. Grains of corn, beans, buttons, etc., if they enter the windpipe, are drawn into the lungs by the first breath and may occlude one entire lung, resulting in almost instant death. Suddenly turning the patient head-downward and striking the back may dislodge the body and throw it off. This condition will be recognized by the extreme difficulty in breathing. When bodies are retained in the windpipe any length of time they produce a dropsy of the mucous membrane, which greatly complicates matters, hence the desirability of immediate removal. The doctor should be summoned at once, and he must be informed as to the condition and be prepared to perform



tracheotomy (or opening the windpipe through the throat) in order that the object may be removed. Foreign bodies are now located and removed with the laryngoscope.

**In the Stomach.**—When objects are swallowed, they are not necessarily dangerous. Tubes three inches long, used for intubating the larynx in cases of membranous croup, are swallowed and pass from the bowels in three or four days and do no harm; and a case is reported where a five-year-old negro girl swallowed a barb-wire staple, and it passed in four days without causing a particle of trouble. The patient should be fed mashed potatoes or solid materials, which surround the object and help to carry it along the alimentary canal. Round bodies, such as bones, when not too large, and coins, may be pushed into the stomach, where they do no harm and pass off in a few days. Sharp objects, as fish-hooks, hatpins, and sharp-pointed instruments, must be removed at all hazard. Little attempt at removal must be made by anyone but a physician, who should be summoned with all haste. Instances are reported where false teeth, table fork, hatpins and scarf-pins have been removed from the stomach through a gastroscope. When this fails, an abdominal section is required.



## CHAPTER VII

### BANDAGING

Bandages are usually made from muslin or cheesecloth, but they may be of flannel or rubber webbing.

**Uses of Bandages.**—Bandages are used as follows: a. To hold dressings in position; b. to secure splints and appliances in position; c. to support injured parts; d. to control bleeding by making pressure.

**Varieties of Bandages.**—There are six varieties of bandages: a. Roller; b. triangular; c. four-tailed; d. many-tailed; e. T and double-T; f. special.

The ordinary *roller* bandage is of most universal service and is made of cheap muslin, cheesecloth, flannel, old sheets or bolster-cases. In applying the bandage the roll must be taken in the right hand, the back of the bandage held to the skin with the left thumb resting on the end. The following rules may be observed for the extremities:

Begin bandaging at the toes or at the fingers and go toward the body. Never bandage an extremity from the body. Circular turns should be made and the turns reversed where the extremity is conical, so that the edge will not cut into the skin, but instead the pressure will be uniform. This is known as a spiral reversed bandage. Figure-of-eight turns should be made over the joints at the knee and elbow.

For the hip and shoulder a *spica* serves the best. For the shoulder, this bandage is applied by making two or three turns around the arm near the shoulder, after which the bandage is carried over the point of the shoulder, down



across the chest in front, under the opposite arm and across the back to the point of the injured shoulder, and from there it is carried around the arm to the point, as in start-

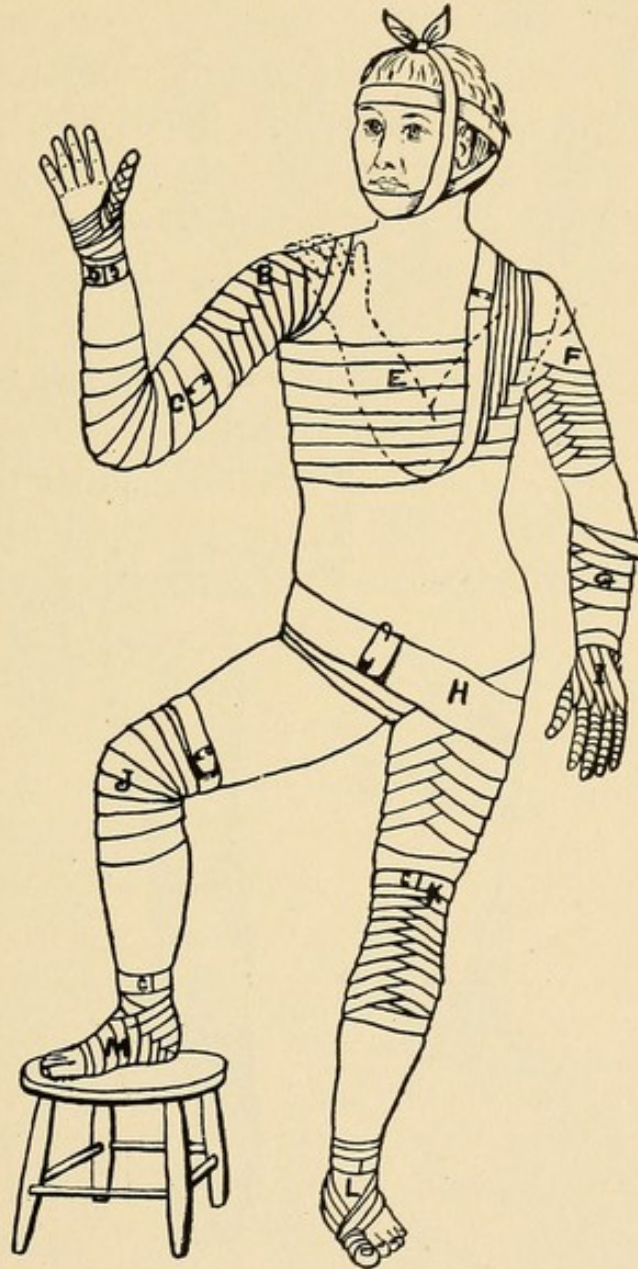


FIG. 7.—ROLLER BANDAGES. A. Four-tailed bandage for fracture of the lower jaw and head. B. Reverse spiral for the shoulder. C. Figure-of-eight for the elbow. D. Figure-of-eight for the thumb. Begin at the wrist. E. Roller bandage for fracture of the clavicle and injury of shoulder. F. Ascending spica for shoulder and arm. Begin near the elbow. G. Reverse spiral for the forearm. H. Descending spica for the groin and hips. Begin at the thigh. I. Gauntlet for the fingers and thumb. Begin at the wrist, wrap from finger-tips toward hand and return to wrist from every finger. J. Spica for the knee. K. Reverse for the knee. L. Roller for big toe. Begin at the foot. M. Divergent spica for the heel.



ing. This is repeated, each time lapping the layers about half the width of the bandage until the shoulder is covered. (Fig. 7.) For the hip, the bandage is applied in the same way, except that it goes around the pelvis.

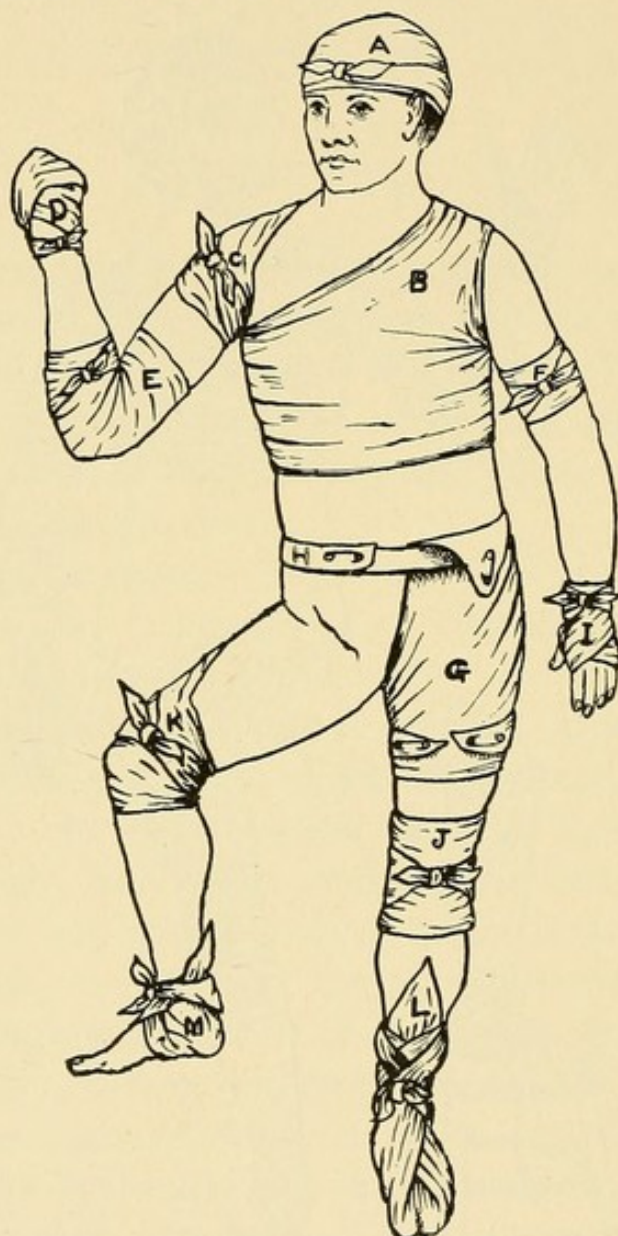

FIG. 8—TRIANGULAR BANDAGES. A. Triangular bandage for the head. Free angle is turned up even at back of head and pinned. B. Triangular bandage for the chest. The three ends are tied together at the back. It is reversed for the back. C. Triangle for the shoulder. The upper free angle may be turned down or the knot may be made at the shoulder. D. Triangle applied to the fist. It is used in the same way for the foot, or for stumps after amputation. E. Triangle for the elbow. F. As applied for the arm or elbow and for holding splints in position. G. Triangle for the hips. H. Circular bandage about the pelvis to hold triangle of hip in position. I. Triangle for hand and wrist. J. and K. Triangles as applied to the knee. L. Triangle for the entire foot. M. Triangle for the heel.



The *triangle* is a most convenient bandage and can be made more readily than the roller bandage, since smaller portions of muslin are necessary and an ordinary handkerchief serves well. The triangle is best for the head, neck, shoulder, hip or other joints, but where even pressure is desired the roller is best. A *four-tailed* bandage is used for the chin most frequently. *Many-tailed* bandages are used for the abdomen or thorax, and are used by applying the belly of the bandage in front, crossing the tails in the back, and bringing them forward, where they are tied or pinned. (Fig. 8.)

*Special* bandages are made to accomplish special purposes, such as to make traction upon an extremity in fracture or hip-joint disease.

Plaster-of-paris, starch, silicate of soda, and other materials are incorporated in bandages when firmness and permanency are required.



## CHAPTER VIII

### SHOCK AND MEDICAL EMERGENCIES

#### SHOCK

Shock, commonly known as collapse, is a traumatic torpor of the system following injuries and surgical operations. In this condition the mechanism of the vital organs is disconcerted.

According to Kinneman: "Shock must not be considered as due to the lowering or exhaustion of one bodily function, but as a composite condition embracing an interference with the normal height of the blood-pressure (lowering), an interference (lowering) with the respiratory act, and a marked fall in the body temperature. Of these, as shock increases in severity, the most uniform and progressive factor is the fall in temperature. That there is a relationship existing between the fall in body temperature and shock is evident by considering: (1) That in one series the fall in temperature was the sole cause of the shock; (2) that where, by continuous bath, the temperature fell but one degree Centigrade (average), the respirations were increased instead of diminished, and the fall in blood-pressure was greatly lessened; (3) that by raising the body temperature previously lowered in shock, the respiratory rate was increased and the blood-pressure raised. This relationship may be thus expressed: (a) A sufficient fall in the body temperature can cause a decrease in the respiratory rate and a marked fall in the blood-pressure, which,



together with the former, we designate as shock; (b) conversely, a limiting of the fall limits the fall in pressure and prevents a fall in the respiratory rate. Therefore, shock is limited or prevented. (c) Antagonistically, a rise of the temperature causes a rise in the blood-pressure and the respiratory rate (reduced in shock), with the result of a gradual amelioration of all the symptoms. Thus, of the three factors concerned, the temperature commands first place by its power of production, by its power of limitation, and by its power of amelioration of the composite condition—shock.”

**Symptoms.**—The symptoms are muscular relaxation, with a white skin, and usually a cold and clammy sweat. The features are pinched, face shrunken, eyes deep, weird and uncanny. The temperature is subnormal, respiration and pulse slow. There is reflex vasomotor and pneumogastric paresis. Syncope or fainting is usual, and the patient lies motionless and apparently lifeless.

**Diagnosis.**—Diagnosis must be made from alcoholic intoxication, apoplexy, brain injury and from drug poisoning.

**Treatment.**—The general management of cases suffering from shock may be summarized as follows:

(1) Quiet, rest in the horizontal position and artificial moist heat have long been recognized as valuable means of restoring the lost tone to the vasomotor system.

(2) The head should be lowered enough to make gravity aid in furnishing sufficient blood to nourish and excite to proper function the important reflex centers of respiration and the heart's action in the medulla, as well as the visceral ganglia in the lungs and heart themselves.

(3) Experiments have conclusively shown that, while shock first affects the vasomotor system, respiration is early impaired or stopped, sometime before the heart's action is seriously deranged or stopped, and, therefore, artificial respiration may be the means of continuing life by furnishing oxygenated blood for the vital centers in the



medulla. The inhalation of oxygen is likewise indicated for the same purpose.

(4) The interstitial and intravenous injection of warm salt solution is perhaps our most efficient, certain, powerful and lasting remedy, particularly when there has been hemorrhage. When the case is not especially urgent, the same solution may be efficient when introduced into the stomach or rectum, and when convenient the peritoneal cavity may be used for the same purpose.

(5) The therapeutic remedies are those which will restore the tone of the vasomotor system and support respiration and the heart's action. Of the many drugs which have been recommended and used, strychnia probably rightfully claims the most friends, used in the way the operator deems best to reach the circulation and, so, the nerve-centers. Next come digitalis, strophanthus, nitroglycerin, and ergot in appropriate doses.

### UNCONSCIOUS CONDITIONS

**Coma.**—Coma, or loss of consciousness, is a state of more or less profound insensibility allied to sleep, but differing from natural sleep in its character as well as in the circumstances under which it occurs. The long-continued action of cold, and the narcotic influence of alcohol, opium or tobacco will produce death through coma. In coma the patient lies on his back, and is either simply insensible to external impressions, or has a confused and dull perception of them, with restlessness and low delirium. In such a case the pulse is generally strong, the pupils dilated and the face flushed. Treatment consists in placing the patient in a quiet, reclining position, and making cold applications to the head. In suffocation from gas, use artificial respiration; when due to drugs, the usual antidote may be given.

**Apoplexy** (*Paralytic Stroke*).—Apoplexy means a rupture of a blood vessel with escape of blood either within or



upon the surface of the brain, the pressure resulting in paralysis of one or a group of muscles of one or more extremities. The affected arm or leg is lifeless and cold, while the unaffected parts are normal. The causes are advanced age, with over-exertion, mental and physical excitement, and hardening of the blood vessels. The symptoms are a flushed face, unconsciousness, slow pulse, irregular breathing (stertorous), eyes insensible, pupils irregularly dilated. Convulsions may occur. Treatment includes quiet, in a horizontal position. Loosen all tight clothing. Apply cold to head and heat to the extremities. Hot rectal injections are beneficial. Do not use stimulants.

**Asphyxia.**—Asphyxia is loss of consciousness by exclusion of air from the lungs. Causes are anything that would interfere with proper respiration. Only a scanty supply of air may be admitted, as in strangulation, drowning, choking, or disease of the windpipe; and again, although there may be every capacity of respiration, the air may contain too little oxygen in proportion to other elements. As the condition of asphyxia advances, in drowning or otherwise, the small vessels of the lungs become gorged with blood, which the heart no longer has power to force freely through them, and the pulmonary artery and the right side of the heart become filled with blood, while but little returns to the left side of the heart. Treatment is to fill the lungs with fresh air, and undoubtedly the most efficient method is that of Dr. Sylvester.

**Epileptic Fits.**—Epileptic fits, or convulsions or falling fits, are periodic convulsive seizures. They are due to some brain disease, such as pressure caused by an old injury, or are the result of some previous disease, such as meningitis. The symptoms are a peculiar cry, followed by unconsciousness, grinding of the teeth, and “frothing at the mouth.” Convulsive seizures of the face, mouth, arms and legs, and rolling of the eyeballs are followed by a deep sleep. The patients frequently fall unconscious and injure



the head or other parts of the body. Treatment is to prevent the unfortunates from injuring themselves, and to care for them until consciousness returns. Trephining, where there is a history of injury or disease, is an advisable operation, and cures result in a majority of cases.

**Convulsions of Children.**—Convulsions, or fits, of children are muscular paroxysms due to irritation of the nervous system. They are due to high temperature from teething or other causes, intestinal irritation, indigestion, worms, constipation, etc. As a rule, they are not dangerous, and children seldom die from these attacks. Symptoms associated with the convulsions are fretfulness, restlessness, gritting the teeth and stupor. Muscles of the face and other parts of the body twitch and may become stiff. The limbs move in various directions. The pulse is rapid and weak. The skin is cold and clammy, with perspiration in the later stage. Breathing is hurried and labored. A period of quiet may precede a second or third convulsion. Treatment consists in promptly immersing the patient in a bath of hot water, friction to the extremities and the body, with cold to the head. Convulsions in children, however, may be a forerunner of meningitis or serous inflammation of the spinal cord or brain, and the physician should assume responsibility in all cases.

**Convulsions from Kidney Diseases.**—*Convulsions* from *kidney* diseases (Bright's disease, etc.) are due to uremic poisoning when the kidneys fail to cast off the waste products. Symptoms are dropsy of the feet and other parts of the body, with urine scanty or suppressed. Other early symptoms are headache, nausea and vomiting. The convulsions may be followed by coma and death. Treatment belongs to the physician. Quiet, with an effort to produce sweating, is useful.



## CHAPTER IX

### ASEPSIS AND ANTISEPSIS

*Asepsis* is the practice of thorough cleanliness in a wound already sterile. *Sepsis* is a condition where specific or infective microbes exist, and inflammation in some degree always follows. *Antisepsis* is an effort to destroy germs, or septic conditions already present in wounds or tissues, by means of some germicidal agent.

If wounds are already sterile, or aseptic, it is not necessary that germicides or chemicals be used to prevent infection. In removing a tumor where no wound or pus exists, the only thing necessary to keep the parts sterile is to thoroughly destroy the germs which may be on the hands of the operator or his assistant by scrubbing and cleansing in hot water, to scrub the skin about the proposed incision with hot water, and to boil the instruments and dressings at least twenty minutes, or to sterilize them by the use of steam or dry heat. When a wound has already been infected, or is septic, disinfectants or germ-destroying agents must be used to produce sterile conditions. It is now necessary to practice antisepsis. This is done by the use of a flesh brush rubbed over the skin of the hands and arms under running water or in water as hot as can be tolerated for ten or twenty minutes, the nails being thoroughly cleansed with a tool, as germs are most liable to be lodged here, the skin about the field of operation being given the same scrubbing; or by the use of certain chemicals as germicides, when it is thought that the hot water has not destroyed all germs.



**Germicides.**—Germicidal agents are numerous, and their power to destroy microörganisms varies greatly. Those in most common use, with their relative values, are as follows:

*Tincture of iodin* (U. S. P.) is one of the most effective antiseptics known to surgery. If introduced into a tissue containing bacteria, it will destroy them and leave the tissue in the best possible condition for repair. Its use in erysipelas is well known. It has the power of penetrating tissue and in abraded surfaces it is absorbed and carried along the lymphatic vessels originally infected, destroying the germs.

*Mercuric chlorid* should be used in solution strength from one to six hundred to one to eight thousand. For disinfecting the skin one to two thousand is generally used, and for irrigating wounds one to four thousand is sufficiently strong. A convenient form in which to use mercuric chlorid in private practice is in tablets of seven and one-half grains each, prepared by the chemist. One tablet added to one quart of water makes a one to two thousand solution.

*Phenol* was the first antiseptic used and was introduced by Lister in 1865. The usual strength for the hands and skin is one to forty. To sterilize instruments they should be allowed to remain in solution of one to twenty for thirty minutes. This should be diluted one to forty with hot water before the instruments are handled, as so strong a solution produces anesthesia of the skin, and otherwise injures it. For irrigating purposes a one to sixty solution should be used. Phenol is not so reliable as mercuric chlorid and may produce systemic poisoning and local gangrene, and should be used with great care. For deep sterilization it is not necessary, the reason being that it is a coagulant and the material formed by its action constitutes a wall that prevents it from penetrating into deeper structures of the bone. To follow the use of phenol with alcohol, as is ad-



vised, to prevent too great corrosive action, is hardly founded upon scientific principles, since carbolic acid immediately coagulates soft tissues and absorption from such surfaces is not to be feared. If good comes from this treatment it must be due to the alcohol itself rather than to the phenol.

*Hydrogen dioxid*, so frequently recommended and so commonly used by the average surgeon, has no place in the surgery of bones. It must be admitted that its power as a parasiticide is in its action upon pus or the products from pathological or granulated tissues, and that effervescence is evidence that pus is present. As a matter of fact, the moment this liquid becomes effervescent, its power to destroy bacteria is ended. As the gas thus produced must push out in every direction, it carries before it not a germicide, but an inert bubble. Hydrogen dioxid should not be used in a cavity because of its effervescence, for it distends the tissue and these inert bubbles carry infective germs, when they are present, deeper into the tissues, thus infecting new areas.

For the preservation and sterilization of instruments and suture needles, there is nothing that serves so well as *lysol*. This is especially adapted for dental purposes. Instruments should always be absolutely free from germs, so that inoculation of one patient from another is made practically impossible. The instruments can be immersed in *lysol* for months, always remaining bright and clean. The odor is not so objectionable as that of phenol or other solutions.

Other antiseptics are *zinc chlorid*, five to twenty grains to the ounce, and *potassium permanganate*, a dram to one ounce of water. Some useful antiseptic dusting powders are *acetanilid*, *ichthyol*, *boric acid*, and *bismuth* in some form.

**Sterilization of Dressings and Instruments.**—Materials used in the performance of surgical operations are: sponges



made of cotton or gauze; gauze, which may be used instead of sponges, or for the purpose of drainage and packing of wounds and for external dressings; absorbent cotton used for external dressings and as sponges; and bandages used to secure dressings in position.

*Absorbent cotton and bandages* should be thoroughly sterilized if antiseptic results are to be expected. This is accomplished by subjecting the materials to a dry heat for twenty minutes. Operating gowns, towels, instrument trays, suture and ligature materials, as well as instruments and dressings, should be sterilized before they are used.

**The Operating Room.**—The operating room, if other than one constructed for the purpose in a modern hospital, should be first divested of carpets, curtains, and draperies, then sterilized with a formaldehyde lamp, mercuric chlorid or sulphur candles. The heat of the room should be from seventy to eighty degrees F., and should be kept uniform throughout the operation.

**The Patient.**—Preliminary to all operations the skin about the field of operation should be thoroughly cleansed (all hair removed by being shaved sometime before operation), and the patient wrapped in sterile dressings composed of gauze and cotton. Just before operation the field of operation should again be scrubbed with ether soap and irrigated with pure alcohol, or it may be painted with tincture of iodine.

**Sutures and Ligatures.**—A *suture* is a stitch made through the edges of a wound to approximate them and hold them in position until union takes place. Materials used in making sutures are silk, catgut, silkworm gut, kangaroo tendon, silver and iron wire, and horsehair. For deep suturing, catgut and kangaroo tendon are used, because they are absorbed and do not require removal, although silver or other non-absorbable material may become encysted and do no injury.

*Ligation* is the act of tying a blood vessel, lymphatic



or other pervious duct or canal. The materials used for this purpose are catgut, silk and kangaroo tendon. Catgut is to be preferred, since it lasts three or four days within the tissues and is sufficiently permanent to insure repair and the formation of a permanent clot within the vessel ligated.

Surgical needles must be kept absolutely sterile, bright and always ready for use. This may be done with pure lysol in the manner previously described.



## CHAPTER X

### GENERAL DIAGNOSIS

The foundation of correct diagnosis must be a thorough understanding of the structural changes and a correct knowledge of the relation of the symptoms observed to such changes. If one would make the best preparation for this work, he must look for guidance to physiology, to normal and pathological anatomy, to chemistry, to microscopy and to the skiagraph and other special means of investigation.

**Case History.**—A systematic method of examining all patients should be followed and a written record kept of the findings. Record should be kept in about this order: Name, age, sex, race, nationality, residence, occupation, habits or mode of living, married or single (if patient is a married woman, date of last confinement and number of previous confinements); age of parents, if living, or, if dead, cause of death; condition of health of brothers and sisters, or, if dead, cause of death; causes of death of deceased uncles and aunts. As complete a *family history* as possible should be obtained. The aim of such inquiries as these is of valuable assistance in making a diagnosis in tuberculosis and cancer.

Investigation of *previous illnesses* may throw considerable light upon the case. Inquire particularly as to rheumatism and syphilis. While it may occasionally seem indelicate to ply suspicious patients with questions, if specific conditions are suspected, an appointment may be made and the family physician consulted in the meantime. If no physician or surgeon has been seen, it is the duty of the



dentist to advise the patient to see one. Especially is this true of conditions about the oral cavity. Simple ulcerations on the tongue or mucous membrane of the mouth or lips, which, if attended to early, might not terminate fatally, are often left untreated until there is involvement of deep structures by a malignant growth. One who recognizes a grave condition and insists upon proper treatment is entitled to as much credit as the operator, whose duty is clear.

The *symptoms* include the date of the beginning of the present attack, the mode of seizure, whether sudden or gradual, etc., and the present complaints of the patient. Observe the general nutrition and the appearance of the face, skin and tongue. Note the character of the pulse and respiration. Inquire as to appetite, thirst, and the condition of the bowels.

*Examination of the heart, lungs and other organs* and recording their conditions are next in order. With all the facts of the case then at hand, one is able to judge the nature and extent of the diseased structures, or, in other words, to make a *diagnosis*.

The *treatment* is then recorded as the final item of the case history. The *progress of the disease* or the *results of treatment* should be recorded from time to time, as the patient is seen at the office.

#### **How to Obtain a Complete Knowledge of a Disease.—**

In making a study of diseases it is necessary that the subject be divided into several heads, so that it can be taken up systematically. The usual course of study is as follows: 1. Definition; 2. Anatomy; 3. History; 4. Etiology; 5. Pathology; 6. Symptoms; 7. Diagnosis; 8. Differential diagnosis; 9. Prognosis; 10. Complications; 11. Sequelæ; 12. Mortality; 13. Treatment.

A *definition* often leads to a very fair understanding of the disease. A brief review of the *anatomy* of the parts under consideration is a convenience and avoids the necessity of making further research, as well as insures knowl-



edge of the subject at hand which might otherwise be neglected. We must know the normal to detect the abnormal.

The *history* of a given case previous to the onset of active symptoms is of importance, such as in a case of heredity. Previous injury or illness usually have important bearing. *Etiology* is the cause or causes which precipitate the onset of disease. *Pathology* is a study of the tissue changes during the course of the disease.

*Symptoms* are the manifestations of disease. *Subjective* symptoms are those appreciable to the patient alone, such as pain; *objective* symptoms are those appreciable to the examiner, such as swelling. *Diagnosis* is the naming of the disease and is arrived at by summing up all of the preceding conditions. *Differential diagnosis* is distinguishing the disease under consideration from others which may have symptoms quite similar.

*Prognosis* is the prediction of the result or termination. Under *complications* a study is made of the diseases or changes which might develop, secondary to the original trouble or simultaneously. *Sequelæ* include all remote or subsequent results. *Mortality* is a study of the death rate.

*Treatment* is the application of preventives to stop a suspected onset or to cut short an existing disease, and the administration of restoratives after the disease has run its course. Diseases are *self-limited* when they run a regular course requiring a definite time, after which spontaneous recovery may be expected. Typhoid fever, measles, scarlatina, smallpox, etc., are self-limited diseases. Many conditions have no definite course, such as enlarged glands, nephritis, osteitis or periostitis.

**Diagnostic Signs.**—The study of diagnostic signs, which are in reality objective symptoms, is not given in detail in this book, as it should be in a truly medical work. For convenience to the dental student the subject is divided into three heads: a, medical diagnosis; b, physical diagnosis; c. surgical diagnosis (or examination).



MEDICAL DIAGNOSIS.—Medical diagnosis comprises what may be learned by a careful general inspection of the patient. Much can be found out in a few seconds regarding the health, habits, strength and mode of life of a particular individual. A general observation of all patients who enter the dentist's office is necessary. *Skin eruptions* are to be studied and at least approximately made out. The *general health* of the patient must be observed, and bilateral physical conformity be made out. The color of the skin is an index to general health. In anemic persons the skin will be very white and bloodless. In advanced cancerous conditions there will be a sallow, waxy complexion. When the skin is yellow, with the same discoloration of the eye, liver trouble is to be suspected. Puffiness below the eyes indicates kidney trouble. The eyes also serve as an index to the condition of health. Protrusion indicates exophthalmic goiter or tumors of the brain and antrum. When there is bilateral protrusion goiter may be suspected, while in tumors but one eye is generally involved. When one lid droops it is ptosis, due to paralysis of the third nerve from brain lesions or trauma along the trunk. An irregular contraction of one pupil may be from the same cause. When both pupils are contracted, the patient is under suspicion as an opium habitué. When both pupils are widely dilated the patient is usually under the influence of belladonna or has been given a mydriatic by an ophthalmologist. Strabismus is usually of no particular significance. Glaring eyes indicate mania, which may be from alcohol. Bright and sparkling eyes are seen in tuberculosis and in persons with fever.

The *tongue* may be coated, due to a disordered stomach, mouth or throat disease, or some infectious or constitutional disease. It may be swollen, due to inflammation; or ulcerated, due to syphilis, cancer or tuberculosis. It may be bilaterally or unilaterally paralyzed, due to nerve, or nerve center, involvement. In unilateral paralysis the tongue, when protruded, points toward the paralyzed side.



The *lips* may be blue (cyanosis), due to heart or lung disease. They are frequently the seat of ulcerations, including herpes or coldsores, chancres and cancer. Dyspnea, or shortness of breath, may be caused by exertion, obesity or some lung or heart trouble.

*Swelling* or edema of the feet and ankles is suggestive of heart, kidney or liver disease.

PHYSICAL DIAGNOSIS.—Physical examination comprises an examination of a particular organ by means of inspection, mensuration, palpation, percussion, auscultation or combinations of the same.

*Inspection* is the making of ocular observation. The principal organs of the *thoracic cavity*, the heart and lungs, are very prone to pathological changes, some of which exhibit well-marked symptoms, while others give almost no symptomatic evidence of their existence. We may discover on inspection the “alar chest” or tuberculous chest, characterized by the prominence of the scapulæ and a flattened condition of the anterior wall of the thorax; the “pigeon chest” and beaded ribs of rickets and deformities caused by curvature of the spine; and the “barrel chest” of emphysema.

The rate of respiration in an adult is eighteen. It may range from forty in the infant to from fourteen to sixteen in the adult, and during sleep may be as low as eight or ten per minute.

*Mensuration* is making measurements and computing bilateral symmetry.

*Palpation* is the use of the sense of touch. It is performed by the use of the whole hand applied to the surface of the thorax or by the use of the tips of the fingers only, giving information as to the vocal fremitus, the location and character of the cardiac pulsation and the friction rub of pleuritis and pericarditis.

*Percussion*, either by the use of the fingers or the percussion hammer and pleximeter, is the production of sounds



by pounding or percussing a part, and is probably the most useful of all means in the diagnosis of pathological changes in the thoracic viscera, aiding as it does in the discovery of solidified areas in the lungs, which elicit a pulmonary resonance. The bowels distended with gas elicit a tympanic resonance. At the margin of the liver or heart there is dullness. Where there is absence of sound, as over the centers of the liver or heart, it is known as flatness. Pulmonary resonance, elicited by percussion, is the normal sound, described as a clear, resonant note, heard most distinctly below the clavicle and in the axillary space. It indicates a normally inflated lung. When the normal note is not elicited and a dullness is found, it is indicative of consolidation of the lung, abscess, or pleuritic effusion. When dullness is substituted by flatness, which is an absence of all pulmonary resonance, it shows that the lung is entirely displaced by pleuritic effusion or is completely consolidated. As percussion extends from the right lung downward over the liver, the sounds change to dullness at about the fifth rib and to flatness as the lower margin of the lung is passed and the liver reached.

Tympanic note is found over cavities in the lungs from abscess or phthisis. In pneumothorax and emphysema the normal pulmonary resonance is exaggerated. A metallic note is produced by percussing over large cavities with smooth walls. A cracked-pot resonance, or the *bruit de pot fela* of the French, is heard when the act of percussion forces the air out of a lung cavity through a restricted opening.

*Auscultation* is the act of making physical examinations with the ear, which may be aided by the use of a stethoscope, or a phonendoscope. The sound heard during normal respiration is known as pure vesicular breathing. Vesicular breathing may be exaggerated in difficult respiratory acts, in bronchitis, hypersecretion of mucus, etc. It may be prolonged or accelerated during asthma, emphy-



sema, etc. Jerking vesicular breathing is found in painful affections, such as pneumonia, pleurisy and beginning pulmonary tuberculosis. Bronchial breathing is heard over cavities communicating with the large bronchial tube, in consolidation and compression of the lungs from whatever cause—pneumonia, tuberculosis, gangrene and tumor. Amphoric breathing is a blowing sound, indicating the presence of large cavities with smooth walls, and is generally associated with metallic note on percussion. Râles are abnormal sounds heard during respiration, caused by the passing of the air over mucus. They are dry when they whistle and indicate viscid or scanty secretion, found in catarrhal conditions. Moist râles, which may be small, medium size, or large, indicate a thin, abundant secretion, the size depending upon the size of the bronchi in which they are found. The largest râles indicate cavities. Crepitant râles are usually heard on deep inspiration and are caused by the sudden separation of the walls of the alveoli and bronchioles, previously collapsed. They are heard during the first stage of pneumonia, pulmonary edema, and atelectasis. Hippocratic succussion is a metallic splashing sound heard upon vigorous shaking of the patient, and indicates the presence of a cavity containing air and fluid.

Auscultation also elicits exaggerated or lessened vocal sounds, indicating a change of certain conducting media of vibrations of the spoken voice. Exaggerated vocal resonance is an intensified sound and is known as bronchophony, or pectoriloquy. When it resembles the bleating of a goat, it is known as egophony. Pleurisy with effusion, empyema, which is a purulent pleuritic effusion, and consolidation of the lungs, all destroy the normal lung sounds in both percussion and auscultation. Friction sounds are heard during dry pleurisy and in pericarditis.

Eruptions may be discovered on the surface of the *abdomen*, such as the “rose spots” of typhoid fever and purpura. By lightly palpating the abdomen in such a way as



not to cause contraction of the abdominal muscles, one can make out many conditions which under more vigorous or rough handling would not be apparent. It is sometimes necessary to resort to the use of an anesthetic on account of the rigidity of the abdominal muscles. The examination should be begun with the patient on his back. He should next be placed on one side and then on the other, and gentle palpation practiced in each of these positions. This procedure is of great value in examining for movable kidney and enlarged or displaced liver, kidney or spleen, and tumors. The tenderness due to peritonitis and the localized tenderness due to gastric ulcer and appendicitis are found on deeper pressure. Percussion will demonstrate the size of the liver and spleen and their position, and the accumulation of gases or fluids in the abdomen, all of which are common conditions resulting from a number of pathological changes.

When deemed necessary, we have access to chemical analysis of urine for the presence of albumen, sugar, bile, blood and other abnormal constituents. Microscopic examinations are made for tube casts, epithelium from the bladder, ureter and kidneys, alkaline and acid crystals of the various alkaline salts and uric acid, the presence of tubercle bacilli, gonococci and other pathogenic bacteria.



## CHAPTER XI

### DISEASES AND INJURIES OF THE VASCULAR SYSTEMS

In making a study of the pathological conditions of the vascular systems, it is convenient to consider them as follows:

*The heart:*

- Diseases of valves.
- Diseases of muscles.
- Diseases of pericardium.

*Blood vessels:*

- Diseases of walls.
- Diseases of contents.
- Aneurism and varix.
- Hemorrhage. (See page 58.)
- Tumors.

*Lymphatics:*

- Diseases.
- Tumors.

### THE HEART

**Heart Sounds.**—The heart has two sounds. The first, represented by the syllable *lub*, is heard during systole, and is caused by the closure of the mitral and tricuspid valves and the rush of the blood from the heart through the aorta and pulmonary artery. It is synchronous with the apex beat and carotid pulse. There is also a muscular element in the first sound caused by the contraction of the heart muscles and the impact of the heart against the chest wall. The second sound is represented by the syllable *dub*, and is heard during diastole, being caused by the closure



of the aortic and pulmonic valves, and by the blood's rushing from the auricles to the ventricles.

**Diseases of the Valves.**—Every one of the sets of valves of the heart is subject to two varieties of disease, viz.: (1) Regurgitation or insufficiency, where the valves fail to close and the blood rushes back to the cavity which it just left,

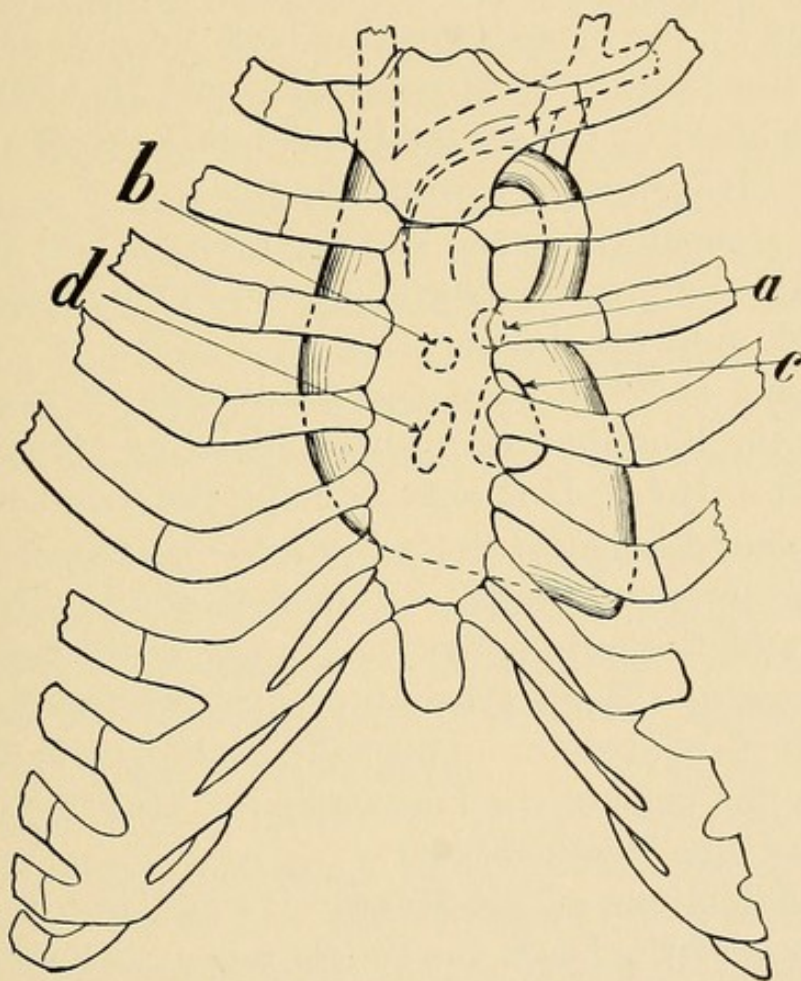


FIG. 9.—SHOWING WHERE THE HEART SOUNDS ARE MORE INTENSE. *a.* Pulmonic valve. *b.* Aortic valve. *c.* Mitral valve. *d.* Tricuspid valve.

and (2) stenosis, or a failure of the valves to properly open, thus resisting the free passage of the blood current.

*Mitral regurgitation* is the most common valvular lesion. It is systolic in time, and is heard most distinctly over the apex of the heart. The murmur is transmitted in the direction of the regurgitated blood or toward the left axilla and angle of the scapula.



In *mitral stenosis* the murmur is presystolic in time (occurring in the latter part of diastole), is heard best a little within the apex of the heart and is not transmitted. The murmur is prolonged and rough in character and increases in intensity as it approaches the first sound and ends in a sharp systolic shock.

*Aortic regurgitation*.—The murmur is diastolic in time. It is caused by the blood's rushing back into the left ventricle from the aorta. It is most distinctly heard over the base of the heart at the second intercostal space on the right side, and is transmitted toward the apex.

*Aortic stenosis* is heard during systole, and the sound is transmitted along the course of the aorta, sometimes to the carotids and subclavian.

*Tricuspid regurgitation* occurs during systole, and is caused by the blood's flowing back from the right ventricle to the right auricle. It is heard during the first sound. The abnormal sound is heard throughout the length of the heart back of the sternum slightly to the left of the median line.

Lesions of the pulmonary valves are quite rare and always congenital. Regurgitation occurs during diastole and stenosis during systole. The sounds are most distinctly heard over the base of the heart, and are transmitted in the direction of the blood current.

**Other Affections of the Heart.**—In addition to the valvular lesions of the heart the following conditions are mentioned and briefly described, so that the dentist may determine whether his patient has a normal heart before the administration of an anesthetic.

*Pericarditis* is an inflammation of the serous lining of the pericardium. It is usually associated with rheumatism or other acute diseases. Pericardial effusion frequently follows. The principal symptoms are pain over the heart, dyspnea and embarrassment of the heart's action during recumbency.

*Endocarditis* is an inflammation of the endocardium or



endothelial lining of the internal portion of the heart. It most frequently attacks the valves, resulting in heart murmurs. Pain, difficulty of breathing and frequency of pulse are symptoms. It is generally of rheumatic origin, although it may occur as a sequela of the acute fevers and of gonorrhea.

*Hypertrophy* of the heart is an enlargement of the organ, usually compensatory, or because of some mechanical obstruction demanding more than normal work, and the muscle develops up to the demands made upon it.

*Dilatation* of the heart usually follows hypertrophy and is evidence that the muscle can no longer do its work and is degenerating. Fatty degeneration is an increased deposit of fat and a corresponding diminution of the muscular elements. Fibroid degeneration is a replacement of the normal histological tissue by tendonous connective tissue.

*Angina pectoris*, also known as stenocardia, is characterized by severe pain in the heart, radiating about the back, shoulder and arm, accompanied with the fear of impending death. It is indicative of sclerosis of the coronary arteries, and is a grave condition.

*The pulse beat* is indicative of the heart's action, and the radial artery is usually selected for examination, although any other artery may be used. The average rate is seventy-two per minute, with a range of from sixty to eighty in health. In children the normal range is from ninety to one hundred and twenty per minute. As old age advances, the heart beat increases in frequency. The pulse is increased in frequency, or accelerated, during muscular exertion, excitement and acute disease, or during exhaustion. It usually increases in frequency as death approaches. Certain drugs, such as ammonia, and alcoholic products, accelerate the pulse.

Retardation of the pulse may depend upon weakness of the heart or valvular disease or undue stimulation of the



vagus by drugs, such as opium, veratrum viride, etc. A quick pulse is a result of shortened systole, and may be accompanied by either increased or diminished frequency. Irregular pulse is found in degenerative changes in the heart muscle, as myocarditis, and in cardiac lesions. We speak of alternating pulse where only every other heart beat is strong. The pulse is large when it is full and bounding, small when it is weak, hard when it is not easily compressed, soft when easily compressed, and thready when it is so rapid and weak as to be scarcely perceptible.

### DISEASES AND INJURIES OF THE ARTERIES AND VEINS

The blood vessels are composed of three coats: (1) Adventitia, an external elastic covering composed principally of white connective tissue with elastic fibers; (2) media, composed of two layers of non-striated muscular fibers, viz., circular and longitudinal; (3) the intima, which is the serous lining of the cavity of the vessels. It is covered internally with endothelium. The structure of the veins is practically the same as that of the arteries, except that they are thinner, offer less resistance, and collapse after being emptied.

**Diseases of the Walls.**—Diseases of the walls may be classified as inflammatory when an acute process begins in the walls or in an adjacent tissue and extends to the arterial wall. When the external coat alone is involved it is known as periarteritis, when the pathological change is in the muscular coat as mesarteritis, and when the serous membrane alone is involved as endarteritis. Maier has described a nodular variety of disease which not only enlarges without, but within, obstructing the lumen of the vessel. When such areas are infected with pyogenic bacteria, suppuration is the result. In addition to the acute processes, pathological changes may be caused by syphilis or tuberculosis, either as a primary or secondary condition.



*Fatty degeneration* of the arterial wall, especially of the aorta and large vessels, develops as a complication of similar degeneration in other organs.

*Calcareous degeneration* or atheroma is a degenerative change of the vessels, usually of the muscular coat, in which the wall becomes hard, resulting in impairment of functional activity. It may be diffused or local. The diffused variety involves all the smaller vessels throughout the body, so that they feel hard under the finger. The usual elasticity disappears from the pulse, and as the disease advances, the impulse is entirely lost. It is a condition found in advanced life or as the result of disease or alcoholism. Since all vessels are similarly affected, the skin of the hands, feet, etc., becomes dry and harsh, and the intellect gradually impaired, so that patients may become helpless invalids for several years before death. Local atheroma is confined to a single artery or organ, such as a coronary artery of the heart. Sudden deaths are more frequently due to atheromatous changes than to valvular heart disease as popularly understood.

*Phlebitis* is an infection of the veins. It may run an acute course, as seen after contusions or infections of the wall directly or secondary to an adjacent pathological change. A sub-acute form sometimes appears after parturition, known as *phlegmasia alba dolens*, popularly known as "milk leg." It is not usually fatal, but may terminate in death. It extends over several months. A later complication is chronic ulcer of the leg, a most painful and annoying condition. The treatment for chronic phlebitis, or a resultant ulcer, is ferric chlorid in twenty-drop doses after eating. For the ulcer antiseptic powder, such as boric acid, answers quite well. Strapping with adhesive straps is excellent. Phlebitis may be caused by gout, syphilis, tuberculosis, or may be a sequela of any of the acute diseases, especially rheumatism. In all varieties of phlebitis the affected parts should be elevated above the heart so



that the pressure of the blood column may be removed. Clots frequently form, especially when the disease is of the sinuses of the brain, in which locality the treatment is prompt operation for their removal.

**Diseases of the Contents.**—Abnormal conditions within the vessel wall or of the liquid contents are considered in works on pathology under the following heads: Thrombosis and Embolism.

**Aneurism.**—An *aneurism* is a circumscribed dilatation of one or more coats of a vessel communicating with its cavity. The causes are trauma, such as a puncture or a rupture of its wall, and dilatation of the wall due to some pathological changes. Aneurisms are classified according to their shape, as tubular, fusiform, sacculated and dissecting; according to their origin, as idiopathic and traumatic; or according to their structure, as true, when the coats constitute the sac, and false, when the coats have been perforated and the aneurismal walls are composed of the surrounding tissues. Other forms are recognized as arterio-venous aneurism, known as aneurismal varix, when the blood passes directly from an artery to a vein. A varicose aneurism occurs when a sac intervenes between an artery and a vein. Varix, or varicose veins, is a dilated condition of veins usually found in the superficial vessels of the leg. The *symptoms* of aneurism are pulsation, fluctuation, thrill, *bruit* and compressibility. A differential diagnosis must be made from tumors of all kinds, which develop from other tissues, and from tumors of the vessels themselves. The course is necessarily chronic and the termination in all deep aneurisms of large vessels is fatal. When aneurisms are found in the vessels of the extremities or upon the surface, proper treatment promises recovery. Fatal termination is due to rupture and exsanguination, to pressure of the sac upon important structures, as the trachea, esophagus, nerves, heart, etc.

The treatment includes compression, manipulation, gal-



vanopuncture, acupuncture, ligation of various kinds, and enucleation. The methods and merits of these various procedures make a long story which may be found in works on general surgery.

**Tumors.**—*Angiomata* are tumors composed principally of blood vessels. Park groups them into three classes: (a) *Nevus*, or birthmark, or port-wine mark, assumes the shape and color of fruit or other object. This is called capillary angioma and is supposed to be due to an increase in number and size of the capillaries and smaller blood vessels throughout the tumor. Angiomata are congenital, or appear soon after birth. They may occur on any part of the body, and when in the skin of the face or mucous membrane of the lips or conjunctivæ are most objectionable, marring the personal appearance of the individual. Otherwise they have no clinical significance, remaining, as a rule, the same size throughout life, though occasionally increasing or diminishing.

(b) *Cavernous angiomata* are sometimes known as erectile tumors, because they contain dilated, tortuous and thickened veins and capillaries. The blood forced into the tumors through the distension results in a denseness not found in the first variety. They are usually subdermal or are connected with the skin, and are quite common in the thyroid gland and liver.

(c) *Circoid aneurisms*, or plexiform angiomata, are composed of dilated blood vessels, are larger in size than either of the former varieties, and, when they are located over a firm bony base, as the scalp or forehead, the line of the vessel leaves a distinctly outlined depression upon the bone. They are generally found over the forehead, face and scalp, and mucodermal junctions, but appear also in other parts of the body. The treatment, as accepted to-day, is of two kinds: First, electrolysis, which consists in introducing into the tumor a negative needle, while the positive pole is on some part of the body, the idea being to coagulate the



contents of the tumor and finally obliterate it by cicatrization; and second, the more radical course of complete enucleation under an anesthetic. This is quite a bloody procedure unless all vessels leading to the involved area are ligated before removal.

### LYMPHATICS

The lymphatics are subject to injury, infections, dilatation, occlusion and tumors. Injuries are seldom so extensive as to require attention, since anastomosis is so complete that several trunks may be severed and no ill consequences result. Lymphangitis, or infection of the vessels, is, as a rule, secondary to an adjacent infection beyond. One or many glands are involved, and in many instances a chain extends toward the thorax. The glands or ganglia become perceptibly enlarged and tender. Acute infections of the glands of the neck are seen in scarlatina, diphtheria and acute diseases about the mouth, abscesses of the teeth, pyorrhea, etc.

Chronic enlargement of the glands is seen most frequently in syphilis and tuberculosis. Syphilitic lymph nodes in the neck, groin, axillary and epitrochlear spaces are common conditions. Abscess of the glands results from any acute infection in any part of the body. Tuberculous enlargements of the glands frequently suppurate and require incision.

Obstruction of the lymph channels follows infections producing uniform enlargement of a part or extremity known as elephantiasis. This enlargement of a leg may cause it to reach many times its normal size.

*Treatment* for acute infections includes cold or heat, as may be selected, with counter-irritants, such as iodine and the thermocautery. Suppurating glands should be incised, curetted and packed. The so-called scrofulous gland, known to the laity as "King's Evil," is either a tubercu-



lous or syphilitic infection. Syphilitic glands should not be incised.

*Lymphangioma* resemble angioma in structure, the difference being that one involves the blood vessels and the other the lymph vessels. The most common form, and that which is most frequently found in the field of dental operations, is that form developing from the surface of the tongue in papillæ varying in size and number. When they are large and numerous they abnormally enlarge this organ and cause the condition known as macroglossia, or, when the lip is involved, as macrocheilia.

*Treatment* consists in the use of electrolysis, as described above, but the electric current does not coagulate lymph as it does blood, the benefit coming from the absorption of the tissues. Aspiration, followed by injections of iodine, is frequently successful. When these methods fail, or when prompt result is desired, extirpation by the knife is followed by repair and cure. Macroglossia and macrocheilia are best treated by radical operation.







PART II  
ORAL SURGERY







## CHAPTER XII

### GENERAL INTRODUCTION

Introductory to the study of the mouth, a review of some points of its anatomy and general pathology will prepare the student to more readily appreciate the pathological conditions of this cavity as they are found in practice.

Pathology is the same, whether of the mouth or of other parts of the body; hence, to understand general tissue changes means an appreciation of mouth lesions. There is a difference, however, since the oral cavity contains more diverse and complex tissues than any other part of the body.

The many functions performed in the mouth make the demands upon the various tissues more exacting, yet the repair by natural and artificial means is vastly better than in any other of the complex visceral systems of the body. Its proximity to so many structures of major importance, such as the accessory sinuses of the skull, the brain, the organs of respiration and deglutition, and the anatomical structures connected with the special senses, makes the care of the mouth of great importance.

The mucous membrane is a light pink in children and in anemic persons. It is also light in color in old age. During vigorous adult life it is a deep pink, approaching a red. The blood supply which controls the color is also influenced by inflammatory changes about the mouth, which, in turn, influence the blood current, producing congestion; or a hyperemia may result from a reflex vasomotor disturbance due to remote changes, such as neuralgia, etc. Localized



discolorations of the mucous membrane over the alveolar process are suggestive of localized internal infections of a subacute or chronic character, and the teeth should be thoroughly examined in such cases.

**Disturbances Due to Dentition.**—Dentition is a frequent cause of general disturbance. From the fourth to the eleventh month children begin to cut their teeth, contemporaneous with which is the secretion of a very largely increased amount of saliva. "Playthings," alternately in the mouth and on the floor, contaminate the saliva with all varieties of microorganisms which, when taken into the stomach, cause indigestion and intestinal derangements, such as diarrhea, etc.

Symptoms of a general nature which are the result of difficult dentition are restlessness, fretfulness, disturbed sleep, occasional elevation of temperature, vomiting, colic, and diarrhea. Any of the infective fevers may develop during teething, due to the absorption from the alimentary canal of the germs which are taken into the system by the excessive salivation.

Many nervous manifestations have been recorded as dependent upon reflex spasm, caused by the pressure of a tooth in its effort to pass through the soft tissues overlying the alveolar process. If these nerve symptoms are very severe and there is evidence of many teeth coming through at the same time, it is good practice, when the symptoms persist, to incise a very highly distended gum over an erupting tooth.

It is a curious fact that the tooth makes its way through the bone without causing any reflex nerve symptoms. It is also a well-known fact that teeth which do not pass through the alveolar process in the normal direction, the course being diverted, produce many varieties of reflex neuroses, the cure of which is only effected by the removal of the offending tooth. (Attention to this has been called in the pages on "Reflex Neuroses.")



Many skin lesions are observed during the period of dentition, due either to reflex neurosis or to intoxication following intestinal fermentation, viz., dermatitis and eczema; and other eruptions of the face and neck are directly traceable to the excessive flow of saliva from the mouth to the skin.

Owing to the presence of the great number of bacteria found in the saliva of teething children, their diet should be very carefully considered and an effort should be made to eliminate as far as possible materials furnished to the baby for teething and amusement, which might contain great quantities of these germs. While it would be a difficult matter to entirely avoid such practices without constant watching, the danger would be greatly reduced by permitting children to use only such playthings as can be sterilized.

**Oral Hygiene.**—Cleanliness of the mouth is of the greatest importance if the vitality of the teeth is to be prolonged and if those various constitutional conditions which are undoubtedly traceable to mouth diseases are to be avoided. This subject presents itself under several heads: first, mouth lesions traceable to constitutional diseases, and, second, constitutional or systemic pathological changes dependent upon lesions within the oral cavity.

Under the first head are found the various ulcerative conditions, to be considered under the head of stomatitis, also bleeding of the gums associated with rickets, scorbutus and cretinism. Mouth lesions are not uncommon as a sequel to typhoid and the eruptive fevers.

Users of tobacco and alcohol, and people who are careless about using a toothbrush regularly are liable to have mouth lesions. Pyorrhea and other ulcerative conditions are frequently found in individuals who have syphilis as an underlying factor or who have a tuberculous lesion in some other part of the body.

General diseases are so frequently the cause of lesions



in the mouth that the subject has attracted a great amount of attention during the last few years. Miller, in his wonderful studies of the bacteria of the mouth and their consequences, has placed this subject upon a scientific basis. Black and many others have made innumerable cultures of the contents of the oral cavity and have found that the saliva possesses toxic properties, due to the presence of microorganisms. Many of the bacteria producing general diseases are constantly found in the mouth. Frankel's pneumococcus, several varieties of streptococci, as well as diphtheritic bacilli, are sometimes found in the mouths of healthy persons.

In all cases where any variety of ulceration is found, such as pyorrhea, etc., the bacterial culture is carried on more rapidly, and constitutional infection necessarily results where the vitality is reduced. These bacteria are taken into the stomach, producing fermentation and absorption, and consequent constitutional symptoms.

Netter found that ten per cent. of all mouths contain some variety of streptococcus, and that the diplococcus of pneumonia is found in fifteen per cent. of healthy mouths. Shriver states that 75 per cent. of apical abscesses contain the diplococcus of pneumonia, and Valpain produced septicemia by inoculating animals with saliva from healthy men.

The constant presence of bacteria and their products in the mouth sometimes exerts a deleterious influence upon the normal mucous membrane, inhibiting taste and appetite and producing a condition spoken of as "disordered stomach."

Many cases of infection following dental operations are due to self-infection, the open wound left by the extraction of a tooth furnishing a convenient point of entrance for bacteria. Death from septic causes is not uncommon after major operations on the mouth, the most common condition being septic pneumonia. One of the commonest and most



important effects of carious teeth is the enlargement of the cervical lymphatic glands, and tonsillar enlargement may be due to the same cause. Ludwig's angina, characterized by diffuse cellulitis of the region between the lower jaw and the hyoid bone, is in some cases due to infections from a carious tooth. The bacteria of the mouth may also produce remote infections, such as malignant endocarditis, osteomyelitis, etc. The mouth may be the means of transmitting disease to others, the transmission of syphilitic virus by means of saliva and instruments employed in the mouths of syphilitics being of frequent occurrence.

Alveolar abscess in its various forms results in practically all of the bone destructions not traceable to the exanthemata, constitutional and specific diseases. Symptoms of constitutional infection resulting from mouth intoxication are mild elevation of temperature, rigors, loss of appetite and consequent loss of weight, languor, and headaches, which in some instances may persist for many months.

In a recent case, a very suspicious sinus, following the extraction of an upper lateral, produced the above conditions, the most prominent symptom being persistent headaches for four years. The correction of the carious condition removed the source of infection and restored the patient to perfect health. It is a well-known fact that a large proportion of malignant diseases of the mucous membrane of the mouth and the maxillary bones are caused by neglected teeth. Sharp projections of enamel excoriate or abrade the mucous membrane every time the tongue or mandible is moved, and the constant irritation furnishes a field for absorption or is the cause of cell proliferation, and an epithelioma results.

The question of development of the teeth, or rather failure of the teeth to properly develop, resulting in defects of various types which have been classified under the heads of atrophy, indented or Hutchinson teeth, is one which has attracted attention for a great many years. It remained



for Dr. G. V. Black of Chicago, in his very exhaustive study of the subject, to disprove the theory of Hutchinson teeth as diagnostic of hereditary syphilis. Indeed, Dr. Black points out that Magitot, a French surgeon, questioned the correctness of Hutchinson's statement regarding the subject, and that Hutchinson himself yielded the point so far as to say that inherited syphilis was a frequent cause, but for many years he had held that this type of teeth was always caused by inherited syphilis.

The most frequent cause of defective teeth, according to Black, is improper feeding of children, which will result in the cupping of teeth or an atrophy of the middle lobe. Serious sickness at any given time in a child's life may result in a defect in the line of all of the teeth, advanced up to a certain point of development, and which will be shown on the crowns of these teeth, as illustrated in Fig. 10.

The exhaustive researches made by Black, which appear in his work on operative dentistry, place the subject in such a position that no one dares to question the correctness of his statements. He says:

"I have followed this subject pretty carefully ever since Hutchinson wrote, adding observation after observation until I have arrived at the conclusion that there is no special form of disease that is especially blamable for this affliction, but that any form of disease which seriously interferes with nutrition is liable to bring about this result, i. e., that it is not the particular form of disease, *but that it is the condition of malnutrition that is the cause*, no matter what the disease which has induced that condition. I have seen several cases of typical Hutchinson teeth that were certainly in no way connected with a syphilitic taint of any kind."

**Complications of Extraction.**—Occasionally there results from extraction of teeth certain major conditions requiring extraordinary measures for their management and control.

During extraction of teeth many accidents occur requir-



ing the services of a surgeon. Fracture of the mandible or a considerable portion of the maxilla may occur, requiring replacement or wiring. Slipping forceps or excavator may perforate important structures and injure an artery or nerve, resulting in dangerous complications. Dislocation of one or both sides of the mandible may occur. Probably the most disastrous complication of extraction is to have the extracted tooth, or more likely a root, slip from the forceps, drop into the pharynx and be carried along with the inspired air into the air passages. Such a disaster requires prompt tracheotomy or death may follow within

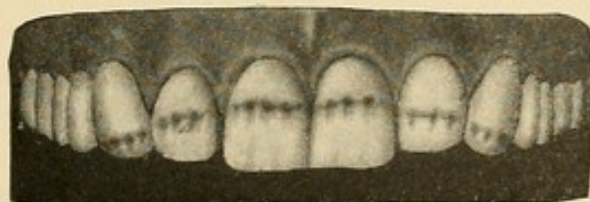


FIG. 10.—ATROPHY MARKS ON TEETH. (Dr. Black.)

a few hours. When a tooth or root is swallowed it need not cause alarm, since it usually passes through the alimentary canal without difficulty. Other complications, such as injury to the nerve, lip or tongue, by the forceps or an irregular tooth, perforation of the antrum by a tooth's being pushed forward by the forceps, or forcing a root into an abscess cavity, are not infrequent. Such complications may be followed by severe and lasting changes unless properly treated.

Under the head of antral disease, extractions have been given as a cause, and in the chapter on fractures it is learned that extractions may destroy the continuity of the mandible. Hemorrhage following extractions, especially of molars, is sometimes alarming. In one case reported, exsanguination and syncope was the hemostatic that stopped the flow of blood and saved the patient. In "bleeders" extractions should not be made until the patient is told of the danger if he does not already understand it.



Almost every dentist sees severe hemorrhage after extraction, but ordinarily experiences little difficulty in controlling it.

A most satisfactory method of controlling hemorrhage is to make a pad large enough to cover the entire lacerated surface, and thick enough to extend well above the remaining teeth. Place it in position and have the patient close the jaws. The continued pressure controls the bleeding. If pressure fails, plug the sockets with cotton saturated with adrenalin chlorid solution.

**Reflex Neuroses from the Teeth.**—From time to time, during the past one hundred years, surgeons and dentists have written articles upon the subject of reflex neuroses, with special reference to the irritating factor's being some lesion in the alveolar process. Richter, in 1795, recognized the connection between dental irritations and affections of the eye and ear, and is very emphatic in his opinions. In 1817, Bier reported a case where a contracted visual field was entirely corrected by the extraction of a carious tooth. Jonathan Hutchinson, of London, was the first to prepare a systematic paper upon this subject, and he reported many cases of defective vision, both in adults and infants, that were entirely cured by the correction of pathological conditions found in the mouth. Wright reported a corneal ulcer which was cured by the extraction of a carious upper molar on the same side. Deafness and other impairment of hearing have been corrected after the removal of impacted teeth and other abnormal conditions. Trismus, or spasmodic ankylosis, is, in the majority of cases, caused by impacted third molars and may be due to other dental irregularities and diseases.

The author has recently operated upon a case of impaction where four teeth were found in various parts of the mandible and maxilla in irregular position in a man aged about forty, who had been suffering for several years with a condition very much resembling writer's cramp of the



right arm, with a special wrist drop, the symptoms of which disappeared after the repair of the mouth from the operation. Another case in practice is that of a woman about thirty years of age who was suffering with a very severe form of neuralgia in the neighborhood of the right hip, which might be likened to sciatica. Shortly after the case was seen she made a call upon her dentist to have her teeth put into proper condition. An abscessed tooth was found and treated and, immediately thereafter, the pain in the hip entirely disappeared. Several of such cases have been reported during the past twenty-five years.

More recently many papers and one book have appeared on the subject of insomnia and nerve strain dependent upon ulcerations about the teeth and impacted teeth. Upson, in his book, reports his investigations in an insane asylum of Ohio, stating that he found quite a number of the inmates suffering with impacted teeth, alveolar abscess, pyorrhea, and other ulcerative conditions in the mouth, the correction of which entirely restored their reason so that they were cured and discharged from the hospital.

Dementia precox, melancholia, mania, hypomania, hysteria and neurasthenia are all included in the list of general conditions occasionally dependent upon impaction of teeth, requiring operation. The investigations carried on by physicians interested in the juvenile courts have demonstrated that many cases of degeneracy, as indicated by thieving and other acts of incorrigibility, have been due to impacted teeth, and, where no other cause can be found, it is now customary to suspect the teeth and to have X-ray pictures taken of the face.

In a recent paper by Van Doorn, a number of cases of insomnia, nerve strain and other hysterical manifestations are referred to which were found to be due to the improper filling of root canals and, in an instance or two, the death of pulp after the filling of a tooth had so affected an



individual as to produce general neurosis of a marked type.

Muscular spasms in the form of torticollis and contraction of the masseter or temporal muscles resembling true tetanus have been reported, the muscles remaining in a condition of tonic spasm until the irritant was removed. Clonic spasms of muscles and groups of muscles are attributed to the same cause, and Ramskill reports one case of epilepsy due to a decayed molar tooth.

Neuralgias of the shoulder, arm, neck and ear and of every part of the head have disappeared after the removal of carious or suppurating teeth or abscesses of the roots of teeth. The pressure of artificial teeth against a nerve terminal caused, in one case reported by Mr. Bell, a severe neuralgia of the forearm, which disappeared after the pressure was removed. Salter states that a young woman suffered a paralysis of the arm from a carious wisdom tooth, and upon its extraction the arm power immediately returned. Paralysis of the seventh nerve, or Bell's palsy, and paralysis of muscles remote from the face have resulted from diseases of the teeth.

Nutrition has been perverted as a result of irregularly developed teeth, resulting in superficial ulceration of the tongue and cheek, and even of the skin over the neck, shoulder and arm. Deafness, visual disturbances and pupillary irregularities, which appeared to be dependent upon grave lesions in the brain, promptly cleared up after a correction of defects in the teeth.

Some most troublesome complications may be associated with the eruption of the molar teeth. This is especially true of the third molar, since in fifty per cent. of cases there is scant room for the tooth to erupt, and its course through the alveolus is at variance with the normal, making pressure upon important nerves and resulting in temporary ankylosis of the mandible. Impaction of a lower molar may cause infection, resulting in abscess formation and



ulceration through the skin over the angle of the jaw, and the resulting sinus cannot be closed until the offending tooth is removed. A probe passed through the opening from the interior usually comes in contact with the tooth, thus readily making out the true nature of the trouble.



## CHAPTER XIII

### ALVEOLAR ABSCESS AND ITS MORE GRAVE CONSEQUENCES

The causes which may be factors in producing extension of pathological changes in the teeth may be enumerated as infective and non-infective. The *non-infective* conditions are such factors as arsenic left in the periapical tissues after treatment, the filling of a root canal with an irritating substance, or the protrusion of a canal filling through the apical foramen. A frequent error in this direction is made following the adjustment of a crown where the drilled hole, instead of following the root canal of the tooth, passes out through the side and into the bony tissue, the operator assuming that he is entirely within the tooth structure. Arsenic left in the tissue in such condition cannot be removed and must necessarily result in a very low grade of osseous disintegration, which will eventually destroy considerable tissue.

A second variety of *non-infective* disease is that following cystic degeneration of the root of a tooth around the apical foramen. In this instance the little sac which is so frequently seen upon the root of a tooth develops where there is little resistance to the accumulation of serum in the bony tissues. It is quite infinitesimal in the beginning, being increased in microscopic quantities, as occurs in all tissues which are undergoing the process of repair. In other words, the serum is that of repair which, instead of making its escape as we see it in surface wounds, accumulates in some instances to a considerable amount. In a recent case it was the size of an English walnut, encroach-



ing upon the nose, antrum and the external plate, causing considerable of a tumefaction over the right side of the face. Operation showed that the roots of the lateral and cuspid projected into the cavity for about one-eighth of an inch, the vessels and nerves of the apex of the teeth being entirely destroyed and the roots being roughened. In another instance, three lower incisors and the right cuspid projected into a cyst the size of the last joint of the thumb.

A frequent cause of pyorrhea and abscess of the mandible in the neighborhood of the angle is the almost constant presence of putrefactive bacteria in the pocket which is always found immediately back of the posterior lower molar. As the corresponding upper molar articulates with this tooth on its posterior cusp, the tendency is to push foods back into this pocket.

*Infective* diseases include all of those more serious destructions of bone included under the head of alveolar abscess and necrosis.

The course of extension of disease to the tissues around the teeth depends upon the cause, and in those cases where there is no infection the development must be very slow, extending over a period of several years, the tumor gradually increasing in size and, in many cases, spontaneously opening or being incised by the surgeon.

In the infective varieties, the course depends upon the variety of germ which is found as a causative factor. In some instances, a very insignificant alveolar abscess develops quite rapidly about the root of a tooth, spontaneously opens, and a sinus is left, which may be without pain or marked symptoms—indeed, attracting very little attention. This variety is dependent, as a rule, upon a chronic form of germ, such as the staphylococcus pyogenes aureus. If the disease is dependent upon streptococcic infection, it runs a more rapid course, involving a great area of bone in the course of a week.

A girl aged ten had a decayed first molar which was



treated for what appeared to be an acute disease confined entirely to the tooth. In the course of forty-eight hours the infection had broken under the periosteum on the lingual side of the mandible. When it was incised one week later, about four ounces of pus of very offensive character and of a greenish color escaped and the inferior margin of both sides of the body of the bone was bare from the angle to

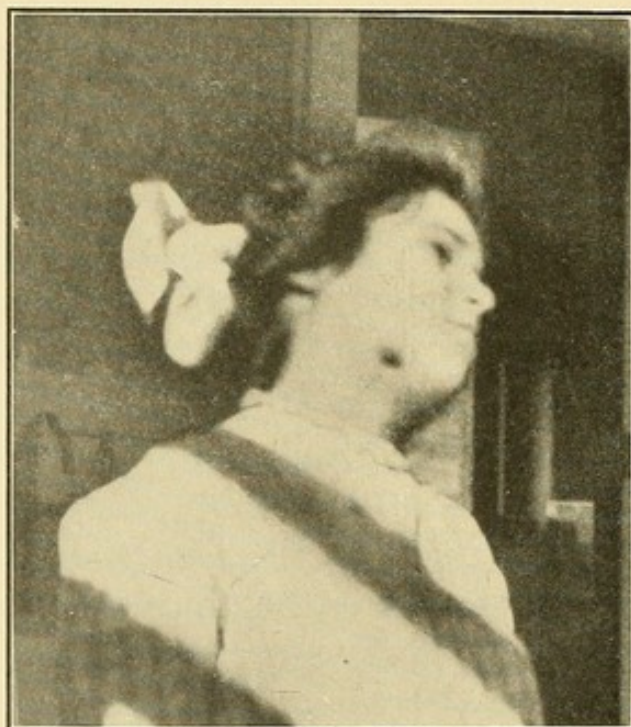

FIG. 11.—CASE OF ALVEOLAR ABSCESS.

the mental foramen. Such a lesion is, of course, dependent upon streptococcic infection. (Figure 11.)

That alveolar abscess is the cause of many of the grave and more serious pathological changes about the oral cavity, there can be no doubt. It has been ascribed by many authorities to traumatic pericementitis, resorption of the roots of permanent teeth and death of the dental pulp and the resultant apical pericementitis.

**Pathology.**—Whether infection really comes from the tooth cavity or from the apical tissues, the course is about the same. The product of the decomposition forces its way through the root canal to the bone, where it becomes



active, resulting in abscess formation. The pressure distends the peridental membrane, which thus becomes the wall of the abscess. The first change is quite small, beginning in the form of an infiltrate, which later liquefies. This change involves the tissues immediately around the apex of the root, either destroying or promoting the resorption of the bone. The process of the destruction is in the direction of the least resistance from the root involved, which appears to be on the buccal side of the alveolar abscess. The destruction continues to the surface of the bone, when external manifestations of the abscess are present, that is, a fluctuating tumor. The process of destruction is in proportion to the activity of the germ responsible for the disease. The liquid, after escaping through the compact structure of bone, goes underneath the periosteum and, in the case before referred to, the lower half of the body of the right side of the mandible was involved. Eventually it breaks through the periosteum into the surrounding tissues and finally through the mucous membrane into the oral cavity in maxillary disease, and from the body of the mandible through the skin anywhere from the symphysis to the angle, being deflected downward by the platysma muscle and its fascia. Opening of the abscess cavity either spontaneously or by incision naturally leads the inexperienced practitioner to believe that he has reached the end of the disease. If, however, the sinus persists, we have then established what is known as a chronic alveolar abscess.

A fact not to be forgotten in consideration of all diseases of the bones of the face, where a fistulous opening which has persisted for a few months is found, is that a tooth must be reckoned with as the cause. If a tooth has been extracted and the wound does not heal and the sinus does not close, there is undoubtedly the root of another tooth denuded of its membrane and standing bare in the cavity.

Surgeons recognize low-grade chronic infections as a



cause of serious constitutional conditions, such as headache, usually intermittent in type, loss of appetite, loss of weight, and general impairment of vitality. The dentist should have in mind the fact that an alveolar abscess, even without pain and without extensive discharge, can produce the same variety of symptoms. The absorption of the smallest quantity of toxins from an infected area may produce very perceptible constitutional disturbances.

It is proper here to call attention to that variety of alveolar abscess which has for its only method of exit the root of a tooth through the pulp chamber. In such cases considerable of a cavity may be found around the apex, with symptoms enumerated above. The amount of destruction of bone ranges from the smallest cavity to the complete destruction of the mandible. In one instance a low form of destruction extending through a period of months, destroying little bone, occurs; in others a great quantity of bone is destroyed before the infection can be controlled.

It often occurs, after the extraction of a tooth where considerable destruction has taken place, that the socket is emptied of its usual blood-clot and that the labial or the buccal process, or both, is denuded of periosteum. This means that the blood supply has been cut off from the bone and that if it is left without operative interference it will exfoliate, the size of the piece of bone depending entirely upon the limitation of blood supply.

In these cases there is usually considerable suppuration, possibly parasitic infection and always saphrophytic putrefaction. If the case has extended over a period of a few weeks, possibly five or six, there will be much granulated tissue developed around the margin of the wound, which is Nature's effort to build up a granuloma sufficiently large to cover the bone. Such granulation tissue is called proud flesh, and may be mistaken for a polypus, fibroma or papilloma.

Treatment in such cases consists in one of two proce-



dures: First, a radical operation by chiseling and cutting away the dead bone back to the point where it bleeds, when the remaining periosteum and soft tissues are approximated and the cavity obliterated, if possible, with sutures; second, treatment with antiseptics and packing, a conservative and expectant plan, and one which is adopted too frequently. In this event, there will eventually be exfoliation of that part of the bone which has been deprived of its nutrition. These fragments may be removed without any difficulty, or occasionally it may be necessary to enlarge the opening through the mucous membrane, when the fragment which is found detached may be removed.

The question as to what occurs after an alveolar abscess has existed for considerable time and the bone has been destroyed for an area of about one-quarter of an inch upward from the root of the tooth, one-half an inch long, and one-quarter of an inch horizontally, is one for speculation. We have already stated that it is in just this variety of cavity that blood-clot organization occurs, yet we also see cases where there is a sinus which remains open for several months or a year, that will open, close and spontaneously open again after a period of possibly months or years, to again close in the same way and possibly open again. This is not uncommon in the management of old tuberculous joint diseases. The explanation, where this occurs, is that, while the external orifice may close, there is a small cavity left somewhere, and since its wall is neither covered with epidermis nor epithelial cells, but with granulation tissue, it must necessarily throw out a little of the serum of repair as well as a few leucocytes and reparative cells. As this fluid is in small quantities and is retained, it will eventually distend the original cavity, force its way along the sinus, and finally break through at the point of original exit.

It cannot be claimed in any of these cases that such a cavity would fill in with new bone. After the extraction of



teeth in the alveolar process, there is not only blood-clot organization but an approximation of the alveolar ridges, and eventually an absorption and collapse of the entire alveolar framework, so that it is brought nearer to the central canal of the bone in the case of the mandible and nearer to the floor of the antrum and the nose in the case of the maxilla.

It is believed that blood-clot organization does take place and that real bone tissue is thrown out to fill in these

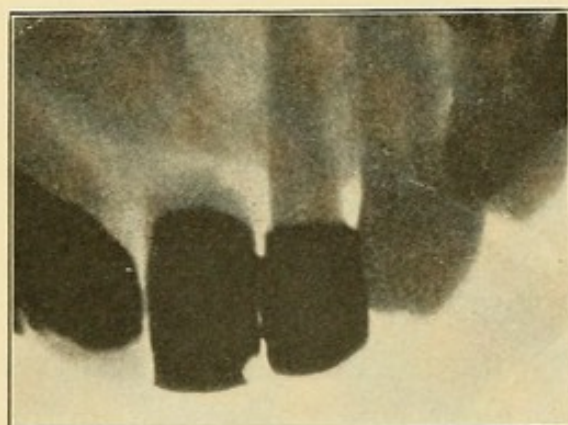


FIG. 12.—X-RAY OF ALVEOLAR ABSCESS

spaces just as surely as new bone is thrown out after a fracture. The conduct of the blood cells is based upon the amount of stimulation they receive, and there is no reason why the same amount of new formation cannot occur in an injury to a bone as in a fracture of a bone.

Exostoses are undoubtedly due to such an injury to the external surface of a bone as the displacing or detaching of the periosteum and increasing the piling up of new bone material in a conical shape.

Figure 12 shows an X-ray picture of a chronic alveolar abscess. It will be observed that the cavity extends from the root of the central through the alveolar process above the crown. The root of the tooth, which is found within the abscess cavity, is considerably atrophied. It will also be observed that there is a very small space on the opposite side of this tooth, showing that the entire apex of the root is denuded, extending into the center of the cavity. The treatment for such a case is the extraction of the tooth, which alone, in some instances, might completely cure the disease. It is better, however, if a prompt recovery is desired, to curette away that part of the alveolar process labial to the tooth which has been extracted and sufficient



of the process through the tooth which was formerly removed, to allow the periosteum to collapse back into the depression, thus obliterating it. Of course, it is necessary to curette the entire cavity so as to make it bleed freely. No packing should be used.

Figure 13 shows an alveolar abscess following the infection of a root canal, which occurred after the tooth

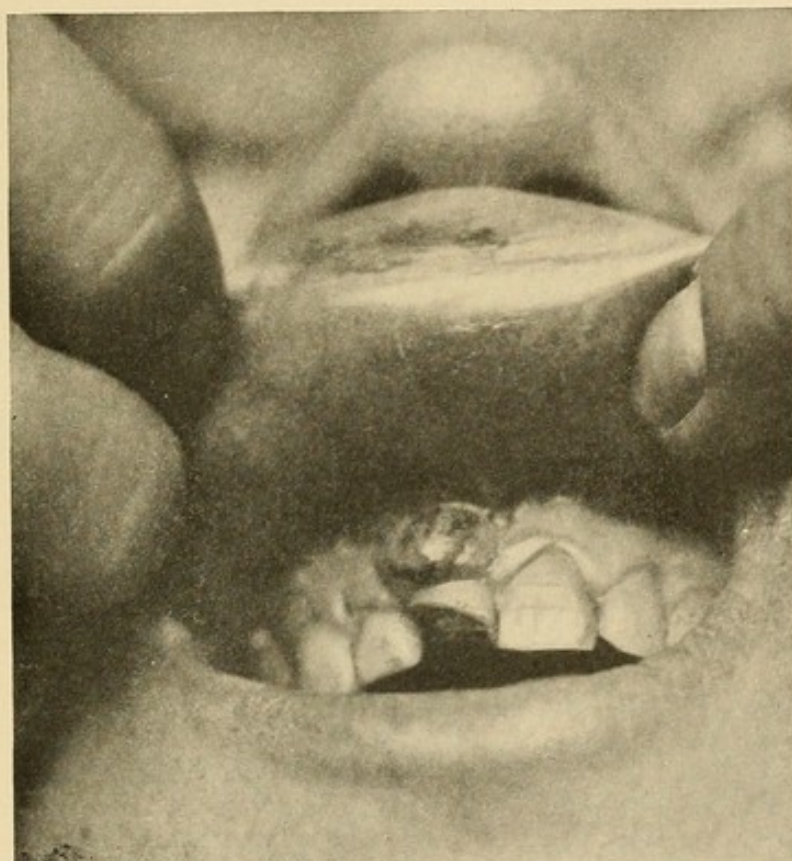


FIG. 13.—GRANULATION FROM ABSCESS RESEMBLING PAPILLOMA.

had been broken off. The case illustrates the characteristic granuloma which is found around a canal leading into denuded bone. It might be mistaken for an epulis, papilloma, or even more grave varieties of tumors. An opening is always found in the center of a granuloma which leads into dead bone. This case was cured, however, without the loss of the tooth.

**Alveolar Abscess of the Maxilla.**—Attention must be called to the difference in the course of an abscess from a tooth in the mandible and from one in the maxilla. Those



of the maxilla run a more satisfactory course naturally, because the drainage from the diseased area is better. Where the disease is in the mandible, there is no drainage from the dependent or lowest point of the cavity. Drainage must be upward, out through the alveolar mucous membrane or through the skin below the body of this bone.

If the root of the tooth affected is in proximity to the maxillary sinus, this cavity will be affected, resulting in antral disease. In many of these abscesses the bony floor

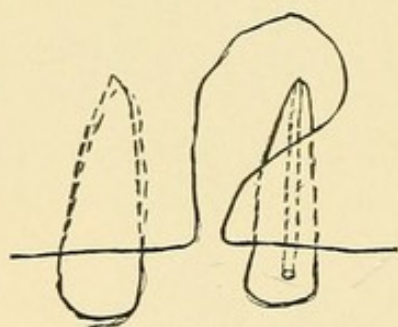


FIG. 14.—THE MOST COMMON ALVEOLAR FISTULA OF THE MAXILLA. Usually persists for years until the tooth is extracted, and the bone on the buccal side removed.

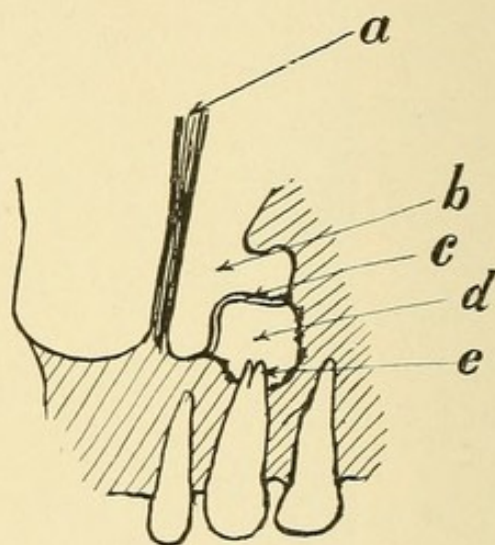


FIG. 15.—METHOD OF ESTABLISHMENT OF NASO-ORAL FISTULA. *a*, nasal septum; *b*, nasal cavity; *c*, membranous floor; *d*, abscess cavity; *e*, denuded root of tooth.

of the antrum is destroyed, yet the antral cavity is not entered because the membranous floor is still intact. In alveolar abscess of the mandible it is not uncommon for the abscess to break through the cheek. It is all a question of dependent drainage.

The second serious consequence of alveolar abscess is a more grave variety of destruction of the maxillary bone, when the nasal floors, membranous and osseous, are destroyed, leaving a naso-oral fistula. In this condition we have a very troublesome complication, making it necessary for the patient to keep the opening packed constantly, re-



quiring removal of the packing after meals, and withal leaving the mouth in a very unsanitary condition.

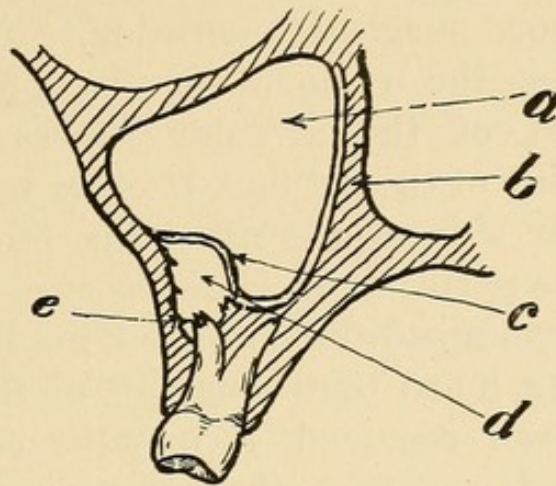


FIG. 16.—ABSCCESS. *a*, antral cavity; *b*, naso-antral septum; *c*, membranous floor of the antrum; *d*, abscess cavity ready to rupture into the antrum; *e*, root of tooth denuded and cause of disease.

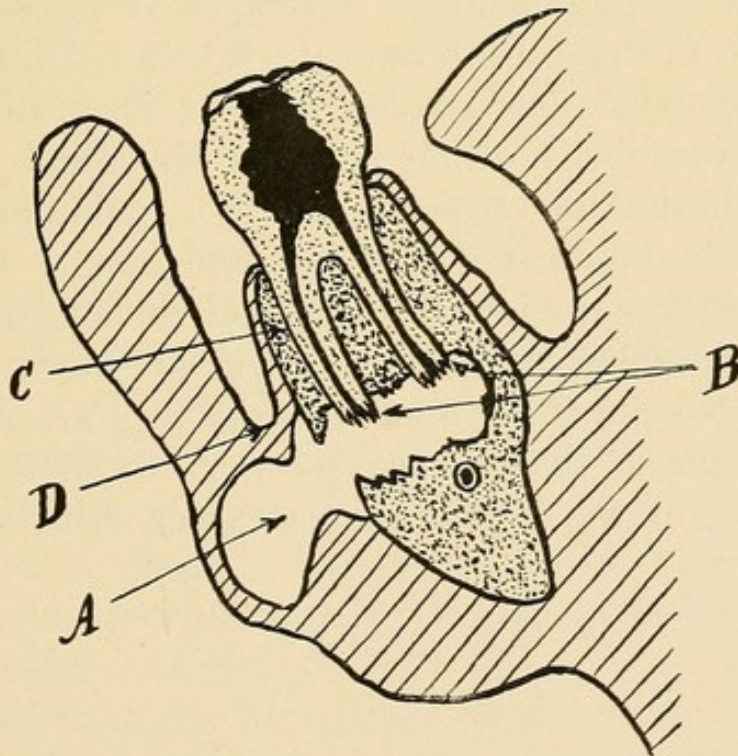


FIG. 17.—ALVEOLAR ABSCESS OF THE MANDIBLE. *A*, abscess cavity; *B*, roots of tooth; *C*, external alveolar plate to be removed with tooth; *D*, point of incision.

**Treatment.**—Assuming that the dentist has made an effort to close an alveolar fistula by cutting off the root of the tooth and by draining through the tooth, and



that neither of these methods has resulted in a closure, and that the process of disintegration of the bone has extended through a period of several months, the case is one for major surgical operation. The operative treatment includes the removal of the offending tooth and of that part of the alveolar process external to the tooth on the side of the fistula. If other teeth have been removed on either side of the offending tooth which has been extracted, the periosteum should be carefully dissected away from the bone up to the fistula. This is for the purpose of preserving it, so that, after all of the bone up to the fistula has been removed, it may be collapsed back against the posterior wall of the cavity and in this way serve as a flap, so that repair may take place without further exfoliation.

The later management of an alveolar abscess varies greatly with the different operators. It is the author's practice to convert an alveolar abscess or a suppurative condition of the bones, either acute or chronic, into a sterile field by the use of strong antiseptics, after a thorough removal of all devitalized and infected bone. Then it is closed by either suturing the gingival mucous membrane together across the cavity or making pressure upon the outside between the cheek and the bone with a considerable piece of gauze, so that the cavity may be obliterated by the collapsing of the membranous walls against the floor.



## CHAPTER XIV

### MOUTH LESIONS

*Stomatitis* is an inflammation of mucous membrane and, secondarily, of other structures of the mouth. The different varieties are undoubtedly due to bacterial invasion, rendered possible by reduced vitality. It is a term very loosely and generally used by writers to include any variety of irritation or inflammation or congestion of the mucous membrane and, secondarily, of the deeper structures. Oral pathologists and pediatricists have not agreed upon a uniform and systematic classification, the basis of which has been the remote etiological factors. Many conditions produce similar lesions in the mouth, the remote factor having passed and a local inflammation remaining to be treated. Again, mouth lesions form one of many symptoms of constitutional diseases, as typhoid fever, scarlatina, measles, syphilis, etc. We further observe that what have been classed as distinct diseases are only different stages, one passing over into another, i. e., catarrh may become ulcerative and finally result in bone exfoliation; herpetic ulcerations may coalesce into larger ulcers, resembling the primary ulcerative variety.

To simplify, and at the same time present a classification sufficiently clear to answer all requirements of the student of dentistry, the following is selected. It is based upon the earliest lesion of the various diseases, which, as has been said, may become a second form as the disease advances. The word *aphtha* is used by both Holt and Smith (pediatricists) as a synonym of *herpes*, but dictionaries say that it



is a synonym of *thrush*. Burchard says: "Thrush and aphtha are different diseases." Holt, in a personal letter, says: "It (aphtha) is a general term," and for this reason it is not used in this book as being a primary disease.

The following classification appears to be most acceptable. See also the differential table later in the chapter.

Local acute stomatitis.....	{	(a) Catarrhal.	{	1. Canker sores.
		(b) Ulcerative.....		2. Alveolar ulcerations.
		(c) Herpetie.		
		(d) Mycosic.		
		(e) Gangrenous.		
Symptomatic mouth lesions...	{	Acute Constitutional.. Diseases.	a. Measles.	
			b. Diphtheria.	
			c. Scarlatina.	
			d. Typhoid.	
	{	Chronic Constitutional.. Diseases	a. Tuberculosis.	1. Chancre.
			b. Syphilis.....	2. Patches.
				3. Gumma.
				4. Ulcerative gin- givitis.
	{	Drugs.....	a. Mercury.	
			b. Lead.	
			c. Iodids.	
			d. Pilocarpin.	
			e. Iodin.	

Mouth lesions associated with skin diseases.

Vincent's angina.

## LOCAL ACUTE STOMATITIS

### (a) CATARRHAL STOMATITIS

This condition is an acute disease beginning in the mucous membrane, characterized by redness, with injection and dilatation of the capillaries, with a tendency to oozing and swelling, especially of the alveolar mucous membrane. It may include the lips, tongue and other parts.

**Symptoms.**—Local elevation of temperature is marked, the mouth is hot, the tongue coated, edges red and papillæ prominent, with fissures in the tongue as a later manifesta-



tion. Pain is quite severe and tenderness so marked that solids and even hot liquids cause the patient great distress. The normal salivary secretion is markedly increased, being so abundant as to trickle from the mouth and soil the clothing. There is usually induration of the neighboring lymphatic glands during active symptoms. Constitutional symptoms are mild. The causes are some mechanical or chemical irritations from decayed or neglected teeth.

**Treatment.**—The treatment is simple and consists in removal of the cause and correction of unhealthy conditions about the teeth. The teeth should be thoroughly cleansed and kept clean. The use of boric acid or other antiseptic washes is usually followed by recovery. The bowels should be emptied and nutritious foods given.

#### (b) ULCERATIVE STOMATITIS

Two forms of ulceration may be considered, the first being the most common.

##### 1. *Canker Sores*

These may be associated with gastrointestinal disturbances or they may follow trauma. They have also been known to depend upon excessive acid saliva. Cases of canker ulcers, developing periodically, have disappeared entirely after defective teeth have been filled or removed. They appear on the cheek, tongue or gums as depressed ulcers, the base is dark and rough and has a hyperemic zone. They are sensitive at all times and painful to the touch, especially when eating.

##### 2. *Ulcerative Stomatitis or Alveolar Ulceration*

This is an ulcerative process, beginning at the free gum margin, usually on the buccal side, and extending to other parts of the oral cavity. Ulcerous membranous stomatitis



is a contagious infectious disease. Although the investigations of Netter, Bergerou and Fruehwald have not led to a positive result in regard to the demonstration of a specific cause, the endemic occurrence of this disease, as well as its rapid spreading under given circumstances, is unquestionable. Brotonneau, for instance, reports concerning an endemic spread of stomatitis ulcero-membranosa in the Army de la Vendée at Tours in the year 1828. Moussu records the case of a soldier who infected himself from a pipe, and who transmitted the disease to five comrades. De Sotolongo cites the clinical history of a sergeant, who, from unknown cause, had been infected with ulcerous membranous stomatitis, and within the first five or six days had transmitted the disease to many soldiers.

Contributing causes are scurvy, depraved conditions of the constitution, such as may be found among the poorer classes, in whom no attention is given the mouth, and bad hygienic conditions. No other bacteria than the usual pyogenic variety have been found. The appearance is at first that of a superficial ulcer, extending backward and forward in a continuous process until several teeth are included, and extending down over the bone to the buccal membrane, resulting in large ulcers. When neglected it may include the peridental membrane, the teeth becoming loose. The periosteum may become involved and superficial necrosis result.

**Symptoms.**—The symptoms are fetid breath with profuse salivation. The gums are purple or red, swollen and spongy. The gingival margin of the ulcer is a muddy yellow, and bleeds freely when curetted or touched. The ulcer is very painful and tender. In scorbutic ulcers the spongy condition may extend about the teeth. The tongue is swollen extensively and coated with a dark fur. The adjacent lymphatics are enlarged. The constitutional conditions, usually bad to begin with, become worse, and in neglected cases extensive ulceration and even loss of teeth



follow. A fatal termination is rare, except that it so reduces the system that intestinal or other complications may develop.

**Treatment.**—The treatment consists in most painstaking cleansing of the mouth, together with the removal of all tartar from the teeth, and washings with antiseptic solutions. Cauterization with iodine, silver nitrate, etc., is useless. In such cases pure hydrochloric acid has proved to be an excellent, always effective, almost specific, therapeutic agent. The plaques and gingival borders are touched therewith, and rinsings with boric acid mixed with phenol are prescribed after the following formula: Three per cent. boric acid, 950 grams; glycerin, 50 grams; phenol, 0.05 gram.

Before cauterizing, the anesthetizing of the mucosa with a two per cent. cocain solution is recommended. The expeditious effect of hydrochloric acid is attributed directly to the destruction of the bacteria. Holt says that potassium chlorate, in two-grain doses, largely diluted, given every hour for twenty-four hours, to be reduced one-half the second day, is a specific. When decayed or loose teeth or concealed roots are present, they should be removed or treated. Exfoliations should be removed. Under proper and vigorous treatment repair should follow in a week or two, but when hygienic conditions cannot be corrected, the ulceration may last for several weeks. In scorbutic cases, special diet, such as orange and beef juice, with a proper artificial food, such as malted milk, should be given.

**Illustrative Case.**—A boy, aged twelve, had had pneumonia, from which he made a fair recovery. In about two weeks ulceration of the gingival mucous membrane was observed. This continued until all of his teeth below were loose, the floor of the mouth necrotic, temperature high and fetor marked. He died in two weeks from onset. See figure 18.



## (c) HERPETIC STOMATITIS

Herpes of the mouth, sometimes called follicular stomatitis, is an inflammation of the follicles of the mucous membrane.

**Symptoms.**—The appearance is of small, yellowish-white spots, one-eighth of an inch in diameter, which break down into superficial ulcers. Two or more may coalesce,

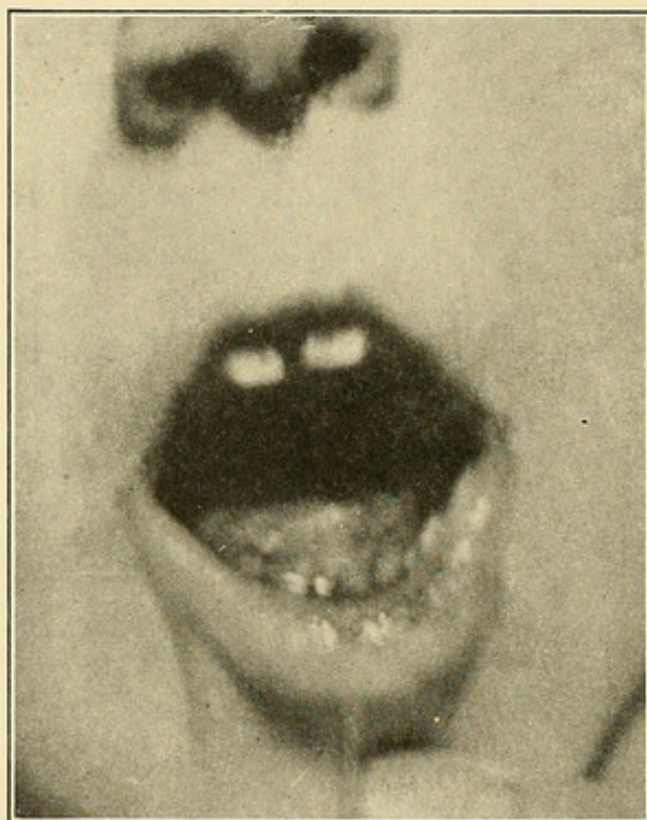


FIG. 18.—ULCERATIVE STOMATITIS.

forming large ulcers. The ulcers are shallow, healing in the course of a few days, to be followed by another crop. They are located along the margin of the tongue and on the internal surface of the lips. The cause is supposed to be nervous, or a primary lesion in the nervous system, resembling herpes circinatus (shingles) and herpes frontalis.

The local lesions are attributed to trophic changes, due to a neuritis of the nerve supplying the involved parts. The only two diseases of the mouth for which herpetic stomati-



tis may be mistaken (and then only in the early stage; for later, when eruption is complete, no confusion is possible) are ulcerative stomatitis and aphthous stomatitis.

**Treatment.**—The treatment is the same as that outlined for the catarrhal form, with the addition of alum or other caustic applied directly to the ulcer. Tonics containing iron and strychnia may be given internally. Repair follows in a week or ten days.

#### (d) MYCOSIC STOMATITIS (APHTHOUS)

Thrush is a fungoid disease of the mucous membrane of the mouth. The *saccharomyces albicans* is the variety of fungus producing the trouble. The lesion is caused by spores forcing their way between the different layers of epithelial cells and gradually extending to the surrounding cells. It begins by the formation of many small spots, which spread until they are united, and a patch of one-fourth to one-half of an inch or larger in diameter is formed. The borders are irregular and the patches are slightly elevated above the healthy membrane. They look like flakes of coagulated milk, but, while the latter can easily be removed, the former are intimately adherent. They are usually located upon the tongue, inside of the cheek, pillars of fauces, tonsils and pharynx, although no part of the oral cavity is exempt.

**Symptoms.**—The mouth is usually dry, painful and tender, the tongue is coated, and there is difficulty in swallowing. Glandular enlargements are rare. It is differentiated from the other varieties of stomatitis by the absence of ulceration or pus formation, but there is instead an irregular elevated patch, which is at first pearly white, but, as time approaches for it to shed, becomes yellow. Diphtheritic patches most resemble thrush, but in diphtheria the patches usually begin on the tonsils or in the pharynx, the deposit is thicker, more defined and continuous, and there is glandular infiltration with marked constitutional



symptoms. Recovery usually follows, though in feeble children the condition may persist and death may result from inanition.

**Treatment.**—The treatment should begin with correction of the diet and methods of administration of food. The

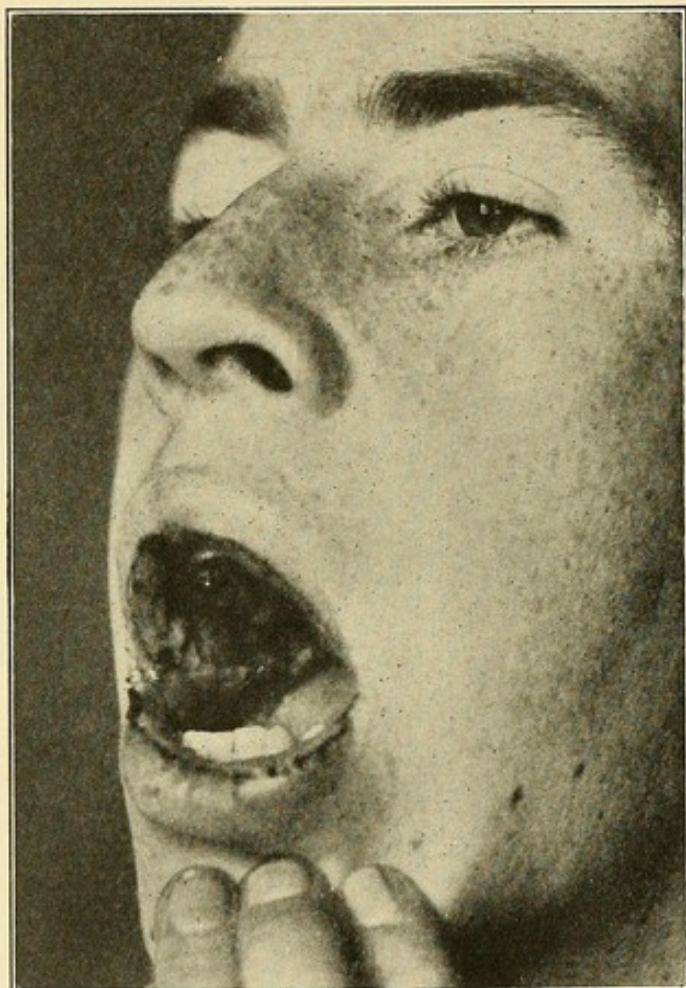


FIG. 19.—MYCOTIC STOMATITIS.

mouth should be cleansed and, in artificially fed children, the bottle, nipple, etc., should be kept sterile, while the food products should be of the best. Antiseptics, such as borax and bicarbonate of soda, in a powder, should be applied locally. Honey and sugar should not be used, as they encourage fermentation.  $\text{AgNO}_3$  applied to ulcers and keeping the mouth clean are the most satisfactory treatments. One application is usually all that is necessary.



## (e) CANCRUM ORIS

Gangrenous stomatitis, also known as noma and cancrum oris, is a destructive inflammation of the mucous membrane and other structures of the mouth. It is generally a sequela of measles, but may follow any of the eruptive fevers. A predisposing cause is the low vitality of the child from the former disease. A specific microbe or parasite has not been found, although streptococci are usually present in cultures made from the product.

**Symptoms.**—It begins with marked constitutional symptoms. The temperature is high, the pulse rapid, the muscles relaxed, and grave conditions develop in four or five days. Fetid breath is very early observed. Locally there is discoloration or a mottled condition of the mucous membrane over the alveolus or on the buccal surface of the cheek. The tissues are swollen and doughy, with marginal infiltration. The skin over the cheek is swollen and glossy. At first red, it soon becomes purple and then black. The epidermis loosens and is cast off during the first few days. The teeth become loose, necrosis of the process soon follows, or, when the disease is confined to the cheek, the line of demarcation is soon established and the necrotic slough comes away in the course of a week, leaving a perforation from skin to mucous membrane. Pain is not severe. The entire cheek or the entire mandible or maxilla may be destroyed by the disease.

The accompanying illustration is that of a child aged five years, who had typhoid fever beginning June 8. On June 22, when fever had about run its course, the attending physician noticed a swelling of the left cheek. On June 24 the skin over the cheek became glossy. On June 26 the physician decided that an abscess had formed and made an incision through the mucous membrane over the maxilla of the superior sulcus of the mouth, and, to his great surprise, the knife passed directly into the bone, which was denuded. With a probe he found that almost



the entire external surface of this bone was denuded of periosteum. June 30, the epidermis of the cheek, about one and one-half by two and one-half inches, came off, leaving a glossy discolored derma vera, which was evidence to him that gangrene had begun. At this time a diagnosis of *cancrum oris* was made and the patient removed to the hospital July 1. The history of the case from this time

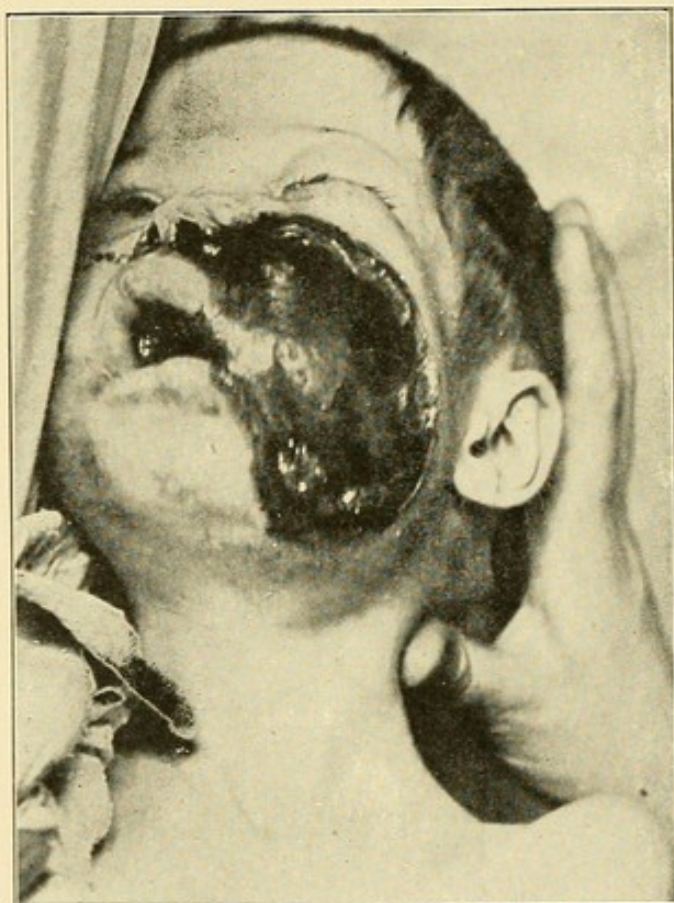

FIG. 20.—*CANCNUM ORIS*.

on was that of progression, the gangrene rapidly extending into new fields in every direction, so that at the time of death, July 10, the outer angle of the mouth and the left anterior naris were included; the entire maxilla was destroyed, since the entire surface was bare as well as the roof of the mouth on the left side.

**Prognosis.**—The prognosis is grave, and it is only when the disease is limited within itself that recovery takes place. Three-fourths of the cases terminate fatally in from four



to six days. When the line of demarcation is early established the slough comes away, repair is very slow, requiring many weeks for granulation and cicatrization, and an objectionable cicatrix or perforation or other deformity is the legacy.

**Treatment.**—The treatment consists in cleanliness, attention to diet, stimulation and nutrition. The slough should be removed early, under an anesthetic if necessary, and the margin of the ulcer cauterized by the actual cautery or by lunar caustic. Vigorous and prompt measures are demanded if recovery is to be expected.

### SYMPTOMATIC MOUTH LESIONS

Symptomatic lesions of the mouth are found when some general or constitutional disease exists, and, along with other well-defined symptoms, there is also present a lesion in the mouth, always secondary and of minor importance. They are included here to make a more complete differential table and to acquaint the dentist with all lesions of the mouth.

*Measles* has no mouth lesion except the earliest manifestation of the eruptive stage, which is observed in the roof of the mouth in the form of dark red or brown irregular or mottled spots. About the same time similar spots may be observed back of the ears and neck.

*Diphtheritic* lesions first appear in the pharynx and tonsils and only appear in the mouth by extension. They can readily be differentiated from thrush on account of the marked constitutional symptoms.

*Scarlatinal* lesions of the mouth appear in the form of membranous deposits termed erythema, or pseudo-diphtheria. Here are found marked constitutional symptoms and the skin eruption so characteristic of the disease.

*Typhoid fever* is a frequent forerunner of gangrenous stomatitis. The case reported in this chapter followed that disease.



Tuberculous and syphilitic mouth lesions are fully considered in the chapters treating of these diseases.

### MERCURY POISONING

*Mercurial stomatitis* is an inflammation of the mouth and salivary glands caused by the excessive use of mercury. A similar condition is rarely seen as a result of the therapeutic use of other drugs. This is seen in barometer-makers, mirror silverers, chemists and others who handle mercury in their daily work. The exciting cause of ptyalism is the ingestion, inhalation or cutaneous absorption of mercury.

**Symptoms.**—A metallic taste in the mouth is first noticed by the patient. Soon the gums become red, swollen, tender to the touch, and sore during the act of mastication. A marked secretion and flow of saliva, with a fetid breath and swollen tongue, follow. Very rarely in this disease the infection passes into an ulcerative stomatitis and causes loosening of the teeth and necrosis of the maxilla.

### CHRONIC LEAD POISONING

The characteristic blue line at the borders of the gums is rarely absent, especially in those who are not scrupulous in their attention to the teeth. It is, as a rule, most distinct at the roots of the lower cuspids and incisors, and is formed by a deposition of lead sulphite. Bluish patches may also be met with. Gowers points out that this line is black instead of blue and is present only when the gums are slightly separated from the teeth.

### PILOCARPIN

Pilocarpin may cause swelling of the salivary glands and tonsils.



# DIFFERENTIAL DIAGNOSIS OF DISEASES IN THE MOUTH

DISEASES.	COLOR.	NUMBER.	SIZE.	MARGIN.	SURFACE.	COURSE.	LOCATION.	TEMP.	AGE.
Catarrhal stomatitis.....	Red to purple.	Diffused.	.....	Not defined.	Same.	Acute.	General.	Moderate.	All.
Ulcerative stomatitis.....	Red.	One or more.	Not large.	Irregular.	Ulcer.	"	Gingiva.	Moderate.	All.
Mycotic stomatitis.....	White.	Diffused.	Irregular.	Defined and irregular.	Smooth.	"	Cheeks.	Little.	Children.
Herpetic stomatitis.....	Red to yellow.	Many.	Small.	Regular.	Elevated Pustule.	"	One side of tongue.	Slight.	Indefinite.
Cancrum oris.....	Red to black.	One.	Large.	Defined.	Depressed.	"	Cheek.	High.	Young.
Milk curds.....	White.	Indefinite.	Irregular.	Uneven.	Rough.	"	Indefinite.	None.	Infants.
Gonorrheal stomatitis.....	Dark red.	Diffused.	.....	Not defined.	Same.	"	General.	Moderate.	All.
Diphtheria.....	White to gray.	Several.	Increasing	Defined and regular.	Smooth.	"	Tonsils.	High.	Young.
Follicular tonsillitis.....	White to yellow.	Many.	Small.	Irregular.	Ulcer.	"	Tonsils.	High.	All.
Syphilitic patch.....	White to yellow.	Diffused.	Finger-nail.	Irregular.	Smooth.	Sub-acute.	Cheek and tongue.	Slight.	All.
Chancre.....	Red.	One.	Small.	Indurated and regular.	Cut out.	"	Lips or tip of tongue.	None.	All.
Gumma.....	Muddy.	One.	Indefinite.	Indefinite.	Elevated.	Chronic.	Tongue or alveola.	None.	All.
Tuberculous ulcer.....	Reddish gray.	One.	Irregular.	Irregular.	Irregular ulcer.	"	Indefinite.	None.	All.
Epithelioma.....	White.	One continuous.	Indefinite.	Defined but rough.	Irregular.	"	Indefinite.	None.	Old age.
Leucoplakia.....	White.	Indefinite.	Large.	Uneven.	Rough.	"	Tongue.	None.	Middle life.



## IODIN

Under the name of iodism, the profession recognizes a state of the body brought about by the prolonged and excessive use of iodine in any of its forms. The earliest notable signs of this state are a peculiar metallic taste in the mouth, particularly in the morning, slight tenderness of the teeth and gums, increase of salivary secretion, morning nausea and a lack of appetite for breakfast, and perhaps some coryza or evidence of gastric irritation.

**SOME AFFECTIONS OF THE NASAL AND ORAL CAVITIES  
WHICH ARE RELATED TO SKIN DISEASES**

Among specialists, the consideration of mucous membrane affections as related to skin diseases is chiefly one of diagnosis. The correlation of the two structures is recognized not only in purely dermatological cases, where, in obscure diseases, we usually rely upon mucous lesions to establish a diagnosis, but also in general conditions, such as the acute exanthemata, where much importance is attached to the primary Koplik spots on the buccal and labial mucosæ in measles, the vesicles and pustules in the mouth and pharynx of smallpox and varicella patients, and some to the strawberry tongue and pharyngitis in scarlet fever. On the mucous membranes, however, lesions present peculiarities which are not seen on the skin, making the question of diagnosis more complicated.

The most important disease of the skin, *eczema*, has its counterpart in catarrh of the mucous membrane. The pathological process is the same in both, namely hyperemia, swelling, exudation and epithelial desquamation. Etiologically there is a further relationship in that local irritants or some remote factor, such as inherent vulnerability, may be operative in both conditions, while, among the subjective symptoms, an analogue has been drawn between the pruritus of the skin and the coughing and sneezing follow-



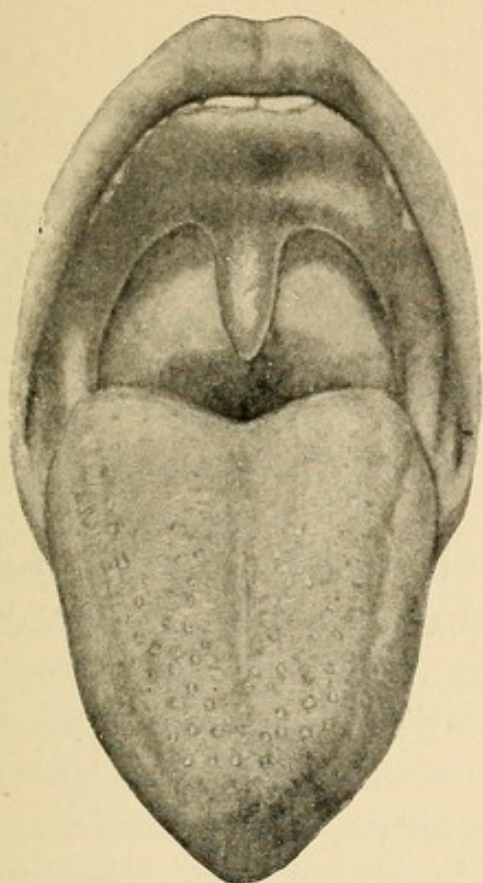


FIG. 21.—STRAWBERRY TONGUE.

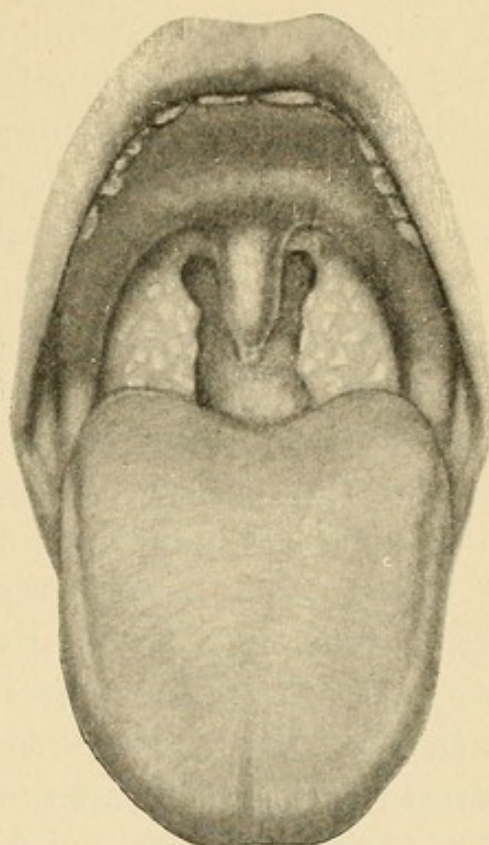


FIG. 22.—FOLLICULAR TONSILITIS.

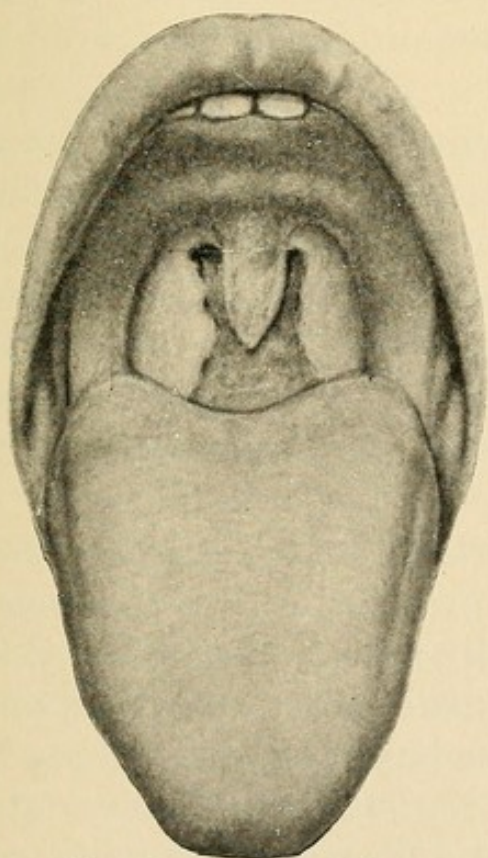


FIG. 23.—DIPHThERITIC THROAT.

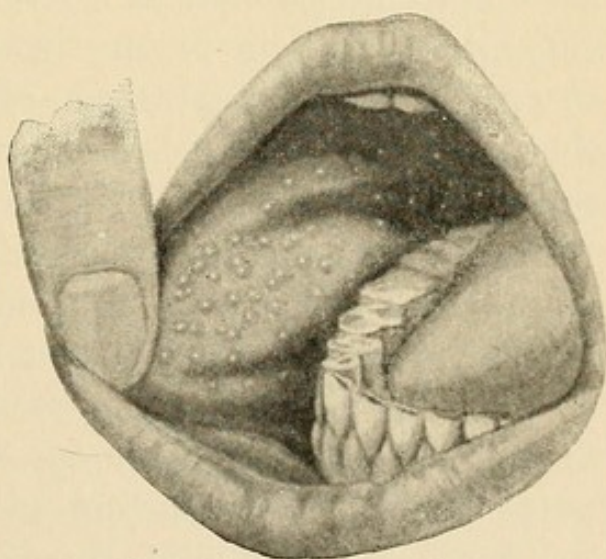


FIG. 24.—KOPLIK'S SPOTS.

(Palisade Mfg. Co.)



ing catarrhs of the respiratory tract. Catarrhal inflammations of the skin may alternate with those of the mucous membranes, the one being active while the other is held in abeyance. This view is upheld by Broca, and it may be due to the same pathological law which governs the subsidence of an inflammation in one organ while it is active in another. The absence of febrile disturbances in cutaneous catarrhs has been accounted for by the heat radiation from the surface and the elimination of toxic products through the excretions.

A catarrhal condition of the skin is often set up by one of the mucous membranes and, conversely, the mucous membranes may be involved by autoinoculation from the skin. This is frequently illustrated by an eczematoid dermatitis of the contiguous skin resulting from discharges from the eye, ear, nose, mouth or genitals. The lesion, usually staphylogenic in origin and vesicular or erythematous, soon forms eczematous plaques, which by confluence or progression involve large areas, or by autoinoculation produce new ones.

Eczema of the cheeks in children can often be traced to sleeping with the *mouth* open and the dribbling saliva in subjects of adenoids. The connection between the mucosa and integument is further demonstrable in cases of refractory sycosis of the lip produced by pus organisms in an irritating nasal discharge and in facial erysipelas or the recurring erysipelatoid flush of the face from picking the nose.

*Impetigo contagiosa* also attacks the mucous membranes of the nose and mouth, and may precede, accompany or follow the skin eruption. It is usually seen as isolated vesicles or pustules which become encrusted. More rarely a papillomatous condition develops. The impetigo of Bockhart results from autoinoculation with the staphylococcus, and is produced by scratching in pruritic diseases. The *lips and mouth* are eroded and the lesions may by confluence give



rise to phlegmonous areas. In a case of *fulminating ecthyma* the lesion began on the hand and by autoinfection involved the head, face, thighs, *mucous surface of the lips*, and soft palate and nose, where numerous pea-sized superficial erosions were present, accompanied by a fetid sero-purulent nasal discharge. Marked septic symptoms were present, and the case had a fatal issue. At autopsy the entire larynx and the trachea were also found ulcerated. The bacteriological examination showed staphylococci, streptococci, and a slender unclassified bacillus.

All the types of *pemphigus* attack the mucous membranes, that of the *mouth* most frequently. They may be involved early or late in the course of the disease, often preceding the skin eruption by months, so that early diagnosis may rest with the nose and throat specialist rather than with the dentist or an oral surgeon. Early manifestations in the mouth and in the larynx are not uncommon, however, and the presence of bullæ and erosions in the oral cavity, accompanied by constitutional disturbance and loss of weight, are frequent symptoms. The onset is gradual, requiring several months for development. Differentiation must be made from simple bullous lesions, and from intermittent mouth infections which come and go without constitutional disturbance. They are usually associated with bullous dermatitis. This disease may begin on the tongue or any part of the mouth or throat, as well as the vermilion border of the lips.

*Herpes zoster* may be understood if the reader refers to this subject earlier in the chapter, where it has been duly considered.

In the *erythema* group, as well as in *urticaria*, *angio-neurotic edema* and some forms of *purpura*, the mucous membranes of the mouth, nose, and respiratory tract may show lesions. These conditions cause constitutional symptoms to some extent. There is a resemblance between erythema and purpuric conditions. In the latter condition,



there is usually hemorrhage, which, as a rule, comes on very suddenly. This is typically illustrated in Henoch's purpura. There is also a close resemblance between purpura and erythema multiforme. Erythema of the mouth must be differentiated from contagious exanthemata, and a thorough inspection of the entire body should be made.

*Perlèche* is a parasitic disease of the lips, occurring most frequently in children and in old people in institutions and asylums. It affects the commissures with fissuring and a tendency to bleeding, and resembles mucous patches.

*Psoriasis* of a true nature is so rarely found that it need not be described here. It resembles leucoplakia.

*Seborrheic dermatitis* of the scalp and face, sometimes associated with lesions of the mucous membrane of the mouth and scalp, should be thoroughly examined to differentiate it from other lesions.

*Lichenization* is a chronic skin affection, associated with itching and thickening from intoxication and the ensuing pruritic diseases. It may be associated with leucokeratosis of the mouth and must be differentiated from the latter, which is due to tobacco and syphilis.

*Leprosy* results in mouth lesions, and frequently this disease is first manifested here or in the nose, resembling a coryza from potassium iodid.

*Rhinoscleroma* generally begins in the mucous membrane in the anterior nares, extending from the pharynx into the mouth.

*Lupus erythematosus* begins with lesions of the mouth and pharynx and is associated with cutaneous eruptions. Plaques on the tongue resembling leucoplakia and syphilitic scars are found. The lips are swollen, purplish red, and eroded, and later become dry and scaly.

*Pigmentation of the mucosa* of the mouth is found with Addison's disease, vagabond's disease, Darier's disease,



diabetic melanoderma, and acarus infection, and may be associated with the use of arsenic or silver nitrate.

Mouth lesions also result from ringworm and epithelioma; and many of the skin lesions, well known to the dermatologist and not above enumerated, have mouth lesions. In any case where a mouth lesion is associated with a skin lesion, a dermatologist should be consulted with a view to clearing up the probability of association.

### VINCENT'S ANGINA

**Synonyms.**—Diphtheroid angina; ulcero-membranous tonsillitis; ulcerating lacunar tonsillitis; chancriform tonsillitis.

**Definition.**—An acute infection of the mouth.

**Etiology.**—It is generally regarded as due to the symbiotic action of the bacillus fusiform and a spirillum (*Spirochæta denticola*).

**History.**—Vincent's first description of this disease appeared in the *Archives of Laryngology*, in 1896. In 1903 Emil Mayer's paper was published in the *American Journal of Medical Science* for February. W. H. Bruce also published a paper in the *London Lancet* for July 16, 1904. The standard textbooks of this country, so far as the author is able to find, furnish but two brief descriptions: on page 249 of "Syphilis" by Keyes, this disease is considered under the head of chancre; and in "American Practice of Surgery," Volume V, page 822, is found a very satisfactory description. In Thomson's "Diseases of the Nose and Throat," Cassell & Co., Limited, London (Appleton, U. S.), is found the best description. The following is quoted from the latter:

**Bacteriology.**—"The bacillus of Vincent is fusiform, pointed at the ends, and somewhat bulging in the middle. It is distinguished from the Klebs-Löffler bacillus by being broader and longer; its length is 6 to 12 micromillimetres.



The bacilli are frequently arranged in pairs, or in radiating bundles. They form vacuoles, do not stain with Weigert or Gram, but take up the ordinary basic stains, such as fuchsin or methylene blue. The bacillus has very free movement. It can be cultivated on the ordinary media, to which human blood serum or ascitic or hydrocele fluid has been added (Hewlett).

“The spirillum (*Spirochæta denticola*) is thin and long, does not stain by Gram, and does not take up fuchsin so readily as the bacillus, has free movements but no flagellæ. Cover-glass preparations should be spread and stained while fresh. It has only been grown in pure culture under anaërobic conditions.

“Some observers point out that fusiform bacilli and spirilla can be found in any ulcerating affection of the mouth (syphilis, lupus, malignant disease, and gingivitis), and that, although they are constantly present and remarkably predominant in cases of Vincent’s angina, it is at present sufficient to allow that the resistance in such cases is singularly modified in favor of these bacilli and spirochetes, and that the infectivity of the disorder has not been proved (M. Letulle).

“This form of ulcerating tonsilitis is an uncommon disease and is most frequently met with in debilitated subjects who are overworked or in unsanitary surroundings. It occurs chiefly in children, but is not uncommon in hospital residents. It is but feebly contagious.

**Symptoms.**—“The incubation period is said to be six or seven days. The onset of the disease is insidious, and the throat may be so little complained of that attention is directed to it by the accompanying glandular enlargement. The disease is ushered in with headache, malaise, coated tongue, anorexia, and pains in the back. The temperature rarely exceeds 101° F., and may remain normal throughout the case. The glands at the angle of the jaw are enlarged and tender on the affected side. Discomfort in the throat,



fetid breath, and slight dysphagia may be complained of, but the constitutional symptoms are not, as a rule, severe. The fetor is generally present and is characteristic.

**Clinical Features.**—"The local features are fairly typical. On the first day one tonsil shows an easily detachable exudation; on the second day this membrane is found to rest on an ulcerated surface; and on the third and fourth days it becomes thicker and softer. The membrane may become detached at its edges, and expelled or swallowed, leaving a slightly ulcerated surface, on which new membrane forms. The so-called membrane is, correctly speaking, simply formed by the necrotic tissue from the surface of the ulcer. It is soft, gray, yellowish-gray, or greenish in color. When pinched up with forceps it comes away in soft, easily torn fragments, leaving an anfractuous, eroded area dotted with small bleeding

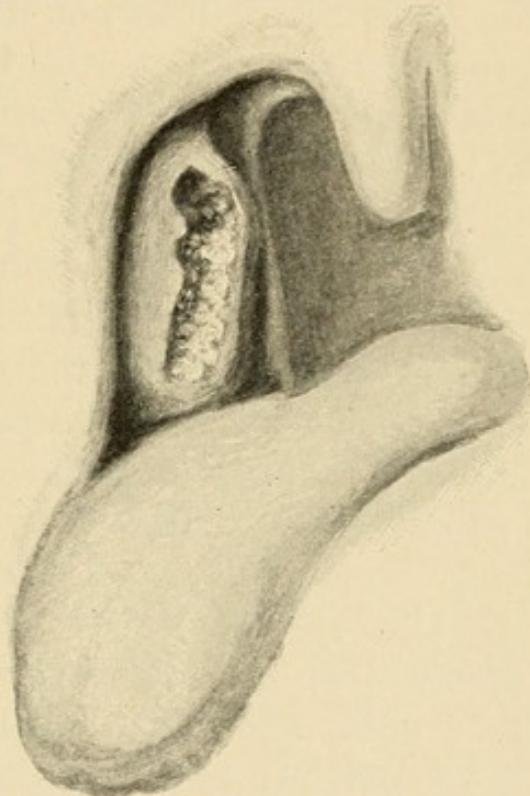


FIG. 25.—VINCENT'S ANGINA. ("Diseases of the Nose and Throat," Dr. St. Clair Thomson, Cassell and Company, Limited.)

points. The ulcer has an irregular, indolent, flattened base, the edges of which are abrupt or sloping. . . . The surrounding tissue may be reddened and edematous. After four to ten days the pseudo-membrane ceases to re-form, and the ulcerated surface soon gets clean and heals over. But in more pronounced cases the tissues are involved more deeply and the process extends over the whole tonsil, the adjoining faucial pillars, the gums, and, rarely, the side of the pharynx. The destruction of the tissue occurs three to four days after the onset of the disease. The surface involved may separate, leaving a deep excavation which heals



up with slight cicatricial contraction. In the great majority of cases Vincent's angina is a unilateral affection."

**Diagnosis.**—Different writers on this subject have entirely different opinions as to what variety of syphilis is most nearly akin to this disease. Keyes considers it under the head of chancre and says it must be differentiated from this lesion, and does not at all refer to it as resembling either secondary or tertiary lesions. Thomson in his book states that it can be confused with tertiary syphilis. It is the author's opinion, after having seen several cases, that the disease is more likely to be confused with the mucous patches of secondary syphilis than with the chancre or tertiary lesion. It is difficult to differentiate it from any stage of syphilis, since the fusiform bacillus and the spirillum are found in both diseases, and a diagnosis is only possible after taking into consideration the preceding and succeeding history. In a recent case, where there were practically no constitutional symptoms except a slight temperature and rigor for the first few hours, there were two patches over the soft palate just internal to the pillars of the fauces, about one inch long and one-half inch wide. These patches looked quite uniform in margin and appeared to be very much alike. Specific patches were suspected, but after nitrate of silver had been applied to the ulcerations for a few days they repaired without scars and the patient was entirely well in ten days. Keyes reports one case of Vincent's angina of the tip of the tongue which had persisted for three months, and another case which ran its course in a few weeks. He also reports a case in which a man had an ulceration on the left tonsil, covered with false membrane, and his wife showed a similar lesion on the right side of the mouth at the angle of the jaw. In both of these cases a diagnosis of syphilis was made, but the ulcerations repaired in a few weeks without the development of syphilitic symptoms. The following is quoted from Keyes: . . . "the differentiating points, which are: 1.



The tenderness is much more marked in Vincent's angina than in chancre. 2. The anginous sore (unless cauterized) is more superficial than chancre, and is likely to be surrounded by more or less general inflammation. 3. The glands may be large and tender in either case. 4. Chancre gets well spontaneously; the angina may or may not. 5. Microscopic examination of a smear establishes the diagnosis."

**Prognosis.**—It is rare for the disease to extend back of the tonsils into the larynx or into the trachea, but it is quite common to find it both in the hard palate and in the mucous membrane of the cheek, or about the teeth, resembling stomatitis. Bruce has reported one fatal case, but, as a rule, the disease runs a very mild and harmless course. Complications including the viscera are unknown.

**Treatment.**—Pure tincture of iodine, Lugol's solution of iodine, and nitrate of silver in various strengths have been used in the treatment of this disease. It is certain that whatever application is made should be strong enough to destroy the germs, but that this should be discontinued after two or three applications, since if continued it might prevent repair of the ulcerations. A mild antiseptic mouth wash should be used at all times.



## CHAPTER XV

### DISEASES OF THE TONGUE

The dentist, who has the tongue as a background to his field of operation at all times, should not only be prepared to recognize a normal organ, but should also be able at a glance to make an approximate estimate as to which of the various diseased conditions that are liable to affect it are present.

A furred tongue occurs in nearly all fevers. If it is a heavy fur, there is systemic disturbance, usually serious. If a light, moist fur, simple indigestion is present. Unilateral furring may result from disturbed innervation, as in conditions affecting the second and third branches of the fifth nerve. It has been noted in neuralgia of these branches. Light yellow fur indicates liver derangement. Brown fur denotes neurasthenia, also intestinal putrefaction, and is a bad indication, especially if of a very dark color. If this is combined with dryness and fissures, the condition is very grave.

A beefy tongue occurs in chronic inflammations of the bowels, liver or mucous surfaces, but if the tongue is flabby and gray-coated with an oval bare spot in the center which is red and glossy, as is sometimes seen in children, it is indicative of gastrointestinal catarrh.

A black coating on the tongue is found in dysentery, and indicates collapse and impending death, and in jaundice, when it denotes organic disease of the liver. It is also an unfavorable sign in smallpox. A bluish tongue denotes impeded circulation and interference with respiration. It is indicative of heart disease and asthma. Redness along



the center of the tongue means intestinal irritation and is an early sign in typhoid fever. Glistening is very unfavorable. If cracked, it points to kidney trouble. A scarlet tongue denotes acute inflammation, usually of the stomach, especially if red along the edges and the tip. A lead-colored tongue is found in cholera and sometimes in malignant disease of the stomach. If combined with thrush it denotes death.

A sharp, pointed tongue is observed in meningitis. A tremulous tongue is seen in many acute diseases and in cerebral involvement.

White fur on the tongue, through which project bright red and prominent papillæ, usually called "strawberry tongue," is seen in the early stage of scarlet fever.

If the tongue clears slowly, commencing at the tip and edges, leaving a natural appearance, permanent recovery can be expected. If the fur comes off in patches, leaving a smooth red surface, recovery will be slow, but if it disappears rapidly, leaving a shiny cracked surface, it is unfavorable.

A bitter taste indicates errors of diet or the use of drugs.

### CONGENITAL DEFECTS

Congenital defects are divided into: (a) Congenital fissures or bifid tongue, due to a failure of the branchial arches which go to form the tongue in embryonic life to coalesce. This is a very rare condition.

(b) *Ankyloglossia*, or tongue tie, not a frequent deformity; a result of shortness of the frenum or of its attachment too far forward toward the tip.

(c) *Abnormally long frenum* with lax attachments between the under surface of the tongue and posterior surface of the mandible, allowing the tongue to drop back against the wall of the pharynx and over the glottis, interfering with the respiratory act.



(d) *Abnormalities in size.*—The tongue may be either too large, too small or congenitally absent, cases of which kind have been reported. An abnormally large tongue is called macroglossia and is generally congenital, but does not attract attention for the first year. The growth is usually confined to the apex. It is a hyperplasia of the connective tissue. The tongue sometimes grows to enormous size, even extending beyond the teeth for some distance.

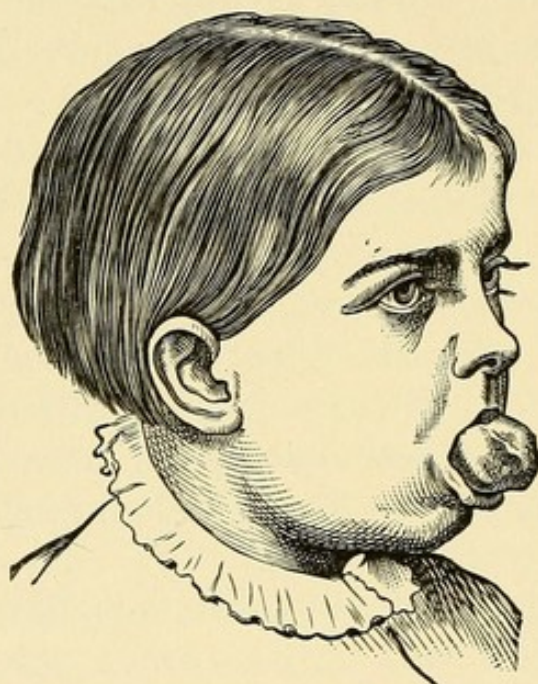

FIG. 26.—HYPERTROPHY OF THE TONGUE. (Bryant.)

Its size changes the normal dental arch and every proximal tissue is distorted. That part of the tongue which protrudes and is exposed to the atmosphere becomes parched and brown, losing its normal characteristics.

**Treatment.**—The operation for ankyloglossia consists in elevating the tongue and cutting the band with scissors, taking care to point the scissors downward, so as to avoid the ranine artery.

Treatment for macroglossia consists in the amputation of sufficient of the tongue to reduce it to a normal size. This is done by first passing ligatures through the sides of the tongue so as to draw it forward, when with a stout scissors



a V-shaped section is cut from the center. The hemorrhage is controlled and the side flaps adjusted and sutured. Repair follows, and no return is expected.

### ACQUIRED AFFECTIONS

Acquired affections of the tongue may be divided into:

Inflammations.....	{ Acute (Ludwig's angina). Chronic (leucoplakia).
Injuries.....	{ Mechanical. Thermic. Chemical.
Tumors.....	{ Benign lingual goiter. Malignant. Specific.

### INFLAMMATIONS

Glossitis, or inflammation of the tongue, may be acute or chronic.

#### *Acute Inflammations*

The acute form may be confined to the mucous membrane or to the deeper structures and to the floor of the mouth. When it is located in the mucous membrane, it is generally associated with a stomatitic erysipelas, or is a result of other infections. The tongue becomes red, swollen and painful, the salivation is profuse, and a muco-purulent fluid is discharged. Swallowing and talking are performed with effort. The pulse is frequent, the temperature high, and there is considerable constitutional disturbance. Deep inflammation or parenchymatous glossitis may develop without any assignable cause, although it is usually associated with suppurative process about the mouth or jaws, or is caused by injuries. Abscess formation is liable to follow.



**Treatment.**—Treatment consists in removing the cause when it is due to secondary infection, and when an inoculation has occurred vigorous local treatment must be given. Local astringents are of value. Hot water up to tolerance, continuously held in the mouth, will destroy infections very rapidly. Just as the colony of bacteria causing the trouble is destroyed, active symptoms will subside. This does not mean that recovery will follow, for reinfection from a latent colony may cause a return of active symptoms. For this reason, treatment must be persistent and continuous, until there is some assurance that the improvement is permanent.

**Ludwig's Angina.**—This condition is an acute infection of the deeper structures of the tongue and floor of the mouth, usually associated with infection from inflammatory conditions of the teeth or mandible. It may, however, develop without the presence of other infections about the mouth. It may go on to suppuration and abscess formation, or may subside short of this. The surface of the tongue may not be involved. The disease produces local signs before general symptoms, and attention may first be attracted by a swelling, which may be either below the jaw in the submaxillary region or posteriorly over the parotid region. The hard, "board-like" character of the swelling is almost pathognomonic. Sometimes the skin is pale, sensitiveness not marked, and the temperature raised but one or two degrees. In other cases the skin may be a dusky red, tender, hard, and painful to the touch, and the temperature high, 102° or 103°. Swelling of the floor of the mouth, pushing the tongue upward to the roof and forward, with difficulty in swallowing and some difficulty in breathing, are early noticed. Chills may occur, and dirty, offensive pus may break into the mouth near the molar teeth. The swelling may extend down to the clavicle and up to the temple, and a large abscess may form beneath the lower jaw. Death may occur early from involvement of the larynx, with



edema and dyspnea developing rapidly, this involvement being indicated first by a hoarseness of the voice and then by its loss. The progressive involvement of the deeper tissues should settle at once the question of diagnosis.

Treatment consists in the use of tincture of iodine in the tissues of the mouth to destroy the bacteria. If an abscess develops it should be incised, care being taken not to sever blood vessels, which are numerous about the tongue. Median incision from below is to be preferred. Drainage either with rubber or gauze should be instituted. Tracheotomy may be required to prevent a fatal termination.

*Illustrative Case.*—In the case illustrated the disease ran a very acute course with considerable temperature. The

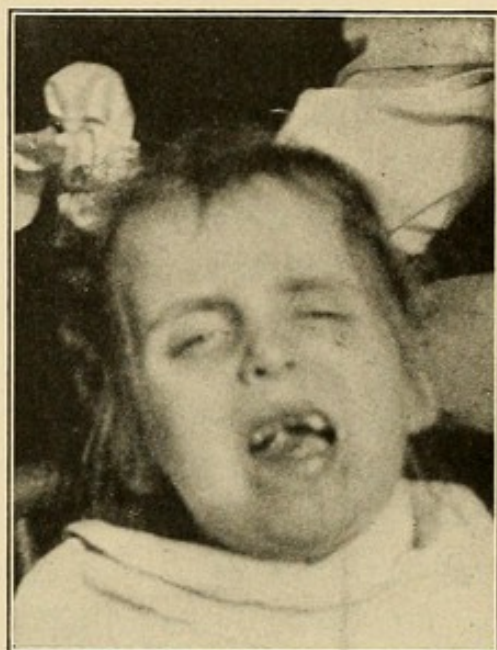


FIG. 27.—LUDWIG'S ANGINA.

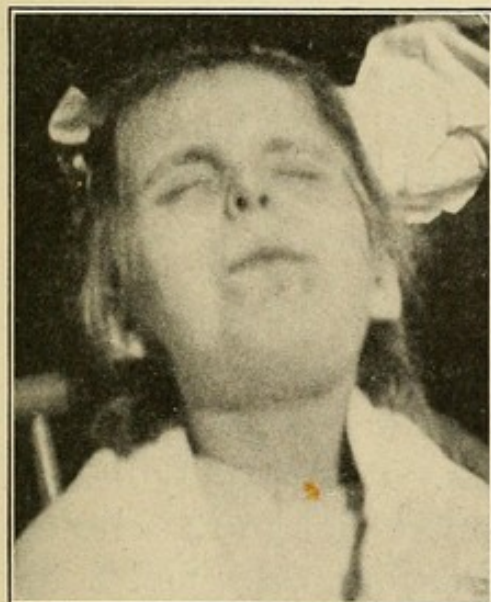


FIG. 28.—LUDWIG'S ANGINA.

photographs shown were taken one week after the onset. At the time the case was seen, tincture of iodine had been used freely throughout the oral cavity and instructions were left to use it three times in twenty-four hours. Symptoms had not advanced at the end of this time, and the iodine was continued. To our great satisfaction the infiltration diminished, the symptoms subsided, and the patient recovered without operation. The theory of the use of iodine is that it is absorbed from the mucous membrane of the mouth by the lymphatics and passes along



the same lymph channels which have been infected at the beginning of the disease.

### *Chronic Inflammations*

Chronic inflammations *per se* are rare, for they are generally assignable to specific or other causes, the tongue condition being only a symptom. Icthyosis linguæ, or leucoplakia, is a chronic localized thickening of the mucous membrane of the tongue, which may be caused by excessive smoking, the use of alcohol as a beverage, or by other irritants, and by syphilis. Beginning as an inflammation, it progresses to the formation of ulcers, which may persist and develop into deep destructions. Mixed infection, as with the tubercle bacillus and true lupus of the tongue, may follow, and epithelioma has been preceded by this form of inflammation. A marked symptom is dryness of the tongue, the surface is red, and sometimes furrowed, during the early stage before ulcerations begin.

Treatment consists in the removal of the cause, the withdrawal of alcohol and tobacco, etc. The curettement of a tuberculous ulcer is good practice. If it is syphilitic, mixed treatment should be given, with antiseptic mouth washes for cleansing purposes. If epithelioma develops, that part of the tongue which is involved should be amputated. For details see chapters on these subjects.

**Leucoplakia of the Mouth.**—This condition is so named because of its white appearance. It was first lucidly described by Schwimmer, and Hutchinson called it leucoma. By other writers it has been called lingual psoriasis, lingual ichthyosis and smoker's tongue. It is usually located on the upper surface of the tongue anterior to the circumvallate papillæ. It is also found along the sides and under the tip of the tongue. It may, however, be found on other parts of the mouth. It is an idiopathic disease characterized by milk-white, opaque plaques slightly elevated above the surface. At first small patches are found, which dur-



ing several months become larger and coalesce, covering the entire tongue or cheek. The patches are at first soft and smooth, but later become hard and feel rough and warty. The surface may become furrowed or ulcerative and bleeds during mastication or following slight injury.

The plaques appear to be many layers of squamous epithelium piling up, instead of desquamating, as is usually the case. The tendency is to harden, similar to skin horns or cornification. During the early stage the papillæ are not involved and plaques may be desquamated without hemorrhage. As the disease advances, the deeper structures are included in the hyperplastic changes, about which will be found an area of leucocytic infiltration. When not checked by treatment, this epithelial proliferation continues and carcinoma is the result.

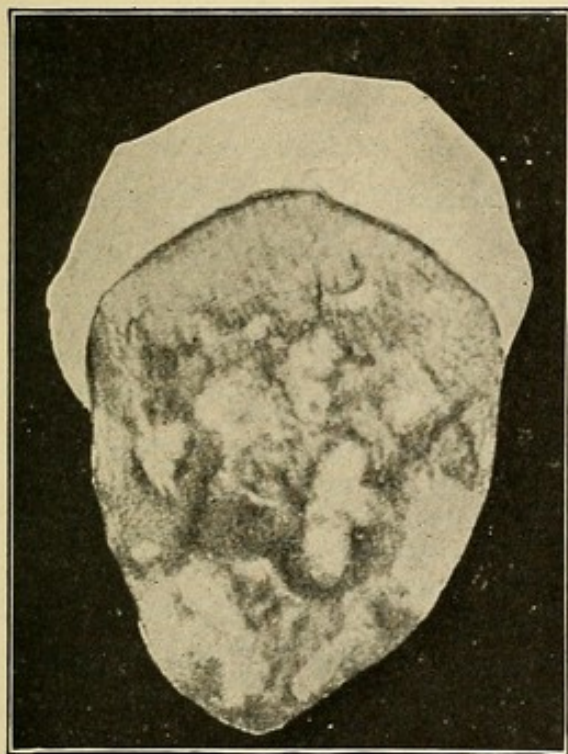


FIG. 29.—LEUCOPLAKIA LINGUÆ. (Reproduction in black and white from Jacobi's dermachromes. By permission of The Rebman Company.)

The etiology is not well understood. It is almost always developed in men who smoke, although about ten per cent. of the cases are found in women, many of whom smoke. It is definitely known that smoking stimulates the formation of the patches, which will disappear during abstinence. Symptoms, other than the patch, are absent during the early course. Later there is some pain and tenderness. As the plaques become deeper and larger, symptoms are intensified. If the condition passes over into malignancy, the symptoms are those of a carcinoma.

A syphilitic leucoplakia is described by some authors



in connection with the general subject, and since syphilitic lesions of the tongue are described in detail in the chapter on this subject, further description is unnecessary here.

Diagnosis must be made from syphilitic patches, infiltration, gumma and epithelioma. In the syphilitic lesions the history must be considered. (See syphilis of the mouth.) Leucoplakia begins gradually and painlessly and grows continuously. In syphilis the growth is rapid and is usually sensitive. The glands of the neck are enlarged in syphilis, but not so in leucoplakia. It more nearly resembles carcinoma, in which condition the white patches are almost identical. In the latter the whiteness is pearly and resembles that of a phenol burn. In leucoplakia there is a dead whiteness.

Treatment should be radical and prompt. Fournier says that thirty per cent. of cases become carcinoma when permitted to advance to the deeper tissues. The use of escharotics, as chromic and other acids, affords no permanent curative result and should not be depended upon. Smoking and the use of tobacco must be forbidden. Mouth washes must be used. Ice may be used to control pain.

The X-ray has furnished a therapeutic agent of some value. The Pacquelin cautery is to-day the most acceptable means of treatment. Repeated burnings should be done until all of the patches and more deeply involved tissues are destroyed. The operations may be done under cocain anesthesia.

### INJURIES

*Mechanical* injuries may be the result of punctures, of bites from falls with a pipe or other article in the mouth, or while the tongue is caught between the teeth, or of bites during epileptic seizures. When the incisions or lacerations are deep, a considerable vessel may be injured, resulting



in alarming hemorrhage and requiring ligation. Such cases should be treated with antiseptic washes, etc., as wounds are treated on other parts of the body. The edges should be adjusted with fine catgut. Union is the general result, and repair follows without complication.

A chronic irritation of the tongue may result from the projecting edge of a decayed tooth which has been neglected. The constant rubbing of such a sharp point against the tongue produces a granular surface which persists until the tooth is filled or extracted. It is very important that either one or the other of these should be done, as it is claimed that carcinoma frequently results from such cases.

As to the *thermic* injuries, heat, in the form of food or otherwise, and chemicals may come in contact with the mucous membrane, resulting in destruction and ulceration. Scalds and burns from the introduction into the mouth of hot food or drink cause superficial destruction of the mucous membrane, and the ulcer resulting may be mistaken by the dentist for a more severe affection unless the history be considered. Abscess of the tongue is not common and is mostly that following Ludwig's angina, and has already been considered. If from other causes, the treatment should be the same. The lesions caused by drinking of any corrosive liquid, as acid or alkaline solutions, etc., with suicidal intent or accidentally, result in destruction of the tongue. The treatment already outlined is sufficient.

Other ulcerations of the tongue are due to particular causes, as syphilis, tuberculosis or cancer, and are considered under these several heads.

*Lingual goiter* is an enlargement of the lingual tonsil, which is situated at the base of the tongue. It varies in size in proportion to the length of time it remains without treatment. The tumors are bi-lobed and are firm but elastic to the touch.

Microscopically they resemble thyroid tissue containing



colloidal material which is confined to the sinu, which are, in turn, found to be lined with cuboid epithelium.

These conditions are rare and must be differentiated from gummata before breaking down, and cysts of other glands of the tongue. Occasionally they are due to extravasation of blood, but they develop more rapidly. They must also be differentiated from dermoid cyst, which develops more rapidly, pits on pressure, is not so vascular, and is usually yellow when found upon the dorsum of the tongue.

A lingual goiter develops very slowly and is located at the center of the base of the tongue about as far forward as the foramen cecum. This surface is smooth, pinkish in color, and covered with mucous membrane, showing vascular network.

Treatment consists in removal by surgical operation. Tracheotomy is usually necessary on account of extensive hemorrhage which follows, and anesthetic is given through the tracheotomy tube.

### TUMORS

Tumors of the tongue are benign and malignant.

*Benign tumors* are dermoid, lipoma, fibroma, papilloma and encondroma. Under the same head may be included other enlargements of the tongue, such as nevus, macroglossia, and retention cysts, such as ranula and the retention of normal secretion from the sebaceous glands and the glands of Nuhn, all of which have been considered under general heads.

*Malignant diseases* of the tongue are principally epithelial carcinomata. They develop in advanced life, between forty and sixty years of age, and about ninety per cent. are in males.

Barker reports two hundred and ninety-three cases, and two hundred and forty-seven were in men. St. Thomas's Hospital treated one hundred and sixty cases, sixteen of



which were women. The causes, as they have been determinable, are lacerations of the tongue from ragged teeth, smoking, trauma, and injuries of the tongue by the teeth during falls. Tuberculous and syphilitic ulcerations are followed by the development of epithelioma. Leucoplakia

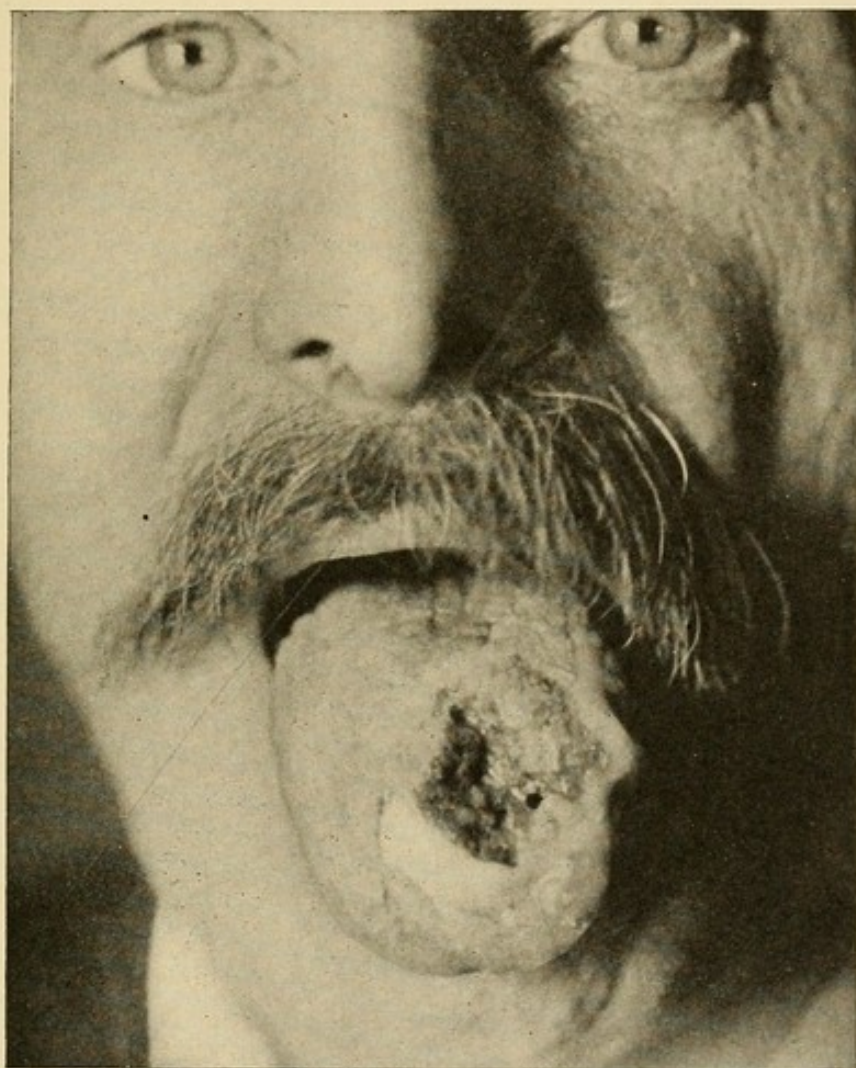


FIG. 30.—EPITHELIOMA OF THE TONGUE. Case of Dr. Jerome Longenecker, Philadelphia, Pa.

and other chronic maladies of the tongue apparently predispose to cancer. The disease, usually beginning on the dorsal surface of the tongue, extends to deeper structures, involving the sublingual tissues, and later on extends down into the cervical glands. From four to six months may pass before the patient consults a surgeon, so insidious is the onset.



**Diagnosis.**—Diagnosis is of the greatest importance since many mistakes are made. It is wise, and, indeed, essential, that a section of the suspected area be removed for microscopic examination before any important operation be done on the tongue. Cocain should be used so that a piece of sufficient size may be obtained. The cut should be through the edge of the ulcer, and at a right angle with the surface of the sore. Esmarch called attention to the many mistakes that had been made in the removal of parts, often of great importance, under diagnosis of malignancy, when the disease afterward proved to be syphilitic, or even merely inflammatory. He thought that many syphilomata had been removed as sarcomata.

*Differential diagnosis* between syphilis of the tongue and cancer is sometimes difficult. Anderson called attention to the fact that precancerous conditions, which at the outset may appear benign, have grafted over them cancerous conditions. He says: "Therefore, no surgical lesion of the tongue, unless it be of a merely transitory nature, must be regarded as unimportant.

**Treatment.**—Operative treatment is the only means which promises anything for these cases—the complete eradication of the ulcer and the surrounding tissues so that all involved structure is removed.

Operation involves the removal of a section of the tongue. When the disease is on one side, the other side need not be removed unless the infiltration is very close to the median line. Partial and complete amputation of the tongue are well known procedures. In partial operations the operation is done through the oral orifice. After cleansing the mouth, the patient is anesthetized. The tongue is now secured with a silk thread or volsellum forceps. The wire clamp forceps are most efficient, and not only serve to retract the tongue, but also control the hemorrhage, which is generally profuse. A mouth gag is now inserted. With a stout scissors a V-shaped section of the tongue is removed.



It may be necessary to sever the frenum. The bleeding vessels are caught up with hemostats and ligated. The lateral flaps are now approximated and held in position with silkworm-gut sutures. Amputation of the entire tongue may be performed after the methods of Kocher, Barwell, Billroth, etc., or modified to suit the case or the operator.



## CHAPTER XVI

### SURGICAL DISEASES AND INJURIES OF THE FACE

Nothing affords so much information as to the health and character of a new patient as a glance at the face. A clean skin, clear eye and open countenance are evidences which speak for themselves. When these things are not present, other avenues for gaining information must be used. Experience leads to a knowledge of the character of people. Pathological conditions of the skin, however, are learned by accurate study. The simple conditions about the face which should be understood and recognized by the dentist, and which should not be mistaken for malignant, specific or tuberculous eruptions, may be described as follows:

*Erythema*, or rose rash, is a marked redness of the skin, due to congestion of the smaller vessels. It appears in many forms: as a diffused redness in small and large spots and in nodes. The redness disappears on pressure. It is usually due to digestive disturbance and disappears when this is corrected.

*Petechiæ* are small red spots formed by effusion of blood, as in typhoid and purpura. They resemble insect bites.

A *macula* is a stain or discolored spot of the skin, not elevated above the surface, which does not disappear on pressure. When due to hemorrhage it is known as purpura hemorrhagica.

A *papule* is a small, circumscribed, solid elevation of skin. It does not contain liquid.



A *vesicle*, sometimes called a bulla, blister or bleb, is a small circumscribed elevation of skin containing serous liquid.

A *pustule* is a small, circumscribed elevation of skin containing pus. It is typical in acne, chicken-pox and smallpox. It is usually preceded by the foregoing conditions, in order: macule, papule and vesicle.

*Crustaceous* conditions succeeding pustules, abrasions and ulcerations are solid layers of matter caused by the drying of the secretions or body exudates.

*Dermatitis* is any infection of the skin, regardless of the cause or course. It is an indefinite term requiring little consideration under the bacteriological classification of disease. Mechanical dermatitis, however, requires special mention. It is caused by some form of drug or mechanical irritant, escharotics, acids, etc., which accidentally or otherwise come into contact with the skin, destroying the epidermis and setting up irritation, and it cannot be considered true inflammation unless infection occurs. Mechanical dermatitis usually subsides without special treatment when the cause is removed.

## DISEASES OF THE SEBACEOUS GLANDS

*Acne vulgaris* is an infection of the sebaceous glands with a tendency to the formation of pustules. It appears about puberty and disappears usually at about twenty-five years of age. The eruption is most profuse over the cheeks, forehead and nose, but may also extend over the breast, shoulders and back.

*Comedo*, a most simple form, commonly called black-heads, is an accumulation of sebum in the duct. The comedone is white, the black top being due to a discoloration from dust particles.

*Papular acne* usually begins from a comedo and is due to infection by some form of pyogenic bacteria. It is at



first red and tender, but becomes less active later on, and, as pus formation is established, is known as pustular acne. The pustule is surrounded by an inflammatory base which disappears as the pustule dries into a crust, and is shed in a few days, leaving a purple pit. The pustules become quite tender, especially when they are on the nose. All of these conditions destroy the personal appearance of the individ-

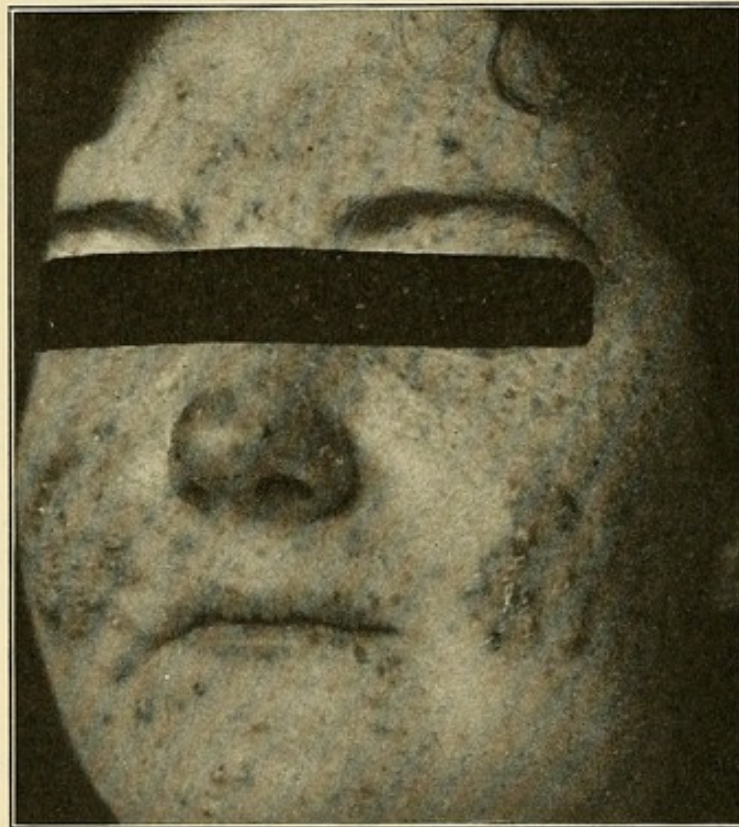


FIG. 31.—ACNE VULGARIS. (Dr. Geo. C. Johnston.)

ual thus affected, and it is quite desirable that an effective treatment be instituted to eradicate them. They must be differentiated from tuberculous and syphilitic eruptions, whose characteristics are described under those heads. The history is most important.

Treatment should be directed to an improvement of the general health and the administration of alteratives and reconstitutives. Calcium sulphid in grain doses three times a day is of undoubted value. Locally the pustules may be curetted away, but these local operative procedures



should be postponed until constitutional treatment has been tested, since scars usually follow the use of surgical means. Applications of quite hot absorbent cotton saturated in boric acid solution is a most satisfactory treatment. The applications should be continued for several hours each day to be effective.

*Milium* is an accumulation of sebum near the orifice of a duct and contains but thin covering. These accumulations are usually the size of a pinhead, but may be larger. They are found most frequently on the face and about old scars, but may appear on any part of the body.

*Sebaceous cysts* develop wherever such glands are found, usually in the face, scalp, back of neck and back. They contain a cheesy material with sufficient consistency to readily stand alone when removed from the capsule. They are usually small, but may grow to considerable size. The centers are always adherent to the skin at the original location of the duct, but they are freely movable above the deep tissues. Treatment consists in complete removal of the sac, as otherwise it will return.

*Papilloma* include all those benign or rough growths of the skin and mucous membrane known as warts, villous growths and horny excrescences.

*Verruæ*, or warts, are hypertrophies of the skin or mucous membrane, due to persistent irritation. They occur singly and in crops, growing in various shapes, sometimes broad and flat, with smooth surfaces or having villi projecting from the surface, and sometimes assuming a cauliflower shape. The surface is covered with epithelium, sometimes piled up in many layers, constituting the principal portion of the growth. Treatment consists in removal with nitric or chromic acid or by excision.

*Horns* from the skin and nails grow from (a) scars, and are composed of a hardened piling-up of epithelial tissue constituting the cicatrix; (b) sebaceous tumor, caused by



the contents gradually hardening as it exudes from beneath; (c) nail horns, or abnormal growths of the finger- and toe-nails of invalids; (d) warty horns, resembling epithelial warts, except that the papillomatous projections calcify. They grow from the forehead or scalp and may as-

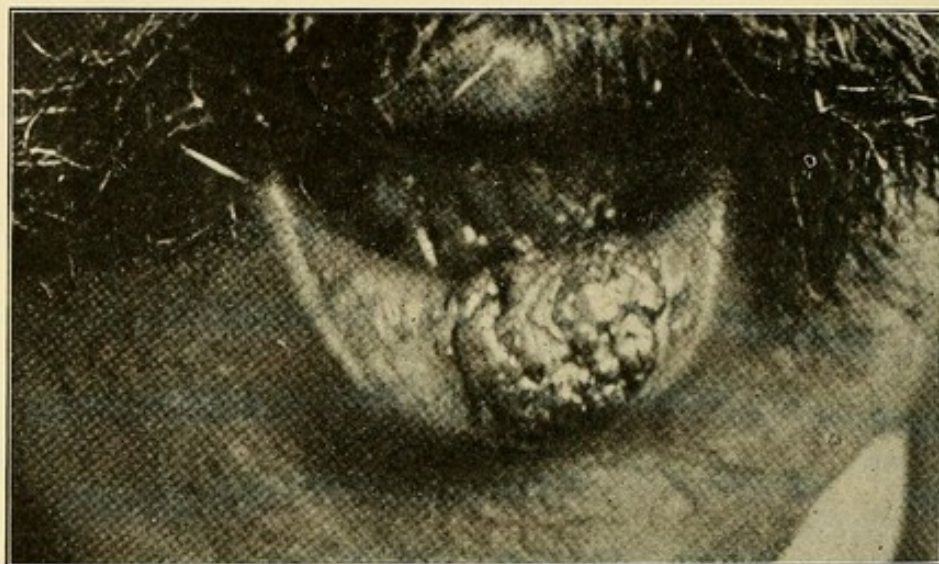


FIG. 32.—BLASTOMYCOSIS. (Hyde & Montgomery.)

sume enormous lengths. Treatment consists in removal. The sebaceous horns are dissolved by liquor potassæ.

### PARASITIC DISEASES OF THE SKIN

The parasitic diseases of the face which are of special interest to the dentist and which should be differentiated from other conditions are:

(a) *Tinea trichophytina*, or ringworm, due to the trichophyton, a contagious parasite, beginning as a brown spot slightly elevated, with a tendency to desquamation, and gradually increasing in size as the center repairs, leaving crescentic or concentric areas. The disease is most common in children. In addition to the characteristic arrangement of the eruption, the one prominent symptom is itchiness.

(b) *Tinea sycosis*, commonly known as barber's itch, is similar to the former, except that it is located in the beard.



Treatment involves the use of some parasiticide. Sodium hyposulphite is no doubt the best, a solution of one dram to the ounce being applied to the affected parts. Other remedies, such as tincture of iodine, carbolic acid, etc., are

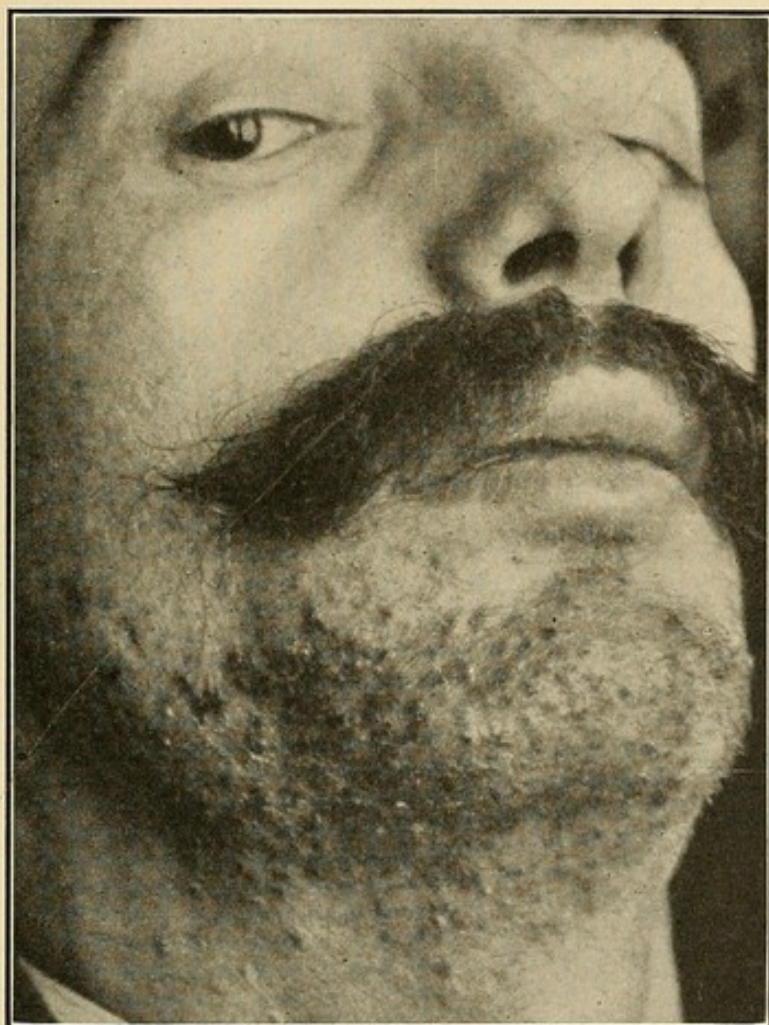


FIG. 33.—TINEA SYCOSIS. (Dr. Geo. C. Johnston.)

effective, but the first-named drug causes no pain and for this reason is to be preferred.

(c) *Scabies*, or itch, is due to an animal parasite, appearing between the fingers, where the skin is thin, and has least resistance. It appears in many very small, dark red spots in continuous chain, showing the route of the parasite as it burrows its way under the epidermis. Treatment consists in application of hot water, followed by sodium hyposulphite solutions, or sulphur ointment, for three or four



days, after which a very hot bath is taken and the clothing is entirely renewed.

### ACUTE INFECTION OF THE SKIN

*Furuncle*, commonly known as a "boil," is an acute infection of the glands of the skin or hair follicles, terminating, as a rule, in the necrosis of a central area, which comes away *en masse* and is known as the "core." *Staphylococcus pyogenes aureus* is the germ found.

The trouble may be single, when it is generally quite large, or it may be multiple, the individual infections appearing simultaneously or successively, varying in size from a pea to a walnut. The affection is quite common and the course well known. It may be described as beginning in an induration which is painful, tender and red, upon the apex of which is usually seen a small vesicle at a hair follicle, showing the point of infection. As the central mass becomes necrotic, as a result of withdrawal of nutrition, there is formed about it a suppurating area. Around this the tissues become infiltrated, red and tender. In several days it points, which means that the zone of pus approaches the surface. This spontaneously erupts if not incised, and but little pus escapes. The necrotic center can now be seen, which in thirty-six to forty-eight hours is thrown off, leaving a granular cavity healing from the bottom in a few days. In some individuals, or when the boil is large, the pain and infection may result in fever, loss of appetite, and general impairment of normal vitality. The treatment may be of two kinds: (a) Abortive, which consists in the continuous use of heat from a coil or hot-water bottle at a temperature of 110° F. for six hours. This treatment can only be effective when it is instituted before suppuration begins. Many cases have been cut short of suppuration by this method by the author. The theory of this treatment is that the colony of *staphylococcus pyogenes aureus* which pro-



duces the inflammation is destroyed by the heat. (b) If suppuration has begun, incision may be made to hasten repair. The cut must extend down into the necrotic area, which must be curetted away, the cavity swabbed with pure alcohol or tincture of iodine and packed. Such an operation should be followed in a few hours by subsidence of all active symptoms. Secondary infections are usual, and should be treated in the same way.

*Carbuncle* is one or more furuncles, of large size, running a more severe course with more marked constitutional symptoms than "boils," and ushered in by a chill. What has been said of the symptoms of furuncle applies to carbuncle, except that they are intensified many fold. The same microorganism is found. There are several openings showing the multiform character of the trouble. While "boils," as a rule, do not endanger life, carbuncles have a grave prognosis, especially when they develop on the head or face. Treatment here also may be considered as abortive and operative. Every effort should be made to cut short the course. When this is not possible, early incision should be made. This must be thorough, the line of incision extending so as to include every orifice, and may be crucial, "V"- or "Y"-shaped. Curettement and irrigation with tincture of iodine, pure alcohol or other antiseptic solution, or hot water, must be used so as to thoroughly eradicate every pocket of infection. The constitutional treatment consists in the use of anodynes to control pain, tonics, reconstructives and a nutritious and stimulating diet.

## WOUNDS OF THE FACE AND MOUTH

Wounds of the face do not differ greatly from those of other parts of the body, and are classified and treated as described under the chapter on wounds.

Incised and punctured wounds bleed very freely owing to the extreme vascularity of the tissues of the face, but



for the same reason heal readily, and, when antiseptic precautions are taken and the skin is properly adjusted, they heal with smooth scars. Great care should be taken in dressing wounds of the face—scars are very noticeable and the cosmetic appearance is a matter to be considered. After cleansing the wound, the skin should be neatly adjusted with horsehair or fine catgut suture. A small curved needle should be used, as large needles make a puncture which alone may leave a scar, and they sometimes puncture a blood vessel and produce considerable hemorrhage. A small piece of antiseptic gauze should be placed over the suture, held in position with strips of adhesive plaster. Adhesive plaster should not be permitted to come in contact with the wound, but the gauze should interpose. Even in abrasion of the skin, if adhesive plaster is permitted to come in contact with the denuded surface, infection is very likely to occur. The suture should be removed on the sixth or seventh day, or just as soon as union has taken place, so as to avoid stitch-hole abscesses.

*Contusions* of the face result from fist blows, kicks, and falls, and are followed by great swelling and discoloration, especially about the eyes, a condition known as black eye, which is a form of ecchymosis. When the blow is directly over a bony prominence, a hematoma is likely to occur, and, when care is not taken to sterilize the wound, even if it be but an abrasion, infection is likely to occur and suppuration of the hematoma follow. Severe contusion associated with fracture of the bones of the face and punctured wounds have, as a not infrequent complication, rupture of a deep blood vessel and alarming hemorrhage, or a perforation of the maxillary or another sinus. A case is recalled where a blow over the superior orbital ridge resulted in fracture of the process into the frontal sinus, requiring the removal of the ridge and anterior wall of the sinus upward for three-quarters of an inch. The wound healed without complication or sequela. Gunpowder stains should be removed at



once, under local or general anesthesia if necessary, for if allowed to remain for forty-eight hours they become permanent. The parts should be scrubbed with a stiff flesh-brush, using a one per cent. solution of mercuric chlorid. Gauze saturated with flexible collodion makes the most satisfactory dressing.

Later complications of the wounds of the face are neuralgia, contractures, cramps of muscles, twitching, edema of the tongue or pharynx, and infection either in the form of erysipelas or cellulitis. Permanent deformities are entropion or ectropion, eversion of the lips and contractions of the masseter, temporal or other muscles, causing occlusion.

A very troublesome variety of complication of wounds of the face is salivary fistula, usually of Stenson's duct. It is treated under a separate head. Anesthesia of the face can result only from a deep injury including one of the branches of the trifacial, and corresponds to the area of distribution of the nerve injured.

Death seldom results from wounds of the face, but extensive deformity is not uncommon. Poison wounds of the face, such as stings of insects, spiders, etc., should be differentiated from other varieties of facial blemishes, especially of a specific nature. The reader is also referred to the chapter on syphilitic manifestations on the face and mouth. Fracture of the bones of the face is considered under fractures.

Burns and scalds of the face should be treated as outlined in Chapter VI.

## NEUROSES OF THE FACE

*Neuroses* of the face which distort the expression or otherwise impair normal function are anesthesia, hyperesthesia, paralysis, hypertrophy, atrophy, leontiasis ossea and acromegaly, the two latter considered elsewhere.



*Anesthesia* is a loss of sensation, and when of the face it is caused by a lesion of the fifth nerve, usually located within the cranial cavity.

*Hyperesthesia* of the face is an oversensitive condition resulting from some irritation or inflammation of the fifth nerve, or it may be due to inflammation of the skin. In neuralgia there is usually hyperesthesia with pain.

*Paralysis* of the muscles of the face is due to a lesion of the seventh nerve, when the muscles of the entire side of the face droop and are expressionless. Saliva trickles from the mouth. This condition is known as Bell's palsy. When both sides of the face are involved it is known as diplegia.

*Facial spasms*, also known as a convulsive tic, are tonic spasms of a certain muscle, or possibly a group of muscles, which only appear during wakeful moments.

*Hypertrophy* of the face is usually congenital and due to some perversion of the trophic nerves during early development.

*Atrophy* of one side of the face is seen in torticollis, and is a result of withdrawal of nutrition, no doubt caused by the tonic spasm of the vasomotor nerves of the affected side.

*Risus sardonicus* is a contraction of the risorius muscles, which have their origin from the fascia over the masseter muscles and are inserted in the skin at the angle of the mouth. A spasm of these muscles produces a characteristic grin and is seen in strychnia poisoning.



## CHAPTER XVII

### GENERAL BONE DISEASES

#### **Classification of the Inflammatory Diseases of Bones.—**

Diseases of the bones fall into two general classes: *Osteomyelitis*—(1) General infective, (2) acute circumscribed, (3) chronic circumscribed, (4) acute diffused, (5) chronic diffused; and *Periostitis*—(1) Acute infective, or suppurative, (2) post febrile (following typhoid, pneumonia, scarlatina, etc.)

### OSTEOMYELITIS

**1. General Infective Osteomyelitis.**—This condition constitutes the vast majority of bone diseases. The *acute* form is less common than the chronic, and twice as many males as females are affected. The disease occurs four times as frequently among children as among adults. It is rare in mature bones. As to *location*, bones are affected in the following order: the maxilla, the mandible, either end of the tibia, lower end of the femur, upper end of the humerus, the ulna, fibula, radius, metacarpal and metatarsal phalanges. Other bones are rarely affected. The *bacterium* producing the majority of the cases is the *Staphylococcus aureus*, although other organisms may be the cause. The *course* is determined by the variety of bacterium producing the disease. *Streptococcus* produces the acute, rapidly developing disease, with chill, high temperature, stupor and, in some instances, death in a few days. *Staphylococcus aureus* is the germ present in the low-grade destruc-



tions extending over months or years. The author has had several cases without symptoms except pain—one for fifteen years, one for twelve, one for eight and one for seven, and others from three to five years.

*Predisposing factors* are general impairment of health from any cause, and exposure to which has been added an injury of the bone. Growing bones are also a factor. *Infection* occurs by inoculation from abrasions in the mouth or nose, or from skin pustules and from eczema or other skin lesions. Staphylococci may pass through the blood current via the nutrient artery and set up the disease immediately or may remain latent for months.

*Pathological changes* that occur are much the same, whether the course is acute or chronic. The bone marrow is the primary seat of the infection, the usual point being the ossifying center where the nutrient artery terminates and spreads out in the form of loops. This being the weakest point of a growing bone, it is first injured. Congestion, which may be very slight, is the nidus or culture medium for the development of the colony of bacteria. The invaded area, first red, soon changes to a gray and yellow or may become greenish, due to the hemolytic action of bacteria. The cancellous nature of the bone may permit extensive involvement of the medullary canal before suppuration occurs. Solution of the soft tissues of the marrow first occurs, the trabecula later breaking down, and cavities are formed.

The *cortex* is invaded rather early by extension through the Haversian canals, the inflammatory exudate escapes through it, and the periosteum may be lifted for a considerable space. *Abscess*, subperiosteal, is formed, which may break through the tissues and skin. *Toxemia* and death may ensue if prompt incision is not made. *Spontaneous fracture* may occur as the result of destruction of the cortex or at the epiphysis.

*Sequestrum* is formed as the pus lifts the periosteum



from the body of the bone or shaft, and the periosteum, because of its regenerating function, proceeds to build up new bone and an involucrum is formed. *Regeneration* of bone is from the periosteum and endosteum, principally the former. Bone has little if any power to repair itself. *Destruction* of bone is irregular and repair is also irregular and coextensive with the preservation of the periosteum and endosteum. When these membranes have been destroyed there can be no regeneration.

**2. Acute Circumscribed Osteomyelitis.**—This is a very common form, and is sometimes called bone furuncle. The *symptoms* are localized pain with tenderness later. There is no swelling unless the periosteum is secondarily involved. Pain is most severe at night, especially in syphilitics. The joint is usually freely movable. The condition is usually *located* at an ossifying center, such as the lower end of the tibia or the femur. The *course* is rather subacute, with acute exacerbations, when the pain is very severe and when the patient may lose weight. *Diagnosis* is confirmed by the use of the X-ray, which will show a light area near the epiphyseal line.

**3. Chronic Circumscribed Osteomyelitis.**—Chronic circumscribed osteomyelitis may continue from the acute form, becoming latent with recurring attacks of pain. There may be nothing more than a displacement of organic structures, with pus and some destruction of the trabecula. A distinct cavity may not form for several years, as was observed by the writer in three cases. In other cases a distinct abscess will be found which may extend throughout the shaft and a sequestrum is usually found. *Symptoms* will include pain and loss of weight. Other local symptoms, such as swelling and redness, are absent, only occurring when the cortex is perforated and the pus escapes underneath the periosteum.

**4. Acute Diffused Osteomyelitis.**—Acute diffused osteomyelitis has a sudden onset with chills and high tempera-



ture. Prostration and stupor are marked. This is followed by coma and death unless the source of the toxemia is destroyed. *Pain* is severe and confined to the bone involved. Extension to the periosteum produces swelling, redness, a glazed skin and spontaneous eruption. The *abscess* may be large, since the pus may burrow throughout an extremity in a week or so when diagnosis and operation are not made.

The bacterium causing the acute form is streptococcus. The *pathological changes* in the bone are usually extensive. Multiple abscesses are found in some bones. In others the entire shaft is involved, extending to the epiphysis. In streptococcic infection it is not unusual for the disease to extend into the joint cavity. When extensive destruction occurs, troublesome sinuses or deformity are not infrequent results. *Recovery* should result when prompt incision, drainage and disinfection are carried out. Sequestrotomy and even amputation are in many cases demanded.

**5. Chronic Diffused Osteomyelitis.**—Chronic diffused osteomyelitis resembles the tuberculous and syphilitic forms. Indeed, it is a question whether it is not usually specific rather than true osteomyelitis.

**Differential Symptoms.**—In all forms of osteomyelitis there is no swelling unless the periosteum is secondarily involved; *pain* is localized, but may radiate to other parts of the same extremity; *tenderness of the bone* is generally found to be more marked at the epiphyseal line; and *temperature* ranges in proportion to the toxemia, which depends upon bacterial activity and increases with pain and persists through abscess formation, but drops, as a rule, when the abscess is opened. *Periosteal involvement* produces swelling or edema which pits on pressure, redness of the skin resembling erysipelas or extension under the skin resembling cellulitis. *Rheumatism* is the one condition confounded with this disease more frequently than any other.



*Localized pain* in a bone or joint is seldom, if ever, rheumatism. The X-ray should always be used when available.

**Local Complications.**—The local complications are *arthritis* by extension into the joint, and *fracture* (pathological) due to destruction of bone and very slight violence.

**General Complications.**—Pyemia is a general complication in which secondary foci may be found in other bones. Endocarditis, infective embolism, metastasis, etc., are not uncommon. During active attacks the patient is dull, listless, restless and may become delirious. *Typhoid condition* (so-called) is present and this disease is often confounded with osteomyelitis. *Scarlatina* is also mistaken for osteomyelitis, since in some cases there is an erythema, with scanty urine containing blood and albumen.

**Differential Diagnosis.**—Differentiation must be made from superficial inflammation, erysipelas, cellulitis, primary periostitis, rheumatism, and arthritis of various forms.

**Prognosis.**—The prognosis is good when a diagnosis is made early and proper drainage, disinfection, etc., are carried out promptly. *Procrastination* means death or extensive destruction in the acute cases and, in the chronic cases, disability due to destruction of bone.

**Treatment.**—1. Drainage may be made by drilling, followed by chiseling to make an opening large enough to reach the seat of the disease.

2. Curettement should be done cautiously, yet with sufficient thoroughness to remove all detritus, pus or sequestrum, and until red or bleeding bone is reached.

3. Tincture of iodine (U. S. P.) should now be poured into the cavity and permitted to stand there for from three to five minutes. When a cavity is deep a syringe long enough to reach the bottom of it should be used. Gauze may be saturated with tincture of iodine and packed into the cavity when it is found more convenient. The iodine will infiltrate into the cancellous bone and reach out and destroy germs in the zone of invasion far beyond the extent



of curettement. Iodin poisoning need not be feared, as the author has used an ounce without a toxic symptom. Excessive amounts of iodine placed in a cavity should be mopped out after three or four minutes.

4. Permit the cavity to well full of blood, and seal. If, however, hemorrhage is excessive, it may be necessary to pack the cavity for twenty-four hours, after which time packing should be removed. The wound will usually well full of blood and it should then be sealed as before.

5. Skin wounds should be closed with catgut or silk-worm gut. When there is doubt as to the thoroughness of the disinfection, etc., drainage may be left through the skin only to guarantee against possible infection of blood-clot.

6. Second dressing is used only when symptoms of return of pain or temperature demand it, which may not be for a week.

*Blood-clot organization* is typified in the repair of the maxillary process after the extraction of teeth. Here we may extract many teeth, leaving holes of considerable size which are immediately filled in with blood, and even the patient never hear of it again. Why not larger cavities? As must be well known to all observing surgeons, no operation is performed without there being more or less blood-clot interposed between the flaps and portions of the area included in the operation after adjustment of sutures. This blood-clot is nature's method of filling in cavities and vacant spaces which must necessarily exist. To be sure, these cavities vary in size in different operations. They disappear and the wound entirely heals without the surgeon's being cognizant of their existence in all sterile wounds. This is what surgeons choose to call blood-clot organization.

The *method of repair* is about as follows: The blood-clot which fills in the cavity serves as a trellis work into which the leucocytes begin to pour from the healthy blood



vessels immediately after all operations and injuries. In the course of a few days the blood-clot has been entirely displaced by the scavenger leucocytes and the cells thrown out along the margin of the wound for the purpose of reconstruction and repair. The reparative cells eventually take the place of the leucocytes and become thoroughly organized, and the cavities are thus filled in with the new-formed tissue or scar tissue.

The practice of packing sterile cavities with gauze at every dressing is, in the author's opinion, wrong, since it breaks down and destroys blood-clots and valuable plastic material thrown out by nature to rebuild damaged tissues. If gauze is pushed into the center of the bone cavity daily, months will be required for repair of such a large opening in the center of the bone. If the work has been complete, all active symptoms will have disappeared and the conduct of the wound will be the same as that of wounds after operations in soft parts. This is not a theoretical proposition, but it has been demonstrated in practice in a sufficient number of cases to claim for it a place in surgical practice.

## PERIOSTITIS

**Classification** (Peters).—Cases of periostitis fall into two classes: (1) *Suppurative* disease, a sequel or terminal result of acute osteomyelitis, or diffused periostitis; (2) *post-febrile periostitis* following typhoid fever, pneumonia, scarlatina, measles, etc.

1. **Acute Suppuration.**—Some authorities doubt the existence of an acute suppurative periostitis as a primary condition, but say that it is a cortical osteitis or is secondary to an acute osteomyelitis. The *causes* may be *predisposing*, such as a weakened resistance from any cause, and a slight contusion; and *exciting*, such as the presence of some bacterium, as streptococcus (acute form) or staphylococcus (in subacute form), to which is usually added an injury.



*Pathology.*—The injury results in congestion of the periosteum, the stasis of blood being a nidus for implantation and growth of the bacteria. The disease is usually circumscribed. The *fluid accumulation* is at first serous and only becomes purulent when sufficient time has elapsed for phagocytosis to occur. Extensive accumulations of serum may form in two or three days. The *symptoms* are *swelling*, which is prominent from the beginning; *edema* which pits on pressure, which is almost pathognomonic of periostitis when associated with local acute symptoms; and, in acute forms, *chill*, high temperature, frequent pulse, red and glossy skin, severe pain during the early stage, poor appetite, sleeplessness, emaciation and general loss of vital forces, and boggy and fluctuation, which will be observed as liquid accumulation increases.

*Treatment.*—The following measures are to be adopted: (1) Incision down to the bone, opening to be long enough to guarantee free drainage; (2) disinfection with tincture of iodine after the wound has been thoroughly cleansed; (3) closure of the wound in all acute cases to permit the periosteum to adhere to the bone, which can be expected when the operation is complete and the wound sterile.

**2. Post-febrile Periostitis.**—Typhoid and other post-febrile conditions not uncommonly develop as sequels to this disease during reduced resistance. *Cultures* of the product show pure typhoid bacillus when it follows this disease. Keene reports thirty-seven cases. *Treatment* consists in incision, disinfection, and drainage through the skin. Repair is usually prompt, without exfoliation, unless there has been great delay in operating. Other post-operative periostitis or osteomyelitis requires similar treatment. Tuberculous and syphilitic diseases of the bone and periosteum are to receive special consideration under those heads.



## CHAPTER XVIII

### DISEASES OF THE MANDIBLE

After the student has made a study of the preceding chapter and has mastered the subject of bone diseases in general, he will have little difficulty in understanding diseases of the bones of the face as they are seen in dental practice.

The bones of the face which may be diseased, and, therefore, of special interest to the dentist, are the mandible, the maxilla, the palatine, the ethmoid, and the pterygoid plates of the sphenoid.

**Classification.**—The diseases may be classified etiologically as follows: 1. Alveolar necrosis. 2. Periostitis of the body. 3. Osteomyelitis. 4. Chemical necrosis—a. phosphorus; b. mercury; c. arsenic. 5. Exanthematous—a. scarlatina; b. measles; c. typhoid; d. pneumonia.

Death of the bones of the face may occur as a necrosis or death *en masse*, and a caries or a molecular disintegration of the bone. These terms are intimately associated, for caries or molecular disintegration is present at the periphery of the diseased area before the sequestrum can be cast away from the healthy bone, and when the sequestrum is in very deep tissue, as the body of a vertebræ, a large piece of bone may dissolve by a carious process. In fact, these terms apply to incidents in the history of a disease when it is considered etiologically and not to distinct diseases. However, much respect must be given them because they have been revered since the beginning of medicine.



**Faulty Use of Hypodermic Syringe as an Etiological Factor.**—In the author's experience the injudicious use of the hypodermic syringe to produce local anesthesia before extraction is a most fruitful source of acute periostitis, resulting in exfoliation of a portion of the alveolus. Death of bone may result by infection from the needle; or it may follow the mechanical destruction of the periosteum caused by the needle's being pushed into the membrane, the anesthetic being forced into the tissues destroying its vitality; or the needle may be forced between the bone and the periosteum, lifting the latter, thus causing death of bone.

### ALVEOLAR NECROSIS

A most common condition and one frequently seen by the dentist is simple exfoliation of the alveolar process, as a result of suppurative conditions about the teeth, such as alveolar abscess, traumatism, extractions, ulcerative stomatitis, or other gingival destructions or infections. As a rule, such minor conditions are cared for by the dentist. A portion of the bone representing the process over a tooth is removed, and repair follows in a few days.

Occasionally the disease runs a more grave course, larger areas of bone are involved, suppuration is continued, and a sinus, persistent in its nature, is established. These conditions run a very acute course and are caused by the introduction of streptococcus or some other active bacterium into the tissues.

**Symptoms.**—The most important symptoms are persistent pain and swelling that pits on pressure, known as edema, tenderness, rigors and possibly chills, followed with slight fever. All swelling of the process, however, must not be considered a forerunner of serious necrosis. Indeed, such a result would be the exception.

**Diagnosis.**—The diagnosis is very important since it is



upon the early and proper management of such a case that the subsequent history depends.

**Prognosis.**—The prognosis is very good if the trouble is recognized and incised before pus formation. Even after pus formation, recovery may take place if delay has not been too great.

**Treatment.**—The treatment includes the removal of the cause. If stomatitis, use local antiseptics and control infec-

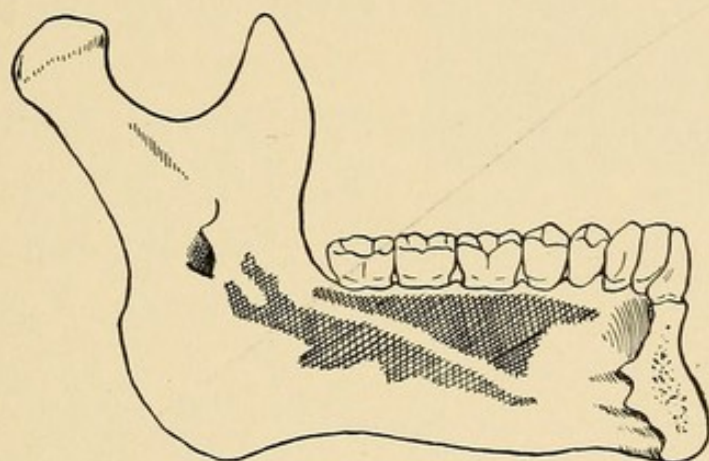


FIG. 34.—PERIOSTITIS OF MANDIBLE. Showing area of exfoliation of bone from internal surface.

tions. Disinfect the ulcer early with tincture of iodine, with the hope that sequestration will not occur. Early curettage of the bone and disinfection, in cases where the periosteum is involved, may also induce repair without exfoliation. When the latter is evident, time should be given for the line of demarcation to be established before extensive operations are performed. It should be remembered, however, that the great majority of cases are averted by early incision and disinfection.

**Traumatism.**—Injuries of the alveolus, other than those from tooth extractions, may come from blows or be associated with fractures. Here we usually have infection, periostitis and exfoliation of a portion of the external table of the bone, as the accompanying case shows.

A boy, aged twelve years, received a blow over the right side of the mandible with sufficient force to loosen two



teeth. Shortly afterward the wound became infected, and during the course of several weeks extensive swelling, pain and constitutional symptoms developed. At the end of two months an examination showed that the lingual alveolar margin for more than an inch was exposed and imbedded in pus and surrounded by granulation tissue. At this time, under local anesthetic, the bone, as shown in Fig. 34, was removed. Other smaller pieces exfoliated later. The teeth were, however, all preserved except the second bicuspid.

### PERIOSTITIS OF THE BODY OF THE MANDIBLE

This variety of disease usually follows infection from the gingival margin, extending along the bone under the

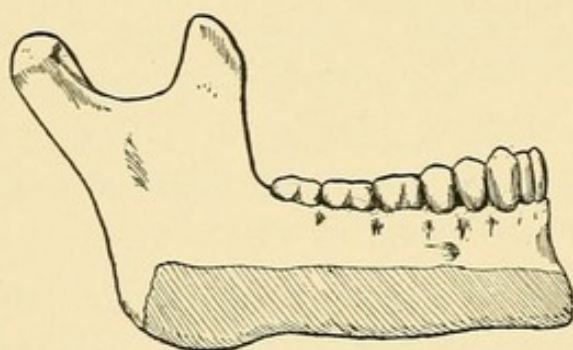


FIG. 35.—PERIOSTITIS. Shaded portion showing area of denuded bone.

periosteum. Some of these cases are most persistent, and the dentist or family physician may carry out the usual methods of treatment, such as injections with supposedly valuable germicidal remedies, without repair. In such cases a radical operation is neces-

sary before repair can be effected.

**Treatment.**—When the existence of a periostitis is fully determined, a free incision should be made down to the bone, for just as soon as the colony of bacteria that is causing the trouble is reached and disconcerted, their activity ceases and repair begins. When, however, myriads of bacteria are permitted to go on and multiply and destroy living cells, destruction is relatively great. The early treatment would appear to be applications of iodine and heat or ice, to be followed by incision in two or three days if no improvement is obtained by these remedies.

**Illustrative Case.**—A boy, aged twelve years, had a sinus



from the right side of the mandible for several months, which failed to repair even after operations and medication. A free incision from the facial artery to the symphysis, baring the bone, as shown in the drawing, was made. At some points along the under surfaces of the body of the bone little vitality was shown, and the surface was chiseled away until blood oozed from the entire surface. The cavity was then thoroughly disinfected with iodine. The periosteum was first sutured with fine catgut. The skin was closed over this with silkworm gut. Nothing but silkworm gut drainage was used. The wound healed as promptly as occurs following clean wounds without a drop of pus or a symptom. (Figs. 35 and 36.)

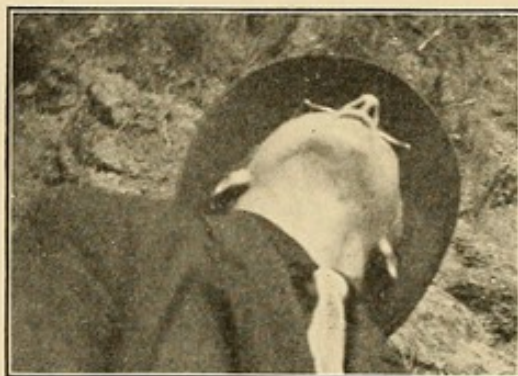

FIG. 36.—PERIOSTITIS. Photograph ten days after operation showing immediate repair without symptoms.

### OSTEOMYELITIS OF THE BODY OF THE MANDIBLE

A more severe form of acute periostitis and other destructive diseases of the bone are dependent upon causes independent of the teeth and only secondarily involving them. The usual causes are blows and injuries associated with extractions, such as fracture of the process opening up a deep area for infection.

**Causes.**—These conditions may develop as a periostitis or, from the surface of the bone, as an osteomyelitis, beginning in the central canal, the infection gaining entrance through the root of a tooth. Injudicious use of *arsenic* in the treatment of root canals is unquestionably a cause of extensive necrosis. Several cases from this cause have been under treatment.

**Illustrative Cases.**—(1) A patient, a man aged fifty, with infection of the mandible, had lost all of his lower teeth but



three, and the cavity included practically all of the mandible on its external surface, the bone being bare throughout. The alveolar process, on its external margin, including the cavities left by the extracted teeth, stood out perfectly nude in the floor of the mouth. It had required just a month for the case to advance to the condition described. The oper-

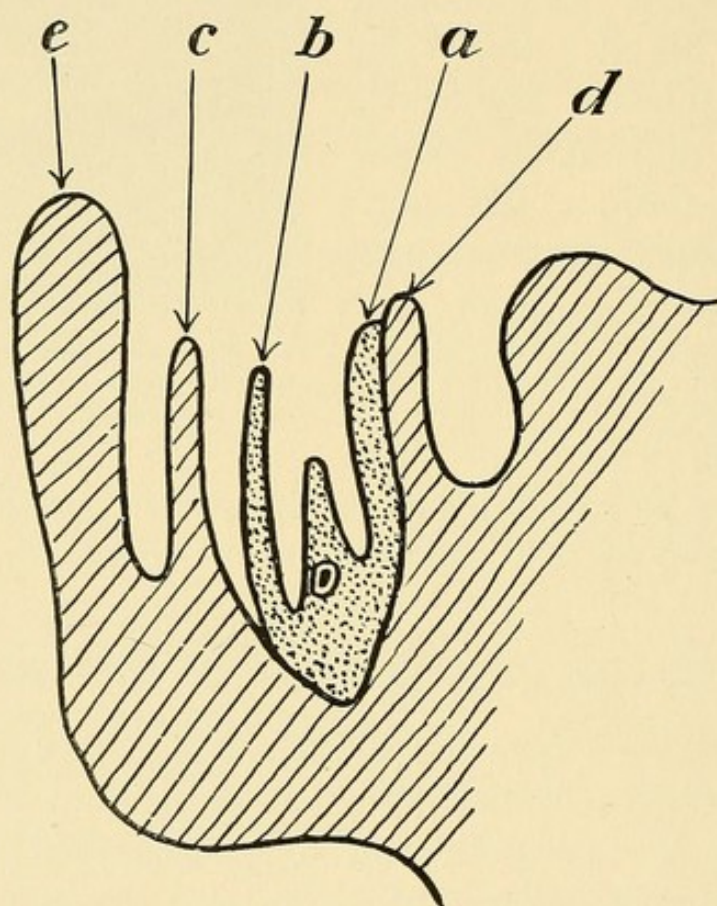


FIG. 37.—ALVEOLAR PROCESS IN OSTEOMYELITIS. a. Internal alveolus; b. external alveolus; c. external gingiva; d. internal gingiva; e. lip.

ation included a complete removal of the external half of the mandible from the second molar on the right side to the second bicuspid on the left, through the roots of the teeth and to the external inferior margin of the bone. This left the internal alveolar plate intact throughout with the periosteum undisturbed. The cavity was mopped out with pure tincture of iodine. The usual method of procedure would doubtless have been to pack the entire cavity, with the hope that the bone would heal by being granulated over



from later approximation of the external periosteum. It was decided, however, that such an extensive cavity should be immediately obliterated. Dependent drainage was absolutely necessary if this were to be accomplished; hence, an incision was made from the lowest point of the cavity in the median line through the skin under the chin large enough

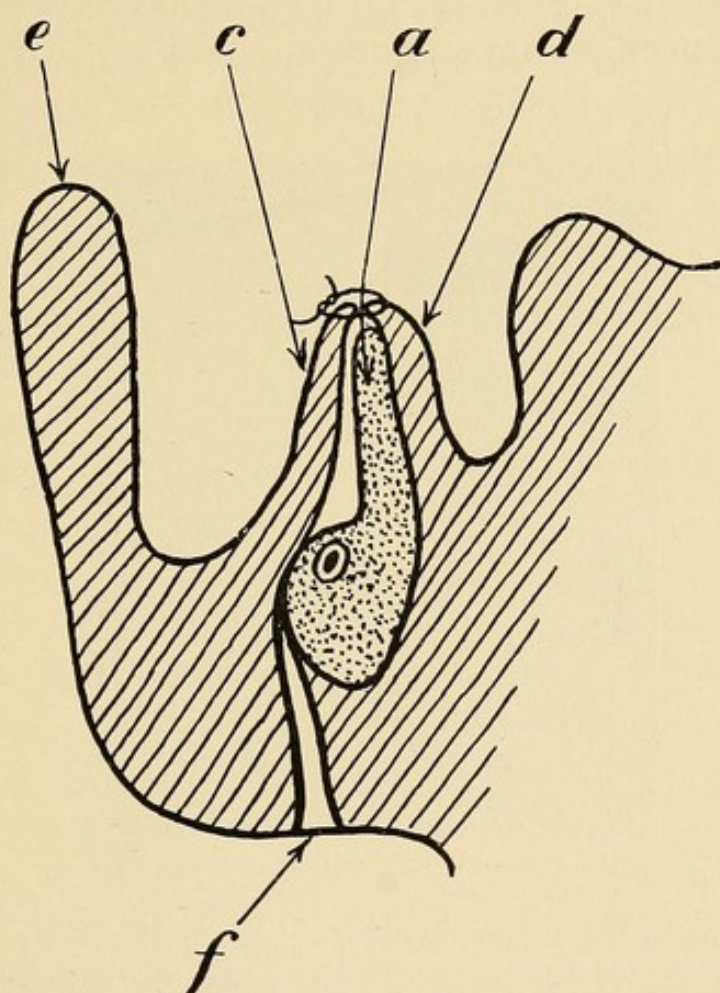


FIG. 38.—ALVEOLAR PROCESS IN OSTEOMYELITIS. a. Internal alveolus; c. external gingiva; d. internal gingiva; e. lip.

to admit a rubber drain the size of a lead pencil. The next step was to stitch together with catgut the labial and buccal gingival margins, thus closing off the field of operation entirely from the oral cavity. (Figs. 37 and 38.)

*Post-operative History.*—The two gingival margins completely united and not a drop of pus was ever found in the oral cavity. The drainage established from below was quite sufficient to carry off the small quantity of reparative



lymph and detritus and the patient was practically well in ten days after his operation.

This method of obliterating cavities is applicable regardless of the extent of operation, whether of one or many teeth, or of the mandible or the maxilla, or whether of the alveolus or of half of the body. It is well in such cases to disinfect the cavity and close it off as nearly as possible. In both instances iodine should be used to disinfect and an effort should be made to obliterate the cavity in order to

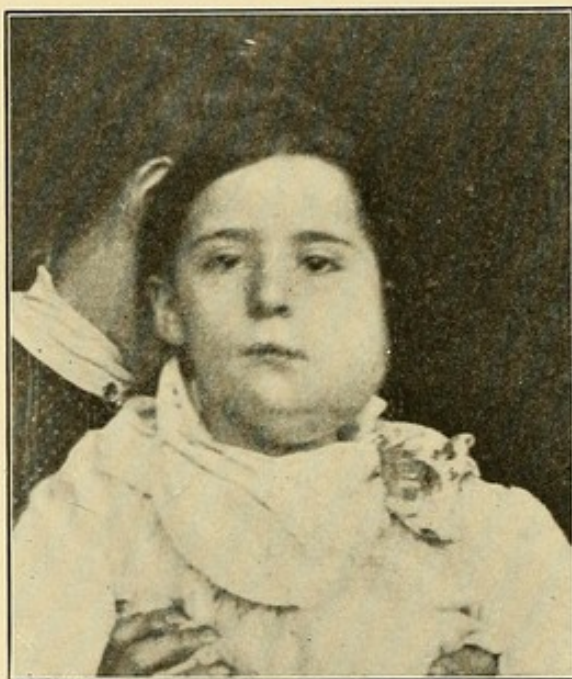

FIG. 39.—OSTEOMYELITIS OF THE MANDIBLE.

preserve blood-clot organization. In neither of these cases should the wound be packed, because the blood-clot of repair will be destroyed. Besides, the soft tissues will be pushed away from the bone and, further, death of bone must be expected.

It is not advisable, however, to establish drainage as in this case, except in very extensive destructions. In view of the almost certain possibility of a spontaneous opening in severe cases, an incision made where the scar will show the least is preferable to the establishment of an opening where the scar may be dimpled and on the external surface of the bone.



(2) Figure 39 shows a girl, aged five years, who had extensive enlargement over the left angle of the mandible. There was a sinus three inches below this bone just at the posterior margin of the platysma leading up to the angle. Several sinuses also terminated in the mouth. The bone was denuded at several points. This condition was preceded by a history of abscess formation, pain, and spontaneous eruption. The bone was denuded of periosteum along the external surface of the ramus and the greater part of the bone was removed, only a thin table upon the internal surface remaining. Operation consisted in chiseling away the entire process down to the central canal and removing at least the upper half of the bone at the angle. The cavity was not packed, but the external periosteum was allowed to collapse upon the bone with the hope that it would become adherent. Repair followed in a few weeks.

### CHEMICAL NECROSIS

Chemical necrosis includes all those destructions of bone due to the corrosive action of drugs, either by inhalation or by their internal administration or local application. Drugs which have caused death of bone are phosphorus, mercury and arsenic.

#### PHOSPHORUS NECROSIS

Phosphorus necrosis is usually of the alveolar process and more frequently of the mandible than of the maxilla. It is found in the younger workers in match factories, and is due to the corrosive action of the fumes of phosphorus upon the bone or its membrane. It was thought by some that it acted through the system like mercury, but all are now of the opinion that its action is entirely local. The corrosive action upon the periosteum and bone structures gains access either through an abrasion about a tooth or through an exposed pulp or open root canal, probably the latter.



The first symptom is an ache, which gradually increases in severity until the pain becomes excruciating. The gums swell and bleed at the gingival margin. Swelling increases and the gums ulcerate and a condition of pyorrhea alveolaris is developed. Fistulous openings form through the mucous membrane and not infrequently through the skin. The sequestrum is rapidly separated as the extent of the disease is defined, and involucrum rapidly forms, producing a permanent hard enlargement throughout the course of the disease. One very prominent and early symptom is a characteristic fetor of the breath.

The disease does not develop except where yellow phosphorus is used. In Denmark, where this variety of the element was superseded twenty years ago by sesquisulphid of phosphorus, a case of phosphorus necrosis has not been seen since.

*Prognosis and treatment* are the same as for other forms of necrosis.

*Phosphorus necrosis of the maxilla* is rare and when it does develop is more amenable to early treatment because of the advantage in drainage. Otherwise, the treatment does not differ from disease of the mandible.

#### MERCURIAL NECROSIS

Mercurial necrosis is practically unknown to the modern practitioner of medicine or dentistry because of a more judicious use of this drug in recent years. In this disease destruction of tissue is extensive. It begins in the gums with a bluish tinge. This is followed by ulceration and involvement of the alveolus and adjacent oral tissues. The teeth become loose and are removed or drop out. The mandible and maxilla are destroyed. Death results in many of the cases. *Treatment* differs little from that for other forms. The administration of large doses of potassium iodid is thought to eliminate the mercury from the system and to encourage repair and eventual recovery.



## ARSENICAL NECROSIS

Arsenical necrosis is dependent upon the too free use of this drug by the dentist, for the purpose of devitalizing a tooth-pulp, or upon the imperfect sealing of the drug in the cavity. It is most common in children because the apical foramina are larger and the drug is more likely to reach the peridental membrane, and from there come in contact with the bone. The dentist should carefully observe instructions as to the use of arsenic for fear of pro-

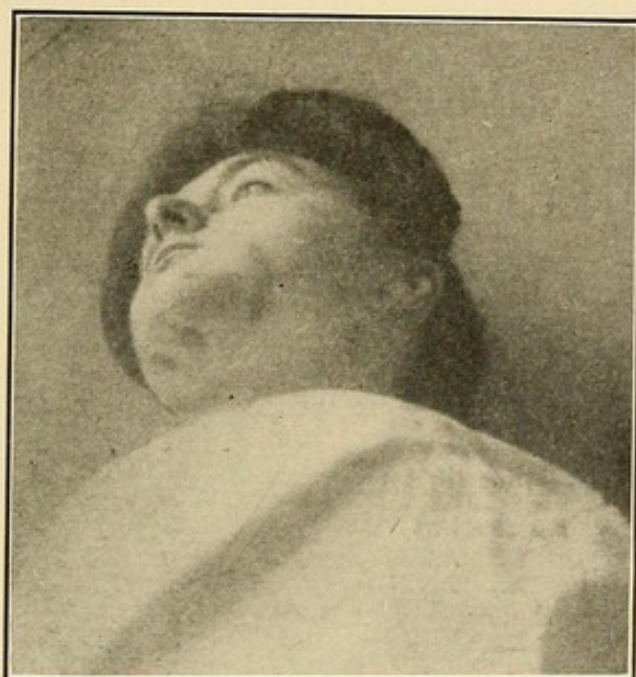


FIG. 40.—ARSENIC NECROSIS.

ducing necrosis, since the drug, when it comes in contact with the bone on the side of a tooth, will destroy its nutrition, and result in death of the process.

*Treatment* consists in the application of a chemical antidote—hydrated sesquioxid of iron, if the case is seen early, but when the destruction is well defined this is of no value. Extensive necrosis is not usual, the disease being confined to the bone immediately around the tooth. The sequestrum usually separates, and, after its removal, repair takes place and no important ill consequences follow.

**Illustrative Case of Arsenic Necrosis.**—In May, the first



lower molar, after the usual treatment to devitalize the nerve, etc., was capped with gold. One month later, June 2nd, the bone began to swell back of this tooth. An abscess formed and was incised by a surgeon. This operation was no doubt as thorough as conditions demanded at the time.

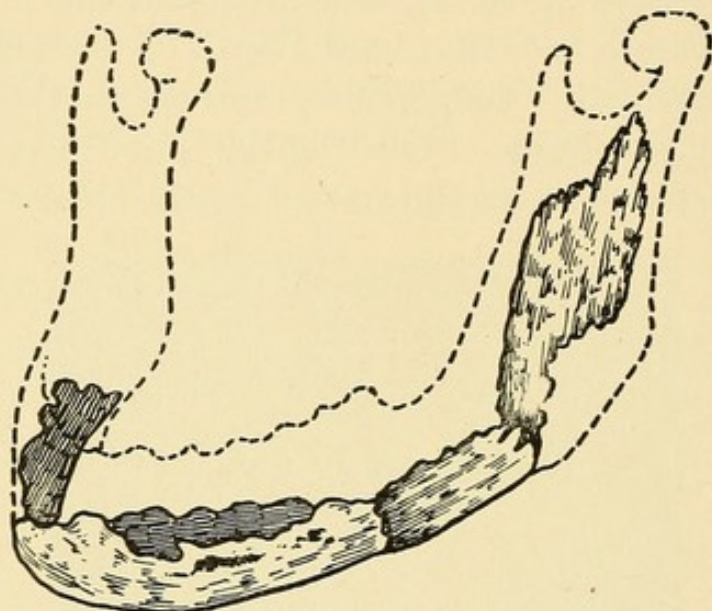


FIG. 41.—SCHEMATIC OUTLINE OF BONE REMOVED.

July 6th, two other abscesses showed themselves along the body of the bone and at the symphysis, and were incised

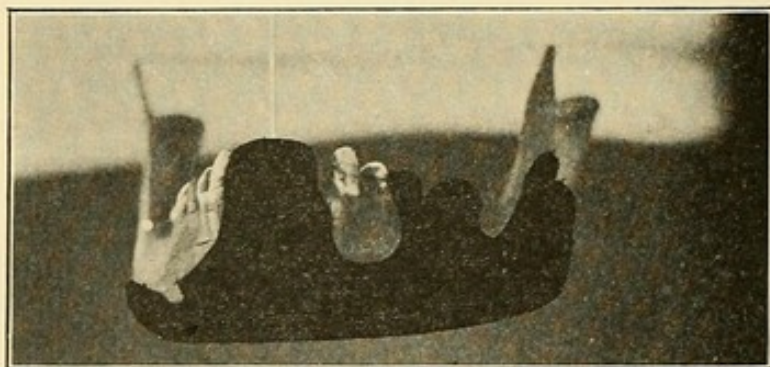


FIG. 42.—REPRODUCTION ON MANDIBLE OF BONE DESTROYED.

by the same surgeon. October 16th there were several discharging sinuses through the skin below the bone and several openings into the mouth, all discharging profusely. The patient lost weight and was suffering with constitutional sepsis. A radical operation was advised. Operation through the mouth was done under a general anesthetic.



Incisions were made along the process and external sulcus as necessary to remove the sequestra. The teeth that were loose were removed. The cavity from which the bones were removed extended throughout the length of the bone, as indicated above. Some small bones were removed at subsequent times without anesthetic. The patient made a perfect recovery and was entirely well in a few weeks. There

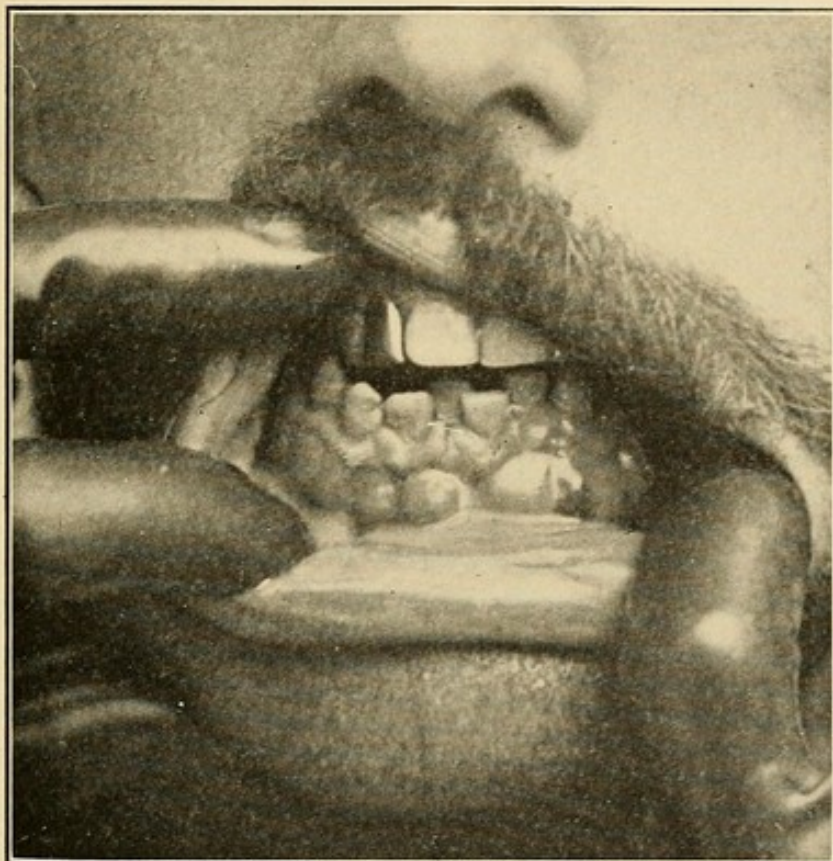


FIG. 43.—SUPPURATIVE PERIOSTITIS OF THE MANDIBLE. (Dr. J. Howard Crawford.)

was no deformity of the face. With a partial lower plate, functional usefulness of the parts was practically normal. (Figs. 40, 41, 42.)

**Illustrative Case of Periostitis.**—Figure 43 shows extensive suppuration of the entire alveolar process of the mandible, with the teeth and gum practically floating in pus, the buccal alveolar process being bare throughout.

The author saw the case thirty days after the onset of the trouble, when all of the teeth had been extracted. Op-



eration similar to the one described in the preceding case was performed, which included the removal of the external half of the mandible and all of the teeth throughout, back to the lingual plate and to the bottom of the sockets. The labial and lingual gingival margins were sutured throughout with thirty-day catgut, and drainage established underneath the chin. The case did not, however, repair so promptly as the one just described, due no doubt to the fact that there was likely a specific element to contend with. It, however, finally repaired without any further operation, with the exception of the removal of two or three small sequestra.

### EXANTHEMATOUS NECROSIS

From time to time there are developed as sequelæ of certain acute diseases, such as typhoid fever, scarlatina, measles and pneumonia, inflammatory destructions of bones, joints, glands, etc. The inflammation begins shortly after cessation of fever and other active symptoms, as pain in a bone, developing rapidly into an acute osteitis or periostitis. The course is not very different from that resulting from streptococcic infection, except that it is less acute. The history of the preceding disease and the local symptoms of osteomyelitis must be considered in making a diagnosis. Treatment is not different from that already outlined.



## CHAPTER XIX

### DISEASES OF THE MAXILLA

#### ACUTE SUPPURATIVE DISEASES

Several cases of acute suppurative disease of the body of the maxilla have been under treatment. In three recent cases the periosteum was lifted from the bone for a greater portion of the external surface. The development in two of the cases was rapid. Another patient had tuberculosis of the hip at the time. *Treatment* consisted in making a free incision to the cavity. After the pus escaped, the cavity was thoroughly disinfected with tincture of iodine. The cavities were not packed. The bone was curetted in two of the cases. No symptoms developed in any of them. The wounds repaired, the periosteum readhered to the bone, and no necrosis followed.

Such prompt repair after diseases of the maxilla is dependent upon favorable drainage, as against no drainage from the mandible. In no case of disease of the maxilla should the skin be incised. All incisions should be made within the mouth, usually through the highest point of the sulcus.

*Complications* by loss of portions of the maxillary bones are deformity, perforation of the nasal and antral cavities, leaving permanent fistulæ, antral suppuration and nerve injuries. Probably the most troublesome complication is naso-oral fistula. In several cases this condition resulted, and a second plastic operation was required.

A. A. J., aged fifty-eight years, went to a dentist for the



extraction of a right lateral root, which was very small and was causing but little inconvenience. The dentist used a local anesthetic with the usual care, taking such precautions as sterilizing his instruments and the tissues. There fol-

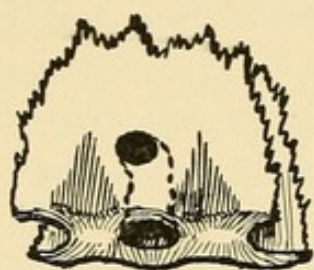


FIG. 44.—SEQUESTRUM REMOVED FROM THE MAXILLA. Note the opening through the process from the apex of the tooth socket, indicating the point where the original alveolar abscess which was the cause of the trouble spontaneously opened through the bone, and by burrowing under the periosteum destroyed the nutrition to the bone in every direction until three teeth were involved. This typically illustrates what occurs in all cases of failure to promptly incise alveolar abscesses.

lowed, however, in the course of twenty-four hours, extensive periostitis, which resulted in the complete destruction of the processes, including one tooth before and one behind the extracted tooth, and extending up toward the anterior nares about three-quarters of an inch. The bone separated, and the line of demarcation having been formed, the sequestrum was removed about two weeks after the trouble began. The cavity was freely curetted and sponged out with iodine. In a few weeks the patient was entirely well.

An operation which has been done in several cases for the closure of naso-oral fistula may be described as follows: Assuming that the labial gingival structures are completely destroyed and that the lingual periosteum and mucous membrane extend well down to the normal line, two incisions are made through the latter structure, either with scissors

or knife, back up to the orifice of the fistula and far enough back on the two sides to make the tongue wide enough to cover the opening. The end margin of the flap thus made is freshened and the corners made round. The next step is to freshen the orifice of the fistula for a distance equal to the thickness of the flap. The flap is now turned up over the orifice of the fistula and sutured there with chromicized catgut. In the three cases in which the operation has been performed the results have been satisfactory (Figs. 45, 46, 47).



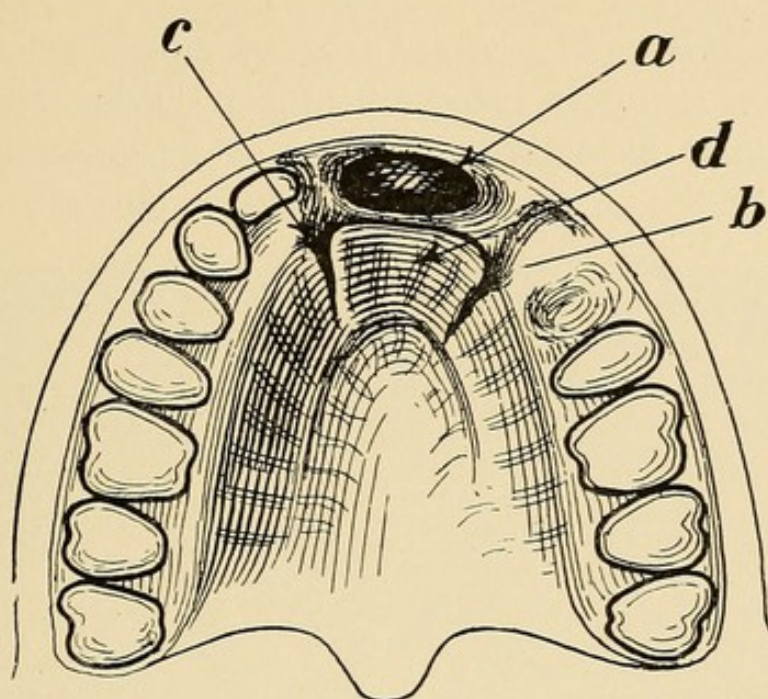


FIG. 45.—METHOD OF CLOSING NASO-ORAL FISTULA. *a*, opening into nose; *b* and *c*, incisions; *d*, flap to be turned upward and outward over *a*.

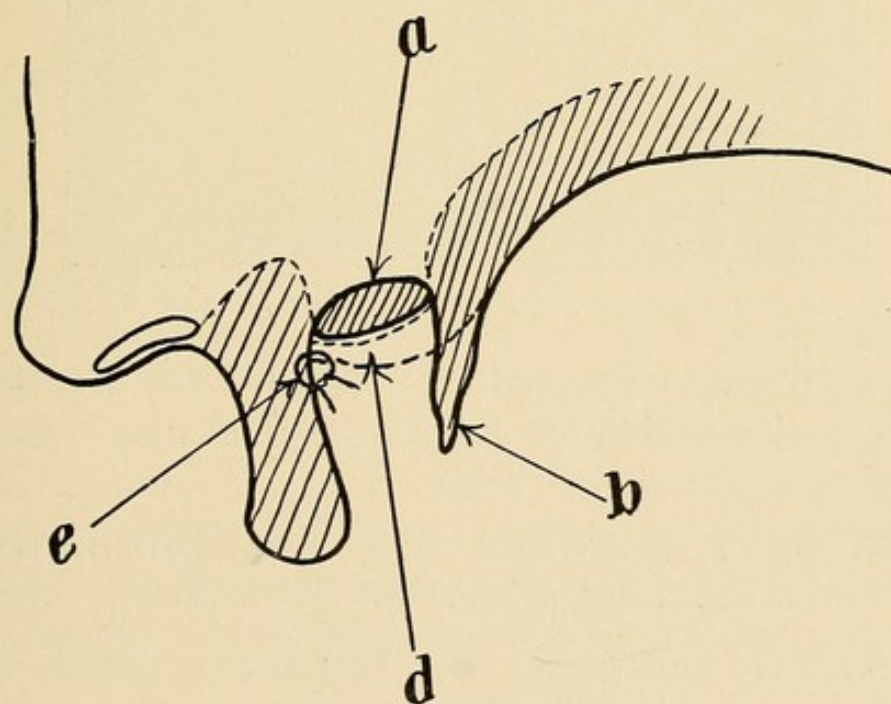


FIG. 46.—COMPLETED OPERATION FOR NASO-ORAL FISTULA. *a*, fistula with flap over it; *d*, flap in new position; *e*, sutures.



**TUBERCULOUS DISEASES**

These conditions, *per se*, are not so common as those associated with acute infection and syphilis, but are occasionally found associated with lupus and secondary to a general infection. The course is very chronic and never

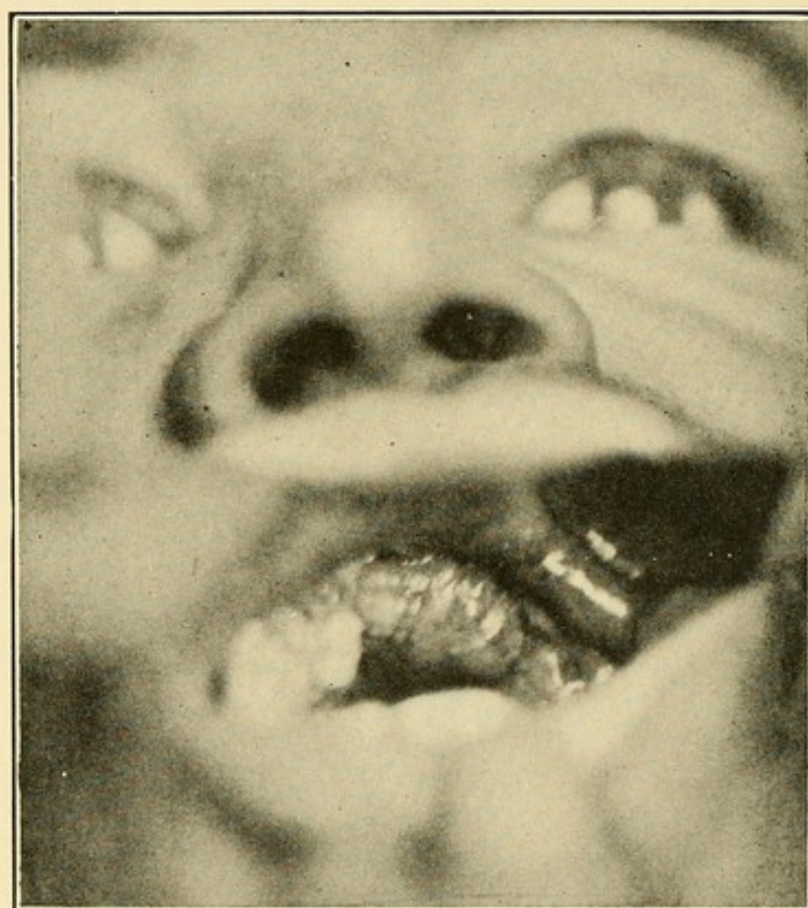


FIG. 47.—FINAL RESULT OF OPERATION SHOWN IN FIGS. 45 AND 46.

becomes active unless mixed infection occurs. For further consideration, see chapter on Tuberculosis.

**DISEASES OF THE BONES DUE TO LESIONS IN THE CENTRAL NERVOUS SYSTEM****TABETIC DISEASE OF THE MAXILLARY BONES**

In tabes dorsalis (locomotor ataxia) any bone of the body may become inflamed and disintegrate. In cases of obscure inflammatory changes of the jaw during middle



life, it is well to bear in mind these causes and consider other tabetic symptoms. The course is chronic. The teeth eventually fall out. There is anesthesia of the gums and possibly of the lips. There may be atrophy or suppuration with sequestration.

Local treatment consists in meeting the acute demands. No permanent impression can be made short of constitutional treatment, which is directed to the sclerotic changes in the spinal cord. Some of these cases are specific and a Noguchi-Wassermann test should be made and, if positive, salvarsan treatment should be given.

### ACROMEGALY

Acromegaly is a chronic hypertrophy of the bones and other parts of the body, and is of a nervous origin. It is also known as Marie's malady, because a French physician of that name furnished the first accurate description of a case in 1888. The morbid change which is supposed to be the cause of the extraordinary growth is possibly located in the pituitary body, but similar changes are also found in the thyroid gland. It is associated with impairment of the senses, and is characterized by abnormal growths of the skeleton, especially of the bones of the face, hands and feet. The hypertrophy extends to the skin, nails, muscles, glands and other soft structures.

So uniform and symmetrical is the growth in some instances that the afflicted pose in museums as giants. Cornelius McGrath, the Irish giant, who was seven feet and six inches tall, and the great American giant, who measured seven feet, eight and three-quarter inches, were possibly both acromegalics. In many of the recent cases reported, the tendency has been to hypertrophy of the mandible.

### LEONTIASIS OSSEA

Leontiasis ossea is an hypertrophy of the bones of the face and skull. The affected bones appear to grow uni-



formly in all directions, pressing upon vital parts, closing foramina and thus destroying the nerves and blood vessels which pass through them. When the maxilla or frontal bones are involved, the eyeball may be pushed from the orbit, and the antral or nasal cavities may be entirely obliterated.

The growth is usually bilateral. Pain is a prominent symptom. Loss of function with great deformity follows.

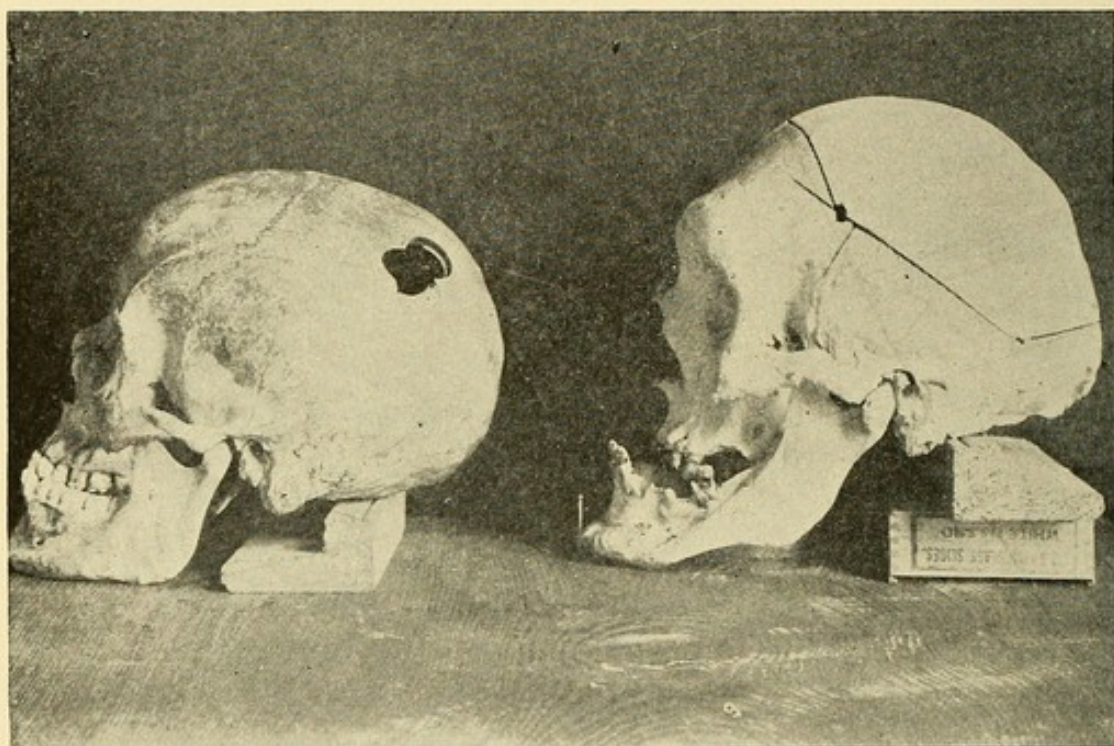


FIG. 48.—ACROMEGALY.

The course is very slow, requiring years before marked enlargement or severe pain is developed. The hypertrophy is doubtless of central origin, since both sides are uniformly involved. Treatment with the hope of stopping the growth is not known. When nerves are pressing upon the bone the latter may be chiseled away to relieve the pressure.

Under the title of "Diffuse Hyperostosis of the Upper Maxilla," L. Poisson, of Nantes, discusses the curious and obscure condition known more familiarly by the name of leontiasis ossea (Virchow). This disease is, by its course, more or less symmetrical in character, and is distinguished



absolutely from the exostomas of the antrum, which involve the surrounding parts, also from the eburnated exostoses of the face, osteoperiostitis (intra- or extra-alveolar), and from the hypertrophic variety of osteoperiostitis. It is equally distinguished from sarcoma, which may, however (in two cases, at least, that were reported by Le Dentu and Pacquet), graft itself upon preëxisting hyperostosis. The reported cases, if we accept only those which are indisputable, are not very numerous, numbering about ten in all. The oldest observation is Ribell's (1823). The symptoms observed are uniform enough to permit of a general description and even to allow an attempt at definition of this affection. It may be said to be a disease characterized by the hyperostosis that is most often bilateral and symmetrical; which begins ordinarily by attacking the upper jaws, and especially their antra; which causes prominences under the skin of the face and projections into the nasal passage; which tends to propagate itself into the bones of the face and cranium; which makes its début in youth, and progresses with exceedingly slow steps until it ends in death by virtue of the fatally progressive development.

### REGENERATION OF BONE

Every part of every bone is developed from its own center of ossification, and bone growth is not only from the periosteum, but from the endosteum, which receives its blood supply from the arteries which enter the nutrient foramina and pass along the medullary canals. While the periosteum furnishes the material for the circumferential growth of the bone, its longitudinal growth is principally from the diaphyseal side of the epiphyseal cartilage, which receives its blood supply from the central canal of the bone, and not from the periosteum.

Death of bone is in proportion to the destruction of nutrition. In osteomyelitis, the nutrient vessels in the central canal are destroyed for the entire length of the shaft,



and the bone becomes a sequestrum and is cast off, the periosteum being lifted from its surface as the infection extends to this part of the bone. The new bone, known as chloaca, is deposited in concentric layers. The experiments of Wieder determined that when the sequestrum, or old bone, was removed, the periosteum did not have the same power of regenerating bone, but produced cartilage mainly. This, however, is due to the fact that when the entire bone is removed early the periosteum collapses one side against the other, and the regenerated bone is much smaller than if it were formed around the sequestrum.

In cases where a less extensive area has been deprived of its nutrition, a somewhat different course of reproduction is found. In periostitis or osteomyelitis, where a small portion of bone is exposed or deprived of its periosteum, the sequestrum which is cast off may be a very small part of the entire bone. The line of demarcation, or that line between the dead and the living tissue, is well established, and, when the sequestrum is cast off, the periosteum, when it is permitted to do so, becomes adherent to the living bone and the cavity is in that way obliterated, but there is interposed between the old bone and the periosteum a considerable amount of new bone. In some instances, as is illustrated in the chapter on diseases of the mandible, the bone may be deprived of its periosteum on account of an inflammation, yet, when the inflammatory serum is permitted to escape or when the infected area is treated by curettement or disinfection, followed by a complete adjustment of the periosteum to the bone with sutures, exfoliation does not take place.

The foregoing general comments are introduced in order that the regeneration of the mandible after destruction may be better understood. The histories of the following cases are reported, which typically illustrate the method of regeneration of this bone after disease. Early operations may be performed to prevent sequestration, but when it is



decided that a considerable piece of the entire shaft must be cast off, operation should be postponed until the new bone has formed around the sequestra, as the following cases fully demonstrate. The time required for the reproduction of bone is several weeks, and it is recommended that too much time be allowed rather than not enough.

A boy, aged eight, had what was considered ordinary toothache, but which became so severe that, on the ninth day after the onset, he was taken to a hospital and a surgeon did an operation for abscess. Two months later a second operation was performed, at which time the face was ex-




FIG. 49.—SEQUESTRUM REMOVED IN CASE DESCRIBED IN TEXT. Result Shown in Fig. 50.

ceedingly swollen and the periosteum was gone from the bone, and a piece of bone was removed. Ten months later a third operation was performed, and the sequestrum, as shown in Fig. 49, was removed through the mouth. Fig. 50 shows the perfect articulation between the teeth as evidence of a perfect reproduction of the left half of the mandible from the sigmoid notch to the symphysis. The bone came away in four pieces, but represented the entire half except the condyle. Had not sufficient time elapsed from the onset of the trouble until the removal of the bone for the regeneration of the new bone around the sequestrum, great deformity would have resulted. All of the teeth on the left side had been extracted at the time of the two preceding operations.



Fig. 51 is introduced to show a typical papilla, indicating that there is denuded bone, with usually a sequestrum back of it. When this granuloma is found, an opening is always present in its center which leads into the necrotic area. The exuberant granulations, which are observed around the orifice of a sinus, represent a condition commonly known as "proud flesh," a growth or proliferation of the histological elements of the tissue involved, indicat-

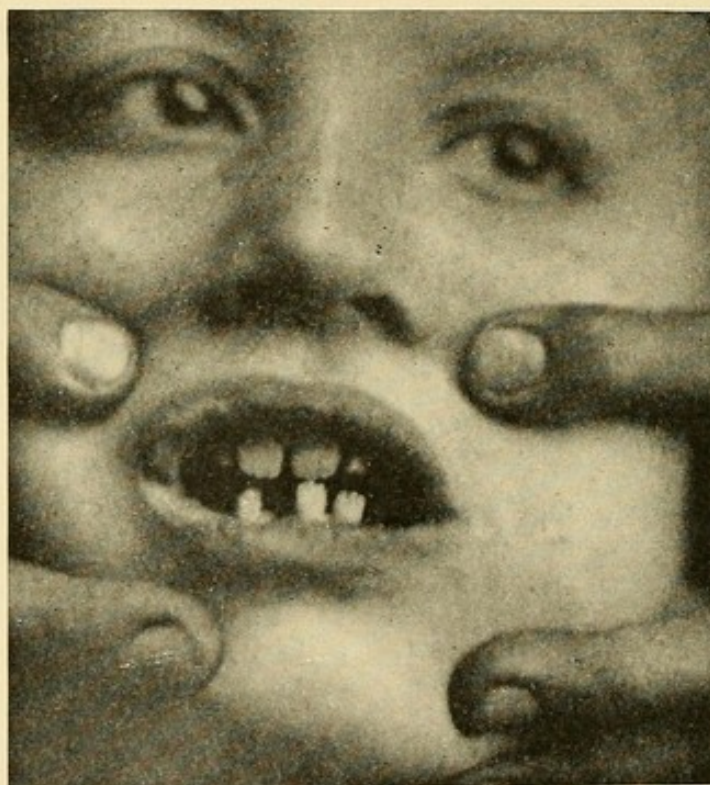


FIG. 50.—PERFECT ARTICULATION FOLLOWING OPERATION. Described in Text.

ing, in instances where it is around a sinus, carious bone, but indicating on the surface of the body exuberant growth and a favorable condition rather than an unfavorable. If on the surface of the body, it may be removed by the use of scissors or lunar caustic, or will disappear under pressure. When around a sinus leading into bone, cauterization is of no value except to remove the granulation temporarily, for so long as the bone is disintegrating the granulation tissue will be re-formed in the course of a few weeks.



A young woman, aged twenty, was having the left first molar and the second bicuspid prepared for filling. The usual treatment was being carried out to destroy the nerve preparatory to the filling of the root canal. Pain and swelling were marked symptoms. Pain began on the left side and extended around to the right along the body of the man-

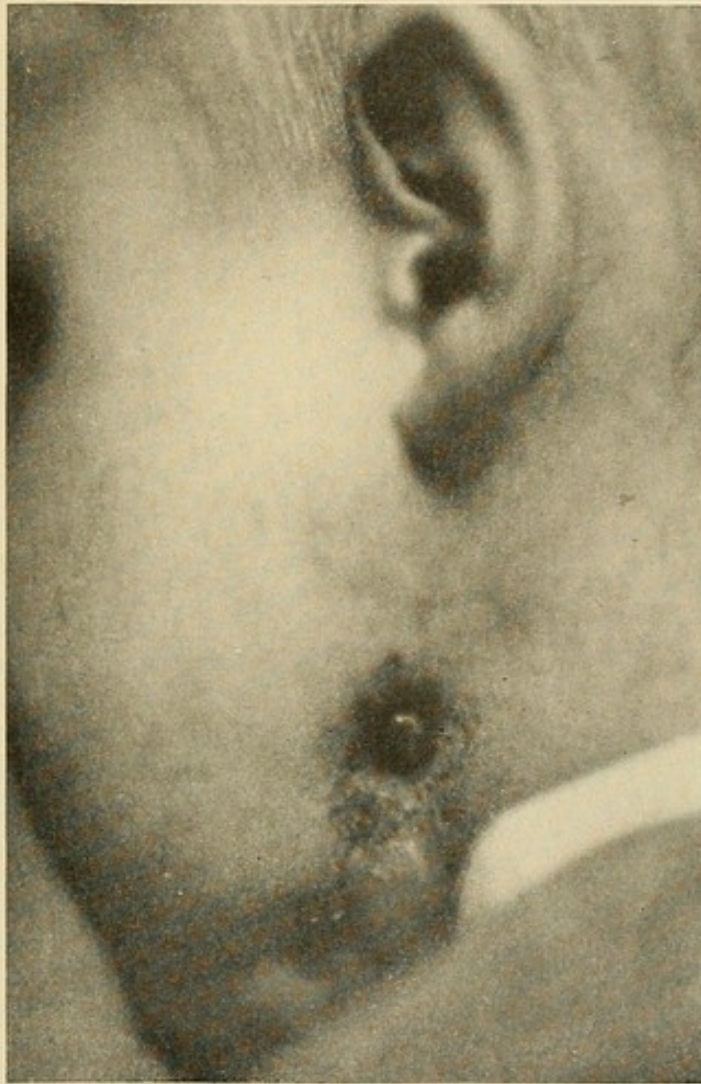


FIG. 51.—PAPILLA FROM NECROSIS.

dible. Two months after the onset of the trouble an abscess showed itself under the chin and was incised. A sinus was established and the discharge was continuous for another month, when she was taken to the hospital, and, through the incision shown in Fig. 52, the body of the bone was removed, as represented in Fig. 53. After the operation was over, complete separation of the bone was found



at points where the two teeth had been treated. The patient described it by saying that "the jaw fell to one side when she was lying down". There were several openings into the mouth on the external surface of the mandible

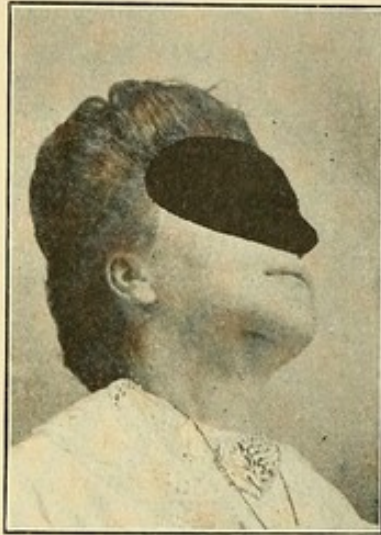

FIG. 52.—EXTERNAL APPEARANCE.

within the mouth, as well as a large opening through the skin under the chin. Three or four small pieces of bone were taken out of the mouth. All active symptoms subsided shortly after the operation and all of the sinuses leading into the mouth closed and the patient suffered little inconvenience after that time. The sinus continued to discharge for four months, and it was decided that sufficient time had elapsed for the bone to completely repair across the points of

fracture and that whatever was causing the sinus to remain open should be removed. The wound under the chin was enlarged and the root of the bicuspid on the right side

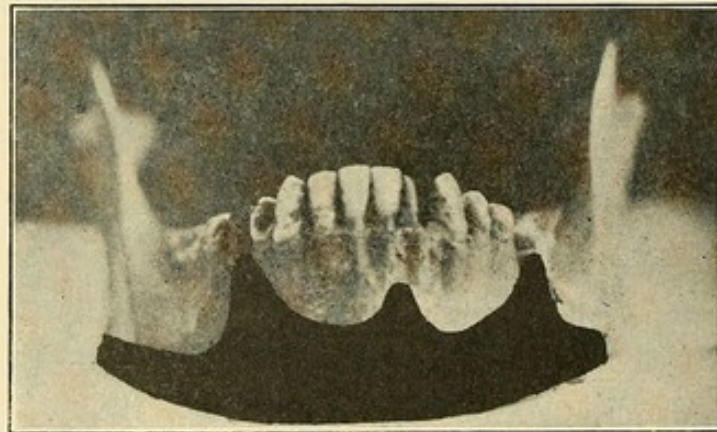


FIG. 53.—AREA BONE DESTROYED. Diagrammatic reproduction of bone showing points of complete destruction of bones through the teeth at two points and a central point communicating with the left central.

was found extending down into the cavity. After its removal the sinus closed. It was found that the bone had completely reproduced itself and was perfectly firm.

H. H., aged thirty, presented himself with a mouth



converted into a pus basin. This putrescent condition had existed for many months. He had had a chancre four years before, but this history had apparently been overlooked, for specific medication had not been administered. An examination revealed a denuded left mandible from symphysis to condyle. The first step was to remove the entire right body. This was done through the mouth with a pair of Cryer universal upper tooth forceps; the ramus was removed with great difficulty, the bone coming away in four fragments. The ultimate result may be seen by studying Fig. 57. Articulation between the teeth in the remaining half of the mandible and those in the corresponding maxilla is as nearly perfect as possible. The

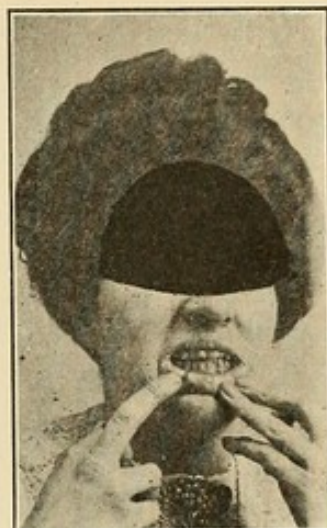


FIG. 54.—TEETH TOGETHER.

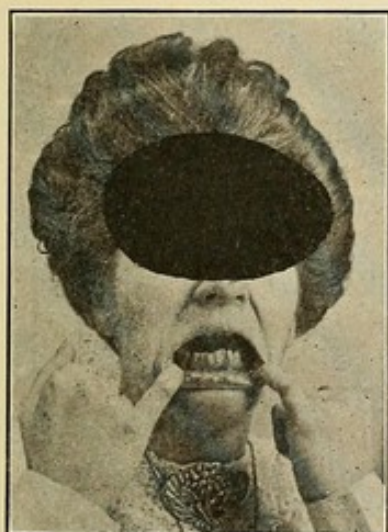

FIG. 55.—MOUTH OPEN.

Figures 54 and 55 show the range of motion of the jaw and the articulation of the teeth. The arch was shortened slightly, making it impossible to force the incisors far enough forward to articulate with the upper incisors.

wound itself repaired without incident under specific medication. This case illustrates that many extensive incisions are made through the tissues of the face for operations on the mandible and bones of the face that could be done through the mouth. Fig. 58 shows that no deformity of the face is present either from unnecessary incisions through the face or from loss of bone.

### TECHNIQUE OF OPERATIONS UPON THE BONES OF THE FACE

The technique of operations upon the alveolar processes and the contiguous structures is not well understood by the general operating surgeon.



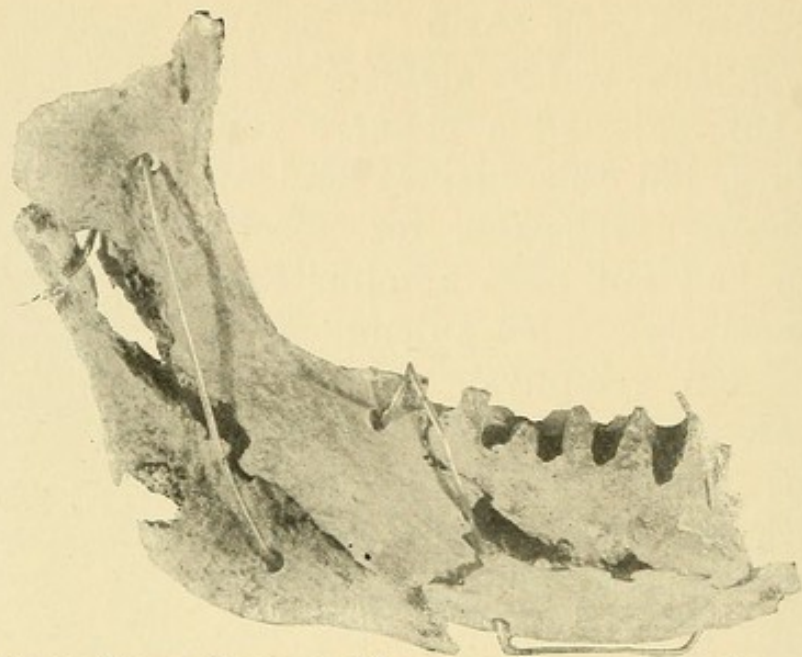


FIG. 56.—ENTIRE RIGHT HALF OF MANDIBLE REMOVED IN FOUR FRAGMENTS.

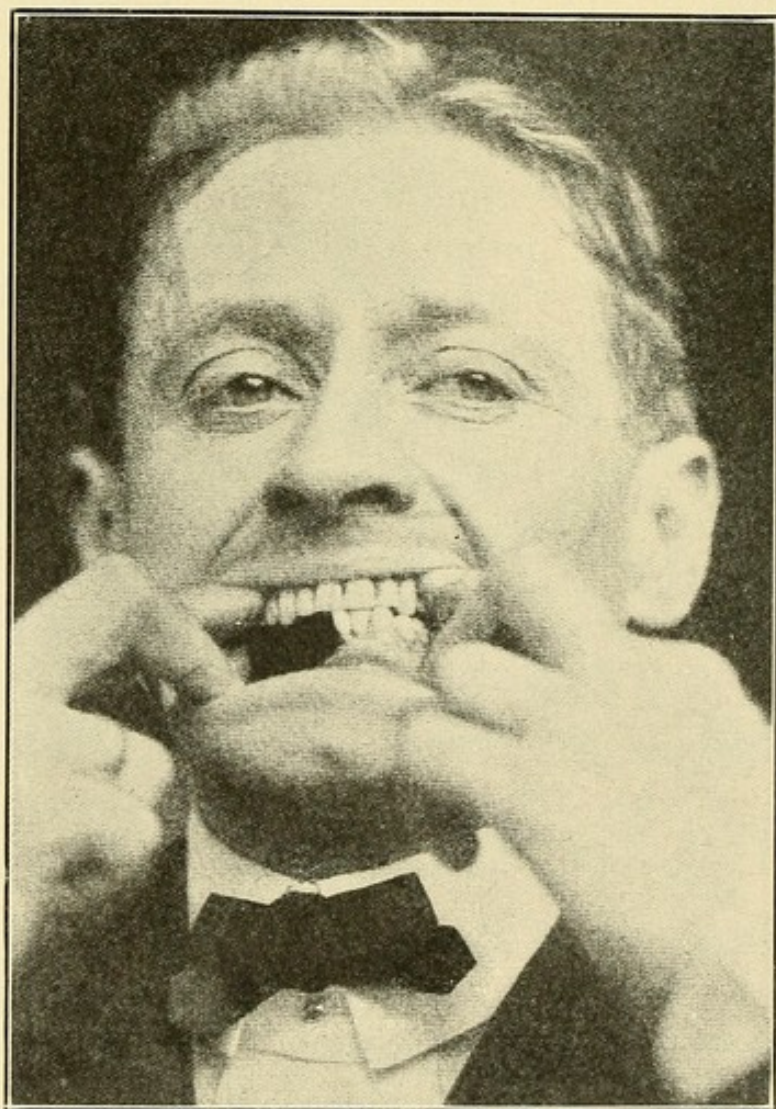

FIG. 57.—RESULT AFTER REGENERATION OF BONE. Teeth in perfect articulation on left side.



The practicing dentist is able to do operations upon the mouth and the teeth that would be considered almost impractical and impossible. The soft tissues extending from the oral orifice in every direction to the point of attachment to the bones of the face are very yielding and, under gentle or continued traction, especially during profound anesthesia, every part of the mandible can be reached without

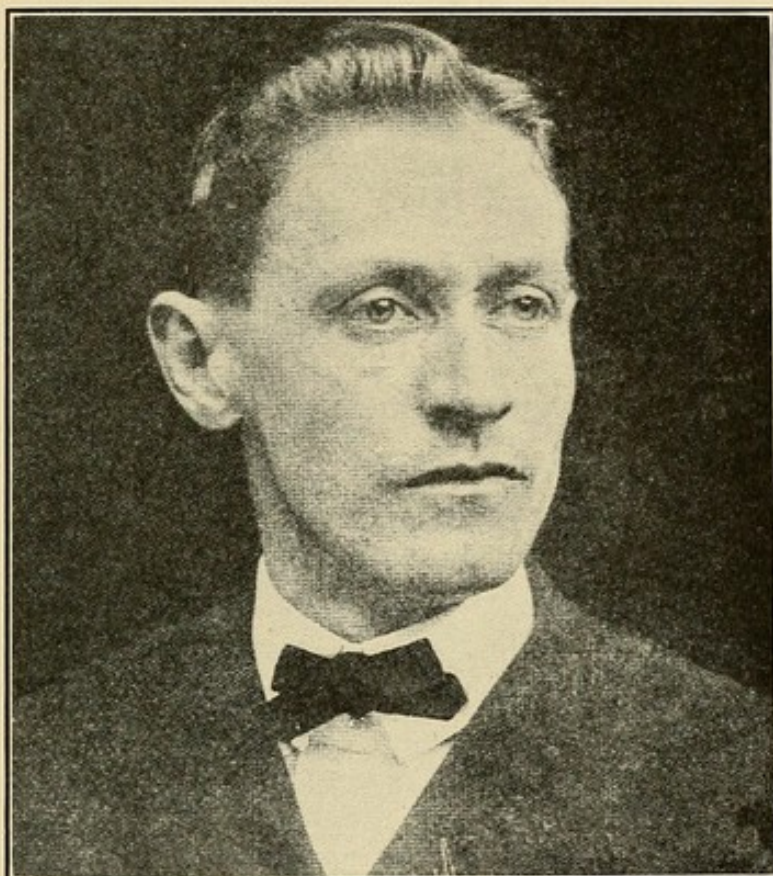


FIG. 58.—COSMETIC RESULT. Bone removed through mouth. Skin incisions not necessary.

incisions through the skin. So also may the maxilla be reached, up to the infraorbital foramen through the mouth.

General practitioners of medicine are constantly incising through the skin at various points between the eye and the mouth for supra-alveolar abscesses, leaving unsightly scars and in no way establishing proper drainage. So, also, is it the common practice to incise abscesses of the mandible along the external surface of the bone, even before an effort is made to evacuate pus through the inferior sulcus of the mouth.



A surgeon was recently operating in a hospital, and, upon inquiry, it was learned that the patient had necrosis of the mandible in the region of the molar teeth. As a great surprise, it was observed that the face had been cut from the angle of the mouth to near the angle of the jaw, for

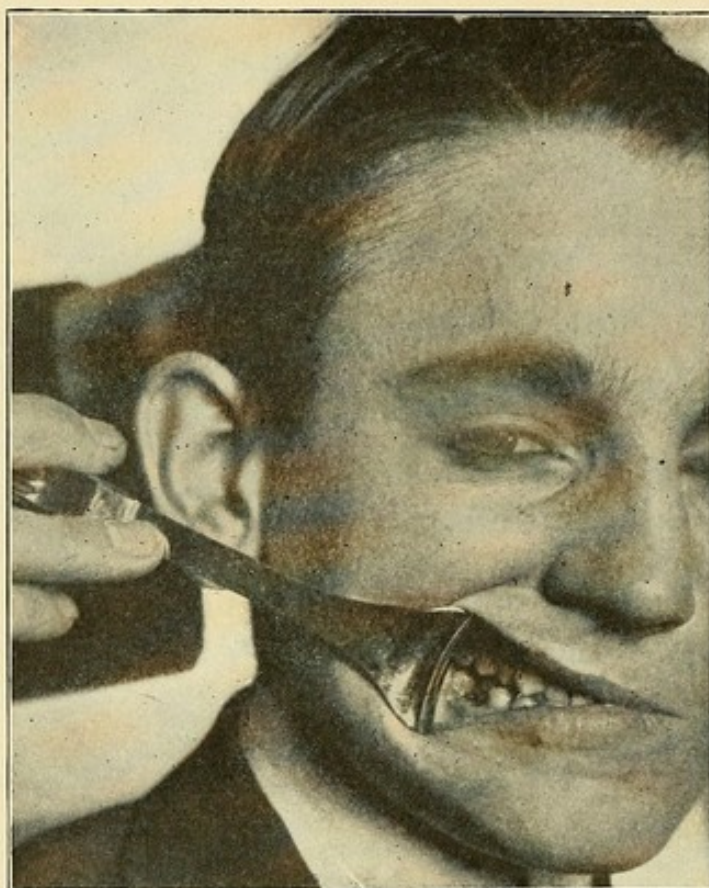


FIG. 59.—MOUTH RETRACTOR.

the purpose, as the surgeon said, of giving him more room to do his curettement. Such mistakes are too frequent.

By referring to the chapter on Ankylosis, it will be learned that the mandible may be severed at any point half way up the ramus above the inferior dental canal throughout its entire course. The only incision necessary is one not longer than three-fourths of an inch, at such point as to permit the passage of the Gigli saw. Indeed, it is possible to remove the entire mandible, from molar to molar, through the mouth after section is made with the Gigli saw, as described.



## CHAPTER XX

### TUBERCULOSIS OF THE FACE, MOUTH AND JAW

#### TUBERCULOSIS OF THE FACE

Tuberculosis of the face, as classified since the discovery of Koch, includes many affections and facial blemishes formerly known by other names. Three forms will be described: (1) Scrofuloderma; (2) Tuberculosis cutis; (3) Lupus vulgaris.

##### SCROFULODERMA

Scrofuloderma is a subcutaneous or glandular form of the disease. It is most common in the glands of the neck, beginning by a chronic enlargement, gradually increasing in size and becoming softer until a fluctuating tumor is present. It is painless and doughy. The skin becomes bluish and finally opens spontaneously, discharging a serum. Considerable skin may come away, leaving a ragged ulcer with undermined edges. The course is chronic, requiring many months to repair, if left untreated.

##### TUBERCULOSIS CUTIS

Tuberculosis cutis develops secondarily to tuberculosis of the internal structures or organs. It is most frequently seen at the muco-cutaneous junctions, such as the mouth and the nose. It is quite rare. The ulcer is not deep and the borders are irregular. The floor is filled with granular tissue from which is excreted a sero-pus, occasionally drying into crusts. From the granular floor may develop new tubercular nodules, and the ulcer increases in size in



the same way. There is little tendency to heal. Pain is more severe than in other tuberculous troubles

### LUPUS VULGARIS

Lupus vulgaris first shows itself as several brownish-red spots, usually on the cheek or some part of the face or hands. The spots become nodules of granular tissue, gradually increasing in number, and extending in every direction, until eventually several may coalesce, constituting one large tubercle. The nodules are slightly raised above the

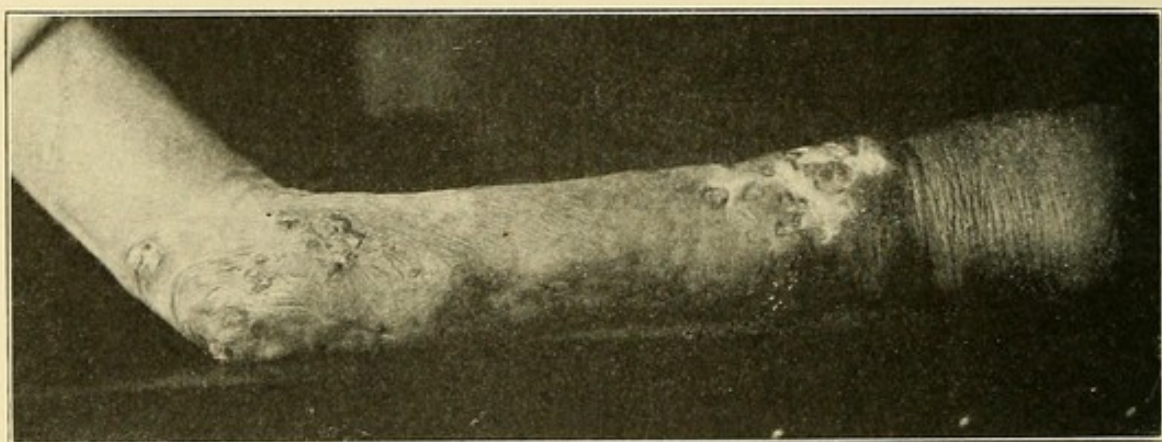


FIG. 60.—TUBERCULOSIS CUTIS. (Dr. Geo. C. Johnston.)

skin for a time, when they have a semi-transparent “apple-jelly-like” appearance. The liquid resulting from the coalescence may be absorbed, and the center collapse and cicatrize, leaving a pit around which the tuberculous process extends to surrounding structures. Not infrequently the ulceration extends through the skin, when there is present the usual tuberculous ulcer. The infection extends to the deeper structures, even to the muscles and periosteum, and finally to the bone, when left untreated. It most frequently attacks the exposed parts of the body, such as the face and the backs of the hands.

**Etiology.**—The infection of the skin, mucous membrane, or glands, enters through the glandular structure by inoculation with the tubercle bacillus. It is most common in children, and is not hereditary except in rare instances.



**Pathology.**—Lupus of the skin presents the following histological elements: (a) Tubercle bacillus; (b) Granulation tissue nodules; (c) Giant cells.

**Diagnosis.**—Lupus vulgaris must be differentiated from simple granular affections, as acne, epithelioma and syphilis. In lupus the course is generally markedly chronic. It usually occurs in young manhood, and nodules are gener-

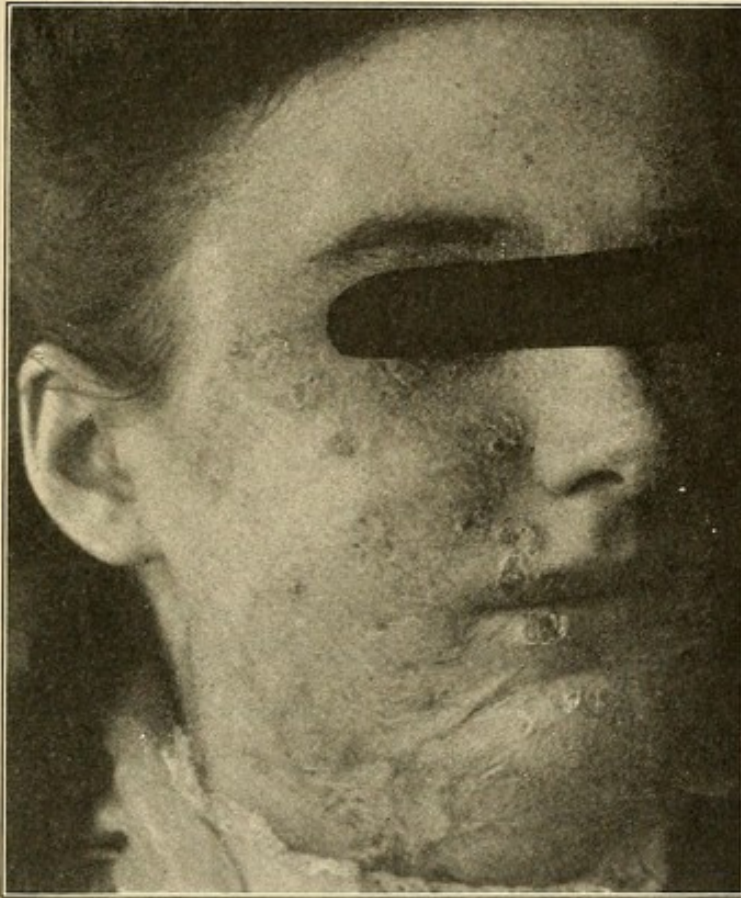

FIG. 61.—LUPUS VULGARIS IN EARLY STAGE. (Dr. Geo. C. Johnston.)

ally found about the margin of the ulcer. Epithelioma or lupus exedens occurs in middle or advanced age. The border is smooth, with little, if any, peripheral involvement.

*Syphilitic ulcer* of the face runs a course of complete development in a few weeks, while lupus requires many years. In tertiary syphilides there may be many nodules rapidly breaking down into as many ulcers, and these may rapidly coalesce. Syphilodermatic ulcers have sharp-cut edges; in lupus the skin margin drifts off into the depth of



the granular base, and may be quite irregular or scalloped. The history of the case is of value and must be reckoned with. Antisyphilitic treatment will cut short the progress in the one, but has no influence on the other. The initial lesion of syphilis, presenting as it does the indurated base, should never be mistaken for lupus, in which there are nodules instead of a hard ring about the periphery.

**Prognosis.**—The prognosis is not as promising as might be expected since, after enucleation of the ulcer, the infection may extend to other parts. This is especially true of skin lupus, which, when untreated, extends, and repair of the ulceration results in unsightly cicatrices. Under early eradication repair takes place in many cases, and if the general condition is excellent, there is no great probability of its return.

**Treatment.**—Treatment may be divided into: (a) preventive; (b) general; (c) local.

*Preventive Treatment.*—Since tuberculosis is admitted to be inoculable, great care should be exercised by those who have to do with tuberculous cases that the skin of the hands is constantly disinfected, especially if abrasions exist. Those who are members of tuberculous families should avoid exposure. Everything about should be repeatedly sterilized and made antiseptic.

*General Treatment.*—This includes change of climate, the internal administration of tonics and a nutritious diet.

*Local Treatment.*—This is subdivided into medical and operative. Pure tincture of iodine is to be preferred for the former, since it does not sear the tissues, is more penetrating and more readily absorbed.

Operative treatment consists in a curettement of the floor of the tuberculous ulcer, after which iodine is applied. If the exposed surface be extensive, it may be closed by Riverdin's method of skin grafting, practiced from time to time until the healing occurs. If small nodules still remain, or develop about the periphery, they should be promptly



scooped out. Complete enucleation is undoubtedly the accepted method of treatment, since, if thorough, it should completely eradicate the disease. Plastic operations should be made to close the break, if skin cannot be procured from the sides to reach across. The cicatrix left after healing is white and irregular.

Tuberculous glands should be enucleated, and if this is done before ulceration occurs return is not, as a rule, to be expected. Broken-down glands may be incised, scooped out with a spoon, and the cavity mopped out with tincture of iodine. The cavity is packed with iodoform gauze and permitted to granulate from the bottom.

### TUBERCULOSIS OF THE MOUTH

The protective character of the mucous membrane of the mouth and the digestive action of the saliva greatly reduce the possibility of inoculation of this membrane by pathogenic germs. Rarely do we see acute infections following teeth extractions. It is quite as true of the more subacute and chronic forms of disease.

Primary tuberculosis of the mucous membrane of the oral cavity *per se* is not common. It is usually secondary to lung lesions. Inoculations have occurred from cigars, pipes, and utensils, and from kissing. The lesion begins as a nodule, followed by others which eventually break down into an ulcer. They are usually located in the angle of the mouth in the mucodermal line, or on the tongue. Secondary involvement from the primary oral inoculation is not uncommon, the metastatic extension being along the lymphatics. The glands of the neck are usually enlarged. Infection of glands can also occur through open root canals of decayed teeth, and by absorption through exposed peridental membranes where recession of the gums has occurred, as in pyorrhea.

Secondary lesions of the mouth may develop from the



face through the mouth, from the pharynx along the fauces or velum, or the sputum from the lungs may inoculate the mouth. Regardless of the method of inoculation, the course is usually the same.

The primary change is in the form of a nodule on the tip or edge of the tongue or on the oral orifice. There may be many miliary tubercles that become vesicles, eventually coalescing. They present a roughened granular appearance and are usually elevated. When they become ulcerative, the margin is defined with undermined edges. They also develop in "rhagades", or simple slits, differing from syphilitic grooves, which are branching and irregular. The ulcers of the miliary form are small and have a yellowish base with a surrounding red zone, which eventually develops other miliary nodules. The entire base is infiltrated. The lesions are sensitive. General health declines rapidly.

**Prognosis.**—Prognosis in the primary form is favorable. When secondary to other tuberculous lesions, the primary condition governs the outcome. Treatment in the primary form is local. Curettement of the miliary lesions under cocain is acceptable. When larger ulcers involve a considerable portion of the tongue, enucleation should be done. Cocain may be brushed over the tongue to control pain at all times. The general health must be improved. X-ray treatment of all tuberculous lesions of the face or mouth is of undoubted value and should be used as soon as a diagnosis has been made. Many cases of lupus vulgaris and tuberculous ulcerations melt away under the rays properly focused.

Dr. Richard L. Sutton reports a very interesting case of recurring necrosis of the gingival mucosa, and draws the following conclusions:

"Although it is not possible to generalize from the data secured in a single case, the following deductions may safely be drawn:

"*Periadenitis mucosa necrotica recurrens* is a chronic



recurring necrotic granulomatous affection of the lingual and buccal mucosa. Pathologically, the disease is characterized by an intense inflammatory process in the periglandular tissues, with ensuing necrosis, and separation of the central part of the affected area.

"It is probable that the disorder is tuberculous in origin. The course of the disease strongly points to a long-standing, general intoxication, which periodically gives rise

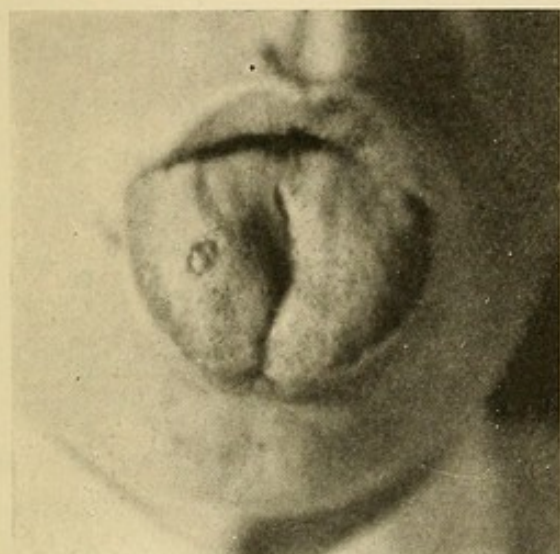


FIG. 62.—PERIADENITIS MUCOSA NECROTICA RECURRENS. Mature lesion on tongue (plug was thrown off twelve hours later.) (Sutton, *Journal of Cutaneous Diseases*.)

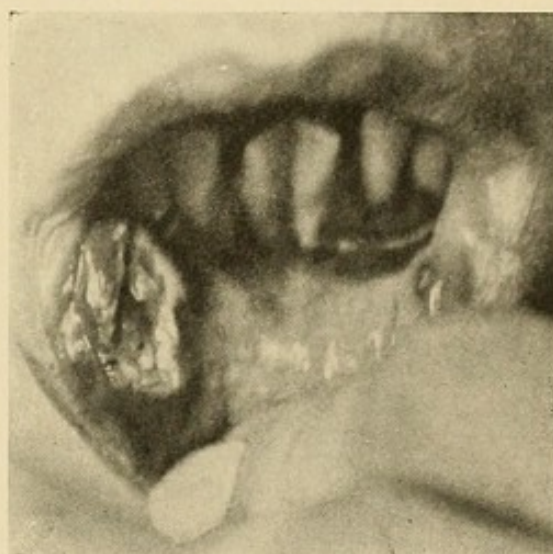


FIG. 63.—PERIADENITIS MUCOSA NECROTICA RECURRENS. Depression left by a recently detached plug. The condition of the gums also is shown. (*Journal of Cutaneous Diseases*.)

to acute local manifestations, intensely inflammatory in character."

**Illustrative Case.**—The author herewith reports another case of this very rare ulceration. A man, aged thirty-one, has a family history which is good, with the exception of one sister's dying with tuberculosis. The patient has always been well, although his appearance is not robust. He had an ulceration of the posterior sulcus of the mouth on the left side, external to the molars. This occurred about eighteen months ago. This ulcer was oblong, being about half an inch wide and an inch long. The only assignable cause for it was the irritation of a bridge. It healed after five months, leaving a distinct scar. Seven months ago ul-



ceration began back of the right molar on the palatal side and gradually increased until it involved the internal posterior surface of the last molar and the soft tissues over it about an inch and a half long, reaching over the palate half an inch from the internal surface of the molar. The superior apex of the ulcer stands inward, within a quarter of an inch from the median line. The soft tissues are de-

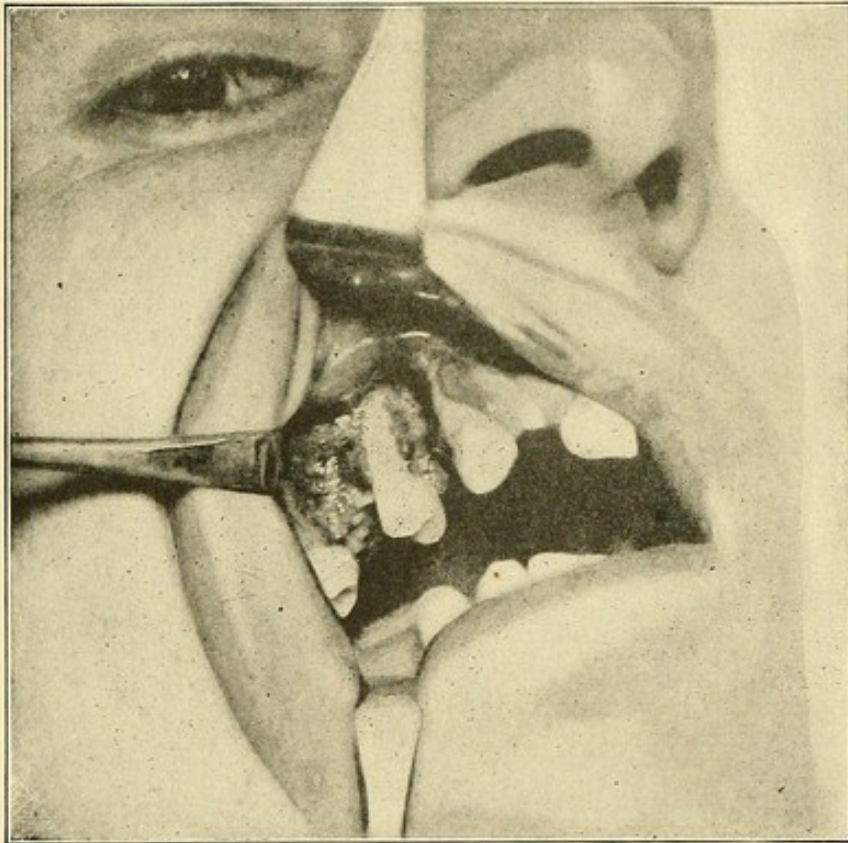


FIG. 64.—TUBERCULOSIS OF THE MOUTH. (Foote.)

stroyed back of the tooth for a considerable distance, so that a probe can be passed up into it at least half an inch. The surface of the ulcer is very granular, the granulations being the size of half a grain of wheat. The margin is distinctly outlined and everted slightly. There is practically no hemorrhage from the surface of the ulcer. A Noguchi-Wassermann test was negative, as was also a microscopic examination of the granulations, and a culture of the bacterium from the surface of the ulcer showed no special germs.

*Treatment.*—Tincture of iodine was applied at the first



visit, and by the time the pathologist was ready to report the ulcer was greatly improved. A second treatment made further repair, and it had reduced about half its original size. The case is still under treatment.

### TUBERCULOSIS OF THE FACIAL BONES

While not common, a sufficient number of cases of tuberculosis of the facial bones occur to demand special mention. It is rare *per se*, and is usually secondary to other foci.

When primary, the inoculation occurs after an injury of the gingival tissues, or through some abrasion caused by calculi, carious teeth, or chronic granulation about the teeth. The reduced condition of the system from typhoid, measles, and other acute diseases, is a forerunner of tuberculous diseases. The inoculation is followed by a swelling and infiltration of the tissues. The bone, in the course of several weeks, melts away or becomes sequestered, and is cast off, if not removed by operation.

The primary focus may also be located, either in the bone or periosteum, anywhere over the maxillary bones. The margin of the orbit or the malar or palatal processes may be primarily involved. The disease gradually extends over the entire bone, unless cut short by early incision, curettement, and disinfection.

Mandibular tuberculosis runs a different course from tuberculosis of the maxilla. The first symptom is a diffused thickness of the tissues, dense, uniform, and not very painful. Constitutional symptoms are absent or very mild. As in other tuberculous bone disease, the muscles are in spasm and their trismus especially marked when the insertion of the masseter or internal pterygoid is involved. The teeth become loose, and, when not extracted, drop out. The teeth are too frequently considered the cause and extracted. The disease tends to extension in every direction and the entire mandible to the articulation with the temporal is



involved, as a rule. The glands of the neck are enlarged. It requires months or years to end fatally. Mixed infection with suppuration must be expected.

When the bone becomes diseased, secondary to a primary focus in the lungs, hips, spine, or from a lupus, the course is more acute. The constitutional symptoms are more marked and suppurative periostitis is developed. Pain is more marked, and the stage of sequestration must be expected earlier than in the primary variety.

Diagnosis must be made from syphilis, actinomycosis, sarcoma, and periostitis from staphylococcus. The glandular involvement is more prominent in tuberculosis. In sarcoma this is absent, late in actinomycosis, and not so marked in syphilis.

Treatment, if results are to be obtained, must be radical at all stages. Incision, chiseling back to healthy bone, removal of all diseased soft tissue, and disinfection with tincture of iodine, form the most acceptable practice. Forced feeding and open-air life are just as important as they are in tuberculosis of the lungs.



## CHAPTER XXI

### SYPHILIS OF THE MOUTH

The number of physicians and dentists who are inoculated with syphilis during the administration of service is quite surprising. A leading gynecologist, whose work on the subject was translated into five languages, contracted syphilis from a patient and died with the disease. It was the author's privilege to hear the address of the president of the New York Academy of Medicine about twenty years ago, whose voice was so impaired that only a portion of the address was spoken above a whisper, due to the contraction of the disease while pursuing his duties as an obstetrician. Five dentists have presented themselves to the author with chancres on their fingers, contracted during the extraction of teeth. Many physicians and surgeons are suffering with this disease, in the majority of cases contracted innocently.

With the history of these cases before us, it is very proper to sound a note of warning to those who are entering into the practice of dentistry, as well as to present in the most realistic form possible such various specific lesions of the mouth as would be observed in patients who apply indiscriminately for treatment.

Attention is called to the classification of the lesions of syphilis in a preceding chapter and it is important that this classification be carefully studied, since almost every change which appears on the skin may also appear on the mucous membrane of the mouth. It must not be thought that the disease cannot be contracted from people who do



not have mouth lesions or other lesions, since the saliva, contaminated with secretions from mouth lesions, even microscopic in size, is most virulently inoculable during the entire time of secondary syphilis, which may extend over a period of four or five years. During this time, skin and mucous lesions are coming and going, and may be absent at the time of operation. From this it will be observed that the practice of prevention, especially during the extraction of teeth, would be the proper course, and this is best accomplished by the use of rubber finger-stalls.

Syphilitic lesions of the mouth and contiguous tissues, which are of importance to the dentist, may be presented as:

1. Initial lesion.
2. Secondary manifestations.
  - a. Erythema.
  - b. Mucous patches.
3. Tertiary lesions.
  - a. Gummata.
    1. Tongue.
    2. Cheek.
    3. Tonsils.
  - b. Sclerosing glossitis.
  - c. Ulcerative gingivitis.
  - d. Bone diseases.
4. Hereditary lesions.
  - a. Teeth.
  - b. Soft tissues.
  - c. Bones.

### THE INITIAL LESION

The initial lesion, already described, begins as an elevated, hardened papule, the margin in the course of a few days increasing in height above the skin, producing a char-



acteristic indurated mass. Location of chancre depends entirely upon the point of inoculation, usually of the lips, or it may be of the tongue, either at the tip, on the surface or margin, or of the internal surface of the cheek, and even back as far as the fauces. There may also be present ecthymic papules or pustules, or erosions resembling the condition known as Vincent's angina.

The surrounding soft tissue is usually infiltrated, and the glands of the neck are involved quite early. The chancre varies in size, sometimes growing as large as a nickel. It contains well-defined borders and is bright red, with a depression in the center, which gives it the appearance of an ulcer, but is not distinctly one, since the skin is not entirely destroyed. It gives off a serum which eventually becomes dry and forms a crust over the entire area before final repair occurs.

The initial lesion always disappears without treatment in the course of several weeks. The secondary manifestations are those enumerated in Chapter V, under the heads of "Forms of Syphilides," and little attention needs to be paid them here, except the most common forms.

A chancre of the lip is generally on the vermilion border, and may vary in size from a small papule to a large mass. It usually begins as a small oval sore, with a raw, flat, shining surface and rounded edges. More or less induration develops at its usual time, and the sub-maxillary bubo is usually marked. In this location the chancre usually occasions

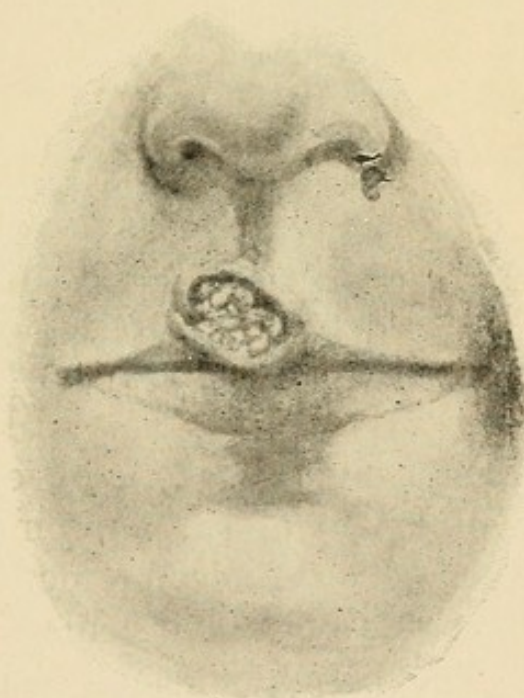


FIG. 65.—CHANCRE OF LIP.



considerable distress. *The character of the lesion and the appearance at stated intervals of its specific features (induration and adenitis) are the essentials upon which its nature is determined.* An epithelioma (cancer) of this region can usually be differentiated by the fact that it is rarely seen in persons under forty years of age, and is extremely rare in women; that its surface is irregular with

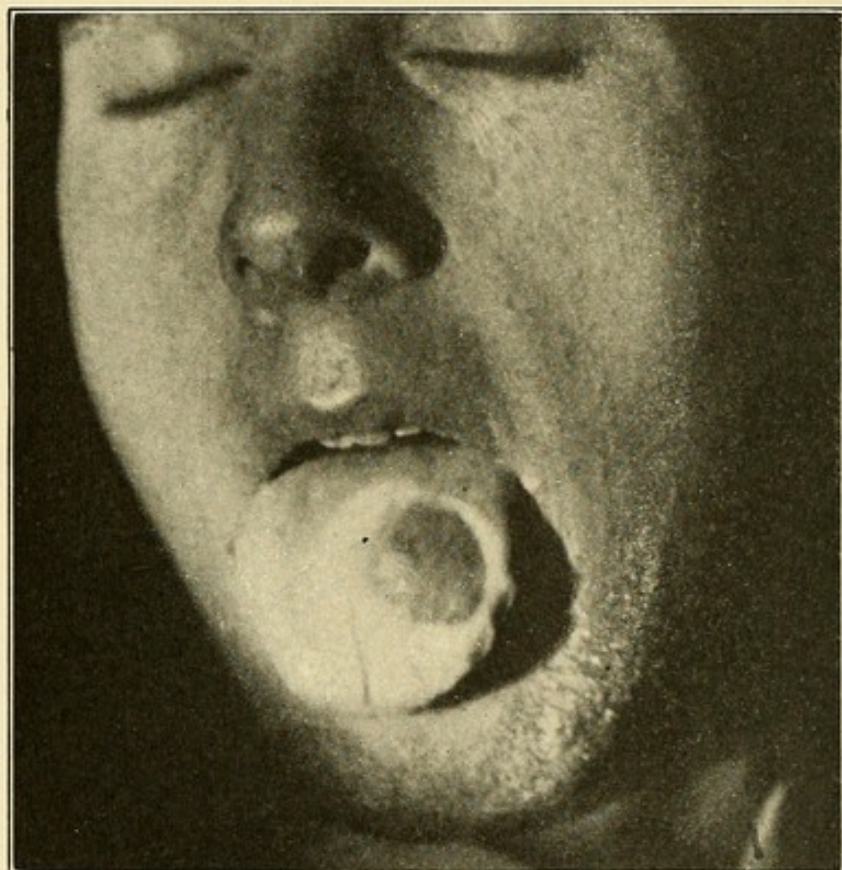


FIG. 66.—CHANCRE OF TONGUE. (Dr. Geo. C. Johnston.)

everted edges; that it develops more slowly; and that the involvement of the anatomically related lymph glands appears only after some months (usually at a time when the chancre would have healed spontaneously).

The primary lesion may appear on any part of the tongue, but is most commonly seen on the dorsum toward the tip, and on the anterior portion of the border. The lesion is likely to be quite large, and the surrounding tissues infiltrated widely by the lymphangitis. The induration is of cartilaginous hardness, and subhyoid adenitis appears.



Chancre of the gum is an exceedingly rare lesion. It appears as an eroded induration surrounding the roots of several teeth.

When the primary lesion develops upon the tonsil, it is likely to be mistaken at first for an ordinary sore throat. There are the general and local symptoms of a tonsillitis—fever with local pain on deglutition and general enlargement of the tonsil. When due to syphilitic infection, the disease is unilateral. The chancre may appear as a small eroded papule, but more commonly the tonsil is swollen to double or triple its size, and covered with a thick adherent false membrane, under which the surface is flat, eroded, or ulcerated. The surrounding tissues are swollen. Adenitis of the lateral cervical glands develops. All of the glands of this region may be enlarged, but the largest of the lymphatics of the tongue causes a visible projection. This largest gland is difficult to palpate, owing to its situation under the middle of the sterno-mastoid muscle. It may be on or at the angle of the jaw. Palpation of the tonsil with the fingers should not be omitted, as it reveals a marked induration—the tonsil is firm and tense. The pain on deglutition is severe. The tonsil increases rapidly in size. It is unusual for hemorrhage to occur, as is common in malignant disease.

## SECONDARY MANIFESTATIONS

(a) **Erythematous Syphilides.**—Erythematous syphilides, sometimes called macular or roseola, appear in bright red blotches, which at first disappear on pressure, but later, when pigmentation develops, leave a brownish stain. They are located on the fauces, soft palate, and sides of the tongue and cheek. They have illy-defined borders and are superficial.

(b) **Mucous Patches.**—The papular varieties, sometimes called mucous plaques and patches, are caused by cellular infiltration of the mucous membrane, are slightly ele-



vated, and are covered with a grayish-white false membrane, which, when it exfoliates, leaves a red area known as papulo-erosive plaque, sensitive, but not painful. There is no induration, as found in a chancre, and no inflammatory zone. The patches vary in size from one-eighth to one-half inch in diameter, and the borders are irregular. The surface is covered with hypertrophied epithelium, which later becomes macerated and takes on a pale gray color, and is eventually cast off, leaving a superficial ulcer, which may persist for several weeks. When a papule is found in the angle of the mouth, it is gray on the mucous membrane and copper-colored on the skin. When on the tongue, it is dark in color and has a mirror-like smoothness, called by Fournier "plaque lisse." These lesions may disappear and recur again at other points, or they may persist and become papulo-hypertrophic.

A *diffuse symmetrical erythema* of the fauces may precede or accompany the secondary syphilides. It occasionally occurs as round or oval areas (macular). This diffuse redness may be limited by a sharply defined margin. It persists longer than an ordinary sore throat. It is almost always present when the first mucous patches appear. The mucous patch is the form assumed by the papular syphilide when occurring on the mucous membranes. On these surfaces it is not markedly elevated, as is the cutaneous papule, and its surface is always denuded. It occurs as an erosion, a circumscribed diphtheroid patch, a superficial ulceration or a vegetating papule.

The *erosion* is a round or oval infiltrated area but little elevated above the surrounding surface, flat or slightly convex, and denuded of its epithelium, showing a smooth or slightly roughened, glistening, moist surface. It may be of raw-ham color, or only a little redder than the surrounding mucosa. It varies in size from a pin-head to a split pea or larger. It appears and disappears in a day or two, or may persist several days. It may be sensitive, but is not usually



so. Its site of election is the dorsum of the tongue. When the lesions are confluent, the outline of the combined lesion is made up of segments of circles.

The *circumscribed diphtheroid patch* is the commonest form of the mucous papule. It occurs on the tonsils, uvula, free border of the soft palate and its pillars, on the side of the tongue and on its under surface, on the inner surface of the cheeks, and on the mucous surface of the lips. It elects particularly the pillars of the fauces and the tonsils. It occurs anywhere in the mouth, but on the dorsum of the tongue and on the gums less frequently. Commonly lesions coexist on these several areas. In size they vary from that of a tack-head to a finger-nail. In shape they are rounded or oval. They may be discreet or confluent (then the lesion is of polycyclic outline). As occurring in the mouth, the diphtheroid papule is usually not elevated, but level with the surrounding surface or slightly depressed at the center. As the surface of the papule is poorly nourished, it soon becomes macerated. When fresh, it is of a bright-red or raw-ham appearance, but becomes covered with a gray or grayish-yellow pellicle of thickened and softened epidermis, giving the appearance of being penciled with the nitrate of silver stick. This pseudo-membrane is usually closely adherent, but sometimes can be separated and leaves a bright-red surface, which bleeds easily. This grayish membrane covering particularly the central portion after a time sloughs off, leaving an abraded lesion, which may become more deeply invaded, giving a shallow, well-defined ulceration with a mucoid or mucopurulent secretion. There is no induration of the base. The sharp-cut, well-defined edge is surrounded by a well-marked, narrow, hyperemic areola, and beyond this there is often a gray ring rendering the dimensions of the lesion larger. When healing, the patch loses its diphtheroid covering, presenting the appearance of an erosion, and ultimately only a pigmented spot.



A patient may present numerous lesions in his mouth and not be aware of their existence, as they may cause no pain or inconvenience. The mucous patch is not, as a rule, very sensitive. It may, however, be quite sensitive, particularly if irritated by a rough tooth and inflamed from septic infection (from want of oral hygiene), and hot drinks and

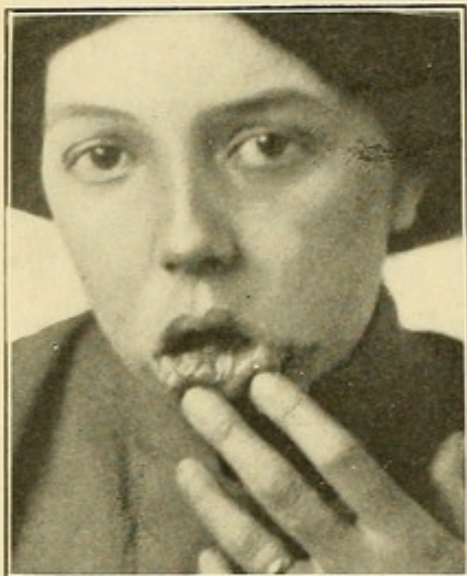

FIG. 67.—SECONDARY LESION  
WITH SALIVATION.

acid foods will then provoke pain. At the angle of the mouth, where fissures usually develop, it is quite painful. On the tonsil, where deep ulceration is prone to occur, it may be very painful and interfere with deglutition. If, during its course, from irritation or sepsis, the patch becomes distinctly inflammatory, the related lymph glands may swell and sometimes suppurate. Local irritation acts as a predisposing cause, and tobacco (smoking or chewing) preëminently so.

The mucous patch is less frequently seen in women, who do not smoke. A decayed or broken tooth may determine the site. When occurring on the edge of the tongue it is prone to ulcerate on account of contact with the teeth. Mucous patches persist as a manifestation of syphilis, not through persistence of the individual lesion, but by the constant development of new ones. When they appear as late lesions—that is, several years after the chancre—they may be exceedingly resistant to treatment. When the patches have recurred persistently, and ulceration has been deep, the mucous membrane of the tongue and buccal walls may be glazed, cracked and fissured. There is no elevation of temperature or other systemic disturbance accompanying the eruption of mucous patches, and the course of each lesion is slow and indolent. They must be differentiated from Vincent's angina and diphtheria.



## TERTIARY LESIONS

(a)**Syphilitic Gummata.**—Syphilitic gummata of the tongue and mucous membrane of the mouth are manifest in three forms: 1. Superficial circumscribed gumma (tongue);

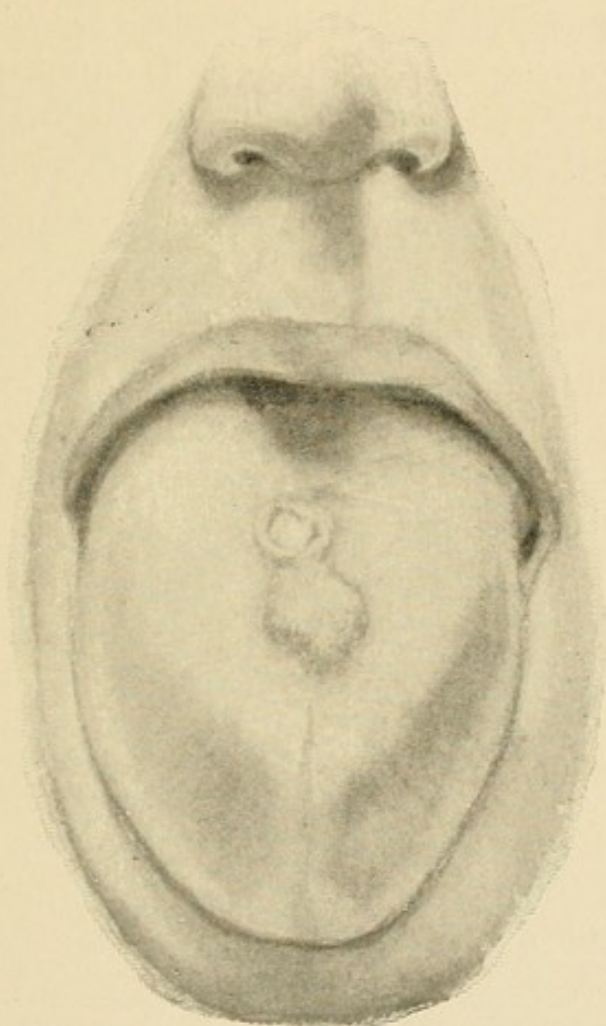


FIG. 68.—GUMMA OF TONGUE. (Palisade Mfg. Co.)

2. Gummatous infiltrations (cheek); 3. Gummata of the tonsil.

1. The *superficial gumma* forms a distinct protuberance, usually in the anterior third of the tongue. It may be in the mucous, submucous or muscular tissue. It varies in size from a bean to a walnut. There may be several. The surface is first covered with smooth mucosa, but breaks down in the center and emits a dirty yellow mucilaginous discharge, containing lumps. The center covering breaks



away, leaving a granular ulcer. The gummata are usually in the horizontal plane and involve one side. When multiple, they may develop on both sides simultaneously and the tongue may part in the median line, leaving a bifid condition, or the double tongue of syphilis. Destruction continues unless arrested by treatment.

2. *Gummatous infiltration* more frequently involves the cheek, beginning at the angle of the mouth and extending backward, resulting in the characteristic serpigenous ulcer, and eventually perforating the cheek. Other parts of the body are usually involved at the same time, such as the bones and the viscera. The soft and hard palates are frequently the seats of gummatous infiltration. Destructive lesions usually appear first in the nasal cavity or pharynx, the ulceration extending to and destroying the palate, as the two reported cases demonstrate.

A differential diagnosis must be made from the initial lesion where it is single and without other symptoms and lesions; from leucoplakia, which is local and more diffused and not nodular; from actinomycosis, which is rare and without a syphilitic history, and in which the lesion is more irregular and nodular; from tuberculosis, which is most frequent upon the tip of the tongue, beginning on the surface as a small tubercle, eventually becoming ulcerative. The borders are irregular and not elevated.

3. *Gummata of the tonsil* and soft palate are commonly diagnosed after ulceration has occurred. The tonsil is swollen and hard. There is little pain, but usually some interference with hearing. The lymphatic glands behind the angle of the jaw (contrary to the general rule) are usually inflamed and sensitive from mixed infection. A gummatous infiltration producing redness, tumefaction, and relative immobility, may develop in the soft palate, causing scarcely any pain, to which the patient may pay little attention until necrosis sets in and causes ulceration, perforation or destruction. Similar processes cause perforation of the hard



palate and communication between the nasal and oral cavities. Such more commonly commence in the nasal structures. Everyone is familiar with the ultimate contractions, adhesions and deformities resulting in these cases.

(b) **Sclerosing Glossitis.**—Sclerous glossitis is a characteristic lesion of syphilis. No other condition simulates

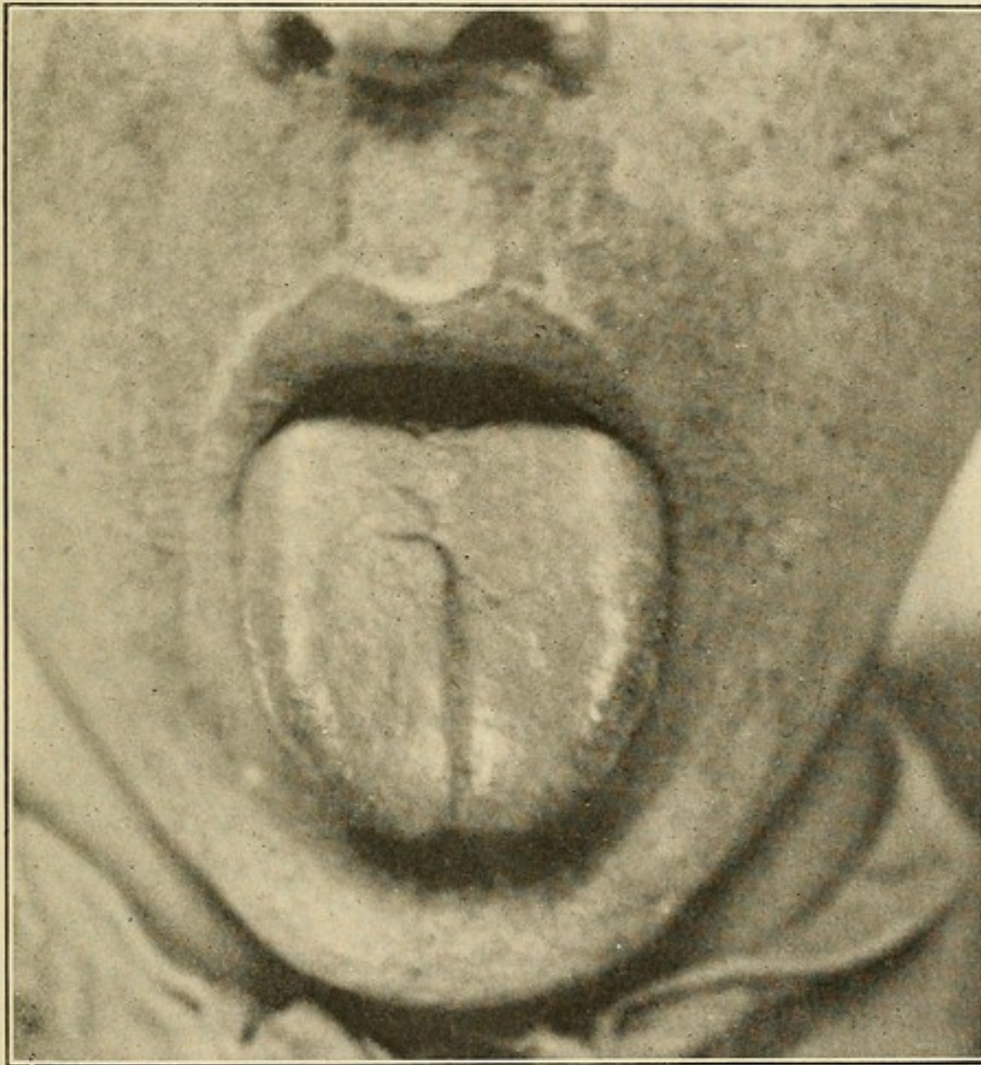


FIG. 69.—SCLEROSING GLOSSITIS OF SYPHILIS.

it. The tongue is increased in size and lobulated—deformed by irregular swellings and separated by deep furrows. The lobules are of cartilaginous density. The tongue is insensitive, clumsy and stiff. The swellings are caused by gummatous infiltration of its substance, but there is no tendency to softening and ulceration—the masses retain their hardness. The whole tongue may be affected, or there may be



only a few infiltrated areas. Secondary fissures and excoriations which are quite sensitive may develop. Ultimately gradual and progressive contraction of the gummatous deposit leaves the tongue smaller than normal.

(c) **Ulcerating Gingivitis.**—Gingivitis, or the so-called pyorrhea alveolaris, which has received so much attention from dentists during the past few years, is in many instances found in patients who have had syphilis, either hereditary or acquired, and, indeed, it is quite difficult to differentiate between these conditions without a Noguchi-Wassermann reaction and without medication with iodid of potash. When of a syphilitic nature, the ulcerations disappear under "606" and iodid of potash very promptly, but the other varieties may persist for many years. The following case is reported as typically illustrative of these conditions:

A woman, aged thirty, had been treated by a dentist for a few weeks for trouble which began as an ulceration about the molar teeth, during which time a tooth had been extracted. The ulceration continued around both the buccal septal and lingual margins of the gums as far forward as the lateral, and the ordinary treatment failed to check its advance. After the examination it was observed that some of the process was denuded of periosteum and required curettement. For confirmation the patient was placed upon potassium iodid for a few weeks before an operation was to be resorted to. About this time an ulcerative process began around the upper teeth on the same side, and it was decided to have an operation. After curetting, it was learned that the family physician had not carried out the increasing doses of saturated solution of potassium iodid, but had given the same dose three times a day. The patient failed to improve, however, after the operation, and an eminent specialist examined the case and confirmed the diagnosis of specific disease. She was now placed upon increasing doses of potassium iodid, until she was taking 150



grains every twenty-four hours. Within a few weeks the ulcerations had entirely healed, the bone had covered with reparative material, and she was well. The patient belonged to the middle class, refined and intelligent, and no intimation was made to her as to the real cause of the trouble. The diagnosis was unquestioned, however, as nothing checked the advance of the ulceration but specific treatment.

(d) **Syphilitic Diseases of the Facial Bones.**—These may be classed as: (1) Acquired syphilitic bone disease. (2) Hereditary syphilitic bone disease, which is taken up under Hereditary Lesions.

Syphilitic destruction of bones of the face runs a chronic course and is rarely confounded with the acute varieties of necrosis. It is only possible, however, to differentiate these destructions from periostitis and osteomyelitis during the stage of sequestration by taking into account the history of the disease and the general history of the patient. The patient who has had a chancre will generally withhold the fact, and many will positively deny such a history when questioned directly.

Symptoms of the most importance are gradual development without acute pain, as a rule, but an ache during the night. Swelling is gradual. Thickening of the soft tissues is marked. When the wound becomes suppurative, showing mixed infection, the development is more rapid, and pain and septic symptoms more exaggerated.

Diagnosis must be made from other destructive diseases, such as periostitis and osteomyelitis, from streptococcic, staphylococcic, tuberculous and chemical etiology. Here the history of the disease is valuable. The gradual onset and the night pain, with moderate swelling, are most prominent diagnostic points.

Treatment is constitutional. In no case should the knife be used except to remove sequestra or to liberate an active mixed suppuration. In both acquired and congenital diseases, iodid of potash in some form is as near a specific



as any medicine known. The saturated solution of the crystals is doubtless the best form. In a solution of one ounce of the crystals to an ounce of distilled water, a drop represents a grain of the drug. An adult should begin on five drops three times a day, after meals, in milk or water. Increase one drop every day up to tolerance. When increased in this way 100 grains have been given at a dose without injurious effect. Syphilitics have a tolerance for iodids.

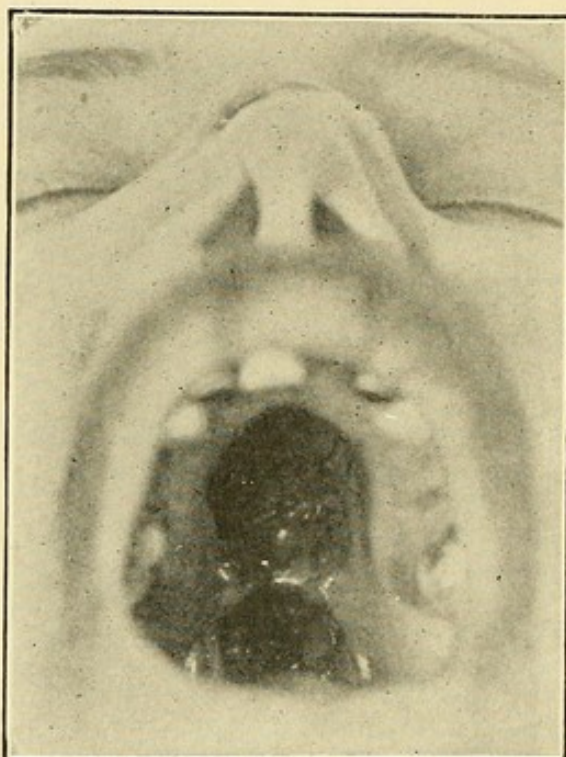


FIG.70.—ACQUIRED CLEFT PALATE FROM SYPHILIS.

People who have not had the disease cannot take such large doses. Iodid of potash is a gastric irritant unless given with liquid after meals.

*Illustrative Cases.*—H. M., aged twenty-nine years, had a chancre eight years ago, with usual history and no tertiary symptoms until two years ago, when he had beginning destructive disease of the nasal bones and roof of the mouth. In spite of what it was reasonable to suppose was good treatment, the destruction continued and would, no doubt, have destroyed the entire maxilla. Iodid of potash was pushed to sixty grains three times daily. The destruction ceased, and repair on the ulcerative surfaces was com-



plete in one year. The case presented a most extensive destruction. The bones in the roof of the nasal cavity were so destroyed as to freely expose the base of the skull. The ethmoid cells were destroyed well up to the cribriform plate. At no time, however, were there any cerebral symptoms. A vulcanite prosthetic appliance attached to a set of teeth enabled the patient to talk well. An aluminum bridge for the nose was introduced through the under surface of the lip after dissecting loose the mucous membrane from about the bony nares.

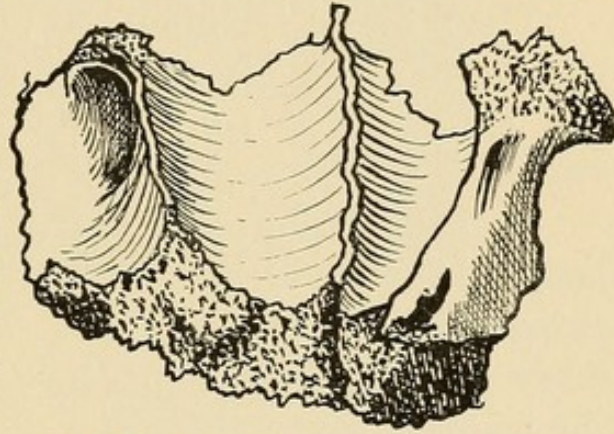


FIG. 71.—SEQUESTRUM. (G. W.)

This resulted in producing a very satisfactory nose.

G. W., aged forty, gave a history of chancre eight years before the beginning of the present trouble. Examination revealed extensive denuded bone in the central part of the

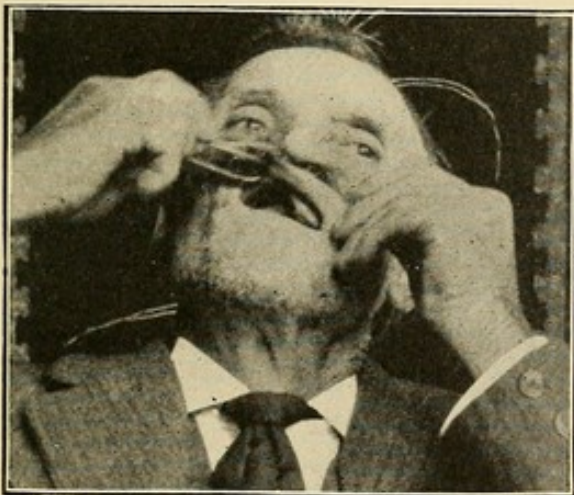


FIG. 72.—APPEARANCE OF MOUTH.

roof of the mouth. Under a general anesthetic the sequestrum, which is shown in figure 71, was removed, as well as the floor of the nasal cavities, the right antral and the left nasal processes of the maxillary bone. This represented practically the entire roof of the mouth. Figure 72 shows the condition of the mouth

after the operation. Medication was continued for a year. Packing was used to fill the immense cavity that was left after the removal of the bone, and eventually a prosthetic appliance was made. Incidentally it might be stated that the family of this man did not discover that he had any



difficulty, so perfect was his articulation during the time he used the packing, as well as the denture.

### HEREDITARY LESIONS

That heredity plays a most important part in the production of bone disease of the faces of children there can be no doubt. Indeed, the great majority of cases under twenty years of age have a syphilitic ancestry.

Surgeons who see many cases of bone disease of young people learn to recognize this factor as a cause of hip, knee, spinal and other bone- and joint-destruction, and accordingly place these patients on constitutional treatment from the beginning.

(a) **Teeth.**—Defects in the size of the teeth are characteristic of hereditary syphilis, but do not necessarily imply its presence. The Hutchinson's teeth (the two upper central incisors of the permanent dentition), with concave, crescent-shaped borders directed toward the median line, have until recently been generally accepted as definite evidence, but so many innocent cases are met with in dentistry as to invalidate this condition as a symptom.

An acute gummatous infiltration may destroy a portion of the alveolar border of the inferior maxilla. It begins as a swelling around the root of one or more teeth, the teeth become loose, and in a few days or weeks a portion of the alveolar process is shed and the teeth come out. At times the process may be checked with the loss of little or no bone.

(b) **Soft Tissues.**—By referring to Chapter VI, figure 6, a case of multiple gummata of hereditary origin will be seen. In such cases, the soft tissues are probably involved, and occasionally the tissues of the oral cavity are attacked, but not so frequently as some other parts of the body. The gummatous infiltration begins as a granuloma about the teeth or of the tongue and, in a very short time, extends to



the deeper structures, involving the bone. The course is practically the same as that of an acquired gumma.

(c) **Bones.**—Bone lesions in hereditary cases, as a rule, follow upon the gummatous stage, and the destruction is in

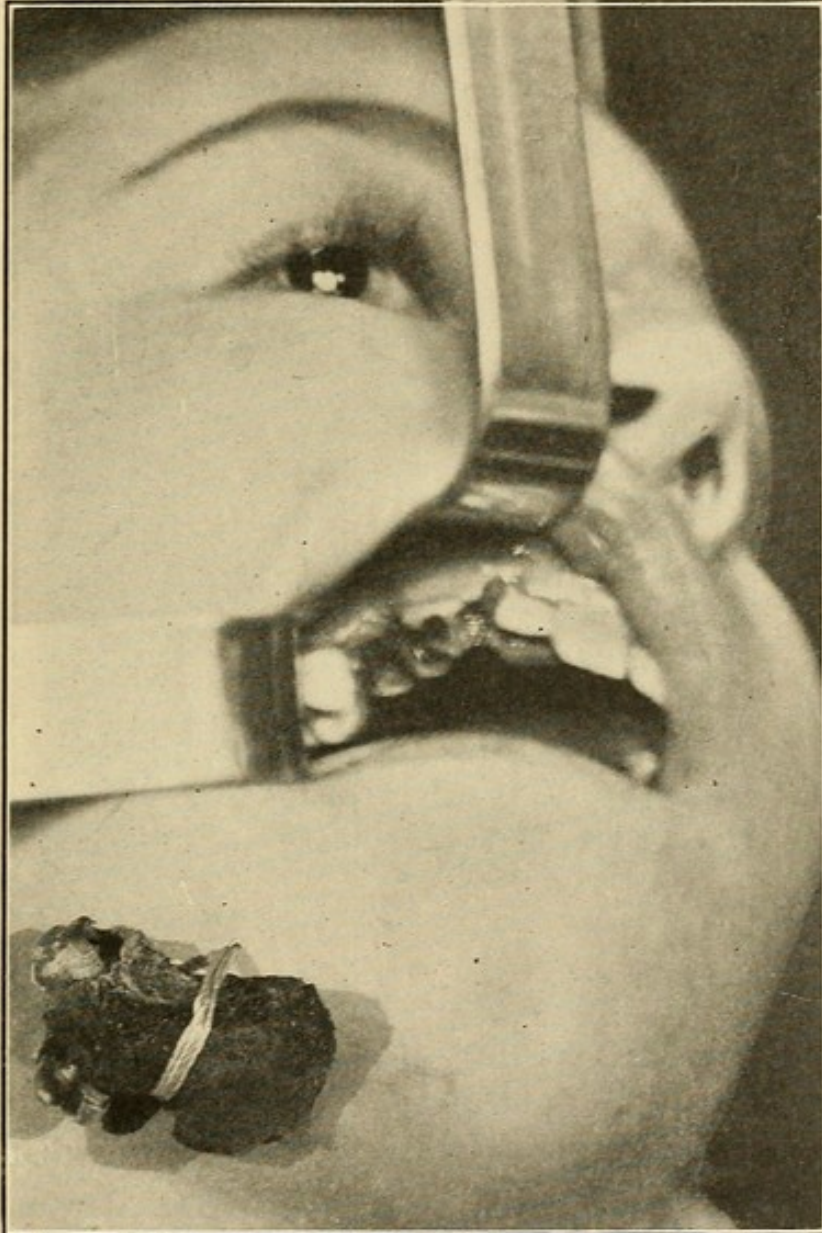


FIG. 73.—HEREDITARY NECROSIS. Sequestrum including floor of the antrum. proportion to the extent of the original infiltrate. Cases such as the one shown in figure 73 appear to be self-limited, or are limited by constitutional treatment. But such cases as that shown in figure 6 have several gummatous deposits, as will be observed by studying the history. Treatment in this case cut short further formation of gummata,



and the patient recovered without return of the symptoms after several years.

*Illustrative Cases.*—Girl, aged about eleven, shown in figure 73, with a history of hereditary syphilis, had some form of operation in England three or four years previous. As may be observed in the picture, the bone was denuded of its periosteum throughout the entire internal and external surface on the right side of the mouth. Under an anesthetic, the soft tissues were retracted up to the antral

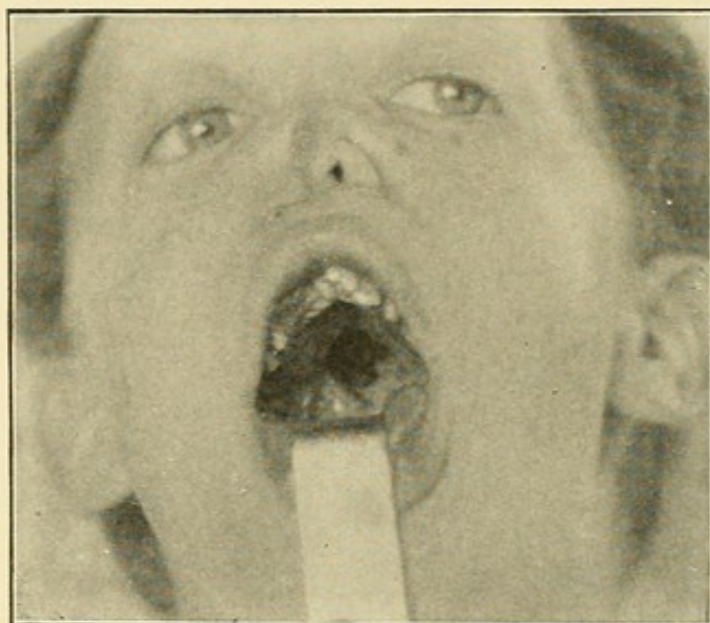

FIG. 74.—CLEFT PALATE FROM HEREDITARY SYPHILIS.

floor and to the nasal cavity and were removed. This included all of the alveolar process up to these cavities and up to the pterygoid process. The sequestrum removed is also shown in the figure. The antral and nasal floors may be observed. It will also be noticed that a molar was encapsulated. Neither the antral nor the nasal cavity was entered. Repair followed promptly, but the patient was placed upon constitutional treatment for several months.

Another girl, aged six years, had diffused syphilitic periostitis of the tibia, which required the removal of a sequestrum, after which recovery followed the usual treatment. This patient returned in several years with com-



plete destruction of the nasal bones, the nasal process of the maxilla, the nasal septum and the floor of both nasal cavities. The hard and soft palate were also destroyed, as well as the faucial walls. The destruction was extending in every direction. Constitutional treatment stopped the progress, and, barring the deformity of the nose and absence of the roof of the mouth, the patient enjoyed good health. A return may be expected in such cases unless the iodids are continued for a year or two, and the patient kept under observation for several years.



## CHAPTER XXII

### TUMORS IN GENERAL

A tumor or neoplasm is a new formation or localized swelling composed of cells which more or less conform to the tissue in which the tumor is developed, and having no physiological function. Tumors are to be distinguished from inflammatory enlargements associated with acute infections, from infiltrations, and from hypertrophies.

The etiology of tumors is not well understood, several theories being advanced. Heredity appears to play some part as an underlying factor in the growth of tumors, since persons who have had parents with malignancy have a blood or cell condition favorable to the growth of tumors of a similar nature. Statistics show that about twenty-five per cent. of malignant tumors are found in persons whose ancestors have had the same disease.

Injuries and irritations no doubt play an important part as the cause of tumors, as seen in epithelioma of the lip from pipe smoking, and carcinoma of the breast from injuries.

Infection has been considered by some authorities as a cause, in that, in certain respects, some tumors resemble infectious processes in their effect upon the general health and their tendency to metastasis.

Other investigators have determined that no ordinary bacteria play any causative part. The possibility of ultra-microscopic organisms has been considered. Secondary and accidental invasions of bacteria into tumors may occur and lead to confusion.

The transplantation of tumors from one part to another does not differ from ordinary metastasis. It, however, proves only the proliferative tendency of the cells of the growth, and not the infectious origin.



A further illustration of the metastasis of tumors is shown in a case where a thigh was amputated for sarcoma of the knee. The wound healed very promptly, and the patient went home in three weeks. In three months, however, she developed sarcoma of the lung, which destroyed her life very rapidly. The cause, or, rather, the route traversed by the cells from the knee, evidently entered the system through the veins before the amputation, going through the venous circulation and the heart, and being deposited in the lung at a point where it would reach the first capillary circulation.

**Classification.**—Tumors are classified both from a histological and from a clinical standpoint. In histological classification the tumor gets its name from the embryonic tissue from which it grows, or from the character of the tumor itself.

*Histologically*, tumors may be classified as follows:

Connective Tissue Group	{	Odontoma (tooth).
		Sarcoma (fleshy).
		Osteoma (bone).
		Fibroma (fibrous).
		Lipoma (fatty).
		Glioma (nerve-like).
		Myxoma (mucus-like).
Epithelial Group.....	{	Encondroma (cartilaginous)
		Carcinoma (crab-like).
		Cystoma (sac).
		Adenoma (glands).
		Teratoma (dermoid).
Group of Higher Order of Tissue.....	{	Endothelioma (serous).
		Myoma (muscle).
		Neuroma (nerve).
		Angioma (blood vessels).
		Lymphangioma (lymphatics).



*Clinical classification* is into malignant and benign. Every variety in the above table is benign, except two, viz., sarcoma and carcinoma.

1. Benign tumors are those which do not apparently affect the health. They are dangerous by reason of their pressure on vital parts due to the enormous size to which they may grow.

2. Malignant tumors are those which shorten life. A malignant tumor infiltrates the surrounding tissue. It tends to recur after removal. It spreads to distant organs by the blood vessels and lymphatics (metastasis) or is transplanted from one part of the body to another. A specific poison is formed by the tumor cell, which disturbs the health from the first, and the patient shows a peculiar sallow complexion known as a cachexia.

White classifies tumors into three divisions: (1) Organ tumors, (2) tissue tumors, (3) cell tumors. The first and second classes are benign, and the third malignant.

**Fibroma.**—Fibroma is a benign connective tissue neoplasm, which develops from any of the different fibrous tissues, and has the characteristics of the tissue from which it originates. It is usually dense, but sometimes has some elasticity, due to the presence of serum within the meshes formed by the loose and wavy arrangement of the slender fibrous tissue. Fibroma usually develops in the skin, in the form of keloid and moluscum fibrosum, from the gums (as fibrous epulis), from nerve sheaths, the uterus, ovaries, and intestines. *Keloid* is a pinkish-white, or white, densely hard, flat, elevated tumor, having irregular borders with claw-like projections extending into the healthy skin. It always has its origin in an old scar, the tumor usually conforming to the outline of the cicatricial area. It develops from stitch holes, ear-ring punctures, and scars resulting from smallpox and acne, and is more frequent in negroes than in others. Its treatment is not satisfactory, since its removal is usually followed by return in the scar left after



the operation. *Moluscum fibrosum* is an hypertrophy of the fibrous tissue of the skin, which hangs in folds. It need not be discussed. *Epulis* is described as an hypertrophy of the fibrous tissue. Fibromata of the other structures above named are general surgical conditions and will not be considered here.

**Lipoma.**—Lipoma is a benign accumulation of fat or adipose tissue, and may be found in any part of the body. Lipomata are most common under the skin, and are of two forms: (a) sacculated, which means that the tumor is circumscribed; (b) diffused, when the abnormal piling up of adipose tissue is blended with the normal fat surrounding the growth. Their only clinical significance is the resulting deformity. When this is objectionable, enucleation should be made. Return is not usual.

**Adenoma.**—Adenoma is a benign epithelial tumor of a normal secreting gland, composed of cells and fibrous stroma similar to the structure of the gland in which it grows. It resembles carcinoma in many respects, but is not malignant, although malignant tumors of the glands, or adeno-sarcomata are seen, and it is often quite a difficult matter to distinguish between them, since they are both of the epithelial variety. There will be considered, as having particular interest to the dentist, three varieties: (a) Sebaceous cysts, commonly called "wens," result from an occlusion of the excretory duct of a sebaceous gland (for description see Cysts). (b) Adenoma of the thyroid gland, commonly known as goiter or bronchocele, consists in an enlargement of the thyroid gland, entire or (occasionally) of but one side. It contains a colloid fluid, in which is found cholesterin. The fluid accumulates from the center, gradually destroying the gland structure. There are no symptoms except those due to pressure. These tumors are not usually removed unless the size is enormous. (c) Adenoma of the salivary glands develops from the gland itself, and is contained within its capsule.



**Neuroma.**—Neuroma is a tumor of a nerve and may be epiblastic or epithelial. It develops along nerve trunks, especially the sensory nerve; hence, the extreme pain, which is frequently met with, and which is sometimes the only symptom. The most common variety of neuroma is fibro-neuroma, which develops from the fibrous sheath of the nerve. Fibro-neuromata are quite frequently multiple. In two cases in which dissections were made over one thousand tumors were counted in each. They are found on the branches of the nerves distributed to the tissues of the face, especially of the fifth nerve, producing a most painful affection of the teeth, for which many teeth are extracted with the hope that the cause of the pain will thus be removed. For further consideration see the chapter on Neuralgia.

**Cysts.**—A cyst is a benign tumor containing fluid or semifluid, surrounded by a capsule. It is due to an obstruction of the normal outlet of some fluid of the body. There are four varieties: (a) Retention cyst, or the accumulation, in a previously existing cavity, resulting from an obstruction of the orifice of exit; (b) tubulo-cyst, or a dilatation of a duct or tube carrying fluid, due to obstruction; (c) hydrocele, or accumulation in a serous cavity; (d) gland cyst. It is the latter variety which concerns the dentist.

Gland or mucous cysts are due to obstruction to the orifice of exit of the mucus coming from a gland of the mucous membrane. They are most frequently found on the inner surface of the lips. Rarely they develop from the gingival mucous membrane, or from the vault of the mouth, resembling in course those found in the antrum. They may spontaneously erupt and result in a cure, although they may return after repair takes place, provided the cicatrix includes the duct. Obstruction to the ducts from the glands of Nuhn near the tip of the tongue produces cysts. Treatment consists in enucleation of the entire gland and duct.



## NON-INFECTIVE TUMORS OF THE SOFT TISSUES OF THE MOUTH

In addition to the tumors of the bones of the mouth, malignant growths, and tumefactions, there remain the tumors of the soft tissues of the mouth. They may be studied under the following heads:

- |                     |   |                                    |
|---------------------|---|------------------------------------|
| (1) Cysts.....      | { | (a) Muciparous Cysts.              |
|                     | { | (b) Cysts from the Glands of Nuhn. |
|                     | { | (c) Echinococcus Cysts.            |
|                     | { | (d) Dermoid Cysts.                 |
| (2) Vascular Tumors | { | (a) Hemangioma.                    |
|                     | { | (b) Lymphangioma.                  |
|                     | { | (c) Macroglossia.                  |
| (3) Solid Tumors... | { | (a) Fibromata.                     |
|                     | { | (b) Papillomata.                   |
|                     | { | (c) Endotheliomata.                |
|                     | { | (d) Adenomata.                     |

### (1) CYSTS

(a) *Muciparous cysts* are found anywhere in the mucous membrane of the mouth, but probably most frequently on the lips. They have a bluish, glossy appearance with a lighter center, indicating the thinness of the sac. They are small spherical masses, the margins of which shade off into the surrounding tissues. When opened, the fluid will be found to be a clear viscid or colloid, of the consistency of the white of an egg. These cysts are the result of obstruction of the duct of a mucous gland, usually following an injury. They are simple and have no complications.

Treatment consists in incision and curettement to destroy the sac, and the use of phenol, after which repair usually follows without complication.

(b) *Cysts from the glands of Nuhn* are found along the sides of the tongue. They contain a transparent fluid and



may reach the size of a walnut. They result from obstruction of the duct of one of these glands. They are pale red, with a thin wall. Treatment includes incision, curettement, cauterization, and, if large, packing. Repair is usually uneventful.

(c) *Echinococcus cysts* or hydatids are rare. They are caused by the larva of *Tenia*. When found, they resemble hydatids in the liver and other structures. They are always multiple, spherical, harder than the other varieties, and movable under the mucous membrane. They may at the same time be found on other parts of the body.

(d) *Dermoid cysts* are the result of an abnormal invagination of the first and second, or the second and the third, gill-arches or embryonic clefts, as a result of an incompletely developed mandible. They are usually subdermal, under the floor of the mouth. They may also be found above or below the mylohyoid muscle, or attached to the mandible or hyoid bone, or within the substance of the tongue. Their size varies, but they may become as large as a baseball. When above the membranous floor of the mouth, their growth encroaches upon the oral cavity; if below, they appear in the form of a double chin. They are firm and doughy and seldom fluctuate. They are usually in the median line, are hard, and rarely painful. The growth is, as a rule, slow; but when they grow rapidly there is tenderness or pain. The overlying skin is not attached and is otherwise normal.

Diagnosis must be made from ranula and other cysts and tumors of the tongue.

Treatment is extirpation. This is best done through a median incision from the genial tubercles to the hyoid bone, separation of the geniohyoid muscles, and removal. The cyst is easily shelled from its capsule. The cavity is packed for several days and then permitted to close from the bottom.



## (2) VASCULAR TUMORS

In addition to the cysts and other tumors above referred to, there are the following vessel tumors requiring mention: (a) Hemangioma; (b) lymphangioma; (c) macroglossia.

(a) *Angiomata* develop in the mucous membrane of the mouth, in the tongue, and occasionally along the alveolar process. In all of these locations they are, as a rule, not large, and are usually single. They have a darkened bluish-red color. They are composed of dilated venules, from which blood may be squeezed back into the other vessels. They are soft in consistency and are usually congenital. When they involve the cheek, they are, as a rule, much larger, producing in some cases marked deformity.

When they are small and on the tongue they should be let alone. If so large as to interfere with speech, mastication, or other faculties, they may be removed. The operation is very bloody, and several methods of procedure have been practiced. A provisional ligature about the base of the tongue is first introduced. The tumor is then incised, curetted down to the healthy tissue, and sutured sufficiently deep to include all bleeding vessels. Secondary hemorrhage may follow. It is better to pick up and ligate all bleeding vessels after the provisional ligature is removed, and after the sutures have been introduced, but before they have been tied. Ignipunctures by the Thiersch Paquelin cautery, alcohol and hot water injections, have all been successfully used by various operators.

(b) *Lymphangiomata* are usually cystic when found in the mouth, but may be cavernous. The cystic variety are single, situated usually in the end of the tongue or in the cheek. The size varies, and the outline is irregular. They are congenital, but do not attract attention until a child is several months old. They resemble retention cysts and must be differentiated from them. Their content is serous,



while that of cysts is viscid. A second variety is the nodular, appearing on the back of the tongue, as vesicles containing a turbid fluid. The vesicles appear some months in advance of the roughened nodular stage. The base of the vesicles becomes indurate, forming the nodules as a result of the inflammatory change. The primary cause is doubtless an infection.

Under local anesthesia the individual vesicles and nodules should be destroyed by curettement, followed with the use of the Paquelin cautery, or the latter may be used without curettement. A second operation may be required to destroy all the vesicles.

(c) *Macroglossia*, formerly supposed to be a congenital hypertrophy, is now considered as cavernous lymphangioma. The tongue is congenitally enlarged and increases in size gradually, soon protruding from the lips. The oral cavity is finally filled and the enlargement shows externally. The surface of the tongue may be studded with nodules and vesicles. The lymph spaces become considerable sinuses, containing serum or lymph. The connective tissue is hypertrophied.

Treatment includes destruction of individual cysts with the Paquelin cautery. A large portion of the tongue may be removed by excision. Hemorrhage is a serious complication owing to the irregular and abundant blood supply. In excision, scissors should be used instead of a scalpel. The cut should include a wedge of the center of the tongue. The sides should be adjusted with deep through-and-through sutures, so as to constrict the blood vessels.

### (3) SOLID TUMORS

The benign solid tumors of the mouth resemble those developing in other parts of the body. The most common forms are: (a) Fibromata, (b) papillomata, (c) endotheliomata, (d) adenomata.

It is hardly necessary that an extended study of these



varieties of tumors be made, since the dentist will require only to exclude them from the common forms of tumefactions bearing more nearly upon his field of operation.

Introductory to the presentation of the subject of tumors of the alveolar process, it might be well to call attention to the unsystematic method in which the subject has been studied.

Bland-Sutton's classification of tooth tumors which was given to us many years ago has not been improved upon so far as embryological tumors are concerned.

The classification used here, I think, will make it much easier for the student of oral surgery to grasp the differential points between connective tissue and epithelial tumors. It will be observed that enlargements of the alveolar process that are inflammatory or infective, in that they depend upon microörganisms as a cause, have not been considered, and that only the hypertrophies or cystic conditions associated with the teeth are included.

This subject is best presented by observing the following arrangement:

Developmental Tumors of the Teeth.

Neoplasms of the Alveolar Soft Tissues.

Bone Tumors and Cysts.

Malignant Tumors.

Cysts and Tumefactions from Developed Teeth.



## CHAPTER XXIII

### DEVELOPMENTAL TUMORS OF THE TEETH

Neoplasms that have as their cause some portion of the teeth during embryonic development are not uncommon. The literature is not extensive, and the classification given by Bland-Sutton twenty years ago has not been changed. Cysts and tumors in connection with the teeth during their development originate from one or more of the dental tissues of tooth germs during the process of development. They differ from impaction, in that the tooth does not properly develop and some portion of the histological structure is the nucleus for, and enters into the formation of, a new growth. They also differ from tumors having their origin about the roots of matured teeth.

The following summary of odontomata is taken from Bloodgood: In his analysis of ten cases, four cases occurred on the upper jaw; four cases on the lower jaw; two cases on the ethmoid. The ages of the patients varied from six to thirty years; four were under fifteen years of age, six between twenty and thirty. The duration of the tumors varied from three months to thirteen years.

Writers have not agreed as to the real cause of tooth cysts. Sutton says: "Histologically, an epithelial odontome consists of branching and anastomosing columns of epithelium, portions of which form alveoli, the cells occupying the alveoli varying, and the outer layer being columnar, while the central cells degenerate and give rise to a tissue resembling the stratum intermedium of an enamel organ. They probably arise from persistent portions of the epithelium of enamel organs."



Dr. J. C. Oliver says: "Several explanations are possible, for instance: First, misplacement of the dental germ, either in reference to position and depth in the gum tissue, or in reference to the axis of embryonal development and embryonal forceps. Second, embryonal rests. The neck of the primitive bud that springs from the primary enamel germ for the development of the permanent tooth may persist and develop cysts in definite relationship to the crown of a fairly well-developed tooth. Such a process is entirely analogous to the rest of the ovary which is left after the infolding of the germinal epithelium, and which is responsible for the cystadenomata of the ovary. Third, failure in evolution. (a) The membrane of Nasmyth may become unusually thick and tough, and fail to resorb. This may occur with a normally placed follicle, but more particularly when the axis is misplaced and it lies in an oblique, transverse or reversed position. (b) The wall of the follicle is unusually dense and resistant, giving rise to a similar series of changes to the above. A general or partial jumbling of the enamel and dental papilla at the time of their formation may take place. Fourth, irritation. (a) The proliferative activity of the cells concerned in the evolution of the teeth, by reason of displacement, does not meet with the normal juxtaposition and arrangement of cell force and interaction that are believed to be requisite to the normal histologic arrangement of cells in their development. This results in a proliferative activity on the part of the cells of the dental papilla; or, as occurred in the three cases reported, and as most often occurs, the surrounding periosteal and other connective tissue structures undergo proliferation. The histologic structure of the tissue found in the cysts reported is that of giant-celled sarcoma, but is not sarcomata. It is composed of connective tissue, which has reverted to an embryonal or granulation tissue type under the influence of prolonged irritation. (b) The mechanical irritation by an obliquely or transversely placed tooth crowding into the side



of an alveolar border may certainly give rise to the same irritative changes that have just been described, and may also explain the three cases reported. The interior wall of the cyst shows typical granulation tissue. This irritative change is analogous to that found around encysted bullets or other foreign bodies."

Sutton's classification of developmental neoplasms of the teeth is as follows:

- |                 |   |  |
|-----------------|---|--|
| Odontomata..... | { | 1. Epithelial (enamel organ).<br>2. Follicular (fibrous; cementous).<br>3. Radicular (from the root).<br>4. Composite (from the whole germ). |
|-----------------|---|--|

(1) **Epithelial Tumors.**—Enamel organ tumors are developed from the epithelial cysts. They are usually multilocular, filled with mucus, and have a red circumferential area resembling sarcoma. They generally develop at from eighteen to twenty-three years of age, but may appear at any age. Their origin is probably from persistent remains of epithelium of the original enamel organ.

(2) **Follicular Odontomata.**—This variety of tooth tumor, according to Sutton, appears in three forms. Unless the successive stages are studied microscopically, the follicular and fibrous forms and the composite variety present very much the same characteristics. These tumors are typical of the so-called dentigerous cysts. They develop from the permanent teeth, usually the molars. The wall is formed by the expanded tooth follicle, which is filled with a viscid fluid, and in which is found the imperfectly developed, loose and displaced tooth. The tumors may grow to enormous size, causing great deformity. This variety is known as fibrous. The sac wall usually calcifies. The cementum of the tooth, i. e., structure which gives origin to the cementum of the tooth, has to do with the calcareous change above mentioned; hence, the name sometimes used, cementoma. Two or more tooth follicles may join in the



process, when it is known as compound follicular odontomata. Dozens of tooth-like bodies have been removed from such a cavity. Suppuration rarely, if ever, occurs.

Bloodgood says: "Under the microscope one sees the normal mucous membrane of the gum, then a zone of connective tissue, beneath which is the circumscribed tumor. The tumor is composed of branching epithelial alveoli in a connective tissue stroma. Some of the alveoli are cysts lined with the typical basal adamantine epithelium. Other alveoli are solid with cells showing the various morphologic changes of the adamantine epithelium."

*Cementous Follicular Odontomata.*—Certain tooth tumors take upon themselves the consistency of a tooth, and

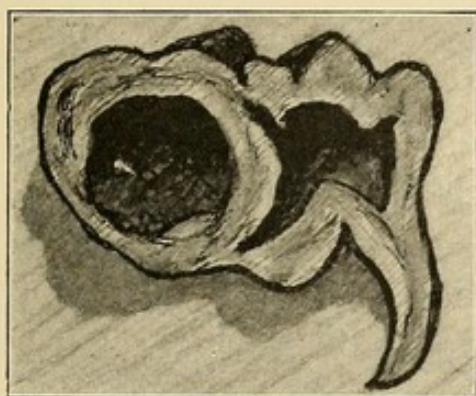


FIG. 75.

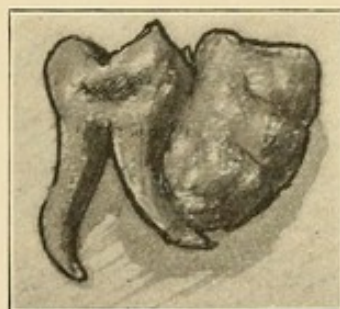


FIG. 76.

ODONTOMATA, OR ENAMEL DEPOSIT ON A DEVELOPED TOOTH. (Case of Dr. H. E. Friesell.)

may be a simple budding from the side of a tooth, from the root or the crown, or the cementous growth may include the entire tooth, leaving the crown projecting in only one place to identify it with the particular tooth.

Thomas L. Gilmer has very ably presented this subject and furnished pathological specimens from his own practice. He may be quoted with profit, as follows: "Odontomes are rare in man. They are more frequently found in the jaws of the horse and other animals, but when both those found in man and those found in animals are considered, the number is relatively small. Composite



odontomes are most frequently found in the mandible, but are not to be excluded from the maxilla, since two of those in this report were from the upper jaw. They seem to belong to the molar region of the jaws. The composite odontome, as indicated, is made up of enamel, dentine and cementum. These tissues may be thrown together in a more or less homogeneous mass, plus well-formed diminutive teeth, all united by cementum, easily made out macroscopically, or the formation may appear to the eye only as a conglomerate mass with no well-marked tooth forms. This simple, homogeneous mass, as observed by the unaided eye, is transformed by magnification into a complex tumor of regularly formed teeth with their roots and canals all cemented into a solid and compact body.

“The composite odontome differs from the ordinary dentigerous cyst containing diminutive teeth or dentary bodies in that the dentigerous cyst contains no cement substance other than that which covers the root of the individual tooth, when perfectly formed teeth are found, with each little tooth or denticle separate and distinct from the other; besides, there is a well-defined cyst wall and cyst fluid. In the composite odontomes there is no cyst wall or cyst fluid, so far as I have been able to discover. The origin of composite odontomes has not been fully made out, but it is reasonable to attribute them to the same source as that of multilocular cysts or adamantomas, that is, to unatrophied remains of the epithelial cord; or possibly to extra buds given off from the epithelial lamina, which have become distorted in development. Black attributes supernumerary teeth to additional buds, which buds he has demonstrated. I removed a remarkable growth from the right side of the lower jaw of a young man. This odontome is the most remarkable I have ever seen. It is composed of diminutive teeth more or less perfectly developed, of the incisor, cuspid and bicuspid types, and large numbers of denticles and enamel drops, cemented together within this



oblong, crescentic mass. The odontome measures antero-posteriorly 34 mm., bucco-lingually 18 mm., from crown rootwise 19 mm. Measurements of the growth are 24 mm. from before backward, 20 mm. from side to side, and 14 mm. from above downward. From sections of the tumor Dr. F. B. Noyes has made photomicrographs, which show most beautifully and perfectly the characteristic composition of this class of odontomes." In the report to the Illinois Society, Dr. Black said of the histologic appearance of the sections: "For the purpose of examining its structure I sawed it through, halving it in an antero-postero-perpendicular direction, and cut some sections. I found all the tissues of a normally developed tooth, but in a state of confusion. There is an entire absence of any proper pulp cavity. The disposition or arrangement of the tissues is peculiar and striking. It is as though there were a thousand teeth, exceedingly minute, growing as close together as they could be crowded, and the interstices between them filled up with enamel and cement. In the field of the microscope, with the sections I have, we shall often be able to see a number of these diminutive teeth at a single view. Each has its own little pulp chamber in due form, its own separate dentine and its own enamel cap, and plastered in and about and added on to these there is a considerable amount of both enamel and cement of very irregular formation. Many of the pulp chambers are partially filled with calcospherites. These also appear in many parts of the specimen in profusion. It is interesting to note the resemblance of this odontome to the normal structure of the teeth of some of the lower orders of animals, especially some species of fishes, in which there are branching and radiating pulp cavities."

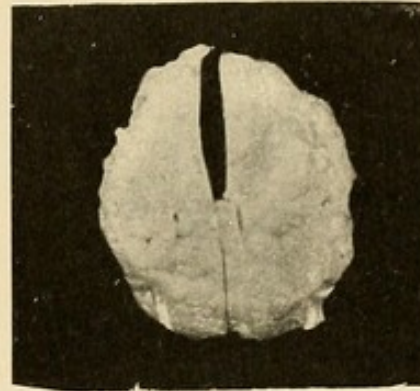


FIG. 77.—ODONTOMA FROM WHICH SECTION IN FIG. 78 WAS CUT. (Dr. Thos. L. Gilmer.)



(3) **Radicular Odontomata.**—Radicular odontomata differ from the follicular in that the crown of the tooth does not enter into the diverted process, as it is composed of unalterable enamel. The dentine and cementum enter into

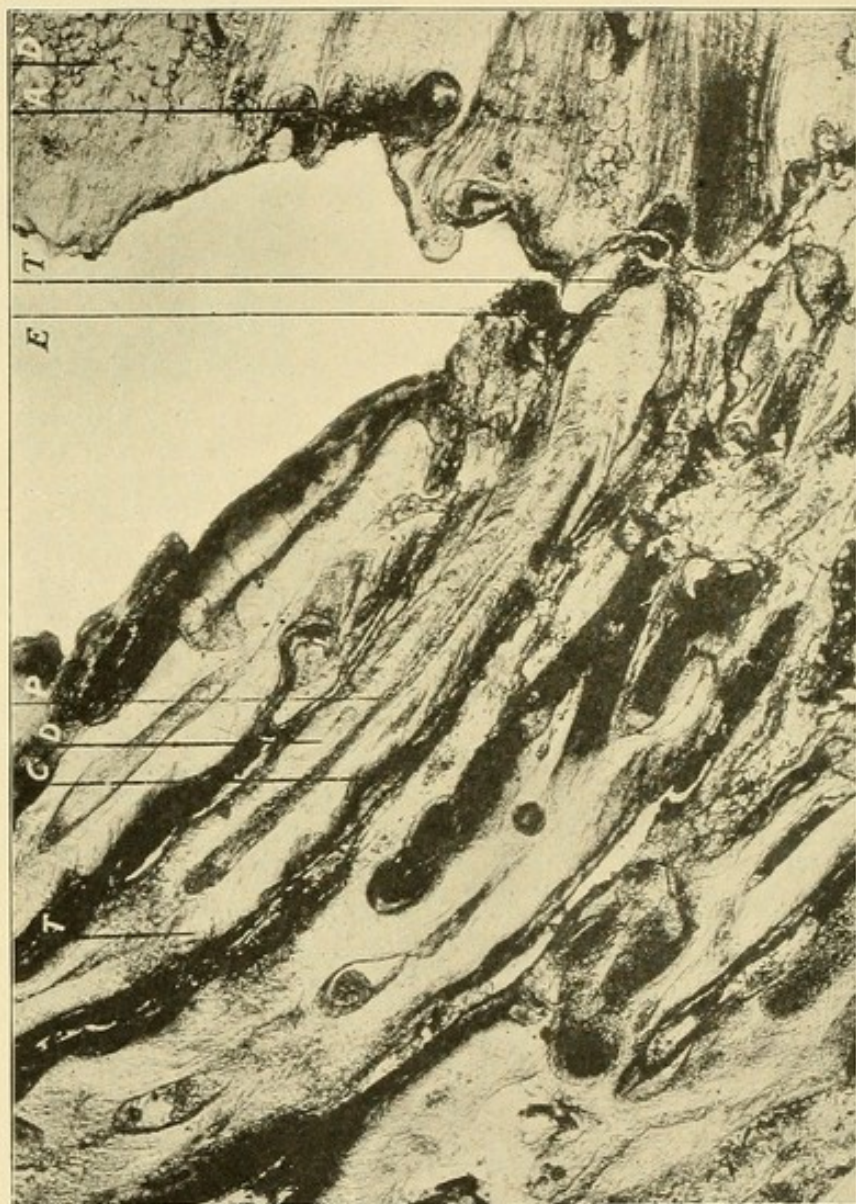

FIG. 78.—MICROSCOPIC SECTION. (Dr. Thos. L. Gilmer.)

the formation in varying proportions. The tooth erupts, but loses its identity in the tumor which is attached to the base. Tumors of this sort are rare, and are seen more frequently in the lower animals.

(4) **Composite Odontomata.**—These comprise a combination of two or all of the tissues of the teeth. The ce-



mentum, enamel and dentine may be involved. The normal tooth structures are entirely displaced by the new process. In other regards they do not differ from the first three varieties.

**Symptoms.**—One of the symptoms of odontomata is tumefaction, beginning, as a rule, from the side of the alveolar process, increasing outward uniformly in all directions, or, if the growths develop from a buccal root, enlarging inward. The growth is not rapid, requiring many months to produce much deformity, but, as it is progressive, there is no limit to the deformity if left unoperated upon. Pain may be severe and is caused by the pressure upon the normal nerve terminals and surrounding structures. There are no constitutional symptoms from the tumor *per se*, and when present they are the result of involvement of adjacent vital tissues.

**Diagnosis.**—Broca says that any new growth of the jaw which occurs after complete development of the teeth is certainly not odontoma. The diagnosis is very important. No tumor beginning in the alveolus before maturity should be removed until odontoma is excluded. This may be done by passing a sterile needle into the tumor at several points, or an exploration incision may be made and the central structure examined. The incision should be made in view of radical operation in case malignancy is found. Having this in mind, useless sacrifice of tissue is prevented. Firm pressure upon some of these tumors reveals a parchment-like crackling. A most frequent error of the general surgeon who is on the lookout for sarcoma, exostoma, etc., and seldom sees a dentigerous cyst or a tumor due to non-eruption, is to mistake the latter condition for the graver one. In this event, he makes a complete removal of a maxilla or half of the mandible. After the operation is complete and the tumor is incised, a tooth is found in the center. Had the true condition been suspected, the tumor would have been removed, such abnormal process of the



bone as was found would have been chiseled away, and in a few weeks repair would have followed without deformity or destruction of functional usefulness of the parts.

*Differential diagnosis* must be made from tooth and bone cysts, osteoma, exostosis, sarcoma, carcinoma, actinomycosis, and the swellings associated with chronic bone diseases, such as syphilitic gumma and tuberculosis.

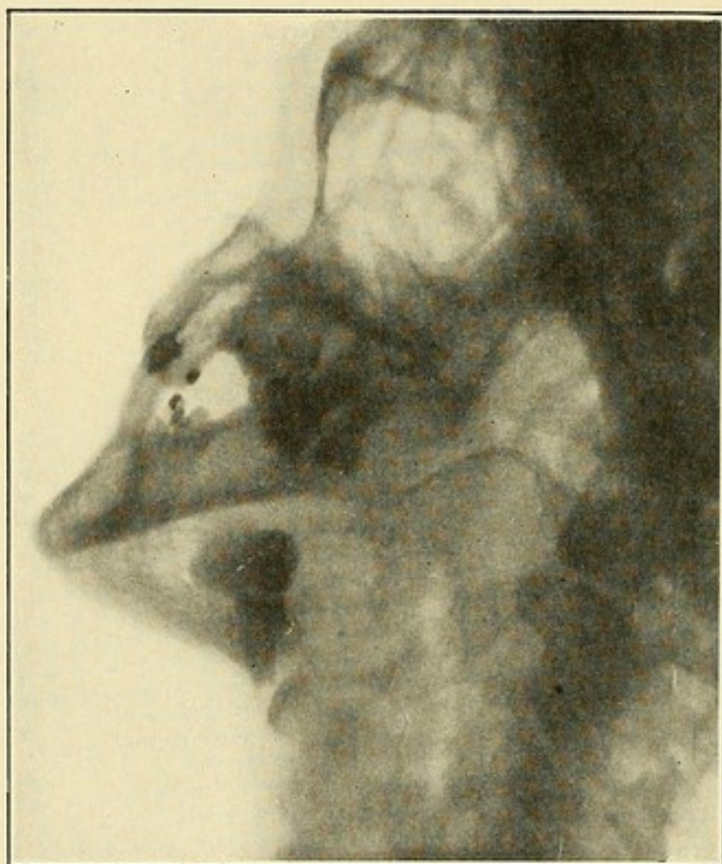


FIG. 79.—MULTIPLE CYST OF MANDIBLE CAUSED BY THE IMPACTION OF TWO TEETH RESTING AT RIGHT ANGLES TO EACH OTHER.

**Treatment.**—The treatment of the simple variety is obvious and efficacious, namely, to incise the cyst as early and as thoroughly as possible, remove the impacted rudimentary or fully grown tooth, scrape away the epithelial lining, and pack the cavity with suitable material. In some instances it may become necessary to remove part of the jaw and of the cyst-wall, in order to gain access to the cavity. Many surgeons advise that such operations be made from within the mouth, as often as this is possible. While sur-



geons have erred in making too aggressive operations in cases of simple dentigerous cyst, error has also been committed in treating proliferating cystomata ineffectively, thus subjecting the patient to many operations, each with its risk, when one correctly performed operation would have been sufficient.

A woman, aged about fifty years, had a large tumor of the molar region which had been removed two or three times, to be followed by a return. Malignancy was not suspected. An X-ray (figure 79) showed two impacted teeth. They were removed. It was undoubtedly a multilocular cyst and none of the operations performed had removed all of the cyst; hence, the return.

As already indicated, the surgeon should regard the incision into a supposed simple cyst as exploratory, because a differential diagnosis between a simple and a proliferating cyst, particularly in the early period of growth, cannot be made without direct inspection. The surgeon should also prepare the patient, and be prepared himself, for the more severe operation, in case the growth should be a multilocular one. In fact, it would seem to be a good plan, as suggested by McLane Tiffany, in all cases of operation upon tumors of the maxilla, to incise the tumor first, in order to be absolutely certain that mistake in diagnosis may not result in an unnecessarily severe and disfiguring operation.



## CHAPTER XXIV

### NEOPLASMS OF THE ALVEOLAR SOFT TISSUES, AND BONE TUMORS AND CYSTS

#### NEOPLASMS OF THE ALVEOLAR SOFT TISSUES

Independent of odontomata and osteomata, other neoplasms are found to develop from the alveolar soft tissues.

The most common forms are the following: (a) Papilloma; (b) polypus; (c) hypertrophy; (d) fibroid and myeloid epulis.

##### (a) PAPILLOMATA

Several forms of growth develop from the gums and occur as elongated papillæ in the form of little tufts. Their centers are composed of mesoblastic tissue and they have a covering of the thickened epithelium. They are of the epithelial type, and have an irregular surface with a strawberry appearance. These tufts develop from the gingival margin about one or many of the teeth. The cause is some mechanical irritant, such as tartar, etc.

A typical case was that of a pregnant woman, aged twenty years, upon whom a radical operation was not advisable. The granulations were strawberry red and irregular, and bled freely upon the least irritation. At several points they grew as high as the crowns of the teeth, and more than two-thirds of the teeth were included in the area of growth. Tartar was found throughout the lingual surfaces of the teeth.

Treatment consisted in curetting the granulations back to the healthy mucous membrane. The hemorrhage was



controlled with adrenalin solution, and tincture of iodine was applied to the wounds. The patient was seen twice every week for four or five weeks, when all tendency to return had been controlled. She remained well when seen eight months later.

There is a great tendency for these papillomata to return, and even in three or four days they have been seen

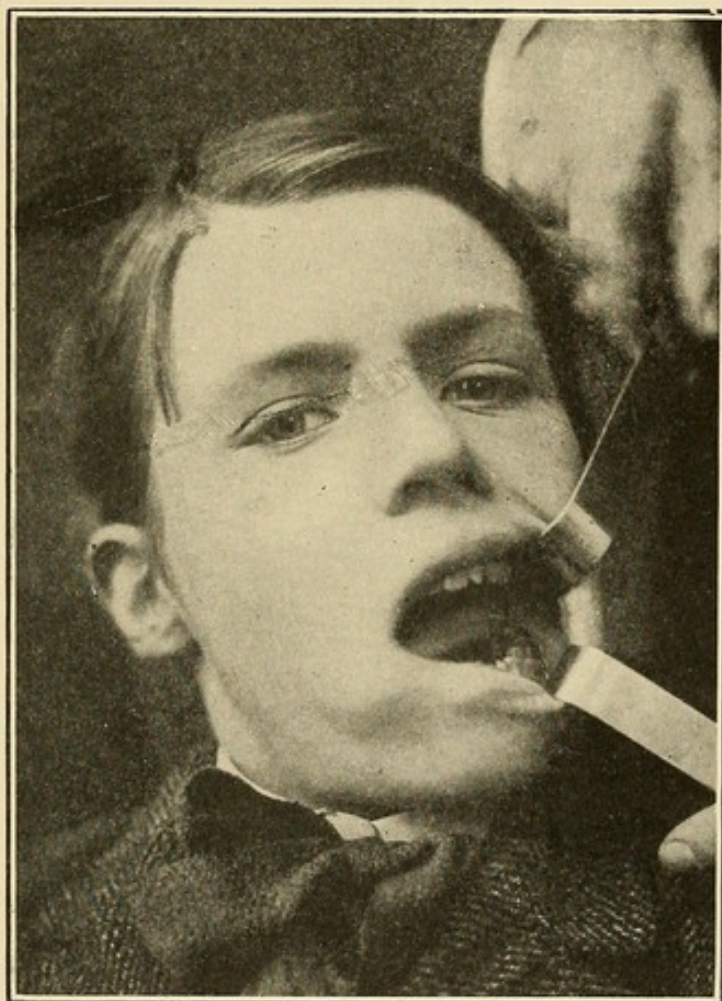


FIG. 80.—PAPILLOMA OF ALVEOLUS.

to grow an eighth of an inch at points where it was thought they had been thoroughly removed by curettement. Thorough removal, cauterization and disinfection are essential if return is to be prevented. There is no tendency toward malignancy.

Figure 80 illustrates a case of papillomatous growth of the gingival mucous membrane extending entirely around two teeth and including a third along the sides. It was



removed by the use of a curette under local anesthesia and followed by the application of commercial tincture of iodine. There was no return in several months. The surface was strawberry-like and bled under slight pressure.

Figure 81 shows papillomata of the alveolar process and resembles the case illustrated in figure 80, save that

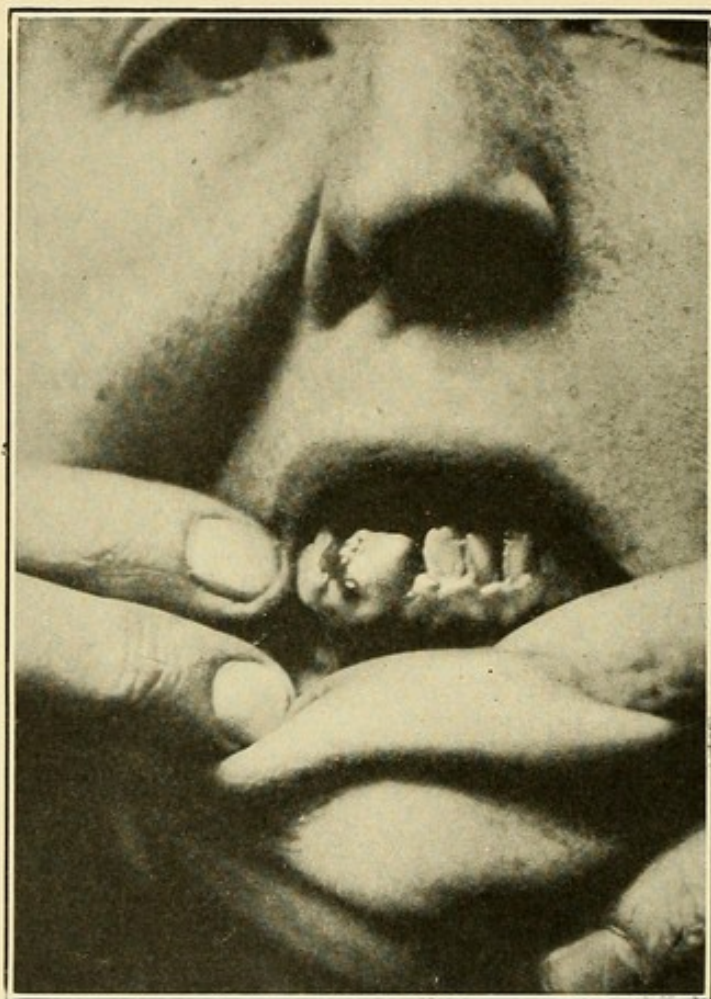


FIG. 81.—PAPILLOMA OF ALVEOLUS.

its surface was not granular except at some points. Operation included removal by the use of the knife under local anesthesia. There was no return after several months.

#### (b) POLYPUS

Polypi of the gums are seen quite frequently and resemble such growths in other parts of the body. They differ from papillomata in that they are usually single, grow to



considerable size, and have a distinct pedicle, while tumors of the papillomatous variety are multiple and grow exuberantly and rapidly.

These tumors vary from the size of a pea to a horse chestnut, and are found on the gums in the neighborhood of diseased teeth. They are said to be caused chiefly by the ragged edge of a carious tooth, but it is probable that ptomaines from the operations of bacteria stimulate papil-

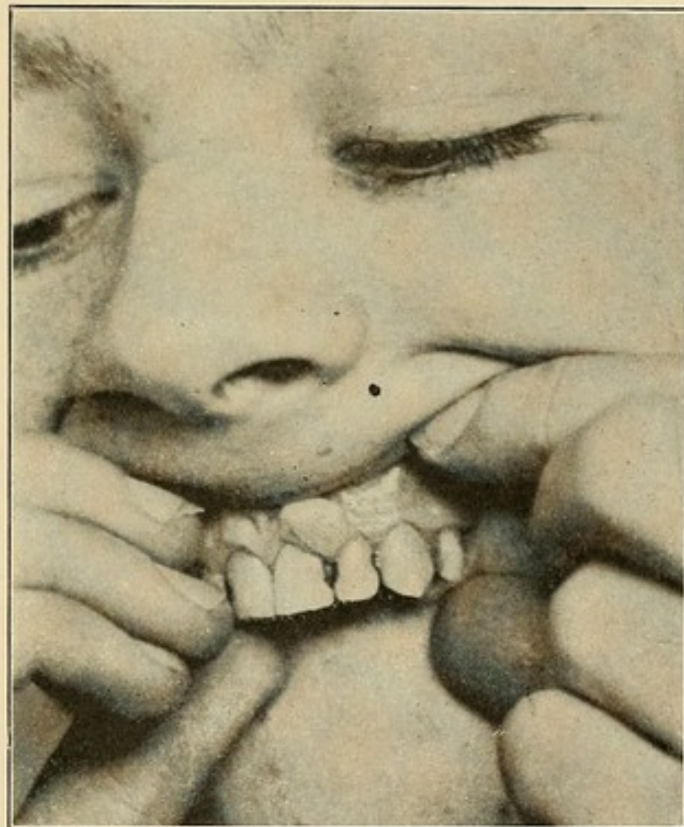


FIG. 82.—PAPILLOMA OF ALVEOLUS. (Case of Dr. C. B. Bratt.)

lomatous growths upon granulating mucous surfaces and have more to do with their etiology than is usually supposed. The growths in question exhibit on section large, branching papillæ, covered with an abnormally thick layer of squamous epithelium. The polypi are purely local in their origin and are non-malignant.

**Treatment.**—The treatment consists in removal under a local or general anesthetic. A scalpel or scissors may be used. There is no tendency to return. If there is return,



however, the growth will be from a new point of the gum, and not at the point of original growth.

**Illustrative Cases.**—Figure 84 shows a typical polypus of the process in a girl of eight years. The growth was over the alveolus with a distinct pedicle or contracted base attached to the lingual gingival margin. The surface, while slightly roughened, did not bleed as do papillomata. Operation was performed by severing the pedicle with a

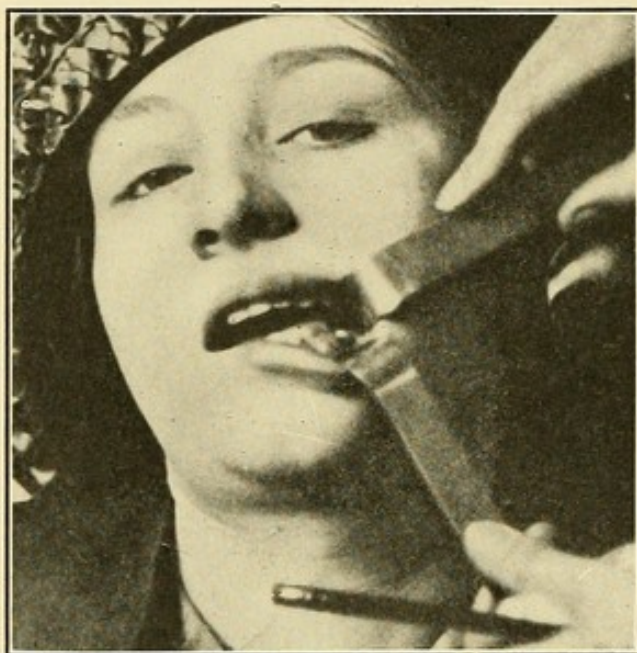


FIG. 83.—PAPILLOMA OF ALVEOLUS.

scalpel under a very mild degree of chloroform anesthesia. There has been no return.

Figure 85 shows a second case of polypus in a woman, aged thirty years. It had been growing for several years. In physical appearance it was the same as in the preceding case. Operation was performed under local anesthesia. Hemorrhage, which was quite severe, was controlled by pressure. Repair was prompt, and there has been no return.

#### (c) HYPERTROPHY

Hypertrophy of the soft tissues over the alveolus, and independent of it, is a growth of the connective tissue between the bone and mucous membrane.



The enlargement is uniform, developing on both sides of the process and extending around the teeth. The margin of the growth is not defined, as in the former varieties, but disappears in the normal mucous membrane. The surface is covered with normal mucous membrane. There is almost a bony hardness, resembling osteoma, odontoma, and malignant growths during their early history. There is little if any pain and no other local or constitutional symptoms. The condition may be the early stage of epulis, but the cases operated on were very different from cases of this

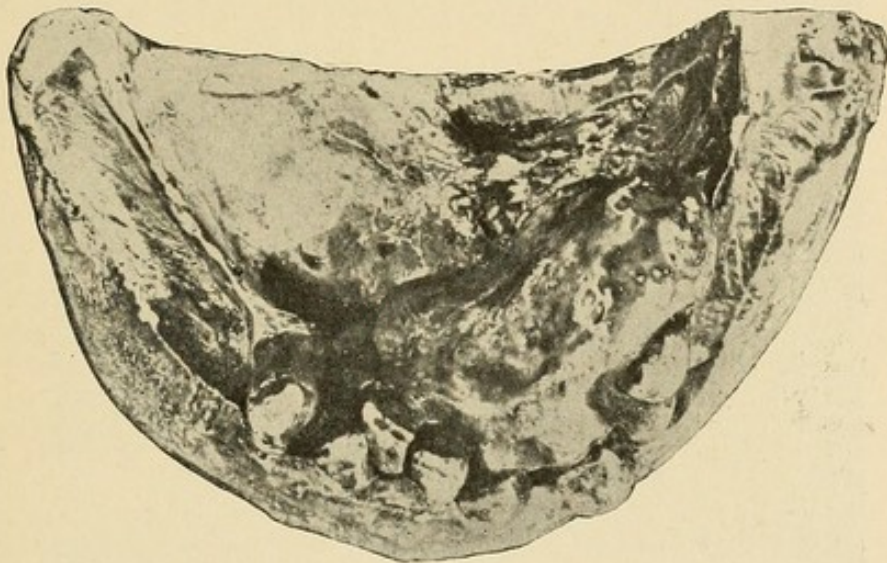


FIG. 84.—POLYPUS OF GUM.

condition under observation. The growths resemble, or may be histologically identical with, fibroid epulis as heretofore understood.

**Treatment.**—Treatment consists in removal of the growths by excision. They are not malignant and there is usually no return.

**Illustrative Cases.**—Figure 86 shows a case of hypertrophy of the left upper alveolar tissue in a woman aged forty-five years. It had been growing for eighteen months. The surface was smooth, uniformly developed, and without symptoms. Removal was done by cutting to the bone on both sides. The process was severed with a circular saw on a dental engine. The section was below the nasal



and antral cavities. The bone was not involved. Repair was prompt and there had been no return in two years, when the patient was last seen.

The second case (figure 87) is very similar to the foregoing. The patient was about thirty-five years of age. The enlargement involved the upper process from the median line to about the first bicuspid. The teeth had previously been extracted. The operation was performed as

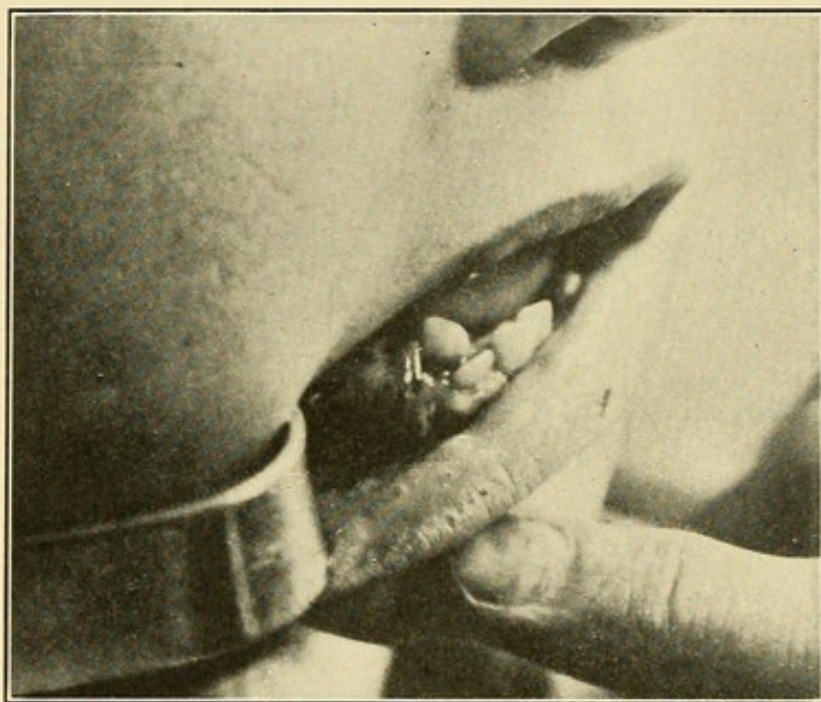


FIG. 85.—POLYPUS OF GUM.

outlined in the former case. Repair was prompt, and there was no return.

#### (d) EPULIS

From the present-day viewpoint, epulis appears to include any variety of growth of the alveolar process which takes the form of a distinct tumor. The tumor generally grows in connection with bone, does not show metastasis, and, as a rule, does not recur after removal. During the early stages, unless a section is examined microscopically to prove its histological structure, it is difficult to say whether it is a hyperplasia, fibroma, or sarcoma. The age of the patient has little to do with the development, al-



though the majority of cases have been observed in young manhood.

Epulis is a connective tissue tumor arising from the mesoblast. The most recent authorities divide the so-called epulitic growths into myeloid and fibroid, the former being of a spongy nature, with irregular surfaces. The tendency is to grow in every direction, and in some instances to carry the teeth along. The surface is warty, and the color conforms quite nearly to the normal mucous membrane, during early development; later, however, the color becomes

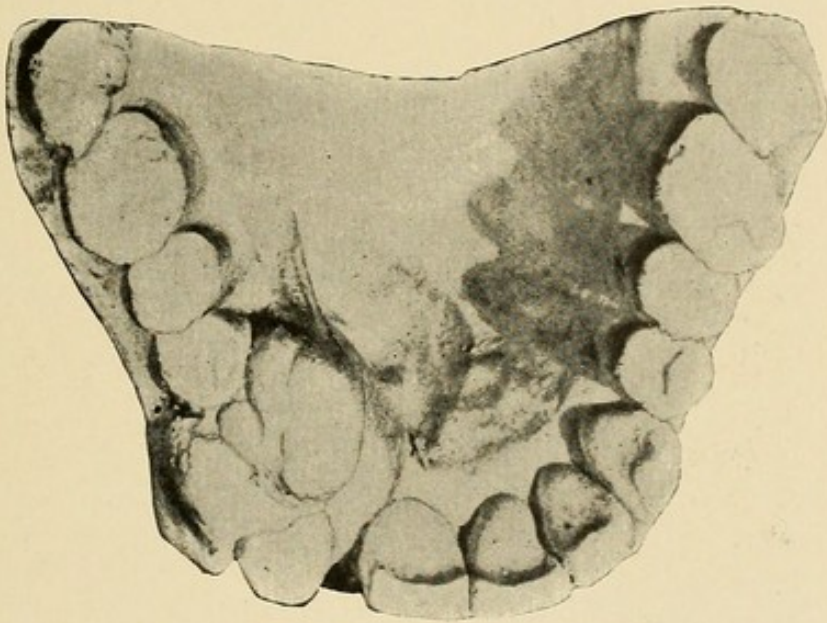


FIG. 86.—HYPERTROPHY OF GUM.

a darker red and, in cases that become infective and suppurative, reparative patches of a lighter hue will be found over the red surface.

The second class, or fibroid epulis, is most common upon the mandible. Fibromata are benign connective tissue growths, consisting chiefly of fibers with cells, which become more numerous in proportion to the rapidity with which the tumor grows. The growth is usually exceedingly slow. They are destructive only in so far as they are capable of producing mechanical injury by pressure. In some cases they will recur after removal, and in these instances they resemble sarcoma.



Hard fibroma is a dense, tendon-like formation, having only a few cells and flat fibers. It is often encapsulated. It is seen in the periosteum particularly of the dental alveoli.

Soft fibroma is of a soft consistency and of a loose texture. It is seen as a non-capsulated tumor of the skin, also as a polypus of the nose. During the early stage it resembles the myeloid type, but soon assumes a plum or

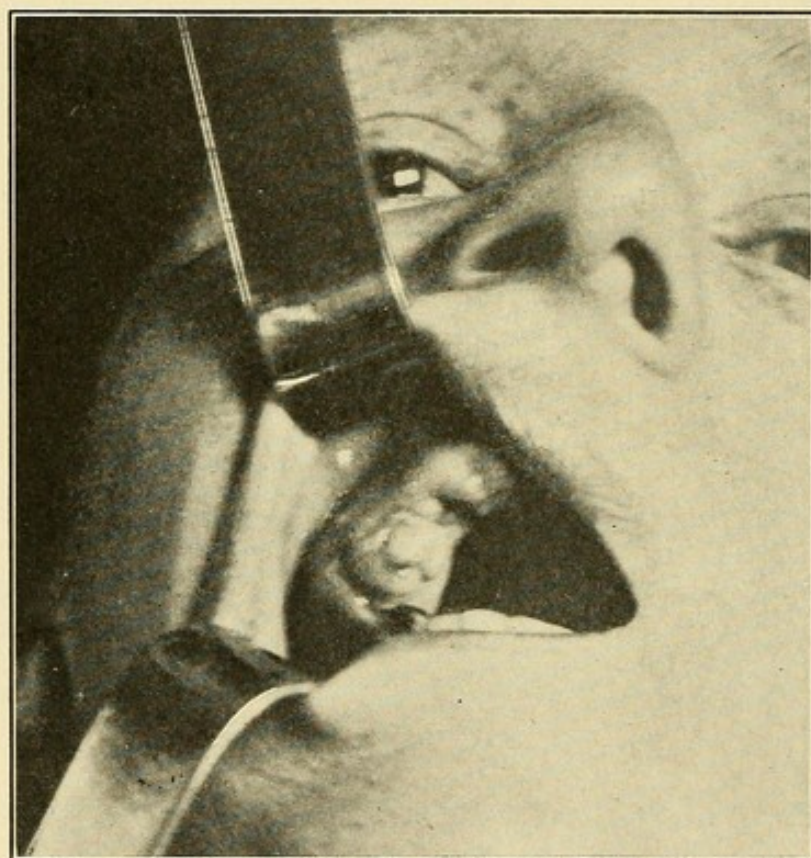


FIG. 87.—HYPERTROPHY OF GUM.

a maroon color. There is a tendency to grow from the buccal surface. There is also a tendency to develop in concentric forms, as may be seen in figure 89.

Hutchinson made a microscopic study of a case of myeloid epulis, typical of myeloid sarcoma, with giant cells. Nodules of bone were observed in the slide. It had been said that these tumors did not ossify, but he found the reverse to be the case. The plum color of the tumor was very characteristic. A case of epithelial epulis in a woman



aged fifty-eight, and successfully treated by partial excision of the maxilla, is reported by Malloch.

Diagnosis must be made from simple acute inflammatory diseases that run an acute course, from polypi that have smooth surfaces, from cysts, hypertrophies, exostoses of the process, and malignant diseases of the bones. The myeloid variety, as a rule, has a warty appearance and

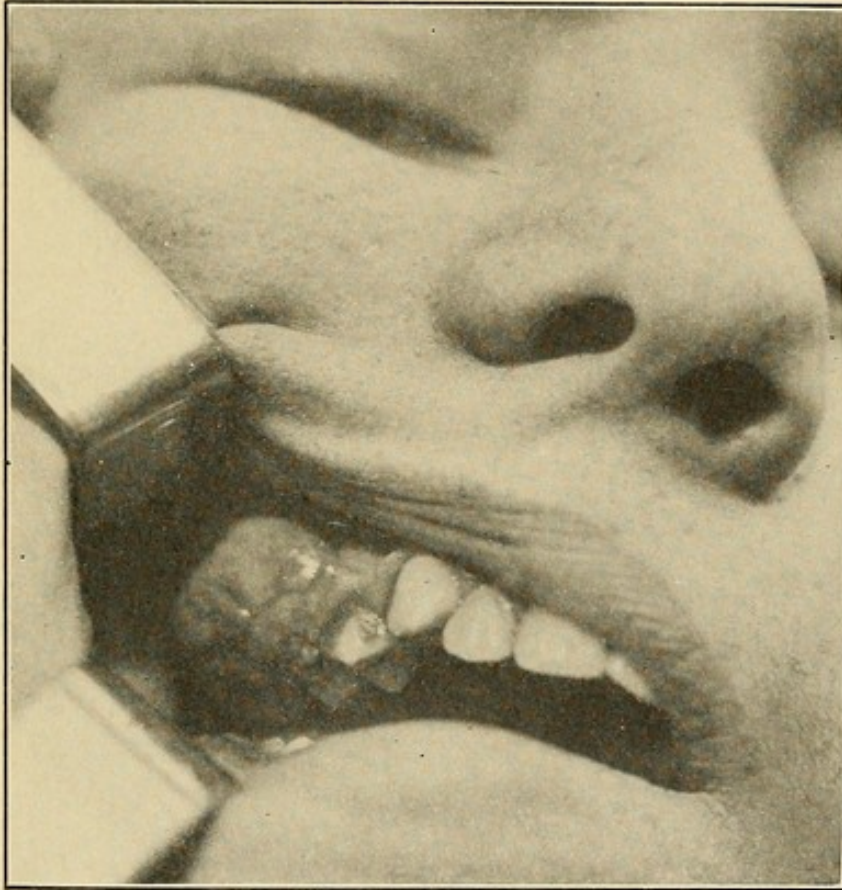


FIG. 88.—MYELOID EPULIS.

grows outward in every direction from the process, carrying along with it a tooth, or many teeth if unmolested. The teeth rest insecurely in a jelly-like mass and may easily be extracted. The surface, when irritated, bleeds readily and sometimes alarmingly. In a recent case in the author's practice, a small portion was removed for microscopic examination, and the hemorrhage was so profuse as to require constant pressure for half an hour to control it.

The *treatment* consists in early and effectual removal.



The teeth must not be considered, as the growth usually includes the process down to the roots, as well as the periosteum and mucous membrane. The accompanying cases will furnish typical examples, as well as outline the treatment, with results.

Treatment for the fibroid variety consists in removal, without destroying the bone to any considerable extent. Repair follows and there is no tendency to return.

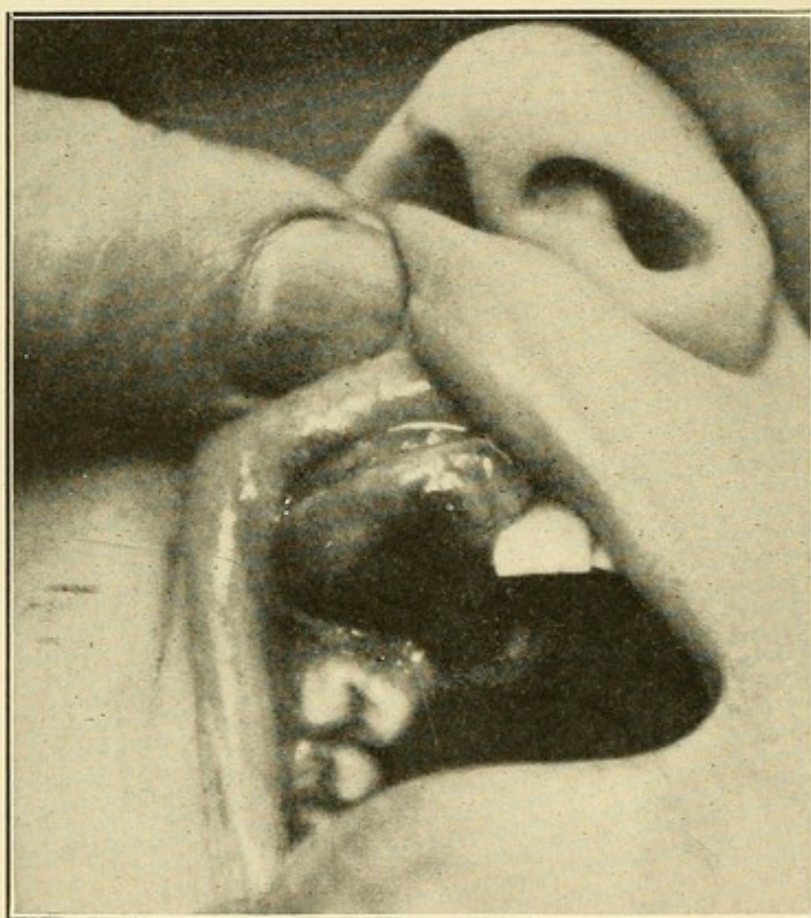


FIG. 89.—FIBROID EPULIS BEFORE OPERATION.

**Typical Case of Fibroid Epulis.**—In the case illustrated in figures 89 and 90 the growth had a maroon color. A tooth appeared to be the irritant, or the teeth that were included in the growth were thought to be the cause and were removed by a dentist. The growth as shown developed in three months. It was principally from the buccal surface and had a concentric tendency. It was soft and spongy and only slightly roughened.



Operation consisted in the removal of the growth down to and including the external half of the process. One

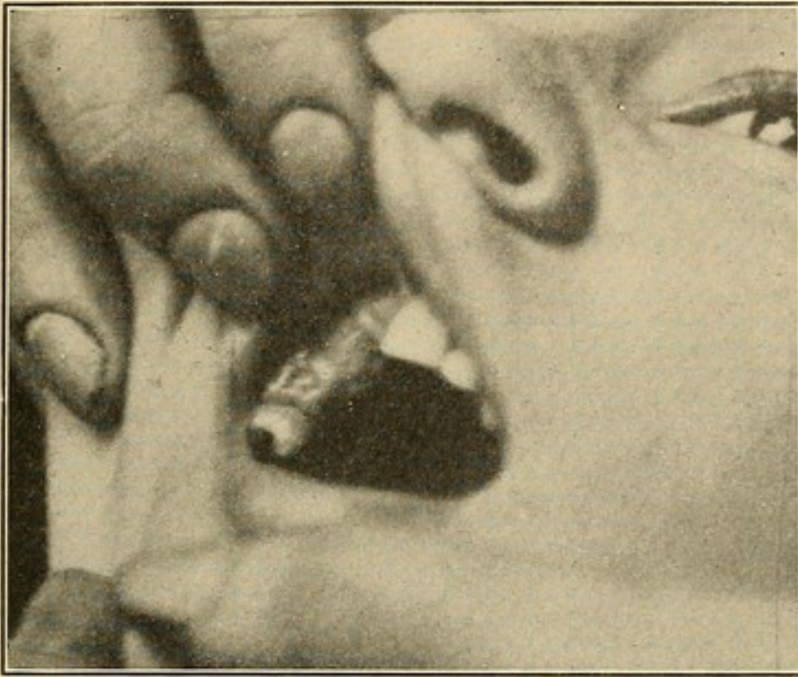


FIG. 90.—FIBROID EPULIS AFTER OPERATION.

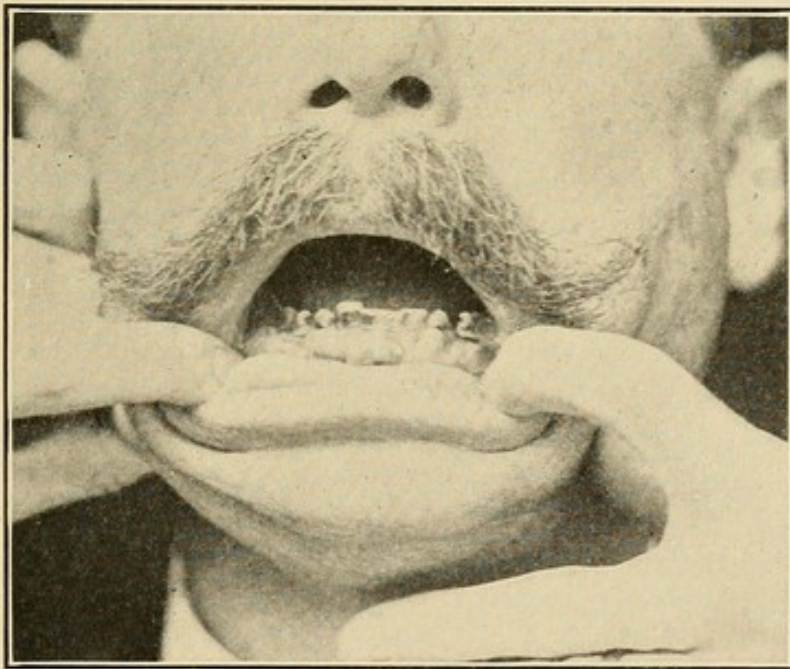


FIG. 91.—CHLOROMA, LOWER JAW.

tooth back of the tumor was included and required removal. Repair was prompt, the patient remaining in the hospital but three days. The result is shown in figure 90.



**Case of Chloroma.**—The hypertrophy began in the gingival mucous membrane throughout both maxillary bones, and extended from these points uniformly in every direction.

Photos were taken six months after the onset. The patient lived one year after this. There was no bone involvement. Very little local infection or abscess formation developed. The metastasis extended down the neck, the

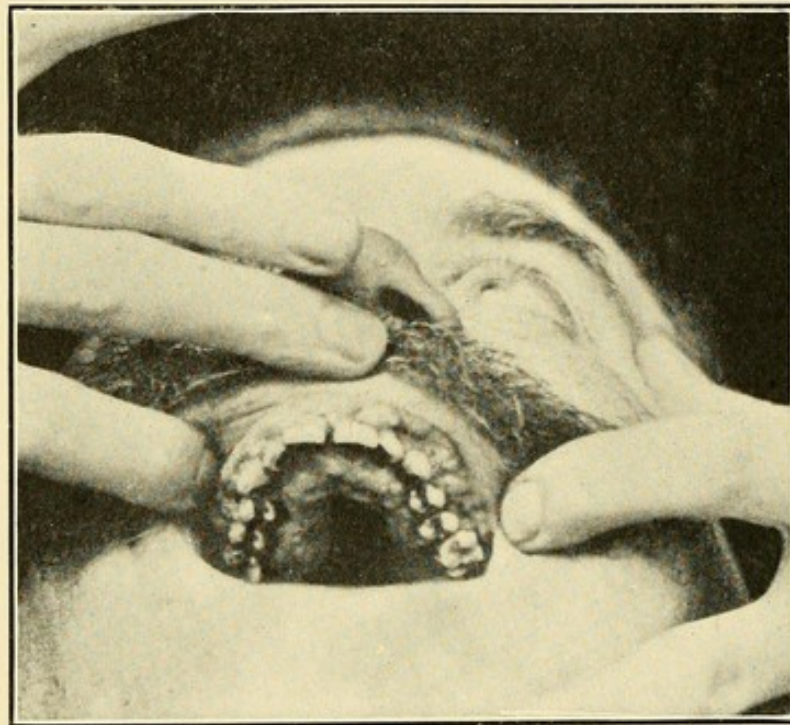


FIG. 92.—CHLOROMA, UPPER JAW.

glands being involved but the skin not being affected. The growth extended across the roof of the mouth, and the oral mucous membrane was universally hypertrophied, so that the patient could take only liquid foods for several months before death. X-ray treatment made no impression.

Microscopic examination did not show malignancy.

### BONE TUMORS AND CYSTS

These may be grouped in three classes: (a) Exostoses or osteophytes; (b) osteomata or hyperostoses; (c) cysts of bone.



## (a) EXOSTOSES

Exostoses or osteophytes are small, round, bony growths arising in the periosteum and spreading laterally as a result of inflammatory or traumatic disturbance of this membrane and its attachment to the bone. They are products of the periosteum, just as reproduced bone after necrosis. They are composed of branching trabeculæ or sheaves filled in with cellular connective tissue or spongy formation. They have no clinical significance, do not cause death, and should be removed only when making pressure on other structures or when their size demands an operation. Endosteomata are the same except that the growth is from the endosteum in the center of bone. They will not be considered here. Exostoses of the accessory sinuses of the face are not uncommon. In the anterior or frontal sinuses they grow to enormous size. The growth is outward. They require removal when their size produces deformity. They are benign.

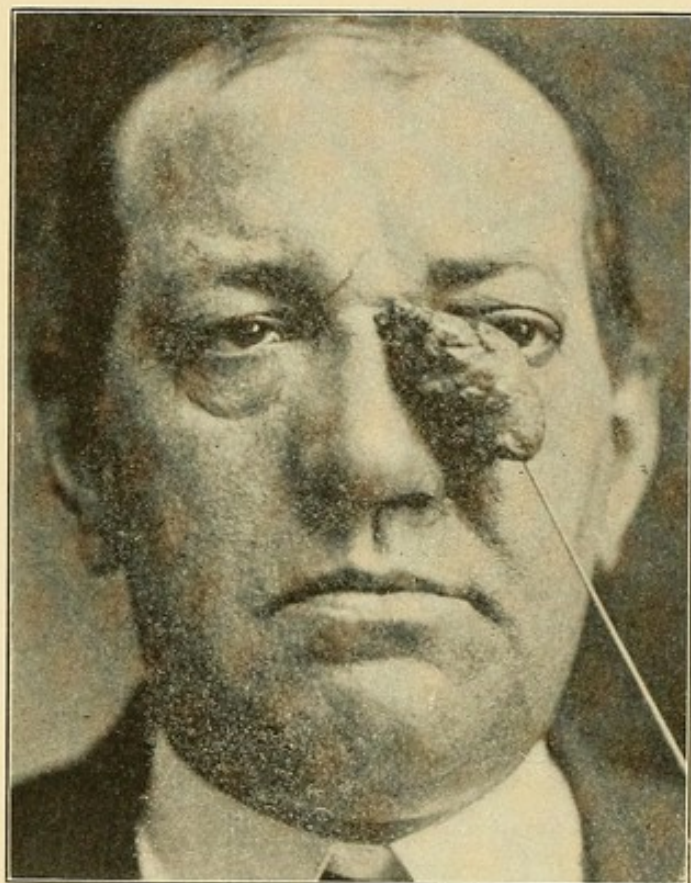
## (b) OSTEOMA

Osteoma or hyperostosis is a new formation of bone or a growth including the bone in general and not circumscribed as in exostosis. The entire bone structure is involved. The growth, while occasionally circumscribed, is usually diffused, including a hyperplastic change of the cancellous and compact structure uniformly. It may be found anywhere in the skeleton. A form is seen in the alveolar process, where it is usually diffused and the entire process is involved, but occasionally it is localized. An assignable cause (i. e., a specified irritant) is not always obtainable. Leontiasis ossea is a typical disease of this variety.

The accompanying illustration shows the case of a man aged forty-nine years, who had an osteoma. At the time of operation it had encroached upon the antrum, obstructed both nasal cavities, and had pressed upon the orbital floor



so as to force the eyeball practically out of the orbital cavity, throwing it entirely out of line so as to destroy the bifocal vision. The nasal duct was obstructed on the right side, and there was an abscess over the top of the tumor, extending up to the frontal bone. Operation consisted in



**FIG. 93.—OSTEOMA OF MAXILLA.** Osteoma shown returned after two years, growth extending laterally, occluding nasal cavities. In consultation with Dr. M. Delmar Ritchie, lateral incision exposed bone filling up entire nasal cavities, encroaching upon orbits, floor of mouth and antra, and apparently continuous with maxillary bones, so as to prevent removal. Hole was made through center of bone into pharynx, cutting through about two inches of solid bone.

making an incision over the top of the abscess, which was evacuated, and a week later, under general anesthetic, incision was made from above downward, parallel with the right side of the nose, down to the bone. The periosteum and all the soft tissues were then lifted from the tumor to its posterior side. The bone was chiseled away from the septum and from the maxilla. The growth had extended back slightly beyond where it was removed by the chisel, and this portion was removed by bone-cutting forceps. The accompanying X-

ray (figure 94) shows distinctly the extent of the tumor, with part of the shadow extending beyond the facial line made by the bone. The faint shadow shows the porous condition of the growth. As a rule, these tumors are very hard, but this growth was not so.



## (c) CYST OF BONE

This is a tumor beginning as a small enlargement of the alveolus, usually upon the external surface. As a rule, there is no pain or other inflammatory symptom. The growth is gradual, extending over a period of many months

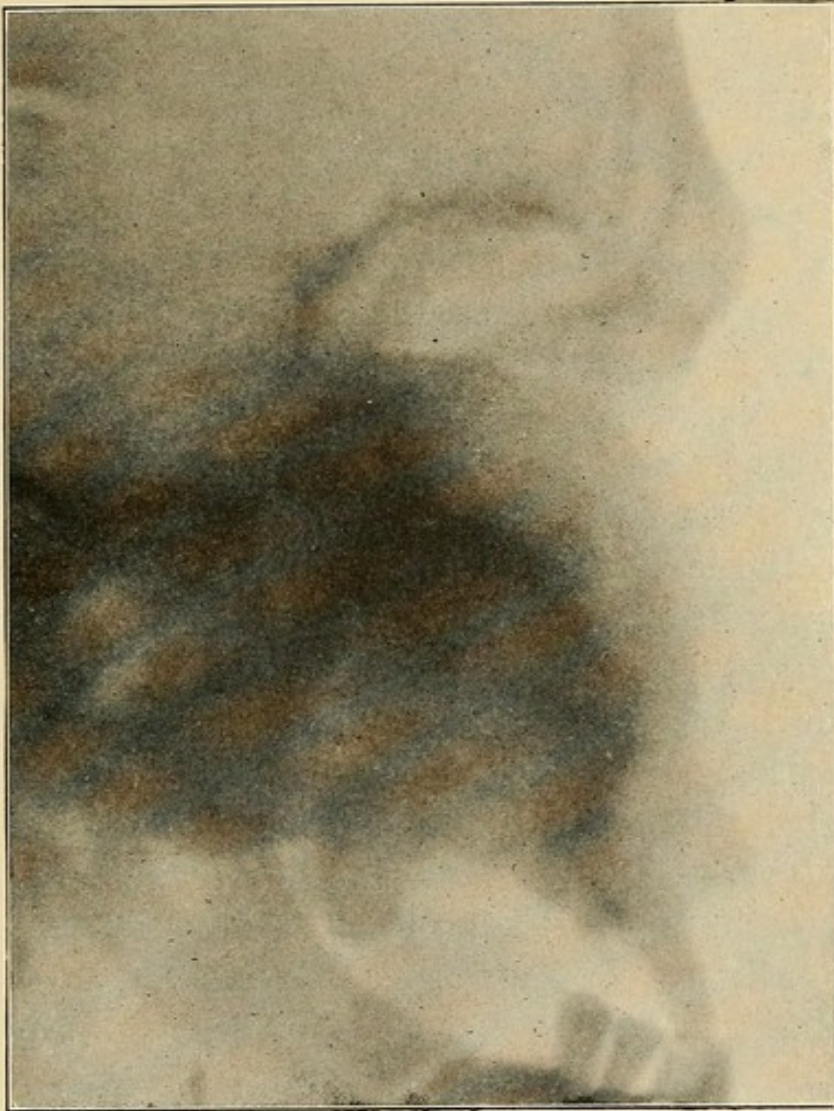

FIG. 94.—X-RAY OF OSTEOMA IN FIG. 93.

or years. The tumor is uniform, its margins well defined. The mucous membrane over the surface is normal, as a rule, and only becomes red if infection and pus formation occur. The tumor may develop years after teeth have been removed and run the same course as other bone cysts.

The bone gradually melts away and the space is occupied



by a fluid formation. The bone around the margin is usually elevated, due to the tendency of the periosteum that is left after the bone destruction to reproduce bone. The elevated margin recedes, however, as the cyst encroaches upon new bone. The external margin is denuded in the direction of the extension only, the remaining wall being well-defined and composed of well-organized granulation tissues.

Operation requires free incision, removal of denuded bone and curettement of such portion of the cyst wall as appears incapable of repair. The cavity should be cleansed with pure alcohol, and only moderately packed, to control hemorrhage; subsequent packing should be to prevent the entrance of food only. The walls should be permitted to collapse so that the cavity may be obliterated as early as possible. The orifice should be kept open with packing until the deeper portion of the cavity has healed. Repair without complication or return may usually be expected.

An unusual tumor developed in the roof of the mouth in a woman aged thirty years. It first appeared about the center of the median line. It had been growing about two years when she asked for an operation. At that time the left nasal cavity and all but the upper part of the right were obstructed. The tumor projected downward, flush with the teeth, and filled the vault of the mouth. The content was callous. Operation was done through the roof of the mouth. The bone was denuded at several points.



## CHAPTER XXV

### MALIGNANT TUMORS OF THE MOUTH

#### SARCOMA IN GENERAL

Sarcoma is a malignant growth which has its origin from the mesoblast and is composed of embryonic tissue. It develops in all deep tissues, the cells being deposited within the normal structures, finally displacing and destroying them. Its name is derived from its gross resemblance to flesh, but, since a microscopic study has been made, the following distinct varieties are recognized:

(a) **Round-celled Sarcoma.**—This variety is composed of small cells, with a little intercellular substance, growing very rapidly. The smaller the cell, the more rapid the growth. Round-celled sarcomata rapidly involve other tissues, and when enucleated quickly recur. They develop at all ages.

(b) **Spindle-celled Sarcoma.**—Spindle-celled sarcomata resemble the round-celled variety in clinical history in that the large size of the cell retards the rapidity of the growth. The cells are spindle-shaped. In these, as in the round-celled, the fleshy material is found between the cells. The cells are occasionally so intimately interwoven as to give rise to the belief that they contain voluntary muscular fibers, but this is not correct. When the growth is slow, the cells may take on a fibrous change, when they are known as fibro-sarcoma.

(c) **Giant-celled Sarcoma.**—This is sometimes known as myelo-sarcoma. It has as a characteristic large, round or



spindle-shaped cells containing many nuclei. The cells are imbedded in a tissue resembling red bone marrow. (Mixed-cell sarcoma means a combination of any two or all three of the above variety of cells.)

(d) **Melano Sarcoma.**—Melano sarcoma is so named because the tumor is stained by brownish or black pigment. It is very malignant, and, when glands (its most common location) affected by it are removed, it invariably returns and proceeds to a fatal termination.

(e) **Alveolar Sarcoma.**—Alveolar sarcoma is so named because the cells assume the arrangement seen in carcinoma. Microscopic examination shows that the cells are separated by a substance similar to that found in other varieties of sarcoma. It is thought that these cells have their origin from the endothelial cells.

The terms *osteosarcoma* (bone) and *gliosarcoma* (nerve) merely locate the growths, and do not mean that they differ histologically from the original varieties.

**Location.**—Sarcoma develops in every tissue of the body, bone, glands, skin and viscera. It makes its appearance at all ages, but most frequently between the ages of fifteen and twenty-five years. In the skin, especially of the face, it develops from birth-marks (nevus), and several may appear at the same time or in succession. The growth begins as a nodule and is very slow in its course, eventually breaking down in an ulcer, progressing by ulceration and metastatic involvement of deeper structures until it terminates fatally.

The bones of the face are a common location of the trouble. It may begin in what is known as malignant epulis, or it may develop from the center of the bone, involving it in its entirety. It has a tendency to calcification. Sutton states that sarcoma may develop from a tooth follicle. The cells of sarcoma of the bone are always round or spindle-shaped. This form of sarcoma concerns the dentist most, since, in its incipency, as it develops from the periosteum



of the alveolar process, it may be mistaken for simple tuberculosis or syphilitic periostitis, or the warty appearance which it assumes later may be mistaken for the simple granulation tissue found during repair from extraction, or pyorrhea and other inflammatory conditions of the gums.

Unless it is a result of trauma, its origin is not known. Park says that it is quite a common sequela of delayed bone union, developing from the ends of the bones.

**Symptoms.**—Pain is most constant and as the disease advances becomes unendurable, except under an anodyne. Fever, running a low continuous course, is usual, but seldom goes high, and may be entirely absent during the early course. Emaciation is rapid. Untreated, the disease progresses to suppuration and ulceration.

**Diagnosis** is to be made from syphilis, tuberculosis and benign growths. If the growth is ulcerative a microscopic examination should be made to confirm a suspicion of malignancy. If located where an exploratory incision can be made to secure a section, this should be done, since it is highly important that sarcoma, if removed at all, should be removed early. Tuberculous enlargements may require operation, while syphilitic gumma should never be cut.

**Prognosis** depends upon the date at which the growth is removed. If quite early, return may not occur. In rapidly growing tumors, when enucleation of the primary focus has been effective, it is quite common for a secondary deposit to develop in the brain, lungs or other viscera, destroying life in a few months. So, if an operation is to be preferred, it must be made early or not at all.

**Treatment** consists in total and thorough extirpation. When a bone is diseased it should be entirely removed, especially if the growth is rapid. In one case, while the bone was not entirely removed, no return occurred until five years afterward, and then did not develop in the bone, but in the glands and soft tissues. This does not argue against extirpation, for in this case operation was primarily



done to remove an offensive ulceration from the mouth, and not with the hope of eradicating the disease.

In sarcoma of the bones of the extremities, amputation should be made at the proximal joint. In sarcoma of the glands, the glands should be removed to the deepest point. In skin sarcoma, the skin, tumor and cellular tissue beneath, along with the adjacent lymphatics, should be included in the mass removed.

### SARCOMA OF THE MOUTH

Sarcoma presents the most formidable and rapidly growing of all tumors involving the alveolar process. Recent investigations show that sarcoma is the result of trauma, such as injuries from extractions, contusions or blows. Apparently simple conditions about the teeth requiring operation may be followed by sarcoma. The growth is uniform, the course rapid, the tumor in a few weeks becoming many times the size of the bone itself. When involving the mandible, it rapidly involves the skin, which breaks down, and as mixed infection occurs the discharge becomes profuse and offensive. Further skin and soft tissue are involved. The glands toward the clavicle are enlarged and become suppurative during later stages.

**Symptoms.**—It usually occurs in young manhood from fifteen to twenty-five years. The growth is rapid and painful. Temperature from 99 to 101 degrees is usually found before suppuration, and it may increase after systemic toxemia from absorption following suppuration.

**Diagnosis.**—During the stages of sequestration sarcoma must be differentiated from the various forms of bone infection. The bone may be cast off, resembling periostitis. Syphilitic gummata resemble sarcomata very much, except that the latter develop rapidly and in young manhood, and syphilis occurs at all ages. Exostosis and osteoma are not usually confounded with sarcoma, since they are character-



ized by a uniform, painless enlargement without suppuration. Carcinoma must also be excluded. It occurs in middle life, and the growth is slow.

**Treatment.**—Early diagnosis and removal is vital. When operation is not done early, sarcoma is best controlled with judiciously administered X-ray treatment, followed by the removal of the tumor as soon as the rays have controlled the growth. Several operations may be required during the time the rays are being used. Many cases are cured in this way and all are greatly benefited.

**Illustrative Case.**—The case illustrated in figure 95 presented the usual symptoms of necrosis following alveolar periostitis extending over a period of several months. No signs of growth were present. The sequestrum was removed, and a favorable prognosis was made. The patient left the hospital in one week. Four weeks later she returned with an unmistakable sarcoma. Four weeks after this, the

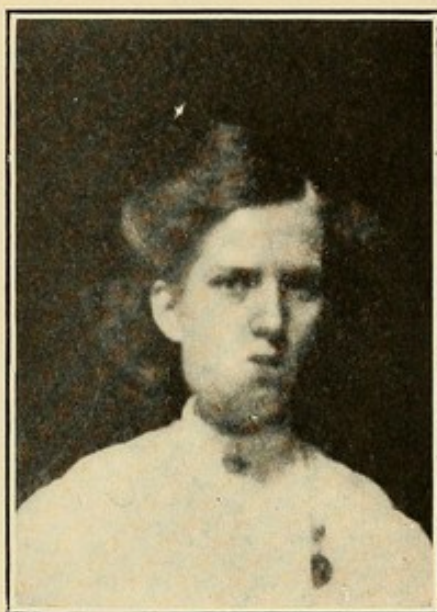


FIG. 95.—SARCOMA OF MANDIBLE.

growth seen in the figure had developed. It was inoperable, since complete enucleation could not be promised. The growth remained latent during two months' serum treatment, when the patient withdrew. At the end of another month it began to grow and she died in four months.

## CARCINOMA IN GENERAL

Carcinoma or "hard cancer" belongs to the epithelial group of tumors. Certain forms develop most frequently about the face and mouth, and their clinical significance should be well understood by the dentist.



Carcinoma is composed of epithelial cells arranged in concentric layers and contained in an alveolus formed by a fibrous stroma, with a tendency to invade surrounding tissues. In different localities they have the characteristics of the epithelial cells from which they have their origin. In these growths the tendency is to harden even during the early course of development. There is a marked tendency

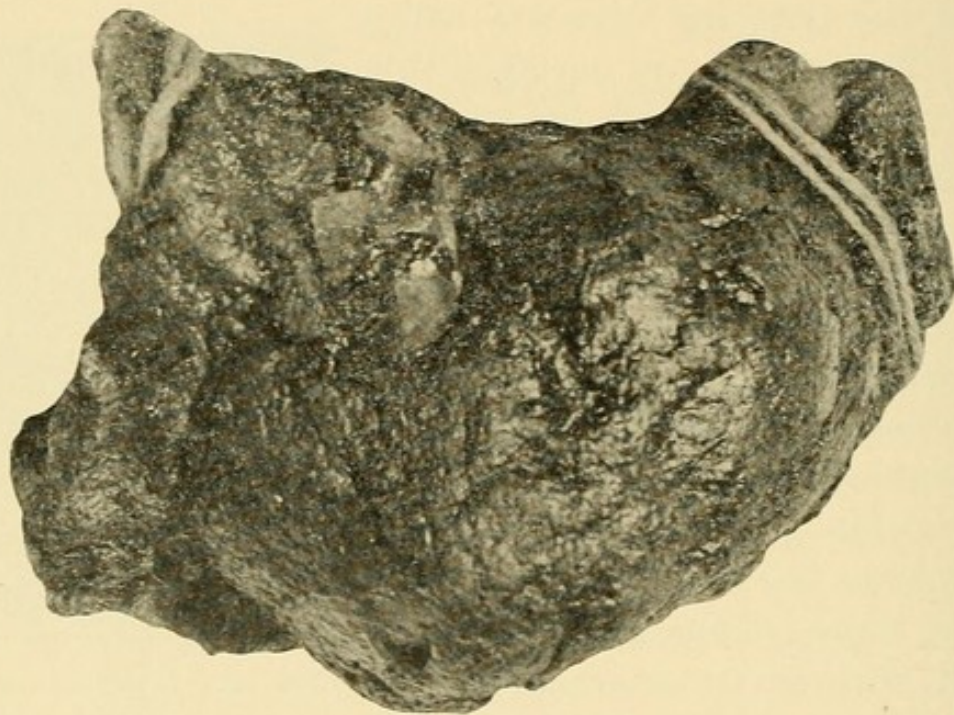


FIG. 96.—SARCOMA OF MAXILLA.

for the proliferating cells to penetrate the basement membrane and the cellular tissue about. When subdermal tissue is involved, the corium is included in the growth. When the tumor is defined, the skin or tissue in which it is located becomes quite hard as a result of inanition; ulceration follows, upon which a crust forms, which is shed and reformed, usually increased in area because of the extension. There is no inflammatory infiltration, and the disease is quite well outlined. The cells are held together by a cement material, there being no intercellular substance, such as is found in sarcoma. There is no blood supply to the central portion, and for this reason this portion undergoes either



colloid, fatty or myxomatous degeneration or ulceration. There is a tendency to inflammatory changes as a result of mixed infection.

Metastatic involvement of the surrounding tissues through the lymphatics and veins is usual, and eventually along these channels will be found small tumors which may extend in the form of a chain of nodes into the cavities of the body. There are three varieties:

- (a) Epithelioma.
- (b) Tubular carcinoma.
- (c) Acinous carcinoma.

(a) **Epithelioma.**—Epitheliomata comprise two-fifths of all malignant growths. In 13,824 cases of primary neoplasms reported by Williams, 7,297 were malignant, 352, or 4.5 per cent., were of the lips, and 340 of the lower lip. About the same per cent. are found on the tongue. About 75 per cent. of epitheliomata develop from the face and lips. The development begins in congenital defects, such as nevi, in warts and scars, and these forms are very malignant. They develop quite frequently on the face in the mandible and maxilla, and in other bones of the face. They attack the mammary glands, larynx, esophagus, stomach, and, in fact, every part of the body where flat epithelium is found.

*Lupus exedens.*—Rodent ulcer, or Jacob's ulcer, is an epithelioma of the face, formerly not included in the cancer group, but thought to be a local ulcer. It begins as a nodular condition of the skin, well supplied with vessels, eventually breaking down into an irregular, deeply scooped-out ulcer, without elevation of the margin. It develops slowly, requiring from one to twenty years to terminate fatally. There is little tendency to metastasis. There are few or no local symptoms and no constitutional disturbance until quite late in the course of the destruction.

*Treatment* for skin epithelioma is eradication by some method. Many dermatologists use Bougard's paste. Excision must be made sufficiently far back from the margin



of the ulcer to insure complete removal, and down deep enough to include the infiltrated tissue constituting the base of the ulcer. The gap thus left must be closed by transferring skin from adjacent parts. On the face, especially, the skin is quite adjustable, and plastic operation is capable of bridging over a considerable extent of surface.

(b) **Tubular Carcinoma.**—Tubular carcinoma is that variety which grows from mucous surfaces containing tubu-

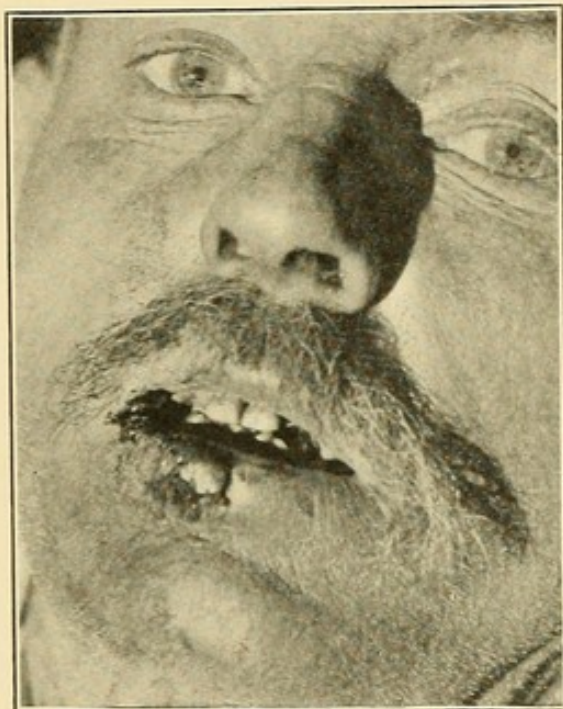


FIG. 97.—EPITHELIOMA OF LIP BEFORE X-RAY. (Geo. C. Johnston.)

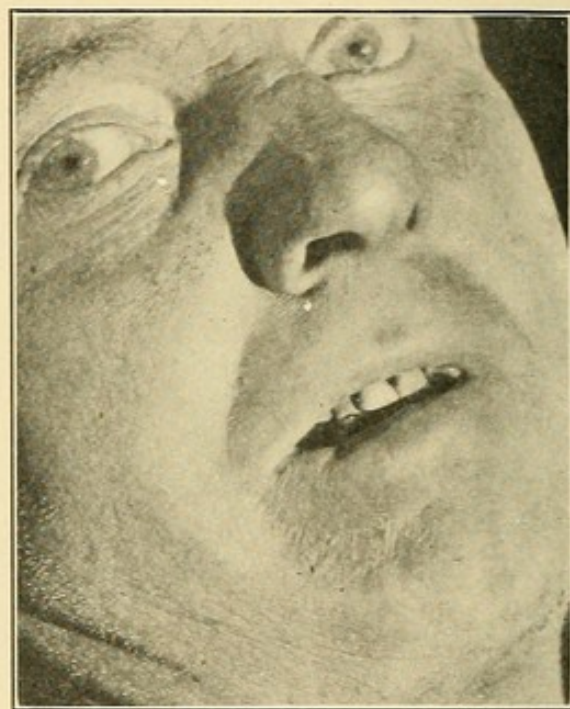


FIG. 98.—EPITHELIOMA OF LIP AFTER X-RAY.

lar glands. The alimentary canal below the pavement epithelium of the larynx is the principal territory in which it is seen. It may develop in the sebaceous glands of the skin. It has its origin in the columnar epithelium lining the ducts leading from the glands. Owing to its location, it is of little significance to the dentist.

(c) **Acinous Carcinoma.**—Acinous carcinoma develops in such glands as the salivary, thyroid, pancreas, and mammary, and in the ovaries, testicles and prostate. This variety grows quite slowly, requiring from five to twelve years to terminate fatally. There is little tendency to ul-



ceration. Acinous carcinoma develops late in life, rarely being seen under forty years of age. The most common form is known as scirrhus or hard cancer, usually in the pyloric end of the stomach, in the breast, or in the lower alimentary canal.

*Encephaloid carcinoma* grows rapidly, with early tendency to ulceration.

**Treatment.**—The treatment of all forms of carcinoma is complete and early enucleation before infiltration into the deeper structures of the body occurs, or all operation is useless. Even in the tongue, stomach, and intestines early operation effectually removes the disease and return may never occur.

## EPITHELIOMA OF THE MOUTH

Epitheliomata of the tissues overlying the maxilla and mandible develop as a result of some chronic irritant. Bad teeth are most frequent causes. A rough tooth constantly coming in contact with adjacent mucous membrane, or excessive tartar and spiculæ of bone in neglected mouths are fruitful causes. Papillomata, epulitic or other fibromata, when cauterized frequently for their removal, a proceeding too often practiced by dentists, may result in malignancy. Cases of this character are reported.

**Symptoms.**—The growth is slow and not painful until it reaches considerable size. It is found in middle or advanced life. It involves neighboring lymphatics. The tumor, as it is found in the mouth, is irregular and warty, the normal mucous membrane entirely disappearing. Further extension includes the skin. Suppuration, as a result of mixed infection, with the usual constitutional symptoms, must follow. It then becomes very painful.

**Diagnosis.**—Diagnosis must be made from sarcoma, gumma, periostitis, osteomyelitis, actinomycosis and other simple mouth tumors and ulcers. Sarcoma involves the



entire bone, but the tendency is to enlarge outward. In carcinoma the growth extends under the tongue and in every direction uniformly.

**Prognosis.**—Prognosis points toward a fatal end unless extirpation is done early and effectually.

**Treatment.**—Treatment is enucleation followed with Röntgen rays for several months to destroy the cells in the

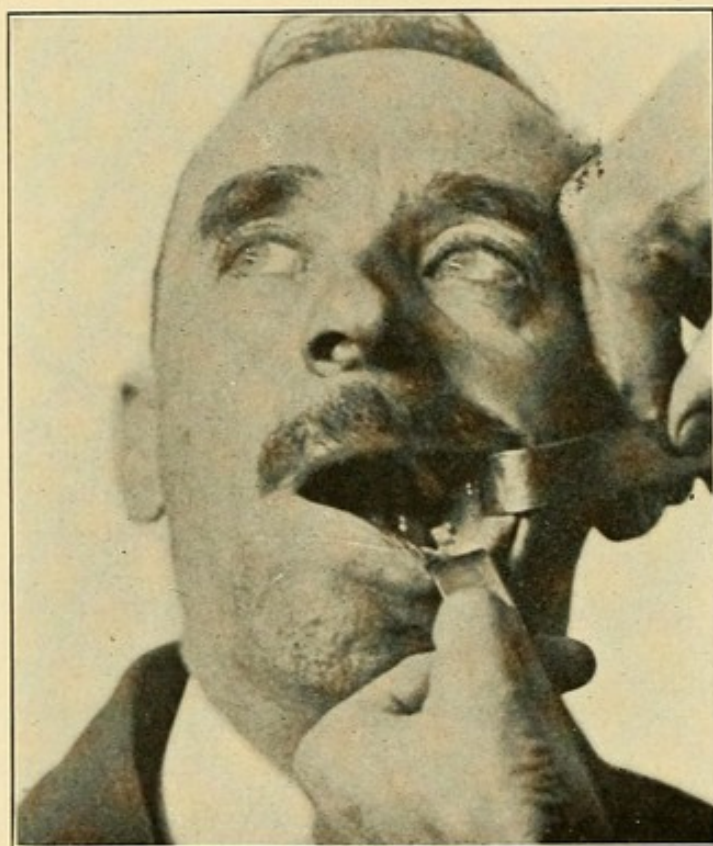


FIG. 99.—EPITHELIOMA OF CHEEK.

deep structures, if any remain, and to prevent return in scar tissue.

**Report of Case.**—A warty growth was found upon the left side of the mouth, crowding the tongue in and the cheek out, and extending from the ramus to the symphysis of the inferior maxillary. The growth included the upper half of the bone. The fact that a previous curettement of the growth had been made about a year before was conclusive evidence of the malignancy of the growth. The cause, as stated by the patient, was an injection of anesthetic



about two years previously, given by a dentist before the extraction of a tooth. It was decided to remove the entire left half of the inferior maxillary and substitute an aluminum bridge in place of bone. Measurements were made on the well side, and two sizes of bridge were made, so as to be prepared for emergency.

*Operation.*—A cut was made with a scissors from the upper edge of the lower lip down to the symphysis, and an-

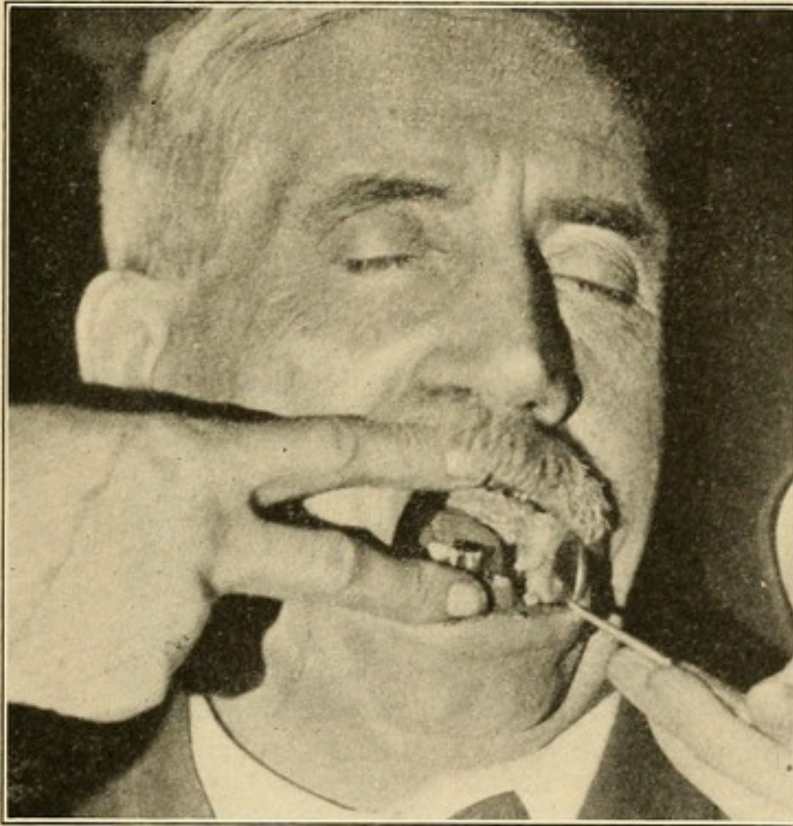


FIG. 100.—EPITHELIOMA OF MOUTH.

other free incision made from the lower end of this cut along the inferior margin of the jaw, back almost to the facial artery. This flap was dissected from the tumor and turned back. Two cuts were next made through the bone, one at the symphysis, and the other at the groove for the facial artery. The bone thus severed was easily removed. All evidence of infiltration of the tumor was dissected out.

The larger bridge which had been made fitted perfectly, except that the ends were not bent at quite the correct angle to rest evenly against the ends of the bone. Two



holes had been made in both ends of the bridge. Corresponding holes were made through the bone, the drill entering from the external surface and passing out through the bone (figure 103). A strong silver wire was passed through these holes and through those in the aluminum bridge. The ends of the wire were twisted until the bridge rested snugly




FIG. 101.—EPITHELIOMA OF ALVEOLUS. An effective treatment in cases such as this is the use of an electric or actual cautery, when the disease has advanced beyond the point of radical operation. This is the usual practice in cases of epithelioma of the os uteri. The practice is to burn off the warty growths as they appear at various points from time to time. This prevents further growth, and prolongs the life of the patient many years, unless metastasis develops, when further use of the cautery is not advisable.

against the bone. The same procedure was carried out at the other end. The twisted ends of wire were cut off quite short and bent down along the internal surface of the bridge. The sublingual and buccal mucous membranes were stitched together over the bridge and the skin wound closed from the angle of the jaw to the edge of the lip. The wound healed by primary union, and no complication presented itself. The patient left the hospital on the



fourteenth day, practically well. He had little pain during the course of repair. He could open his teeth one and one-eighth inches, and could close them with enough force for the snap to be heard across the room. During the time




FIG. 102.—CARCINOMA OF MANDIBLE.

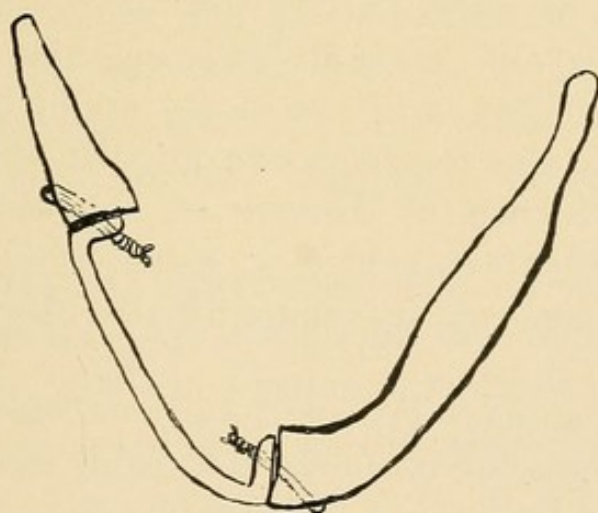


FIG. 103.—ALUMINUM BRIDGEWORK AS SUBSTITUTE.

from the original operation to the return of the disease (five years) he had very fair use of his jaw, and was able to masticate his food, and even chew tobacco, so firm was the fibrous tissue and bony deposit between the ends of the bone. The aluminum bridge became loose at the end of three months and was removed.



## CHAPTER XXVI

### CYSTS AND TUMEFACTIONS FROM DEVELOPED TEETH

The subject of cysts and tumefactions from developed teeth includes: (a) Impacted teeth; (b) delayed eruption; (c) cysts from the roots of developed teeth.

### IMPACTION OF TEETH

Occasionally teeth fail to erupt. The process of budding may be in the wrong direction, and the tooth grows upward or to one side, or some obstruction may interfere with the normal eruption, and instead of the crown's pushing its way through the alveolus it grows in the opposite direction.

Discharging sinuses from the maxilla or mandible are not always evidence of disease of the antrum or other sinuses, nor of osteomyelitis or tuberculous bone disease. These sinuses are not infrequently the result of impacted teeth.

Indeed, all sinuses giving a very chronic history associated with slight, or possibly no, pain, extending over a period of years, are more likely to be caused by non-eruption than by destructive bone diseases.

In mouths where all of the teeth have been extracted and a plate worn, if a tooth remains impacted, the pressure of the plate will usually result in absorption of the mucous membrane and the tooth will present itself by the formation of an opening.

**Illustrative Cases.**—The following cases are typical:



(1) Mrs. A. T., aged forty-nine years, had suffered with pain in the right maxilla, just external to the ala, for nineteen years. There had been no discharge for sixteen years, when a small opening which discharged small quantities of pus and serum was discovered, internal to the second incisor. This had remained open for three years; occasionally it would close and be followed by pain, which continued until spontaneous eruption relieved the suffering (figure 104).

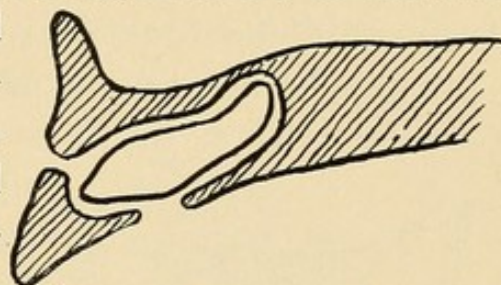


FIG. 104.—IMPACTED CENTRAL.

An effort to determine whether it was a case of necrosis or impaction resulted in a decision of the latter for the following reasons:

(1) In necrosis a greater amount of tissue would have been involved.

(2) The character of discharge would have been pus at all times, usually of an offensive odor.

(3) The patient was uncertain as to the eruption or extraction of the second incisor.

(4) In osteomyelitis or tuberculous bone disease a sinus would have formed long before it appeared in this case.

(5) Associated symptoms, such as swelling, involvement of secondary structures, as the antrum, would have resulted, none of which were ever present.

(6) The general health of the patient would have been impaired.

An operation under general anesthesia consisted in enlarging the opening in the mucous membrane along the line of the alveolus. As the sinus in the bone was slightly back of the alveolus, the bone was cut inward with a chisel. After enlarging the opening sufficiently to admit a pair of bone forceps, they were entered with some difficulty, and a tooth was dislodged from its abnormal location. The depth



of the cavity thus left after the removal of the tooth was two inches, as determined by actual measurement.

The subsequent history showed that no foreign substance had been allowed to remain, and the sinus was entirely closed in a week. It has remained so and has been free from pain for four years.

(2) Mrs. A., aged fifty-four years, had had her teeth extracted when thirty-five years old and had worn a full

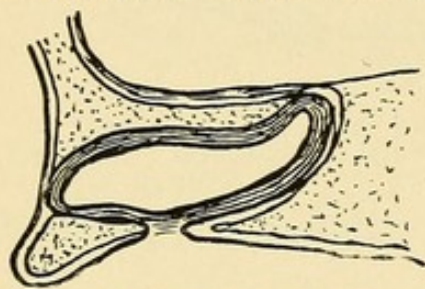


FIG. 105.—IMPACTED LATERAL.

upper vulcanite plate for fifteen years with perfect comfort. After wearing a new plate for several weeks, she returned to the dentist and accused him of making the suction cavity too large, dead bone resulting in the roof of her mouth. A careful examination revealed the existence of a tooth slightly to the center of the oral vault. There was a very small sinus; the orifice was not granular, as it would have been were dead bone present, and there was but slight discharge. A probe came in contact with a smooth hard substance characteristic of a tooth. An operation was advised and accepted. A perfectly developed canine was removed. The wound promptly repaired and a malpractice suit was averted.

(3) Another case was that of a woman aged twenty-four years, who had been wearing a full upper plate for about two years. A sinus was discovered in the roof of her mouth slightly to the left. A second sinus opened on the labial aspect of the alveolus. Upon introduction, a probe came in contact with a tooth. Under somnoform anesthetic, it was removed. Repair followed without complication, and so little change occurred that the plate used before the operation fitted perfectly afterward.

(4) Miss B., aged twenty, had been suffering pain in the region of the superior molars since her twelfth year. She knew that her twelfth-year molars had not erupted



and was of the opinion that they had something to do with her suffering. This appeared to be quite evident.

Operation was advised, and under chloroform an incision was made from the first molar backward along the crest of the alveolus. The incision was extended down to the bone. The soft tissues, including periosteum and mucous membrane, were dissected back from the alveolar ridge so as to permit freedom in further operation. The tooth was found partially covered with bone. This was chiseled away, and the tooth was pried from its position with a bone elevator. The crown of the tooth pointed directly forward and rested against the first molar (figure 106). The roots projected slightly downward, parallel with the long axis of the alveolus.

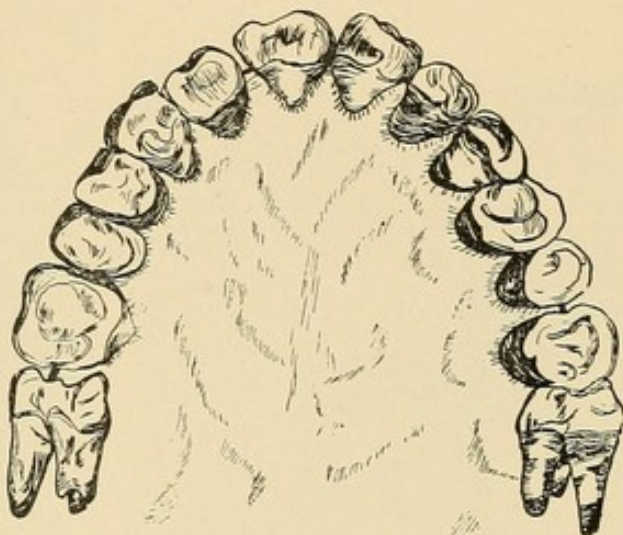


FIG. 106.—IMPACTIONED TEETH.

The operation on the other side was exactly the same, the tooth being found in the same position. The flaps were adjusted and secured with catgut sutures. Repair followed without complication.

The case is unusual because of the bilateral condition, the teeth being in the same position on each side.

(5) An interesting case of multiple malposition with cysts becoming suppurative is that of a young man of twenty years who had had discharging sinuses and tumefactions of the right maxilla for eight years. A sinus led into the right cuspid and another into the right upper molar, with other sinuses extending back of the maxillary bone on both sides, well into the zygomatic fossæ. The patient had had two operations, one in the antrum and another for



necrosis, but in neither instance were the impacted teeth found (figures 107 and 109).

Operation included the removal of the impacted teeth, with curettement, and repair followed in the course of a few weeks, with no further symptoms from the maxilla. The patient returned in three months with an enlargement over the lower left second bicuspid. This tooth had not

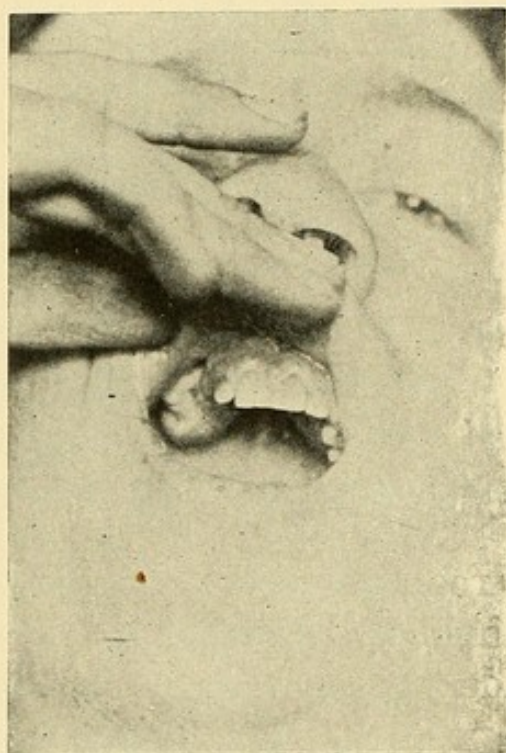


FIG. 107.

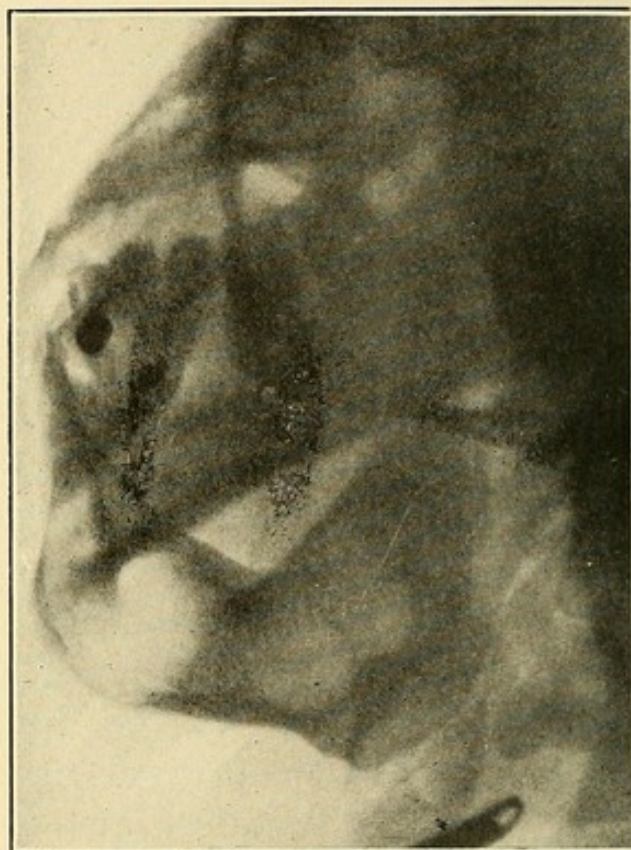


FIG. 108.

FIGS. 107, 108.—IMPACTION OF TEETH WITH ABSCESSES AND CYSTS. Illustrating case described in text.

erupted. An operation was performed and this tooth, imbedded in cystic material, fully developed, was removed after chiseling away sufficient of the external table.

The patient returned seven years later with tumefactions on the external surface of both angles of the mandible. These enlargements were the size of a silver quarter and at least half an inch outward from the bone. With the knowledge that neither one of the lower third molars had erupted, and with the experience that had been furnished



by the other teeth, diagnosis of cysts developing from the impactions was readily made out. Operation was performed, and the teeth were removed.

The cysts had become suppurative and offensive and required irrigation for about three weeks. The cavities,

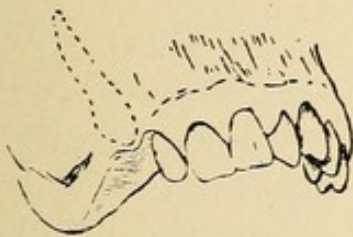


FIG. 109.

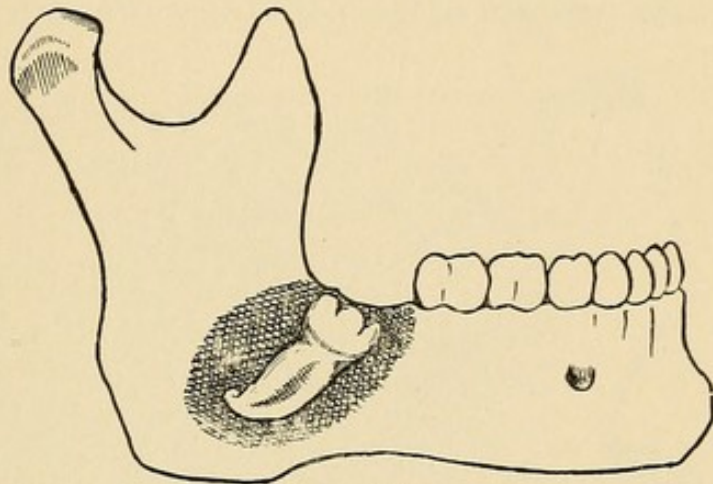


FIG. 110.

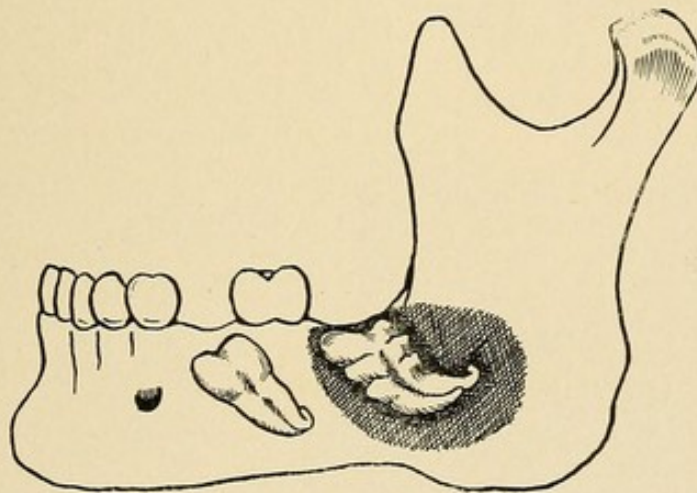


FIG. 111.

FIGS. 109, 110, 111.—IMPACTION OF TEETH WITH ABSCESSES AND CYSTS. Illustrating case described in text.

which were quite large, finally collapsed and were entirely obliterated.

(6) Figure 112 shows a skull in the collection of the author. The third molar is unerupted; the second bicuspid is clearly outlined as impacted. This clearly illustrates an average case and the impacted tooth would no doubt have required removal eventually.



(7) Figure 113 shows an impacted lower third molar of the usual type, which required removal. This case was associated with considerable pain and stiffness of the muscles of the jaw, which interfered with mastication.

(8) In the case illustrated in figure 114 the patient first presented herself for extensive periostitis of the mandible, in which the entire bone was bare on the left side, and

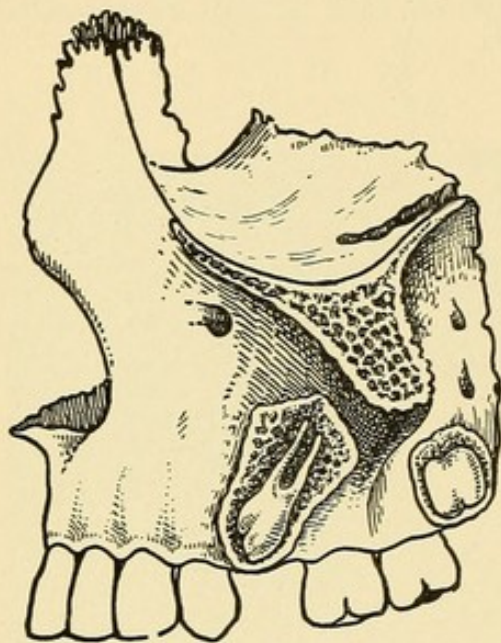


FIG. 112.—IMPACTED BICUSPID FOUND IN A SKULL. Also shows unerupted upper third molar.

which finally resulted in necrosis, as may be observed in the lower part of the figure. By careful study of the plate, four impacted teeth will be observed, two in the mandible, the lower third molars, and upper third molar, as well as the upper first bicuspid. All of these teeth had to be removed, as well as considerable of the lower part of the body of the mandible, before repair took place. Observe that there are several sequestra on

the lower border of the mandible. The patient recovered with perfect function of the jaw.

### CYSTS FROM DELAYED ERUPTION

The teeth do not always erupt at the usual time because of some obstruction at the point of usual exit or because of cystic or perverted development. In some instances the development is outward and an enlargement is formed, often so large as to attract the attention of the dentist, who, if he does not suspect the real condition, will send the patient to a surgeon. In this way an operation is too often performed.

The principal diagnostic point is the absence of the



tooth, when it should have erupted. While there is some discomfort—even more than is usual with ordinary eruption—the pain is never very severe. There may be nervousness, slight fever and loss of appetite, but all symptoms are mild. No operation should be done unless the delay extends over several months, or special reasons exist for sur-

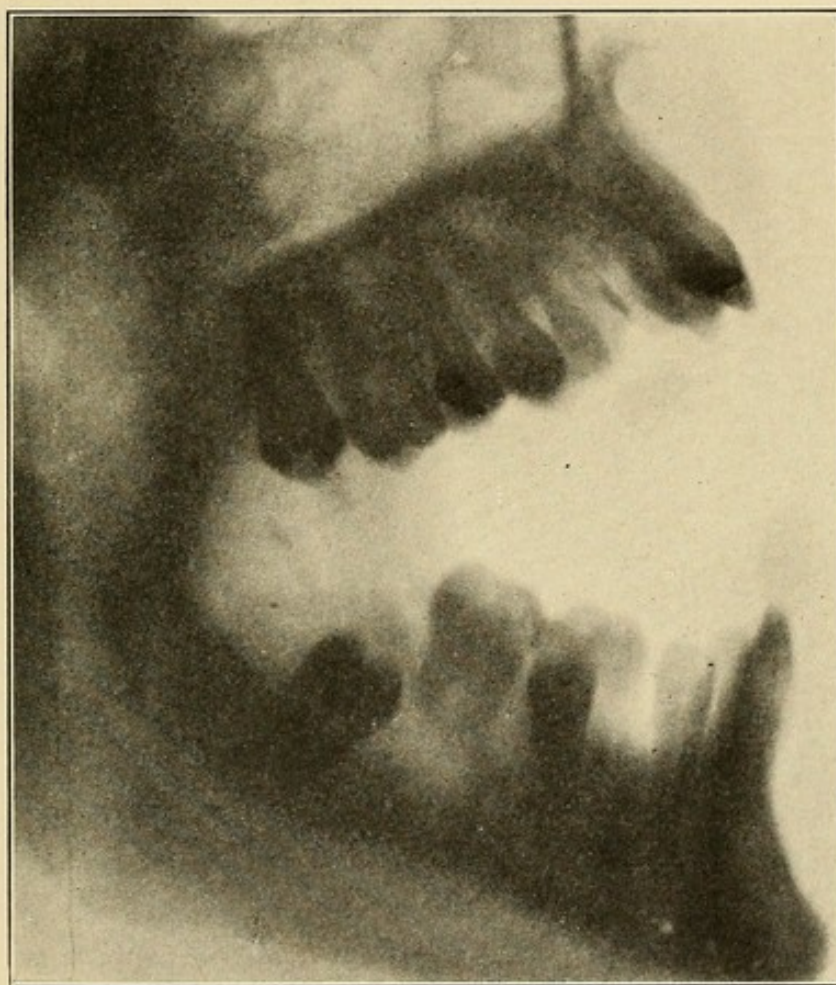


FIG. 113.—IMPACTED LOWER MOLAR.

gical interference, such as suppuration, unusually large tumor, etc. If left undisturbed, the teeth will make their own way through the usual canal.

A case in point is that of a girl ten years old, who had been examined by dentists and doctors for a tumor over the root of the left lower cuspid (figure 117). It was half an inch in circumference and almost as high, and gradually increasing in size. Further examination revealed the same



condition just beginning on the opposite side at the same point. During the course of the next six weeks, the cuspids

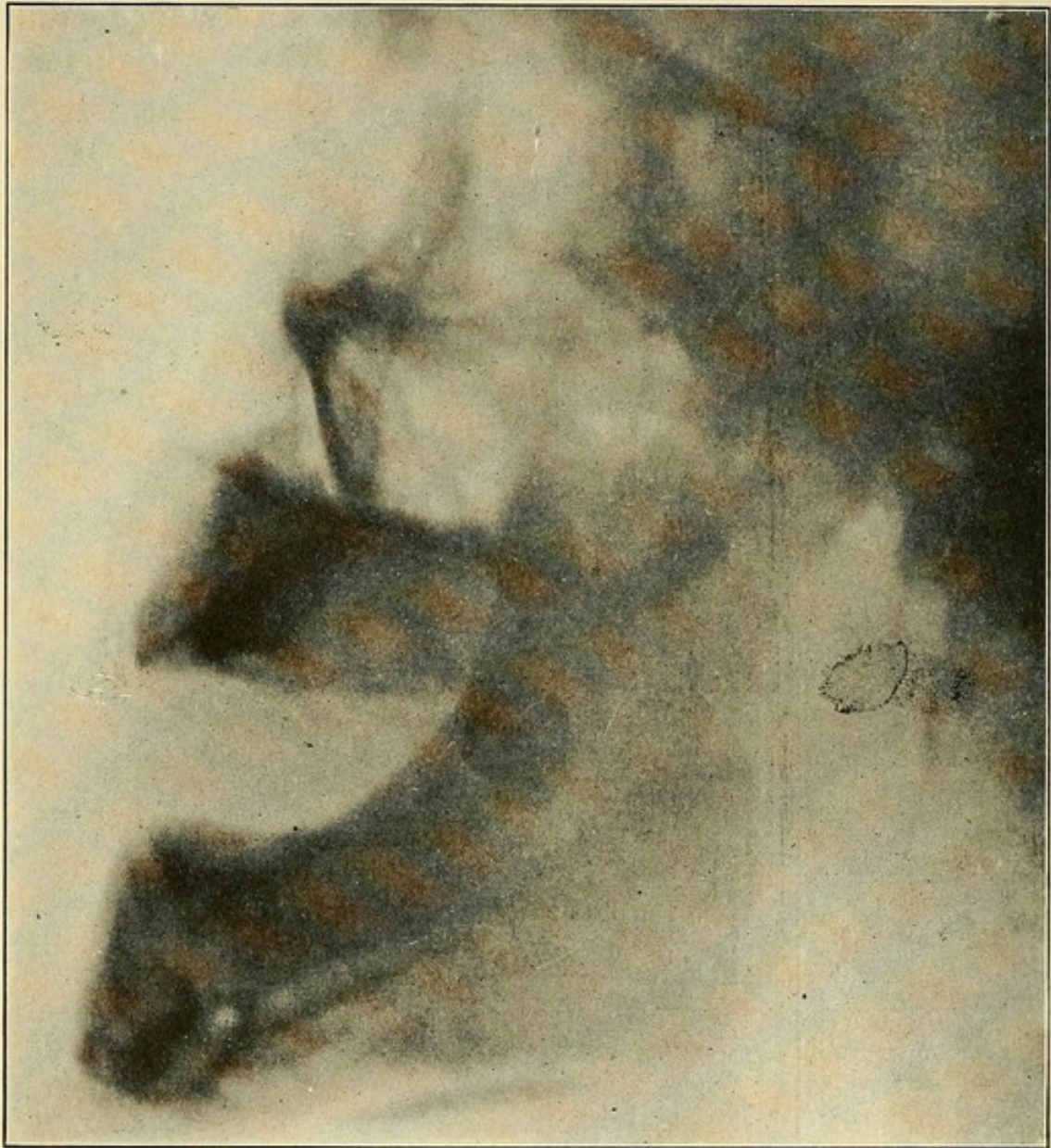


FIG. 114.—FOUR IMPACTED TEETH IN ONE CASE.

above showed the same tendency toward development outward.

**Treatment.**—It is proper to permit the teeth to develop, uninterrupted, until they erupt. When they are not in proper position, the orthodontist will be able to correct defects and deformities.



## CYSTS FROM ROOTS OF DEVELOPED TEETH

A more common form of cyst develops from the roots of teeth after eruption. One or several teeth may be included. The roots of the teeth involved melt away, thus destroying the blood and nerve supply. The growth is usually upon the external surface only, because there is

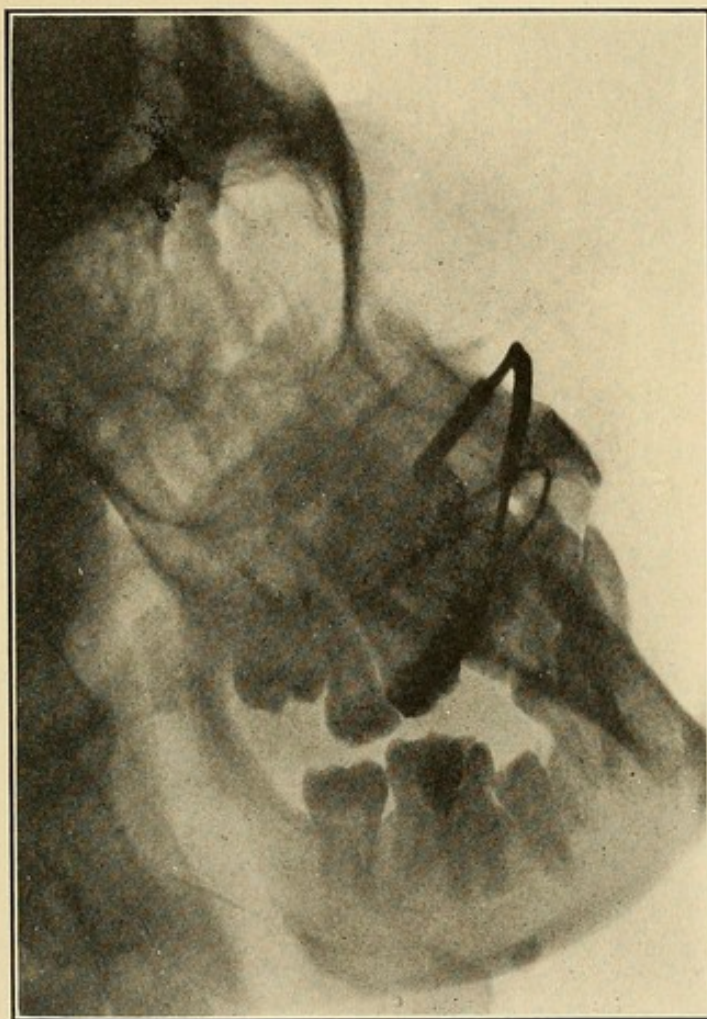


FIG. 115.—IMPACTED UPPER MOLAR.

less resistance in this direction. It is doubtless caused by irritation and infiltration at the apex, as an apex cyst, following the removal of a nerve and filling the root canal. The fluid is turbid. The cavity is quite distinctly outlined. The apices of the teeth extend into the open cavity and are denuded back to the bony wall. When these cysts develop in the maxilla adjacent to the antral floor,



this cavity is usually involved. In some cases they become suppurative and a diagnosis is more difficult.

The case shown in figures 118 and 119 was that of a woman about thirty-five years of age. The lump had been growing gradually for more than two years. The cavity contained a thick, straw-colored liquid with some shreds. The wall was well defined, but irregular. The roots of the teeth stood out into the cavity, surrounded by the fluid. They were denuded back to the bone, and the entire external table was destroyed to the gingival margin. The apices were gone, thus destroying the blood and nerve supply.

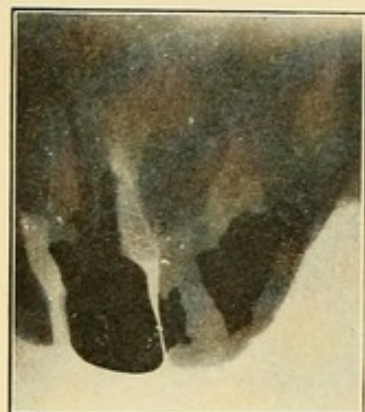

FIG. 116.—IMPACTED CENTRAL.

The operation was done through the mouth, and consisted in making an incision down through the center of the tumor and evacuating the contents of the cyst. The teeth were removed without difficulty. Such portions of bone as were thought to be dead were removed. The subsequent history was uneventful; repair followed rapidly.

Figure 120 is a case of a young woman, aged thirty years, who had a tumor on the external surface of the maxilla immediately above the lateral and cuspid. The tumor was about the size of the half of a split English walnut. A diagnosis of cyst was made, since there had been no inflammatory symptoms from the onset of the development of the tumefaction.

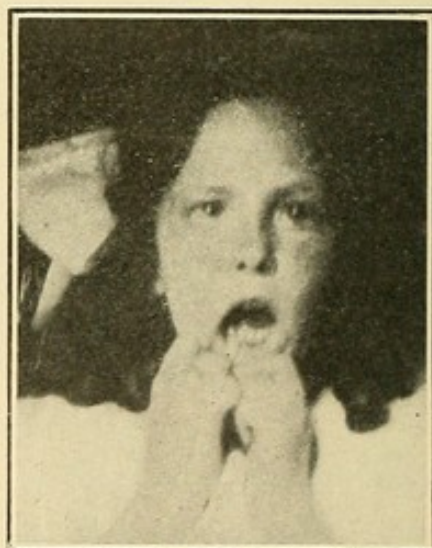

FIG. 117.—CYST FROM ERUPTING TOOTH.

The operation included an incision into the tumor through the buccal sulcus of the oral cavity, going directly into the cyst. The material found was similar to that in



the preceding case, being mucilaginous and straw-colored. The roots of the two teeth involved were found projecting into the cavity, as may be observed by looking at the X-ray picture. The entire external bony wall and soft tissues

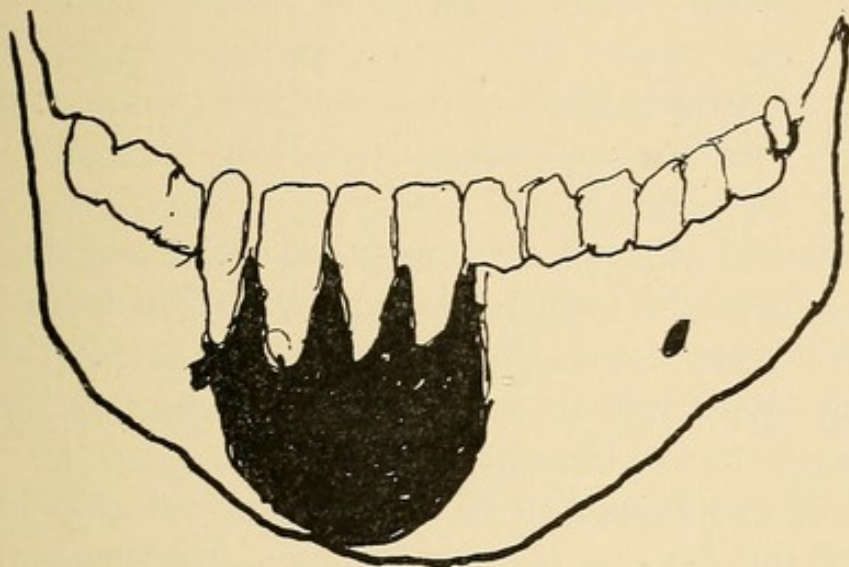


FIG. 118.—ROOT CYST.

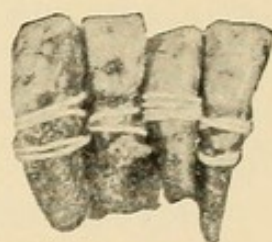

FIG. 119.—TEETH FROM SAME CYST.

were removed so as to make the cavity of the cyst continuous with the oral cavity. The two offending teeth were extracted and the external bony and membranous walls were removed, making the opening as large as possible, so as to make the oral cavity and the cyst cavity continuous with each other. It would not be desirable to have a cavity this size close until the architectural reconstruction of the bone took place for fear there might be some accumulation. The cavity was packed in order that it might not close. There were no symptoms following the operation, as there had been none from the beginning, and the cavity was obliterated in the course of three months, the patient remaining perfectly well.

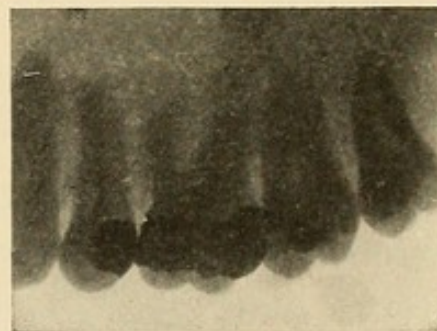

FIG. 120.—CYST FROM DEVELOPED TOOTH.



## CHAPTER XXVII

### CONGENITAL AND ACQUIRED DEFORMITIES OF THE FACE AND MOUTH IN GENERAL

The most common variety of congenital defect of the face is hare lip, and of the mouth, cleft palate. Defects of the face may vary from the slightest cleft or fissure of the lip, not requiring operation, to a complete cleavage of the face from the mouth to the base of the brain.

**Development of the Face and Mouth.**—The first step in the formation of the face is the development of the oral plate, the earliest indication of the future mouth. The oral plate appears about the twelfth day and is formed from the epiblast and the hypoblast, the monoblast being absent. It is situated in the ventral part of the head of the embryo. The oral plate being depressed by the upgrowth of surrounding tissues, the produced fossa constitutes the oral pit, or stomodeum. The oral plate now becomes the pharyngeal membrane. The second factor in the development of the face is the appearance of the first and second visceral arches, which occurs in the third week. The maxillary processes and mandibular arches grow toward the median line of the ventral surface of the body. The oral pit deepens from the twenty-first to the twenty-third day, and the third week it is a fossa. The upper boundary is formed by the nasofrontal process, which is the thickening of the ventral wall of the forebrain vesicle. The lower boundary is formed by the mandibular arches forming the lateral extent of the fossa.

Soon the future nares are formed, foreshadowed by the development of olfactory plates, one on each side of the



nasofrontal process. These epithelial areas soon become depressions—the nasal pits—closely united with the wall of the forebrain vesicle from the first; and later they develop into nasal mucous membrane. The nasofrontal process the fifth week becomes globular processes, which constitute the inner boundaries of the pits. From the nasofrontal process, growing down and forward, are the lateral frontal processes, forming the lateral boundaries of the nasal pits. The nasofrontal process is the forerunner of the intermaxillary portion of the upper jaw, including the corresponding part of the upper lip and nasal septum and the bridge of the nose. The lateral frontal process becomes the wing of the nose.

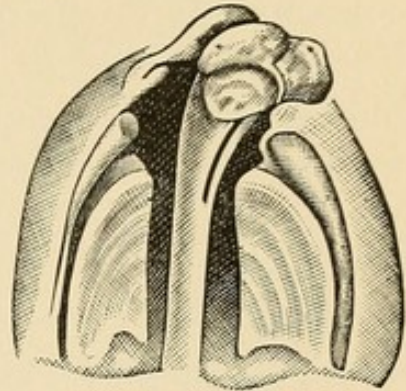


FIG. 121.—EMBRYONIC DEVELOPMENT OF FACE. Showing position of the intermaxillary bone and its relationship to the alveolar process in unilateral cleft palate.

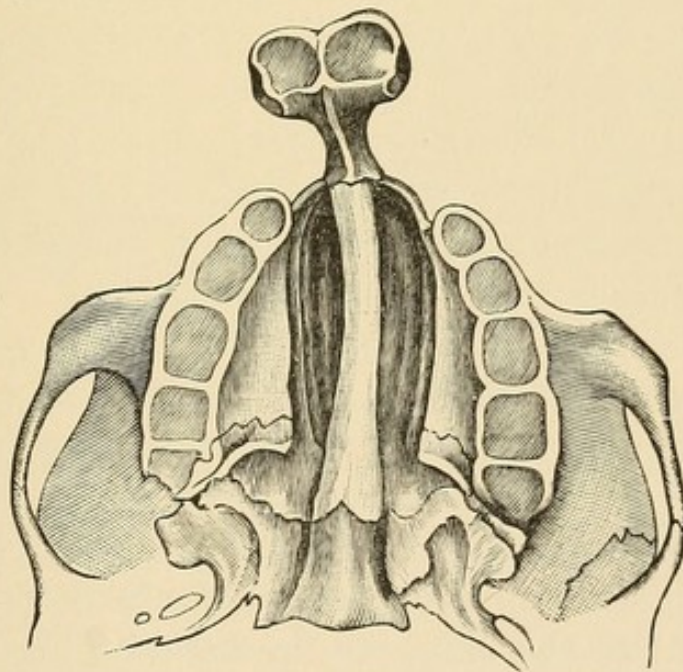


FIG. 122.—PREMAXILLARY BONE. Showing maxillary bone projecting well forward beyond the line of the alveolar processes in a case of double cleft of the alveolar arch as well as double cleft palate.

Hare lip is a deformity resulting from failure of union of the nasofrontal and maxillary processes. The mandibular



arches do not unite until the thirty-fifth day. The angle between the maxillary processes and the mandibular arches corresponds to the angle of the future mouth. The primitive oral cavity is first separated from the gut by the pharyngeal membrane, which ruptures about the fourth week. Soon after the formation of the upper jaw the oral surface presents two parallel ridges. The outer is larger and develops into the upper lip; the inner is smaller and becomes gum. The lip and gum of the lower jaw are produced in a similar manner. The only demarcation between the mouth and the nose is the tissue representing the united nasofrontal, lateral nasal, and maxillary processes.

The nares open widely into the oral cavity, posterior to this partition. The formation of the palate effects a separation between the two. On the inner or oral surface of the upper jaw, two shelf-like projections appear, one on each side, which are rudiments of the future palate; they grow toward each other, the tongue projecting between them. At the eighth week, union of the two lateral halves begins at the anterior ends; the ninth week, the hard palate bones unite; the eleventh week, the soft palate is developed completely and unites. The uvula appears the latter half of the third month as a small protuberance at the posterior edge of the soft palate.

From this mode of formation, it can be seen that the cleft is never in the median line, but on one side or both, and when complete extends downward from the anterior nares. When union does not occur, the nasofrontal or intermaxillary bone is usually found projecting beyond the normal face line, and when unilateral, where there is union of the bones on but one side, the free end at the cleft is usually projected beyond the normal side.

Like hare lip, cleft palate is a failure of the processes or tubercles of early embryonic life to properly coalesce. The central process, which forms the vomer, sends out a coalescing margin to the right and left to meet a shelf



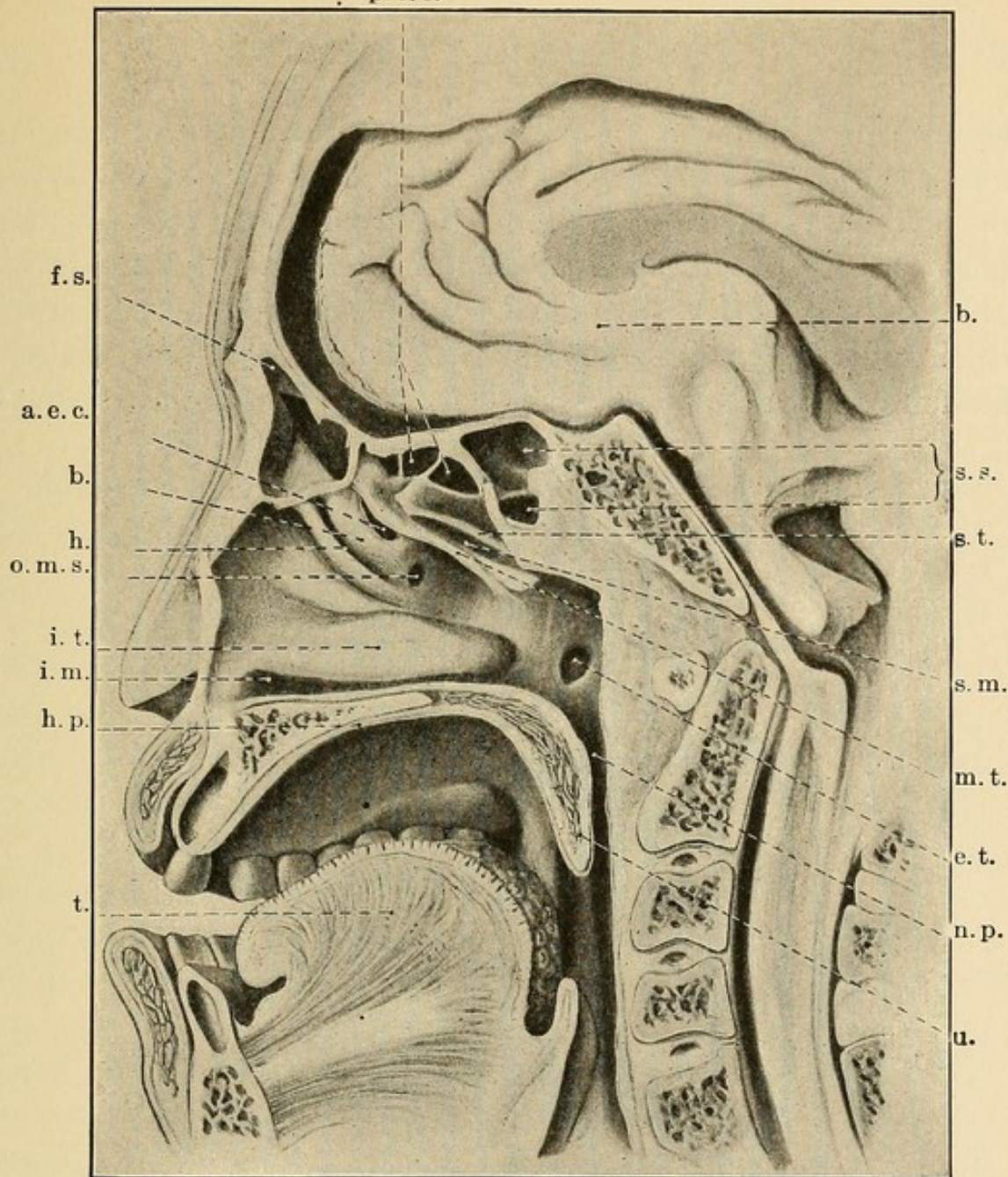


FIG. 123.—CROSS SECTION OF FACE.

t. Tongue  
 h.p. Hard palate.  
 i.m. Inferior meatus.  
 i.t. Inferior turbinal.  
 o.m.s. Opening of maxillary sinus.  
 h. Hiatus semilunaris.  
 b. Bulla ethmoidalis.  
 a.e.c. Anterior ethmoidal cells.  
 f.s. Frontal sinus.  
 p.e.c. Posterior ethmoidal cells.

b. Brain.  
 s.s. Sphenoidal sinus.  
 s.t. Superior turbinal.  
 s.m. Superior meatus.  
 m.t. Margin to which middle turbinal  
 was attached.  
 e.t. Opening of Eustachian tube.  
 n.p. Naso-pharynx.  
 u. Uvula.

—Copied from Onodi's atlas.

A deeper view is here given of the structures on the outer wall of the right nasal cavity. The middle turbinal has been entirely removed (m.t. indicates its point of separation from the rest of the ethmoid), so as to show the anatomy of that part of the outer wall which it covers. The section passes through the accessory sinuses in the frontal bone, the ethmoid, and the sphenoid, and shows the proximity of these cavities to the brain. The openings of all the accessory cavities can be easily studied; particularly well brought out are the relations of the hiatus semilunaris, with the infundibulum opening into its anterior part, the orifice of the maxillary sinus at its posterior extremity, and the opening of the anterior ethmoidal cells separated from it by the swelling of the bulla ethmoidealis. This plate shows how the posterior ethmoidal cells and the sphenoidal sinus open into the superior meatus, the former being below and the latter above the superior turbinal. (Reik.)



which is projected from either side of the maxillary process. By the union of these the floor of the nasal cavity is formed. A failure to unite may occur on both sides, when there results a complete cleft; the septum standing down into the oral cavity furnishes the plates from either side, which seldom grow beyond the lateral nasal wall. The cleft in such cases usually extends between the maxillary bones

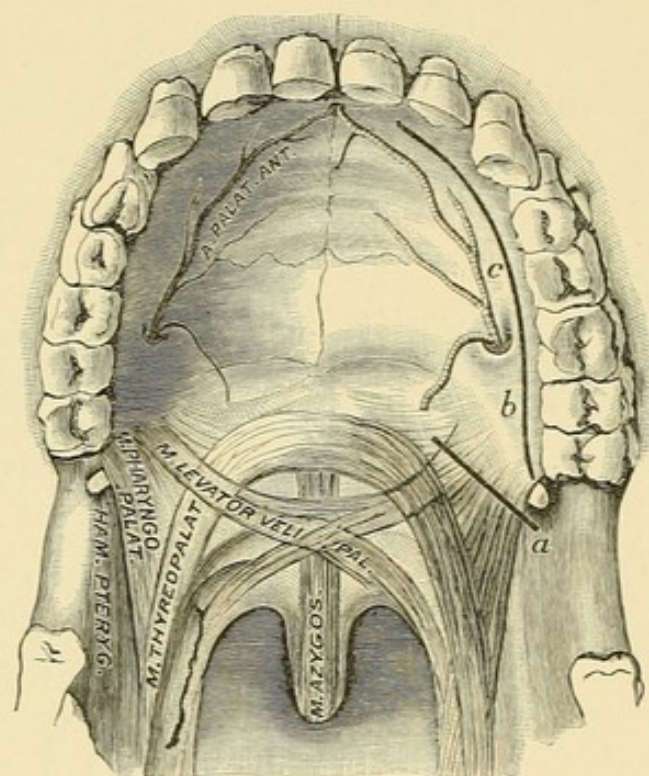


FIG. 124.—MUSCLES OF THE SOFT PALATE.

- a. Line of division of muscles.
- b. Line of incision.
- c. Palatine vessels. (Bryant.)

through the lip, causing combined bilateral hare lip and cleft palate. Union may take place on one side only, a unilateral cleft remaining. In other instances the lips unite and the bones coalesce to form a perfect alveolar ridge, leaving a naso-oral cleft. In still other instances where the bones unite and only the soft palate remains open, the abnormal condition may be so slight as to be no more than a bifid uvula.

The causes which have been given as accounting for



these defects are arrested development from malnutrition or sickness, disease of the mother during the early part of gestation, maternal impressions, and heredity. Indeed, it is all speculation, and the pros and cons of these various theories have no place here.

Fifty per cent. of the cases of hare lip have an associated cleft palate. There is one hare lip in 2,500 births and about one cleft palate in 5,000 births.

**Median Facial Cleft.**—A very rare case of median facial cleft in an infant twenty-three days old is reported by A. Wolfer. The lower lip was split in the median line into two halves, which were again connected by a cicatricial bridge in the lip proper. The latter, more strongly developed in its upper part and drawn toward the oral cavity, extended into the median line of the chin and into the neck down to the suprasternal fossa, becoming narrow and flatter as it descended. The cicatricial fissure in the lip corresponded to a defect in the lower jaw itself. This consisted of two halves, which were united by loose connective tissue and ran downward. The movable median ends of the two halves of the lower jaw were decidedly thinned and narrowed and terminated in a rounded and flat extremity. More interesting yet was the condition of the tongue; the anterior portion was divided longitudinally in two halves, like the leaves of an open book. The mobility of these two halves was much interfered with by the adhesion of a median cicatrix, at the bottom of the fissure, to the floor of the mouth. The base of the tongue was not split. It was, therefore, a median cleft of the lower lip, involving the lower jaw and the tongue, the lateral halves being held together at a distance by a cicatrix formation.

**Other Congenital Defects.**—The various processes which go to form the skin of the face may fail to unite at any point, leaving clefts. The frontal and lateral tubercles may fail to unite, leaving a cleft extending upward and outward from the ala nasi, or a cleft may extend from the angle of



the mouth. Clefts of the lower lip are rarely seen. They may be associated with cleft of the mandible, or it is possible for the cleft to include the tongue, as seen in Wolfer's case.

Delayed closure of any of the clefts leaves an unsightly fissure across the face, which may be closed by operation.

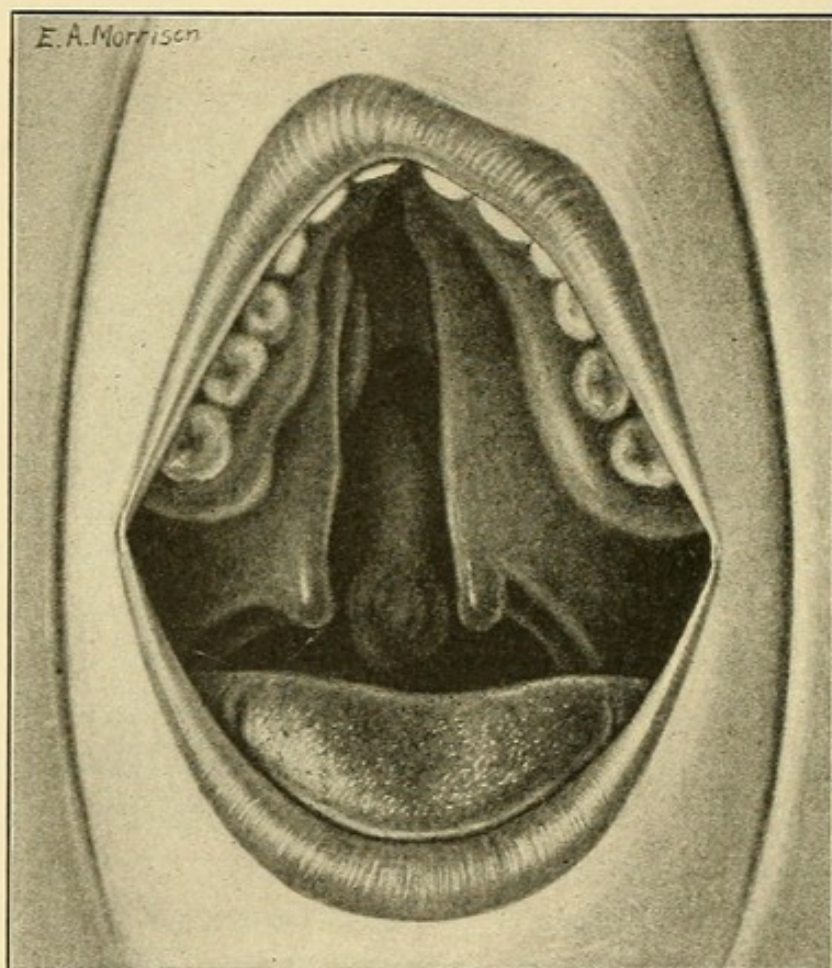


FIG. 125.—AN UNUSUAL OPPORTUNITY TO VIEW AN ADENOID IN SITU, THROUGH A CLEFT PALATE. (REIK.)

The cut should include the buccal mucous membrane. Rarely there is an over-production of tissue, leaving a red ridge along the line of union of the processes. This can be removed by operation and the skin adjusted, leaving a simple scar only. Sinuses, dimples and tubercles are occasionally seen and are due to an incomplete coalescence of the processes at the angles where they meet.

*Acheilia*, or absence of the lips, is seldom seen, although



it does occur, and can be corrected by plastic operation. *Astomia* is absence of the oral cavity, and *atresia* the absence of an oral orifice, though back of the occlusion there is an oral cavity. In the latter condition an artificial orifice can be made. *Microstoma* is a congenitally small mouth usually due to arrest of development, and *macrostoma* is a very large mouth, due to a failure of the lateral and man-

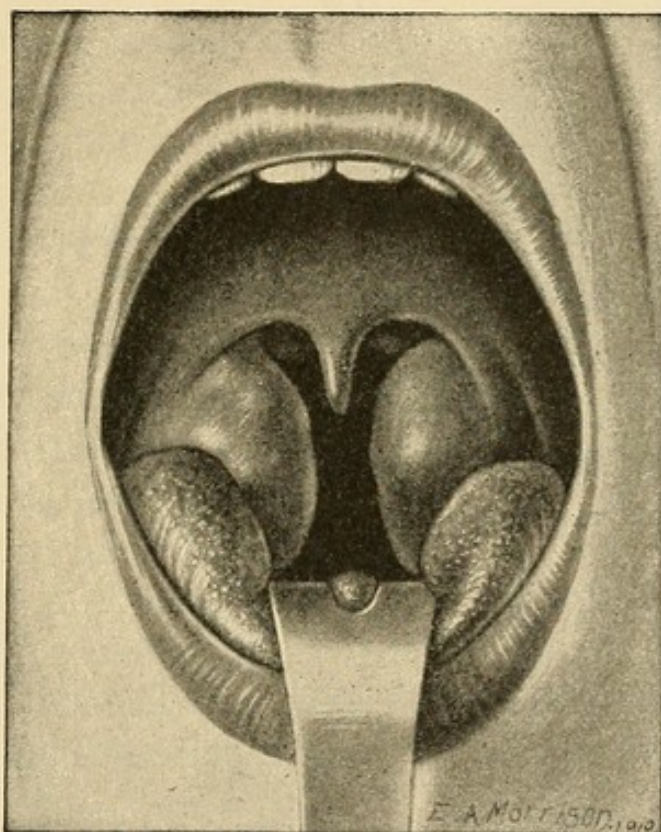


FIG. 126.—VERY LARGE HYPERTROPHIED TONSILS AND ADENOID, THE LATTER VISIBLE AS IT HANGS BELOW THE MARGIN OF THE SOFT PALATE. (REIK.)

dibular processes to coalesce. *Coloboma*, or bucco-orbital fissure, is a fissure extending from the mouth to the eye, and is due to non-coalescence of the superior and frontal processes. Hypertrophy, or *macrocheilia* and *microcheilia*, may occur as a congenital defect or from disease or injury.

*Ectropion* is an eversion or folding-out of the mucous membrane of the eye or lips, and *entropion* a folding-in of the lips or margin of the eyelids. These conditions may be



congenital or acquired, the latter usually resulting from burns or some variety of injury. Plastic operations make wondrous changes in these cases.

*Case of True Double Lower Lip.*—Dr. John B. Roberts presented a patient upon whom he had operated for the removal of a true second lower lip. The photograph, which

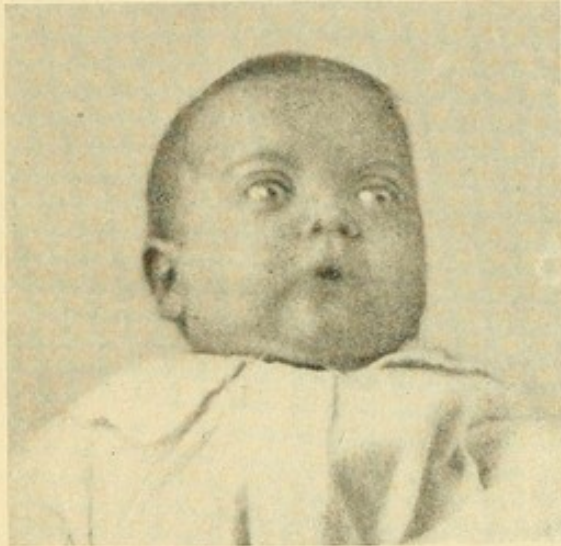

FIG. 127.—CONGENITAL MICROSTOMA.

was taken before operation, showed the double lip to consist of a thick outer lip and a thinner internal structure separated from the outer by a deep fossa lined with mucous membrane. In the median line of the mouth the two lips were fused together at the vermilion border and downward to the attachment of the structure to the alveolar portion of the

mandible. The inner lip was dissected from the outer and excised. The raw surface was then covered by drawing flaps of mucous membrane over it. The patient's curious anomaly was corrected, and his appearance much improved.

### ACQUIRED DEFORMITIES IN GENERAL

Acquired defects of the hard and soft palate are found and are caused by traumatisms and syphilis.

Traumatism, as a cause of perforation through the palate, is rare, and when it does occur is usually followed by repair. When repair does not occur, a plastic operation is usually successful.

Syphilitic ulcerations of the palate very commonly result in complete perforation into the nasal cavity. An elongated orifice sometimes results, resembling congenital cleft palate. (See two cases under Syphilitic Necrosis.) Opera-



tions should not be performed until sufficient time has been given for thorough specific medication, which may be one year, for large perforations diminish in size under treatment, when union would not follow a closure by operation.



## CHAPTER XXVIII

### HARE LIP

Hare lip is the most frequently occurring of all congenital defects of the face.

**Clinical Varieties.**—There are four main varieties: 1. Partial unilateral; 2. partial bilateral; 3. complete unilateral (into naris); 4. complete bilateral (into nares). Rarely it may be partial on one side and complete on the other.

**Prognosis.**—The prognosis of uncomplicated hare lip is excellent, especially when the operation is performed before the end of the first year. Owing to the possibilities for doing plastic adjustment, as well as the promptness with which the face repairs when adjustment is skilfully made, repair can be expected in ninety-five per cent. of operations. A resultant scar is, of course, unavoidable.

**Operation for Hare Lip.**—The operation for closure of clefts of the lips is known as cheilorrhaphy or cheiloplasty. Of the many operations that have been described as original or modifications, only a few can be considered here. The end sought in all operations is to pare the margins of the cleft, bring them together, and hold them there until union has occurred. The principal difficulty is to avoid a notch at the lip margin, and various methods have been proposed to overcome the difficulty. Malgaigne's operation, shown in figures 131, 132, 133, consists in making the incisions from the margins of the cleft outward to near the skin line of the lip. The flaps thus made are turned down and the free margins adjusted. If the flaps are too long they may



be trimmed back so as not to project beyond the lip line after repair takes place. It is better to allow some projections

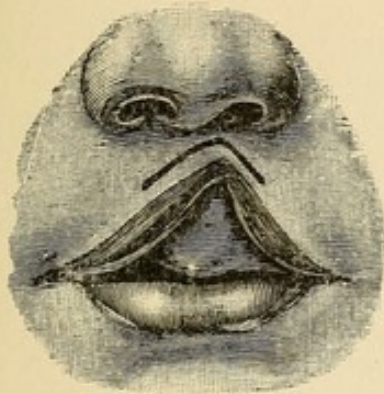


FIG. 128.

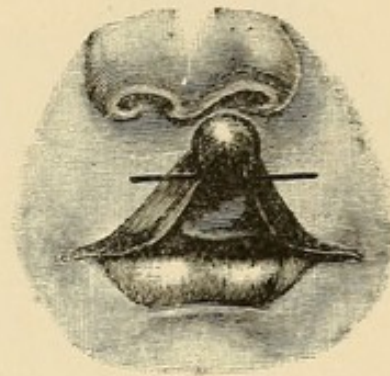


FIG. 131.

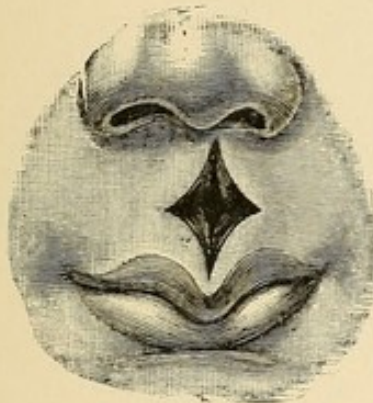


FIG. 129.

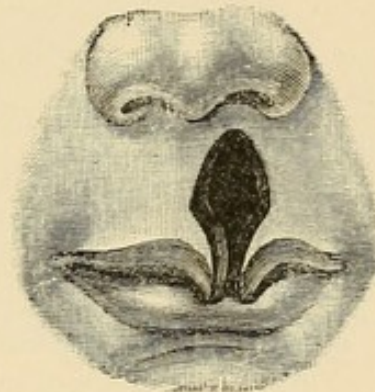


FIG. 132.

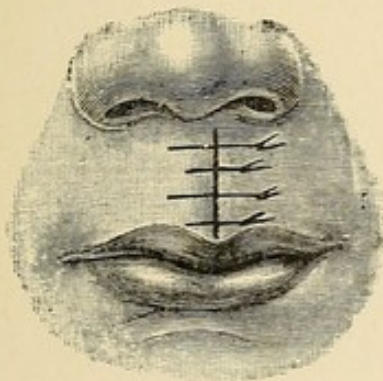


FIG. 130.

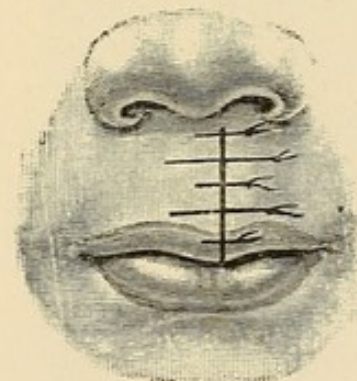


FIG. 133.

FIGS. 128-130.—NELATON'S METHOD. FIGS. 131-133.—MALGAIGNE'S METHOD.

128.—Freshening.

131.—Freshening.

129.—Wound after adjustment of lip.

132.—The lip on either side is dislocated downward.

130.—Suture.

133.—Sutures in position.

rather than to make them even, for a certain amount of contraction will occur along the cicatrix. Mirault's opera-



tion differs from Malgaigne's only in that one of the flaps is entirely cut through, and the notch filled in by the re-

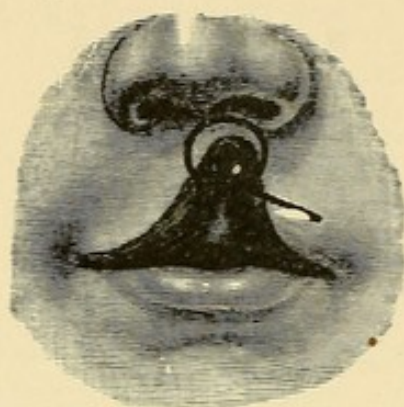


FIG. 134.

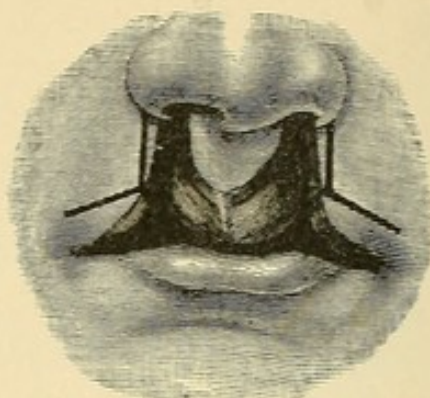


FIG. 137.

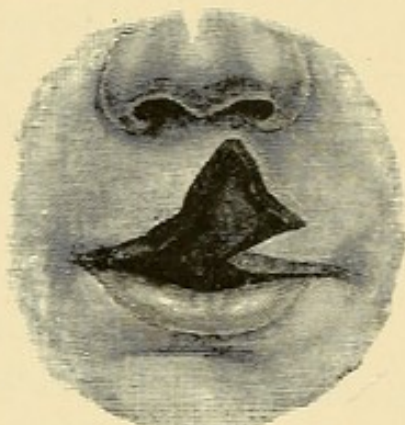


FIG. 135.

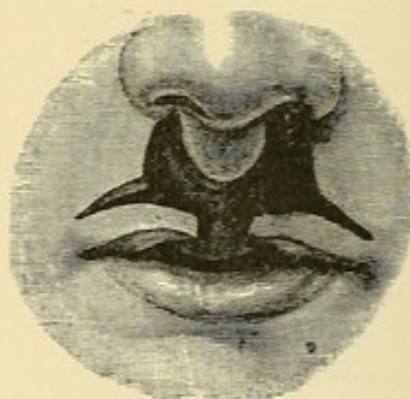


FIG. 138.

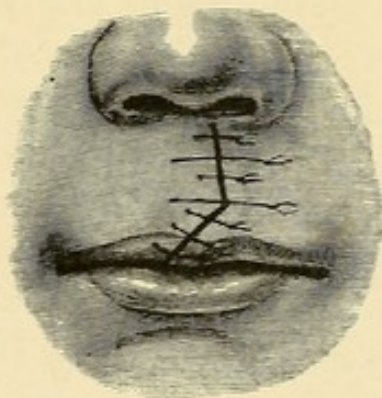


FIG. 136.

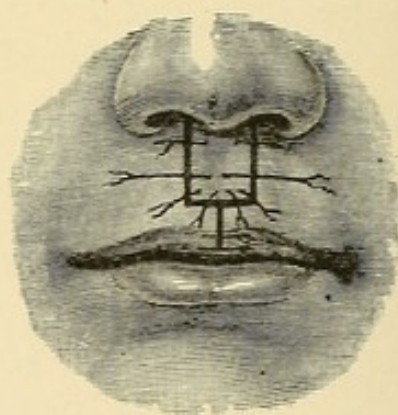


FIG. 139.

FIGS. 134-136.—MIRAULT-LANGENBECK'S METHOD.

134.—Freshening.

135.—Wound.

136.—Suture.

FIGS. 137-139.—OPERATION FOR BILATERAL HARE LIP.

137.—Freshening.

138.—Wound.

139.—Suture.

maining flap. Hagerdorn's operation requires the removal of both marginal flaps down almost to the lower margin of



the lip. On one side an incision is extended back into the lip far enough to make the adjustment neat. Nelaton's operation, figures 128, 129, 130, is for incomplete cleft, and con-

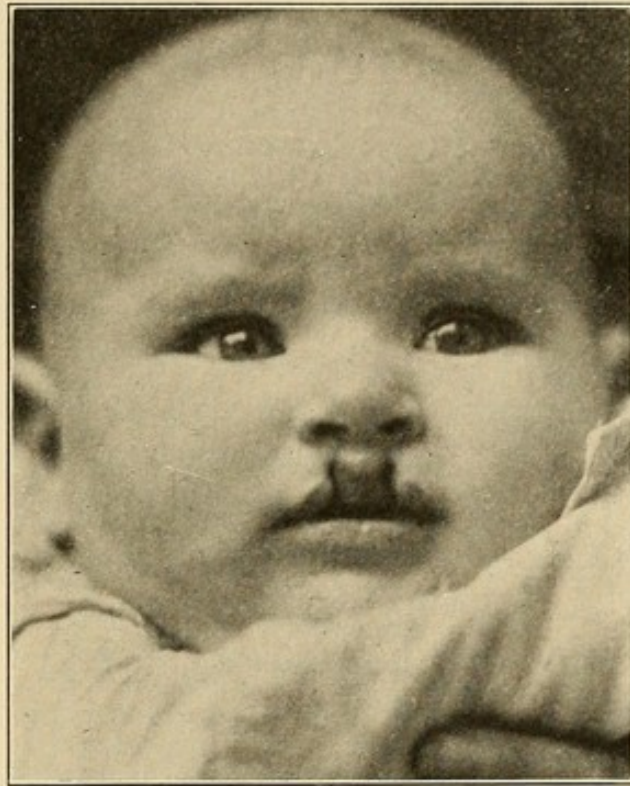


FIG. 140.—BILATERAL INCOMPLETE HARE LIP.

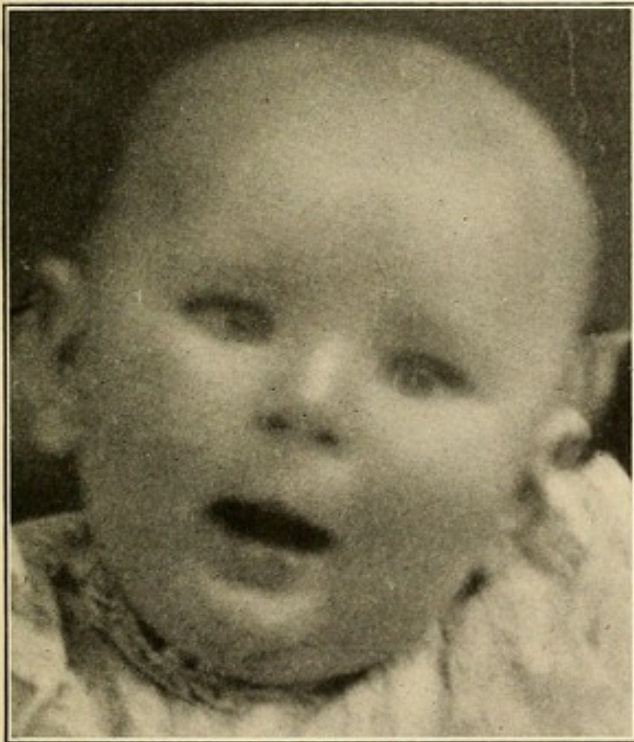


FIG. 141.—RESULT OF OPERATION.

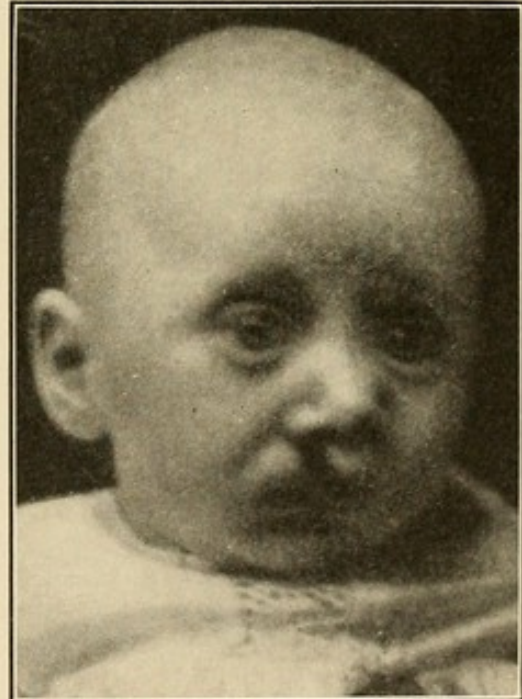


FIG. 142.—UNILATERAL COMPLETE HARE LIP.



sists in making an arc incision through the lip, parallel with the margin of the cleft. By buckling the flap downward a

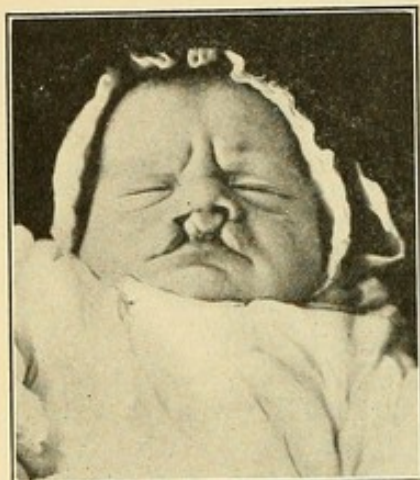

FIG. 143.—BILATERAL COMPLETE HARE LIP, WITH PROJECTING INTERMAXILLARY PROCESS.

transverse incision becomes a vertical one. Fillebrown makes a straight instead of a circular cut, otherwise his is the same as the operation devised by Nelaton. Operation for double hare lip is practically a double Mirault's incision, the flaps removed being those from the intermaxillary portion, allowing the outer flaps to be turned down, as shown in figure 138.

In all operations for hare lip, when much tension is made upon the flaps in making the adjustment, the cheek should be dissected away from the bone far enough back to permit free adjustment. In complete hare lip, care must be taken to freshen the anterior surface of



FIG. 144.—RESULT AFTER HARE LIP OPERATION.




FIG. 145.—RESULT AFTER HARE LIP OPERATION.

the process near the nasal orifice, as well as the upper part of the posterior surface of the lips to insure union; other-



wise there will remain a fistula from the nose to the mouth between the lip and the alveolar ridge, a condition not at all desirable.

Suture materials differ with different operators. To-day horsehair is used for superficial suturing and silkworm gut for deep through-and-through sutures. Roe introduces his sutures from beneath the lip, crossing the cleft through the margin of the skin to the opposite side, and not through to the surface, thus avoiding suture scars in the skin.

Dressings formerly used find no place in modern practice. The adhesive plaster, gauze and collodion alone serve as pockets for infection and can in no way assist repair. When adhesive strips are necessary to make traction, they should cross the mouth below the wound to the angle of the mandible, as suggested by Ferguson.



## CHAPTER XXIX

### CLEFT PALATE

**History.**—The first recorded staphylorrhaphy was done by Le Moneir, a French dentist, in 1764, and Roux of Paris improved the technic of the operation and published his results in 1819. Independently of Roux, Warren of Boston operated and published his case in 1820. This was followed by operations by Pollock, Lister and Ferguson in England, and Graefe, Diffenbach and others in various parts of Europe. In this country, Pancoast and Gibson of Philadelphia, Stevens, Hassock, Wells and others did plastic operations for the closure of the hard and the soft palate.

**Etiology.**—Brophy says: "The causes of congenital cleft palate are: 1. Heredity; 2. mechanical force exerted by lower jaw against the upper jaw in embryo. In congenital cleft palate in young infants, the full amount of tissue is developed to form a normal palate, and the defect is due to failure of union. General debility of the mother in early months of gestation may be a factor. Prenatal impressions possibly, but evidence not conclusive."

**Varieties.**—The clinical varieties of cleft palate are: 1. Incomplete—(a) bifid uvula, (b) bifid soft palate, (c) partial cleft of the posterior border of the hard palate, and (d) fissure of the alveolar process and anterior border of the hard palate; 2. complete—(a) unilateral, and (b) bilateral; 3. complicated with hare lip, unilateral or bilateral.

**Time of Operation.**—The time at which operation should be performed should be determined by the condition of the



patient. Wolff, the German surgeon, has operated as early as two days after birth, and Billroth, Knapper, Langenbeck and Salzer have, from time to time, been advocates of early operation.

Arguments in favor of postponement of cleft palate operations are: First, the very young do not stand shock well; second, they do not stand the loss of blood so well as older patients; third, anesthetics are not taken with as much safety as by older children; fourth, the operation is more difficult owing to the smallness of the mouth, and the after-treatment cannot be carried out with the same degree of satisfaction.

Arguments in favor of early operation are: First, as long as the cleft remains open the patient cannot be properly nourished, since food passes into the nasal from the oral cavity; and the act of suckling is imperfect on account of the continuity of the mouth with the anterior nares; second, patients are more liable to have respiratory diseases and may die of bronchitis or pneumonia; third, the peculiar twang so characteristic of this defect, when once acquired, is almost never completely overcome by a closure of the defect; fourth, if it is desirable, as suggested by Brophy, to approximate the maxillæ, this can be done more readily in the very young.

Ferguson says: "The younger the patient, the greater the danger." Brophy says: "The younger the patient, the less the shock." From the foregoing contradictory statements from two of the leading operators of to-day, any operator may consider himself free to use his own judgment, taking into consideration the condition of the patient. If a patient is fairly well nourished, the operation may be postponed until he is several months old. It is best, of course, to operate before children begin to talk, to avoid, as far as possible, the nasal intonation.

**Anesthesia.**—Various operators use different methods of anesthetizing. Brophy uses ether through a nasal tube,



forcing the vapor through the nose with a rubber ball. Profound ether anesthesia should first be secured. This may be followed by the use of Brophy's method or one of the others where an atomizer is used, or chloroform may be used intermittently as the patient shows signs of recovery. Nitrous oxid and oxygen must not be disregarded. These are destined eventually to come into more general use. At this time, however, they are not used in the general hospitals, partly because of the habit of using ether and because of the greater expense, but principally for reasons of safety. Nitrous oxid is safe in skilled hands, but ether can be given by the unskilled, and a death almost never follows its use which cannot be attributed to other causes.

**Mouth Gags.**—A self-retaining mouth gag adds greatly to the operator's convenience, and greatly assists in expediting the operation. For this purpose, the instrument herewith shown was devised (figure 147). It is made like an ordinary gag, except that it has extending from the end of the upper arm, about the side of the head, above and around the ears, a plate made of malleable metal, so that it can be accurately adjusted to the side of the head without being tilted from the teeth. This is held in position by a head band, which may be an ordinary sterilized gauze bandage. With this simple device, the assistant is free to render double service. A self-retaining tongue depressor is attached to the gag, as shown. The tongue can be thrown up to any desired position by moving the lever, which is pivoted on the lower arm of the gag. The outer lever of the tongue plate is bent along the lower bar of the gag to near the end, where it is turned up at right angles, this part passing through an opening on the lower arm of the gag. It is secured by a ratchet or thumb-screw, as may be desired. As the gag is closed, the pressure made by the tongue plate is relieved, and as it is opened, the tongue is thrown up out of the field of operation, or it may be adjusted as may be desired.



Brophy uses a tubular mouth gag, which extends back on the lower side and acts as a tongue depressor.

Whitehead's mouth gag has been used for many decades.

### OPERATIONS

Cleft palate closure is called *uranoplasty* or *uranorhaphy* when the operation includes the bones that constitute the roof of the mouth, and *staphyloplasty* or *staphylorhaphy* when the defect to be closed is confined to the soft palate and uvula. The aim in operating is to close the chasm existing in the roof of the mouth and shut off the nasal from the oral cavity. Many methods have been devised for this purpose, but none can be absolutely relied upon with any degree of certainty that union will take place. It is not usually a difficult matter to obtain sufficient tissue to close the cleft, but it is quite another matter to procure union. For this reason the ingenuity of the surgeon has been put to test for many years, but as satisfactory an operation as may be procured in other branches of surgery is yet to be devised.

**Causes of Failure, as Outlined by Ferguson.**—Although very commonly vomiting, tearing out of the stitches, hemorrhage, swallowing solid food, allowing the infant to put its fingers into its mouth, and various diseases, are recognized as causes of failure, the chief causes are: (1) tension, (2) unskilfulness and devitalizing the tissue by bruising, etc., (3) unsuitable local and constitutional conditions, (4) failure to select a suitable operation for the case, and (5) poor nursing. Poor nursing is a fruitful cause of failure. As a rule, the mother is the worst nurse to place in charge of the patient. She is overcome by her sympathy for him, and rarely ever appreciates the necessity and importance of surgical cleanliness. For this reason the surgeon should insist on having the patient placed in a hospital where he can have full and complete control of everything bearing on his case.



The approximation of the maxillary bones by wires, screws and bands is recommended by operators. Brown's method is illustrated in the accompanying figure.

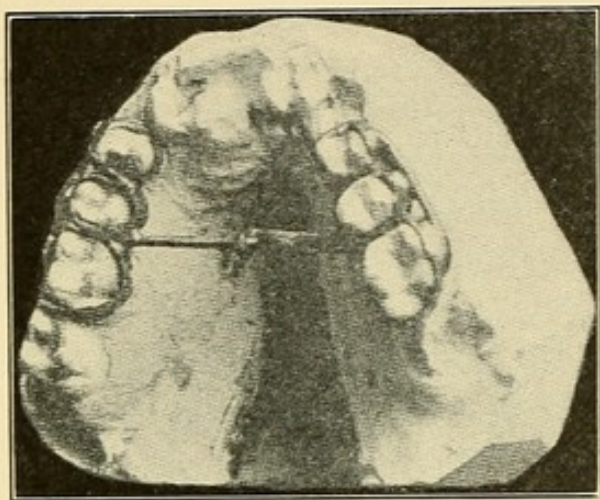


FIG. 146.—BROWN'S MODEL SHOWING HIS METHOD OF APPROXIMATING MAXILLARY BONES.

Manipulation, or forcing the bones together with the fingers, daily for several months, is recommended in the very young, to diminish the width of the cleft. All operations by breaking the maxillary bones formerly practiced have, the author believes, been abandoned.

#### Position for Operation.

—The Rose position is favored by many operators. It is claimed, first, that it facilitates hemostasis by compression; second, that it favors the ready outward flow of blood through the nostrils, mak-

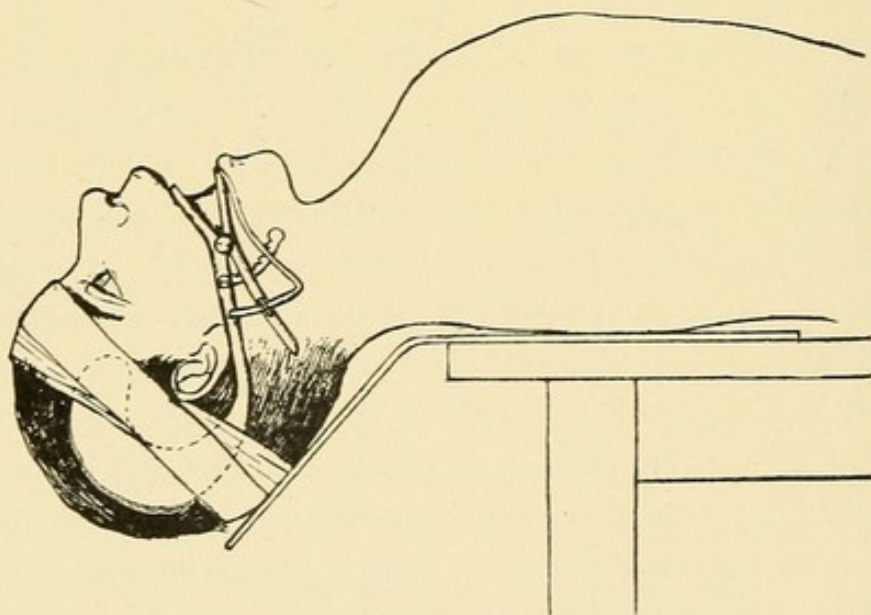


FIG. 147.—ROSE POSITION AND SELF-RETAINING MOUTH GAG.

ing the field of operation cleaner—instead of the blood going to the stomach it remains in the nasal cavities or is discharged through the anterior nares; third, it aids



anesthesia; fourth, it places the head in the best position for operation, the operator sitting at the head of the patient, working over the superior teeth (see figure 147).

The Rose position is best secured by the use of the head-rest of an ordinary operating table, or by an extra head-rest with a body portion passed under the patient—the head-piece being placed at an angle of 45 degrees to the plane of the body.

Brophy and many other operators do not place their patients in the Rose position, but on a horizontal table.




FIG. 148.




FIG. 149.

FIGS. 148 and 149.—BROPHY'S PERIOSTEAL ELEVATORS.



FIG. 150.—FILLEBROWN'S HOE.

**Instruments for Cleft Palate Operation.**—The following is a list of instruments required:

Hemostats and sponge holders.

Staphylorrhaphy bistouries, Langenbeck or Goodwillie.

Toothed fixation forceps, curved and straight.

Scissors, straight, curved and right angle.

Scalpels.

Needles, small curved.

Needles on handles, eye at end (see figure 165).

Hook and eye (see figure 166).

Wire cutter and twister.

Fillebrown's hoes.

Brophy's periosteal elevators (3 sizes and angles).



Mouth gag (see Rose position).

Suture material: horsehair, catgut, silkworm gut, silk, silver wire, iron wire (soft enameled copper wire—Baldwin).

Lead or aluminum plates.

**Varieties.**—Operations for defects of the roof of the mouth may be divided as follows:

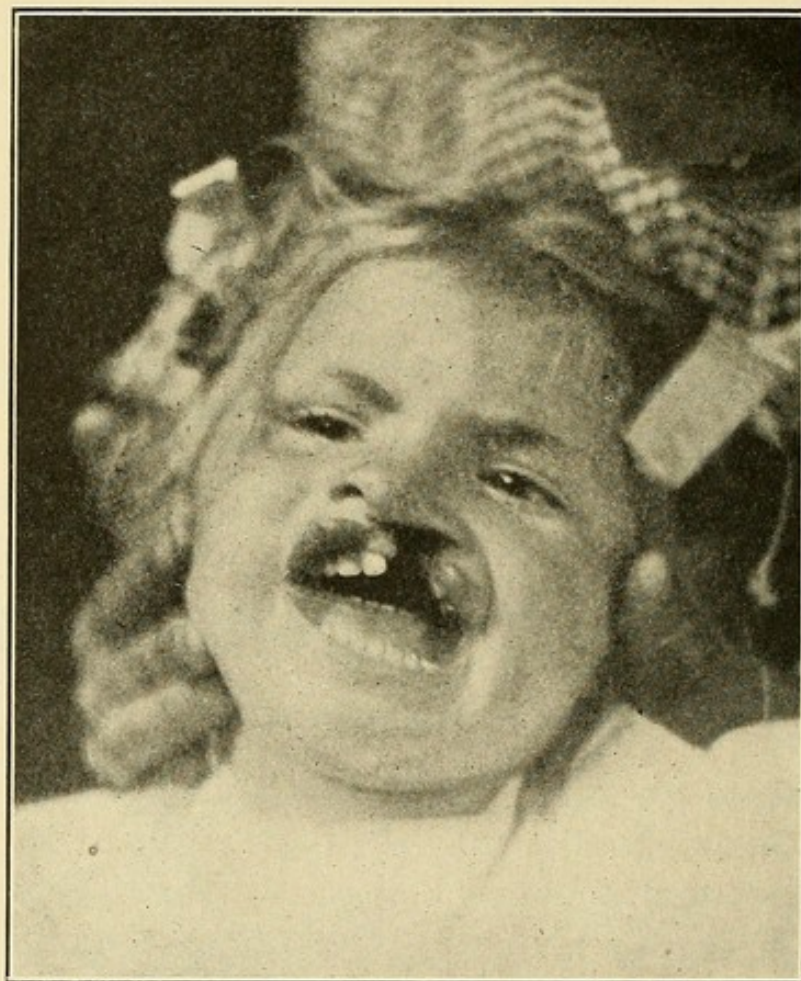


FIG. 151.—CLEFT ALVEOLAR PROCESS.

- (1) Uranoplasty, or upon the soft palate.
- (2) For cleft alveolar process.
- (3) For complete defects of the hard palate.
- (4) For unilateral cleft palate.

(1) *Uranoplasty*.—Under the first head, where the defect does not reach the hard palate, two methods of operation are practiced: (a) The margin of the tissue may be



split from apex of cleft to the tip of the uvula. The superior and inferior flaps readily unfold, leaving sufficient raw surface for adjustment. (b) The edges may be pared by using a Langenbeck or Goodwillie bistoury.

Suturing may be done with horsehair, silkworm gut, or 30-day chromicized catgut. Repair usually follows when

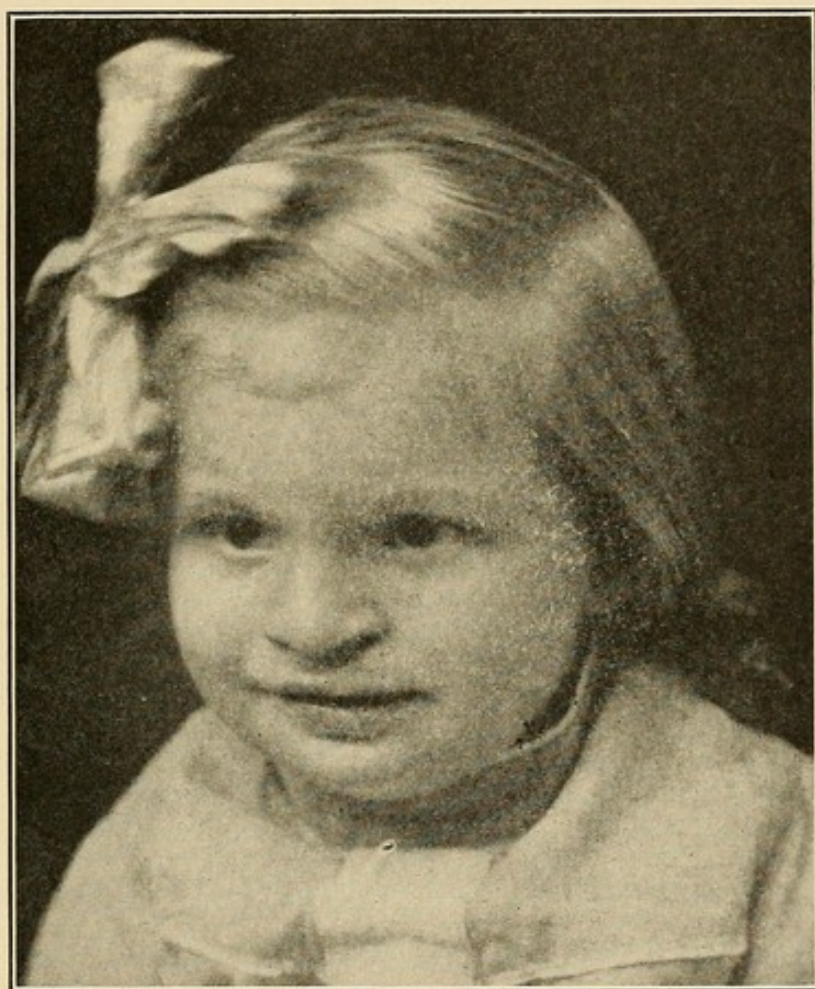


FIG. 152.—RESULT IN CASE ILLUSTRATED IN FIG. 151.

adjustment is good, and when tension upon the sutures is correct.

(2) *Operation for Cleft Alveolar Process.*—Cleft of the alveolar process may occur with hare lip without cleft palate, but it rarely occurs alone. Whether there is or is not a cleft of the palate, the operation is pretty much the same. When the bones cannot be approximated by manipulation or the screw or wire devices, and especially when



the free end of the incisive bone extends out beyond the line of the face, as in the case shown in figure 122, the method is to fracture the bone into the naris on the good side.

The following case is reported as typical of this class of cases:

Figures 151 and 152 show a case of single cleft palate and hare lip. The cleft in the bone was three-eighths of an inch, and in the lip one inch.

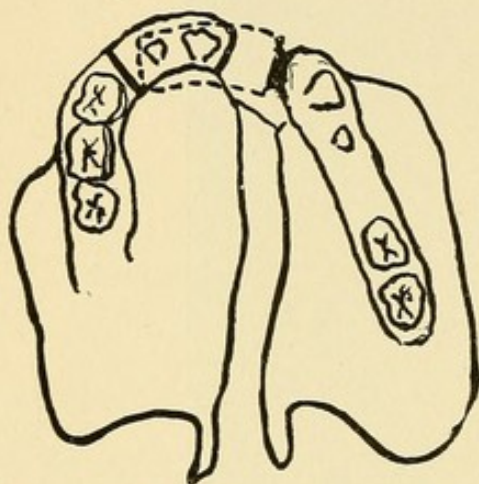


FIG. 153. — OPERATION FOR CLEFT ALVEOLAR PROCESS. Representing the method of operating upon the case illustrated in Figs. 151 and 152. This is especially applicable in cases of children who have arrived at such an age as to make the adjustment of the two maxillary bones crossing the line difficult, if not impossible.

Operation consisted in extracting the third tooth from the cleft. The alveolar process was fractured into the right anterior naris with a chisel, through the tooth socket. The intermaxillary bone was then forced around so as to close up the cleft. The free ends of the process were freshened, and the bones were held together by wiring. The drill holes were made back of the second tooth from the cleft. Iron wire was used.

The hare lip was operated on eleven days after the first operation. The wire was removed on the twenty-ninth day. The second picture was taken on the thirtieth day, when the patient left the hospital. No operation was done on the roof of the mouth since the left nasal cavity was not open and there was no palate floor on the other side. The inferior turbinated extended downward, forming a satisfactory roof for the mouth.

(3) *Defects of the Hard Palate.*—All cases of defects of the hard palate are not operable, because of the great width of the cleft, and prosthetic devices must be made to meet the conditions.



Operable cases may be divided into: (a) Gothic or high arches, where abundance of tissue is formed; (b) cases of low arch, where dropping of the soft tissues from the arch does not bridge the cleft, and other lateral incisions are necessary.

In cases of the first class Brophy's, Baldwin's and Ferguson's operations are to be advised. In other cases the

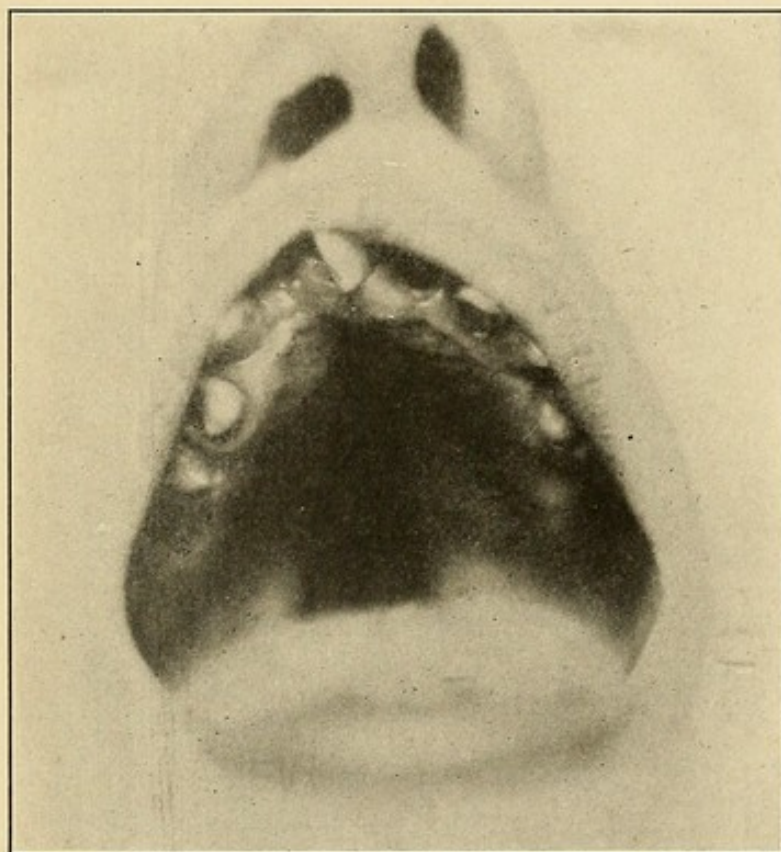


FIG. 154.—CLEFT PALATE.

Langenbeck, Wolff, Diffenbach, or Davies-Colley operations are required to secure sufficient material to close the defect.

(4) *Unilateral Defects*.—Lane's, Lanelongue's, and H. A. Ferguson's operations are advised in unilateral defects.

**Technique in Operations for Bilateral Complete Cleft Palate.**<sup>1</sup>—"The muco-periosteal tissues are separated from the hard palate in the usual way, generally using Brophy's instruments. With curved scissors the soft palate is de-

---

<sup>1</sup> J. F. Baldwin, M. D., Columbus, Ohio.



tached from the hard palate by the usual transverse cut across the upper or nasal mucous membrane. Before making this transverse cut, the edge of the soft palate is split, for this purpose sharp-pointed, slightly curved scissors being used, and the tip of the uvula caught with tissue forceps. The edge is split back about one-eighth of an inch. (By




FIG. 155.—UNION OF ENTIRE CLEFT AFTER OPERATION ON CASE ILLUSTRATED IN FIGURE 154. Photograph would indicate that union is not complete, but cleft is closed completely.

the ordinary operation the edges of the soft palate are denuded by cutting off a strip of tissue. This is an unnecessary sacrifice, and does not give as broad a surface of apposition, and in case of failure there is less tissue to work with in a second operation.)

“In bringing the flaps together use a small sharply curved needle affixed to a handle, the handle being at right



angles to the needle. Instead of an eye at the tip of the needle there is a little hook. The needle is passed so that it is entered about one-eighth of an inch from the edge, is brought out at the bottom of the split, then passed across to the opposite side, where it enters at the bottom of the split on that side, and comes out one-eighth of an inch from the edge of the flap. The thread, or soft enameled copper wire which I have used of late, is caught in the hook and the needle withdrawn, carrying one end of the wire. The needle is passed in again at a distance of about one-fourth of an inch in the same way, and the other end of the wire is caught and drawn back. Both ends of the wire are now at one side of the fissure, and the loop on the opposite side, thus making a mattress suture. One after another the necessary sutures are introduced until all are in place, each being caught by hemostats to prevent entanglement of the ends. When all are in place the surfaces are thoroughly freed from blood, then approximation is secured by perforated shot. By the splitting of the soft palate the mattress stitch results in a turning downward of the oral mucous membrane, and upward of the nasal, thus securing about one-quarter of an inch of raw surface in close apposition. Lateral incisions, if necessary, are made close to the alveolar process on each side to take off the tension.



FIG. 156.—RESULT FROM HARE LIP OPERATION.

“Stitches are introduced into the tissues corresponding to the hard palate in the same way, except that here there is no splitting of the flap, but the introduction of the stitches



is made in such a way that the edges of the flaps are turned downward so that a broad surface of apposition is secured.

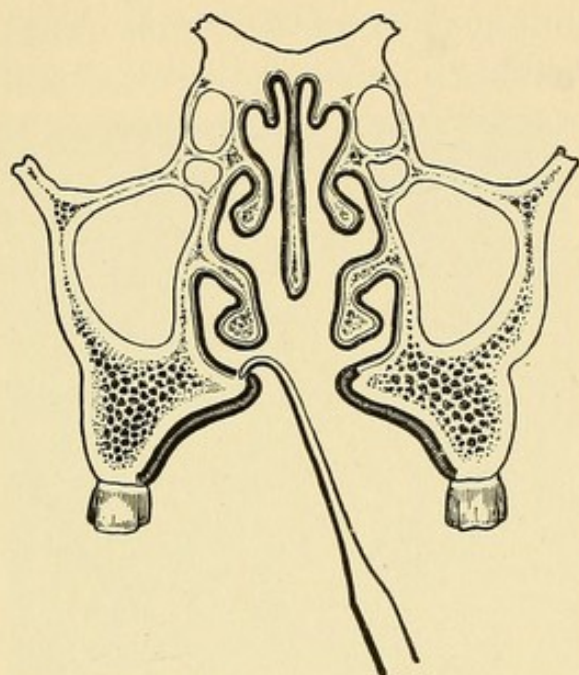


FIG. 157.—METHOD OF FORMING AND ADJUSTING FLAPS IN CLEFT-PALATE OPERATIONS. (Usually practiced by the Author.) Diagram of the hard palate showing the point at which section is made along the margin of the cleft but within the nasal cavity. Section is made from the anterior margin of the cleft to the posterior margin of the hard palate, with Fillebrown's hoe, and separated along the margin with the same instrument.

learn to enunciate properly."

*Roe's method*, which is a revival of Garretson's operation (see page 638, the latter's work), is described as follows: 1. Drill holes through margins of cleft one-half inch apart; (2) introduce wires through holes; (3) sever soft tissue and bone from alveolar

"The stitches should be removed in about ten days. When these cases are under my control, I operate on the hare lip as soon as the patient is brought to me, preferably within a few days after birth. Operation is made on the cleft palate when the child is one year old, so as to have the palate repaired before the child commences to talk. The older the child the easier the palate operation, but the more difficult for the child to

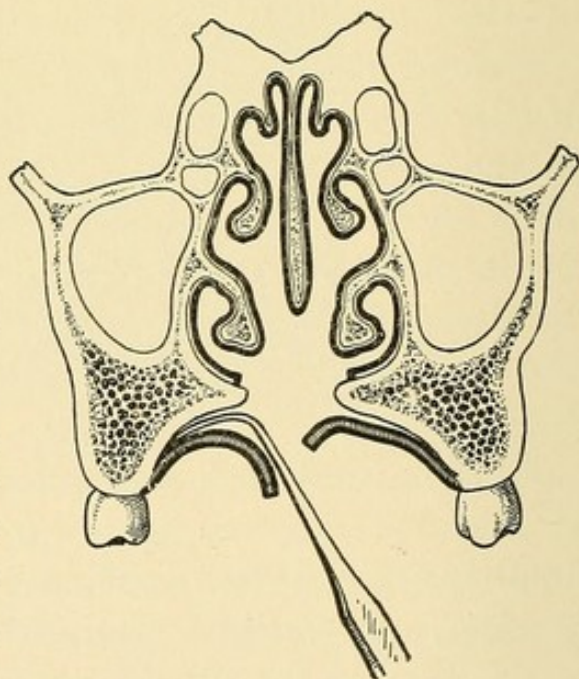


FIG. 158.—METHOD OF FORMING AND ADJUSTING FLAPS IN CLEFT-PALATE OPERATIONS. (Usually practiced by the Author.) Showing the usual method of making muco-periosteal flaps with a periosteotome, which is shown in figure 148.



process with scalpel and chisel; (4) force the palates toward each other; (5) freshen the margins of the cleft; (6) hold bones and soft palate securely together with the wires previously introduced.

**Unilateral Operations.**—Ferguson says: “The operation must be selected for the case, and not vice versa. To meet this condition, I have employed an operation with much success in cases where the roof of the mouth is like a Gothic arch—where the palate segments extend upward into the cleft in a more or less oblique manner, and where the cleft extends into one nostril. Two muco-periosteal flaps are liberated—one from the inner or nasal segment, and the other from the outer or oral segment. These flaps are overlapped, bringing the two raw surfaces in contact. These are held in position by two rows of interrupted silk sutures. This operation is suitable at all ages.

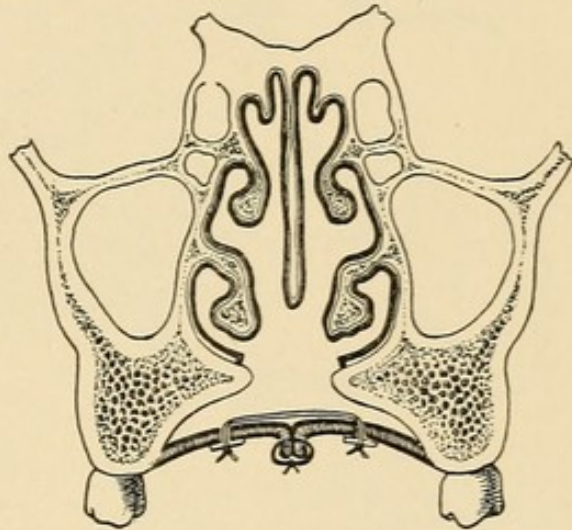


FIG. 159.—METHOD OF FORMING AND ADJUSTING FLAPS IN CLEFT-PALATE OPERATIONS. (Usually practiced by the Author.) Showing the flaps after sutures have been introduced. The plates and deep sutures shown in this figure are used by Brophy and some other operators, but they are found to be unnecessary by many operators, and the author does not use plates.

“The first muco-periosteal flap (figure 162) is taken from the nasal septum and inner segment of the hard palate, commencing as high in the nose as possible, and liberated from above downward to a point where it is hinged to the hard palate along the border of the teeth. The incision should be extended in the under surface of this segment of the soft palate and uvula, so as to cause the completed dissection to form one large flap from the hard and soft palates. The second flap (figure 162) is formed from the outer segment by making an incision along the teeth down



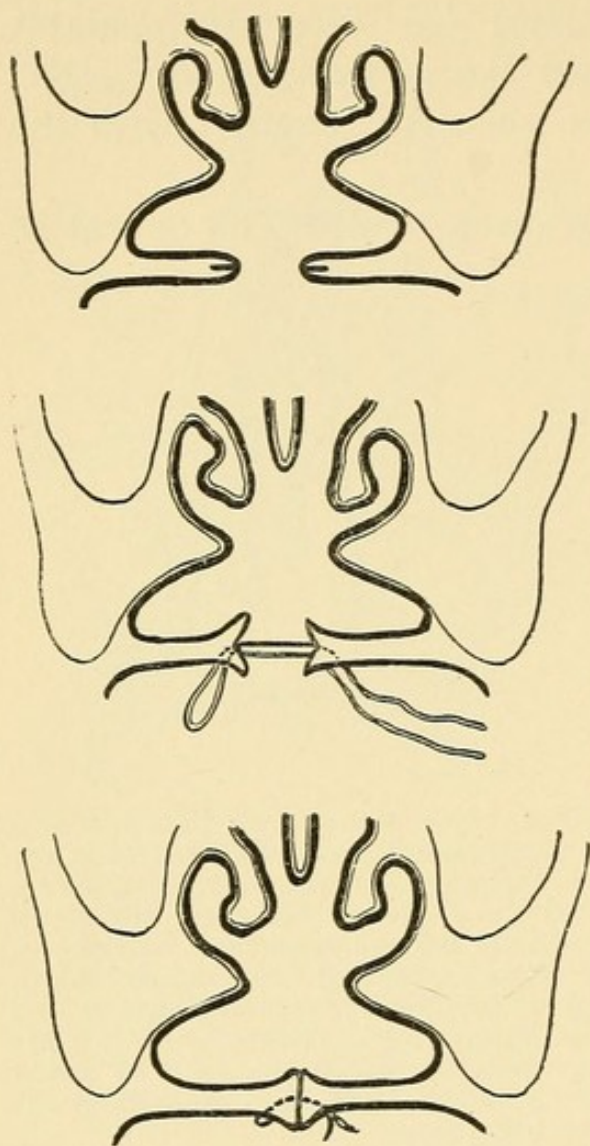


FIG. 160.—THE THREE STEPS IN CLOSING THE SOFT PALATE AND PRACTICALLY THE SAME METHOD OF CLOSING THE HARD PALATE. Illustrating Baldwin's Operation.

to the bone, and with a periosteal elevator detaching a muco-periosteal flap until it is hinged by the mucous membrane along the inner border of the bone segment.

“The soft palate and uvula segment on this side are then split along the anterior surface. The mucous membrane of the first flap faces downward, while that of the second flap faces upward, so that raw surface is placed to raw surface, the flaps being held in position by two rows of sutures (figure 163). The roof of the mouth is thus converted into a Norman arch.

“In all cases in which this operation was done, the speech (if the patient was old enough to talk) was improved. In order to benefit speech further, and lessen the nasal twang, the patient

should either begin to learn another language and forget the mother tongue (Ochsner), or be placed in charge of a teacher who has made a special study of this class of cases, one, for instance, who instructs deaf and dumb children.” (Owen).

*Lanelongue's Method.*—In unilateral cases Lanelongue constructed a quadrilateral-shaped flap proportionate to the dimensions of the gap from the mucous membrane of the contiguous surface of the nasal septum. A



long horizontal and two short perpendicular incisions outline the flap, which is then detached with a thin periosteotome and reflected downward, its base remaining attached

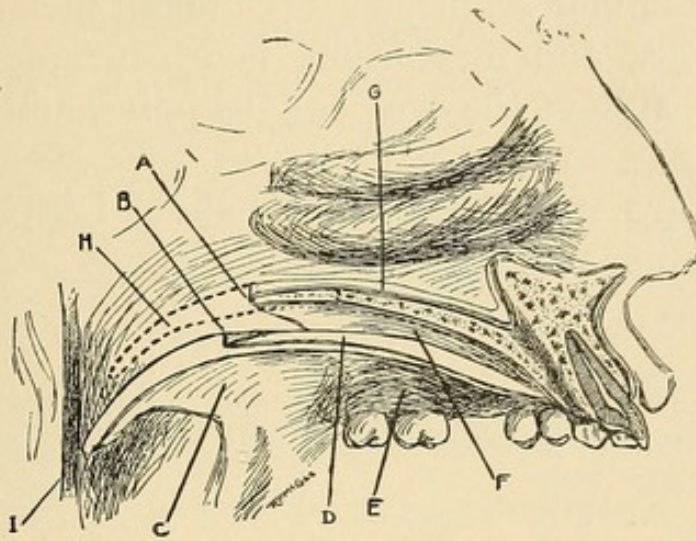


FIG. 161.—LEFT SUPERIOR MAXILLARY BONE WITH ASSOCIATIVE PARTS, ILLUSTRATING SURGERY OF THE PALATE. A. Posterior border of horizontal plate of left palate bone. B. Velum separated from muco-periosteum of nasal surface of palate bone. C. Velum separated from the hard palate, and the palate lengthened so as to restore palatal function. D. Periosteum denuded from hard palate. E. Palatal mucous membrane. F. Bones denuded of membrane. G. Nasal muco-periosteum. H. Position occupied by palate before operation. I. Posterior wall of the pharynx. (Brophy.)

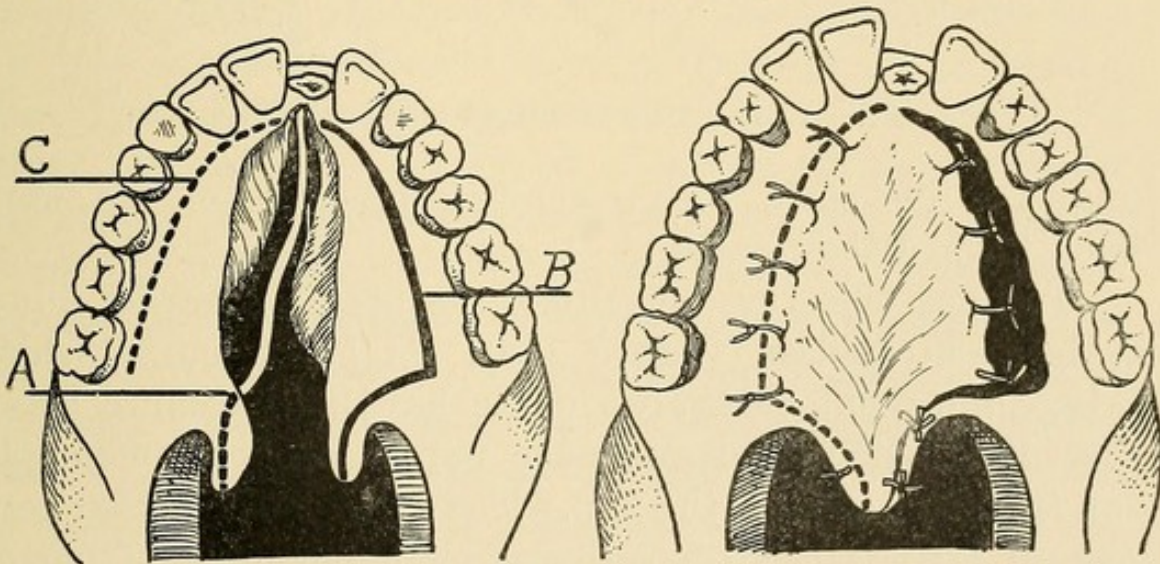


FIG. 162.—FERGUSON'S OPERATION FOR UNILATERAL CLEFT PALATE.

FIG. 163.—FERGUSON'S OPERATION COMPLETED.

below to the septum. The free border of this flap is then joined to the freshened outer border of the cleft with sutures. While this ingenious measure can be wisely em-



ployed as a *dernier ressort*, still it may also be useful as a supplementary step in the other methods of closure.

**Introduction of Sutures.**—To use a needle with an ordinary needle-holder requires a very small needle and skilful manipulations, and much time is consumed. The cervix needles, which have the eye near the point, and the end bent at right angles to the staff, answer quite well through the uvula, but are most difficult to handle between the bony clefts. The usual staphylorrhaphy needle is bent at right

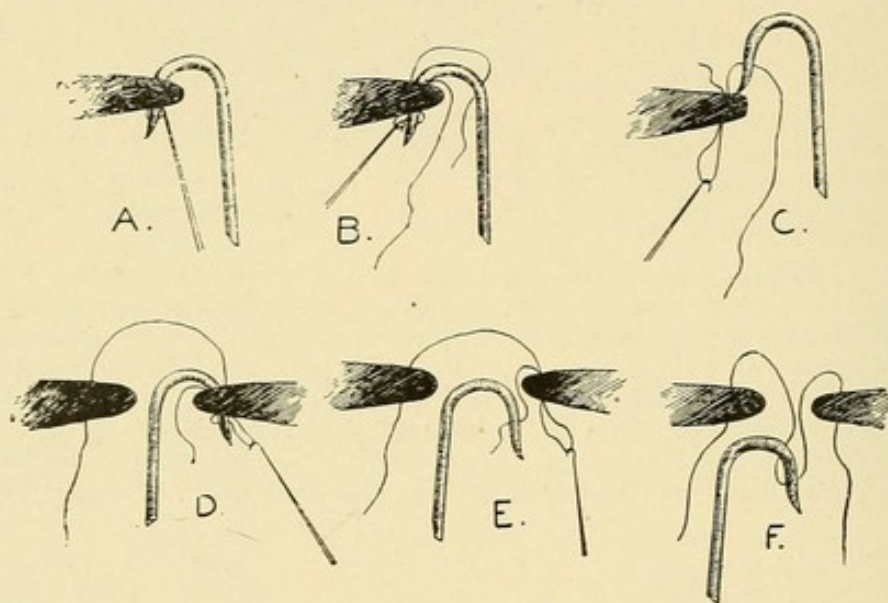


FIG. 164.—AUTHOR'S METHOD OF INTRODUCING SUTURES.

angles to the staff, with a very slight curve of the point back toward the handle.

To overcome the difficulties, the needle herewith illustrated was devised (figure 165). It has a curve which brings the point back toward the handle, the curve being just great enough to make the puncture back sufficiently far from the edge of the flap. The instrument shown here (figure 166) is necessary to complete the introduction of the suture skilfully. It has a ring on one end, bent at right angles to the staff with an opening large enough to admit the threaded needle. On the other end is a hook. The needle, after being loaded with the desired suture material, is passed through back of the flap into the nasal cavity.



It is then pushed through the flap from the nasal into the oral cavity. The ring end of the instrument containing the hook and ring above described is pressed against the flap to support it and prevent laceration. After the needle and suture pass through the flap, the hook is made to engage the suture on the side of the needle away from the staff (figure 164-B), and with traction the free end is drawn through into the oral cavity as the needle is pushed back into the nasal cavity (C). The needle, with the thread still in position, is turned around to the opposite side, and passed



FIG. 165.—ORIGINAL CURVED NEEDLE.



FIG. 166.—HOOK AND EYE.

through the flap as above described (D). As the thread is hooked up on the inside of the needle, the free end on the same side is let go, and the one on the opposite side held—otherwise the needle would be unthreaded. The hook is again passed around the suture external to the needle, as before (E), and as the thread is drawn through into the oral cavity, the needle is pushed back into the nasal cavity and drawn out between the flaps unthreaded. This method permits the introduction of sutures at the extreme anterior angle. It is done quickly, and no undue violence is done to the flaps. An important detail is that the hook must be passed around the suture on the side of the needle next the staff, on both sides, or when it is withdrawn, instead of its unthreading itself, it remains threaded and the two ends are drawn through the flaps on the two sides of the cleft (F). The thread may be drawn from the internal side of the needle, on both sides, and the steps are just the same.



## CHAPTER XXX

### DISEASES OF THE MAXILLARY AND OTHER SINUSES

#### ANATOMY

The sinuses accessory to the nasal cavity are the maxillary sinuses, the frontal sinuses, the ethmoid cells, and the cavities of the body of the sphenoid.

The mucous membrane which lines the nasal cavity, known as the Schneiderian membrane, is continuous through the various foramina of entrance into these cavities. The same membrane is continuous through the posterior nares over and around the soft palate, becoming the mucous membrane of the oral cavity, the difference between the membranes being in the variety of epithelium. The oral cavity, except the dorsal surface of the tongue, is lined with stratified epithelium, while the nose is lined with pavement, columnar and ciliated, and the upper part of the pharynx with columnar ciliated epithelium.

The maxilla is one of the most important bones of the face from a surgical point of view, and to the dentist the most important in the skeleton, on account of the many diseases to which it is liable. Next to the mandible, it is the largest bone of this region, and forms, by union with its fellow of the opposite side, the upper jaw. The two bones assist in the formation of three cavities, forming the roof of the oral cavity, the floor of the orbital cavity, and the external walls of the nasal cavities. They also enter into the formation of the zygomatic and sphenopalatine fossa, and the sphenomaxillary and pterygomaxillary fissures.



The cavity of the maxilla is the antrum of Highmore. It is pyramidal, with its apex outward and formed by the malar process, and its base formed by the lateral wall of the nasal cavity. Its superior boundary forms the floor

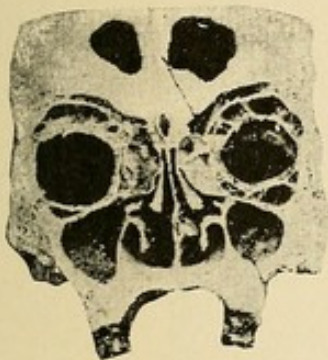


FIG. 167.—A SECTION CUT VERTICALLY IN THE REGION OF THE SECOND MOLAR TOOTH. The frontal sinuses will be observed passing well over the orbits, and the cell in the crista galli is clearly shown. The inner surfaces of the anterior walls of the bulla ethmoidalis will be observed extending inward toward the middle turbinate bones, the wire marking the infundibulum, the hiatus semilunaris, and the ostium maxillary sinus, the last named being small in proportion to the size of the skull.

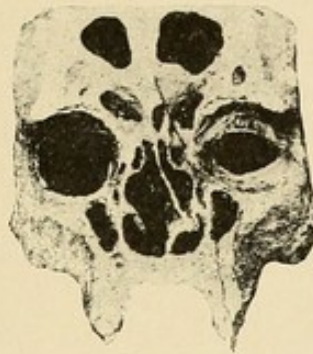


FIG. 168.—A TRANSVERSE VERTICAL SECTION. The anterior cut is made in the region of the premolar teeth. It will be noticed that the septum of the nose is deflected and the spur comes in contact with the right turbinal. The frontal sinuses are large, extending outward over the orbits. They also extend down below the middle of the orbit. Between the two frontal sinuses there is an interfrontal cell extending backward into the crista galli, which is shown in Fig. 167. It will be noticed that a wire passes from the right frontal sinus downward and is again seen in the antrum.

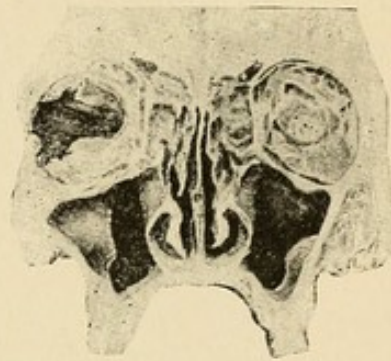


FIG. 169.—A SECTION CUT ANTERIORLY TO THE SECOND MOLAR TEETH. In this case the maxillary sinuses are almost cuboidal in shape and extend down below the level of the nose, and upward into the region of the middle ethmoidal cells. The inner walls are not straight, as they are in a typical skull. Beginning at the floor of the antrum, almost over the center of the dome of the mouth, the inner wall extends upward in a convex manner to the point at which the inferior turbinal projects into the nasal cavity. There is a direct communication with the anterior ethmoidal cells and the frontal sinuses.

(After Cryor.)

of the orbit, while its floor is formed by the alveolar process. Its anterior wall constitutes the face, while its posterior wall goes to form the zygomatic surface. Through its base, or inner wall, passes the only foramen of exit, leading into the nasal cavity, high up and well back, and terminating



in the middle meatus or under the middle turbinated bone. In the green state of the skull usually but one orifice exists, but in the prepared skull two are found, one of which is closed by the mucous membrane during life. Projecting lamina of bone are frequently found crossing the cavity, most frequently on the floor, separating the cavity into several compartments and making a most troublesome complication in diseased conditions.

There are also found projecting from the floor several

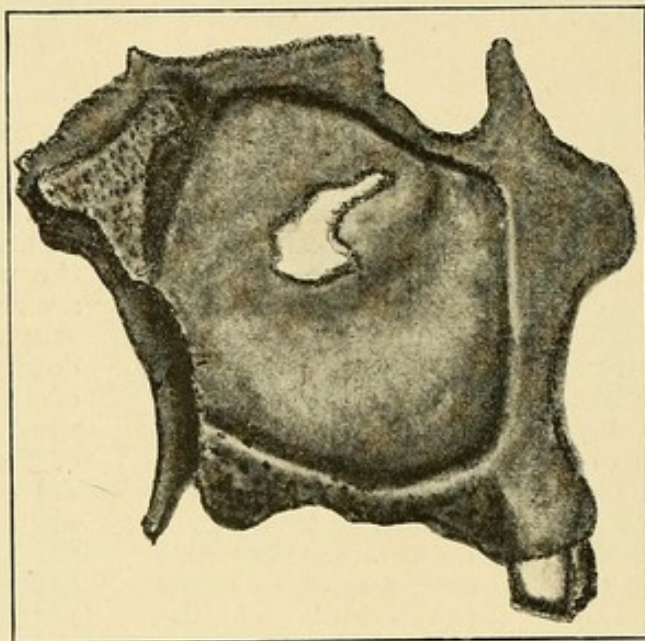


FIG. 170.—ANTERO-POSTERIOR SECTION THROUGH THE ANTRUM NEAR THE NASOANTRAL SEPTUM. Showing an unusually large antral cavity extending well forward and upward.

conical processes corresponding to the roots of the first and second molar teeth, which in some cases perforate the floor. Through the posterior wall pass the posterior dental canals for the transmission of the posterior dental nerves, a branch of the second division of the fifth nerve and a branch of the internal maxillary artery of the same name as the nerve.

Owing to the extreme thinness of the walls, which in places may even be absent, tumors or accumulations force out in every direction, encroaching upon adjacent parts, displacing the eyeball, occluding the nasal cavity, bulging



the cheek, and forcing down the alveolus and making pressure backward into the zygomatic fossa.

The maxillary cavity is situated immediately above the alveolar process. The base or internal wall, constituting

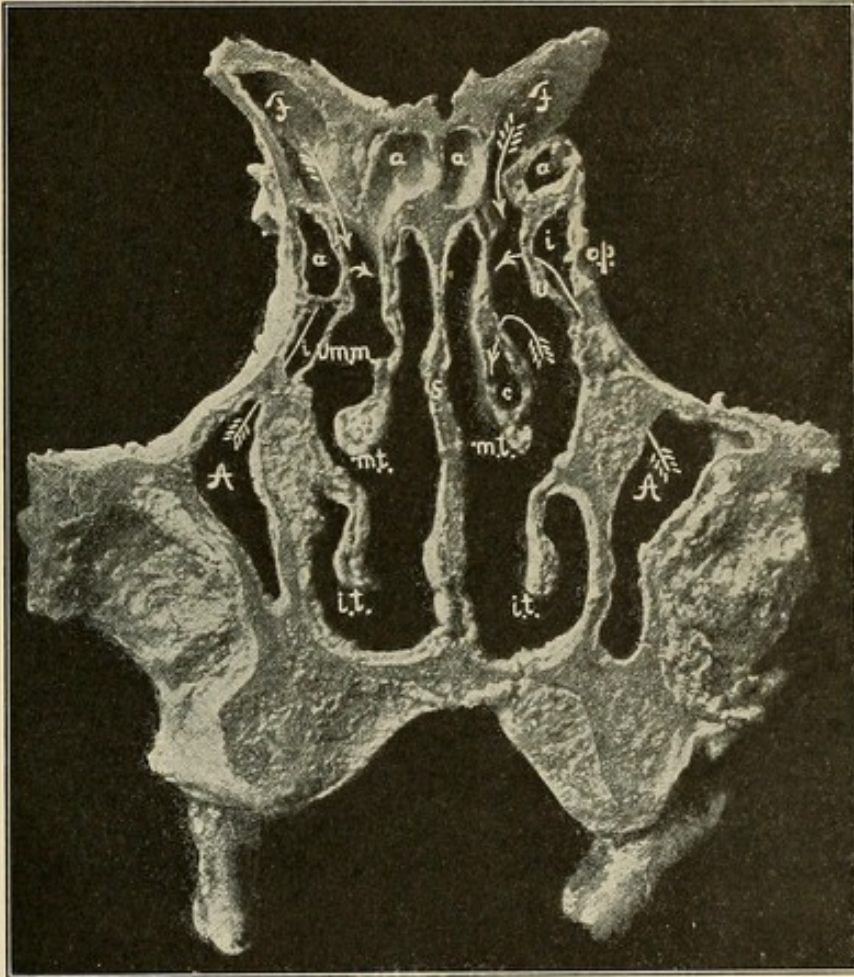


FIG. 171.—TRANSVERSE SECTION JUST ANTERIOR TO THE OSTIUM MAXILLARE. *F*, frontal sinuses, with arrows passing through their ostia directly into the middle meatus without entering the infundibulum (*i*); *a*, *a*, anterior ethmoid cells; *A*, antrum. Arrows pass into the infundibulum (*i*) through the ostium maxillare, thence through the hiatus semilunaris into the middle meatus under the middle turbinate bone. *U*, uncinate process, which is placed obliquely and forms the internal wall of the infundibulum; *s*, septum nasi; *m.t.*, middle turbinate. On the left side this turbinate contains a cell (*c*) which communicates with the middle meatus, as shown by an arrow. *i.t.*, inferior turbinate; *o.p.*, os planum. (Lathrop.)

the external wall of the nasal cavity, is immediately above and on a perpendicular line with the internal surface of the alveolar process from the second bicuspid backward to the last molar. A drill passed perpendicularly up through the roof of the mouth will enter the nasal cavity and not the



antrum. The apex of the antrum (as it is formed by the malar process of the maxilla) projects outward beyond the external alveolar line about one-half the length of the cavity. It begins at the canine fossa, or about perpendicular to the first bicuspid. The author saw a case where antral disease was suspected, because of a discharging sinus which termi-

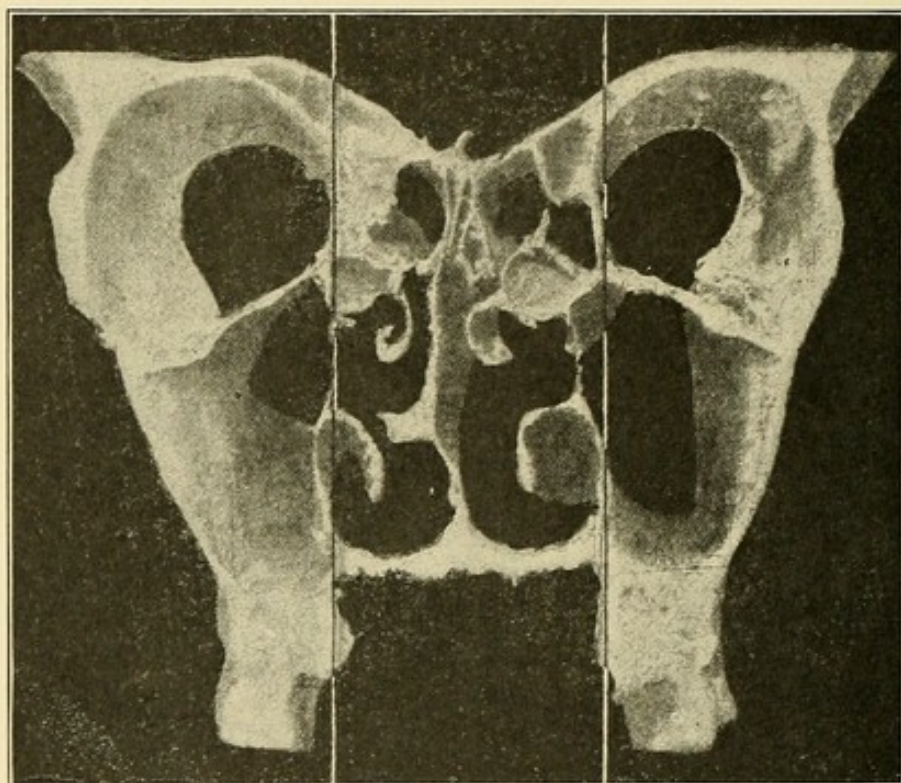


FIG. 172.—LATERAL WALL OF ANTRUM. This figure is introduced to show that the antral cavity does not extend internal to the internal surface of the alveolar process above the molar teeth. The following law may be appended, viz.: A line bisecting the nasoantral partition will pass along the internal surface of the alveolar process at the second molar. The point is that if a drill were passed through the roof of the mouth it would enter the nasal cavity. Or, to enter the antrum, the drill when passed through the socket of a tooth must be directed outward.

nated above the first bicuspid. Two operations were performed by a surgeon for antral disease, but a canine tooth was found up in the walls of the maxilla, anterior to the antrum, and removed. The antrum was not entered at either operation. It must be remembered that the antrum does not extend as far forward as the canine fossa.

*Drainage.*—The antral cavity has no normal drainage except through its orifice terminating in the middle meatus



of the nose. This opening ends in the hiatus semilunaris, which is in close proximity to the infundibulum, the opening from the frontal sinus, and drainage from the latter may readily pass into the antrum. Fluid has ready escape through the antral opening, but the nasal secretion does not enter this cavity because the unciform process in front of the opening acts as a guard, and fluid is deflected along the hiatus semilunaris. The antral or frontal mucous membrane normally secretes only enough mucus to keep these membranes moist and properly lubricated.

### DISEASES OF THE ANTRUM

Owing to the immediate proximity of this cavity to the field of dental operation, the surgery of the antrum concerns the dentist most. Certain pathological conditions of the mouth are so intimately associated with diseases of the antrum that a differential diagnosis is most difficult. Pain, swelling and face-ache are all characteristic of inflammatory changes about a tooth as well as of antral diseases. So, also, do suppurative changes about the alveolar process resemble antral suppuration, and it is difficult to determine which might have been the primary trouble. A thorough knowledge of the anatomy of the maxilla and of the general pathological changes occurring in this bone and in the soft structures about it is necessary if the dentist is to differentiate a true tooth change from one of a more severe character. Many teeth are sacrificed in making a diagnosis, when, with an intimate knowledge of every diseased condition about the mouth, they might have been preserved and a more prompt recovery might have been insured.

It must not be concluded that, because the antrum has a fistulous opening leading into the oral cavity, it is "diseased," for such an opening may exist without infection or suppuration.



**Classification.**—From an etiological standpoint the following would appear to be the best classification:

- (1) Diseases and injuries from teeth.
  - (a) Tooth extractions with a rupture into the antrum (through the floor).
  - (b) Carious teeth and alveolar abscess with an extension of the disease to the maxillary floor, finally destroying the muco-periosteal lining of the cavity.
- (2) Traumatism.
- (3) Acute infections.
  - (a) Inflammatory diseases of the nasal cavity, such as acute coryza, catarrh, and grip.
  - (b) The acute exanthematous and other fevers, such as scarlatina, measles, typhoid and pneumonia.
- (4) Neoplasms.
  - (a) Polypoid growths and mucous engorgement.
  - (b) Mucous cysts, or polypi, associated with nasal growths of the same sort.
  - (c) Other tumors and growths within the cavity or in its walls.
- (5) Destructive diseases of the bones.
  - (a) Osteomyelitis.
  - (b) Periostitis.
  - (c) Tuberculous disease.
  - (d) Syphilis.

(1) **Diseases and Injuries from Teeth.**—(a) *Extractions.*—Probably twenty-five per cent. of all cases of antral diseases are caused by tooth extractions. In an examination of many skulls it was found that the second roots of the second bicuspid and of the first and second molars not infrequently extended quite up to and sometimes through the floor of the antrum, leaving, after extraction, the soft structures only as a membranous protection. It must be



remembered that the roots of teeth are somewhat irregular in position, and they may be found at every angle, and curved in many varied directions. Not infrequently two roots of the molar project into the compact structures of the floor, and, if extraction was done for pain from acute inflammation about the roots, other inflammations may have preceded, resulting in destruction of the peridental membrane and ossification between them. In such a condition a portion of bone is usually carried along with the tooth, for the ossification is usually more firm than the thin plate of the bone constituting the floor of the antrum. Again, during the extraction of a root, the act of going down between the alveolar ridges for the root, may, instead of bringing it within the grasp of the instrument, push it in front and into the antral cavity.

It may also be stated that teeth sometimes grow upward instead of downward, and erupt into the antrum instead of through the alveolus. Marshall reports a case of this kind, with a history of suffering extending over a period of sixteen years, in which a tooth was dropped from the nose while the head was thrown forward.

(b) *Carious teeth* or alveolar abscess or devitalized pulp, or infection extending from periostitis, may by metastasis involve the periosteal lining of the antrum, finally infecting the mucous membrane of the cavity and producing a suppurative antritis. Marshall thinks that alveolar abscess is the most common factor in producing suppurative conditions of the antrum. There is a difference of opinion as to whether antral disease reaches the root of a tooth and produces, secondarily, an alveolar abscess, or whether carious teeth and primary abscess produce antral suppuration. Mears and several other authorities are of the latter opinion, while Dawburn, Stout and others oppose this position.

(2) **Traumatisms.**—Here may be enumerated traumatic causes other than those resulting from tooth extractions,



such as fracture into the cavity with involvement of the mucous membrane, punctures of the face by wood, or injuries due to missiles during fights or accidents. These are not frequent causes of disease of this cavity. Other foreign bodies, as bullets, etc., when they find lodgment in the antrum, cause suppurative disease of this cavity. In old sinuses following antral diseases, which are otherwise well, particles of food may gain access and thus set up a suppurative antritis, requiring the removal of the foreign substance before acute symptoms subside.

(3) **Acute Infections.**—(a) *Inflammatory diseases of the mucous membrane of the nasal cavity* may extend into the antrum, resulting in suppuration. Catarrhal affections, when atrophic, usually involve the antrum. This occurs quite commonly. Grip in many instances leaves suppurative diseases of the antrum as sequelæ. Repeated colds, the most manifest symptom of which is coryza, so common during the winter in damp climates, are a cause of antral suppuration by the extension of the germs from the nasal to the antral mucous membrane.

Acute frontal infection occurs quite frequently, but, owing to the perfect drainage which the course of the infundibulum furnishes to the frontal sinuses, chronic disease is quite rare. In considering antral suppuration due to, or associated with, nasal inflammation, the condition of the turbinate bones must be studied. In hypertrophic rhinitis the mucous membrane is so engorged and thickened that the nasal cavity is obstructed, which condition necessarily closes the antro-nasal orifice, and suppuration of the cavity may result.

(b) *The acute exanthematous diseases*, such as measles and scarlatina, are productive of antral disease. Facial erysipelas may extend to the nasal and antral mucous membrane, the streptococcic infection of the cavity does not readily subside, and a chronic suppurative disease is the result. Diphtheritic membrane not infrequently extends



from the pharynx through the posterior nares and into the antrum. The Klebs-Loeffler bacillus in its development of new membrane destroys the vitality of the tissues. To this is added the presence within the antrum of the cast-off membrane which will naturally be retained, and the constant exposure of all tissues to streptococcic infection accounts for antral suppuration as a sequela of this disease.

(4) **Neoplasms.**—Under this head may be included all growths from the antral mucous membrane or bony wall.

(a) *Polypus* is the most common variety of neoplasm. Peavler, of Bristol, Tenn., states that sixty-three per cent. of all cases of chronic diseases of the antrum of more than one year's standing are caused by, or have present, mucous polypi, but statistics from other sources do not substantiate this claim. Locelie, a Swiss specialist, gives the per cent. at thirty-five. It is a question whether nasal polypi cause antral disease or whether, as claimed by one writer, suppuration of the antrum does not cause the growth of the polypi. Certain it is that polypoid growths from the nasal mucous membrane so occlude the cavity as to obstruct the escape of the normal antral secretions, and the retained fluid eventually becomes suppurative by the entrance of pyogenic bacteria.

(b) *Mucous cysts* of the antrum develop gradually in every direction, resembling in this respect polypoid growths, but the absence of the latter in the nasal cavity does much to exclude them in diagnosis.

(c) *Other growths* found in the antrum are fibrous sarcoma, usually involving the bone as an osteosarcoma, and, in the aged, epithelioma.

Osteomic tumefaction also develops gradually in all directions. The author saw one case in which the entire maxilla became solid bone, the antrum being entirely obliterated. Sarcoma is associated with pain and develops rapidly in the course of two or three months, and there is usually some temperature. In empyema of the antrum there is



chill, fever, pain, emaciation and general impairment of the vital forces.

**Symptoms of Suppurative Antral Disease** (*Empyema of the Antrum*).—The symptoms of suppurative antral disease are as follows: 1st. *Pain*, which may be constant, but is usually paroxysmal. However, when drainage is good, it may be absent. It is characterized by an ache and is increased by colds and exposure to a damp, humid atmosphere, but is relieved by local heat. The pain is much like an ordinary neuralgia. It may be mistaken for toothache, and extractions are not infrequently made with this idea in mind. When antral disease is due to extension of inflammation from a suppuration about the root of a tooth, it is necessarily preceded by the ordinary symptoms of toothache, with acute swelling of the face. 2d. *Tenderness, on pressure*, of the entire maxilla, usually found extending to the teeth, elicited especially by percussion of the latter. 3d. *Swelling*, when the periosteum on the outside of the bone is involved. 4th. *Discoloration* with swelling. 5th. *Purulent discharge* from one side of the nose when the head is thrown forward with the suspected side upward, which discharge usually greatly reduces the intensity of the symptoms. It may be that the antranasal foramen is occluded, preventing the escape of the pus, in which case the liquid accumulates and makes pressure upon the walls, forcing them out in every direction, intensifying the symptoms of pain and discomfort. If a diagnosis is not made and an operation is not performed for relief of the retention, it usually spontaneously erupts either into the nasal or the oral cavity. During sleep the pus is unconsciously swallowed, producing a most disagreeable morning nausea and vomiting, if much has entered the stomach. Great distension closes the nasal cavity by forcing in the wall, and the floor of the orbit may be forced upward so as to displace the eyeball and disconcert the normal lines of vision of the two eyes. Tumefaction of the entire side of the face is pro-



duced. The discharge is usually very offensive and is due to the generation of hydrogen sulfid gas. The patient is sensible of a foul taste and smell. *Constitutional symptoms* are *rigors*, which may become chills, indicating pus accumulation and retention. These are followed by fever, loss of appetite, and general lowering of vitality.

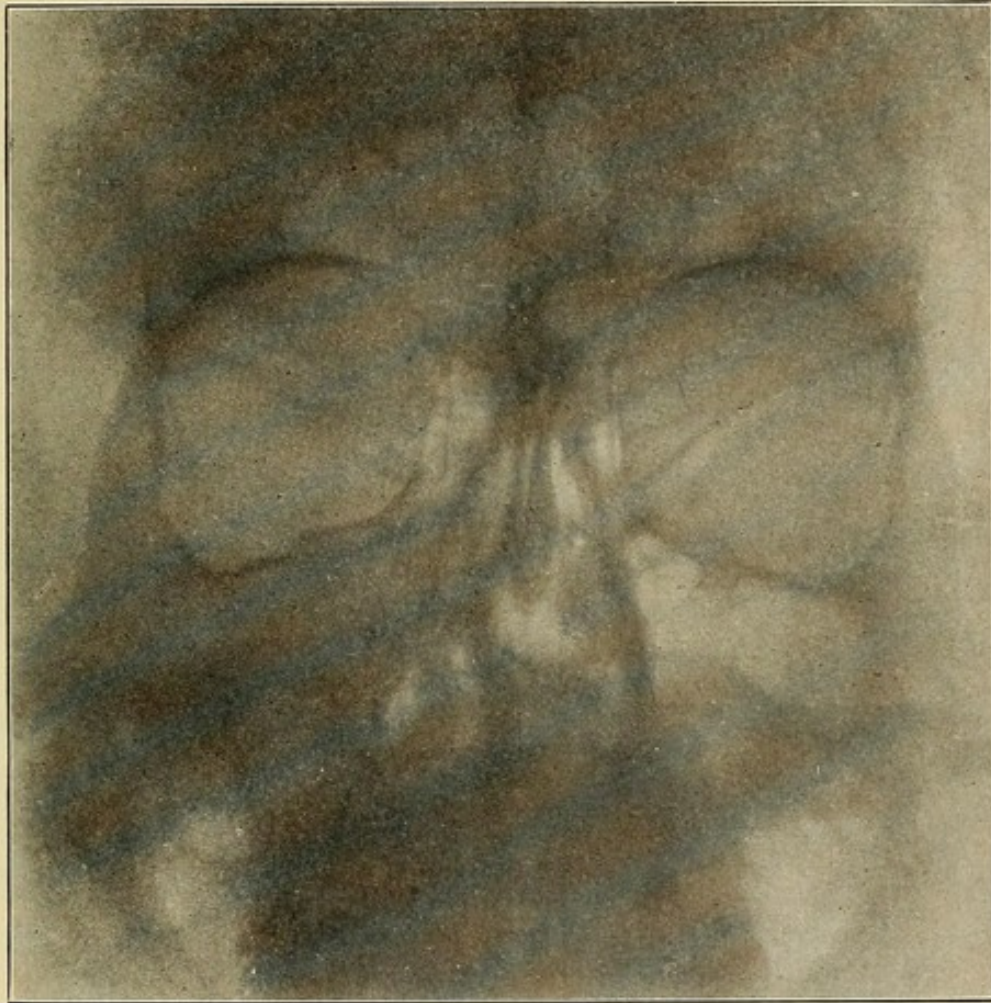


FIG. 173.—X-RAY SHOWING DISEASE OF ANTRUM ON RIGHT SIDE WITH PUS.  
(Dr. Geo. C. Johnston.)

**Diagnosis.**—The diagnosis of antral disease is based upon the following: 1, pain or face ache; 2, morning sickness; 3, unilateral discharge of pus from the nose, accelerated by position; 4, tenderness on percussion; 5, fetid breath; 6, slight swelling, not always present, except in retention; 7, exploratory operation, when no pus escapes, either through the nasoantral walls or through a root



socket, if one exists, or preferably through the outer wall of the antrum, of value in determining whether the cavity is normal; 8, transillumination of the maxilla, which is recommended. The eyelids should be closed to obtain the best results. It shows whether the antrum is empty or whether

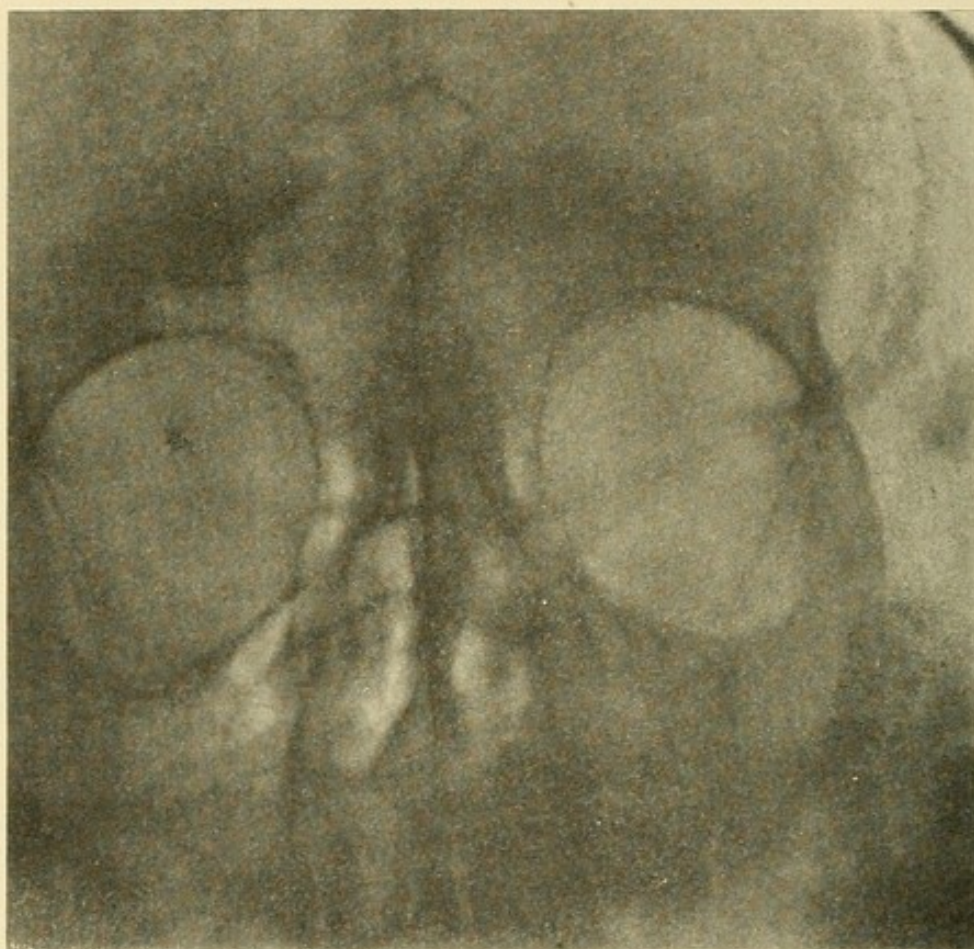


FIG. 174.—X-RAY SHOWING DISEASE OF THE ANTRAL AND FRONTAL SINUSES ON THE LEFT SIDE, WITH PUS. (Dr. Geo. C. Johnston.)

it contains some foreign content, but does not show whether it is pus, sarcoma, polypi or a cyst.

When tumors are present the history will be different. Growths develop usually very gradually, and the enlargement uniformly encroaches upon all structures. When polypoid disease is present there are usually also found similar growths in the nasal cavity. Cystic tumors develop without symptoms other than tumefaction, and possibly a sense of fullness. In destructive diseases of the bone result-



ing in secondary involvement of the antrum the history is a guide.

*Differential diagnosis* must be made from *tic douloureux*, in which the only symptom is pain; from exostosis, in which the principal symptom is the uniform enlargement; from malignant neoplasms, such as sarcoma, angioma, etc., which have few if any constitutional symptoms and no local symptoms, but tumefaction with a uniform development.

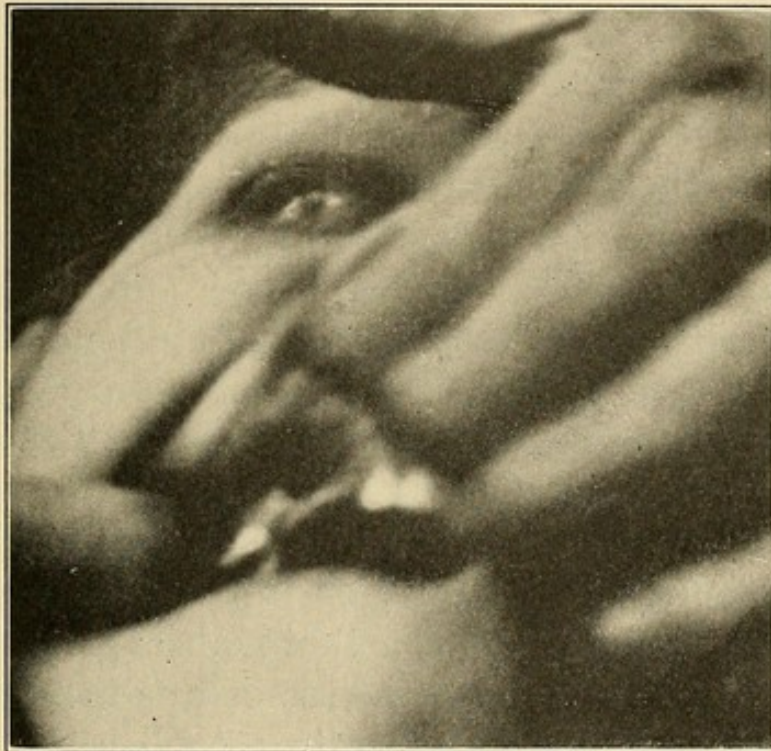


FIG. 175.—MOUTH AFTER ANTRAL OPERATION. In this case the entire floor of antrum was removed. Photograph was taken several months after operation, when architectural arrangement of the bone was so changed as to almost obliterate the cavity, being practically part of the mouth and requiring no packing or attention.

**Prognosis.**—Every case of antral disease due to infection of the mucous membrane or caused by non-malignant growths can be made comfortable, and the patient may go through life with comparative ease. It cannot be promised, however, that, when suppuration has existed for months or years, the opening formed to establish free drainage or an existing fistula can be closed. In other words, all active symptoms and suppurative conditions can be con-



trolled, but, as a rule, an antro-oral fistula is left—not a troublesome condition, however, since modern prosthetic appliances can so effectually shut off the fistula and prevent the entrance of liquids and food particles into the antrum.

**Treatment.**—The treatment of diseases of the antrum depends greatly upon the cause of the trouble, and this must be divined if prompt results are to be obtained. The treatment will be given under the several etiological heads.

When tooth extractions have produced an opening into the cavity through a root socket, resulting in infection and suppuration, the first step in treatment is to establish dependent drainage. In the second variety of cases, dependent upon the extension of inflammation from carious teeth or alveolar abscess, as has already been intimated, the treatment is drainage by the extraction of the offending tooth. The tooth to be removed is not easily selected, for a differentiation as to causes is, in many instances, impossible. When alveolar abscess exists and the usual local remedies do not control the discharge, or if the discharge appears to be from a definite point, a thorough exploration should be made with a fine probe. A free escape of pus following such an extraction will go far to establish the diagnosis, and a probe will confirm it. It is not, however, an easy matter to find the orifice. Continued discharge of pus should cause one to suspect antral disease or a destructive disease of the maxilla. It is not wise to perforate the antrum whenever such symptoms exist, for periostitis or syphilis or odontomata may have a sinus leading to the seat of the trouble which is without the antrum. For cases, see chapter on Tumors.

For the reason that an antrum, once open, generally remains open, great care should be practiced to avoid puncture. When an antrum is once opened, of course it can be claimed that there is antral disease, for infection and sup-



puration usually follow, whether they existed previous to the operation or not, and the claim is verified and a diagnosis falsely confirmed. When a diagnosis is made early, before destruction of the wall has occurred, and when no sinus exists, with proper medication and placing of the head in a position to favor drainage, there is no reason why recovery should not take place and practically a normal condition of the parts result.

Injuries to the bony wall rarely result in antral suppuration, unless the injury produces an antrooral fistula. The treatment does not differ from that for suppuration from other causes.

Inflammatory diseases of the nasal cavity which extend into the antrum require treatment for the correction of the nasal trouble. If catarrhal, this should be treated as such; if there is a hypertrophic condition of the turbinated bones, they should be amputated. In atrophic rhinitis local improvement of the tissues may be expected after a curettement of the cavity, followed by irrigation by or inhalation of a bland solution of salt and water at the temperature and specific gravity of the human blood. Infection of the antrum from acute coryza is not uncommon, a condition similar to infection of the frontal and ethmoid sinuses, called a "cold in the head," and chronic suppuration does not often follow.

As the claim is made by competent authorities that from thirty-five to sixty-three per cent. of all chronic antral diseases have nasal polypi as an associated condition, it is of vital importance that the nasal cavity be thoroughly explored. The first step in treatment is the removal of the nasal growths to ascertain whether true antral disease exists, or whether the nasal tumors occlude the antral orifice and prevent the escape of the normal fluid. Not infrequently what appear to be symptoms of antral disease disappear after the nasal cavity is evacuated and nasal breathing restored. When there is no question as to the exist-



ence of polypi in the antrum, an open operation should be done.

Mucous cysts of the antrum require similar treatment.

When the acute exanthemata, or fevers, have as a sequela suppurative antritis which does not yield to treatment through the nose in the course of several weeks, drainage should be established.

OPERATIONS.—*The Oral Route.*—When the tooth is involved or suspected, or when a tooth of election is absent, it is best to enter the antrum through a tooth socket. When no teeth have been extracted, or when the teeth are free from caries or other disease, the following method of entering the antrum is the practice of the author. The operation consists in entering the bone through the eminence back of the canine fossa just in front of the malar ridge, usually between the roots of the first and second molars, but low down, passing the drill upward, backward and inward, at an angle of from thirty to forty-five degrees, but above and between the roots of the teeth, so as to enter the cavity at the most dependent portion. It may be claimed for this operation, first, that it places the orifice at a point where the cheek rests against it, and when food is masticated on the opposite side (and antral patients should learn to do this), food particles seldom enter, and with care liquids may pass through the mouth without causing disturbance. Second, drainage is as good as when through the alveolus and better than when through the outer wall higher up.

Zerber opens and evacuates the antrum through the canine fossa, then resects the wall of the antrum between it and the middle meatus of the nose, working through the antrum. This opening is, in fact, nothing more than an enlargement of the natural ostium and serves for permanent drainage. The mucosa in the fossa canina is then sutured. He has applied this method on fifteen patients and has found it extremely satisfactory and permanently suc-



cessful for the most severe cases, especially those in which the antrum is full of recesses or the mucosa is much degenerated. The method combines the advantages of both the Decault-Kuster and the Siebenmann methods with extensive natural drainage.

*The Nasal Route.*—L. Rethi, of Vienna, says: “The technic of my operation is as follows: First of all, it is necessary to paint with a cocain-adrenalin solution the lower concha inside and outside and the external nasal wall of the lower and middle nasal duct. As only a small quantity of cocain is being used, there is no danger of intoxication. The operation is nearly entirely painless, and it is very seldom necessary to again use the cocain during the operation. The lower concha is then loosened from its insertion in its outer two-thirds with one or two clippings of the scissors and dissected in its inner one-third with a conchotome or curved scissors. The external wall is opened with a chisel through pressure of the hand, and the edges of the opening so formed are to be made even on all sides, not only upward but also downward, that is, toward the external wall of the lower as well as of the middle nasal duct, so that a broad opening for communication is formed between the maxillary antrum and the nose.”

The practice of using canula and tubes is a relic of by-gone days, and it is hardly conceivable that they could be used with advantage in the light of modern methods of practice. They act as an irritant and certainly obstruct the free exit of pus if they extend into the cavity, and, if they do not so extend, the pus is as liable to run back of as through the orifice of the tube. It may be claimed that they prevent closure of the fistula, but this is not necessary, for there is little tendency to close as long as pus formation continues, and when it ceases, if it closes of its own accord, well and good. Such a condition is quite desirable unless active symptoms follow.

Tumors of the antrum or maxilla do not differ from



growths from other structures about the face, and will not be considered under the head of antral disease.

(5) **Destructive Bone Diseases.**—Periostitis, osteomyelitis and tuberculosis as causes of disease of the antrum *a primari* are rare, and when the antrum becomes so involved it is secondary to disease beginning in the bone and will be considered under the head of Bone Diseases.

Syphilitic disease of the antrum is characterized by destructive processes similar to those found elsewhere, and will receive no discussion here.



## CHAPTER XXXI

### FACIAL NEURALGIA

Neuralgia is a functional disturbance of a nerve, characterized by pain along its course, without local symptoms, except possibly a slight flush, and with no constitutional symptoms other than those which may be considered causative factors. The subject matter contained in this chapter applies especially to the fifth nerve.

Neuralgia is a disease of middle and advanced life. It occurs in the sexes about equally. Many things are considered as *causes*. It most frequently develops in debilitated, anemic, or neurasthenic persons, and is associated with constitutional diseases, such as syphilis, rheumatism, malaria, gout, etc. It is difficult in all cases to find an exciting cause. Neuralgia is no doubt most frequently due to some irritation about the teeth. Impaction of teeth and the roots of teeth, and injuries, such as fractures and contusions, may all be followed by neuralgia. Caries, suppuration, exposed pulp or denuded periosteum communicating with a very harmless-appearing sinus, latent necrosis, badly adjusted crowns, filling of teeth without regard to the proper preparation of cavities or with failure to make the proper pressure at all points are causes. Use of arsenic and other drugs in cavities may also be causes. The author once saw a case of neuralgia caused by a few drops of urine being splashed against the conjunctiva, which was followed by conjunctivitis and cellulitis of the side of the face and forehead. The pain had been almost constant for six years, coming and going in varying degrees of severity. Damp climates and humidity exaggerate neuralgia.



How a small irritation may give rise to the most painful and most widely distributed of reflex neuroses is well illustrated by a case from the practice of a dentist, Herrman of Halle. He says: "A man of forty-seven had suffered for twenty years with an intense pain, which began in the frontal region, but afterward involved the whole right side of the face and neck, and ultimately resulted in periodical mental excitement accompanied by delusions. A score of doctors and most varied remedial measures had been ineffectual in affording relief. Finally he sought admission to an asylum, where the physicians hit upon a misplaced wisdom tooth as the morbid manifestation and called in a dentist to extract it. In addition to malposition, its root had large exostoses, as was seen on removal under chloroform. A year has now elapsed since the operation, and the patient has been free during this period of all psychological or neurotic disturbance."

A case of persistent facial neuralgia due to an unerupted cuspid tooth is described by Kirk. (See chapter on Reflex Neuroses.)

**Symptoms.**—Pain is not constant as a rule, but there are intermissions for a day or more—possibly a week—between attacks, but in some cases it is practically continuous. It is most severe, and the muscles on the affected side of the face twitch during paroxysms. It is the practice of patients to throw their hands up and press the palms firmly against the skin to quiet the muscles, with the idea of affording relief. The twitching will be confined to muscles supplied by the division of the nerve affected. *Tender points* are found along the nerve trunks at points where they pass over bony prominences. If the first division of the fifth nerve is affected, one point will be at the supra-orbital notch. If the second division, pressure over the infraorbital foramen will cause pain; and in the third division the nerve is most superficial at the mental foramen, and pressure here usually causes pain. Tenderness may be



found over the entire involved area, the lips or tongue being so sensitive at times as to cause the patients to avoid eating when suffering from an attack. It is usual for the skin over the area of distribution of the affected nerve to be flushed during a paroxysm. Vasomotor or trophic changes are not present, since these functions are controlled by the sympathetic system. Faculties of heat and cold sensation, etc., are impaired. A cold sensation over the cheek, forehead or chin is experienced by one patient, while the opposite may be the experience of another. In neuralgia *per se* there is no temperature or constitutional disturbance, and when these are present the cause of the pain is inflammatory changes. Arterial sclerosis is often found as an associated condition, but whether it is the cause or the result has not been determined. The exact location of the cause in many cases is difficult to determine. Some patients are entirely relieved by peripheral operations, others require central resections, and even then the relief is in some cases only temporary.

The right fifth nerve is affected twice as often as the left. In fifty-three cases reported by Tiffany, ten were of the third division, six of the second, twenty-two of all divisions, and the remaining fourteen of the second and third combined. In no case was the first affected alone.

**Diagnosis.**—Diagnosis must be made from all inflammatory diseases of the bones and structures of the face. Osteomyelitis, periostitis, syphilis, antral diseases, diseases of the teeth, and ulcerative and cancerous diseases of the soft structures must all be taken into account and excluded. When there is persistent pain anywhere within the area of distribution of the fifth nerve, without a well-defined cause elsewhere, the teeth should be thoroughly examined, since in the majority of cases the irritant will be found there. Neuritis, which is an inflammation of the connective tissue of a nerve, is an acute process, but may be followed by neuralgia. Necrosis of the alveolar process, with removal of



considerable bone, which is necessarily followed by the formation of extensive cicatrices, involves the nerve terminals or a considerable trunk and produces severe neuralgia. In malarial neuralgia, in the form of "brow ague," the pain comes on at a particular hour every day, and, after continuing for from one to three hours, disappears entirely. Syphilitic pain is more severe at night.

**Prognosis.**—Andrews presents the results of his experience with relapsing cases. He says that "neurectomy performed for *tic douloureux* permanently cures some patients and effectually stops the pain of nearly all of the rest for a period of from four to six months to nearly two years, but the majority sooner or later relapse." Clinical experience has demonstrated to the author the valuable fact that these relapsing cases may be freed from their pain for considerable intervals of time by operations repeated at the site of the original operative cicatrix. According to Andrews, it is not necessary to find the central stump of this resected nerve and subject it directly either to traction or excision; it suffices simply to remove the scar-tissue resulting from the previous operation. The immediate and prolonged benefit resulting from the avulsion of the scar-tissue is explained by the stretching to which the nerve stump is subjected in thus forcibly tearing away the cicatrix.

**Treatment.**—Treatment may be divided into: 1. medical treatment; 2. injections; 3. operations, which may be peripheral or deep.

1. MEDICAL TREATMENT.—In all cases of facial neuralgia, medical treatment should be thoroughly tried before operations are performed. The chief remedies are belladonna, aconite, strychnia, gelsemium, and large doses of quinin. Locally, heat, electricity, menthol and ether are used with benefit. The coal-tar anodynes afford relief in some cases. Pain recurring daily, known as "brow ague," due to malaria, is quite common in malarial regions, and is readily



cured with arsenic. Begin giving Fowler's solution with five drops three times daily, increasing by one drop each day to fifteen, or even thirty, drop doses. When pain disappears, gradually diminish the dose.

2. INJECTIONS.—*Deep injections* of alcohol as a method of relieving the intense pain of facial neuralgia were introduced by Levy and Baudouin, of Saltpetrière, and Dr. Patrick, of Chicago, made a personal study of their method and used it upon one hundred cases, with quite flattering results. He may be quoted as follows:

“The aim is to reach the inferior maxillary branch of the fifth nerve just after its exit from the foramen ovale, the superior maxillary branch just after its exit from the foramen rotundum, and the first or supraorbital branch immediately after its entrance into the orbit, and to place an injection of alcohol at these points, within the nerve sheath if possible. The instrument employed is a straight needle, 1.5 mm. in diameter and 10 cm. long, fitted with a stylet exactly like a trocar, except that in this case the needle is sharp and the stylet blunt. The needle is marked in centimeters from the point up to five, so that the operator may know what depth he has reached. In making the operation the stylet is at first slightly withdrawn, and the puncture is made with the sharp point of the needle. After the point is well through the skin and subcutaneous tissue, the stylet is pushed home. In this position its end is flush with the needle point, making a blunt instrument for the remainder of the penetration; this avoids injury of deep blood vessels. Having obtained the proper depth, the stylet is withdrawn, the syringe, already filled, is fitted to the needle, and the injection is slowly made. Ordinarily the needle should be allowed to remain *in situ* a couple of minutes to avoid any oozing from the puncture. Pressure for a few minutes has always controlled such oozing. Sometimes there is no bleeding. A touch of collodion serves as dressing.

“The solution first used is 75 per cent. alcohol contain-



ing chloroform and cocain. The following should be used to begin with:

Cocain hydrochlorate.....	gr. i
Chloroform .....	m x
Alcohol .....	z iii
Distilled water, enough to make	z ss
Mix.	

“Of this 2 c.c. are injected. For succeeding injections the proportion of alcohol is increased so that if several are needed for the same branch, the strength of the solution

reaches about 90 per cent. For reaching the different branches of the nerve the procedure is as follows: (Figure 176.)

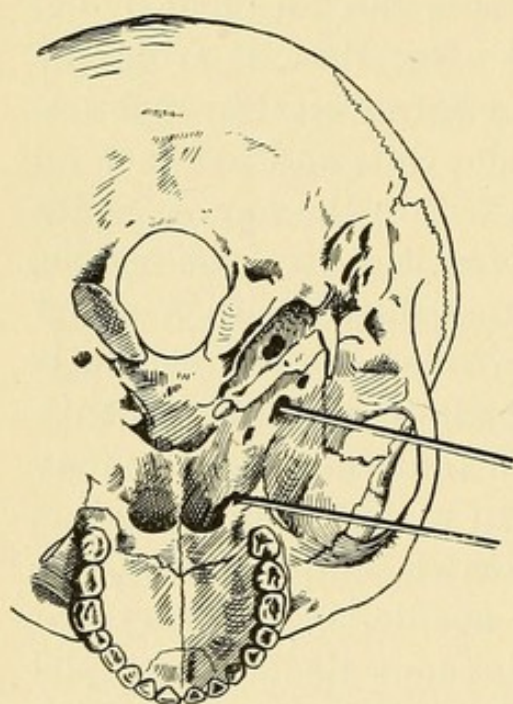


FIG. 176.—DEEP INJECTIONS FOR NEURALGIA. Showing the course the needles take under the zygomatic arch to reach the point of exit of the second and third divisions of the fifth nerve at the foramina rotundum and ovale.

“For the inferior branch the needle is inserted at the lower border of the zygoma 2.5 cm. in front of the descending root of the zygoma, which always can be felt, and almost coincides with the anterior bony border of the external auditory meatus. The needle is directed slightly upward, so as to hug the base of the skull, and a little backward, and at a depth of 4 cm. should reach the nerve at its exit from the cranium.

“To attain the middle branch, the line of the posterior border of the ascending (orbital) process of the malar bone (ascending to articulate with the frontal) is prolonged to the lower border of the zygoma and the needle inserted .5 cm. posterior to this point. It is directed vertically to the anteroposterior line,



but inclined slightly upward in a direction which would attain, at the depth of the foramen rotundum, the level of the inferior extremity of the nasal bones. At a depth of 5 cm. the nerve is reached at its emergence from the foramen rotundum into the pterygomaxillary fossa."

Levy and Baudouin advise reaching the supraorbital branch by inserting the needle at the external margin of the orbit opposite the frontomalar articulation (suture), passing it along the external orbital wall to a depth of 3.5 to 4 cm., when the point should reach the nerve. This injection Dr. Patrick has made but once.

*Superficial Injections.*—Before major operations are performed it is advisable to inject alcohol into the nerves at their points of exit from the anterior surface of the skull.

For the *first division*, the needle should enter the supra-orbital notch. For the *second division*, the infraorbital foramen is selected, the needle passing well into the bone. For the *third division*, the needle should be passed into the mental foramen in the same manner.

The *solution* to be used is that given above for deep injections.

3. OPERATIONS.—The question of operating is under debate, and the time to operate is just as unsettled. One operator advises an early operation, while another recommends delay, using medicines and other means, hoping that the cause will be removed short of a major operation. The various procedures recommended below are those usually practiced, in the order in which they are given.

Peripheral operations are divided as follows: (a) Nerve stretching; (b) avulsion; (c) neurotomy; (d) neurectomy; (e) deep operations.

(a) *Nerve stretching* consists in exposing the nerve by cutting down to the sheath at the most superficial point; isolating it by careful dissection, and, if it be the supra- or infraorbital, passing a blunt hook beneath it, and making sufficient traction in both directions. Vogt says that a nerve



can be stretched one-twentieth of its length. Considerable tension may be made, since the simple act of stretching is of questionable value if stopped short of a rupture of the fibers.

(b) *Avulsion* of Thiersch consists in carrying stretching to the point of completely tearing the nerve away, both from its periphery as well as from the deeper structures. For neuralgia of the *ophthalmic* division, an incision is made over the superior orbital notch, the nerve is isolated, and seized with a hemostat. By gradually twisting toward the periphery, the terminal trunks are drawn from beneath the skin for possibly an inch. The nerve is freed from the notch, or, if a foramen exists, chiseled away, care being taken to avoid injuring the nerve, and while slight traction is being made upon the nerve with a hemostat it is dissected away from other structures with a narrow, blunt periosteotome as far back as practicable. The nerve is now wound about the forceps until it gives away. The traction thus made is supposed to have a beneficial influence upon the nerve trunk even back as far as its origin from the Gasserian ganglion. Avulsion of the *second* division is done much in the same way. A "T" incision is made over the infraorbital foramen, the stem of the incision extending downward through the cheek. After the nerve is exposed, it may be torn from its peripheral attachment. It is now necessary to open the canal by chiseling away the bone, making the opening sufficiently large to permit the nerve to be forced back along the floor of the orbit to near its apex. This is done with a narrow periosteal elevator. The nerve thus freed is grasped as deeply down as possible by a narrow but strong forceps, and by tugging and twisting may be torn from its exit through the foramen rotundum. Torsion of the nerve must be done very slowly, gradually winding the nerve about the forceps. The same operation may be made for neuralgia of the *mandibular* nerve, the traction being made as the nerve makes its exit, or a portion



of the nerve may be exposed by chiseling the bone away. It is thought impossible to remove the entire nerve back as far as the last tooth, in this manner accomplishing as much as

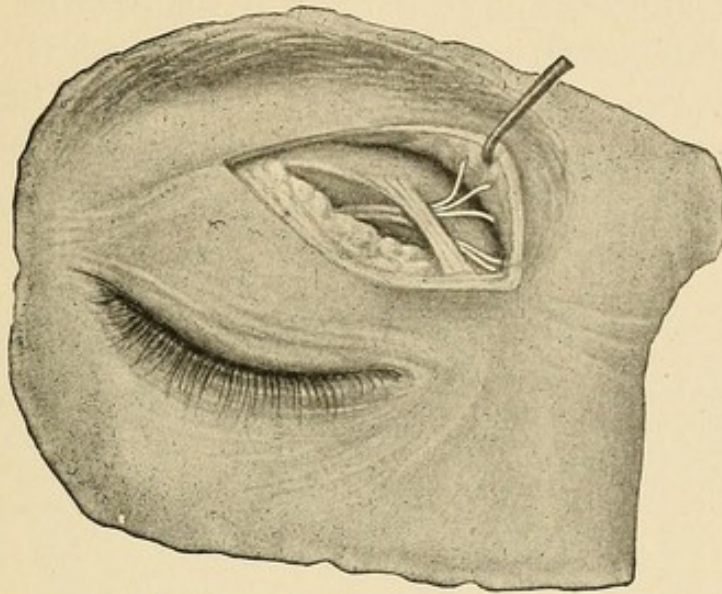


FIG. 177.—METHOD OF EXPOSING THE SUPRAORBITAL BRANCH OF THE FIFTH NERVE.

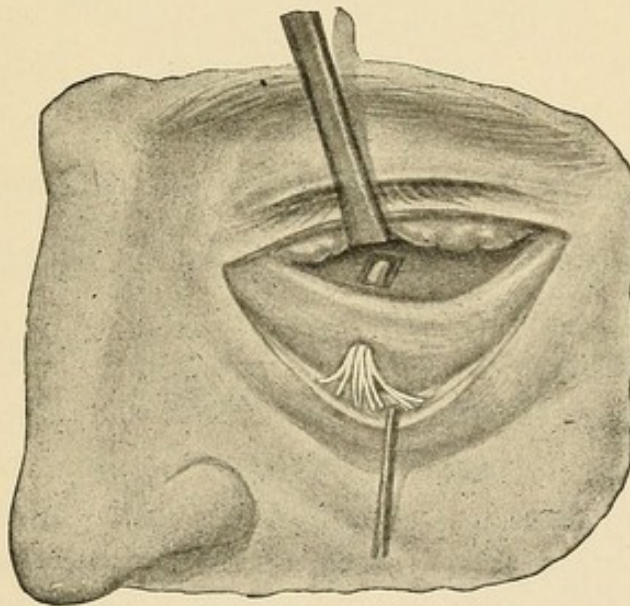


FIG. 178.—EXPOSED INFRAORBITAL BRANCH OF THE FIFTH NERVE AS IT EMERGES THROUGH THE INFRAORBITAL FORAMEN, ALSO WHERE IT RESTS IN THE GROOVE ALONG THE FLOOR OF THE ORBIT.

can be done by neurotomy at the inferior dental canal. When simple avulsion of the third division of the nerve, as shown in figure 179, does not give relief, the bone may be chiseled away down to the central canal from the mental



foramen. An inch or more of the central canal may be opened in this way through the mouth. The nerve is now lifted from the vessels as it rests in the canal, and by grasping it well back, it may be torn away toward the inferior dental foramen. Or, if it is thought best, a screw probe may be introduced into the canal and pushed back as far as desired to the inferior dental foramen and the nerve destroyed by twisting. In two cases this procedure was prac-

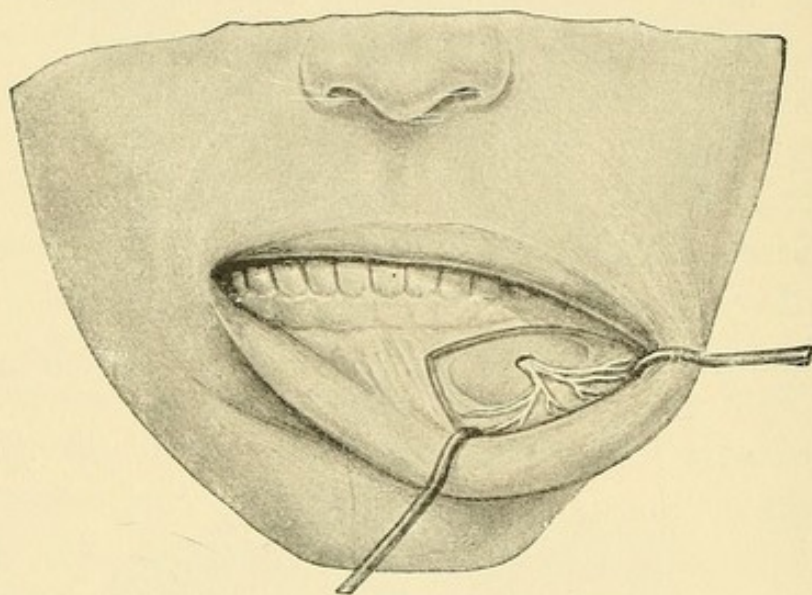


FIG. 179.—MENTAL BRANCH AT FORAMEN AS EXPOSED THROUGH THE MOUTH.

ticed with success. There were no complications during or following these operations.

(c) *Neurotomy*, or nerve section, is the division of a nerve in its course, and is practiced for the relief of pain or spasm. The nerve is exposed, section is made with scissors or knife, and the wound is closed. Relief usually follows, but it is generally temporary, since union of the cut ends takes place in many instances, function is reëstablished, and pain returns as a consequence.

(d) *Neurectomy* is the removal of a section of a nerve of sufficient length to guarantee that the nerve will not reunite. Incision through the skin for superficial operations is made as for stretching and avulsion, except that it may be longer, in order that more of the nerve may be exposed.



Section is made of the ophthalmic division as its branches emerge from the skull, as above described. Nerves may be resected at any point along their course, but such points have been selected as to bring the nerve trunk as near the surface as possible, or such routes have been chosen as would offer the least resistance to an entrance.

(e) Exclusive of the superficial operations already described, each of the three branches of the fifth nerve may be reached at its exit from the base of the skull. The Gasserian ganglion has frequently been removed from within the cranial cavity, but owing to the danger attending this operation, and because of the success of alcohol injections, it is not so frequently resorted to as it formerly was.



## CHAPTER XXXII

### THE SALIVARY GLANDS

*Congenital absence* and atrophy of the parotid or other salivary glands is a rare condition. Their absence would attract little attention previous to the third year, since their perfect development and functional activity does not occur until about that time. The absence of one or two glands would not be discovered, since a compensatory function would be performed by the remaining glands.

### DISEASES OF THE SALIVARY GLANDS

The pathological conditions requiring treatment may be divided into:

1. Acute infection.
2. Suppuration.
3. Injuries of the glands or ducts resulting in fistula.
4. Concretions in the glands or ducts.
5. Obstructions of the ducts other than concretions.
6. Malignant growths.

1. **Acute Infection.**—Acute infection of the salivary glands is usually called parotitis or mumps. It is an acute, specific, contagious, self-limited infection of the parotid gland, attacking principally the young. Boys are more liable to it than girls. It may develop at any age, but is rarely seen beyond middle life. It may be bilateral or unilateral. One of the chief *symptoms* is pain, increased by chewing and swallowing. The use of acids, as vinegar, produces an



ache of the affected parts. Swelling is seen early and is located immediately under the lobe of the ear, pushing this organ out beyond the normal line. If the swelling is below the ear, leaving a depression between the ear and the tumor, mumps may be excluded. There is no redness, heat, induration or fluctuation, and very little constitutional disturbance. The disease develops rapidly and leaves suddenly. It is rarely followed by suppuration. *Complications* are orchitis in the male, and ovaritis or mastitis in the female, in which cases the functional powers of the organs affected are destroyed if the inflammation has been extensive. The duration is about ten days when no complications develop. There is immunity against subsequent attacks, if both glands have been involved; otherwise the remaining gland may become infected.

*Treatment.*—The treatment consists in the use of salines to keep the alimentary canal free from torpidity. Locally, hot applications and stimulating aliments are all that is required. In an adult, recumbency should be required, since there is then less danger of metastatic infection of other parts.

2. **Suppuration.**—Acute enlargement of the salivary glands, principally of the parotid, has been known to follow fevers and septic inflammation of other parts. Parotitis is frequently associated with abdominal infections. Hanau reports five cases of suppurative inflammation of the salivary glands, two with appendicitis, one each with pneumonia, phthisis and thrush. One had pyemic parotitis of both glands. Wlardimirow, of Moscow, reports three cases of acute inflammation of the submaxillary glands. The symptoms are like mumps, and in one of the cases a brother of the patient had the mumps at the same time. In deep-seated inflammations of the glands, running a rapid course and resulting from streptococcic infection, a grave prognosis must be given, since suppuration is almost always the result and the gland sometimes breaks down into a gan-



grenous mass. The pus burrows into the deeper structures, and may open into the ear, blood vessels, air passages, or the thoracic cavity, resulting in serious complications. Other abscesses may develop, increasing the gravity of the trouble.

*Treatment.*—The treatment consists in early and effectual evacuation, and constant disinfection of the oral cavity.

**3. Injuries of the Glands or Ducts Resulting in Fistula.**  
—Injuries of the ducts of the salivary glands may occur, resulting in a fistula of the duct at the point of injury, such as wounds, or cuts during fights, surgical operations, etc. In suppuration about the glands requiring incision, the duct may be cut, and Shelly reports a case of this kind, while Spitzka reports a case where Stenson's duct was divided during excision of a tumor of the face. In fistula of Stenson's duct the orifice is usually situated over the buccinator muscle. The orifice is granular and surrounded by cicatricial tissue. The normal fluid, which is viscid, is discharged constantly, but in increasing quantity during mastication. A small blunt-pointed probe can usually be passed into the duct, its course being horizontally backward and inward.

*Treatment.*—The treatment of recent cases resulting from clean cuts consists in adjusting the ends with catgut. The wounds usually heal if properly adjusted. In chronic cases the orifice of the fistula should be cauterized, and if there is an oral orifice closure will usually follow. When this is absent there is but one thing to do, viz., to reestablish an internal opening. Agnew suggests an effective and simple method of closing fistula of Stenson's duct. He says: "Everting the cheek with the thumb on the inside and the fingers on the outside, a curved needle armed with a silk thread is carried beneath and around the duct, a short distance posterior to where it opens into the mouth, both the entrance and exit of the needle being on the mucous surface



of the mouth and not deep enough to reach the integument of the cheek. The needle is now detached from the thread, and the ends of the latter, after being tied together, are brought out of the corner of the mouth and secured to the outside of the face by a strip of adhesive plaster. As the thread ulcerates its way through the included tissues, the duct is separated from the cheek, causing the saliva to flow

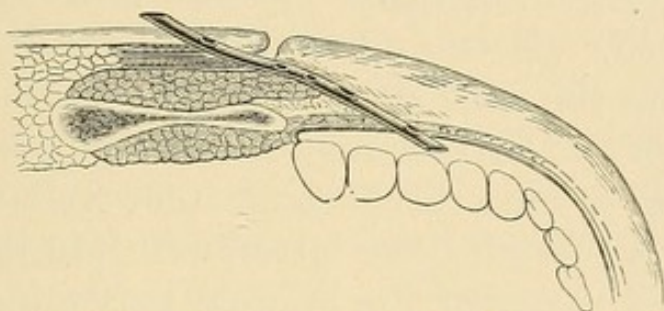


FIG. 180.—OPERATION FOR SALIVARY FISTULA. (Bryant.)

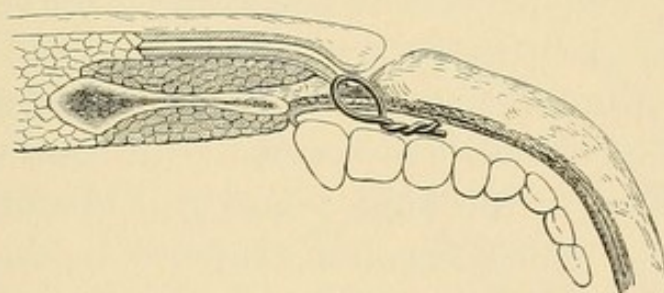


FIG. 181.—OPERATION FOR SALIVARY FISTULA. (Bryant.)

into the mouth, which is quickly followed by closure of the fistulous orifice on the cheek.”

Other methods have also been used. Hartman passes a trocar from the orifice obliquely forward through the cheek, and allows it to remain until repair has taken place.

The external wound is closed either by cauterization or by a plastic operation. Rechelot makes a double puncture—the external one back of, and the internal one anterior to, the fistula. It includes the normal duct near the fistula. This is loaded with a drainage tube, which is allowed to remain until repair takes place.

In all of these methods the object is to establish a new internal orifice and close the external opening. The tech-



nic must be varied slightly to suit the variations in different cases.

4. **Concretions of the Glands and Ducts.**—Salivary calculus is a concretion of lime salts, principally of lactophosphate, together with some magnesia and soda. The formation, according to Burchard, is due to the action of lactic acid upon the salivary secretion, causing a coagulation of mucin, which forms the meshwork in which the salts are precipitated. Klebs and Waldyer believe that masses of microbes are the most common cause of salivary stones, the phosphates and carbonates of lime, magnesia and soda being deposited around them; some other writers think that the nucleus is a foreign body introduced into the duct from the mouth. Many are of the opinion that the formation is due to a systemic condition or a gouty diathesis, and state that calculi are also present in the kidneys and gall bladder, and that in the great majority of instances salivary calculi occur in individuals who have calcareous deposits upon their teeth. The calculi are deposited in concentric layers, like those formed in the kidney and gall bladder, and have organic centers, which furnish evidence in favor of their bacterial origin. Fross reports a case from which three facet-shaped stones were removed, stating that facet-shaped calculi are very rare.

Salivary calculi are seen at all ages, but are most frequent between the ages of twenty-five and forty. Moiseff reports a case of multiple calculus in a patient aged seventy, and Wyeth, one in a girl four years old, in both of which the calculi were successfully removed. Bardel reports a removal in a case three weeks old.

The stones vary in size, the size depending upon the age of the accumulation. Clinton Wagoner removed a calculus which weighed  $93\frac{1}{2}$  grains, and Eagle removed one weighing 1,080 grains, while Robertson removed from a Bushman in South Africa a calculus the size of a bantam's egg. In ninety-six cases that the author has been able to collect,



seventy-two were of Wharton's duct, ten of the submaxillary gland, seven of the sublingual gland and ducts, and eight of Stenson's duct and the parotid gland. In many reported cases the location is not given.

*Symptoms.*—The symptoms are not always acute, but become so as the calculus increases in size so as to become an irritant, when inflammation and swelling ensue as the result of metastatic cellulitis, beginning on one side of the tongue, extending to the base of this organ and about the mandible on the same side. The swelling extends down along the neck. The presence of such symptoms is evidence of pyogenic infection, and there will usually follow a chill, high temperature, and other constitutional symptoms, such as nausea, loss of appetite, etc. When acute inflammation does not develop the symptoms are confined to the floor of the mouth. As the calculus increases in size, the tongue is crowded backward and to the opposite side, and the tumefaction is observed below the mandible. In almost every case obstruction of the duct occurs, and as the saliva accumulates the case presents symptoms of simple obstruction, or ranula. On palpation, when fluid is present, the tumor will fluctuate, and pressure will generally force some of the contents from the normal orifice of the duct. In Fross's case palpation forced out a few drops of pus.

The first symptom of calculus of Wharton's duct is the presence of a hard lump in the floor of the mouth. A diagnosis must be made from ranula, which is a simple obstruction of the duct, from benign or malignant tumors, cysts, tuberculous glands and cellulitis with suppuration. One case was sent to a hospital for a tongue amputation, another presented erosion resembling epithelioma and many are mistaken for malignant diseases of the glands.

The one procedure which is without danger, when practiced under strict antiseptics, is to pass a fine sewing needle into the mass. This may be thrust in at several places, so as thoroughly to explore the tumor. In making such an



exploration a knowledge of anatomy is necessary, for blood vessels, nerves, etc., should not be injured. The needle will impart to the experienced touch the presence of the concretion. Before making a puncture of the tumor with a needle, an effort should be made to probe the duct. If this can be done, the probe will pass up to the calculus and confirm a diagnosis.

*Treatment.*—Treatment consists in the removal of the calculus through the oral mucous membrane. The incision is made with a small finger knife over the most superficial part of the tumor, and should be sufficiently large to remove it. The practice of dilating the duct is not to be depended upon unless the stone is found near the orifice. Extra openings into a duct along its course are of no consequence. When the calculi are in the gland, or when they are well back in Stenson's duct, it is not always possible to remove them through the mouth. In such cases an external operation will be necessary. The skin incision should not be made, however, unless it is impossible to operate through the mouth, since a salivary fistula is usually the result. After-treatment is of little consequence, since all active symptoms will subside in the course of a few days.

**5. Obstructions of the Ducts Other Than Concretions.**—Other obstructions of the salivary glands causing pathological conditions are of three varieties:

1st. Congenital defects, generally an imperforate Wharton's duct.

2d. Obstructions due to the entrance of foreign substances into the duct. Several cases are on record where fish bones have been introduced into the orifice of the duct, resulting in suppuration or simple accumulation or ranula. Overall reports a case of the passage of a hair into Stenson's duct, causing an obstruction resulting in external abscess and fistula.

3d. Laceration of the duct from injuries, the cicatrix causing obstruction. Sinne reports a case of this kind fol-



lowed by inactivity of the corresponding parotid gland. As there were present no signs of either fistula or abscess—complications which were anticipated—Sinne concluded that the parotid gland, owing to the continued pressure, became hermetically sealed by the union of the flap to the underlying part and ceased activity, in time probably undergoing atrophy because of non-use. The patient did not complain of pain or other ailment, and was to all appearances perfectly well. This case simply compels us to conclude that it is best to postpone surgical interference in all similar cases. A case is also recorded where the pressure of a hard apple against the floor of the mouth caused an acute congestion of Wharton's duct and accumulation of saliva.

**RANULA.**—Ranula is an accumulation of the normal fluids of some of the glands accessory to the oral cavity as a result of obstruction of the duct. It is usually of the ducts of the submaxillary or the sublingual glands. Wolfer reports a ranula, due to the obstruction of the excretory duct of the glands of Nuhn, in a child nine months old. It was the size of a pecan, was situated under the side of the tongue, and contained whitish-green protoplasmic-like fluid filled with plate epithelium. Ranula must be differentiated from dermoid cysts and lymphangioma. Ranula may be congenital or it may develop at any time during life.

N. Muller, of Moscow, states that he has seen five cases of *congenital ranula* in 80,000 children in seven years. Sir W. Ferguson, Dubois, and Lombard report one case each, while Bryant has seen two.

Since saliva is not secreted in fetal life, it is thought that these so-called congenital ranulæ are either obstructions of the ducts of the glands of Nuhn, or accumulations in Fleischman's bursa. Others think they are dermoids. In a paper by Dr. Richard von Hippel (Berlin) he discusses and criticises the various theories which have been advanced to explain the origin of ranulæ. The careful macroscopic and microscopic examinations of numerous speci-



mens leads him to very positive ideas on the subject. He agrees with Neumann and others that certain ranulæ arise from unobliterated portions or branches of the thyro-glossal duct, and reports one interesting and thoroughly convincing case in support of this view. To anyone who has studied true median cervical fistula, the conception of such an origin presents no difficulties. Most cases of ranula have

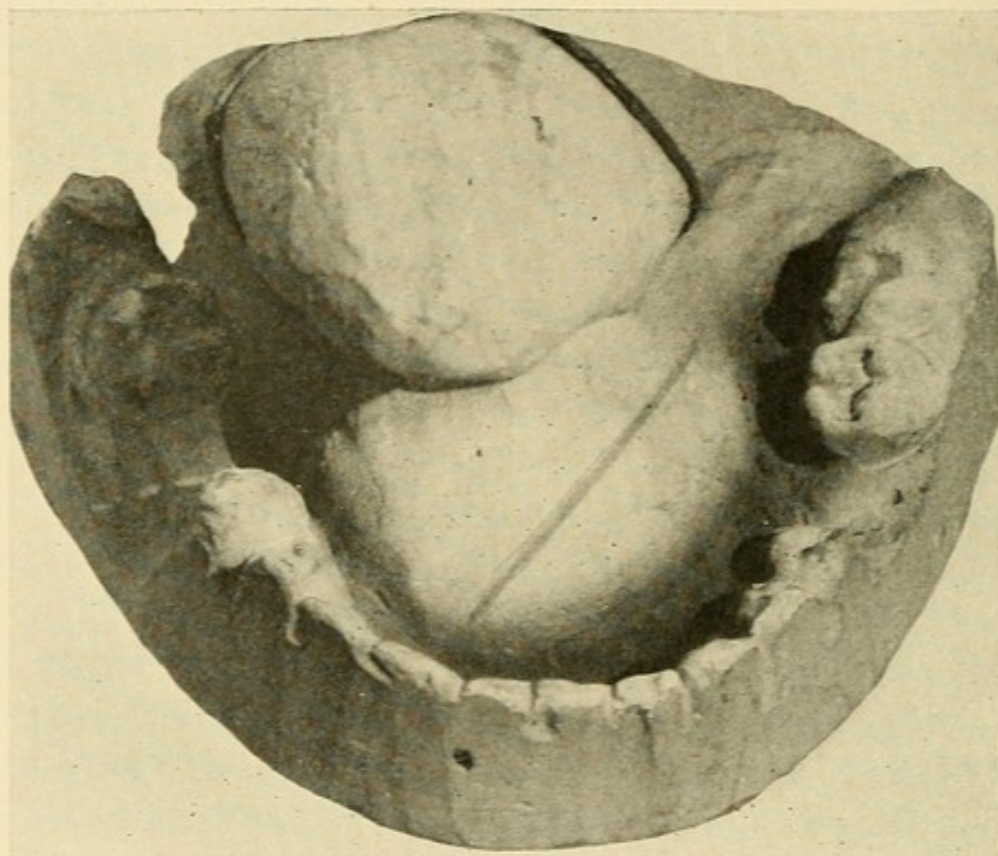


FIG. 182.—MODEL OF RANULA BEFORE OPERATION.

another origin. In studying this subject von Hippel makes free use of the excellent researches of Suzann, with whose views he largely agrees.

A rare case of double *acute ranula* is reported by Carre. He was called to attend a man who felt something suddenly form in his mouth which was nearly suffocating him. When he arrived he found the mouth occupied by two large oval swellings of a pale, pinkish color with translucent walls; the tongue was displaced backward over the glottis, occasioning severe dyspnea and complete inability to swallow.



On the right side swelling was also present below the angle of the jaw. The patient had just begun dinner, having previously been in excellent health, when his mouth suddenly filled up with the tumor below the tongue, which, rapidly increasing, pushed the tongue backward so that only the under surface of the tip was visible on examination. There was nothing in the diet to account for the symptoms, and

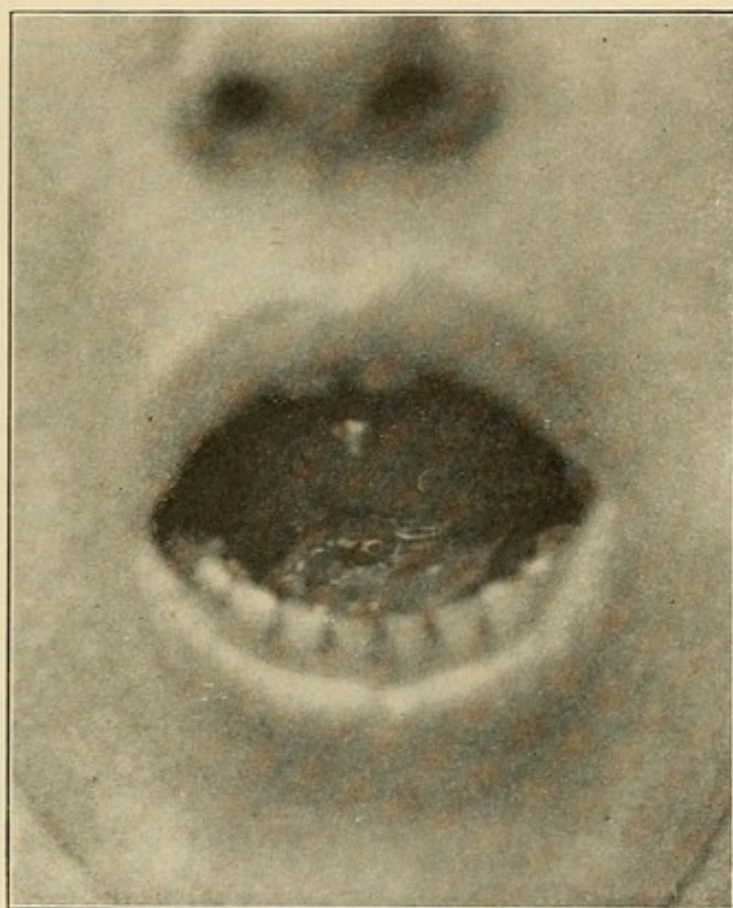


FIG. 183.—RANULA SHOWING INCISION.

no calculi or stenoses of Wharton's duct could be discovered. A free incision was made, which gave exit to one and one-half ounces of a fluid which resembled saliva. Relief promptly followed.

The location of the tumor in all varieties varies within somewhat wide limits. Generally it is near the frenum and grows outward and backward; sometimes it spreads toward the other side, and so appears median. In other cases the tumor is from the first distinctly lateral and never ap-



proaches close to the middle line. All these peculiarities are simple when the topography of the sublingual gland is considered, and depend on the part of the gland attacked by the chronic interstitial inflammation. If both glands are attacked by this inflammation, cysts will develop more or less symmetrically on both sides of the frenum. Occasionally, but rarely, cysts are truly median, and may lie close to the alveolus of the jaw. In these cases it is not the sub-

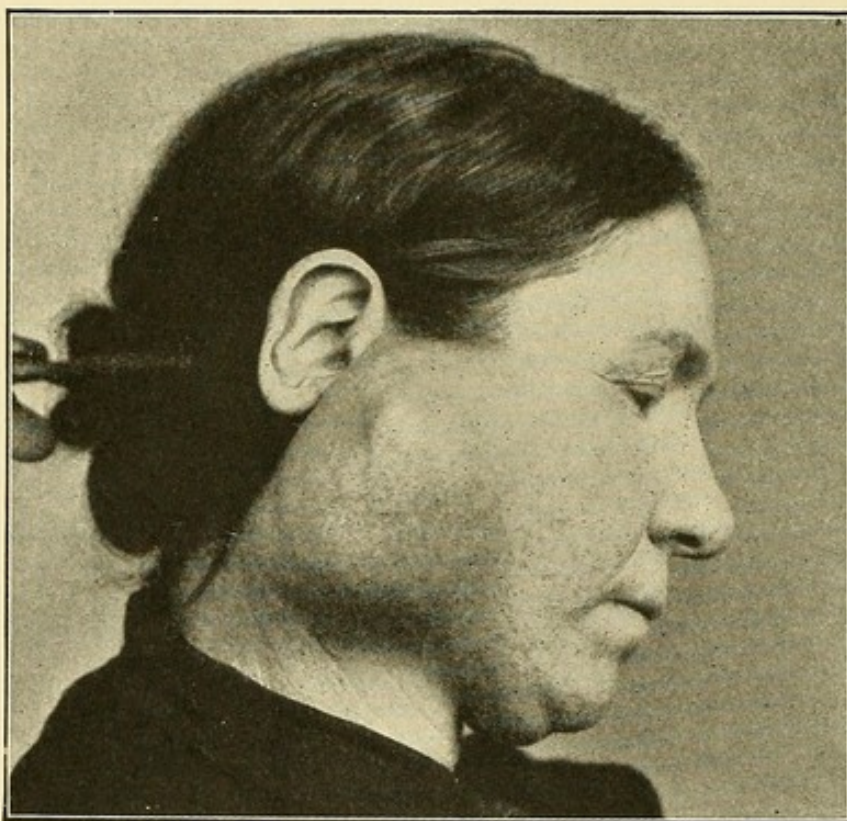


FIG. 184.—SARCOMA OF THE PAROTID GLAND. (Collection of Dr. Charles McBurney.) (Johnson.)

lingual but the “incisor glands” which are diseased. (The *grandula incisiva* lies in the middle line of the floor of the mouth, immediately behind the incisor teeth.)

*Treatment.*—The treatment of ranula consists in the evacuation of the cyst by incision, and the establishment of an orifice, so that the fluid secreted by the gland may be permitted to escape into the oral cavity as it makes its escape from the gland. The method of operation is to incise the sac from end to end or to make the opening so large



that it cannot close during repair, thus making the cavity of the sac a part of the oral cavity. The mucous membrane and the wall of the sac are sutured throughout with ten-day catgut to prevent closure. Other methods of treatment have been introduced. Chlorid of zinc in solution has been injected into the cavity, but this method is not rational, since it, as well as other caustic injections, may obliterate the sac and cause accumulation of the fluid farther back.

**6. Malignant Growths.**—Malignancy of the salivary glands does not require special attention here. Sarcoma and carcinoma are considered in detail in the chapter on Tumors.

*Tuberculosis* of the salivary glands is not so common as malignant diseases. It does occur, and Frederick Kammerer reports a case in which the patient, a woman, had tuberculosis of both elbows. A tumor was removed from the side of the neck, which, upon microscopic examination, proved to be tuberculous.

For further consideration of tumors and tuberculous diseases of the salivary glands the reader is referred to the chapter on these subjects.



## CHAPTER XXXIII

### ANKYLOSIS

Ankylosis is an impairment, from any cause, of the functional usefulness of a joint. Ankylosis of the temporo-maxillary articulation is of special interest to the dentist, since free movement at this point is necessary if any dental operation of importance is to be performed unimpeded.

For convenience of study, the several kinds of ankylosis may be tabulated as follows:

Temporary:

From tooth eruptions and impactions.

From inflammations of adjacent soft structures.

From tuberculous and other bone diseases.

Permanent:

Fibrinous.

Osseous.

### TEMPORARY ANKYLOSIS

In temporary, or spasmodic, ankylosis, due to the non-eruption of the last lower molar, or to the pain associated with late eruption, the removal of the offending tooth will be followed by disappearance of symptoms. Erupting teeth may cause rigidity of the muscles, which disappears when the mucous membrane overlying the tooth is removed, either by operation or naturally.

Inflammatory disturbance of the soft structures,\* such as inflammation of the parotid gland, cellulitis or abscesses involving the masseter or temporal muscles, is an occasional cause. When the inflammatory trouble subsides the functional usefulness is restored if the destruction has not been



extensive or has not changed the normal relationship of parts.

Tuberculous, syphilitic, or other destructive diseases of the bones which give origin or insertion to the muscles of mastication, also limit the motion of the mandible during activity. In a case recently under treatment the motion was limited to two-thirds of the normal range, as a result of

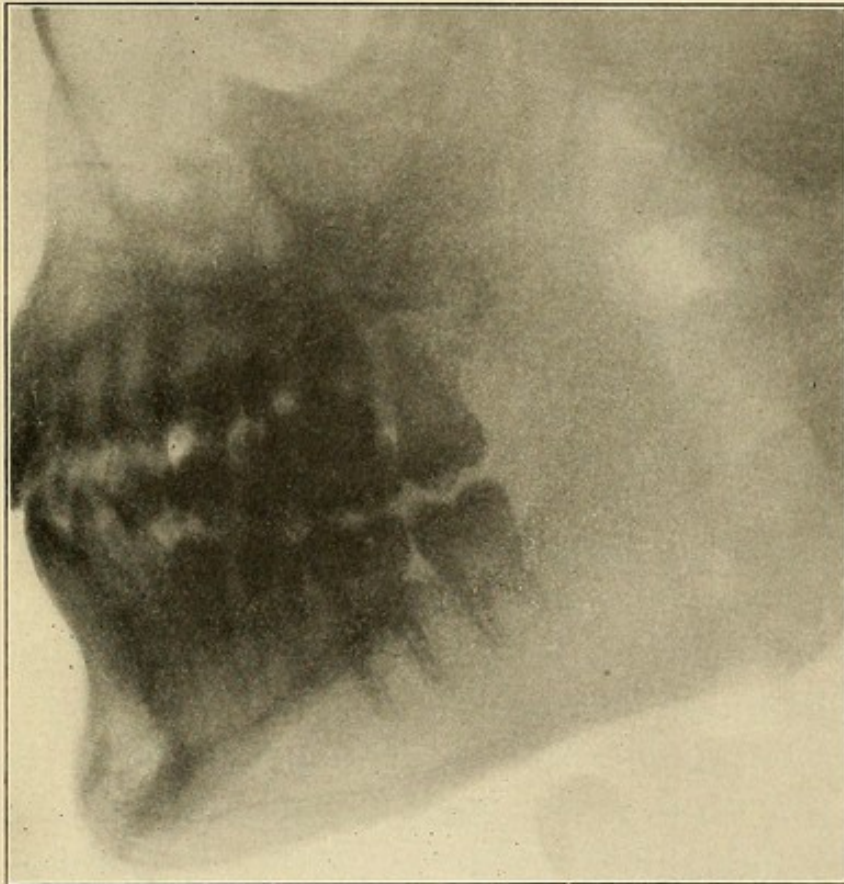


FIG. 185.—IMPACTED THIRD UPPER MOLAR, IN A BOY AGED ABOUT 15, CAUSING SPASMODIC ANKYLOSIS.

periostitis of the internal surface of the ramus of the mandible, and continued to be so until the sinus caused by operation for the removal of a sequestra had closed. Alveolar abscesses and osteitis following infection have as an almost constant symptom a limited range of motion. As has been stated in the chapter on Tuberculosis, the one ever-present symptom is muscular spasm, producing a rigid joint. This must always be taken into account in computing ankylosis and predicting the final outcome. Burns involving deeper



structures quite frequently produce limited motion of the mandible.

**Illustrative Cases.**—Figure 185 shows the case of a boy about fifteen or sixteen years old, who was suffering with temporary ankylosis of the jaw, for which no apparent cause could be found. While it was known that his molars had not erupted, there was but slight irritation in this region. An X-ray picture, however, showed that the upper third molar, instead of developing in the proper direction, was tilted and pressing upon the root of the second molar. After its removal, the spasmodic ankylosis entirely disappeared, and the boy became perfectly well.

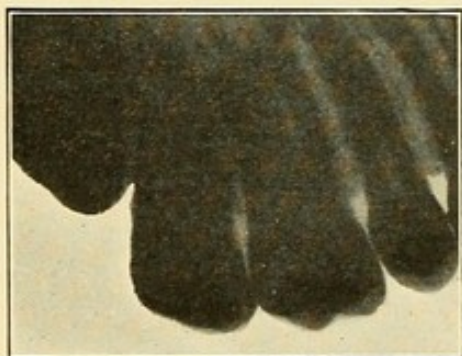


FIG. 186.—IMPACTED THIRD MOLAR CAUSING SPASMODIC ANKYLOSIS.

Figure 186 shows several irregularities, the principal one an impacted upper third molar. The symptom was the inability of the patient to open the mouth properly, temporary ankylosis being due to reflex spasms. Removal of the offending tooth resulted in complete relaxation of the muscular spasm.

**Treatment.**—The treatment depends upon the cause, and a proper diagnosis is of paramount importance. If the condition is due to delayed eruption, encourage eruption by scoring the gum, or by removing a square of tissue from over the crown. If to an encysted tooth, chisel away the bone, and remove the tooth. If to necrosis, remove the dead bone, or at least curette the part thoroughly. If to syphilis, medicate as outlined in the chapter on that subject. The removal of the cause will be followed by relief.

### PERMANENT ANKYLOSIS

Chronic, true, or permanent occlusion may be due to cicatricial contractions of the muscles of mastication and



the surrounding soft parts, when it is known as incomplete or false occlusion, or to a destruction of the temporo-maxillary joint, when it is known as true ankylosis. In the former, the conditions producing the limitation of motion are abscesses or inflammations of the tissues about the ramus, resulting after repair in a shortening of the tissues between the zygomatic arch or the squamous portion of the temporal bone, or pterygoid plates of the sphenoid bone above and the mandible below. Gangrenous stomatitis, syphilitic lesions with destructive salivation beginning in the mucous membrane are causes of occlusion. Surgical operations and lacerations of these parts are followed by cicatricial contraction of the structures and impairment of free motion of the mandible.

The most common variety of true ankylosis is due to destruction of the temporo-mandibular joint. The causes are rheumatoid arthritis, when the ankylosis is generally associated with a similar affection of other joints throughout the skeleton, and gonorrhea, which has been known to produce ankylosis of this joint by secondarily producing a synovitis of the joint followed by destruction.

Otitis media resulting in destruction of the bone in front of the meatus results in infection of the temporo-mandibular joint, followed by destruction and ankylosis. This is quite a common cause of osseous ankylosis.

**Treatment.**—The treatment for contraction of cicatricial tissue following scarlatina, ulcerations, injuries, and abscesses, is not at all times satisfactory. Two methods are recommended: (a) by the formation of a pseudoarthrosis anterior to the attachment of the cicatricial tissue, and (b) by the severing or removal of the scar tissue. For the former the reader is referred to the methods described for permanent occlusion. Section is done by simple subcutaneous incision, with a small tenotome, of all shortened tissues that resist an effort toward opening the mouth. The



entire cicatricial area is dissected away. Neither of these methods is entirely reliable.

The treatment of *permanent osseous occlusion* consists in an effort toward the formation of a pseudoarthrosis at a point which will afford the best functional usefulness of the mandible. If the joint has been destroyed by fibrous adhesions, daily use of a screw-gag up to tolerance will increase the range of motion in many cases, and this method should be tried before major operation is practiced. Passive motion may also be carried out with a screw incline. Before the use of any form of mechanical apparatus to force the jaws apart, the teeth should be protected with a strip of lead or gutta-percha plates, as the enamel may be chipped, defacing a normal tooth. When the method just described does not avail, an anesthetic should be administered and great force used to break up, if possible, the adhesions between the condyle and the temporal bone. Little damage can be done if care is taken not to force the teeth farther apart than a normal distance, or possibly slightly more. If the effort is successful, the mouth should be held open with a cork or other substance secured between the teeth by a ligature, which may be anchored to the teeth. In forty-eight hours the gag may be removed, passive motion practiced, and a slightly smaller gag inserted. Daily passive motion must be done just as soon as the soreness sufficiently subsides to permit of it.

Diffenbach was the first to recommend and practice the formation of a false joint in the mandible for the reestablishment of mandibular motion. Esmarch recommended that a V-shaped section be removed from the bone. Rizzole was first to state that the false joint should be anterior to the cicatricial band causing the occlusion. Helferick recommends resection of the condyle and reports successes, as does Lentz by the same method. The internal maxillary artery should be ligated to prevent hemorrhage after the operation. Arbuthnot Lane, of London, reports four cases



successfully treated by this method, and states that failure follows insufficiently free removal of bone. All of these operators interpose a portion of the masseter muscle or fascia between the cut surface of bone to prevent union. Elliott, of Boston, reports success following resection of the condyles in a boy aged twelve.

Recently the Gigli wire saw has been introduced, which

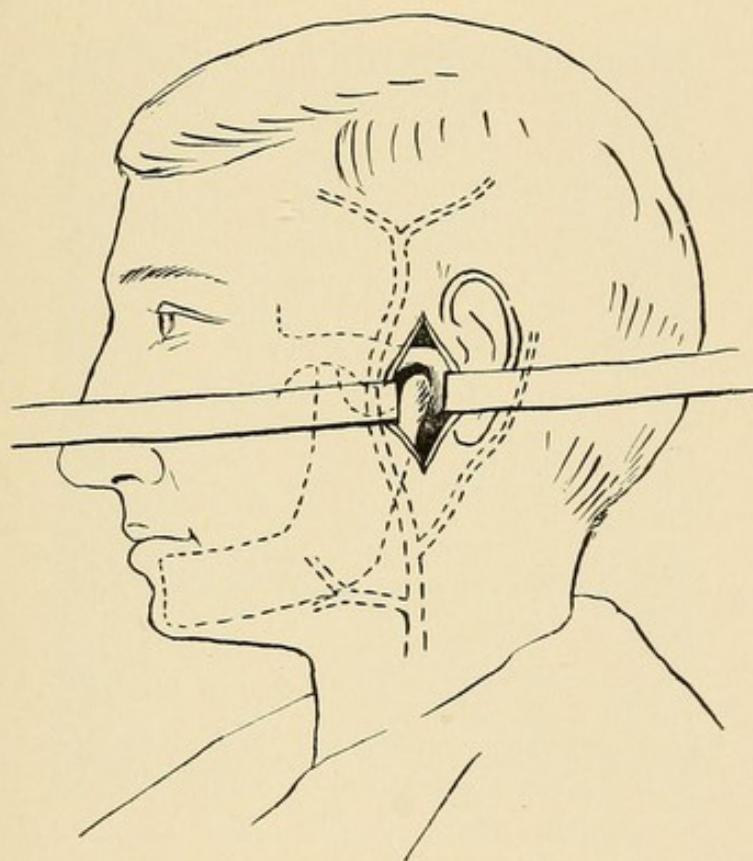


FIG. 187.—RESECTION OF THE MANDIBULAR CONDYLE. (After Roe.)

takes the place of all other methods in making section through bones in deep structures. It is flexible, cuts on all sides, and can be passed around a bone through a skin wound of small size.

Pneumonia, typhoid fever and the exanthemas have caused osseous ankylosis. In the following case the cause was smallpox.

*Case Report.*—The patient was forty-four years old when operated upon. When eight years of age he had smallpox, resulting in complete ankylosis of the right



temporo-mandibular articulation, with no motion, and the approximation of the teeth was so complete that the crowns of the cuspids and the bicuspid had ulcerated through the gums, covering the opposite process. He was compelled to live on liquids or to force solid particles of food through between the teeth, yet he was well nourished and had worked at his trade as a boiler-maker for years, with com-

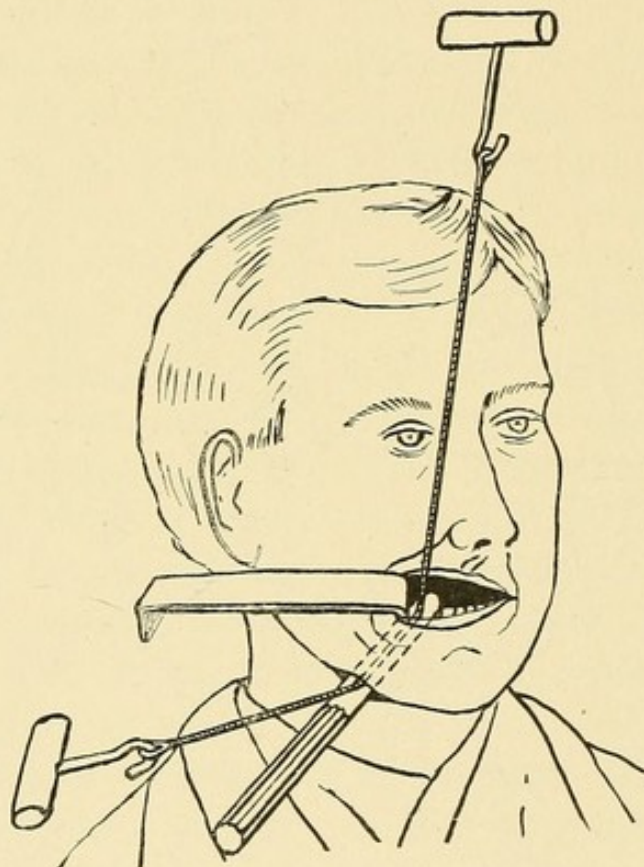


FIG. 188.—RESECTION OF MANDIBLE, SHOWING GIGLI SAW IN POSITION.

parative health and strength. In order that as little scar as possible might result from the operation, an incision one-half inch long was made immediately under the angle of the mandible, parallel to it, and in front of the facial artery. A Gigli saw was passed into the mouth, internal to the mandible. The lips were retracted so as to prevent their laceration while sawing. The bone was cut through. The mouth was easily forced wide open, the joint on the left side remaining in a practically normal condition after having been fixed for thirty-six years. To prevent motion between the



several ends of the bone, about half an inch of the posterior fragment was broken off with forceps. The cavity was filled with sterile gauze to prevent approximation. The packing was removed and repacked every second day for several weeks. The second figure shows result. (Figure 189.)

So far as the author has been able to learn, four operations for ankylosis of the mandible by section of the rami

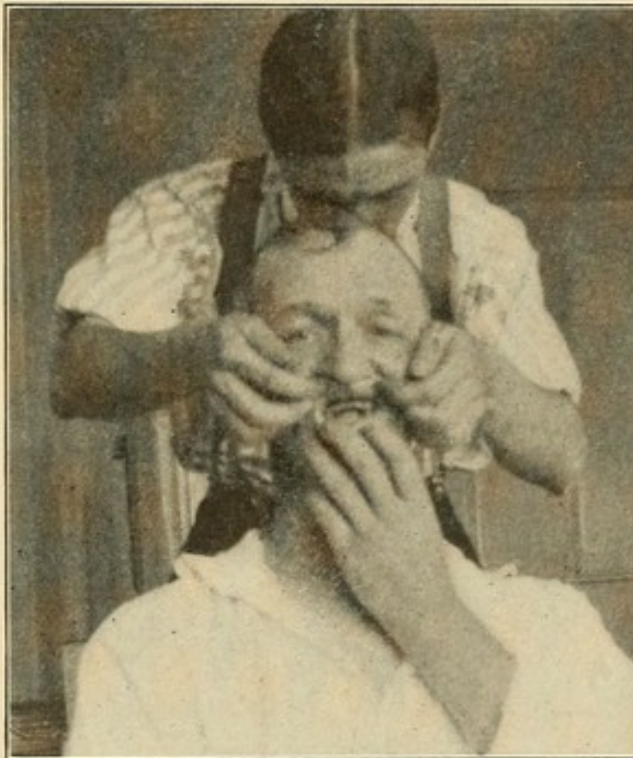

FIG. 189.—RESULT OF RESECTION.

have been reported: the first by Dr. Wayne Babcock, the second and third by Dr. Blair, the fourth by Dr. Cathcart and Dr. Solomons, of Charleston, S. C.

A fifth case is herewith recorded.

A boy, when four years of age, fell down a balustrade, striking his chin against the floor and fracturing the mandible in several places, resulting in complete ankylosis of the jaw so that the deciduous teeth were extracted and the permanent teeth came in without any regard to normal growth, owing to the pressure.

At the age of twenty-seven, or twenty-three years after



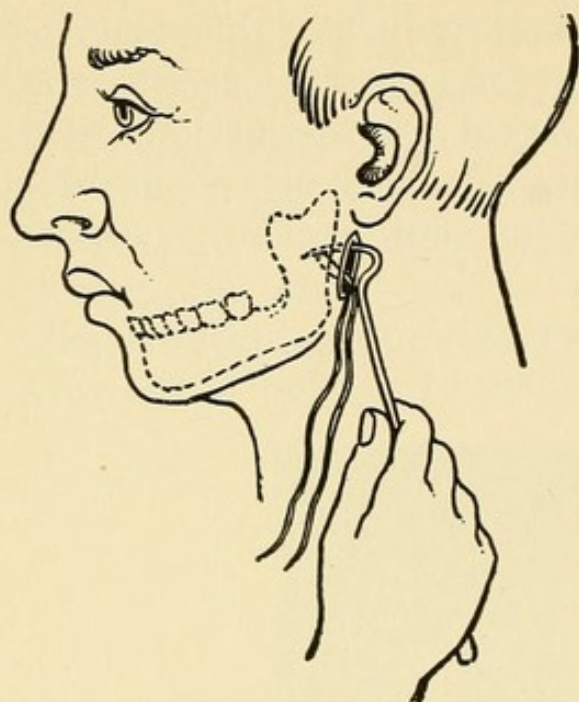


FIG. 190.

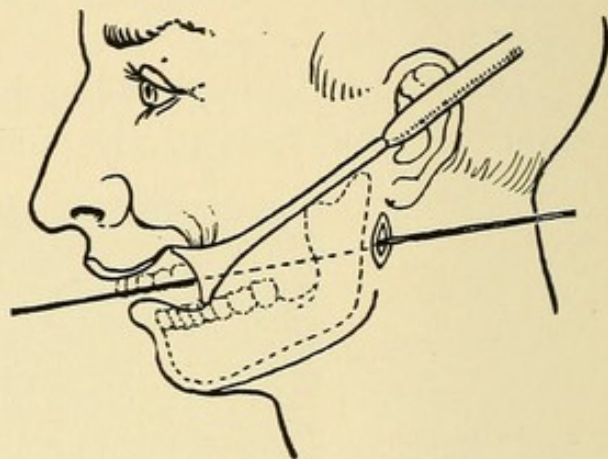


FIG. 191.

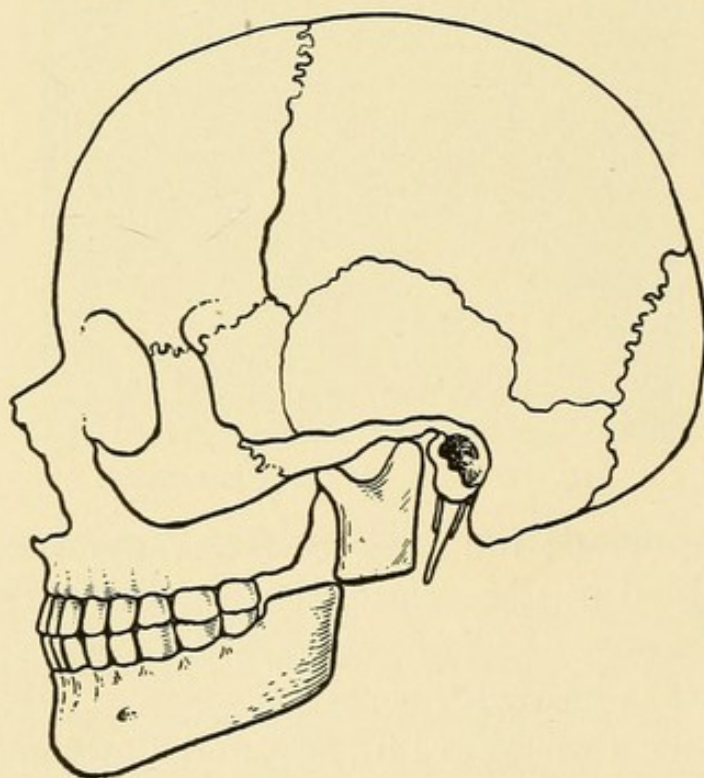


FIG. 192.

FIGS. 190-192.—INCISION THROUGH SKIN AND NEEDLE PASSING UNDER MAXILLA INTO MOUTH. Fig. 190.—Method of introducing pedicle needle, with eye in the end threaded so as to be withdrawn through the mouth, and for the purpose of drawing the Gigli saw through back of the bone. Fig. 191.—Gigli saw in position, showing method of sawing through the bone, with the mouth retracted so that the saw does no damage to the soft tissues. Fig. 192.—Severed jaw advanced to the position where it is to be held to the upper teeth with Angle's bands and wires.



the accident, it was possible to get a silver ten-cent piece between some of the teeth, but there was absolutely no masticating power. The chin had so far receded that the gingival margin in the median line below was five-eighths of an inch back of the incisors above. This was the one point of entrance for food, and he had lived on soft foods, especially prepared, during the twenty-three years.

The operation consisted in making an incision immedi-



FIG. 193.—CASE BEFORE OPERATION. FRONT VIEW.

ately below the lobes of the ear as shown in figure 191, down to the parotid gland. Owing to the fact that the space normally found between the ramus and the mastoid was obliterated by the displacement of the bone, the parotid gland was found resting upon the external surface of the ramus. The gland was carefully dissected away from the masseter muscle, and, along with the seventh nerve and Stenson's duct, which are included in it, were all pushed upward and



held there by retraction. A long curved pedicle needle, bent almost at a right angle with the shaft, was pushed around back of the ramus underneath the bone and forward into the oral cavity immediately back of the molar teeth. The needle has an eye at the end. This was threaded and with a hook the thread was pulled out into the mouth. A Gigli saw was now drawn through back of the bone and




FIG. 194.—CASE BEFORE OPERATION. SIDE VIEW.

with the retractor (figure 191) the angle of the mouth was drawn back, so as not to do any damage to the cheek. The bone was now severed by the Gigli saw, one end passing through the mouth and the other through an incision below the ear. The incision through the skin was about one inch long. The other side was operated on in the same way. When the bone was cut off on the second side it dropped away from the upper teeth fully an inch, and was freely movable in every direction. It is necessary in this operation to avoid the carotid artery and the cranial nerves, which pass down from the base of the skull at this point.



This was done by hugging the bone closely as the needle passed around underneath into the mouth. A pair of these needles are necessary, since the curve is different on the two sides.

Several problems naturally present themselves. The first is the question of nutrition for the body of the bone

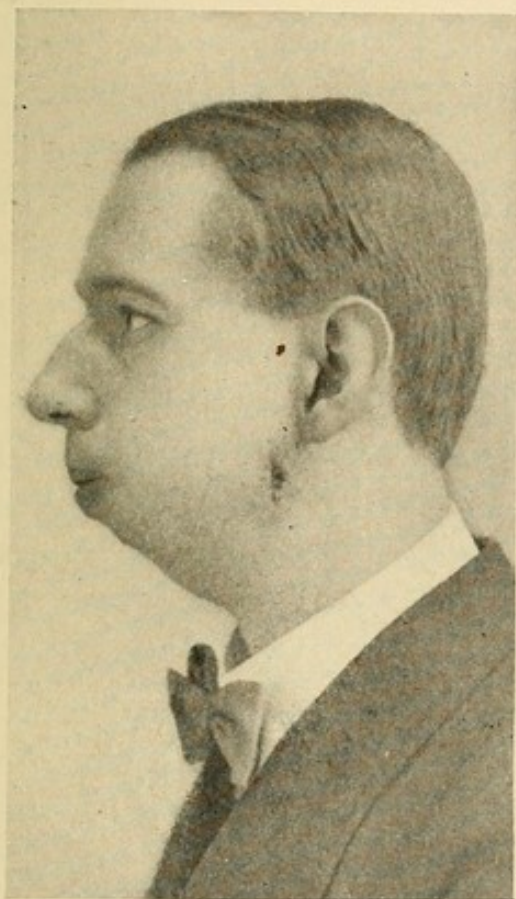

FIG. 195.—CASE AFTER OPERATION.  
Incision and advancement of jaw.

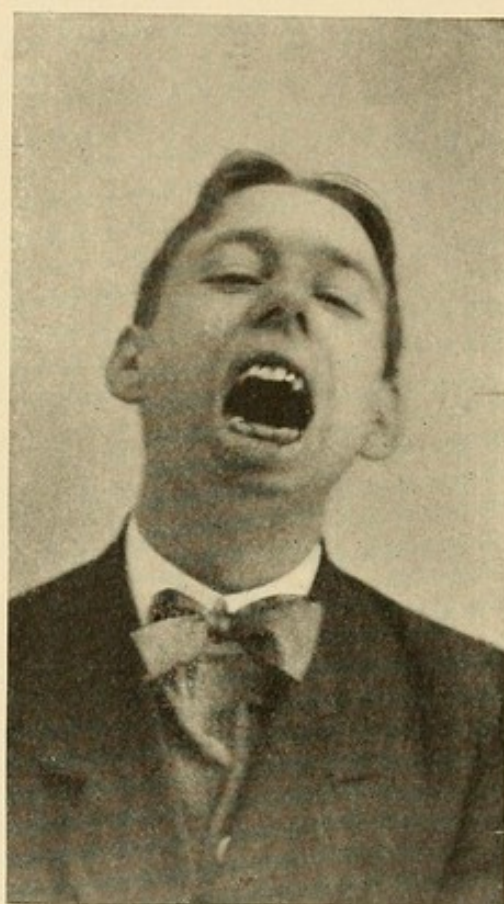


FIG. 196.—CASE AFTER OPERATION.  
Mouth open.

after both inferior dental arteries are destroyed. It must be remembered that the nutrition of the bone, while partially from these arteries, is not wholly so, and that with their destruction the periosteum will take up the work of thoroughly nourishing the entire bone, including the teeth. The dentist naturally wonders whether the withdrawal of the blood supply to the teeth through their apices will not result in dental caries. So far as has been observed at this time, about six months from date of operation, the teeth



are thoroughly nourished and there is no evidence of these complications. As to the nerve supply, the only impairment of nerve function evidenced is some numbness over the symphysis, and this is not at all troublesome. A permanent functional joint, following section of the mandible where the bone is not advanced so that the cut ends completely pass each other, is hardly to be expected, but while there is for a time almost perfect functional usefulness, it has been the experience of operators that the cicatrices formed around the end of the bone to some extent interfere with free motion. For this reason it is very desirable that during the operation sufficient bone be removed to prevent union between the fragments.

*Hysterical occlusion* is a condition occasionally seen. Diagnosis is not easy, and the skill of the surgeon is tested. When there is doubt an anesthetic should be administered, and if the case is neurotic the joint will be freely movable.



## CHAPTER XXXIV

### FRACTURE IN GENERAL

Fracture is a sudden and violent solution of continuity of bone into two or more fragments. Fractures constitute one-seventh of all injuries. Three times as many cases occur in males as in females. Fractures are most common in infants and after fifty years of age. In middle life there are ten times as many cases in men as in women.

**Varieties.**—The varieties are: *simple* or *closed*, when the skin is not open; *compound* or *open*, when the skin is torn and there is atmospheric communication; *complete*, where the bone is broken entirely across; *incomplete* where the break is not entirely through, called green stick or infraction; *single*, when but one bone is broken; *multiple*, when there is more than one point of fracture; *comminuted*, when the bone is broken into many pieces; *complicated*, when important structures are injured at the time of fracture, such as blood vessels, nerves, viscera, brain, etc.; *impacted*, when one bone is driven into another; *congenital*, when resulting from violence during intrauterine life, as from external violence, uterine contractions, malformations, syphilis, etc.; *obstetric*, when produced during the act of delivery; *spontaneous*, when the result of very slight violence in fragile bones, caused by disease or tumor; *pathological*, when predisposed by disease of the bone; *ununited*, where there is no union; *delayed union*, where the bones fail to unite at the usual time, but unite subsequently.

*Diastasis*, or *epiphyseolysis*, is a separation of an epiphysis from the shaft at the diaphysoepiphyseal line. It occurs in the young before ossification.



Fractures may occur through a bone in the following *directions*: *transverse*, when the break is at a right angle with the long axis of the bone; *oblique*, when it passes across the bone in an oblique direction; *longitudinal*, when the bone is split lengthwise; *spiral*, when the break passes spirally around the bone; *stellate*, when the lines of fracture radiate in several directions from a common point, as of the skull or patella; *dentated* or *serrated*, when the line of fracture is irregular.

The *displacements* of fragments in a fracture may be: *lateral*, when the ends are displaced to one side; *angular*, when the long axis is bent; *rotary*, when the extremity is twisted or rotated; *longitudinal*, when the ends are disengaged at the point of fracture and the extremity is either shortened or lengthened.

**Etiology.**—The causes of fracture are usually divided into *predisposing* and *exciting*. *Predisposing* causes are *sex*, *age*, *previous diseases*, and *prominence of parts*. *Exciting* causes are *external violence*, which may be either *direct*, when the bone is broken where the violence is received, or *indirect*, when the violence is received at a point remote from the point of fracture, as a Colles' fracture, resulting from a fall on the hand, or fracture of the clavicle, resulting from violence upon the shoulder; and *muscular action*, also a form of indirect violence, which may produce a fracture of a long bone, as fracture of the femur, caused, while running, by the powerful *quadriceps femoris*.

**Symptoms.**—The symptoms may be *subjective* or *objective*. The first are *pain*, in proportion to the trauma and nerve involvement; *loss of*, or diminished, *function*, in proportion to the importance of the bone fractured; *shock*, depending upon the complications. The objective symptoms are *deformity*, which may be swelling caused by the hemorrhages and transfusion, or due to displacement of the bones at the point of fracture, which may be angular, lateral, rotary, shortening, lengthening or impaction; and



*crepitation*, a most constant and very valuable sign, caused by the fractured ends of the bone coming into contact during manipulation or movements. This, however, is absent in impaction and diastasis.

**Diagnosis.**—Diagnosis depends usually upon crepitation, loss of function and preternatural mobility, the three cardinal symptoms. To these must be added the history of the injury, pain, swelling, and other injury to the soft parts. The X-ray should be used if necessary.

**Prognosis.**—Prognosis is usually good except in advanced life. *Diseases* such as syphilis, tuberculosis, etc., interfere with repair.

*Complications* of fracture are rupture of a blood vessel, laceration of nerves and lymphatics, involvement of joints, emphysema, embolism, etc. *Compound* fracture, when it occurs, is always a complication and frequently leads to bacterial invasion (infection) and subsequent supuration, cellulitis, malignant edema, etc.

*Repair* of bone after fracture uniformly occurs, and requires from five to eight weeks. Repair is the result of the deposit, about the ends of the fractured bones, of reparative products, which eventually ossify. The injury produces laceration of the periosteum and other tissues, resulting in hemorrhage from torn vessels, extravasation, hyperemia, cellular exudation, osteoporosis, and architectural reconstruction.

*Callus* is usually called (a) *external*, or that developed from periosteum; (b) *internal*, or that developed from the endosteum within the medullary canal; and (c) *intermediate*, or that between the ends of the broken bone.

The *bloodclot* that fills the spaces about the ends of bone is displaced in a few days by leucocytes, which in turn are displaced by the osteoblasts, in which are deposited lime salts, becoming the solid framework for the new bone, and eventually becoming bone. Other reparative cells are also deposited to repair the injured soft tissues.



**Treatment.**—*General* treatment includes measures for the comfort of the patient, remedies for the shock, and the control of the hemorrhage when it is present. *Antiseptic* precautions must be taken. The parts should be placed in as near the normal position as possible, which is usually the most comfortable position. A temporary splint, support or bandage should be adjusted. Permanent dressings should be applied as soon as possible, as swelling, extravasation, hemorrhage, and injury to the soft parts by the ends of the bones remaining in false positions, all tend to permanent complications.

The cardinal points in treatment are *reduction* and *retention*. The injury produces some insensibility and early reduction is less painful. It is also easier, as the muscles are temporarily relaxed. This is best accomplished by grasping the extremity, making firm, gentle and continuous traction with one hand, and with the other hand forcing the bones into position, placing them as near the normal position as possible. An *anesthetic* may be necessary if there is great displacement or marked muscular contraction, or if there has been much delay, with consequent swelling, etc., or when the pain is very great. An anesthetic should always be used if the reduction is questionable or not satisfactory. Retention of the fragments in the reduced position is usually accomplished by using coaptation splints, sandbags, or plaster of Paris, along with extension and counter-extension. The best results are obtained by splints of boards, perforated metal, wire gauze, felt, sandbags, etc., held in position with a roller or other bandage. Plaster of Paris is the most universally used permanent splint. When reduction cannot be accomplished after a few days, some advise immediate wiring.



## CHAPTER XXXV

### FRACTURE OF THE MANDIBLE

Owing to its prominence, as well as to the fact that it is composed of a semicircle supported at points remote from where violence is received, this bone is subjected to quite frequent fracture. It exhibits, however, considerable elasticity throughout the arch from one condyle to the other, and for this reason may be subjected to considerable violence, especially in young subjects, without fracture.

**Frequency.**—Fractures of the mandible occur as frequently as fractures of all other bones of the face combined. They may be of any of the varieties enumerated under the general head of fracture, but are most frequently compound when the fracture is through the horizontal portion, since a force sufficient to produce a fracture of this bone will generally tear through the periosteum and mucous membrane surrounding it. Simple fractures may be expected when the break is through the angle or ramus. Five per cent. of fractures are at two or more places, or multiple, and many of them are comminuted.

**Location.**—The most frequent points of fracture are about as follows, a slight variation depending upon the variety and direction of the violence: First, mental foramen; second, second molar; third, symphysis; fourth, ramus; and fifth, neck of condyle.

**Causes.**—The causes that produce fractures are fist blows and other crushing forces imparted directly against the bone, as when the head is caught under a wheel or in falling from a height, as from a bicycle.



**Symptoms.**—The symptoms are deformity, pain, crepitation, and mobility. Abrasion of the skin and swelling with disability or inability to use the mandible may also be present.

The amount of *displacement* and resultant *deformity* depends greatly upon the variety of fracture. Transverse fractures through the symphysis and at other points, unless produced by great violence, are generally in very fair position and are retained so with little difficulty. In oblique fractures at any point displacement occurs, but it is most marked when the fracture is through the body of the mandible. Oblique fractures are most difficult of reduction, and, when reduced, remain so only until the patient has had an opportunity to place the muscles in contraction after an anesthetic. The deformity is then as bad as before reduction. Probably the most difficult variety of fracture to reduce and retain in position is one beginning at the mental foramen and extending backward and inward through the first molar. It can be readily observed that the geniohyoid and geniohyoglossus, with their attachments to the genial tubercles, pass directly backward, and every movement of the tongue tends to draw the symphysis backward. In opposition to this, the masseter and temporal muscles have a tendency to draw the angle and remaining portion of the body upward. With two such forces as these working in opposite directions, it can readily be seen that mechanical means are necessary to overcome them so as to readjust the fragments.

**Diagnosis.**—Diagnosis is not difficult, and is based upon a consideration of the symptoms already enumerated. In fractures through the ramus, neck of the condyle, and coronoid process, it is sometimes very difficult to make out the existence of the discontinuity.

**Complications.**—Complications which are likely to be present are excessive hemorrhage, rupture of the dental artery, and infection, which frequently follows compound



fracture, since it is difficult to treat the wound antiseptically, in which case more or less necrosis of the process results.

**Repair.**—Repair generally follows if adjustment has been made early and the wound is kept fairly clean. Liquid food can always be taken into the mouth through the teeth, or it may be introduced through a curved tube or catheter, back of the molars. The patient should be taught from the start to hold the teeth firmly together.

**Treatment.**—Treatment may be briefly summarized as follows:

- First.     Aseptic measures only.
- Second.   Wire splints about the teeth.
- Third.     Angle's method.
- Fourth.    Bone wiring.
- Fifth.     Interdental splints.
- Sixth.     External bandages and appliances.

*Aseptic Measures Only.*—When no displacement exists, no mechanical treatment is required. Care should be taken to keep the parts in an aseptic condition to prevent infection.

*Wire Splints.*—When slight displacement exists, the parts may be held together by wire splints extending about several or all of the teeth. Hammond throws a wire about all of the teeth, including the molars on both sides, passing along the lingual as well as the buccal surfaces of the teeth. Additional wires of much smaller gauge are thrown about and between the teeth on either side of the fracture. This method is not satisfactory when there is much tendency to re-displacement. In almost all fractures one or more teeth are loosened, and when an effort is made to hold the fragments in position by the use of wire, it should be carried far enough away from the line of fracture to guarantee firm teeth. Kingsley and Weston have devised a retaining splint by swaging silver or other metal over a die



which corresponds with the remaining projection from the mandible. This method is satisfactory when there is little tendency to displacement. (Figure 197.)

*Angle's Method.*—More recently it has been the practice to secure a better juxtaposition of the parts by the use

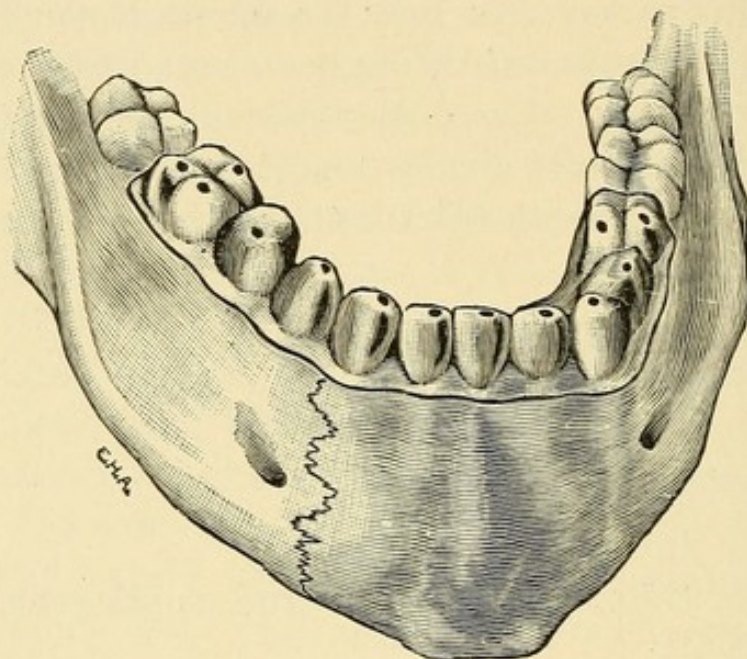


FIG. 197.—DENTAL SPLINT SWAGED TO FIT THE TEETH AND CEMENTED INTO POSITION.

of bands and screws thrown about the teeth, devised by Angle. He has introduced a method of securing fragments which is very satisfactory in many instances. The essential

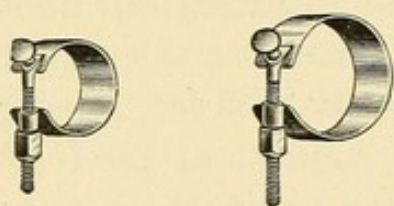


FIG. 198.—ANGLE'S BANDS.

step of this method is to secure an anchorage from the solid teeth with metallic bands thrown about them and firmly held by screws. Angle has several methods in making traction from one band to another. If the fracture is single and transverse without much displacement, the fragments are held by a rod which passes from one band to another and which is tightened by a screw. By this means the fragments can be drawn toward each other with considerable force. He also uses buttons instead of the rod, projecting from the band on both sides of the fracture, which are drawn together by the use of wire. If



it is impossible to secure proper adjustment from the teeth of the mandible, or in cases where there is more than one fracture, he suggests that bands may be placed about the teeth in the maxilla, and wires carried up to them, thus holding the fragments of the broken mandible against the teeth of the maxilla.

*Bone Wiring.*—In all cases of fracture of the mandible, as well as of other bones throughout the skeleton, where there is the least tendency to displacement, nothing serves, in the author's opinion, such an ad-

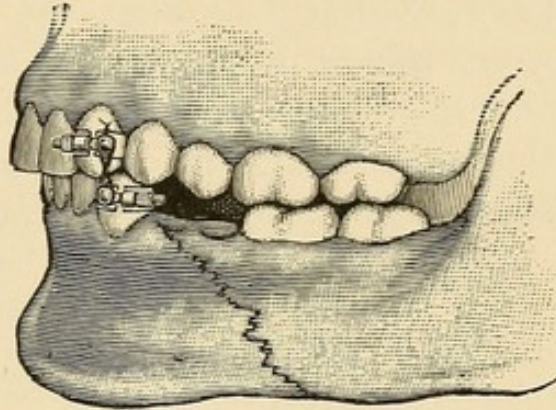


FIG. 199.—HOLDING FRACTURED MANDIBLE TO MAXILLA WITH WIRE AROUND PINS ON THE BAND.

mirable purpose as bone wiring. In this method there is a certainty that the bones can be readjusted and sufficient traction placed upon the fragments to hold them in apposition until repair has taken place, and this is the treatment which should take the place of all other methods in fracture of the mandible with displacement. The operation is not difficult and, when properly done, requires no after attention, the patient being permitted to open and close the mouth with almost as much freedom as though fracture did not exist.

The method consists in drilling a hole through the mandible from the external surface of the bone into the sublingual cavity. The drill hole should be made between the apices of the second and third teeth from the lines of fracture, when this is possible, so as to guarantee firm anchorage for the wires. The wire is passed from without through the bone to the lingual surface and with a notched or perforated drill it is drawn out through the second drill hole. The two ends of the wire are now drawn out firmly, and the loop on the inside of the bone is molded to the surface of the mucous membrane. The



free ends are twisted so as to bring the ends of the bones into perfect apposition. The wire is now turned up along the remaining teeth, so that the sharp end may not irritate the mucous membrane of the lip. When one side has a tendency to drop, the drill holes should not be on the same plane; but, instead, the hole in the high fragment should be well up to the gingival margin, and the one in the lower fragment close to or below the dental canal. In some instances it will require but one hole, the teeth being

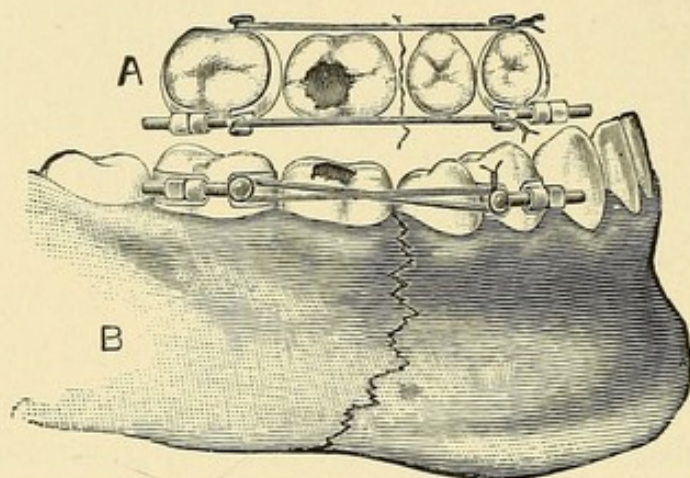


FIG. 200.—HOLDING FRAGMENTS IN POSITION WITH A SCREW ROD FROM BANDS.

used for anchorage. This is usually the case in fractures near the angle.

Before the adjustment of the fragments, the field should be thoroughly cleansed with a fifty-per-cent. solution of alcohol. Iron wire, 20-gauge, is always used, since it is tougher, less irritating, and in every way superior to silver wire.

The wires are permitted to remain in position for about six weeks, or longer if union has not taken place. They cause little irritation or sloughing of the gum or mucous membrane, as might be supposed; and, if necrosis of bone from pressure of the wire ever occurred in the author's cases, it was too insignificant to attract attention. Bandages and swaddling-cloths are not necessary. The patient soon learns to hold the teeth together. The mouth should



be cleansed with some strong antiseptic every hour or so. If infection occurs, an ice-cap should be applied directly to the face. Under this treatment suppuration seldom occurs.

In the case illustrated in figure 205 the posterior fragment was tilted up by the masseter, leaving a displacement

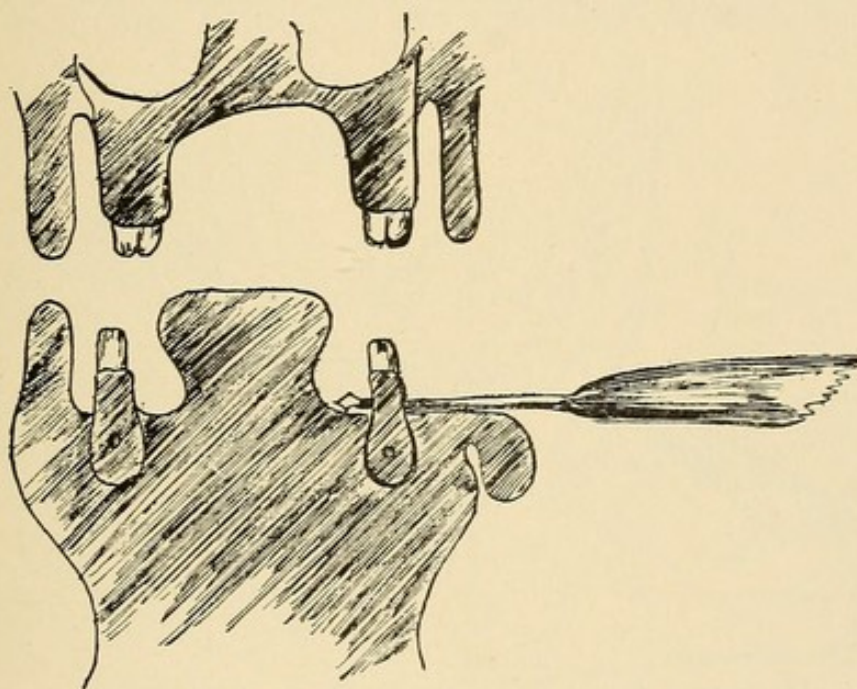


FIG. 201.—DRILLING THE BONE IN A FRACTURED MANDIBLE.

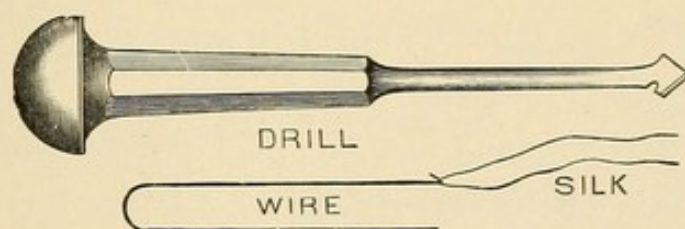


FIG. 202.—NOTCHED DRILL AND WIRE. Showing method of attaching thread.

of about half an inch. The object in wiring was to pull the anterior fragment upward against the posterior. Since the molar was perfectly solid, it served for an anchorage. The drill was passed through between the roots of the bicuspids. This furnished an upward and backward traction and a perfect adjustment was not difficult. Union followed, and the wire was removed in six weeks, with perfect articulation and no external deformity.



The case illustrated in figure 206 was that of a boy aged seventeen, whose face was caught by the drop-chute of a coal-tipple, resulting in two fractures of the mandible, the first being through the angle on the left side, and the second passing obliquely across from without, inward and forward, beginning at the first bicuspid and ending at the first incisor on the same side. This case was not seen until

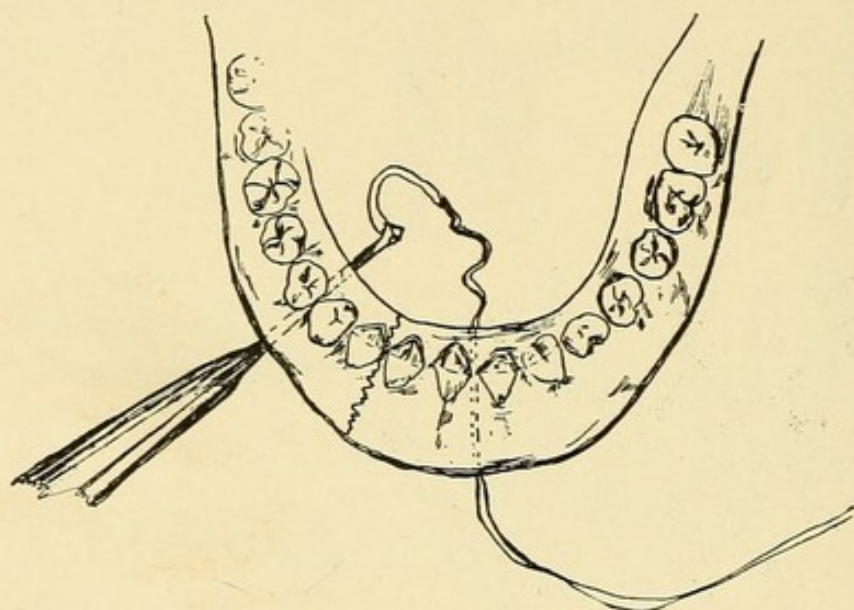


FIG. 203.—THREADING DRILL HOLE WITH WIRE.



FIG. 204.—CHISEL USED TO FRESHEN ENDS OF BONES IN OLD FRACTURES.

the ninth day, after the ordinary mechanical methods had been used without success. Since the fracture was quite oblique, but one drill hole was made through the bone, and the wire brought up over the alveolus and twisted with sufficient force to hold the fragments in position. After wiring the anterior fracture by the usual method, there was no tendency to displacements of the fragments at the posterior fracture, and repair took place with but slight deformity.



Figure 207 shows a fracture through the ramus above the molar teeth on the right side as the result of a direct blow against the body of the mandible on the left side. The displacement was toward the right and downward. To throw the teeth in articulation, a wire was secured to the first molar on the right and a second to the upper central from the right. After throwing the mandible around into proper position, the wires were twisted together and held

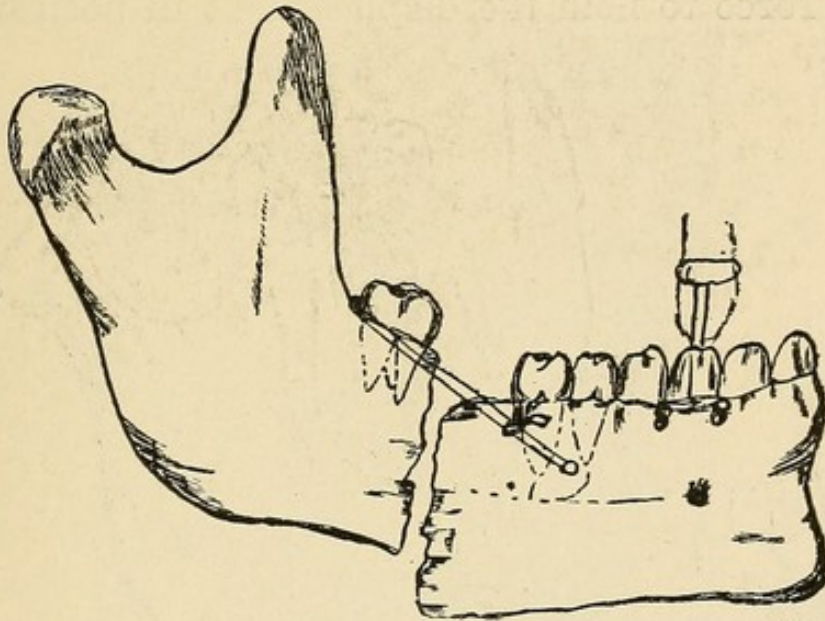


FIG. 205.—FRACTURE THROUGH MOLARS, SHOWING METHOD OF MAKING TRACTION TO OVERCOME A MUSCULAR SPASM AND APPROXIMATE THE BONES.

in this position without difficulty. Repair followed with satisfactory results.

Figure 208 shows a fracture through the symphysis as a result of a blow on the left side of the face. There was considerable displacement, and the dentist and physician were unable to hold the fragments in position. At the end of two weeks the bone was wired by the through-and-through method. Four weeks later the wire was removed, satisfactory union having taken place without complication.

*Interdental Splints.*—Interdental splints answer very well to retain the fragments in position in some cases. In their use the splint rests against the upper teeth, and the



fractured mandible is held up against the under surface of the splint by a Barton or other bandage. This necessitates making a fenestra in the splint through which food may be given to the patient. Theoretically, interdental splints appear to be a very satisfactory method of treatment, but in the author's hands they have been anything but satisfactory, since it is difficult to keep them in position, and, if there is a tendency to displacement of the fragment, sufficient force to hold the displacement in position is not

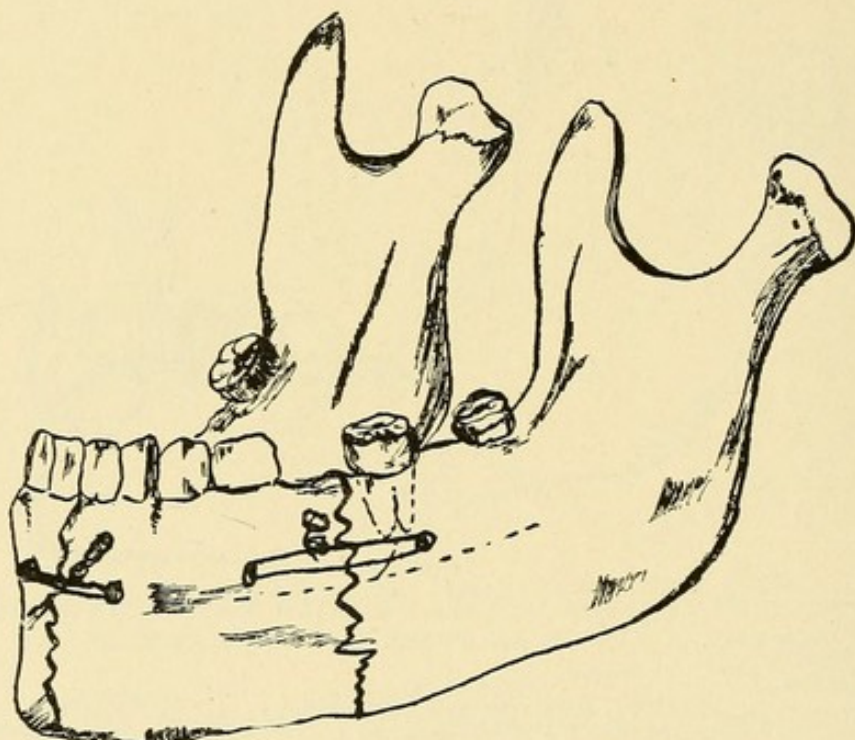


FIG. 206.—DOUBLE FRACTURE SHOWING WIRES IN POSITION.

easily obtained. Any mechanism that remains in the mouth for extended periods must necessarily be unsanitary. Especially is this true in cases of fracture where open wounds exist. An interdental splint, to be effective, must be continuously worn for at least one month, usually six weeks. While an effort is made daily toward cleansing, putrefactive conditions are always found. Removal of the splint would mean displacement.

*External Appliances.*—The treatment of fractures of the mandible has included almost every variety of mechanical apparatus that could possibly have been used for the



purpose. The bandage of Barton, or of Hamilton, or Garretson's modification of Barton's, or the vulcanite splint adjusted to the external surface of the mandible, as advised by Heath, or the same variety of external support made of metal, plaster of Paris or other material, are all methods of a more or less temporary nature, and are efficient only in those cases where the fracture is transverse and the displacement is not great, or when reduction has

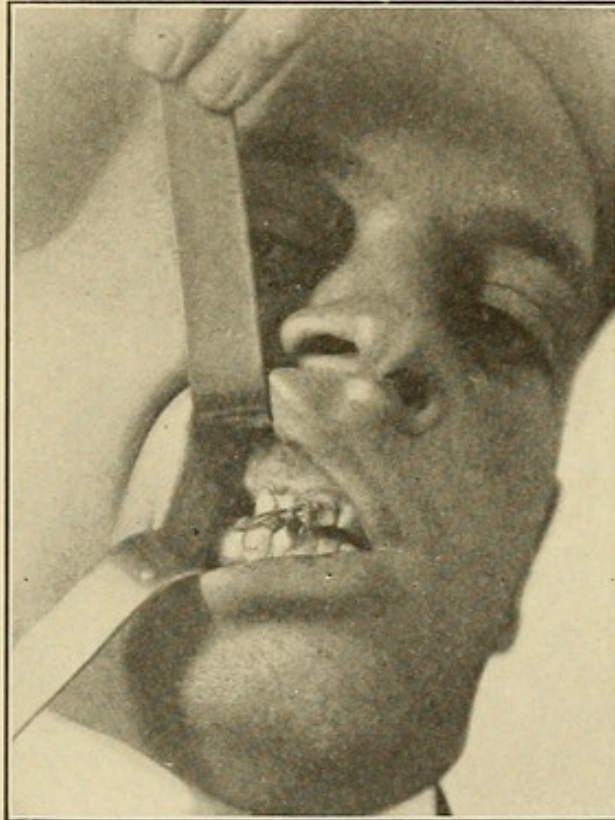


FIG. 207.—FRACTURE OF RAMUS WITH WIRES IN POSITION.

been accomplished and there is no tendency for displacement to return. With these methods it is impossible to hold oblique fractures of the ramus, or any part of the bone which includes the teeth, in perfect position. Previous to the introduction of interdental splints and wiring, it was quite common for considerable deformity to follow fractures of the mandible.

*After-Treatment.*—In the after-treatment of fracture of the mandible, if the retaining apparatus has secured and maintained a perfect adjustment throughout, it should be



kept in position for six or eight weeks in the most favorable cases. In compound fractures with suppuration, which is usual, a much longer time is required for perfect union to take place. If mechanical means are perfect, external bandages and apparatus are entirely unnecessary.

**Fractures of the Alveolar Process.**—Not an infrequent condition is a fracture through the alveolar process, the line of break extending along the roots of teeth and parallel

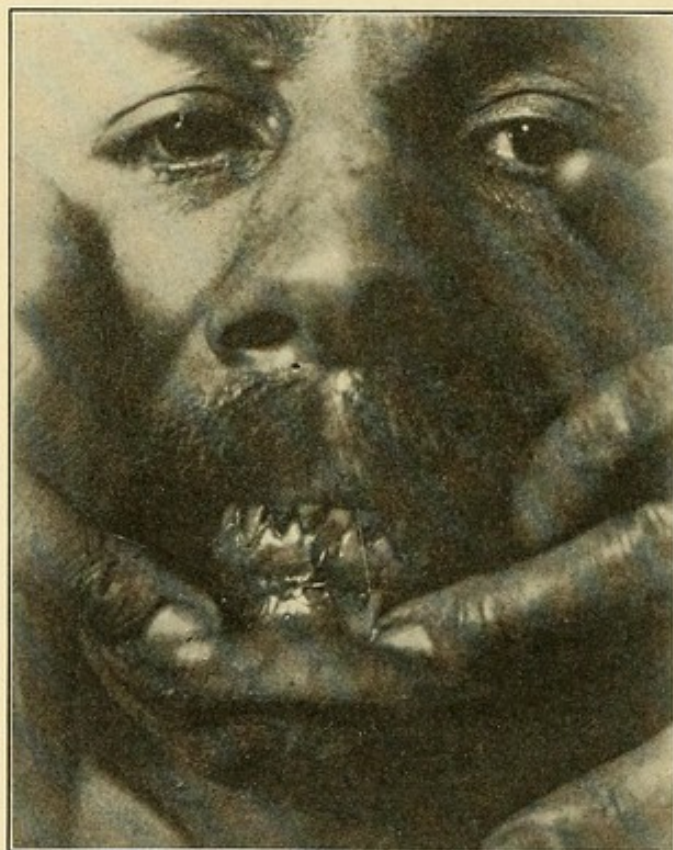


FIG. 208.—FRACTURE OF SYMPHYSIS WITH WIRES IN POSITION.

with the line of the teeth, splitting off one side of the process. The most frequent fracture of the alveolar process results from extraction of teeth. Such fractures, in rare instances, may be the result of unskilful extractions, but in the majority of cases are the result of unusually curved roots, or ankylosis between the tooth and process, following old inflammation. As a rule, no treatment is necessary, since the surface granulates and the parts are restored to a normal condition, the amount of deformity depending en-



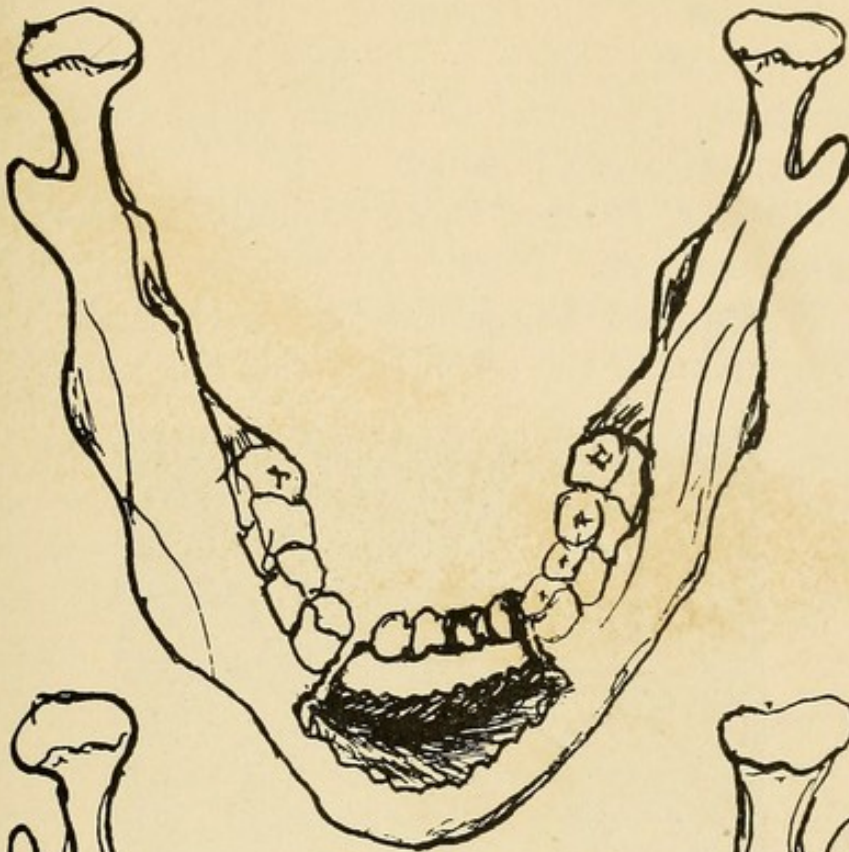


FIG. 209.

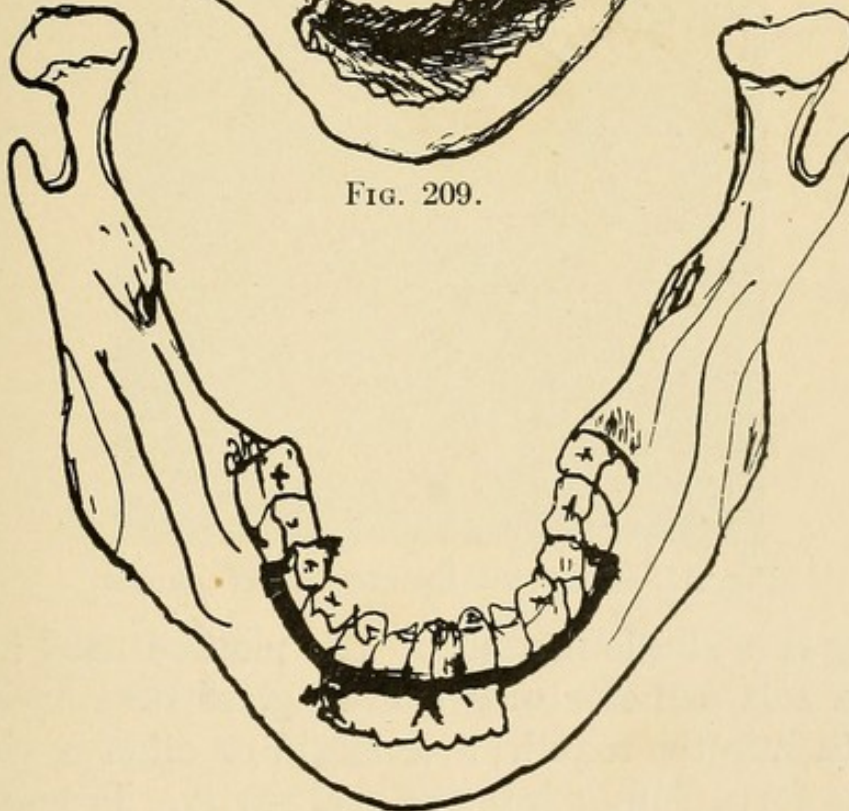


FIG. 210.

FIGS. 209 AND 210.—LONGITUDINAL FRACTURE OF THE ALVEOLAR PROCESS, INCLUDING FOUR TEETH, AS A RESULT OF A KICK BY A HORSE. Treatment included replacement of the fragment which was held in position by the use of wires extending back to the molars on both sides, which were held in position by finer wires passing from the internal to the external bar between the teeth.



tirely on the size of the fragment removed. If it includes several teeth down to the apex, it may be necessary to make an interdental splint-bridge to remedy the defects, and make perfect the masticating powers.

The method of feeding these patients is always a question of some concern. In cases where no teeth have been removed, it has been suggested that a tooth be extracted before adjustment of the teeth; but this has not been found

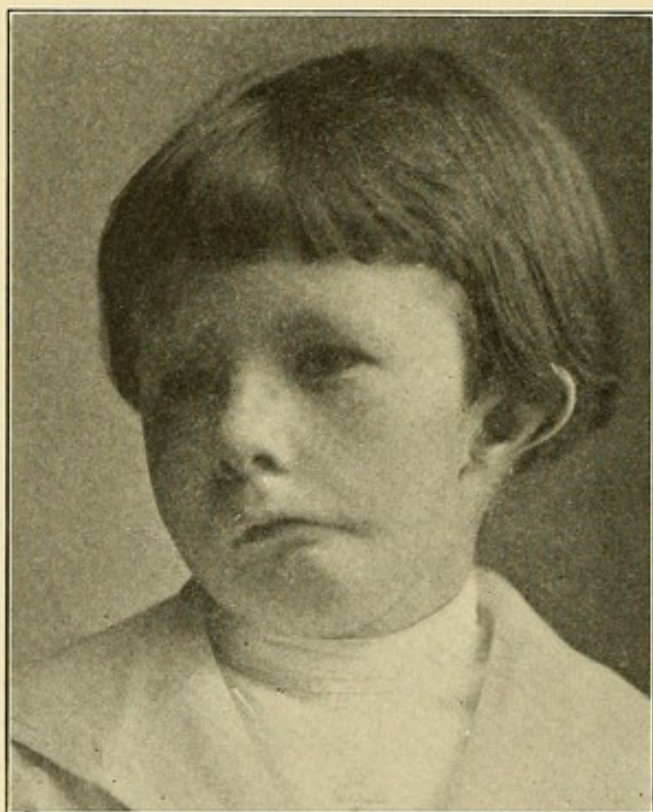


FIG. 211.—OBSTETRIC FRACTURE OF MANDIBLE.

necessary in a single instance. The method used has been to pass a soft catheter or a curved glass tube back of the back teeth into the mouth; a fountain or other syringe can be used to force liquids into the oral cavity. In many cases the patient can suck the liquid from a glass with ease, provided the tube is made with sufficient curve to permit closure of the lips.

**Case of Obstetric Fracture.**—In figure 211 we have a case of obstetric fracture of the jaw which must have at the same time injured the sympathetic nervous system,



since there is not only atrophy of the bone, but of all of the soft tissues of the left side of the face, including the lower half of the ear, and apparently all that part of the temporal bone which forms the external meatus.

It will be observed that the entire left half of the mandible has never developed, and that it is practically a straight line from the temporomandibular joint to near the symphysis. The only operation that could be done in this case would be to fracture the bone near the median line and make a second fracture at the angle. After this is done, the bone is to be held out either by a bridge work, which extends across the tongue within the oral cavity, or an external bridge work extending from the side of the head to the joint, the bone being wired up to it.

The operation has not been done for the reason that the boy has recently had scarlatina, which has left nephritis.



## CHAPTER XXXVI

### FRACTURE OF MAXILLA AND UPPER PART OF FACE

#### FRACTURE OF THE MAXILLA

Fractures of the maxilla are most frequently of the nasal process as a complication of nasal fractures, or of the alveolar process as a result of extraction or blows received upon the teeth, the force carrying along with the teeth a considerable portion of bone back of them. Such fractures are usually of the incisors or cuspid teeth, but may include the bicuspid or molars, when a not infrequent complication is perforation of the antral floor.

These fractures are generally compound, and are the result of direct violence. The line of fracture may include the antrum, when the palate bone is also included. Sufficient force may crush in the malar bone so as to fracture the anterior wall of the antrum. Force applied to the alveolus across the upper lip may break the entire roof of the mouth from the skull. Either the right or left maxilla may be torn from the face, the line of fracture being through the antrum into the nasal cavity and out through the roof of the mouth.

**Symptoms.**—Hemorrhage from the nose, mouth, or pharynx is quite common and may require ligation of the external carotid. Crepitation, mobility and emphysema are usually present, and, with hemorrhage and the history, constitute the principal diagnostic evidence. Patients bear these injuries well, as well as all injuries **about the face**, and complete union generally **takes place**, though deform-



ity is not always controlled, since, owing to the usually extensive swelling with emphysema, it is not always possible to effect a perfect adjustment of the displaced bones.

**Treatment.**—Treatment consists in reduction of fracture and retention of the fragments by wire or mechanical means for six or eight weeks.

Figure 212 represents the apparatus used in a fracture of both maxillæ through the nasal and antral cavities with separation of the two bones in the median line. The apparatus is that devised by Kingsley many years ago and is undoubtedly the best for treating these cases. The apparatus was removed every two or three days and boiled so as to keep it in a sterile condition. The accident was the result of the kick of a horse, breaking the nose as well as causing several lacerations of the face. Extensive ecchymosis of the left conjunctiva occurred. The use of the splint was permanently discontinued on the twenty-second day after the accident, sufficient union having taken place.

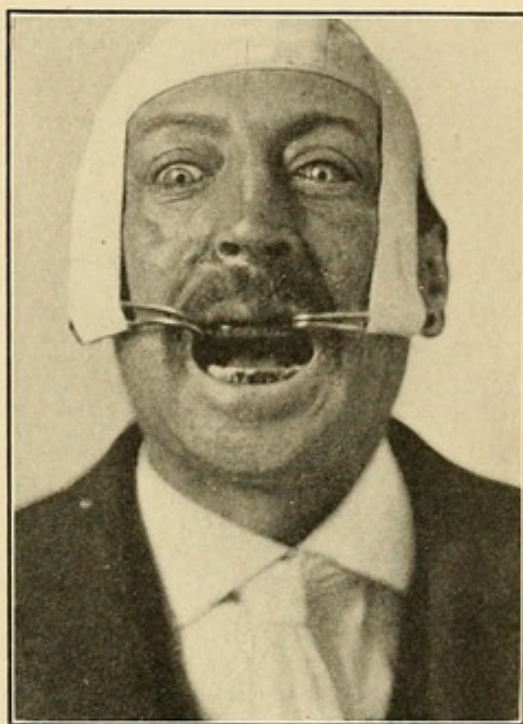


FIG. 212.—FRACTURE OF MAXILLA, SHOWING APPARATUS.

A. L. C. (see figure 213), while looking down a freight elevator shaft, with face over a gate, was struck by the elevator upon the top of the head between the parietal eminences. The line of force was from this point to the tip of the nose. The upper edge of the gate struck the bridge of the nose, crushing it down and tearing the cartilage loose. The line of fracture extended through the antra back from the anterior nares through the posterior nares, and included both the pterygoid processes of the sphenoid.



The roof of the mouth could be freely moved, and the fragment carried along with it the hamular process of the internal pterygoid plate, as well as the external plate. At the time of the injury the external maxillary artery, or a considerable branch of it, was torn off, resulting in such excessive hemorrhage as to produce syncope, one of the natural hemostatics which served well in this case. A sa-

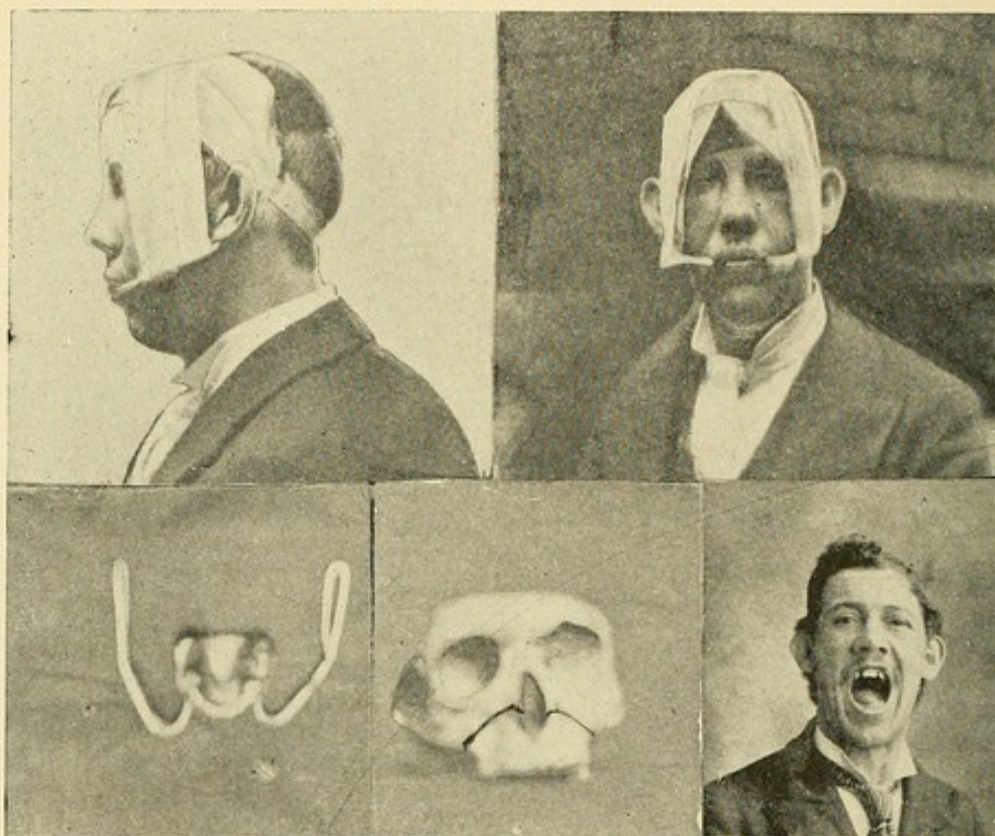


FIG. 213.—FRACTURE OF MAXILLA, SHOWING SKULL APPARATUS, METHOD OF APPLYING BANDAGE, AND RESULT.

line of one quart was injected into the median cephalic at the elbow, and when the patient aroused hemorrhage had ceased. The only inconvenience resulting from the accident has been occasional neuralgic pain, confined to the maxillary division of the fifth nerve.

All appliances are made of metal to fit the roof of the mouth and the teeth. Arms are soldered to the sides of the plate and project from the mouth through the angles. The plate is held firmly with a bandage passing over the head. (See figures 212, 213, 214.)



**Maxillary Fracture From Extractions.**—During extraction of teeth it is quite common for small portions of bone to come away with a tooth, but for no ill results to be anticipated. If, however, any considerable portion of bone is attached to the tooth or detached from the process by the tooth or forceps, careful examination of the parts should be made by the operator, so as to guard against complications.

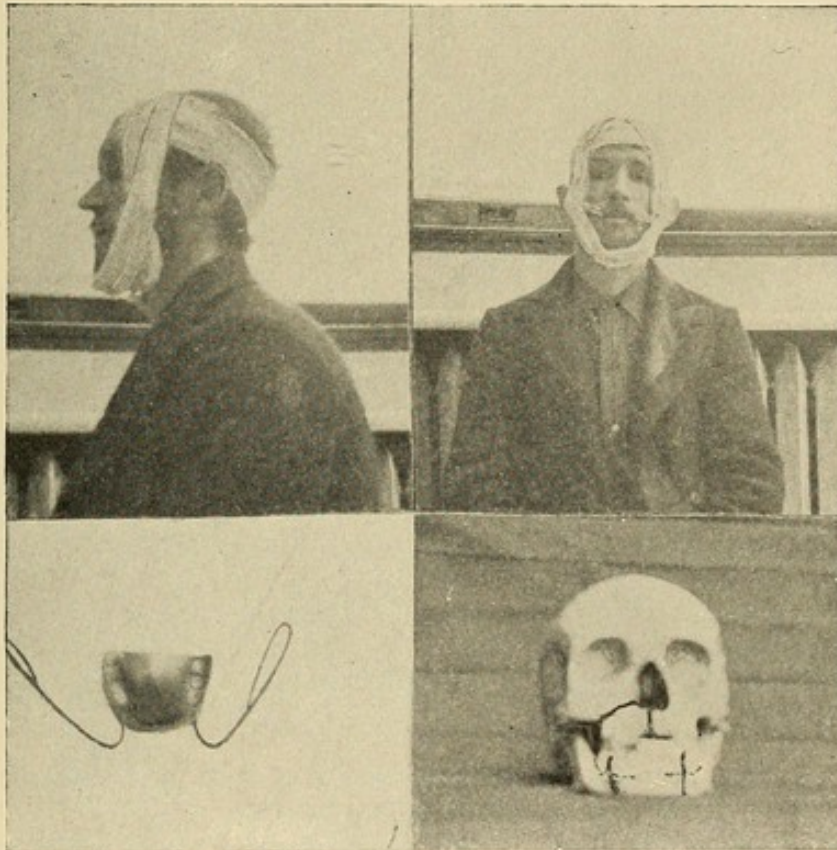


FIG. 214.—FRACTURE OF MAXILLA AND MANDIBLE.

It is an occasional complication for the mandible to be broken through and a more frequent occurrence for the outer or inner half of the process to be split away down to the apices of one or more teeth. In the maxilla, especially in the intermaxillary process where the bone is not so stable, the entire process is occasionally torn away. This is more liable in mouths that have had suppurative conditions about the teeth, for in such cases ankylosis of the tooth to the bone usually follows if the pathological change



has extended down in the socket for any distance. (Figure 216.)

A dentist recently came to the author and showed a molar to which was attached the process, including the

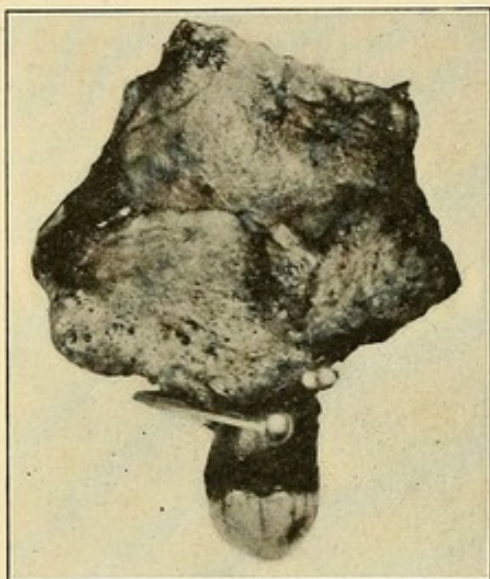


FIG. 215.



FIG. 216.

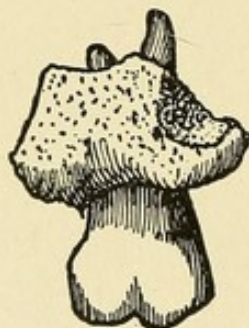


FIG. 217.

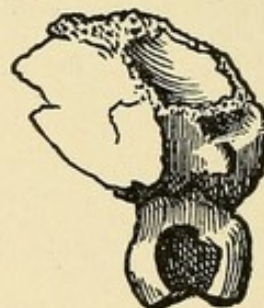


FIG. 218.

FIGS. 215-218.—FOUR CASES IN WHICH PORTIONS OF THE MAXILLÆ WERE BROKEN AWAY IN AN EFFORT TO EXTRACT A TOOTH. In three, the bony floor of the antrum was removed. The membranous floor remained intact and antral suppuration did not follow.

floor of the antrum. He was very much worried and wanted to know what he should do. He was advised to be sure that the lacerated gum and soft tissues were adjusted across the cavity left by the removed bone. This was done and repair followed, and the patient never knew that so much bone had been removed. (Figure 215.)



draw the nose into line, when other methods fail. For the correction of old deformities following fracture of these bones, see the chapter on Facial Deformities.

### FRACTURE OF THE MALAR BONE

Fracture of the malar bone is generally in the form of a depression and is the result of great force applied directly




FIG. 220.—DEPRESSED FRACTURE OF THE MALAR BONE, AFTER OPERATION. A half-inch incision was made down to the bone between the two branches of the transverse facial artery, and no vessels requiring ligation were severed. The bone was drilled and the coat hook screwed into it. Since this was a delayed case some effort was required to effect an adjustment, but this was satisfactorily done.

to the bone. It usually involves the orbital cavity and the antrum. If this bone is depressed greatly, it leaves a very disagreeable deformity, and should be reduced by all means. When the antrum is included, disease of this cavity does not necessarily follow, unless the fracture is made compound by a rent through the mucous membrane. Reduction is best accomplished by cutting down upon the bone and, if it cannot be returned to the normal position by



the use of elevators, a coat hook, gimlet or other screw may be bored into the bone deeply enough to take a firm grasp, when sufficient traction may be made to lift it from its false position. In delayed cases it may be necessary to make the skin incision to include the margin of the bone, so as to permit the use of an elevator under the edge, when, by prying, the bone can usually be lifted from its impacted position. When once returned to place, it usually remains so until repair is accomplished.

Some surgeons have used screws for this purpose, but a strong forceps or pliers is necessary to secure proper ad-

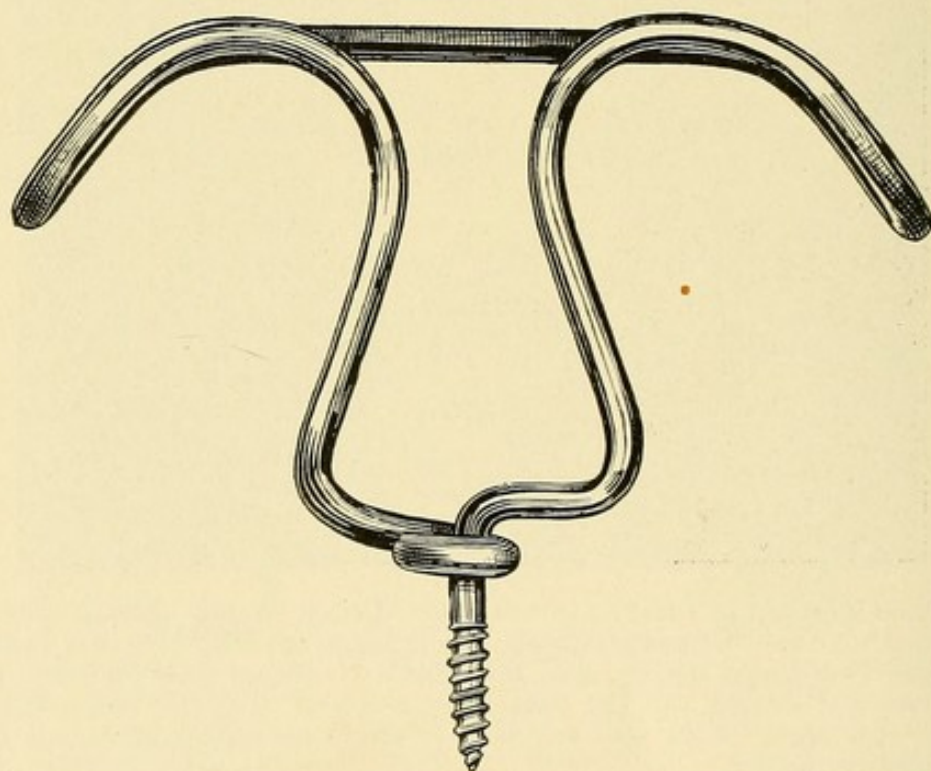


FIG. 221.—COAT HOOK FOR ELEVATING DEPRESSED FRACTURES OF THE MALAR AND OTHER BONES.

justment. With the coat hook can be accurately determined just how much force is being made, and the surgeon has perfect control of the fragment.

In operating, care must be taken to avoid the temporo-malar canal on the external surface of the bone. There is also danger of wounding the alveolar branch of the internal



maxillary artery with the drill point as it passes through the bone, since this artery passes forward and downward between the malar and maxillary bones.

### FRACTURE OF THE ZYGOMATIC ARCH

Fracture of the zygomatic arch is quite rare, and is usually the result of direct violence. It is of special interest to the dentist because the masseter muscle, which is inserted into the mandible, has its origin from this arch, and when this is fractured the movements of the mandible are restricted, if not entirely prevented.

**Symptoms.**—The symptoms are swelling and contusion, with local tenderness, which, when marked, prevent a thorough examination when the arch is depressed. The depressed bone may press upon the temporal muscle and contribute toward restriction of the movements of the mandible.

**Treatment.**—Treatment consists in immobilizing the mandible by a Barton bandage until repair takes place. When the arch is depressed it may be necessary to cut the skin down, and, with a hook or silver wire passed underneath, to draw the bones into place. When once replaced, there is little tendency to redisplacement.



## CHAPTER XXXVII

### DISLOCATIONS

#### DISLOCATIONS IN GENERAL

Dislocation is the displacement of one bone from another at its place of normal articulation.

The varieties are as follows: *partial*, when there is a displacement with some portion of one articular surface in contact with some portion of the other involved in the dislocation; *complete*, when there is an entire separation of the two articular surfaces; *simple* or *closed*, when the skin is not torn; *compound* or *open*, when the joint has atmospheric communication; *complicated*, when important structures are injured; *traumatic*, dependent upon an injury or where immediate violence causes displacement; *pathological* or *spontaneous*, when the result of destruction of a portion of the joint, and muscular contraction or other force gradually produces the displacement; *primitive*, when it is the first displacement of a given joint; *habitual* or *consecutive*, when subsequent, or possibly frequent, dislocations occur in the same joint; *double*, when the same joints are displaced on the two sides; *bilateral*, when both ends of a bone, such as the mandible, are displaced at the same time; *total*, when both ends of a long bone are displaced; *multiple*, when two or more joints are simultaneously displaced; *recent*, when seen immediately after the accident; *ancient* or *old*, when observed after some repair about the joint has taken place; *congenital*, when occurring in utero, as a result of defective development of some structure entering into



the formation of the joint. Dislocations occurring during parturition are usually classed as traumatic, yet are ultimately considered congenital, since they generally go unrecognized until the patient begins to use the joint.

**Anatomy.**—Structures which enter into the formation of a joint are bones, cartilages, ligaments and synovial membrane. Structures which surround the joint, which control the movements and which are affected by injuries to it are tendons, muscles, nerves, blood vessels, fascia and skin. Any one or more of these structures may be injured in dislocations.

*Bones* are held together by muscular contraction, and in some joints by internal ligaments, as in the knee; but the capsule and external ligaments have little to do with keeping the articular fibro-cartilages in contact. Flail-joint, found in paralysis, is an illustration of the muscular element in holding bones together. Atmospheric pressure is an element which only assists in holding bones in contact. The distal portion is considered the dislocated part.

The *location* average for dislocations is: ninety-two per cent. in the upper extremities, fifty-four per cent. in the shoulder, six per cent. in the lower extremities, and two per cent. in the vertebral column.

**Etiology.**—The causes of dislocation have to be considered under two heads, *predisposing* and *exciting*.

*Predisposing Causes.*—Ball-and-socket joints are more liable to displacements on account of the very free motion in every direction, while hinge joints are better protected by dense ligaments and are not so frequently dislocated. So it may be laid down as a rule that the greater freedom of motion there is in a joint, the greater liability there will be to dislocation. Some joints are so *situated* as to be much more exposed to violence than others, and are, therefore, more frequently dislocated. Dislocations generally occur in *adults* or middle-aged individuals, being rare in children (with the exception of those of the elbow joint), and in old



people. *Males* are much more liable to suffer from dislocations than females on account of their greater exposure to serious injuries. The *condition* of the *structures* around a joint may predispose to dislocation; for example, if they have been stretched by previous injury or effusion.

The *exciting causes* are twofold; either external violence or muscular action. Violence may cause dislocation in two ways, either *directly*, from a blow on one bone entering into the formation of a joint, driving it directly away from the other; or *indirectly*, where a fall or blow on one part of the bone is transmitted to its extremity and forces it away from the articular surface with which it is in contact.

**Symptoms.**—The signs by which a dislocation may be recognized are: *pain*, which is usually of a severe and sickening character; *impaired mobility*, so that the patient to a great extent is unable to perform the various voluntary movements of the joint; *change in the shape* of the joint; *alteration in the relationship* of the bony prominences in the neighborhood of the joints to each other; *displaced bone*, which can sometimes be felt in its new situation; an *alteration in the length* of the limb, as it is sometimes lengthened and sometimes shortened, according to the position of the head of the bone; an *alteration in the direction* of the long axis of the bone.

**Diagnosis.**—Dislocations may sometimes be mistaken for fractures. The chief points of distinction are impaired mobility, the absence of crepitus, and the fact that when the deformity is reduced it does not, as a rule, recur, whereas, in fractures the displacement recurs as soon as the extending force has been removed.

**Pathology.**—Motion in joints is limited by tension made upon the ligaments and joints, as in extreme positions. The *sac* is on tension on one side and relaxed on the other. *Hinge joints* permit motion in but two directions, and when lateral displacement occurs the lateral ligament must be de-



stroyed. *Ball-and-socket joints* permit range of motion in every direction on account of the redundant joint sac on all sides, permitting displacements with less force than occurs in more fixed joints. *Force* which dislocates joints is usually sufficient to rupture the sac and ligaments. *Synovia* escapes into the surrounding tissues when the sac is rent. *Muscles* and *tendons* are placed in extreme tension or dislocated under the displaced head of the bone, greatly interfering with reduction. *Repair* is prompt when bones are replaced promptly and when there is no complication.

**Complications.**—There may be fracture, or sprain fracture, which means that a portion of bone is carried with a ligament. *Joint sac laceration* may be extensive. *Compound* dislocation may occur with associated laceration of skin and soft parts on the side of the joint injured. Fracture or *epiphyseal separation* is a frequent complication, and a diagnosis is not easy when swelling is present. *Blood vessels* may be injured, resulting in a corresponding degree of impairment and nutrition, swelling, or even gangrene. *Nerves* are occasionally torn or injured, resulting in pain or paralysis of muscles, and when the sympathetic is injured vasomotor paralysis may result. *Traumatic synovitis* varying in proportion to the amount of injury always occurs.

**Treatment.**—Treatment of dislocation is divided into reduction, which is the prime aim; retention of the bones in a normal position until repair has taken place; and operation. *Immediate reduction* is advisable for two reasons: first, because the muscles are relaxed, especially if the patient is sick or faint; and, second, because the trauma results in some anesthesia of the parts, and reduction is less painful. When an effort at reduction is not made for several hours, the muscles will have become rigid, and an anesthetic may be required. Reduction is accomplished in two ways—by *manipulation* and by *extension*. Manipulation should always be tried first. The aim is to make the



head of the displaced bone retrace the course it made when the dislocation occurred. The direction of the force causing the displacement should be ascertained. The member should now be placed in the position relaxing the most muscles. The head of the bone is now rotated and pushed toward the joint. Reduction will usually follow such a procedure in partial, and many times in complete, displacement.

*Extension* is used only when manipulation fails. This method includes forcible traction upon the dislocated member, so as to overcome the muscular contraction, then lifting the bone back into place. Manipulation may be used along with extension.

*Operation* to return the bone by opening into the joint may be required. When reduction cannot be accomplished by the above methods, this should be done without hesitation. *Old dislocations* should be given a trial at reduction under an anesthetic by the bloodless method, but care should be taken not to do great damage to the soft surrounding tissues. Open operation is much more scientific, for the wound is made where desired, the bones can usually be replaced and the joint closed, and repair will occur without great damage to any tissues.

### DISLOCATION OF THE MANDIBLE

Simple dislocations of this bone occur in two forms: unilateral, when only one side is displaced, and bilateral, when both articulations are thrown forward. They are most frequent in women, and between the ages of twenty and thirty, being rare in the young and in the very aged.

**Causes.**—Conditions which predispose to this dislocation are paralysis, shallow glenoid fossa, and dental irregularities. The exciting causes are traumatism applied to one side of the chin, or downward, forcing the mouth open, objects forced into the mouth, yawning, laughing, and manipulation about the mouth as in the extraction of teeth.



**Anatomy and Mechanism.**—In forward dislocations the force applied is sufficient to depress the jaw so as to overcome the masseter and temporal muscles, throw the condyle on the eminentia articularis in partial, and over in complete, luxations. The pterygoid muscles assist in the dislocation, and the hypoglossus and digastric hold the tips of the mandible down, while the masseter and internal pterygoid hold the condyle firmly against the temporal bone in its abnormal position, thus locking the jaw. The capsule is not always ruptured.

**Symptoms.**—Symptoms are inability to close the mouth, with the mandible in a fixed condition, and the condyles abnormally forward. In unilateral dislocation the chin is thrown around to one side. The diagnosis is not difficult when the foregoing symptoms have been considered. Care must be taken to exclude fracture of the ramus or neck of the bone. The direction of the displacement is almost always forward and may be partial when the condyle of the mandible rests on the eminentia articularis and complete when it is thrown anterior to this process. Backward dislocations are very rare and are produced by a blow or by falling upon the chin.

**Treatment.**—Treatment is immediate reduction, with four weeks' rest, which will be followed by complete recovery. Cases have gone unrecognized for weeks, and the teeth gradually approximate each other. The only deformity noticeable will be the prominence of the chin. Reduction has been done as late as ninety-five days after the accident.

If for any reason, such as ignorance or timidity of the attendant, a dislocation remains unreduced for any length of time, say from six to eight weeks or more, reduction by manipulation is very difficult. If a *nearthrosis* or formation of a new joint has occurred and the member is fairly useful, no attempt at reduction should be attempted.

When, for special reasons, it is desirable that further



effort at reduction should be made, the rational procedure is to open the joint and, where possible, scoop out the old joint cavity and replace the bone in its normal position. When this is impossible, resection or arthrotomy may be practiced with promise of a fairly useful joint.

*Reduction* is best accomplished by standing in front of the patient, who is sitting on a chair, placing the thumbs,



FIG. 222.—REDUCING DISLOCATED MANDIBLE. One hand shown; both should be used in the same position as shown. Bandage placed around thumb to prevent injury from teeth when the bone slips into position.

protected by gauze or a napkin, well back in the angles of the mouth and against the rami, and, with the fingers resting under the symphysis and body, elevating the chin, while with the thumb the condyle is slid down and back under the eminentia articularis into place. In bilateral dislocations one side should be reduced at a time. The joint should be kept at rest by the use of a Barton bandage for two or three weeks, except during meals, and great care should be observed, as recurrence is quite common.



## CHAPTER XXXVIII

### X-RAY IN ORAL SURGERY <sup>1</sup>

Diagnosis of oral lesions is so difficult that the assistance of the X-ray is desirable. There is no difficulty in showing the lesions by this method. The only difficulty lies in the interpretation.

Its scope of usefulness may be summarized as follows:

1. Teeth.
2. Fracture.
3. Sarcoma and carcinoma.
4. Salivary calculi.

Abscesses of teeth may be recognized before the actual formation of pus occurs, by a slight increase in density, usually about the root of the tooth. When pus formation occurs, this density markedly increases. Later, after the pus has been either evacuated or absorbed and necrosis begins, the density of the abscess is replaced by a rarefaction of the bone, and the root of the tooth usually stands boldly up into this shadow. Abscesses about the roots of the lower molars frequently burrow downward and open externally. Such a sinus may be opened and the bone curetted, but, following this procedure, the wound refuses to close completely, and the X-ray shows a sinus leading up to the apex of one or more molar roots. Extraction of a tooth and through-and-through drainage is followed by cure.

Impaction of teeth is beautifully demonstrated by the X-ray, and the subsequent extraction or regulation is ren-

<sup>1</sup> George C. Johnston, Pittsburg, Pa.



dered much easier. Necrosis of the jaw, other than that arising from tooth abscess, is easily recognized by the rarefaction of the bone. Bone cyst is diagnosed from bone abscess by the failure of the cystic contents to cast the dense shadow characteristic of pus.

The orthodontist who makes routine use of the X-ray is thereby enabled to proceed more intelligently and with greater certainty of satisfactory results. Unerupted, misplaced or missing teeth are localized exactly, and their relations to the surrounding teeth accurately known. Great care must be exercised in the search for missing unerupted teeth. That a tooth is not found near its proper location is no evidence that the patient does not possess this tooth. It may be in the antrum or lying transversely beneath the root of an erupted tooth or lying in the proper position to erupt, being unable to do so because of a second unerupted tooth lying directly above, transversely in the bone.

The diagnosis of infection of the antrum with pus can be made with great accuracy by means of an antero-posterior view of the bones of the face, the plate placed against the nose and teeth, and the ray directed through the spinal column beneath the base of the skull, in a line parallel with the floor of the nose and directly in the median line. For the diagnosis of ethmoidal and frontal disease, the ray should be directed from behind forward, but at an angle of twenty-two and one-half degrees with the basal plane of the skull, which plane passes through the glabella and the two external auditory meati. The infected sinuses, or those containing edematous mucous membrane or pus or granulation tissue, will cast a much darker shadow than the normal sinus or sinuses filled with air.

Malignant disease of the bones, such as carcinoma and sarcoma, may be recognized by a rarefaction of bone and distortion of the outlines and a density other than that of normal bone. Sarcomata in or about the upper jaw usually



force various bony plates from their correct location, producing marked distortion and density.

Fracture of the lower jaw may be easily recognized if there be present more or less displacement of the fragments; but if the bone be merely cracked, a hasty examina-

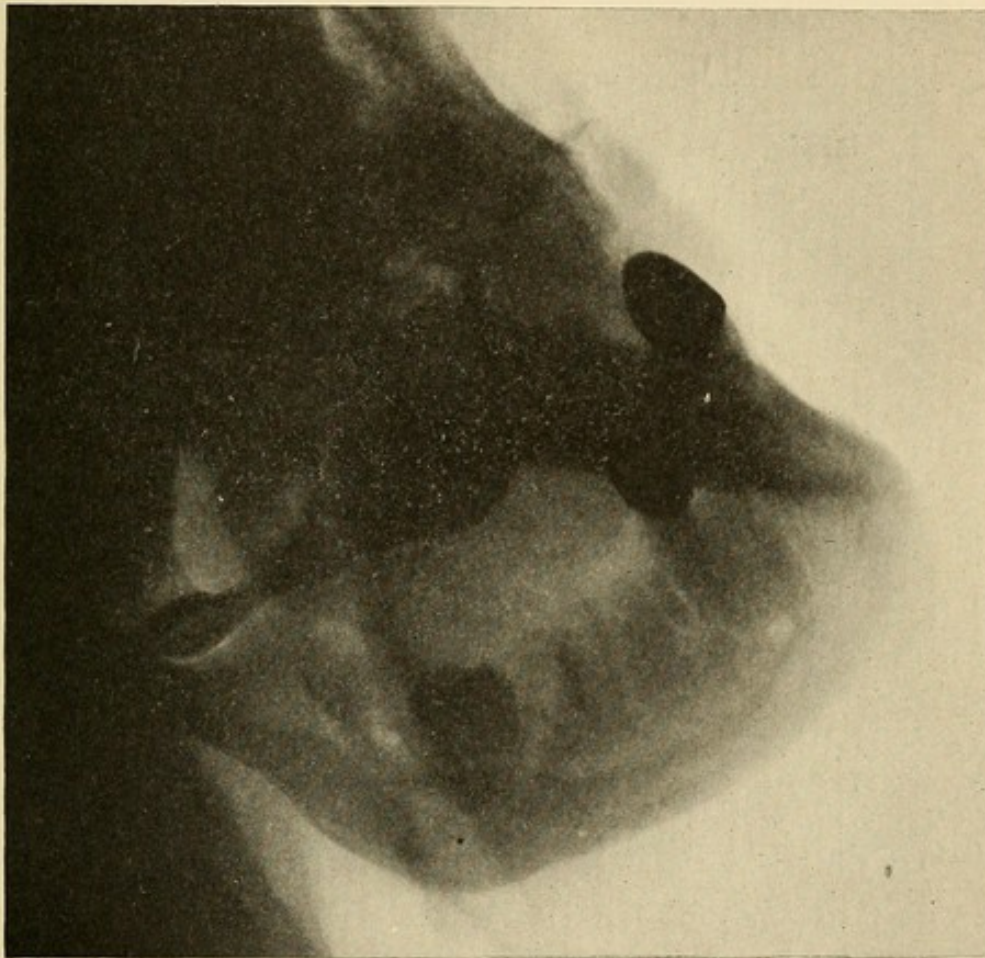


FIG. 223.—EPITHELIOMA ABOUT THE MOLAR TOOTH. Appearance of lower jaw when made on plate at correct angle. Teeth as far forward as lateral incisors may be shown perfectly. Half of jaw next to tube is thrown up on shadows of molar and orbit and is to be disregarded.

tion may fail to reveal the fracture, which may be discovered only when the path of the ray is made to traverse the path of the fracture. Usually, however, fractures of the jaw are accompanied by considerable displacement and the diagnosis is easy. Dislocation of the lower jaw and ankylosis are not easily diagnosed by the X-ray, on account of the difficulty of passing the ray in such a direction that the articulation may not have superimposed upon it the



shadows of the dense portions of the base of the skull. Foreign bodies in or about the mouth are best located stereoscopically, as described below.

Salivary calculi are usually quite opaque to X-ray. They are more frequent in the submaxillary duct, and here

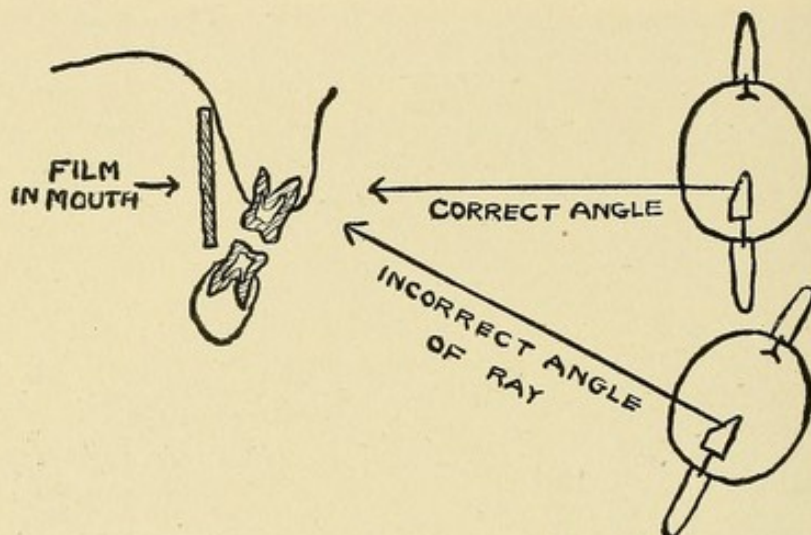


FIG. 224.—X-RAY TECHNIC.

the shadow of the calculus is usually superimposed upon the shadow of the lower jaw, and hence may be overlooked, unless a careful scrutiny of the plate be made.

**Technic.**—The length of exposure necessary to produce a radiogram varies with the location. Thus, a plate which

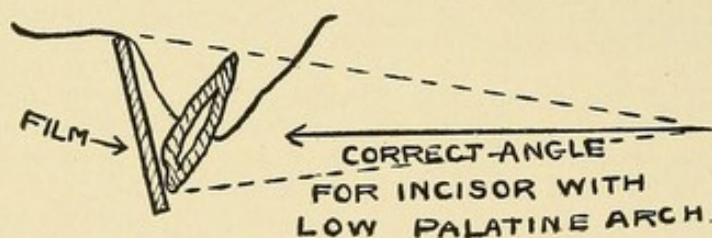


FIG. 225.—PROPER METHOD OF TAKING X-RAY OF JAW.

must show the antrums requires a considerable length of exposure, usually fifty to one hundred milliampere seconds. A film of the incisor teeth, on the contrary, requires but twenty to thirty milliampere seconds. Films an inch and a quarter by an inch and a half are about as large as can be used satisfactorily within the mouth. They may be ob-



tained ready folded from the Eastman Company, each packet containing two films face to face, folded in light-proof envelopes, which are fairly water-tight, at least sufficiently so to permit of placing them in the mouth long enough to secure an exposure. They must be pressed closely against the process and extend high enough up into

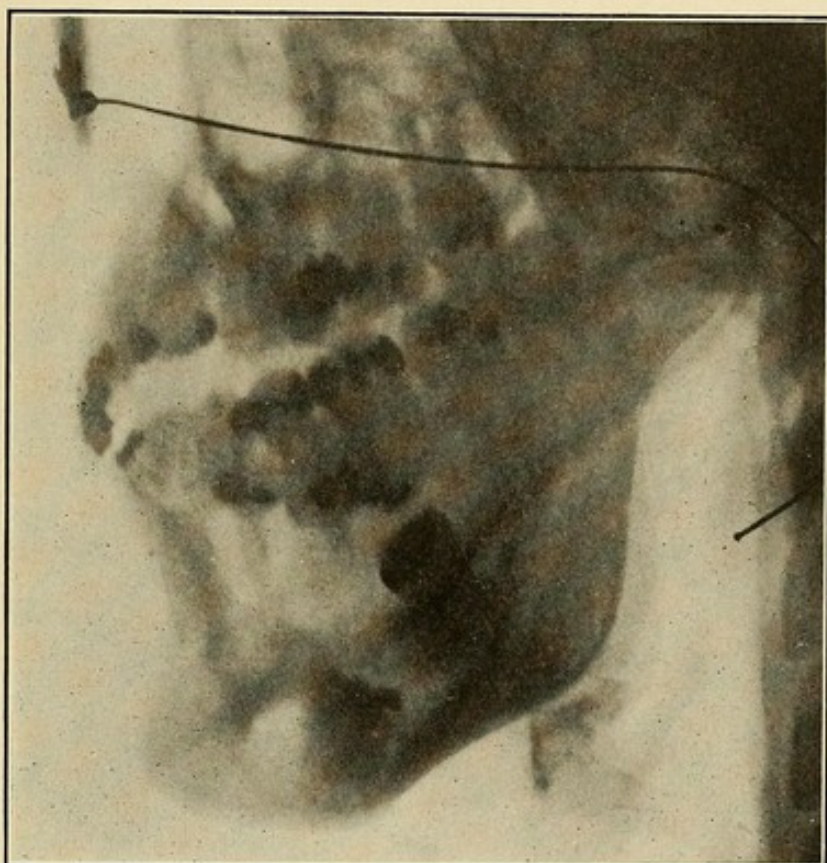


FIG. 226.—IMPACTION OF LOWER LEFT FIRST MOLAR, CONSIDERED A MOST RARE VARIETY OF IMPACTION. The tooth was removed with great difficulty. It will be observed that the lower margin of the body of the mandible is pushed down below the normal line on account of the encroachment upon the inferior line by the depth of the tooth.

the upper jaw and far enough down in the lower to receive the image of the apex of the roots. In the upper jaw, owing to the shape of the arch, a film usually lies at an angle of from thirty to sixty degrees from the median plane of the tooth, the image of which is desired. If the ray, therefore, be passed on a line perpendicular to the median plane of the tooth, the image of the tooth will be much elongated and distorted. If the ray, on the other hand, be passed



perpendicular to the plane of the film, the image of the tooth will be foreshortened and again distorted. Experience will teach a compromise angle, which in nearly every case will so correct the distortion as to do away with the

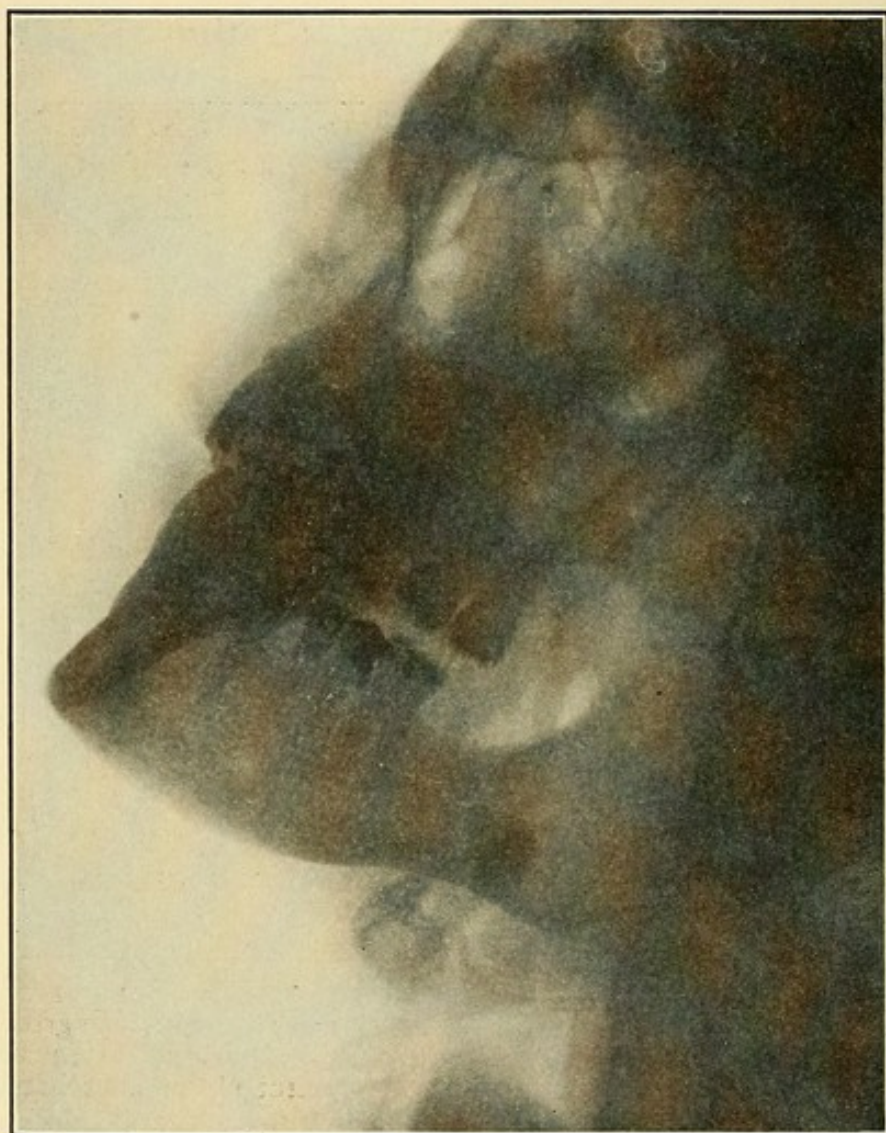

FIG. 227.—SALIVARY CALCULUS IN THE DUCT OF THE SUBMAXILLARY GLAND.

elongation and foreshortening and produce an approximately correct image on the film. The posterior portions of the lower jaw are best obtained upon a plate, the patient lying down with the affected side of the jaw upon the plate placed film side up in a light-proof envelope. By moving the tube toward the patient's body, the ray may be directed beneath the upper half of the jaw, which will appear upon



the plate as overlying the orbit and antrum of the affected side, and a clean image of the affected side will be cast upon

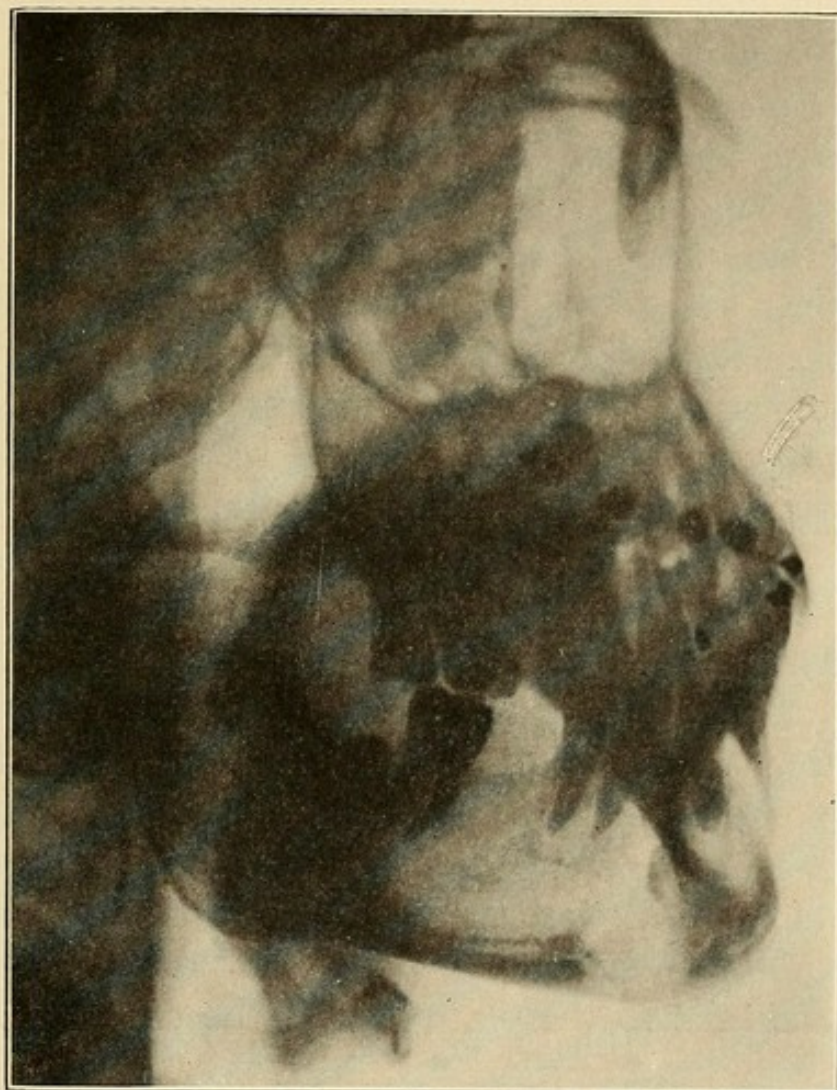


FIG. 228.—X-RAY PICTURE REPRESENTING A CYST OF THE MANDIBLE WHICH DEVELOPED IN ABOUT NINE MONTHS FROM THE DATE OF THE FIRST APPEARANCE OF ENLARGEMENT. Four months ago first molar was extracted and considerable serum was discharged. This did not, however, prevent the enlargement of the tumor on the external surface of the bone. Operation consisted in the extraction of the second molar, removal of the third molar, and removal of both cuspids, as the roots had been carried outward along with the wall of the cyst and the crowns inward at an angle of 45 degrees to the mandible. The teeth were removed because the apices were exposed in the cavity. The soft tissues on the external surface of the cyst and teeth were dissected loose. The bony cyst wall which had been developing was also removed. The entire soft tissues on the external surface were removed and dropped down into the cavity of the cyst after it had been curetted, with the idea of adhesion taking place between the two surfaces. Packing was placed on top of the membrane thus forced into the cavity. Repair followed immediately and the patient left the hospital on the fourth day without an unfavorable symptom. It will be observed that the mandible is nearly destroyed immediately under the bicuspid, and this would no doubt have occurred in a short time.



the plate, free from the shadows of the other half of the jaw.

When desired, a stereoscopic pair of negatives may be obtained by anchoring the patient's head securely against movement, placing the head upon a tunnel, centering the tube so as to pass the ray in the direction of desired inspection, moving the tube one and one-half inches to the right, making an exposure, removing the exposed plate and substituting a second plate in the exact position of the first, the patient meantime refraining absolutely from movement, then shifting the tube to the left until it occupies a position two and one-half inches to the left of its first position, and making a second exposure of exactly the same duration as the first. The resulting pair of plates should then be developed to the same density and placed in a Wheatstone reflecting stereoscope, wherein, upon transillumination, the right eye of the observer sees the plate made in the first tube position, and the left eye, the plate made in the second tube position. The blending of the images produces a correct stereoscopic effect. The plates upon the stereoscope should be so placed that the distance from the observer's eye to the plate is exactly the same as the distance from the anode of the tube to the plate during the exposure.



## APPENDIX

### QUESTIONS IN ORAL SURGERY







## PART I

### CHAPTER I

1. When was the first microorganism demonstrated and in what secretions?
2. What was the variety of the first microorganism demonstrated?
3. Who made the first systematic classification of microorganisms?
4. When and by whom were the first bacteria discovered in the blood?
5. Who established the nature of splenic fever and anthrax and thus defined the relationship of bacteria to disease?
6. Give the morphology of a bacterium.
7. How are bacteria reproduced?
8. Give the biology of a bacterium.
9. What is a saphrophyte?
10. What is a parasite?
11. Define the difference between a parasite and a saphrophyte.
12. What are the products of bacteria?
13. What are the substances found in the media of bacterial growth?
14. Define proteins.
15. What are ferments?
16. What are toxins?
17. Define the two divisions of toxins.
18. What are meant by the following terms as applied to the products of bacteria: pigments; photogenesis; fluorescence; odors; gas?
19. What are the effects of bacteria upon the tissues?



20. Define the local effects of bacteria upon the tissues.
21. In what general way do the products of bacteria affect the system?
22. What is the difference between a primary and a secondary focus of disease? Give illustrations.
23. What is immunity?
24. What is infection?
25. Name some of the infectious diseases.
26. What germs produce acute infections?
27. What germs produce suppurative diseases?
28. Define the difference between a pyogenic and a pathogenic germ.
29. Define the difference in the course of diseases due to streptococcic and those due to staphylococcic infections.
30. Give the definition of inflammation.
31. Give the five cardinal symptoms of inflammation.
32. Give the causes of inflammation.
33. What are the phenomena of inflammation?
34. Describe the vascular change in inflammation.
35. What is meant by exudation as applied to inflammation?
36. Describe the process of proliferation in an inflammatory area.
37. What is degeneration of tissues during inflammation?
38. Name the six varieties of inflammation.
39. What is hyperemia?
40. What is the difference between active and passive hyperemia or congestion?
41. What are the causes of congestion?
42. Give six results of inflammation, briefly defining each change.
43. What is necrosis as applied to soft tissues?
44. Give the five causes of necrosis.
45. Name and define the varieties of necrosis.
46. What is gangrene and give its causes?
47. Name the varieties of gangrene.
48. What is suppurative inflammation?
49. What is pus?
50. What is an abscess?
51. What is an ulcer?
52. What is a sinus?
53. What is a fistula?



## CHAPTER II

54. Name the non-specific infections.
55. What bacteria usually cause cellulitis?
56. Describe the clinical features of cellulitis.
57. Give the treatment of cellulitis.
58. What is sapremia?
59. Give the symptoms of sapremia.
60. Give the treatment of sapremia.
61. What is septicemia?
62. Give the symptoms and treatment of septicemia.
63. What is pyemia?
64. Give the differential symptoms between septicemia and pyemia.
65. What diseases are liable to be confused with pyemia?

## CHAPTER III

66. What is erysipelas?
67. What is the germ producing erysipelas?
68. What pathological changes take place in the tissues in erysipelas?
69. Give the local symptoms of erysipelas; the constitutional symptoms.
70. What are the varieties of erysipelas?
71. From what diseases must erysipelas be differentiated?
72. What is the prognosis of erysipelas?
73. Give the local treatment of erysipelas; the constitutional treatment.
74. What is actinomycosis?
75. What microorganisms produce actinomycosis?
76. What tissues of the mouth is mycosis likely to involve?
77. Give the treatment of mycosis.
78. What is tetanus?
79. What variety of bacterium causes tetanus and how does the infection occur?
80. Give the symptoms and treatment of tetanus.
81. What is hydrophobia and how does the inoculation occur?
82. Give the symptoms, prophylaxis and treatment of hydrophobia.
83. What is anthrax?
84. How is diagnosis of anthrax made?
85. What serum is used in the treatment of anthrax?



## CHAPTER IV

86. What is tuberculosis?
87. What are the four principal etiological factors of tuberculosis?
88. Give the avenues of entrance of the bacillus of tuberculosis into the body.
89. Describe the pathology of a tubercle.
90. What is the general course of tuberculosis?
91. What tissues are likely to be involved?
92. What are the usual fates of a tubercle?
93. Give the general and local treatment of tuberculosis.

## CHAPTER V

94. What are the venereal diseases?
95. How are the venereal diseases usually transmitted?
96. Give the definition of gonorrhea.
97. Give the name and classification of the germ of gonorrhea.
98. What tissues are usually infected and what other tissues may be infected in gonorrhea?
99. What are the complications of gonorrhea?
100. What are the remote serious results of gonorrhea?
101. Give the treatment for gonorrhea.
102. What is chaneroid?
103. In what way is chaneroid transmitted?
104. Describe the characteristic sore of chaneroid.
105. What is meant by autoinoculation as applied to chaneroid?
106. What are the complications of chaneroid?
107. Give the treatment for chaneroid.
108. Is chaneroid a constitutional disease?
109. Give the definition of syphilis.
110. By whom and in what year was the microorganism of syphilis demonstrated?
111. Name and define the microorganism of syphilis.
112. Where is the microorganism of syphilis found?
113. What is meant by the Noguchi and the Wassermann reactions?



114. What are the modes of contagion of syphilis?
115. What is Colles' Law?
116. Give the stages and periods of syphilis.
117. Define the primary lesion of syphilis, giving its appearance.
118. What are the complications of the first stage of syphilis?
119. Give eight points in making a diagnosis of chancre.
120. What are secondary lesions?
121. When in relationship to time of the chancre do the secondary lesions generally occur?
122. Give the usual secondary lesions.
123. Define tertiary lesions.
124. When in relationship to time may the tertiary lesions occur?
125. What is the difference in the course and the effect upon the tissues between the secondary and the tertiary lesions?
126. What are the usual lesions of tertiary syphilis?
127. Give the pathology of a gumma.
128. How does syphilis attack the bones?
129. Where are gummata usually located?
130. What is hereditary syphilis?
131. Describe the appearance of a syphilitic child.
132. What is the prognosis in the various stages of syphilis?
133. In what stages of syphilis is the disease most virulently inoculable and when is it not inoculable?

## CHAPTER VI

134. Classify wounds, giving a brief description of each class.
135. Describe the difference between arterial and venous hemorrhage.
136. How is external hemorrhage controlled?
137. What is internal hemorrhage and where may it occur?
138. How is internal hemorrhage controlled in the various organs of the body?
139. Give the treatment of burns and scalds from various causes.
140. Give the differential symptoms of concussion and compression as applied to injuries of the brain and skull.
141. What should be done in cases of foreign bodies in the following locations: eye; nose; throat; larynx; stomach?



## CHAPTER VII

142. Give the uses of bandages.
143. What materials are used in making bandages?
144. Name the varieties of bandages.
145. Give the uses of a roller bandage.
146. Give the uses of a triangular bandage.
147. Describe a Barton bandage.

## CHAPTER VIII

148. What is shock?
149. Give the symptoms, diagnosis and treatment of shock.
150. Name and briefly define the following terms: coma; apoplexy; asphyxia; epilepsy.
151. Give the usual causes of convulsions in children and the usual prognosis and treatment.
152. What diseases of the kidneys result in convulsions and what is their significance?

## CHAPTER IX

153. Give the definitions of the three following terms: asepsis; sepsis; antisepsis.
154. What do asepsis, sepsis and antisepsis mean as applied to surgical practice?
155. What is a germicide?
156. Name several germicides, giving their usual strength of solution and method of use.
157. How are dressings prepared for use in surgical cases?
158. How is the operating room prepared for surgical cases?
159. How is the patient prepared for an operation?
160. Define the terms suture and ligature.
161. How are sutures and ligatures used and of what materials are they made?

## CHAPTER X

162. What things are necessary to make a correct diagnosis?
163. What points must be considered in making a case history?
164. What things must be taken into consideration in obtaining a complete knowledge of a disease?



165. Define the various terms used in studying a disease.
166. What points are to be considered in making a medical diagnosis?
167. What is meant by physical diagnosis?
168. Define the following terms and explain their scope of usefulness: inspection; mensuration; palpation; percussion; auscultation.
169. What is pulmonary resonance?
170. What is dullness and what does it indicate?
171. What is flatness and what does it indicate?
172. What is a râle?
173. What is tympanitis?
174. What is vesicular murmur?

## CHAPTER XI

175. How are the diseases of the heart classified?
176. What elements produce the heart sounds and what are they likened unto?
177. To what diseases are the heart valves subject?
178. What is the difference between regurgitation and stenosis as applied to the valves of the heart?
179. Describe pericarditis, endocarditis, hypertrophy and dilatation as applied to disease of the heart.
180. Give the usual pulse rate and tell what artery is made use of in determining the character of the pulse.
181. Describe the difference between a frequent and a quick pulse.
182. What drugs increase the frequency of the heart and what drugs diminish it?
183. What are the diseases of the blood vessels?
184. What diseases are likely to attack the walls of the blood vessels?
185. What are the diseases of the contents of the blood vessels?
186. What is aneurism and what are the varieties?
187. What is angioma?
188. Name and describe the various diseases of the lymphatic system.
189. What is a lymphangioma?



## PART II

## CHAPTER XII

1. Is there a difference in the pathology of the mouth and that of other parts of the body?
2. Describe the complex nature of the mouth.
3. Name the many functions of the mouth.
4. Name the accessory cavities of the mouth.
5. Describe the mucous membrane of the mouth.
6. Name the disturbances of dentition.
7. What reflex neuroses may result from dentition?
8. What skin lesions are observed as apparent results of dentition?
9. Name some of the prominent mouth lesions associated with general or constitutional diseases.
10. What effect do alcohol and tobacco have on the tissues of the oral cavity?
11. What can be said regarding the presence of bacteria in the mouths of apparently healthy persons?
12. What is meant by Hutchinson's teeth?
13. What is Black's theory regarding the cause of defects of teeth in children?
14. Name some of the complications of extractions.
15. What is a reflex neurosis?
16. What general diseases have been traceable to impacted teeth, ulcerations, and other defective conditions of the teeth and peridental structures?
17. What general diseases of the nervous system have been traceable to diseases of the mouth?

## CHAPTER XIII

18. What bearing has alveolar abscess upon the production of serious lesions of the facial bones?
19. How is an apical cyst developed and how may it result in more serious conditions?



20. In what way does infection occur in alveolar abscess?
21. Give the pathology of an alveolar abscess.
22. What is the treatment for alveolar abscess of the mandible?
23. What do you understand by blood clot organization?
24. What is the difference between the course of an alveolar abscess in the mandible and one in the maxilla?
25. What cavities may be perforated from diseased teeth in the maxilla?
26. What is a naso-oral fistula?
27. Give the treatment for a chronic alveolar abscess where the root of a tooth is exposed in the cavity.

#### CHAPTER XIV

28. Give a definition for stomatitis.
29. Give the two general divisions of mouth lesions.
30. Name the varieties of stomatitis.
31. What acute constitutional diseases produce mouth lesions?
32. What chronic constitutional diseases produce mouth lesions?
33. What drugs produce mouth lesions?
34. Give the symptoms, diagnosis and treatment of catarrhal stomatitis.
35. What are the two forms of ulcerative stomatitis?
36. Give the symptoms of ulcerative stomatitis.
37. Name some of the complications of ulcerative stomatitis.
38. What is the treatment for ulcerative stomatitis?
39. Give the symptoms, diagnosis and treatment for herpetic stomatitis.
40. Give a description, diagnosis and treatment of mycotic stomatitis.
41. Give the differential symptoms between mycotic stomatitis and diphtheria.
42. Give the differential symptoms between catarrhal stomatitis and ulcerative stomatitis.
43. Differentiate between the mouth lesions of mercury poisoning and chronic lead poisoning.
44. What are the mouth lesions from pilocarpine poisoning?



45. What conditions result from the excessive use of iodine?
46. Name and describe some of the skin diseases which have mouth lesions.
47. What are Koplik's spots?
48. What is strawberry tongue?
49. What is perlèche?
50. Give the definition and cause of Vincent's angina.
51. Give the history of Vincent's angina.
52. What bacteria produce Vincent's angina?
53. What diseases and conditions are liable to be confused with Vincent's angina?
54. Give the symptoms of Vincent's angina.
55. What are the clinical features in the lesion of Vincent's angina?
56. Give the diagnosis of Vincent's angina.
57. What is the prognosis of Vincent's angina?
58. What is the treatment for Vincent's angina?

## CHAPTER XV

59. Of what importance to the dental practitioner is the study of the tongue?
60. What clinical significance is found in the coating of the tongue?
61. What does a beefy or red tongue indicate?
62. What significance do the different colors of the tongue have?
63. What significance is there in the shape of the tongue in diagnosing general diseases?
64. What does a bitter taste indicate?
65. What are the congenital defects of the tongue and briefly describe each?
66. What is the treatment for ankyloglossia and macroglossia?
67. Classify the acquired affections of the tongue.
68. Describe glossitis, giving its treatment.
69. What is Ludwig's angina and what is the treatment for it?
70. Describe chronic inflammation of the tongue, giving cause and treatment.



71. What is leucoplakia of the mouth?
72. Give a description of the tongue in leucoplakia.
73. What diseases must be differentiated from leucoplakia?
74. What is the treatment of leucoplakia?
75. What varieties of injury is the tongue liable to?
76. What is lingual goiter?
77. Name the tumors of the tongue.
78. What are the steps required to differentiate between benign and malignant tumors of the tongue?
79. Should operations be performed on the tongue before microscopic examinations are made?
80. What diseases are liable to be mistaken for malignant diseases of the tongue?
81. What is the treatment for benign tumors of the tongue?
82. What is the treatment for malignant diseases of the tongue?

## CHAPTER XVI

83. What are the characteristic features of a healthy face?
84. What pathological conditions should be observed in the first glance in the study of a face?
85. What is erythema?
86. What is meant by the following terms: petechia; macula; papule; vesicle; pustule?
87. What is dermatitis?
88. What is acne vulgaris?
89. What is the difference between comedo and milium?
90. Give the pathology and treatment of a sebaceous cyst.
91. What is verruca?
92. Give the pathology of verruca.
93. What are skin horns?
94. Differentiate between tinea sycosis and tinea trichophytina.
95. Give the pathology and treatment of carbuncle and furuncle.
96. What is neurosis of the face?
97. Give the differential points between hyperesthesia and anesthesia.
98. Give the difference between hypertrophy and atrophy.



## CHAPTER XVII

99. Give the classification of general bone diseases.
100. What is general infective osteomyelitis?
101. What bacteria produce general infective osteomyelitis?
102. What pathological changes occur in general osteomyelitis?
103. What is a sequestrum as applied to bone disease?
104. What is acute circumscribed osteomyelitis?
105. What is chronic circumscribed osteomyelitis?
106. What is acute diffused osteomyelitis?
107. What is chronic diffused osteomyelitis?
108. Differentiate acute general from circumscribed osteomyelitis.
109. Differentiate chronic circumscribed from diffused osteomyelitis.
110. What are the complications of infective bone disease?
111. What is the treatment for infective bone disease?
112. What is bloodclot organization?
113. Describe the method of repair after bone destruction and operation.
114. Classify periostitis.
115. Give the pathological changes in acute suppurative periostitis.
116. What general diseases produce disease of the bones?

## CHAPTER XVIII

117. Give the etiological classification of diseases of the mandible.
118. What is necrosis as applied to bone disease?
119. How may the use of the hypodermic syringe cause necrosis of the alveolar process?
120. What are the causes of alveolar necrosis?
121. Give the symptoms of alveolar necrosis.
122. Give the treatment of alveolar necrosis.
123. Describe the symptoms of acute periostitis of the body of the mandible.
124. What is the treatment for acute periostitis of the body of the mandible?
125. Give the cause of osteomyelitis of the body of the mandible.
126. Give the treatment for osteomyelitis of the body of the mandible.



127. What is meant by chemical necrosis and what drugs produce destruction of bone?
128. Describe phosphorus necrosis of bone, giving its management.
129. How may mercury produce necrosis?
130. What are the characteristic symptoms of the early stage of mercurial necrosis?
131. How does arsenic result in death of bone?
132. What is exanthematous necrosis and of what diseases is it a sequela?

## CHAPTER XIX

133. Give the symptoms of acute suppuration of the maxilla.
134. What is the treatment for acute suppuration of the maxilla?
135. Where should incision be made for abscess of the maxilla?
136. What are the complications of destruction of the maxilla?
137. What is a naso-oral fistula?
138. Describe the operation for closure of a naso-oral fistula.
139. Is tuberculosis a common cause of necrosis of the maxilla?
140. How may tabes dorsalis cause facial bone disease?
141. What is acromegaly and what bones are most frequently hypertrophied?
142. What is leontiasis ossea, and in what way does it produce symptoms in the dental field of operation?
143. How is bone regenerated after destruction?
144. What would be your practice in a case of destruction of the entire body of the maxilla as regards removal?
145. What is the advantage in leaving the sequestrum in the mouth even after it is detached?
146. What is meant by the following terms as applied to bone disease: papilla; sinus; chloaca; involucrum; sequestrum?
147. Describe the technique of operations upon the alveolar process.
148. Would you incise through the skin in operations upon the maxilla or mandible; if not, why not?

## CHAPTER XX

149. In what forms do tuberculous lesions appear on the face?
150. Give the symptoms and pathology of scrofuloderma.
151. What is tuberculosis cutis?



152. What is the pathology of lupus vulgaris?
153. Differentiate lupus vulgaris from lupus exedens.
154. Differentiate syphilitic ulcer of the face from lupus vulgaris.
155. Give the treatment for tuberculous diseases of the skin.
156. What are the characteristic mouth lesions of tuberculosis?
157. Describe a characteristic tuberculous ulcer of the mouth.
158. What are the usual tuberculous diseases of the bones of the face?
159. Give the treatment of tuberculosis of the mouth.

## CHAPTER XXI

160. What is the danger to the dentist in operations upon the mouths of syphilitic patients?
161. Is it common for dentists to become inoculated with syphilis from their patients?
162. What is the appearance of an initial lesion of the mouth?
163. What are the usual secondary manifestations as found in the mouth?
164. What are the tertiary lesions of the mouth?
165. In hereditary syphilis where are the lesions to be found?
166. Differentiate an initial lesion from a secondary patch.
167. Differentiate a secondary patch from a gumma.
168. Differentiate a secondary patch from ulcerative stomatitis.
169. In what stages is syphilis virulently inoculable and in what stages and varieties is it not inoculable?
170. Differentiate a gumma of the mouth from an epithelioma.
171. Differentiate gumma from a tuberculous ulceration of the mouth.
172. What is sclerosing glossitis?
173. What is specific ulcerative gingivitis?
174. Classify the syphilitic diseases of the facial bones.
175. Give the symptoms of syphilitic bone disease.
176. What diseases must be differentiated from syphilitic bone disease?

## CHAPTER XXII

177. What is a tumor?
178. How are tumors distinguished from inflammatory conditions and hypertrophies?
179. Give the theories as to the etiology of tumors.



180. Give the histological classification of tumors.
181. Give the clinical classification of tumors.
182. Give White's classification of tumors.
183. Describe fibroma and give its pathology, varieties and treatment.
184. Describe lipoma and give its pathology, varieties and treatment.
185. Describe adenoma and give its pathology, varieties and treatment.
186. Describe neuroma and give its pathology, varieties and treatment.
187. Describe cystoma and give its pathology, varieties and treatment.
188. Give the classification of the non-infective tumors of the soft tissues of the mouth.
189. What are cysts of the glands of Nuhn and where are they located?
190. Give the general divisions of tumors of the alveolar process.

## CHAPTER XXIII

191. What are developmental tumors of the teeth?
192. Give the probable histology of developmental tumors of the teeth.
193. Give Sutton's classification of odontomata.
194. From what tissues does an epithelial odontome develop?
195. What is a follicular odontome?
196. What is a dentigerous cyst?
197. What is the pathology of follicular odontomata?
198. What are cementous follicular odontomata?
199. What are reticular odontomata?
200. Why is the term composite odontomata used?
201. Give the general symptoms of odontomata.
202. What does Broca say regarding the diagnosis of odontomata?
203. Give the characteristic symptoms during the course of development of odontomata.
204. At what age do odontomata develop?
205. From what other pathological conditions of the alveolar process is a differential diagnosis of odontomata to be made?
206. What is the treatment for odontomata?



## CHAPTER XXIV

207. Name the most common forms of the neoplasms of the alveolar soft tissues.
208. Differentiate papilloma from polypus of the alveolar process.
209. What is hypertrophy of the mucous membrane of the alveolar process?
210. What is epulis?
211. How many varieties of epulis are recognized?
212. What is the difference between the varieties of epulis as regards prognosis?
213. What is chloroma?
214. Give history and prognosis of chloroma.
215. What are the bone tumors and cysts of the alveolar process?
216. Differentiate an exostosis from an osteoma.
217. What conditions cause cysts of bones?
218. What is the treatment for bone cysts?
219. What are the essential points in operating upon bone cysts and why may they return?

## CHAPTER XXV

220. What is sarcoma?
221. Give the varieties of sarcoma.
222. Give the prognosis and treatment of sarcoma.
223. How does sarcoma attack the tissues of the mouth?
224. What tissues are most likely to be attacked by sarcoma?
225. Give the symptoms of sarcoma of the tissues of the oral cavity.
226. Give the treatment for sarcoma of the tissues of the mouth.
227. What is carcinoma?
228. Give the three varieties of carcinoma.
229. What is lupus exedens and differentiate it from lupus vulgaris?
230. What is the treatment for epithelioma of the skin?
231. What is tubular carcinoma and what tissues does it attack?
232. What is acinous carcinoma?
233. Describe epithelioma of the mouth.
234. Differentiate epithelioma of the mouth from other mouth lesions.
235. What is the treatment for epithelioma of the mouth?



## CHAPTER XXVI

236. What are the diseases that are likely to develop from fully developed teeth?
237. What are impacted teeth?
238. What are the symptoms of impacted teeth without a sinus?
239. What are the symptoms of impacted teeth with a sinus?
240. What teeth are most frequently impacted?
241. What is the position of an impacted third molar and why does it assume this position?
242. What complications are likely to be associated with impactions of teeth?
243. What is the treatment for impacted teeth?
244. May cystic tumors of the alveolar process develop during the eruption of teeth?
245. What is the treatment of cystic tumors of the alveolar process?
246. What is a cyst from the root of a developed tooth?
247. What is the pathology of a cyst from the root of a developed tooth?

## CHAPTER XXVII

248. What are the usual congenital defects of the face and mouth?
249. Describe the embryology of the development of the face.
250. What is the intermaxillary process?
251. What is the cause of harelip and cleft palate?
252. Why is harelip never in the median line?
253. What are some of the minor congenital defects of the face and mouth?
254. What are the causes of acquired cleft palate?

## CHAPTER XXVIII

255. Give the clinical varieties of harelip.
256. What is the prognosis in cases of harelip?
257. Describe an operation for complete unilateral harelip.
258. Describe an operation for incomplete unilateral harelip.
259. Describe an operation for complete bilateral harelip.
260. What sutures are usually used for closure of harelip?
261. What is the usual practice regarding dressings after operations for harelip?



## CHAPTER XXIX

262. Give the history of cleft palate operations.
263. Give the causes of cleft palate.
264. Give the clinical varieties of cleft palate.
265. What are the arguments in favor of early and those in favor of late operations for cleft palate?
266. What anesthetic is best for operations for cleft palate?
267. What is the difference between uranoplasty and staphyloplasty?
268. What are the usual causes of failure of union after cleft palate operations?
269. What are the arguments for and against approximation of the maxillary bones in infancy for cleft palate cases?
270. What is the best position for the patient in cleft palate operation?
271. What instruments are used in cleft palate operations?
272. Name the varieties of operation for cleft palate.
273. Describe uranoplasty.
274. Describe operation for cleft of the alveolar process.
275. Describe operation for bilateral complete cleft palate.
276. What suture materials are usually used in cleft palate operations?
277. Describe Ferguson's operation for unilateral cleft palate.
278. Describe a method of introducing sutures in cleft palate operations.

## CHAPTER XXX

279. Name the sinuses accessory to the nasal cavity.
280. Describe the mucous membrane of the nose and its extensions.
281. What cavities are partly formed by the maxillary bones?
282. Describe the cavity of the maxillary bone in detail, giving its shape, foramina of exit, etc.
283. What is the relationship of the maxillary sinus to the alveolar process at the first molar?
284. Give the anatomical relationship of the orifice of the frontal sinus to that of the maxillary sinus.
285. In what way may the antrum become infected from the frontal sinus?



286. Give the etiological classification of diseases of the maxillary sinus, giving the divisions and subdivisions.
287. How is the maxillary diseased from the teeth?
288. What conditions produce acute infections of the maxillary sinus?
289. What are the growths found in the maxillary sinus?
290. Give the symptoms of suppurative antral disease.
291. Name the principal diagnostic points to be considered in suppurative antral disease.
292. Give the differential diagnosis of suppurative disease of the antrum.
293. What is the prognosis in suppurative antral disease?
294. Give a brief outline of the treatment of suppurative antral disease.
295. Describe two operations for the purpose of entering the antral cavity.
296. What is your idea as to the use of canula after opening the antrum into the mouth?
297. What destructive bone diseases are likely to have as a complication antral suppuration?

## CHAPTER XXXI

298. Give definition of neuralgia.
299. Name some causes of neuralgia of the fifth nerve.
300. Give the symptoms of neuralgia of the fifth nerve.
301. At what points do the three divisions of the fifth nerve come nearest to the surface?
302. What does tenderness of these points indicate?
303. Give the differential points between neuralgia and other diseases of the same region.
304. What is the prognosis of neuralgia?
305. How is the treatment of neuralgia divided?
306. Give the medical treatment of neuralgia.
307. How is neuralgia treated by injections?
308. What is the usual solution used in injections for neuralgia?
309. Describe a deep injection of the second division of the fifth nerve.



- 310. What are the peripheral operations for neuralgia of the fifth nerve?
- 311. What is the difference between neurotomy and neurectomy?
- 312. What are the deep operations for neuralgia of the fifth nerve?
- 313. What is the comparative value of deep operations as against deep injections of alcohol?

## CHAPTER XXXII

- 314. What are the congenital defects of the salivary glands?
- 315. Divide the diseases of the salivary glands.
- 316. Give the symptoms, complications and treatment of acute infection of the parotid gland.
- 317. Give the symptoms and treatment of suppuration of the salivary glands.
- 318. What are the causes of fistula of the salivary glands?
- 319. What is the treatment of external fistula of Stenson's duct?
- 320. What is salivary calculus?
- 321. In what ducts are salivary calculi usually found?
- 322. What is the treatment for salivary calculus of Wharton's duct?
- 323. Why is it best to open a salivary duct within the mouth?
- 324. What other conditions obstruct the salivary duct?
- 325. What is ranula?
- 326. What ducts are usually obstructed in ranula?
- 327. Give the treatment for ranula.
- 328. What conditions cause tumors of the salivary glands?

## CHAPTER XXXIII

- 329. Give a definition of ankylosis.
- 330. What joint, when ankylosed, is of the greatest importance to the dentist?
- 331. Classify the causes of disease of the temporo-mandibular joint.
- 332. Give the causes of temporary ankylosis.
- 333. How do impacted and erupting teeth cause ankylosis?
- 334. What is the treatment for temporary ankylosis?
- 335. What are the causes of permanent ankylosis?
- 336. Describe an operation for fibrous ankylosis.



- 337. Describe an operation for permanent ankylosis from destruction of the temporo-mandibular joint.
- 338. Describe a method of making section of the mandible.

## CHAPTER XXXIV

- 339. What is fracture?
- 340. Give the general varieties of fracture.
- 341. How do fractures occur through bones?
- 342. In what way are fragments displaced in fracture?
- 343. What are the causes of fracture?
- 344. What are the symptoms in fracture?
- 345. What are the three cardinal symptoms in fracture?
- 346. What are the complications of fracture?
- 347. How does repair occur after fracture?
- 348. Give the treatment of general fracture.

## CHAPTER XXXV

- 349. Why is fracture of the mandible a frequent accident?
- 350. Give the points of fracture of the mandible in order of frequency.
- 351. What are the causes of fracture of the mandible?
- 352. What are the symptoms of fracture of the mandible?
- 353. What are the complications of fracture of the mandible?
- 354. Why is fracture of the mandible usually compound?
- 355. Give six methods of treatment for fracture of the mandible.
- 356. How are wire splints applied in fracture of the mandible?
- 357. Describe Angle's method of treating fracture of the mandible.
- 358. Describe bone wiring and why it is resorted to.
- 359. What is an interdental splint and what is its value in the treatment of fracture of the mandible?
- 360. What is the value of external bandages and appliances and why are they not effective?

## CHAPTER XXXVI

- 361. What are the causes of fracture of the maxilla?
- 362. What are the usual lines of fracture of the maxilla?
- 363. In what way may fracture of the maxilla result from extractions?
- 364. What are the complications of fracture of the maxilla?



- 365. How would you treat a fracture of the maxilla with displacement of the fragment?
- 366. Describe the splint used to hold a fracture of the maxilla in position and tell how it is applied.
- 367. What are the usual causes of fracture of the nasal bone?
- 368. What are the complications of fracture of the nasal bone?
- 369. What is the treatment for fracture of the nasal bone?
- 370. Why is fracture of the malar bone of importance to the dentist?
- 371. What cavity is likely to be injured or infected in fracture of the malar bone?
- 372. How is depressed fracture replaced?
- 373. Why is fracture of the zygomatic arch of importance to the dentist?

#### CHAPTER XXXVII

- 374. What is dislocation?
- 375. Name the varieties of dislocation.
- 376. Name the structures entering into the formation of a joint.
- 377. What joints of the body are most frequently dislocated?
- 378. What are the causes of dislocation in general?
- 379. What are the symptoms of dislocation in general?
- 380. How is dislocation diagnosed?
- 381. What are the complications of dislocation?
- 382. What are the principal points in treating dislocation?
- 383. What are the forms of dislocation of the mandible?
- 384. What are the causes of dislocation of the mandible?
- 385. Give the anatomy and mechanism of a dislocated mandible.
- 386. What are the symptoms of a dislocated mandible?
- 387. How would you reduce a unilateral dislocation of the mandible?
- 388. How would you reduce a bilateral dislocation of the mandible?
- 389. What would be the practice in chronic dislocated mandibles where the jaw had assumed an almost normal position before examination?

#### CHAPTER XXXVIII

- 390. Describe the use of X-ray pictures to the dentist.
- 391. Describe the technique of taking X-ray pictures of teeth.



## INDEX







# INDEX

## A

- Abscess, 14.
- Absorption of bacteria, 104.
- Acheilia, 306.
- Acinous carcinoma, 282.
- Aene vulgaris, 161.
- Acquired affections of tongue, 149.
- Acquired deformities, 308.
- Acromegaly, 197.
- Actinomycosis, 26.
- Acute osteomyelitis, 173.
- Addison's disease, 140.
- Adenoids, 306.
- Adenoma, 241.
- Alcohol, effects of, on mouth, 103.  
injections of, 357.
- Alveolar abscess, 105.  
as cause of bone disease, 115.  
infective causes of, 113.  
mechanical causes of, 112.  
non-infective causes of, 112.  
operation for, 114.  
papilloma from, 118.  
pathology of, 114.  
treatment of, 116.  
X-ray of, 118.
- Alveolar necrosis, 180.
- Alveolar sarcoma, 276.
- Anesthesia, 170.
- Aneurism, 94.
- Angina, Ludwig's, 150.  
Vincent's, 141.
- Angina pectoris, 91.
- Angioma, 95, 245.
- Angle's method, 396.
- Ankyloglossia, 147.
- Ankylosis, cause of, 377.  
classification of, 376.  
fibrinous, 379.
- Ankylosis, osseous, 380, 388.  
permanent, 378.  
temporary, 377.  
treatment of, 379.
- Anthrax, 30.
- Antisepsis, 75.
- Antrum, acute infections of, 344.  
diseases of walls of, 338.  
classification of, 340.  
injuries as cause of, 343.  
neoplasms in, 345.  
operations for, 350.  
nasal route in, 351.  
oral route in, 350.  
teeth as cause of, 342.  
X-ray of, 340.  
empyema of, 345.  
suppuration of, 345.
- Aphthous stomatitis, 129.
- Apoplexy, 72.
- Arsenic necrosis, 188.
- Arteries, calcareous degeneration  
of, 93.  
coats of, 92.  
diseases of walls of, 92.  
fatty degeneration of, 93.
- Asepsis, 75.
- Asphyxia, 73.
- Astomia, 307.
- Atresia, 307.
- Atrophy, of face, 170.  
of teeth, 107.
- Auscultation, 85.

## B

- Bacteria, absorption of, 104.  
Black's study of, 104.  
composition of, 4.  
discovery of, 3.



- Bacteria, effects of, 5.  
     in dentition, 103.  
     Miller's study of, 104.  
     morphology of, 3.  
     Netter's study of, 104.  
     of mouth, 102, 123.  
     of osteomyelitis, 171.  
     of Vincent's angina, 142.  
     products of, 5.  
     reproduction of, 4.  
 Baldwin's operation, 325.  
 Bandaging, 66.  
     roller bandage, 67.  
     triangular bandage, 68.  
 Barber's itch, 165.  
 Barton's bandage, 403.  
 Bell's palsy, 110, 170.  
 Blastomycosis, 165.  
 "Bleeders," 107.  
 Bloodclot organization, 176.  
 "Boil," 166.  
 Bones, cysts of, 273.  
     diseases of, classification of, 171.  
     iodin in, 175.  
     repair in, 176.  
     fractures of, 391.  
     intermaxillary, 301.  
     malar fracture of, 415.  
     nasal fracture of, 413.  
     regeneration of, 199.  
     wiring of, 397.  
 Brain, compression of, 63.  
     concussion of, 63.  
     injuries to, 62.  
 Brophy's operation, 324.  
 Burns, 60.  
     treatment of, 61.

## C

- Calcareous degeneration, 93.  
 Calculus, salivary, 368.  
 Callus, 391.  
 Cancerum oris, 130.  
 Canker sores, 125.  
 Carbuncle, 167.

- Carcinoma, 279.  
     acinous, 282.  
     tubular, 282.  
 Case history, 80.  
 Catarrhal stomatitis, 124.  
 Cellulitis, 16.  
 Cementous odontomata, 251.  
 Chancre, of lip, 222.  
     of mouth, 222.  
     of tongue, 223.  
     of tonsil, 222.  
 Chaneroid, 37.  
     primary lesion of, 40.  
 Chemical necrosis, arsenic, 188.  
     mercury, 187.  
     phosphorus, 186.  
 Chloroma, 269.  
 Chronic osteomyelitis, 174.  
 Circumscribed osteomyelitis, 174.  
 Cleft, of face, 305.  
     of palate, 236, 316.  
 Cleft palate, causes of failure to  
     unite in, 319.  
     etiology of, 316.  
     history of, 316.  
     operations for, anesthetics in, 317.  
     Baldwin's, 325.  
     Brophy's, 324.  
     Ferguson's, 329.  
     instruments in, 321.  
     Lanelongue's, 330.  
     Roe's, 328.  
     sutures in, 325, 332.  
     time of, 317.  
     varieties of, 322.  
     statistics of, 305.  
     varieties of, 316.  
 Coating of tongue, 146.  
 Colles' law, 39.  
 Coloboma, 307.  
 Coma, 72.  
 Comedo, 161.  
 Composite odontomata, 254.  
 Compression, 63.  
 Concretions, 367.  
     in Wharton's duct, 369.  
 Concussion, 63.



- Congenital defects, absence of  
     salivary glands, 364.  
     of face, 147.  
     of tongue, 147.  
 Congestion, 10.  
 Contusions, 54.  
     of face, 168.  
 Convulsions, 74.  
 Cryer's section of face, 335.  
 Cystic tumors, 242.  
 Cysts, dentigerous, 250.  
     dermoid, 244.  
     echinococcus, 244.  
     from developed teeth, 297.  
     from erupting teeth, 294.  
     muciparous, 243.  
     multiple, 256.  
     of bone, 273.  
     of glands of Nuhn, 243.  
     sebaceous, 163.

## D

- Deafness, 110.  
 Defects, congenital, 147.  
     of face, 305.  
     of tongue, 147.  
 Deformities, acquired, 308.  
 Degeneration, 8.  
 Dementia precox, 109.  
 Dentigerous cysts, 250.  
 Dentition, bacteria in, 103.  
     digestive disturbances of, 102.  
     neuroses of, 102.  
     skin lesions in, 103.  
 Dermatitis, 161.  
 Dermoid cysts, 244.  
 Development of face, 300.  
     of mouth, 300.  
 Developmental tumors, 248.  
 Diagnosis, general, 80.  
     medical, 83.  
     physical, 84.  
 Differential table, 134.  
 Diffused osteomyelitis, 173.  
 Diphtheria, 137.  
     mouth lesions in, 134.

- Diseases of bones, classification of,  
     171.  
     iodin in, 175.  
     repair in, 176.  
 Dislocations, 418.  
     of mandible, 422.  
     anatomy of, 423.  
     reduction of, 424.  
 Ducts, concretions in, 369.  
     fistula of, 366.  
     Stenson's, 166.  
     Wharton's, 369.

## E

- Echinococcus cysts, 244.  
 Ectropian, 307.  
 Eczema of mouth, 138.  
 Embryology, 300.  
 Empyema of antrum, 345.  
 Endocarditis, 90.  
 Endothelioma, 246.  
 Entropian, 307.  
 Epilepsy, 73.  
 Epithelial odontomata, 250.  
 Epithelioma, 271.  
     of mouth, 283.  
     of tongue, 157.  
 Epulis, 264.  
     fibroid, 266.  
     myeloid, 267.  
 Eruption of teeth, 102.  
     cysts from, 298.  
 Erysipelas, 23.  
 Erythema, 139.  
     of face, 160.  
     of fauces, 224.  
 Etiology, 82.  
 Exanthematous necrosis, 192.  
 Exostosis, 271.  
     cause of, 118.  
 Extraction, 106.  
     fracture from, 410.  
     hemorrhage from, 107.  
 Exudation, 8.



## F

- Face, atrophy of, 170.  
 clefts of, 305.  
 contusions of, 168.  
 Cryer's section of, 335.  
 dermatitis of, 161.  
 development of, 300.  
 erythema of, 160.  
 hypertrophy of, 170.  
 Lathrop's section of, 337.  
 macula of, 160.  
 neurosis of, 169.  
 papule of, 160.  
 petechia of, 160.  
 pustule of, 161.  
 spasms of, 170.  
 vesicle of, 161.  
 wounds of, 167.  
 Fatty degeneration, 93.  
 Ferguson's operation, 329.  
 Ferments, 4.  
 Fibrinous ankylosis, 379.  
 Fibroid epulis, 264.  
 Fibroma, 240.  
 Fifth nerve, neuralgia of, 353.  
 Fistula, 14.  
   naso-antral, 121.  
   naso-oral, 120.  
   of ducts, 366.  
 Fluorescence, 5.  
 Follicular odontomata, 250.  
 Follicular tonsillitis, 135.  
 Foreign bodies, in the ear, 64.  
   in the eye, 63.  
   in the larynx, 64.  
   in the nose, 64.  
   in the stomach, 65.  
   in the throat, 64.  
 Fracture, bone wiring in, 397.  
   callus in, 391.  
   from extraction, 410.  
   obstetric, 404.  
   of alveolar process, 404.  
   of malar bone, 415.  
   of mandible, 393.  
   of maxilla, 408.

- Fracture, of nasal bones, 413.  
   of zygomatic arch, 417.  
   repair of bone in, 391.  
   splints for, 397.  
   varieties of, 389.  
 Frankel's pneumococcus, 104.  
 Fulminating ecthyma, 139.  
 Furuncle, 166.

## G

- Gag for mouth, 318.  
 Gangrene, 12.  
 Gangrenous stomatitis, 131.  
 Germicides, 76.  
 Giant-celled sarcoma, 275.  
 Gingivitis, syphilitic, 239.  
   ulcerative, 230.  
 Glands, concretions in, 367.  
   fistula of ducts of, 366.  
   of Nuhn, 243, 371.  
   salivary, 364.  
   sarcoma of, 374.  
   sebaceous, 161.  
 Glossitis, 149.  
   sclerosing, 229.  
 Goiter, lingual, 155.  
 Gonorrhea, 35.  
   complications of, 36.  
   treatment of, 36.  
 Gumma, 44.  
   of tonsil, 228.  
   syphilitic, 227.  
 Gunshot wounds, 58.

## H

- Hare lip, bilateral, 313.  
   complete, 314.  
   dressings for, 315.  
   incomplete, 313.  
   operations for, 310.  
     Malgaigne's, 311.  
     Mirault-Langenbeck's, 312.  
     Nélaton's, 311.  
   statistics of, 305.



Hare lip, unilateral, 313.  
     varieties of, 310.  
 Heart, dilatation of, 91.  
     diseases of, 88.  
     hypertrophy of, 90.  
     murmurs of, 88.  
     sounds of, 88.  
     valves of, 89.  
 Hemangioma, 245.  
 Hemorrhage, 58, 107.  
     external, 59.  
     internal, 59.  
 Hereditary syphilis, 234.  
 Herpes, 123, 128.  
 Herpes zoster, 139.  
 Herpetie stomatitis, 128.  
 Horns of nails and skin, 163.  
 Hunterian chancre, 41.  
 Hutchinson's teeth, 106.  
 Hydrogen dioxide, 77.  
 Hydrophobia, 29.  
 Hygiene, oral, 103.  
 Hyperemia, 10.  
 Hyperesthesia, 170.  
 Hyperostosis, 271.  
 Hypertrophy, alveolar, 263.  
     of face, 170.  
     of gum, 265.  
     of tongue, 148.  
 Hysterical occlusion, 388.

I

Immunity, 6.  
 Impacted teeth, 288.  
 Impetigo contagiosa, 139.  
 Incised wounds, 55.  
 Infections, acute antral, 344.  
     as cause of alveolar abscess, 113.  
 Inflammation, of tongue, 149.  
     of tonsil, 137.  
     phenomena of, 7.  
     results of, 11.  
     symptoms of, 7.  
     varieties of, 9.  
     vascular changes in, 7.  
 Initial lesion, 220.

    Injections for neuralgia, 357.  
     Injuries, as cause of antral diseases,  
         343.  
         of tongue, 154.  
 Inspection, 84.  
 Instruments, 321.  
 Interdental splints, 401.  
 Intermaxillary bone, 301.  
 Iodin, in bone diseases, 175.  
     in surgery, 76.  
     mouth lesions from, 135.

## J

Jacob's ulcer, 281.

## K

Koplik's spots, 136.

## L

Lacerations, 55.  
 Lanelongue's operation, 330.  
 Lathrop's section of face, 337.  
 Lead poisoning, 134.  
 Leontiasis ossea, 197.  
 Leprosy, 140.  
 Leucoplakia, 152.  
 Lichenization, 140.  
 Ligatures, 78.  
 Lingual goiter, 155.  
 Lip, chancre of, 222.  
     double, 308.  
 Lipoma, 241.  
 Ludwig's angina, 150.  
 Lupus erythematosus, 140.  
 Lupus exedens, 281.  
 Lupus vulgaris, 210.  
 Lymphangioma, 97, 245.  
 Lymphatics, diseases of, 96.

## M

Macrocheilia, 307.  
 Macroglossia, 246.  
 Macula, 160.  
 Malar fracture, 415.  
 Malignant tumors, 275.



- Mandible, diseases of, 179.  
   dislocations of, 422.  
   fracture of, 393.  
     causes of, 393.  
     location of, 393.  
     repair of, 395.  
   multiple cysts of, 256.  
   necrosis of, 171.  
   osteomyelitis of, 182.  
   periostitis of, 181.  
   tuberculosis of, 196.  
 Mania, 109.  
 Maxilla, diseases of, 193.  
   complications in, 194.  
   fracture of, 408.  
   sinus of, 334.  
   suppuration of, 193.  
   tabes of, 196.  
   tuberculosis of, 196.  
 Measles, mouth lesions in, 134.  
 Melanotic sarcoma, 276.  
 Mensuration, 84.  
 Mercurial necrosis, 107.  
 Mercurial poisoning, 134.  
 Metallic splints, 397.  
 Microcheilia, 307.  
 Microstoma, 307.  
 Miliun, 163.  
 Miller's study of bacteria, 104.  
 Mitral regurgitation, 89.  
 Mitral stenosis, 90.  
 Mouth, bacteria of, 103, 123.  
   chancre of, 222.  
   complex structure of, 101.  
   development of, 300.  
   eczema of, 138.  
   effect of alcohol on, 103.  
   effect of tobacco on, 103.  
   epithelioma of, 284.  
   fulminating ecchyma, 139.  
   impetigo contagiosa, 139.  
   leprosy of, 140.  
   leucoplakia of, 152.  
   mucous membrane of, 101.  
   pemphigus of, 139.  
   perlèche, 140.  
   psoriasis, 140.  
 Mouth, sarcoma of, 278.  
   scorbutic lesions of, 103.  
   skin lesions of, 123.  
   syphilis of, 219.  
   tuberculosis of, 213.  
   urticaria of, 139.  
 Mouth gag, 318.  
 Mouth lesions, differential table of, 134.  
   eczema, 136.  
   from iodine, 175.  
   from lead, 134.  
   from skin diseases, 136.  
   herpes zoster, 139.  
   impetigo contagiosa, 138.  
   in diphtheria, 133.  
   in measles, 133.  
   in rickets, 103.  
   in scarlatina, 133.  
   in typhoid fever, 133.  
   leprosy, 140.  
   lichenization, 140.  
   lupus erythematosus, 140.  
   of skin, 138.  
   pemphigus, 139.  
   perlèche, 140.  
   pigmentation, 140.  
   psoriasis, 140.  
   rhinoscleroma, 140.  
   scorbutus, 103.  
   seborrhea, 140.  
   symptomatic, 133.  
   Vincent's angina, 141.  
 Mouth operations, 205.  
 Mouth retractor, 208.  
 Muciparous cysts, 243.  
 Mucous patches, 223.  
 Multiple cysts, 256.  
 Muscles of soft palate, 304.  
 Muscular spasms, 109.  
 Mycosic stomatitis, 129.  
 Myeloid epulis, 267.
- N
- Nasal fracture, 413.  
 Nasal route, 351.



- Naso-antral fistula, 121.  
 Naso-oral fistula, 120.  
 Necrosis, 11.  
   alveolar, 180.  
   chemical, 186.  
     arsenic, 188.  
     mercury, 187.  
     phosphorus, 186.  
   exanthematous, 192.  
   of mandible, 171.  
   of maxilla, 193.  
   papilla from, 203.  
   varieties of, 12.  
 Neoplasms, 345.  
 Netter's study of bacteria, 104.  
 Neuralgia, from reflex neurosis, 108.  
   of fifth nerve, 353.  
   prognosis of, 356.  
   *tic douloureux*, 356.  
   treatment of, avulsion, 360.  
     injections, 356.  
     medical, 353.  
     neurectomy, 362.  
     neurotomy, 362.  
     operations, 359.  
 Neurasthenia, 109.  
 Neurectomy, 362.  
 Neuroma, 242.  
 Neurosis, 108.  
   of dentition, 102.  
   of face, 169.  
 Neurotomy, 362.  
 Noguchi reaction, 38, 53.  
 Non-specific infections, 16.  
 Nuhn, glands of, 371.  
   cysts of, 243.
- O
- Obstetric fracture, 404.  
 Obstruction of ducts, 370.  
 Occlusion, hysterical, 388.  
 Odontomata, 249.  
   cementous, 251.  
   composite, 254.  
   epithelial, 250.  
   Odontomata, follicular, 250.  
     radicular, 254.  
 Operations, for alveolar abscess, 117.  
   for ankylosis, 379.  
   for antral disease, 350.  
   for cleft alveolus, 323.  
   for cleft palate, 316.  
     anesthetics for, 317.  
     Baldwin's, 325.  
     Brophy's, 324.  
     Ferguson's, 329.  
     instruments for, 321.  
     Lanelongue's, 330.  
     Roe's, 328.  
     sutures for, 325, 332.  
     time of, 316.  
   for dislocations, 423.  
   for fracture, 392.  
     of malar bone, 415.  
     of mandible, 395.  
     of maxilla, 409.  
     of nasal bones, 413.  
     of zygomatic arch, 417.  
   for hare lip, bilateral, 313.  
     dressings for, 315.  
     Malgaigne's, 311.  
     Mirault-Langenbeck's, 312.  
     Nélaton's, 311.  
     sutures for, 315.  
     unilateral, 313.  
   for neuralgia, 359.  
   for osteomyelitis, 183.  
   for ranula, 371.  
   of mouth, 205.  
     retractor for, 208.  
     technique of, 205.  
 Oral hygiene, 103.  
 Oral route, 350.  
 Osseous ankylosis, 380.  
 Osteoma, 271.  
 Osteomyelitis, acute, 173.  
   bacterium of, 171.  
   chronic, 174.  
   circumscribed, 173.  
   differential symptoms of, 174.  
   diffused, 173.



- Osteomyelitis, of mandible, 182.
- of maxilla, 193.
- Osteophytes, 271.

## P

- Palpation, 84.
- Papilla, 203.
- Papilloma, 118.
- of alveolus, 258.
- sinus of, 118.
- Papular acne, 161.
- Papule, 160.
- Paralysis of muscles, 170.
- Parasites of skin, 164.
- Patches, mucous, 223.
- Pathology, 82.
- Pemphigus, 139.
- Percussion, 84.
- Periadenitis, 215.
- Pericarditis, 90.
- Periostitis, acute suppurative, 177.
- classification of, 177.
- diffused, 50.
- of mandible, 181.
- pathology of, 178.
- post-febrile, 178.
- suppurative, 53.
- treatment of, 178.
- Perlèche, 140.
- Permanent ankylosis, 378.
- Petechia, 160.
- Phenol, 76.
- Phlebitis, 93.
- Phosphorus necrosis, 186.
- Pigmentation, 140.
- Pigments, 5.
- Pilocarpin, 134.
- Pneumococcus of Frankel, 104.
- Poisoned wounds, 57.
- Poisoning, by arsenic, 112, 188.
- by iodine, 136.
- by lead, 134.
- by mercury, 134.
- by phosphorus, 186.
- by pilocarpin, 134.

- Polypus of alveolus, 260.
- of gum, 263.
- Post-febrile periostitis, 178.
- Premaxillary bone, 301.
- Primary lesion, 40.
- Prognosis, 82.
- Proliferation, 8.
- Proteins, 4.
- Psoriasis, 140.
- Pulse, 91.
- Pus, 13.
- Pustule, 161.
- Pyemia, 20.
- Pyorrhea, 103.
- syphilitic, 230.

## R

- Radicular odontomata, 254.
- Ranula, 371.
- Reactions, Noguchi, 38, 53.
- Wassermann, 39, 53.
- Reflex neurosis, 108.
- muscular spasms from, 109.
- neuralgia from, 110.
- Regeneration of bone, 199.
- Regurgitation, 89.
- Repair of bone, in dislocation, 176.
- in fracture, 391.
- Retractor for mouth, 208.
- Rhinoscleroma, 140.
- Rickets, 103.
- Ringworm, 165.
- Risus sardonius, 170.
- Rodent's ulcer, 281.
- Roe's operation, 328.
- Rose position, 320.
- Round-celled sarcoma, 275.

## S

- Salivary calculus, 368.
- Salivary glands, acute affections of, 368.
- congenital absence of, 364.
- diseases of, 364.
- obstruction of ducts of, 370.



- Salivary glands, sarcoma of, 374.  
 suppuration of, 365.  
 tuberculosis of, 375.
- Sapremia, 17.
- Sarcoma, alveolar, 276.  
 giant-celled, 275.  
 melanotic, 276.  
 of mouth, 278.  
 of salivary glands, 374.  
 round-celled, 275.  
 spindle-celled, 275.  
 treatment of, 279.
- Scabies, 165.
- Scalds, 60.  
 treatment of, 61.
- Scarlet fever, mouth lesions in, 134.
- Sclerosing glossitis, 229.
- Scorbutus, 103.
- Serofuloderma, 209.
- Sebaceous cysts, 163.
- Sebaceous glands, 161.
- Seborrhea, 140.
- Secondary lesion, 223.
- Section of face, Cryer's, 335.  
 Lathrop's, 337.
- Self-infection, 104.
- Sepsis, 75.
- Septicemia, 18.
- Sequestrum, 172.
- Shock, 70.  
 symptoms of, 71.  
 treatment of, 71.
- Shriver's statistics, 104.
- Sinus, 14.  
 of maxilla, 334.  
 papilloma with, 118.
- Skin eruptions, 83.
- Skin horns, 163.
- Skin lesions, in dentition, 103.  
 of mouth, 138.
- Skin parasites, 164.
- Soft palate muscles, 304.
- Spasms, facial, 170.  
 muscular, 109.
- Specific infections, 23.
- Spindle-celled sarcoma, 275.
- Spirochæta pallida, 38.
- Splints, interdental, 401.  
 metallic, 397.  
 wire, 395.
- Staphylococcus, 6.
- Staphyloplasty, 319.
- Stenosis of heart, 90.
- Stenson's duct, 166.  
 fistula of, 167.
- Stomatitis, aphthous, 129.  
 cancrum oris, 131.  
 canker sores, 125.  
 catarrhal, 124.  
 classification of, 124.  
 follicular, 128.  
 gangrenous, 131.  
 gonorrheal, 135.  
 herpetic, 128.  
 mercurial, 134.  
 mycotic, 129.  
 ulcerative, 125.
- Strawberry tongue, 137.
- Streptococcus, 7.
- Suppuration, 13.  
 of antrum, 345.  
 of maxilla, 193.  
 of salivary glands, 365.
- Surgical dressings, 77.
- Sutures, 78.  
 in cleft palate, 325, 332.  
 in hare lip, 315.
- Sycosis, 165.
- Symptoms, 82.
- Syphilides, forms of, 43.
- Syphilis, bone diseases of, 47.  
 cleft palate from, 232.  
 diagnosis of chancre in, 42.  
 diffused periostitis, 50.  
 forms of, 43.  
 general treatment of, 51.  
 gingivitis, 239.  
 gummata, 228.  
 hereditary, 234.  
 inherited, 47.  
 modes of contagion of, 39.  
 of bones, 231.  
 of mouth, 219.  
 forms of, 220.



Syphilis, of mouth, initial lesion of, 220.

secondary lesion of, 223.

tertiary lesion of, 227.

of soft tissues, 234.

of tongue, 227.

primary lesion of, 40.

prognosis of, 51.

pyorrhea, 230.

sclerosing glossitis, 230.

secondary symptoms of, 43.

"606" (Salvarsan) in, 53.

stages of, 39.

suppurative periostitis, 53.

tertiary, 44.

## T

Tabes dorsalis, 196.

Technique, in operations, 205.

in X-ray, 425.

Teeth, as cause of antral disease, 342.

atrophy of, 107.

cysts from developed, 297.

cysts from erupting, 298.

eruption of, 102.

Hutchinson's, 106.

impaction of, 288.

reflex neuroses from, 108.

tumors of, 248.

Temporary ankylosis, 377.

Tertiary lesions, 44, 227.

Tetanus, 28.

Thrush, 124.

Tie douloureux, 353.

Tinea sycosis, 165.

Tinea trichophytina, 165.

Tobacco, effect of, 103.

Tongue, 83.

acquired affections of, 149.

appearance of, 146.

chancre of, 223.

coatings on, 146.

congenital defects of, 147.

epithelioma of, 157.

hypertrophy of, 148.

Tongue, inflammation of, 149.

injuries of, 154.

leucoplakia of, 152.

Ludwig's angina, 150.

strawberry tongue, 137.

syphilis of, 227.

tongue tie, 147.

tuberculosis of, 214.

tumors of, 156.

Tongue tie, 147.

Tonsil, chancre of, 222.

enlarged, 307.

gumma of, 228.

inflammation of, 137.

Tonsillitis, 137.

follicular, 135.

Toxins, 5.

Traumatism in necrosis, 181.

Trichophytina, 165.

Tuberculosis, in general, etiology of, 32.

pathology of, 33.

treatment of, 34.

of face, 209.

of facial bones, 196, 217.

of jaw, 209.

of maxilla, 196.

of mouth, 209.

of salivary glands, 375.

of tongue, 214.

recurring ulcer of, 213.

Tuberculosis cutis, 209.

Tubular carcinoma, 282.

Tumors, adenoma, 241.

carcinoma, 279.

cystic, 242.

developmental, 248.

endothelioma, 246.

epithelial, 281.

fibroma, 240.

hemangioma, 245.

in general, 238.

lipoma, 241.

lymphangioma, 245.

macroglossia, 246.

malignant, 275.

neuroma, 242.



Tumors, odontomata, 249.  
 of teeth, 248.  
 of tongue, 156.  
 papilloma, 258.  
 polypus, 260.  
 sarcoma, 275.  
 vascular, 245.

U

Ulcer, 14.  
 Jacob's, 281.  
 rodent, 281.  
 Ulcerating gingivitis, 230.  
 Ulcerative stomatitis, 125.  
 Uranoplasty, 319.  
 Urticaria, 139.

V

Vascular tumors, 245.  
 Verruca, 163.  
 Vesicle, 161.  
 Vincent's angina, 141.

W

Warts, 163.  
 Wassermann reaction, 39, 53.  
 Wharton's duct, concretions in, 369.  
 Wire splints, 395.  
 Wiring of bones, 397.  
 Wounds, 54.

contusions, 54.  
 gunshot, 58.  
 incised, 55.  
 lacerations, 55.  
 of face, 167.  
 poisoned, 57.  
 punctured, 56.

X

X-ray, 425.

Z

Zygomatic arch, 417.
































COLUMBIA UNIVERSITY LIBRARIES (hsl.stx)

**RD 523 M13 C.1**

Oral surgery; a text-book on general sur



2002099977

